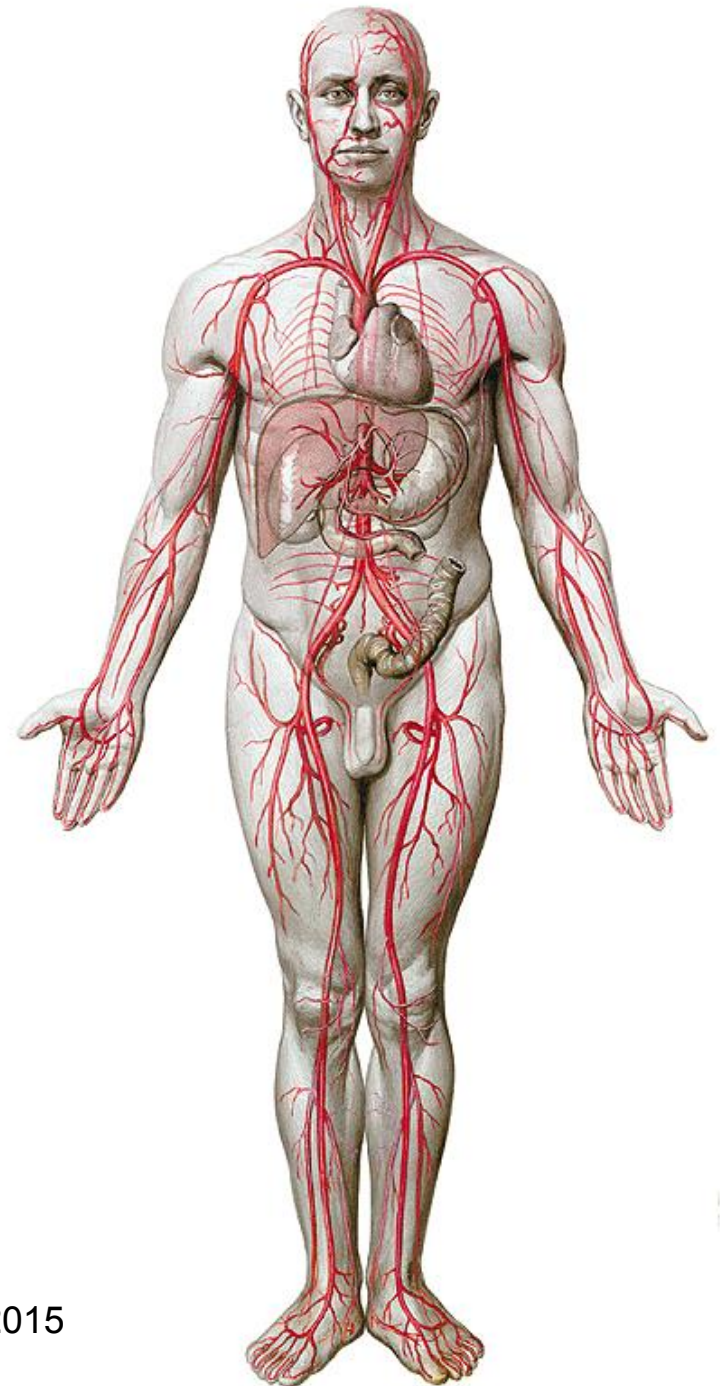


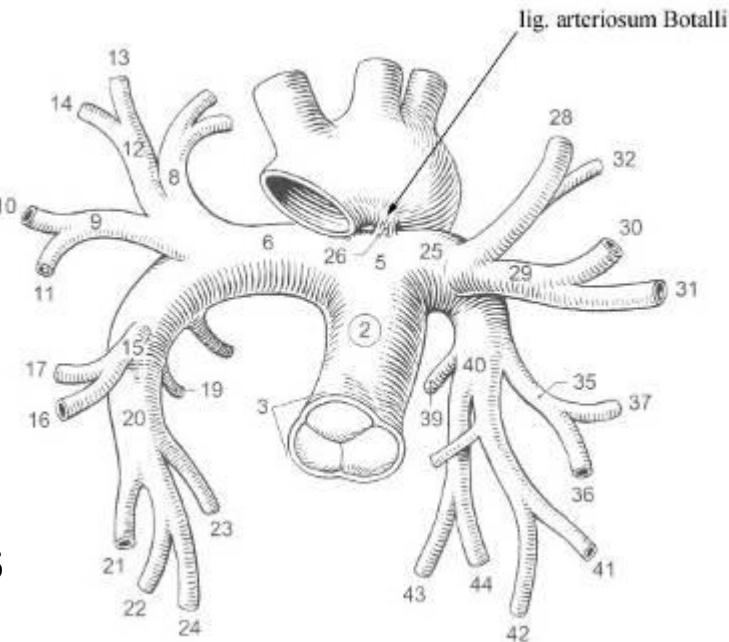
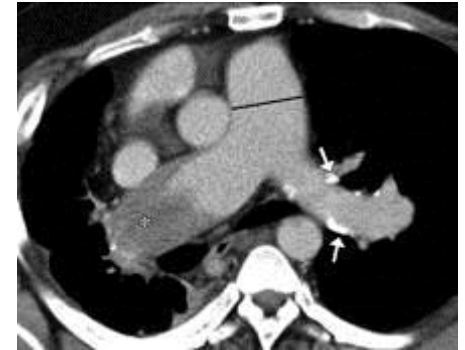Arterial system

Systema arteriarum

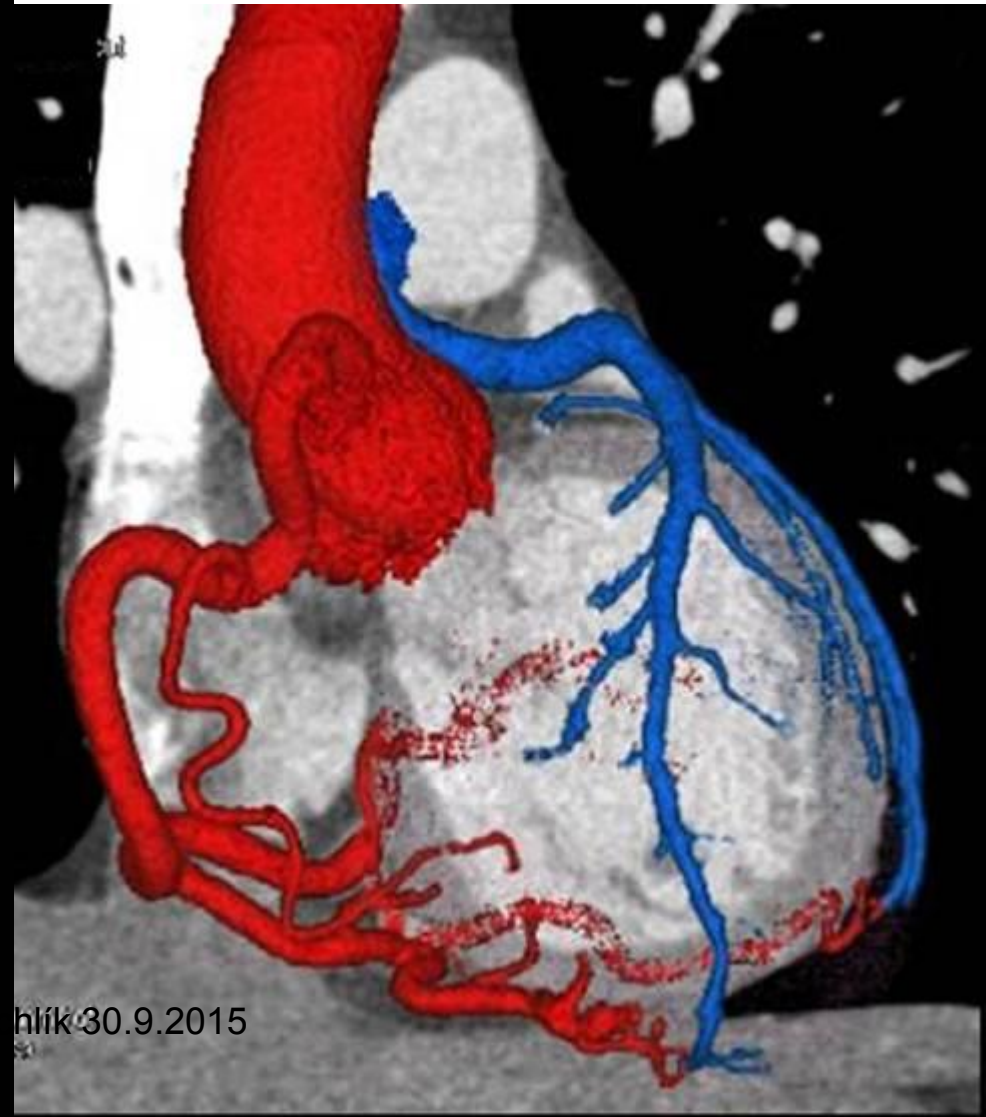
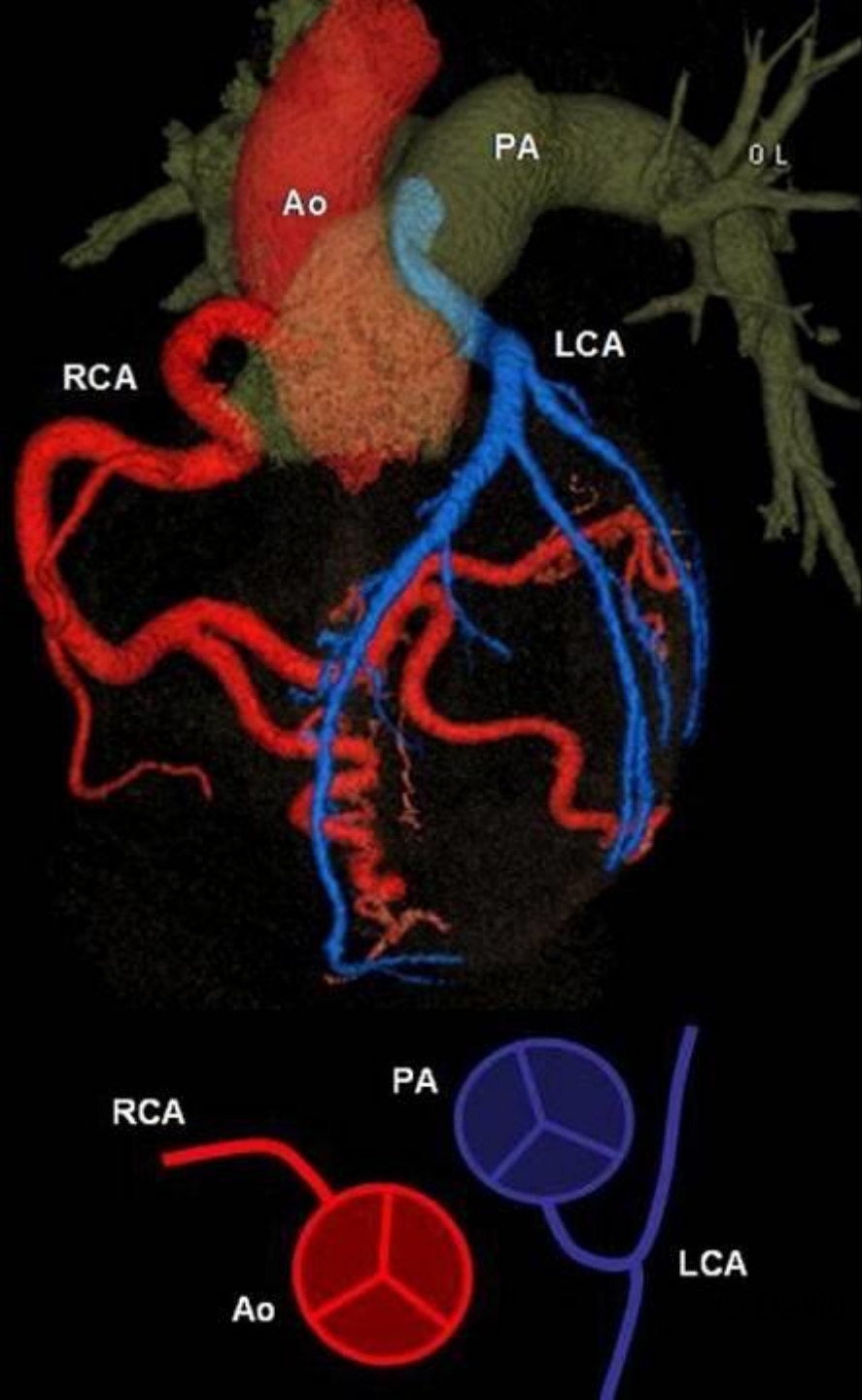


Truncus pulmonalis = pulmonary trunk

- sinus trunci pulmonalis (dx., sin., ant.)
- crista supravulvularis
- bifurcatio trunci pulmonalis
 - arteria pulmonalis dx. + sin.
- lig. arteriosum (Botalli)
- *functional lung circulation*
- *pulmonary capillary wedge pressure (PCW)*
- *lung embolia*



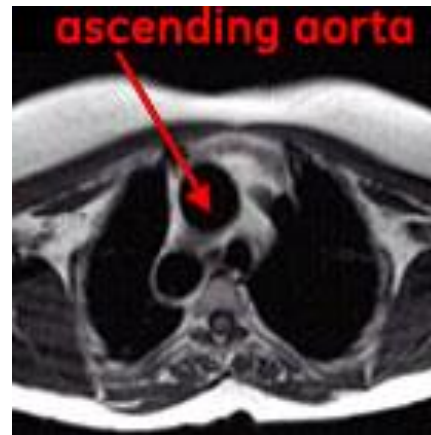
ACS from TP



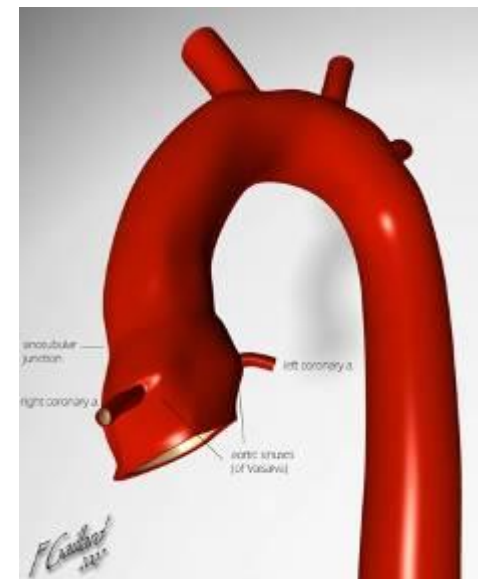
hlík 30.9.2015

Aorta ascendens; Pars ascendens aortae = Ascending aorta

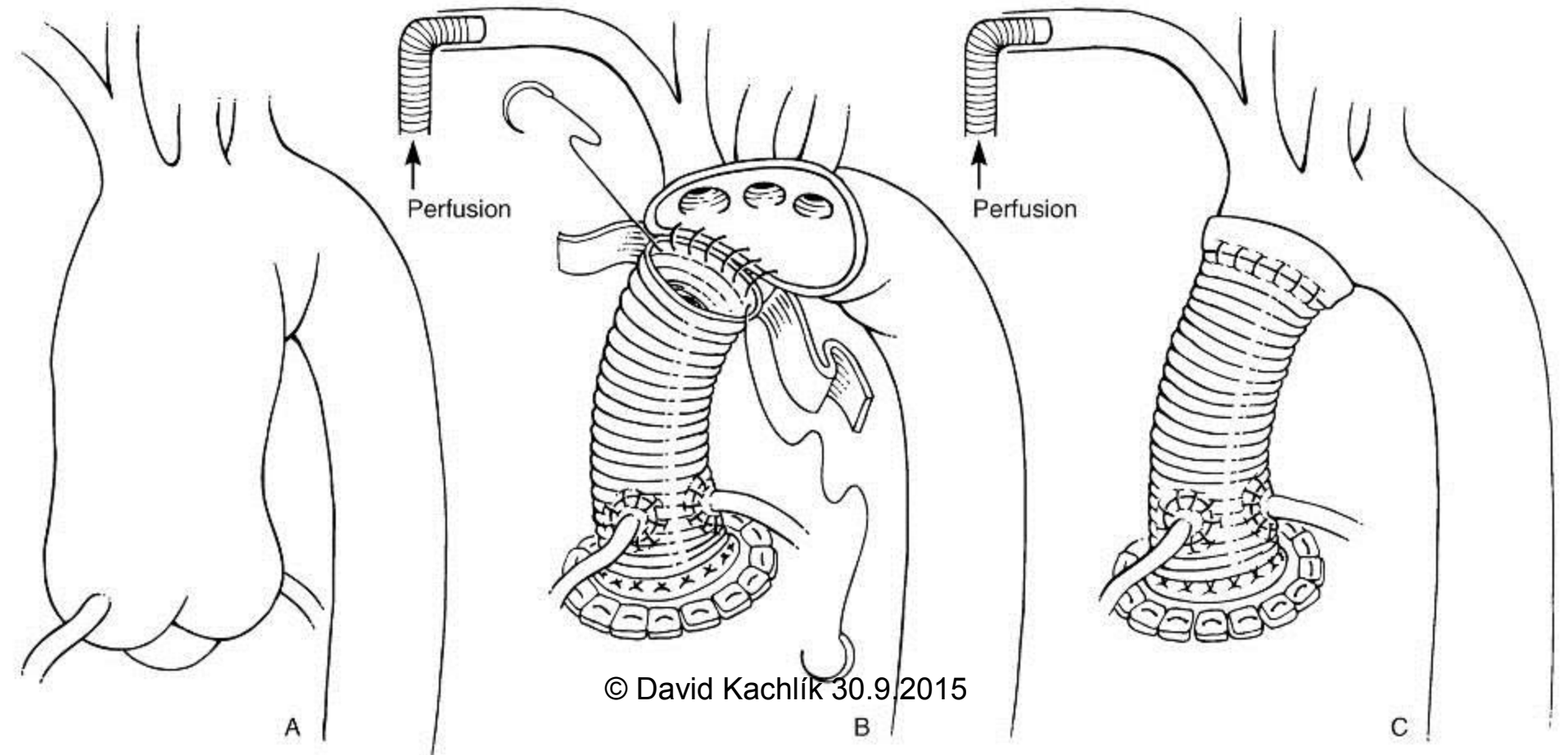
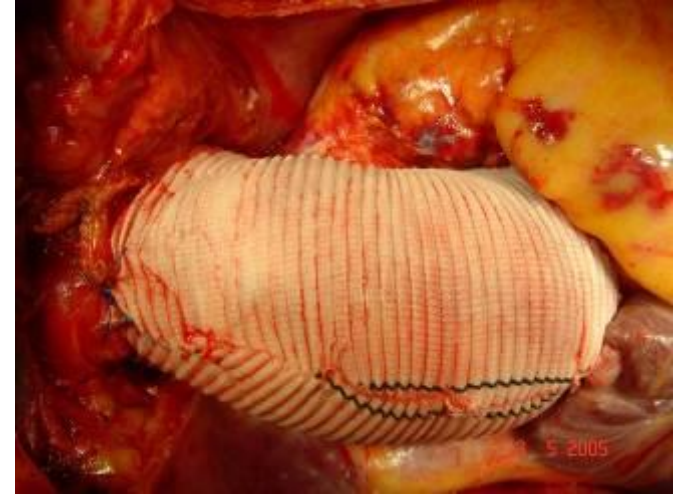
- sinus aortae Valsalvae (dx., sin., ant.)
 - arteria coronaria dx. + sin.
- crista supravulvularis
- bulbus aortae
- aneurysms



© David Kachlik 30.9.2015



Aneurysma aortae ascendentis *surgical solution*



© David Kachlík 30.9.2015

Arcus aortae

left-sided (right-sided in birds)

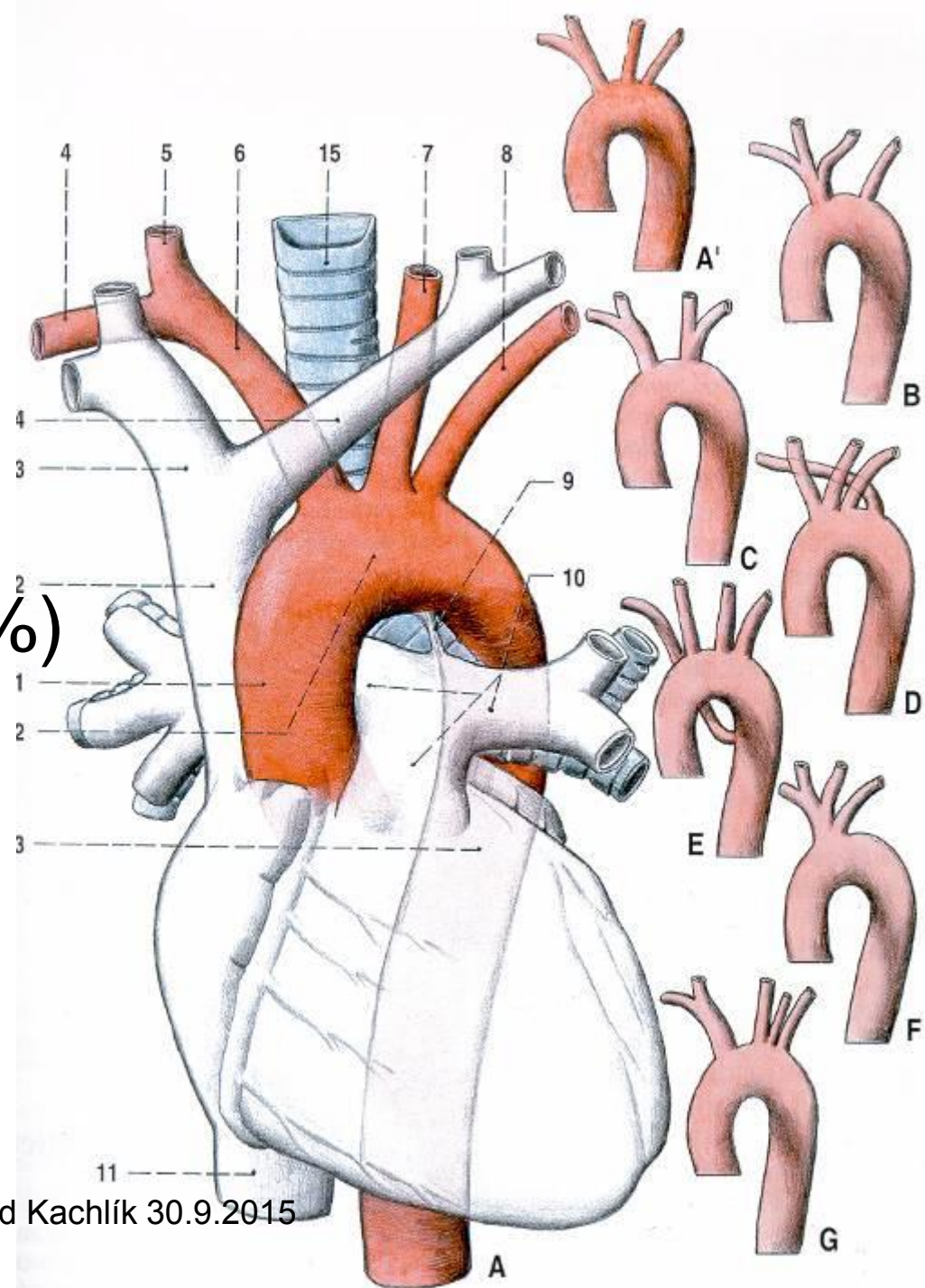
- truncus brachiocephalicus
 - a. subclavia dx.
 - a. carotis communis dx.
- a. carotis communis sin.
- a. subclavia sin.
- isthmus aortae
 - lig. arteriosum *Botalli*

glomera aortica (*chemoreceptors*)

topography: superior mediastinum, veins ventrally,
trachea and oesophagus dorsally

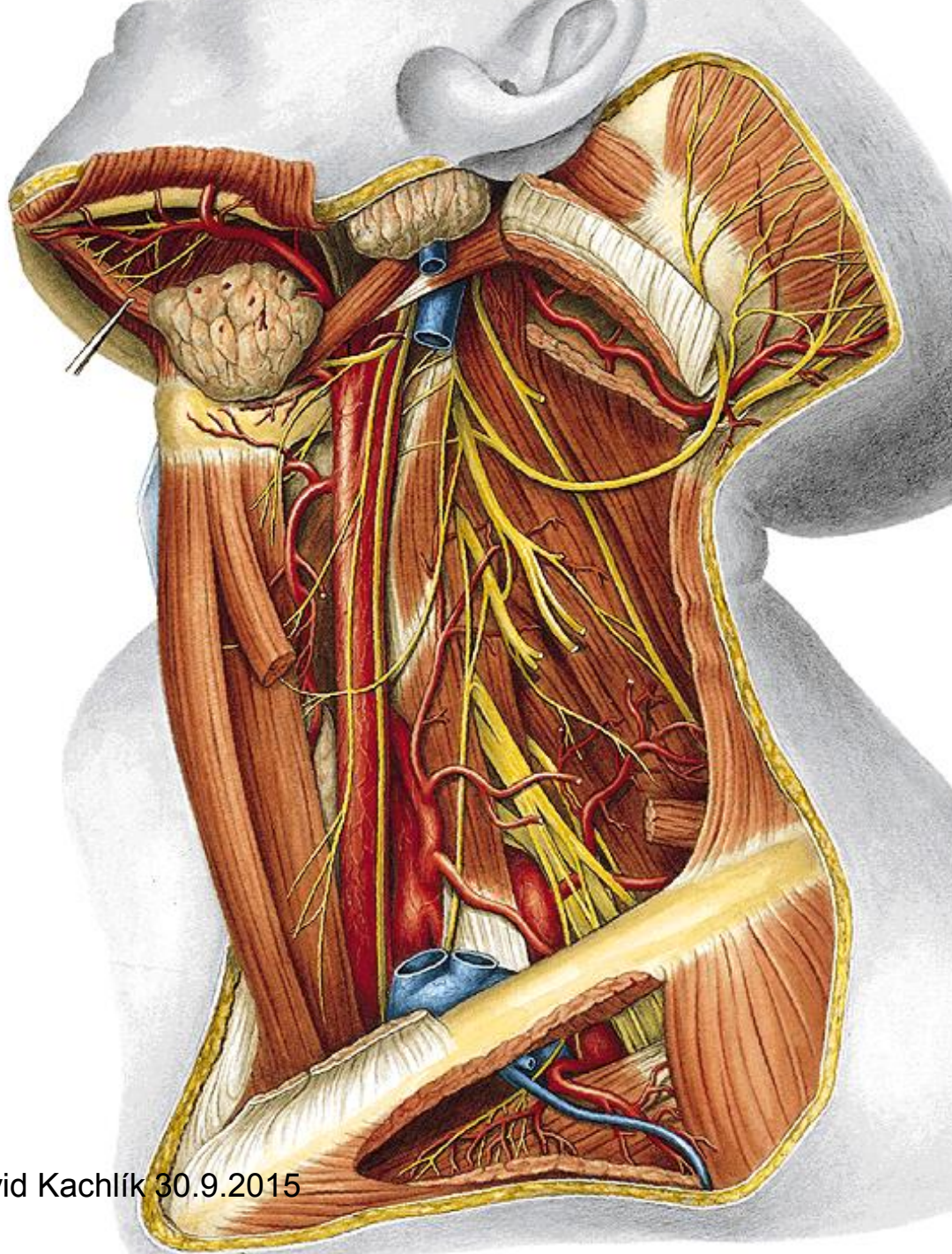
Branching variants of arcus aortae

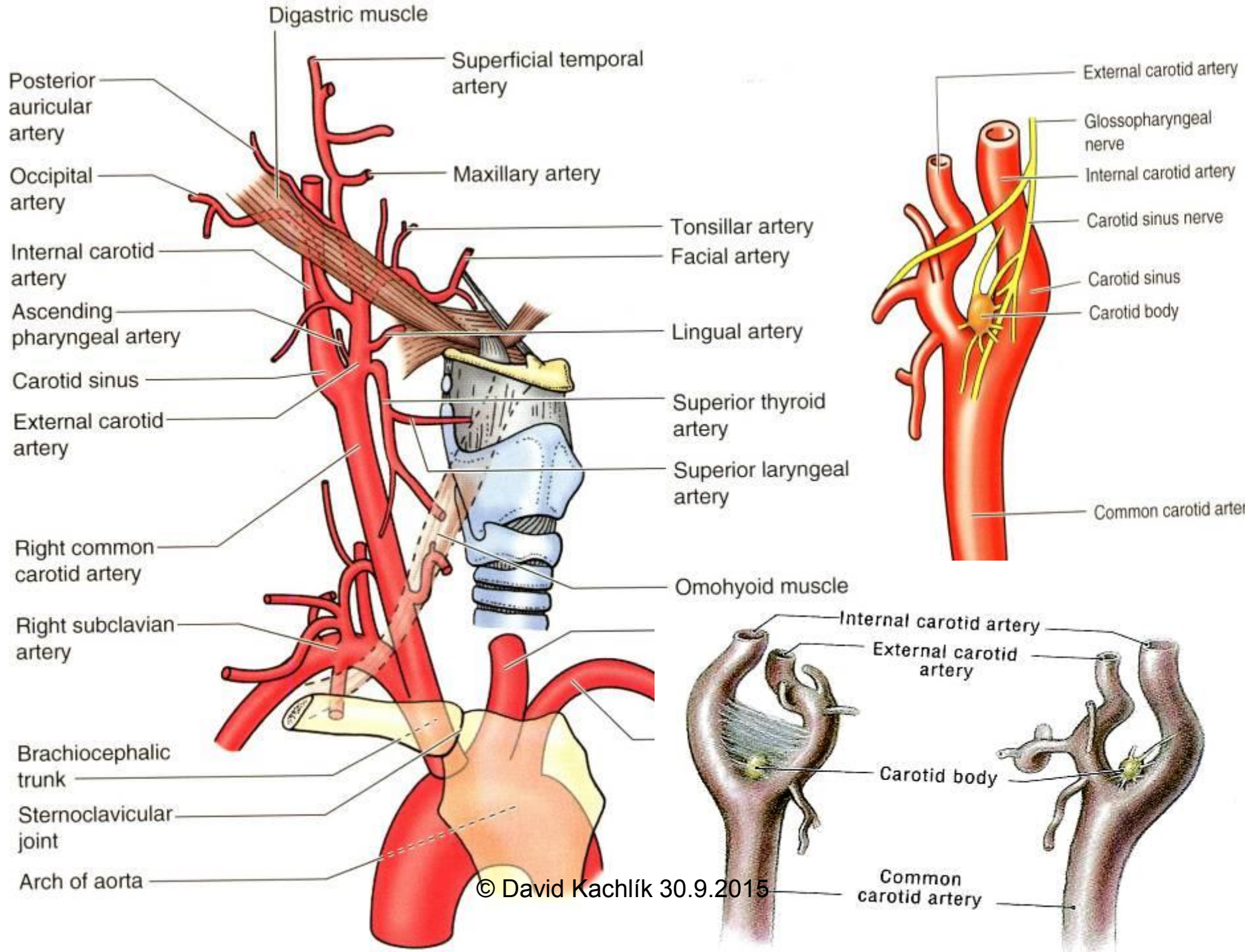
- a. thyroidea ima (2 %)
- a. vertebralis (3 %)
- a. lusoria (1,5 %)



A. carotis communis

- glomus caroticum (*chemoreceptor*)
- tuberculum caroticum (C6) Chassaignaci
- vagina carotica
- spatium parapharyngeum
- trigonum caroticum + omotracheale
- bifurcatio carotidis – C4
 - a. carotis interna
 - a. carotis externa



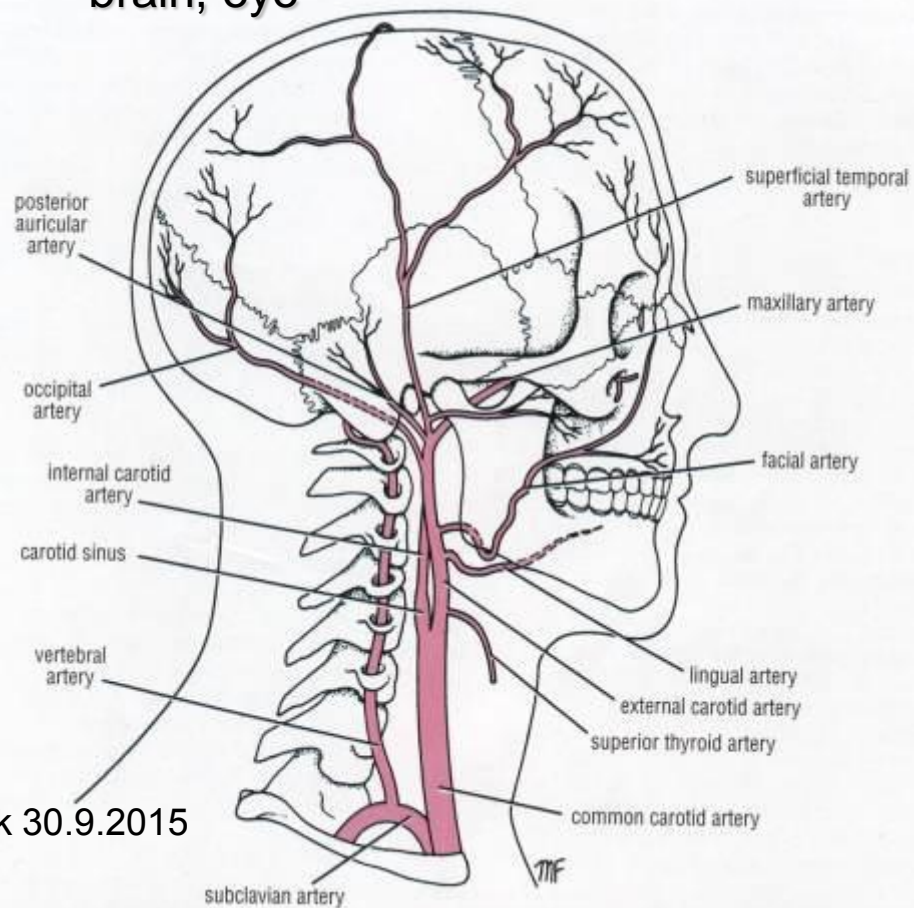
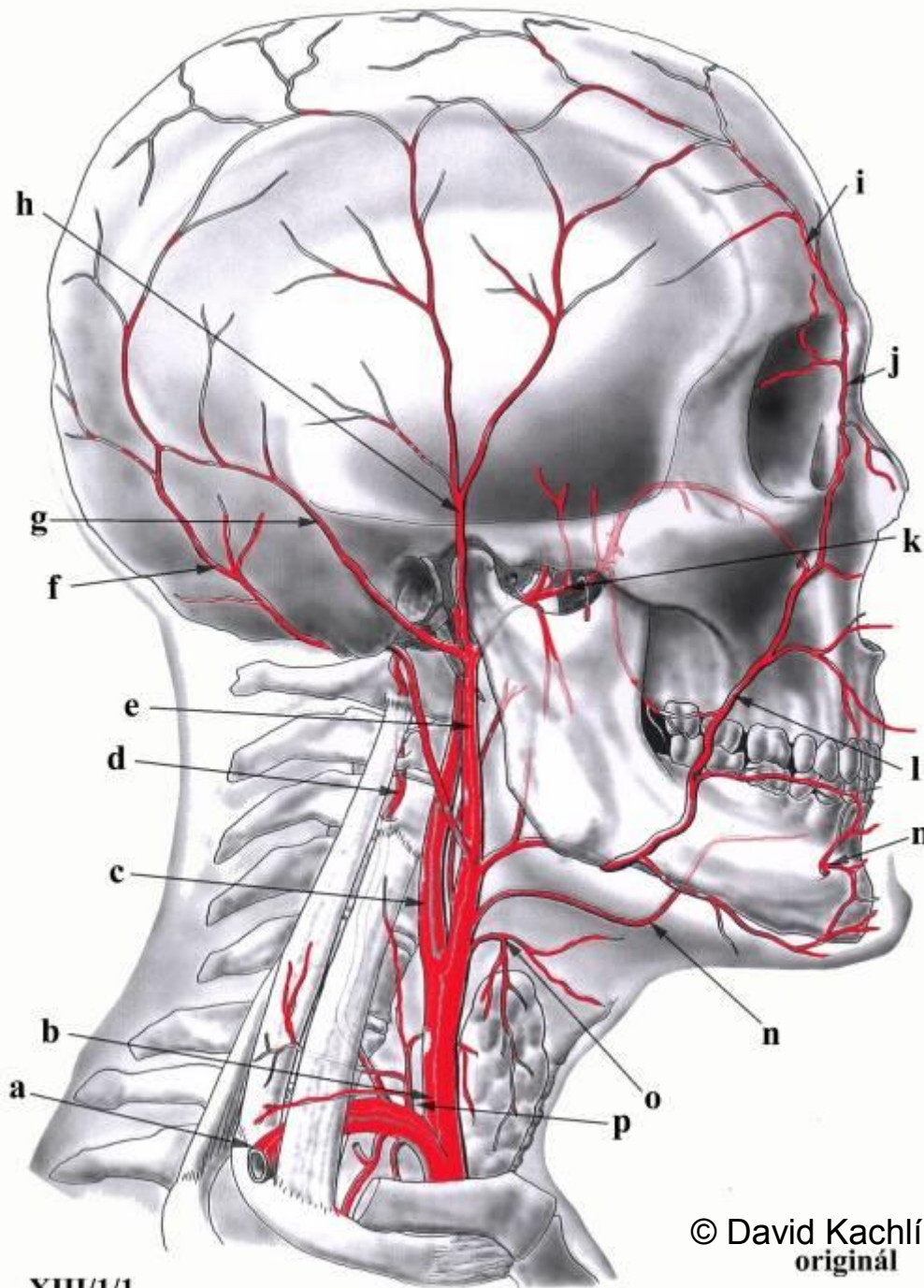


A. carotis externa

- ventromedially
- 8 branches
- face, tongue, oral cavity, pharynx, meninges

A. carotis interna

- dorsolaterally
- no branch within neck
- brain, eye



© David Kachlík 30.9.2015
original

Arteria carotis externa *topography*

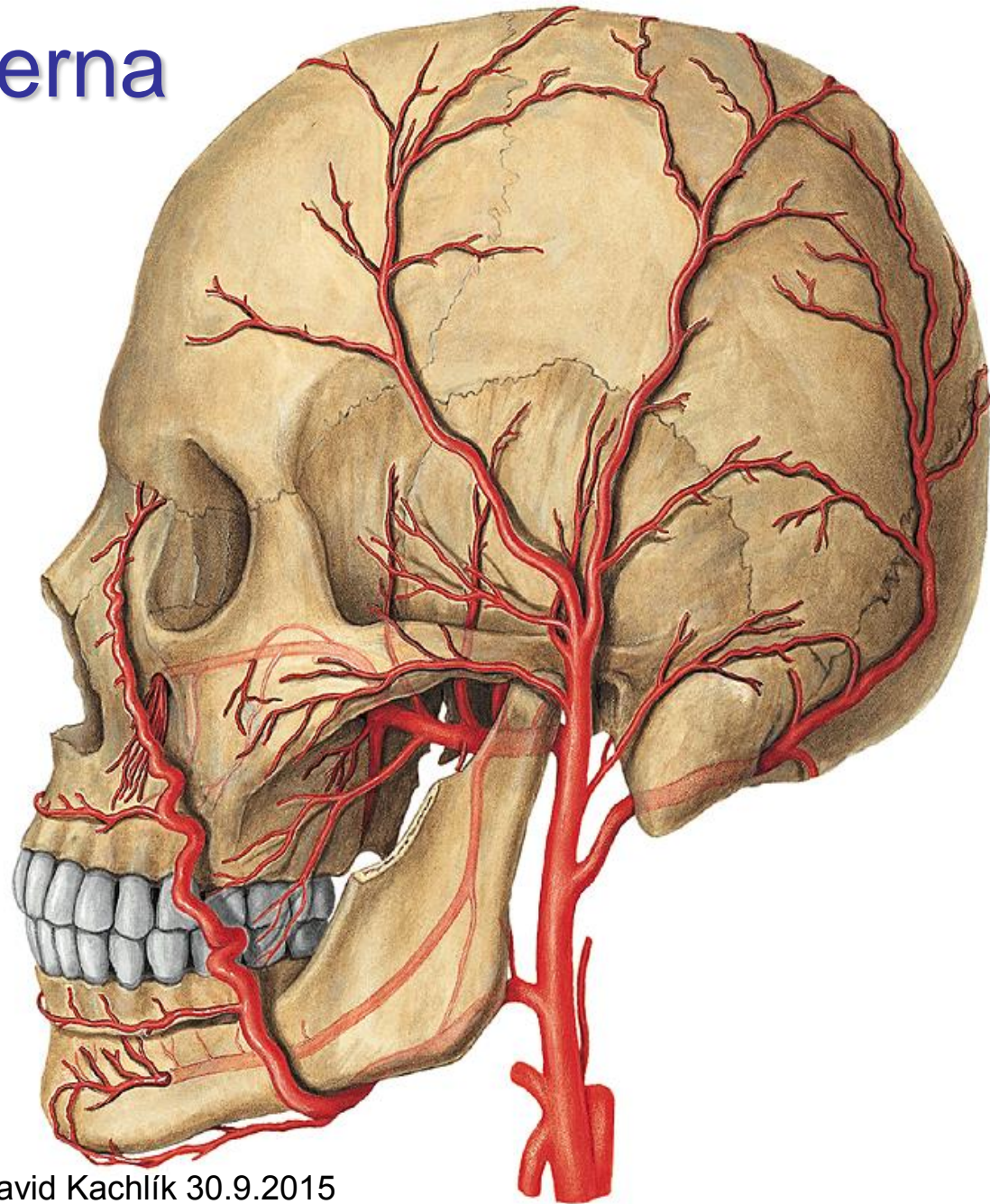
- trigonum caroticum
- spatium prestyloideum

ventrolaterally:

- m. sternocleidomastoideus
- n. XII
- inside glandula parotis crossed by branches of n. VII

medially:

- pharynx
- a. carotis int. (first dorsolaterally, then dorsomedially)
- m. stylopharyngeus

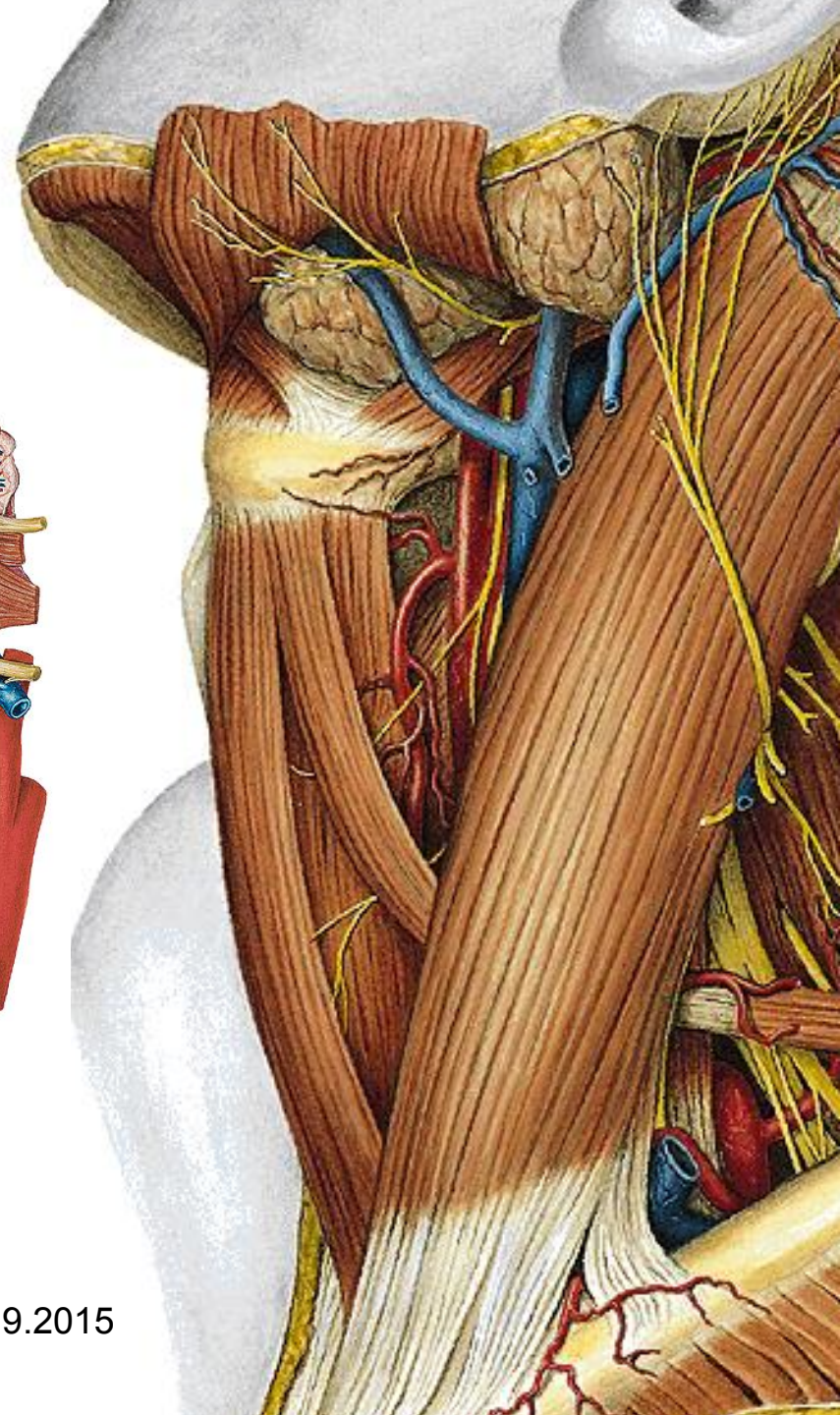
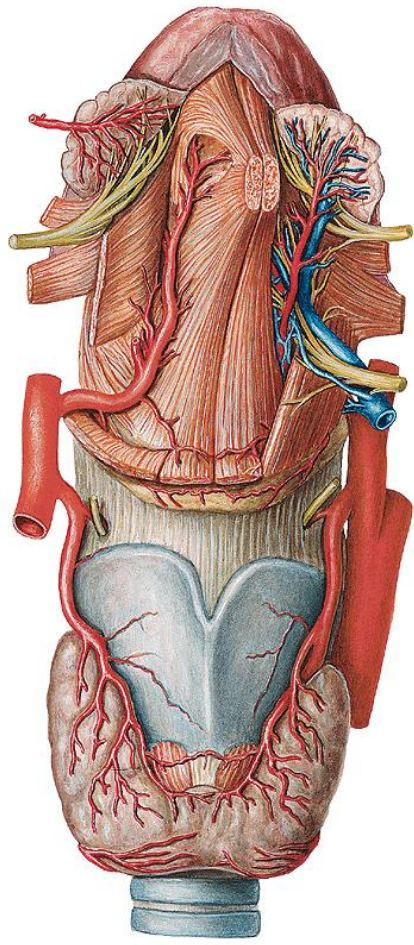


A. thyroidea superior

- r. infrahyoideus
- r. sternocleidomastoideus
- **a. laryngea superior**
- r. cricothyroideus
- r. glandularis anterior
- r. glandularis posterior
- r. glandularis lateralis

together with n. laryngeus superior

can branch from ACC or bifurcatio ACC



A. lingualis

- r. suprahyoideus
- rr. dorsales linguae
- a. sublingualis
- a. profunda linguae

angulus Béclardi

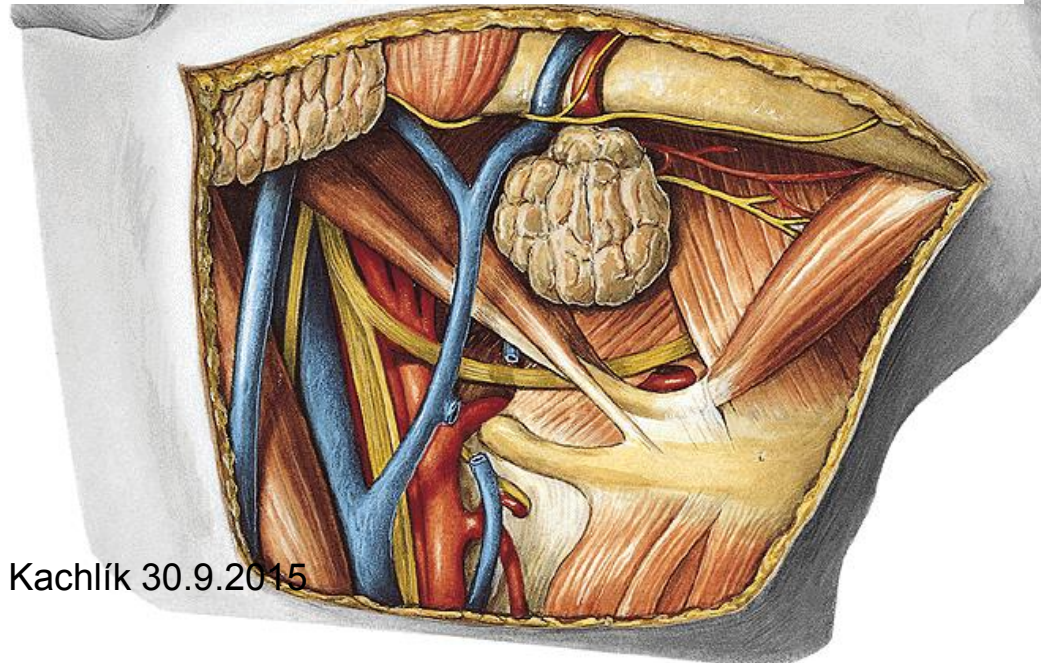
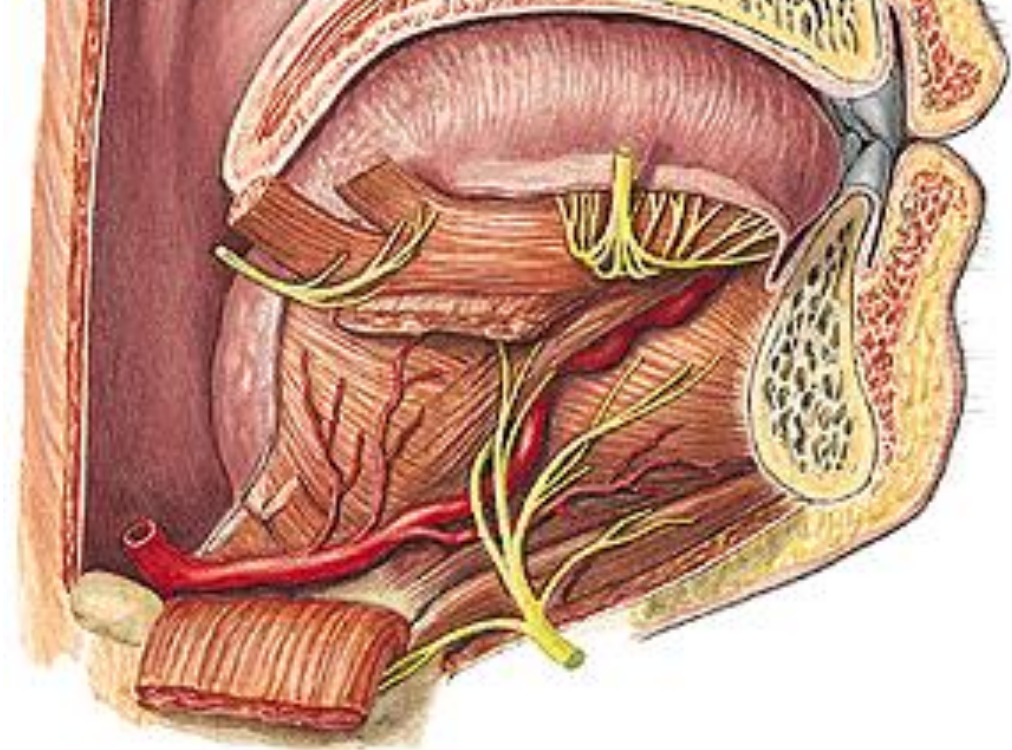
trigonum a. lingualis Pirogovi

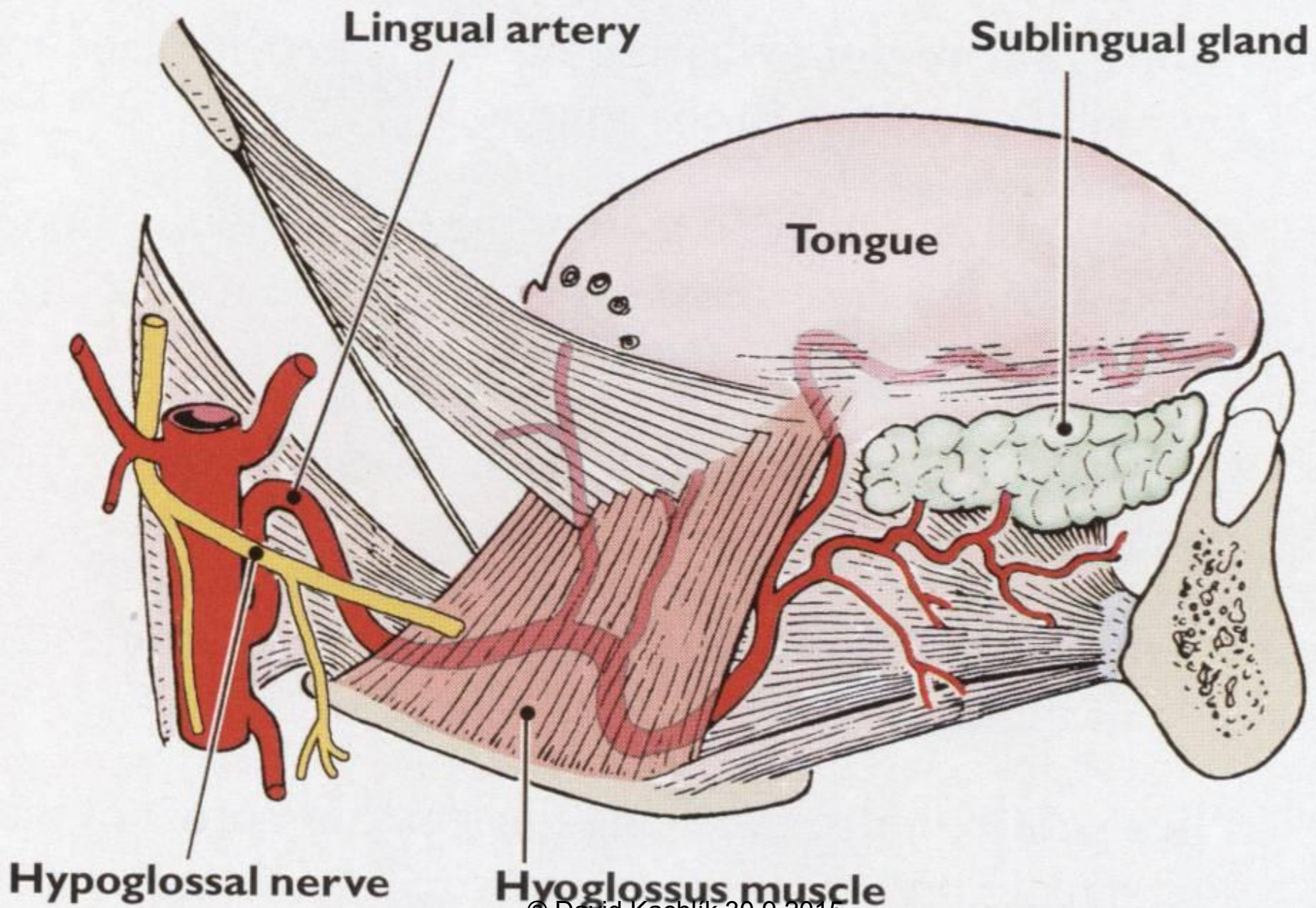
- ligation
- compression

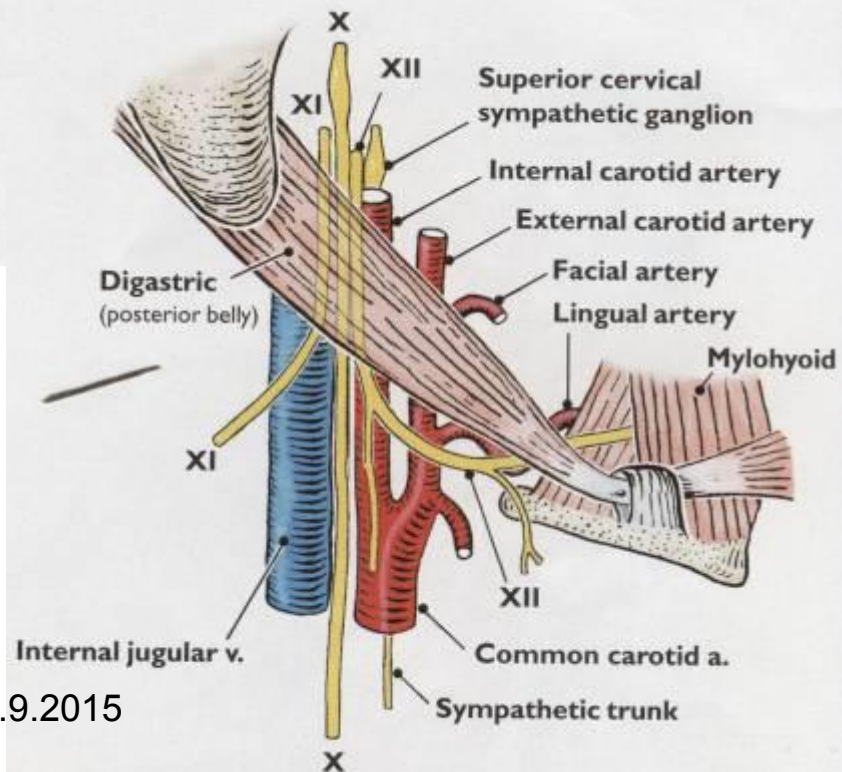
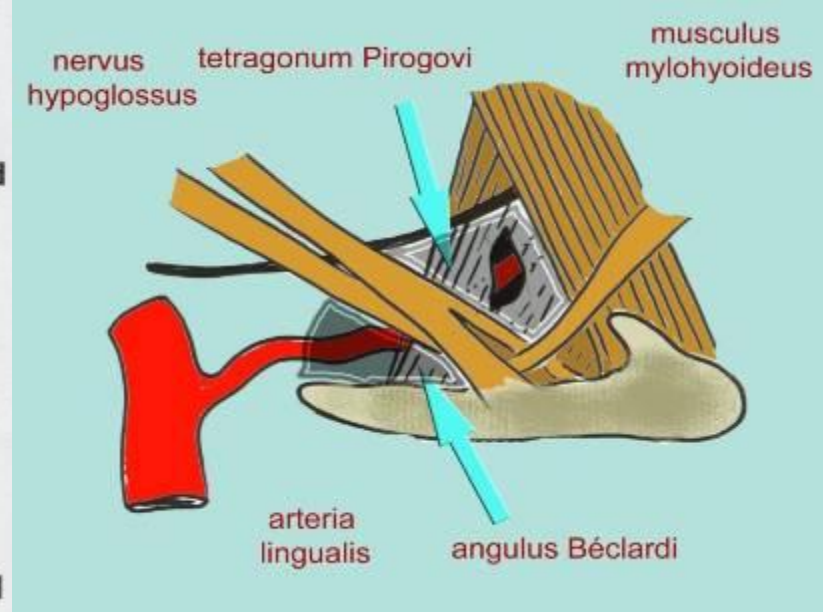
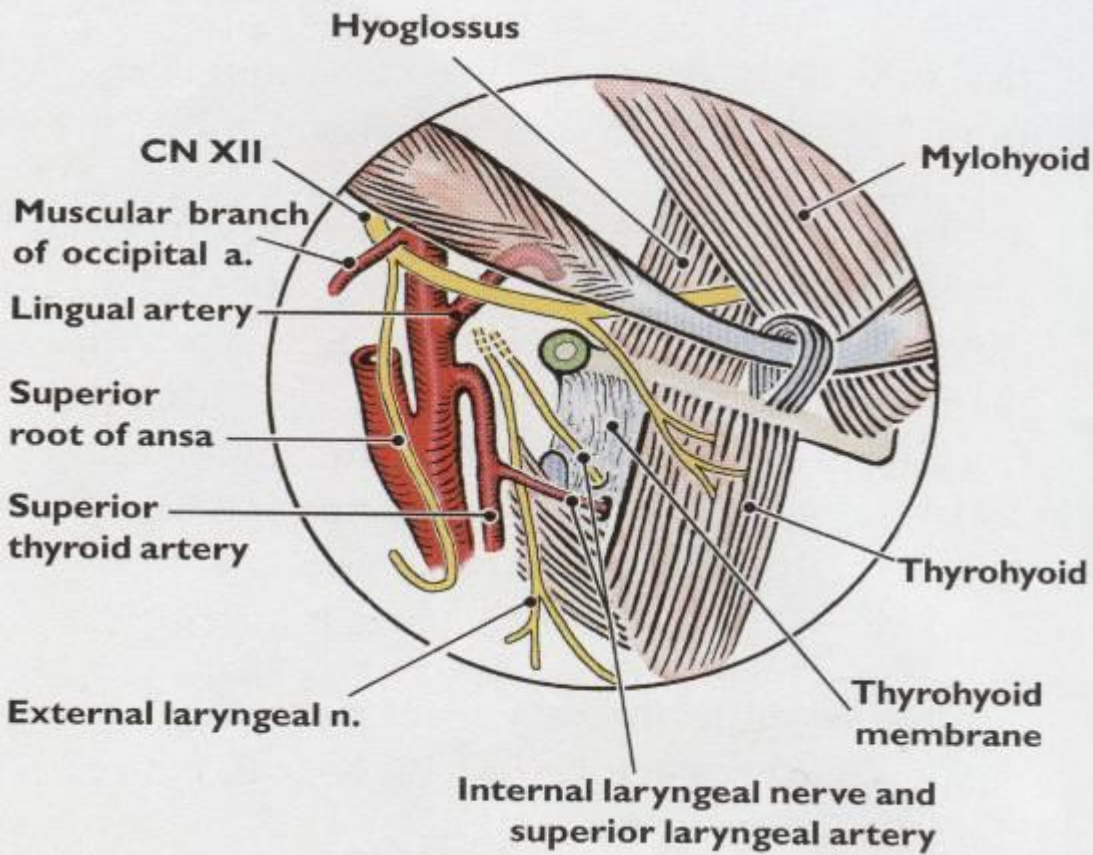
canalis paralingualis

passes under:

- n. XII
- v. post. m. digastrici
- m. stylohyoideus
- m. hyoglossus







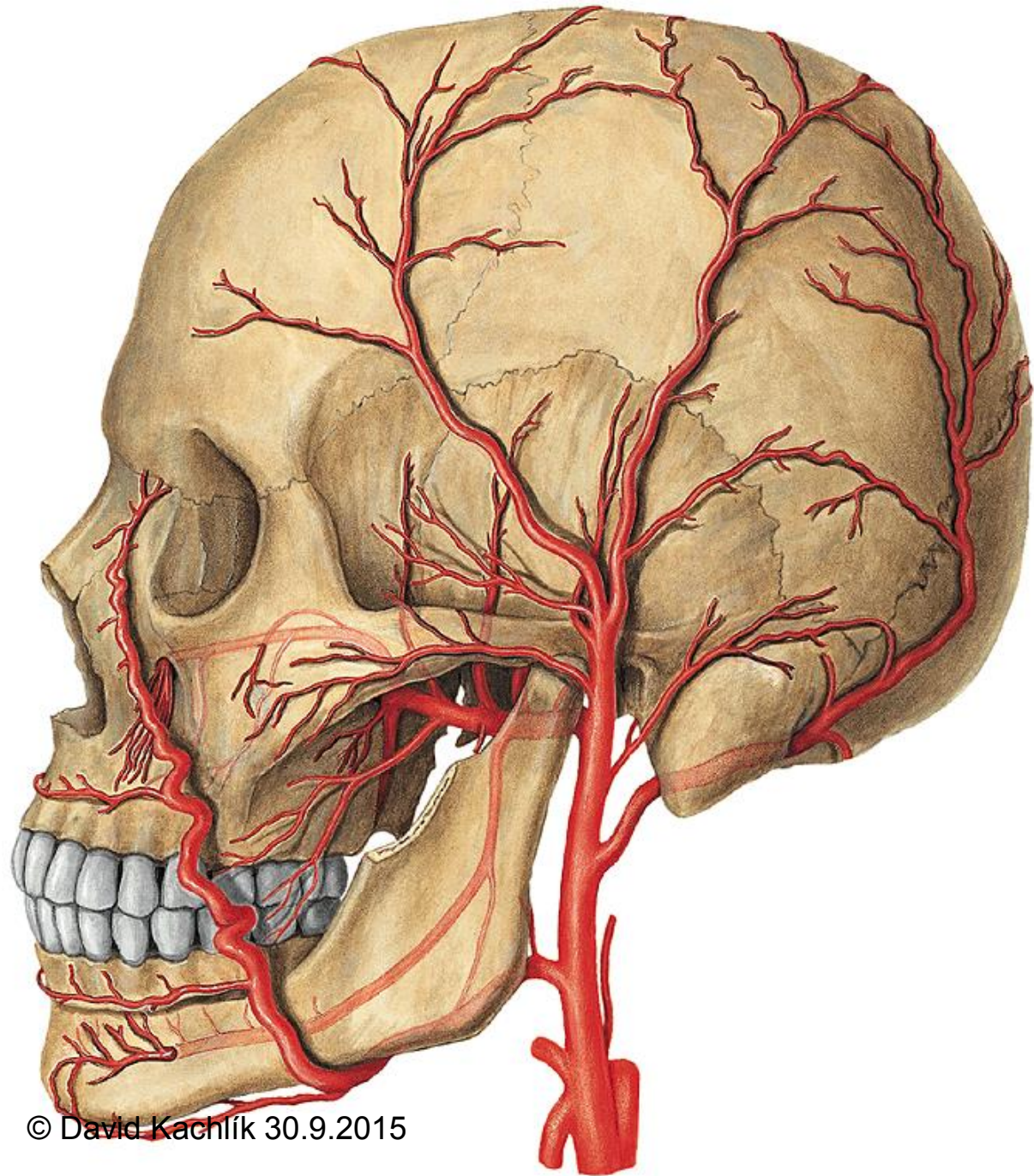
Trigonum a. lingualis
Pirogovi

Angulus Béclardi

A. facialis

- a. palatina ascendens
- r. tonsillaris
- a. submentalis
- rr. glandulares

- a. labialis inferior
- a. labialis superior
 - r. septi nasi
- r. lateralis nasi
- a. angularis



A. facialis

trigonum
submandibulare

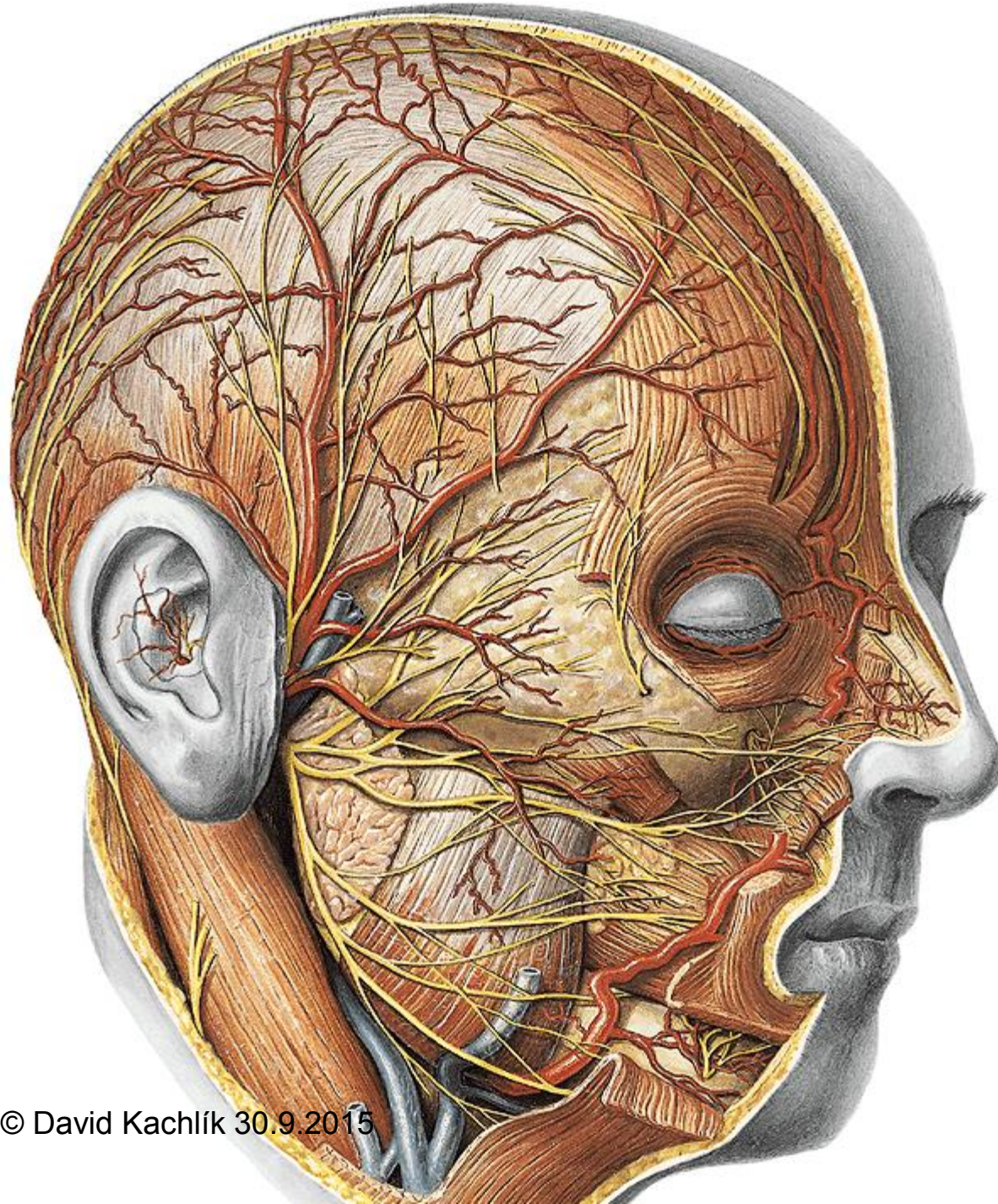
passes under:

- venter post. m.
digastrici
- m. stylohyoideus
- glandula
submandibularis

compression point:

caudal margin of
mandibula ventral to
m. masseter

sinuous course in face



A. occipitalis

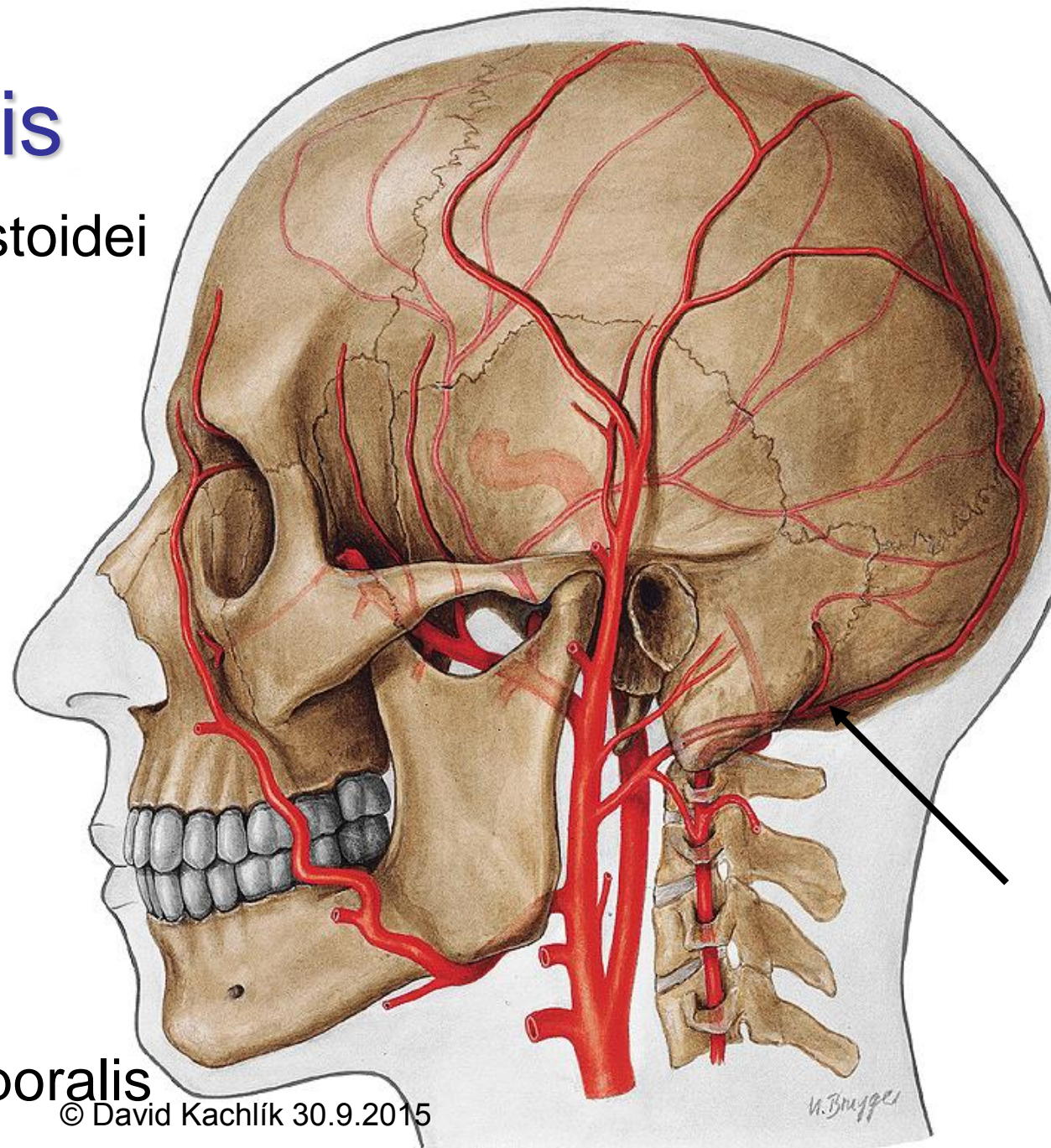
- rr. sternocleidomastoidei
- r. mastoideus
- r. descendens
- r. auricularis
- rr. occipitales
- r. meningeus

passes over:

n. XII

vagina carotica

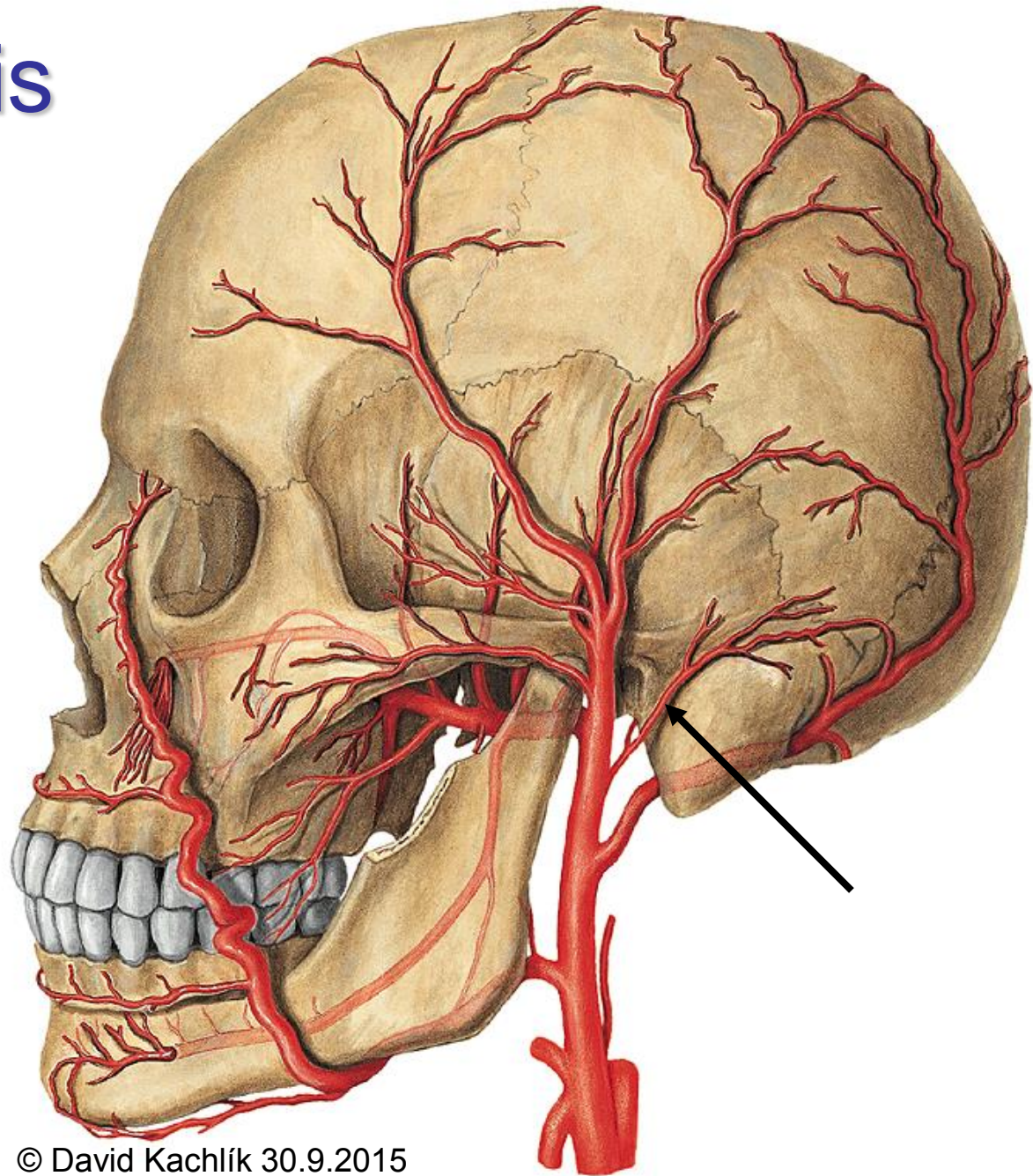
sulcus AO ossis temporalis



A. auricularis posterior

- rr. parotidei
- r. auricularis
- r. occipitalis
- a. stylomastoidea
 - rr. mastoidei
 - a. tympanica post.
 - r. stapedius

origin cranial to
venter post. m.
digastrici

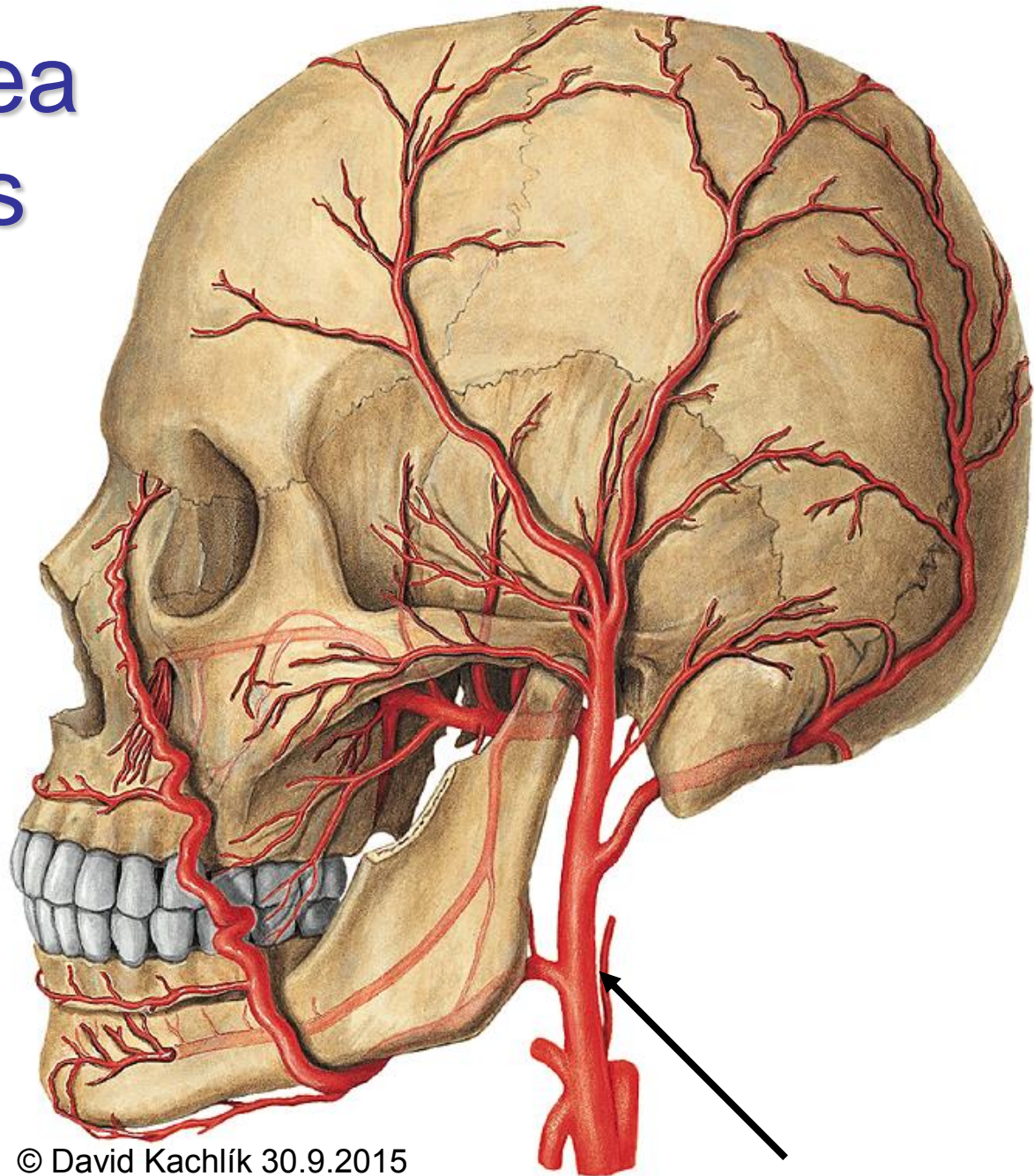


A. pharyngea ascendens

- rr. pharyngei
- a. meningeae post.
- a. tympanica inf.

thinnest branches of
ACE

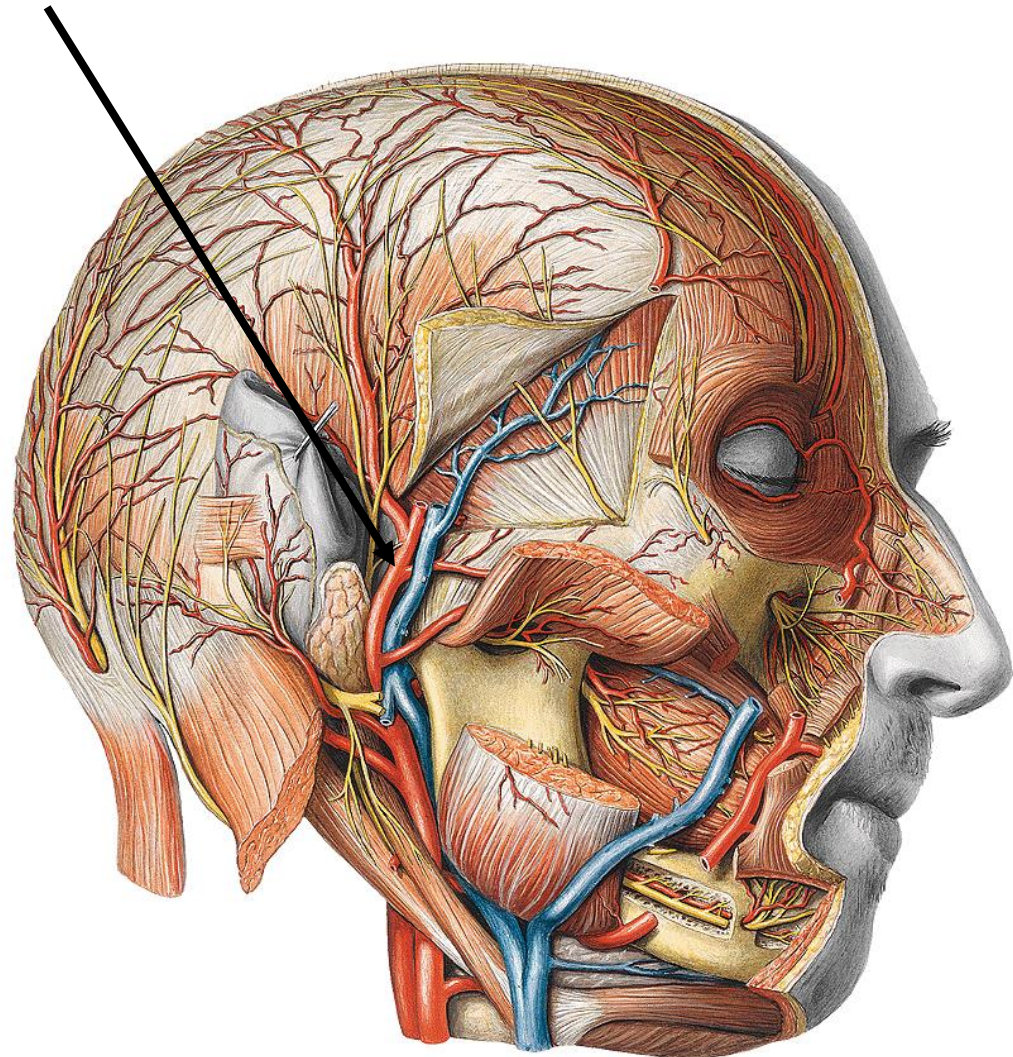
ascends between ACI
and pharynx



Arteria temporalis superficialis

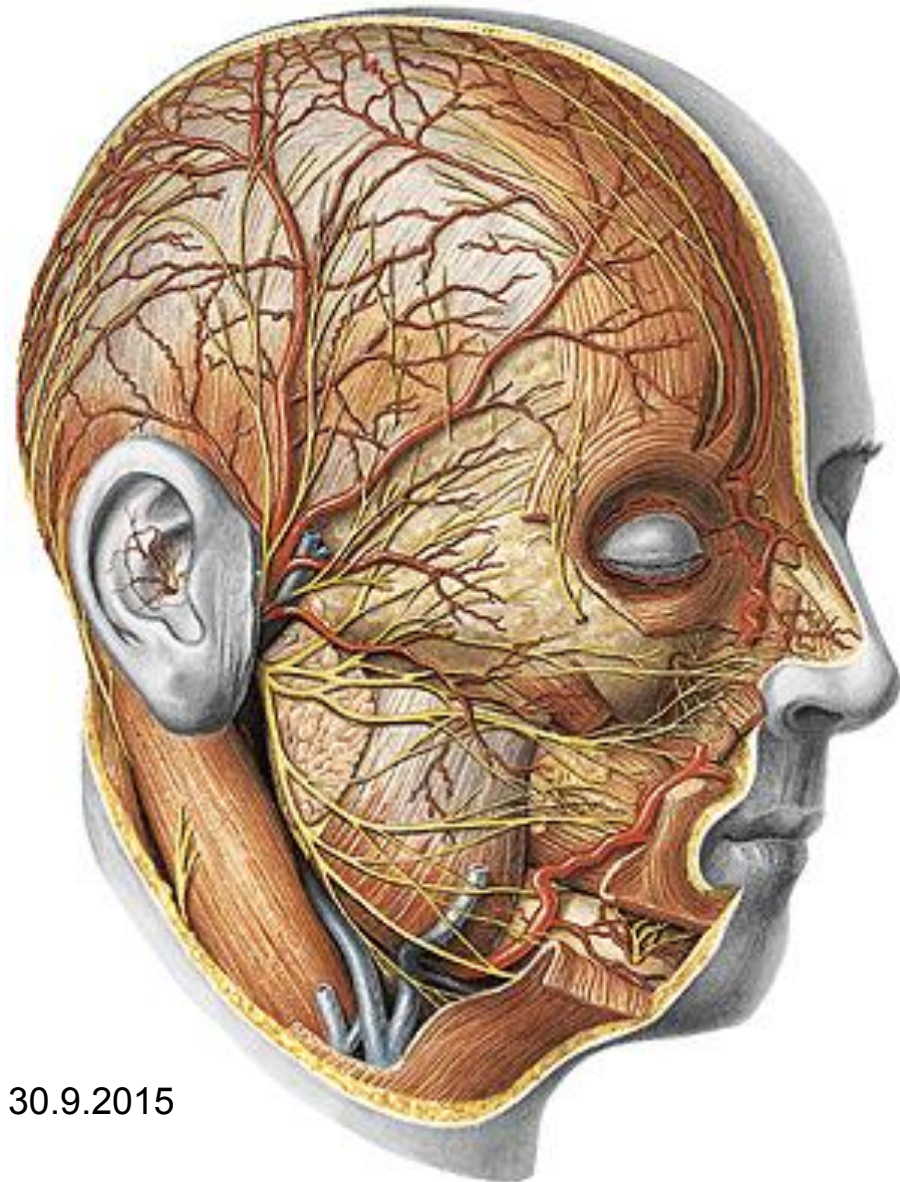
terminal branch

- r. parotideus
- a. transversa faciei
- rr. auriculares anteriores
- a. zygomaticoorbitalis
- a. temporalis media
- r. frontalis
- r. parietalis



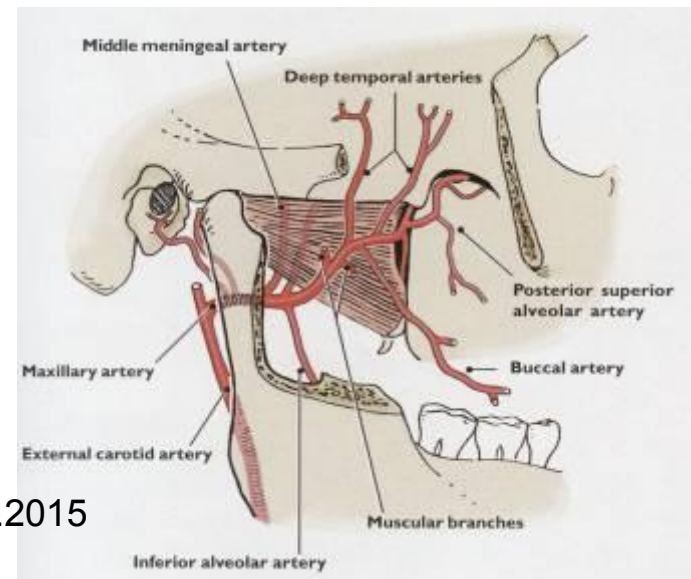
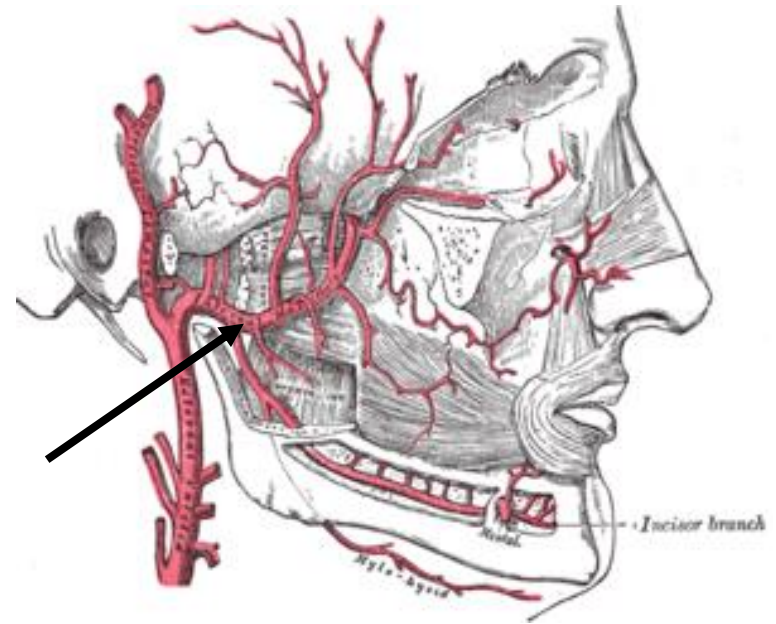
Arteria temporalis superficialis

- compression point:
ventral to auricula
- pedicle vessel for
skin and
musculocutaneous
flaps
- *arteritis temporalis*
(Horton)
 - *inflammatory*
rheumatic disease



Arteria maxillaris

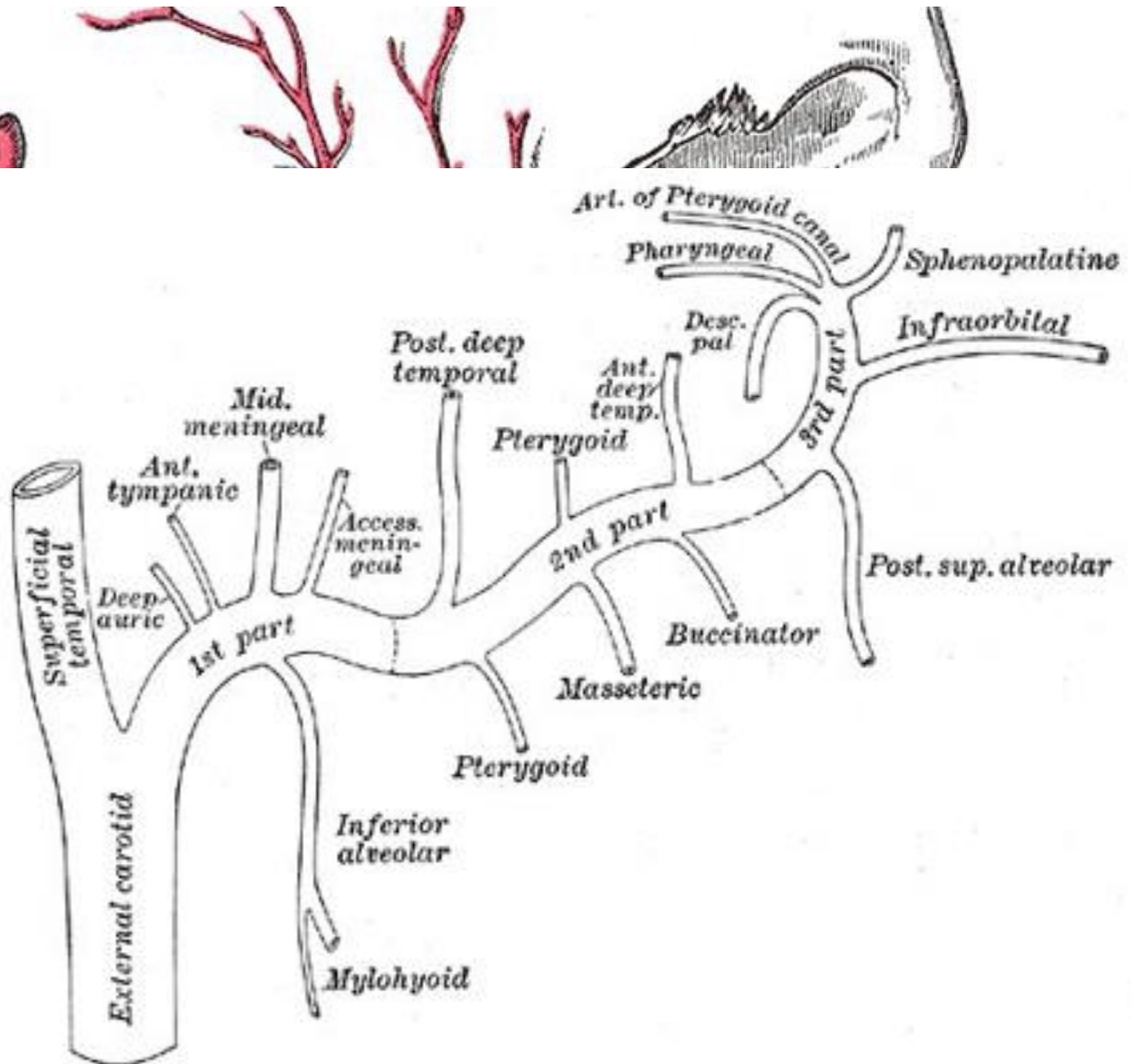
- spatium prestyloideum
 - inside glandula parotidea
 - ventral to lig. sphenomandibulare
- fossa infratemporalis
 - ventral/dorsal to m. pterygoideus lat. (1:1)
- fissura pterygomaxillaris
- fossa pterygopalatina
- 3 parts
- 13 branches
- *maxillofacial surgery*



ARTERIA MAXILLARIS

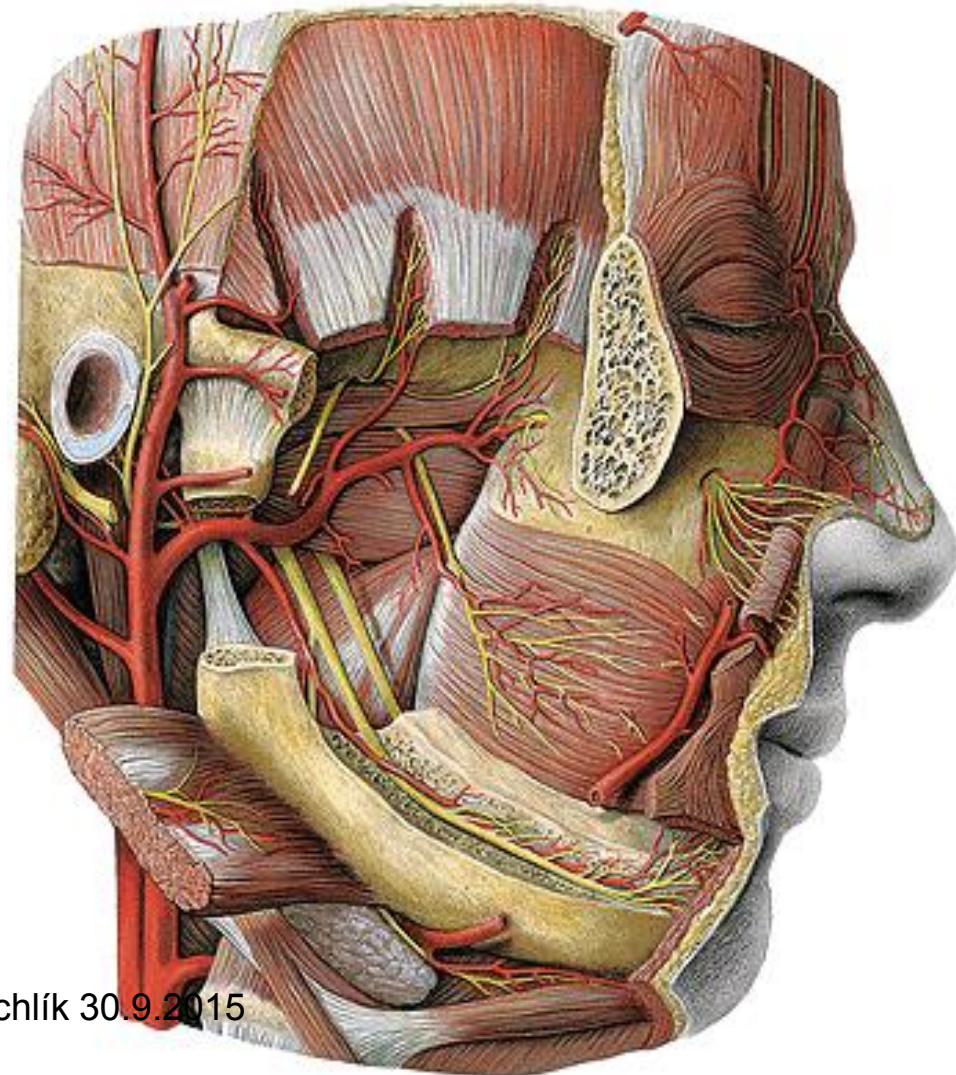


- 1 - pars mandibularis
- 2 - pars pterygoidea
- 3 - pars pterygopalatina



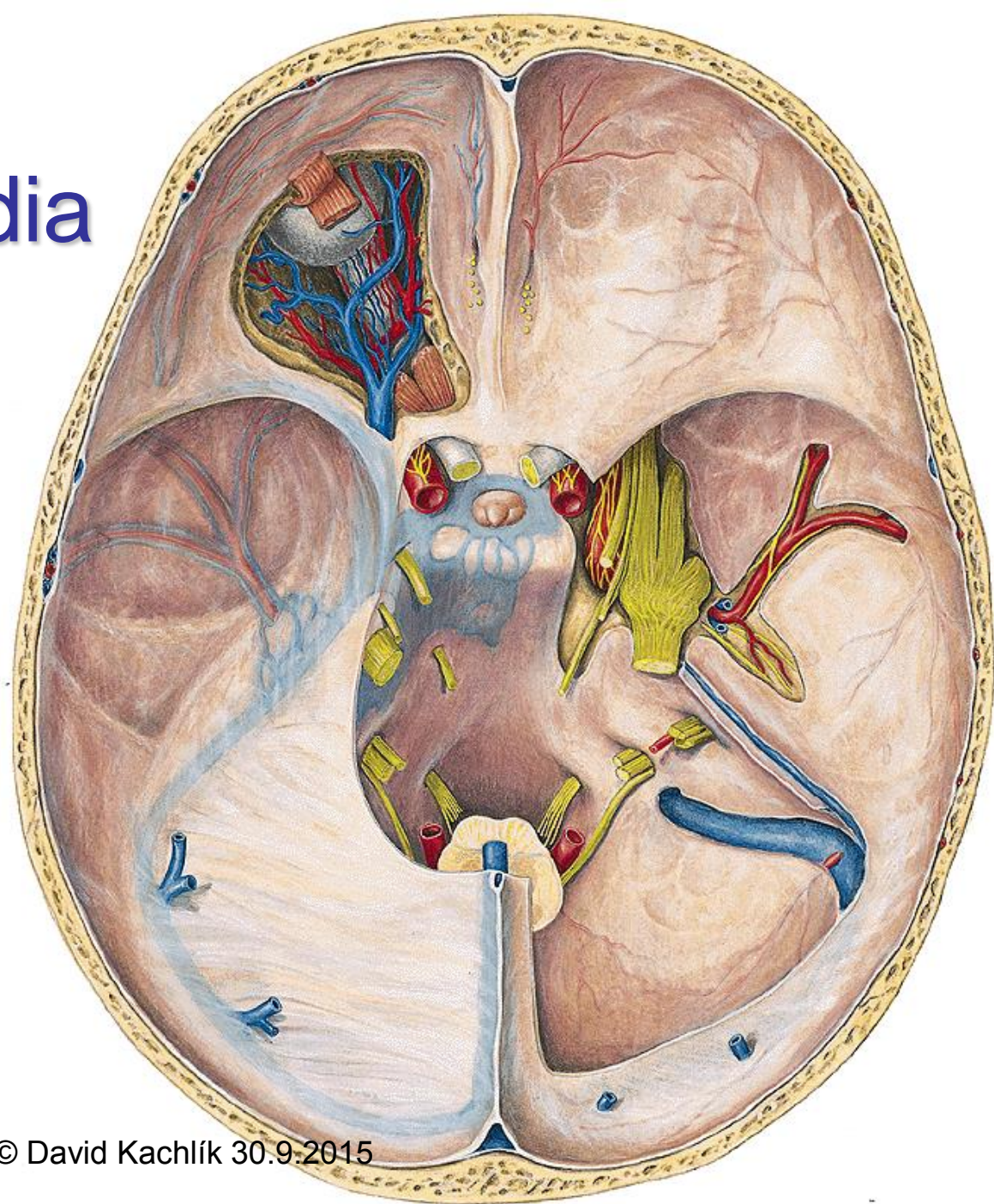
Arteria maxillaris pars mandibularis

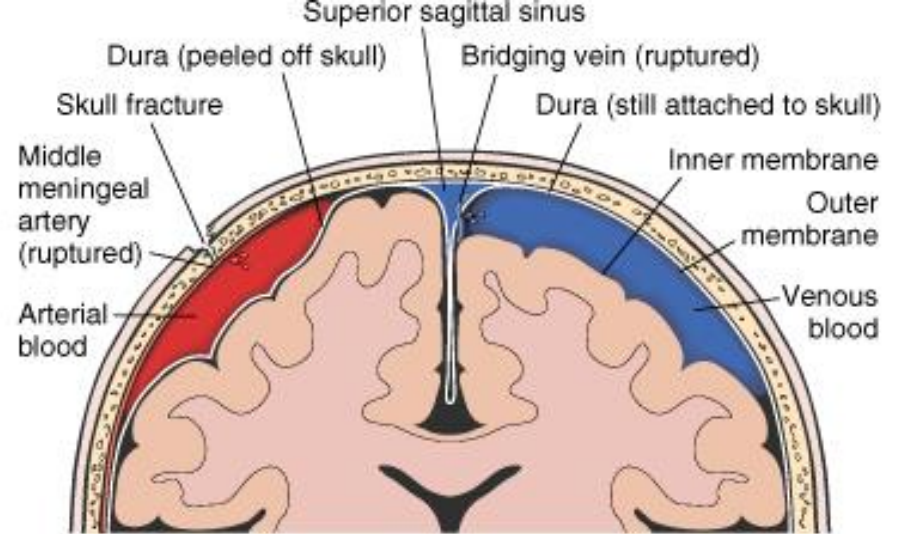
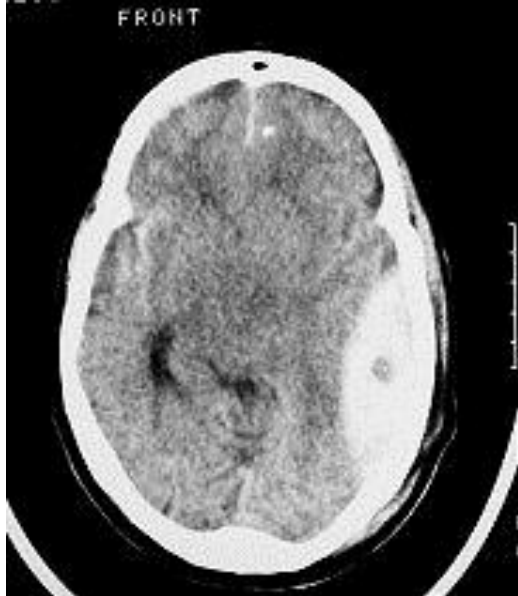- a. auricularis profunda
- a. tympanica anterior
fissura petrotympanica
- a. alveolaris inferior
canalis mandibulae
 - r. mylohyoideus
 - rr. dentales + peridentales
 - r. mentalis
foramen mentale
- a. meningea media
foramen spinosum
 - r. accessorius
 - r. frontalis
 - r. orbitalis
 - r. parietalis
 - r. petrosus
 - canalis n. petrosi majoris*
 - a. tympanica superior
canalis n. petrosi minoris



Arteria meningea media

- epidural bleeding (trauma)
- lentiform shape
- rapid intervention
 - trepanation
 - removal of blood

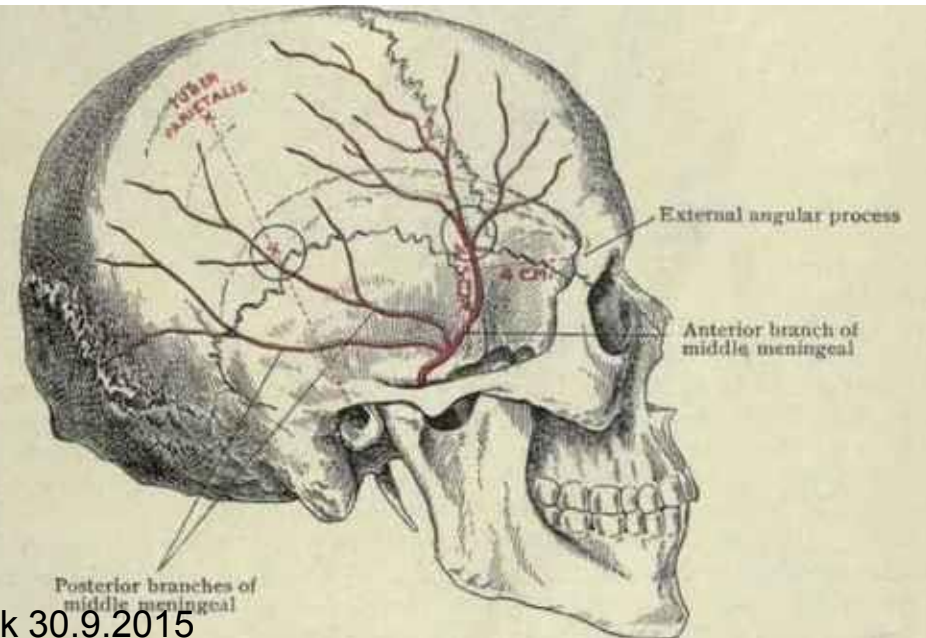
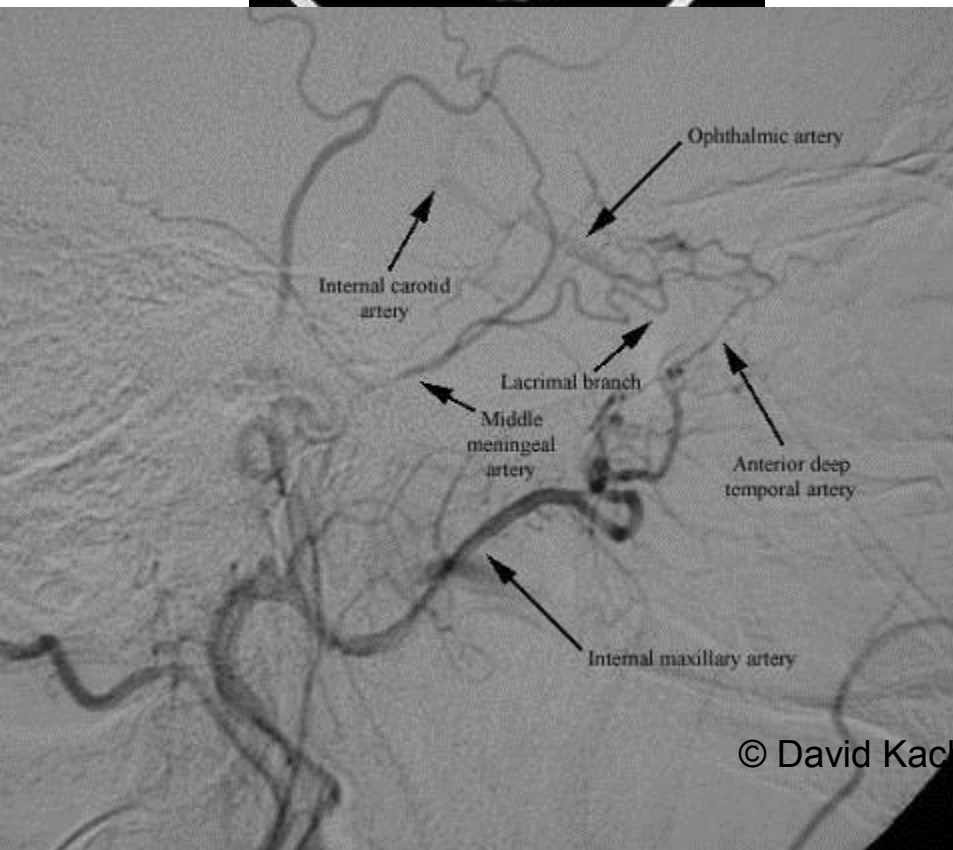




A. Epidural hematoma

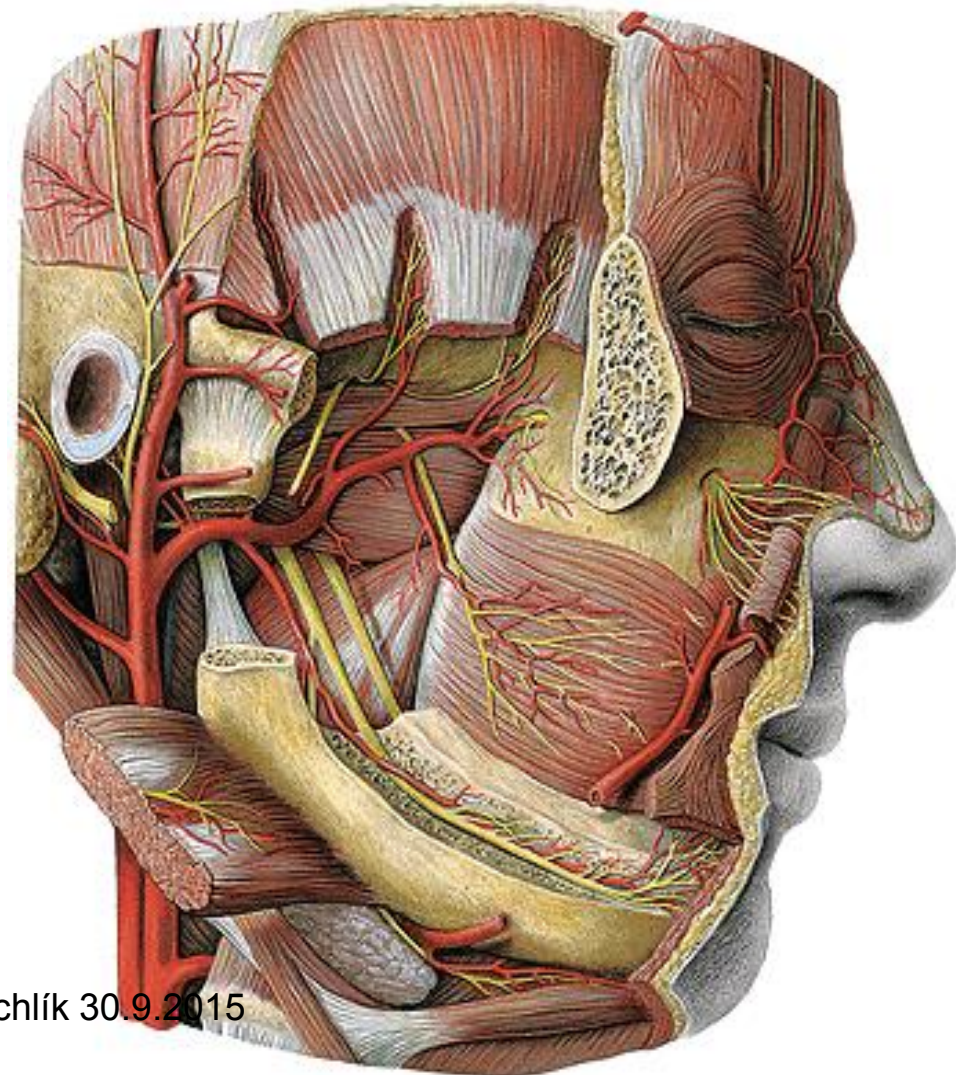
B. Subdural hematoma

Elsevier Ltd. Kumar et al: Basic Pathology 7E www.studentconsult.com



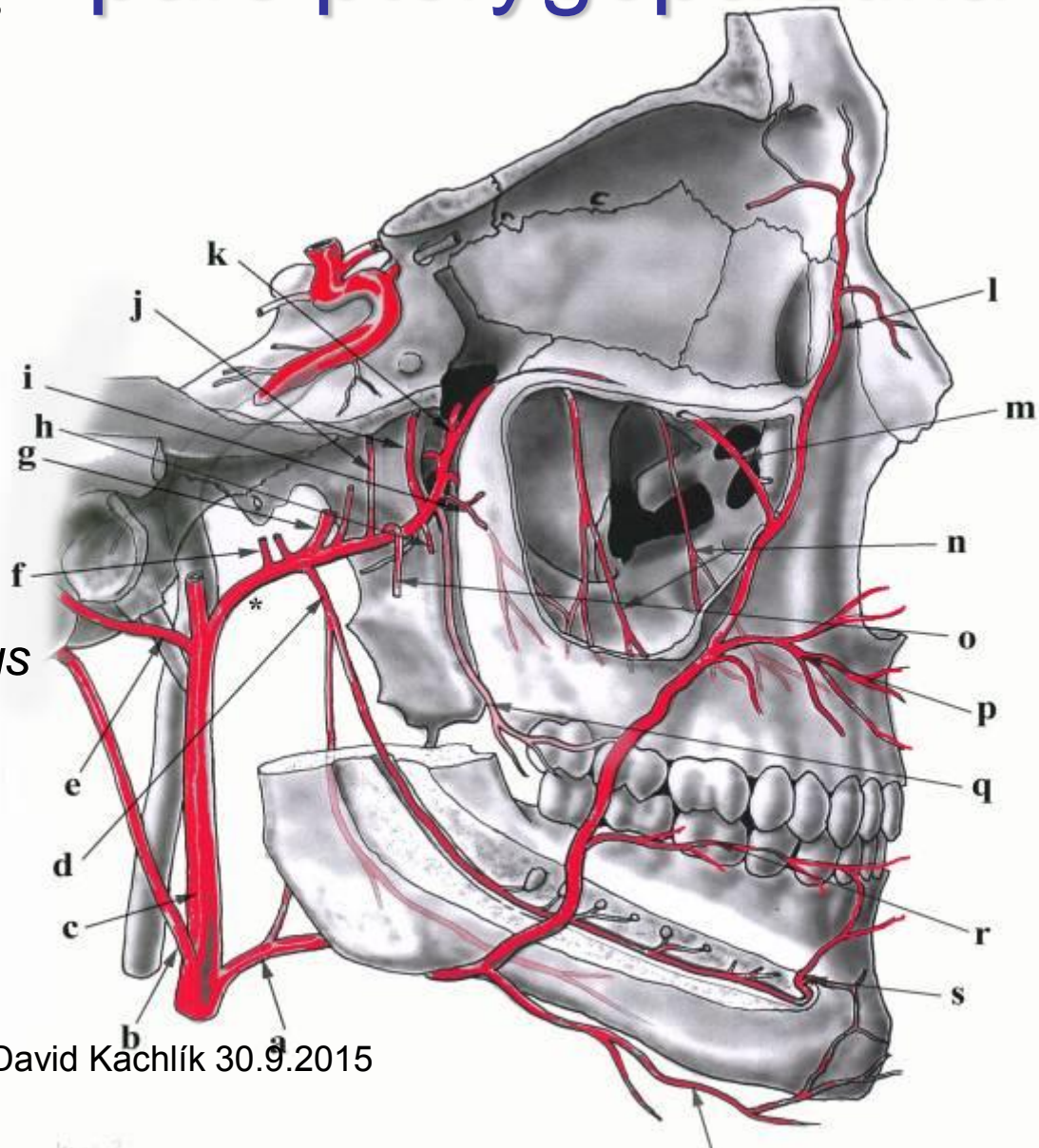
Arteria maxillaris pars pterygoidea

- a. pterygomeningea
- a. masseterica
incisura mandibulae
- a. temporalis profunda
anterior + posterior
– rr. pterygoidei
- a. buccalis



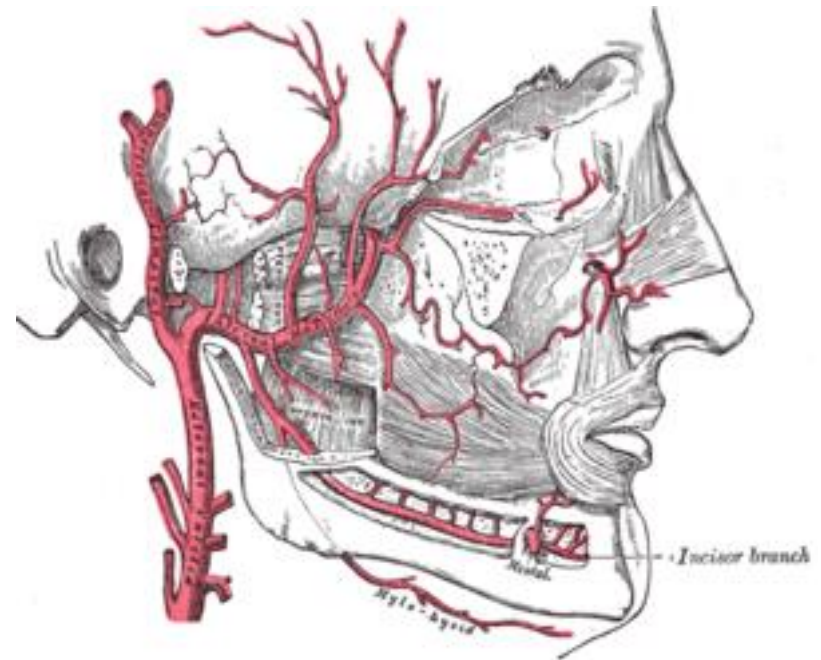
Arteria maxillaris pars pterygopalatina

- aa. alveolares sup. post.
foramina + canales alveolares
 - rr. dentales + peridentales
- a. infraorbitalis
sulcus + canalis infraorbitalis
 - a. alveolaris sup. media
 - a. alveolaris sup. ant.
- a. canalis pterygoidei
canalis pterygoideus
 - r. pharyngeus
 - canalis palatovaginalis*
- a. palatina descendens
 - a. palatina major
 - canalis + for. palatinum majus*
 - aa. palatinae minores
 - cann. + forr. palatina minora*
- a. sphenopalatina
foramen sphenopalatinum
 - aa. nasales post. lat.
 - rr. septales post.
 - a. nasopalatina
 - can. + for. incisivum*



Arteria maxillaris

- maxillofacial surgery
 - deep, difficult to reach
- a. sphenopalatina
 - bleeding in nasal cavity
 - *bleeding at septum from locus Kiesselbachi*
 - hypertension
 - *cauterization*
 - *embolization*




Arteria carotis interna

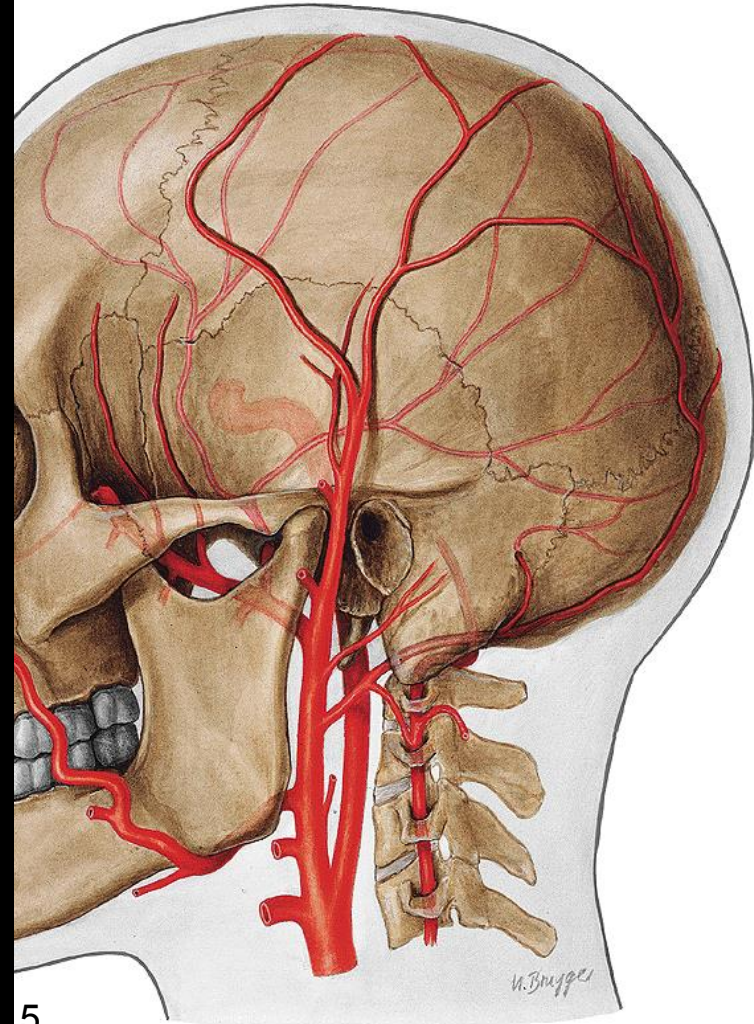
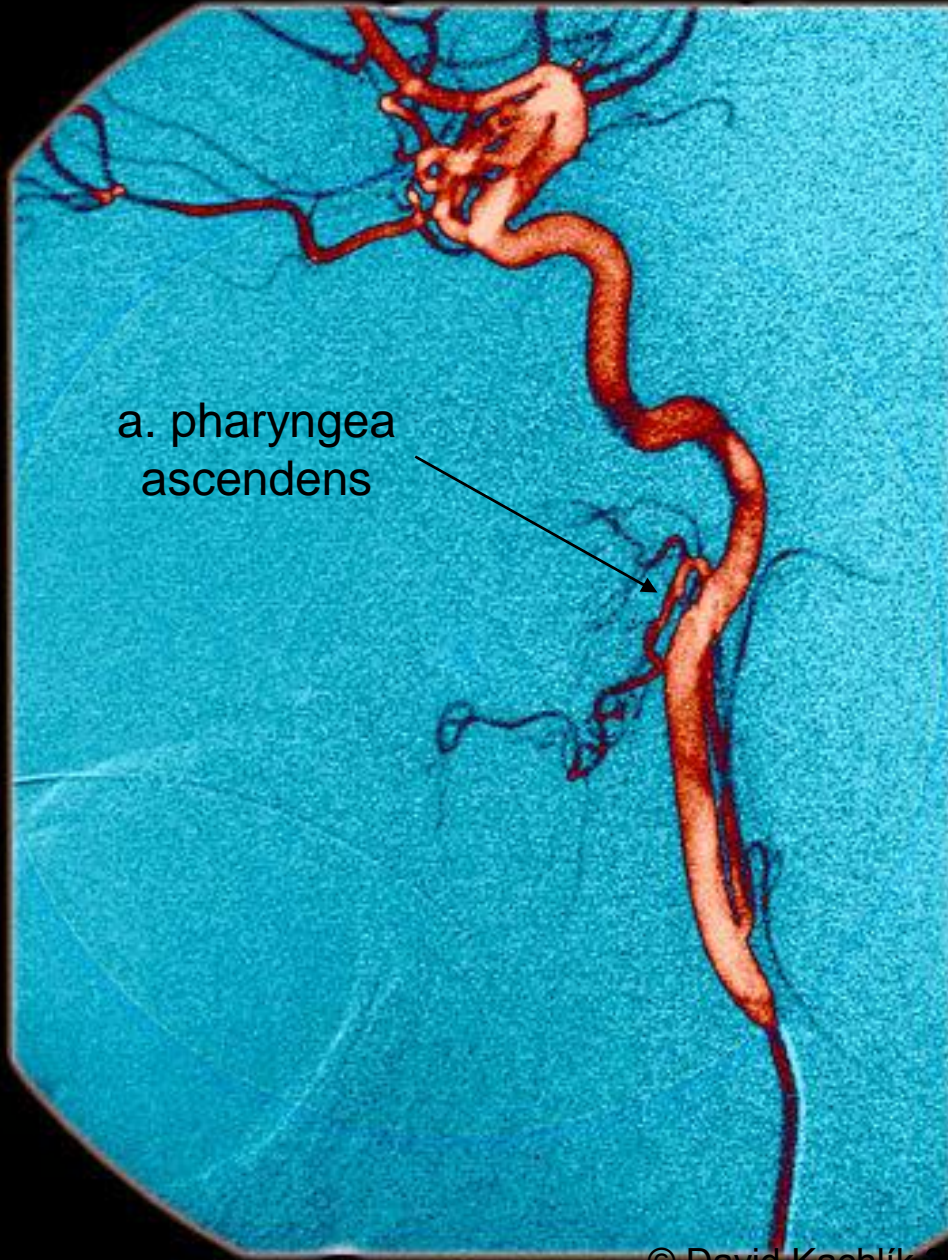
- brain (80 % of blood), eye
- 4 anatomical parts – 7 clinical parts
- siphon caroticum
- circulus arteriosus cerebri *Willisi*

ČÁSTI VNITŘNÍ KRKAVICE

Anatomical parts of ACI

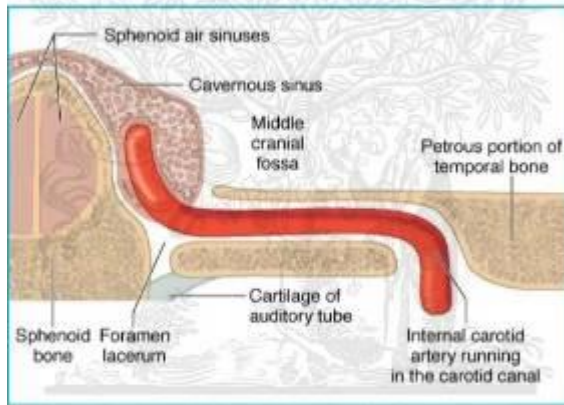


ars cervicalis

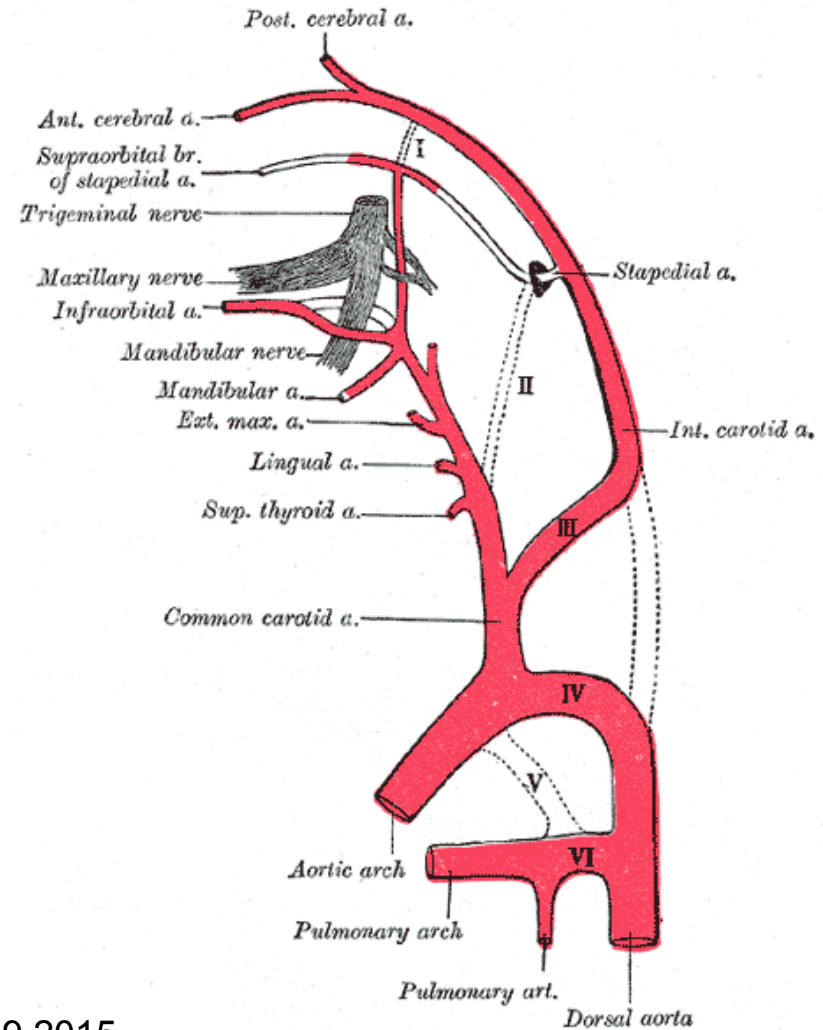


A. carotis interna – pars petrosa

- aa. caroticotympanicae

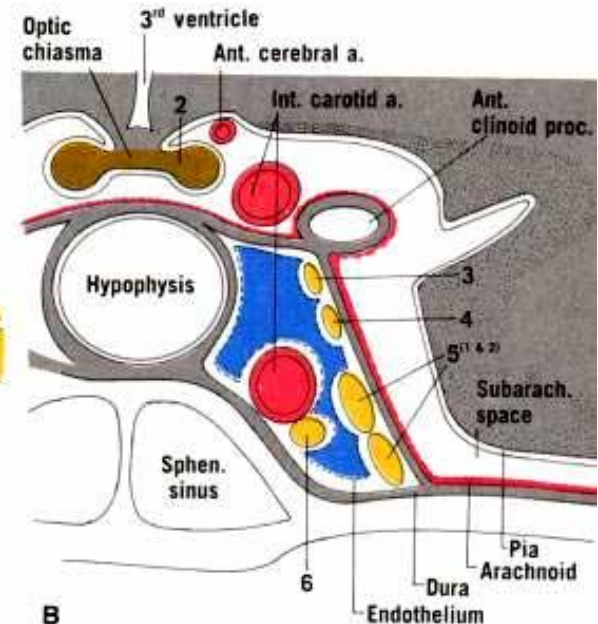
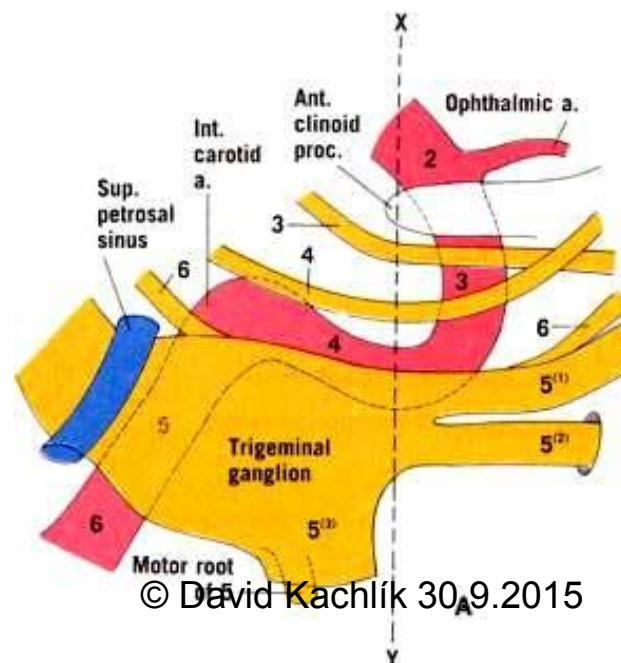
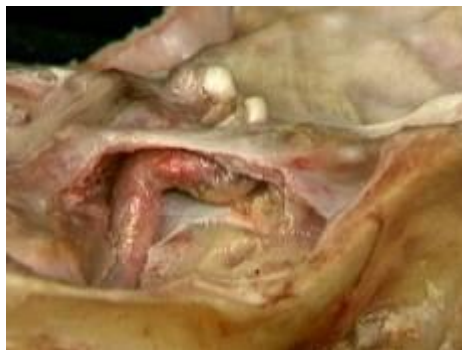
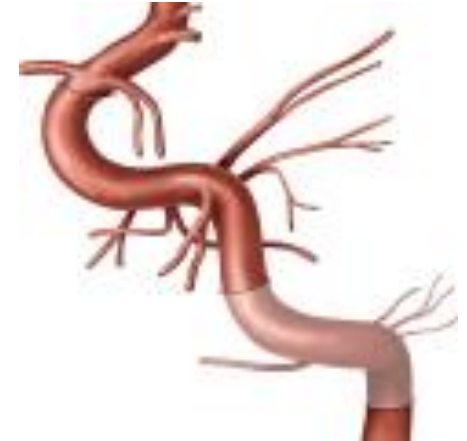
©ELSEVIER, INC. - ELSEVIERIMAGES.COM



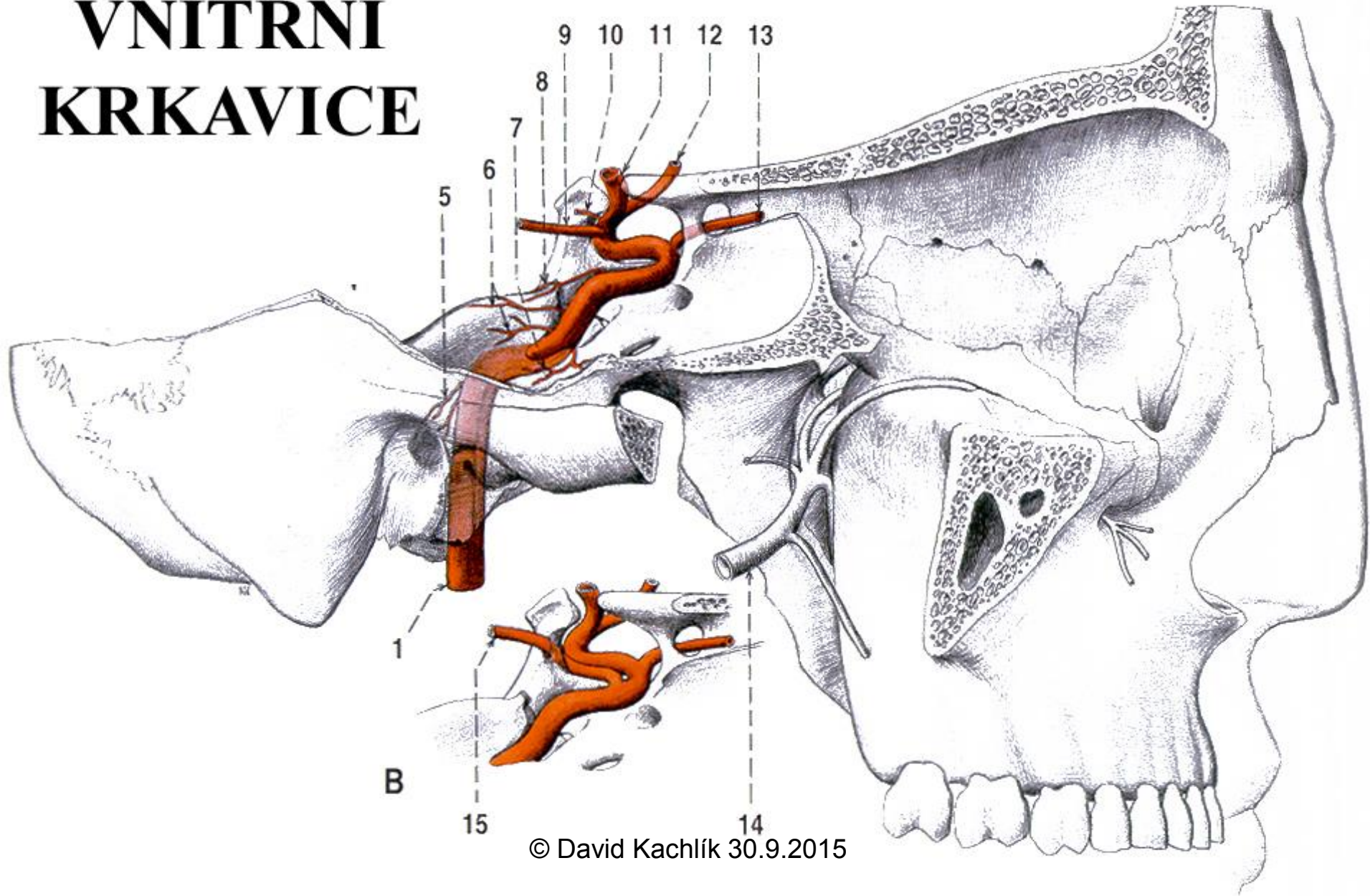
A. carotis interna – pars cavernosa

- r. meningeus
- r. sinus cavernosi
- a. hypophysialis inferior
- rr. ganglionares trigeminales



A. carotis interna

VNITŘNÍ KRKAVICE

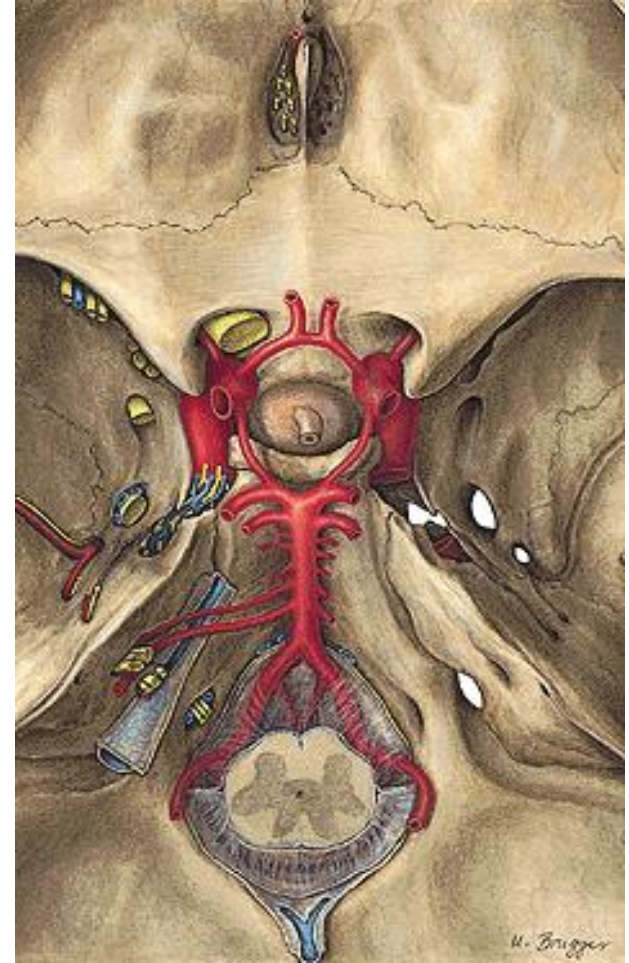


A. carotis interna – pars cerebralis

- **a. ophthalmica**
- a. hypophysialis superior
- a. communicans posterior
- a. choroidea anterior

terminal branches:

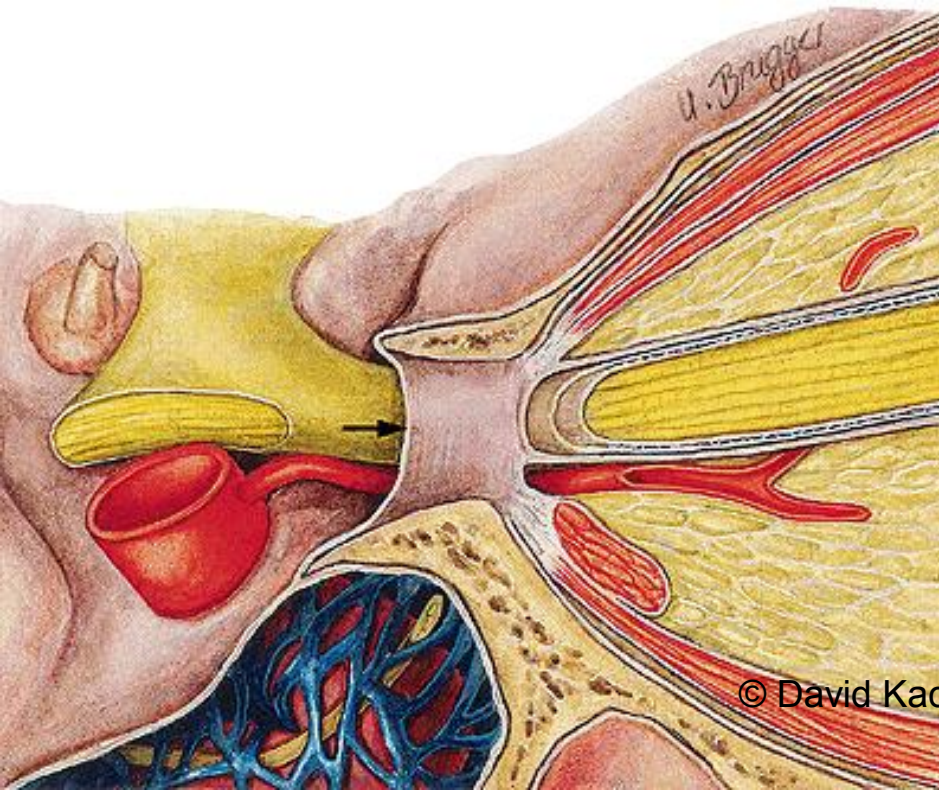
- **a. cerebri anterior**
- **a. cerebri media**



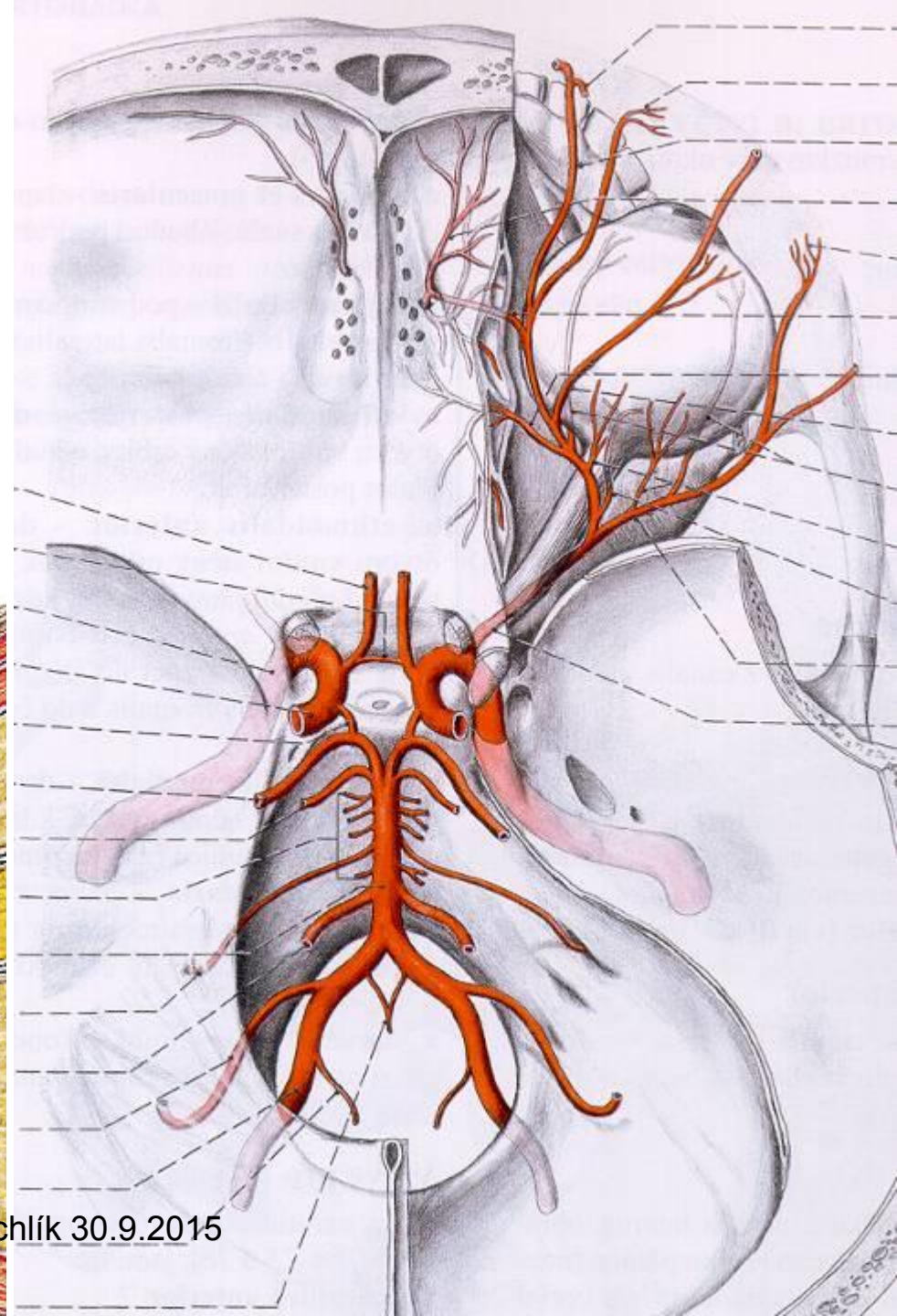
circulus arteriosus cerebri Willisii

A. ophthalmica

- origin in right angle
- *canalis opticus*
 - relation to n.II
- orbit and eyeball
- retina
 - *arterioles' lesion in hypertension and diabetes mellitus*

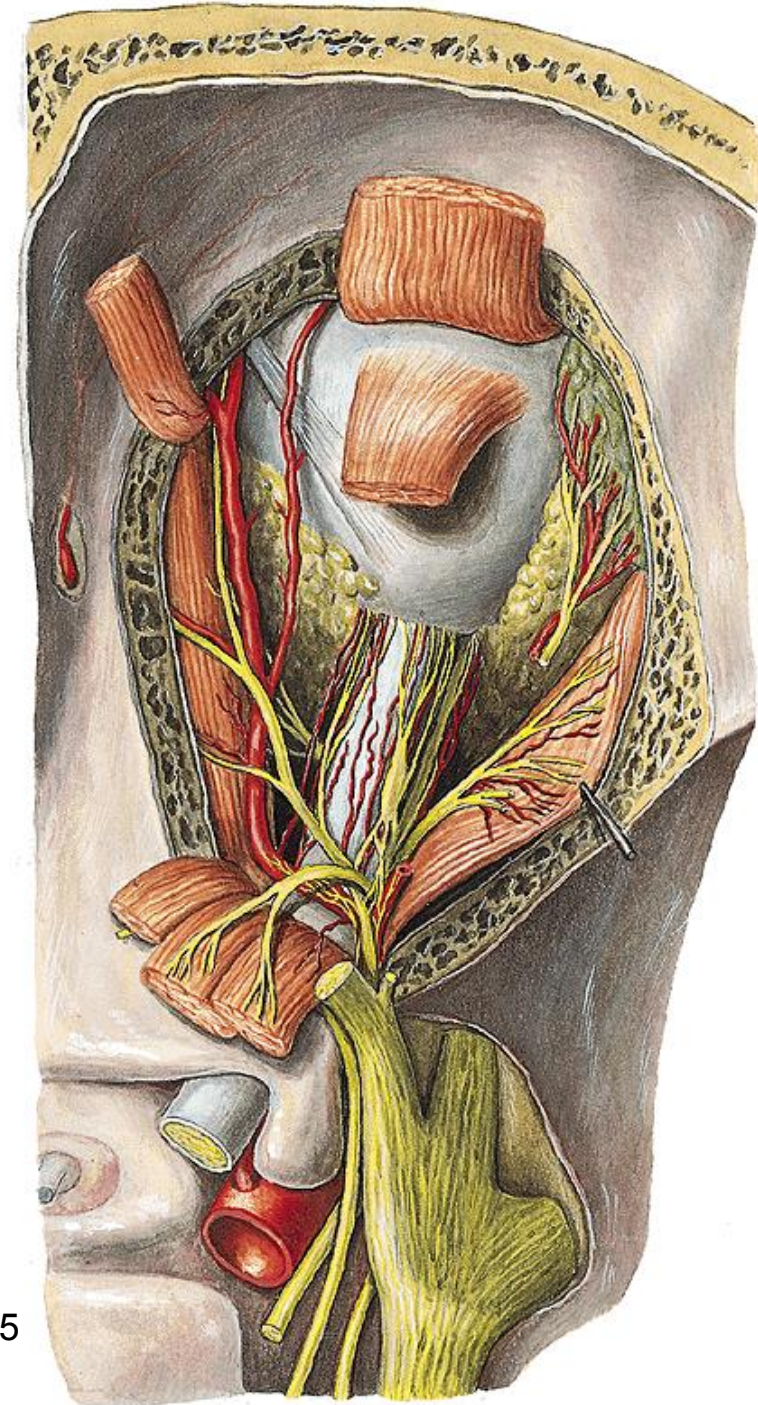

© David Kachlík 30.9.2015



Arteria ophthalmica

- a. centralis retinae
 - pars extraocularis + intraocularis
- a. lacrimalis
- aa. musculares
- a. supraorbitalis
- a. ethmoidalis anterior
 - r. meningeus anterior
 - rr. septales anteriores
 - rr. nasales anteriores laterales
- a. ethmoidalis posterior
- a. supratrochlearis
- a. dorsalis nasi

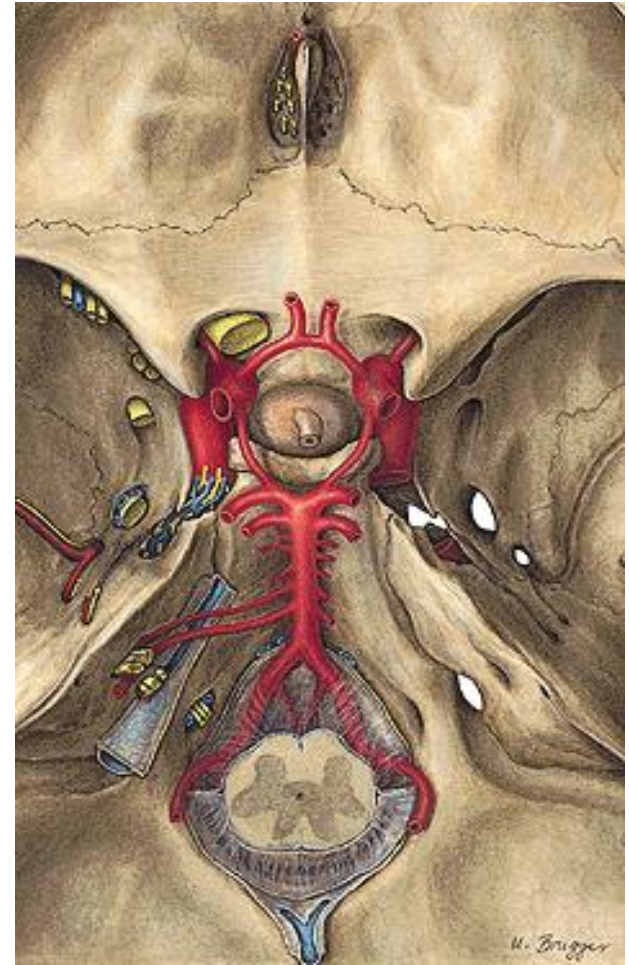


A. carotis interna – pars cerebralis

- a. ophthalmica
- a. hypophysialis superior
- a. communicans posterior
- a. choroidea anterior

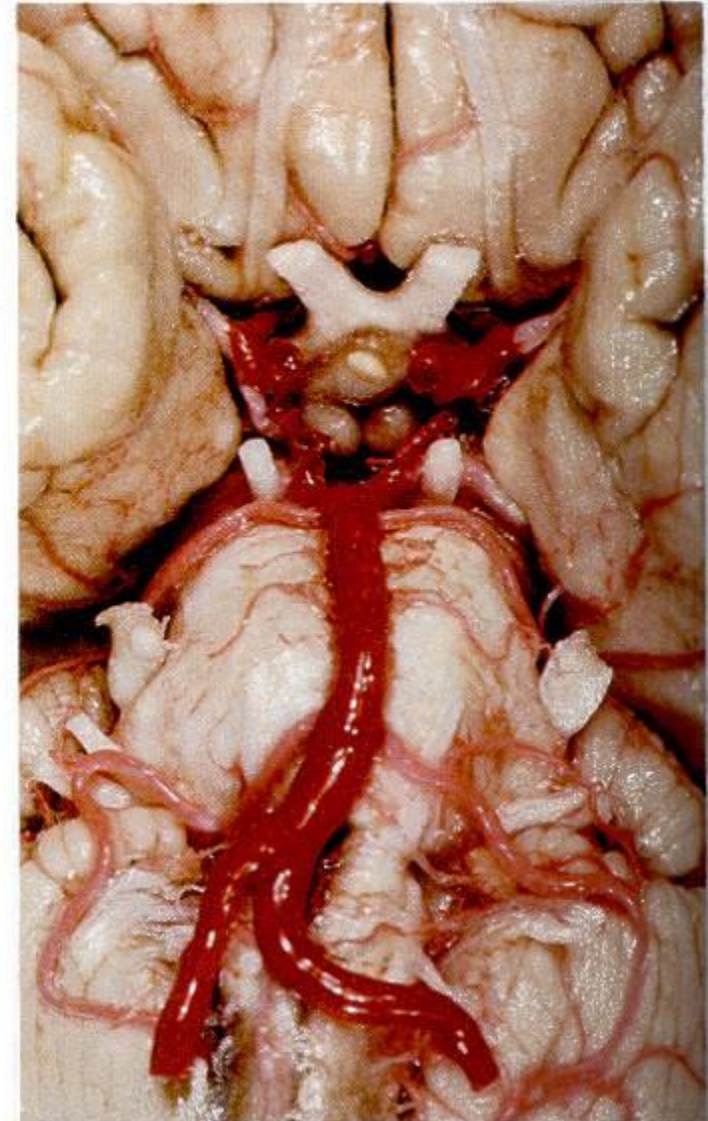
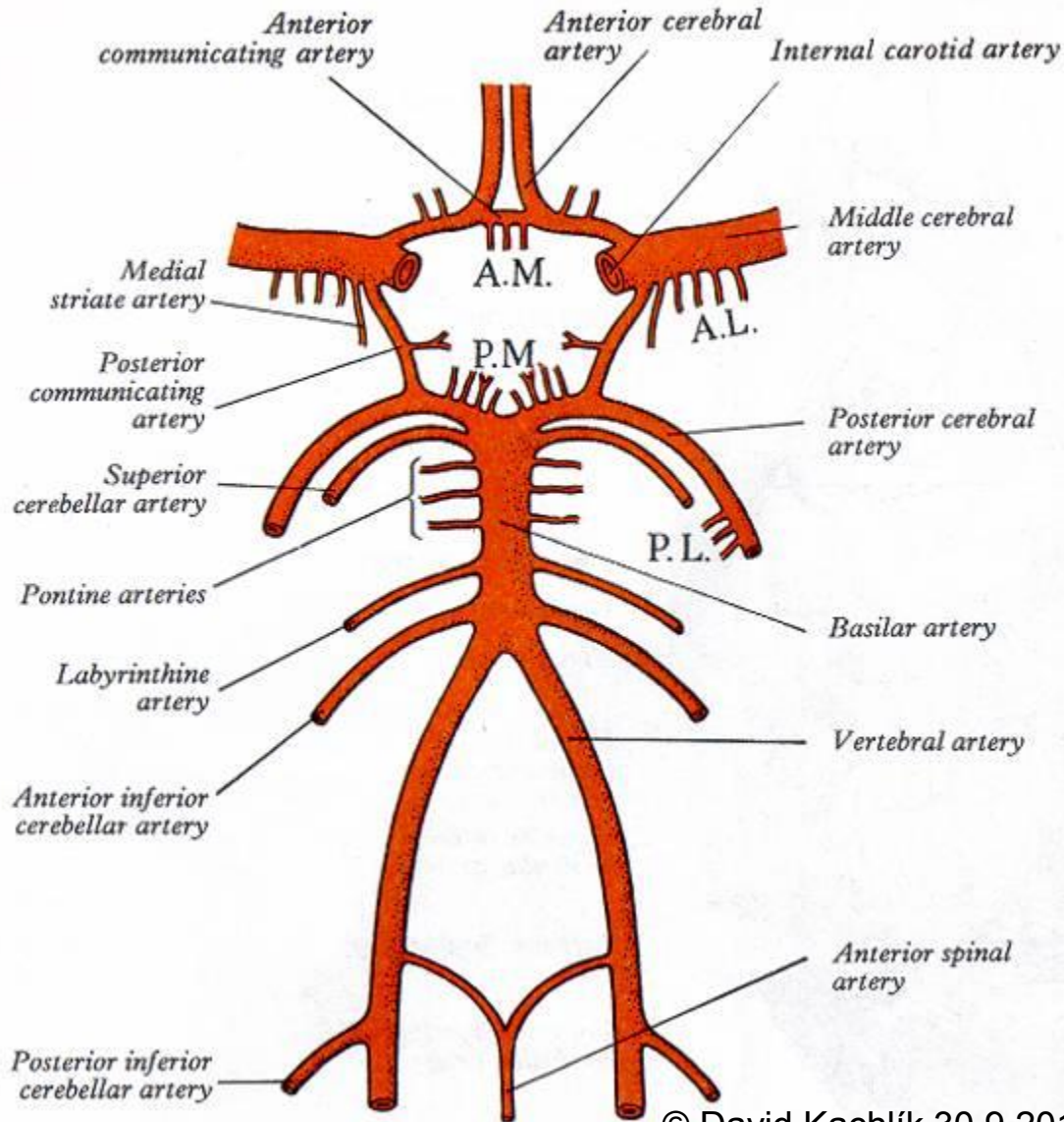
terminal branches:

- **a. cerebri anterior**
- **a. cerebri media**

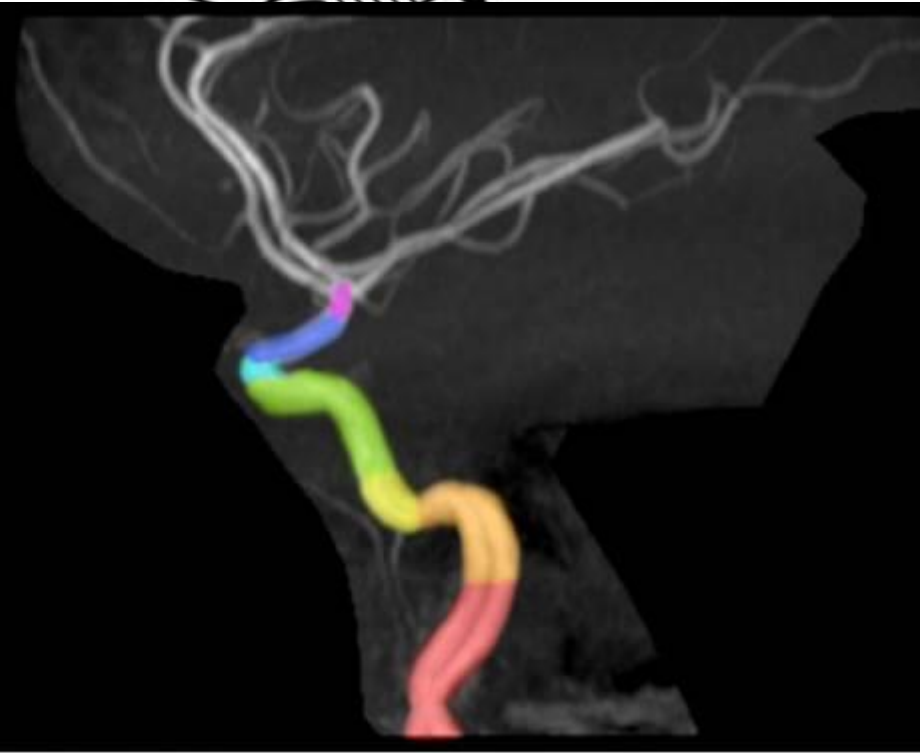
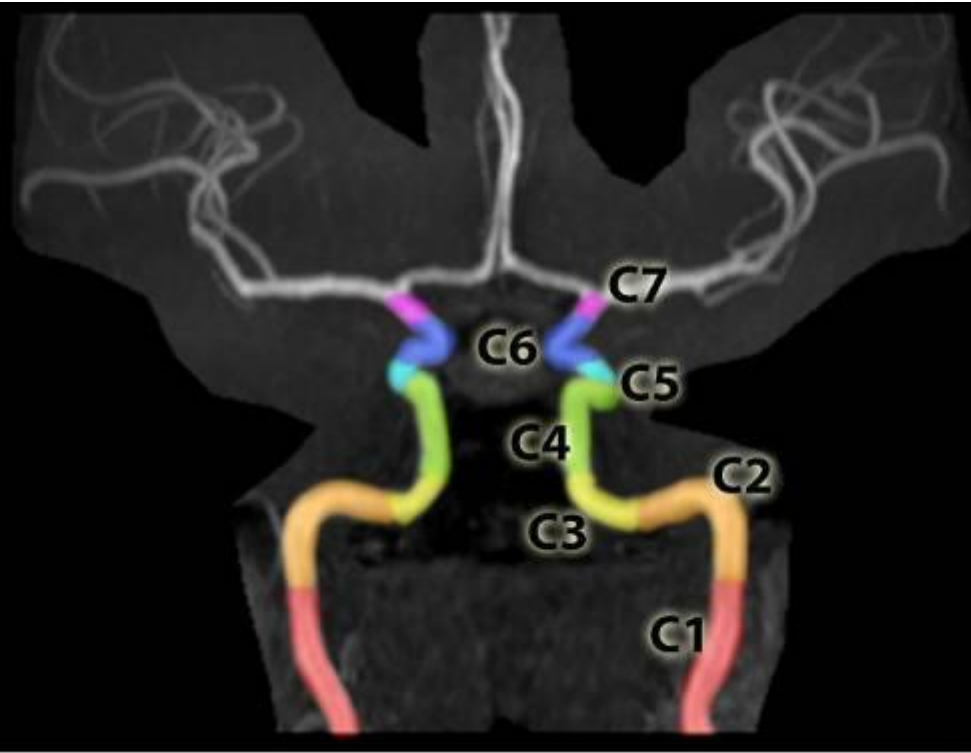


circulus arteriosus cerebri Willisii

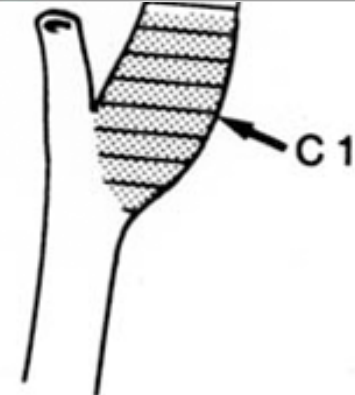
CIRCULUS ARTERIOSUS CEREBRI *WILLISI*



Clinical division of ACI



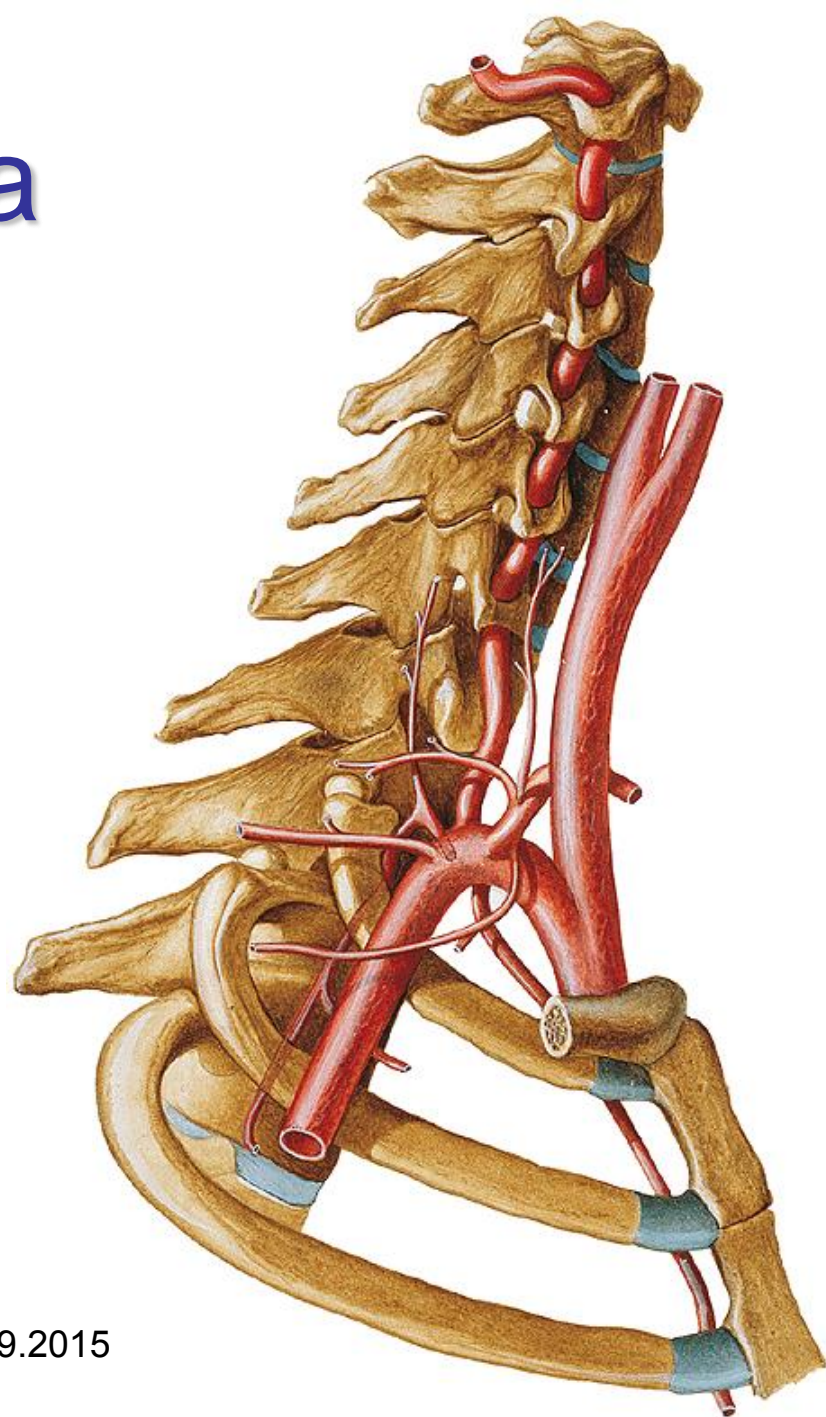
C6 = ophthalmic segment
C7 = communicating segment



Reprinted with permission from Osborn AG: **Diagnostic Cerebral Angiography**, ed 2, Lippincott Williams & Wilkins, Philadelphia, 1999. © David Kachlík 30.9.2015

Arteria subclavia

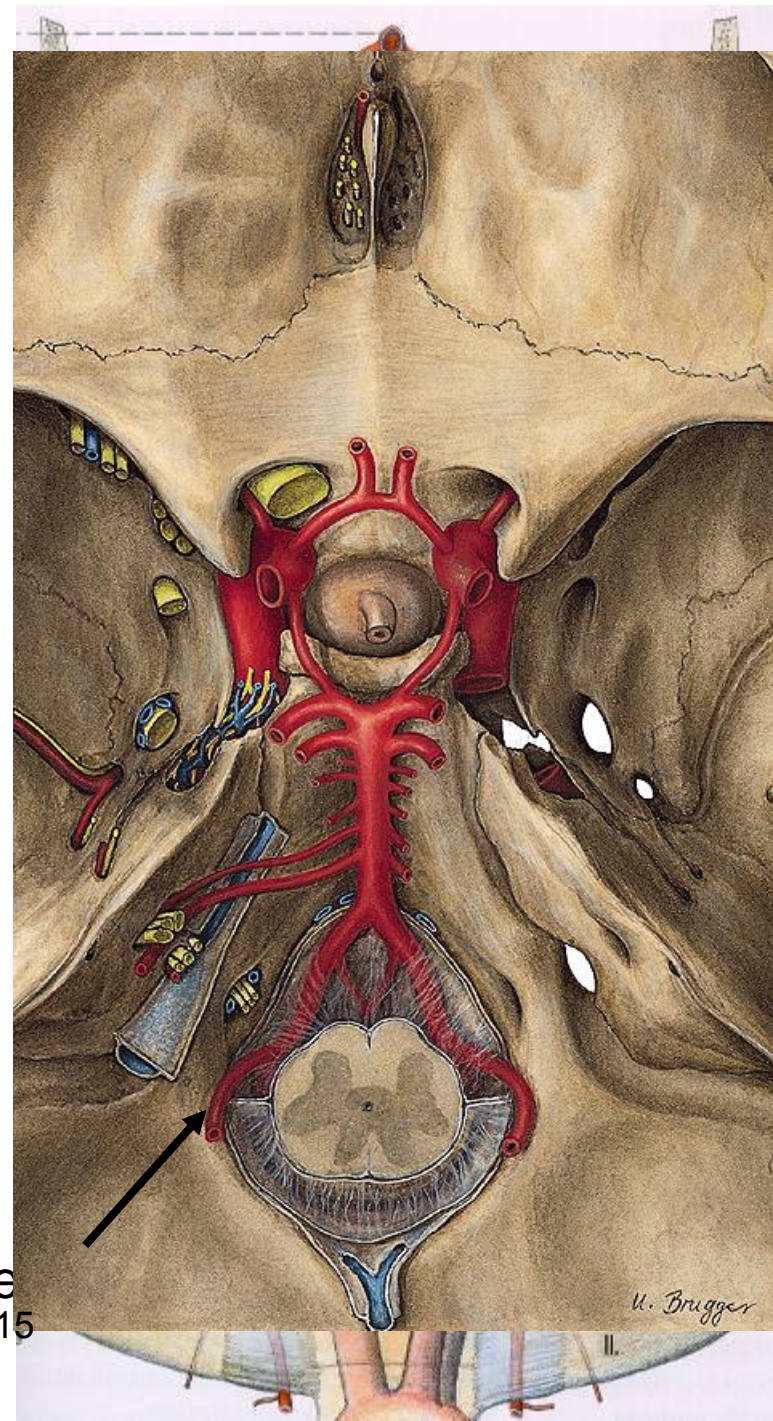
- pars intrascalenica
 - **a. vertebralis**
 - a. thoracica interna
 - truncus thyrocervicalis
- pars interscalenica
 - truncus costocervicalis
- pars extrascalenica
 - (a. transversa coli)



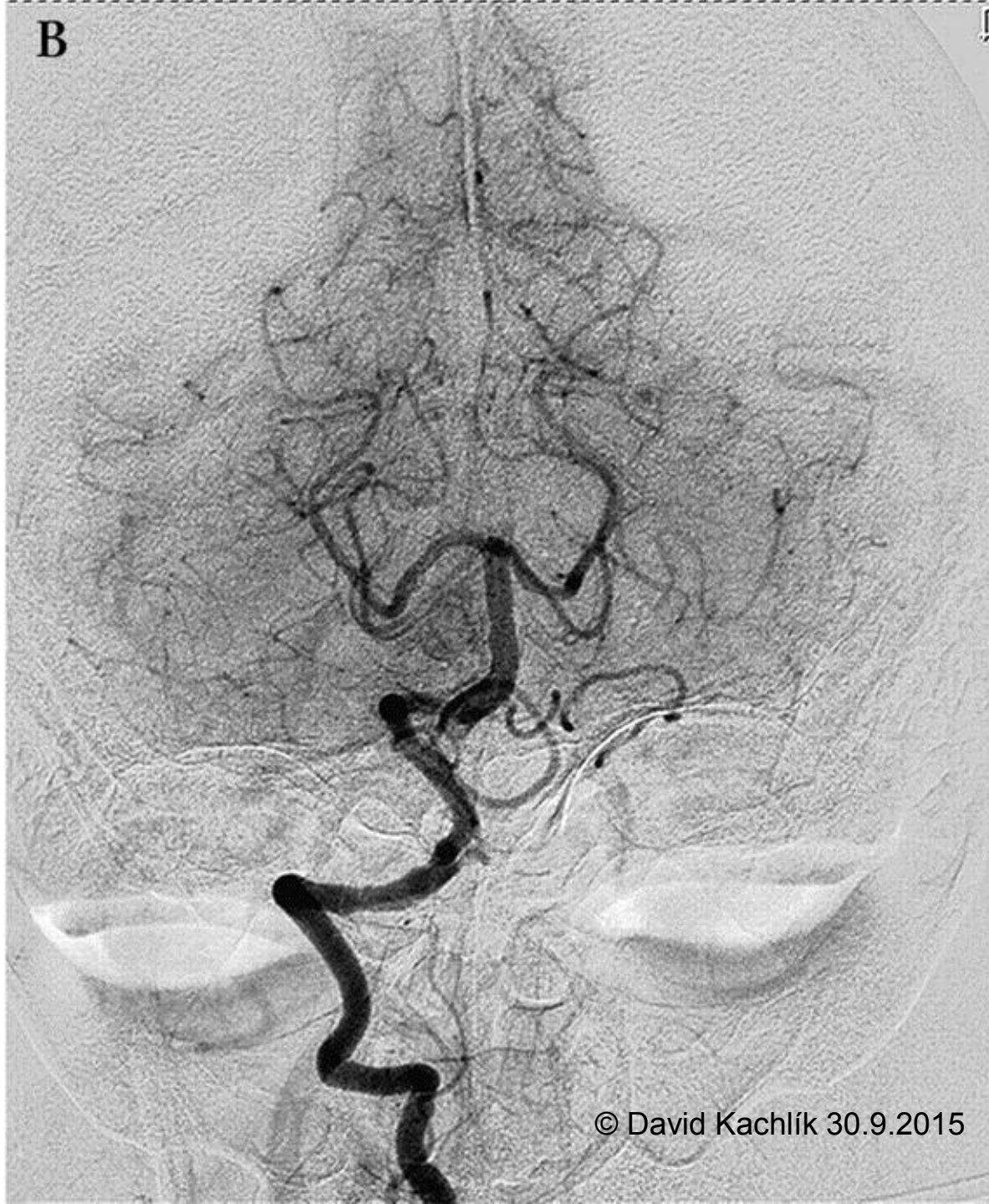
Arteria vertebralis

- pars prevertebralis
- pars cervicalis s. transversaria
 - forr. transversaria C6-C1
 - rr. spinales et musculares
- pars atlantica
 - sulcus a.v. (canalis a.v.)
 - membrana atlantooccipitalis post.
 - foramen magnum
- pars intracranialis
 - rr. meningei
 - a. inferior posterior cerebelli
 - a. spinalis post.
 - a. spinalis ant.
 - unpaired from paired short innominate source arteries

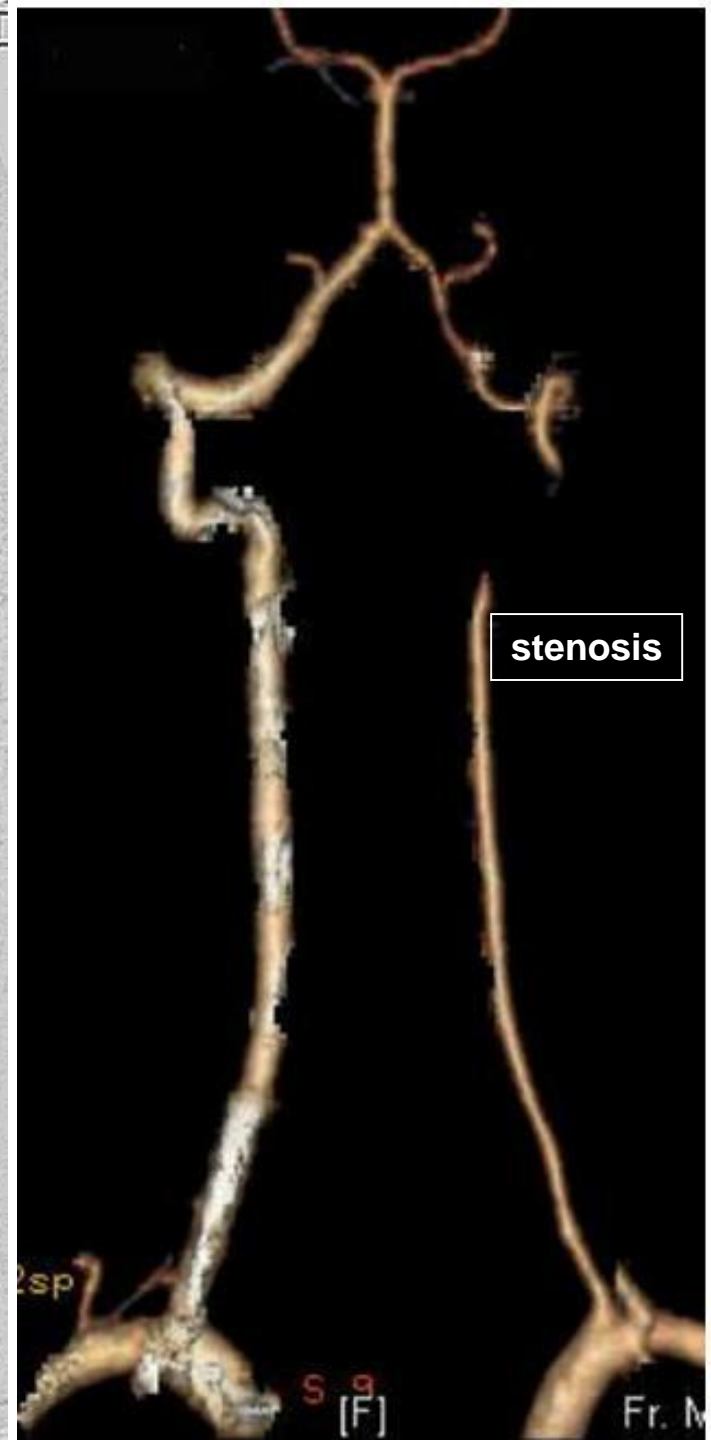© David Kachlík 30.9.2015



B



© David Kachlík 30.9.2015

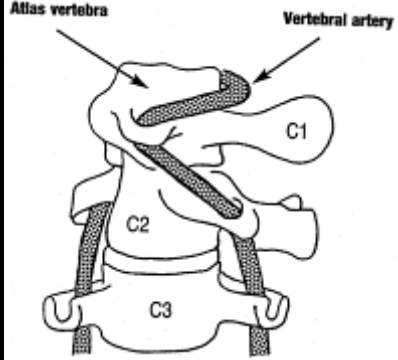


stenosis

sp

S 9 [F]

Fr. M



Posterior cerebral arteries

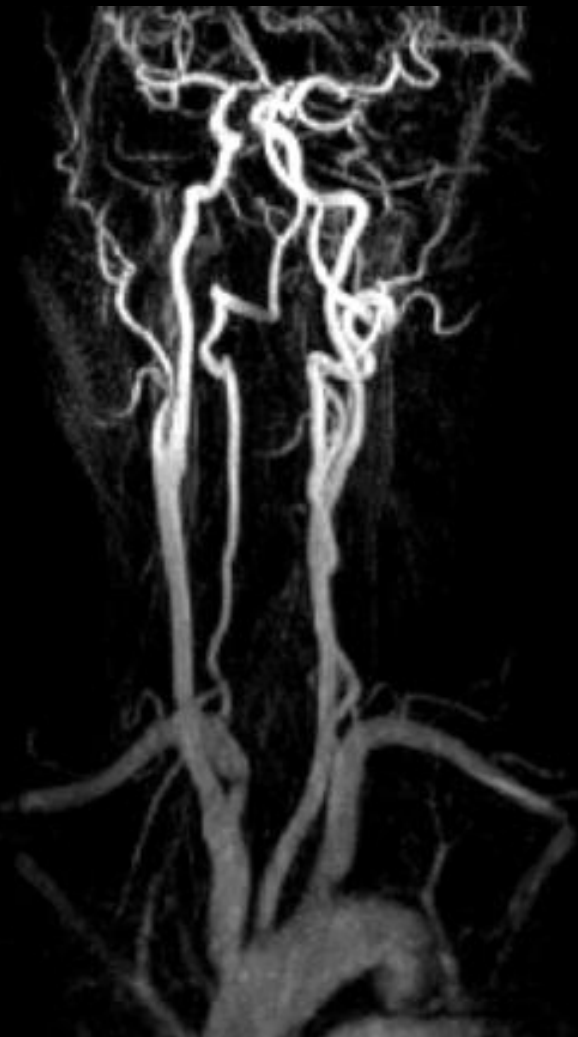
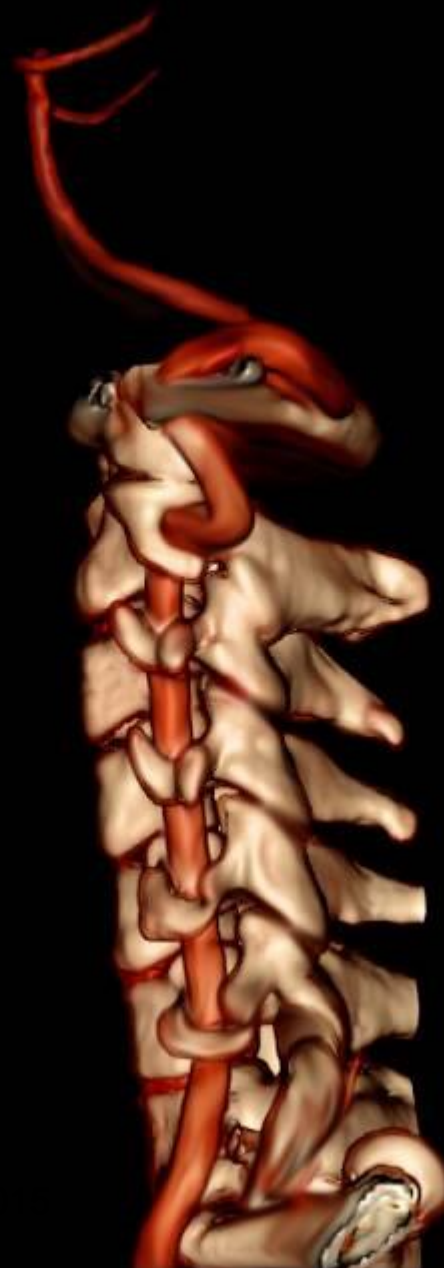Basilar artery

V4 (intradural)

V3 (C2 to dura)

V2 (foraminal)

V1 (pre-foraminal)

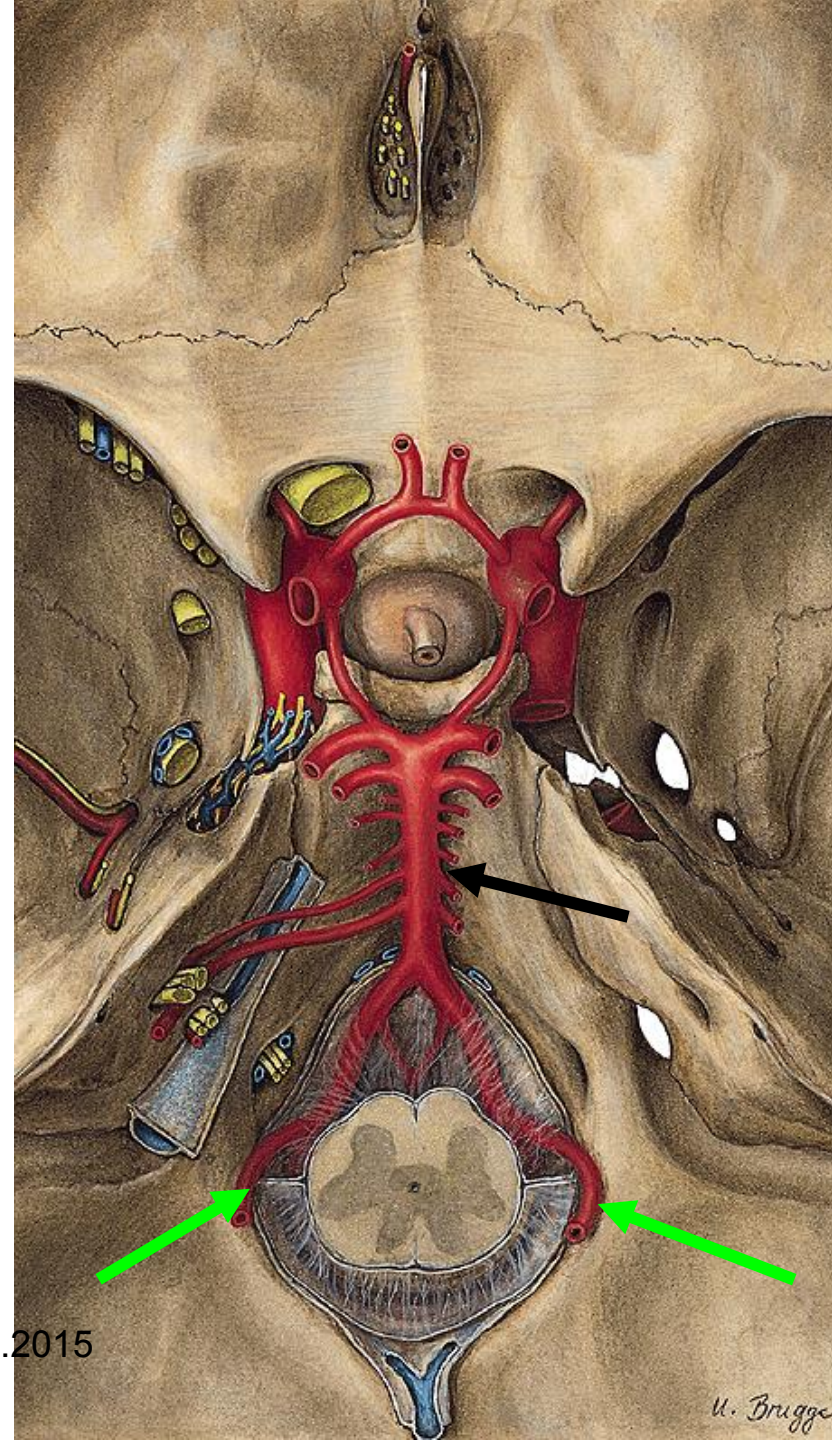


Arteria basilaris

- 2 aa. **vertebrales** → **a. basilaris**
- a. inferior anterior cerebelli
 - a. labyrinthi
- aa. pontis
- aa. mesencephalicae
- a. superior cerebelli
- aa. cerebri posteriores

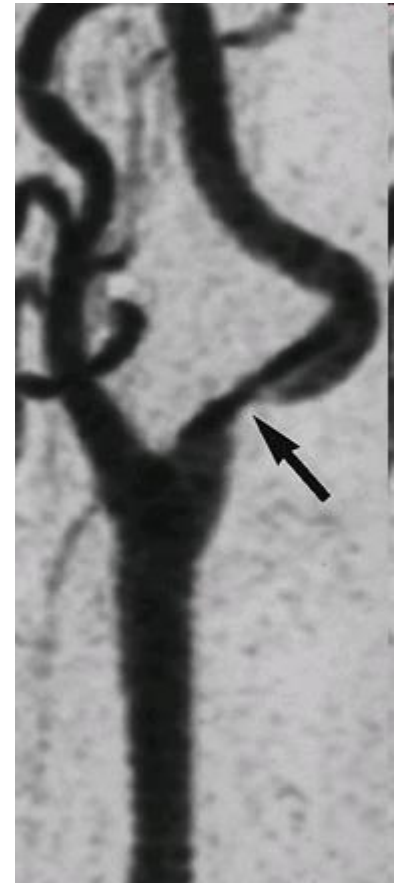circulus arteriosus cerebri
Willisi

© David Kachlík 30.9.2015



Clinical relevance

- *vertebrobasilar insufficiency*
- *beauty parlour syndrome*
 - vertigo
 - diplopia, blurred vision
 - stroke
- *steal syndrome*



S

Cor>Sag 39
>Tra -7

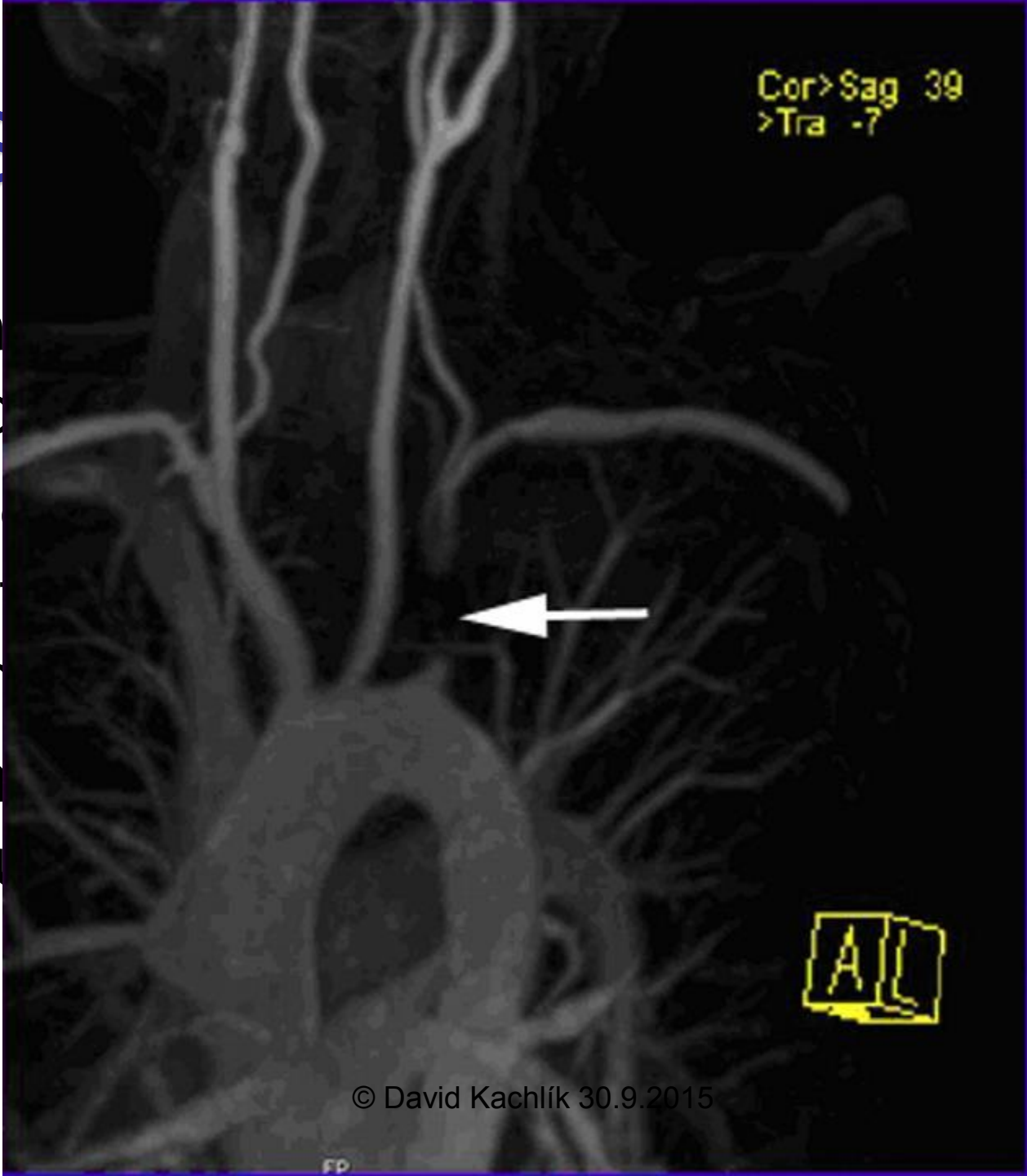ne

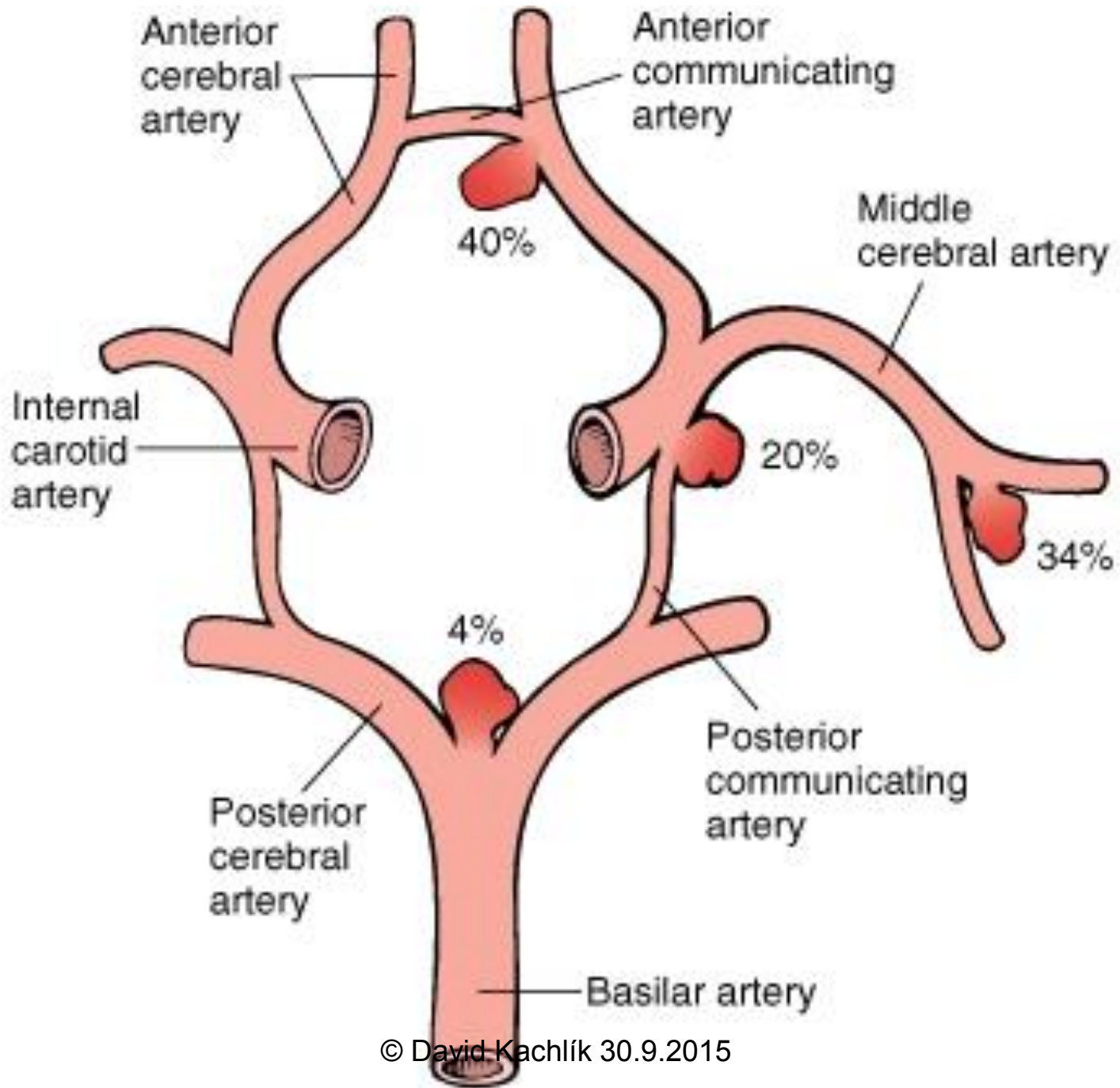
d

s of

tent

- clin
sup
- rev
ver
cer
- syn
clat





© David Kachlík 30.9.2015

A
A

M
M

A
A

P
P
P

S
S

L

ery
ent
A2

ery
ent
A1

ery
CA

ery
oA

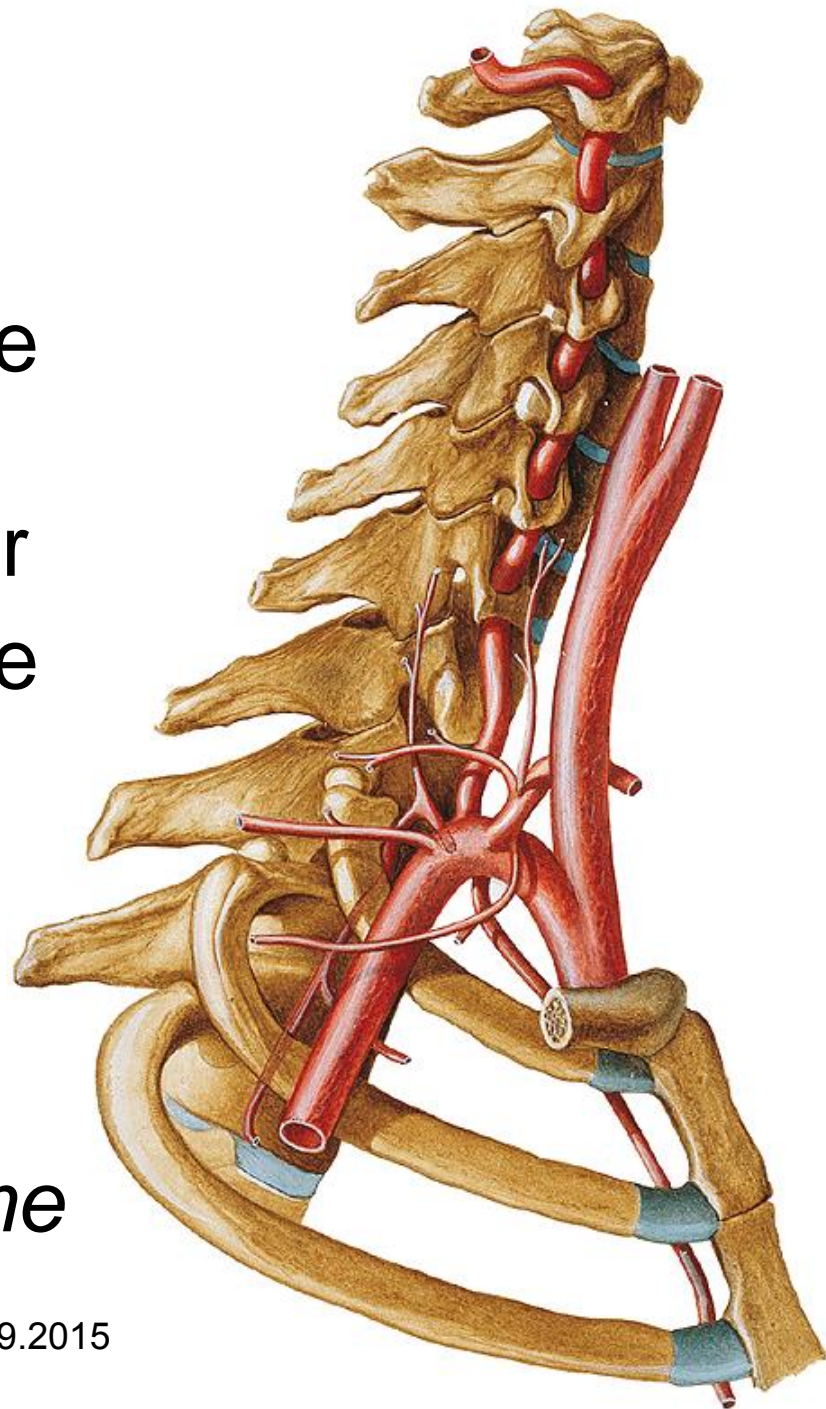
ery
ent
P2

ery
BA

ide

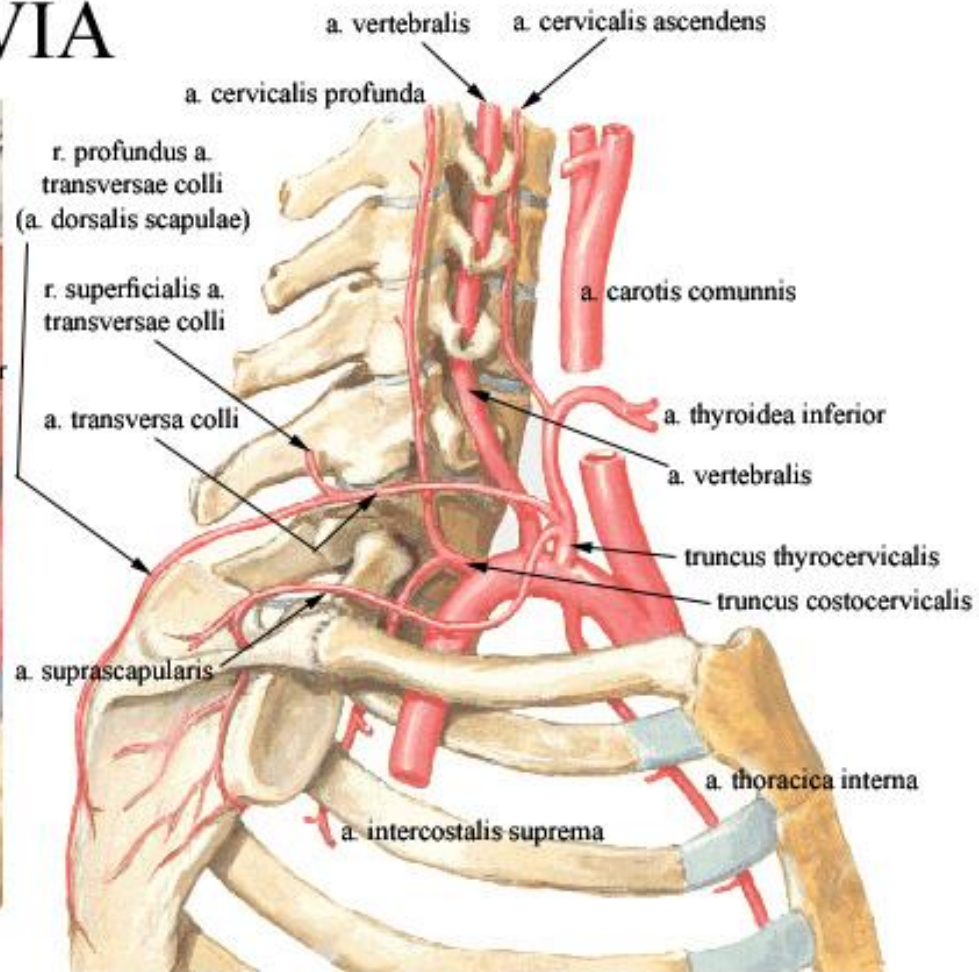
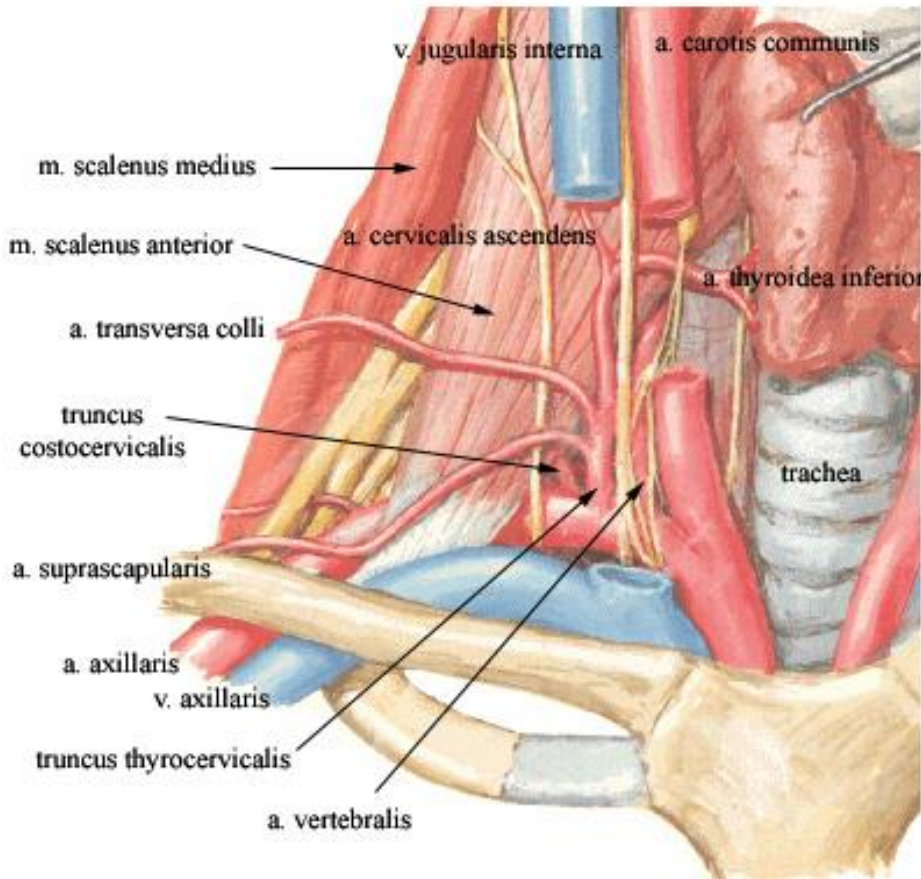
Arteria subclavia

- sulcus arteriae subclaviae pulmonis
- apertura thoracis superior
- sulcus arteriae subclaviae costae primae
- fissura scalenorum
- *thoracic outlet syndrome*
- *subclavian steal syndrome* (a. vertebralis)



Arteria subclavia

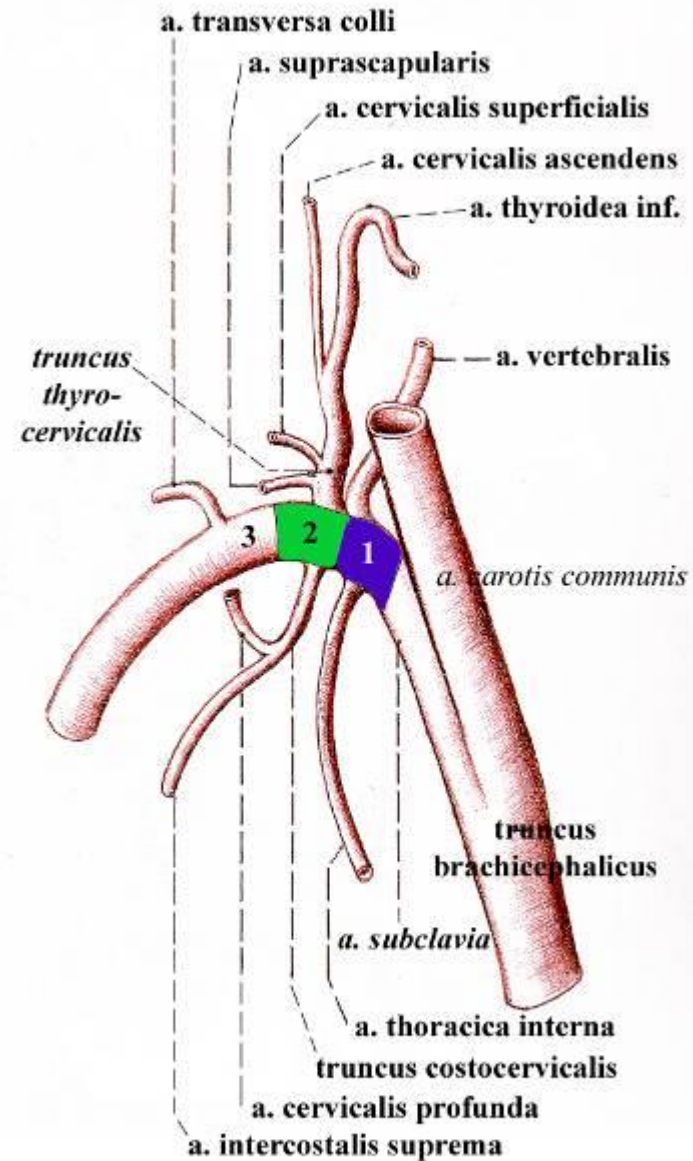
ARTERIA SUBCLAVIA



Arteria subclavia

- pars intrascalenica (1)
 - a. vertebralis
 - a. thoracica interna
 - truncus thyrocervicalis
- pars interscalenica (2)
 - truncus costocervicalis
- pars extrascalenica (3)
 - (a. transversa colli)

some branches are variable



- 1 - pars INTRAscalenica
- 2 - pars INTERScalenica
- 3 - pars EXTRAscalenica

A. thoracica interna

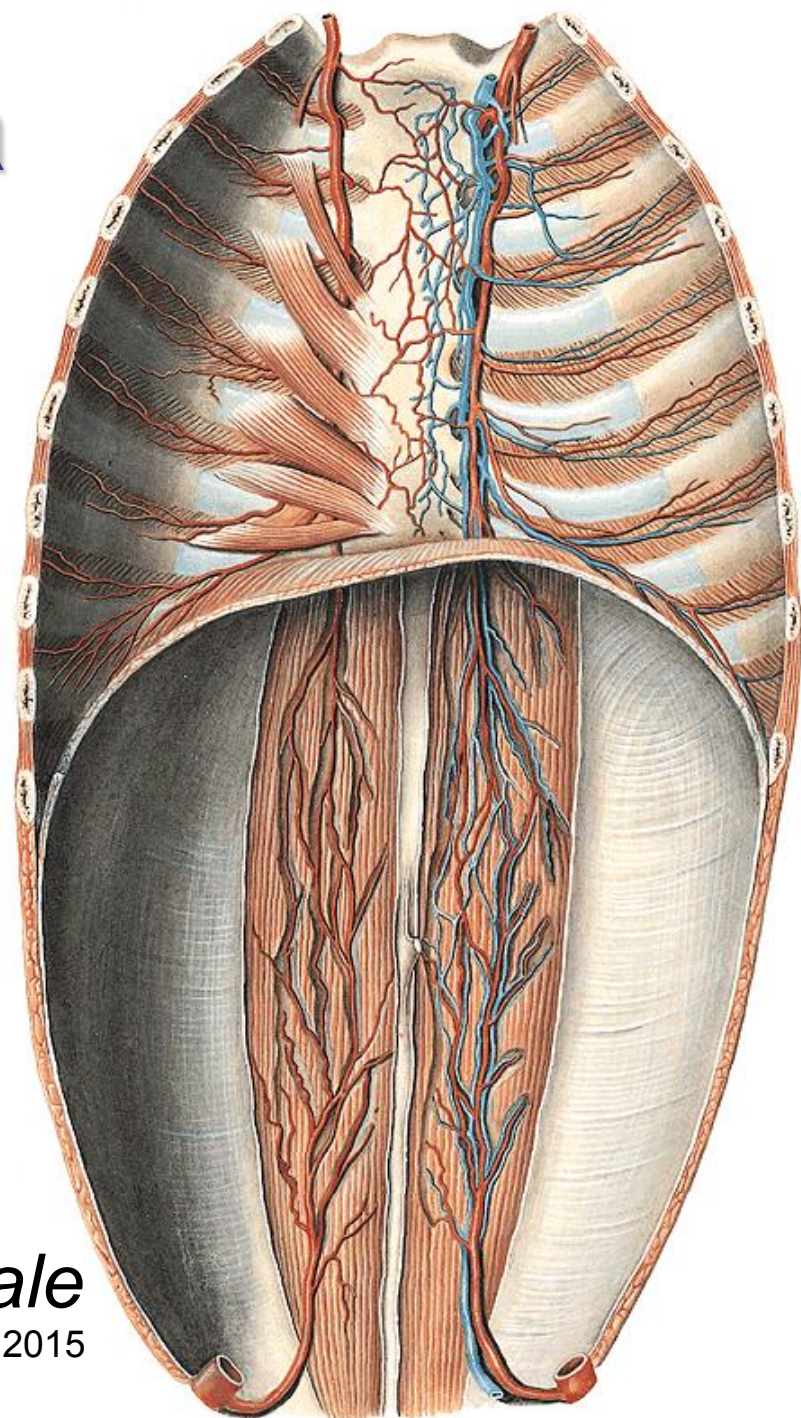
- rr. mediastinales
- rr. thymici
- a. pericardiophrenica
- rr. sternales
- rr. perforantes
 - rr. mammarii mediales
- (r. costalis lateralis)
- rr. intercostales anteriores

terminal branches:

- a. musculophrenica
- a. epigastrica superior

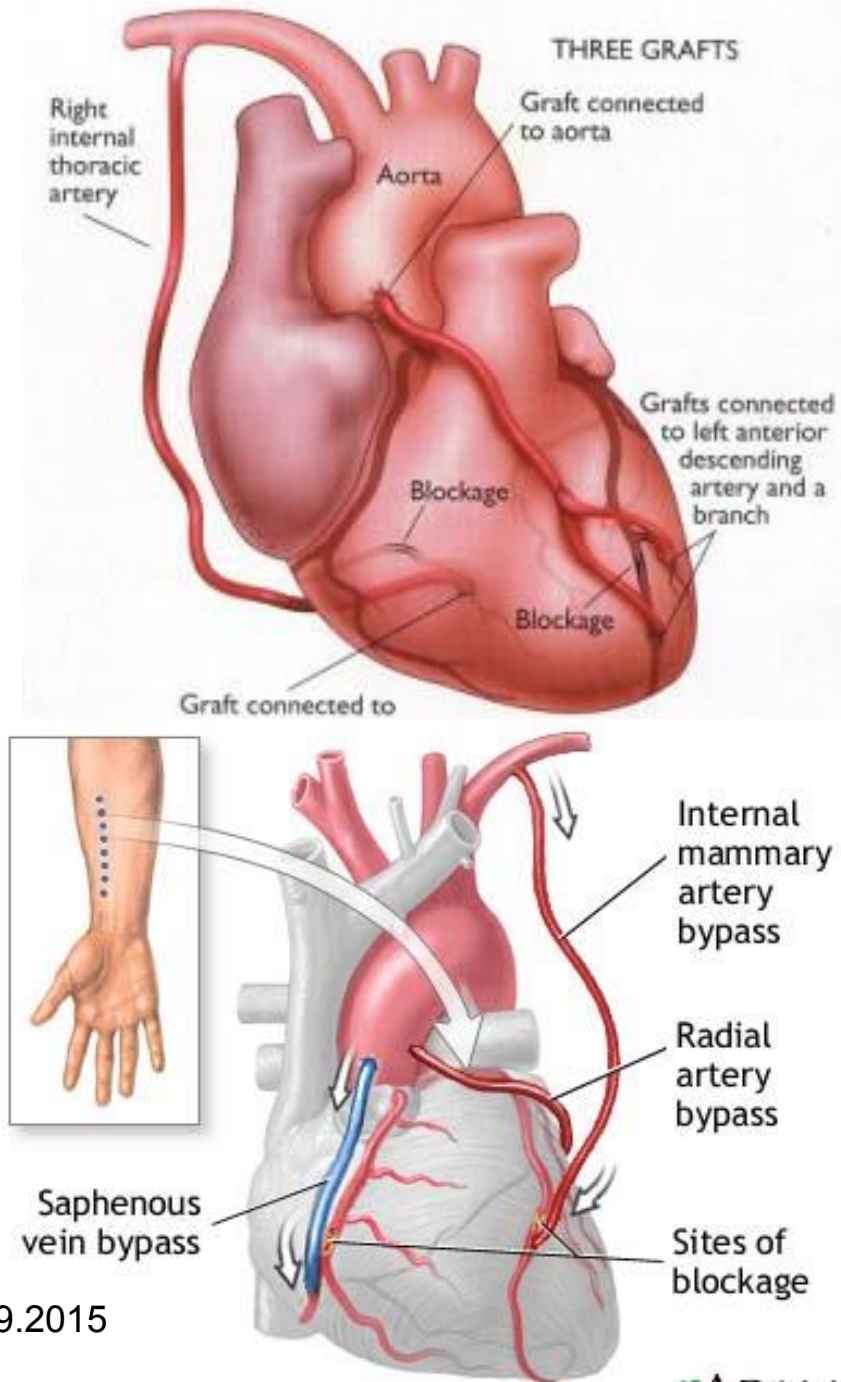
ventral to trigonum sternocostale

© David Kachlík 30.9.2015



A. thoracica interna

- mediastinum superius
 - 1st layer
- mediastinum inf. anterius
- obsolete „a. mammaria int.“
- clinical abbreviation „LIMA, RIMA“
- elastic artery
- *by-pass of aa. coronariae*



A. thoracica interna

Coronary Artery Bypass Graft

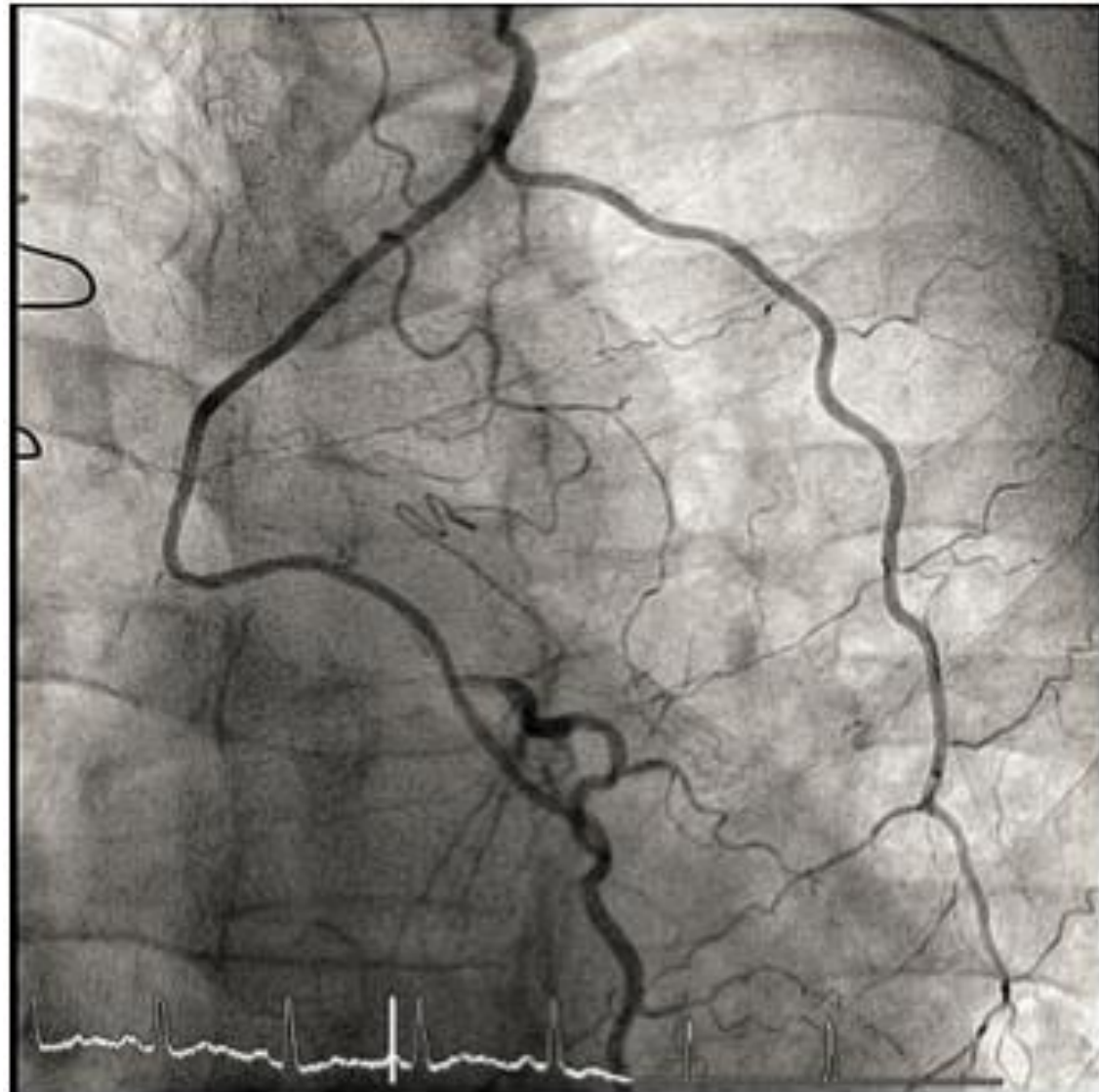
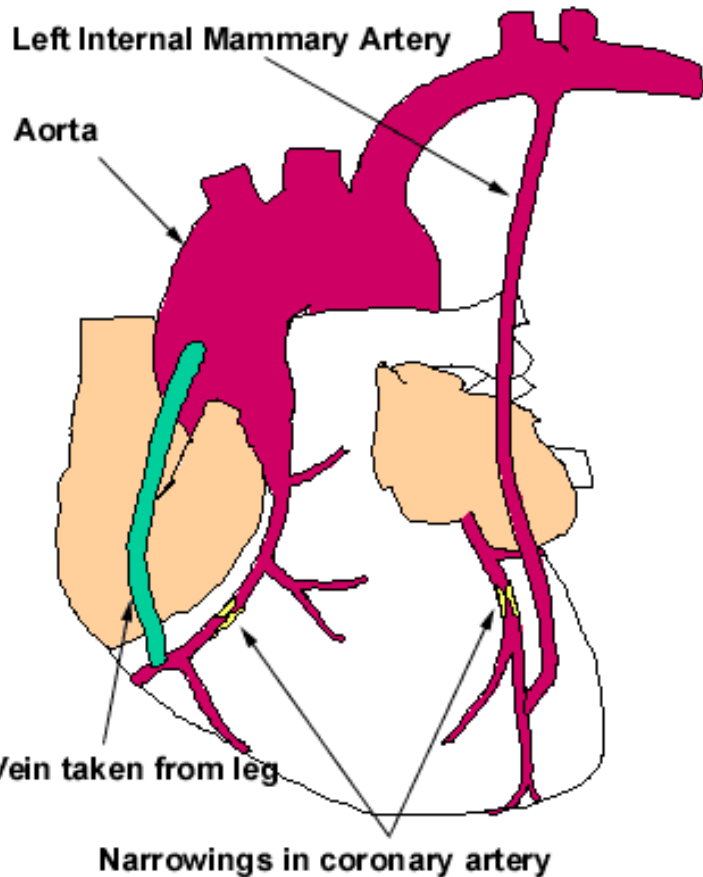


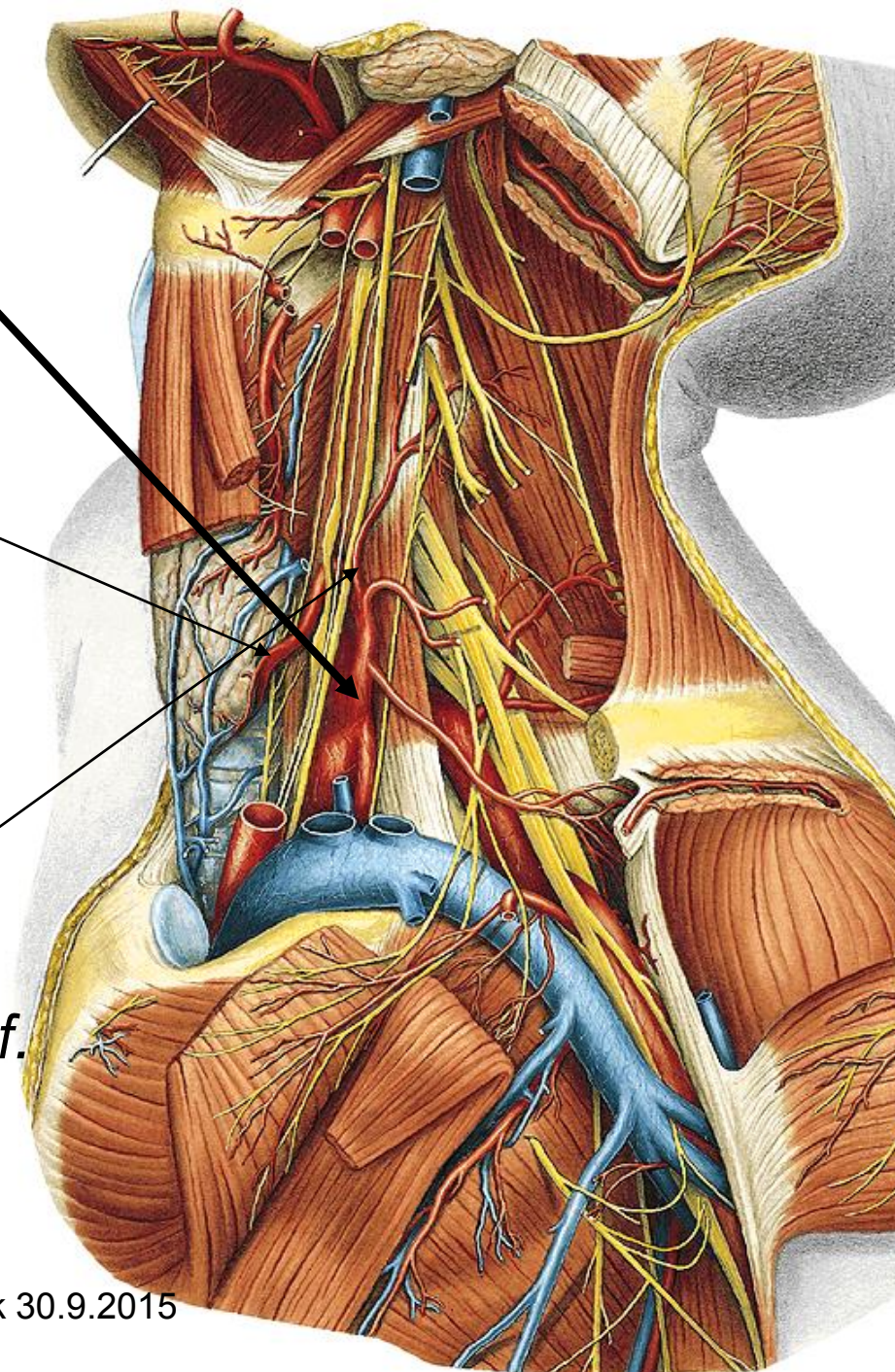
Figure 1. Cineangiogram with a 4 French Judkins Right catheter showing a patent left internal mammary artery (LIMA) graft to the left anterior descending coronary artery and a large intercostal branch arising from the proximal part of the LIMA.

Truncus thyrocervicalis

- a. thyroidea inf.
 - a. laryngea inf.
 - rr. glandulares
 - rr. oesophageales
 - rr. pharyngeales

crossed with n. laryngeus recurrens

- a. cervicalis ascendens
*often branch from a. thyroidea inf.
together with n. phrenicus on
ventral aspect of m. scalenus anterior*



Truncus thyrocervicalis

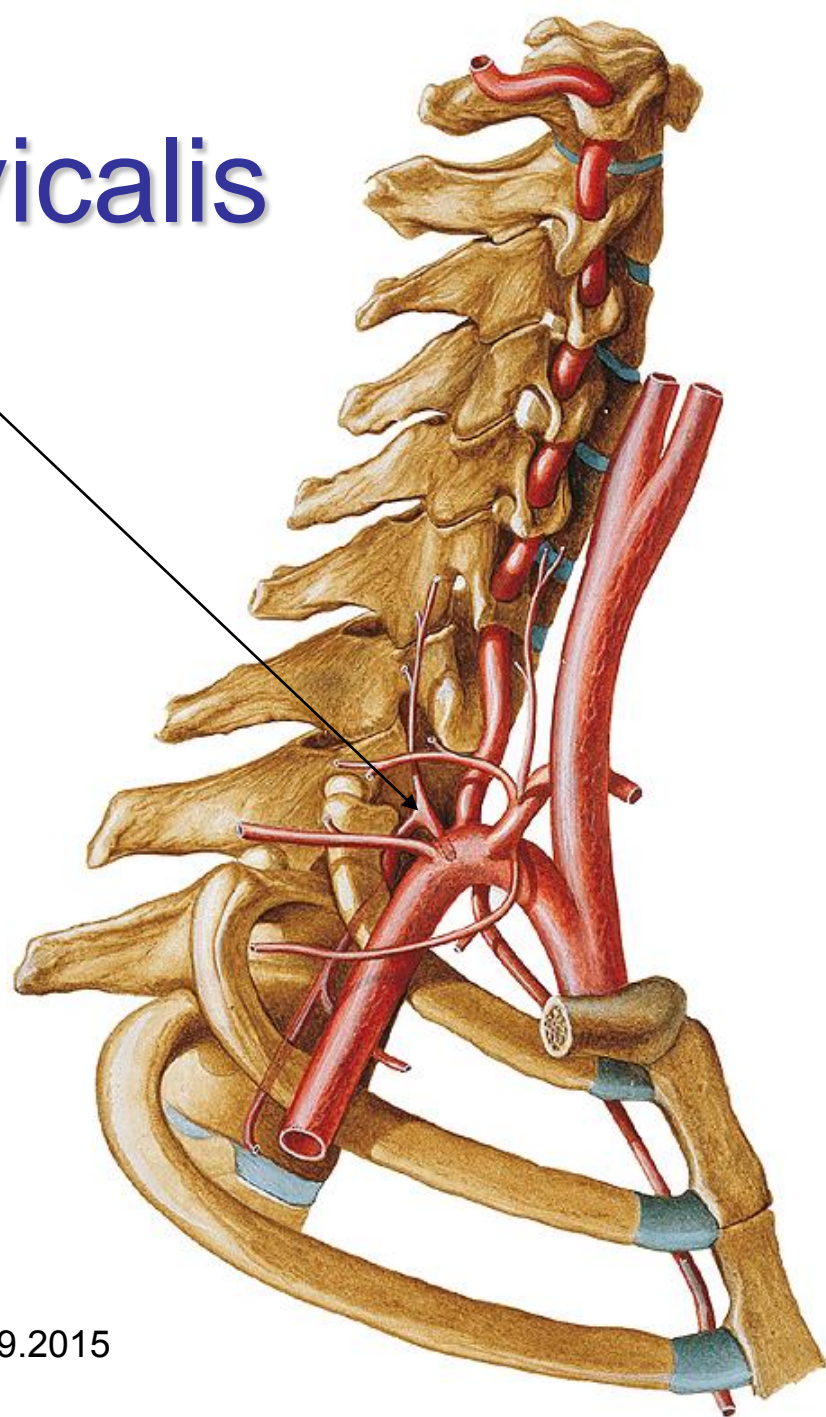
- a. suprascapularis (86% from TTC)
- a. transversa colli (36%)
 - r. superficialis
(as a. cervicalis superficialis in 83% from TTC)
 - r. profundus
(as a. dorsalis scapulae in 36% from TTC, otherwise from pars extrascalenica arteriae subclaviae)

great variability without clinical relevance

Truncus costocervicalis

from pars interscalenica

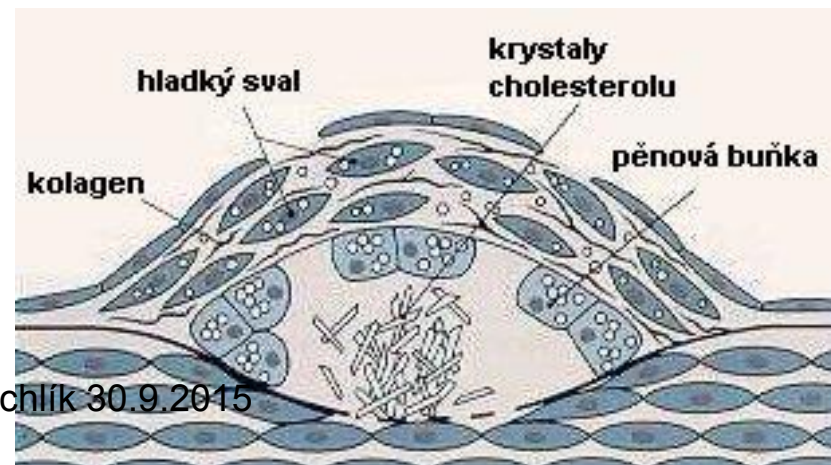
- a. cervicalis profunda
trigonum omotrapietium
- a. intercostalis suprema
 - a. intercostalis posterior prima
 - a. intercostalis posterior secunda



Clinical remarks

atherosclerosis

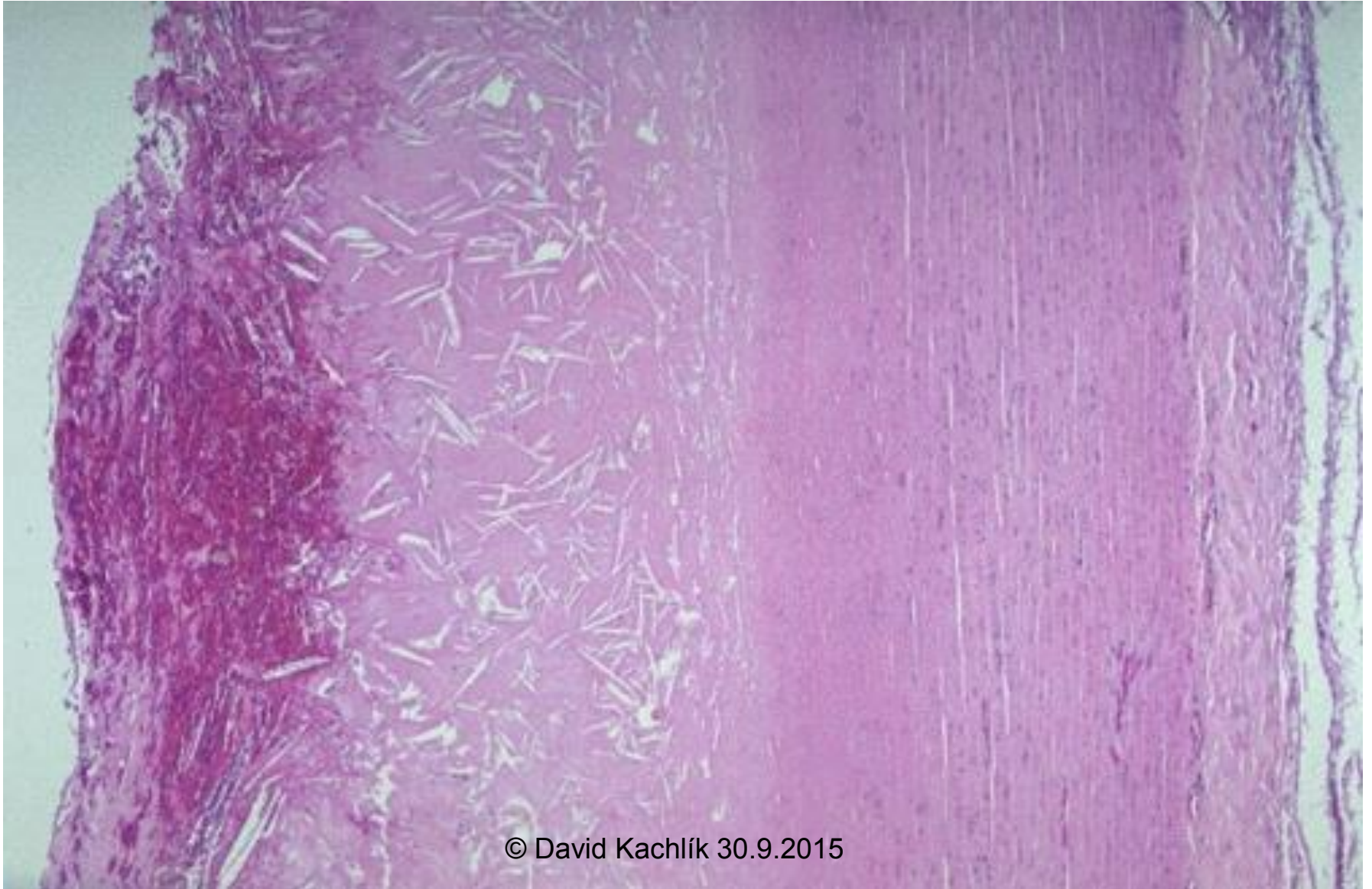
- causes 50% of death in civilized countries
- combination of: arterial tunica intima changes + deposits of lipids, polysacharides, thrombocytes
- subintimal thickening is formed = atheroma
- later fibrotization and calcification occur ► thrombotization ► vessel closure ► hypoxia



Atherosclerosis

- risk factors:
 - ↑LDL
 - hypertension
 - smoking
 - DM
 - obesity
 - lack of movements

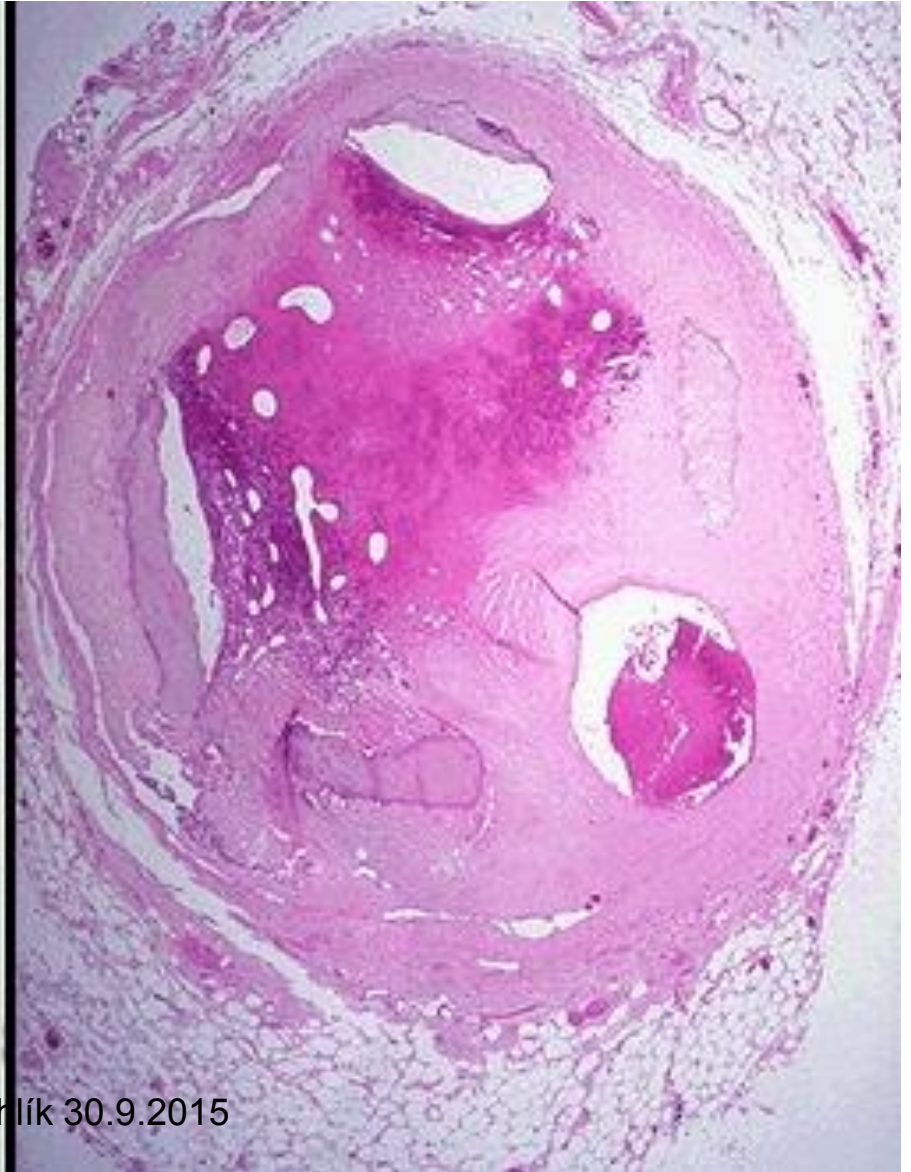
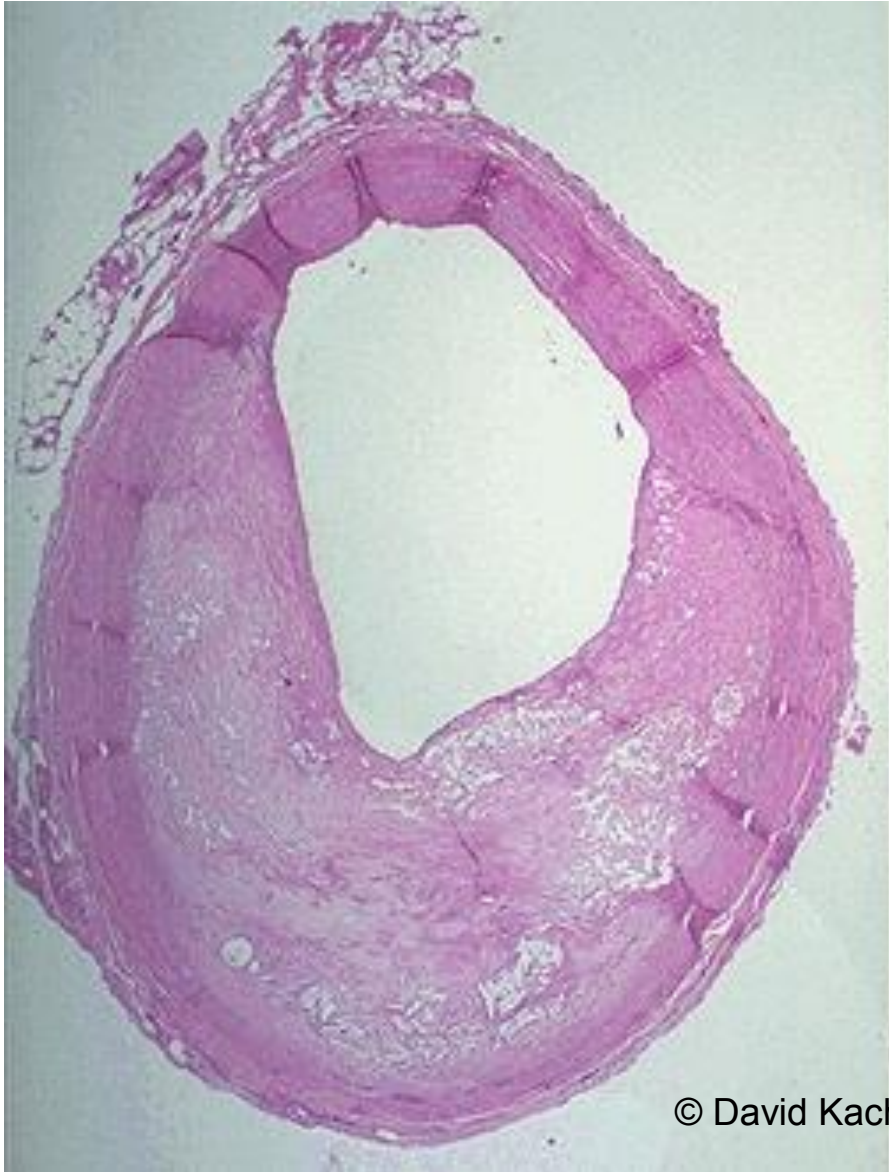Aortal atheroma (HE)



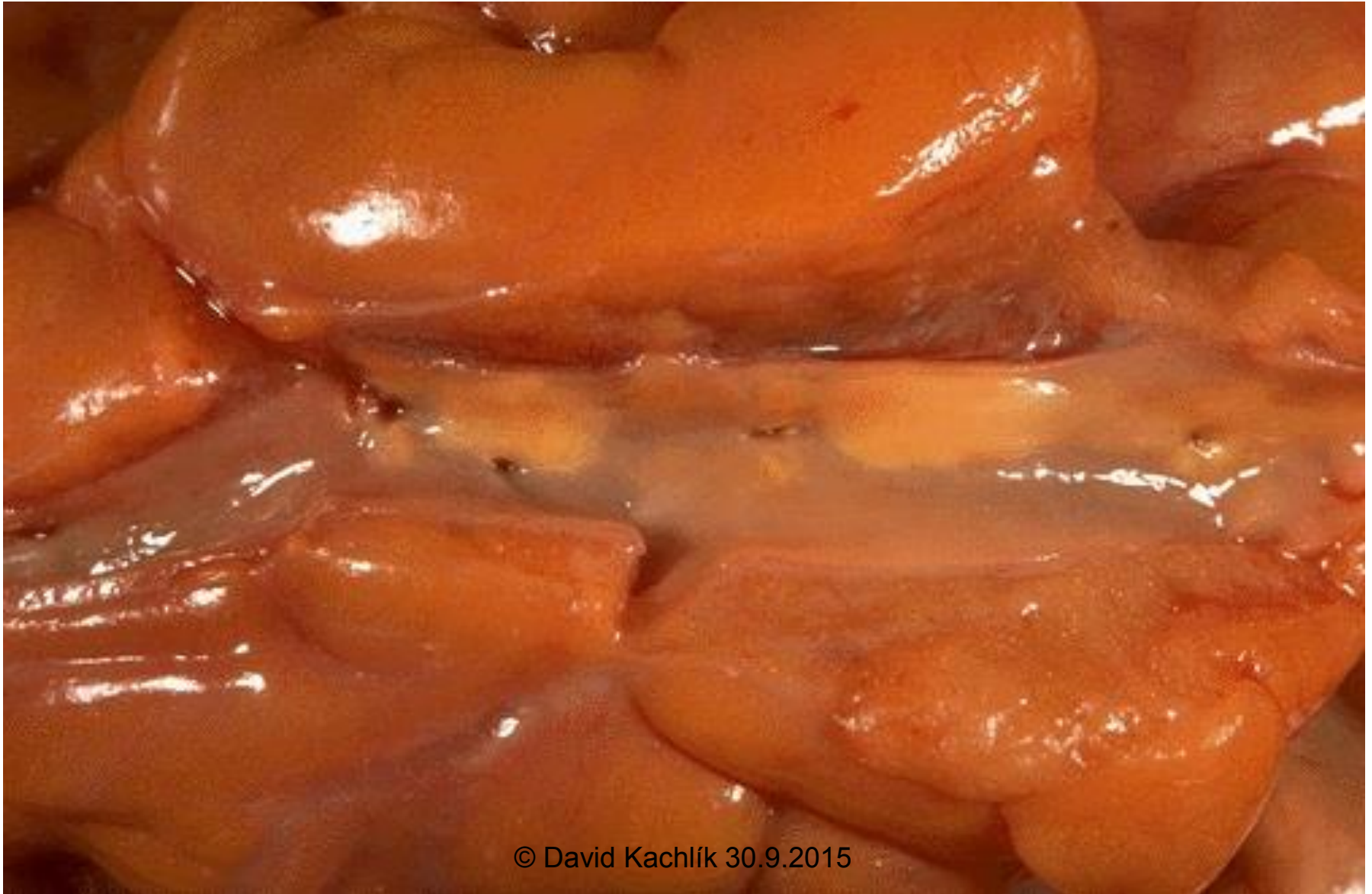© David Kachlík 30.9.2015

Healthy a. coronaria

Atheroma

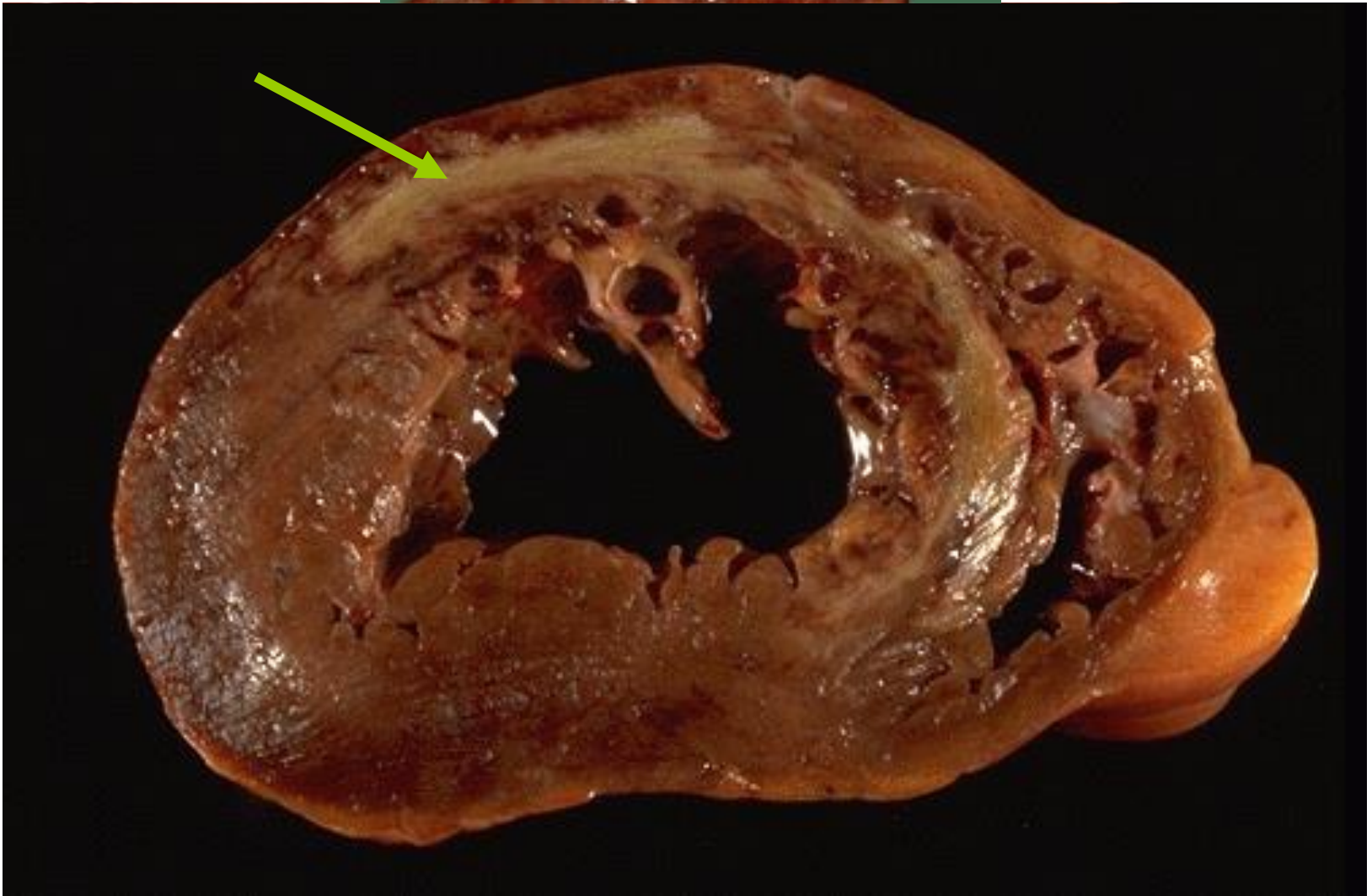


Lipid plaques



© David Kachlík 30.9.2015

Thrombosis → infarction



Atherosclerosis (AL)

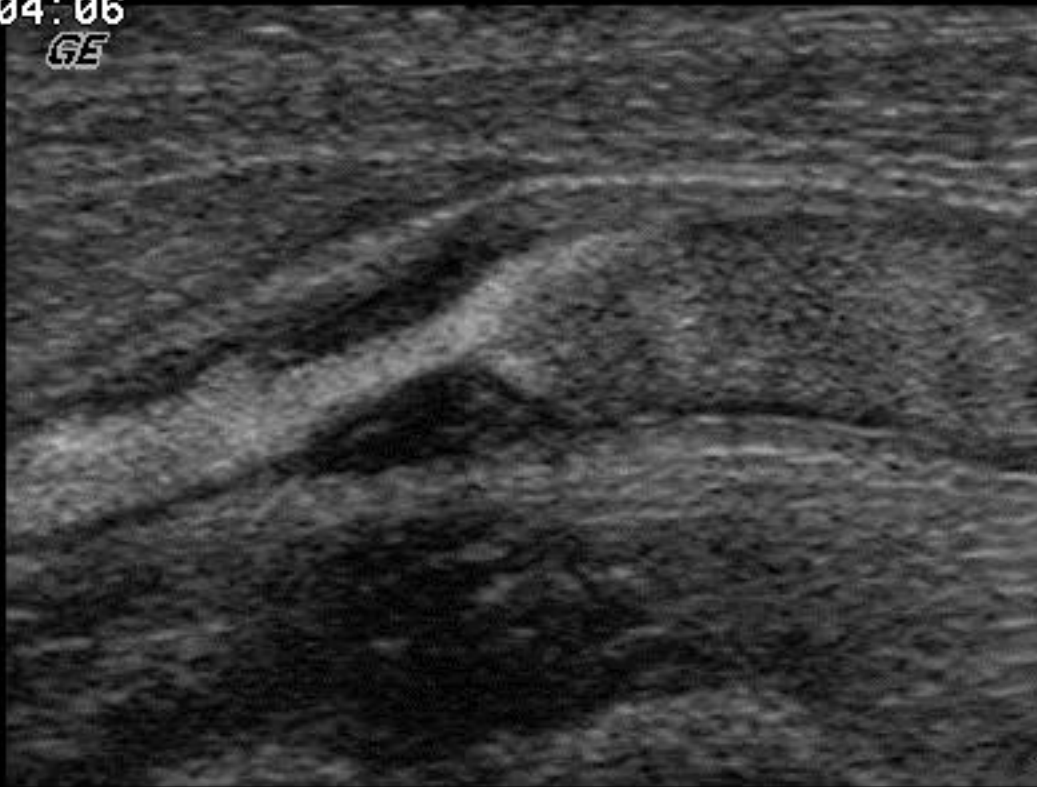
- AT is clinically silent until critical stenosis / thrombosis / aneurysma/ emboly occurs
- insufficient supply of peripheral tissue
 - intermitent claudication, angina pectoris
 - sudden closure: AIM, CMP

diagnosis: angiography, ultrasound examination

therapy: ↓ risk factors, ↓ LDL (statins)

BAPTIST MED CTR
IM#1 +2:04:06

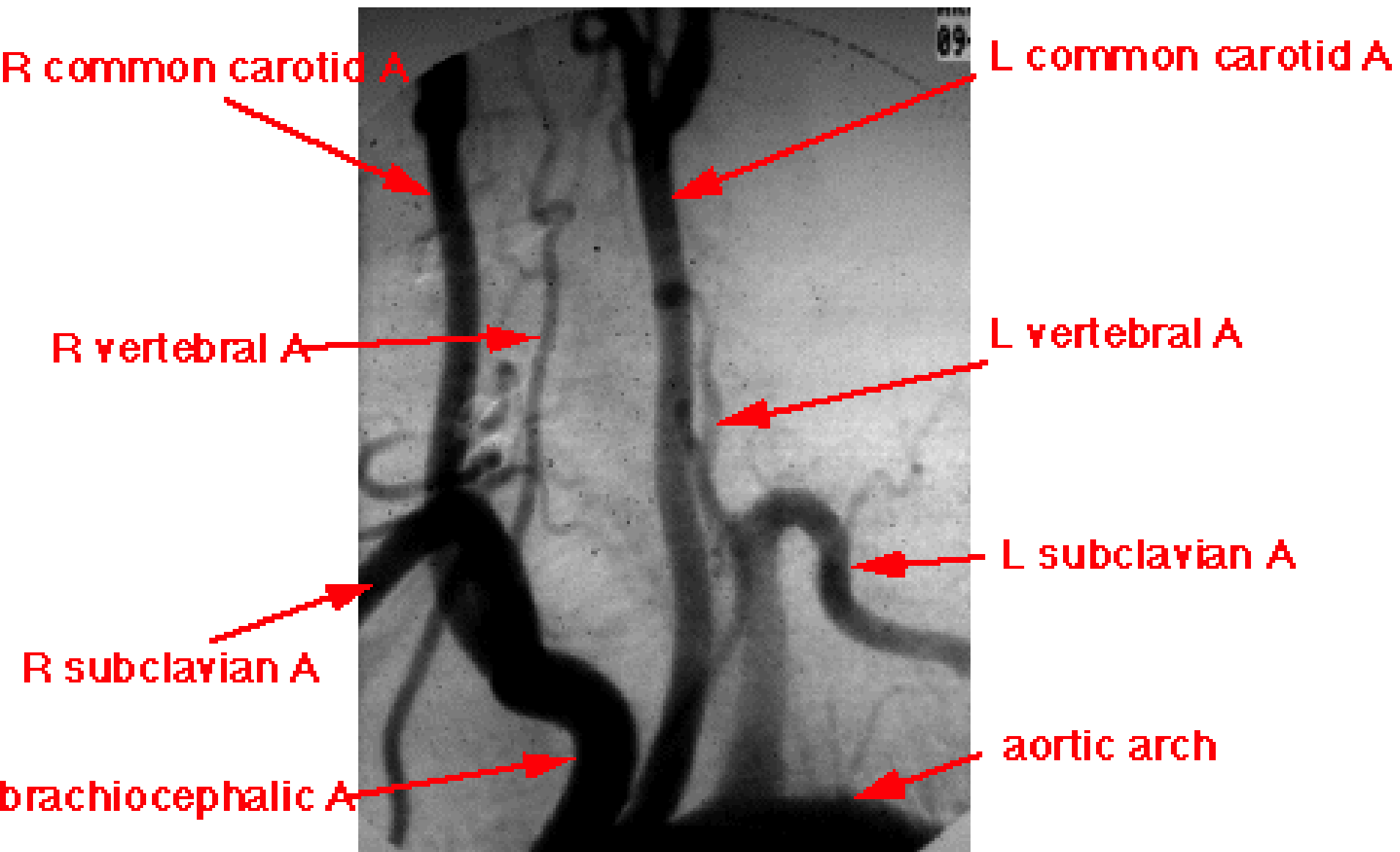
D0.3cm 5739L
RENAL
CINE 0439
29G
60DR
E3 ME A2



B - FLOW
INTERNAL CAROTID STENOSIS

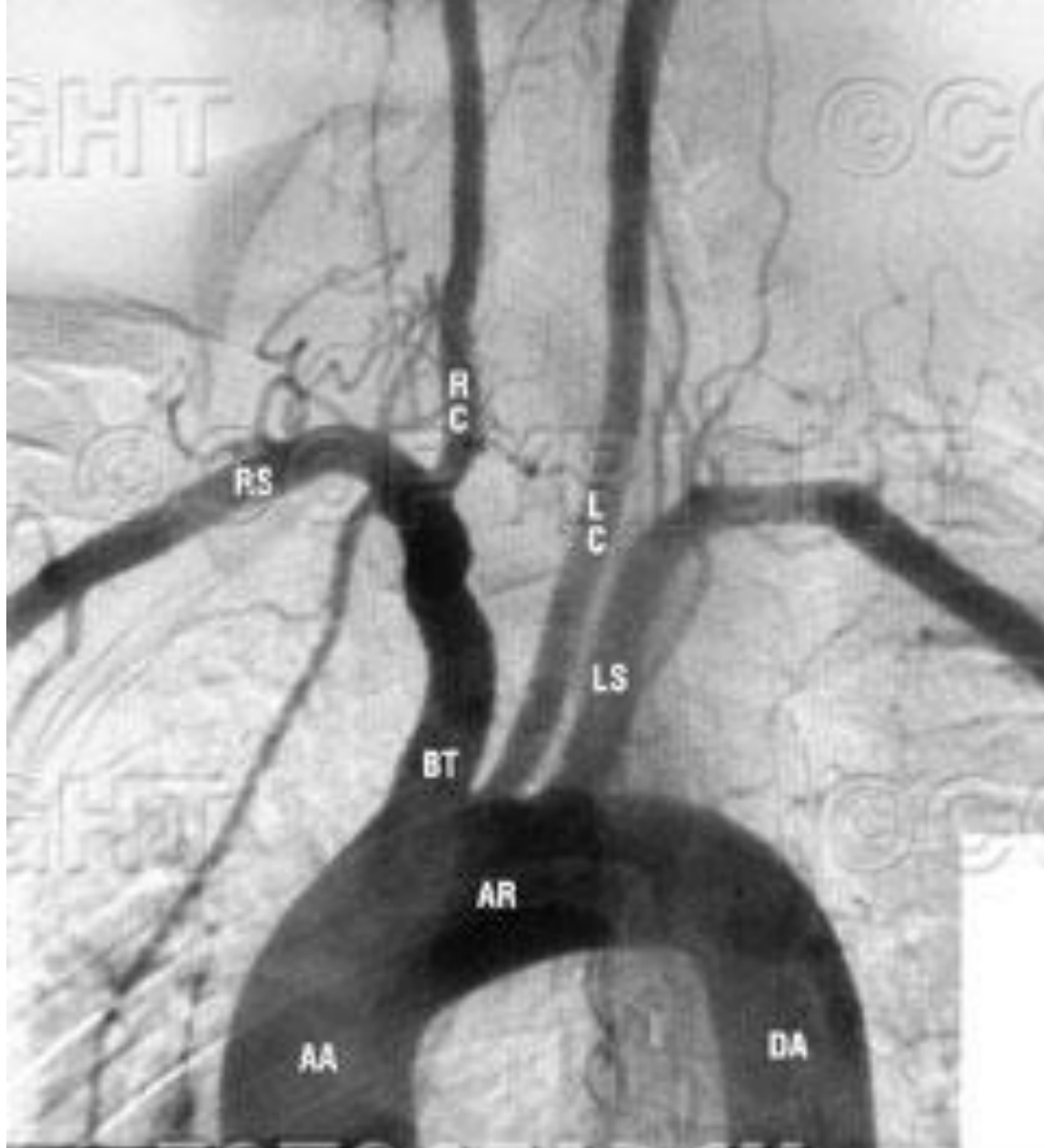
MI=0.7 AO=100%

CT and MR



angiogram of the aortic arch

© David Kachlík 30.9.2015



Courtesy Dr. E. L. Landsman
University of Toronto
Toronto, Ontario, Canada

© Pan, L. et al. 8/2/5

05108098

3/11/55

M: 4/1

I: 12/1

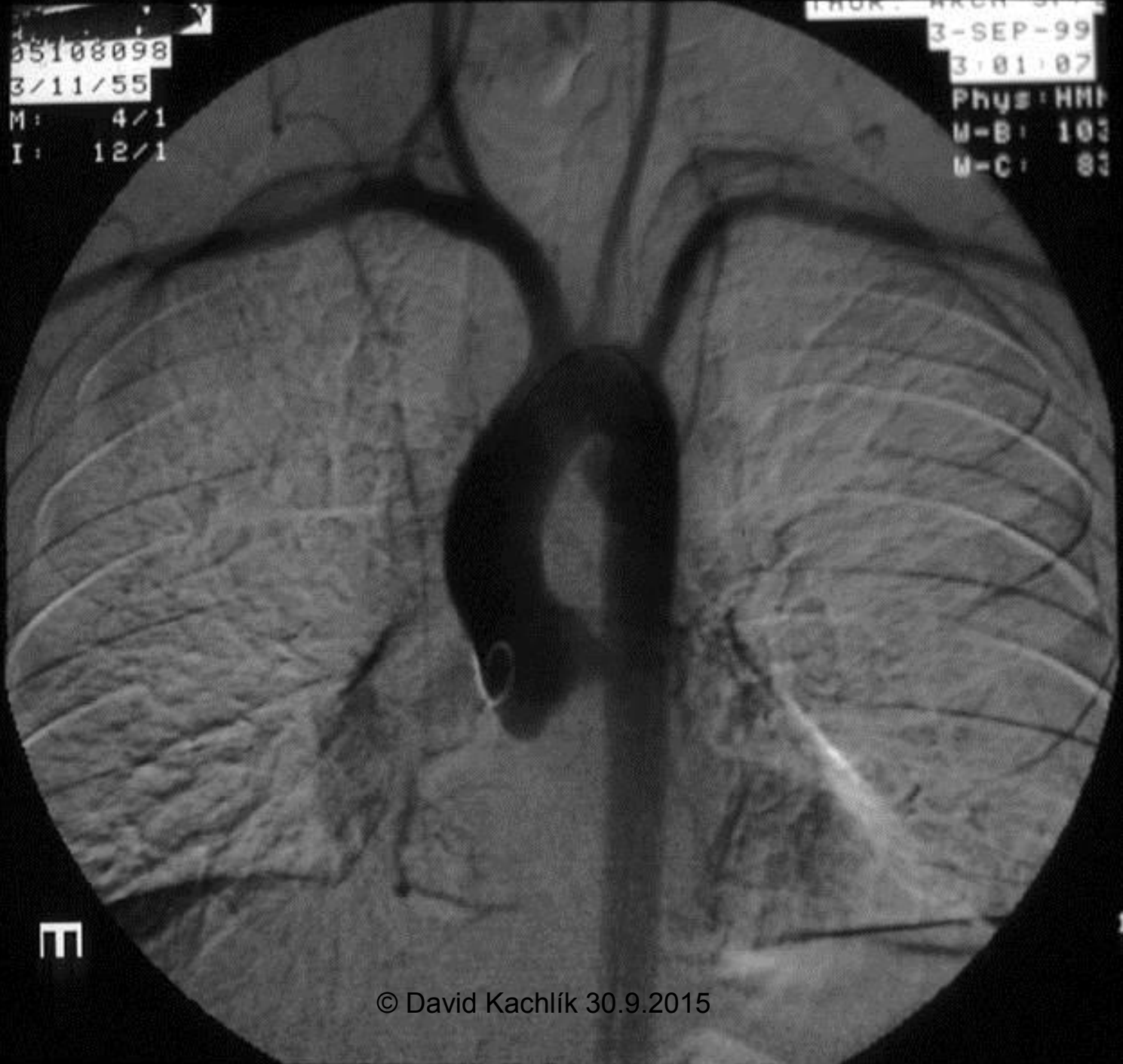TRUCK: ARON ST
3-SEP-99

3:01:07

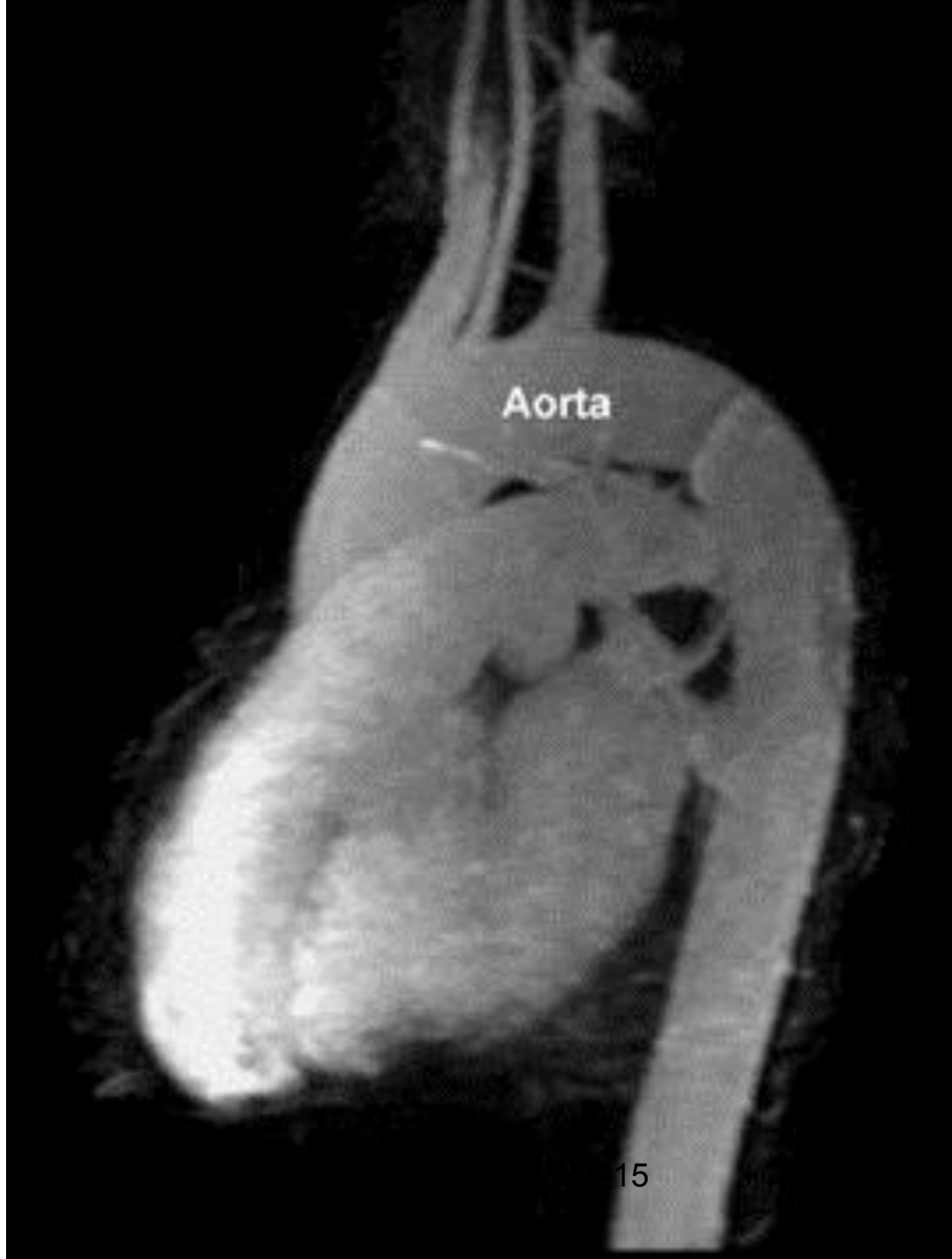Phys: HMT

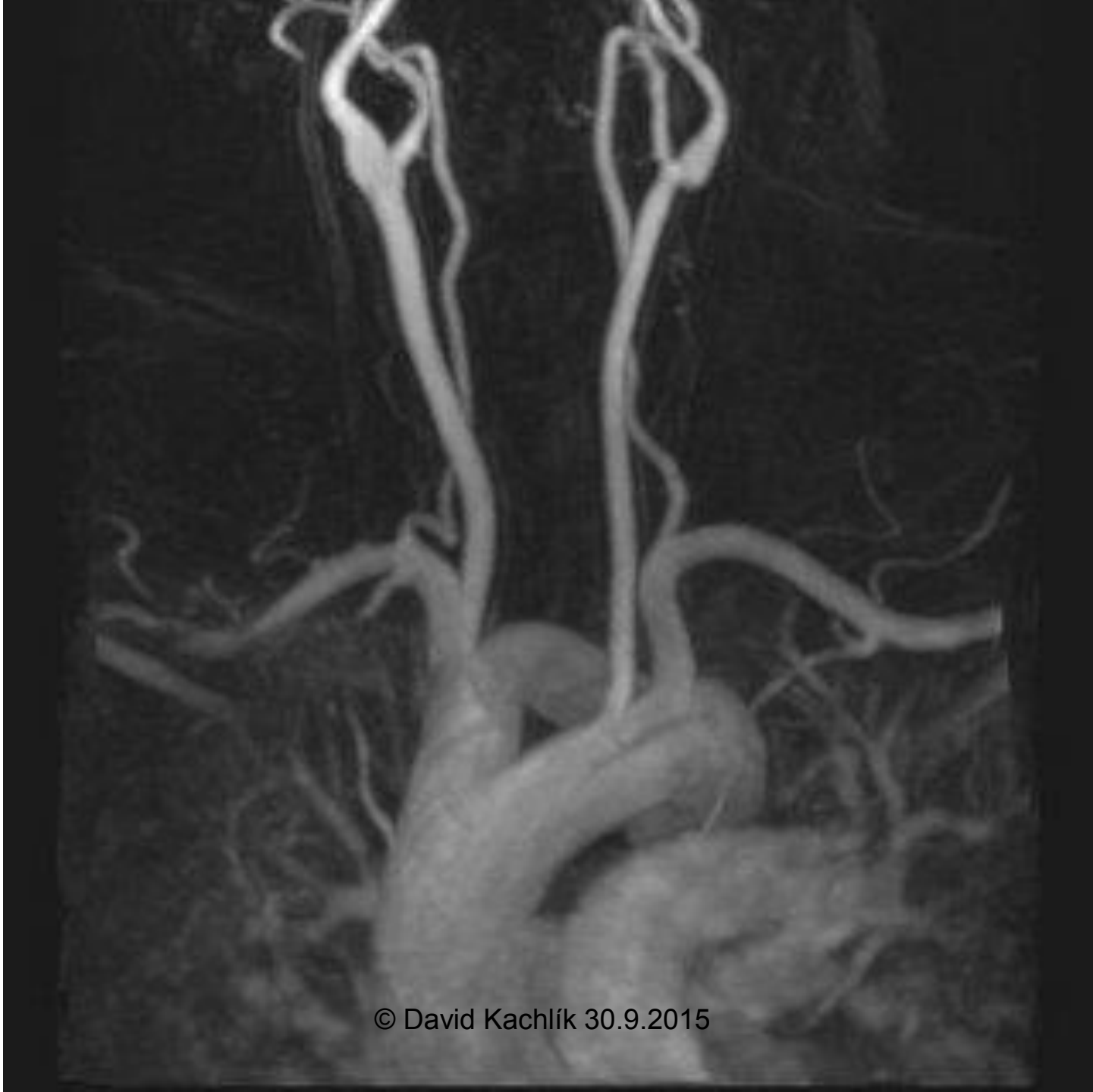M-B: 103

M-C: 83

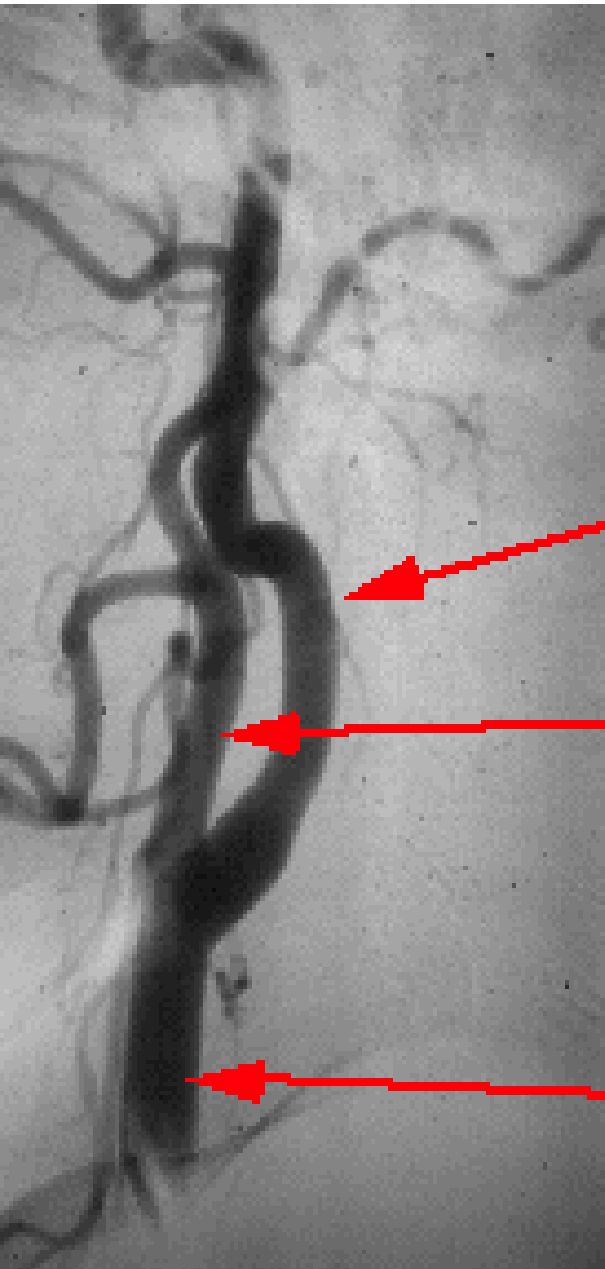


E





© David Kachlík 30.9.2015



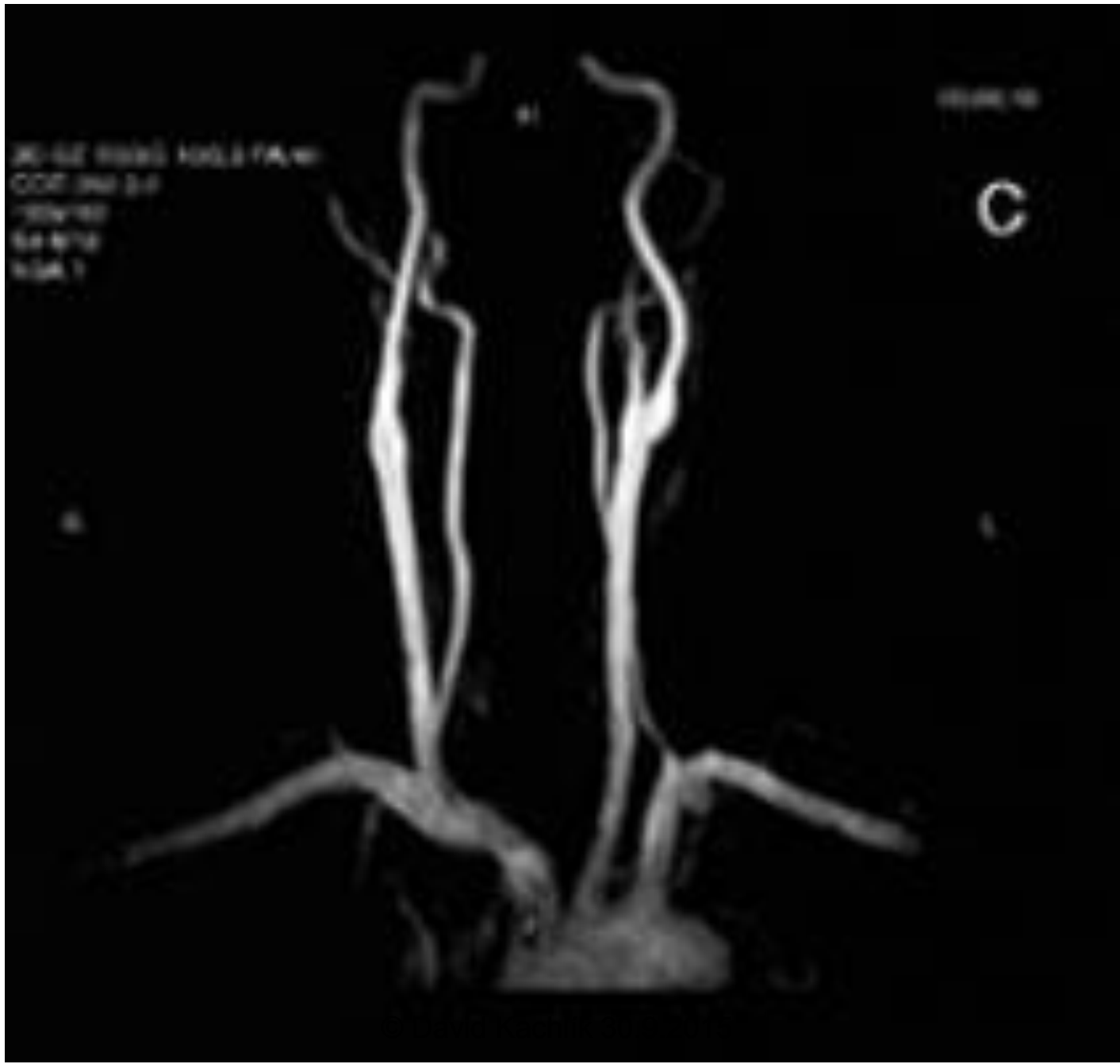
internal carotid artery: no branches

external carotid artery: branches in neck

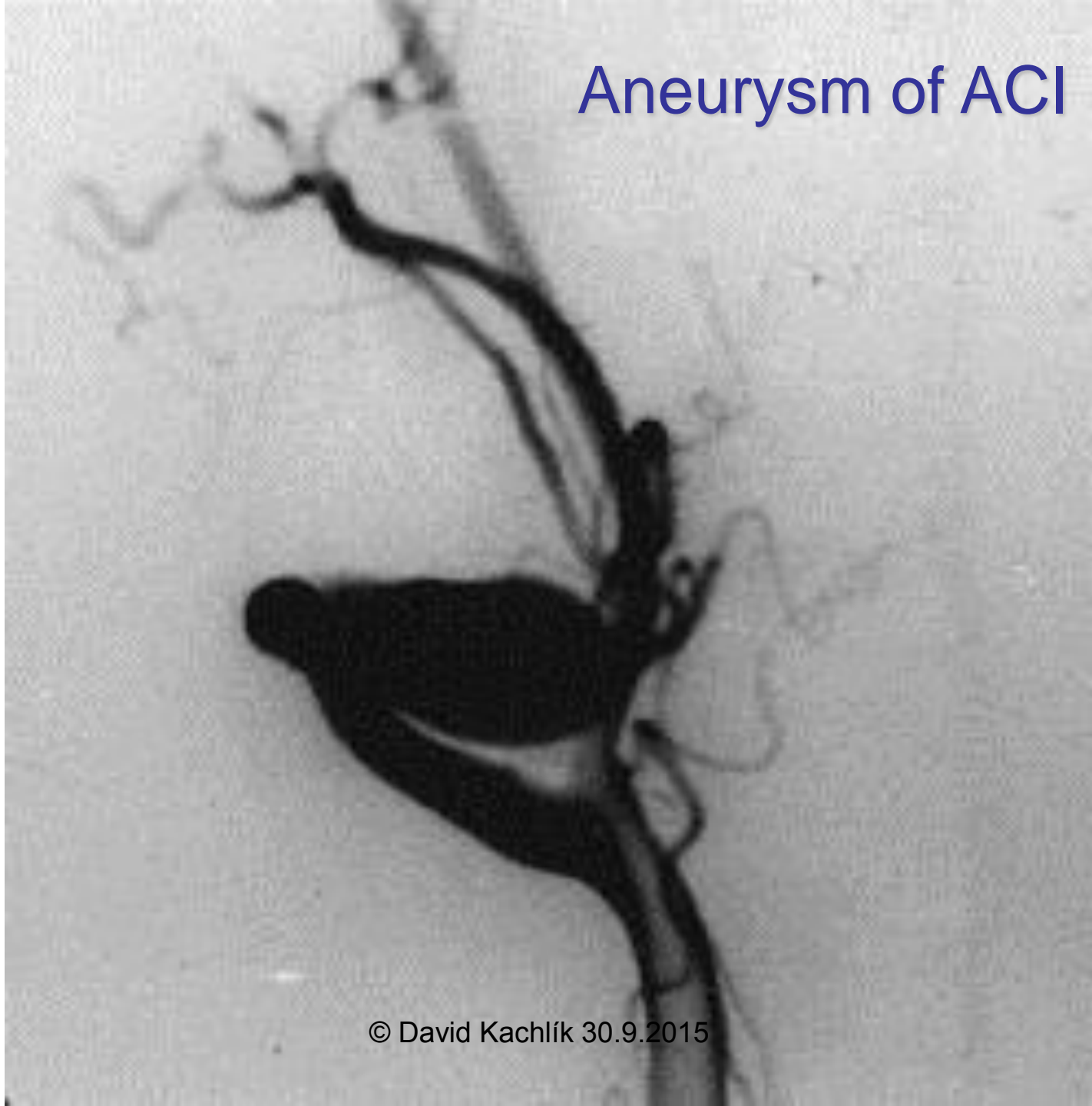
common carotid artery

30-62 1000 1000 PA w
000 100 2-1
100000
10 100
1000 1

1000 10
C



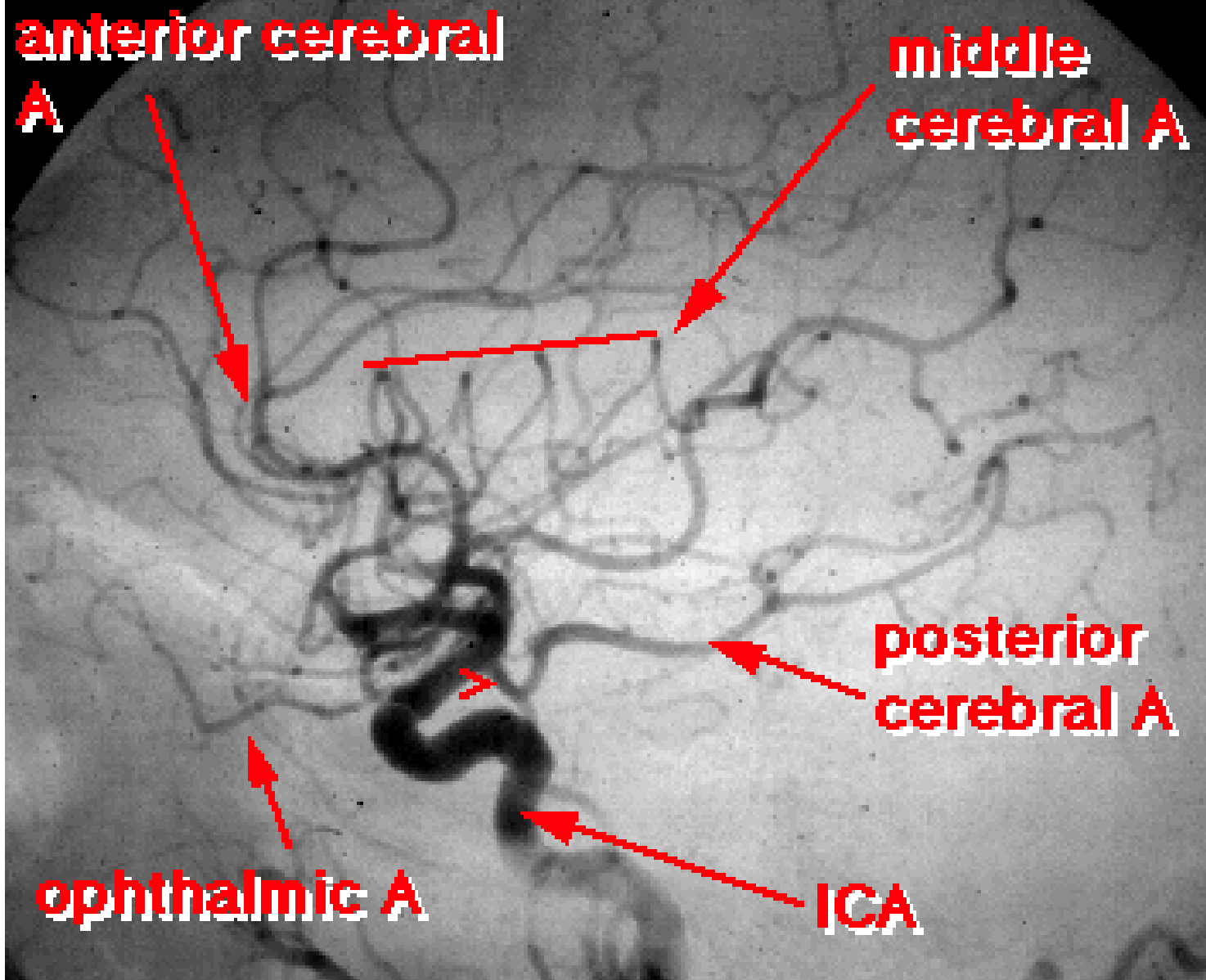
Aneurysm of ACI



anterior cerebral

A

middle cerebral A

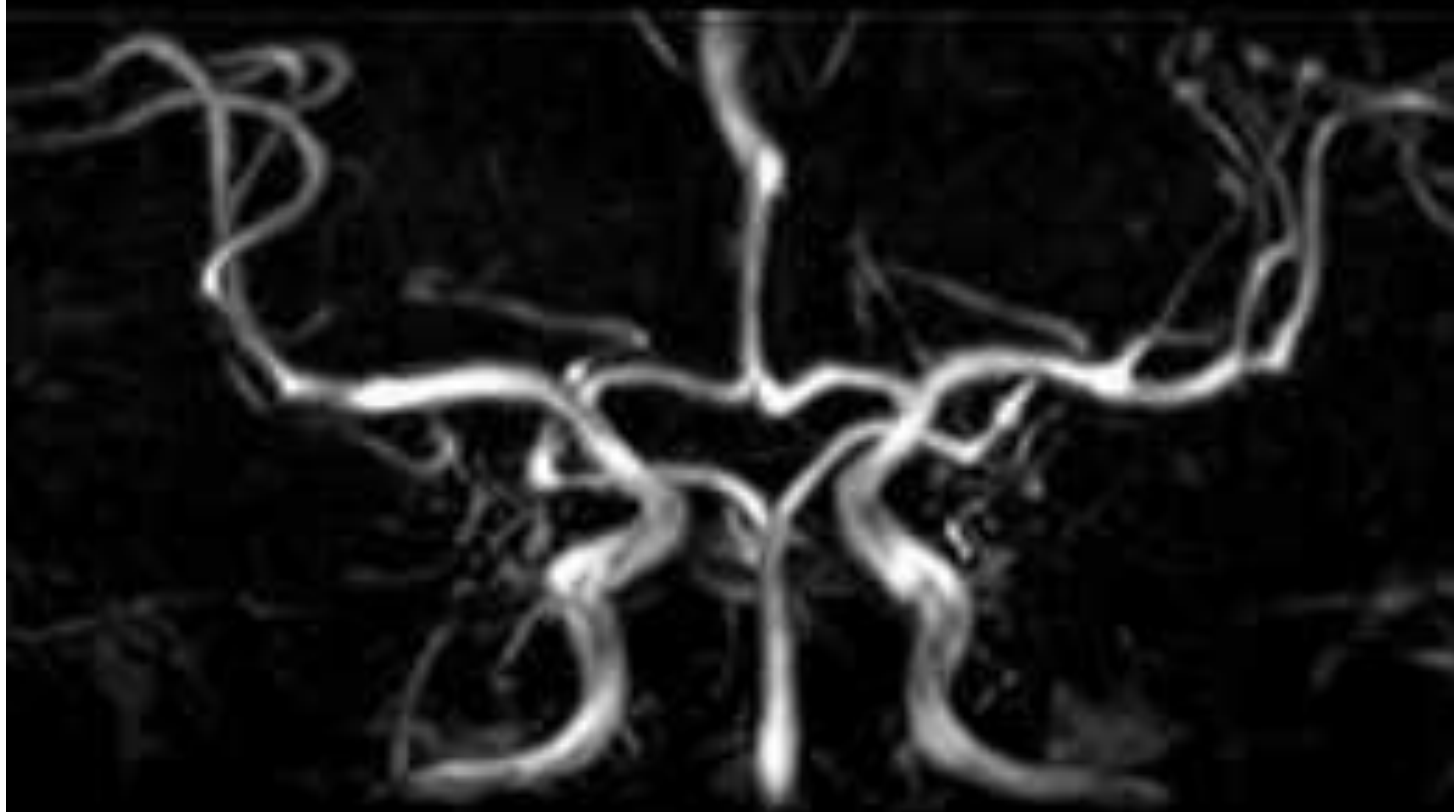


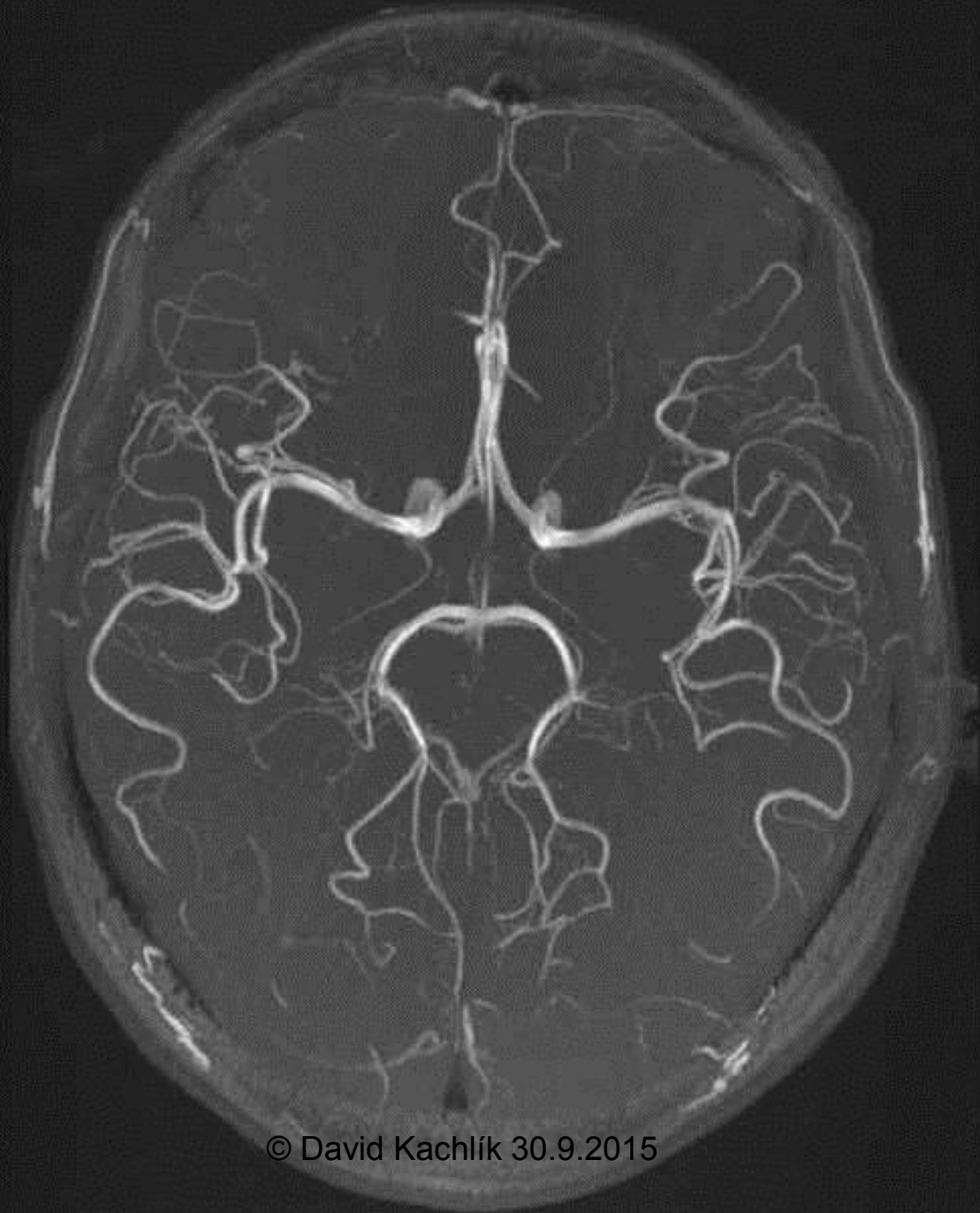posterior cerebral A

ophthalmic A

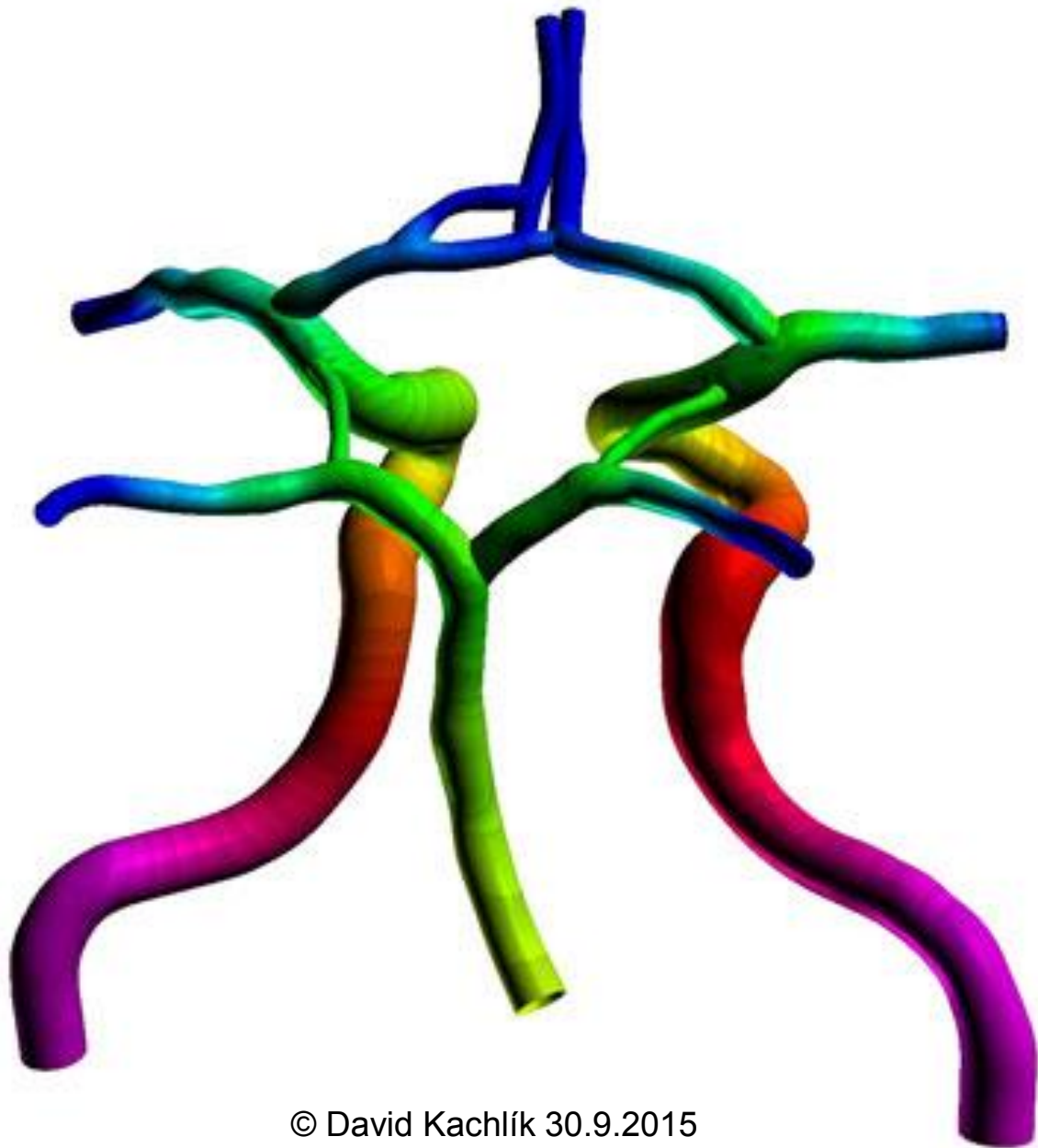
ICA

> = posterior communicating A





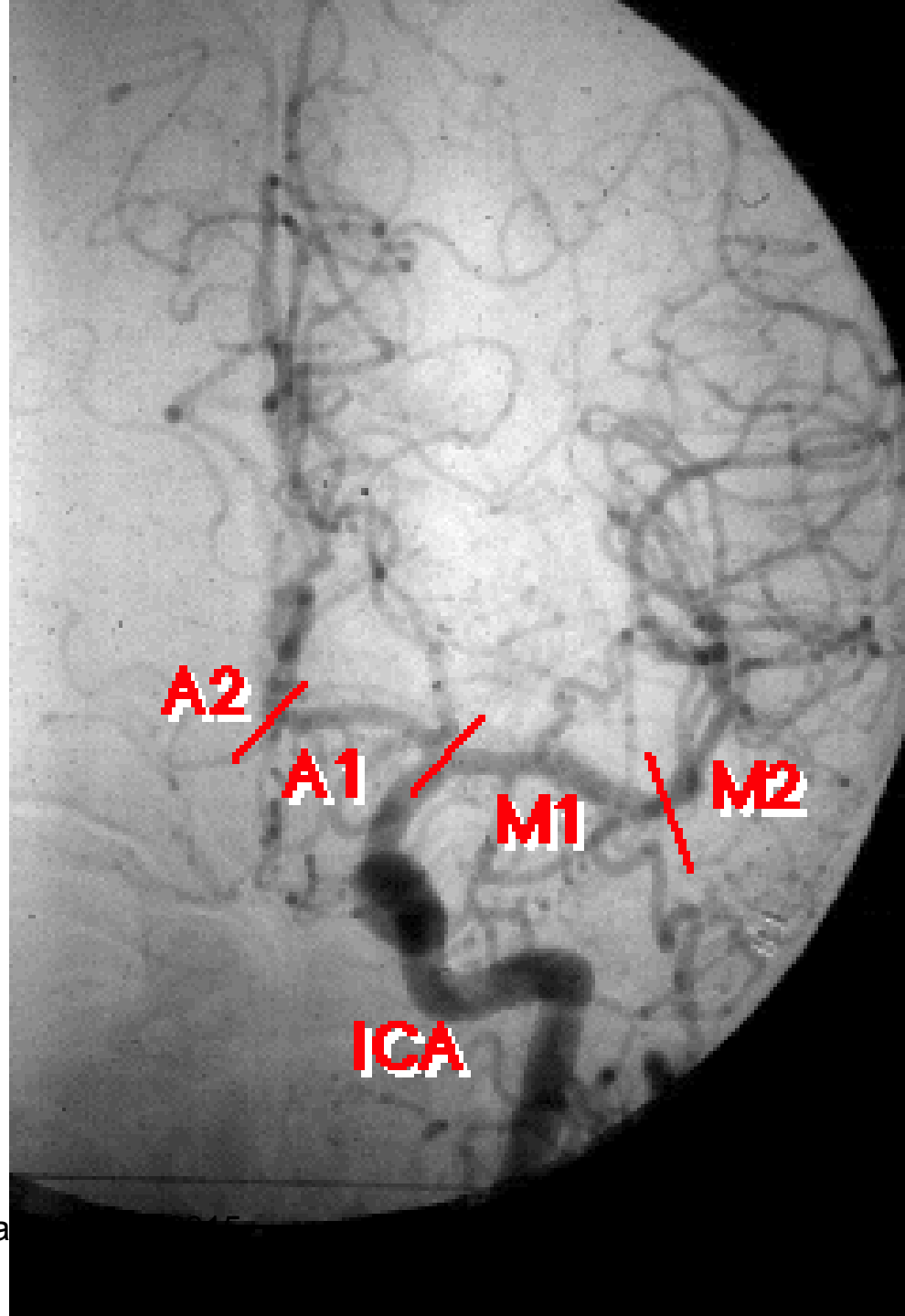
© David Kachlík 30.9.2015

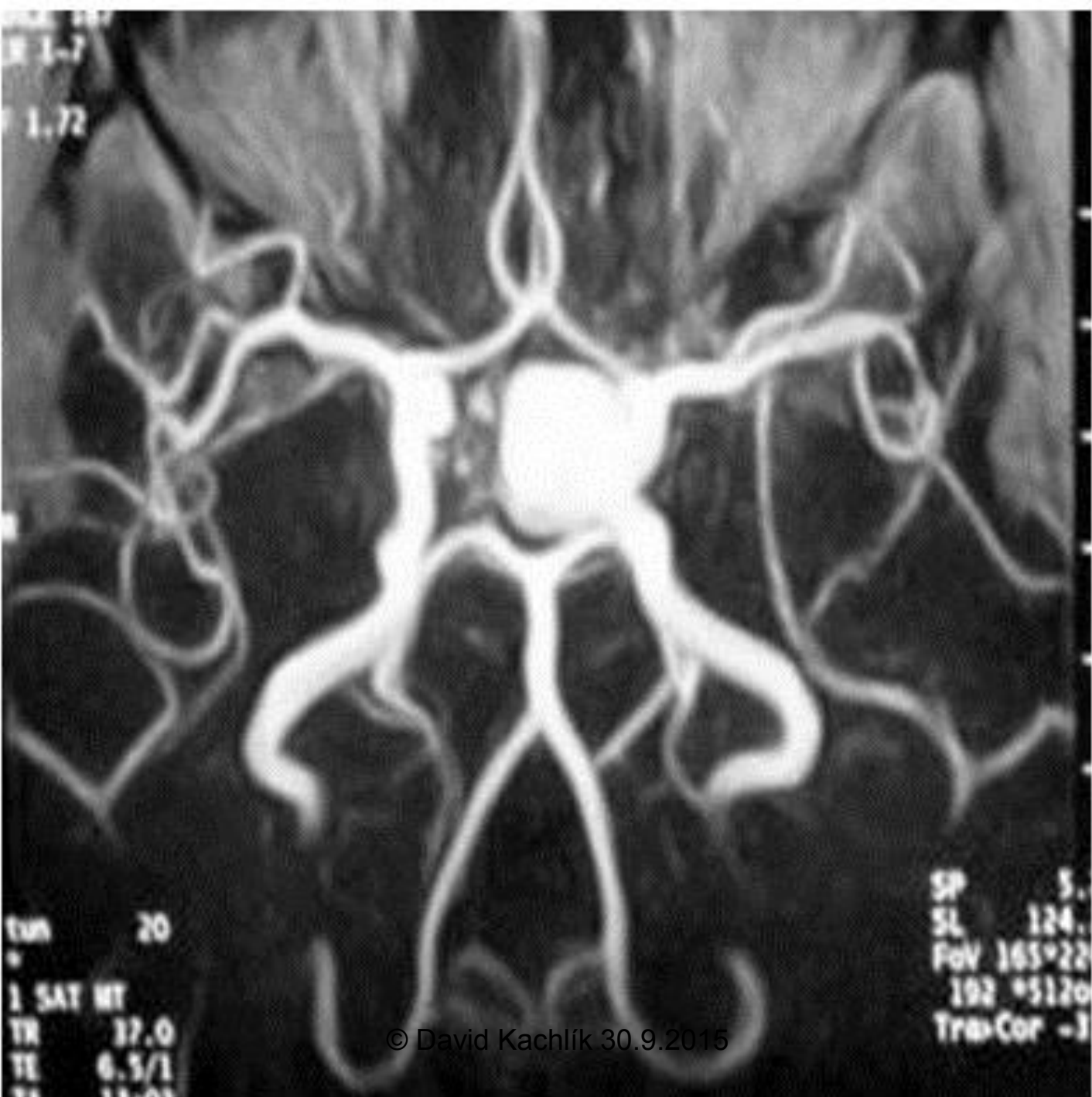


© David Kachlík 30.9.2015

Patrs of aa. cerebri

- a. cerebri ant.
 - pars precommunicalis;
segmentum **A1**
 - pars postcommunicalis;
segmentum **A2**
- a. cerebri media
 - pars
sphenoidealis/horizontalis;
segmentum **M1**
 - pars insularis; segmentum
M2
- a. cerebri post.
 - pars precommunicalis;
segmentum **P1**
 - pars postcommunicalis;
segmentum **P2**





1.72

20
1 SAT NT
TR 37.0
TE 6.5/1

SP 5.
SL 124.
FoV 165*22
192 *512
TraCor -3

© David Kachlík 30.9.2015

Aneurysma ACA

I: 8/1
FI: 30%
A

U-B: 128
U-C: 20

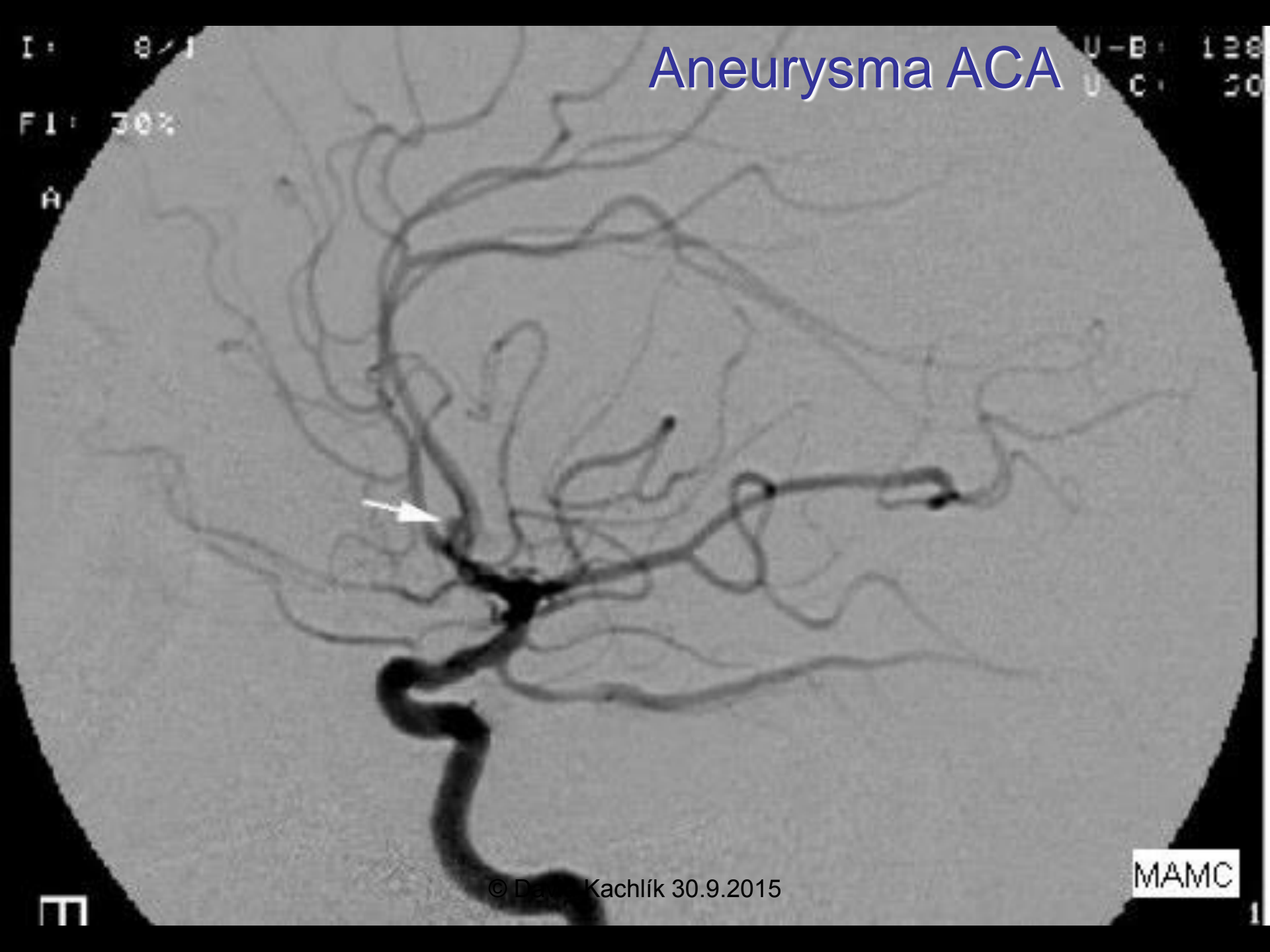


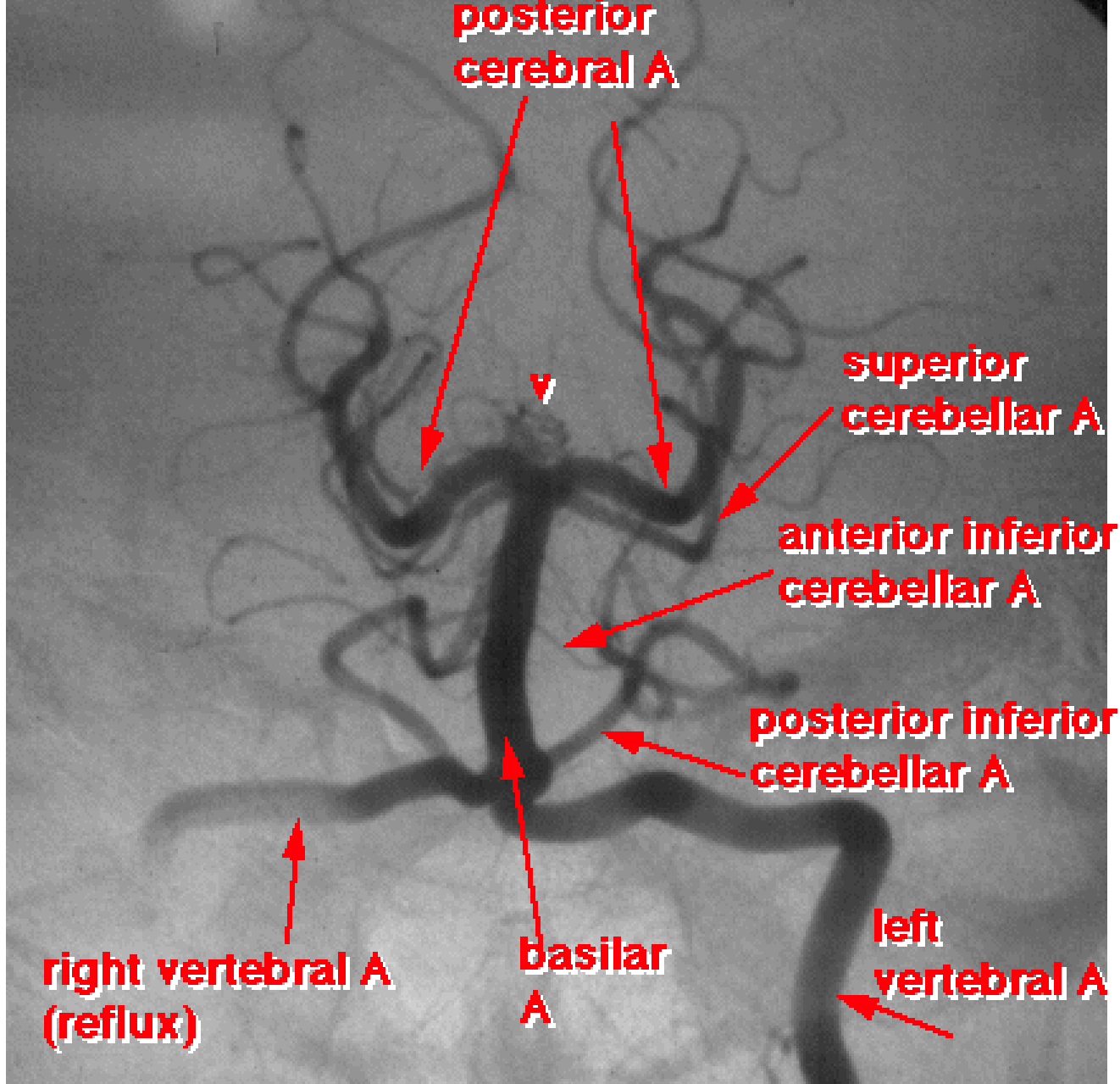
© David Kachlík 30.9.2015

MAMC

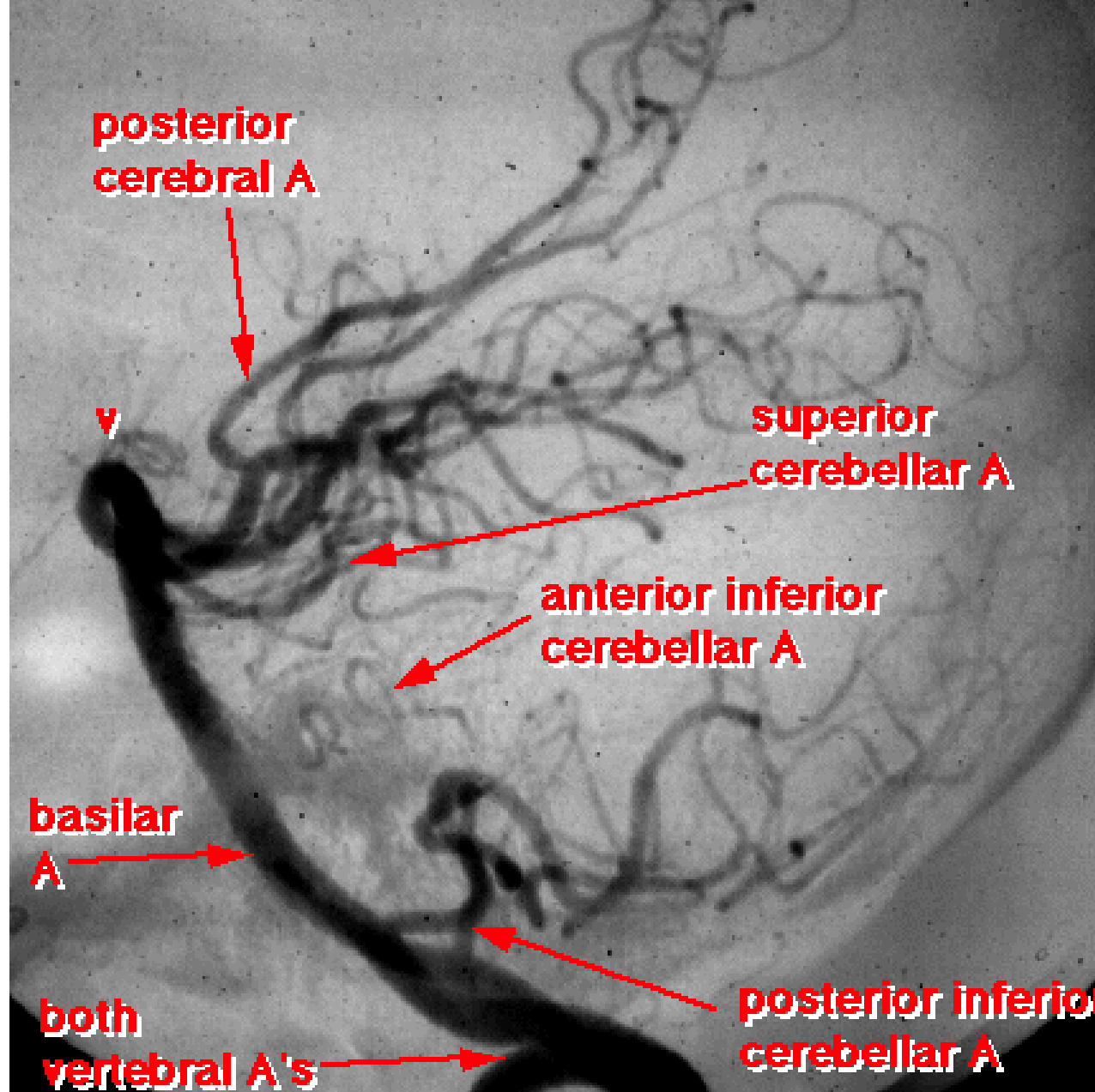
E

1





© David Kachnik 30.9.2015
U = perforators off the top of the basilar



v = perforators off the top of the basilar

© David Kachlik 30.9.2015

