

Mastering The Boards and Clinical Examinations In Internal Medicine

Part II

Neurology, Respiriology and Rheumatology

This book complements

Mastering The Boards and Clinical Examinations

In Internal Medicine - Part I,

Cardiology, Endocrinology, Gastroenterology,

Hepatology and Nephrology

A.B.R. Thomson



Disclaimer: Neither the author(s) nor CAPStone Academic Publishers can ensure the accuracy of the information contained in these books with regards to regional variations for recommended indications, dosages, and reportable adverse events. With the rapid expansion of medical knowledge, there may be, from time to time, variations between what is published in these books and the latest information and consensus recommendations made by different organizations. It is the responsibility of the reader to confirm independently any practice decisions related to an individual patient.



Mastering The Boards and Clinical Examinations In Internal Medicine

Part II

Neurology to Rheumatology

A.B.R. Thomson



CAPstone (Canadian Academic Publishers Ltd) is a not-for-profit company dedicated to the use of the power of education for the betterment of all persons everywhere.

*“The Democratization of Knowledge”
2012*



Medical drawings by S. Lee and E. Howell
Cover design by R. Burnett





THE WESTERN WAY





Table of Contents

Mastering The Boards and the CANMED Objectives	x
Prologue	xii
Dedication	xiii
Acknowledgements	xiv
NEUROLOGY	1
Introduction: General Neurological History and Physical Examination	13
Cranial Nerves	32
The Eye: CN II	36
Eye movement: CN III, V, IV, VI	74
Ear: cranial nerve VIII	112
Articulation: Cranial nerves IX, X, XII	116
Speech	122
Nystagmus and vertigo	129
Headache and facial pain	132
Hyperthermia/ Hypothermia	143
Brain Stem	146
Cerebellum	162
Radiculopathy and nerve roots	201
Syringomyelia and Syringobulbia	214
Peripheral Nerves	224
Peripheral neuropathy	233
Neuromuscular disease	248
Myasthenia gravis	258
Restless legs syndrome (RLS)	277
Parkinsonism, Extrapyrarnidal Disease, Tremor and Involuntary Movements	278
Dementia	304
Meningitis and subarachnoid hemorrhage	343
Syncope and Dizziness	347
Multiple Sclerosis	350
Neurofibromatosis	353
RESPIROLOGY	365
Questions in Respirology Chapter	367
Commonly used terms	370
Chest examination	372
Tracheal deviation	388
Cough	389
Hemoptysis	392
Consolidation, collapse, effusion, fibrosis	392
Clubbing	404
Granulomatous lung disease	411
Pulmonary fibrosis	413
Pneumonia	417



Influenza	424
Airflow obstruction and Asthma	425
Chronic obstructive pulmonary (lung) disease (COPD)	436
Carcinoma of the lung	442
Pulmonary hypertension and Cor pulmonale	450
Acute respiratory distress syndrome (ARDS)	453
Deep vein thrombosis	457
Pneumothorax	462
Lung abscess	463
Bronchiectasis	464
Extrinsic allergic alveolitis (hypersensitivity pneumonitis)	465
Chest X-ray	470
Suggested practice case scenarios for OSCE examinations	495
RHEUMATOLOGY	497
Questions in Rheumatology Chapter	499
Introduction	502
Hands and Wrists	514
Elbows	531
Shoulder	533
Spine	543
Hips	550
Knees	554
Ankles	561
Feet	563
Gout and pseudo-gout	563
Rheumatoid arthritis	568
Osteoarthritis	582
Pressure Ulcer	588
Ankylosing spondylitis (AS)	589
Systemic lupus erythematosus	597
Scleroderma	601
Raynaud's phenomenon	602
Vasculitis/Arteritis	605
Polymyalgia rheumatica-like syndromes	609
Aseptic necrosis of the bone	611
Charcot's joint	611
Arthropathy	613
Miscellaneous	618
Suggested practice case scenarios for OSCE examinations	625



MISCELLANEOUS	627
Questions in Miscellaneous Chapter	629
Fever	630
Viral infections	639
Sepsis	642
Sexual transmitted disease	643
Care of the elderly	643
Lifestyle issues	644
Abuse	646
 INDEX	 65151



Mastering The Boards and the CANMED Objectives

Medical expert

The discussion of complex cases provides the participants with an opportunity to comment on additional focused history and physical examination. They would provide a complete and organized assessment. Participants are encouraged to identify key features, and they develop an approach to problem-solving.

The case discussions, as well as the discussion of cases around a diagnostic imaging, pathological or endoscopic base provides the means for the candidate to establish an appropriate management plan based on the best available evidence to clinical practice. Throughout, an attempt is made to develop strategies for diagnosis and development of clinical reasoning skills.

Communicator

The participants demonstrate their ability to communicate their knowledge, clinical findings, and management plan in a respectful, concise and interactive manner. When the participants play the role of examiners, they demonstrate their ability to listen actively and effectively, to ask questions in an open-ended manner, and to provide constructive, helpful feedback in a professional and non-intimidating manner.

Collaborator

The participants use the “you have a green consult card” technique of answering questions as fast as they are able, and then to interact with another health professional participant to move forward the discussion and problem solving. This helps the participants to build upon what they have already learned about the importance of collegial interaction.

Manager

The participants are provided with assignments in advance of the three day GI Practice Review. There is much work for them to complete before as well as afterwards, so they learn to manage their time effectively, and to complete the assigned tasks proficiently and on time. They learn to work in teams to achieve answers from small group participation, and then to share this with other small group participants through effective delegation of work. Some of the material they must access demands that they use information technology effectively to access information that will help to facilitate the delineation of adequately broad differential diagnoses, as well as rational and cost effective management plans.

Health advocate

In the answering of the questions and case discussions, the participants are required to consider the risks, benefits, and costs and impacts of investigations and therapeutic alliances upon the patient and their loved ones.



Scholar

By committing to the pre- and post-study requirements, plus the intense three day active learning Practice Review with colleagues is a demonstration of commitment to personal education. Through the interactive nature of the discussions and the use of the “green consult card”, they reinforce their previous learning of the importance of collaborating and helping one another to learn.

Professional

The participants are coached how to interact verbally in a professional setting, being straightforward, clear and helpful. They learn to be honest when they cannot answer questions, make a diagnosis, or advance a management plan. They learn how to deal with aggressive or demotivated colleagues, how to deal with knowledge deficits, how to speculate on a missing knowledge byte by using first principals and deductive reasoning. In a safe and supportive setting they learn to seek and accept advice, to acknowledge awareness of personal limitations, and to give and take 360° feedback.

Knowledge

The basic science aspects of gastroenterology are considered in adequate detail to understand the mechanisms of disease, and the basis of investigations and treatment. In this way, the participants respect the importance of an adequate foundation in basic sciences, the basics of the design of clinical research studies to provide an evidence-based approach, the designing of clinical research studies to provide an evidence-based approach, the relevance of their management plans being patient-focused, and the need to add “compassionate” to the Three C’s of Medical Practice: competent, caring and compassionate.

 “They may forget what you said, but they will never forget how you made them feel.”

Carl W. Buechner, on teaching

“With competence, care for the patient. With compassion, care about the person.”

Alan B. R. Thomson, on being a physician.



Prologue

HREs, better known as, High Risk Examinations. After what is often two decades of study, sacrifice, long hours, dedication, ambition and drive, we who have chosen Internal Medicine, and possibly through this a subspecialty, have a HRE, the [Boards] Royal College Examinations. We have been evaluated almost daily by the sadly subjective preceptor based assessments, and now we face the fierce, competitive, winner-take-all objective testing through multiple choice questions (MCQs), and for some the equally challenging OSCE, the objective standardized clinical examination. Well we know that in the real life of providing competent, caring and compassionate care as physicians, as internists, that a patient is neither a MCQ or an OSCE. These examinations are to be passed, a process with which we may not necessarily agree. Yet this is the game in which we have thus far invested over half of our youthful lives. So let us know the rules, follow the rules, work with the rules, and succeed. So that we may move on to do what we have been trained to do, do what we may long to do, care for our patients.

The process by which we study for clinical examinations is so is different than for the MCQs: not trivia, but an approach to the big picture, with thoughtful and reasoned deduction towards a diagnosis. Not looking for the answer before us, but understanding the subtle aspects of the directed history and focused physical examination, yielding an informed series of hypotheses, a differential diagnosis to direct investigations of the highly sophisticated laboratory and imaging procedures now available to those who can wait, or pay.

This book provides clinically relevant questions of the process of taking a history and performing a physical examination, with sections on Useful background, and where available, evidence-based performance characteristics of the rendering of our clinical skills. Just for fun are included "So you want to be a such-and-such specialist!" to remind us that one of the greatest strengths we can possess to survive in these times, is to smile and even to laugh at ourselves.

Sincerely,

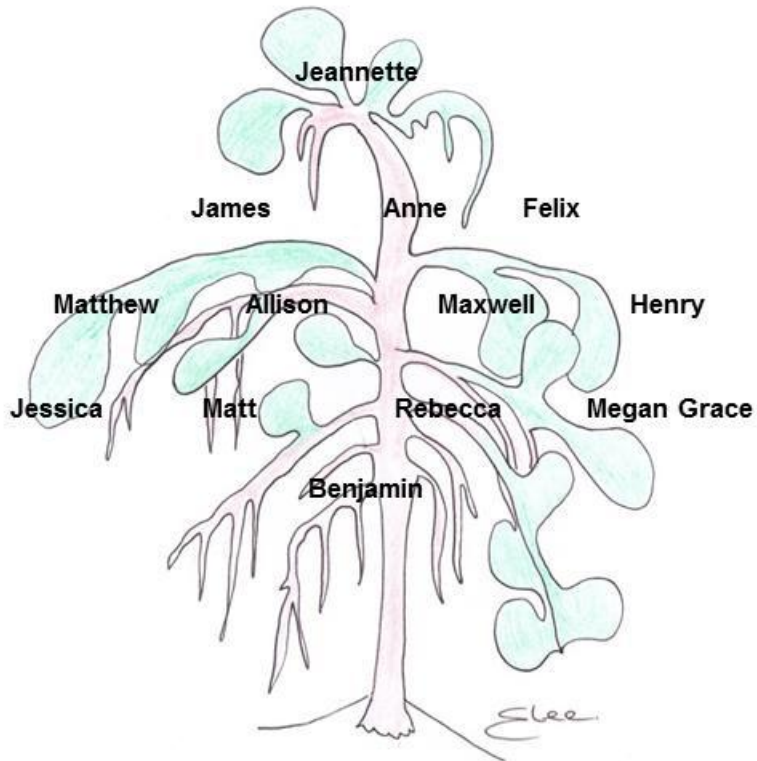


Emeritus Distinguished University Professor, University of Alberta
Adjunct Professor, Western University



Dedication

To My Family



For your support, caring and love
During these challenging years
And always.

Mark 15:34

Luke 23:34

Domenichino 16:41

Corinthians 1:13



Acknowledgements

Patience and patients go hand in hand. So also does the interlocking of young and old, love and justice, equality and fairness. No author can have thoughts transformed into words, no teacher can make ideas become behaviour and wisdom and art, without those special people who turn our minds to the practical - of getting the job done!

Thank you, Naiyana and Duen for translating those terrible scribbles, called my handwriting, into the still magical legibility of the electronic age. Thank you, Sarah, for your creativity and hard work.

My most sincere and heartfelt thanks go to the excellent persons at JP Consulting, and CapStone Academic Publishers. Jessica, you are brilliant, dedicated and caring. Thank you.

When Rebecca, Maxwell, Megan Grace, Henry and Felix ask about their Grandad, I will depend on James and Anne, Matthew and Allison, Jessica and Matt, and Benjamin to be understanding and kind. For what I was trying to say and to do was to make my professional life focused on the three C's - competence, caring, and compassion - and to make my very private personal life dedicated to family - to you all.



ARE YOU PREPARING FOR EXAMS IN GASTROENTEROLOGY AND HEPATOLOGY?

See the full range of examination preparation and review publications from CAPstone on Amazon.com

Gastroenterology and Hepatology

- First Principles of Gastroenterology and Hepatology, 6th edition
(ISBN: 978-1461038467)
- GI Practice Review, 2nd edition (ISBN: 978-1475219951)
- Endoscopy and Diagnostic Imaging Part I (ISBN: 978-1477400579)
- Endoscopy and Diagnostic Imaging Part II (ISBN: 978-1477400654)
- Scientific Basis for Clinical Practice in Gastroenterology and Hepatology (ISBN: 978-1475226645)

General Internal Medicine

- Achieving Excellence in the OSCE. Part I. Cardiology to Nephrology
(ISBN: 978-1475283037)
- Achieving Excellence in the OSCE. Part II. Neurology to Rheumatology (ISBN: 978-1475276978)
- Bits and Bytes for Rounds in Internal Medicine (ISBN: 978-1478295365)
- Mastering the Boards and Clinical Examinations. Part I. Cardiology, Endocrinology, Gastroenterology, Hepatology and Nephrology
(ISBN: 978-1461024842)



Questions

Neurology

1. Perform a focused physical examination of the nervous system to determine the site of the disorder causing the muscle weakness, altered tone as well as deep tendon reflexes.
2. Perform a focused physical examination of the nervous system.
3. Take a directed history and perform a focused physical examination for disease of the cerebral hemispheres.
4. Perform a focus physical examination of the motor cortex.
5. Perform a focused physical examination for a disorder of the cortex of the frontal lobe.
6. Perform a focused physical examination for a disorder of the cortex of the parietal lobe.
7. Perform a focused physical examination for a disorder of the temporal lobe.
8. Take a directed history and perform a focused physical examination to determine the presence of disease of the parietal, temporal, frontal and occipital lobes.
9. Perform a focused physical examination to distinguish between an intramedullary from an extramedullary cord lesion.
10. Perform a focused physical examination for the "dorsal midbrain syndrome".
11. Perform a focused physical examination of the cranial nerves (CN).
12. Perform a focused physical examination for the causes of sudden blindness.
13. Perform a focused physical examination for the causes of retinal hemorrhage.
14. Perform a focused physical examination of the fundus for hypertensive retinopathy.
15. Perform a focused physical examination of the eye for macular degeneration.
16. Perform a funduscopic examination for papilledema (edema of optic nerve disc, papilla).
17. Perform an examination for acute angle closure glaucoma.
18. Perform a focused physical examination for swelling (edema) of the head of the optic nerve (disc, papilla).



19. Take a directed history and perform a focused ocular examination for papillitis (a form of papillitis is optic neuritis) / optic neuritis.
20. Take a directed history and perform a focused physical examination for AION (anterior ischemic optic neuropathy).
21. Perform a focused physical examination to distinguish between the retinal vein and artery.
22. Perform a focused physical examination to distinguish between papilledema vs papillitis.
23. Perform a focused physical examination to determine the cause of unequal pupils (anisocoria).
24. Perform a focused physical examination for the causes of ptosis.
25. Perform a focused physical examination for Horner's syndrome.
26. Perform a focused physical examination for the causes of the Argyll Robertson pupil.
27. Perform a focused physical examination of the patient with a large pupil (regular or irregular, oval or circular) which reacts slowly to light and accommodation (Holmes-Adie Syndrome).
28. Perform a focused physical examination for CN III palsy.
29. Perform a focused physical examination for CN III palsy due to a lesion.
30. Perform a focused physical examination for a CN III lesion (of the left side in this example).
31. Perform a focused physical examination for the causes of unilateral or bilateral ptosis.
32. Perform a focused physical examination for a CN III lesion (of the left side in this example).
33. Perform a focused physical examination for a CN IV lesion (of the right side in this example).
34. Perform a focused physical examination of the eye to differentiate between a red eye caused by conjunctivitis (conj) versus/ keratitis (kera).
35. Perform a focused physical examination for a CN VI lesion (on the left side in this example).
36. Perform a focused physical examination to determine the cause of a person's diplopia.
37. Perform a focused physical examination of the eye for light-near dissociation (aka Argyll Robertson pupils), and its causes.



38. Perform a focused physical examination to determine the site of the lesion causing nystagmus.
39. Perform a focused physical examination to distinguish between UMN and LMN lesion of CN VII (facial)?
40. Perform a focused physical examination to determine the neuroanatomical site of the facial nerve (CN VII) resulting in unilateral paralysis of the upper and the lower facial muscles.
41. Perform a focused physical examination for a disorder in the facial nerve, CN VII.
42. Perform a focused physical examination for the causes of facial weakness/ paralysis (CN VII lesion).
43. Perform a focused physical examination for the causes of facial pain.
44. Perform a focused physical examination for a lesion in the cavernous sinus, cerebellopontine angle, jugular foramen, pseudobulbar and bulbar palsy (multiple cranial nerve palsies), and its causes.
45. Take a directed history and perform a focused physical examination for a lesion at the cerebellopontine angle.
46. Perform a focused physical examination for labyrinth disease.
47. Take a directed history and perform a focus physical examination to distinguish between cerebral, psychogenic and hypertensive vertigo.
48. Perform a focused physical examination to determine the site of defect and the causes of dysarthria (disorder of articulation).
49. Perform a focused physical examination for a lesion in the posterior fossa (jugular foramen syndrome).
50. Perform a focused physical examination of the tongue to distinguish between a lower motor neuron (LMN) lesion, bulbar palsy, and pseudobulbar/bilateral upper motor neuron (UMN) lesion.
51. Take a directed history and perform a focused physical examination for the jugular foramen syndrome.
52. Perform a focused physical examination for posterior inferior cerebellar artery thrombosis.
53. Perform a focused physical examination for a disorder of CN IX/X.
54. Perform a focused examination of a patient with dysphasia.
55. Take a directed history and perform a focused physical examination for a speech disorder.
56. Perform a focused physical examination for the causes of nystagmus/vertigo.



57. Take a directed history to determine the causes of facial pain.
58. Take a directed history for hypothalamic disease.
59. Give a systematic approach to the causes of hypothalamic disease.
60. Perform a focused physical examination of hypothalamic disease.
61. Take a directed history and perform a focused physical examination for disease of the brainstem.
62. Perform a focused physical examination for a brainstem lesion.
63. Perform a focused physical examination for locked-in state.
64. Perform a focused physical examination for a brainstem lesion (crossed paralysis/hemiplegia).
65. Perform a focused physical examination for an ischemic event involving the midbrain, pons, as well as the lateral and medial portions of the medulla.
66. Take a directed history and perform a focused physical examination to distinguish between bulbar versus pseudobulbar palsy, and their cause.
67. Take a directed history and perform a focused physical examination for increased intracranial pressure.
68. Perform a focused physical examination for a temporal pressure cone.
69. Perform a focused physical examination for a foramen magnum pressure cone.
70. Perform a focused physical examination for a brainstem lesion.
71. Perform a focused physical examination to distinguish between an intramedullary from an extramedullary cord lesion.
72. Perform a focused physical examination for Wallenberg's syndrome (Lateral Medullary Syndrome)
73. Perform a focused physical examination for lateral medullary syndrome (LMS).
74. Take a directed history and perform a focused physical examination to distinguish between pseudobulbar and bulbar palsy.
75. Perform a focused physical examination for a unilateral cerebellar lesion.
76. Perform a focused physical examination for the cerebellum.
77. Perform a focused physical examination to determine the site of a spinal cord and nerve root lesions.



78. Perform a focused physical examination to localize a spinal cord lesion to a specific lumbar or sacral nerve root level.
79. Perform a focused physical examination to distinguish between total spinal cord transaction, or incomplete cord compression.
80. Perform a focused physical examination of site in the spinal cord for loss of sensation.
81. Perform a focused physical examination to detect the following sensory syndromes. Perform a focused physical examination for the causes and site of spinal cord compression.
82. Perform a focused physical examination for a protrended intervertebral disc.
83. Perform a focused physical examination for the cauda equina syndrome.
84. Give the anatomical basis of the diseases that cause dissociated anaesthesia.
85. Perform a focused physical examination to distinguish between the cauda equina syndrome (please see above), and the cauda equina claudication syndrome (see below).
86. Perform a focused physical examination for causes of spastic paresis.
87. Take a directed history and perform a focused physical examination for tabes dorsalis.
88. Perform a focused physical examination to determine the nerve roots involved in spinal cord disease (sensory dermatomes).
89. Take a directed history and perform a focused physical examination for Guillain Barre syndrome (GBS).
90. Perform a focused physical examination for a lesion of the posterior column.
91. Perform a focused physical examination for a posterior column lesion.
92. Perform a focused physical examination for subacute combined degeneration of the cord.
93. Perform a focused physical examination for closed spina bifida.
94. Perform a focused physical examination to determine if a person has a UMN or an LMN lesion.
95. Perform a focused physical examination of the motor system of the upper limbs.



96. Perform a focused physical examination of the patient with footdrop to determine to site at which the lateral popliteal nerve is affected.
97. Perform a focused physical examination for loss of corticospinal inhibition.
98. Perform a focused physical examination for hemisection of the spinal cord (Brown-Sequard syndrome).
99. Perform a focused physical examination for a lesion in the spinal canal at any level below T10 (cauda equina syndrome).
100. Perform a directed physical examination to establish the neurological cause of a brachial plexus lesion, and the cervical rib syndrome.
101. Take a directed history and perform a focused physical examination for Friedreich's ataxia.
102. Perform a focused physical examination for syringomyelia in a portion of the cervical cord.
103. Take a directed history and perform a focused physical examination for syringomyelia.
104. Give 4 neuro anatomical sites where lesions result in muscle weakness.
105. Give 6 differences in the physical examination of upper (UMN) versus lower motor neuron (LMN) disorders.
106. Perform a focused physical examination for muscle or UMN nerve root disease in the muscle groups of the upper and lower body.
107. Perform a focused physical examination for damage to C5 to T₁ motor nerve roots and brachial plexus trunks.
108. Perform a focused physical examination to establish the neurological cause of wasting of the small muscles of the hand.
109. Perform a focused physical examination of the cutaneous sensory innervation of the hand.
110. Perform a focused physical examination for carpal tunnel syndrome (median nerve compression).
111. Perform a focused physical examination for ulnar nerve palsy (C8, T1)
112. Take a directed history and perform a focused physical examination to distinguish between brachial plexus lesions and nerve root compression.
113. Perform a focused physical examination for the cause of a carcinomatous neuropathy.



114. Perform a focused physical examination for the causes of benign intracranial hypertension (pseudotumour cerebri).
115. Perform a directed physical examination for the causes of peripheral neuropathy.
116. Perform a focused physical examination for hysterical anaesthesia.
117. Take a directed history and perform a focused physical examination for autonomic neuropathy.
118. Perform a focused physical examination for the causes of fasciculations.
119. Perform a focused physical examination for Charcot-Marie-Tooth disease (features of hereditary motor and sensory neuropathy due to peripheral nerve degeneration which does not usually extend above the elbows or above the middle third of the thighs).
120. Perform a focused physical examination of the peripheral nerves of the hand (see figure).
121. Perform a focused physical examination for a hereditary peroneal muscular neuropathy.
122. Perform a focused physical examination of the type and location of lesion causing abnormal sensation.
123. Perform a focused physical examination for inflammatory polyradiculoneuropathy.
124. Take a directed history and perform a focused physical examination for common peroneal nerve palsy (aka: lateral popliteal nerve palsy [L4, 5]).
125. Perform a focused physical examination for peripheral neuropathy.
126. Perform a focused physical examination for foot drop.
127. Perform a focused physical examination for muscle disease.
128. Perform a focused physical examination for dystrophin myotonia.
129. Take a directed history of the causes of muscle weakness.
130. Perform a focused physical examination for (Becker) muscular dystrophy (MD).
131. Take a directed history and perform a focused physical examination for myotonia dystrophin.
132. Perform a focused physical examination for limb girdle dystrophy.
133. Perform a focused physical examination for myasthenia gravis.
134. Perform a focused physical examination for motor neuron disease.



135. Perform a focused physical examination to determine a neuromuscular cause of weakness.
136. Perform a focused physical examination to distinguish upper and lower motor neuron lesions.
137. Perform a take focused physical examination for motor neuron disease (MND) in the adult.
138. Give four terms to describe different abnormalities of movement.
139. Perform a focus physical examination of a gait (movement) disorder.
140. Perform a focused physical examination to distinguish between rigidity and spasticity of muscle.
141. Perform a focused physical examination for Parkinsonism.
142. Perform a directed physical examination for extrapyramidal disease.
143. Take a directed history and perform a focused physical examination to distinguish between Parkinson's disease and atherosclerotic Parkinsonism.
144. Perform a focused physical examination for different types of abnormal involuntary movements.
145. Perform a focused physical examination to determine the cause of each.
146. Perform a focused physical examination of tremor.
147. Take a directed history and perform a focused physical examination for chorea.
148. Take a directed history for seizures.
149. Give the indications for performing a CT of the head.
150. Take a directed history and perform a focused physical examination for the causes of dementia.
151. Take a directed history and perform a focused physical examination for dementia.
152. Take a directed history to differentiate between delirium and dementia.
153. Take a directed history and perform a physical examination for a cerebral vascular accident (CVA) or for transient ischemic attack (TIA).
154. Perform a focused physical examination to determine which vessel of the circle of Willis has been blocked by a thrombus or embolus and is responsible for a cerebrovascular "accident" (CVA).
155. Perform a focused physical examination of the patient's visual fields to determine the site of an occlusion of posterior cerebral artery (AKA).



156. Perform a focused physical examination of the patient's visual fields to determine the site of an occlusion of the internal carotid artery.
157. Perform a focused physical examination for cavernous sinus thrombosis (CST), and for sagittal sinus thrombosis (SST).
158. Perform a focused physical examination for obstruction at the base of the anterior spinal artery.
159. Perform a focused physical examination for the causes of paraplegia.
160. Take a directed history and perform a focused physical examination for TIA-associated ischemia of carotid and MCA, as well as basilar artery and PCA.
161. Perform a focused neurological examination to determine the location of an arterial cerebral occlusion.
162. Perform a focused physical examination to determine the site of pathology causing a person's motor defect.
163. Perform a focused physical examination to determine if a lesion affects functions of the dominant cerebral hemisphere.
164. Perform a focused physical examination to determine the presence of parietal lobe dysfunction.
165. Take a directed history of differentiated between a carotid or vertebrobasilar transient ischemic attack (TIA).
166. Take a directed history of spastic paraparesis.
167. Perform a focused physical examination to determine the location of lesions causing sensory loss.
168. Perform a focused physical examination to determine the cause of a patient's coma as arising from the cerebral cortex or brainstem.
169. Perform a focused physical examination for coma.
170. Take a directed history to detect disease of the frontal, parietal or temporal lobe, or the motor cortex.
171. Take a directed history for delirium.
172. Perform a focused physical examination to distinguish between meningeal irritation, versus lesion of the sciatic nerve or its spinal roots (Lasègue's sign).
173. Perform a focused physical examination for meningitis (the numbers in brackets represent values for sensitivity)
174. Take a directed history to distinguish communicating from and obstructive (non-communicating) hydrocephalus.
175. Take a directed history to determine the cause of a patient's dizziness.



176. Take a directed history and perform a focused physical examination for multiple sclerosis (MS).
177. Take a directed history and perform a focused physical examination for neurofibromatosis.
178. Give the types of urinary incontinence
179. Take a directed history for neurological bladder
180. Take a directed history for arteritis.
181. Give a differential diagnosis of difficulty initiating or maintaining sleep.

Respirology

1. Give an approach to the auscultation of the breath sounds to determine the nature of underlying lung disease.
2. Perform a focused physical examination for causes of Cheyne- Stoke respiration.
3. Perform a directed physical examination for asymmetry in the expansion of the chest.
4. Perform a directed physical examination of the pulmonary system for tracheal deviation.
5. Take a directed history for cough.
6. Take a directed history of hemoptysis.
7. Perform a focused physical examination for fibrosing alveolitis
8. Perform a directed physical examination of the pulmonary system for consolidation, collapse, effusion, or fibrosis.
9. Give the causes of pulmonary fibrosis.
10. Perform a focused physical examination to distinguish between the major causes of dullness at a lung base.
11. Give 3 causes of dullness of the lung base not related to consolidation, cavitation or callable.
12. Perform a focused physical examination to distinguish between the four commonest causes of dullness at the base of the lung.
13. Perform a focused physical examination to distinguish between peripheral versus central cyanosis.
14. Perform a focused physical examination for a pulmonary cavity.
15. Perform a directed physical examination for clubbing.
16. Give a systematic approach to the causes of clubbing.



17. Perform a directed physical examination for sarcoidosis.
18. Perform a focused physical examination for sarcoidosis.
19. Give a systematic approach to the causes of pulmonary fibrosis.
20. Give the typical radiological features of silicosis.
21. Give the typical signs of pulmonary infarction seen on chest X-ray.
22. Perform a focused physical examination for complications of pneumonia.
23. Give a systematic approach to the causes of recurrent pneumonias.
24. Take a directed history for asthma.
25. Perform a focused physical examination for asthma.
26. Take a directed history and perform a focused physical examination for asthma.
27. Take a focused history and perform a directed physical examination for chronic bronchitis.
28. Take a directed history to differentiate between bronchial asthma, chronic bronchitis, and emphysema.
29. Take a directed history for the harmful effects of cigarette smoking.
30. Take a focused history and perform a directed physical examination for bronchiectasis.
31. Perform a focused physical examination for bronchiectasis.
32. Take a directed history and perform a focused physical examination for the effects/complications of smoking.
33. Perform a directed physical examination of the pulmonary system in the patient with suspected mediastinal compression (e.g. carcinoma of the lung).
34. Perform a focused physical examination for lung cancer.
35. Perform a directed physical examination for Pancoast's (superior pulmonary sulcus tumor) syndrome (often from cancer [often non-small cell] of the apex of the lung, infiltrating C8, T1, 2; may also occur with lymphoma, or by spread of lymph node metastases in breast or lung cancer).
36. Give a systematic approach to the non-metastatic, non-pulmonary complications of bronchial cancer.
37. Provide a systematic approach to the tumors which are associated with polycythemia.



38. Give the non- metastatic, extra – pulmonary complications of bronchial carcinoma.
39. Take a directed history and perform a focused physical examination for pulmonary hypertension.
40. Perform a focused physical examination for cor pulmonale
41. Perform a focused physical examination for acute respiratory distress syndrome (ARDS).
42. Take a directed history and perform a focused physical examination to determine the possible presence of a deep vein thrombosis (DVT).
43. Take a focused history for the causes of pneumothorax.
44. Take a focused history for the causes of lung abscess.
45. Take a directed history and perform a focused physical examination for fibrosing alveolitis.
46. Take a focused history and perform a focused physical examination for obstructive sleep apnea (aka Pickwickian Syndrome).
47. Give the typical signs of hyperinflation seen on chest X-ray.
48. Give the distinction between pulmonary fibrosis (PF) vs collapse (C) on a chest X-ray.
49. Give the chest X-ray findings of each of the following
50. Give 15 causes of mediastinal tumours seen on chest X-ray

Rheumatology

1. Take a directed history for a musculoskeletal (MSK) disorder.
2. Perform a focused physical examination to determine the causes of a patient's motor or sensory neuropathy.
3. Perform a focused physical examination of the joints of the upper and lower body and from the abnormal articular findings, give the most likely diagnosis.
4. Take a directed history for the common side effects of nonsteroidal anti-inflammatory drugs.
5. Perform a focused physical examination of the hand to distinguish between rheumatoid arthritis (RA) and osteoarthritis (OA).
6. Perform a focused physical examination for carpal tunnel syndrome. (actually, Tinel's sign is the reproduction of symptoms any nerve; eg, Tinel's sign may be positive over ulnar nerve at the medial side of the elbow).
7. Give a systematic approach to localized areas of translucent bone.



8. Give a systematic approach to localized areas of calcified bone (periostitis).
9. Perform a focused physical examination of the wrist for rheumatoid arthritis.
10. Perform a directed physical examination of the hands for acromegaly, Marfan's syndrome, and Turner's syndrome.
11. Perform a focused physical examination of the elbow.
12. Take a directed history and a focused physical examination for features differentiating diseases affecting the elbow.
13. Perform a focused physical examination of the elbow to distinguish between "tennis" and golfer's elbow.
14. Perform a focused physical examination of the shoulder.
15. Perform a focused physical examination for causes of shoulder pain.
16. Perform a focused physical examination for shoulder syndromes.
17. Take a directed history of back pain.
18. Perform a focused physical examination of back pain.
19. Perform a focused physical examination for gluteal muscle weakness.
20. Perform a directed physical examination of the knee.
21. Perform a focused physical examination of the ankle.
22. Perform a focused physical examination of the feet.
23. Perform a focused physical examination for complications of RS.
24. Perform a focused physical examination which would help to distinguish BS from S-JS.
25. Give the radiological features of Gout
26. Perform a focused physical examination of extra – articular complications of rheumatoid arthritis (RA).
27. Perform a focused physical examination for rheumatoid arthritis (RA), and its complications.
28. Give non-MSK (musculoskeletal) associations of rheumatoid arthritis (RA).
29. Give the radiological features of Rheumatoid arthritis.
30. In both rheumatoid arthritis (RA) and osteoarthritis (OA), there is slow insidious onset of progressive disease, exacerbations, and the development of limitations in motion. Take a directed history and perform focused physical examination to distinguish RA from OA.



31. Perform a focused physical examination for diseases that may have positive rheumatoid factor.
32. Perform a focused physical examination for non-articular signs of rheumatoid arthritis.
33. Give a systematic approach to the causes of sacroiliitis.
34. Perform a focused physical examination for dermatomyositis/ polymyositis.
35. Perform a focused physical examination for the causes of spondyloarthritis.
36. Juvenile chronic arthritis (still disease) may be pauciarticular and polyarticular. Define still disease and its two major forms. Define still disease and its two major forms. Perform a focused physical examination for juvenile chronic arthritis and its complications.
37. Perform a focused physical examination for ankylosing spondylitis.
38. Take a directed history for ankylosing spondylitis.
39. Take a directed history for Ankylosing Spondylitis
40. Give the distinction between peripheral arthritis vs. sacroiliitis in Crohn disease (CD) and ulcerative colitis (UC).
41. Perform a focused physical examination for primary vs secondary osteoarthritis.
42. Give the radiological features of Ankylosing spondylitis
43. Perform a focused physical examination for psoriatic arthritis.
44. Perform a focused physical examination to distinguish psoriatic arthritis (PA) from rheumatoid arthritis (RA).
45. Perform a focused physical examination for erythema multiforme.
46. Perform a focused physical examination for systemic lupus erythematosus (SLE) and its complications.
47. Perform a focused physical examination for skin, CNS and systemic changes in SLE..
48. Perform a focused physical examination for scleroderma and its complications.
49. Take a directed history and perform a focused physical examination for secondary Raynaud phenomenon (not related to drug use).
50. Perform a directed physical examination for Raynaud's phenomenon (white->blue->red fingers/toes in response to cold temperature).
51. Give the causes of arteritis.



52. Take a directed history and perform a focused physical examination for systemic vasculitis.
53. Give 7 syndromes which may mimic vasculitis (i.e., the differential diagnosis of vasculitis)
54. Take a directed history and perform a focused physical examination for causes of polymyalgia rheumatica-like syndromes.
55. Perform a focused physical examination to distinguish PMR from the other causes of polymyalgia-rheumatica (PMR) – like syndromes.
56. Take a directed history of the cause of aseptic necrosis of the bone. (acronym: ASEPTIC).
57. Perform a directed physical examination for Charcot's joint (neuroarthropathy).
58. Perform a focused physical examination of Charcot joint
59. Give the radiological features of Osteo-arthritis
60. Perform a focused physical examination for patterns of arthropathy.
61. Perform a focused physical examination for polymyositis/ dermatomyositis.
62. Perform a focused physical examination for Marfan's syndrome.
63. Perform a focused physical examination for common types of leg ulcers.

Miscellaneous

1. Perform a focused physical examination for fever of unknown origin.
2. Give 5 conditions which in the patient with fever of unknown origin, a bone marrow may be useful to diagnose.
3. Take a directed history and perform a focused physical examination for postoperative (post-op) fever.
4. Perform a directed physical examination for fever and infection in a patient in hospital.
5. Perform a directed physical examination for flushing.
6. Take a directed history for functional assessment in the elderly.
7. Take a directed history of lifestyle issue.
8. Give 4 complications of rapid weight loss.



NEUROLOGY



Table of Contents

	Page
Introduction: General Neurological History and Physical Examination	13
Cranial Nerves	32
The Eye: CN II	36
Eye movement: CN III, V, IV, VI	74
Ear: cranial nerve VIII	112
Articulation: Cranial nerves IX, X, XII	116
Speech	122
Nystagmus and vertigo	129
Headache and facial pain	132
Hyperthermia/ Hypothermia	143
Brain Stem	146
Cerebellum	162
Radiculopathy and nerve roots	201
Syringomyelia and Syringobulbia	214
Peripheral Nerves	224
Peripheral neuropathy	233
Neuromuscular disease	248
Myasthenia gravis	258
Restless legs syndrome (RLS)	277
Parkinsonism, Extrapyrarnidal Disease, Tremor and Involuntary Movements	278
Dementia	304
Meningitis and subarachnoid hemorrhage	343
Syncope and Dizziness	347
Multiple Sclerosis	350
Neurofibromatosis	353
Neurofibromatosis	354



Questions in Neurology Chapter

1. Perform a focused physical examination of the nervous system to determine the site of the disorder causing the muscle weakness, altered tone as well as deep tendon reflexes.
2. Perform a focused physical examination of the nervous system.
3. Take a directed history and perform a focused physical examination for disease of the cerebral hemispheres.
4. Perform a focus physical examination of the motor cortex.
5. Perform a focused physical examination for a disorder of the cortex of the frontal lobe.
6. Perform a focused physical examination for a disorder of the cortex of the parietal lobe.
7. Perform a focused physical examination for a disorder of the temporal lobe.
8. Take a directed history and perform a focused physical examination to determine the presence of disease of the parietal, temporal, frontal and occipital lobes.
9. Perform a focused physical examination to distinguish between an intramedullary from an extramedullary cord lesion.
10. Perform a focused physical examination for the "dorsal midbrain syndrome".
11. Perform a focused physical examination of the cranial nerves (CN).
12. Perform a focused physical examination for the causes of sudden blindness.
13. Perform a focused physical examination for the causes of retinal hemorrhage.
14. Perform a focused physical examination of the fundus for hypertensive retinopathy.
15. Perform a focused physical examination of the eye for macular degeneration.
16. Perform a funduscopic examination for papilledema (edema of optic nerve disc, papilla) .
17. Perform an examination for acute angle closure glaucoma.
18. Perform a focused physical examination for swelling (edema) of the head of the optic nerve (disc, papilla).
19. Take a directed history and perform a focused ocular examination for papillitis (a form of papillitis is optic neuritis) / optic neuritis.



20. Take a directed history and perform a focused physical examination for AION (anterior ischemic optic neuropathy).
21. Perform a focused physical examination to distinguish between the retinal vein and artery.
22. Perform a focused physical examination to distinguish between papilladema vs papillitis.
23. Perform a focused physical examination to determine the cause of unequal pupils (anisocoria).
24. Perform a focused physical examination for the causes of ptosis.
25. Perform a focused physical examination for Horner's syndrome.
26. Perform a focused physical examination for the causes of the Argyll Robertson pupil.
27. Perform a focused physical examination of the patient with a large pupil (regular or irregular, oval or circular) which reacts slowly to light and accommodation (Holmes-Adie Syndrome).
28. Perform a focused physical examination for CN III palsy.
29. Perform a focused physical examination for CN III palsy due to a lesion.
30. Perform a focused physical examination for a CN III lesion (of the left side in this example).
31. Perform a focused physical examination for the causes of unilateral or bilateral ptosis.
32. Perform a focused physical examination for a CN III lesion (of the left side in this example).
33. Perform a focused physical examination for a CN IV lesion (of the right side in this example).
34. Perform a focused physical examination of the eye to differentiate between a red eye caused by conjunctivitis (conj) versus/ keratitis (kera).
35. Perform a focused physical examination for a CN VI lesion (on the left side in this example).
36. Perform a focused physical examination to determine the cause of a person's diplopia.
37. Perform a focused physical examination of the eye for light-near dissociation (aka Argyll Robertson pupils), and its causes.



38. Perform a focused physical examination to determine the site of the lesion causing nystagmus.
39. Perform a focused physical examination to distinguish between UMN and LMN lesion of CN VII (facial)?
40. Perform a focused physical examination to determine the neuroanatomical site of the facial nerve (CN VII) resulting in unilateral paralysis of the upper and the lower facial muscles:
41. Perform a focused physical examination for a disorder in the facial nerve, CN VII.
42. Perform a focused physical examination for the causes of facial weakness/ paralysis (CN VII lesion).
43. Perform a focused physical examination for the causes of facial pain.
44. Perform a focused physical examination for a lesion in the cavernous sinus, cerebellopontine angle, jugular foramen, pseudobulbar and bulbar palsy (multiple cranial nerve palsies), and its causes.
45. Take a directed history and perform a focused physical examination for a lesion at the cerebellopontine angle.
46. Perform a focused physical examination for labyrinth disease.
47. Take a directed history and perform a focus physical examination to distinguish between cerebral, psychogenic and hypertensive vertigo.
48. Perform a focused physical examination to determine the site of defect and the causes of dysarthria (disorder of articulation).
49. Perform a focused physical examination for a lesion in the posterior fossa (jugular foramen syndrome).
50. Perform a focused physical examination of the tongue to distinguish between a lower motor neuron (LMN) lesion, bulbar palsy, and pseudobulbar/bilateral upper motor neuron (UMN) lesion.
51. Take a directed history and perform a focused physical examination for the jugular foramen syndrome.
52. Perform a focused physical examination for posterior inferior cerebellar artery thrombosis.
53. Perform a focused physical examination for a disorder of CN IX/X.
54. Perform a focused examination of a patient with dysphasia.
55. Take a directed history and perform a focused physical examination for a speech disorder.



56. Perform a focused physical examination for the causes of nystagmus/vertigo.
57. Take a directed history to determine the causes of facial pain.
58. Take a directed history for hypothalamic disease.
59. Give a systematic approach to the causes of hypothalamic disease.
60. Perform a focused physical examination of hypothalamic disease.
61. Take a directed history and perform a focused physical examination for disease of the brainstem.
62. Perform a focused physical examination for a brainstem lesion.
63. Perform a focused physical examination for locked-in state.
64. Perform a focused physical examination for a brainstem lesion (crossed paralysis/hemiplegia).
65. Perform a focused physical examination for an ischemic event involving the midbrain, pons, as well as the lateral and medial portions of the medulla.
66. Take a directed history and perform a focused physical examination to distinguish between bulbar versus pseudobulbar palsy, and their cause.
67. Take a directed history and perform a focused physical examination for increased intracranial pressure.
68. Perform a focused physical examination for a temporal pressure cone.
69. Perform a focused physical examination for a foramen magnum pressure cone.
70. Perform a focused physical examination for a brainstem lesion.
71. Perform a focused physical examination to distinguish between an intramedullary from an extramedullary cord lesion.
72. Perform a focused physical examination for Wallenberg's syndrome (Lateral Medullary Syndrome)
73. Perform a focused physical examination for lateral medullary syndrome (LMS).
74. Take a directed history and perform a focused physical examination to distinguish between pseudobulbar and bulbar palsy.
75. Perform a focused physical examination for a unilateral cerebellar lesion.
76. Perform a focused physical examination for the cerebellum.



77. Perform a focused physical examination to determine the site of a spinal cord and nerve root lesions
78. Perform a focused physical examination to localize a spinal cord lesion to a specific lumbar or sacral nerve root level.
79. Perform a focused physical examination to distinguish between total spinal cord transaction, or incomplete cord compression.
80. Perform a focused physical examination of site in the spinal cord for loss of sensation.
81. Perform a focused physical examination to detect the following sensory syndromes. Perform a focused physical examination for the causes and site of spinal cord compression.
82. Perform a focused physical examination for a protrended intervertebral disc.
83. Perform a focused physical examination for the cauda equina syndrome.
84. Give the anatomical basis of the diseases that cause dissociated anaesthesia.
85. Perform a focused physical examination to distinguish between the cauda equina syndrome (please see above), and the cauda equina claudication syndrome (see below).
86. Perform a focused physical examination for causes of spastic paresis.
87. Take a directed history and perform a focused physical examination for tabes dorsalis.
88. Perform a focused physical examination to determine the nerve roots involved in spinal cord disease (sensory dermatomes).
89. Take a directed history and perform a focused physical examination for Guillain Barre syndrome (GBS).
90. Perform a focused physical examination for a lesion of the posterior column.
91. Perform a focused physical examination for a posterior column lesion.
92. Perform a focused physical examination for subacute combined degeneration of the cord.
93. Perform a focused physical examination for closed spina bifida.
94. Perform a focused physical examination to determine if a person has a UMN or an LMN lesion.



95. Perform a focused physical examination of the motor system of the upper limbs.
96. Perform a focused physical examination of the patient with footdrop to determine to site at which the lateral popliteal nerve is affected.
97. Perform a focused physical examination for loss of corticospinal inhibition.
98. Perform a focused physical examination for hemisection of the spinal cord (Brown-Sequard syndrome).
99. Perform a focused physical examination for a lesion in the spinal canal at any level below T10 (cauda equina syndrome).
100. Perform a directed physical examination to establish the neurological cause of a brachial plexus lesion, and the cervical rib syndrome.
101. Take a directed history and perform a focused physical examination for Friedreich's ataxia.
102. Perform a focused physical examination for syringomyelia in a portion of the cervical cord.
103. Take a directed history and perform a focused physical examination for syringomyelia.
104. Give 4 neuro anatomical sites where lesions result in muscle weakness.
105. Give 6 differences in the physical examination of upper (UMN) versus lower motor neuron (LMN) disorders.
106. Perform a focused physical examination for muscle or UMN nerve root disease in the muscle groups of the upper and lower body.
107. Perform a focused physical examination for damage to C5 to T₁ motor nerve roots and brachial plexus trunks.
108. Perform a focused physical examination to establish the neurological cause of wasting of the small muscles of the hand.
109. Perform a focused physical examination of the cutaneous sensory innervation of the hand.
110. Perform a focused physical examination for carpal tunnel syndrome (median nerve compression).
111. Perform a focused physical examination for ulnar nerve palsy (C8, T1)
112. Take a directed history and perform a focused physical examination to distinguish between brachial plexus lesions and nerve root compression.



113. Perform a focused physical examination for the cause of a carcinomatous neuropathy.
114. Perform a focused physical examination for the causes of benign intracranial hypertension (pseudotumour cerebri).
115. Perform a directed physical examination for the causes of peripheral neuropathy.
116. Perform a focused physical examination for hysterical anaesthesia.
117. Take a directed history and perform a focused physical examination for autonomic neuropathy.
118. Perform a focused physical examination for the causes of fasciculations.
119. Perform a focused physical examination for Charcot-Marie-Tooth disease (features of hereditary motor and sensory neuropathy due to peripheral nerve degeneration which does not usually extend above the elbows or above the middle third of the thighs).
120. Perform a focused physical examination of the peripheral nerves of the hand (see figure).
121. Perform a focused physical examination for a hereditary peroneal muscular neuropathy.
122. Perform a focused physical examination of the type and location of lesion causing abnormal sensation.
123. Perform a focused physical examination for inflammatory polyradiculoneuropathy.
124. Take a directed history and perform a focused physical examination for common peroneal nerve palsy (aka: lateral popliteal nerve palsy [L4,5]).
125. Perform a focused physical examination for peripheral neuropathy.
126. Perform a focused physical examination for foot drop.
127. Perform a focused physical examination for muscle disease.
128. Perform a focused physical examination for dystrophia myotonica.
129. Take a directed history of the causes of muscle weakness.
130. Perform a focused physical examination for (Becker) muscular dystrophy (MD).
131. Take a directed history and perform a focused physical examination for myotonia dystrophia.
132. Perform a focused physical examination for limb girdle dystrophia.



133. Perform a focused physical examination for myasthenia gravis.
134. Perform a focused physical examination for motor neuron disease.
135. Perform a focused physical examination to determine a neuromuscular cause of weakness.
136. Perform a focused physical examination to distinguish upper and lower motor neuron lesions.
137. Perform a take focused physical examination for motor neuron disease (MND) in the adult.
138. Give four terms to describe different abnormalities of movement.
139. Perform a focus physical examination of a gait (movement) disorder.
140. Perform a focused physical examination to distinguish between rigidity and spasticity of muscle.
141. Perform a focused physical examination for Parkinsonism.
142. Perform a directed physical examination for extrapyramidal disease.
143. Take a directed history and perform a focused physical examination to distinguish between Parkinson's disease and atherosclerotic Parkinsonism.
144. Perform a focused physical examination for different types of abnormal involuntary movements.
145. Perform a focused physical examination to determine the cause of each.
146. Perform a focused physical examination of tremor.
147. Take a directed history and perform a focused physical examination for chorea.
148. Take a directed history for seizures.
149. Give the indications for performing a CT of the head.
150. Take a directed history and perform a focused physical examination for the causes of dementia.
151. Take a directed history and perform a focused physical examination for dementia.
152. Take a directed history to differentiate between delirium and dementia.
153. Take a directed history and perform a physical examination for a cerebral vascular accident (CVA) or for transient ischemic attack (TIA).



154. Perform a focused physical examination to determine which vessel of the circle of Willis has been blocked by a thrombus or embolus and is responsible for a cerebrovascular “accident” (CVA).
155. Perform a focused physical examination of the patient’s visual fields to determine the site of an occlusion of posterior cerebral artery (AKA).
156. Perform a focused physical examination of the patient’s visual fields to determine the site of an occlusion of the internal carotid artery.
157. Perform a focused physical examination for cavernous sinus thrombosis (CST), and for sagittal sinus thrombosis (SST).
158. Perform a focused physical examination for obstruction at the base of the anterior spinal artery.
159. Perform a focused physical examination for the causes of paraplegia.
160. Take a directed history and perform a focused physical examination for TIA-associated ischemia of carotid and MCA, as well as basilar artery and PCA.
161. Perform a focused neurological examination to determine the location of an arterial cerebral occlusion.
162. Perform a focused physical examination to determine the site of pathology causing a person’s motor defect.
163. Perform a focused physical examination to determine if a lesion affects functions of the dominant cerebral hemisphere.
164. Perform a focused physical examination to determine the presence of parietal lobe dysfunction.
165. Take a directed history of differentiated between a carotid or vertebrobasilar transient ischemic attack (TIA).
166. Take a directed history of spastic paraparesis.
167. Perform a focused physical examination to determine the location of lesions causing sensory loss.
168. Perform a focused physical examination to determine the cause of a patient’s coma as arising from the cerebral cortex or brainstem.
169. Perform a focused physical examination for coma.
170. Take a directed history to detect disease of the frontal, parietal or temporal lobe, or the motor cortex.
171. Take a directed history for delirium.



172. Perform a focused physical examination to distinguish between meningeal irritation, versus lesion of the sciatic nerve or its spinal roots (Lasègue's sign).
173. Perform a focused physical examination for meningitis (the numbers in brackets represent values for sensitivity)
174. Take a directed history to distinguish communicating from and obstructive (non-communicating) hydrocephalus.
175. Take a directed history to determine the cause of a patient's dizziness.
176. Take a directed history and perform a focused physical examination for multiple sclerosis (MS).
177. Take a directed history and perform a focused physical examination for neurofibromatosis.
178. Give the types of urinary incontinence
179. Take a directed history for neurological bladder
180. Take a directed history for arteritis.
181. Give a differential diagnosis of difficulty initiating or maintaining sleep.

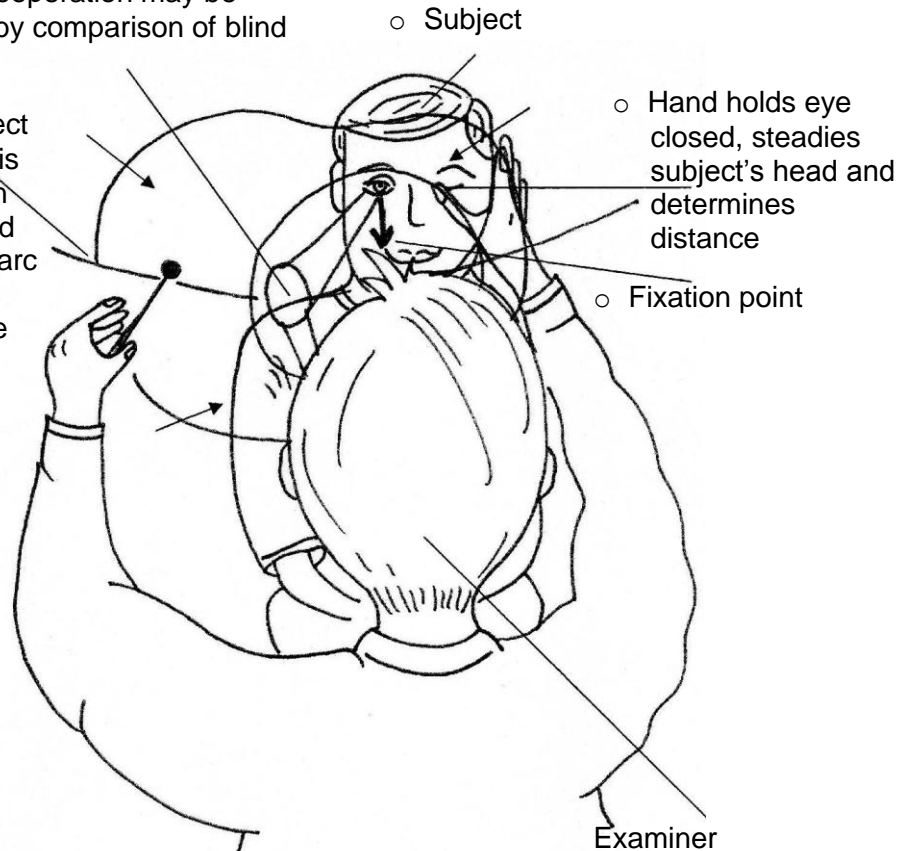


Introduction: General Neurological History and Physical Examination

➤ Neurologic examination

- Subject cooperation may be checked by comparison of blind spots

- Bring object in from this position in an arc and on same arc from the nasal side as shown



Adapted from: Mangione S. *Hanley & Belfus* 2000, page 409.


Useful background:

Useful terms

- Odds that a given symptom or sign is present in a person without the targeted disorder.
 - Sensitivity (SENS)
 - Likelihood of finding a sign or symptom when the target disorder is present (pid – positive in disease)
 - Specificity (SPEC)
 - Likelihood of not finding a sign or symptom when the target disorder is not present (nih- negative in health)



- Odds that a given symptom or sign is present in person with the target disorder (likelihood ratio)
 - LR (>1) = SENS/ 1-SPEC of a present finding in a person with the target disorder
 - LR (<1) of an absent finding in a person with the target disorder = 1-SENS/SPEC



- Sen N out – Sensitive test; when negative, rules ot disease
- Sp P in – Specific test; when positive, rules in disease

Abbreviation: NLR, negative likelihood ratio; PLR, positive likelihood ratio

Source: Filate W, et al. *The Medical Society, Faculty of Medicine, University of Toronto* 2005, page 25.

The language of neurology

- Agnosia
 - Failure to recognize, whether visual, auditory or tactile; Related to receptive dysphagia.
- Apraxia
 - Inability to carry out purposive movements in absence of motor paralysis, sensory loss or ataxia; Related to expressive dysplasia.
- Dysarthria
 - Difficulty with articulation
 - Causes
 - UMN lesion of the cranial nerves – pseudobulbar or bulbar
 - Extra pyramidal disease – monotonous speech
 - Cerebellar disease – altered rhythm of speech
 - Mouth ulcerations
 - Hearing
 - Alcohol intoxication



- Dysphasia
 - Disorder in use of symbols for communication, whether spoken, heard, written or read.
 - Expressive – Lesion of post. inf. 3rd frontal convolution
 - Receptive – Lesion of post. sup. temporal cortex, an angidengyrus of parietal lobe.
 - Dominant higher center disorder of the use of language (handedness: 94% of right-handed people and 50% of left-handed people have a dominant left hemisphere for language and math)
 - Screening flowing speech “Describe the room”
 - Comprehension “Touch your chin”, “Is this your right hand?”
 - Ask patient to name two objects you point to
 - Say “British constitution”
 - Writing
 - Conductive aphasic patients have impaired writing (dysgraphia) while receptive aphasic patients have abnormal content of writing.
 - Patients with dominant frontal lobe lesions may also have dysgraphia
 - Receptive
 - No understanding for spoken (auditory dysphasia) or written words in absence of deafness or blindness
 - Cannot follow verbal or written commands (“touch your nose, then your chin, then your ear”)
 - Cannot repeat “No ifs, ands or buts”
 - Lesion in posterior part of first temporal gyrus of the dominant hemisphere (Wernicke’s arga)
 - Expressive dysphasia
 - Motor apraxia – the patient understands spoken or written words, but cannot answer correctly
 - Automatic (recite a list, such as days of the week); emotional speech, maybe preserved
 - Lesion in posterior part of the third frontal gyrus (Broca’s area) of the dominant hemisphere
 - Nominal dysphasia
 - Specific objects cannot be named, but person may give a long answer to try to explain what the object is (circumlocution)
 - Lesion of posterior temporoparietal area of dominant hemisphere; encephalopathy; increased intracranial pressure (poor localizing value, and may occur in the recovery phase of receptive, expressive or conductive dysphasia)



- Conductive dysphasia
 - Poor naming, poor repetition of statements, good following of commands
 - Lesion of fibers joining Wernicke's and Broca's areas, or lesion in arcuate fasciculus
- Dysphonia
 - Decreased volume and altered tone of speech
 - Damage to larynx or recurrent laryngeal nerve palsy
- Echolalia
 - Parrot-like repetition by the subject of statements or acts made before them.
- Epilepsy
 - A paroxysmal transitory disturbance of brain function, ceasing spontaneously, with a tendency to recurrence.
- Myoclonus
 - A brief shock-like contraction of a number of muscle fibres, a whole muscle or several muscles, either simultaneously or successively.
- Perseveration
 - Meaningless repetition of an activity
- Verbigeration
 - Meaningless repetition of words or sentences

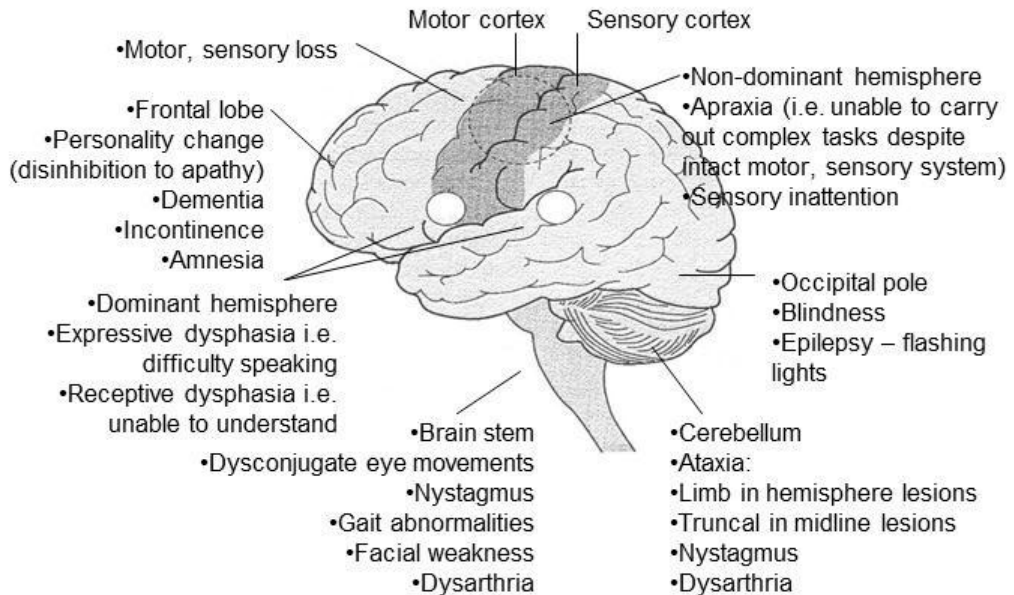
"A lot of things in medicine that make sense,
don't work out"

Grandad



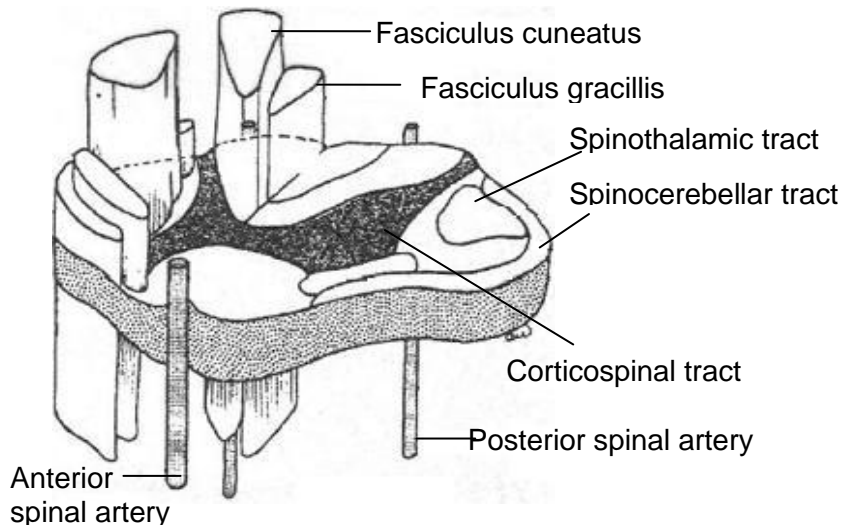
- Neuroanatomy refresher

- CNS lesion localization



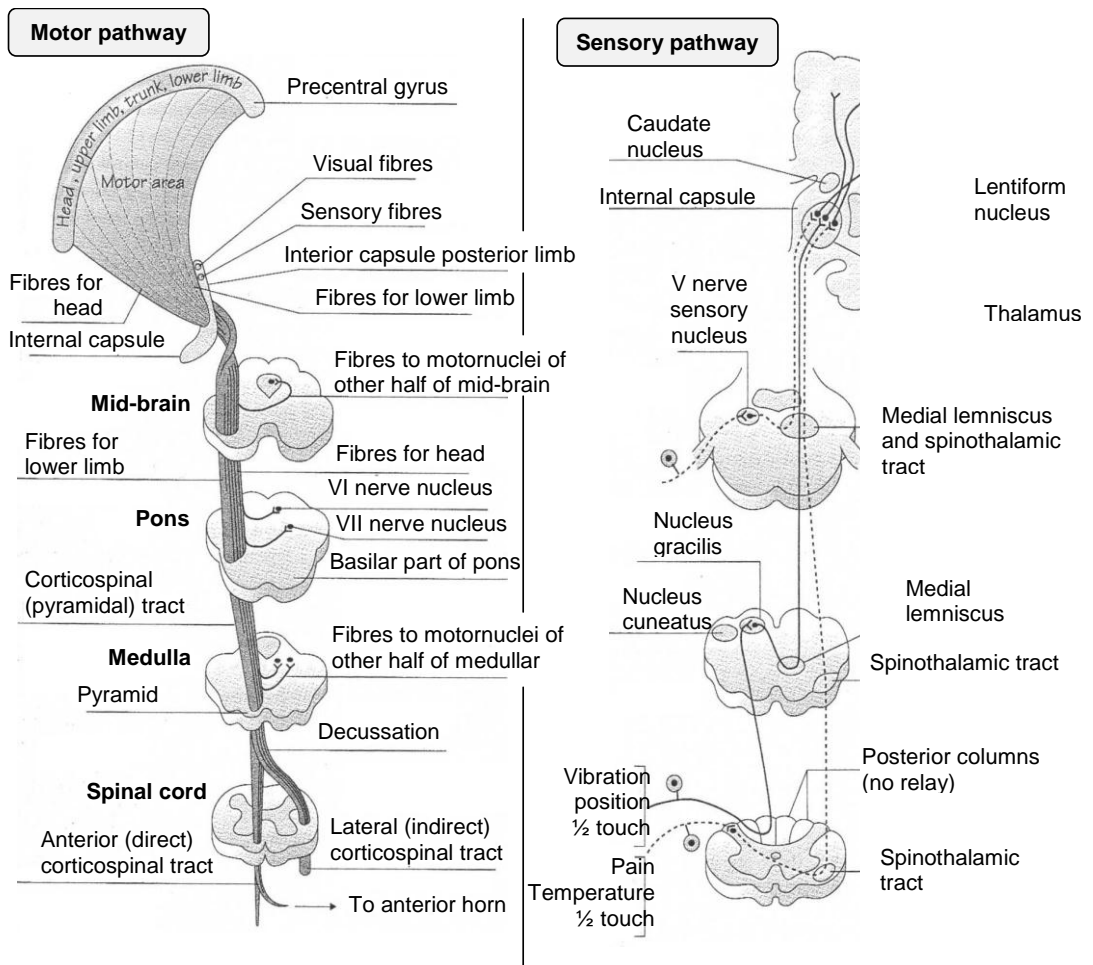
Adapted from: Davey P. *Wiley-Blackwell* 2006, page 88.

- Spinal cord section



Adapted from: Filate W., et al. *The Medical Society, Faculty of Medicine, University of Toronto* 2005, page 155.





Adapted from: Davey P. *Wiley-Blackwell* 2006, page 88.

Useful background: Muscle weakness may be caused by disorders at several sites of the nervous system:

- UMN
- LMN
- Cerebellum
- Extrapyrarnidal tracts
- Muscle diseases
- Malingering
- Sensory disturbance (the patient may describe their disability as “weakness”).



- Perform a focused physical examination of the nervous system to determine the site of the disorder causing the muscle weakness, altered tone as well as deep tendon reflexes.

	LMN*	UMN
Weakness	+	+
Wasting	+	-
Fasciculations	+	-
Tone	↓	↑ (“clasp knife” rigidity)
Affected muscle groups	Involves only a few muscles	Affects muscles of entire limb
Reflexes deep	↓ / Absent	↑
Superficial	↓	↓
Extensor plantars	-	+ (up-going toe)
Clonus	-	+

*Caused by involvement of motor pathway anywhere from anterior horn cell to nucleus (unlikely to be in spinal cord).

- Distinguish the hypotonicity of a LMN lesion from other lesion sites
 - Cerebellar
 - Posterior column
 - Sensory nerve tract
 - Transient after acute lesions of hemispheres or spinal cord
- Hypertonicity of an UMN lesion for extrapyramidal lesions
- ↓ deep tendon reflexes (DTR) of a LMN lesion from
 - A lesion of first sensory neurons (posterior nerve root or posterior column)
 - Decreased reflexes in absence of wasting, suggests a peripheral lesion
- ↑ DTR of an UMN lesion from
 - Pain
 - Emotion
 - Anxiety
 - Hysteria



- LMN
 - Weakness
 - Wasting
 - Fasciculation
 - Decreased tone
 - Decreased or absent reflexes (Reflexes present until late in the course of the muscle disease)
 - LMN wasting involves only a few muscles, whereas disease affects muscles of an entire limb
- UMN
 - Weakness
 - Increased tone clasp knife rigidity
 - Extensor plantars
 - Sustained true clonus
 - Increased deep tendon reflexes
 - Decreased superficial reflexes

Localizing Signs in UMN Weakness

Anatomic location	Associated finding
➤ Cerebral hemisphere	<ul style="list-style-type: none"> ○ Seizures ○ Hemianopia ○ Aphasia (right hemiparesis) ○ Inattention to left body, apraxia (left hemiparesis) ○ Cortical sensory loss* ○ Hyperactive jaw jerk
➤ Brainstem	<ul style="list-style-type: none"> ○ Crossed motor findings unilateral cranial nerve palsy opposite the side of limb weakness) ○ Contralateral third nerve palsy (midbrain) ○ Contralateral sixth nerve palsy (pons) ○ Sensory loss on contralateral face*
➤ Spinal cord	<ul style="list-style-type: none"> ○ No sensory or motor findings in face ○ Specific sensory level* ○ Pain and temperature sensory loss on contralateral arm and leg* ○ Additional LMN findings (e.g., atrophy, fasciculations)

Printed with permission: McGee SR. *Saunders/Elsevier* 2007, Table 57-4, page 720.



➤ Muscle stretch reflex scale

Grade	Finding
0	Reflex absent
1	Reflex small, less than normal; includes a trace response or a response brought out only with reinforcement
2	Reflex in lower half of normal range
3	Reflex in upper half of normal range
4	Reflex enhanced, more than normal; includes clonus if present, which optionally can be noted in an added verbal description of the reflex

Source: McGee SR. *Saunders/Elsevier* 2007, Table 59-2, page 757.

- Perform a focused physical examination of the nervous system.

➤ Handedness and conscious level

➤ Neck stiffness and Kernig's sign

➤ Cranial nerves

I	Smell
II	Visual acuity and fields Fundoscopy
III, IV, VI	Pupils and eye movements
V	Corneal reflexes Facial sensation
VII	Facial muscles
VIII	Hearing
IX X	Palate and gag
XI	Trapezius and sternomastoids
XII	Tongue

➤ Upper limbs

➤ Lower limbs

- Motor system (Tone, power, reflexes)
- Co-ordination
- Sensation

➤ Saddle region

➤ Back

➤ Gait

Adapted from: Talley NJ, et al. *Maclennan & Petty Pty Limited* 2003, page 441.



Useful background: Take a neurological history (mnemonic “**SHOVE**”)

- **S**yncope, speech defect, swallowing difficulty
- **H**eadache
- **O**cular disturbances; diplopia, field defects
- **V**ertigo
- **E**pilepsy; seizures
- History pertaining to motor and sensory components of the cranial nerves and limbs, e.g. pain paraesthesia, weakness, incoordination

Source: Baliga RR. *Saunders/Elsevier* 2007, page 107.

Neurological Examination

- Assessing level of mental status
 - Alertness
 - Lethargy
 - Consciousness
- Orientation
 - Time
 - Place
 - Person
 - Memory
 - Stuper
 - Coma
 - Language / speech
- Localization of Neurologic Disorders
 - Level
 - Cerebral hemisphere
 - Cerebellum
 - Brainstem
 - Spinal cord
 - Nerve root
 - Peripheral nerve
 - Neuromuscular junction
 - Muscle
 - Extent
 - Focal
 - Diffuse

Source: Mangione S. *Hanley & Belfus* 2000,



Useful background: Directed history for disorders of the central (CNS) and peripheral nervous system (PNS) (e.g. the Neurological system).

- Where is the lesion and what is the lesion? (example - loss of consciousness (LOC)/(syncope vs. seizure))
 - Complete vs. partial
 - Duration
 - Changes in body position (e.g. loss of balance, fetal position, prone)
 - Associated symptoms (erg tongue biting, body movements, incontinence)
 - Preceding symptoms (e.g. light-headedness)
 - Post attack symptoms (e.g. confusion, sleepiness)
 - Previous diagnosis of systemic disorders (e.g. cardiovascular problems)
 - Current medications
 - Collateral /corollary information (e.g. bystanders)

- Course
 - Onset (e.g. thunderclap)
 - Pattern (e.g. worse in the morning=increased ICP)
 - Differences from previous headaches (type/pattern)
 - Associated symptoms (e.g. nausea and/or vomiting, neck stiffness)
 - Preceding symptoms/aura
 - Systemic conditions (e.g. infections)
 - Current medications/addictions

Abbreviations: CNS, central nervous system; LOC, loss of consciousness; PNS, peripheral nervous system

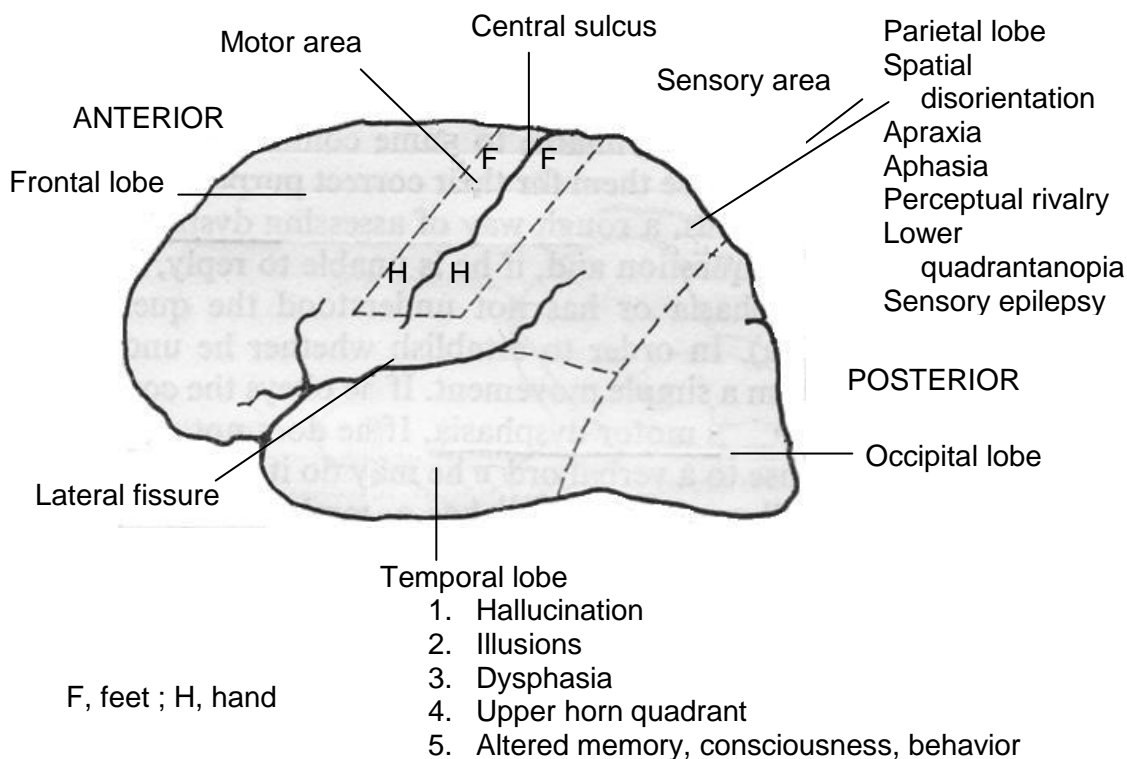
Source: Filate W., et al. *The Medical Society, Faculty of Medicine, University of Toronto* 2005, Table 2, page 156 to 159; and Baliga RR. *Saunders/Elsevier* 2007, page 107.

"All life is an experiment. The more experiments you make, the better"

Ralph Waldo Emerson



The cerebral cortex: position of the lobes and the motor and sensory areas



Adapted from: Davey P. *Wiley-Blackwell* 2006,

- Take a directed history and perform a focused physical examination for disease of the cerebral hemispheres.
 - Mental status
 - Cortex
 - Seizures
 - Speech / language
 - E.g., aphasia
 - Eyes
 - Visual field defects
 - Motor
 - Hemiparesis
 - Involuntary movements
 - Dystonia
 - Chorea
 - Hemiballismus
 - Sensory
 - Hemianesthesia



Cerebral Cortex

- Precentral gyrus
 - Anterior to central sulcus
 - Motor function
 - The top of the motor cortex (precentral gyrus) is involved with movements of the feet, whereas the bottom of the motor cortex is involved with movement of the face.
- Postcentral gyrus
 - Posterior to central sulcus
 - Sensory function
 - Just as with the precentral gyrus, with the post central gyrus, the top of the sensory cortex (post central gyrus) is involved with feet, and the bottom is involved with the face.
- Frontal lobe
 - Forethought
 - Consequences
 - Apathy
 - Dementia
 - Group reflex
 - Ataxia
 - Akinesia
 - Asplasia
- Motor cortex
 - UMN hemiplegia
 - Jacksonian-epilepsy
 - Expressive dysphasia
- Parietal lobe
 - spatial disorientation
 - apraxia
 - agnosia
 - perceptual
 - receptive dysphasia
 - homonymous hemianopia
 - Jacksonian sensory epilepsy
- Temporal lobe
 - Hallucinations
 - Illusions
 - Receptive dysphasia
 - Altered - memory, concentration, behavior
 - Upper homonymous quadrant anopia
- Perform a focus physical examination of the motor cortex.
- Expressive dysphasia
- Hemiplegia focal



- Jacksonian focal epilepsy
- Agnosia (sensory, receptive)
 - Failure to recognize
 - Visual
 - Auditory
 - Tactile
- Apraxia (motor, expressive)
 - Failure to carry out purposeful movements in the absence of motor, sensory
- Perform a focused physical examination for a disorder of the cortex of the frontal lobe.
 - Intellectual function
 - Dementia
 - Indifference
 - Incontinence
 - Lack of fore thought
 - Failure to anticipate/recognize consequence of behavior
 - Precentral motor cortex
 - Hemiplegia
 - Jacksonian focal epilepsy
 - Expressive dysphasia (only if the frontal lobe of the dominant hemisphere is affected)
 - “grasp” reflex of limbs of the opposite side of the body
 - Compression of olfactory tracts
 - Anosmia
 - Compression of optic nerves
 - Optic atrophy of affected side
 - Papilledema of opposite side
- Perform a focused physical examination for a disorder of the cortex of the parietal lobe.
 - Eyes
 - Lower homonymous quadrantanopia
 - Post-central gyrus
 - Cortical sensory loss to the same side of the body
 - Tests of cortical sensory loss:
 - Stereognosis



- Two point discrimination
 - Localization of stimulus to the correct part of the body
 - Correct recognition of letters or figures traced out on the skin
- Dominant lobe, parietal lobe cortex
 - Sensory aphasia
 - Acalculia
 - Alexia
 - Agraphia
 - Non-dominant lobe
 - Inattention
 - Inability to recognize the left half of the body
 - Variation of signs from one day to another
 - Perform a focused physical examination for a disorder of the temporal lobe.
 - Eyes
 - Upper homonymous quadrant anopia
 - Hallucinations
 - Taste and smell
 - Auditory (associated with temporal lobe epilepsy)
 - Dazed look
 - Illusions
 - Excessive number of sensations of deja-vu phenomenon
 - Receptive dysphasia
 - Altered memory, consciousness, memory
 - Take a directed history and perform a focused physical examination to determine the presence of disease of the parietal, temporal, frontal and occipital lobes.
 - Parietal lobe
 - Dysphasia (dominant)
 - Dominant parietal lobe signs (Gerstmann syndrome)
 - Acalculia
 - Agraphia
 - Left - right disorientation
 - Finger gnosis



- Sensory and visual inattention
- Construction and dressing apraxia
- Spatial neglect and inattention and non-dominant parietal lobe signs
- Non-dominant parietal lobe signs
 - Lower quadrantic hemianopia
 - Asterognosis
- Temporal lobe
 - Memory loss
 - Upper quadrantic hemianopia
 - Dysphasia (receptive if dominant lobe)
 - Seizures
- Frontal lobe
 - Personality change
 - Primitive reflexes (e.g. grasp)
 - Anosmia
 - Optic nerve compression (optic atrophy)
 - Gait apraxia
 - Leg weakness (parasagittal)
 - Loss of micturition control
 - Dysphasia (expressive)
 - Seizures
- Occipital lobe
 - Homonymous hemianopia
 - Alexia
 - Seizures (flashing light aura)

Adapted from: Talley NJ, et al. *Maclennan & Petty Pty Limited* 2003, Table 10.4, page 353.

Useful background: Clinical Features of Seizures

- Simple partial seizures
 - Motor, sensory, autonomic or cognitive/perceptual features
 - No impairment of awareness
 - Usually brief (<60 seconds)
- Complex partial seizures
 - Focally originating seizures characterized by impaired awareness and a blank stare



- May begin with an aura (simple partial seizure), but may also have impaired awareness from onset
 - Usual duration of 1-2 minutes
 - Frequently accompanied by motor automatisms, such as lip smacking, chewing movements or fumbling/picking hand movements
 - Brief postictal confusion or fatigue is common
 - Commonly misdiagnosed as absence seizures, a much less common seizure type (see below)
- Absence (“petit mal”)
 - Primarily generalized seizure type
 - Usually last only 10-15 seconds
 - Recur daily (sometimes > 100 times per day) in the untreated patient
 - No warning signs or postictal confusion
 - Onset in childhood or adolescence (almost never *begin* in adulthood)
 - Do not confuse with complex partial seizures (see above)
 - Primarily or secondarily generalized tonic-clonic (“grand mal”):
 - Fairly uniform sequence of motor feature (tonic and clonic phases)
 - Impaired consciousness
 - Duration of 1-2 minutes
 - Postictal stupor, confusion and headache
 - A careful history may reveal a partial seizure, e.g., simple partial or complex partial, that secondarily evolves to a generalized tonic-clonic seizure
 - Atonic seizures
 - Abrupt loss of consciousness and muscle tone
 - No other motor features
 - Return to awareness within seconds
 - Occur as part of a clinical scenario in patients with childhood onset epilepsy, significant intellectual disability and other seizure types
 - Almost never occur in otherwise intellectually and physically normal adults
 - Myoclonic seizures
 - A generalized seizure type consisting of brief, bilateral “shock-like” jerks
 - Multifocal asynchronous myoclonic jerks most commonly occur in the setting of a metabolic encephalopathy
 - Consider whether the clinical features suggest one of the entities commonly mistaken for epileptic seizures, such as syncope or psychogenic nonepileptic seizures

Reproduced with permission: Therapeutics Choices. Sixth Edition. Ottawa, Canada: *Canadian Pharmacist Association* 2012, page 292-293.



Anterior cerebral artery (ACA)

- The medial striate artery (Heubner's artery) provides blood to the anterior portion of the internal capsule, which carries fibers which supply the upper portion of the body.
- Occlusion of the ACA beyond the medial striated artery will cause the following signs:
 - Speech
 - Motor dysphasia
 - Involvement of dominant side
 - Results from damage to the precentral gyrus (motor cortex) of the frontal lobe
- Sensory
 - Cortical sensory loss of contralateral leg (only if the superior surface of the cerebral cortex is affected)
- Motor
 - Cortical flaccid weakness of contralateral leg
- Frontal lobe signs
 - Grasp reflex
 - Incontinence
 - Intellectual decline
 - Indifference

• Middle cerebral artery (MCA)

- This important artery supplies
 - Most of the internal capsule by way of the lateral striated arteries
 - Cortical receptive and expressive speech areas
 - Superior part of the motor and sensory cortex (affecting the upper part of the body)
 - Most of the frontal, temporal and parietal lobes
- Obstruction of the lateral striate branches causes:
 - Eyes
 - Hemianopia (visual fibers in the internal capsule)
 - Motor
 - Contralateral spastic paralysis, or
 - Flaccid paralysis (if frontal branches are blocked)
 - Sensory
 - Cortical sensory loss in the upper part of the body (rontal branches)
 - Parietal and temporal lobe signs (of branches to the parietal and temporal lobes are obstructed)



Posterior cerebral artery (PCA)

- Flows to the occipital lobe, thalamus and midbrain
 - Occlusion of PCA
 - Distal to the thalamic branch
 - Homonymous
 - Hemianopia with macular sparing
 - Proximal to the thalamic branch
 - As above, plus the thalamic syndrome
 - Thalamic syndrome
 - Enhanced sensory sensitivity of one half of body
 - Severe pain
 - Occlusion of both PCAs
 - Cortical blindness
 - Blindness:
 - Patient does not know when a light is shone in the eyes
 - Patient may not realize that they are blind, or may even deny that they cannot see
- Perform a focused physical examination to distinguish between an intramedullary from an extramedullary cord lesion.

	Intramedullary	Extramedullary
➤ Root pain	○ Rare	○ Common
➤ Corticospinal signs	○ Late onset	○ Early onset
➤ LMN signs	○ Extend for several segments	○ Localized
➤ Sensory loss	○ Dissociated sensory loss (pain and temperature) may be present	○ Brown-Sequard syndrome if lateral cord compression
➤ Sacral sparing	○ May have sacral sparing	○ No sacral sparing
➤ CSF fluid	○ Normal or minimally altered	○ Early, marked abnormalities

Abbreviations: CSF, cerebrospinal fluid; LMN; lower motor neuron

Adapted from: Talley NJ, et al. *MacLennan & Petty Pty Limited* 2003, Table 10.28, page 427.



- Perform a focused physical examination for the "dorsal midbrain syndrome".
(A hint: aka "Parinaud's Syndrome", "Sylvian Aqueduct Syndrome", or "Pretectal Syndrome")
- Light-near dissociation
- Vertical gaze palsy
- Lid retraction
- Convergence-retraction nystagmus (a rhythmic inward movement of both eyes from co-contraction of the extraocular muscles, usually elicited during convergence or upward gaze)
- Causes
 - Pinealoma (in younger patients)
 - Multiple sclerosis and basilar artery strokes (in older patients)

Adapted from: McGee SR. *Saunders/Elsevier* 2007, page 216.

Cranial Nerves

Introduction

Remember: You need to establish where is the lesion, and what likely is the lesion.

Useful background: Cranial nerve supply

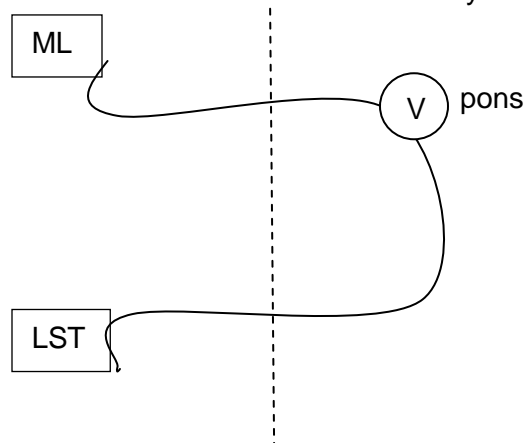
- Olfactory
 - Smell
- Optic
 - Vision
- Oculomotor
 - All ocular muscles, except superior oblique and lateral rectus
 - Ciliary muscle
 - Sphincter papillae
 - Levator palpebrae superioris
- Trochlear superior oblique muscle
 - Tested by asking patient to look down and inwards
- Trigeminal
 - Sensory for face, cornea, sinuses, nasal mucosal, teeth, tympanic membrane and anterior two thirds of tongue
 - Motor to muscles of mastication



- Abducens (External rectus muscle)
- Facial
 - Motor to scalp and facial muscles of expression
 - Taste in anterior two thirds of tongue (via chorda tympani)
 - Nerve to stapedius muscle
- Auditory and vestibular components
- Glossopharyngeal
 - Sensory for posterior one third of tongue, pharynx and middle ear
 - Taste fibres for posterior one third of tongue
 - Motor to middle constrictor of pharynx and stylopharyngeus
- Vagal
 - Motor to soft palate, larynx and pharynx (from nucleus ambiguus)
 - Sensory and motor for heart, respiratory passages and abdominal viscera (from dorsal nucleus)
- Spinal accessory
 - Motor to sterno mastoid and trapezius
 - Accessory fibres to vagus
- Hypoglossal Motor to tongue and hyoid bone depressors

Source: Burton JL. *Churchill Livingstone* 1971, page 73.

- Medial longitudinal bundle
 - Interconnects the cranial nerve nuclei
 - Co-ordinates movements of face and eye



- CN V (trigeminal nerve)
 - Ascending tract
 - Fibers for proprioception and left touch (just like the posterior columns)
 - Ascending tract (AT) fibers cross the midline and join the medial lemniscus (ML)
 - Descending tract (of CN V)
 - Fibers for pain and temperature (just like the lateral spinothalamic tracts)
 - Descending tract (DT) fibers descend to C2 on the same side
 - From C2, DT fibers cross the midline to join the lateral spinothalamic tract (LST)

- Tractus solitarius
 - Fibers for taste

- Corticospinal tracts

SO YOU WANT TO BE A NEUROLOGIST!

Q1. Crossed hemiplegia may be caused for example by a CVA, causing hemiplegia on one side of the body, but weakness on the other side of muscles supplied by cranial nerves IX to XII. Give two other causes of crossed hemiplegia.

- A1.
- Weber's syndrome - Ipsilateral cranial nerve III LMN lesion, with contralateral hemiplegia
 - Miller-Gubler syndrome - Ipsilateral cranial nerve VI lesion (supplies the lateral rectus muscle), with contralateral hemiplegia
 - Foville's syndrome - The eyes are fixed towards the side of the hemiplegia (paralysis of conjugate deviation towards the side of the lesion)

Q2. Distinguish by looking at the eyes whether a patient's hemiplegia is due to a lesion in the internal capsule or brainstem (Foville's syndrome)

- A2. Conjugate deviation towards side of lesion Foville's syndrome
 Conjugate deviation away side of lesion internal capsule

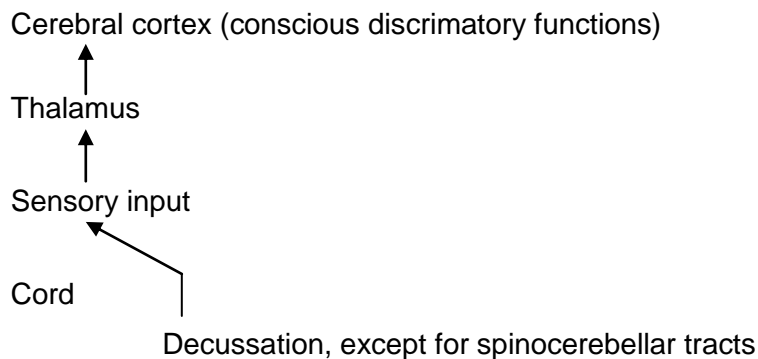


The medial lemniscus terminates in the thalamus.

➤ Nuclei of the cranial nerves

- Midbrain
- Culomotor
 - Trochlear
- Pons
 - Abducens
 - Trigeminal
 - Facial
 - Auditory
- Medulla
 - Glossopharyngeal
 - Vagus
 - Accessory
 - Hypoglossal

Sensory pathway



- Perform a focused physical examination of the cranial nerves (CN).

➤ I (Olfactory) smell (sensory) (detecting non irritating odours)

- Coffee, mint, vinegar

Translational Neuroanatomy

CN I

- Nerve endings in ciliated receptors in mucous membrane of upper part of nasal cavity
 - ↓
- Cribriform plate of ethmoid bone
 - ↓
- Olfactory bulb and tract

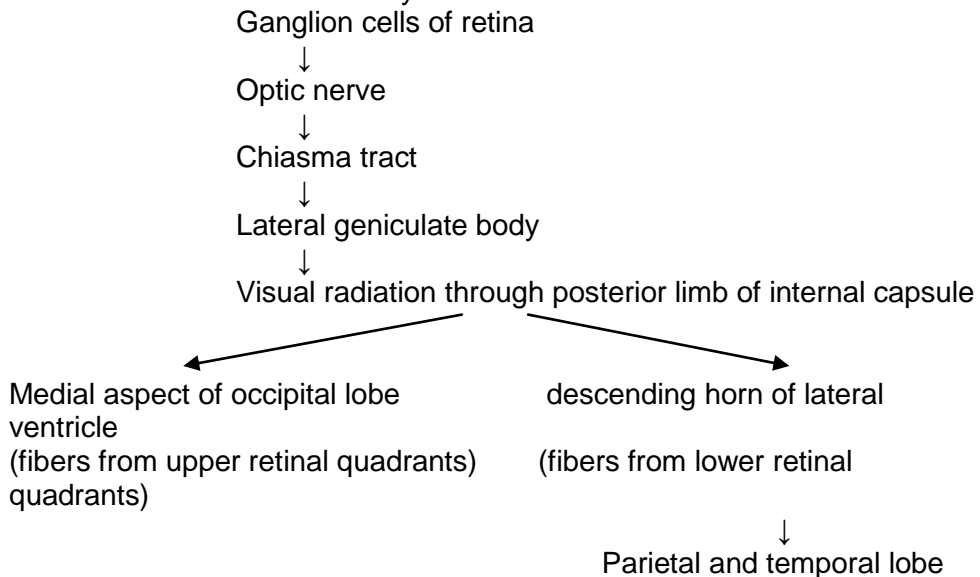


- ↓
- Mammillary bodies of hypothalamus
- ↓
- Uncinate and hippocampal gyri of both temporal lobes

The Eye: CN II

- The eyes, and cranial nerve II (Optic)-vision (sensory)
 - Visual acuity (Snellen visual chart)
 - Visual fields by confrontation
 - Colour test
 - Reflex
 - Papillary light reflex (perform at time of fundoscopy: tests CN III)
 - Accommodation to light
 - Red reflex
 - Fundoscopy
 - Retinal vessels
 - Optic disc
 - Macula
 - Lesions

➤ Translational Neuroanatomy



➤ Fibers from

- Upper retinal quadrant cuneate gyri above calcarine fissure
- Lower retinal quadrant lingular gyri below
- Macula
 - Posterior aspect of occipital pole
 - Bilateral cortical representation



Useful background: Visual Field Defects

- Monocular defects are usually due to a problem in the affected eye, whereas binocular visual field defects are usually intracranial in origin
- III Nerve palsy: affected side dilated (mydriasis), ptosis, weak extraocular muscle except lateral rectus and superior oblique

Causes of sudden blindness

- Brain
 - Trauma- ocular or post head injury
 - CVA
 - Migraine
 - Hyteria Vitreous haemorrhage, especially in diabetics
- CN II
 - Cranial arteritis
 - Toxins eg methanol
 - Retrobulbar neuritis
- Retinal vessels
 - Embolism of retinal artery
 - Thrombosis of retinal vein
- Retina
 - Retinal detachment
- Intraocular
 - Acute glaucoma

Adapted from: Burton JL. *Churchill Livingstone* 1971, page 82.

Useful background: Causes of uveitis

- (Uveal tract= iris, ciliary body and choroid)
- Miscellaneous, systemic disease
 - GI
 - Ulcerative colitis
 - Crohn's disease
 - MSK
 - Ankylosing spondylitis
 - Rheumatoid arthritis
 - Reiters disease
 - Behcets disease



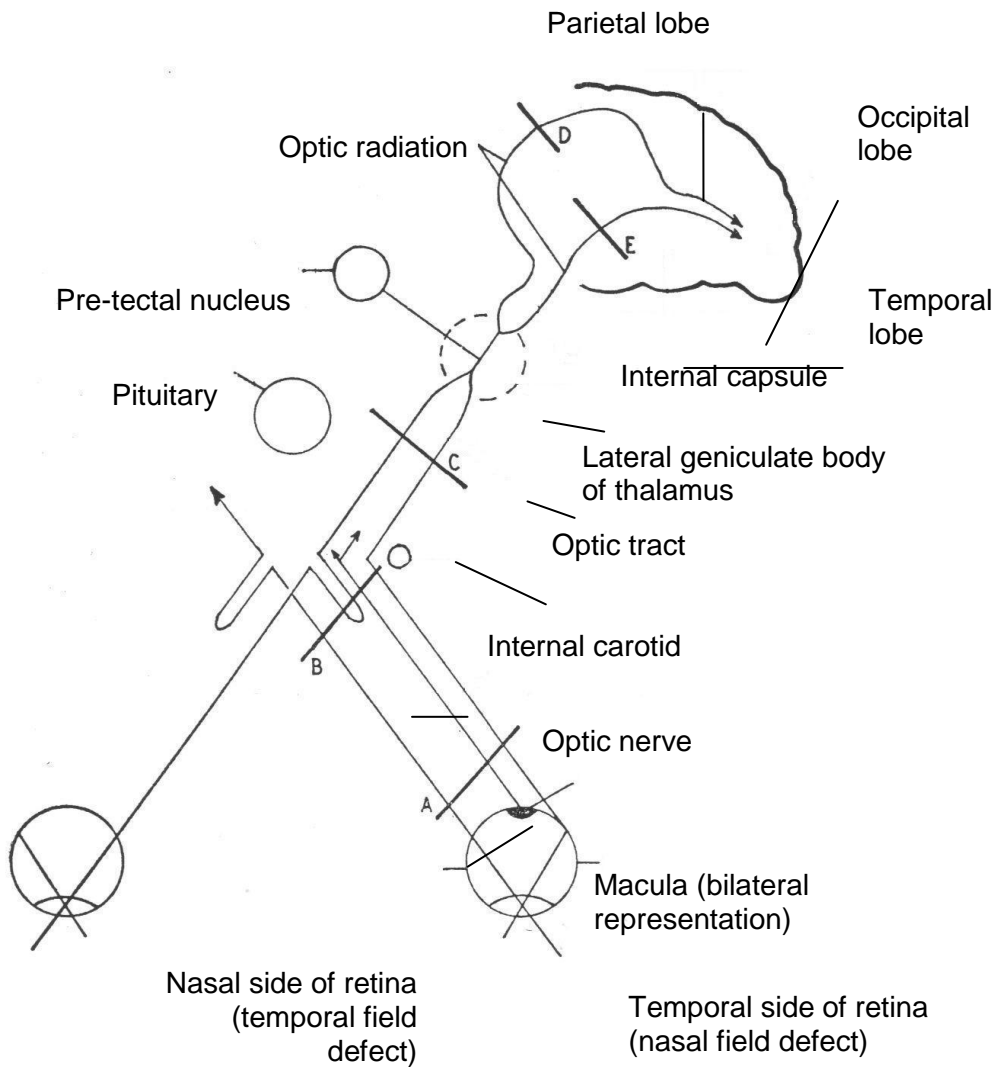
- Lung
 - Sarcoidosis
- Infections
 - Bacterial: TB
 - Spirochaetal: Sy. Relapsing fever, Weil's disease
 - Protozoal: Malaria, toxoplasmosis
 - Nematode larvae: Toxocara of dog or cat
- Secondary to ocular disease
 - Ophthalmitis
 - Trauma
- Idiopathic

Adapted from: Burton JL. *Churchill Livingstone* 1971, page 81.

- Perform a focused physical examination for the causes of sudden blindness.
- Artery
 - Embolus
 - Arteritis
- Vein
 - Thrombus
- Ret. Neurotic, including toxins
- Retinal detachment
 - Trauma
 - Tumour
 - Toxemia
 - Myopia
- Retinal hemorrhage
 - Diabetes
 - Edwards
- Glaucoma
- CVA
- Migraine
- Hysteria



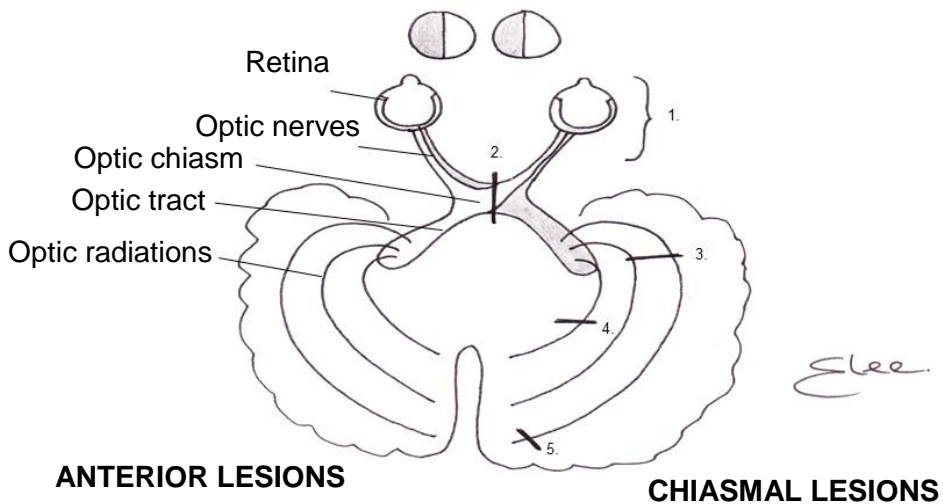
The visual pathways



- Note the pituitary in relation to nasal fibres from both retinae.
- The optic radiation.
- The internal carotid artery
- The macular fibres passing to both optic tracts.



Useful background: Lesions of the visual fields



- 1. Constricted visual field
- 1. Arcuate scotoma
- 1. Altitudinal defect
- 1. Central scotoma

- 2. Bitemporal hemianopia
- 3. **POSTCHIASMAL LESIONS**
Left homonymous superior quadrantanopia
- 4. Left homonymous inferior quadrantanopia
- 5. Left homonymous hemianopia with macular sparing

Adapted from: Talley NJ, et al. *MacLennan & Petty Pty Limited* 2003, page 363; McGee S. R. *Saunders/Elsevier* 2007, pages 664-665; and Davey P. *Wiley-Blackwell* 2006, page 99.



➤ Visual field defects (CN II)

Lesion Location	Anatomy	Signs and symptoms
➤ One eye	○ Anterior to optic chiasm	- Glaucoma - Retinal hemorrhage - Optic neuropathy - Central retinal artery occlusion (leads to potential monocular blindness [amaurosis fugax])
➤ Both eyes (bitemporal hemianopia)	○ At optic chiasm	- Upper > lower – inferior chiasmal compression (pituitary adenoma) - Lower > upper – superior chiasmal compression
➤ Both eyes (homonymous hemianopia)	○ Behind optic chiasm	- Cerebral infarcts - Hemorrhage - Tumors

Source: Filate W, et al. *The Medical Society, Faculty of Medicine, University of Toronto* 2005, page 158.

SO YOU WANT TO BE A NEUROLOGIST!

Q1. What is the 'reversed' Argyll Robertson pupil?

- A1. ○ The pupil react to light but not to accommodation
○ Seen in parkinsonism caused by encephalitis lethargic

Q2. What causes miosis?

- A2. ○ Old age
○ Pilocarpine (treatment for glaucoma)

Q3. What non-neurological conditions cause an eccentric pupil?

- A3. ○ Trauma
○ Iritis



Useful background: Amaurosis fugax – definition

- Transient monocular blindness due to episodic retinal ischemia, usually associated with ipsilateral carotid artery stenosis or embolism of the retinal arteries resulting in a sudden and frequently complete, loss of vision in one eye.

Useful background: Causes of gradual blindness

- CNS – Migraine
- CN III - Optic neuritis
 - Atrophy
 - Papilloedema
- Retina - Retinal degeneration
- Intraocular – Glaucoma
- Lens - Cataracts
- Perform a focused physical examination for the causes of retinal hemorrhage.
 - Brain
 - ↑ ICP, including subarachnoid hemorrhage
 - Eye
 - Eye – trauma
 - Retinal vessels
 - Artery
 - HBP
 - Arteritis
 - Vein
 - Thrombosis
 - Retina
 - Retinal detachment, including tumour
 - Hematology
 - Anemia (severe)
 - Bleeding diathesis (severe)
 - Diabetes

Abbreviations: CNS, central nervous system; ICP, intracranial pressure; HBP, hypertension

Adapted from: Burton JL. *Churchill Livingstone* 1971, page 22.



SO YOU WANT TO BE A NEUROLOGIST!

Q1. In the context of blindness, what is amaurosis fugax?

- A1. A transient monocular blindness due to episodic retinal ischemia, usually associated with ipsilateral carotid artery stenosis or embolism of the retinal arteries resulting in a sudden, and frequently complete, loss of vision in one eye.

Source: Jugovic PJ, et al. *Saunders/ Elsevier* 2004, page 150.

Q2. Why does obstruction of the PCA distal to the thalamic branch not affect the macula?

- A2. Because the macula is supplied by both the MCA and the PCA

Q3. From the physical examination, how would you determine if the patient had cortical blindness (CB) from occlusion of the PCAs, versus damage to the optic tracts (OT), optic nerve (ON) or the retina (R)?

A3.	Finding	OT/ON/R	CD
<input type="radio"/>	Pupillary reflexes	+	normal
<input type="radio"/>	Fundus	+	normal
<input type="radio"/>	Awareness when light shone in eyes	+	no

Q4. In the context of an abnormal examination of the eyes, what is Eales' Disease.

- A4. Periodic vitreous hemorrhage and pre-retinal (subhyaloid) hemorrhages.
 Disease of young man attributed to tuberculosis periphlebitis.

Useful background:

- Causes of concentric diminution (tunnel vision)
- Brain
 - Anterior calcarine cortex
 - Migraine
 - Hysteria
 - Occipital cortex
- CN II
 - Papilloedema
 - Retro-neuritis



- Retinal vessels
- Retinal disease
- Glaucoma
- Causes of bitemporal hemianopia (Central chiasmal lesions)
 - Pituitary or peri-sellar tumour
 - Inflammatory, vascular or traumatic lesions
- Binasal hemianopia
 - Bilateral lesions confined to the uncrossed optic fibres.
- Causes of homonymous hemianopia (HN)
 - Optic tract lesions – usually due to tumours, which produce a progressive hemianopia, which bisects the macula, commonly due to thrombosis of the posterior cerebral vessels.
- Causes of homonymous quadrantanopia
 - Anteriorly placed lesions of the optic radiation, especially temporal lobe tumours. More posterior lesions of the optic radiation become more hemianopic.

Abbreviations: HN, homonymous hemianopia

Source: Burton JL. *Churchill Livingstone* 1971, page 79.

- Perform a focused physical examination of the fundus for hypertensive retinopathy.
- Vasoconstrictive phase
 - Constriction of 2nd or 3rd branching point of the
 - Retinal arteries usually not visible with direct
 - Examination with ophthalmoscope
- Sclerotic phase
 - Narrowing of arteries
 - AV nicking (narrowing of retinal vein where crossed by the artery)
 - ↑ light reflex (from thickening of anterior wall of retinal artery)
- Exudative phase
 - Flame-like hemorrhages
 - Exudates, hard
 - Cotton-wool spots



➤ Complications

- Central retinal artery occlusion (CRAO)*
- Branch retinal artery occlusion (BRAO)
- Central retinal vein occlusion (CRVO)**
- Branch retinal vein occlusion (BRVO)***

*appearance of CRAO

- Fundus – pale
- Retina – swelling
- Macula – cherry – red
- Afferent papillary defect

**appearance of CRVO

- Veins
 - Engorgement
 - Dilation – microaneurysm
- Retina
 - Multiple dot or flame hemorrhages in all parts of retina
 - Cotton-wool spots
- Optic disc – edema

***BRVO

- Occlusion of branch vein produces changes only in that quadrant
- Flame hemorrhages
- Cotton-wool spots
- Vein distal to occlusion
 - Dilated
 - Tortuous

Source: Mangione S. *Hanley & Belfus* 2000, page 96.

● **Retinal lesions**

➤ Light-coloured spots

- Cotton-wool spots (“soft” exudates); small retinal infarcts due to occlusion of the end-arteriole.
 - White
 - Opaque
 - Indistinct
 - Can obscure adjacent vessels
- Hard exudates (leaky vessels)
 - Whitish yellow
 - Distinct
- Drusen deposit



- Yellow
- Located in the macula or in the peripheral retina
- Distinct
- Round
- Myelinated nerve fiber
 - White
 - Obscure blood vessels
 - Bright
 - No clinical significance

Source: Mangione S. *Hanley & Belfus* 2000, page 97.

Useful background:

- Causes of cotton-wool spots and hard exudates
 - Metabolic
 - Hypertension
 - Diabetes
 - Infiltration
 - Leukemia
 - Lymphoma
 - Infection
 - Bacterial endocarditis
 - HIV-associated CMV
 - Vascular
 - Microemboli
 - Anemia
 - Increased intracranial pressure (papilledema)
- Causes of red spots
 - Microaneurysms
 - Blot and dot hemorrhages –
 - arise from bleeding in the middle retinal layer in the retina
 - Common in diabetes
 - Flame and splinter hemorrhages
 - Arise from bleeding in the superficial nerve fiber layer in the retina
 - Paralle to orientation of nerve fibers running out from the optic disc
 - Common in hypertension
 - Preretinal hemorrhages (including subhyaloid hemorrhages)
 - Roth spots
 - Red (hemorrhage) with white (fibrinous) centre
 - SBE, diabetes, intracranial bleed

Source: Mangione S. *Hanley & Belfus* 2000, page 99.



➤ **Dark-coloured spots**

- Retinitis pigmentosa
 - Pigment arranged in a spicule formation
- Retinal pigment epithelial hypertrophy
 - Pigmented lesions
 - Numerous (>4)
 - Bilateral
 - Varying sizes and shapes
 - The grouping together of the pigmented spots suggest “bear tracks”
 - Normal vision
 - 78% sensitive, and 95% specific for Gardner’s syndrome
- Choroid pigmentation
 - Benign nevi
 - Flat
 - Grey/ green
 - Indistinct borders
 - Melanoma raised
- Healed chorioretinitis
- Laser scars, treated diabetic retinopathy

Source: Mangione S. *Hanley & Belfus* 2000, page 18.

➤ **Finding in diabetic retinopathy**

- Microaneurysms
- Dot and blot hemorrhages
- Cotton-wool spots, and hard exudates
- Neovascularization PDR (proliferative diabetic retinopathy)
 - Cotton-wool spot followed by development of tiny, irregular vessels
 - Preretinal or vitreous hemorrhages
 - Traction retinal detachment
 - Whitish area of retina
 - Fine surface folds
 - Loss of light reflex
- Almost always followed by diabetic nephropathy (Kimmel stiel-wilson glomerular disease)



- Perform a focused physical examination of the eye for macular degeneration.
- Dry type
 - Drusen yellow, round, distinct deposits
 - Loss of pigmentation
 - Prominent choroidal vessels (because of the loss of the retinal pigment epithelium)
- Wet type
 - Grey/ green area
 - Hemorrhage and exudates
 - Scaring of the macula

Useful background: Causes of central scotoma*

- Brain
 - Demyelinating disorders (multiple sclerosis)
- CN II
 - Optical nerve compression by tumor, aneurysm
 - Toxins – methanol, tobacco, lead, arsenical poisoning
 - Hereditary disorders – Friedreich’s ataxia, Leber’s optic atrophy
- Retinal vessels
 - Ischemia
 - central retinal artery occlusion (thromboembolism)
 - temporal arteritis
 - syphilis
 - idiopathic acute ischemic neuropathy
- Retina
 - Secondary to retinitis pigmentosa
- Intraocular
 - Glaucoma
- Metabolic
 - Vitamin B₁₂ deficiency

*Scotoma is a small patch of visual loss within the visual field.

Adapted from: Baliga RR. *Saunders/Elsevier* 2007, page 135.



SO YOU WANT TO BE A NEUROLOGIST!

Q1. What is the Argyll Robertson pupil; give its clinical features, explain the underlying neuroanatomy and provide a systemic approach to its causes.

A1.

- Definition: The Argyll Robertson pupil is a pupil which reacts to accommodation, but not to light
 - Neuroanatomy
 - Unlike the pupillary light reflex, the efferent fibers of the accommodation reflex do not pass through the ciliary ganglion
 - Thus, a lesion of the oculomotor (CN III) nerve fibers damages the area of the ciliary ganglion will prevent the light reflex but not the accommodation reflex
 - Sympathetic innervation may also be impaired
 - Clinical features
 - Pupils react to accommodation but not to light
 - Pupils are not always small
 - Pupils may react a little to light (constriction), but with constriction not being maintained
 - Small irregular pupil
 - Patchy atrophy of iris
 - Depigmentation of iris
- Perform a focused physical examination for the causes of the Argyll Robertson pupil.
 - Infection
 - Neurosyphilis – tabes dorsalis
 - Brainstem encephalitis
 - Sarcoidosis
 - Infiltration
 - Pinealoma
 - Tumors of the posterior portion of the third ventricle



- Metabolic
 - Diabetes mellitus and other conditions with autonomic neuropathy
 - Lyme disease
- Degenerative
 - Multiple sclerosis
 - Syringobulbia

Adapted from: Baliga RR. *Saunders/Elsevier* 2007, page 128.

Cause of dilated pupils and contracted pupils

- Dilated
 - CN III
 - Third nerve lesion
 - Holmes – Adie syndrome (degeneration of nerve to the ciliary ganglion)
 - Iris
 - Blunt trauma to the iris (pupil may be irregularly dilated and reacts sluggishly to light – post – traumatic iridoplegia)
 - Lens
 - Lens implant
 - Iridectomy
 - Drugs
 - Mydriatic eye drops
 - Drug overdose, eg. cocaine, amphetamine
 - Poisoning, e.g. Belladonna
 - Coma, death
 - Deep coma
 - Death
- Contracted
 - Old age
 - CN III
 - Pons
 - Argyll Robertson pupil (distinguish)
 - Pontine lesion
 - Narcotics
 - Sympathetic
 - Horner syndrome
 - Drugs
 - Pilocarpine eye drops

Adapted from: Baliga RR. *Saunders/Elsevier* 2007, page 131.



➤ Causes of papilledema

- Increased intracranial pressure
 - Space occupying lesion (causing raised intracranial pressure), or a retroorbital mass
 - Benign intracranial hypertension (pseudotumour cerebri) (small or normal sized ventricles)
 - Idiopathic
 - Oral contraceptive pill
 - Addison's disease
 - Drugs- e.g. nitrofurantoin, tetracycline, vitamin A, steroids
 - Head trauma
- Increased formation of CSF- e.g. choroids plexus papilloma (rare)
- Decreased absorption of CSF
 - Tumour causing venous compression
 - Subarachnoid space obstruction from meningitis
- Decreased outflow
 - Hydrocephalus (large cerebral ventricles)
 - Obstruction (a block in the ventricle, aqueduct or outlet to the fourth ventricle) e.g. tumour
- Communicating hydrocephalus
- Systemic hypertension (grade 4)
- Central retinal vein thrombosis

Adapted form: Baliga RR. *Saunders/Elsevier* 2007, page 81.

- Perform a funduscopic examination for papilledema (edema of optic nerve disc, papilla).
 - Bilateral changes
 - Disc
 - Blurred margins
 - Swelling
 - No loss of cupping (cup-to-disc ratio, < 50%)
 - Retinal veins
 - Loss of spontaneous pulsations

Source: Mangione S. *Hanley & Belfus* 2000, page 93.

- Perform an examination for acute angle closure glaucoma.
 - Cornea



- Haziness (edema)
- Halos, with rainbow-colored fringes around points of light
- Ciliary flush (circumcorneal erythema)
- Conjunctiva
 - Redness
 - Tearing
- Pupils
 - Partially dilated
 - Non responsive
- Optic disc
 - ↑ optic cup-to-disc ratio, > 50%
 - ↓ visual acuity

Adapted from: Mangione S. *Hanley & Belfus* 2000, page 92.

- Perform a focused physical examination for swelling (edema) of the head of the optic nerve (disc, papilla).
- Increased intracranial pressure (ICP)
- Normal ICP
 - Inherited
 - Inflammatory e.g., papillitis
 - Infiltration (e.g., lymphoma)
 - Ischemia
 - Anterior ischemic optic neuropathy (AION)
 - Central retinal vein obstruction
 - Hypertension, malignant
 - Metabolic
 - Thyroid eye disease

Adapted from: Mangione S. *Hanley & Belfus* 2000, page 94.

- Take a directed history and perform a focused ocular examination for papillitis (a form of papillitis is optic neuritis) / optic neuritis.
- History
 - Eye pain
 - Acute, unilateral loss of vision
- Physical
 - Loss of vision in one eye
 - Defect in color vision



- Swelling of the optic disc, without \uparrow ICP
- Afferent pupillary defect (Marcus Gunn pupil) on the affected side
- Take a directed history and perform a focused physical examination for AION (anterior ischemic optic neuropathy).
 - History
 - Sudden, total loss of vision in one eye (infarction of optic disc or nerve head)
 - Physical
 - Afferent pupillary defect in affected eye (Marcus Gunn pupil)
 - Pale optic nerve head
 - Dyschromatopsia
 - May be associated signs of temporal (giant cell) arteritis
- Perform a focused physical examination to distinguish between the retinal vein and artery.
 - Retinal vein
 - Larger than artery (3:2 diameter)
 - Darker
 - Spontaneous pulsations
 - No light reflex

Adapted from: Mangione S. *Hanley & Belfus* 2000,

"A journey of a thousand miles begins with a single step"

Lao Tzu



- Perform a focused physical examination to distinguish between papilladema vs papillitis.

Papilladema	Papillitis
<ul style="list-style-type: none"> ➤ Optic disc <ul style="list-style-type: none"> ○ Swollen without venous pulsation 	<ul style="list-style-type: none"> ○ Optic disc swollen
<ul style="list-style-type: none"> ➤ Visual acuity <ul style="list-style-type: none"> ○ Normal (early) 	<ul style="list-style-type: none"> ○ Poor
<ul style="list-style-type: none"> ➤ Blind spot <ul style="list-style-type: none"> ○ Large 	<ul style="list-style-type: none"> ○ Large central scotoma
<ul style="list-style-type: none"> ➤ Visual fields of peripheral constriction <ul style="list-style-type: none"> ○ Usually slow onset of bilateral ○ Colour vision normal ○ Eye movement- no pain 	<ul style="list-style-type: none"> ○ Onset usually sudden and unilateral ○ Painful

Adapted from: Baliga RR. *Saunders/Elsevier* 2007, page 128.

- Causes of retinitis pigmentosa
 - Congenital (associated with cataract and deaf mutism)
 - Laurence Moon Biedl syndrome
 - Hereditary ataxia
 - Familial neuropathy i.e. Refsum's disease

Abbreviation: CSF, cerebrospinal fluid

Source: Talley NJ, et al. *MacLennan & Petty Pty Limited* 2003, Table 10.5, page 363.

Useful background: Cervical sympathetic pathway to the eye

- Mid brain (superior colliculus)
- Tectospinal tract
- C8, T1 and 2 ventral roots
- Cervical sympathetic trunk



➤ Internal carotid and cavernous nerve plexus

➤ Ophthalmic division of the trigeminal nerve

Source: Burton JL. *Churchill Livingstone* 1971, page 81.

- Perform a focused physical examination to determine the cause of unequal pupils (anisocoria).
 - Definition:
 - Anisocoria is a difference ≥ 0.4 mm in diameter of the pupils
 - Represents either a problem with the papillary constrictor muscle (parasympathetic denervation, iris disorder, pharmacologic pupil) or the papillary dilator muscle (sympathetic denervation, simple anisocoria)
 - Normal variant (20%)
 - CN III Palsy
 - Drug
 - Unilateral blindness (affected eye is dilated)/ eye disease
 - Iritis
 - acute angle closure glaucoma
 - trauma
 - previous surgery
 - Horner's syndrome
 - Pharmacological
 - Blindness or amblyopia in one eye (pupil larger in the affected eye)
 - Cerebrovascular accidents
 - Severe head trauma
 - Hemianopia due to optic tract involvement

Adapted from: McGee SR. *Saunders/Elsevier* 2007, page 217-219; Baliga RR. *Saunders/Elsevier* 2007, page 129.



Q1. Unequal size of the pupil (anisocoria) may occur congenitally. In the comatose patient, how do you determine by physical examination if the anisocoria is due to a pathological process?

A2. Pathological anisocoria is asymmetry of the pupils plus loss of reaction of the pupils to light.

Useful background: Pupils

Finding	Sensitivity (%)	Specificity (%)	PLR	NLR
➤ Detecting intracranial structural lesion in patients with coma				
○ Anisocoria > 1mm	39	96	9.0	0.6
○ Absent light reflex in at least one eye	83	77	3.6	0.2

Source: McGee SR. *Saunders/Elsevier* 2007, Box 19-1, page 222.

Useful background: Causes of ptosis

- Old age
 - Surgery/trauma
 - Congenital
 - Horner's syndrome
 - III nerve palsy, myasthenia gravis
- Perform a focused physical examination for the causes of ptosis.
 - Unilateral
 - Third nerve palsy
 - Horner's syndrome
 - Myasthenia gravis
 - Congenital or idiopathic
 - Perform a focused physical examination for Horner's syndrome.
 - Syndrome
 - Miosis
 - No sympathetic activity to balance parasympathetic action: paralysis of the dilator of the pupil
 - Ptosis



- Damage to sympathetic nerves of eyelids, with paralysis of upper tarsal muscle.
- Often, slight elevation of brow lid, due to paralysis of lower tarsal muscle
- Rarely, enophthalmos due to paralysis of the muscle of muller.
- Anhydridosis (not always present)
- Associated neurological signs
 - Ipsilateral
 - Nystagmus
 - V (pain/ temperature)
 - IX, X
 - Lower cranial nerves, recurrent laryngeal nerve palsy (hoarseness)
 - Loss of cerebellar function
 - Contralateral – loss of pain/ temperature over trunk and limbs
- Associated non-neurological signs (see causes below)
 - Clubbing, weak finger abduction, abnormal respiratory examination of lung apices, lymphadenopathy, thyroid mass, (carcinoma), carotid aneurysm or bruit
 - Test for syringomyelia, with central cord, lesions (look for disassociated sensory loss, and possible bilateral Horner's syndrome)

Understanding Horner's Syndrome

SO YOU WANT TO BE A NEUROLOGIST!

Q1. What is Horner syndrome?

A1. Horner's syndrome

- Signs
 - Miosis
 - Ptosis (at rest, but not on looking upwards)
 - Anhidrosis
 - Lack of tears
- Causes
 - Cervical lymphadenopathy
 - Lesions of medulla
 - Syringomyelia
 - Syringobulbia
 - Vascular lesions



Q2. In Horner syndrome, how would you differentiate clinically whether the lesion is above the superior ganglion (peripheral) or below the superior cervical ganglion (central)?

A2. Test	Above	Below
Sweating	Such lesions may not affect sweating at all as the main outflow to the facial blood vessels is below the superior cervical ganglion	Such lesion affect sweating over the entire head, neck, arm, and upper trunk Lesions in the lower neck affect sweating over the entire face

Source: Baliqa RR. *Saunders/Elsevier* 2007, page 127.

➤ Translational Neuroanatomy of Sympathetic Fibers to Eye and Face

- Hypothalamic ganglia
 - ↓
 - Superior colliculus of midbrain
 - ↓
 - Tectospinal tract
 - ↓
 - Lateral horns of spinal cord
 - ↓
 - Preganglionic rami
 - ↓
 - Anterior nerve roots
 - ↓
 - Cervical sympathetic chain
 - ↓
 - Superior cervical ganglion
 - ↓
 - Postganglionic fibers
 - ↓
 - Internal carotid and cavernous sinus plexus -----> Ciliary nerve of eye (from V1)
 - Levator palpebrae superioris
 - ↓
 - Dilator pupillae
- Same side of face ←-----vasomotor and sweat fibers



- Causes of Horner's syndrome
 - Neck
 - Malignancy- e.g. Thyroid
 - Trauma or surgery
 - Lower trunk brachial plexus lesions
 - Trauma
 - Tumour
 - Carotid arterial lesion
 - Carotid aneurysm or dissection
 - Pericarotid tumours (Raeder's syndrome- sweating not affected since tumor involves internal carotid artery)
 - Cluster headache
 - Brainstem lesions
 - Vascular disease (especially the lateral medullary syndrome)
 - Tumour
 - Syringobulbia
 - Syringomyelia (rare)
 - Lung
 - Carcinoma (usually squamous cell carcinoma) of the apex of the lung

Adapted from: Talley NJ, et al. *MacLennan & Petty Pty Limited 2003*, Table 10.10, page 389; Baliga RR. *Saunders/Elsevier 2007*, page 126.

SO YOU WANT TO BE A NEUROLOGIST!

Q1. How would you distinguish congenital from non-congenital Horner's syndrome?

A1. Incongenital Horner's, there are all the usual features of miosis, ptosis, enophthalmos, and elevation of the lower lip, plus there would be heterochromia of the iris (i.e. the iris remains grey-blue). Easy- Migraine.

Q2. In the patient with ipsilateral Horner's syndrome and contralateral loss of pain and temperature sensation, what is Wollenberg's syndrome?

A2. Wollenberg's syndrome is also known as the lateral medullary syndrome, which usually presents with the above features in the person who has suffered a stroke.

Q3. Give one cause of intermittent Horner's syndrome.

A3. Easy- Migraine.



Useful background: Causes of abnormal reaction to light or to accommodation

- Pupil fails to constrict to light, but does constrict with accommodation (Argyll Robertson pupils)
 - Syphilis, tertiary
 - Diabetes
 - Alcohol (Wernicke encephalopathy)
- Pupil fails to constrict to light and to accommodation (Adie's pupil)
- Pupil fails to constrict to light, and actually dilates (Marcus Gunn pupil, or afferent pupillary defect, seen in optic neuritis or severe retinal damage such as central retinal artery occlusion)

Source: McGee SR. *Saunders/Elsevier* 2007, pages 213 and 223.

SO YOU WANT TO BE A NEUROLOGIST!

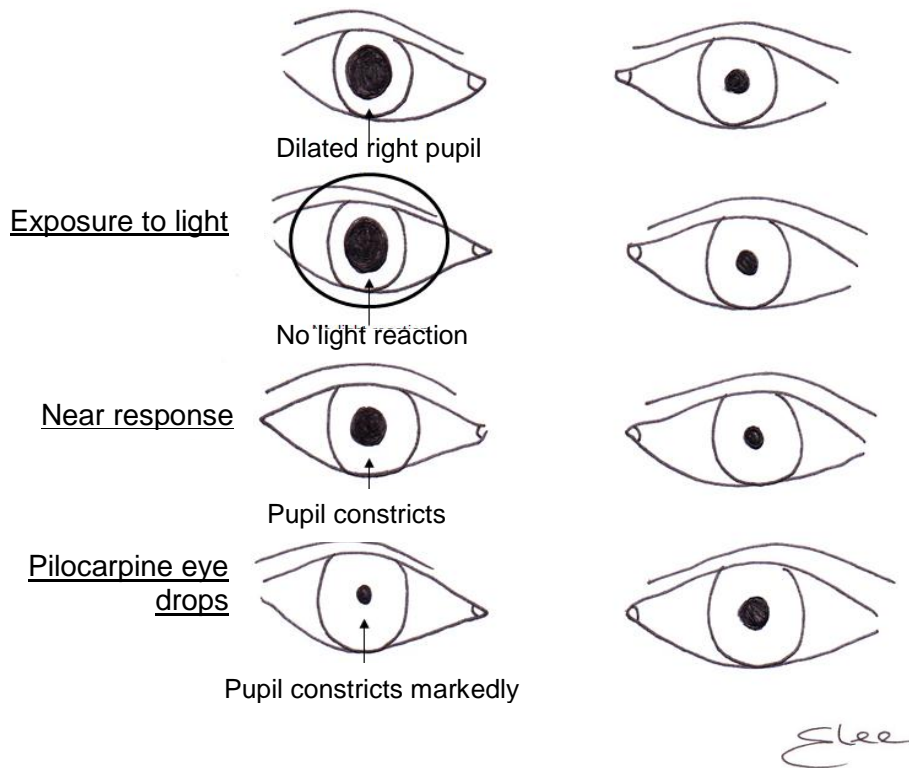
Q. Distinguish between Argyll Robertson pupils (ARP), and the pupils of the patients with aberrant regeneration of CN III (AR III)

| A. | Clinical | AR III | ARP |
|----|--|----------------|-----------|
| ○ | Constriction of pupil during convergence, but not to light | Unilatera
I | Bilateral |
| ○ | Associated anisocoria, ptosis, diplopia | Yes | No |



Useful background: Tonic pupil (Adie's Pupil)

Tonic pupil (Adies pupil)



- The patient in this figure has a right tonic pupil. At baseline, there is anisocoria with the right pupil larger than the left (first row). The dilated pupil fails to react to light (second row) but constricts slowly (i.e. 'tonic' contraction) when the patient focuses on a near object (third row). After instillation of dilute pilocarpine eye drops (fourth row), the pupil constricts markedly.

Adapted from: McGee S. R. *Saunders/Elsevier* 2007, page 223.



SO YOU WANT TO BE A NEUROLOGIST!

Q1. What is the Holmes-Adie pupil?

- A1.
- Large pupil
 - Reacts only slowly to accommodation, but not to light
 - Unilateral
 - Usually occurs in women
 - Associated with slow deep tendon reflexes

Q2. Be prepared to differentiate between the pupils in Argyll Robertson versus Holmes-Adie syndrome.

A2. Please see answers above

SO YOU WANT TO BE A NEUROLOGIST!

Q1. A “fixed pupil” is a pupil which does not react to light or to accommodation. A fixed pupil which is dilated may be due to iritis or to oculomotor (CN III) lesion. How can you distinguish between the two by examining the eyes?

- A1.
- Iritis
 - Fixed, dilated, irregular pupil
 - Does not react to light or accommodation
 - Retrobulbar neuritis
 - Fixed dilated pupil
 - Reacts slowly to direct light

Q2. In the context of the Argyll Robertson pupil (ARP), what is Adie’s pupil (AP)?

A2.

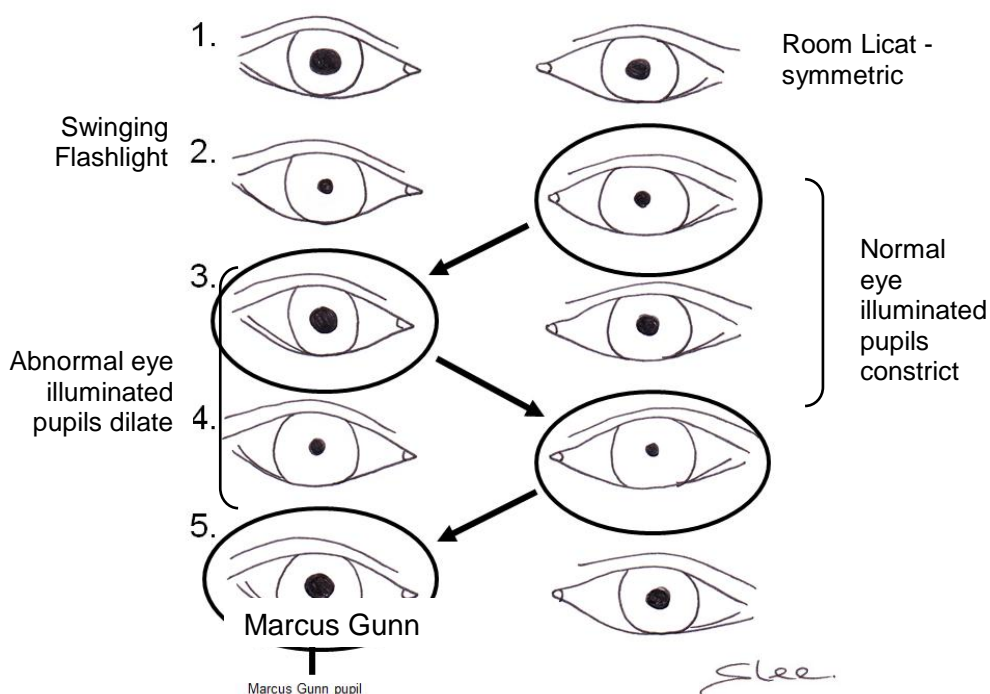
| | Light | Accommodation |
|-----|-------|---------------|
| ARP | No | Yes |
| AP | No | No |



- Perform a focused physical examination of the patient with a large pupil (regular or irregular, oval or circular) which reacts slowly to light and accommodation (Holmes-Adie Syndrome).
 - Near vision
 - ↓ constriction in response to near vision.
 - ↓ re-dilation after near vision.
 - If a strong and persistent stimulus is used
 - The pupil contracts excessively to a very small size
 - When the stimulus is removed, the pupil slowly returns to its former size (known as the “myotonic” pupil).
 - Segmental palsy and segmental spontaneous movement of iris
- Ankle reflexes – absent

Adapted from: Baliga RR. 250 *Saunders/Elsevier* 2007, page 130.

Useful background: The relative afferent papillary defect (Marcus Gunn Pupil)



- This shows a patient with an abnormal right optic nerve.
- The pupil that dilates during the swinging flashlight test has the 'relative afferent papillary defect' and is labelled the 'Marcus Gunn pupil'.

Adapted from: McGee SR. *Saunders/Elsevier* 2007, page 213.



SO YOU WANT TO BE A NEUROLOGIST!

Q. Give the translational neuroanatomical basis for the Marcus Gunn pupil (afferent pupillary defect)

- A.
- Afferent stimulus from
 - Disease eye weak
 - Contralateral healthy eye strong
 - Efferent system
 - Normal in diseased and healthy eye
 - With the swinging flashlight test
 - Light in normal eye
 - Normal pupil constricts
 - Light taken away from normal eye to diseased eye
 - Loss of constriction signal from to normal eye
 - No afferent pathway from diseased eye to cause constriction of pupil on that side
 - The pupil in the affected eye initially dilates in response to light, rather than constricting as would be normal

SO YOU WANT TO BE A NEUROLOGIST!

Q. In the context of the pupil of the eye, distinguish between "near-light dissociation" (NLD) and "light-near dissociation" (LNA)

A.

| Pupil reaction to | NLD | LND |
|-------------------|-----|-----|
| ➤ Light | Yes | No |
| ➤ Synkinesis | No | Yes |

Adapted from: McGee SR. *Saunders/Elsevier* 2007, page 216.



Useful background: Causes of cataract

- Inherited
 - Rubella syndrome
 - Down's syndrome
 - Hepatolenticular degeneration
 - Galactosemia
 - Dystrophia myotonica
- Senility
- Heat, radiation
- Secondary to ocular disease
 - Glaucoma
 - Ophthalmitis
 - Trauma (contusion cataract)
- Metabolic
 - Diabetes mellitus
 - Hypoparathyroidism (lamellar cataract)
 - Corticosteroid therapy
- Miscellaneous causes
 - Atopic eczema
- Heat and irradiation

Adapted from: Burton JL. *Churchill Livingstone* 1971, pages 80 and 186.

Useful background: Causes of retinal hemorrhage

- CNS
 - Subarachnoid hemorrhage
 - Raised IC pressure
- Retinal vessels
 - Arteritis (PN, cranial arteritis, etc)
 - Retinal vein thrombosis
- Retina
 - Trauma and retinal detachment
- Hypertension



- Diabetes
- Hematology
 - Severe anemia, especially PA
 - Bleeding diathesis-defect in platelets, vessels or coagulation factors

Affected pupil size may be dilated, depending on the cause of the CN III palsy, (e.g. intracranial aneurysm).

Abbreviation: PA, pernicious anemia

Adapted from: Burton JL. *Churchill Livingstone*, 1971, page 82.

SO YOU WANT TO BE A NEUROLOGIST!

Q1. What is the neurological changes associated with hyperparathyroidism?

- A1.
- Cataracts
 - Papilloedema
 - Basal ganglia defects
 - Benign intracranial hypertension

Source: Burton JL. *Churchill Livingstone* 1971, page 81.

Q2. Of course, we all know that blue sclerae are usually associated with osteogenesis imperfecta. But name other associations.

- A2.
- Anemia
 - Marfan's syndrome
 - Pseudo-pseudo hypoparathyroidism
 - Newborns, small children, some "normal" adults

Source: Mangione S. *Hanley & Belfus* 2000, page 83.

Q3. From fundoscopic examination of the ocular vessels, how can you distinguish between choroidosis and retinitis?

A3. Choroidosis – exudate is under the vessel (superficial to the exudate)

Retinitis – exudate interrupts the vessel



Can't decide whether YOU WANT TO BE A NEUROLOGIST OR
OPHTHALMOLOGIST!

Q1. From the physical examination of the eye, how can you distinguish between retrobulbar neuritis, and papilledema?

- A1.
- Retrobulbar neuritis
 - Early severe reduction in vision
 - Central scotoma affecting
 - Blind spot
 - Slow direct light reaction
 - Papilledema with papillitis
 - Macula (fixation spot)
 - Rapid reaction to consensual light
 - Normal accommodation
 - Papilledema
 - Late, milder loss of vision
 - Larger blind spot
 - Increased nasal blurring
 - Pink disc
 - Secondary optic atrophy
 - Smaller peripheral field of vision
 - Macula (fixation spots) is unaffected
 - If papilledema is severe, there may be hemorrhage and exudates

Q2. From the examination of the ocular blood vessels at fundoscopy, how can you distinguish an artery from a vein?

- A2.
- As compared to vein, the artery is
 - Slightly tortous
 - Smaller (2:3)
 - Lighter in the centre than at the periphery
 - May have disease associated changes, eg. silver wiring, hemorrhages



Other common visual eye symptoms and disease states

| Visual Symptoms | Possible Causes |
|---|---|
| ➤ Coloured haloes around light | <ul style="list-style-type: none"> ○ Acute angle closure glaucoma, ○ Opacities in lens or cornea |
| ➤ Difficult seeing in dim light | <ul style="list-style-type: none"> ○ Myopia ○ Vitamin A deficiency ○ Retinal degeneration ○ Cataract ○ Diabetic retinopathy |
| ➤ Distortion of vision | <ul style="list-style-type: none"> ○ Retinal detachment ○ Macular edema ○ Wet age-related macular degeneration ○ Macular pucker ○ Central serous retinopathy |
| ➤ Flashes (photopsias) | <ul style="list-style-type: none"> ○ Migraine, retinal tear ○ Detachment ○ Posterior vitreous detachment ○ Choroiditis ○ Retinitis |
| ➤ Glare, photophobia | <ul style="list-style-type: none"> ○ Iritis ○ Meningitis ○ Encephalitis ○ Syphilis ○ Migraines ○ Foreign bodies ○ Corneal deposits |
| ➤ Loss of visual field or presence of shadow or curtain | <ul style="list-style-type: none"> ○ Retinal detachment or hemorrhage ○ Branch retinal vein or arterial occlusion ○ Chronic glaucoma |
| ➤ Spots/Floaters (usually of no significance) | <ul style="list-style-type: none"> ○ Retinal tear/detachment ○ Vitreous hemorrhage |

Printed with permission: Filate W, et al. *The Medical Society, Faculty of Medicine, University of Toronto* 2005, page 202.

Useful background: Causes of eye abnormalities

- Cataracts
 - Old age (senile cataract)
 - Endocrine - e.g. diabetes mellitus, steroids
 - Hereditary or congenital - e.g. dystrophia myotonica, Refsum's disease
 - Ocular disease - e.g. glaucoma



- Radiation
- Trauma
- Papilledema vs. papillitis
 - Papilledema*
 - Optic disc swollen without venous pulsation
 - Acuity normal (early)
 - Large blind spot
 - Peripheral constriction of visual fields
 - Colour vision normal
 - Usually bilateral
 - Papillitis*
 - Optic disc swollen
 - Acuity poor
 - Large central scotoma
 - Pain on eye movement
 - Onset usually sudden and unilateral
 - Colour vision affected (particularly red desaturation)
- Causes of optic neuritis
 - Infective
 - Local: retinitis, periostitis
 - Systemic: syphilis, toxoplasmosis, typhoid fever, mumps
 - Toxins
 - Methyl alcohol
 - Lead
 - Benzene
 - Tobacco
 - Metabolic
 - Diabetes mellitus
 - B12 deficiency
 - Intestinal or uterine haemorrhage
 - Demyelinating disease eg.
 - Multiple sclerosis (MS)
 - Devic's disease
 - Schilder's disease
 - Hereditary degenerations
 - Leber's disease
 - Marie's disease
 - Freidreich's ataxia



- Giant cell arteritis
- Trauma

Source: Burton JL. *Churchill Livingstone* 1971, page 81.

- Causes of Optic Atrophy
 - Glaucoma
 - Chronic papilledema
 - Retinal lesions
 - Chorio-retinitis, meningitis
 - Intra-ocular hemorrhage, etc.
 - Optic neuritis (retrobulbar neuritis)
 - Pressure on an optic nerve
 - Tumour
 - Pituitary
 - Optic Nerve
 - Aneurysm
 - Intracavernous aneurysm of internal carotid artery
 - Paget's disease
 - Division of optic nerve
 - Surgery
 - Trauma
 - Lesions of optic tract

Adapted from: Burton JL. *Churchill Livingstone* 1971, page 79.

- Causes of retinitis pigmentosa
 - Congenital (associated with cataract and deaf-mutism)
 - Laurence-Moon-Biedl syndrome
 - Hereditary ataxia
 - Familial neuropathy, i.e. Refsum's disease

Adapted from: Talley NJ, et al. *MacLennan & Petty Pty Limited* 2003, page 363.



SO YOU WANT TO BE A NEUROLOGIST!

Q1. When is the red eye conjunctivitis and not uveitis?

A1. ➤ Conjunctivitis

- Diffuse red edematous, sclera and palpebral conjunctivae
- Discharge (bacterial-purulent/mucopurulent; viral and chemical – watery discharge)
- Discomfort, with scratchy feeling of sand in eye

➤ Uveitis

- Circumcorneal injected vessels (at the limbus) (aka ciliary flush)
- Photophobia
- Deep, aching pain, not relieved with a topical anesthetic

Source: Mangione S. *Hanley & Belfus* 2000, page 83.

Q2. Is the cornea reflex lost if a patient has weakness of the face as a result of damage to the facial nerve and LMV lesion?

A2. No, since there is bilateral innervation of the orbicularis oculi

Q3. Give four causes of retinal artery microaneurysms.

A3.

- Diabetes
- Systemic hypertension
- Thrombosis of retinal vein
- Sickle cell anemia



SO YOU WANT TO BE A NEUROLOGIST!

Q1. What are causes of red eye?

- A1.
- Conjunctiva
 - Conjunctivitis
 - Allergic
 - Viral
 - Bacterial
 - Cornea
 - Inflammation of the cornea or keratitis
 - Episclera
 - Episcleritis is inflammation of the connective tissue between the sclera and conjunctiva
 - Sclera
 - Inflammation of the sclera (scleritis)
 - Indicates an underlying systemic disease; such as connective tissue disease
 - Iris and ciliary body
 - Acute iridocyclitis is inflammation of both the iris and ciliary body
 - Adnexal structures
 - Tear or sebaceous glands; both dacryocystitis and styes are common disorders
 - Intraocular
 - Acute glaucoma

Source: Mangione S. *Hanley & Belfus* 2000, page 103.

Q2. Give three examples of physical findings of the optic disc, and their interpretation.

- A2. Normally the disc is pale, sharply defined but with slight blurring of nasal margin, and slightly paler on temporal than on the nasal side
- Increased temporal palor
 - Multiple sclerosis
 - Increased nasal blurring
 - Papilledema
 - Pink disc
 - Papilledema
 - Papillitis
 - Pale disk
 - Optic atrophy



- Nerves pass between posterior cerebral artery and superior cerebellar artery
 - ↓
- Middle fossa CN III, with IV, V, VI
 - ↓
- Cavernous sinus
 - ↓
- Through dura
 - ↓
- Superior orbital fissure
 - ↓
- Orbit, supplying extraocular muscles, as well as levator palpebrae superioris and sphincter pupillae

➤ Translational Neuroanatomy

Afferent pathway

Efferent pathway

➤ Light reflex

- | | |
|---|---|
| <ul style="list-style-type: none"> ○ Optic nerve <ul style="list-style-type: none"> ↓ ○ Chiasma <ul style="list-style-type: none"> ↓ ○ Optic tract <ul style="list-style-type: none"> ↓ ○ Superior corpora quadrigemina (same side) | <ul style="list-style-type: none"> ○ CN III <ul style="list-style-type: none"> ↓ ○ Ciliary ganglia <ul style="list-style-type: none"> ↓ ○ Short ciliary nerve <ul style="list-style-type: none"> ↓ ○ Sphincter pupillae <ul style="list-style-type: none"> ↓ ○ Constriction of pupil |
|---|---|

➤ Accommodation convergence reflex

- Same afferent and efferent pathways as for light reflex
- Constriction of pupils, ptosis, convergence

➤ IV (Trochlear) – look in and down (superior oblique)

Translational Neuroanatomy

Functional Neuroanatomy

Midbrain paired nuclei in grey matter of aqueduct of Sylvius



Fibers cross in the posterior medullary velum



Around the cerebral pedicles



With CN III into cavernous sinus



Through superior orbital fissure



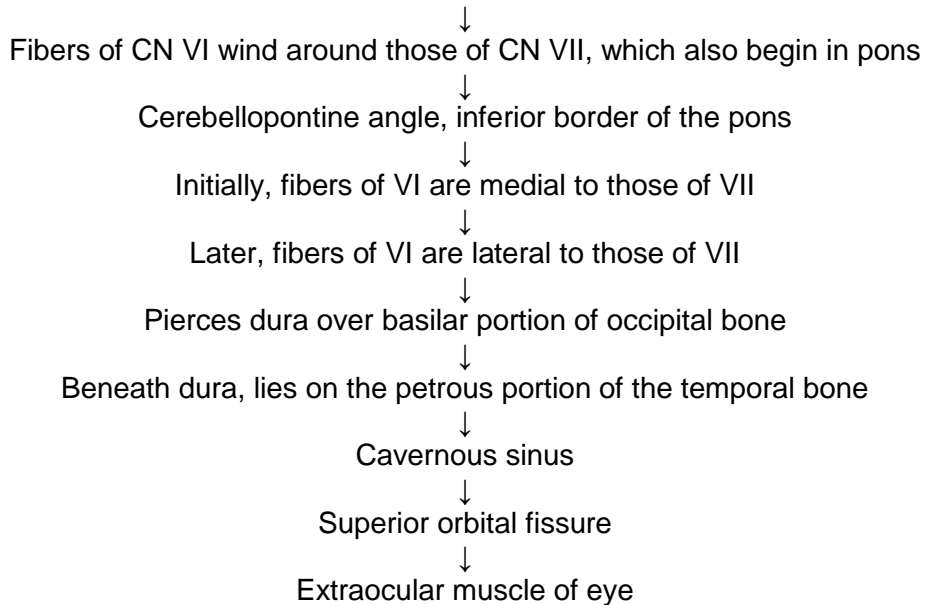
↓
Orbit, to superior oblique muscle

➤ VI (Abducens) – (lateral rectus)

Translational Neuroanatomy

Functional Neuroanatomy

Nucleus of CN VI in pons



- Perform a focused physical examination for CN III palsy.
 - Paralytic squint
 - Diplopia
 - Defective ocular movement
 - Dilated pupil
 - Loss of light and accommodation reflexes
 - Ptosis

"We don't see things the way they are.
We see them the way WE are"

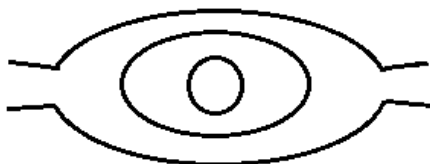
Talmud



- Perform a focused physical examination for CN III palsy due to a lesion
- Brainstem (crossed paralysis)
 - Ipsilateral CN III LMN hemiplegia
 - Contralateral CN III UMN hemiplegia
- Crus lesion, usually from thrombosis of posterior cerebral artery (aka Weber syndrome)
 - Same findings as crossed paralysis from brainstem lesion

Ptosis CN III

- Neuroanatomy
 - Movement : CN III → levator
 - Tone: sympathetic fibers in CN V → palpebrae superioris



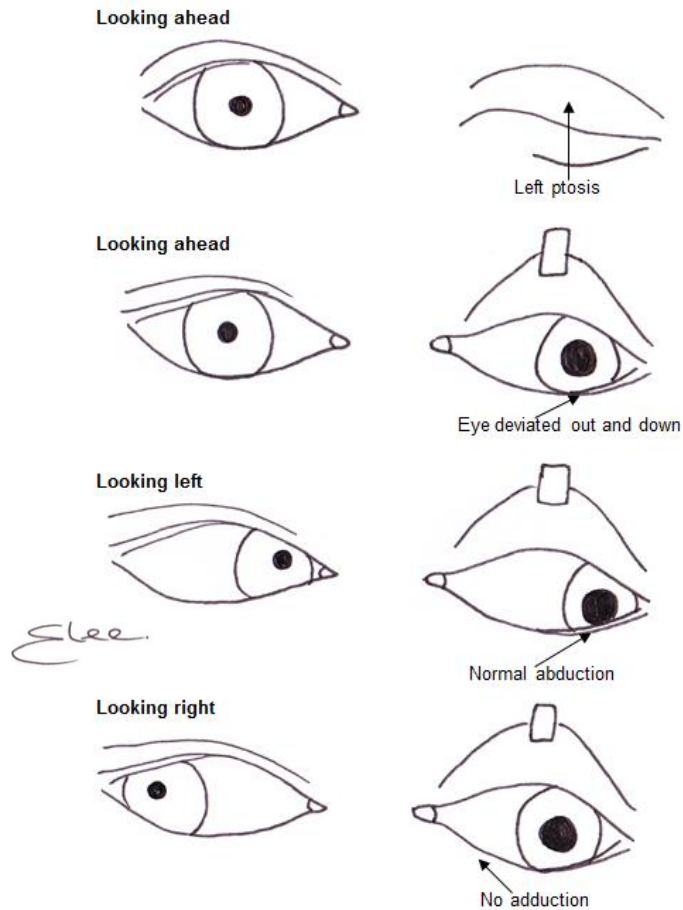
| Sign | CN VI sympathetic lesion | CN III |
|-------------------------------|--------------------------|--------|
| ➤ Ptosis at rest | + | - |
| ➤ Movement on looking upwards | + | - |

The upper eye lid may move a little way of over action of the frontalis muscle (forehead wrinkles)

- Ptosis due to damage to CN V, in addition to ptosis, may be associated with myosis, lack of sweating or tearing (lacrimation)
- Causes
 - Congenital
 - Hysterical (ptosis always unilateral)
 - Muscle diseases
 - Neurological disorders
 - III
 - VI
 - Tabes dorsalis



- Perform a focused physical examination for a CN III lesion (of the left side in this example).



Adapted from: McGee SR. *Saunders/Elsevier* 2007, Figure 55-5, page 681.

"The best way to predict the future is to create it"

Unknown



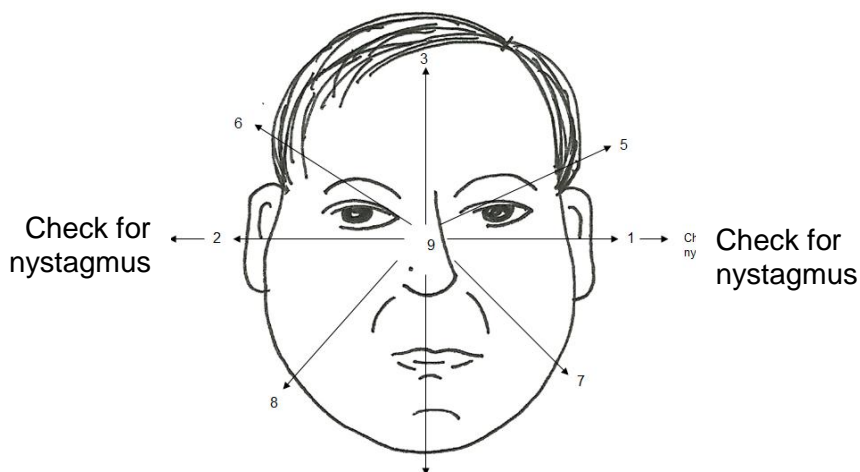
- Perform a focused physical examination for the causes of unilateral or bilateral ptosis.
 - Unilateral
 - Congenital (usually bilateral) – always partial
 - Oculomotor nerve lesion – usually unilateral, complete, frontalis overaction
 - Cervical sympathetic lesion (Horner's)
 - Myasthenia gravis
 - Myopathy (senile) – facioscapulohumeral, dystrophia, myotonica, trauma
 - Tabes dorsalis, syphilis
 - Hysterical –unilateral, no frontalis overactivity, complete
 - Ideopathic

(Exclude congenital microphthalmos, contralateral exophthalmos)

- Bilateral
 - Myasthenia gravis
 - Myotonia dystrophia
 - Ocular myopathy or oculopharyngeal dystrophy
 - Mitochondria dystrophy
 - Tabes dorsalis
 - Congenital
 - Bilateral Horner's syndrome (e.g. syringomyelia)

Adapted from: Burton JL. *Churchill Livingstone* 1971, page 82 and Baliga R.R. *Saunders/Elsevier* 2007, page 127.

Useful background: Cardinal positions of gaze

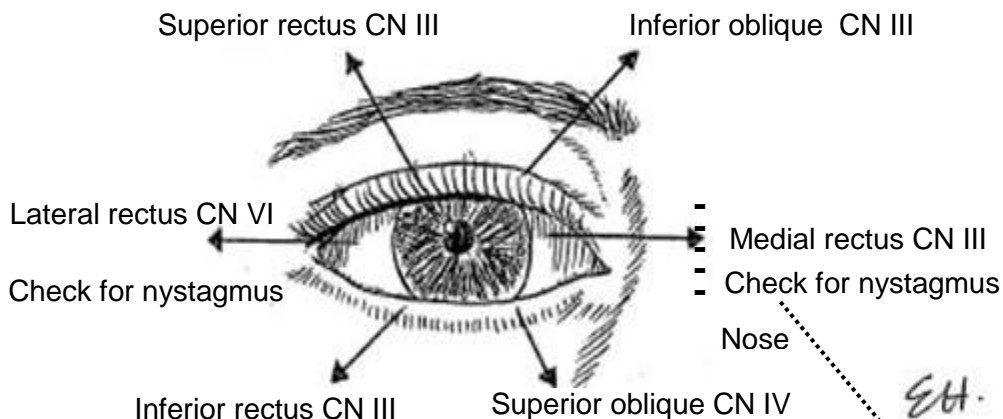


Adapted from: Filate W., et al. *The Medical Society, Faculty of Medicine, University of Toronto* 2005, page 159



- Perform a focused physical examination for a CN III lesion (of the left side in this example).

Useful background: The eye muscles and nerve innervations



Adapted from: Talley NJ, et al. *Maclennan & Petty Pty Limited* 2003, Figure 10.9, page 366.

SO YOU WANT TO BE A NEUROLOGIST!

Q. Nystagmus may be horizontal, vertical or rotatory, and has a quick and slow component. The rhythmic movement of the extraocular muscles may arise from disease of the cerebellum, vestibularis or oculomotor system. And so, the question: how would you determine if nystagmus is "physiological"?

A. Test for "optokinetic" nystagmus by having the person look at a rapidly rotating vertically striped drum.

Useful background: The eye

➤ Eye movements

- With the eyes turned *laterally* - the *elevators* and depressors are the *superior* and inferior recti, respectively
- With the eyes turned *medially* - the *elevators* and depressors are the *inferior* and superior obliques, respectively
- Bilateral centres in the frontal cortices provide for voluntary eye movements through the superior oblique (CN IV) and all the other muscles through CN III.



- Nuclei for oculomotor and trochlear nerves (CNs III and IV) provide for conjugate deviation of eyes up and down.
 - Nuclei for the (CN VI) in the pons provides for lateral conjugate movement through the lateral rectus muscle the medial longitudinal bundle connects the nuclei.
- Diplopia is caused by CN III, IV, VI disease or disease of extraocular muscles, e.g. trauma, tumour, vascular disease, multiple sclerosis, syphilitis.
- Exophthalmos
- Inflammation (cellulitis)
 - Thrombus (cavernous sinus thrombosis)
 - Bleeding or tumour behind the eye.
 - Thyroid disease

Source: Burton JL. *Churchill Livingstone* 1971, page 82.

Useful background: Gaze defects of CN III, IV, VI

| Gaze defect | Location of lesion |
|---|--|
| ➤ Looks down and out (including ptosis) | ○ CN III palsy (look for pupil involvement) |
| ➤ Can't look in and down (difficultly walking downstairs) | ○ CN IV palsy |
| ➤ Can't move affected eye laterally | ○ CN VI palsy |
| ➤ Slow adduction of ipsilateral eye and nystagmus in abduction of contralateral eye | ○ Medial longitudinal fasciculus (MLF)
○ Internuclear ophthalmoplegia (suggests Multiple Sclerosis) |

Source: Filate W, et al. *The Medical Society, Faculty of Medicine, University of Toronto* 2005, page 159.

Useful background: Common causes of third nerve palsy

- Infection
- Encephalitis
 - Basal meningitis
 - Carcinoma at the base of the skull



- Infiltration
 - Parasellar neoplasms
 - Meningioma at the wing of sphenoid
 - Tumors, collagen, vascular disorder, syphilis.
- Vascular
 - Ophthalmoplegic migrane
 - Aneurysms of posterior communicating artery (painful ophthalmoplegia).
- Degenerative
 - Multiple sclerosis
- Metabolic
 - Hypertension
 - Diabetes (pupil-sparing CN III palsy)
- Trauma

Adapted from: Baliga RR. *Saunders/Elsevier* 2007, page 154.

The CN III, IV, VI have a long and common intracranial pathway

- Within the brainstem
- On the meninges
- Pierce the dura
- In the cavernous sinus
- Through the superior orbital fissure

Useful background: causes of red eye

- Conjunctiva
 - Conjunctivitis
 - No blurred or lost vision
 - Improved vision with blinking
 - Scratchy discomfort, but no pain
 - No photophobia dischart
 - Yellow – bacterial infection
 - Clear – viral infection
 - Prepuricular lymphadenopathy
- Cornea
 - Keratitis (inflammation of the cornea)
- Episclera
 - Episcleritis (inflammation of the connective tissue between the sclera and the conjunctiva)



- Sclera
 - Scleritis
- Iris and ciliary body
 - Iridocyclitis
 - Anisocoria
- Adnexal structures
 - Rainbow – like ring around a point of like, looking like a halo
 - Pupil, mid-dilated non reactive to light

Useful background: Causes of a red and painful eye

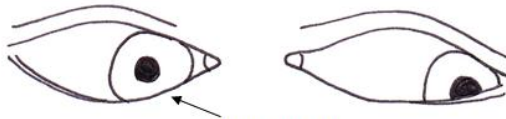
| Disease | Distribution of redness | Corneal surface | Pupil | Vision | Iris | Discharge |
|-------------------------------|---|--|--|---|---|---|
| ➤ Bacterial conjunctivitis | <ul style="list-style-type: none"> ○ Peripheral conjunctiva ○ Bilateral (central sparing) | - Normal | <ul style="list-style-type: none"> ○ Normal ○ Reactive | <ul style="list-style-type: none"> ○ Normal | <ul style="list-style-type: none"> ○ Normal | <ul style="list-style-type: none"> ○ Mucopurulent |
| ➤ Acute iritis | <ul style="list-style-type: none"> ○ Around cornea ○ Unilateral | - Dull | <ul style="list-style-type: none"> ○ Irregular shape ○ Miotic ○ Slowly reactive | <ul style="list-style-type: none"> ○ ↓/ blurred ○ Photophobia | <ul style="list-style-type: none"> ○ Normal | <ul style="list-style-type: none"> ○ Watery |
| ➤ Acute closure glaucoma | <ul style="list-style-type: none"> ○ Around cornea ○ Unilateral | - Dull | <ul style="list-style-type: none"> ○ Oval partially dilated ○ Non-reactive | <ul style="list-style-type: none"> ○ ↓/ blurred | <ul style="list-style-type: none"> ○ Corneal edema | <ul style="list-style-type: none"> ○ Watery |
| ➤ Corneal ulcer/abrasion | <ul style="list-style-type: none"> ○ Around cornea ○ Unilateral | <ul style="list-style-type: none"> - Dull - Fluorescein dye stains ulcer - Irregular light reflex | <ul style="list-style-type: none"> ○ Normal ○ Reactive | | <ul style="list-style-type: none"> ○ Defect shadow | <ul style="list-style-type: none"> ○ Watery/mucopurulent |
| ➤ Sub-conjunctival hemorrhage | <ul style="list-style-type: none"> ○ Localised hemorrhage ○ No posterior limit | - Normal | | | | |
| ➤ Conjunctival hemorrhage | <ul style="list-style-type: none"> ○ Localised hemorrhage ○ Posterior limit present | - Normal | | | | |



Adapted from: Talley NJ, et al. *MacLennan & Petty Pty Limited 2003*, Table 10.8, page 385; Davey P., *Wiley-Blackwell 2006*, page 112; and Filate W, et al. *The Medical Society, Faculty of Medicine, University of Toronto 2005*, page 201.

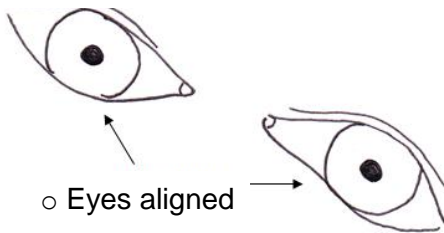
- Perform a focused physical examination for a CN IV lesion (of the right side in this example).

- Looking down and *left*



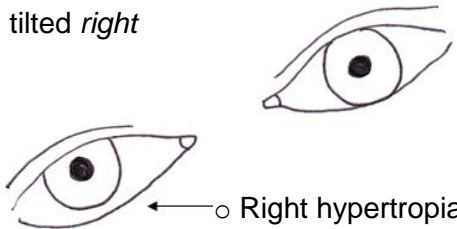
○ Right eye is weak

- Head tilted *left*



○ Eyes aligned

- Head tilted *right*



○ Right hypertropia

- Simple inspection (first row) reveals that the right eye lags behind left eye, indicating that the weak muscle is indeed on the right side) e.g. right superior oblique).

- Tilting the head away from the affected side (e.g. to the left side, away from the weak right superior oblique, aligns the eyes normally).

- Tilting the head toward the affected side (e.g. to the right side, third row) brings out a prominent right hypertropia (e.g. the right eye is higher than the left eye).

Elee

Adapted from: McGee SR. *Saunders/Elsevier 2007*, Figure 55-6, page 684.



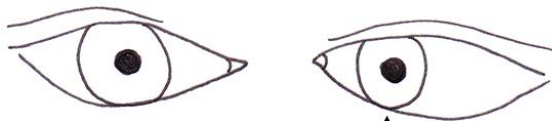
- Perform a focused physical examination of the eye to differentiate between a red eye caused by conjunctivitis (conj) versus/ keratitis (kera).

| | Conj | Kera |
|--------------------------------|---------|--------------------------------------|
| ➤ Vision Blurred | No | Yes |
| ○ Improvement with blinking | yes | No |
| ➤ Sensation | Scatchy | Pain |
| ➤ Photophobia | No | Yes |
| ➤ Discharge | Yes | No |
| ➤ Anisocoria | No | Yes (more common with iridocyclitis) |
| ➤ Preauricular lymphadenopathy | Yes | No |

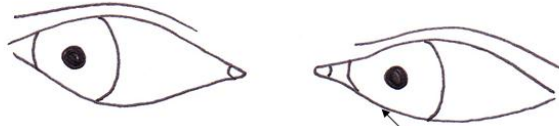
Source: Mangione S. *Hanley & Belfus* 2000, page 19.

- Perform a focused physical examination for a CN VI lesion (on the left)

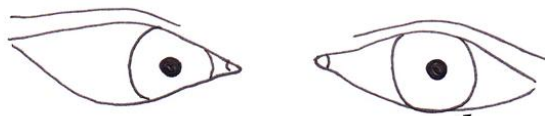
- Looking ahead



- Looking right



- Looking left



- Eye deviated slightly inward

- Normal adduction

- No abduction

Elee

Adapted from: Baliga RR. *Saunders/Elsevier* 2007, Figure 55-7, page 685.



Paralysis of the CN VI causes esotropia, and an inability to fully abduct the affected left eye.

➤ Naming

- Nystagmus is usually named from the side of the fast component, but the pathology causing the nystagmus is on the side of the slow component
- The exception is nystagmus caused by an eye condition, in which case both phases of the nystagmus are the same speed

➤ Causes

- Lesion of the eye of the vestibular system (labyrinth nerve and vestibular nerve), or of the brain stem/cerebellum (multiple sclerosis, syringomyelia, cerebellar lesions, hereditary ataxia)

Nystagmus

➤ Caused by disease of

- CN III (oculomotor)
- CN VIII (vestibular)
- Cerebellum

Useful Pointers

- The main features of any ocular palsy are the symptom of diplopia, as well as the sign of strabismus and the inability to move both eyes in the same direction.
- When examining the patient for diplopia, determine if diplopia is present, where is it maximal and what is the most peripheral image?
 - Present
 - Move the eye in the direction of the muscle which is suspected to be paralyzed
 - Maximal
 - Move the eye in the direction of the pull of the muscle which is suspected to be paralyzed
 - Peripheral
 - The most peripheral of the two images from the two eyes is from the eye with the weak muscle
 - Cover one eye, to establish which eye has the weak muscle
- When examining the patient with suspected diplopia, look for possible causes
 - Trauma
 - Tumor



- Vascular lesion
- Syphilis
- Multiple sclerosis
- Perform a focused physical examination to determine the cause of a person's diplopia.
- Diplopia is worst when looking down and to the left, indicating that the weak muscle is either the left inferior rectus muscle or right superior oblique muscle.
- Side-by-side images
 - Only lateral (VI) or medial (III) cranial nerves
- One-above-the-other
 - Superior (IV) or inferior (III) oblique, inferior rectus (III)
- False image
 - Pale, peripheral, poorly seen
- Loss of lateral image with covering one eye at point of maximum separation indicates that the covered eye is causing the diplopia.
- Persistence of both images with covering one eye is due to dislocated lens, astigmatism, or false reporting

Adapted from: McGee SR. *Saunders/Elsevier* 2007, pages 671 to 679.

- Strabismus
- Concomitant Strabismus
 - Slight asymmetry of corresponding ocular muscles
 - Extent of squint remains similar when eyes are looking in any direction
 - Normal ranges of movements of each eye present at rest
 - No diplopia associated
- Divergent (paralytic) strabismus
 - Paralysis of ocular muscles
 - Often not present at rest
 - Becomes apparent only when the eye is moved in the direction of the pull of the paralysed muscles
 - Associated diplopia



Useful background: Causes VI nerve palsy

- Hypertension
- Diabetes
- Raised intracranial pressure (false localizing signs)
- Multiple sclerosis
- Basal meningitis
- Encephalitis
- Nasopharyngeal carcinoma
- Acoustic neuroma

Source: Baliga RR. *Saunders/Elsevier*, Philadelphia 2007, page 156.

SO YOU WANT TO BE A NEUROLOGIST!

Q1. In what eye disease is it not possible to properly assess anisocoria?

A1. With iritis, the patient may have so much photophobia that it is not possible to determine if the size of the pupils is not equal.

Q2. Isolated palsies may occur in CN III (oculomotor), IV (trochlear) or VI (abducens). Give the commonest cause of a isolated CN palsy of each of these 3 nerves.

A2. III ischemia
 IV head trauma, idiopathic, ischemia
 VI neoplasm, ischemia

Source: McGee SR. *Saunders/Elsevier*, 2007, Table 55-1, page 680.

“Let’s change the interactions between alerting, orienting and executive functions, and control in a standard cuing paradigm.”

.....Grandad



SO YOU WANT TO BE A NEUROLOGIST!

Q1. You are familiar with how to examine CN III. Perform an examination for "aberrant regeneration" of CN III.

A1. Pathogenesis: After damage to the third nerve (from trauma, aneurysms, or tumors but not ischemia), regenerating fibers originally destined for the medial rectus muscle may instead reinnervate the pupillary constrictor

- Clinical
 - Unilateral pupillary constriction during convergence but no reaction to light. Unlike Argyll Robertson pupils, however, this finding is unilateral
 - Anisocoria, ptosis, and diplopia

Q2. What are the eponymous syndromes affecting CN VI?

- A2.
- Pons Infarction
 - Raymond's syndrome: ipsilateral CN VI paralysis and contralateral paresis of extremities
 - Millard-Gubler syndrome, in which there is ipsilateral VI and VII palsy, with contralateral hemiplegia.
 - Foville's syndrome has all the features of Millard-Gubler paralysis, plus lateral conjugate gaze palsy.
 - Gradenigo's syndrome
 - Inflammation of the tip of the temporal bone, involving V and VI, as well as the greater superficial petrosal nerve
 - This results in unilateral paralysis of the lateral rectus, nerve, pain in the distribution of V (particularly V₁), and excessive lacrimation
 - Others
 - Duane's syndrome: widening of the palpebral fissure on abduction, and narrowing on adduction
 - Gerhardt's syndrome: bilateral abducens palsy
 - Mobius syndrome: paralysis of extraocular muscles, especially abducens, with paresis of facial muscles

Adapted from: Baliga RR. *Saunders/Elsevier* page 157.



SO YOU WANT TO BE A NEUROLOGIST!

Q1. In the context of a blow-out fracture of the floor of the orbit, what are the defects in the cranial nerves (CN)?

- A1.
- Inferior rectus muscle CN??
 - Numbness on side of injury CN V

Q2. Give four conditions which may cause spasms of conjugate deviation of the eye.

- A2.
- At the beginning of a seizure
 - At the beginning of CVA
 - Early, head and eye turn away from the side of the lesion
 - Later, head and eye turn towards the side of the lesion
 - Oculogyric crisis in encephalitis lethargica
 - Hysteria

Q3. In the context of the CN V and VI, what is Gradenigo's syndrome?

A4. Gradenigo's syndrome is involvement of CN V and VI, with facial pain and sixth nerve palsy, such as may occur as a complication of otitis media and periostitis of the petrous

Q5. In the presence of increased intracranial pressure, which two nerves give a false-localizing sign of a lower motor neuron (LMN)?

A5. Cranial nerves III and VI

Q6. Which cranial nerve (CN) is most susceptible to a transient increase in intracranial pressure, such as might occur with a subarachnoid hemorrhage?

A6. CN VI

Q7. What are the causes of pin-point pupils?

- A7. Pin-point pupils are caused by
- Opiates
 - Positive hemorrhage

Q8. What are the structures in close proximity to the CN VI nucleus and fascicles?

- A8.
- Facial and trigeminal nerves
 - Corticospinal tract
 - Median longitudinal fasciculus
 - Parapontine reticular formation
 - Temporal bone

Source: Baliga RR. *Saunders/Elsevier* 2007, page 151.



SO YOU WANT TO BE A NEUROLOGIST!

Q1. What three muscle groups are supplied by the oculomotor nerve (CN III)?

- A1.
- All eye muscles, except lateral rectus (LR) and superior oblique (SO)
 - Eye is rotated out by LR and down by SO
 - Levator palpebrae superioris
 - Constrictor muscle of pupils
 - Loss of constrictor muscle leads to unopposed sympathetic effects on pupil

Q2. The cranial nerves to the muscles of the eye run closely together, so then two or three may be affected by the same lesion. What is the lesion which damages CN IV, and usually not CN III and VI?

A2. Aneurysm of PCA

Q3. What is the difference between hyphema and hypopyon?

A3. Hyphema is blood, and hypopyon is pus in the anterior chamber of the eye.

Q4. What are the neurological conditions causing ptosis?

- A4.
- CN III palsy
 - Horner's syndrome
 - Myasthenia gravis

Source: Mangione S. *Hanley & Belfus* 2000,

Q5. What is 'Fisher's one and a half syndrome'?

A5. Horizontal eye movement is absent, and the other eye is capable only of abduction ("one and a half movements are paralysed").

- The vertical eye movements and the pupils are normal.
- The cause is a lesion in the pontine region involving the medial longitudinal fasciculus and the parapontine reticular formation on the same side.
- This results in failure of conjugate gaze to the same side, impairment of adduction of the eye, and nystagmus on abduction of the other eye.

Source: Baliga RR. *Saunders/Elsevier* 2007. page 222.



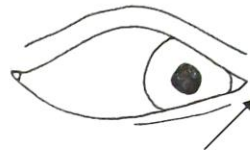
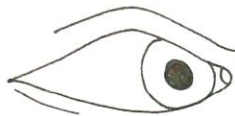SO YOU WANT TO BE A NEUROLOGIST!

Q6. How may you distinguish clinically between CN III palsy and exophthalmos due to a cavernous sinus thrombosis or aneurysm versus a tumor of the orbit?

- A6.
- With a tumor of the orbit
 - The CN III palsy and exophthalmos are usually bilateral
 - Associated chemosis (red, edematous conjunctive)
 - Associated papilledema

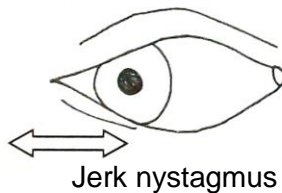
- Internuclear ophthalmoplegia

Looking left: Both eyes move normally

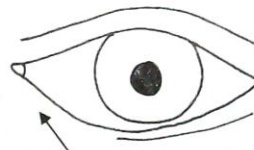

Normal abduction

Looking right: Left eye fails to adduct



Jerk nystagmus



No abduction

See

- The finding is named for the side with weak adduction (i.e. in this example, a left internuclear ophthalmoplegia).
- The lesion is in the ipsilateral medial longitudinal fasciculus (i.e. left medial longitudinal fasciculus in this example).

Adapted from: McGee SR. *Saunders/Elsevier* 2007, Figure 55-4, page 678.

➤ Pupillary Light Reflex

- CN III → ciliary ganglion → parasympathetic → constrictor pupillary muscle
- CN V (ophthalmic division) → ciliary ganglion → cervical sympathetic nerves → dilator pupillary muscle



- Pupillary light reflex → optic nerve afferents → lateral geniculate body → biliary nuclei in midbrain
- Accommodation
 - Afferent component: Frontal cortex – efferent component: CN III (note: unlike the pupillary light reflex, the efferent fibers do not pass through the ciliary ganglion)
 - Output
 - Convergence of eyes (medial recti)
 - Contraction of ciliary muscle
 - Constriction of pupil

Useful background: Pupil physical examination to distinguish between Argyll Robertson, Adie's and Murrum Gunn

- Argyll Robertson pupils: normal pupillary constriction with accommodation, but not to light (light-near dissociation, usually bilateral; seen mostly in diabetics, alcoholics (Wernick's encephalopathy) and tertiary syphilis)
- Marcus Gunn Pupil (afferent pupillary defect): swinging a light back and forth from one eye to another, the eyes affected by an optic nerve lesion (e.g. optic neuritis) or massive retinal lesion (e.g., central retinal artery occlusion)

Congenital colour blindness must be distinguished from dyschromatopsia, an acquired disorder of colour vision, which may be caused by diseases of optic nerve or medulla.

Anisocoria

- Perform a focused physical examination of the eye to distinguish the unequal size of the pupils (anisocoria) due to hippus from an afferent pupillary defect.
- Hippus
 - Normal (physiological) constant changing in the size of the pupil, in which the pupil, initially constricts to light
- Afferent pupillary defect (aka Marcus Gunn pupil)
 - The pupil from the affected eye initially dilates, in response to light
 - Due to optic nerve lesion (optic neuritis, optic neuropathy), or massive retinal lesion (retinal artery occlusion)
-



Perform a focused physical examination of the eye for light-near dissociation (aka Argyll Robertson pupils), and its causes.

- No response to light
- Normal response to accommodation
- Causes
 - Infections, including 3^o syphilis
 - Drugs / toxins, especially alcohol (Wernicke encephalopathy)
 - Miscellaneous causes

Useful background: Horner's Syndrome

➤ Horner's syndrome

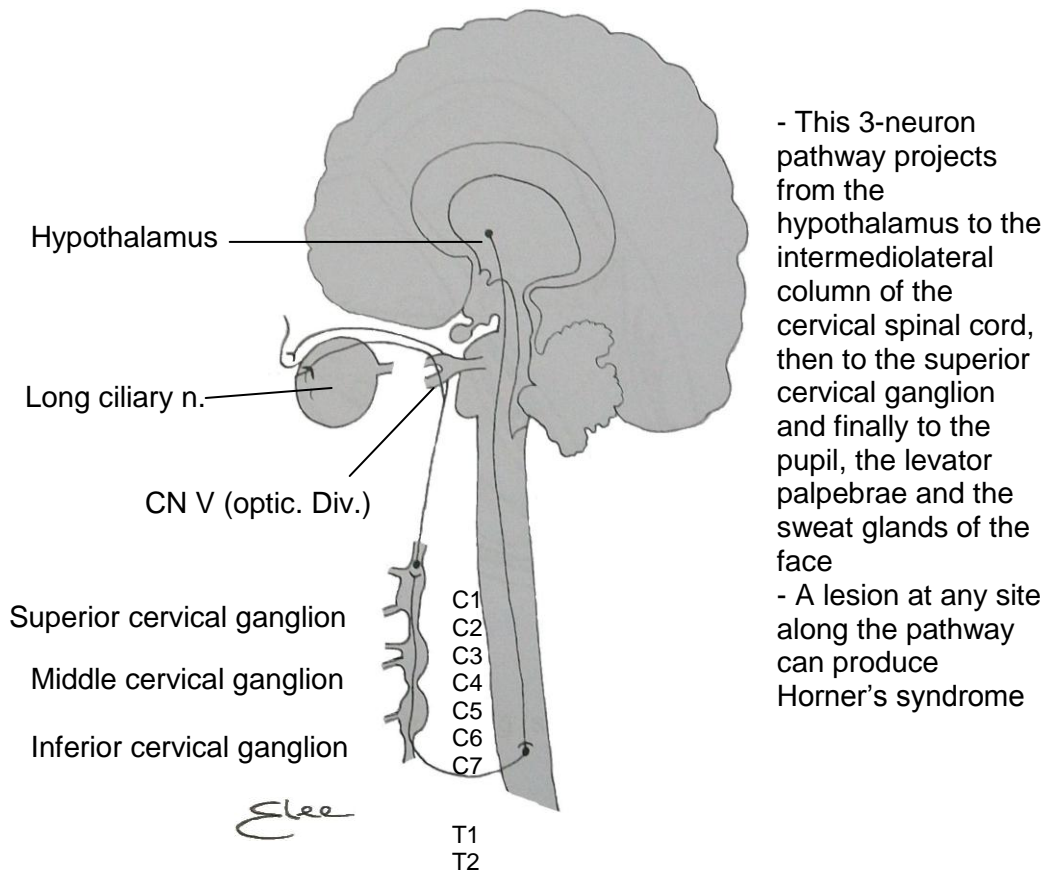
- Definition
 - Interruption of the sympathetic innervation of the eye
- Signs
 - *Partial ptosis* (as sympathetic fibres supply the smooth muscle of both eyelids)
 - *Constricted* pupil (unbalanced parasympathetic action) which reacts normally to light
 - Decrease in the *sweating* over each eyebrow
 - As part of the lateral medullary syndrome
 - Syringomyelia
 - dissociated sensory loss
 - bilateral Horner's syndrome)
 - Nystagmus to the side of the lesion
 - Ipsilateral fifth (pain and temperature)
 - Ninth and tenth cranial nerve lesions
 - Ipsilateral cerebellar signs
 - Contralateral pain and temperature loss over the trunk and limbs

Adapted from: Talley NJ, et al. *MacLennan & Petty Pty Limited* 2003, Table 10.10, page 389.

"Help navigate outside the hospital setting
for the quality total care of your patient"
Grandad



➤ Oculosympathetic pathway involved in Horner's syndrome



- This 3-neuron pathway projects from the hypothalamus to the intermediolateral column of the cervical spinal cord, then to the superior cervical ganglion and finally to the pupil, the levator palpebrae and the sweat glands of the face

- A lesion at any site along the pathway can produce Horner's syndrome

Abbreviation: CN, cranial nerve

Adapted from: Talley NJ, et al. *MacLennan & Petty Pty Limited* 2003, Figure 10.23, page 388.

- Perform a focused physical examination to determine the site of the lesion causing nystagmus.
 - Eye
 - Both phase of nystagmus are the same speed
 - Associated vision defect
 - Vestibular system
 - With lesions of the labyrinth nerve or vestibular nerve there is usually associated deafness, tinnitus and vertigo



- The excursions back and forth are larger when looking in the direction of the fast phase, and are smaller when looking in the direction of the slow phase (i.e., the side of the lesion)
- o Central lesions (brain stem, cerebellum)
 - No associated visual changes, deafness, tinnitus or vertigo
 - Slow phase towards rest position of eye
 - Slow and fast phases change with full excursion of the eyes

Trigeminal nerve (CN V)

- V (Trigeminal)
 - o Sensory - Pain, temperature and light touch for same side of face, cornea, sinuses, nasal mucosa, teeth, tympanic membrane, anterior 2/3 of tongue? or VII
 - o Motor- Mouth, open symmetrically, open against resistance, move jaw against resistance, clench teeth, chewing (masseter and lateral pterygoid muscles)
 - o Reflex
 - Corneal reflex (afferent limb), jaw jerk (afferent and efferent limbs)
 - Glabellar reflex (limb)
 - o Asymmetry of face

- V1= ophthalmic Forehead and tip of nose
Afferent limb of the corneal reflex

- V2= maxillary Medial aspect of cheek
Afferent limb of jaw jerk reflex
Chin, except angle of the jaw(C2)

- V3= mandibular Innervates jaw muscles

- o Eye V1 sensory, Vs motor to orbicularis oculi
- o Face
- o Nose
- o Pharynx, mouth-motor to muscle of mastication
- o Tongue – anterior 2/3, taste
- o V2 (mandibular branch, CN V – to lingual nerve)
- o Ear – fibers from lingual nerve to
- o Chorda tympani
- o Jaw



Corneal Light Reflex

- Neuroanatomy
 - V1
 - Ophthalmic branch of the trigeminal nerve, sensory to eye, including cornea
 - V3
 - Motor branch of the trigeminal nerve
 - Innervates the orbicularis oculi
 - Orbicular oculi of each eye are innervated bilaterally
- Clinical
 - Touching the cornea of the one eye causes contraction of the orbicularis oculi of loss of cornea) reflex is an early sign of a tumor of the cerebellopontine angle

Jaw Jerk

V1 – sensory branch of trigeminal nerve CN III

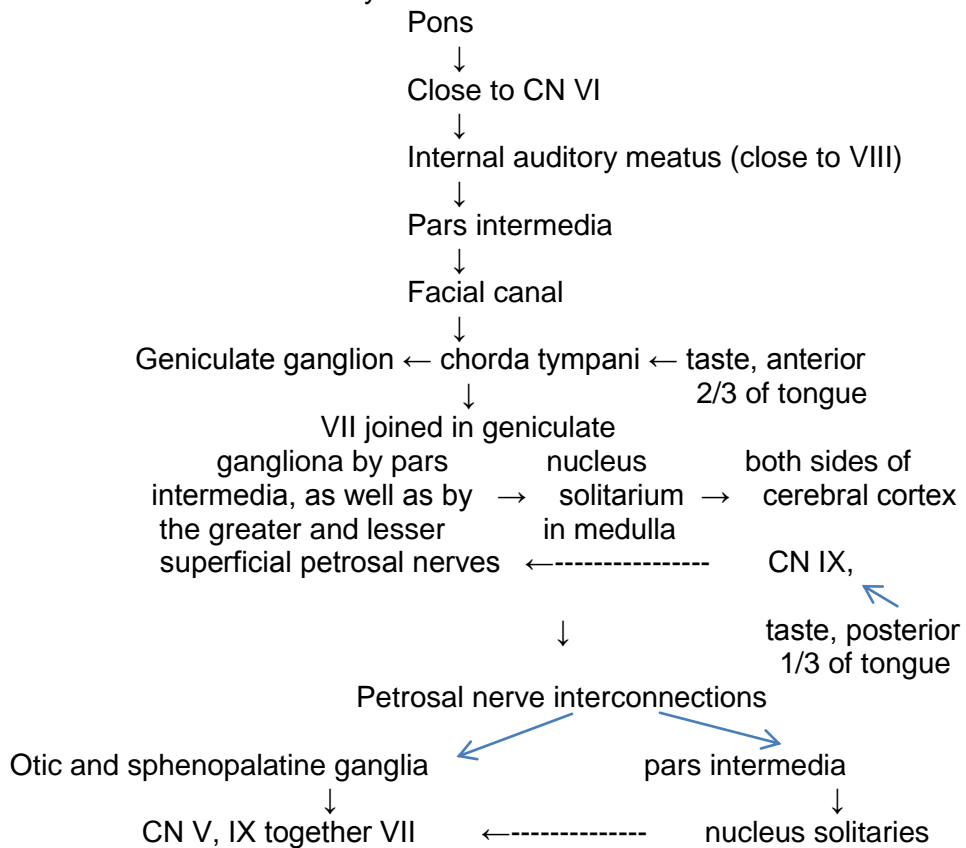
V3 – motor branch

- Bilateral innervation of jaw muscles
- Jaw muscles: masseters, pterygoids

- Deviation of jaw
 - Fracture of jaw bone
 - Deviation of side of weakness
 - Unilateral weakness represents a LMN lesion (because V3 innervation to jaw is bilateral)
- Weakness of jaw
 - UMN
 - Bilateral weakness
 - Associated with bilateral weakness of CN VII
 - LMN
 - Unilateral weakness of jaw
 - Unilateral deviation of jaw
- When testing the corneal reflex, what are the expected findings with a LMN lesion of CN VII
 - Contralateral closure of eye
 - Withdrawal of the eye from the stimulus



➤ Translational Neuroanatomy



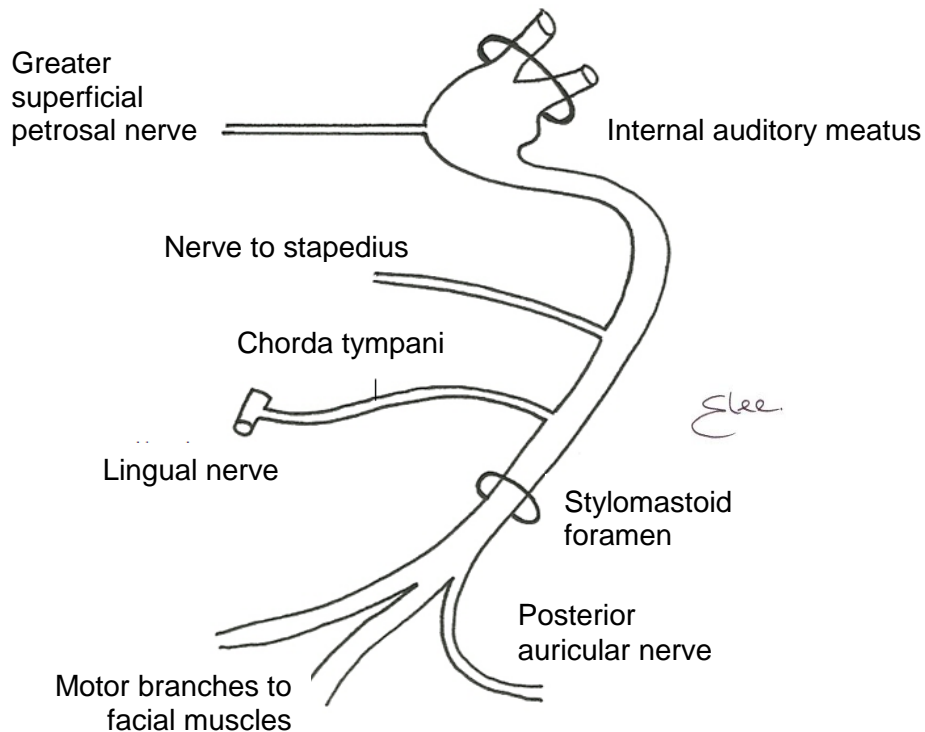
The face, and cranial nerve VII

➤ VII (Facial)

- Motor (scalp and fascial muscles of expression; all facial movements except eyelid elevation [CN III])
 - Raise eyebrows, wrinkle forehead (all facial movements except lid elevation [CN III] or mouth and jaw movement [CN V])
 - Open/close eyes
 - Smile, showing teeth
 - Puff out cheeks
 - Phonation
- Sensory
 - Speech, say 'PAH' (via the chorda tympani)
 - Taste, anterior 2/3 of tongue taste to (posterior 1/3 of tongue [CN IX])
- Corneal reflex (efferent limb; afferent limb, CN V)
- Glabellar reflex (efferent limb afferent limb, CN V)
- Nerve to stapedius muscle



Useful background: The anatomy of the facial nerve (CN VII)



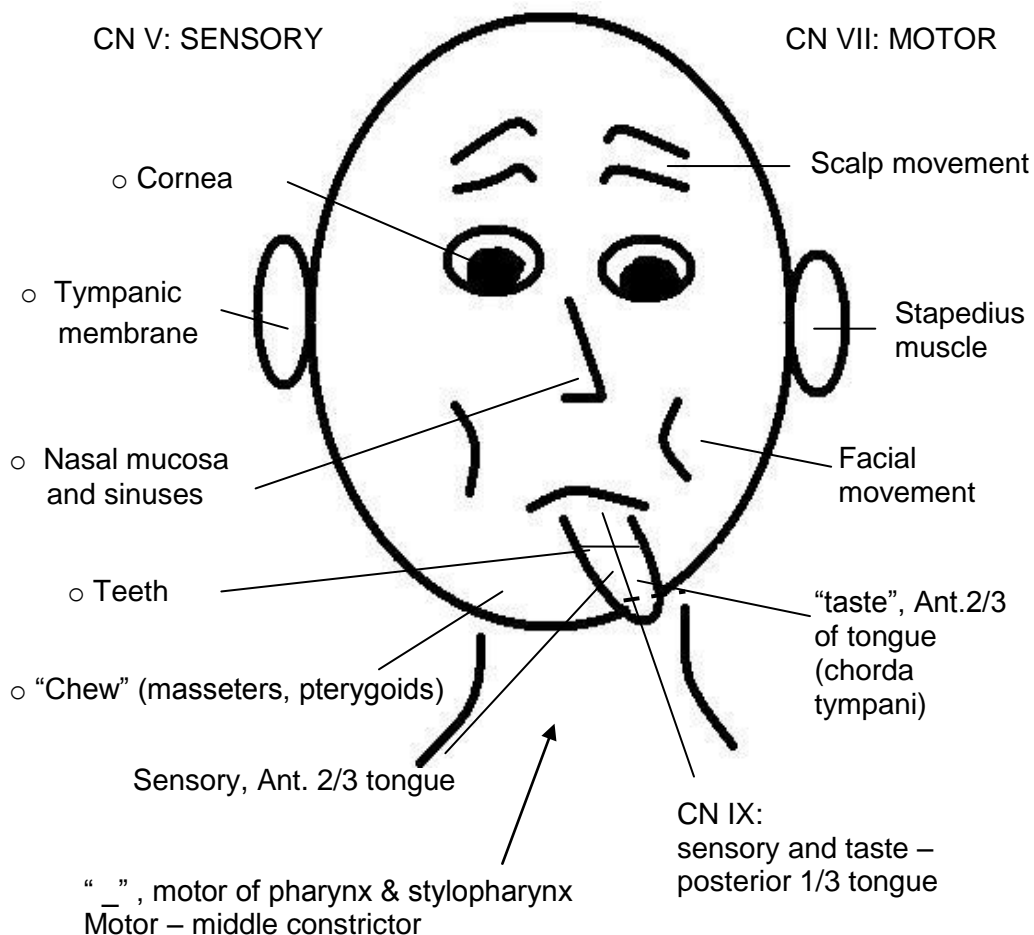
Adapted from: Burton JL. *Churchill Livingstone*, 1971, page 74.

CN VII

- Accompanies
 - Through the cerebello-positive angle
 - Acoustic neuroma may affect CN V, VI, VII, VIII
 - Accompanies V
 - Over the petrous temporal bone
 - Periostitis from otitis media
- Perform a focused physical examination to distinguish between UMN and LMN lesion of CN VII (facial)?
 - UMN damage
 - Central damage
 - Weakness of muscles only in the only in the lower half of the face



- LMN damage
 - Damage to brainstem
 - CN VII itself
 - Weakness of muscles in both the upper and lower halves of the face



CN V is sensory except for "chewing"

CN VII is motor, except for "taste", anterior 2/3 of tongue

Clinical Pearl

Uvula – deviates to strong side; jaw and tongue – deviate to weak side.



- Distinguish between a UMN and a LMN lesion of CN VII
 - UMN
 - Eg, internal capsular lesion
 - Paralysis of the lower facial muscles on one side (that part of the nucleus of CN VII which innervates the upper facial muscles is supplied by both sides of the motor cortex, and so the upper facial muscles are intact)
 - LMN
 - Damage to the facial nerves eg, Bell's palsy
 - Paralysis of both the upper and the lower facial muscles on one side
- Perform a focused physical examination to determine the neuroanatomical site of the facial nerve (CN VII) resulting in unilateral paralysis of the upper and the lower facial muscles:
 - Pons associated
 - Paralysis of lateral rectus muscle
 - CN V
 - Spinothalamic tract
 - Pyramids
 - Cerebellopontine angle
 - Loss of taste, anterior 2/3 of the tongue
 - Hyperacusis, damage to the stapedius muscle
 - Facial canal
 - Loss of taste, anterior 2/3 of tongue
 - Facial nerve
- Perform a focused physical examination for a disorder in the facial nerve, CN VII.
- Anatomy
 - The nervus intermedius or pars intermedia of Wrisberg is the sensory or the parasympathetic root of the facial nerve, and is lateral and inferior to the motor root.
 - Inside the internal auditory meatus it lies between the motor root and the eighth cranial nerve.



- The sensory cells are located in the geniculate ganglion (at the bend of the facial nerve in the facial canal) and their nerve fibres enter the pons with the motor root.
 - The geniculate ganglion is continued distally as the chorda tympani, which carries taste and preganglionic parasympathetic fibres
 - This nerve consists of contributions from three areas:
 - Superior salivary nucleus (in the pons) supplies secretory fibres to the glands
 - Gustatory or solitary nucleus (in the medulla) receives taste fibres via the chorda tympani
 - Dorsal part of the trigeminal nerve receives cutaneous sensation from the external auditory meatus and the skin behind the ear (distributed with the facial nerve proper).
 - The branches of the facial nerve
 - Greater superficial petrosal nerve (supplies lacrimal, nasal and plantine glands)
 - Nerve to stapedius muscle
 - Chorda tympani (supplies taste to anterior two thirds of the tongue, submaxillary and sublingual glands)
 - Motor branches (exit from the stylomastoid foramen)
 - Reflexes involving the facial nerve
 - Corneal reflex
 - Palmomental reflex
 - Suck reflex
 - Localizing facial nerve palsy
 - Involvement of the nuclei in the pons - associated ipsilateral sixth nerve palsy.
 - Cerebellopontine angle lesion - associated fifth and eighth nerve involvement.
 - Lesion in the bony canal - loss of taste (carried by the lingual nerve) and hyperacusis (due to involvement of the nerve to stapedius).
- Clinical
- Asymmetry (diminished ipsilateral)
 - Weakness of most ipsilateral facial muscles (muscles used during speaking, blinking, raising eyebrows, smiling, wrinkling the forehead, closing the eyes, showing teeth, and retracting the chin)
 - May be abnormalities of ipsilateral tearing (lacrimal gland), hearing (stapedius muscle), taste (anterior two third of the tongue), and the corneal and glabellar reflexes



- Central (UMN) facial weakness
 - Unilateral facial weakness may be "central" (lesions in the contralateral motor cortex or descending pyramidal tracts)
 - Weakness of lower facial muscle (wrinkling of the forehead is relatively spared in central lesions because the facial nuclei innervating these muscles receive bilateral cortical innervation).
 - Affect voluntary movements affected but not spare emotional ones.
 - May be unable to wrinkle one corner of the mouth voluntarily yet can move it normally during laughter or crying (occurs because emotional input to the facial nuclei does not come from the motor cortex)
- Peripheral (LMN) facial weakness
 - Lesions in the peripheral nerve or facial nucleus in the ipsilateral pons
 - Affect upper as well as lower facial muscles
 - All facial movements on the side affected are paralyzed

Adapted from: McGee SR. *Saunders/Elsevier* 2007, page 695.

Useful background: Ramsay-Hunt Syndrome (herpes zoster of geniculate ganglion)

- Pain in ear and mastoid region
- Facial paresis or spasm
- Deafness, dizziness or hyperacusis
- Vesicles on auricle or anterior fauces
- Ipsilateral taste loss in anterior two-thirds tongue

Source: Burton JL. *Churchill Livingstone* 1971, page 74.

- Perform a focused physical examination for the causes of facial weakness/ paralysis (CN VII lesion).
 - Supranuclear
 - Cortico-pontine tract lesions
 - Sub-thalamic and corpus striatum lesions
 - Temporal lobe lesions
 - Nuclear and infra-nuclear
 - Pontine
 - Polio
 - DS
 - Neoplasm



- Cerebello-pontine angle
 - Acoustic neuroma
 - Meningionoma
 - Basilar artery aneurysm
 - Guillain-Barré syndrome
 - Chordoma
 - Chronic meningitis, including carcinomatous
- Internal auditory canal
 - Acoustic neuroma
 - Geniculate herpes
- Facial canal
 - Bell's palsy
 - Chronic otitis, cholesteatoma or mastoidectomy
 - Head injury
 - Hypertension in children
 - Sarcoidosis
 - Leukemic infiltrate
- Face
 - Forceps delivery
 - Stab wounds
 - Parotid tumours
 - Leprosy
- Unilateral
 - UMN (sparing of forehead)
 - Melkersson-Rosenthal syndrome (facial palsy, recurrent facial edema, and pliciation of the tongue)
 - Myasthenia (may mimic bilateral facial nerve palsy)
 - LMN lesion
 - Ideopathic (Bell's palsy)
 - Herpes zoster
 - Cerebelloptine angle tumors
 - Parotid tumors
 - Old polio
 - Otitis media
 - Stroke (hemiplegia)
 - Skull fracture
- Bilateral
 - Facial nerve (VII) damage
 - Guillain-Barré syndrome
 - Sarcoidosis
 - Bilateral parotid disease
 - Lyme disease



- Mononeuritis multiplex
- o Muscle disease
 - Myopathy, myasthenia gravis

Abbreviations: MS, multiple sclerosis; LMN, lower motor neurons; UMN, upper motor neurons

Source: Burton JL. *Churchill Livingstone* 1971, page 75; Baliga RR. *Saunders/Elsevier* 2007, page 159.

- Perform a focused physical examination for the causes of facial pain.
 - CNS
 - o Migrainous neuralgia ('cluster' headache)
 - Skull / spine
 - o Cervical spondylosis, Paget's of skull
 - Disease of teeth, sinuses, ear, nose or throat
 - CN VII
 - o Post-herpetic neuralgia
 - o Trigeminal neuralgia
 - TMJ
 - o Temporo-mandibular arthritis (Costen's syndrome)
 - Ear
 - o Acoustic neuroma
 - Heart
 - o Myocardial ischemia
 - Blood vessels
 - o Cranial arteritis
 - o Aneurysm of posterior communicating artery- posterior inferior cerebellar artery
 - Miscellenous
 - o Atypical facial pain – Constant, nagging deep pain not corresponding to any anatomical sensory distribution
 - o MS - facial

Abbreviations: MS,

Adapted from: Burton JL. *Churchill Livingstone* 1971, page 74.



- Perform a focused physical examination for a lesion in the cavernous sinus, cerebellopontine angle, jugular foramen, pseudobulbar and bulbar palsy (multiple cranial nerve palsies), and its causes.

| Site | Affected cranial nerve |
|---|------------------------------------|
| ➤ Cavernous sinus | ○ Unilateral III, IV, V and VI |
| ➤ Cerebellopontine angle lesion (usually a tumor) | ○ Unilateral V, VII and VIII |
| ➤ Jugular foramen lesion | ○ Unilateral IX, X and XI |
| ➤ Bulbar (LMN) and pseudobulbar (UMN) palsy | ○ Combined bilateral X, XI and XII |

Bell's Palsy

- Definition
 - "Bell's palsy is a lower motor neuron paralysis of the facial nerve [CN VII], often due to herpes simplex virus -1 infection, causing inflammation and edema" (Pryse-Phillips W, et al. Chapter 19. In: Therapeutic Choices. Grey J, Ed. 6th Edition, *Canadian Pharmacists Association*: Ottawa, ON, 2011, page 258).
 - Bell's palsy is more frequent with
 - Pregnancy (trimester III)
 - Diabetes
 - Hypertension

SO YOU WANT TO BE A NEUROLOGIST!

Q. In the patient with Bell's palsy, what is Bell's phenomenon?

A. Bell's palsy is a peripheral mononeuropathy of CN VII which affects the peripheral nerve and results in both UMN and LMN lesions. In a person with lower (peripheral) CN VII damage, the eyelid of the affected side cannot be closed, so the eyeball on that side moves (upwards when the person closes the eyelid of the unaffected side (synkinesis), using the intact orbicularis muscle contraction on that side.

Source: Mangione S. *Hanley & Belfus* 2000, page 410.



Useful background: Differential diagnosis of unilateral Bell's Palsy

- Ramsay Hunt syndrome (herpes zoster infection; vesicles in the ear or throat)
- Facial nerve tumors (usually painless; examine for neurofibromatosis)
- Cerebellopontine angle tumors (added neurologic signs)
- Parotid tumors (clinical examination)
- Mastoiditis (clinical examination; deafness, discharge)
- Lyme disease (skin and joint signs)
- Neurosarcoidosis (chest x-ray)
- Brainstem lesions such as multiple sclerosis (other neurologic signs)

Reproduced with permission: Therapeutics Choices. Sixth Edition. Ottawa, Canada: *Canadian Pharmacist Association* 2012, Table 1, page 259.

Useful background: Causes of multiple cranial nerve palsies

- Inherited
 - Arnold Chiari malformation
- Infection
 - Guillain Barre syndrome (spares sensory nerves)
 - Tuberculosis
 - Sarcoidosis
- Infiltration
 - Nasopharyngeal carcinoma
 - Hematological malignancy,
 - Brainstem tumor (eg in the cerebellopontine angle) have similar signs
- Vascular
 - Brainstem vascular disease causing crossed sensory or motor paralysis (i.e. cranial nerve signs on one side and contralateral long tract signs).
- Trauma
- Metabolic
 - Paget's disease
 - Mononeuritis multiplex (rarely, e.g. diabetes mellitus)

Abbreviations: LMN, lower motor neurons; MS, Multiple sclerosis; UMN, upper motor neurons

Adapted from: Talley NJ, et al. *Maclennan & Petty Pty Limited* 2003, Table 10.7, page 384.



- Take a directed history and perform a focused physical examination for a lesion at the cerebellopontine angle.

➤ Definition

- Symptoms and signs related to cranial nerves VIII and IX.
- The cerebellopontine angle is the shallow triangular fossa lying between the cerebellum, lateral pons and the inner third of the petrous temporal bone.
- This angle extends from the trigeminal nerve (above) to the glossopharyngeal nerve (below).
- The abducens nerve runs along the medial edge, whereas
- Facial and auditory cranial nerves transverse the angle, to enter the internal auditory meatus.

➤ Causes

- Infection
 - Local meningeal involvement
 - Syphilis
 - Tuberculosis
- Infiltration
 - Acoustic neuroma.
 - Meningioma
 - Cholesteatoma
 - Hemangioblastoma
 - Pontine glioma.
 - Medulloblastoma and astrocytoma of the cerebellum.
 - Carcinoma of the nasopharynx.
- Vascular
 - Aneurysm of the basilar artery

Adapted from: Baliga RR. *Saunders/Elsevier* 2007, pages 222 and 223.

SO YOU WANT TO BE A NEUROLOGIST!

Q. In the context of CN VII, what are the Raeder's paratrigeminal syndrome, and the superior orbital fissure syndrome?

A.

- Raeder's paratrigeminal syndrome - Severe retro-orbital pain succeeded by ipsilateral miosis and ptosis
- Superior orbital fissure syndrome – Boring retro-orbital pain and paresis or cranial nerves III, IV, V and VI



SO YOU WANT TO BE A NEUROLOGIST!

Q1. Why can the patient with central damage to CN VII wrinkle their foreheads?

A1. Both sides of the cortex supply the LMN innervation of the upper half of the face.

Q2. What are the causes of Bell's palsy?

- A2.
- Idiopathic
 - Infection
 - Epstein Barr Virus (infections mononucleosis)
 - Guillain-Barr'e syndrome
 - Infiltration
 - Tumor of cerebellopontine angle
 - Metabolic
 - Diabetes

SO YOU WANT TO BE A NEUROLOGIST!

Q1. Why can the patient with Bell's palsy not wrinkle their foreheads?

A1. Bell's palsy is a peripheral mononeuropathy of CN VII.

- Their peripheral nerve damage causes paralysis of both UMN and LMN, so the motor function of both upper and lower portions of the face are affected.
- The eyelid of the affected side cannot be closed

Q2. What is the difference between Bell's palsy and Bell's phenomenon?

A2. Bell's phenomenon is the normal upwards rotation of the orbit which occurs when the ipsilateral orbicularis muscle contracts when the person closes their eye, i.e., the eyelid closes; because the eyelid closes, the physiological synkinesis of the upward movement involuntary of the eye with the voluntary closure of the eyelid is not normally seen.



SO YOU WANT TO BE A NEUROLOGIST!

Q1. What is the component of the facial nerve (CN VII). Which is sensory and what does it supply?

- A1. The nervus intermedius of Wrisberg
 Taste sensation from the anterior two thirds of the tongue
 Probably, cutaneous impulse from the anterior wall of the external auditory canal.

Source: Baliga RR. *Saunders/Elsevier* 2007, page 159 and 160

Q2. How do you localize the site of the facial nerve palsy?

- A2. Involvement of the nuclei in pons – associated ipsilateral sixth nerve palsy.
 Cerebellopontine angle lesion – associated fifth and eighth nerve involvement.
 Lesion in the bony canal – loss of taste (carried by the lingual nerve) and hyperacusis (due to involvement of the nerve to stapedius).

Q3. What reflexes involve the facial nerve?

- A3. Corneal reflex
 Palmomental reflex
 Suck reflex

Q1. Perform a focused physical examination to distinguish between an upper vs lower motor neuron damage to cranial nerve (CN) VII (facial nerve).

- A1. Oh boy!
 UMN (cortical damage) weakness of lower facial muscle on the opposite side as the damage.
 LMN (damage to CN > VII): inability to wrinkle the forehead, close the eye tightly, or smile on the same side as the damage.

Source: Mangione S. *Hanley & Belfus* 2000, pages 409 and 410.

Q2. Cranial nerve V (trigeminal nerve) is entirely sensory, except motor to which muscle?

- A2. The masseter muscle for chewing



SO YOU WANT TO BE A NEUROLOGIST!

Q. What is the neuroanatomical basis for only the tongue and lower face being affected in UMN-associated hemiplegia?

- A.
- All cranial nerve are innervated bilaterally, except the lower half of the face and tongue; thus all muscles except tongue and lower face escape in UMN hemiplegia

Q. What is the neuroanatomy which explains the corneal reflex?

- A.
- The sensory fibers of the CN V (touch, proprioception) enter the brainstem and cross the midline to ascent in the medial lemniscus to the thalamus and cerebral cortex

Sensory nuclei in pons CN V → brainstem → decussate → medial lemniscus → thalamus and cerebral cortex

Sensory and motor V → leave the pons V cross the cerebellopontine angle → sensory root in a large ganglion at the apex of the petrous temporal bone → sensory V accompanies CN III, IV, and VI in the cavernous sinus

SO YOU WANT TO BE A NEUROLOGIST!

Q. What are the epomous syndrome in which the third cranial nerve (CN III) is involved?

- A.
- Weber's syndrome: ipsilateral third nerve palsy with contralateral hemiplegia. The lesion is in the midbrain.
 - Benedikt's syndrome: ipsilateral third nerve palsy with contralateral involuntary movement such as tremor, chorea and arthetos. It is due to a lesion of the red nucleus in the midbrain.
 - Claude's syndrome: ipsilateral oculomotor paresis with contralateral ataxia and tremor. It is due to a lesion of the third nerve and red nucleus.
 - Nothnagel's syndrome: unilateral oculomotor paralysis combined with ipsilateral cerebellar ataxia.

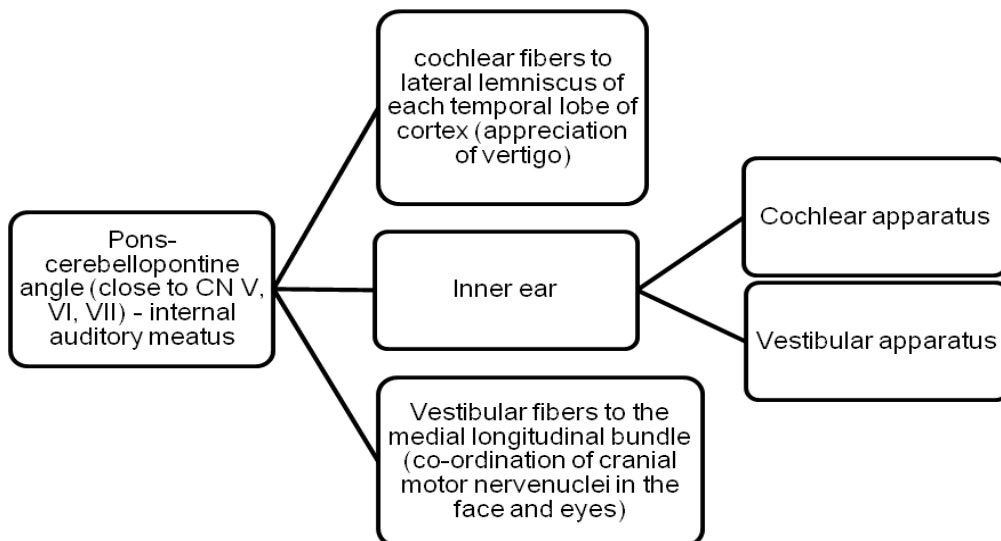
Source: Baliga RR. *Saunders/Elsevier* 2007, page 155.



Ear: cranial nerve VIII

- VIII (Vestibulo-cochlear) – auditory and vestibular components (sensory)
 - Hearing (whisper test)
 - Local sound and vibration (S12 Hz tuning fork)
- Auditory Nerve CN VIII

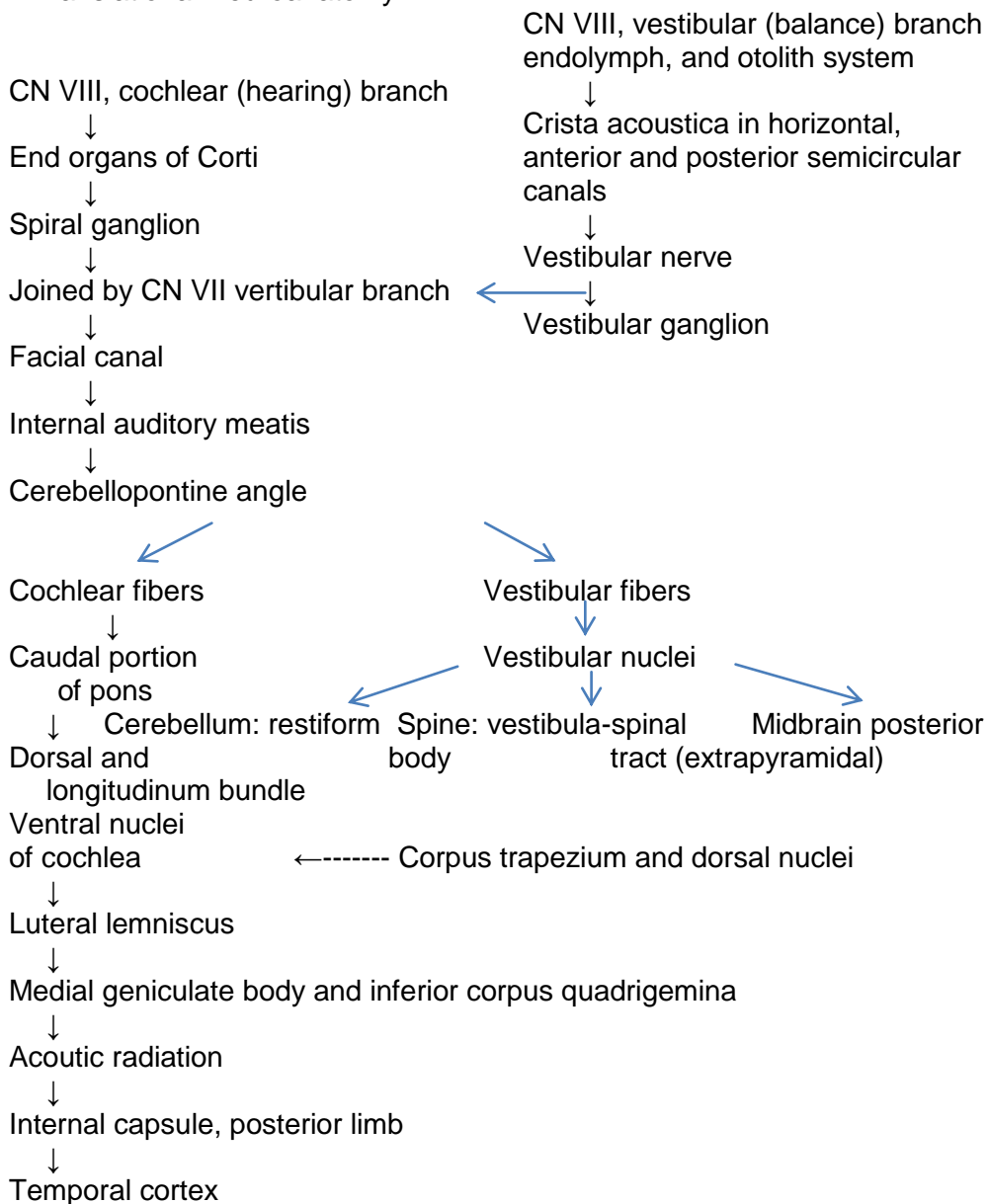
Translational Neuroanatomy



- Perform a focused physical examination for labyrinth disease.
 - Vertigo
 - Nystagmus
 - Postural defect (inability to maintain the position of an outstretched arm when the eyes are open)
 - Past-pointing
- Take a directed history and perform a focus physical examination to distinguish between cerebral, psychogenic and hypertensive vertigo.
 - Cerebral vertigo
 - Associated with epilepsy, migraine, increased intracerebral pressure
 - Psychogenic vertigo
 - Often associated with parathesine of lower limbs
 - Hypertensive vertigo
 - Comes on with or worsens on stooping



➤ Translational Neuroanatomy



Cranial Nerve VIII, acoustic branch

Tuning fork is normally heard longer with air conduction (AC) than with bone conduction (BC; mastoid bone) (Rinne test)

| | |
|--------------------|------------------------|
| AC > BC | Normal |
| AC < BC or BC > AC | Conductive deafness |
| AC = BC | Sensorineural deafness |



Deafness

➤ Causes

- Conduction deafness
 - Middle ear
 - Otitis media
 - Otosclerosis
 - Bone conduction > air conduction
- Nerve deafness
 - Cochlear
 - Infection –mumps
 - Idiopathic – Meniere’s disease
 - Drugs

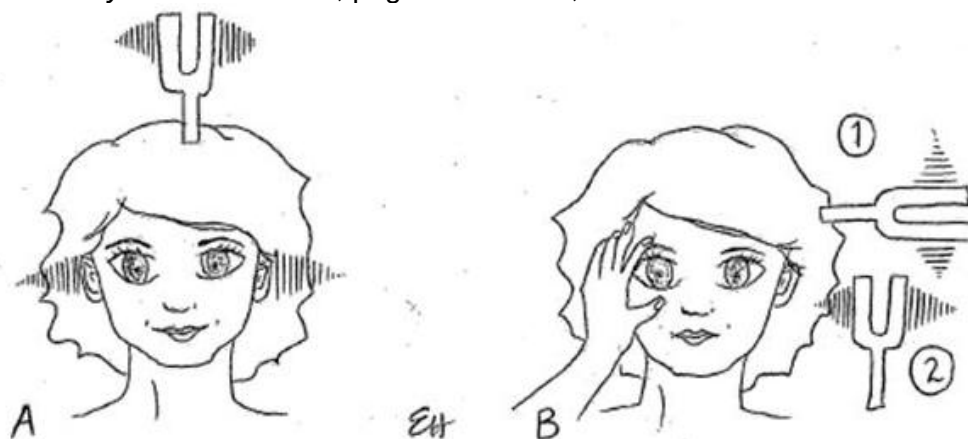
Useful background:

- Rinne – normal: air > Bone conduction ([BC], conduction hearing loss)
- Weber - lateralizes to good ear – neurosensory loss; lateralizes to bad ear – conductive loss
- Vestibulo-ocular reflex (vestibular component)

| | Nerve | Middle ear |
|---------|---------------------|-----------------------|
| ➤ Rinne | ○ AC > BC | ○ AC = AC; ACb, BCb |
| ➤ Weber | ○ Normal ear louder | ○ Abnormal ear louder |

Abbreviations: AC, air conduction; BC, bone conduction; C, conductive; CN cranial nerves

Adapted from: Filate W, et al. *The Medical Society, Faculty of Medicine, University of Toronto* 2005, pages 153 to154, and 157 to158.




Adapted from: Mangione S. *Hanley & Belfus* 2000, page 113; McGee SR. *Saunders/Elsevier* 2007, Figure. 21, page 245.



| Weber test | Rinne test | Possible interpretations |
|-------------------|-----------------------------------|--|
| ➤ Midline | ○ AC> BC, bilateral | - Normal hearing, bilateral
- Neurosensory loss, bilateral |
| ➤ Louder in left | ○ BC> AC, left
○ AC> BC, right | - Conductive loss, left |
| ➤ Louder in left | ○ AC> BC, bilateral | - Normal hearing, bilateral
- Neurosensory loss, worse on right |
| ➤ Louder in right | ○ BC> AC, bilateral | - Conductive loss, bilateral but worse on right
- Conductive loss on right and severe neurosensory loss on left |

Adapted from: Filate W, et al. *The Medical Society, Faculty of Medicine, University of Toronto* 2005, page 162; Baliga RR. *Saunders/Elsevier* 2007, page 107; McGee SR. *Saunders/Elsevier* 2007, Table 21-1, page 246.

| Finding | Sensitivity (%) | Specificity (%) | PLR | NLR |
|--|-----------------|-----------------|------|------|
| ➤ Hearing tests | | | | |
| ○ Abnormal whispered voice test | 90-99 | 80-87 | 6.0 | 0.03 |
| ➤ Tuning fork tests (patients with unilateral hearing loss) | | | | |
| ○ Rinne test, detecting conductive hearing loss | 60-90 | 95-98 | 16.8 | 0.2 |
| ○ Weber test, lateralizes to good ear, detecting neurosensory loss | 58 | 79 | 2.7 | NS |
| ○ Weber test lateralizes to bad ear, detecting conductive loss | 54 | 92 | NS | 0.5 |



- Sen N out – Sensitive test; when negative, rules ot disease
- Sp P in – Specific test; when positive, rules in disease

Abbreviation: NLR, negative likelihood ratio; NS, not significant; PLR, positive likelihood ratio

Source: McGee SR. *Saunders/Elsevier* 2007, Box 21-1, page 247.

SO YOU WANT TO BE A NEUROLOGIST!

Q. What structural damage causes Nystagmus?

A. Nystagmus is the involuntary oscillation of the eye. It is caused by damage to the mechanisms in the brain or brainstem for the coordination of eye movements (not due to damage to CN III, IV, VI).

Articulation: Cranial nerves IX, X, XII

Translational Neuroanatomy of IX, X, XI

- Interconnected nuclei of IX, X, XI
- All three situated in the dorsum of the open medulla in the floor of the fourth ventricle
- Ventral nucleus solitaries
 - Motor
- Dorsal nucleus and solitaries
 - Sensory
 - Autonomic

Translational Neuroanatomy

Cranial Nerve (CN) IX

- IX (Glossopharyngeal)
 - Sensory- posterior third of tongue, pharynx, nasopharynx, middle ear; voice-hoarse, nasal, taste; phonation
 - Motor
 - Initiate swallow (middle constrictor of pharynx, and stylopharyngeus)
 - Gag reflex (afferent limb, IX; efferent limb, X)
 - Ipsilateral palate elevation (with CN X)
 - Soft palate, larynx, pharynx (nucleus ambiguus)



- Sensation (including taste) to
 - Back of tongue
 - Fauces
 - Palate
 - Secretory fibers to parotid gland
 - Motor fibers to
 - Stylo – pharyngeus
 - Palate – palato – pharyngeus
 - Palato – glosses
- Weakness of the sternomastoids is not a reliable sign for CN XI damage: look for wasting of sternomastoid muscles

CN IX, X, XI

- Bilateral representation
 - No unilateral UMN lesion
 - Only bilateral UMN lesion
- Unilateral LMN lesion
 - Jugular foramen syndrome
 - Cancer of nasopharynx
 - Fracture of base of skull
 - Paget's disease
 - Basal meningitis
 - Jugular vein thrombosis
 - Unilateral LMN lesion isolated to trapezius and sternomastoid
 - Injury to neck
- CN X – Sensory and motor supply to larynx
- X (Vagus)
 - Motor
 - Gag reflex (afferent limb, IX; efferent limb, X)
 - Soft palate, larynx, pharynx (nucleus ambiguus)
 - Ipsilateral palate elevation (with CN IX)
 - Swallowing, phonation
 - Reflex
 - Gag reflex (afferent limb, IX; efferent limb, X)
 - Secretory
 - Parotid gland
 - Afferent and efferent pathways to heart, lung and, GI tract (nucleus solitaries)
- XI (Spinal accessory) (motor)
 - Rotate head against resistance (sternocleidomastoid muscle)



- Shrug shoulders (trapezius muscle)
- Necessary fibers to vagus nerve
- XII (Hypoglossal)
 - Motor to tongue and hyoid bone depressors
 - Tongue movement (deviation, fasciculation, atrophy, pushing tongue against teeth)
 - Speech- say 'AH' (dysarthria)
- Perform a focused physical examination to determine the site of defect and the causes of dysarthria (disorder of articulation).

| Site of defect | Causes | Characteristics of speech |
|--|--|---|
| ➤ Supra-nuclear (pseudo-bulbar palsy)
- UMN lesions of CN IX, X or XII) | <ul style="list-style-type: none"> ○ CVA ○ MND ○ MS | <ul style="list-style-type: none"> - Monotonous - High-pitched - "hot potato" speech |
| ➤ Nuclear (bulbar palsy, LMN lesions of CN IX, X or XII) | <ul style="list-style-type: none"> ○ MND ○ Guillain-Barré syndrome ○ Tumour of medulla ○ Bulbar polio ○ Syringobulbia | |
| ➤ Basal ganglia | <ul style="list-style-type: none"> ○ Parkinsonism ○ Wilson's disease ○ Chorea/athetosis | <ul style="list-style-type: none"> - Slow - Quiet - Slurred - Monotonous |
| ➤ Cerebellum | <ul style="list-style-type: none"> ○ MS ○ Tumour ○ Drugs and toxins (alcohol) | <ul style="list-style-type: none"> - Staccato - Scanning |
| ➤ Muscle | <ul style="list-style-type: none"> ○ Myasthenia gravis ○ Muscular dystrophy | |
| ➤ Mouth | <ul style="list-style-type: none"> ○ False teeth ○ Cleft palate ○ Stuttering | |

Abbreviations: CN, cranial nerve; CVA, cerebrovascular accident; LMN, lower motor neuron; MND, motor neuron disease; MS, multiple sclerosis; UMN, upper motor disease

Adapted from: Burton JL. *Churchill Livingstone* 1971, page 170; Baliga RR. *Saunders/Elsevier* 2007, pages 149 and 153



Clinical Gem: Uvula- deviates to strong side; jaw and tongue-deviate to weak side

- In the absence of wasting of the tongue, then even if there is fibrillation or deviation of the tongue, a CN XII LMN cannot be diagnosed
- In the absence of an UMN lesion causing hemiplegia, an UMN lesion of tongue cannot be diagnosed (in the absence of pyramidal UMN lesion of area or leg there cannot be a pyramidal lesion of the tongue)
- Bilateral lesion of tongue
 - UMN – pseudobulbar palsy
 - LMN – bulbar palsy

Syndrome of the Jugular Foramen (posterior Fossa)

- Perform a focused physical examination for a lesion in the posterior fossa (jugular foramen syndrome).
- Glossopharyngeal nerve, CN X
 - Nucleus ambiguus (motor branch)
 - Taste, posterior 1/3 of tongue
 - Sensation of the inside of the mouth
- Accessory nerve, CN XI
 - Motor
 - Trapezius and sternomastoid muscles
 - Accessory nerve is joined by a branch of the upper cervical spine
- Hypoglossal, CN XII

Useful background: Multiple Cranial nerves abnormalities

| CN Combination | Common cause |
|------------------------------|--|
| ○ Unilateral III, IV, V1, VI | ➤ Cavernous sinus lesion |
| ○ Unilateral V, VII, VIII | ➤ Cerebellopontine angle lesion |
| ○ Unilateral IX, X, XI | ➤ Jugular foramen syndrome |
| ○ Bilateral X, XI, XII | ➤ Bulbar palsy (LMN), pseudobulbar palsy (UMN) |

Adapted from: Filate W, et al. *The Medical Society, Faculty of Medicine, University of Toronto* 2005, page162.



- Perform a focused physical examination of the tongue to distinguish between a lower motor neuron (LMN) lesion, bulbar palsy, and pseudobulbar/bilateral upper motor neuron (UMN) lesion.
 - LMN
 - Atrophy on half of the tongue
 - With mouth, tongue deviates away towards the weak side
 - Protruding tongue from the mouth, tongue deviates away towards the weak side
 - Bulbar
 - Bilateral wasting of tongue (bilateral LMN)
 - Pseudobulbar
 - Bilateral UMN
 - Tongue is stiff, opeptic
 - No atrophy
 - Patient has difficulty protruding tongue

- Take a directed history and perform a focused physical examination for the jugular foramen syndrome.
 - Definition
 - Symptoms/signs from impaired function of cranial nerves IX, X and XI.
 - The jugular foramen is located between the lateral part of the occipital bone and the petrous portion of the temporal bones.

 - History
 - Eye
 - Ptosis (due to Horner's syndrome).
 - Ear
 - Pain in and around the ear (due to damage of the ninth and tenth cranial nerves which carry sensation to the external auditory meatus and behind the ear).
 - Head
 - Headache
 - Voice
 - Hoarseness of voice.
 - Nasal quality to the speech.
 - Throat
 - Nasal regurgitation and dysphagia.
 - Aspiration of food with choking attacks.
 - Tongue
 - Wasting of the tongue (often noticed by the dentist).
 - Neck
 - Weakness of the sternomastoids and trapezii.



- Physical Examination
 - Throat
 - Sluggish movement of the palate on the affected side when the patient says 'aah'.
 - Absent gag reflex on the same side.
 - Chin
 - Weakness when the patient moves her chin to the opposite side.
 - Neck
 - Flattening of the shoulder on the same side.
 - Wasting of the sternomastoid.
 - Difficulty in shrugging the shoulder on the same side.

- Causes
 - Infection
 - Basal meningitis.
 - infiltration
 - Carcinoma (of the pharynx is the commonest cause).
 - Neurofibroma or any tumour.
 - Vascular
 - Thrombosis of jugular vein.
 - Trauma
 - Fractured base of the skull.
 - Metabolic
 - Paget's disease.

Adapted from: Baliga RR. *Saunders/Elsevier* 2007, pages 224 and 225.

- Perform a focused physical examination for posterior inferior cerebellar artery thrombosis.
- V-Ipsilateral loss
- VI, VII, VIII – (Often transient)
- IX, X, XII – (Bulbar palsy)
- Cerebellum – ataxia, with nystagmus to the side of the lesion
- Lateral spinothalamic pathway – (Often transient)
- Homolateral Horner's syndrome
- Bulbar palsy affects motor nuclei.

Adapted from: Burton JL. *Churchill Livingstone* 1971, page 78.



- Perform a focused physical examination for a disorder of CN IX/X.
- Clinical
 - Absent pharyngeal sensation (tested with a cotton applicator stick touching the posterior oropharynx)
 - Diminished velar movement (reduced elevation of the soft palate as the patient vocalizes a prolonged "ah")
 - Abnormal gag reflex (diminished, absent, hyperactive or asymmetric)
- Causes
 - Bilateral cerebral hemispheric disease (Unilateral cerebral hemispheric disease does not ordinarily cause palatal weakness because each nucleus of these nerves receives bilateral corticobulbar innervation)
 - Ipsilateral medulla or peripheral nerves (i.e. cranial nerves IX and X)

Adapted from: McGee SR. *Saunders/Elsevier* 2007, page 697.

Speech

- Component
 - Phonation: abnormality is called dysphonia.
 - Articulation: abnormality is called dysarthria.
 - Language: abnormality is called dysphasia.

Source: McGee S. R. *Saunders/Elsevier* 2007, page 149.

Speaking of speech

- Dysphasia
 - Disorder in use of symbols for communication, whether spoken, heard, written or read.
- Dysarthria
 - Disorder of articulation
- Expressive
- Receptive
- Apraxia
 - Inability to carry out purposive movements in absence of motor paralysis, sensory loss or ataxia
 - Related to expressive dysplasia



- Agnosia
 - Failure to recognise, whether visual, auditory or tactile
 - Related to receptive dysplasia
- Perseveration
 - Continuation or recurrence of an activity without appropriate stimulus
- Verbigeration
 - Meaningless repetition of words or sentences
- Echolalia
 - Parrot-like repetition by the subject of statements or acts made before them
- Epilepsy
 - A paroxysmal transitory disturbance of brain function, ceasing spontaneously, with a tendency to recurrence
- Myoclonus
 - A brief shock-like contraction of a number of muscle fibres, a whole muscle or several muscles, either simultaneously or successively

Adapted from: Burton JL. *Churchill Livingstone* 1971, page 69.

Speech Centres

The four major centres may be disordered by disease and give rise to disorders of speech include

Dysphasia

- Cortex
 - Grey matter
 - Dementia
 - Precentral gyrus
 - Expressive
 - Postcentral gyrus
 - Receptive
-] Dysplasia (aphasia is often associated with acalculia and agraphia)

“Who is an ‘allied health professional’,
when we are all partners in care”

Grandad



- Perform a focused examination of a patient with dysphasia.

| Fluent speech | Nominal | Conductive | Receptive | Expressive no
fluent |
|------------------------|---------|------------|-------------------|-------------------------|
| ○ Name object | ↓ | ↓ | ↓ | ↓ |
| ○ Repetition | - | ↓ | ↓ | +/- |
| ○ Comprehension | - | - | ↓ | - |
| ○ Reading (dyslexia) | | ✓ | ✓ | ✓ |
| ○ Dysgraphic (writing) | | ✓ | ✓ abn-
content | ✓ |

- Look for hemiparesis. The arm is more affected than the leg.
 - As patients are usually aware of their deficit, they are often frustrated and depressed.
- Fluent speech (receptive, conductive or nominal aphasia, usually)
- Name object—Patients with nominal, conductive or receptive aphasia will name objects poorly
 - Repetition—cannot repeat ‘no ifs, ands or buts’.
 - Comprehension—follow commands (verbal or written): ‘Touch your nose, then your chin and then your ear.’
 - Reading—dyslexia
 - Writing—writing (dysgraphia)
- Non-fluent speech (expressive aphasia, usually)
- Naming of objects—This is poor, but may be better than spontaneous speech
 - Repetition—May be possible with great effort. Phrase repetition (e.g. ‘no ifs, ands or buts’) is poor.
 - Comprehension—Often mildly impaired despite popular belief, but written and verbal commands are followed
 - Reading—Patients may have dyslexia
 - Writing—Dysgraphia may be present

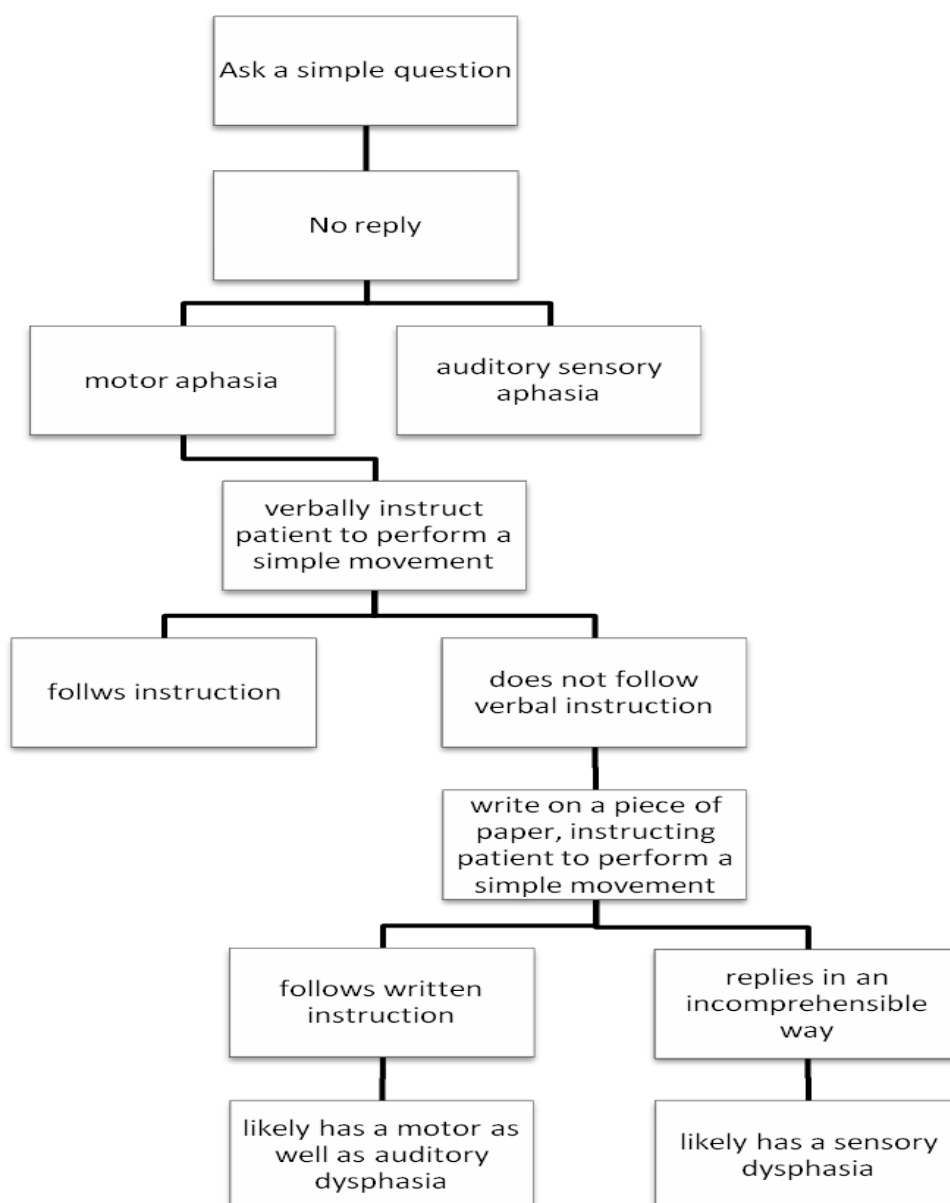
Adapted from: Talley N. J., et al. *Maclennan & Petty Pty Limited* 2003, Table 10.3, page 351.



Dysarthria

Remember

- There are two speech centres, one sensory (receptive) and one motor
- These speech centres are in the dominant hemisphere



- Cranial nerve VII, IX, X
 - Disordered function of lips, tongue and soft palate
 - Dysarthria
 - Dysphonia
 - Disordered function of laryngeal muscles

- Caused by disorder affecting the motor function of cranial nerves VII, IX and X may be caused by disease of the following site:
 - LMN lesion cranial nerve VII, IX, X, XII
 - Bilateral papralysis of lips, tongue and soft palate
 - Bulbar
 - Sounds like the voice of the cortex character, Donald Duck
 - Cerebral cortices
 - Both R and L internal capsules affected
 - “pseudo-bulbar palsy”
 - Cerebrum
 - Signs of cerebellar dysfunction
 - Jerky, monotonous speech, like talking with your mouth full of food
 - Extrapyramidal fibers
 - Monotonous speech
 - Festinations (labial, lingual, palatal and laryngeal)
 - Disease of muscle
 - Myopathy
 - Myasthenia gravis
 - Syphilis
 - GPI (general paralysis of the insane)
 - Sounds like “baby talk”

- Difficulty speaking because of disorder of muscles of articulation; “British constitution muscle)

- Take a directed history and perform a focused physical examination for a speech disorder.

- Dysphasia
 - Definition
 - A disorder of the content of speech
 - Usually follows a lesion of the dominant cortex:
 - Expressive (motor), nominal dysphasia or motor dysphasia
 - The patient understands, but cannot answer appropriately
 - Speech is non-fluent
 - This occurs with a lesion in the posterior part of the dominant third frontal gyrus (Broca's)



- Sensory or receptive dysphasia
 - The site of the lesion is the superior temporal lobe (Wernicke's area)
- Nominal dysphasia: all types of dysphasia
 - Is also a specific type of nominal dysphasia
 - Objects cannot be named (e.g. the nib of a pen) but other aspects of speech are normal
 - The patient may use long sentences to overcome failure to find the correct word (circumlocution).
 - It occurs with a lesion of the dominant posterior temporoparietal area.
 - Certain types of speech may be retained by these patients. These include automatic speech. The patient may be able to recite word series such as the days of the week or letters of the alphabet.
 - Emotional speech may be preserved so that when frustrated or upset the patient may be able to swear fluently.
 - The patient may be able to sing familiar songs while unable to speak the words.
 - Unless the lesion responsible for these defects is very large there may be no reduction in the patient's higher intellectual functions, memory or judgement.
 - Some of these patients may incorrectly be considered psychotic, because of their disorganised speech.
 - Other causes include
 - Encephalopathy or the intracranial pressure effects of a distinct space-occupying lesion;
 - It may also occur in the recovery phase from any dysphasia.
- Conductive dysphasia
 - Repeat statements and name objects poorly, but can follow commands.
 - Caused by a lesion of the arcuate fasciculus and/or other fibres linking Wernicke's and Broca's area.
- Dysarthria
 - Definition
 - An inability to articulate properly
 - Because of local lesions in the mouth, or
 - Disorders of speech muscles or their connections (there is no disorder of the content of speech)
 - The causes of dysarthria are:
 - Stutter, stammer: psychological origin
 - Paralysis of cranial nerves - Bell's palsy, CN IX, X, XI
 - Cerebellar disease - staccato, scanning speech



- Signs of cerebellar dysfunction
 - Parkinson's speech - slow, quiet, slurred, monotonous
 - Pseudobulbar palsy - monotonous, high-pitched 'hot potato' speech
 - Look for bilateral paralysis of lips, tongue, soft palate
 - Progressive bulbar palsy - nasal
- Dysarthria-lips, tongue, palate (VII, IX, X) (Say "The True Methodist Episcopal Church")
 - Expressive or motor dysphasia- understands spoken words and can obey commands; lesions of posterior inferior 3rd frontal convolution
 - Dysarthria
 - A difficulty with articulation
 - Abnormalities of upper motor neurone lesions of the cranial nerves, extrapyramidal conditions (e.g. Parkinson's disease) and cerebellar lesions cause disturbances to the rhythm of speech.
 - Ask the patient to say a phrase such as 'British Constitution' or 'Peter Piper picked a peck of pickled peppers'.
 - Pseudobulbar palsy is an upper motor neurone weakness which causes spastic dysarthria (it sounds as if the patient is trying to squeeze out words from tight lips)
 - Mouth ulceration or disease may mimic dysarthria.
 - Bulbar palsies cause a nasal speech
 - Facial muscle weakness causes slurred speech
 - Extrapyramidal disease
 - Monotonous speech (bradykinesia and muscular rigidity). Other causes of alcohol intoxication and cerebellar disease.
 - Loss of coordination and slow, slurred and often explosive speech, or speech broken up into syllables called scanning speech (page 431)
 - Dysphonia
 - Alteration of the sound of the voice such as huskiness of the voice with decreased volume
 - May be due to laryngeal disease (e.g. following a viral infection or a tumour of the vocal cord), or to recurrent laryngeal nerve palsy, but occasionally may be hysterical.

Adapted from: McGee SR. *Saunders/Elsevier* 2007, page 149.



WHY WOULD ANYONE IN THEIR RIGHT MIND WANT TO BE A NEUROLOGIST IF YOU HAVE TO REMEMBER TRIVIA LIKE THIS?

Q1. What are the eponymous syndromes of the lower cranial nerves (CN)?

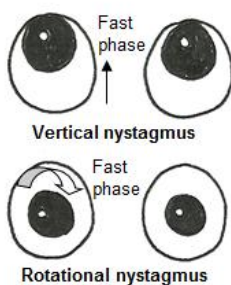
- A1.
- CN IX, X and XI ○ Vernet's syndrome: paresis due to extension of tumour into the jugular foramen.
 - CN IX to XII ○ Collet-Sicard syndrome: fracture of the floor of the posterior cranial fossa.
 - CN IX to XII ○ Villaret's syndrome: ipsilateral paralysis of the last four cranial nerves and cervical sympathetic.
 - CN X, XI ○ Syndrome of Schmidt
 - CN XI, XII ○ Syndrome of Hughlings Jackson

Q2. Why is the hypoglossal nerve not part of the jugular foramen syndrome?

A2. CN XII leaves through the anterior condylar foramen.

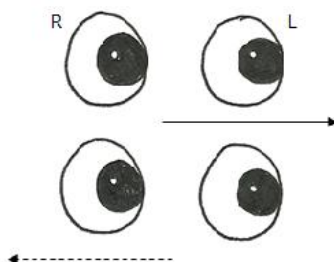
Source: Baliga RR. *Saunders/Elsevier* 2007, pages 224 and 225.

Nystagmus and vertigo



- Peripheral lesions
 - Severe vertigo + nausea/vomiting in acute phase
 - Lying still, fixing eyes on bright objects helps symptoms

Lee



- Central lesions

Fast side Findings with a right sided lesion looking to the left

Slow drifting phase



| ➤ Vestibular nystagmus | Central (vestibular nuclei) | Peripheral (labyrinth or vestibular nerve) |
|--|-----------------------------|--|
| ➤ Vertigo | Rare | Yes |
| ➤ Auditory symptoms | No | Yes |
| ➤ Lying still, fixing eyes on bright objects helpful | No | Yes |

Adapted from: Davey P. *Wiley-Blackwell* 2006, page 90.

- Where is the lesion in vestibular nystagmus?
 - Central (affecting vestibular nuclei), as in
 - Cause
 - CVA
 - MS
 - Tumor
 - Alcoholism.
 - Peripheral (labyrinth or vestibular nerve)
 - Meniere's syndrome
 - Acoustic neuroma
 - Otitis media
 - Head injury.

Adapted from: Baliga R.R. *Saunders/Elsevier* 2007, page 147.

Useful background: Nystagmus

- Definition
 - A series of involuntary, rhythmic oscillation of one or both eyes.
 - May be horizontal, vertical or rotary.
 - Slow drifting of eye, then rapid correcting movement
 - The direction of the rapid correcting movement is the direction used to describe the nystagmus
 - Ascentuate nystagmus by looking away from the straight-ahead or middle line
 - Lesions of vestibular apparatus, cerebellum, toxins (alcohol)
- Causes
- Physiological e.g. opto- kinetic
- Eye
 - Errors of refraction and macular lesions
 - Weakness of ocular muscles (Lesion of CN III, IV or VI)



➤ Lesions of vestibular apparatus, cerebellum, brain stem

Source: Burton JL. *Churchill Livingstone* 1971, page 76.

- Perform a focused physical examination for the causes of nystagmus/vertigo.
 - Eyes (nystagmus)
 - Physiological, e.g. opto-kinetic
 - Errors of refraction and macular lesions
 - Weakness of ocular muscles
 - Lesion of cranial nerves III, IV or VI
 - Brainstem lesions, cerebellum, temporal cortex
 - Vestibular apparatus and overve
 - High cervical cord diseases
 - Vestibular lesions
 - Physiological
 - Labrinthitis
 - Menière's
 - Bledding, in leukemia
 - Drugs, e.g. quinine, salicylates, alcohol
 - Otitis media
 - Motion sickness
 - Vestibular nerve lesions
 - Acoustic neuroma
 - Drugs, e.g. streptomycin
 - Vestibular neuronitis
 - Brain stem, cerebellar or temporal cortical lesions
 - Pontine infarction or hemorrhage
 - Vertebro-basilar insufficiency
 - Basilar artery migraine
 - Temporal lobe epilepsy
 - Disseminated sclerosis
 - Tumours
 - Benign post-traumatic positional vertigo

Adapted from: Burton JL. *Churchill Livingstone* 1971, page 76.



Useful background: Eyes nystagmus

- Phasic nystagmus
 - Slow and fast component of eye movement is in horizontal or vertical direction
 - IV amed according to the direction of the fast component
- Vertical nystagmus
 - Often caused by brain-stem lesions
- Rotatory nystagmus
 - Often present with forward gaze
 - Due to defective vision (often from defective development of visual purple)
 - Lens
 - Cornea
 - Myopia
 - Optic nerve atrophy
 - Albinos
 - Miners (not minors!)

Headache and facial pain

Useful background: Mechanisms of headache production

- Muscle
 - Skeletal muscle contraction (e. g. 'tension' headache)
- ENT
 - Referred pain, e.g. disease of eyes, ears, sinuses, teeth, cervical spine
- Artery
 - Systemic hypertension
 - Arterial dilatation
 - Intra-cranial
 - systemic infections
 - hypertension
 - nitrites
 - postictal
 - concussion
 - Extracranial (e.g. migraines)
 - Traction on arteries e.g. raised IC pressure



- Vein
 - Dilatation or traction on venous sinuses e.g. post lumbar puncture
 - Analgesics
 - Oral contraceptive pill

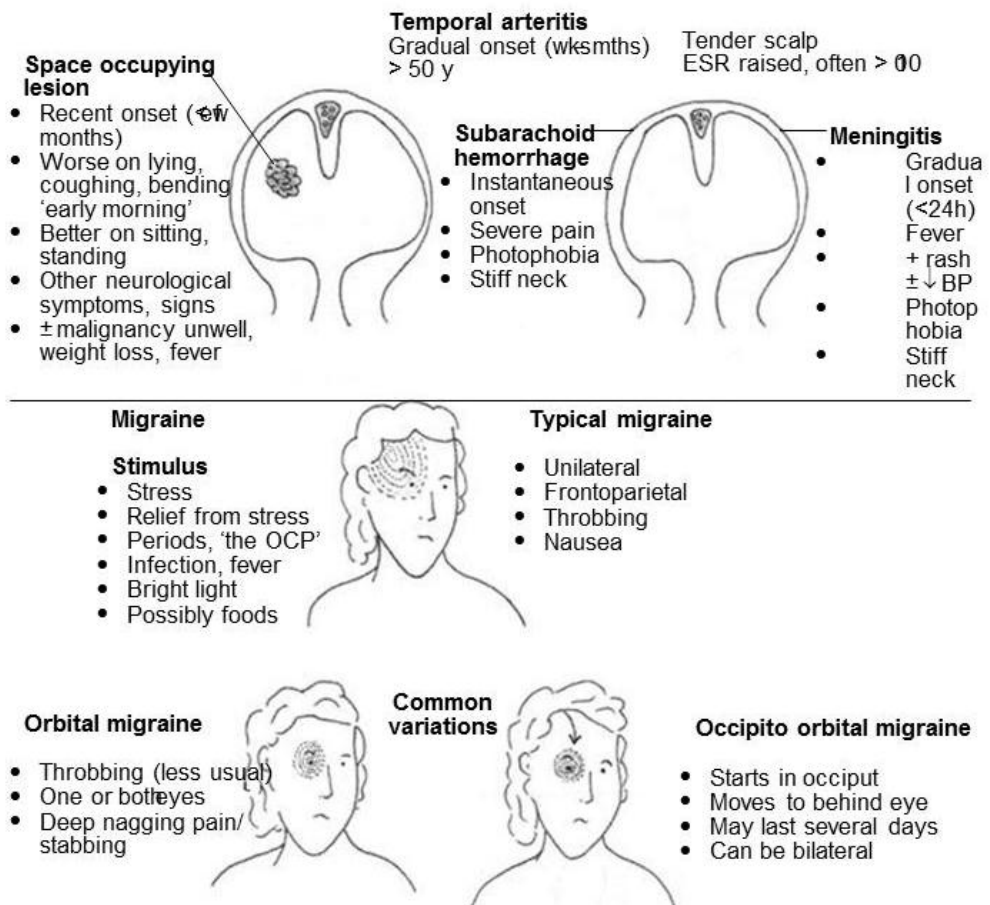
- Inflammation
 - Intra-cranial (e.g. meningitis)
 - Extra cranial (e.g. giant cell arteritis)

- Psychogenic

Abbreviation: IC, intracranial

Adapted from: Burton JL. *Churchill Livingstone* 1971, page 72.

Useful background: Headache and facial pain



Adapted from: Davey P. *Wiley-Blackwell* 2006, page 106.



Useful background: History taking for headache

- Likely many aspects of history taking, a combination of pretest probability estimation, a system of inquiry, and thoughtful reiteration and probing work best. For any pain or discomfort, the “PQRST” mnemonic described in DeGowan and DeGowan works well—provocative or palliating factors, quality, radiation, severity, and temporal relationships. Below is illustrated one approach. It is not intended to be exhaustive.
- Character of headache
 - Quality of pain: Is it steady/throbbing, constant/remittent, sharp/dull, superficial /deep?
 - Location of pain) regional or diffuse
 - Severity of pain: Try to quantify this if possible:
 - Ask “on a scale of 1 to 10, 10 being “the worst pain you have ever had and 1 being pain free, what number would you give the pain?”
 - Temporal relationships
 - Age of patient and age of onset of first episode, relationship to time of day, weekends, menses
 - Clustering or chronicity
 - Rapidity of onset and duration of episodes
 - Palliating and provocative factors: Changes with position, neck movement, chewing, foods, alcohol, menses, cough/straining, stressors, eyestrain, massage, sleep?
 - Associated symptoms: These include systemic illness/infection, nausea/vomiting, diarrhea, photophobia/photophobia, lacrimation/stuffy nose, facial flushing, scalp tenderness, jaw claudications/myalgias and stiffness/temporal tenderness, weight loss, palpitations, depression/change in mentation or personality, aura, scintillating scotomas, neurovisual disturbances
- Medications: include BCP (efficacy or overuse of), analgesics, alcohol
- Past Medical History: Commonly missed on history taking. It should include prior history of headache/ investigations/diagnosis/ treatment. Hypertension, seizures, sinusitis, head injury, glaucoma, problems with refractive error, temporal arteritis, dental or ENT problems.
- Family history: Frequently missed and should include migraine, subarachnoid hemorrhage or stroke at an early age.
- Ominous features
 - Worst headache of patient’s life, especially if rapid onset



- Exacerbation of headache with coughing, sneezing, or bending down
- Headache with seizures, reduced level of consciousness, confusion focal neurological findings
- New or progressive headache persisting for days
- New-onset headache in middle age or older
- Change in frequency, severity, or clinical features of the usual headache pattern
- Presence of systemic symptoms including fever, myalgia, malaise, weight loss, scalp tenderness, or jaw claudication

Abbreviations: BCP, birth control pain

Reproduced with the permission of Dr.B.Fisher, U of A; Jugovic PJ, et al. *Saunders/ Elsevier* 2004, pages 42 and 43.

Useful background: Characteristics of headache

- Tension
 - Lasts 30 min – 7 days
 - Not pulsating, mild/moderate in intensity, bilateral
 - Not aggravated by exertion, not associated with nausea/vomiting, or sensitivity to light, sound, or smell
 - Episodic or chronic, bilateral frontal/ occipital/ frontal arga, not awakening person at night, with no vomiting, no photophobia or stiff neck
- Migraine with aura
 - Unilateral headache preceded by flashing light or zig-zag lines, associated with photophobia.
 - Lasts 4-72 hrs
 - Throbbing, moderate/severe intensity, unilateral (not always the same side)
 - Worse with exertion
 - Associated with photophobia, phonophobia, nausea/vomiting
 - May be preceded by short prodromal period of depression, irritability, restlessness, or anorexia, 10-20% occurrences associated with an aura-transient, reversible neurologic visual, somatosensory, motor, and/or language deficit-usually precedes headache by no>1 h, can be concurrent
 - Diagnosis of migraine without aura plus neurological dysfunction sensed before or during an attack



- Migraine without aura
 - a. A diagnosis of migraines without aura requires each of the following:
 - i. Minimum of 5 attacks
 - ii. Duration of headache is 2-72 h (with or without therapy)
 - iii. Two of the following are present: unilateral pain, pulsing or throbbing quality to pain, moderate-to-severe intensity preventing daily activities, or pain provoked by routine physical activity
 - iv. One of the following is present: nausea, vomiting, photophobia, phonophobia, or osmophobia
 - v. No evidence of other causes of headache

- Cluster
 - Usually with pain over one eye with tears, runny nose, and flushing of the forehead lasting minutes to hours, in bouts lasting several weeks, and coming a few times a year.
 - Lasts 15-180 min, occurs up to 8 times per day
 - Severe, unilateral, located periorbitally and or temporally
 - Associated with at least one of: tearing, red eye, stuffy nose, facial sweating, ptosis, miosis

- Subarachnoid hemorrhage
 - Acute, severe, 'thunderclap'
 - May have neurologic deficits or changes in level of consciousness

- Brain tumour
 - Presents on wakening and improves during the day
 - Symptoms due to increased intracranial pressure
 - Generalized, may be more severe in occipital region, worse when lying down or with a Valsalva maneuver
 - May be associated with nausea/vomiting, blurring of vision, papilloedema, transient visual obscuration

- Cervical spondylosis
 - Occipital headache, neck stiffness

- Meningitis
 - Generalized headache, neck stiffness, photophobia, fever

- Increased intracranial pressure
 - Generalized headache, worse in the morning, with vomiting and drowsiness



- Temporal arteritis
 - Unilateral headache, blurred vision, tenderness over temporal artery
- Sinusitis
 - Generalized headache, pressure/ fullness behind the eyes/ cheek/ forehead
- Subarachnoid hemorrhage
 - Localized generalized headache, sudden onset, neck stiffness

Adapted from: Filate W, et al. *The Medical Society, Faculty of Medicine, University of Toronto* 2005, page 172; Jugovic PJ, et al. *Saunders/ Elsevier* 2004, page 43.

SO YOU WANT TO BE A NEUROLOGIST!

Q. Give the serious causes of headache in which neuroimaging findings may be normal.

- A.
- Giant cell or temporal arteritis
 - Glaucoma
 - Trigeminal or glossopharyngeal neuralgia
 - Lesions around sella turcica
 - Sentinel bleed of aneurysm (warning leak)
 - Inflammation, infection, or neoplastic invasion of leptomeninges
 - Cervical spondylosis
 - Pseudotumor cerebri
 - Low intracranial pressure syndromes

Source: Ghosh AK. *Mayo Clinic Scientific Press* 2008, Table 19-10, page 759.

- Take a directed history to determine the causes of facial pain.
- Eye
 - Glaucoma
 - Superior orbital fissure syndrome
- TMJ
 - Arthritis
- Blood vessels
 - Temporal arteritis
 - Cluster headache
 - Aneurysm of the internal carotid or posterior communicating artery
 - Risk factors for CVA

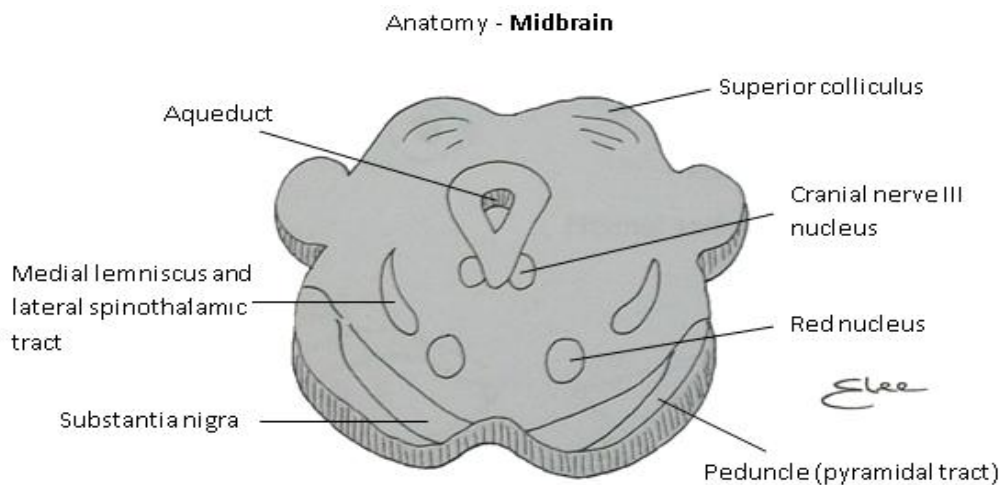


- Hypertension
 - Smoking
 - Diabetes mellitus
 - Hyperlipidemia
 - Atrial fibrillation
 - Bacterial endocarditis
 - Myocardial infarction (emboli)
 - Hematological disease
 - Family history of stroke
- Nerve
 - Trigeminal neuralgia
 - Psychiatric disease

Abbreviation: TMJ, temporomandibular joint

Adapted from: Burton JL. *Churchill Livingstone* 1971, page 74.

- **Translation**



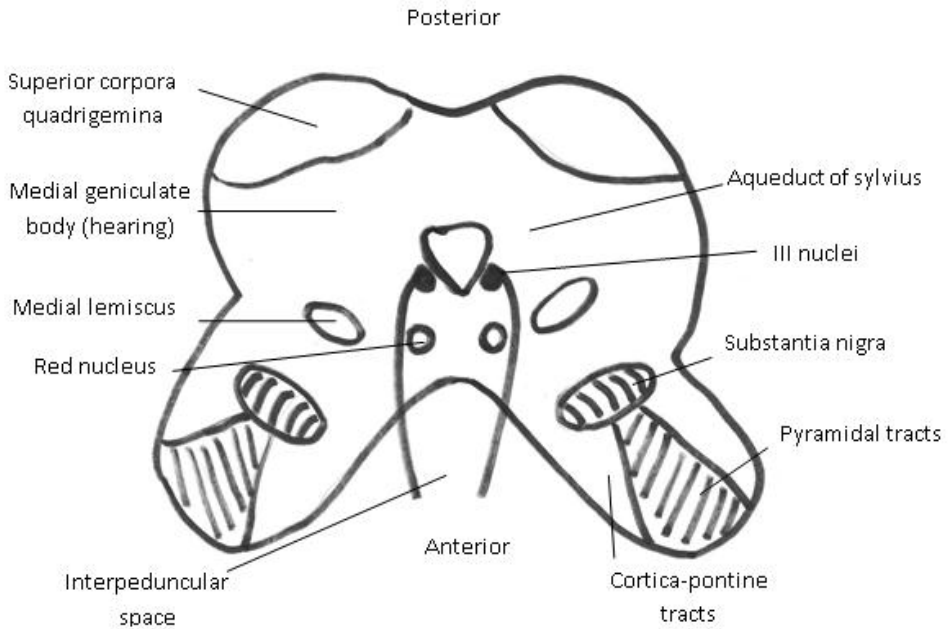
Adapted from: Talley NJ, et al. *MacLennan & Petty Pty Limited* 2003, Figure 10.8, page 365.

“Science is never cast in stone and ideas are
written with a finger on shifting sand.”

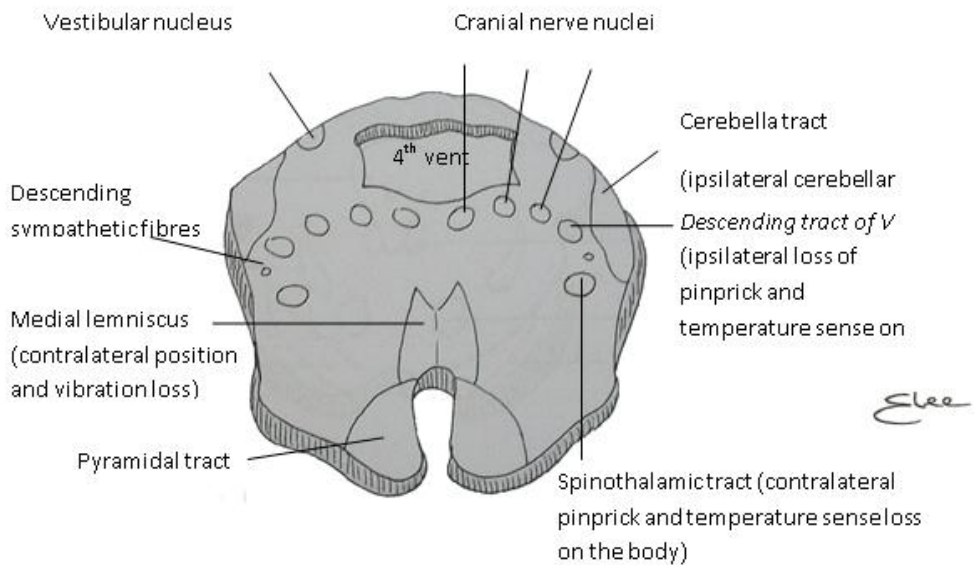
Anonymous



➤ **Midbrain**



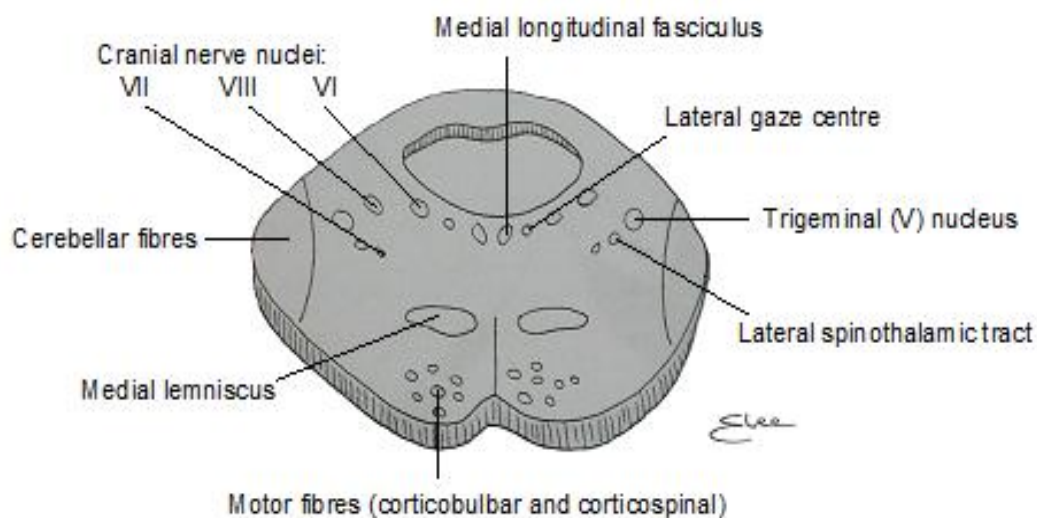
Anatomy - **Medulla**



Adapted from: Talley NJ, et al. *MacLennan & Petty Pty Limited* 2003, Figure 10.17, page 380.

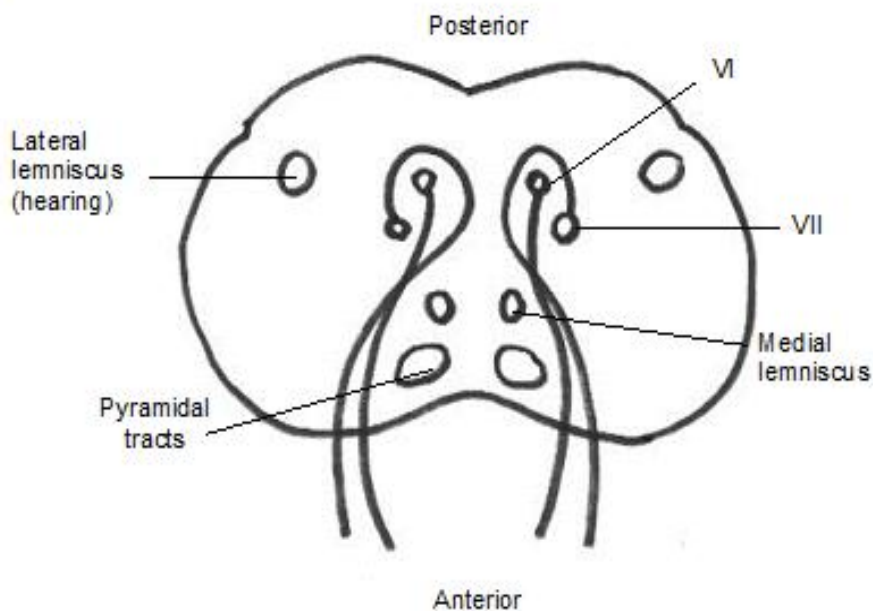


Anatomy - Pons



Adapted from: Talley NJ, et al. *MacLennan & Petty Pty Limited* 2003, Figure 10.11, page 371.

Pons



SO YOU WANT TO BE A NEUROLOGIST!

Q1. Is there a “medial” medullary syndrome?

A1. Yes

- It is caused by the occlusion of the lower basilar artery or vertebral artery.
- Ipsilateral lesions result in paralysis and wasting of the tongue
- Contralateral lesions result in hemiplegia and loss of vibration and joint position sense

Q2. Give four examples of syndromes that result from abnormalities of groups of cranial nerves.

- A2
- Unilateral III, IV, V and VI
 - Suggests a lesion in the cavernous sinus
 - Unilateral V, VII, and VIII
 - Suggests a cerebellopontine angle lesion (usually a tumour)
 - Unilateral IX, X AND XI
 - Suggests a jugular foramen lesion
 - Combined bilateral X, XI, XII suggests bulbar palsy if lower motor neurone changes are present, and pseudobulbar palsy if there are upper motor neurone signs.

Useful background: Hypothalamus

➤ Anatomy

- That part of the brain situated in the interpeduncular space
- Forms the floor of the third ventricle
- Consists of tuber cinereum and mammillary bodies
- Tuber cinereum is a sheet of grey matter which stretches from the mammary bodies to the optic chiasm
- The tuber cinereum is also attached to the infundibulum (posterior part) of the pituitary.
- Receives afferents from
 - Olfactory tract
 - Frontal cortex
 - Thalamus
 - pituitary
- Contains ganglia of sympathetic nervous system



- Structure
 - Consists of tuber cinereum and mammillary bodies
 - Tuber cinereum is a sheet of grey matter stretching from the optic chiasm to the mammillary bodies, attached to which is the infundibulum of the pituitary
- Function
 - Coordinates sympathetic and parasympathetic functions
 - Receives afferents from the olfactory tract, frontal cortex, and thalamus
 - The posterior pituitary is traversed by fibers arising in the hypothalamus.
- Take a directed history for hypothalamic disease.
 - Truncal obesity
 - Hypogonadism
 - Diabetes insipidus
 - Narcolepsy-irreversible urge to sleep
 - Cataplexy-sudden brief loss of power of limbs-eyelids drop, jaw drops, limbs sag, patient falls to the ground but does not lose consciousness
 - Increased sweating, salivation, fever, peptic ulceration, increased gut motility, disturbed appetite, sleep
 - Causes
 - Neoplasm-III ventricle tumor, suprasellar neoplasm, chromophobe adenoma
 - Infection-TB, syphilis, encephalitis lethargica
 - Fracture of the base of skull
 - Idiopathic
- Give a systematic approach to the causes of hypothalamic disease.
 - Neoplasm
 - III ventricle
 - Suprasellar
 - Chromophobe adenoma
 - Infection
 - TB
 - Syphilis
 - Encephalitis
 - Trauma
 - Base of skull
 - idiopathic



- Perform a focused physical examination of hypothalamic disease.
- CNS
 - Narcolepsy
 - Cataplexy
- Endocrine
 - Truncal obesity
 - Hypogonadism
 - Diabetes insipidus
- GI
 - ↑ salivation
 - ↑ peptic ulcer
 - Diarrhea
- Skin
 - ↑ sweating
- General
 - Fever

Hyperthermia/ Hypothermia

Useful background: Name three hypothermia syndromes, and give their clinical characteristics of hyperthermia syndromes

| Diagnosis | Characteristics |
|-------------------|---|
| ➤ Heat Cramps | <ul style="list-style-type: none"> ○ Core body temperature is normal; skin is moist and cool ○ Occurs in muscles following vigorous exercise in the heat ○ Caused by salt depletion from excess sweating combined with hypotonic fluid replacement, resulting in dilutional hyponatremia |
| ➤ Heat Exhaustion | <ul style="list-style-type: none"> ○ Core body temperature is minimally increased and is between 37°C and 40°C ○ Consequence of salt and water losses ○ Symptoms: <ul style="list-style-type: none"> - Muscle cramps - Diaphoresis - Headache - Nausea - Vomiting - Orthostatic syncope |



| Diagnosis | Characteristics |
|--|--|
| ➤ Heat Stroke | <ul style="list-style-type: none"> ○ Core body temperature $\geq 40.6^{\circ}\text{C}$ ○ <i>Classic</i>: develops over several days during heat waves and affects primarily the elderly or those suffering from chronic illness ○ <i>Exertional</i>: occurs acutely with workers, endurance athletes or soldiers submitted to conditions of high heat and humidity without appropriate access to salt and water ○ Signs and symptoms: <ul style="list-style-type: none"> - Dehydration - Central nervous system dysfunction (delirium, seizure, coma) - Hot, dry skin ○ Complications: <ul style="list-style-type: none"> - Disseminated intravascular coagulation - Rhabdomyolysis - Renal failure - Seizures - Permanent neurologic damage |
| ➤ Malignant Hyperthermia | <ul style="list-style-type: none"> ○ Drug-induced reaction characterized by genetic susceptibility to generalized and sustained skeletal muscle contraction after exposure to depolarizing muscle relaxants such as succinylcholine or volatile anesthetic agents, such as halothane or isoflurane ○ Sustained muscle contraction and increased metabolism result in <ul style="list-style-type: none"> - Hyperthermia - Metabolic acidosis - Increased serum creatine kinase (CK) ○ Duchenne disease and myotonic muscular dystrophy have been associated with an increased incidence of malignant hyperthermia |
| ➤ Neuroleptic Malignant Syndrome (NMS) | <ul style="list-style-type: none"> ○ Drug-induced idiosyncratic reaction characterized by <ul style="list-style-type: none"> - Hyperthermia - Altered mentation - Muscle rigidity - Autonomic instability (e.g., cardiac arrhythmias) ○ Drugs implicated are most often <ul style="list-style-type: none"> - Phenothiazines (e.g., chlorpromazine) and butyrophenones (e.g., haloperidol) - Withdrawal of a dopaminergic agent (e.g., levodopa) resulting in reduced central dopamine neurotransmission |



Reproduced with permission: Therapeutics Choices. Sixth Edition. Ottawa, Canada: *Canadian Pharmacist Association* 2012, Table 1, page 187.

Useful background: Common Causes of Syncope

- Volume depletion and drugs
 - Volume depletion
 - Diarrhea
 - Diminished oral intake
 - Polyuria
 - Drugs
 - ACE inhibitors
 - Alcohol
 - Alpha- and beta-adrenergic blockers
 - Antiparkinsonian drugs
 - Diuretics
 - Nitrates
 - Phosphodiesterase type 5 inhibitors (sildenafil, tadalafil, vardenafil)
 - Vasodilators

- Orthostatic intolerance disorders
 - Reflex syncope syndromes
 - Carotid sinus hypersensitivity
 - Vasovagal syncope syndromes
 - Autonomic neuropathies
 - Pure autonomic failure syndromes
 - Multiple system atrophy syndromes

- Arrhythmias
 - Bradycardias
 - Complete (third degree) and bifascicular heart block
 - Sinus node disease
 - Tachycardias
 - Supraventricular arrhythmias (uncommon)
 - Torsades de pointes polymorphic ventricular tachycardia
 - Ventricular tachycardia

- Obstruction
 - Aortic stenosis
 - Pulmonary emboli
 - Many other rare causes

Reproduced with permission: Therapeutics Choices. Sixth Edition. Ottawa, Canada: *Canadian Pharmacist Association* 2012, Table 1, page 597.



Brain Stem

A useful Trick:

- Think of the brainstem as being part of the spinal cord, with the cranial nerves added on
- The brain stem is comprised of the midbrain, pons and medulla.
- There is crossed hemiplegia with disease involvement of the brain stem.

Useful background: Brain stem

- Anatomy
 - Fibers from the internal capsule of the cortex pass to the cerebral peduncle
 - Fibers from the cerebral peduncle to the brainstem
 - The brain stem is comprised of the midbrain, pons and medulla
 - Fibers from the brain stem pass to the spinal cord
 - The brain stem receives the motor and sensory fibers of the cranial nerves also contain the nuclei of the cranial nerves, and their interconnections.
 - The motor fibers of the cranial nerves decussate (cross) higher up the brain stem than do the pyramidal fibers
 - The fibers running from the nuclei of the cranial nerves are lower motor neurons.
 - Because the cranial motor fibers cross higher than the motor fibers from the pyramidal tract, there may be weakness of the cranial muscles on one side, and weakness of the opposite side of the body
 - Crossed hemiplegia occurs because of damage to a cranial nerve after it crosses, and damage to the pyramidal tract after it crosses.

Source: Davies IJT. *Lloyd-Luke (medical books) LTD 1972, Figure 11, page 243 and 247*

- Take a directed history and perform a focused physical examination for disease of the brainstem.

History (the D's)

- Diplopia (CN III, IV or VI)
- Decreased sensation in the face (CN V)
- Decreased strength in the face (CN VII)
- Dizziness and deafness (CN VIII)
- Dysarthria and dysphagia (CN IX, X, XII)



Physical

- Ipsilateral
 - Cranial nerve abnormalities, plus contralateral
 - Diplopia
 - Nystagmus
 - ↓ corneal reflexes
 - Facial weakness
 - Facial numbness
 - Deafness
 - Dysarthria
 - Palate paralysed
 - Gag reflex ↓
 - Tongue deviation
- Contralateral changes in
 - Pyramidal tract
 - Hemiparalysis (weakness)
 - ↑ reflexes
 - ↑ tone
 - Babinski sign positive
 - Spinothalamic tract
 - Hemianaesthesia (numbness: ↓ in all sensory modalities)

Source: Mangione S. *Hanley & Belfus*, 2000,

Babinski sign

- Dorsiflexion of the big toe when the sole of the foot is stimulated from the lateral to the medial side
- Dorsiflexion (Babinski sign is positive) indicates an UMN lesion of the pyramidal (aka corticospinal) pathway

Source: Mangione S. *Hanley & Belfus* 2000,

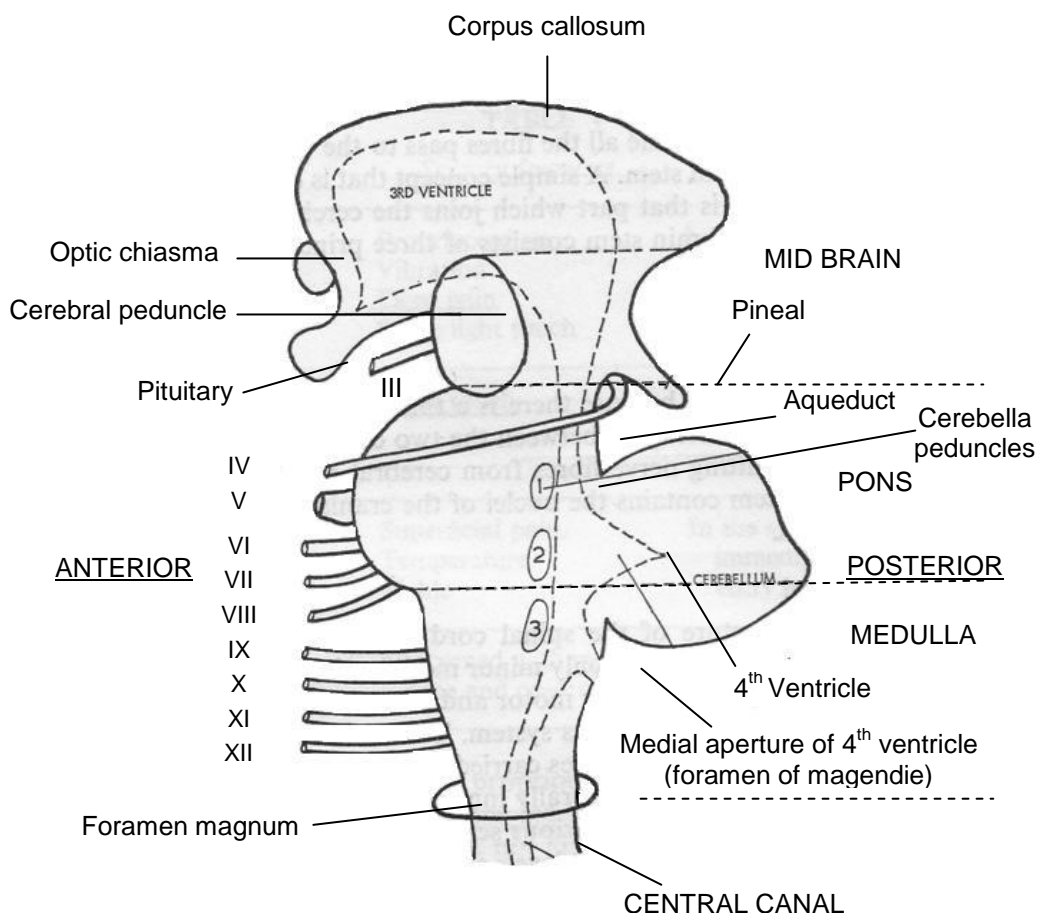
- Perform a focused physical examination for a brainstem lesion.
 - Ipsilateral cranial nerve changes
 - Impaired ocular motility: diplopia
 - Medial longitudinal fasciculus syndrome
 - Nystagmus
 - Dysphagia
 - Vertigo
 - Contralateral corticospinal tract
 - Ataxia, dysarthria

Source: Ghosh AK. *Mayo Clinic Scientific Press* 2008, page 762.



Brain stem

- Perform a focused physical examination for locked-in state.
- Definition
 - Localized damage to brainstem, usually between the upper third and lower two-thirds of the brainstem
- Clinical
 - Patient is awake
 - Only function is CN III and VI (eye move and can be kept open)
 - Patient's eyes may follow the MD as he/she moves around ("tracking")
 - Patient can see and hear, but has no movement or sensation



The brain stem showing the midbrain, pons and medulla as well as the origin of the cranial nerves.

Adapted from: Davey P. *Wiley-Blackwell* 2006, page 243.



Useful background: Clinically important structures which are seen in the brain stem are:

- Medial longitudinal bundle which interconnects the nuclei of the cranial nerves and is concerned with co-ordination of face and eye movements.
 - Ascending tract of the trigeminal nerve which contains proprioceptive and touch fibres, corresponding to the posterior columns. The fibres immediately cross the midline and join the medial lemniscus.
 - Descending tract of the trigeminal nerve which carries pain and temperature impulses corresponding to the lateral spinothalamic tract. This tract descends to the level of C.2 on the same side as it enters, and then crosses the midline and joins the lateral spinothalamic tract.
 - Tractus solitaries, which contains fibres conveying taste.
 - Corticospinal tracts.
 - Nuclei of the cranial nerves. These occur as follows: Midbrain: oculomotor and trochlear. The oculomotor nerve emerges from the midbrain close to the cerebral peduncle so that a lesion in this area gives rise to a lower motor neurone oculomotor palsy on the same side and a hemiplegia on the opposite side (Weber's syndrome). Pons: abducens, trigeminal, facial and auditory. Medulla: glossopharyngeal, vagus accessory and hypoglossal.
- Internal capsule
- Affects eyes, neck, trunk and girdle
- Pyramidal system-internal capsule, midbrain, pons, medulla
- Pyramidal fibers decussate in medulla to form pyramidal tracts
 - The pyramidal tracts pass down the later columns to enter the grey matter of the anterior horns, where they synapse with the anterior horn cells
 - In the brain stem, the pyramidal tracts give off fibers to the contralateral motor cranial nerve nuclei
 - A few pyramidal fibers do not decussate in the medulla but go down the same side as the anterior cortico-spinal tract.



| Tract | Sensory Impulses | Site of Decussation |
|--------------------------|--|---|
| ➤ Posterior columns | <ul style="list-style-type: none"> ○ Proprioception ○ Vibration ○ Deep pain ○ Some light touch | – In the medulla, after forming medial lemniscus |
| ➤ Anterior spinothalamic | <ul style="list-style-type: none"> ○ Light touch | – In the spinal cord several segments above their entry |
| ➤ Lateral spinothalamic | <ul style="list-style-type: none"> ○ Superficial pain ○ Temperature ○ Tickle | – In the spinal cord immediately above entry |
| ➤ Spinocerebellar | <ul style="list-style-type: none"> ○ Concerned with muscle tone and co-ordination | – Probably do not cross |

Source: Davey P. *Wiley-Blackwell* 2006, page 245.

Useful anatomical background: Tracts in the brain Stem

- Posterior columns
 - Fibers in the cord
 - uncrossed → medial lemnisci
 - crossed → medulla
- Anterior spinothalamic
 - Fibers in cord → reticular substance in medulla → medial lemniscus of the pons, crossing several segments above entry → thalamus
- Lateral spinothalamic
 - Fibers in cord → medulla → medial lemniscus of pons, crossing immediately above entry → thalamus

The sensory tracts which end in of the spinal cord at the medulla include fibers from the periphery, as well as the cranial nerves

Peripheral nerves

- Posterior columns
 - Uncrossed fibers form the medial lemnisci
 - The medial lemnisci decussate in the medulla
- Anterior spinothalamic fibers
 - Carrying sensation of light touch



- These fibers form the reticular substance
- Reticular substance is in the medulla

“The motor fibers of the spinal nerves (corticospinal or pyramidal fibers) decussate in the upper part of the medulla just below the pons. They continue on the opposite side to the spinal cord where they become the pyramidal or lateral corticospinal tract” (Davies IJT. *Lloyd-Luke (medical books) LTD* 1972, pg 246).

- Lateral spinothalamic fibers
 - Carry sensation of pain and temperature
 - Continue through the medulla, and in the pons they join the medial lemniscus
 - The medial lemniscus goes from the pons to the thalamus

The basilar artery supplies the brainstem, and as well the midbrain (plus cerebral peduncles), pons and medulla are supplied by the y, plus brainstem basilar artery, plus posterior cerebral artery, anterior inferior cerebellar artery, and the posterior inferior cerebella artery, respectively.

- Perform a focused physical examination for a brainstem lesion (crossed paralysis/hemiplegia).
 - UMN lesion on one side
 - LMN lesion of a cranial nerve on the opposite side

"When we are no longer able to change a situation,
we are challenged to change ourselves"

Viktor Frankl



- Perform a focused physical examination for an ischemic event involving the midbrain, pons, as well as the lateral and medial portions of the medulla.

| | Artery | Site | Clinical |
|------------|---|---|--|
| • Midbrain | ➤ Posterior cerebral | <ul style="list-style-type: none"> ○ Midbrain <ul style="list-style-type: none"> - Severe <ul style="list-style-type: none"> ▪ Cerebral pedicles <ul style="list-style-type: none"> - Quadriplegia ▪ Ipsilateral III, IV <ul style="list-style-type: none"> - LMN <ul style="list-style-type: none"> oculomotor and tracheal pulses - Impaired conjugate movements of eyes - Mild <ul style="list-style-type: none"> ▪ Crossed hemiplegia (corticospinal tract and CN III involvement) ○ Hemiballismus ○ Thalamic syndrome ○ Akinetic mutism (aka coma vigil) ○ Peri-pineal area <ul style="list-style-type: none"> ▪ Impaired upwards movement of eyes | |
| • Pons | <ul style="list-style-type: none"> ➤ Unique features ➤ Cranial nerves | <ul style="list-style-type: none"> ○ Pin-point pupils ○ Hyperventilation ○ LMN lesion | <ul style="list-style-type: none"> ▪ IV – abducent <ul style="list-style-type: none"> - Impaired lateral gaze ▪ V <ul style="list-style-type: none"> - trigeminal ▪ VII – facial ▪ VIII – auditory |



| Artery | Site | Clinical |
|----------------------|--|--|
| ➤ Sensation | <ul style="list-style-type: none"> ○ Unilateral sensory loss ○ The anterior and lateral spinothalamic tracts: location of sensory loss depends on whether the medial lemniscus is involved before or after entry of fibers | |
| ➤ Motor | ○ Corticospinal tracts | ▪ Contralateral hemiplegia |
| ➤ Sympathetic system | ○ Horner's syndrome | |
| ➤ Cerebellar tracts | ○ Cerebellar signs | |
| • Medulla | <ul style="list-style-type: none"> ➤ Cranial nerves <ul style="list-style-type: none"> ○ VIII (vestibular branches) ○ IX (glossopharyngeal) ○ X (vagus) ➤ Sensation <ul style="list-style-type: none"> ○ Medial lemniscus ➤ Motor <ul style="list-style-type: none"> ○ Corticospinal tract ➤ Cerebellum <ul style="list-style-type: none"> ○ Cerebellar peduncle | <ul style="list-style-type: none"> ▪ Dysarthria ▪ Dysphagia ▪ Vocal cord paralysis ▪ Contralateral loss of position and vibration ▪ Contralateral hemiplegia ▪ Unilateral cerebellar signs |
| • Lateral medulla* | <ul style="list-style-type: none"> ➤ Cranial nerve <ul style="list-style-type: none"> ○ V ➤ Sensory <ul style="list-style-type: none"> ○ Lateral spinothalamic ➤ Sympathetic <ul style="list-style-type: none"> ○ Ipsilateral Horner's syndrome | <ul style="list-style-type: none"> ▪ Ipsilateral loss of sensation of face ▪ Contralateral loss of pain and temperature ▪ |

*lateral medullary syndrome



| | Artery | Site | Clinical |
|----------------------|--|--|----------|
| • Medial medulla | ➤ Cranial nerve XII
➤ Sensation | ○ Unilateral atrophy of the tongue
○ Medial lemniscus | |
| • | Take a directed history and perform a focused physical examination to distinguish between bulbar versus pseudobulbar palsy, and their cause. | | |
| ➤ Bulbar palsy | <ul style="list-style-type: none"> ○ Clinical <ul style="list-style-type: none"> - VII, IX, X, XII - Labio-glosso-palato-pharyngeal bilateral LMN lesion ○ Causes <ul style="list-style-type: none"> - Inflammation <ul style="list-style-type: none"> ▪ Poliomyelitis ▪ Acute ascending peripheral neuritis ▪ Encephalitis lethargic ▪ Botulism ▪ Syphilis | | |
| ➤ Pseudobulbar palsy | <ul style="list-style-type: none"> ○ Clinical <ul style="list-style-type: none"> - Tongue – spastic - Palate – paralysed - Jaw jerk positive - Face fixed, emotionless - Pyramidal signs - Emotions disturbed ○ Causes <ul style="list-style-type: none"> - Bilateral cerebral thrombosis - Motor neuron disease - Multiple sclerosis | | |

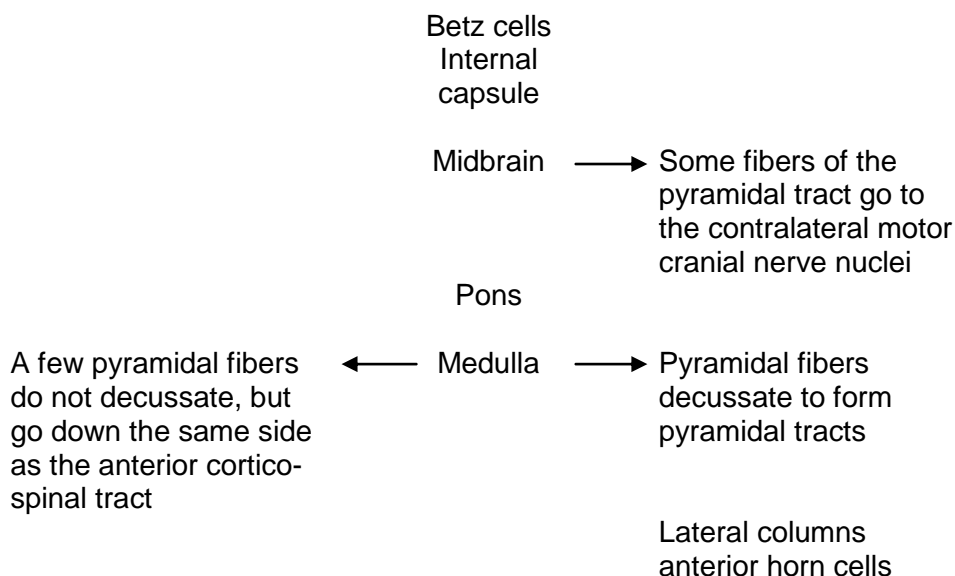
SO YOU WANT TO BE A NEUROLOGIST!

Q. Give three examples of neurologist conditions which undergo remission and relapses.

- A.
- Multiple sclerosis
 - Infections (of CNS)
 - Myasthenia gravis



Useful background: The neuroanatomic parts which constitute the pyramidal system



Source: Davies IJT. *Lloyd-Luke (medical books) LTD* 1972, Figure 12, page 243

- Tips
- Hemiplegia may be
 - UMN
 - Extrapyrarnidal
 - Hysterical
- Take a directed history and perform a focused physical examination for increased intracranial pressure.
- History
 - Headache
 - Vomiting
 - Epilepsy
 - Mental changes
- Papilledema (blockage of retinal veins)
- False localising signs
- Signs of temporal pressure cone
- Perform a focused physical examination for a temporal pressure cone.



- Translational neuroanatomy
 - With an increase in the intracranial pressure (ICP), the temporal lobes and the midbrain may be forced through the hiatus formed by the two free edges of the tentorium
 - This places pressure on
 - Cerebral peduncles
 - Midbrain
 - CN III/VI
 - Posterior cerebral arteries
- Physical findings
 - Contralateral hemiplegia (pressure on cerebral peduncle on side of tumor)
 - Ipsilateral CN III palsy - fixed dilated pupil
 - Ipsilateral CN VI – paralysis of ipsilateral rectus muscle
 - Posterior cerebral artery occlusion – homonymous hemianopia
 - Midbrain infarction
- In the context of increased intracranial pressure perform a focused physical examination for a “false localizing sign” for hemiplegia.
 - Increased intracranial pressure from a tumor will usually place pressure on the same side as the cerebral peduncle, and thereby cause a contralateral hemiplegia
 - Sometimes a brain tumor will displace the brain to the side, putting pressure on the cerebral peduncle on the side opposite to the tumor
 - This causes ipsilateral hemiplegia, so that the paraplegia will appear on the same side as the tumor
 - The localization of the paraplegia to the same as the tumor, rather than opposite side as would be expected, is known as a “false localising sign”
- Perform a focused physical examination for a foramen magnum pressure cone.
- Translational neuroanatomy
 - If the increased intracranial pressure increases in the posterior fossa, the posterior fossa part of the cerebellum is pushed through the foramen magnum, and the medulla is forced downwards with compression exerted on the anterior and posterior parts of the medulla.



- When herniation is due to a congenital anomaly, the foramen magnum pressure cone is due to an Arnold-chiare malformation.
- Physical findings
 - Anterior pyramidal tracts
 - Posterior column nuclei compression of loss of proprioception
 - Bulbar palsy
 - Pain in neck
 - Cerebellar signs
 - Obstructive hydrocephalus if the fourth ventricle is blocked
 - Associated with syringomyelia, meningocele
- Perform a focused physical examination for a brainstem lesion.
 - Ipsilateral cranial nerve changes
 - Impaired ocular motility: diplopia
 - Medial longitudinal fasciculus syndrome
 - Nystagmus
 - Dysphagia
 - Vertigo
 - Contralateral corticospinal tract
 - Ataxia, dysarthria

Source: Ghosh AK. *Mayo Clinic Scientific Press* 2008, page 762.

SO YOU WANT TO BE A NEUROLOGIST!

- Q. The plantar response is extensor in the first year of life, in deep coma, and in lesions of the pyramidal tract. Under what clinical circumstances may this response be falsely negative?
- A.
- Loss of sensation on the sole of the foot
 - Hallux rigidus
 - Paralysis of extensor hallucis longus (L4,5)

Useful background: Crossed hemiplegia

- The fact that the upper motor neurons of the cranial nerves decussate at a higher level than the decussation of the pyramids explains the phenomenon of crossed hemiplegia, i.e. weakness of the opposite side of the body with weakness of the cranial nerve muscles on the same side. A lesion which damages the cranial nerve after it has decussated, which also damages the pyramidal tract



before it has decussated, will cause a crossed hemiplegia. The best known of crossed hemiplegias are:

- The posterior columns, which contain uncrossed fibres, form the medial lemnisci which decussate in the medulla.
- The anterior spinothalamic (light touch) which forms the reticular substance in the medulla, and then joins the medial lemniscus in the pons.
- Perform a focused physical examination to distinguish between an intramedullary from an extramedullary cord lesion.

| | Intramedullary | Extramedullary |
|-----------------------|--|--|
| ➤ Root pain | ○ Rare | ○ Common |
| ➤ Corticospinal signs | ○ Late onset | ○ Early onset |
| ➤ LMN signs | ○ Extend for several segments | ○ Localized |
| ➤ Sensory loss | ○ Dissociated sensory loss (pain and temperature) may be present | ○ Brown-Sequard syndrome if lateral cord compression |
| ➤ Sacral sparing | ○ May have sacral sparing | ○ No sacral sparing |
| ➤ CSF fluid | ○ Normal or minimally altered | ○ Early, marked abnormalities |

Abbreviations: CSF, cerebrospinal fluid; LMN; lower motor neuron

Adapted from: Talley NJ, et al. *MacLennan & Petty Pty Limited* 2003, Table 10.28, page 427.

- Perform a focused physical examination for Wallenberg's syndrome (Lateral Medullary Syndrome)
 - History
 - Severe nausea, vomiting, nystagmus (involvement of the lower vestibular nuclei).
 - Limb ataxia (involvement of the inferior cerebellar peduncle).
 - Intractable hiccups, dysphagia (ninth and tenth cranial nerve involvement).



➤ Examination

- Ipsilateral contralateral loss of pain and temperature sensation
 - Nystagmus
 - Ipsilateral involvement of CN V, VI, VII, VIII
 - Bulbar palsy:
 - impaired gag
 - sluggish palatal movements
 - Horner syndrome
 - Ipsilateral cerebellar signs on the same side
 - Contralateral pain and temperature sensory loss on the opposite side (dissociated sensory loss).
- Perform a focused physical examination for lateral medullary syndrome (LMS).

➤ Definition

- The LMS results from infarction of a wedge-shaped area of the lateral aspect of the medulla and inferior surface of the cerebellum.
- The deficits are caused by involvement of one side of the nucleus ambiguus, trigeminal nucleus, vestibular nuclei, cerebellar peduncle, spinothalamic tract and autonomic fibres.
- Cerebellar signs on the same side (including ipsilateral Horner's syndrome).
- Pain and temperature sensory loss on the opposite side (dissociated sensory loss)
- Due to occlusion of any of the following five vessels:
 - Posterior inferior cerebellar artery
 - Vertebral artery
 - Superior, middle or inferior lateral medullary arteries
- Caused by involvement of one side of the nucleus ambiguus, trigeminal nucleus, vestibular nuclei, cerebellar peduncle, spinothalamic tract and autonomic fibres.
- Nystagmus.
- Ipsilateral involvement of CN V, VI, VII, VIII, IX, X
- Bulbar palsy: impaired gag, sluggish palatal movements.

Adapted from: Baliga RR. *Saunders/Elsevier* 2007, page 222.

➤ Uncus herniation



Herniation on the uncus of the temporal lobe causing sequential compression of the brainstem (thalamus, midbrain, pons, medulla)

- Take a directed history and perform a focused physical examination to distinguish between pseudobulbar and bulbar palsy.

| | Pseudobulbar palsy (UMN) | Bulbar palsy (LMN) |
|-----------------------|---|---|
| ➤ Prevalence | ○ Common | ○ Rare |
| ➤ Type of lesion | ○ UMN | ○ LMN, muscle |
| ➤ Site of lesion | ○ Bilateral, usually in the internal capsule | ○ Medulla oblongata |
| ➤ Tongue | ○ Small, stiff and spastic | ○ Flaccid, fasciculations |
| ➤ Speech | ○ Slow, thick and indistinct | ○ Nasal twang |
| ➤ Nasal regurgitation | ○ Not prominent | ○ Prominent |
| ➤ Jaw jerk | ○ Brisk | ○ Normal or absent |
| ➤ Other findings | ○ UMN lesions of the limbs | ○ LMN lesions of the limbs |
| ➤ Affect | ○ Emotionally labile | ○ Normal affect |
| ➤ Causes | ○ Strokes
○ Multiple sclerosis
○ Motor neuron disease
○ Creutzfeld-Jakob disease | ○ Motor neuron disease
○ Poliomyelitis
○ Guillain-Barre syndrome
○ Myasthenia gravis
○ Myopathy |

Adapted from: Baliga RR. *Saunders/Elsevier*, 2007, page 227; Talley NJ, et al. *Maclennan & Petty Pty Limited* 2003, Table 10.6, page 384.



SO YOU WANT TO BE A NEUROLOGIST!

Q1. What is the medial medullary syndrome?

- A1.
 - Occlusion of the lower basilar artery of vertebral artery.
 - Ipsilateral lesions result in paralysis and wasting of the tongue.
 - Contralateral lesions result in hemiplegia and loss of vibration and joint position sense.

Source : Baliga RR. *Saunders/Elsevier*, 2007, page 230.

Q2. Where is the lesion in the lateral medullary syndrome?

- A2.
 - Infarction of a wedge-shaped area of the lateral aspect of the medulla and inferior surface of the cerebellum
 - The deficits are caused by involvement of one side of the nucleus ambiguus, trigeminal nucleus, vestibular nuclei, cerebellar peduncle, spinothalamic tract and autonomic fibres.

Q3. Which vessels may be occluded?

- A3. Any of the following five vessels
 - Posterior inferior cerebellar artery
 - Vertebral artery
 - Superior, middle or inferior lateral medullary arteries

Adapted from: Mangione S. *Hanley & Belfus*, 2000, page 425.

Q. Why does a lesion of the lateral side of the medulla cause ipsilateral loss of sensation of the face, but contralateral loss of sensation (pain and temperature)?

- A. A lesion of the lateral side of the medulla affects the descending tract of cranial nerve V (trigeminal nerve) before it crosses in the cranial portion of the spinal cord, whereas the fibers of the lateral spinothalamic tract cross after they enter the spinal cord.

Q. What are the clinical tests of the function of the RAS (reticular activating system)?

- A.
 - Oculocephalic reflex ("doll's eye" reflex)
 - Stimulation of receptors in middle ear, afferent signals in CN VIII to brainstem at the cerebellar - pontine angle; efferent pathway to CN III/VI (upper pons), with III and VI connected by MLF (midbrain)
 - (medial longitudinal fasciculus), which is surrounded by RAS
 - thus, damage to RAS affects MLF, which in turn leads to loss of RAS function in the pons, indicating brainstem damage
 - Corneal reflex
 - painful sensory input from CN V, which enters brainstem in pons and medulla; CN VII is the efferent pathway to the orbicularis muscle, causing blinking of the eye

Adapted from: Mangione S. *Hanley & Belfus*, 2000, page 425.



Cerebellum

Useful background: Cerebellum

“The head ganglion of the proprioceptive system”

➤ Anatomical reminder:

The cerebellum is not primarily a motor organ. It is developed phylogenetically from a primary vestibular area and is involved in modulation of motor activity. It receives afferents from the vestibular nuclei, spinal cord and cerebral cortex via the pontine nuclei.

➤ Anatomy

- Superior cerebellar peduncle
 - Afferent (sensory) ventral spinothalamic tract
 - Efferent (motor) to midbrain
 - In midbrain associated with cranial nerves III and IV, as well as extrapyramidal tracts
- a. Middle cerebellar peduncle
 - Afferent ← cerebral cortex
 - Efferent → pons
- b. Inferior cerebellar peduncle
 - Afferent ← dorsal spinocerebellar tract
 - Vestibular nuclei
 - Nucleus gracilis
 - Efferent → medulla

Useful background: Causes of cerebellar disorder

- Congenital/ hereditary
 - Friedreich’s ataxia and other hereditary ataxias
 - Congenital malformations at the level of the foramen magnum
- Drugs/ toxins
 - Phenytoin toxicity
 - Alcoholic cerebellar degeneration (there is atrophy of the anterior vermis of the cerebellum)
- Tumor
 - Space-occupying lesion in the posterior fossa including cerebellopontine angle tumour
 - Paraneoplastic manifestation of bronchogenic carcinoma



- Vascular
 - Brainstem vascular lesion
- Demyelination
 - Multiple sclerosis
- Common
 - Infectious
 - Viral infections
 - Prion disease (Creutzfeldt- Jakob disease)
 - Metabolic
 - Hepatic encephalopathy
 - Hypothyroidism
 - B12 deficiency
 - Thiamine deficiency
 - Hyperthermia
 - Cardiovascular
 - Anoxia
 - Infarction
 - Hemorrhage
 - Inherited
 - Friedreich's ataxia
 - Ataxia telangiectasia
 - Ramsay- Hunt disease
- Causes of ataxia
 - Acute
 - Cerebellar hemorrhage or infarction
 - Trauma
 - Intoxication
 - Migraine
 - Chronic
 - Alcoholic cerebellar degeneration
 - Hypothyroidism
 - Hydrocephalus
 - Chronic infection (panencephalitis, rubella, prion disease)
 - Vitamin E deficiency
 - Paraneoplastic syndrome



- Alcoholic cerebellar degeneration
 - An ataxia that affects the trunk and gait (upper body ataxia and dysarthria are less frequent).
 - Atrophy of anterior vermis in cerebellum
 - Gait is broad - based and is progressive, but partially reversible with abstinence.
 - May present as a complex called Wernicke's encephalopathy (confusion, ataxia, ophthalmoplegia of CN VI).

Adapted from: Jugovic PJ, et al. *Saunders/ Elsevier* 2004, page 166; Talley NJ, et al. *MacLennan & Petty Pty Limited* 2003, Table 10.32, page 433.

All cerebellar signs are ipsilateral

- Clinical
 - The classical clinical triad of cerebellar diseases is ataxia, atonia, asthenia.
 - Disorders of movement:
 - Nystagmus: coarse horizontal nystagmus with lateral cerebellar lesions; its direction is towards the side of the lesion.
 - Scanning dysarthria: a halting, jerking dysarthria which is usually a feature of bilateral lesions.
 - Lack of finger-nose coordination (past-pointing): movement is imprecise in force, direction and distance - dysmetria.
 - Rebound phenomenon - inability to arrest strong contraction on sudden removal of resistance. This is known as Holmes' rebound phenomenon.
 - Intention tremor.
 - Dysdiadochokinesia - impairment of rapid alternating movements (clumsy).
 - Dyssynergia - movements involving more than one joint are broken into parts.
 - Hypotonia.
 - Absent reflexes or pendular reflexes.
 - Lack of co-ordination of gait - patient tends to fall towards the side of the lesion.
- Localization
 - Gait ataxia (inability to do tandem walking): anterior lobe (palaeocerebellum).
 - Truncal ataxia (drunken gait, titubation): flocculonodular or posterior lobe (archicerebellum).
 - Limb ataxia, especially upper limbs and hypotonia: lateral lobes (neocerebellum).



- The difference between sensory ataxia and cerebellar ataxia

| Clinical | Cerebellar ataxia | Sensory ataxia |
|--------------------------|----------------------------------|---|
| ➤ Site of lesion | ○ Cerebellum | - Posterior column or peripheral nerves |
| ➤ Deep tendon | ○ Unchanged or pendular reflexes | - Lost or diminished |
| ➤ Deep sensation | ○ Normal | - Decreased or lost |
| ➤ Sphincter disturbances | ○ None | - Decreased when posterior column involved, causing overflow incontinence |

Source: Baliga RR. *Saunders/Elsevier* 2007, page 145.

- Eyes
 - Phasic nystagmus
- Voice
 - Dysarthria
- Balance
 - Ataxia
- Muscle
 - Intention tremor
 - Hypotonicity
 - Dystonicity
 - Dysdiads kinesia
- Reflexes
 - Pendular
- Causes
 - Hereditary
 - Gradual onset and progression
 - Cerebellar signs
 - Signs in posterior column, and pyramidal tracts
 - Optic atrophy
 - Skeletal abnormalities
 - Degenerative
 - Begin in middle life
 - Not hereditary
 - Often begins as primary corticocerebellar atrophy
 - Tumor



- Toxins
 - Alcohol
 - Dilation
- Inflammation
 - TB
- Vascular
 - Posterior inferior cerebellar artery
 - Multiple sclerosis
- Upper extremities
 - Finger-to-nose test
 - Rapid alternating movements
- Lower extremities
 - Heel-to-shin test
- Gait
 - Walk with legs wide apart
 - Cannot “walk with tight rope” (poor tandem walking)
 - Poor balance and coordination
- Special tests
 - Finger-nose-finger test
 - Dysmetria (overshooting the target)
 - Hypermetria (stopping before reaching the clinician's finger)
 - The patient's finger also may deviate from a smooth course (especially if the clinician shifts the target during the test)
 - Intention tremor (as the patient's finger approaches the target, an increasing side-to-side tremor may appear)
 - Heel-Knee-Shin Test
 - Place the heel of one leg on opposite knee and then slide it down the shin.
 - A positive response may reveal any combination of ataxia, dysmetria, and intention tremor.
 - Rapid Alternating Movements
 - Dysdiadochokinesia (difficulty with rapid alternating movements)
 - Rapid pronation and supination of the forearm, clapping hands, tapping a table, or stamping the foot.
 - The movements of patients with cerebellar disease are slower and more irregular in rhythm, range and accuracy.

Adapted from: McGee SR. *Saunders/Elsevier* 2007, page 794.



- Perform a focused physical examination for a unilateral cerebellar lesion.

| Physical Finding | Frequency (%) |
|-----------------------|---------------|
| ➤ Ataxia | |
| ○ Gait ataxia | 80-93 |
| ○ Limb ataxia | |
| - Dysmetria | 71-86 |
| - Intention tremor | 29 |
| - dysdiadochokinesia | 47-69 |
| ➤ Nystagmus | 54-84 |
| ➤ Hypotonia | 76 |
| ○ Pendular knee jerks | 37 |
| ➤ Dysarthria | 10-25 |

Source: McGee SR. *Saunders/Elsevier* 2007, Table 61-1, page 798

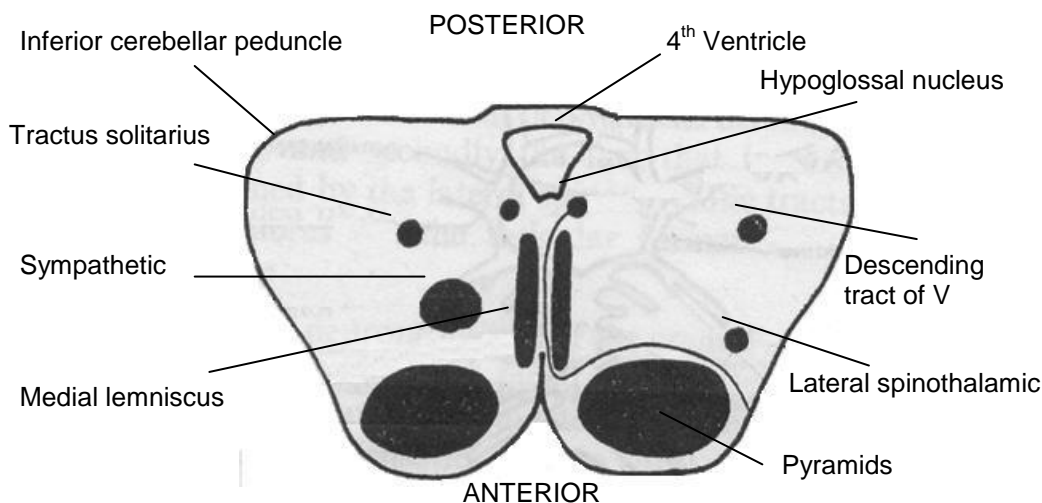
Useful background: Causes of spastic and ataxic paraparesis (upper motor neuron [UMN] and cerebellar signs combined).

- Congenital
 - Arnold-Chiari malformation, or other lesion at the craniospinal junction
- Infection
 - Syphilitic meningomyelitis
- Infiltration
 - Lesion at the craniospinal junction e.g. meningioma
- Ischemic
 - Syringomyelia
 - Infarction (in upper pons or internal capsule on one side – ‘ataxic hemiparesis’)
- Degeneration
 - Spinocerebellar degeneration e.g. Marie’s spastic ataxia
 - Multiple sclerosis
 - Spinocerebellar degeneration

NB: Unrelated diseases that are relatively common (e.g. cervical spondylosis and cerebellar degeneration from alcohol) may cause a similar clinical picture.

Adapted from: Talley NJ, et al. *MacLennan & Petty Pty Limited* 2003, Table 10.34, page 434.

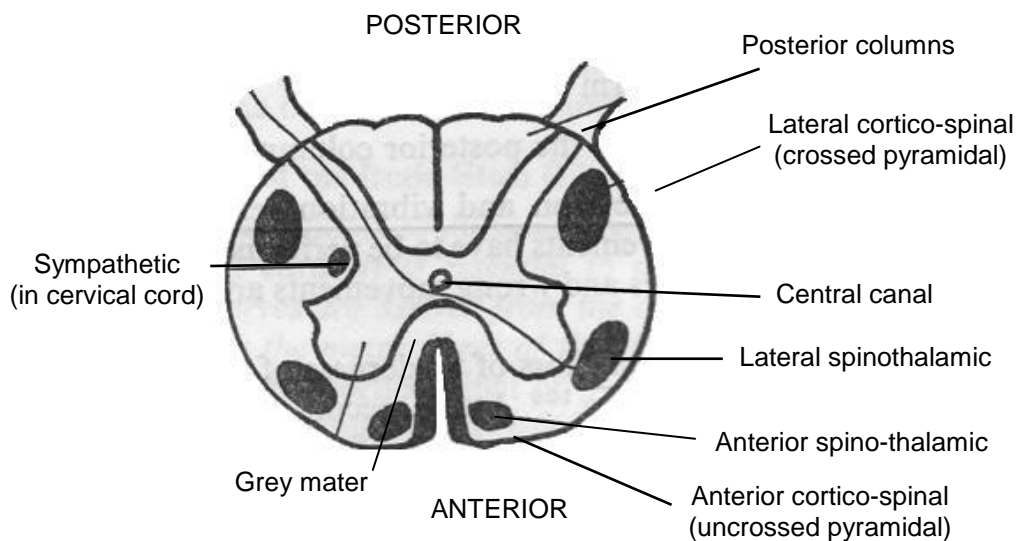




Cross-section of the medulla showing the position of the important tracts.

Adapted from: Davey P. *Wiley-Blackwell* 2006, page 247.

- The lateral spinothalamic (pain and temperature), which continues through the medulla as the lateral spinothalamic tract and then also joins the medial lemniscus in the pons.



Adapted from: Davey P. *Wiley-Blackwell* 2006, page 243.



- Translational Neuroanatomy

What are the sites and causes of a bilateral pyramidal lesion of both lower legs?

➤ Sites

- Lesion of cord
- Bilateral parasagittal cortical lesion

➤ Causes crucial dominance

- Parasagittal meningioma
- Sagittal sinus thrombosis
- Subdural hematoma
- Thrombosis of both anterior cerebral arteries

SO YOU WANT TO BE A NEUROLOGIST!

Q1. What is Benedikt's syndrome?

- A1.
- Cerebellar signs on the side opposite the third nerve palsy (which is produced by damage to the nucleus itself or to the nerve fascicle).
 - Due to a midbrain vascular lesion causing damage to the red nucleus, interrupting the dentatorubrothalamic tract from the opposite cerebellum.

Q2. Name the three parts of the cerebellum, and perform a focused physical examination to distinguish which part is causing the ataxia.

- A2.
- Paleocerebellum - Gait ataxia (inability to do tandem walking): anterior lobe
 - Archicerebellum - Truncal ataxia (drunken gait, titubation): flocculonodular or posterior lobe
 - Neocerebellum - Limb ataxia, especially upper limbs and hyponia: lateral lobes

Source: Baliga RR. *Saunders/Elsevier* 2007, page 145.



- Perform a focused physical examination for the cerebellum.

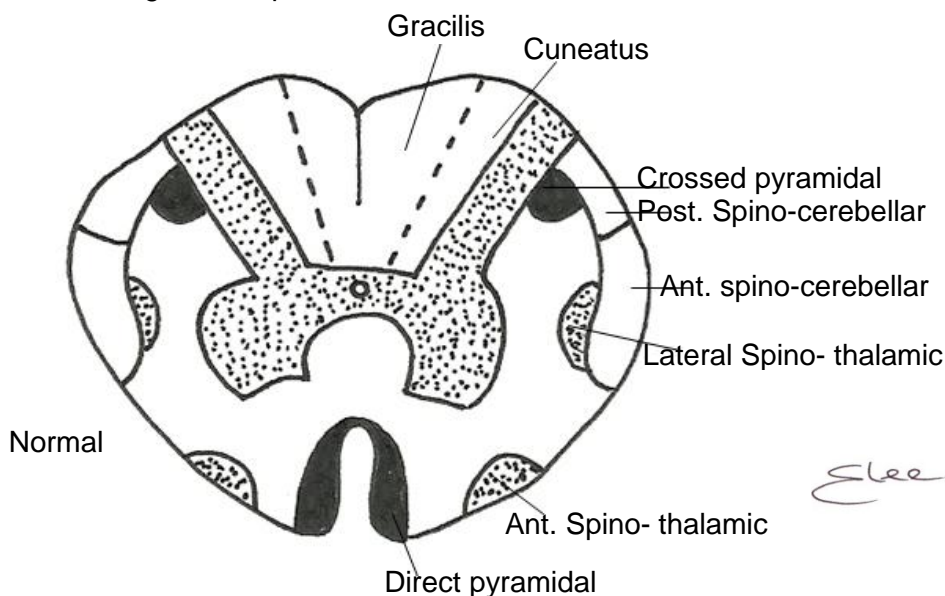
- NYSTAGMUS (75%)
 - The cerebellum receives afferents from the vestibular nuclei, spinal cord and cerebral cortex via the pontine nuclei
- SPEECH
 - Dysarthria (say “British Constitution”)
 - Scanning dysarthria: a halting, jerking dysarthria which is usually a feature of bilateral lesions
- LIMB ATAXIA
 - Dysmetria (~ 75%)
 - Intention tremor (29%)
 - Hypotonia
 - Dysdiadochokinesia (~ 50%)
 - Arm drift (~ 50%)
 - Rebound
- INTENTION TREMOR (29%)
- FINGER – NOSE TEST
- DYSDIADOCHOKINESIS REBOUND (50%)
 - Rebound phenomenon – inability to arrest strong contraction on sudden removal resistance. This is known as Holmes’ rebound phenomenon
 - Intention tremor
 - Dysdiadochokinesia – impairment of rapid alternating movements (clumsy)
- LEG Tone
- KNEE JERKS
 - Pendular
 - Reduced / absent
- GAIT & BALANCE (90%)
 - Balance
 - Rhomberg’s test, Pull test
 - Gait – Normal gait, Toe walking, Heel walking, Tandem gait, Ataxia
 - Dyssynergia – movements involving more than one joint are broken into parts
 - Lack of co-ordination of gait – patient tends to fall towards the side of the lesion
- HEEL – SHIN TEST
- GROSS AND FINE MOTOR INCO-ORDINATION
 - Lack of finger – nose coordination (past-pointing): movement is imprecise in force, direction and distance – dysmetria

Adapted from: Jugovic PJ, et al. *Saunders/ Elsevier* 2004, page 165; Talley NJ, et al. *Maclennan & Petty Pty Limited* 2003, page 431; McGee SR. *Saunders/Elsevier* 2007, Table 61.1, page 198; Baliga RR. *Saunders/Elsevier* 2007, pages 143 and 124.



Spinal cord

Useful background: Spinal cord - Transverse section



Adapted from: Burton JL. *Churchill Livingstone* 1971, page 83.

- Perform a focused physical examination to determine the site of a spinal cord and nerve root lesions

| Site | Signs and symptoms of disorders |
|---|--|
| <ul style="list-style-type: none"> ➤ Supratentorial <ul style="list-style-type: none"> ○ Cerebral hemispheres ○ Intracranial portions of CN I and CN II | <ul style="list-style-type: none"> ○ Defects in vision, olfaction, language, cognition, memory, emotions, autonomic control ○ Motor and /or sensory deficits on contralateral side of head and body ○ Symptoms of increased intracranial pressure |
| <ul style="list-style-type: none"> ➤ Infratentorial <ul style="list-style-type: none"> ○ Midbrain ○ Pons ○ Medulla ○ Cerebellum ○ Intracranial portions of CN III and CN XII | <ul style="list-style-type: none"> ○ Ipsilateral head signs ○ Contralateral signs below neck |
| <ul style="list-style-type: none"> ➤ Spinal cord or Intraspinial portions of spinal nerves | <ul style="list-style-type: none"> ○ Frequently bilateral Motor, sensory, and autonomic defects at and below the level of the lesion |



| Site | Signs and symptoms of disorders |
|---|--|
| ➤ Cranial, autonomic, and spinal nerves outside cranium and vertebral canal | <ul style="list-style-type: none"> ○ Motor, sensory, and autonomic defects in the innervated segments ○ Asymmetric lesions confined to one or a few segments |

Adapted from: Filate W., et al. *The Medical Society, Faculty of Medicine, University of Toronto, 2005*, page 154.

Useful background:

- Spinal pathways
 - The sensations of pain and vibration enter the posterior nerve tracts, to cells in the posterior horn in the posterior column, and terminate in the nucleus gracilis and cuneatus
 - From these nuclei are derived the deep arcuate fibers, which cross the midline to form the sensory decussation
 - In the medulla the sensory decussation is continued upwards as the medial lemniscus, which at this level is not yet split
 - In the pons the medial lemniscus divides into right and left parts, and is joined by the lateral spinothalamic tract
 - This continues through the midbrain into the posterior limb of the interval capsule, and terminates mainly in the thalamus.

Adapted from: Davies IJT. *Lloyd-Luke (medical books) LTD 1972*, page 244.

- Lesions involving various sensory modalities

| Location of lesion | Distribution of sensory loss |
|---------------------------------|---|
| ➤ Cortical (parietal) | <ul style="list-style-type: none"> ○ Able to recognize all primary modalities but localizes them poorly; loss of secondary modalities |
| ➤ Thalamic sensory pathway loss | <ul style="list-style-type: none"> ○ Contralateral hemisensory loss all modalities (face, body) and pain ○ Dysesthesia (eg burning feeling) |
| ➤ Brainstem | <ul style="list-style-type: none"> ○ Ipsilateral face ○ Pain and temperature ○ Contralateral body |
| ➤ Spinal cord | <ul style="list-style-type: none"> ○ Depends on level of lesion and complete vs. partial lesion |
| ➤ Root or roots | <ul style="list-style-type: none"> ○ Confined to single root or roots in close proximity ○ Commonly C5,6,7 in arm and L4,5, S1 in leg |
| ➤ Peripheral nerve | <ul style="list-style-type: none"> ○ Distal "glove and stocking" deficit |



| Location of lesion | Distribution of sensory loss |
|--------------------|------------------------------|
|--------------------|------------------------------|

- Single nerve
 - Within distribution of single nerve; commonly median, ulnar, peroneal, lateral cutaneous nerve

Adapted from: Filate W, et al. *The Medical Society, Faculty of Medicine, University of Toronto* 2005, Table 16, page 168.

Useful background: Spinal cord disorders

- Paraplegia or quadriplegia due to complete transverse lesions
- Effect depends on level (e.g. C1-C3: death from respiratory paralysis)
- Two stages:
 - Two stages:
 - Loss of all reflex activity below level of lesion
 - Atonic bladder/bowel with overflow incontinence
 - Gastric dilatation
 - Loss of vasomotor control
 - Heightened reflex activity
 - Hyperactive tendon reflex
 - Frequency and urgency of urination, automatic emptying of bladder
 - Hyperactive vasomotor and sweating reactions
- Central cord syndrome
 - Occurs more often in older people or in patients with cervical spondylosis
 - Weakened hands with impaired pain sensation (most prominent symptom)
- Relatively little long tract signs
- Anterior cord syndrome
 - Caused by infarction in anterior spinal artery territory or tumor invasion or inflammatory myelitis in similar region
 - Paraplegia or quadriplegia
 - Bilateral loss of pain and temperature sensation below the lesion
 - Sparing of posterior column (joint position and vibration) sense
- Conus Medullaris and Cauda Equina syndrome
 - Pain localized to the low back
 - Severe radicular pain in the legs
 - Loss of bladder and bowel control
 - Laxity of the anal sphincter
 - Erectile dysfunction
 - Loss of sensation in sacral segments (saddle parathesia)
 - Often asymmetric leg weakness with upper and lower motor neuron signs



- Spinal cord syndromes
 - Motor
 - Atrophy and areflexia of the arms
 - UMN lesion of legs
 - Sensory
 - Loss of pain and temperature over neck, shoulders and arms
- Subacute combined degeneration
 - Motor
 - UMN signs in both lower limbs
 - Sensory
 - Bilateral posterior column
 - Bilateral loss of position and vibration with ataxic gait
 - Rarely, peripheral sensory neuropathy
 - Reflexes
 - Ankle reflexes absent
 - Knee reflexes either absent, or exaggerated
 - Dementia
 - Optic atrophy

Abbreviations: UMN, upper motor neuron

Adapted from: Mangione S. *Hanley & Belfus* 2000, page 418; Filate W, et al. *The Medical Society, Faculty of Medicine, University of Toronto* 2005, page 175; Talley NJ, et al. *Maclennan & Petty Pty Limited* 2003, pages 422-423, and McGee SR. *Saunders/Elsevier* 2007, pages 175 and 749.

SO YOU WANT TO BE A NEUROLOGIST!

Q. In the context of a crossed hemiplegia, what is the Weber, Millard and Foville syndrome?

- A.
- Weber's syndrome: ipsilateral lower motor neurone lesion of the oculomotor nerve with contralateral hemiplegia.
 - Millard Gubler syndrome: lower motor neurone lesion of the abducens nerve which supplies the lateral rectus and contralateral hemiplegia.
 - Foville's syndrome: in which there is a hemiplegia with paralysis of conjugate deviation towards the side of the lesion, i.e. the eyes are fixed towards the weak side; in a hemiplegia due to a lesion in the internal capsule, the eyes tend to be fixed away from the weak side.
 - Hemiplegia on one side with weakness of muscles supplied by the lower cranial nerves (IX-XII) on the opposite side.

Source: Davey P, *Wiley-Blackwell* 2006, page 246.



- Perform a focused physical examination to localize a spinal cord lesion to a specific lumbar or sacral nerve root level.
 - 5th lumbar root level
 - Muscular weakness: hamstring, peroneus longus, extensors of all the toes
 - Deep tendon reflexes affected: none
 - Radicular pain/paraesthesia: buttock, posteolateral thigh, anterolaeral leg, dorsum of foot
 - Superficial sensory deficit: dorsum of the foot and anterolateral aspect of the leg
 - 1st sacral root level
 - Muscular weakness: plantar flexors, extensor digitorum bevis, peroneus longus, hamstrings
 - Deep tendon reflexes affected: ankle jerk
 - Radicular pain/paraesthesia: buttock, back of thigh, calf and lateral border of the foot
 - Superficial sensory deficit: lateral border of the foot
 - Lower sacral root level
 - Muscular weakness: none
 - Deep tendon reflexes affected: none (but anal reflex impaired)
 - Radicular pain/paraesthesia: buttock and back of thigh
 - Superficial sensory deficit: saddle and perianal areas

Adapted from: Mangione S. *Hanley & Belfus* 2000, page 418; Filate W, et al. *The Medical Society, Faculty of Medicine, University of Toronto* 2005 , page 175; Talley NJ, et al. *Maclennan & Petty Pty Limited* 2003 pages 422-423; McGee SR. *Saunders/Elsevier* 2007, page 749; Burton JL. *Churchill Livingstone* 1971, page 83.

- Perform a focused physical examination to distinguish between total spinal cord transection or incomplete cord compression.

| Physical finding | Total cord transection | Incomplete cord compression |
|------------------------------|--|--|
| ➤ Paraplegia in flexion | + | + |
| ➤ Paralysis | Symmetric | Asymmetrical |
| ➤ Flexor – withdrawal reflex | + without return (withdrawal phase only) | + with return to original position |
| ➤ Other | Vasomotor and sphincter changes | Variable area of anaesthesia which is not consistent with motor loss |

Source: Baliga RR. *Saunders/Elsevier* 2007, page 17.



Useful background: Causes of dissociated sensory loss of only the spinothalamic tract or the dorsal column.

| Only spinothalamic tract loss | Only dorsal column loss |
|---|--|
| ➤ Brown-Séquard syndrome (contralateral leg) | ○ Brown-Séquard syndrome (ipsilateral leg) |
| ➤ Syringomyelia | ○ Subacute combined degeneration |
| ➤ Anterior spinal artery thrombosis | ○ Spinocerebellar degeneration (Friedreich's ataxia) |
| ➤ Diabetes | ○ Multiple sclerosis |
| ➤ Amyloid | ○ Tabes dorsalis |
| ➤ Lateral medullary syndrome (contra-lateral signs) | ○ Diabetes
○ Hypothyroidism
○ Dorsal root ganglionopathy (cancer, Sjögren's syndrome, diabetes mellitus) |

Adapted from: Talley NJ, et al. *MacLennan & Petty Pty Limited* 2003, page 424.

Useful background: Cervical spine movements and their respective myotomes

| Movement | Myotome |
|---|---------|
| ➤ Neck flexion | |
| ○ Forward | C1-C2 |
| ○ Sideways | C3 |
| ➤ Shoulder | |
| ○ Elevation | C4 |
| ○ Abduction | C5 |
| ➤ Elbow | |
| ○ Flexion and/or wrist extension | C5 |
| ○ Extension and/or wrist flexion | C7 |
| ➤ Thumb | |
| ○ Extension and/or ulnar deviation | C8 |
| ○ Abduction and/or adduction of hand intrinsics | T1 |

Adapted from: Filate W, et al. *The Medical Society, Faculty of Medicine, University of Toronto* 2005, page 138.



Useful background: Muscle groups to test (myotomal distribution)

| Muscle | Movement | Nerve | Spinal |
|----------------------------|--------------------------|----------------------|-----------|
| ➤ Deltoid | Arm abduction | Axillary | C5, 6 |
| ➤ Triceps | Elbow extension | Radial | C6, 7, 8 |
| ➤ Biceps | Elbow flexion | Musculocutaneous | C5, 6 |
| ➤ Wrist extensors | Wrist extension | Radial | C7, 8 |
| ➤ Flexor pollicis longus | Thumb IP flexion | Median | C6, 7 |
| ➤ Interossei of hand | Fingers ab/adduction | Ulnar | C8, T1 |
| ➤ Iliopsoas | Hip flexion | Femoral | L1, 2, 3 |
| ➤ Hip adductors | Hip adduction | Obturator | L2, 3, 4 |
| ➤ Hip abductors | Hip abduction | Superior gluteal | L4, 5, S1 |
| ➤ Quadriceps | Knee extension | Femoral | L2, 3, 4 |
| ➤ Hamstrings | Knee flexion | Sciatic | L5, S1, 2 |
| ➤ Tibialis anterior | Ankle dorsiflexion | Deep peroneal | L4, 5 |
| ➤ Gastrocnemius, soleus | Ankle plantar flexion | Tibial | S1, 2 |
| ➤ Extensor hallucis longus | Great toe dorsiflexion | Deep peroneal | L5, S1 |
| ➤ Tibialis | Posterior foot inversion | Posterior tibial | L4, L5 |
| ➤ Peroneus longus, brevis | Foot eversion | Superficial peroneal | L5, S1 |

Printed with permission: Filate W, et al. *The Medical Society, Faculty of Medicine, University of Toronto* 2005, page 164; Source: Davey P. *Wiley-Blackwell* 2006, page 250.

Useful background: Nerve root lesions

- Nerve root lesions are indicated by sharp, lancinating pain with a dermatomal or myotomal pattern.
- Pain is increased by sneezing and coughing.
- Pain often has a dermatomal pattern.
- Findings are weakness, sensory impairment, and decreased muscle stretch reflexes.



- Radiculopathies have many causes.
- Surgery is considered for increasing weakness, bowel or bladder dysfunction, or intractable pain with an appropriate lesion seen on MRI.

Source: Ghosh AK. *Mayo Clinic Scientific Press*, 2008, page 765.

- Perform a focused physical examination of site in the spinal cord for loss of sensation.

| Tracts | Sensation |
|--------------------------|---|
| ➤ Posterior column | <ul style="list-style-type: none"> ○ Position (proprioception) – ataxia (with eyes closed, aka “Rombergism”) ○ Vibration ○ Deep pain ○ Some light touch |
| ➤ Anterior spinothalamic | <ul style="list-style-type: none"> ○ Light touch |
| ➤ Lateral spinothalamic | <ul style="list-style-type: none"> ○ Superficial pain ○ Temperature ○ Tickle ○ “sex” |
| ➤ Spinocerebellar | <ul style="list-style-type: none"> ○ Tone and co-ordination of muscle - ↓ deep tendon reflexes [DTR]* |

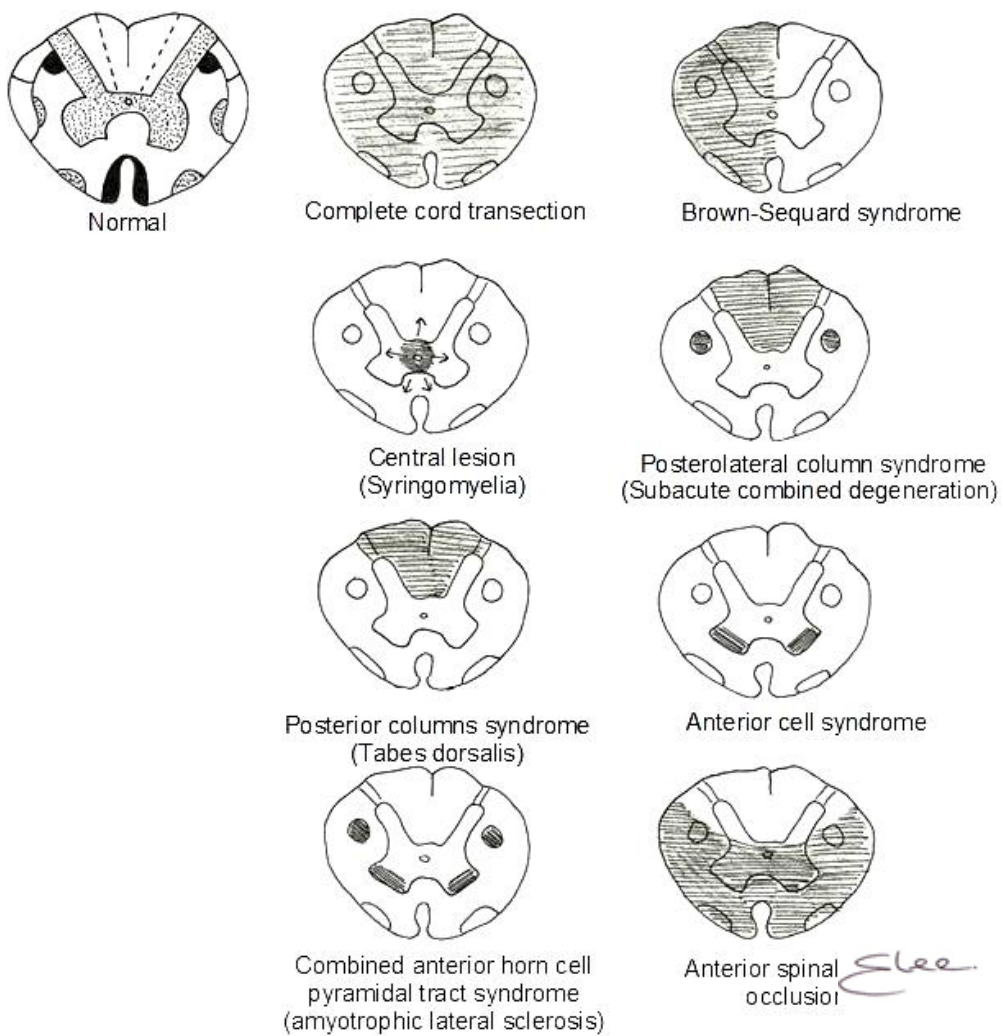
* The stretch reflex is a proprioceptive reflex, so when the stretch sensory stimulus is reduced in posterior column disease, the DTRs are reduced

Source: Davies IJT. *Lloyd-Luke (medical books) LTD* 1972, Figure 12, page 243.

When originality may not be genuine, Check it on
“Turn it in.com”, even Deans deviate.
Grandad



Useful background: Spinal cord syndromes



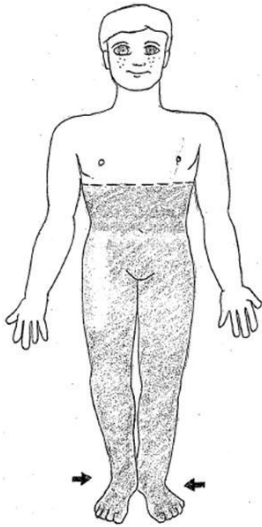
Adapted from: Talley NJ, et al. *Maclennan & Petty Pty Limited* 2003, Figure. 10-52, page 423.

"It is simple to simplify complex issues."

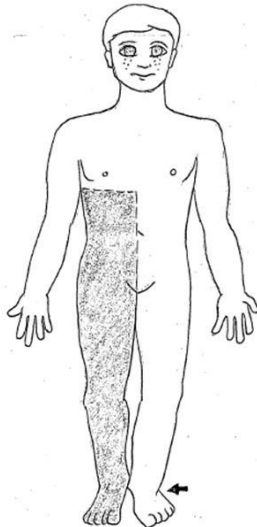
Grandad



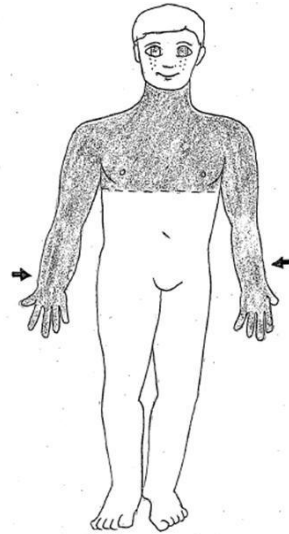
- Perform a focused physical examination to detect the following sensory syndromes.



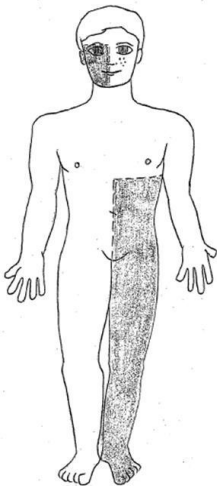
Complete spinal cord injury and anterior cord syndrome



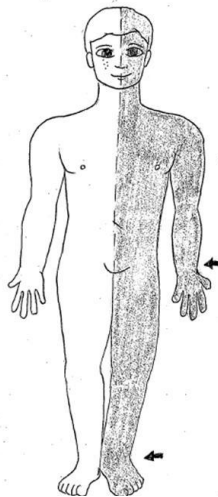
Brown-Sequard syndrome



Central cord syndrome (syringomyelia)



Brainstem injury



Thalamic or cerebral hemisphere injury

EH

Adapted from: McGee SR. *Saunders/Elsevier* 2007, Figure 58-2, pages 746 to 747.



- Perform a focused physical examination for the causes and site of spinal cord compression.
- Intra-medullary
 - Neoplasm
 - Cyst
 - Hematomyelia
- Intra-dural extra-medullary
 - Arachnoiditis
 - Cyst
- Meninges, dura
 - Neoplasm (Meningioma, neurofibroma, metastatic Ca)
 - Hodgkin's leukemic infiltrate
 - Abscess
 - Cyst
 - Epidural abscess
 - Arachnoiditis
 - Leptomeningitis
 - Meningioma
 - Neurofibroma
 - Lymphoma
 - Leukemia
- Vertebral column
 - Congenital bone anomaly
 - Trauma
 - Vertebral collapse
 - Disc prolapse, spondylolisthesis, spondylosis
 - Neoplasm (primary or secondary) –glioma, ependymoma, 2°
 - Infection – TB or pyogenic
 - Crush #
 - Disc protrusion
 - Tumour
 - Myeloma
 - TB
 - Cervical spondylosis
 - Paget's disease

Adapted from: Burton JL. *Churchill Livingstone* 1971, page 83.



Nerve Entrapment syndromes

Cervical Spondylosis

- Disc protrusion – formation of osteophytes
- Disc calcification – osteoarthritis
- Translational Neuroanatomy
 - The intervertebral discs are anterior to the spinal cord
 - These discs herniate laterally where the herniate disc affects the roots (pyramidal tracts)
 - Usually a herniated disc affects motor roots more than sensory, except in the cerebral region
 - Cervical formation may narrow the canal carrying vertebra-basilar ischemia

Prolapsed Vertebral Disc

Useful background

- Distribution prevalence
 - L5-S1 disk (s1 nerve root), 60%
 - L4-5 disk (L5 nerve root), 30%
 - L4-5 plus L5-S1 disks combined, 10%
- Source of pain from prolapsed vertebral disc
 - Acute
 - Tear of annular fibrosis
 - Protrusion of nucleus pulposus
 - Chronic
 - Stretching of posterior longitudinal ligament of the spine
 - Reflex protection spasm of erector spinae muscle
 - Acute/chronic
 - Pressure on the nerve root
 - Pain along nerve
 - Tender nerve
 - Pain in muscles supplied by the nerve (myotome; eg, biceps femoris, gastrocnemius, tibialis anterior)
- Perform a focused physical examination for a protrended intervertebral disc.
- LMN weakness
 - L5-S1
 - Glutei



- Extension of thigh – gluteus (G) maximus
 - Abductors of thigh – G. medius and G. minimus
- Biceps femoris
 - Flexion of knee
- Peronei
 - Eversion of foot
- L4-L5
 - Dorsiflexors of the foot
 - “extensor” muscles
 - Tibialis anterior
- S1-S2
 - Plantar flexors of foot
 - Gastrocnemius
 - Soleus
 - Small muscle of foot
 - Ask the patient shape the sole of the foot into a cup
- Loss of deep tendon reflexes
 - Angle –S1
- Lumbar spine
 - ↓ movement
 - Loss of normal lumbar lordosis
 - Scoliosis
 - Tenderness
- Glutei
 - Unilateral drooping of buttock
- Sciatic nerve
 - Tenderness with pressure over sciatic nerve
- Leg
 - Reduced ability to raise a straightened leg
- Perform a focused physical examination for the cauda equina syndrome.
- Definition
 - Protrusion of disk posterior onto caudia equina, or tumor, causing unilateral or bilateral pressure on nerve below L2
 - LMN signs
 - Pressure is more likely on the lower sacral nerves than on L3-L5



- Paraplegia
 - Weak
 - Wasted
 - Flaccid
- Numbness
- Loss of reflexes
 - Ankle jerk loss, only with S1 lesions
- Disorder of sphincter control
 - Hesitancy
 - Urgency
 - Retention of urine
- Impotence
- Pain in distribution of sciatic nerve
- DRE patubus anal sphincter
- Anesthesia
 - Sacral, anal, perianal regions

Dissociated Anesthesia

- Definition (decreased pain and temperature, but return of other sensation)
- Four types of dissociated anesthesia
 - Lesion in centre of cord-dissociated anesthesia is bilateral, but not necessarily symmetrical, upper and lower border
 - Does not affect lateral spinothalamic fibers , but does affect posterior columns
 - May have involvement of pyramidal tracts
 - Causes include
 - Syringomyelia
 - Neoplasm
 - Spontaneous hematomyelia.
- Give the anatomical basis of the diseases that cause dissociated anaesthesia.
- Definition: dissociated anaesthesia is the loss of pain and temperature, but the retention of other sensory modalities.
- Anatomy
- Types of dissociated anaesthesia
 - Lesion in centre of spinal cord



- Bilateral, but not necessarily symmetrical dissociated anaesthesia
 - Upper and lower border to loss of pain and temperature.
 - Affects posterior columns, but not the lateral spinothalamic fibers.
 - May be associated with involvement of pyramidal tracts and anterior horn cells.
 - Common causes
 - Sphingomyelia
 - Spontaneous hematomyelia
 - Tumor
 - Hemisection of spinal cord (Brown – Sequard syndrome)
 - Dissociated anaesthesia
 - Ipsilateral LMN and posterior column changes at level of lesion.
 - Below lesion
 - UMN changes
 - Contralateral spinothalamic sensory changes
 - Common causes
 - Compression of cord
 - Intramedullary neoplasm (especially ependymoma)
 - Lesion of anterior half of cord
 - Transient dissociated anaesthesia
 - At level of lesion
 - LMN changes
 - Below lesion
 - UMN changes
 - Spinothalamic sensory changes
 - Common cause
 - Thrombosis of anterior spinal artery
 - Lesion of lateral medulla
 - Dissociated anaesthesia of all of the opposite side of the body
 - Common causes
- Perform a focused physical examination to distinguish between the cauda equina syndrome (please see above), and the cauda equina claudication syndrome (see below).
 - The features of the cauda equina claudication syndrome are
 - Exercise aggravated and rest relieved
 - Bilateral
 - Pain
 - Tingling
 - Weak foot dorsiflexors
 - Reflex changes

Source: Davies IJT. *Lloyd-Luke (medical books) LTD* 1972, page 292.



- Hemisection of cord (Brown-Séquard syndrome)
 - Ipsilateral LMN and posterior column, UMN lesion below level of lesion
 - Contralateral spinothalamic below lesion
 - Causes include:
 - Compression of spinal cord
 - Intramedullary neoplasm (ependymoma).
 - Anterior half of cord
 - The dissociated anaesthesia is always a transient phenomenon
 - LMN at site, bilateral UMN below lesion, spinothalamic below
 - Only common cause is anterior spinal artery thrombosis.
 - Lesions in lateral medulla-will affect whole of opposite side of body
- Post column lesion (first sensory neuron)
- Decreased pain and vibration sensation
 - Decreased reflexes
 - Ataxia
 - Hypotonicity
 - Astereognosis
 - Ataxia with eyes closed
 - The patient walks looking at their feet
 - There is Rombergism-steady when standing with feet together and eyes open, becomes unsteady when eyes are closed.

Adapted from: Davies IJT. *Lloyd-Luke (medical books) LTD* 1972, pages 244 to 245.

Cervical Rib (scalenus anterior) entrapment syndrome

- Cause
- Compression of subclavian artery between first rib and clavicle
- Clinical
- Rarely affects T1
 - Vascular symptoms, as in cervical rib syndrome, above
 - Signs in radial pulse
 - Loss of radial pulse, especially when pulling clavical over subclavian artery, such as throwing shoulders backwards
- Perform a focused physical examination for causes of spastic paresis.
- Inherited
- Friedreich's ataxia.
 - Familial spastic paraplegia



- Infection
 - HIV
 - Tabes dorsalis
 - Transverse myelitis (involves all tracts of spinal cord; spastic or flaccid paralysis; may be incomplete cord compression or total cord transection)
- Infiltration
 - Spinal cord tumor (meningioma, neuroma)
 - Metastatic carcinoma
 - Parasagittal falx meningioma
- Degeneration
 - Motor neuron disease
 - Syringomyelia
 - Osteoarthritis of the cervical spine
- Nutritional
 - Vitamin deficiency
 - Subacute combined degeneration of the cord (associated peripheral neuropathy)
- Vascular
 - Anterior spinal artery thrombosis
 - Atherosclerosis of spinal cord vasculature
- Trauma

Adapted from: Baliga RR. *Saunders/Elsevier* 2007, page 116.

- Take a directed history and perform a focused physical examination for tabes dorsalis.
- History
- CNS
 - Ataxia
- Eyes
 - Diplopia or ↓ vision
- Voice – crisis: laryngeal
 - Visceral crises
 - Gastric
 - Rectal

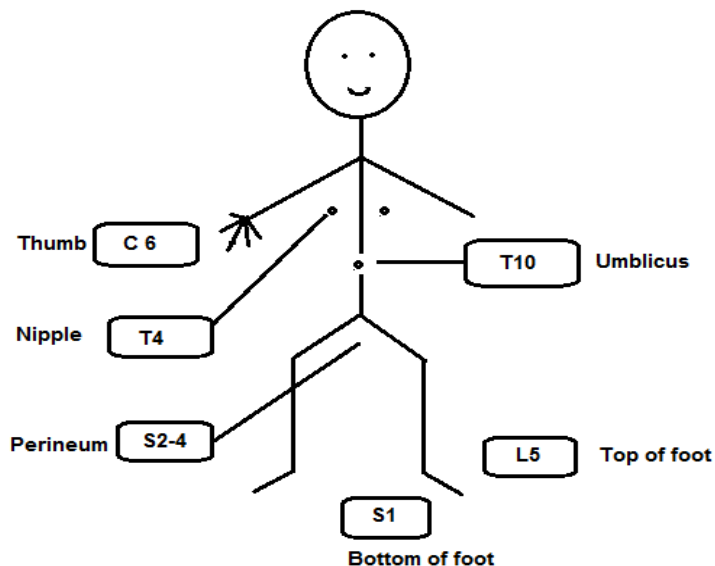


- GI
 - Loss of sphincter control
- GU
 - Impotence
- MSK
 - Paresthesia, especially in feet
 - Lightning pains
- Physical examination
- Face
 - Tabetic facies
- Eyes
 - Ptosis
 - Argyll Robertson pupils
 - Optic atrophy, etc.
- Muscles
 - Hypotonia
- Densation
 - ↓ proprioception and vibration sense, with Rombergism and ataxic gait
 - ↓ superficial and deep pain sensation
- Reflexes
 - ↓ tendon reflexes (ankles affected first)
- MSK
 - Charcot joints
- Skin
 - Neuropathic ulcers

Adapted from: Burton JL. *Churchill Livingstone* 1971, page 89.

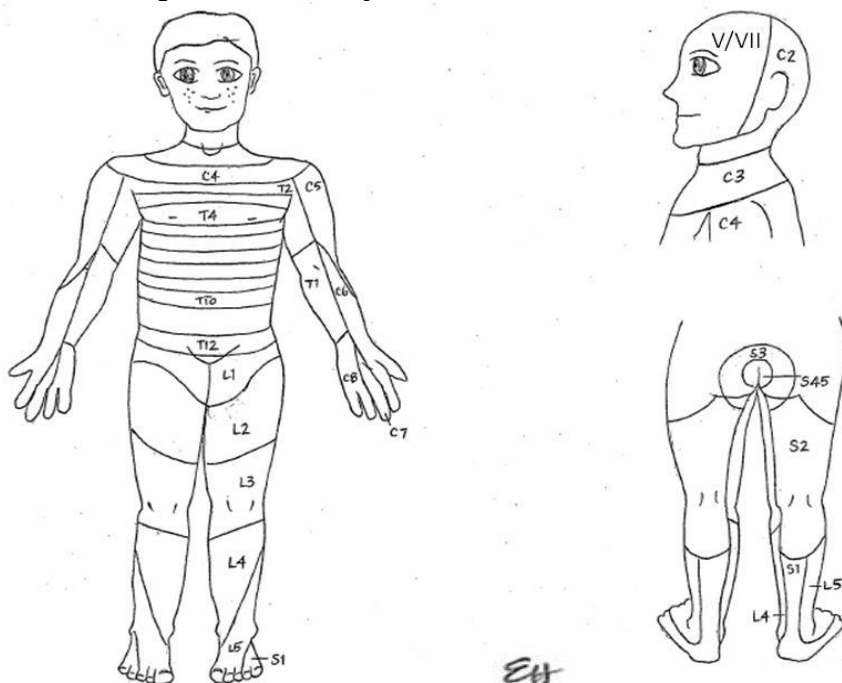


- Know the dermatomes



Source: Mangione S. *Hanley & Belfus* 2000,

Useful background: **Sensory dermatomes**



Adapted from: Filate W, et al. *The Medical Society, Faculty of Medicine, University of Toronto* 2005, Figure 1, page 155.

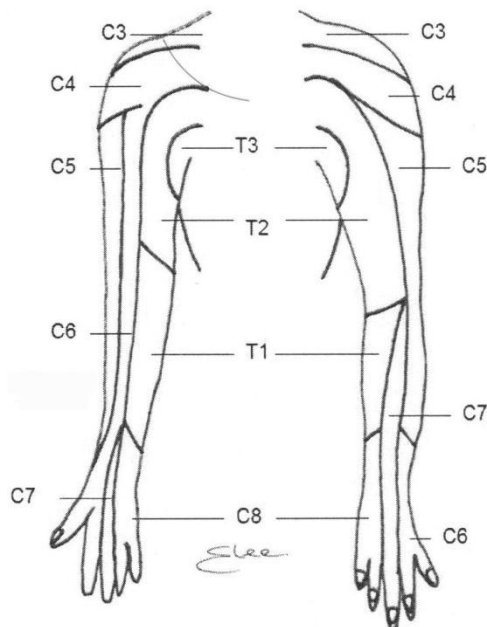


- Perform a focused physical examination to determine the nerve roots involved in spinal cord disease (sensory dermatomes).

➤ Dermatomes in the upper limb

Causes of wasting of small muscles of hand

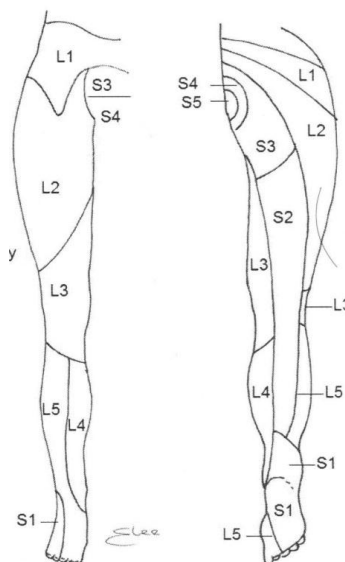
- Cord lesions at C8, T1 level
- Motor neurone disease
- Tumor
- Syringomyelia
- Meningo-vascular
- Syphilis
- Cord compression
- Root lesions
- Cervical Spondylosis
- Neurofibroma, etc
- Brachial plexus lesions
- Klumpke paralysis
- Cervical rib, etc
- Ulnar or median nerve lesions
- Arthritis of hand or wrist, or disuse atrophy



➤ Dermatome of the lower limb

Type of carcinomatous neuropathy

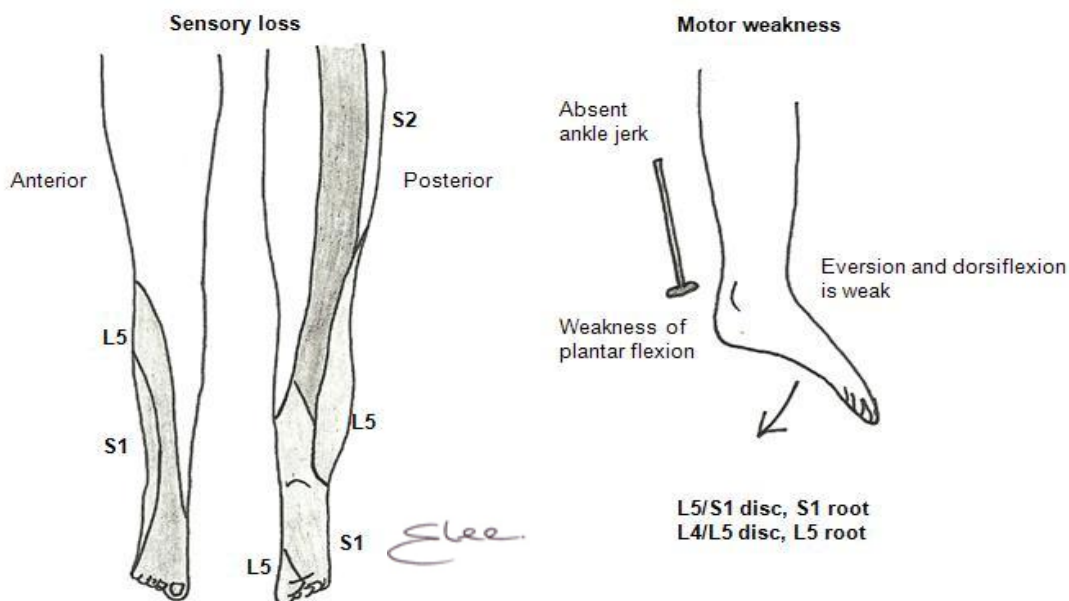
- Dementia
- Encephalomyelitis
- Cerebellum xx
- Cord-bone, xx, cord itself
- Neuropathy
- Myopathy, xx, xx
- Myasthenia syndrome



Adapted from: Burton JL. *Churchill Livingstone* 1971, page 86-87; McGee SR. *Saunders/Elsevier* 2007, page 743.

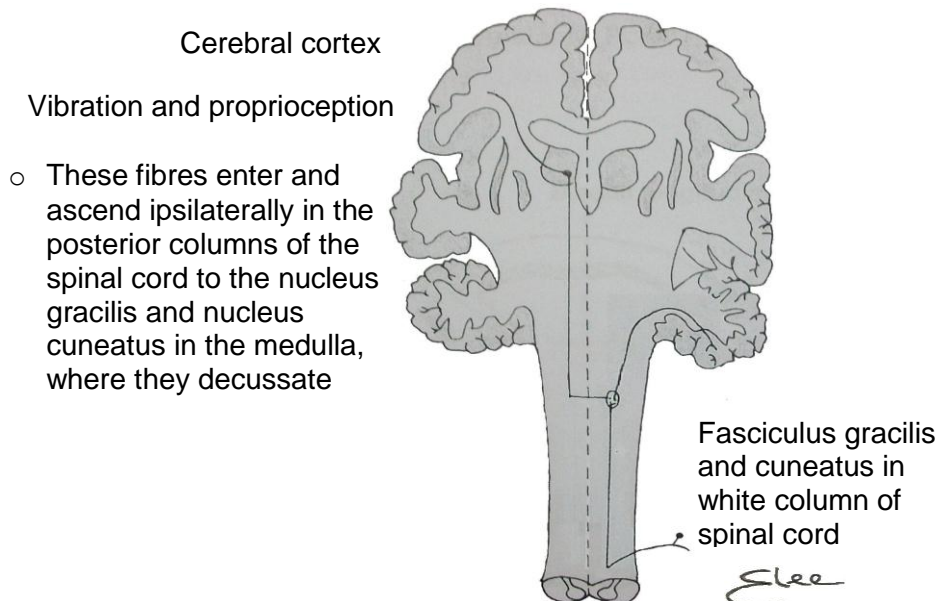


Useful background: Nerve compression at the lumbosacral spine



Damage to the fibers from a single nerve root (radiculopathy) will cause sensory loss to the cutaneous area supplied by this nerve (aka dermatome)

- **Posterior columns:** vibration and joint position sense pathways



Adapted from: Talley NJ, et al. *MacLennan & Petty Pty Limited* 2003, Figure 10.35, page 399.



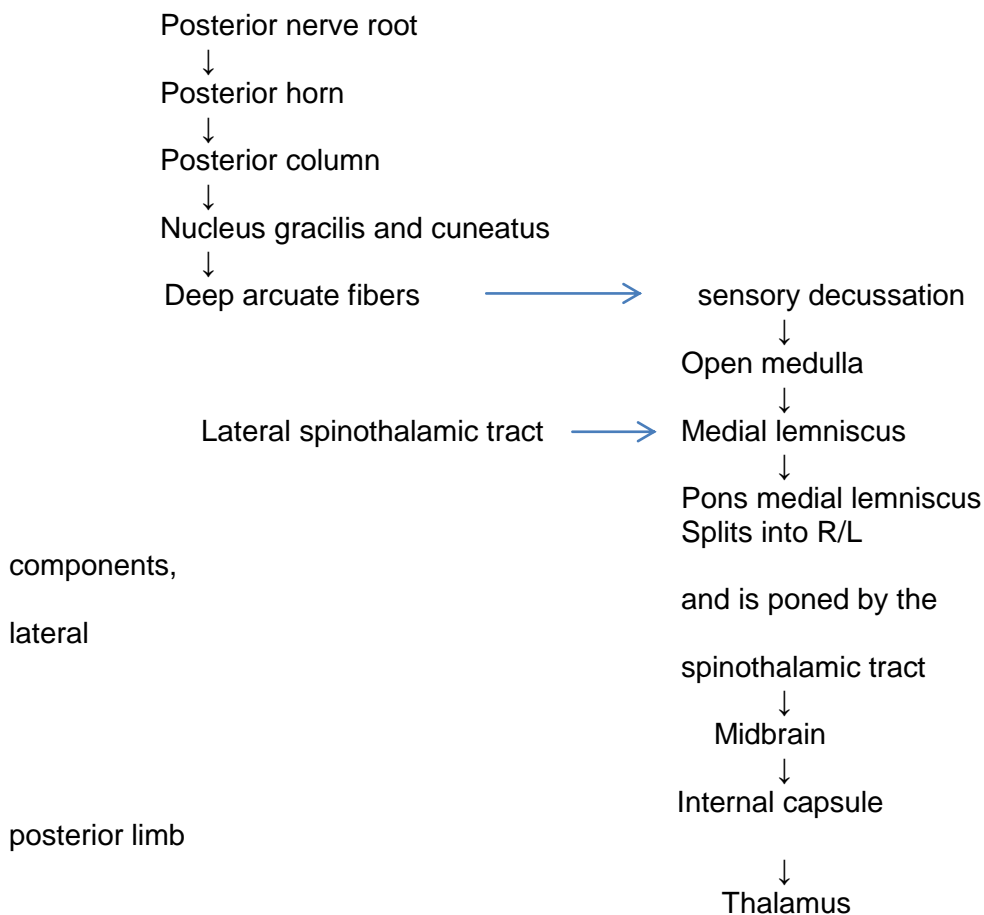
- Take a directed history and perform a focused physical examination for Guillain Barre syndrome (GBS).
 - History
 - Weakness: difficulty in rising up from sitting position or climbing stair; legs usually affected before upper limbs
 - Dyspnea (late in the course of GBS, suggesting diaphragmatic and intercostals muscle weakness)
 - Cranial nerve involvement:
 - Diplopia
 - Drooling of saliva
 - Regurgitation of food
 - Paresthesias
 - Urinary symptoms
 - Systemic symptoms: (e.g fatigue)
 - Ascertain whether the onset was preceded by a trivial viral illness
 - Palsy (weakness)
 - Legs, progressing proximally, including cranial nerves
 - Spincters
 - Bulbar palsy
 - Respiratory muscles
 - Tender muscles
 - Sensory loss (paraesthesiae may occur as a symptom even though there are minimal signs of sensory loss)
- Peripheral Sensory Nerves
- Perform a focused physical examination for a lesion of the posterior column.
 - ↓ position and vibration sensation (AT – which side)
 - ↓ reflexes (deep tendon reflexes, DTR)
 - Ataxia with eyes closed (“Rombergism: steady when standing with feet together and eyes open, but becomes unsteady when eyes closed)
 - Patient walks looking at their feet
 - Hypotonicity
 - Astereognosis
 - Inability to appreciate the size or shape of objects which are held in the hand.

Adapted from: Baliga RR. *Saunders/Elsevier* 2007, page 243.



Useful background: Posterior column tract

➤ Position/vibration



- Perform a focused physical examination for a posterior column lesion.

➤ Sensation

- ↓ Position and vibration appreciation

➤ Reflexes

- ↓

➤ Balance

- Ataxia when eyes close
- Walking, looking at feet, to improve balance
- Rombergism

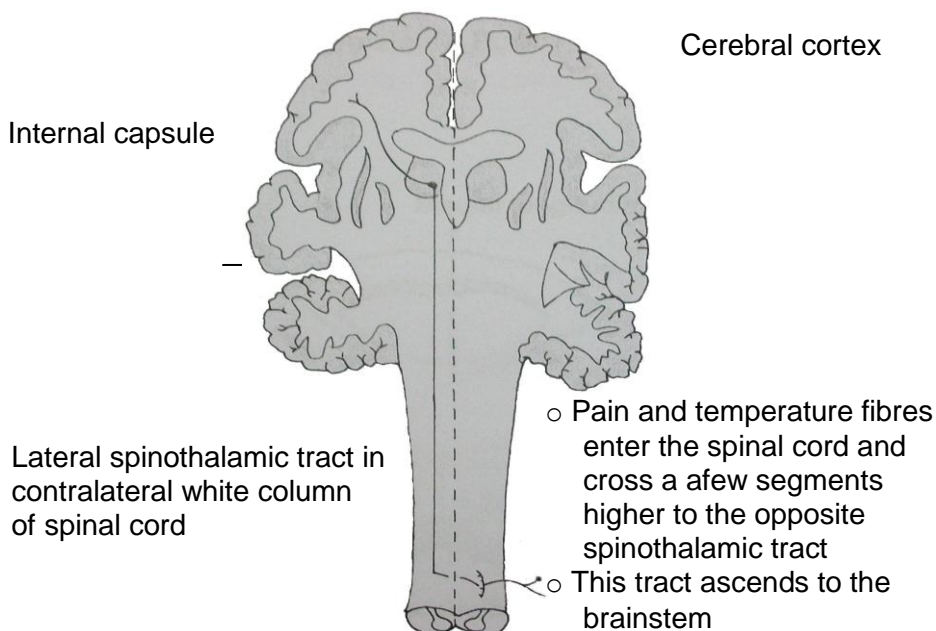


- Steady with eyes open and feet together; becomes unsteady when eyes closed

➤ **Astereognosis**

- Inability to appreciate size or shape of objects held in their hand

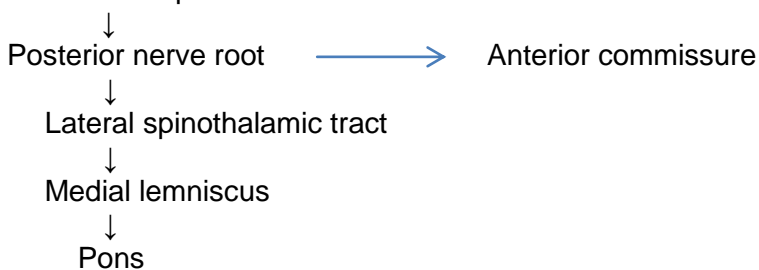
➤ **Spinal Cord: Spinothalamic (pain and temperature) pathways**



Adapted from: Talley NJ, et al. *MacLennan & Petty Pty Limited* 2003, Figure 10.34, page 398.

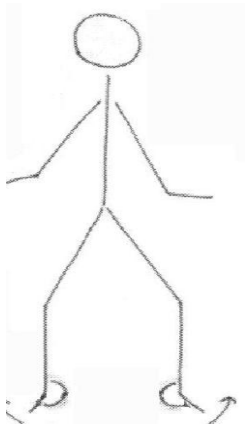
Lateral Spinothalamic Tract

➤ **Pain/temperature**



Useful background: Spinal cord disease

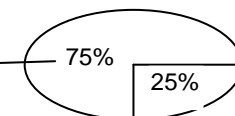
➤ Cognitive impairment



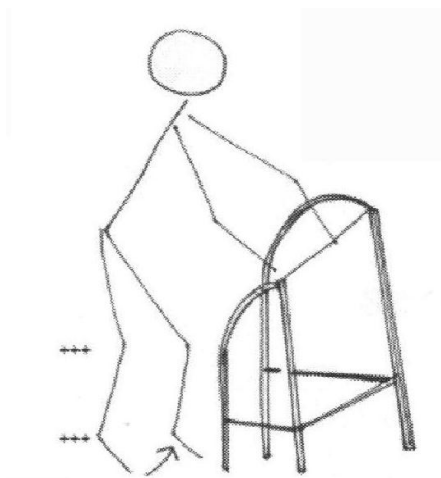
Subacute combined degeneration of the cord

- Typical sequence
 - Peripheral neuropathy = peripheral paresthesia
 - ↓
 - Column loss = sensory ataxia
 - ↓
 - Posterior Corticospinal tract damage = paraplegia
 - No ankle reflexes

- Hematological abnormality



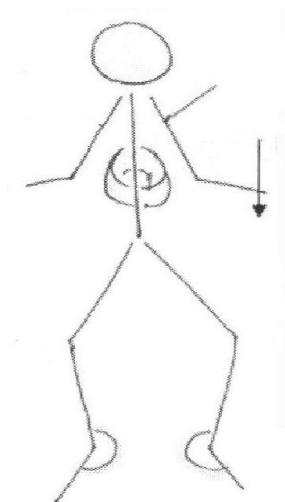
No hematological abnormalities



Cervical myelopathy

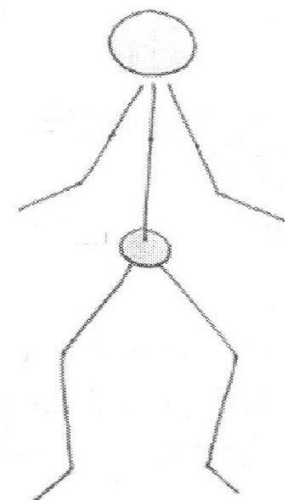
- Spastic tetraparesis progressive over several years
- Sensory symptoms less common
- Often asymmetrical





Transverse myelitis

- Acute onset
 - May relate to recent infection-‘para-infectious’
 - Commonly due to multiple sclerosis
 - Occasionally ‘band of pain’ at affected level’, flaccid paralysis



Anterior spinal artery thrombosis

- Sensory level
- Flaccid paralysis
- Urine retention
- Acute onset
 - Flaccid paraplegia
 - Normal dorsal column sensation
 - Spinal shock
 - Spasticity develops later
- Causes
 - Emboli (e.g. atrial fibrillation)
 - ‘In-situ’ thrombosis (e.g. sickle cell disease, hypercoagulable states)
 - Decompression sickness ‘the bends’

Adapted from: Davey P. *Wiley-Blackwell* 2006, page 380.

Useful background: Motor and reflex changes of spinal cord compression

- Upper cervical
 - Upper motor neurone signs in the upper and lower limbs
 - C5:
 - LMN- weakness and wasting of rhomboids, deltoids, biceps and brachioradialis
 - UMN- signs affect the rest of the upper and all the lower limbs.
 - Reflexes- Biceps reflex is lost, brachioradialis is inverted.
 - C8:
 - LMN weakness and wasting of the intrinsic muscles of the hand.



- Reflexes- UMN signs in the lower limbs.
- Midthoracic
 - Intercostal paralysis
 - UMN signs in the lower limbs
 - Reflexes-loss of upper abdominal reflexes at T7 and T8
 - T10-T11:
 - Loss of the lower abdominal reflexes and upward displacement of the umbilicus
 - UMN- signs in the lower limbs
 - L1:
 - Reflexes- Cremasteric is lost, normal abdominal reflexes
 - UMN signs in the lower limbs
 - L4:
 - LMN weakness and wasting of the quadriceps
 - Reflexes- Knee reflexes lost
 - Ankle reflexes may be hyperreflexic with extensor plantar response (up-going toes), but more often there is a lower motor neurone lesion.
 - L5-S1
 - LMN weakness of knee flexion and hip extension (S1), and abduction (L5) plus calf and foot muscles.
 - Knee present
 - No ankle reflexes or plantar responses
 - S3-S4:
 - Saddle sensory loss
 - Normal lower limbs
 - No anal reflex

*Lower motor neurone (LMN) signs may extend for several segments, and spastic paralysis occurs late, unlike the situation with extramedullary lesions.

- Causes of spinal cord compression
 - Vertebral
 - Spondylosis
 - Trauma
 - Prolapse of a disc
 - Tumour
 - Infection
 - Outside the dura
 - Lymphoma, metastases
 - Infection- e.g., abscess
 - Within the dura but extramedullary
 - Tumour – e.g. meningioma, neurofibroma



- Intramedullary*
 - Tumour- e.g. glioma, ependymoma
 - Syringomyelia
 - Haematomyelia

Abbreviations: LMN, lower motor neuron; UMN, upper motor neuron

Adapted from: Talley NJ, et al. *MacLennan & Petty Pty Limited* 2003, Table 10.26, page 421.

- Perform a focused physical examination for subacute combined degeneration of the cord.
 - Posterior column loss symmetrically (vibration and joint position sense)
 - Ataxic gait
 - Upper motor neurone signs in the lower limbs symmetrically with absent ankle reflexes; knee reflexes may be absent or, more often, exaggerated
 - Peripheral sensory neuropathy (less common and mild);
 - Optic atrophy;
 - Dementia

Source: Talley NJ, et al. *MacLennan & Petty Pty Limited* 2003, page 423.

- Perform a focused physical examination for closed spina bifida.
 - Definition
 - Incomplete closure of the bony vertebral canal
 - Is commonly associated with a similar anomaly of spinal cord
 - The commonest site is the lumbosacral reregion but the cervical spine can be involves.
 - May be associated with hydrocephalus
 - Skin
 - Lumbosacral lipoma
 - Hypertrichosis
 - Sinus or dimple above the sacrum
 - Nevus, or scarring
 - MSK
 - Unilateral shortening of one leg and foot
 - Loss of muscles below the knee
 - Calcaneovalgus or equinovarus deformity
 - Sensory loss in L5/ S1
 - GU
 - Neuropathic bladder
 - Enuresis

Adapted from: Baliga RR. *Saunders/Elsevier* 2007, page 174.



SO YOU WANT TO BE A NEUROLOGIST!

Q. In the context of spinal cord, what is paraplegia-in-flexion?

- A.
- Paraplegia-in-flexion is seen in partial transection of the cord where the limbs are involuntarily flexed at the hips and knees because the extensors are more paralysed than the flexors.
 - In complete transection of the spinal cord, the extrapyramidal tracts are also affected and hence no voluntary movement of the limb is possible, resulting in paraplegia-in-extension.

Source: Baliga RR. *Saunders/Elsevier* 2007, page 116.

SO YOU WANT TO BE A NEUROLOGIST!

Q1. In patients with syringomyelia affecting the middle of the cervical cord what is the neuroanatomical basis for the observation that the sensation of pain and, temperature is lost from only the upper part of the face, and not also from the lower face?

- A1.
- The sensory fibers of the trigeminal nerve (CN V) which carry pain and temperature enter the brainstem and descend to the level of CN III (third cervical segment)
 - From C3, the V1 fibers cross the midline, and then ascend in the lateral spinothalamic tract (LST)
 - The lowest fibers in LST supply the upper part of the face

V1 → brainstem → descend to C3 → decussate → ascend in the LST

Q2. What is the difference between syringomyelia (aka syringobulbia) and syringomyelia?

- A2.
- Hydromyelia is the expansion of the ependyma-lined central canal of the spinal cord.
 - Syringomyelia is the formation of a cleft-like cavity in the inner portion of the cord. Both these lesions are associated with



SO YOU WANT TO BE A NEUROLOGIST!

Q1. What are the commonest causes of posterior root ganglial conditions:

- A1. ➤ Diabetes
 ➤ Tabes dorsalis
 ➤ Carcinomatous neuropathy

Q2. In the context of cervical spondylosis, what is the inversion of the biceps and triceps, deep tendon reflex uses, and what is the neuroanatomic explanation for this sign?

A2. A lesion at C6 will cause a LMN lesion of the biceps muscle supplied by C5, 6, and an UMN lesion of the triceps muscle, supplied by C&. The biceps and triceps have one nerve in common, C6, stimulation of the triceps will contract briskly, in an “inverted” manner.

Q3. In the context of a prolapsed intervertebral disc, what nerve roots supply the pain which radiates to

- Lateral side of lower leg, and medial side of the foot
- Lateral side of the foot, and sole of the foot

A3. No, not L5 and S1!

- Pain from a prolapsed intervertebral disc does not radiate in the cutaneous distribution of the nerve root
- However, numbness and/or tingling (paraesthesiae) may occur along the appropriate cutaneous distribution of L5/S1

Q4. What is the triad of symptoms which suggest spinal cord disease?

- A4. ○ Sensory level, a band of sensory change around the chest or abdomen
 – or a sharp level below which sensation is lost
- Distal
 – usually symmetric weakness
 - Bowel and bladder changes

Source: Mangione S. *Hanley & Belfus* 2000, page 418.

Q5. What are the clinical features of syringobulbia?

- A5. ○ Dissociated sensory loss of the face of the ‘onion-skin’ pattern (extends behind forwards, converging on the nose and upper lip).
 ○ Vertigo (common symptom).
 ○ Wasting of the small muscles of the tongue (important physical sign).
 ○ The process may be limited to the medullary region.
 ○ The main cranial nerve nuclei involved are those of the fifth, seventh, tenth cranial nerves.



Radiculopathy and nerve roots


Useful background: Performance characteristics of a focused physical examination for cervical radiculopathy

| Finding | PLR | NLR |
|---|------|-----|
| ➤ Motor examination | | |
| ○ Weak elbow flexion (C5) | 5.3 | NS |
| ○ Weak wrist extension (C6) | 2.3 | NS |
| ○ Weak elbow extension (C7) | 4.0 | 0.4 |
| ○ Weak finger flexion [C8] | 3.8 | NS |
| ➤ Sensory examination | | |
| ○ Sensory loss thumb (C6) | 8.5 | NS |
| ○ Sensory loss affecting middle finger (C7) | | |
| ○ Sensory loss affecting little finger (C8) | 41.4 | NS |
| ➤ Reflex examination | | |
| ○ ↓ biceps or deep tendon reflex (C6) | 14.2 | 0.5 |
| ○ ↓ triceps reflex (C7) | 3.0 | NS |
| ➤ Other tests | | |
| ○ Straight leg raising manoeuvre | 1.3 | 0.3 |
| ○ Crossed straight leg raising manoeuvre | 3.4 | 0.8 |

NS, not significant; likelihood ratio (LR) if finding present= positive LR; LR if finding absent=negative LR. Findings shown in round () brackets were not associated with a significant LR +/- , and the values of their sensitivity and specificity are not provided. The nerve involved in the radiculopathy is given in square [] brackets.

Abbreviation: NLR, negative likelihood ratio; PLR, positive likelihood ratio

Adapted from: McGee SR. *Saunders/Elsevier* 2007, Box 60-2, pages 779 and 780, and Box 60-4, page 786.



- Sen N out – Sensitive test; when negative, rules ot disease
- Sp P in – Specific test; when positive, rules in disease

What is “the best”? The “best” clinical tests for lumbosacral radiculopathy include:

- Weak ankle extension and dorsiflexion
- Ipsilateral calf wasting,
- Sensory loss in area of LSS
- Asymmetric quadriceps reflex
- Positive crossed straight leg-raising maneuver

Abbreviation: LSS, lumbar spinal stenosis

Useful background: Performance characteristics for diagnosing cervical radiculopathy in patients with neck and arm pain

| Finding | PLR | NLR |
|---|-----|-----|
| ➤ Reflex examination | | |
| ○ Reduced biceps reflex | 9.1 | NS |
| ○ Reduced biceps, triceps or brachioradialis reflex | 3.6 | 0.8 |
| ➤ Other tests | | |
| ○ Spurling’s test | 3.6 | 0.7 |

Note that weakness of any arm muscle, reduced sensation in arm of , vibration or pinprick, reduced triceps reflex, ant rotation of neck to involved side ar not included because than PLR was < 2.

Abbreviation: NS, not significant; likelihood ratio (LR) if finding present= positive LR (PLR); LR if finding absent=negative LR (NLR).

Adapted from: McGee SR. *Saunders/Elsevier* 2007, Box 60.1, page 778.



Useful background: Perform characteristics of tests for Lumbosacral Radiculopathy

| Finding | PLR | NLR |
|---|-----|-----|
| ➤ Motor examination | | |
| ○ Weak ankle extension (L3 or L4) | 3.7 | 0.7 |
| ○ Weak ankle dorsiflexion (L5) | | |
| ○ Weak ankle plantarflexion (S1) | | |
| ○ Ipsilateral calf wasting (S1) | 2.4 | 0.7 |
| ○ Weak ankle dorsiflexion | 4.9 | 0.5 |
| ○ Ipsilateral calf wasting | 5.2 | 0.8 |
| ➤ Sensory examination | | |
| ○ Sensory loss (L5) | 3.1 | 0.8 |
| ○ Sensory loss (S1; leg sensation abnormal) | 2.4 | 0.7 |
| ➤ Reflex examination | | |
| ○ Asymmetric quadriceps reflex (L3 or L4) | 8.7 | 0.6 |
| ○ Asymmetric Achilles reflex (S1) | 2.9 | 0.4 |
| ○ Abnormal ankle jerk | 2.7 | NS |

Note that weak hallux extension (L3 or L4 lesion) is omitted because its PLR was < 2.

Abbreviation: NS, not significant; PLR, positive likelihood ratio, NLR, negative likelihood ratio The nerve involved in the radiculopathy is given in square () brackets.

Adapted from: McGee SR. *Saunders/Elsevier* 2007, Box 60-5, page 787.

Useful background: Diagnosing lumbosacral radiculopathy in patients with sciatica*

| Finding | PLR | NLR |
|---|-----|-----|
| ➤ Motor examination | | |
| ○ Weak ankle dorsiflexion | 4.9 | 0.5 |
| ○ Ipsilateral calf wasting | 5.2 | 0.8 |
| ➤ Reflex examination | | |
| ○ Abnormal ankle jerk | 2.7 | NS |
| ➤ Other tests | | |
| ○ Crossed straight-leg raising maneuver | 3.4 | 0.8 |



*Diagnostic standard: For lumbosacral radiculopathy, surgical findings, electrodiagnostic, or magnetic resonance imaging or computed tomography indicating lumbosacral nerve root compression

Note that abnormal leg sensation and abnormal straight – leg raising have PLR < 2.

Abbreviation: NS, not significant; PLR, positive likelihood ratio, NLR, negative likelihood ratio

Adapted from: McGee SR. *Saunders/Elsevier* 2007, Box 60-4, page 786.

- In the upper limb, weakness is most marked in the abductors and extensors.
- In the lower limb, weakness is more marked in the flexor and abductor muscles.
- Spasticity
 - Increased tone is present (may be clasp-knife) and often associated with clonus
- The reflexes are increased except for the superficial reflexes (e.g. abdominal), which are absent.
- There is an extensor (Babinski) plantar response (upgoing toe)
- Weakness may be more obvious distally than proximally, and the flexor and extensor muscles are equally involved.

Adapted from: Talley NJ, et al *MacLennan & Petty Pty Limited* 2003, Table 10.23, page 418.

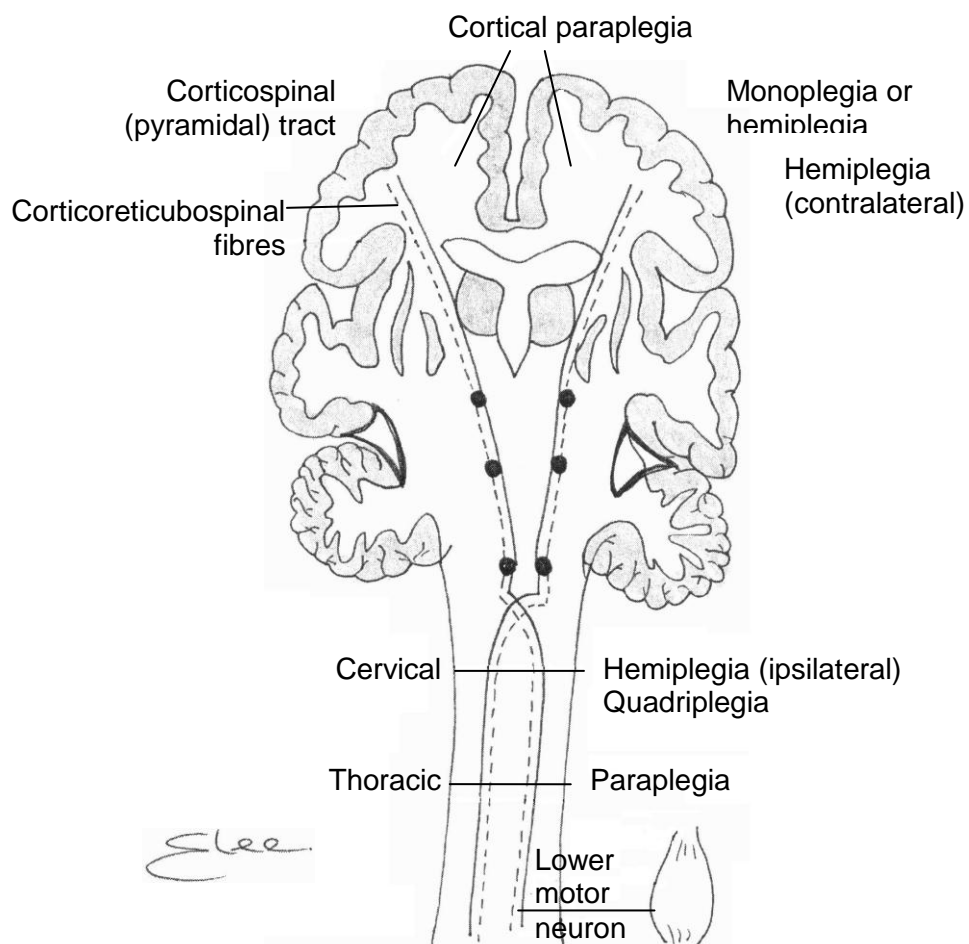
Useful background: Compare UMN versus LMN

| Site | Power |
|----------------------|--|
| ➤ Upper motor neuron | upper limbs - Flexors > extensors
lower limbs - Extensors > Flexors |
| ➤ Lower motor neuron | Reduced power in specific motor neuron (or nerve root) distributions |

Reinforcement can involve teeth clenching, hand grips, etc. Remember to make side-to-side comparisons of tone, pattern of weakness and reflexes.



Useful Background: Anatomical basis for upper and lower motor neuron lesions



Adapted from: Talley NJ, et al. *MacLennan & Petty Pty Limited* 2003, Figure 10.49, page 416.

"The future will bring personalized medicine
based on genetics"

Grandad



- Perform a focused physical examination to determine if a person has a UMN or an LMN lesion.

| Loss | UMN lesion | LMN lesion |
|---|----------------------------|--------------------|
| ➤ Muscle wasting | - | ++ |
| ➤ Fasciculations | - | + |
| ➤ Power | | |
| Upper limbs | F > E | ↓ |
| Lower limbs | E > F | ↓ |
| | Arms flexed, legs extended | Fasciculations |
| ➤ Tone | ↑/ spastic | ↓ |
| ➤ Coordination impaired due to weakness | + | + |
| ➤ Reflexes | | |
| ○ Superficial (e.g. abdominal) | Absent | Absent |
| ○ Deep | Increased/ clonus | Decreased |
| ○ Babinski | up-going (present) | Downgoing (absent) |

Abbreviations: E, extensor muscles; F, flexor muscles; LMN, lower motor neuron; UMN, upper motor neuron

Adapted from: Filate W, et al. *The Medical Society, Faculty of Medicine, University of Toronto* 2005, Table 9, page 163.

- Perform a focused physical examination of the motor system of the upper limbs.
 - Drift of the arms:
 - Upper motor neuron (pyramidal) weakness
 - Muscle weakness
 - Drift of the extended arms, with the eyes closed, tends to be in a downward direction
 - The drifting starts distally with the fingers, and spreads proximally.
 - There may be slow pronation of the wrist and flexion of the fingers and elbow
 - Cerebellar disease
 - The drift is usually upwards.
 - Includes slow pronation of the wrist and elbow



- Loss of proprioception
 - The drift here (pseudathetosis) is really a searching movement
 - Usually affects only the fingers
 - Due to loss of joint position sense and can be in any direction
- Ask the patient to relax the arms and rest them on his or her lap. Inspect the large muscle groups for
- Fasciculations
 - Irregular spontaneous contractions of small areas of muscle which have no rhythmical pattern
 - May be coarse or fine present at rest, but not during voluntary movement
 - If present with weakness and wasting, fasciculation indicates degeneration of the lower motor neurone
 - Usually benign if unassociated with other signs of a motor lesion

Adapted from: Talley NJ, et al. *Maclennan & Petty Pty Limited 2003*, page 391.

- Perform a focused physical examination of the patient with footdrop to determine to site at which the lateral popliteal nerve is affected.
- Peripheral portion of nerve
 - Footdrop because of loss of the dorsiflexors of the foot
- Nerve root
 - Footdrop, plus involvement of glutei (gluteus medius and maximus: loss of abduction of thigh against resistance, loss of ability to push raised leg downwards against resistance)
- Stroke – anterior cerebral artery or lacunar syndrome ('ataxic hemiparesis)
- L4, L5 root lesion
- Lumbosacral plexus lesion
- Sciatic nerve palsy
- Peripheral motor neuropathy
- Common peroneal nerve palsy
- Motor neurone disease
- Distal myopathy

Source: Talley NJ, et al *Maclennan & Petty Pty Limited 2003*, Table 10.20, page 414.



- Perform a focused physical examination for loss of corticospinal inhibition.
 - Hoffman finger flexion reflexes: sudden stretching of finger flexors causes the other finger flexors to contract involuntarily (finding of hyperreflexia).
 - Jaw Jerk: sudden stretching of the masseter muscle causes the jaw to move upwards briskly.
 - Clonus: sudden stretching of a muscle with continued stretch force applied causes continued oscillation of the muscle brachioradialis reflex (aka “inverted supinator reflex”): tapping this muscle causes flexion of the fingers (UMN effect), not the elbow (loss of LMN effect), indicating C5-6 spinal cord disease.
 - Inverted knee reflex: tapping knee causes knee flexion, not extension, indicating L2-4 spinal cord disease.
 - Crossed adductor reflex: tapping on the medial femoral condyle, patella, or patellar tendon causes the contralateral adductor muscle to contract, moving the contralateral knee medially.⁴²

Source: McGee SR. *Saunders/Elsevier* 2007, page 759.

Tendon reflexes: root level

- Ankle S1, 2
- Knee L3, 4
- Biceps C5, 6
- Supinator C5, 6
- Triceps C6, 7

Source: Burton JL. *Churchill Livingstone* 1971, page 83.

- Extensor plantars
 - Pyramidal lesion
 - Deep coma
 - 1st year of life.
 - May not be present if there is complete paralysis of extensor hallucis longus (L4, 5),
 - Loss of sensation of sole of foot
 - Hallux rigidis

Source: Davey P. *Wiley-Blackwell* 2006,



- Clonus
 - Dorsiflex ankle, push down on patella, percuss lower jaw; with “true” clonus, sustained clonus increases with pressure.
- CNS disease with remissions-MS, infection, myasthenia
- Failing memory-common initial intellectual failing
- Delirium-abnormal perception and motor activity
- Hallucination-sensory impression without sensory stimulus
- Illusion-sensory impression which is inconsistently interpreted

Source: Davey P. *Wiley-Blackwell* 2006,

- Perform a focused physical examination for hemisection of the spinal cord (Brown-Sequard syndrome).
- Deficits at the level of the cord lesion:
 - Ipsilateral LMN paralysis
 - Ipsilateral zone of cutaneous anaesthesia and zone of hyperaesthesia just below the anaesthetic zone
 - Segmental signs are usually unilateral
 - Muscular atrophy
 - Radicular pain
 - ↓ tendon reflexes
- Deficits below the level of the cord lesion
 - Ipsilateral monoplegia or hemiplegia
 - Ipsilateral loss of joint position and vibration sense
 - Contralateral loss of spinothalamic (pain and temperature) sensation.
- Causes
 - Cord tumour
 - Syringomyelia
 - Trauma
 - Degenerative disease of spine
 - Multiple myeloma
 - Hematomyelia
- Differentiate from MS

Adapted from: Baliga RR. *Saunders/Elsevier* 2007, pages 236 and 237.



➤ Clinical

- Motor changes
 - Upper motor neurone signs below the hemisection on the same side as the lesion;
 - Lower motor neurone signs at the level of the hemisection on the same side
- Sensory changes
 - Pain and temperature loss on the opposite side to the lesion - NB: the upper level of sensory loss is usually a few segments below the level of the lesion;
 - Vibration and proprioception loss occur on the same side;
 - Light touch is often normal
- Causes
 - Multiple sclerosis
 - Angioma
 - Trauma
 - Myelitis
 - Post-radiation myelopathy

➤ Differential

- Causes of only spinothalamic loss
 - Cord tumor
 - Hematomyelia
 - Bullet or stab wounds
 - Degenerative disease of spine
 - Multiple myeloma
 - Differentiate from MS
 - Syringomyelia
 - Brown-Séquard syndrome (contralateral leg);
 - Anterior spinal artery thrombosis;
 - Lateral medullary syndrome (contralateral to the other signs);
 - Small fibre peripheral neuropathy (e.g. diabetes mellitus, amyloid)
- Causes of dorsal column loss only
 - Subacute combined degeneration
 - Brown-Séquard syndrome (ipsilateral leg);
 - Spinocerebellar degeneration (e.g. Friedreich's ataxia);
 - Multiple sclerosis;
 - Tabes dorsalis;
 - Peripheral neuropathy (e.g. diabetes mellitus, hypothyroidism);
 - Sensory neuronopathy (a dorsal root ganglionopathy which may be caused by carcinoma, diabetes mellitus or Sjögren's syndrome).

Adapted form: Talley NJ, et al. *Maclennan & Petty Pty Limited* 2003, page 422, 425.



Useful background: Characteristics of abnormal tone

| Characteristic | Possible causes |
|---|--|
| ➤ ↓ tone | |
| ○ Flaccid | ○ LMN lesion, cerebellar; rarely myopathies, 'spinal shock' (e.g. early response after a spinal cord trauma), chorea |
| ➤ ↑ tone | |
| ○ spastic ('clasp knife') | ○ UMN lesion; corticospinal tract (commonly late or chronic stage after a stroke) |
| ○ rigidity ('lead pipe', cog wheeling') | ○ Extrapyramidal tract lesion <ul style="list-style-type: none"> - Parkinsonism - phenothiazines |

Adapted from: Filate W, et al. *The Medical Society, Faculty of Medicine, University of Toronto* 2005, page 164.

- Perform a focused physical examination for a lesion in the spinal canal at any level below T10 (cauda equina syndrome).
- Physical Examination
 - Flaccid, asymmetrical paraparesis (LMN)
 - Knee and ankle jerks are diminished or absent.
 - Saddle distribution of sensory loss up to the L1 level.
 - Downgoing plantars.
- Subtypes
 - The lateral cauda equina syndrome:
 - Pain in the anterior thigh,
 - Wasting of the quadriceps muscle,
 - Weakness of the foot invertors (due to L4 root lesion)
 - Absent knee jerk
 - Causes include neurofibroma, a high disc lesion.
 - The midline cauda equina syndrome:
 - Bilateral lumbar and sacral root lesions.
 - Causes include disc lesion, primary sacral bone tumours (chordomas), metastatic bone disease (from prostate) and leukemia.
- Causes
 - Centrally placed lumbosacral disc or spondylolisthesis at the lumbosacral junction
 - Tumours of the cauda equina (ependymoma, neurofibroma)
- Differentiate



- UMN lesion of conus medullaris (lowest part of spinal cord)
- Other causes of crossed hemiplegia (lesion is in the midbrain)
 - Weber's syndrome: contralateral hemiplegia (lesion is in the midbrain) with ipsilateral LMN lesion of the oculomotor nerve.
 - Millare-Gubler syndrome: contralateral hemiplegia (lesion is in the pons) with LMN lesion of the abducens nerve.
 - Foville's syndrome: as Millard-Gubler syndrome, with gaze palsy

Adapted from: Baliga RR. *Saunders/Elsevier 2007*, pages 228,229,237 and 238.

- Perform a directed physical examination to establish the neurological cause of a brachial plexus lesion, and the cervical rib syndrome.
- Brachial plexus lesions
 - Complete lesion (rare)
 - Lower motor neurone signs affect the whole arm
 - Sensory loss (whole limb)
 - Horner's syndrome (an important clue)
 NB: this is often painful
 - Upper lesion (C5, C6)
 - Loss of shoulder movement and elbow flexion – the hand is held in the waiter's tip position
 - Sensory loss over the lateral aspect of the arm and forearm
 - Lower lesion (C8, T1)
 - True claw hand with paralysis of all the intrinsic muscles
 - Sensory loss along the ulnar side of the hand and forearm
 - Horner's syndrome
- Cervical rib syndrome
 - Clinical features
 - Weakness and wasting of the small muscles of the hand (claw hand)
 - C8 and T1 sensory loss
 - Unequal radial pulses and blood pressure
 - Subclavian bruits on arm manoeuvring (may be present in normal persons)
 - Palpable cervical rib in the neck (uncommon)

Adapted from: Filate W, et al. *The Medical Society, Faculty of Medicine, University of Toronto 2005*, page139; Talley NJ, et al. *Maclennan & Petty Pty Limited 2003*, Table 10.18(6), page 407.



- Take a directed history and perform a focused physical examination for Friedreich's ataxia.
- Definition: spinocerebellar degeneration
 - Marked loss of cells in the posterior root ganglia
 - Degeneration of peripheral sensory fibres
 - Involvement of the posterior and lateral columns of the cord
- History
 - Age of onset (usually the same in each family, and ranges from 8 to 16 years of age)
 - High-arched foot in childhood in the family (Friedreich's foot).
 - Scoliosis developing in childhood
 - Cerebellar dysarthria and ataxia
- CNS
 - Cerebellar signs (bilateral) including nystagmus
 - Optic atrophy (uncommon)
 - Normal mentation
- Spine
 - Kyphoscoliosis
- Limbs
 - Pes cavus -cocking of the toes (other causes of pes cavus include hereditary motor and sensory neuropathy, spinocerebellar degeneration or neuropathies in childhood.
 - Upper motor neurone signs in the limbs (although reflexes are absent)
 - Posterior column loss in the limbs
- Heart
 - Cardiomyopathy (ECG abnormalities occur in more than 50% of cases)
- Peripheral nerves
 - Peripheral neuropathy
- Signs of diabetes
 - Diabetes mellitus (common)

Abbreviations: CNS, central nervous system; ECG, electrocardiogram

Printed with permission: Talley NJ, et al. *Maclennan & Petty Pty Limited* 2003, Table 10.33, page 433.



Useful background: Harding's criteria for Friedreich's ataxia

- Essential criteria are onset before the age of 25 years
 - Ataxia of limbs and gait
 - Absent knee and ankle jerks
 - Extensor plantars
 - Autosomal recessive inheritance
 - Motor conduction velocity greater than 40 ms
 - Small or absent sensory nerve action potentials
 - Dysarthria within 5 years of onset
- Additional criteria (present in two thirds)
 - Scoliosis
 - Pyramidal weakness of lower limbs
 - Absent upper limb reflexes
 - Loss of vibration and joint position sense in the legs
 - Abnormal ECG
 - Pes cavus.
- Other features (present in less than 50% of cases)
- Nystagmus
- Optic atrophy
- Deafness
- Distal muscle wasting and diabetes

Source: Baliga RR. *Saunders/Elsevier* 2007, pages 191-193.

Syringomyelia and Syringobulbia

Syringomyelia and Syringobulbia (involvement of the cord or brainstem, respectively)

- Functional Neuroanatomy
- Gliosis and syrinx anterior to
 - The central canal
 - The decussation of the fibers of the lateral spinothalamic tract
 - Anterior horn cells
 - Pyramidal tracts
-



Perform a focused physical examination for syringomyelia in a portion of the cervical cord.

- In the affected cervical segment, or above
 - Lateral spinothalamic tract
 - Loss of pain, temperature, tickle, sex
- In the affected segment
 - Anterior horn cells
 - LMN lesions in the corresponding motor nerve
- Below the affected segment
 - Pyramidal tracts
 - UMN lesions
- Sympathetic pathway in cervical cord
 - Horner's syndrome
 - Nystagmus (vestibular spinal tracts)
 - Loss of sensation of pain and temperature in lower face (descending tract of trigeminal nerve)
- Take a directed history and perform a focused physical examination for syringomyelia.
 - Definition
 - Formation of a cavity in the inner portion of the cord
 - Destruction of the white and grey matter and an accompanying reactive gliosis
 - The process generally begins in the cervical cord, and with expansion of the cavity the brainstem and distal cord also become affected
 - Physical Examination
 - LMN, small muscles of the hands and forearm
 - ↓ tone
 - Weakness
 - Wasting
 - Fasciculation
 - ↓ DTR
 - ↓ pain and temperature sensation
 - Intact vibration, light touch and joint position sense
 - Charcot's joints of the shoulder and elbow
 - *At the level of the syrinx*
 - LMN lesion, causing anterior horn cell involvement
 - Involvement of the central decussating fibres of the spinothalamic tract producing
 - Dissociated sensory loss



- Development of neuropathic arthropathy
- Trophic changes
- *Below the level of the syrinx:*
 - Involvement of pyramidal corticospinal tracts resulting in spastic paraparesis (sphincter function is usually well preserved)
- *Involvement of cervical sympathetic*
 - Horner's syndrome (miosis, enophthalmos, ptosis)
- *la main succulente*
 - Ugly hand
 - Cold
 - Cyanosed
 - Swollen fingers and palms.
- Differentiate from
 - Anterior spinal artery occlusion (affecting the dorsal horn and lateral spinothalamic tract).
 - Diabetic small-fibre polyneuropathy.
 - Hereditary amyloidotic polyneuropathy.
 - Leprosy (the latter three conditions affect small peripheral nerve axons).
- Conditions with a similar picture
 - Intramedullary tumours of the spinal cord.
 - Arachnoiditis around the foramen magnum obstructing the CSF pathway.
 - Hematomyelia.
 - Craniovertebral anomalies.
 - Late sequelae of spinal cord injuries (manifest as a painful ascending myelopathy).
 - Rarely patients may have hypertrophy in limbs hand and feet.
 - If fasciculation is seen, then the other diagnosis to consider is motor neuron disease

Abbreviation: DTR, deep tendon reflex

Adapted from: Baliga RR. *Saunders/Elsevier* 2007, pages 199 to 201.

Neuromuscular disease

- Give 4 neuro anatomical sites where lesions result in muscle weakness.
 - Upper motor neuron (UMN)
 - Lower motor neuron (LMN)
 - Cerebellum
 - Extra pyramidal tract
 - Malingering
 - Sensory disturbances, perceived as "weakness"



- Give 6 differences in the physical examination of upper (UMN) versus lower motor neuron (LMN) disorders.

| Signs | LMN | UMN |
|-----------------------------------|-----|-----|
| Weakness | + | + |
| Wasting | | |
| - a few muscles | + | - |
| - All muscles of one side of limb | - | + |
| Fasciculations | + | - |
| Tone | ↓ | ↑ |
| Reflexes | | |
| - deep | ↓ | ↑ |
| - superficial | - | ↓ |
| Rigidity("clasp-knife") | - | + |
| Extensor plantars | - | + |
| Clonus, sustained | - | + |

Useful background

- LMN lesions, common causes (disorders involving motor pathways from the AHC [anterior horn cell] to the muscles)
 - Motor neuron disease
 - Polio
 - Peripheral neuropathy
 - Muscle disease
 - Unilateral LMN
 - Lesion unlikely to be in spinal cord
- Causes of changes in muscle tone
 - ↑ tone
 - UMN, extrapyramidal disorders
 - ↓ tone
 - LMN
 - Cerebellum
 - Posterior column
 - Sensory nerve root (peripheral lesion)
 - Transient after acute lesions of cerebral hemisphere or spinal cord
- Changes in DTR (deep tendon reflexes; "reflexes")
 - ↑ DTRs
 - UMN lesion
 - Also ↑ DTRs with pain, strong emotion, anxiety, hysteria
 - ↓ DTRs
 - LMN lesion
 - Lesion of posterior column, or posterior nerve root



Useful background: Segmental innervation of muscles (Most muscles are innervated by nerves from more than one spinal root.)

| Spinal Level | Muscles |
|--------------|--|
| Arm | |
| C5 | Elbow flexors (biceps, brachialis) |
| C6 | Wrist extensors (extensor carpi radialis longus and brevis) |
| C7 | Elbow extensors (triceps) |
| C8 | Finger flexors (flexor digitorum profundus of middle finger) |
| T1 | Small finger abductors (abductor digiti minimi) |
| Leg | |
| L2 | Hip flexors (iliopsoas) |
| L3 | Knee extensors (quadriceps) |
| L4 | Ankle dorsiflexors (tibialis anterior) |
| L5 | Long toe extensors (extensor hallucis longus) |
| S1 | Ankle plantarflexors (gastrocnemius, soleus) |

Source: McGee SR. *Saunders/ Elsevier 2007, Table 57-6; Filate W, et al. The Medical Society, Faculty of Medicine, University of Toronto 2005, page 723.*

- Perform a focused physical examination for muscle or UMN nerve root disease in the muscle groups of the upper and lower body.

| Joint | Movement | Muscle | Nerve roots |
|------------|-------------|--|-------------|
| ➤ Shoulder | ○ Abduction | - Deltoid, | C5, C6 |
| | ○ Adduction | supraspinatus
- Pectoralis major,
latissimus dorsi | C6, C7, C8 |
| ➤ Elbow | ○ Flexion | - Biceps, brachialis | C5, C6 |
| | ○ Extension | - Triceps brachii | C7, C8 |
| ➤ Wrist | ○ Flexion | - Flexor carpi ulnar, | C6, C7 |
| | ○ Extension | radialis
- Extensor carpi | C7, C8 |



| Joint | Movement | Muscle | Nerve roots |
|----------------------------|----------------------------|---|-------------|
| ➤ Fingers | ○ Flexion | - Flexor digitorum profundus and sublimis | C7, C8 |
| | ○ Extension | - Extensor digitorum communis, extensor indicis, extensor digiti minimi | C7, C8 |
| | ○ Abduction | - Dorsal interossei | C8, T1 |
| | ○ Adduction | - Volar interossei | C8, T1 |
| ➤ Hamstrings | ○ Knee flexion | - Sciatic | L5, S1, 2 |
| ➤ Tibialis anterior | ○ Ankle dorsiflexion | - Deep peroneal | L4, 5 |
| ➤ Gastrocnemius soleus | ○ Ankle plantar flexion | - Tibial | S1, 2 |
| ➤ Extensor hallucis longus | ○ Great toe dorsiflexion | - Deep peroneal | L5, S1 |
| ➤ Tibialis | ○ Posterior foot inversion | - Posterior tibial | L4, L5 |
| ➤ Peroneus longus, brevis | ○ Foot eversion | - Superficial peroneal | L5, S1 |
| ➤ Hip | ○ Flexion | - Psoas; iliacas | L2, L3 |
| | ○ Extension | - Gluteus maximus | L5, S1, S2 |
| | ○ Abduction | - Gluteus medius and minimus | L4, L5, S1 |
| | ○ Adduction | - Sartorius, tensor fasciae latae
- Adductors longus, brevis, magnus | L2, L3, L4 |
| ➤ Knee | ○ Flexion | - "Hamstrings" (biceps femoris, semimembranosus, semitendinosus) | L5, S1 |
| | ○ Extension | - Quadriceps femoris | L3, L4 |



| Joint | Movement | Muscle | Nerve roots |
|----------------|-------------------|--|-------------|
| ➤ Ankle | ○ Plantar flexion | - Gastrocnemius, plantaris, soleus | S1, S2 |
| | ○ Dorsiflexion | - Tibialis anterior, extensor digitorum longus, extensor hallucis longus | L4, L5 |
| ➤ Tarsal joint | ○ Eversion | - Peroneus longus and brevis, extensor digitorum longus | L5, S1 |
| | ○ Inversion | - Tibialis posterior, gastrocnemius, hallucis longus | L5, S1 |

Abbreviations: UMN, upper motor neuron

Adapted from: McGee SR. *Saunders/Elsevier* 2007, Table 57-6, page 723; Table 10.15, page 404; Table 10.16, page 406.

- Peroneal Muscular Atrophy
 - Damage to peripheral nerve or cord, with some sensory loss
 - Hereditary, progressive wasting of distal parts of lower limbs (arms, face and trunk rarely affected)
 - Muscle wasting starts in legs, below the middle of the thigh or the middle of the calf
 - Wasting has a distinct upper border, with normal muscle above this area
 - Bilateral footdrop and inversion deformity

Useful background: Common muscle stretch reflexes

| Name of reflex | Peripheral nerve | Spinal level |
|-------------------------|------------------|--------------|
| ➤ Brachioradialis | Radial | C5-6 |
| ➤ Biceps | Musculocutaneous | C5-6 |
| ➤ Triceps | Radial | C7-8 |
| ➤ Quadriceps (patellar) | Femoral | L2-L4 |
| ➤ Achilles (ankle) | Tibial | S1 |

Source: McGee SR. *Saunders/Elsevier* 2007, page 756.



Useful background: Nerve innervations of the muscles of the hand and forearm radial nerve (C5-C8): triceps, brachioradialis, extensor muscles of hand

- Median nerve (C6-T1)
 - Muscles on front of forearm, except flexor
 - Carpi ulnaris and ulnar half of flexor digitorum profundus
 - Short muscle of hands (“LOAF” muscles: the two lateral lumbricals, opponens pollicis, abductor pollicis brevis, flexor pollicis brevis [in some persons])
- Ulnar nerve (C8-T1)
 - Small muscles of the hand except for “LOAF” muscles, flexor carpi ulnaris, ulnar half of flexor digitorum profundus

Adapted from: Mangione S. *Hanley & Belfus* 2000, page 462.

Sensory branches of peripheral nerves of the leg

| Nerve | Sensory branches |
|------------------------|-----------------------------------|
| ➤ Femoral nerve | ○ Anterior thigh
○ Medial calf |
| ➤ Obturator nerve | ○ Medial thigh |
| ➤ Sciatic nerve trunk* | ○ Posterior thigh |
| ➤ Peroneal nerve* | ○ Lateral calf and dorsal foot |
| ➤ Tibial nerve* | ○ Sole of foot |

*The sciatic nerve trunk divides above the knee into the peroneal and tibial nerves. Therefore, lesions of the sciatic nerve trunk affect sensation from all three branches.

Source: McGee SR. *Saunders/Elsevier* 2007, Table 63-4, page 785.

SO YOU WANT TO BE A NEUROLOGIST!

Q. You suspect that your patient has a disorder of the motor system of the upper limbs. What is the use of tapping the brachioradialis and biceps muscles to accentuate the finding of fasciculations?

A. None! Fasciculations are spontaneous; movements from a local stimulus is not spontaneous. Even if movement occurs, the movement may have nothing to do with fasciculations.

Source: Talley NJ, et al. *Maclennan & Petty Pty Limited* 2003, page 391.



Useful background: Segmental innervation of muscles of the arm*

| Spinal segments | C5 | C6 | C7 | C8 | T1 |
|---|----|----|----|----|----|
| ➤ Proximal nerves | | | | | |
| ○ Rhomboids (dorsal scapular nerve) | ■ | | | | |
| ○ Supraspinatus (supracapsular nerve) | ■ | | | | |
| ○ Infraspinatus (suprascapular nerve) | ■ | | | | |
| ○ Deltoid (axillary nerve) | ■ | | | | |
| ○ Serratus anterior (long thoracic nerve) | ■ | ■ | ■ | | |
| ➤ Musculocutaneous nerve | | | | | |
| ○ Biceps | ■ | ■ | | | |
| ➤ Radial nerve | | | | | |
| ○ Triceps | | ■ | ■ | ■ | |
| ○ Brachioradialis | ■ | ■ | | | |
| ○ Extensor carpi radialis longus | ■ | ■ | ■ | | |
| ○ Extensor carpi ulnaris | | | ■ | ■ | |
| ○ Finger extensors | | | ■ | ■ | |
| ➤ Median nerve | | | | | |
| ○ Pronator teres | | ■ | ■ | | |
| ○ Flexor carpi radialis | | ■ | ■ | | |
| ○ Flexor digitorum superficialis | | | ■ | ■ | ■ |
| ○ Abductor pollicis brevis | | | | ■ | ■ |
| ➤ Ulnar nerve | | | | | |
| ○ Flexor carpi ulnaris | | | ■ | ■ | |
| ○ Hypothenar muscles | | | | ■ | ■ |
| ○ Interossei | | | | ■ | ■ |

*Spinal levels that usually (black shade) and sometimes (gray shade) contribute to the corresponding muscle

Printed with permission: McGee SR. *Saunders/Elsevier* 2007, Table 60-1, page 773.



Useful background: Segmental innervation of the muscles of the leg*

| Spinal segments | L2 | L3 | L4 | L5 | S1 | S2 |
|---|----|----|----|----|----|----|
| ➤ Proximal nerves | | | | | | |
| ○ Gluteus medius (gluteal nerves, internal rotation and abduction of hip) | | | ■ | ■ | ■ | |
| ○ Gluteus maximus (gluteal nerves; extension of hip) | | | ■ | ■ | ■ | ■ |
| ➤ Femoral nerve | | | | | | |
| ○ Iliopsoas | ■ | ■ | | | | |
| ○ Quadriceps | ■ | ■ | ■ | | | |
| ➤ Obturator nerve | | | | | | |
| ○ Thigh adductors | ■ | ■ | ■ | | | |
| ➤ Sciatic nerve trunk† | | | | | | |
| ○ Hamstring (knee flexion) | | | | ■ | ■ | |
| ➤ Peroneal nerve | | | | | | |
| ○ Tibialis anterior (dorsiflexion of ankle) | | | ■ | ■ | | |
| ○ Extensors of toes | | | ■ | ■ | ■ | |
| ○ Peroneal longus (eversion of ankle) | | | ■ | ■ | ■ | |
| ➤ Tibial nerve† | | | | | | |
| ○ Tibialis posterior (inversion of ankle) | | | ■ | ■ | | |
| ○ Gastrocnemius | | | | ■ | ■ | ■ |
| ○ Flexor digitorum (curl toes) | | | | ■ | ■ | ■ |

*Spinal levels that usually (black shade) and sometimes (gray shade) contribute to the corresponding muscles.

†The sciatic nerve trunk divides above the knee into the peroneal and tibial nerves. Therefore, lesions of the sciatic nerve affect muscles of all three branches.

Printed with permission: McGee SR. *Saunders/Elsevier* 2007, Table 60-3, page 783.

Useful background: Compression of lumbar discs and physical findings

| Disc | Root | Motor weakness | Sensory loss | Reflex affected |
|---------|------|------------------------|---------------------------------|------------------|
| ➤ L4/5 | L5 | Dorsiflexors, EDL, EHL | Lateral calf and dorsum of foot | Medial hamstring |
| ➤ L5/S1 | S1 | Plantar flexors | Lateral foot and sole | Ankle jerk |



Legend: EDL=extensor digitorum longus, EHL= extensor hallucis longus

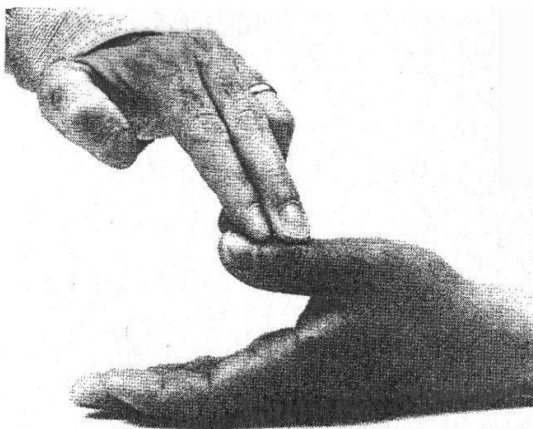
Source: Filate W, et al. *The Medical Society, Faculty of Medicine, University of Toronto* 2005, page 175.

- Perform a focused physical examination for damage to C5 to T₁ motor nerve roots and brachial plexus trunks.

| Nerve roots | Trunks | Muscles supplied |
|-------------|----------|--|
| ➤ C5 and 6 | ○ Upper | – Shoulder (especially biceps and deltoi |
| ➤ C7 | ○ Middle | – Triceps and some forearm muscles |
| ➤ C8 & T1 | ○ Lower | – Hand and some forearm muscles |

Source: Talley NJ, et al. *MacLennan & Petty Pty Limited* 2003, Table 10.15, page 404.

Peripheral Nerves



Useful background: Testing thumb abduction

- Instructed patient to raise their his thumb perpendicular to the palm
- The examiner applies downward pressure on the distal phalanx.
- A defect in the thumb abduction test indicated weakness of the abductor pollicis brevis, which is innervated only by the median nerve.

Adapted from: Simel DL, et al. *JAMA* 2009, Figure 10-2, page 113.

- Perform a focused physical examination to establish the neurological cause of wasting of the small muscles of the hand.
- Spinal cord lesions (C8, T1)*
 - Syringomyelia
 - Cervical spondylosis
 - Tumour
 - Trauma



- Motor neuron disease
- Syphilis
- Anterior horn cell disease
 - Motor neurone disease
 - Poliomyelitis
 - Spinal muscle atrophies
- Root lesion
 - Spondylosis
 - Neuro fibroma
 - Tumour
- Lower trunk brachial plexus lesion
 - Thoracic outlet syndromes
 - Trauma, radiation, infiltration, inflammation
 - Pancoast syndrome
 - Cervical rib
- Peripheral nerve lesions
 - Median and ulnar nerve lesions
 - Peripheral motor neuropathy
- Myopathy
 - Dystrophia myotonica (forearms are more affected than the hands)
 - Distal myopathy
- Trophic disorders
 - Atrophy
 - Ischemia
 - Shoulder hand syndrome
 - Arthritis of hand or wrist

* Rarely diabetes, lead poisoning or a carcinoma-associated neuropathy may display a similar cord lesion

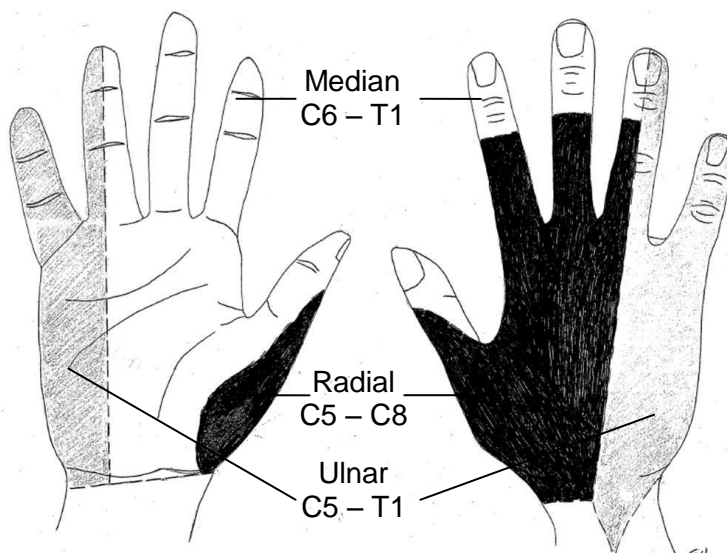
Adapted from: Talley NJ, et al. *Maclennan & Petty Pty Limited* 2003, Table 10.14, page 404.

"You cannot solve a problem with the same mind
that created it"

Albert Einstein



- Perform a focused physical examination of the cutaneous sensory innervation of the hand.



Adapted from: Talley NJ, et al. *Maclennan & Petty Pty Limited* 2003, Figure 10.37, page 401; Mangione S. *Hanley & Belfus* 2000, page 462.

Useful background: Causes of carpal tunnel syndrome

- Joint/ bone
 - Arthritis of wrist (esp. rheumatoid arthritis)
 - Previous scaphoid fracture
 - Intermittent trauma
- Metabolic
 - Myxedema
 - Acromegaly
 - Mucopolysaccharidosis V (Scheie's syndrome)
 - Hyperparathyroidism
- Sarcoidosis
- Amyloid (such as in chronic renal failure or multiple myeloma)
- Idiopathic
- Pregnancy, 'Pill', pre-menstrual

Adapted form: Baliga RR. *Saunders/Elsevier* 2007, pages 212 to 213.



- Perform a focused physical examination for carpal tunnel syndrome (median nerve compression).

| Finding | PLR | NLR |
|--|-----|-----|
| ➤ Hand diagram <ul style="list-style-type: none"> ○ 'Classic' or 'probable' | 2.4 | 0.5 |
| ➤ Sensory examination (median distribution) <ul style="list-style-type: none"> ○ Hypalgesia | 3.1 | NS |
| ➤ Other tests <ul style="list-style-type: none"> ○ Square wrist ratio | 2.7 | 0.5 |
| ➤ Cause | | |

Note that a number of signs are not included because their PLR was < 2: Tinel's sign, Phalen's sign, pressure provocation test, Flick sign, weak thumb abduction, thenar atrophy, Diminished 2-point discrimination, Abnormal vibration sensation, Diminished monofilament sensation

Abbreviation: NS, not significant; likelihood ratio (LR) if finding present= positive LR (PLR); LR if finding absent=negative LR (NLR).

Adapted from: McGee SR. *Saunders/Elsevier* 2007, Box 60-3, page 781.

| | | Probability | | | | | | |
|-----|-----|-------------|------|------|----------|------|------|----|
| | | Decrease | | | Increase | | | |
| | | -45% | -30% | -15% | +15% | +30% | +45% | |
| NLR | | 0.1 | 0.2 | 0.5 | 1 | 2 | 5 | 10 |
| | PLR | | | | | | | |

- Sen N out – Sensitive test; when negative, rules out disease
- Sp P in – Specific test; when positive, rules in disease
- Perform a focused physical examination for ulnar nerve palsy (C8, T1)
- Physical Examination
- Inspection
 - Generalized wasting of the small muscles of the hand.
 - Ulnar claw hand, (hyperextension at the metacarpophalangeal joints and flexion at the interphalangeal joints of the fourth and fifth fingers).



- Ulnar paradox - the higher the lesion in the upper limb, the lesser is the deformity
- A lesion at or above the elbow causes paralysis of the ulnar half of the flexor digitorum profundus, interossei and lumbricals.
- Motor
 - Weakness of movement of the fingers, except that of the thenar eminence
 - *In the forearm* (lesions in the cubital fossa)
 - Flexor carpi ulnaris.
 - Medial half of the flexor digitorum profundus.
 - Ulnar claw hand.
- Sensory
 - Sensory loss over the medial one and half fingers.
 - Movers of the little finger – abductor digiti minimi, flexor digiti minimi and opponens digiti minimi.
 - Adductor pollicis (oblique and transverse heads).
 - Dorsal and palmar interossei.
 - Third and fourth lumbricals.
 - Palmaris bevis.
 - Inner head of flexor pollicis brevis.

Adapted from: Baliga RR. *Saunders/Elsevier* 2007, pages 207 and 208.

- Take a directed history and perform a focused physical examination to distinguish between brachial plexus lesions and nerve root compression.

| | Root | Plexus |
|---------------------------------|------------------------------------|---------------------------------------|
| ➤ Previous trauma | ○ Occasionally | ○ Some types |
| ➤ Insidious onset | ○ Usually | ○ Some types |
| ➤ Neck pain | ○ Yes | ○ No |
| ➤ Unilateral interscapular pain | ○ Yes | ○ No |
| ➤ Weakness | ○ Mild-moderate | ○ Often severe |
| ➤ Pattern of weakness | ○ Most commonly triceps C7 lesions | ○ Usually shoulder and biceps or hand |

Printed with permission: Talley NJ, et al. *MacLennan & Petty Pty Limited* 2003, Tables 10.18a, b; Table 10.19, page 407.



- Perform a focused physical examination for the cause of a carcinomatous neuropathy.
- CNS
 - Dementia
 - Encephalomyelitis
- Cerebellum and corticospinal
- Cord – bone, meninges, cord itself
- Ost root ganglion
- Nerve
 - Neuropathy , mononeuritis multiplex
- Muscle
 - Myopathy,
 - Myasthenic syndrome

Adapted from: Burton JL. *Churchill Livingstone* 1971, page 87.

- Perform a focused physical examination for the causes of benign intracranial hypertension (pseudotumour cerebri).
- Drugs
 - Change in steroid dosage
 - Chlortetracycline, nalidixic acid, oral contraceptives
- Head
 - Head injury
 - Sagittal sinus thrombosis
- Female
 - Pregnancy, obesity, menarche
- Hematology
 - Anemia
 - Polycythemia
- Metabolic
 - Addison's
 - Hypoparathyroidism



Useful background: Sensory branches of peripheral nerves of the arm

| Nerve | Sensory branches |
|--------------------------|---|
| ➤ Musculocutaneous nerve | ○ Radial aspect forearm |
| ➤ Radial nerve | ○ Dorsal arm and forearm
○ Radial aspect dorsal hand |
| ➤ Median nerve | ○ Radial palm
○ First three digits and radial aspect ring finger |
| ➤ Ulnar nerve | ○ Ulnar aspect of hand and digits |

Source: McGee SR. *Saunders/Elsevier* 2007, Table 60-2, page 776.

Trick questions

Q1. Which deep tendon reflexes are affected in L5 lesions?

A1. The knee jerk is innervated through nerve root L3 and L4, so this reflex remains normal with a L5 disc protrusion

Q2. Why does protrusion of L4-L5 or L5-S1 never cause UMN signs?

A2. The spinal cord ends at L2, and below L2 is the Cauda equina consists of all the nerve roots below L2, L4-L5 or L5-S1 prolapse cannot cause UMN signs.

“Trustworthiness is a gating mechanism for social interactions.”

Grandad



SO YOU WANT TO BE A NEUROLOGIST!

Q1. Distinguish ulnar lesions from T1 root lesions (abductor pollicis brevis).

A1. The thumb is moved vertically against resistance, with the hand supine.

Q2. Distinguish between median and ulnar nerve defects affecting the hands:

- A2. The Median nerve supplies
- Motor (mnemonic LOAF)
 - Lateral two lumbricals
 - Opponens pollicis
 - Abductor pollicis brevis
 - Flexor pollicis brevis
 - Sensory to the radial 3½ digits
 - Ulnar nerve supplies all the rest

Source: Burton JL. *Churchill Livingstone* 1971, page 84.

Q3. In the context of cervical radiculopathy. What is the “Spurling’s test” or “neck compression test.”?

A3. In this test, the clinician turns and tilts the patient’s head and neck toward the painful side and then adds a compressive force to the top of the head. Aggravation of pain is a positive response!

Source: McGee SR. *Saunders/Elsevier* 2007, page 776.

SO YOU WANT TO BE A NEUROLOGIST!

Q1. What is the area of the skin (dermatome) which is supplied by the following nerve fibers originating from a single dorsal nerve root:

- | | | |
|-----|------------------------------|---------------------------------|
| A1. | C ₆ - Thumb | L ₅ - Top of foot |
| | T ₄ - Nipple line | S ₁ - Bottom of foot |
| | T ₁₀ - Umbilicus | S ₂₋₄ - Perineum |

Source: Mangione S. *Hanley & Belfus* 2000, page 414.



SO YOU WANT TO BE A NEUROLOGIST!

Q1. From the history, how do you distinguish radiculopathy for peripheral neuropathy?

- A1. ○ Peripheral neuropathy - changes in motor and sensory function (denervation causing LMN lesion with weakness, atrophy, fasciculations)
○ Radiculopathy - motor and sensory loss, plus pain

Q2. What are the causes of a claw hand (all fingers clawed)?

- A2. ○ Ulnar and median nerve lesion (ulnar nerve palsy alone causes a claw-like hand)
○ Brachial plexus lesion (C8-T1)
○ Other neurological disease – e.g. syringomyelia, polio
○ Ischaemic contracture (late and severe)
○ Rheumatoid arthritis (advanced, untreated disease)

Source: Talley NJ, et al. *MacLennan & Petty Pty Limited* 2003, Table 10.13, page 403; Baliga RR. *Saunders/Elsevier* 2007, page 209.

Q3. What is the difference between neuropraxia, axonotmesis, and neurotmesis?

- A3. I don't really care. (Not a good response!)
○ Neurapraxia - concussion of the nerve after which a complete recovery occurs.
○ Axonotmesis the axon is severed, but the myelin sheath is intact and recovery may occur.
○ Neurotmesis - the nerve is completely severed, and the prognosis for recovery is poor.

Source: Baliga RR. *Saunders/Elsevier* 2007, page 211.

Q4. In the patient with symptoms and signs suggestive of peripheral neuropathy, what is the important symptom which suggests that the disease is at the nerve root?

A4. Pain! Severe pain which may radiate down the arms or legs

Source: Mangione S. *Hanley & Belfus* 2000,



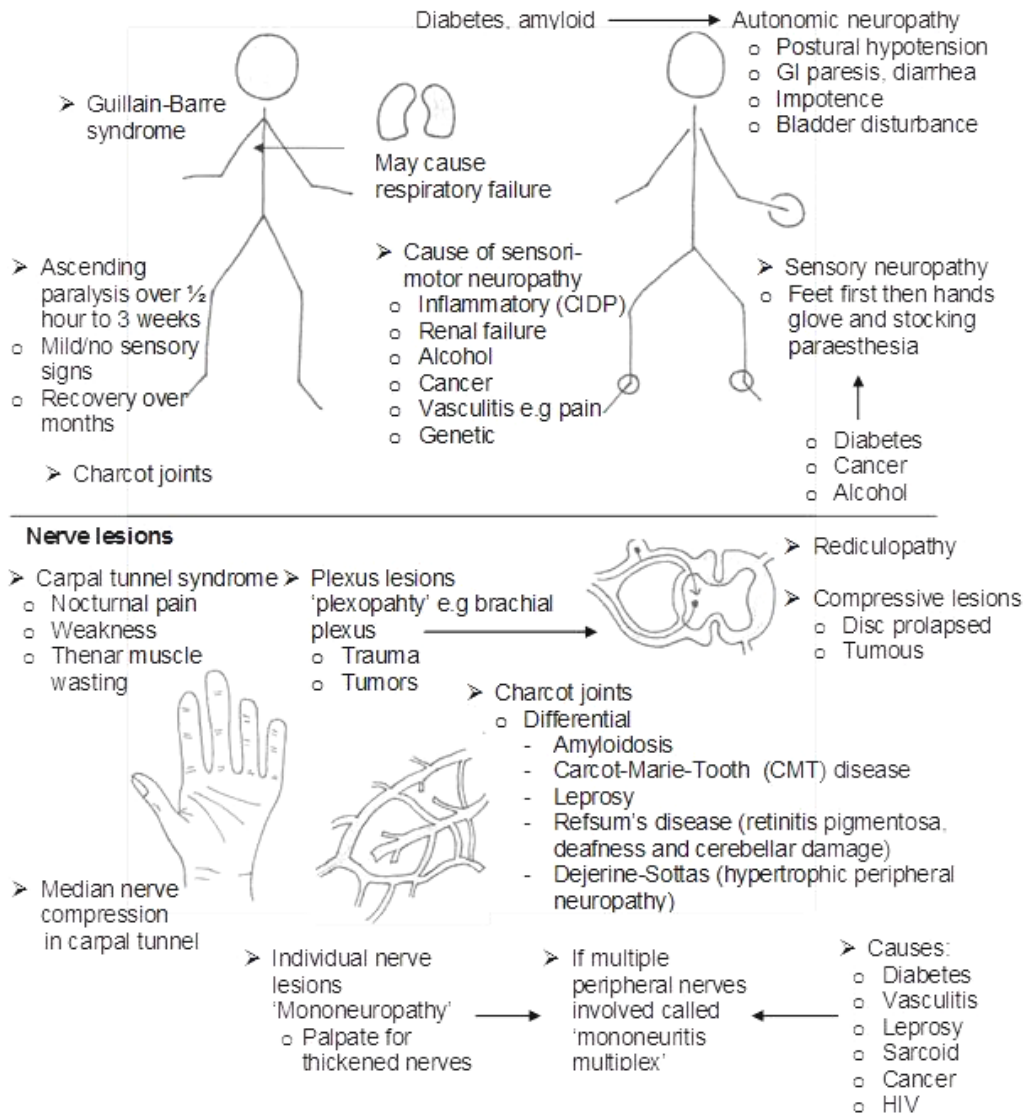
Peripheral neuropathy

Useful background: Peripheral neuropathy

- Definition
 - Bilateral and symmetrical weakness of muscle
- Clinical
 - Legs are affected more than the arms
 - May be symptoms/signs of motor, sensory, or motor plus sensory loss (as in diabetic neuropathy)
 - Rare to have disturbance of sphincters
 - Recovery
 - Fast
 - Demyelination (eg, diabetes, carcinoma, GBS)
 - Slow
 - Loss of neuron
- Causes
 - Hereditary
 - Infection
 - Including GBS (Gullain-Barre' syndrome, aka acute infective polyneuropathy)
 - Allergy
 - Collagen
 - Vascular disease
 - Rheumatoid arthritis
 - Lupis
 - Polyarthritis
 - Tumor
 - Trauma
 - Toxins
 - Alcohol
 - Lead
 - Drugs
 - Metabolic disorders
 - Diabetes
 - Uremia
 - Amyloid
 - Porphyria
 - Deficiency
 - B1, B6, B12
 - Idiopathic
 - Ischemia
 - Entrapment syndrome
 - Hysteria



Useful background: Peripheral neuropathy



Adapted from: Davey P. *Wiley-Blackwell* 2006, page 387; Baliga RR. *Saunders/Elsevier* 2007, pages 164 and 165.



- Perform a directed physical examination for the causes of peripheral neuropathy.
- Definition:
 - Bilateral symmetrical sensory loss for all modalities with all modalities with or without motor weakness.
 - Motor or sensory component, one or more peripheral or cranial nerves, as well as mononeuritis multiplex.
- Causes of peripheral neuropathy
 - Drugs- e.g. isoniazid, vincristine, phenytoin, nitrofurantoin, cisplatinum, heavy metals (e.g. arsenic), amiodarone, thallium poisoning
 - Alcohol abuse (with or without vitamin B1 deficiency)
 - Metabolic –e.g. diabetes mellitus, chronic renal failure, porphyria, acromegaly
 - Infection – HIV, sarcoidosis, diphtheria, leprosy, Lyme disease
 - Guillain-Barre syndrome
 - Malignancy- e.g. carcinoma of the lung (paraneoplastic neuropathy), leukemia, lymphoma
 - Vitamin deficiency (e.g. B12) or excess (e.g. B6)
 - Connective tissue disease - e.g. PAN, SLE, rheumatoid arthritis, amyloid
 - Hereditary
 - Multifocal conduction block neuropathy (MCBN)
 - Compressive neuropathies
 - Idiopathic
- Causes of a predominant motor neuropathy
 - Guillain-Barre syndrome
 - Chronic inflammatory polyradiculoneuropathy
 - Perineal muscular atrophy
 - Give **DAD** some **Rum** (mnemonic)
 - **D**abetes mellitus (diabetic chart, insulin injection sites, insulin pump)
 - **A**lcoholic liver disease (palmar erythema, spider naevi, tender liver)
 - **D**rug history
 - **R**heumatoid arthritis
 - **U**raemia
 - **M**alignancy



- Hereditary motor and sensory neuropathy
- Diabetes mellitus
- Acute intermittent porphyria
- Diphtheria
- MCBN
- Drugs/ toxins e.g
 - Lead
 - Dapsone
 - Organophosphorous poisoning
- Causes of a painful sensory peripheral neuropathy
 - Diabetes mellitus
 - Alcohol
 - Vitamin B1, or B12 deficiency
 - Carcinoma
 - Porphyria
 - Arsenic or thallium poisoning
- Mononeuritis multiplex *
 - Acute causes (usually vascular)
 - Polyarteritis nodosa
 - Diabetes mellitus
 - Connective tissue disease – e.g. rheumatoid arthritis, SLE
 - Chronic causes
 - Multiple compressive neuropathies
 - Sarcoidosis
 - Acromegaly
 - HIV infection
 - Leprosy
 - Lyme disease
 - Others- e.g. carcinoma (rare)
- In diabetes mellitus
 - Symmetrical, mainly sensory, polyneuropathy
 - Asymmetrical, mainly motor, polyneuropathy (diabetic amyotrophy)
 - Mononeuropathy
 - Autonomic neuropathy

*separate involvement of more than one peripheral (or less often cranial) nerve by a single disease

Adapted from: Talley NJ, et al. *Maclennan & Petty Pty Limited* 2003, Table 10.25, page 420.



Hysterical Anaesthesia

- Perform a focused physical examination for hysterical anaesthesia.
 - May have usual motor or sensory symptoms/signs of peripheral neuropathy, including
 - “glove and stocking” distribution of peripheral neuritis
 - Total anaesthesia of one side of the body, such as in thalamic and internal capsule lesions
 - Joint sensation is spared in hysterical anaesthesia
 - Sharp out-off for loss of sensation
 - Distribution of affected area
 - May change over time
 - May change in response to suggestion

Autonomic Neuropathy

- Take a directed history and perform a focused physical examination for autonomic neuropathy.
- An autonomic neuropathy may be suggested by
 - Symptoms
 - Symptoms of damage to hypothalamus: disturbances of
 - Sleep
 - Appetite
 - Temperature
 - Diabetes insipidus
 - Postural hypotension
 - Loss of sweating
 - Impotence
 - Diarrhea
 - Signs of
 - Afferent side of autonomic nervous system (ANS)
 - Postural hypotension
 - Central side of NAS
 - Increased blood pressure with mental arithmetic
 - Loss of sweating when in the heat
 - Signs of loss of spinal cord or medullary sympathetic pathways
 - Efferent side of ANS
 - Failure of parasympathetic system to respond to administration of atropine
 - Failure of sympathetic system to administration of noradrenalin



Useful background: Causes of lower motor neuron (LMN) signs in the legs.

- Peripheral neuropathy
- Prolapsed intervertebral disc
- Diabetic amyotrophy
- Poliomyelitis
- Cauda equine lesions
- Motor neuron disease

Source: Baliga RR. *Saunders/Elsevier* 2007, pages 165 and 173.

- Causes of Mononeuritis multiplex
 - Mnemonic: Go to the **WARDS, PLeaCe**
 - **W**egener's granulomatosis
 - **A**myloidosis
 - **R**heumatoid arthritis
 - **D**iabetes mellitus
 - **S**LE
 - **P**olyarteritis nodosa
 - **L**eprosy
 - **C**arcinomatosis, Churg-Strauss syndrome

Source: Baliga RR. *Saunders/Elsevier* 2007, page 165.

Useful background: Sensory syndromes

- The gray shading indicates hypalgesia (loss of pain temperature sensation)
 - The arrows indicate limbs with significant accompanying weakness.
 - In the Brown-Sequard syndrome (hemisection of the cord), there is often diminished tactile sensation on the side of weakness and opposite the side with hypalgesia.
- Perform a focused physical examination for the causes of fasciculations.
 - Motor neurone disease
 - Motor root compression
 - Peripheral neuropathy - e.g. diabetic
 - Primary myopathy
 - Thyrotoxicosis

Source: Talley NJ, et al. *Maclennan & Petty Pty Limited* 2003, page 392.



- Perform a focused physical examination for Charcot-Marie-Tooth disease (features of hereditary motor and sensory neuropathy due to peripheral nerve degeneration which does not usually extend above the elbows or above the middle third of the thighs).
 - Distal muscle atrophy
 - Pes cavus (short arched feet)
 - Sensation
 - Slight or no sensory loss in the limbs
 - Reflexes
 - Absent
 - Nerves
 - Thickened
 - Eyes
 - Optic atrophy
 - Argyll Robertson pupils
 - Slight or no sensory loss in the limbs
 - Thickened nerves
 - Optic atrophy, Argyll Robertson pupils (rare)

Adapted from: Talley NJ, et al. *Maclennan & Petty Pty Limited* 2003, Table 10.31, page 430.

Loss of pain sensation (pinprick) with lesion of the major nerves of the upper limbs

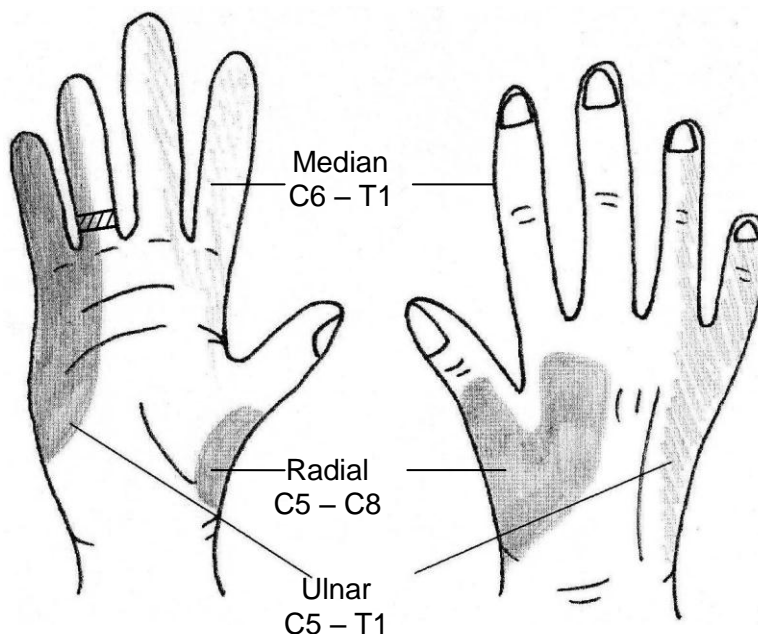
- A lesion of a peripheral nerve causes a characteristic motor and sensory loss
- The radial nerve (C5-C8)
 - Motor supply the triceps and brachioradialis and the extensor muscles of the hand
 - Characteristic deformity from radial nerve injury - wrist drop.



- Pin sensation over the area of the anatomical snuff box is lost with a radial nerve lesion before the bifurcation into posterior interosseous and superficial radial nerves at the elbow.
- The median nerve (C6-T1)
 - Motor supply to all the muscles on the front of the forearm, except the flexor carpi ulnaris and the ulnar half of the flexor digitorum profundus.
 - Also supplies the following short muscles of the hand (LOAF)
 - The lateral two Lumbricals
 - Opponens pollicis
 - Abductor pollicis brevis
 - in many people the Flexor pollicis brevis.
 - Local causes, such trauma or compression, or may be part of a mononeuritis multiplex, where more than one nerve is affected by systemic disease.

Adapted from: Talley NJ, et al. *Maclennan & Petty Pty Limited* 2003, page 401.

- Perform a focused physical examination of the peripheral nerves of the hand (see figure).



Adapted from: Talley NJ, et al. *Maclennan & Petty Pty Limited* 2003, Figure 10.37, page 401.



- Perform a focused physical examination for a hereditary peroneal muscular neuropathy.
- Motor
 - Calves/ thighs
 - Wasting
 - Stops abruptly, usually in the lower third of the thigh
 - Toes
 - Pes cavus (clawing of toes)
 - Contractures of the Achilles tendon
 - Weakness of dorsiflexion
 - Ankle
 - Absent ankle jerks
 - Plantars are downing going or equivocal
- Sensory
 - Mild sensory impairment or no sensory loss (occasionally a response to pain in the stocking distribution).

Adapted from: Baliga RR. *Saunders/Elsevier* 2007, pages 165 and 166.

- Perform a focused physical examination of the type and location of lesion causing abnormal sensation.

| Location of lesion | Abnormal sensation |
|---|---|
| ➤ Brainstem | |
| ○ Thalamus or upper brainstem (extensive lesion) | - Total unilateral loss of all forms of sensation |
| ○ Medulla involving descending nucleus of spinal tract of the fifth nerve | - Pain & temperature loss on one side of face & opposite side of body |
| ○ Ascending spinothalamic tract (lateral medullary lesion) | |
| ➤ Spinal cord | |
| ○ Spinal cord lesion (if only pain & temperature affected: anterior cord lesion) | - Bilateral loss of all forms of sensation below a definite level |
| ○ Partial unilateral spinal cord lesion on opposite side (Brown-Sequard syndrome) | - Unilateral loss of pain & temperature below a definite level |



| Location of lesion | Abnormal sensation |
|---|---|
| <ul style="list-style-type: none"> ○ Intrinsic spinal cord lesion near its centre anteriorly (involves the crossing fibres), e.g. syringomyelia, intrinsic cord tumour | - Loss of pain & temperature over several segments but normal sensation above & below |
| <ul style="list-style-type: none"> ○ More posterior lesions cause proprioceptive loss | |
| <ul style="list-style-type: none"> ○ Intrinsic cord compression more likely | - Loss of sensation over many segments with sacral sparing |
| <ul style="list-style-type: none"> ○ Cauda equina lesion (touch preserved in conus medullaris lesions) | - Saddle sensory loss (lowest sacral segments) |
| <ul style="list-style-type: none"> ○ Posterior column lesion | - Loss of position & vibration sense only |
| ➤ Root | |
| <ul style="list-style-type: none"> ○ Posterior root lesion (purely sensory) or peripheral nerve (often motor abnormality associated) | - Loss of all forms of sensation over a well-defined body part only |
| ➤ Nerve | |
| <ul style="list-style-type: none"> ○ Peripheral neuropathy | - Glove & stocking loss (hands & feet) |

Adapted from: Talley NJ, et al. *Maclennan & Petty Pty Limited* 2003, Table 10.27, page 426.

"The only disability in life is a bad attitude"

Scott Hamilton



Useful background: Common muscle stretch reflexes

| Name of reflex | Peripheral nerve | Spinal level |
|-------------------------|--------------------|--------------|
| ○ Brachioradialis | ○ Radial | - C5-6 |
| ○ Biceps | ○ Musculocutaneous | - C5-6 |
| ○ Triceps | ○ Radial | - C7-8 |
| ○ Quadriceps (patellar) | ○ Femoral | - L2-L4 |
| ○ Achilles (ankle) | ○ Tibial | - S1 |
| ○ Abdominal | ○ Epigastric | - T6-T9 |
| | ○ Mid abdominal | - T9-T11 |
| | ○ Lower abdomen | - T1-L1 |
| ○ Cremasteric reflexes | | - L1, L2 |
| ○ Saddle sensation | | - S3, S4, S5 |
| ○ Anal reflex | | - S3, S4, S5 |

Adapted from: Filate W, et al. *The Medical Society, Faculty of Medicine, University of Toronto* 2005, Table 13, page 164; and McGee SR. *Saunders/Elsevier* 2007, Table 59-1, page 756.

Useful background: Interpreting deep tendon reflexes (DTR)

| Characteristic of DTR | Possible causes |
|--|---|
| ➤ Increased reflex or clonus | <ul style="list-style-type: none"> ○ UMN lesion above root at that level ○ Generalized <ul style="list-style-type: none"> - peripheral neuropathy ○ Isolated-peripheral nerve or root lesion |
| ➤ Reduced (insensitive) | <ul style="list-style-type: none"> ○ Peripheral neuropathy ○ Cerebellar syndrome |
| ➤ Inverted (reflex tested is absent e.g. biceps but there is spread to lower or higher level e.g. produces a triceps response) | <ul style="list-style-type: none"> ○ Spinal cord LMN involvement at the level of the absent reflex |
| ➤ Pendular (reflex continues to swing for several beats) | <ul style="list-style-type: none"> ○ Cerebellar disease |
| ➤ Slow relaxation (especially at ankle) | <ul style="list-style-type: none"> ○ hypothyroidism |

Adapted from: Filate W, et al. *The Medical Society, Faculty of Medicine, University of Toronto* 2005, page 66.



Useful background: Grading the power of deep tendon reflexes

| Grade | Assessment |
|-------|---|
| 0 | Absent No contraction detected |
| 1 | Trace Slight contraction detected but cannot move joint |
| 2 | Weak Movement with gravity eliminated only |
| 3 | Fair Movement against gravity only |
| 4 | Good Movement against gravity with some resistance |
| 5 | Normal Movement against gravity with full resistance |

*Note: since rating scale is skewed towards weakness many clinicians further sub classify their findings by adding a (+) or a (-), e.g. 5- or 3+

Source: Filate W, et al. *The Medical Society, Faculty of Medicine, University of Toronto* 2005, page 164.

Conditions causing thickened nerve plus peripheral neuropathy or mononeuritis multiplex

- Acromegaly
 - Neurofibromatosis
- Amyloid
 - Chronic inflammatory demyelinating polyradiculo neuropathy (CIDP)
- Sarcoid
 - Autosomal dominant hereditary motor and sensory neuropathy
- Leprosy
- Diabetes

Adapted from: Talley NJ, et al. *MacLennan & Petty Pty Limited* 2003, page 420.

- Perform a focused physical examination for inflammatory polyradiculoneuropathy.
- Guillain-Barré syndrome
 - Flaccid paralysis in lower limbs progressing to upper limbs one week after an infective illness
 - Sensory loss and wasting is minimal or absent
 - Cranial nerves rarely affected, but may be confined there
 - Sphincters never affected
- Transverse myelitis
 - As for Guillain-Barré syndrome (as above), with involvement of sphincters:
 - HIV

Abbreviation: HIV, human immunodeficiency virus

Adapted from: Talley NJ, et al. *MacLennan & Petty Pty Limited* 2003, page 420.



- Take a directed history and perform a focused physical examination for common peroneal nerve palsy (aka: lateral popliteal nerve palsy [L4, 5].
- Motor
 - Leg
 - Wasting of the muscles on the lateral aspect of the leg (namely the peronei and tibialis anterior muscle)
 - Foot
 - Weakness of dorsiflexion
 - Eversion of the foot
 - Foot-drop
 - Gait
 - High-stepping
 - Loss of sensation of the lateral aspect of the leg and dorsum of the foot.
 - If the deep peroneal branch is affected, the sensory loss may be limited to the dorsum of the web between the first and second toes.
- Differentiate from other causes of foot-drop
 - L4, L5 root lesion
 - Lumbosacral plexus lesion
 - Sciatic nerve palsy
 - Peripheral neuropathy
 - Motor neuron disease

Adapted from: Baliga RR. *Saunders/Elsevier* 2007, pages 210 and 211.

Useful background:

- Causes of thickened nerves
 - Amyloidosis.
 - Charcot-Marie-Tooth disease.
 - Leprosy.
 - Refsum's disease (retinitis pigmentosa, deafness and cerebellar damage).
 - Déjérine-Sottas disease (hypertrophic peripheral neuropathy).
- Causes of motor neuropathy
 - Guillain-Barré syndrome.
 - Peroneal muscular atrophy.
 - Lead toxicity.
 - Porphyria.
 - Dapsone toxicity.
 - Organophosphorous poisoning.



- Causes of mononeuritis multiplex
 - **W**egener's granulomatosis.
 - **A**myloidosis.
 - **R**heumatoid arthritis.
 - **D**iabetes mellitus.
 - **S**LE
 - **P**olyarteritis nodosa.
 - **L**eprosy
 - **C**arcinomatosis, **C**hurg-Strauss syndrome (Mnemonic: WARDS, PLC).

- Causes of predominantly sensory neuropathy
 - Diabetes mellitus.
 - Alcoholism.
 - Deficiency of vitamins B₁₂ and B₁.
 - Chronic renal failure.
 - Leprosy

- Types of neuropathy in diabetes mellitus
 - Symmetrical, mainly sensory, polyneuropathy.
 - Asymmetrical, mainly motor, polyneuropathy (diabetic amyotrophy).
 - Mononeuropathy.
 - Autonomic neuropathy.

Adapted from: McGee SR. *Saunders/Elsevier* 2007, page 165.

SO YOU WANT TO BE A NEUROLOGIST!

Q. What is the mechanism?

A. A mixture of cerebellar, pyramidal and dorsal column signs with a combination of pyramidal weakness with peripheral neuropathy.

Source: Baliga R.R. *Saunders/Elsevier* 2007, pages 191 and 192.

- Perform a focused physical examination for peripheral neuropathy.
 - Muscle
 - Distal, asymmetrical weakness
 - Atrophy
 - Fasciculations
 - Tone – normal or ↓
 - Reflexes - ↓



- Sensation
 - loss
- Trophic changes
 - Loss of
 - hair
 - nails
 - Skin
 - Smooth
 - Shing
- Perform a focused physical examination for foot drop.
- Nerve
 - Common peroneal nerve palsy
 - Peripheral motor neuropathy
 - Sciatic nerve palsy
- Cord
 - Lumbosacral plexus lesion
 - L4, L5 root lesion
- Muscle
 - Distal myopathy
 - Motor neurone disease
- CNS
 - Stroke—anterior cerebral artery or lacunar syndrome ('ataxic hemiparesis')

Source: Talley NJ, et al. *MacLennan & Petty Pty Limited* 2003, Table 10.2, page 414.

Useful background: Distribution of muscle wasting or weakness

| Pattern | Possible causes |
|------------------------|---|
| ➤ Focal (one limb) | ○ Nerve root or peripheral nerve pathology |
| ➤ Proximal (bilateral) | ○ Myopathy (no sensory loss) |
| ➤ Distal (bilateral) | ○ Peripheral neuropathy (distal sensory loss) |

Source: Filate W., et al. *The Medical Society, Faculty of Medicine, University of Toronto* 2005, page 163.



Neuromuscular disease

Muscle Disease

Spasticity

- Definition: “Spasticity is an involuntary velocity-dependent increase in muscle tone resulting from injury to the motor pathways in the brain or spinal cord” (Devonshire V, et al. Chapter 20. In: Therapeutic Choices. Grey J, Ed. 6th Edition, *Canadian Pharmacists Association*: Ottawa, ON, 2011, page 264).
- Usually occurs as part of the UMN (upper motor neuron) complex
- Characterized by
 - Spasticity, and
 - Weakness of affected limb
 - Slow coordination
 - ↑ DTR (deep tendon reflexes)
 - Babinski sign

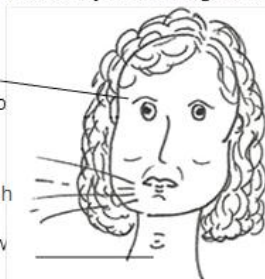
Useful background: Clinical features of Neuromuscular disease

➤ Clinical Features of motor neuron disease

- Predominant symptom is weak, wasted fasciculating muscles
- No sensory symptoms
- No bladder disturbance
- Tongue fasciculation
- May involve: Respiratory muscles → Respiratory failure
- May start as wasting of intrinsic hand muscles.
- Differential diagnosis:
 - Cervical rib
 - Pancoast tumor
 - T1 root lesion
 - Syringomyelia

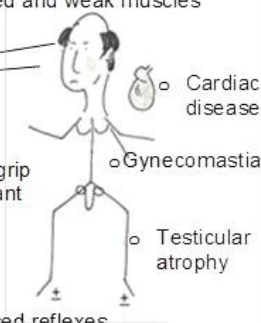
➤ Clinical Features of myasthenia gravis

- Fatigue
- Intermittent ptosis, diplop
- Weak speech
- Difficult chew swallowing
- Usually variable symptoms (i.e fatigueable)
- Improves with edrophonium test (acetylcholinesterase inhibitor)
- Worse with aminoglycosides (and some other drugs)



➤ Myotonic dystrophy

- Wasted and weak muscles
- Frontal balding
- Cataracts
- Cardiac disease
- Gynecomastia
- Testicular atrophy
- Absent or depressed reflexes
- Difficulty relaxing grip
- Autosomal dominant
- Diabetes



➤ Familial hypokalemic paralysis

- Onset aged 10-20 yrs
- offset ± 35 yrs
- Generalized weakness
- Association:
 - Asian people
 - Thyrotoxicosis
 - Food provokes symptoms

Elee

Adapted from Davey P. *Wiley-Blackwell* 2006, page 382.



Useful background: Definitions used in muscle disease

- Myopathy refers to muscle disease
- If the disease is progressive and genetic, it is called dystrophy.
- Myotonic dystrophy: atrophy and weakness begin in the face and sternocleidomastoid muscles.
- Myotonia (ie, normal contraction with slow relaxation) is a feature of myotonic dystrophy. With myotonia, the patient cannot let go quickly after a handshake.
- Acquired myopathy: no underlying cause is found in many adults

Source: Ghosh AK. *Mayo Clinic Scientific Press* 2008, page 771.

Useful background: Classification of muscle disease

- Primary
 - Muscular dystrophy
 - Duchene's (pseudohypertrophic)
 - Affects only males (sex linked recessive)
 - Calves and deltoids: hypertrophied early, weak later
 - Proximal weakness: early
 - Dilated cardiomyopathy
 - Becker
 - Affects only males (sex linked recessive)
 - Similar clinical features to Duchenne's except for less heart disease, a later onset and less rapid progression
 - Limb girdle
 - Males or females (autosomal recessive), onset in the third decade
 - Shoulder or pelvic girdle affected
 - Face and heart usually spared
 - Facioscapulohumeral
 - Males or females (autosomal dominant)
 - Facial and pectoral weakness with hypertrophy of deltoids
 - Dystrophia myotonica (autosomal dominant)
 - Myasthenia
 - Gravis
 - Carcinomatosis myasthenic syndrome



- Myositis
 - Infection
 - Staph. Aureus
 - Streptococcus
 - TB
 - Clostridium welchii
 - Granulomatous
 - Sarcoidosis
 - Trichiniasis
 - Cysticercosis
 - Collagen/ vascular
 - Polymyalgia rheumatica
 - Dermatomyositis
 - Idiopathic
 - Myositis ossificans
 - Progressive myositis fibrosa

- Secondary myopathy
 - Inherited
 - Glycogen storage disease
 - Paroxysmal myoglobinuria
 - Mitochondrial disorders
 - Drugs/ toxic
 - Chloroquine
 - Alcoholism
 - Corticosteroids
 - Endocrine/ metabolic
 - Hyper' and hypothyroidism
 - Diabetes mellitus
 - Cushing's syndrome
 - Hyper' and hypo kalemia (including familial periodic paralysis)
 - Osteomalacia
 - Infiltrative
 - Carcinomatous myopathy
 - Amyloidosis

- Atrophy
 - Secondary to disuse, neurological deficit etc

Adapted from: Burton JL. *Churchill Livingstone* 1971, pages 91 and 92;
 Hauser SC, et al. *Mayo Clinic Gastroenterology and Hepatology Board Review*, 3rd Review, page 771.



- Perform a focused physical examination for muscle disease.
 - Early
 - Proximal and symmetrical (bilateral) muscle weakness
 - Sensory loss – none
 - Late
 - Mild loss of muscle tone, reflexes and bulk (atrophy)
- Perform a focused physical examination for disease of the neuromuscular junctions.
 - Weakness of proximal muscles of face
 - Eyelids – ptosis
 - Eyes – double vision
 - Face – weakness
 - Speech – slurred
 - Chewing / swallowing dysphagia
 - Weakness worsens with exercise (fatigability) and improves with rest
 - Tone, reflexes, muscle bulk – normal
- Perform a focused physical examination for dystrophia myotonica.
 - Definition: Combination of muscular dystrophy and myotonia
 - Clinical
 - Wasting (atrophy, dystrophic)
 - Face
 - Neck
 - Distal part of limbs
 - Frontal baldness
 - Cataracts
 - Atrophy of ovaries/testicles

Useful background: Distribution of muscle wasting or weakness

| Pattern | Possible causes |
|------------------------|---|
| ➤ Focal (one limb) | Nerve root or peripheral nerve pathology |
| ➤ Proximal (bilateral) | Myopathy (no sensory loss) |
| ➤ Distal (bilateral) | Peripheral neuropathy (distal sensory loss) |

Source: Filate W, et al. *The Medical Society, Faculty of Medicine, University of Toronto* 2005, page 163.



- Take a directed history of the causes of muscle weakness.
- Cerebral disease
 - Hemiparesis
 - Paraparesis-anterior cerebral artery
- Spinal cord disease
 - Transverse myelitis
 - Epidural abscess
 - Extradural tumor
 - epidural hematoma
 - herniated intervertebral disk
 - spinal cord tumor
- Peripheral nerve disease
 - Guillain Barre syndrome
 - Acute intermittent porphyria
 - Arsenic poisoning
 - Toxic neuropathies
 - Tick paralysis
 - Neuromuscular junction disease
 - Myasthenia gravis
 - Botulism
 - Organophosphate poisoning
- Neuromuscular junction disease
 - Myasthenia gravis
 - Botulism
 - Organophosphate poisoning
- Muscle disease (no sensory loss; excess tone, atrophy, fasciculations)
 - Polymyositis
 - Rhabdomyolysis-myoglobinuria
 - Acute alcoholic myopathy
 - Electrolyte imbalances
 - Endocrine disease
 - Myopathy
 - Non progressive or relatively non progressive congenital myopathies
 - Inflammatory myopathies
 - Toxoplasmosis, trichinosis, polio
 - Idiopathic-polymyositis, dermatomyositis
 - Collagen vascular disease
 - Metabolic myopathies
 - Glycogenoses

Modified from: Karkal SS. *Updates Neurology* 1991, pages 31 to 39.



- Reflexes
- Other findings
 - Ptosis
 - Diplopia
 - Myotonia
- Proximal weakness
 - Myopathy
 - Neuromuscular junction disease e.g. myasthenia gravis
 - Neurogenic eg motor neurone disease, polyradiculopathy
- Proximal myopathy with peripheral neuropathy:
 - Paraneoplastic syndrome
 - Alcohol
 - Hypothyroidism
 - Connective tissue diseases

Abbreviations: CNS, central nervous system; IBM, inclusion body myositis; PNS, peripheral nervous system

Adapted from: Ghosh AK. *Mayo Clinic Scientific Press* 2008, Table 19-16, page 771; Table 19-17, page 773; Talley NJ, et al. *Maclennan & Petty Pty Limited*, 2003, Table 10.29, page 428; Hauser SC, et al. *Mayo Clinic Gastroenterology and Hepatology Board Review*, 3rd Review, page 773.

Useful background: Classification of muscular dystrophy

- Duchenne (Pseudo-hypertrophic)
 - Affects only males (sex linked recessive)
 - Calves and deltoids: hypertrophied early, weak later
 - Proximal weakness: early
 - Dilated cardiomyopathy
- Limb girdle type
 - Males or females (autosomal recessive), onset in the third decade
 - Shoulder or pelvic girdle affected
 - Face and heart usually spared
- Facio scapulo humeral type (Landouzy-Dejerine)
 - Males or females (autosomal dominant)
 - Facial and pectoral weakness with hypertrophy of deltoids
- Ocular myopathy (Hutchinson)
- Distal myopathy (Gowers)



- Congenital
 - Benign congenital hypotonia
 - Central core disease
 - Nemaline myopathy
 - Myotubular myopathy
 - Arthrogryphosis multiplex congenital
- Myotonic muscular dystrophy
 - Myotonia congenita
 - Dystrophia myotonica
 - Paramyotonia congenita

Adapted from: Burton JL. *Churchill Livingstone*, 1971, pages 91 and 92; Hauser SC, et al. *Mayo Clinic Gastroenterology and Hepatology Board Review*, 3rd Review, page 771.

- Perform a focused physical examination for (Becker) muscular dystrophy (MD).
 - Demography
 - Young adult male
 - Family history of MD
 - Face
 - No facial muscle weakness
 - Calves
 - Pseudohypertrophy of calves.
 - Back
 - Proximal weakness of the lower extremities
 - In later stages more generalized muscle involvement
 - Kyphoscoliosis

Adapted from: Baliga RR. *Saunders/Elsevier* 2007, page231.

- Take a directed history and perform a focused physical examination for myotonia dystrophia.
 - Definition: Continued contraction of muscle after voluntary contraction ceases, followed by impaired relaxation
 - Leg
 - Leg weakness (difficulty in kicking a ball)
 - “Pseudo-drop attacks” (weakness of quadriceps muscles).
 - pharyngeal dysphagia (esophageal involvement)



- GI
- GU
 - Gonadal atrophy (impotence)
- Lung
 - Recurrent respiratory infection (weakness of muscles of bronchioles)
- Eyes
 - Ptosis, bilateral or unilateral .Differentiate bilateral ptosis if myotonia from
 - Myasthenia gravis
 - Congenital muscular dystrophies
 - Ocular myopathy
 - Syphilis
 - Cataracts
 - Difficulty in opening the eye after firm closure.
- Face
 - Wasting of temporalis, masseters and sternomastoid muscles
 - Frontal baldness (Is the patient may wearing a wig?).
- Neck
 - “swan neck”.
- Hands
 - Development of myotonia while shaking hands with the patient, note the myotonia (distal weakness)

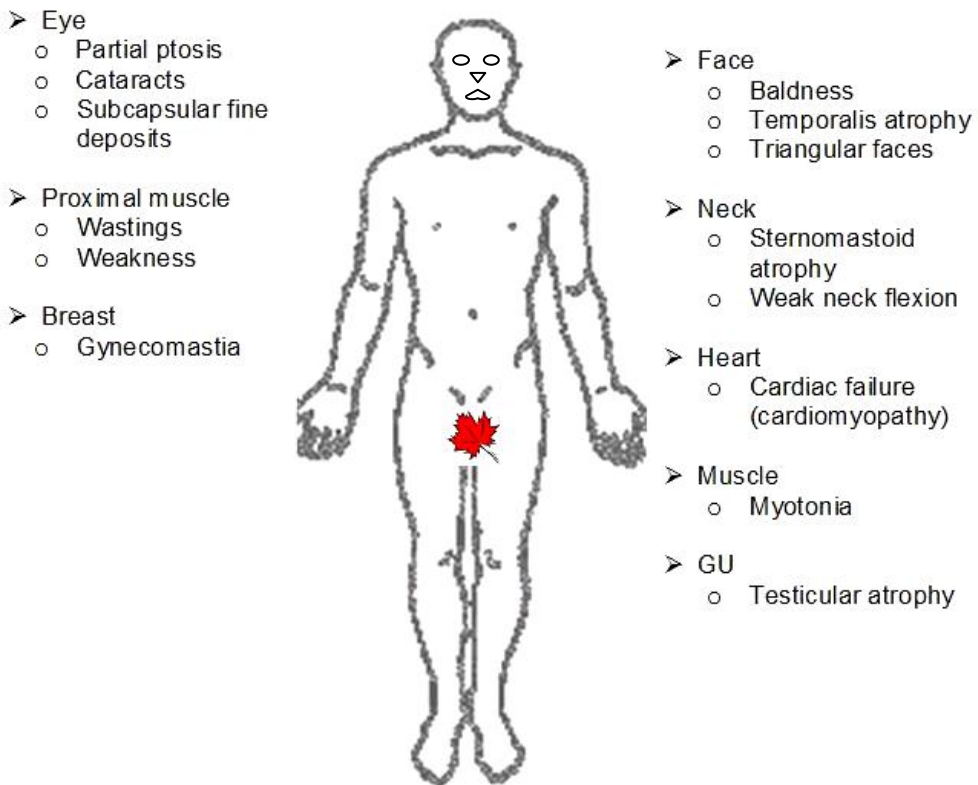
Adapted from: Baliga RR. *Saunders/Elsevier* 2007, pages 168 and 169.

- Perform a focused physical examination for limb girdle dystrophy.
- Definition
 - Weakness and wasting of muscles of shoulder and/or pelvic girdle, but never the face occur
 - Shoulder girdle
 - Biceps
 - Brachioradialis
 - Wrist extensors
 - Deltoids
 - Pelvic girdle
 - In the early stages of the disease
 - Weak hip flexors and glutei
 - Wasting medial quadriceps and tibialis anterior
 - Hypertrophy of lateral quadriceps and calves

Adapted from: Baliga RR. *Saunders/Elsevier* 2007, page 185.



Useful background: Dystrophia myotonica



Adapted from: Talley NJ, et al. *Maclennan & Petty Pty Limited* 2003, Table 10.30, page 428; Table 10.59, page 429.

SO YOU WANT TO BE A NEUROLOGIST!

Q. What conditions cause both a proximal myopathy and a peripheral neuropathy?

- A.
- | | |
|---------------------------|------------------------------|
| ○ Paraneoplastic syndrome | ○ Hypothyroidism |
| ○ Alcohol | ○ Connective tissue diseases |

Source: Talley NJ, et al. *Maclennan & Petty Pty Limited* 2003, Tables 10.29 and 10.30, page 428.



Muscle Cramps

- Definition: “Muscle cramps are sudden, involuntary contractions of one or more muscle groups....caused by hyperexcitability of the anterior horn cells or peripheral nerves that subserve them” (Devonshire V, et al. Chapter 21. In: Therapeutic Choices. Grey J, Ed. 6th Edition, *Canadian Pharmacists Association*: Ottawa, ON, 2011, page 270).
- Causes
 - Inherited
 - Immune (antibodies against voltage-gated potassium channels)
 - Iatrogenic (medications)
 - Idiopathic (commonest cause)
 - Acute depletion of ECV
 - Metabolic
 - Hypothyroidism
 - Renal failure
 - Cirrhosis
 - Pregnancy
- Differential
 - Muscle
 - CNS
 - Spasticity
 - Myalgia
 - Dystonia (“co-contraction of agonist / antagonist muscles during a movement or posture (Grey J, Therapeutic Choices. 6th Edition, *Canadian Pharmacists Association*: Ottawa, ON, 2011, page 270)
 - Contractures
 - Tetany
 - RLS (restless legs syndrome); “....a neurological disorder characterized by an unpleasant sensation in the legs accompanied by an urge to move the legs, especially at bedtime” (Hafontaine A-L, et al. Chapter 22. In: Therapeutic Choices. Grey J, Ed. 6th Edition, *Canadian Pharmacists Association*: Ottawa, ON, 2011, page 274).



Myasthenia gravis

- Definition: Weakness of the eye and facial muscles that worsens with repeated contraction

Useful background

- Likelihood ratio for clinical history and physical findings in a person with symptoms for myasthenia gravis (MG)

| | PLR |
|--|-----|
| ➤ MG more likely | |
| ○ Abnormal sleep test | 53 |
| ○ Peek sign | 30 |
| ○ Abnormal ice test | 24 |
| ○ Positive response to an anticholinesterase test | 15 |
| ○ The history 'speech becoming unintelligible during prolonged speaking' | 4.5 |

Abbreviations: PLR+, makes the diagnosis more likely

Source: Simel, DL, et al. *JAMA* 2009, Table 34-3, page 460.

- Factors which increase the pretest probability of finding MG.
 - Patients with asymmetric fluctuating eyelid ptosis
 - Patients with extraocular dysmotility not referable to a single nerve
 - Patients with weakness of other specific muscles
 - Young women of child-bearing age, and men and women aged approximately 70 years

Source: Simel DL, et al. *JAMA* 2009, page 460.

- Perform a focused physical examination for myasthenia gravis.
- Definition
 - Painless muscle weakness (fatigability) which increases with exercise and in the evening
- Physical examination
- Eyes
 - Worsening of ptosis after sustained upward gaze for at least 45 seconds
 - Diplopia and variable squint

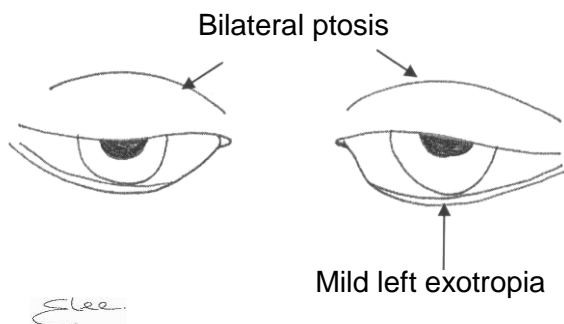


- Face
 - Snarling face when the patient attempts to smile
- Speech
 - Speech is nasal.
- Muscles
 - Weakness without loss of reflexes, or alteration of sensation or coordination. The weakness may be generalized; it may affect the limb muscles, often proximal in distribution, as well as the diaphragm and neck extensors.
 - Muscle wasting is rare, and presents late in the disease.
- Associations
- Endocrine
 - Thyrotoxicosis
 - Hypothyroidism)
 - Diabetes mellitus
- MSK
 - Rheumatoid arthritis
 - Dermatomyositis
 - SLE
 - Sjogren's disease
 - Sarcoidosis
- Skin
 - Pemphigus
- Autoimmune
 - Pernicious anemia
- Differentiate from
 - Botulism
 - Eaton-lambert syndrome
 - Myasthenic disorder, often associated with bronchial small cell carcinoma
 - Commonly, weakness of truncal and proximal limb muscles

Adapted from: Baliga RR. *Saunders/Elsevier* 2007, pages 187 and 188.



Myasthenia gravis



- Myasthenia gravis may mimic any ocular disorder causing diplopia
- Most often it mimics weakness of the superior rectus muscle or medial rectus muscle (i.e. difficulty with sustained elevation or adduction of the eye, respectively)
- Clues to the diagnosis of myasthenia gravis are associated ptosis, fluctuating course, and normal pupils

Source: McGee SR. *Saunders/Elsevier* 2007, Figure 55-3, page 699.

THIS IS FOR THE NEUROLOGY RESIDENT

Q1. What is myasthenic crisis?

A1. Exacerbation of MG, especially bulbar and respiratory involvement, leading to need for ventilation.

Q2. What is cholinergic crisis?

A2. Excessive sensitivity to cholinergics in MG, such as in myasthenic crisis, with excessive salivation, confusion, lacrimation, miosis, pallor and collapse.

Motor Neuron Disease

- Functional Neuroanatomy
 - Anterior horn cells
 - Progressive muscular atrophy from involvement of the LMN
 - Pyramidal tracts
 - Amyotrophic lateral sclerosis
 - Motor cranial nerve nuclei in pons and medulla
 - Progressive bulbar palsy



- Perform a focused physical examination for motor neuron disease.
 - Anterior horn cells
 - Muscle wasting (often starting in hands)
 - Fasciculations decreased deep tendon reflexes (DTR)
 - Pyramidal tracts
 - UMN signs in legs
 - Weakness
 - No atrophy
 - Increased DTRs
 - Bobinski reflex positive
 - When LMN signs later develop in legs, DTRs are lost
 - Cranial nerve nuclei in pons and medulla
 - Pseudobulbar palsy
 - Muscles are stiff, spastic
 - Tongue is stiff but not wasted
 - Positive jaw jerk

Useful background: Common etiologies of neuromuscular weakness

| Location of Lesion | Common Etiology |
|-------------------------------------|---|
| ➤ Upper motor neuron | <ul style="list-style-type: none"> ○ Cerebrovascular disease ○ Multiple sclerosis ○ Brain tumor |
| ➤ Lower motor neuron | <ul style="list-style-type: none"> ○ Polyneuropathy (diabetes, alcoholism) ○ Entrapment neuropathy ○ Trauma |
| ➤ Neuromuscular junction/
muscle | <ul style="list-style-type: none"> ○ Myasthenia gravis ○ Drug-induced myopathy ○ Thyroid disease ○ Polymyositis |

Source: Filate W, et al. *The Medical Society, Faculty of Medicine, University of Toronto* 2005, page 719.

- Perform a focused physical examination to determine a neuromuscular cause of weakness.
 - Upper motor neuron disease ("pyramidal tract disease" or "central weakness")
 - Lower motor neuron disease ("denervation disease" or "peripheral weakness")
 - Consider muscle disease in any patient with symmetric weakness of the proximal muscles of the arms and legs
 - Associated with muscle pain, dysphagia, and weakness of the neck muscles



- Neuromuscular junction
 - Consider in patients whose weakness varies during the day or who have ptosis or diplopia. Associated abnormalities of sensation, tone, or reflexes of the weak limb exclude muscle or neuromuscular junction disease, and argue for upper or lower motor neuron lesions.
- Muscle disease
 - Primary disease of muscle (myopathy) causes weakness.
 - There is no sensory loss with myopathy (an important clue)
 - The motor weakness is similar to that of the lower motor neurone type.
 - There are two major patterns: proximal myopathy and distal myopathy
 - Proximal myopathy is the more common form. On examination there is proximal muscle wasting and weakness.
 - Reflexes involving these muscles be reduced.

Adapted from: McGee SR. *Saunders/Elsevier* 2007, page 716; Talley NJ, et al. *Maclennan & Petty Pty Limited* 2003, page 426.

Useful background: Causes of proximal weakness and myopathy

- Myopathy
 - Congenital myopathies (rare)
 - Acquired myopathy (mnemonic, PACE, PODS)
 - P**olymyositis or dermatomyositis
 - A**lcohol, **A**IDS (HIV infection)
 - C**arcinoma
 - E**ndocrine - e.g. hyperthyroidism, hypothyroidism, Cushin's syndrome, acromegaly,
 - H**ypopituitarism
 - P**eriodic paralysis (hyperkalaemic, hypokalaemic or normokalaemic)
 - O**steomalacia
 - D**rugs - e.g. clofibrate, chloroquine, steroids, Zidovudine
 - S**arcoidosis
 - Hereditary muscular dystrophy
 - Duchenne's (pseudohypertrophic)
 - Affects only males (sex-linked recessive)
 - Calves and deltoids: hypertrophied early, weak later
 - Proximal weakness: early
 - Dilated cardiomyopathy
 - Becker
 - Affects only males (sex-linked recessive)
 - Similar clinical features to Duchenne's except for less heart disease, a later onset and less rapid progression



- Limb girdle
 - Males or females (autosomal recessive), onset in the third decade
 - Shoulder or pelvic girdle affected
 - Face and heart usually spared
- Facioscapulohumeral
 - Males or females (autosomal dominant)
 - Facial and pectoral weakness with hypertrophy of deltoids
- Dystrophia myotonica (autosomal dominant)

- Neuromuscular junction disease, e.g. myasthenia gravis
- Neurogenic, e.g. motor neurone disease, polyradiculopathy, Kufelberg-Welander disease (proximal muscle wasting and fasciculation due to anterior horn cell disease—autosomal recessive)

Adapted form: Davies, IJT. *Lloyd-Luke (medical books) LTD* 1972, page 300; Talley NJ, et al. *Maclennan & Petty Pty Limited* 2003, Table 10.29, page 428.

- Perform a focused physical examination to distinguish upper and lower motor neuron lesions.
- Upper motor neuron lesions
 - Weakness LL – FA □
 UL – EA □
 - ↑ tone (may be clasp-knife and often associated with clonus)
 - ↑ reflexes (except for the superficial reflexes [e.g. abdominal], which are absent).
 - There is an extensor (Babinski) plantar response (up-going toe)
 - No fasciculations
- Lower motor neuron lesions
 - Weakness D > P
 F = E
 - ↓ tone
 - ↓ reflexes
 - Plantar response is normal or absent
 - Fasciculations

Abbreviation: LL, lower limb; UL, upper limb; EA, extensors and abductors; FA, flexors and abductors; D, distal; P, proximal

Source: Talley NJ, et al. *Maclennan & Petty Pty Limited* 2003, Table 10.23, page 418.



Useful background: Diagnostic approach to upper motor neuron weakness

| Distribution of Weakness | STEP ONE | | STEP TWO | |
|--------------------------|--|--|---|--|
| | Diagnostic Possibilities | Additional Finding | Location of lesion | |
| ➤ Left monoparesis | <ul style="list-style-type: none"> ○ Right cerebral hemisphere ○ Right brainstem ○ Left spinal cord | <ul style="list-style-type: none"> - New seizures | <ul style="list-style-type: none"> - Right cerebral hemisphere | |
| ➤ Right hemiparesis | <ul style="list-style-type: none"> ○ Left cerebral hemisphere ○ Left brainstem ○ Right spinal cord | <ul style="list-style-type: none"> - Aphasia - Right homonymous hemianopia - Left sixth nerve palsy - Loss of sensation left arm and leg; face spared | <ul style="list-style-type: none"> - Left cerebral hemisphere - Left cerebral hemisphere - Left brainstem - Right spinal cord | |
| ➤ Paraparesis | <ul style="list-style-type: none"> ○ Bilateral lesion of thoracic cord or above | <ul style="list-style-type: none"> - Sensory level at midchest; normal arm strength and reflexes - Spine tenderness between scapulae | <ul style="list-style-type: none"> - Bilateral lesion, thoracic cord | |
| ➤ Tetraparesis | <ul style="list-style-type: none"> ○ Bilateral lesion of cervical cord or above | <ul style="list-style-type: none"> - Hyperactive jaw jerk - Dementia - Sensory level upper chest - Absent biceps reflexes but hyperactive triceps reflexes | <ul style="list-style-type: none"> - Bilateral lesion, cerebral hemispheres - Bilateral lesion, cervical cord | |

Printed with permission: McGee SR. *Saunders/Elsevier*, 2007, Table 57-5, page 722.



- Perform a take focused physical examination for motor neuron disease (MND) in the adult.
- Definition
 - Bulbar or pseudobulbar palsy
 - Amyotrophic lateral sclerosis
 - Flaccid arms and spastic legs.
 - Progressive muscular atrophy
 - Lesion in the anterior horn cells
 - Retention of deep tendon reflexes
 - Severe muscular atrophy of distal muscles
 - Primary lateral sclerosis (rare): signs progress from an UMN to a LMN picture
- Upper limbs
 - Fasciculations
 - Reflexes
 - Painless weakness
- Lower limbs
 - Spasticity
 - ↑ reflexes
 - Up-going plantars
- Cranial
 - Dysarthria and dysphagia.
 - Sluggish palatal movements, absent gag reflex, brisk jaw jerk.
 - Combination of the above signs
 - Presence of upper and lower motor neuron involvement of a single spinal segment, and motor dysfunction involving at least two limbs or one limb and bulbar muscles.
 - Sensory symptoms or signs are not seen.
 - Ocular movements are not affected.
 - Cerebellar or extrapyramidal systems are not affected.
 - Sphincters are involved late, if at all.
 - Emotional lability (if there is bulbar involvement).

Adapted from: Baliga RR. *Saunders/Elsevier* 2007, pages 193 and 194.

- Power grading system for weakness of the limbs
 - 0- Nil movement
 - 1 -Flicker of movement
 - 2 -Movement cannot overcome gravity
 - 3 -Movement cannot overcome any resistance
 - 4- Movement against resistance is weaker than “normal”
 - 5 –Normal



Adapted from: Filate W, et al. *The Medical Society, Faculty of Medicine, University of Toronto* 2005, page 164; and McGee SR. *Saunders/Elsevier* 2007, Table 57-1, page 709.

Gait, Posture, and Movement Disorders and Parkinsonism

- Give four terms to describe different abnormalities of movement.
 - Tremor
 - Choreiform movements
 - Athetoid movements
 - TIC
 - Myoclonic movements

Useful background: Movement disorders

- Astereognosis
 - Inability to appreciate size or shape of objects held in his hand.
- Involuntary movements
 - Tremor, choreiform, athetoid, tic, myoclonic movements
- Tremor
 - Extrapyramidal-tremor at rest
 - Tremor occurring in a body part that is not voluntarily activated and when it is supported completely against gravity.
 - Disappears with sleep
 - ↑ by emotion and fine movements
 - ↓ by strong movements
 - Intention tremor whose amplitude increases during visually guided movements (eg finger to nose test)
 - Cerebellar-intention (“action”) tremor
 - absent at rest
 - ↑ by any voluntary movement
 - GPI trombone-like tremor of the tongue
 - Present both at rest and on attempted protrusion
 - Fine tremors- caused by fatigue, anxiety, emotion, thyrotoxicosis, as well as poisoning with alcohol, tobacco, cocaine, mercury
- Choreiform movements
 - Sudden, brief, involuntary, jerky movements
 - The same movement is never repeated in succession
 - Due to disease of the extrapyramidal system
- Athetoid movements
 - Slow, writhing, sinuous movements of periphery
 - ↑ by emotion and movement.
 - Due to disease of the extrapyramidal system



- Tic
 - Explosive repetition of the same movement, especially of facial muscles
 - Commonly seen with psychiatric disturbance.
- Myoclonus
 - Sudden contraction of large muscle or muscle group
 - Such as occurs with epilepsy or hiccup (singultus)

Adapted from: Simel DL, et al. *JAMA* 2009, Box 38-1, page 506.

Useful background: The physiological components of gait

- Antigravity support: Provided by reflexes located in the spinal cord and brainstem; anti-gravity reflexes are responsible for maintaining full extension of hips, knees, and neck.
- Stepping: a basic patten of movement based on sensory input from soles and body (including inclination forward and from side to side) and integrated at the midbrain level.
- Equilibrium: Responsible for maiantaining balance and centre and gravity during shifting of weight from one foot to the other.
- Propulsion: Involves leaning forward and slightly to one side, permitting the body to fall a certain distance before being checked by leg support.

Source: Mangione S. *Hanley & Belfus*, 2000, page 12.

Useful background: Gaits

- High-stepping gait
 - Usually unilateral and results from foot-drop.
- Causes
 - Lateral popliteal nerve palsy.
 - Poliomyelitis.
 - Charcot-Marie-Tooth disease.
 - Lead or arsenic poisoning.
- Scissor gait
 - Seen in spastic paraplegia
 - The adductor spasm may be so severe as to lead to the legs crossing in front of one another



- Waddling gait
 - The legs are held wide apart and the patient shifts weight from one side to the other as he walks.
 - Lumbar lordosis
- Causes
 - Advanced pregnancy
 - Proximal weakness (Cushing's syndrome, osteomalacia, thyrotoxicosis, polymyositis, diabetes, hereditary muscular dystrophies.)

Adapted from: Burton JL. *Churchill Livingstone* 1971, pages 88 and 89.

- Perform a focus physical examination of a gait (movement) disorder.
- History
 - Worsening of gait disturbance at night (because of darkness)
 - Association with vertigo or light-headedness
 - Association with pain, numbness, or tingling in the limb
 - Presence of muscle weakness
 - Presence of bladder or bowel dysfunction
 - Presence of stiffness in the limbs
 - Problems initiating or terminating walking
- Walking: Inspect how the patient
 - Gets up from a chair (useful, for example, in Parkinson's disease or limb girdle dystrophy)
 - Initiates walking
 - Walks at a slow pace
 - Walks at a fast pace
 - Walks on toes (toe-walking cannot be done by patients with Parkinson's disease, sensory ataxia, spastic hemiplegia, or paresis of the soleus or gastrocnemius muscle)
 - Walks on heels (unmasks patients with motor ataxia, spastic paraplegia, or foot drop)
- Balance
 - Ask the patient to sit in a chair with his/her back straight against the back of the chair.
 - Ask them to keep their arms folded while standing. Can they:
 - Sit without leaning or sliding?
 - Arise from chair in single movement without use of arms (and at end of gait assessment, sit down in a smooth motion without falling)?
 - Stand immediately without need for support?



- With the patient standing, ask them to place their feet together (without support). Can they:
 - Stand without support for > 30 seconds?
 - Stand without loss of balance with their eyes closed?
 - Turn their neck to both sides and look upward without loss of balance?
 - Maintain balance despite gentle nudging on sternum (nudge three times)?
 - Stand on 1 leg without loss of balance?
 - Reach up and pick a object off a shelf, then reach down and pick up a object off the floor, without loss of balance (this last maneuver can be done at the end of the patients “walk across the room”)?

➤ Gait

- Then, ask the patient to walk across room, turn and walk back as quickly as possible. Can they:
 - Initiate gait immediately?
 - Maintain normal step height, clearing the floor with their feet, but by a maximum of 5 cm (greater than this is “high stepping”)
 - Maintain a step length between stance toe and swinging heel that is at least the length of the patient’s foot?
 - Maintain step symmetry and continuity (raises heel of one foot as other foot touches down)?
 - Maintain a straight path and normal truncal stability (no swaying back, knee flexion, or arm abduction)?
 - Maintain a normal walk stance with feet almost touching as they pass each other (observe from behind)?
 - Turn without discontinuity of steps or motion?

Useful background:

➤ Action tremors

- Postural
- Tremor that occurs while voluntarily maintaining a position against gravity.
- Kinetic
- Tremor occurring during any voluntary movement
- Simple. Tremor occurring during voluntary movements that are not target directed.
- Task Specific. Tremor that appears or is exacerbated by specific tasks (eg writing)



Useful background

➤ Structures Involved in Walking

- Basal ganglia
 - anatomic movements which accompany walking
 - Initiate walking
- Midbrain, locomotor region
 - Anti-gravity reflexes
- Cerebellum
 - Maintains posture, balance, characteristic of movement (trajectory, velocity, acceleration)
- Spinal cord
 - Sense and proprioception
 - Anti-gravity reflexes

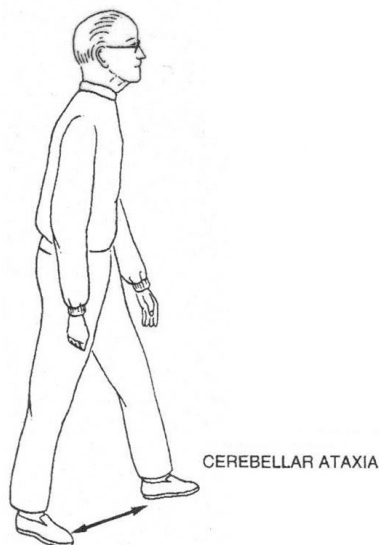➤ Definitions

- Dysmetria – inability to control one’s range of motion
- Dysdiadochokinesia – inability to perform rapid alternating movements
- Ataxia – defective voluntary muscle coordination
- Dysarthria – difficult or defective speech attributed to impairments of the tongue
- Nystagmus – constant involuntary cyclical movements of the eyes

Source: Jugovic PJ, et al. *Saunders/ Elsevier* 2004, page 166.

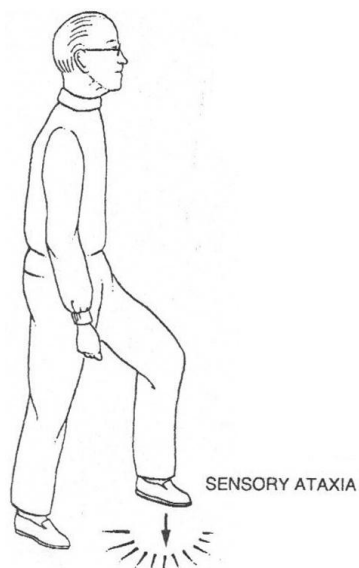
➤ Cerebellar Ataxia Gait

- Clinical
 - Irregular rate, range, direction of gait
 - Tendency to fall in any direction
 - Wide-base gait
 - Standing- titubation, may lead to falls, worse when feet together, unaffected by opening or closing eyes
 - Steps- vary in length, swaying (looks like drunken swagger)
 - Other cerebellar signs present- limbs ataxia, nystagmus)
- Cause
 - Cerebellar disease
 - Chronic alcoholism
 - Demyelination
 - Infection
 - Inherited



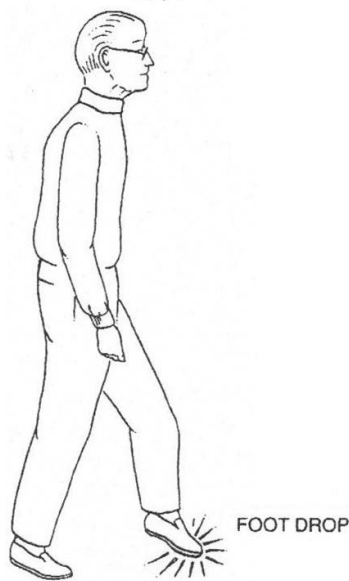
➤ Sensory Ataxia Gait

- Clinical
 - Standing wide stance
 - High stepping gait
 - Wide gait, worsen when opening/closing eyes; sway/fall only when eyes closed (difficult walking at night)
- Cause
 - Impaired sensory and proprioception in lower limbs
 - Peroneal nerve palsy
 - Tertiary syphilis



➤ High stepped gait ("foot drop")

- Clinical
 - No dorsiflexion of ankle while walking: foot is raised high and then brought down quickly, in a flopping manner
 - Asymmetrical wear on soles of shoes
 - Waddling gait if proximal girdle muscles are also affected (eg. motor neuron disease, progressive muscular atrophy); known as the anserine (duck-like waddling) gait.
- Cause
 - Motor neuron disease
 - Peripheral neuropathy
 - Peroneal neuropathy
 - Spinal muscle atrophy (C-M-T gait)



➤ Charcot Marie-Tooth (CMT) Gait

- Clinical
 - High steppage gait (even with high elevation of knees)
 - Pes cavus (equinovarus deformity)
 - Plantar flexion
 - Inversion and adduction of foot
 - Calluses/foot ulcers



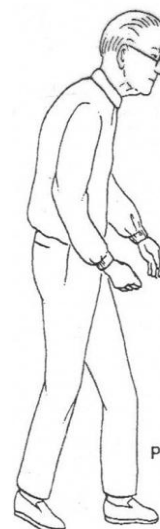- Impaired touch, pain, proprioception sensation
- Absent deep tendon reflex
- Causes
 - Progressive, hereditary degeneration of peripheral nerves and nerve roots (peroneal nerve paralysis)
 - Slow, progressive wasting of muscles of feet/legs (“stork legs”) and then hands/arms

➤ Anserine gait

- Clinical
 - Standing
 - legs spread wide, shoulder sloped forward
 - lumbar lordosis, protruding abdomen
 - Walking
 - Getting up from chair: Gower’s maneuver – bend forward, hands on knees, slide hands up the thighs and pushing up to standing
 - Short steps, waddling from side-to-side (duck-like waddling)
 - Differentiate from with high stepped gait
- Cause
 - Dystrophy of girdle muscles
 - Progressive muscular atrophy

➤ Parkinsonian Gait

- Clinical
 - Slow standing up and starting to walk
 - Standing head and chest bent forward, flexed arms at elbows and knees flexed hips
 - Slow small steps with no arm swinging (automatic movement)
 - Festination – accelerating of walking, once walking started
 - Propulsion- tendency to fall forward, calling festination
 - Walking – further forward bending to chest, non-swinging arms, legs bent at ankles, knees hips
 - Poor balance, poor compensation of flexion/extension, resulting in frequent falls
 - Toes not always on ground

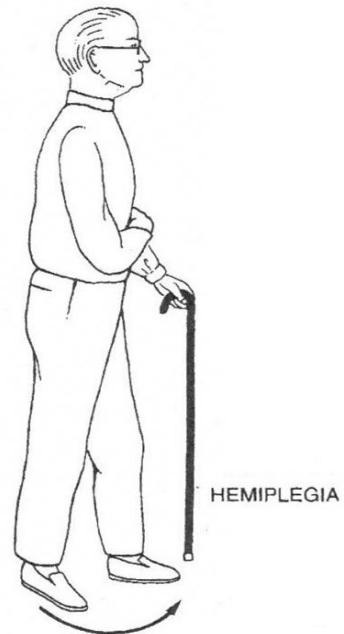

PARKINSON'S DISEASE



➤ Spastic Hemiplegia (circumduction gait)

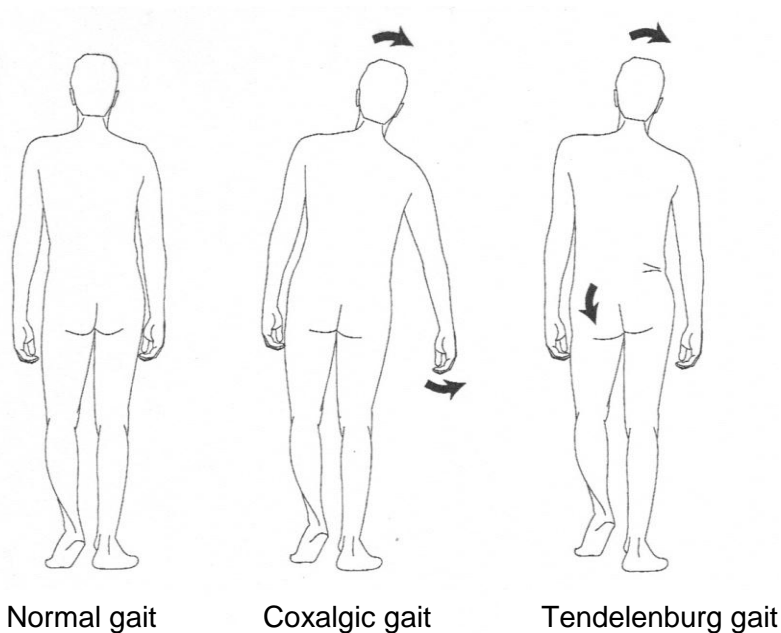
- Clinical
 - Standing: (affected side)
 - Adduction/flexion of fingers, wrist, elbows
 - Extension of ankle, knee, hip
 - Internal rotation of foot
 - Walking (affected side)
 - Upper body tilts to uneffected side
 - Foot/leg of affected side swing in a semi-circle
 - Slow, difficult walk
- Cause
 - Internal capsule hemisphere CVA



➤ Apraxic “magnetic gait”

- Clinical
 - Standing –feet wide apart
 - Walking
 - flexion of upper trunk, arms, knees
 - decreased automatic arm swing
 - shuffling gait
 - normal sensation and reflexes; Babinski plantar reflex may be up-going (abnormal)
- Cause
 - Frontal lobe disease
 - Normopressure hydrocephalus
 - Aging





➤ Trendelenburg gait (abnormal gluteus medius and minimus)

In the Trendelenburg gait (from ineffective or weak hip abductors), the opposite pelvis falls excessively (arrow), and the conspicuous but opposing swings of the upper body and pelvis create the impression of the hinge between the sacral and the lumbar spine.

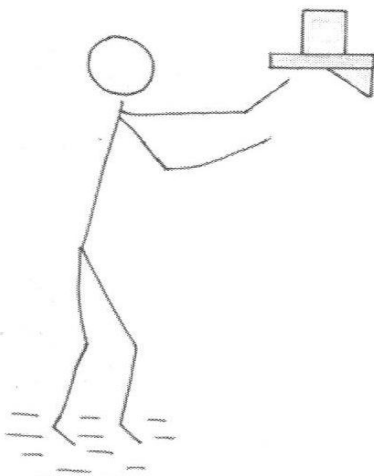
- The patient is bearing weight on the affected right hip, with and ineffective right hip abductors (Trendelenburg gait).
- The trunk may lean over the abnormal leg during stance (arrow).
- Clinical
 - During walking, a slight dip of the opposite pelvis is normal during stance phase on one limb.
 - The finding of excessive drop of the opposite pelvis is the abnormal Trendelenburg gait.
 - When the abnormality is bilateral, the pelvis waddles like that of a duck.
 - Like patients with the coxalgic gait ['Coxalgic Gait'], patients with Trendelenburg gait may lean their trunk over the abnormal leg during stance, but the lean lacks the dramatic lurch seen in coalgic gait, and the opposing sways of the ipsilateral shoulder and opposite pelvis make it
- Causes
 - Occurs when the gluteus medius and menimus do not function properly.



- These two muscles abduct the hip, an action that supports the opposite pelvis and prevents it from dropping excessive amounts during the normal single-limb stance.

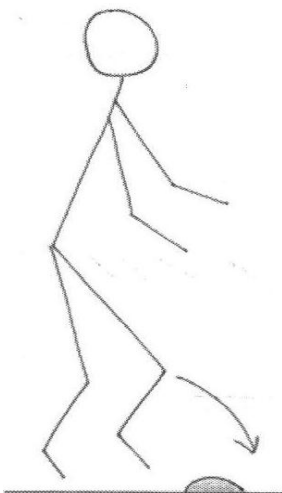
➤ Coalgic gait

- In both abnormal gaits, the trunk may lean over the abnormal leg during stance (arrow).
- In patients with hip pain and coxalgic gait, the trunk lean and accompanying ipsilateral arm movement (arrow) is more dramatic ('lateral lurch'), and the opposite pelvis does not fall excessively.



➤ Proximal myopathy

- Causes
 - Metabolic (K^+ , Ca^{2+} excess/ deficiency)
 - Alcoholism
 - Steroids
 - Thyroid disease
 - Inherited disease
 - Inflammatory (myositis)
 - Myasthenia
- Clinical
 - Difficulty reaching up



➤ Spasticity

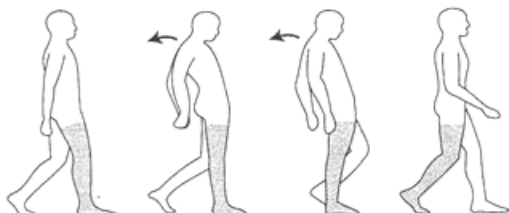
- Causes
 - Spinal cord disease
 - Cervical myelopathy
 - Multiple sclerosis
 - Stroke (legs held in adduction at the hip, thighs rub together, kness slide over each other)
- Clinical
 - Easy tripping
 - Falls



Useful background: Characteristic gait of weak muscles

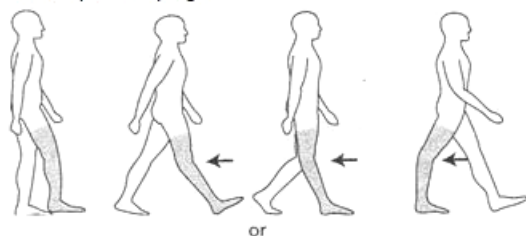
- The shading indicates the limb with the weak muscle and the black arrows indicate the diagnostic movements.

Weak gluteus maximus gait

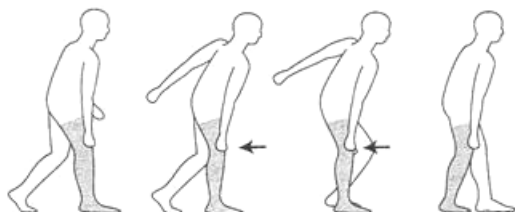


- Abnormal backward lean
 - Because both the gluteus maximus and quadriceps muscles are extensor muscles, abnormalities of these muscles produce characteristic findings during the stance phase.
 - Because the foot dorsiflexors (i.e., the weak muscles causing foot drop) are flexor muscles, abnormalities of these muscles produce characteristic findings during the swing phase.

Weak quadriceps gait

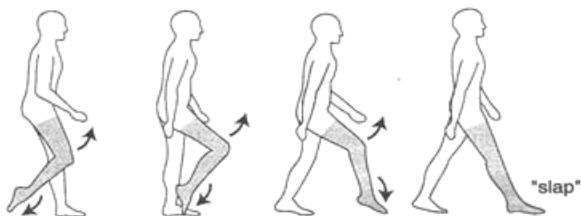


- Hyperextension of knee (genu recurvatum)



- Ipsilateral arm placed on leg to help prevent the knee from buckling

Foot drop gait



- Excessive flexion of the hip and knee during the swing phase (upper arrow)
- A slapping sound of the foot when it strikes the ground.

Adapted from: McGee SR. *Saunders/Elsevier* 2007, pages 12, 13, 60, 61, 64 and 65; Filate W, et al. *The Medical Society, Faculty of Medicine, University of Toronto* 2005, Table 17, page 169; Mangione S. *Hanley & Belfus* 2000, pages 12 to 15; Talley NJ, et al. *Maclennan & Petty Pty Limited* 2003, page 414, Table 10.21; Common types of gait abnormalities (From Swartz MH. *W. G. Saunders* 1997, with permission); and Reproduced with permission of Dr. B. Fisher, (Uof Alberta).



- Perform a focused physical examination to distinguish between rigidity and spasticity of muscle.
- Rigidity
 - ↑ tone of muscles around a joint
 - Causes by degenerative diseases, such as Parkinson's disease
- Spasticity
 - ↑ ton of muscles around a joint
 - Slowly and progressively increasing muscle tone as the joint is moved from muscle stretch
 - At the end of muscle stretch, there may be a sudden loss of the increased tone ("clasp-knife" protective relaxation of muscle)
 - Associated with damage to corticospinal (pyramidal) tract

Restless legs syndrome (RLS)

- Is a neurologic disorder characterized by an unpleasant sensation in the legs accompanied by an urge to move the legs, especially at bedtime.
- These symptoms occur when the limbs are at rest, and are relieved by movement.
- In severe cases, symptoms may extend to the arms and trunk.
- Symptoms are commonly bilateral and symmetrical, but on occasion can be unilateral.

All of the following 4 criteria are required for a diagnosis of RLS:

- An urge to move the legs, usually accompanied or causes by unpleasant sensations in the legs.
 - Symptoms begin or worsen during periods of rest or inactivity such as lying or sitting.
 - Symptoms are partially or totally relieved by movement, such as walking or stretching, for at least as long as the activity continues.
 - Symptoms are worse in the evening or at night than during the day, or occur only in the evening or at night.
 - Supportive clinical features include
 - A positive family history
 - Response to dopaminergic therapy
 - Periodic limb movements during wakefulness (PLM) or during sleep (PLMS)
- *Intermittent* RLS is defined as symptoms that are troublesome enough to require treatment but not frequent enough to require daily therapy
- *Daily* RLS involves symptoms that are frequent and bothersome enough to require daily therapy



- Patients with *refractory* RLS are those who experience inadequate response and/or intolerable side effects and/or “augmentation”

Reproduced with permission: Therapeutics Choices. Sixth Edition. Ottawa, Canada: *Canadian Pharmacist Association* 2012, page 274.

Parkinsonism, Extrapyrimal Disease, Tremor and Involuntary Movements

- Parkinson’s disease

| | | |
|--------------|---|-----------------|
| Bardykinesia | } | Asymetric onset |
| Tremor | | |
| Rigidity | | |

- Resting “cog wheel”
- Greasy skin
- No facial expression = hypomimia
- Intellectual deterioration
- On walking
 - No arm swinging
 - Small footsteps with ‘shuffling’ gait-festinant
 - Difficulty walking and turning-falls
 - Bent posture
- Definition:
 - “Parkinson’s disease (PD) is a chronic, progressive, neurogenerative disease whose cardinal features are tremor, bradykinesia and rigidity.
- Feature
 - Non-motor features such as dementia, psychosis and autonomic dysfunction (excessive sweating, bladder frequency / urgency, orthostasis [postural instability]) [and depression] often because the more disabling features as the disease progresses” (Grimes DA, et al. Chapter 23. In: Therapeutic Choices. Grey J, Ed. 6th Edition, *Canadian Pharmacists Association: Ottawa, ON, 2011, page 282*).
 - Early complaints “..... may include fatigue, loss of smell, sleep disorders, general slowness, poor handwriting and a tremulous feeling in one arm, without obvious tremor”.
 - “Postural mobility, autonomic dysfunction, dementia, impaired eye movemments, rapid progression and poor response to dopaminergic therapy are not features of early PD, and if present suggest a different diagnosis”. (Grimes DA, et al. Chapter 23. In: Therapeutic Choices. Grey J, Ed. 6th Edition, *Canadian Pharmacists Association: Ottawa, ON, 2011, page 282*).



Take a directed history and perform a focused physical examination to determine the type of a seizure.

Grey J, Therapeutic Choices. 6th Edition, *Canadian Pharmacists Association*: Ottawa, ON, 2011, page 292-293.

Useful background: Causes of Parkinson's disease

- Causes of Parkinsonism
 - Ideopathic
 - Atherosclerosis
 - Post-encephalitis
 - Post-traumatic
 - Tumor (midbrain compression)
 - Syphilis
 - Drugs
 - Hepatolenticular degeneration of Wilson's disease
 - Hypoparathyroidism

- True parkinsonism
 - Idiopathic (due to degeneration of the substantia nigra, aka Parkinson's disease or "paralysis agitans")
 - Familial
 - Drug/ toxins
 - Antagonist of D₂ receptors
 - Neuroleptics (haloperidol, risperidone, resperine, etc)
 - Anti-emetics (metaclopramide, prochlorperazine)
 - Other psychiatric drugs
 - Selective serotonin reuptake inhibitors
 - Tricyclics
 - Lithium
 - Cardiovascular drugs
 - Amiodarone
 - Calcium channel blockers (flunarizine)
 - Atorvastatin
 - Anticonvulsants
 - Valproate
 - Others
 - Cyclosporine
 - Metrodinazole
 - Caffeine & other methylxanthines
 - β-Adrenergic agonists
 - Thyroine
 - Prednisone



- Brain damage (e.g cardiac arrest, exposure to manganese or carbon monoxide)
- Postencephalitic – as a result of encephalitis lethargic or von Economo's disease
- Multiple system atrophy
- Progressive supranuclear atrophy
- Post encephalitic
- Syphilis
- Midbrain compression
- Post traumatic
- Wilson's disease (Hepato-lenticular degeneration)
- Hypoparathyroidism
- Kernicterus
- Neurologic
 - Brain tumour
 - Spinal cord trauma
 - Sleep apnea
 - Porphyria
 - Progressive supranuclear palsy
 - Shy-drager syndrome
- Pseudoparkinsonism
 - Essential tremor
- Hemiparkinsonism (presenting feature of a progressive space-occupying lesion)

Adapted from: Baliga R.R. *Saunders/Elsevier* 2007, page 138, and 139; Burton JL. *Churchill Livingstone* 1971, page 89; Ghosh AK. *Mayo Clinic Scientific Press* 2008, page 780.

- Perform a focused physical examination for Parkinsonism.
 - Tone
 - Increased
 - Cog-wheel or lead-pipe rigidity
 - Featureless face
 - Flexed posture
 - Festination
 - Increasing speed of gait on walking
 - When patient is gently pushed, festination increases (aka propulsion)
 - Tremor
 - Athetoid
 - Choreiform
 - Hemiballismus



Useful background: Types of Parkinsonian syndrome

| If: | If: | If: | If: | If: |
|--|--|---|---|--|
| Sudden onset
+ stuttering
progressor
+minimal
tremor
+lower limbs
much more
affected than
upper limb
↓
Consider
vascular
parkinsonism: | Symmetrical
disease
Younger
patient
Taking
dopamine
Antagonists of
lithium
↓
Consider
drug-induced
parkinsonism | Marked
postural
hypotension
5 BP \geq 30
mmHg fall

Sphincter
disturbance
(impotence
or urinary
symptoms)
Cerebellar
signs
↓
Consider
multisystem
atrophy | Early
progressive
dementia
Nocturnal
wandering
\pm confusion
↓
Consider
dementia
with lewy
bodies | Axial rigidity
Failure of
vertical gaze
↓
Consider
progressive
Supranuclear
palsy |

Adapted from: Davey P. *Wiley-Blackwell* 2006, page 386.

SO YOU WANT TO BE A NEUROLOGY RESIDENT!

Q. Describe the abnormal reflexes which occur in Parkinsonism!

A. That was a wasting trick: the deep tendon reflexes are normal

- Perform a directed physical examination for extrapyramidal disease.
- The most typical pathological hallmarks of Parkinson's disease are:
 - Neuronal loss with depigmentation of the substantia nigra
 - Lewy bodies, which are eosinophilic cytoplasmic inclusions in neurons consisting of aggregates of normal filaments
- Face
 - Mask-like facies
 - Absent blinking
 - Titubation (tremor of head)
 - Dribbling



- Speech
 - Soft, faint, monotones (monotonous)
 - Repetition of the end of a word (phalilalia)

- General inspection
 - Tremor (at rest, pill rolling, 4-7 hz), increased by clenching fist
 - Rigid tone (especially wrist for cogwheel rigidity)
 - Akinesia/ dyskinesia
 - Postural instability (stooped)
 - Mask-like face (lack of blinking, dysarthria)
 - Hypophnia
 - Sialorrhea
 - facial seborrhoea, depressed, tendency to protrude tongue/ tongue tremor (mask-like face)

- Coordination test
 - Coarse motor control
 - Heel from knee to ankle test
 - Finger to nose test
 - Fine motor control
 - Rapid alternating movements – tapping feet
 - Rapid alternating movements – Thumb-finger opposition
 - Rapid alternating movements – Pronate-supinate hands
 - Posture and gait
 - Regular, toe, heel, and tandem gait assessments (start hesitation, shuffling steps, loss of arm swing)
 - Examines rising from chair, and walking and turning
 - Looks for festinant gait, foot shuffling, loss of arm swing, postural instability (stooped), flexed posture, pro/ retropulsion (attempt provocation with push), slow (en bloc) turning
 - Heel from knee to ankle test, finger to nose test
 - Looks for loss of spontaneous movements
 - Blank facies
 - Stare with decreased blinking and widened palpebral fissures
 - Writing test for micrographia

- Limbs
 - Bradykinesia
 - Kinesia paradoxical- ability to perform rapid but not slow movements
 - Resting tremor (may be accentuated by person concurrently performing subtraction of “serial 7’s”)
 - Cogwheel rigidity
 - Chorea jerky, abrupt, involuntary movements



- Motor examination
 - Inspection
 - Muscle bulk
 - Fasciculation
 - Muscle tone
 - Tone (palpation)
 - Upper extremities
 - Lower extremities
 - Asymmetry
 - Graded
 - Checks for rigidity with cogwheeling (intensified with clenching other hand into fist) (upper and lower extremities)
 - Tests by flexion-extension of elbow or supination-pronation of wrist

- Upper body dyskinesia

This must be present – it is a symptom complex containing many of the following features:

 - Slowness of movement (bradykinesia)
 - Poverty of movement (mask-like facies, diminished arm swing)
 - Difficulty in initiating movement
 - Diminished amplitude of repetitive alternative movement
 - Inordinate difficulty in accomplishing some simultaneous or sequential motor acts

- Rigidity

This is usually but not always present:

 - Leadpipe rigidity, where the increase in tone is equal in flexors and extensors of all four limbs but slightly more in flexors, resulting in a part flexed 'simian' posture
 - Cog-wheel rigidity is due to superimposed or underlying tremor

- Postural instability; usually a late feature; may cause frequent falls
 - Gait
 - Festinant gait, in a posture of slight flexion

- Tremor

Absent in about one third of patients with Parkinson's disease at presentation and throughout its course in some

 - Resting, pill, pronation and supination rolling tremor of the upper limb
 - Intermittent
 - Intensified by emotion or stress, and disappears during sleep
 - The legs, head and jaw may shake as well distressing; the teeth may pound together until they become unbearably painful



- Speech
 - Monotonous
- Writing
 - Micrographia
- Reflexes – positive globellar tap
- Sleep disorders
- Autonomic involvement
- Neuropsychiatric
 - Hallucinations
 - Medication effect (exclude RBD)
 - Depression
 - Loss of serotonergic neurons
 - Cognitive impairment
 - Badyphrenia
 - Dementia (consider DLB)
 - Sensory symptoms
 - Abnormal behavior
- Anxiety
 - Akathisia
 - Stressors
- Sleep disorders
- Autonomic involvement
- Sensory symptoms
- Abnormal behavior

Useful background: Likelihood ratios of clinical findings for Parkinson disease

| Symptom diagnosing | PLR | NLR |
|--|---------|-----------|
| ➤ Shuffling gait | 3.3-15 | 0.32-0.50 |
| ➤ Bradykinesia (difficultly rising from a chair) | 1.9-5.2 | 0.39-0.58 |
| ➤ Loss of balance | 1.6-6.6 | 0.29-0.35 |
| ➤ Tremor | 1.4-11 | 0.24-0.60 |
| ➤ Rigidity | 1.3-4.5 | 0.12-0.93 |

Abbreviations: PLR, positive likelihood ratio; NLR, negative likelihood ratio

Source: Simel DL, et al. *JAMA* 2009, Table 38-4



Useful background: Other manifestations in Parkinson disease

| Manifestation | Cause |
|-----------------------|--|
| ➤ Pain | <ul style="list-style-type: none"> ○ Early morning dystonia ○ Motor fluctuations ○ Mechanical |
| ➤ Arm paresthesia | <ul style="list-style-type: none"> ○ May reflect insufficient levodopa treatment |
| ➤ Fatigue | <ul style="list-style-type: none"> ○ Multifactorial |
| ➤ Diplopia | <ul style="list-style-type: none"> ○ Medication effect ○ Poor convergence |
| ➤ Pathologic gambling | <ul style="list-style-type: none"> ○ Activation of D3 receptors in limbic striatum |
| ➤ Hypersexuality | |

Abbreviation: DLB, dementia with Lewy bodies; MAO, monoamine oxidase; RBD, rapid eye movement sleep behavior disorder; SSRI, selective serotonin reuptake inhibitor

Adapted from: Talley NJ, et al. *Maclennan & Petty Pty Limited* 2003, page 436,437; Hauser SC, et al. *Mayo Clinic Gastroenterology and Hepatology Board Review, 3rd Review*, page 778 and 779.

- Take a directed history and perform a focused physical examination to distinguish between Parkinson's disease and atherosclerotic Parkinsonism.

| | Parkinson's disease ¹ | Artherosclerotic Parkinsonism ² |
|--------------------------------|----------------------------------|--|
| Dementia | No | Yes |
| Bilateral UMN signs | No | Yes |
| Reflexes increased | No | Yes |
| Extensor plantar responses | No | Yes |
| Increased deep tendon reflexes | No | Yes |
| Pseudobulbar palsy | No | Yes |
| Epilepsy | No | Yes |

¹ idiopathic destruction of basal ganglia

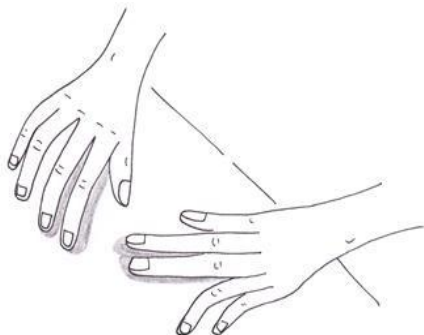
² atherosclerotic ischemia



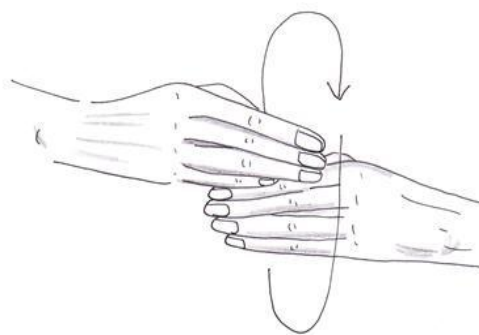
What is “the best”? The “best” clinical tests for the presence of Parkinson’s disease are: the presence of all three of tremor, bradykinesia, and rigidity. Also, useful are a positive glabella tap, soft voice and difficulty or inability to walk heel to toe.

Useful background: Special tests for bradykinesia

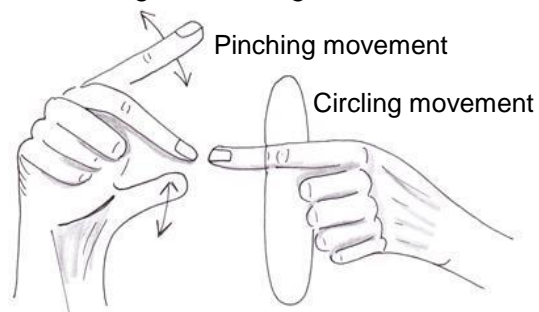
A. Tapping the fingers



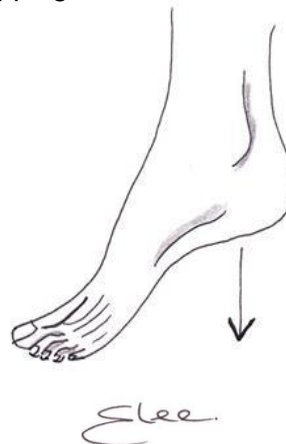
B. Twiddling



C. Pinching and circling



D. Tapping with the heel



Adapted from: Simel DL, et al. *McGraw-Hill Medical* 2009, Figure 38-1, page 507.



Useful background: Glabella tap test



Adapted from: Simel DL, et al. *McGraw-Hill Medical* 2009, Figure 38-2, page 508 and Filate W, et al. *The Medical Society, Faculty of Medicine, University of Toronto* 2005, Figure 38-1, page 507.

Useful background: Likelihood ratios for suspected Parkinson's disease

➤ Diagnosing Parkinson's disease

- Prominent rigidity on initial examination, tremor, tremor as initial symptom, tremor-dominant disease, signs are asymmetric
- Bradykinesia; a combination of tremor, bradykinesia, rigidity; paralysis or weakness, impaired consciousness, asymmetric disease, brady kinesia (akinetic/ rigid disease)
- Good response to levodopa, have a PLR < 2 for diagnosing Parkinson's disease

| Finding | PLR | NLR |
|---|---------|------------|
| ➤ Diagnosing Multiple System Atrophy | | |
| ○ Rapid progression | 2.5 | 0.6 |
| ○ Speech and/or bulbar signs | 4.1 | 0.2 |
| ○ Autonomic dysfunction | 4.3 | 0.3 |
| ○ Cerebellar signs | 9.5 | 0.7 |
| ○ Pyramidal tract signs | 4.0 | Ns |
| ○ Downgaze palsy and postural instability within first year of symptoms | 60.0 | 0.5 |
| ➤ Tremor | | |
| ○ Arms or leg shake | 1.4 -17 | 0.24- 0.25 |
| ○ Tremor of head or limbs | 11 | 0.26 |



| Finding | PLR | NLR |
|--|----------------|------------------|
| ➤ Rigidity | | |
| ○ Rigidity and bradykinesia | 4.5 | 0.12 |
| ○ Muscle stiffness | 2.3 | 0.73 |
| ➤ Facies and general symptoms or historical findings | | |
| ○ Feet freeze | 3.7 | 0.55 |
| ○ Face less expressive | 2.1 | 0.54 |
| ➤ Bradykinesia | | |
| ○ Difficulty rising from chair | 1.9- 5.2 | 0.39- 0.58 |
| ➤ Posture and motor tasks | | |
| ○ Loss of balance | 1.6 –6.6 | 0.29- 0.35 |
| ○ Shuffling gait | 3.3- 15 | 0.32 – 0.50 |
| ○ Trouble turning in bed | 13 | 0.56 (0.41-0.76) |
| ○ Trouble opening jars | 6.1 | 0.26 (0.14-0.48) |
| ○ Trouble buttoning | 3.0 | 0.33 (0.19-0.60) |
| ○ Uncontrolled limbs | 1.3 (0.53-3.1) | 0.93 (0.72-1.2) |
| ○ Micrographia (fine motor) | 2.8 –5.9 | 0.30- 0.44 |
| ➤ Tremor | | |
| ○ Tremor | 1.5 | 0.47 |
| ○ Tremor with rigidity and bradykinesia | 2.2 | 0.50 |
| ➤ Rigidity | | |
| ○ Rigidity | 2.8 | 0.38 |
| ○ Rigidity with bradykinesia | 4.5 | 0.12 |
| ➤ General findings | | |
| ○ Glabella tap | 4.5 | 0.13 |
| ○ Voice softer | 3.7 | 0.25 |
| ○ Change in speech | 2.6 | 0.73 |
| ○ Asymmetric disease | 1.8 | 0.61 |
| ○ Levodopa response | 1.2 | 0.63 |
| ➤ Bradykinesia | - | - |
| ➤ Posture and motor tasks | | |
| ○ Difficulty or inability to walk heel to toe | 2.9 | 0.32 |

Abbreviation: NLR, negative likelihood ratio; PLR, positive likelihood ratio



| | | | | | | | |
|------------|-------------|------|------|------------|------|------|----|
| | Probability | | | | | | |
| | ← Decrease | | | Increase → | | | |
| | -45% | -30% | -15% | +15% | +30% | +45% | |
| NLR
PLR | 0.1 | 0.2 | 0.5 | 1 | 2 | 5 | 10 |

Sen N out – Sensitive test; when negative, rules ot disease

Sp P in – Specific test; when positive, rules in disease

Adapted from: McGee SR. *Saunders/Elsevier* 2007, Box 57-2, page 729; Simel DL, et al. *JAMA* 2009, Table 38-2 and Table 38-3, pages 509 and 510.

DO YOU STILL WANT TO BE A NEUROLOGIST AND HAVEN'T GIVEN UP YET?

Q. In the content of mild Parkinsonism, what other neurological or endocrine conditions may give a slightly abnormal facies?

- A. ➤ Neurological ○ Mild pseudobulbar palsy
 ➤ Endocrine ○ Hypothyroidism
 ○ Acromegaly
 ○ Paget's disease

Source: Davies IJT. *Lloyd-Luke (medical books) LTD* 1972, page 290.

DO YOU STILL WANT TO BE A NEUROLOGIST AND HAVEN'T GIVEN UP YET?

Q. Some persons with Parkinson's disease have other neurological deficits. These are called "Parkinson plus syndromes", Give 4 examples.

- A. ○ Steele – Richardson – Olszewski disease (akinesia, axial rigidity of the neck, bradyphrenia, supranuclear palsy)
 ○ Multiple system atrophy (MSA)
 - Olivopontocerebellar degeneration
 - Strionigral degeneration
 - Progressive autonomic failure (Shy – Drager syndrome)
 ○ Basal ganglia calcification
 ○ Give up and switch to something else

Source: Baliga RR. *Saunders/Elsevier* 2007, page 142.



SO YOU WANT TO BE A NEUROLOGIST!

Q1. What is the difference between rigidity, spasticity, gegenhalten, tardive dyskinesia and the wheelchair sign?

- A1.
- Rigidity indicates increased tone affecting opposing muscle groups equally, and is present throughout the range of passive movement. When smooth it is called 'leadpipe' rigidity, and when intermittent it is termed 'cog-wheel' rigidity. It is common in extrapyramidal syndromes. Wilson's disease and Creutzfeld-Jakob disease.
 - Spasticity of the clasp-knife type is characterized by increased tone which is maximal at the beginning of movement and suddenly decreases as passive movement is continued. It occurs chiefly in flexors of the upper limb and extensors of the lower limb (antigravity muscle).
 - Gegenhalten, or paratonia, is where the increased muscle tone varies and becomes worse the more the patient tries to relax.
 - Tardive dyskinesia is seen in patients taking neuroleptics. Its manifestations are orofacial dyskinesia such as smacking, chewing lip movements, discrete dystonia or choreiform movements and, rarely, rocking movements.
 - Withdrawal of the "Wheelchair sign" in Parkinson's - patients with advanced disease and "on-off" motor fluctuations require a wheelchair when "off" and when "on" are seen to walk about (sometimes pushing the chair!). These patients are rarely permanently wheelchair-bound; in contrast, those who never leave their wheelchair usually do not have Parkinson's disease.

Adapted from: Baliga RR. *Saunders/Elsevier* 2007, page 139; McGee SR. *Saunders/Elsevier* 2007, pages 139 and 140.

Q2. How do you distinguish clinically from rigidity and spasticity?

- A2.
- Rigidity
 - Increased muscle tone through all parts of the movement of the joint
 - Usually seen in degenerative neurological conditions e.g. Parkinson's
 - Spasticity
 - Increasing muscle tone as muscle is stretched more and more, followed by a giveaway phenomenon of protective relaxation, leading to a jack-knife
 - Usually due to damage to the pyramidal (corticospinal) tract

Adapted from: Manzione S. *Hanlev & Belfus* 2000. page 414.

Useful background: The differential diagnosis for Parkinson's disease

- Idiopathic (degeneration of substantia nigra)
 - a. Drugs
 - Neuroleptics



SO YOU WANT TO BE A NEUROLOGIST!

Q1. What simple maneuver performed during the physical examination will help to distinguish cerebellar ataxia from sensory ataxia?

A1. Ataxia (clumsiness) due to cerebellar lesions persists when the eyes are closed, whereas sensory ataxia improves when the eyes are open

Q2. What hematological abnormalities may be associated with chorea?

A2.

- Polycythemia vera
- Neuroacanthocytosis (chorea – acanthocytosis)

Q3. What is Hemiballismus?

A3.

- Sudden onset of unilateral, involuntary, flinging movements of the upper limbs
- Cardiovascular disease (source of emboli)
 - Atrial fibrillation
 - Valvular heart disease
 - Severe left ventricular dysfunction, travelling to the ipsilateral nucleus of lungs and causing an infarction
- Unilateral, involuntary, flinging movement of the proximal upper limb

Source: Baliga RR. *Saunders/Elsevier* 2007, page 218.

Q4. In addition to Friedreich's ataxia, what are other syndromes with spinocerebellar degeneration?

A4.

- Roussy-Levy disease: hereditary spinocerebellar degeneration with atrophy of lower limb muscles and loss of deep tendon reflexes.
- Refsum's disease
- Machado-Joseph disease – dominant inheritance (first described in families of Portuguese origin)
 - Progressive ataxia, ophthalmoparesis, spasticity, dystonia, amyotrophy and parkinsonism.
- Dentatorubral pallidoluysian atrophy, similar to Machado-Joseph disease but maps on the short arm of chromosome 12 rather than 14.

Source: Baliga RR. *Saunders/Elsevier* 2007, page 193.



Tremor







Useful background

- Tremor
 - Extrapyrarnidal
 - Tremor at rest
 - ↓↓ with sleep, strong movements
 - ↑ with emotion, fine movements
 - Course
 - “compound” (affects many joints)
 - Cerebellum
 - Intention tremor
 - ↓↓ at rest
 - ↑ as range of movement is increased
 - GPI
 - Tongue: backward and forward trombone – like tremor
 - Tremor present both at rest and with attempted protrusion of the tongue
 - Fine tremor
 - Cause by
 - Fatigue
 - Anxiety
 - Emotion
 - Thyrotoxicosis
 - Px: alcohol, tobacco, cocaine, mercury
- Choreiform movements
 - Sudden
 - Brief
 - Jerky
 - Involuntary
 - ↑ by emotion, voluntary movement
 - Same movement never repeated in succession
 - Cause – disease of extrapyramidal system
- Athetoid movements
 - Slow
 - Writhing
 - Sinuous
 - Movements of periphery
 - ↑ by emotion, voluntary movement
 - Cause – disease of extrapyramidal system
- TIC
 - Explosive repetition of the same movement
 - Commonly seen in facial muscles
 - May be associated with psychiatric disturbance



- Myoclonus
 - Sudden contraction of a large muscle or muscle group.
 - Hiccups (“singultus”) are an example of myoclonus
 - Epilepsy may be associated with myotonic movements

Useful background: Tremors

| | | |
|--|--|--|
| <p>➤ Action tremor</p>  <ul style="list-style-type: none"> ○ Benign essential tremor ○ Thyrotoxicosis ○ Anxiety | <p>➤ Intention or kinetic tremor</p>  <ul style="list-style-type: none"> ○ Cerebellar disease ○ Severe forms of other tremor | <p>➤ Resting tremor</p>  <ul style="list-style-type: none"> ○ Parkinson's ○ Rare causes: Hg poisoning, Wilson's disease, syphilis |
| <p>➤ Chorea</p>  <ul style="list-style-type: none"> ○ Continuous movements ○ Facial grimacing ○ Teeth grinding ○ Worse with walking ○ 'Fidgety' ○ 'Won't sit still' ○ 'Always crossing and re crossing legs' <ul style="list-style-type: none"> ○ Drugs (e.g L-dopa, anti psychotics) ○ Huntington's disease <ul style="list-style-type: none"> - SLE - Contraceptive pill - Thyrotoxicosis - Hyperviscosity syndrome - Pregnancy | <p>Sustained abnormal tone & posture</p>  <ul style="list-style-type: none"> ○ 'writer's cramp' ○ Torticollis | <p>➤ Dystonia</p>  <ul style="list-style-type: none"> ○ Generalized |

Adapted from: Simel DL, et al. *JAMA* 2009, Box 38-2, page 508; Davey P. *Wiley-Blackwell* 2006, page 105 and Ghosh AK. *Mayo Clinic Scientific Press* 2008, page 778; Davey P. *Wiley-Blackwell* 2006, page 104.



Useful background:

- Tremor of Parkinson Disease
 - Slow frequency (4-6/s) tremor at rest
 - 'Pill rolling quality'
 - Asymmetrical
 - Hands, legs, chin, jaw, but not the head
 - Rigidity, bradykinesia
 - ↓ during movement, sleep
 - ↑ by emotional distress
 - Family history in only 15%
 - No consistent response to alcohol
- Perform a focused physical examination for different types of abnormal involuntary movements.
- Tremor
 - Rapidly repeated single movement
- Athetosis
 - Slow, writhing, purposeless movements
- Chorea
 - Semi-purposeful movements eg, repeatedly pulling at bedclothes
- Myoclonus
 - Sudden, rapid movement of a muscle group
- Tic
 - Repeated complicated movement
- Tonic – clonic movements (convulsion)
- Jacksonian epilepsy

Adapted from: Davies IJT. *Lloyd-Luke (medical books) LTD* 1972, pages 289 and 302.

The three commonest types of involuntary movements are tremor, athetosis and clonus.

- Perform a focused physical examination to determine the cause of each.
- Tremor
 - Senility
 - Familial
 - Basal ganglia Parkinsonism
 - Alcoholism



- Cerebellar disease
- Thyroid disease
- Thyroid disease-thyrotoxicosis
- Psychogenic
- Athetosis
 - Familial
 - Psychogenic
 - Basal ganglia disorders
- Chorea
 - Senility
 - Psychogenic inherited – Huntington’s chorea
 - Rheumatic fever-Sydenham’s chorea
 - Pregnancy (“chorea gravidarum”)
- Perform a focused physical examination of tremor.
- Definition
 - Tremors are involuntary movements that result from alternating contraction and relaxation of the group of muscles.
 - Rhythmic oscillations about a joint or a group of joints
- Rest tremor
 - As seen in Parkinsonism. The hands have characteristic motion of pill rolling, alternating flexion/ extension of fingers or hands, alternating pronation/ supination of forearms .
- Intention tremor (cerebellar)
 - Clinical
 - Worsens with alcohol.
 - Limbs or head tremor
 - ↑ by movement
 - contra-axial
 - Symmetrical
 - Often involves the head
 - Aggravated by voluntary movements
 - Examples
 - Chorea
 - Athetosis
 - Hemiballismus
 - Fasciculation
 - Torticollis
 - Clonus
- Postural and action (kinetic) tremor
 - Clinical



- Fast tremor throughout movement seen best with arms and hands outstretched.
- Exaggerated physiological tremor
- Causes
 - Anxiety
 - Sleep deprivation
 - Fatigue
 - Cold
 - β -agonist drugs
 - withdrawal of alcohol, caffeine, or lithium
 - Hyperthyroidism or hypoglycemia.
 - Brain damage seen in Wilson's disease, syphilis
- Essential tremor
 - Autosomal dominant inheritance
 - Shaking when carrying a teacup, putting a glass to the mouth, or trying to eat soup. It
 - May affect handwriting and voice.
 - Bilateral, usually symmetric postural or kinetic tremor
 - ↑ by action, postural change, alcohol
 - Hands, head, neck voice
 - Tremor due to neuropathy (postural tremor; arms more than legs)
 - No rigidity or bradykinesis
 - Family history in 60%
 - Family history of tremor is common
- Physiologic tremor
 - Variable
 - Enhanced form is visible, postural, and has a high frequency (8-12/s)
 - No underlying neurologic disease
 - Cause is usually reversible (e.g. caffeine)

Adapted from: Baliga RR. *Saunders/Elsevier* 2007, page 163.

- Take a directed history and perform a focused physical examination for chorea.

Causes of Chorea

- Neurological disorder
 - Post CVA
 - Huntington's disease (autosomal dominant)



- Drugs: e.g. excess levodopa, phenothiazines, the contraceptive pill, phenytoin
- Metabolic
 - Wilson's disease
 - Kernicterus (rare)
 - Thyrotoxicosis (very rare)
 - Hypoparathyroidism
- Infection
 - Viral encephalitis (very rare)
 - Sydenham's chorea (rheumatic fever) and other postinfectious states (both rare)
- Hematological
 - Polycythaemia or other hyperviscosity syndromes (very rare)
- Vascular and vasculitis
- MSK
 - Lupus

Adapted from: Talley NJ, et al. *Maclennan & Petty Pty Limited* 2003, Table 10.37, page 437; Baliga RR. *Saunders/Elsevier* 2007, page 216.

Aserixis: Inability of the patient to maintain a voluntary muscle contraction, such as dorsiflexion of wrist. Asterixis consists of a sequence of jerky flexion and extensions.

Source: Mangione S. *Hanley & Belfus* 2000,

“Rewarding anticipation activates a reward network:
that is the success of the not-so-common random
acts of kindness.”

Grandad



Seizures

- Definition: Paroxysmal cerebral dysfunction due to sudden abnormal electrical discharge

Epilepsy - localized (or partial) seizures

- Simple: normal conscious level
- Complex: altered conscious level

Focal motor seizures

= Jacksonian seizures

- Jerking of affected muscle
- Neighbouring muscle groups jerk as electrical discharge spreads ('marches') over motor cortex
- Post-ictal loss of motor function ('paralysis') for a few hours/day ('Todd's paresis')

Temporal lobe seizures

Often relate to structural abnormality e.g scarring from (prolonged) childhood febrile convulsions

Aura

- Over – under-familiarity with surroundings (déjà vu and jamais vu)
- Unpleasant taste or smell
- Epigastric discomfort

Seizure

- Facial grimacing
- Complex motor actions e.g undressing
- Bizarre behaviour

Post-ictal

- Usually rapid recovery
- Amnesia of seizure events

Typical epileptic seizure

Aura

Usually < 1 min
Depends on site

Seizure

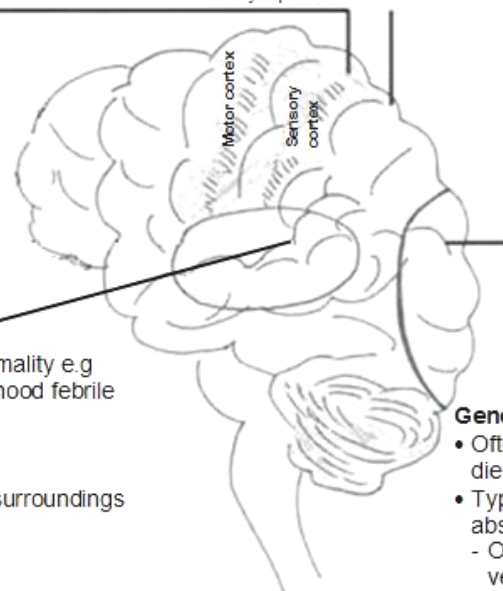
Lasts < few minutes
Rarely continues for prolonged
Periods = status epilepticus

Post seizure phenomena

= post ictal
If generalized → very sleepy < few hours
If focal → temporary loss of function

Focal sensory seizures

- Unpleasant tingling 'marching' over body in < few seconds
- Differential diagnosis includes migraine sensory symptoms here 'march' over body in 10-15 min



Occipital seizures

- Produce 'flashing' lights
- Can produce complex distortion of vision

Generalized seizures

- Often involve diencephalic structures
- Typical childhood absences ('petit mal') - Occur in childhood, very rare to continue in adulthood, common
- Myoclonic epilepsy
- Akinetic epilepsy → sudden complete loss of postural tone → sudden collapse. Rare.
- Grand mal seizures (see text)

Adapted from: Davey P. *Wiley-Blackwell* 2006, page 327.



Useful background: Causes of seizure

- Idiopathic
- Congenital
 - Cerebral malformation
 - Lipidoses (Tay-Sachs disease)
- Trauma
 - Tumour
 - Scar
 - Birth injury
- Infection
 - Encephalitis
 - Meningitis
 - Abscess
 - Cysticercosis
 - GPI
 - Pyrexia (especially in children)
- Metabolic
 - Anoxia
 - Hypoglycemia
 - Hypocalcemia
 - Alkalosis
 - Water intoxication
 - Uremia
 - Hepatic coma
- Drugs/toxins
 - Nikethamide
 - Lead poisoning
 - Cocaine
 - Ether
 - Barbiturate withdrawal
- Tumor
- Vascular
 - CVA
 - Hypertension
- Degenerative
 - Presenile dementias

Adapted from: Burton JL. *Churchill Livingstone* 1971, page 70.

“Mediocrity is metric modulation-bringing people back
(regression) to the mean”



- Take a directed history for seizures.
 - Age (at onset)
 - Onset, off set, duration, fluctuation
 - Type- “phase out”, myoclonic, tonic, tonic clonk, atonic (“drop seizures”), partial (affecting only a part of the brain rather than a generalized seizure affecting all the brain; partial seizures may include OR not include awareness of events)
 - Simple partial seizures
 - Motor, sensory or psychomotor phenomena without loss of consciousness
 - Seizures can begin in one part of the body and spread to other parts
 - Complex partial seizures
 - May be preceded by an aura (sensory or psychic manifestations that represent seizure onset)
 - Staring, performing of automatic purposeless movements, uttering of unintelligible sounds, resisting aid
 - Motor, sensory or psychomotor phenomena
 - Post-ictal confusion
 - Tonic-clonic seizures (formerly known as grand-mal)
 - Tonic phase – stiffening of limbs
 - Clonic phase – jerking of limbs
 - Respiration may decrease during tonic phase but usually returns during clonic phase, although it may be irregular
 - Incontinence may occur
 - Post-ictal confusion
 - Atonic seizures
 - Brief, primarily generalized seizures in children
 - Complete loss of muscle tone, resulting in falling or pitching to the ground
 - Risk of serious trauma, particularly head injury
 - Absence seizures
 - Brief, primarily generalized attacks manifested by a 10 to 30-second loss of consciousness
 - Eyelid flutterings at a rate of 3 Hz
 - No loss of axial muscle tone
 - No falling or convulsing
 - No post-ictal symptoms
 - Status epilepticus – a medical emergency!
 - Repeated seizures with no intervening periods of normal neurologic function



- Generalized convulsive status epilepticus may be fatal
 - With complex partial or absence seizures, an EEG may be needed to diagnose seizure activity
-
- Jacksonian epilepsy
 - Clonic movements
 - Always start at same site
 - Always show same order of speed
 - Early on, may be followed by transient paralysis
 - Later on, may be followed by later paralysis
 - Sometimes, no causative lesion is found

 - Generalized seizures
 - Generalized tonic-clonic seizures.
 - Petit mal and atypical absences
 - Myoclonus
 - Akinetic seizures. Petit mal describes only 3 Hz seizures, rather than clinically similar absence attacks which are partial seizures

 - Partial or focal seizures (a partial seizure is epileptic activity confined to one area of cortex with a recognizable clinical patten)
 - Simple partial seizures (no impairment of consciousness)
 - Jacksonian epilepsy: it is a simple partial seizure which usually originates in one portion of the prefrontal motor cortex so that fits begin in one part of the body (e.g. thumb) and then proceed to involve that side of the body and then the whole body. It suggests a space-occupying lesion.
 - Complex partial seizures
 - Partial seizures evolving to tonic-clonic

 - Todd's paralysis
 - Paresis of a limb or hemiplegia occurring after an epileptic attack, which may last up to 3 days.

 - No precipitating factor identified (e.g., sleep deprivation, alcohol use)

 - Associations- aura, salivation, tongue biting, incontinence, chewing, lip smacking, Jacksonian march, onset during sleep or with fever

 - Other factors
 - Family history of seizures (in first degree relative)
 - History of febrile seizures or birth trauma
 - Postictal Todd paralysis

 - Abnormal electroencephalogram (spikes or non-specific)



- Abnormal imaging study
- Causes
 - Congenital – malformations – birth injury
 - Ideopathic
 - Trauma
 - Tumor
 - Infection
 - Meningitis
 - Encephalitis
 - Abscess
 - Syphilis
 - Cysticercosis
 - Vascular
 - CVA
 - NTN
 - Hypertermia, especially in children
 - Hypothermia
 - Degeneration – presenile dementia
 - Metabolic*
 - Anoxia
 - Hypoglycemia
 - Hypocalcemia
 - Renal failure
 - Hyponatremia
 - Alkalosis
 - Motor intoxication
 - Drugs
 - Lead
 - Cocaine
 - Barbiturate, alcohol withdrawal

➤ Abnormal neurologic examination- CVA, trauma, Meningism

*Metabolic causes may cause delirium.

Abbreviation: CVA, cerebral vascular accident; NTN

Adapted from: Jugovic PJ, et al. *Saunders/ Elsevier* 2004, page 84; Filate W, et al. *The Medical Society, Faculty of Medicine, University of Toronto* 2005, page 173; Burton JL. *Churchill Livingstone* 1971, page 70; Baliga RR. *Saunders/Elsevier* 2007, page 241.



Status Epilepticus (SE)

- Definition
 - “Convulsive SE was traditionally defined as recurrent primarily or secondarily generalized tonic-clonic seizures
 - Lasting > 30 minutes, or
 - Intermittent seizures lasting > 30 minutes, without return to baseline consciousness between events”.
 - “...almost all, isolated tonic-clonic seizure last < 2 minutes”
 - “tonic-clonic seizure lasting > 5 minutes most likely suggests impending SE and should be treated aggressively”
 - “any seizure type CMN evolve to non-convulsive SE”
 - “non-convulsive SE should be considered in any patient with unexplained coma”
 - “brain injury begins at 30-45 minutes after onset of SE”

(Moeller JJ, et al. Chapter 24. In: Therapeutic Choices. Grey J, Ed. 6th Edition, *Canadian Pharmacists Association*: Ottawa, ON, 2011, page 298).

SO YOU WANT TO BE A NEUROLOGIST!

Q. In the woman on AEDs (antiepilepsy drugs), give the recommended method of contraception.

A. In the woman taking a COC (combined oral contraceptive), there is an increased risk of COC failure because of the enzyme-inducing effect of AEDs, so condoms should be used in addition to IUDs (intrauterine devices or hormonal methods).

Dementia

- Definition: “Dementia is aprogressive, deteriorating.....syndrome of acquired global impairment of cognitive function sufficient to interfere with normal activities” (Rockwood K, et al. Chapter 4. In: Therapeutic Choices. Grey J, Ed. 6th Edition, *Canadian Pharmacists Association*: Ottawa, ON, 2011, page 45).
- The common causes
 - Alzheimer disease
 - Vascular dementia
 - Combination of Alzheimer and vascular dementia
 - Lewy body dementia
 - Frontotemporal dementia
 - In association with Parkinson disease
 - Drugs (e.g., anti-cholinergics)



- Case: A patient with memory impairment and cognitive decline is assessed and found to have dementia:
 - Cognitive impairment
 - MoCA, Montreal Cognitive Assessment
 - MMSE, Mini-mental State Examination
 - Functional disability
 - Disability Assessment for Dementia
 - FAST, Functional Assessment Staging Tool

Useful background: Dementia is a syndrome of acquired global impairment of cognitive function sufficient to interfere with normal activities. The most common causes are Alzheimer's disease, vascular dementia, a mixture of the two, Lewy body dementia and frontotemporal dementia. Dementia is also recognized as a complication of Parkinson's disease. Dementias are almost always progressive, deteriorating illnesses in which treatment opinions are different at different stages of the illness (See Table 1).

Useful background: Stages of Dementia

| Stage | Characteristics | Corresponding FAST Rating ^a |
|---------------|---|--|
| ➤ Preclinical | <ul style="list-style-type: none"> ○ Subjective complaints accompanied by very mild objective cognitive decline; functioning is unimpaired ○ This stage has considerable overlap with normal aging and may or may not progress to dementia. | 3 |
| ➤ Mild | <ul style="list-style-type: none"> ○ Impaired instrumental activities of daily living (IADL), e.g., <ul style="list-style-type: none"> - Driving - Medication use - Finances - Use of telephone and housekeeping | 4 |
| ➤ Moderate | <ul style="list-style-type: none"> ○ In addition to IADL impairment, personal activities of daily living (PADL) such as <ul style="list-style-type: none"> - Bathing - Feeding - Dressing - Toileting can be done only with prompting | 5 |



| Stage | Characteristics | Corresponding FAST Rating ^a |
|------------|---|--|
| ➤ Severe | ○ PADL cannot be done even with prompting | 6 |
| ➤ Terminal | ○ Patients must be fed and become immobile and mute | 7 |

^a Included because many jurisdictions use the Functional Assessment Staging Tool (FAST) in adjudicating reimbursement for dementia medications.

Reproduced with permission: Therapeutics Choices. Sixth Edition. Ottawa, Canada: *Canadian Pharmacist Association* 2012, Table 1, page 45.

- Give the indications for performing a CT of the head.
 - Patient
 - < 60 years
 - Recent head injury
 - History and cancer
 - Use of anticoagulants
 - Dementia
 - Rapidly progressive
 - Unusually cognitive symptoms (e.g. early delusions or hallucinations)
 - Neurological
 - Focal or lateralizing signs
 - Gait disorder
 - Early urinary incontinence

Grey J, Therapeutic Choices. 6th Edition, *Canadian Pharmacists Association*: Ottawa, ON, 2011, page 46

Q1: In the context of psychosis, perform a focused physical examination for NMS (neuroleptic malignant syndrome).

- A1: ➤ Definition: Neuroleptic malignant syndrome (NMS) is a drug-induced, idiosyncratic serious medical emergency which can occur at any dose of antipsychotics, and is characterized by
- Autonomic dysfunction
 - Fever (hyperthermia)
 - Labile blood pressure
 - Sweating



- Tachycardia (> 100 bpm)
 - o Varying level of consciousness
 - o Dehydration
 - o Leucocytosis
 - o ↑ CK (creatine kinase)
- History for differential diagnosis (“**Dementia**”)
 - o **D**rugs (alcohol, barbiturates, bromides)
 - o **E**motion (depression, schizophrenia)
 - o **M**etabolic (Wernicke-Korsakoff syndrome, B12/folate deficiency, hyper/hypothyroid)
 - o **E**ye and ear (severe visual and auditory impairment)
 - o **N**eurodegenerative (Huntington’s, Parkinson’s, Alzheimers disease)
 - o **T**rauma (head injury, dementia pugilistica), tumour (subfrontal meningioma)
 - o **I**nfection (HIV, syphilis, viral encephalitis, Creutzfeld-Jacob disease)
 - o **A**rteriosclerotic and vascular (multi infarct dementia, vasculitis, cerebral hemorrhage)

Abbreviations: ADL, activities of daily living

Adapted from: Ghosh A.K. *Mayo Clinic Scientific Press* 2008, Table 10-4, page 390; FOS, page 131. Data from Inouye SK, et al. *Ann Intern Med.* 1991;114 (11):991-992; Jugovic PJ, et al. *Saunders/ Elsevier* 2004, Box 4-1, page 131 M, page 51.

- For an excellent consideration of how to take a focused history to evaluate competency in medical decision-making, please see: Jugovic PJ, et al. *Saunders/ Elsevier* 2004, page 206.
- Determine site of cause
 - o Cortical coma (brainstem functions are present)
 - Brainstem coma
 - Response to pain
 - Decerebrate- mild
 - Upper extremity flexion (hands point towards heart)
 - Lower extremity extension and internal rotation
 - Moderate
 - Upper and lower extremities – extension and internal rotation
 - Severity
 - Midbrain
 - Fixed pupils



- Pons
 - Doll's eye reflex eyes -remain fixed in the midline when head is turned (CNI; normally, touching cornea on one side causes a wink response on both sides with a unilateral disturbance of V, wink response does not occur on either side when affected side is stimulated)
 - Loss of corneal reflex
 - Loss of jaw reflex (CN) jaw will deviate towards the side of the lesion
- Medulla
 - Dysfunction of cardiopulmonary centers
- Cortical pontine-
 - Impaired conjugate eye movement (cerebral or basilar artery thrombosis)
 - Death
 - Global absence of brainstem function on two neurological examinations 12 hours apart, and exclusion of toxic-metabolic cause

Adapted from: Burton JL. *Churchill Livingstone* 1971, page 72; Talley NJ, et al. *Maclennan & Petty Pty Limited* 2003, Table 10.38, page 439.

- Take a directed history and perform a focused physical examination for the causes of dementia.
 - Infection
 - Meningitis
 - Encephalitis
 - Abscess
 - Malaria
 - Septicemia
 - Ischemia
 - Thrombosis, embolism, hemorrhage
 - Hypertensive encephalopathy
 - Causes of syncope
 - Metabolic
 - Alcoholism
 - Drugs
 - Uremia
 - Hepatic failure
 - Myxedema
 - B 12 deficiency
 - Pellagra



- Trauma
- Pressure effects
 - Space-occupying lesions
 - Hydrocephalus
- Hyper- or hypo-thermia
- Hysteria or hypnosis

Adapted from: Burton JL. *Churchill Livingstone* 1971, page 72.

- Take a directed history and perform a focused physical examination for dementia.
- History
 - Initial screen
 - Assesses hearing/vision
 - Assesses orientation (person, place, time)
 - Elicits chief complaint
 - Description of symptoms
 - Onset, duration, and course of current complaint(s)
 - Palliating/provoking factors
 - Limitations in functioning (ADLs, IADLs)
 - Depression symptoms
 - Assesses depression symptoms (low mood, anhedonia, sleep disturbance, etc)
 - Assesses suicidality and homicidality
 - Anxiety symptoms
 - Anxiety symptoms (phobias, obsessions, compulsions, etc)
 - Perception disturbances
 - Psychotic symptoms (hallucinations, delusions, ideas of reference etc)
 - Personality and behavioral disturbances
 - Changes in personality
 - Behavioral abnormalities (apathy, agitation, odd behaviors, etc)
 - Past and family medical history
 - Hx of alcohol/drug abuse
 - Medications and Hx of adverse drug reactions
 - Hx of psychiatric illness
 - Hx of other metabolic or systemic illness(s)
 - Collateral history from family member
 - Elicits concerns
 - Confirms history
 - Inquiries about safety, home fire risks, driving, wandering
- Physical examination
 - Inspection



- Dress and grooming
- Speech
- Attitude and behavior in office
- Folstein mini mental status exam
 - Orientation (place, time: 5pt for each)
 - Registration (name 3 objects: 1 pt for each)
 - Attention and concentration (serial 7's, world, months: 5 pt total)
 - Recall (recall 3 objects: 1 pt for each)
 - Language:
 - identify 2 objects pointed to: 2 pt total
 - ask no ifs ands or buts: 1 pt total
 - perform 3 stage command: 3 pt total
 - read and obey written command: 1 pt total
 - write a sentence: 1 pt total
 - draw intersecting pentagons: 1 pt total
- Additional cognitive tests
 - Perseveration (ask patient to copy a series of loops)
 - Construction ability (draw hands of clock for diff. Times)
 - Concrete thinking (compare word similarities)
 - Abstract thinking (describe meaning of proverb)

Abbreviation: ADL, activities of daily living; IADL, instrumental activities of daily living

Adapted from: Ghosh AK. *Mayo Clinic Scientific Press* 2008, Table 19-3
Differential diagnosis of dementia; UK book; Jugovic PJ, et al. *Saunders/Elsevier* 2004, pages 129-131.

Useful background: Differential diagnosis of dementia

- Structural lesions
 - Normal-pressure hydrocephalus
 - Subdural hematoma
 - Neoplasm
 - Vascular dementia
- Infections
 - Chronic meningitis
 - Neurosyphilis
 - HIV dementia
 - Encephalitis
 - Meningitis
 - Abscess
 - Creutzfeldt – Jakob disease
 - Cryptococcal meningitis



- Inflammatory/immune disorders
- Vasculitis
- Hashimoto/autoimmune encephalopathy
- Tumor
 - Intracranial (especially frontal)
- Degenerative dementia
 - Alzheimer disease
 - Diffuse Lewy body disease
 - Frontotemporal dementia (including Pick disease)
 - Huntington disease
 - Progressive supranuclear palsy
 - Multiple sclerosis

Abbreviation: HIV, human immunodeficiency virus

Adapted from: Hauser SC, et al. *Mayo Clinic Gastroenterology and Hepatology Board Review*. 3rd Review, page 753; Burton JL. *Churchill Livingstone* 1971, page 71.

- Take a directed history to differentiate between delirium and dementia.

| | Delirium | Dementia |
|---------------|---|---|
| ➤ Onset | ○ Rapid | ○ Progressive |
| ➤ Course | ○ Fluctuates over time | ○ Constant or may slowly worsen |
| ➤ Orientation | ○ Disoriented to time and place | ○ Disoriented to time and place usually only in late stages |
| ➤ Psychosis | ○ More likely present | ○ Less likely present |
| ➤ Other | ○ Perceptual disturbances, sleep wake cycles disturbed, ↑ or ↓ psychomotor activity | ○ Loss of judgment, changes in personality present |
| ➤ Reversible | ○ Often | ○ Very rarely |

Adapted from: Filate W, et al. *The Medical Society, Faculty of Medicine, University of Toronto* 2005, page 277 and Jugovic PJ, et al *Saunders/Elsevier* 2004, page 131.



Useful background: Performance characteristics for dementia and delirium*

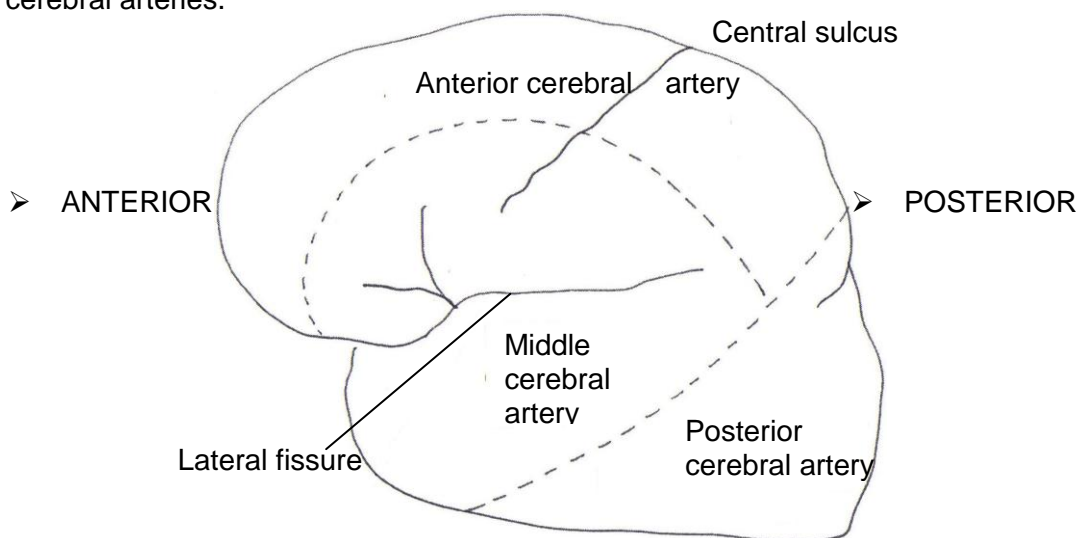
| Finding | PLR | NLR |
|---|------|-----|
| ➤ Dementia | | |
| ○ Abnormal clock drawing test | 5.3 | 0.5 |
| ➤ Mini mental status examination: 3 levels | | |
| ○ ≤ 20 | 14.5 | ... |
| ○ 21 to 25 | 2.2 | ... |
| ○ ≤ 23 | 8.1 | 0.2 |
| ➤ Delirium | | |
| ○ Positive test using "Confusion Assessment Method" | 10.3 | 0.2 |

Abbreviation: PLR, positive likelihood ratio; NLR, negative likelihood ratio

Source: McGee SR. *Saunders/Elsevier* 2007, Box 4-1, page 51.

Cerebral vascular disease

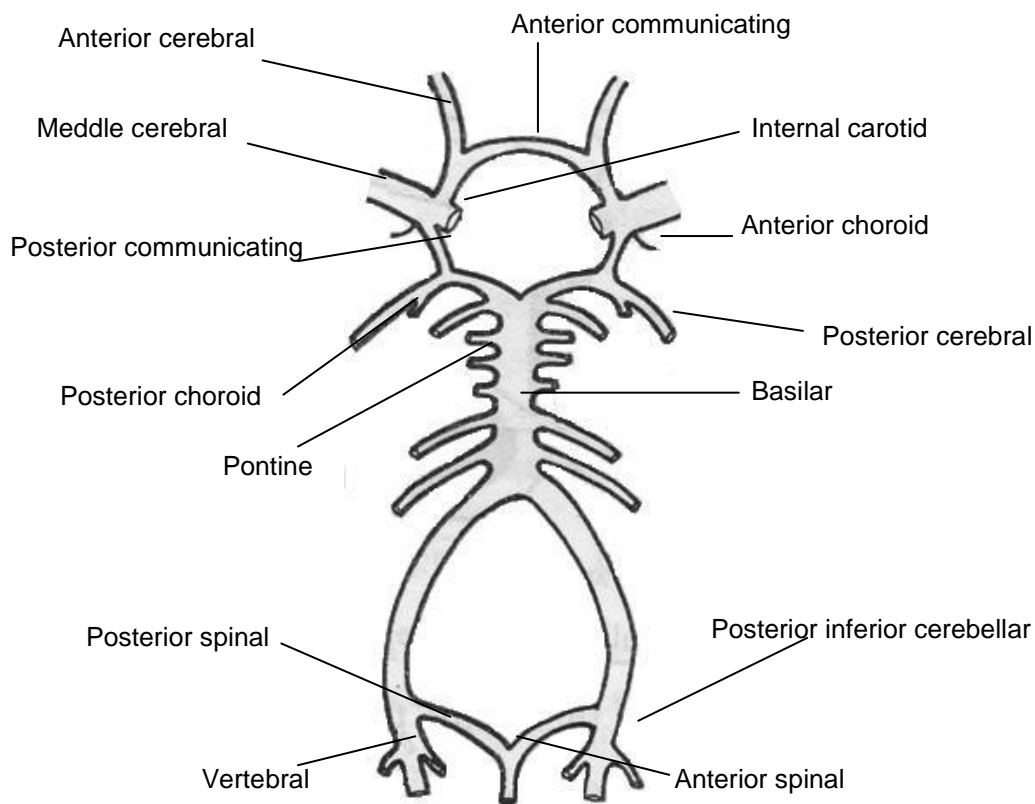
Useful Background: The cerebral cortex showing the distribution of the cerebral arteries.



Adapted from: Davey P. *Wiley-Blackwell* 2006, Figure 17, page 256.



Useful background: The arteries at the base of the brain and the circle of Willis.



- Take a directed history and perform a physical examination for a cerebral vascular accident (CVA) or for transient ischemic attack (TIA).

➤ History

- Weakness
 - Location and extent
 - Time course (onset, duration, change with time)
 - Previous episodes (TIAs)
 - Quality of deficit (sensory, movement, power)
- Associated symptoms
 - Paresthesia
 - Pain
 - Dizziness
 - Level of consciousness
 - Amaurosis Fugax
 - Slurred speech
 - Skin changes (colour, swelling, warmth)
 - Injury or trauma



- Infection (fever, chills, sweating)
- Risk factors
 - Family Hx of neurological Disease
 - Hx of stroke
 - Hx of MI, Murmur, Palpitations, Rheumatic heart disease
 - Atherosclerosis RF (hypertension, DM, FHx of CAD, hypercholesterolemia, smoking)
- Impact on ADLs
 - Is the patient R or L handed?
 - Gross motor (reaching shelves, opening doors)
 - Fine motor (buttoning shirt, using keys, writing)
 - Impact on personal and family life
- Physical examination
 - Inspection
 - Compares right arm to left arm for:
 - Atrophy
 - Fasciculation
 - Abnormal position
 - Abnormal movements
 - Tone
 - Compares right arm to left arm for:
 - Rigidity
 - Spasticity (velocity dependant)
 - Power
 - Compares and grades right arm to left arm power for:
 - Shoulder extension and abduction
 - Elbow flexion, extension, pronation and supination
 - Wrist flexion, extension, ulnar and radial deviation
 - Digit abduction, adduction, thumb extension and thumb opposition
 - Pronator Drift Test
 - Reflexes
 - Compares and grades right arm to left arm reflexes for: Biceps (C5-6), Brachioradialis (C5,6) and triceps (C7,8)
 - Coordination
 - Finger to nose test
 - Rapid alternating movement

Abbreviations: ADL, activities of daily living; AF, atrial fibrillation; CAD, coronary artery disease; CVA, cerebral vascular accident; HBP, hypertension; MI, myocardial infarction; TIA, transient ischemic attack

Source: Jugovic PJ, et al. *Saunders/ Elsevier* 2004, pages 149 and 150.



- Perform a focused physical examination to determine which vessel of the circle of Willis has been blocked by a thrombus or embolus and is responsible for a cerebrovascular “accident” (CVA).

| | Artery | Functional importance |
|--|---|--|
| <p>➤ Midbrain</p> <p>➤ Pons</p> <p>➤ Medulla</p> | ○ Anterior cerebral artery | -- Leg primarily involved |
| | ○ Anterior communicating artery | -- Connects right and left internal carotid |
| | ○ Penetrating, subcortical branches of middle cerebral artery | -- Subcortical lacunes No cortical deficit |
| | ○ Internal carotid, middle cerebral artery | -- Aphasia, or nondominant hemisphere dysfunction |
| | ○ Posterior communicating artery | -- May be large with posterior circulation getting significant supply from internal carotid |
| | ○ Posterior cerebral artery | -- Field cut (supplies occipital lobe), no hemiplegia |
| | ○ Superior cerebellar artery | -- Infrequently involved alone |
| | ○ Basilar artery | -- Occlusion results in quadriplegia and death unless, there are good anterior collaterals |
| | ○ Penetrating branches of the basilar artery to brainstem | -- Small brainstem infarcts, often classic lacunes |
| | ○ Anterior inferior cerebellar artery | -- Infrequently involved alone |
| | ○ Posterior inferior cerebellar artery | -- Lateral medullary syndrome, usually secondary to occlusion of the vertebral artery from which it arises |

*Lacunes: Small infarcts typically from atherothrombotic occlusive disease of the penetrating branches

Adapted from: Talley NJ, et al. *MacLennan & Petty Pty Limited* 2003, Figure 10.50, page 417; Davey P. *Wiley-Blackwell* 2006, page 248.



- Areas supplied by the arteries at the base of the brain and the circle of Willis:
- Anterior cerebral artery (ACA) or anterior communicating artery
 - Optic atrophy (compression of optic nerves)
 - Frontal lobe symptoms (compression of frontal lobes)
- Middle cerebral artery (MCA)
 - Supplies the
 - Upper optic radiation
 - Optic radiation as it passes through the internal capsule
 - Occlusion of MCA
 - Defects of lower visual fields
- Posterior cerebral artery
 - Both cerebral peduncles
 - Ipsilateral III, IV
 - Conjugate eye movement
 - Thalamus
 - Supplies-lower optic radiation
 - Occipital visual cortex
 - Midbrain
 - All cerebral arteries are end anterior
 - Occlusion of even just one vessel supplying the circle of Willis may cause signs
- Anterior inferior cerebellar artery
 - CN-V-VIII
 - Conjugate eye movement
 - Corticospinal, medial lemniscus
 - Anteriolateral spinothalamic
 - Pinpoint pupils
 - Hyperventilation
- Posterior inferior cerebellar
 - Ipsilateral CN V to X; ipsilateral palsy
 - Ipsilateral spinocerebellar tract
 - Ipsilateral Horner's syndrome
 - Contralateral pain and temperature
 - Contralateral hemiplegia
- Perform a focused physical examination of the patient's visual fields to determine the site of an occlusion of posterior cerebral artery (AKA).
- Complete occlusion of PCR
 - Complete homonymous, with macular sparing
- Partial occlusion of PCR



- Upper homonymous quadrantanopia (as in vertebra-basilar insufficiency)
- Aneurysm of PCA or posterior communicating artery
 - Isolated CN III palsy
- Perform a focused physical examination of the patient's visual fields to determine the site of an occlusion of the internal carotid artery.
- Occlusion of internal carotid
 - Findings of middle cerebral artery [MCA] occlusion (since MCA is a continuation of carotid artery)
- Aneurysm of internal carotid artery
 - Nasal or homonymous heminopia (pressure of optic chiasm or optic tracts)
 - If aneurysm is in the cavernous sinus, the anterior choroidal artery may be affected, causing signs of CN III, IV, VI or CN V, ophthalmic division disorder
 - Homonymous congruous scotoma
- Perform a focused physical examination for cavernous sinus thrombosis (CST), and for sagittal sinus thrombosis (SST).
- CST
 - CN III, IV, VI, V – ophthalmic branch
 - Papilledema
 - Exophthalmus
- SST
 - Crural dominance
 - Paralysis and loss of sensation of the legs, from damage to the top of both cerebral cortices
- Anterior Spinal Artery
- Perform a focused physical examination for obstruction at the base of the anterior spinal artery.
 - Medial medullary syndrome
 - Corticospinal tracts
 - Medial lemniscus
 - Hypoglossal nerve (CN XII)
 - Which two areas of the spinal cord are especially prone to ischemic injury, and why?



- Lower cervical region, just above the area where the segmental artery from the costo-cervical trunk enters; blood flow from this segmental artery flows downwards, thus not providing a second source of blood supply to the cord of the ASA is blocked.
 - Mid thoracic region, in the area between the additional supply from costo-cervical trunk, and the area where flow is supplemented by the artery of Adamkiewicz (usually on the left side); blood from this artery flows both upwards and downwards
 - The blood flow in the artery of Adamkiewicz may be damaged, and therefore ischemia of the mid thoracic spinal cord occur with
 - Dissection of the aorta
 - Nerve blocks to left lower nerve
 - Left lower thoracotomies
- Perform a focused physical examination for the causes of paraplegia.
 - Congenital (cerebral palsy)
 - Hereditary ataxia
 - Infiltration
 - Abdominal
 - Anterior cerebral artery occlusions
 - Cord compression
 - Tumourous myelitis
 - Ischemia
 - Superior sagittal sinus thrombosis
 - Spinal artery occlusion (Erb's paraplegia)
 - Infection
 - Poliomyelitis
 - Degeneration
 - Motor neuron disease
 - Multiple sclerosis
 - Syringomyelia
 - Metabolic
 - Subacute combined degeneration

Adapted from: Burton JL. *Churchill Livingstone* 1971, page 84.

Temporal Arterial Insufficiency (TIA, transient ischemic attacks) may include symptoms and signs arising from ischemia of

- Carotid
- Basilar artery



Useful background: Carotid artery stenosis

In patients with TIA, a carotid bruit indicates the presence of a > 50% stenosis of the carotid artery (confirmed by carotid angiography) with 29% sensitivity and 88% specificity.

Adapted from Sauve JS et al., *JAMA* 1993; 270: 2843-5.

Useful background: Common stroke syndromes (right-handed patient)

| Location of artery occlusion | Clinical significance |
|-----------------------------------|---|
| ➤ Left sided | ○ Aphasia |
| ➤ Right sided | ○ Neglect of left space |
| | ○ Lack of awareness of deficit |
| | ○ Apathy |
| ➤ Anterior cerebral artery (ACA) | ○ Contralateral weakness of the lower limb and shoulder shrug |
| ➤ Middle cerebral artery (MCA) | ○ Contralateral motor, sensory and visual loss |
| ➤ Posterior cerebral artery (PCA) | ○ Contralateral hemianopia and hemisensory loss |
| ➤ Internal carotid artery (ICA) | ○ Contralateral MCA and ACA signs |
| | ○ Ipsilateral transient monocular blindness (amaurosis) |
| ➤ Basilar artery | ○ Bilateral motor weakness, ophthalmoplegia and diplopia |

Abbreviation: MCA, middle cerebral artery

Source: Filate W, et al. *The Medical Society, Faculty of Medicine, University of Toronto* 2005, page 171.

- Take a directed history and perform a focused physical examination for TIA-associated ischemia of carotid and MCA, as well as basilar artery and PCA.
- Carotid and MCA
 - Eye
 - Hemianopia
 - Transient monocular blindness
 - Horner's syndrome
 - Speech
 - Stuttering



- Intellect
 - Confusion
 - Motor
 - Hemiplegia
 - Basilar artery and PCA
 - Hemianopia (optic radiation or occipital)
 - Dysarthria
 - Dysphagia
 - Vertigo
 - Facial pain
 - Hemiplegia
 - “drop attacks” (reticular formation)
 - Temporal lobe signs & symptoms
-] Pons and medulla

Adapted from: Davies IJT. *Lloyd-Luke (medical books) LTD* 1972, page 258.

Stroke

- Definition: “Stroke [is] recognized clinically as the sudden onset of a focal disturbance of central nervous system function” (Phillips SJ, et al. Chapter 41. In: *Therapeutic Choices*. Grey J, Ed. 6th Edition, *Canadian Pharmacists Association*: Ottawa, ON, 2011, page 559).
- Take a directed history for warning signs of a stroke.
- Sudden
 - Pain
 - Severe headache
 - Eyes
 - Visual challenges
 - Speech
 - Confusion or difficulty speaking
 - Balance
 - Loss

Ischemic Stroke

- Take a directed history and perform a focused physical examination for identification of persons with a high risk of CVA (cerebrovascular attack, aka “stroke”)
- Nonmodifiable factors
 - Age > 60 years
 - Gender
 - Family history



- Modifiable
 - Habits
 - Smoking
 - Heart
 - Hypertension ($\geq 140 / 90$ mm Hg)
 - Atrial fibrillation
 - Carotid disease (a surrogate marker for associated coronary artery disease)
 - Metabolic
 - Diabetes
 - Dyslipidemia

Note: The prognosis of TIA is worse with

- Age ≥ 60 years
- Hypertension $\geq 140 / 90$ mm Hg
- Diabetes
- TIA duration of symptoms > 10 minutes
- Speech and/or motor symptoms

Adapted from: Cote' R, et al. Chapter 40. In: Therapeutic Choices. Grey J, Ed. 6th Edition, *Canadian Pharmacists Association*: Ottawa, ON, 2011, page 550.

Useful background: Strokes

- 80% Ischemic thrombosis
 - Embolus
 - Systemic hypoperfusion
- 20% Hemorrhagic intracerebral
 - Sub-arachnoid
 - Subdural/extradural

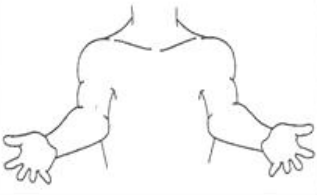
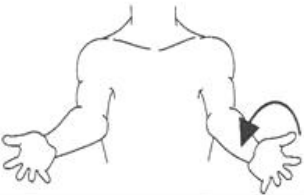
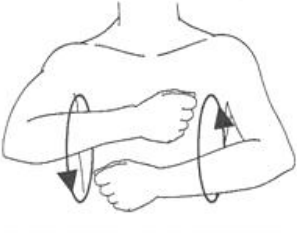
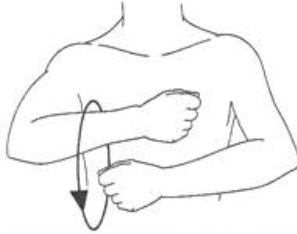


Source: Filate W, et al. *The Medical Society, Faculty of Medicine, University of Toronto* 2005, page 191.

Useful background: Amaurosis fugax – definition

- Transient monocular blindness due to episodic retinal ischemia, usually associated with ipsilateral carotid artery stenosis or embolism of the retinal arteries resulting in a sudden and frequently complete, loss of vision in one eye.



➤

| NORMAL | RIGHT CEREBRAL LESION
(Left-sided findings) | |
|--|--|---|
| Upper limb drift (pronator drift) | | |
|  |  | <ul style="list-style-type: none"> - For 45 sec stretch out both arms, with palms upright and eyes closed - Positive test: the arm on the side opposite to the cerebellar lesion drifts downward and pronates. |
| Forearm rolling test | | |
|  |  | <ul style="list-style-type: none"> - Bend elbows, place forearms parallel to each other, and rotate the forearms about each other in a rapid rolling motion for 10 seconds in each direction. - Positive test: the arm on the side opposite to the cerebellar lesion is stay still, while the other arm "orbits" around it. |
| Rapid finger tapping | | |
|  |  | <ul style="list-style-type: none"> - Tap the thumb and index finger together repeatedly at about two taps per second. - Positive test: the fingers on the side opposite to the cerebellar lesion tap more slowly, and may even look like the two fingers are sticking together |

➤ Special Tests for Unilateral Cerebral Lesions.

Adapted from: McGee SR. *Saunders/Elsevier* 2007, page 710.

- The presence of a carotid bruit may increase the likelihood of a 70-99% carotid stenosis:

| Patient | Ipsilateral bruit | | |
|----------------|-------------------|------------------|---------|
| ○ Asymptomatic | Yes | 4.0-10.0 | PPV 22% |
| | No | Uncertain | |
| ○ Symptomatic* | Yes | 3.0 (1.3-7.1) | PPV 50% |
| | No | 0.49 (0.36-0.67) | |



*Carotid-territory cerebrovascular symptoms.

- The presence of a carotid bruit cannot be used to rule it in, nor can its absence be used to rule it out (JAMA, Chapter 9, page 109).

Abbreviations: CB, carotid bruit; PPV, positive predictive value; TIA, transient ischemic attack

Source: Simel DL, et al. *JAMA* 2009, Table 9-5 and 9-6, page 110.

- Perform a focused neurological examination to determine the location of an arterial cerebral occlusion.

| Middle cerebral artery (MCA) | Posterior cerebral artery (PCA) | Anterior cerebral artery (ACA) | Internal carotid artery (ICA) |
|--|--|--|---|
| ➤ Infarction middle third of hemisphere: UMN face, arm > leg | ○ Infarction of thalamus and occipital cortex | ○ Cortical sensory loss leg only | ○ Contralateral HCA and MCA signs |
| ➤ Homonymous hemianopia; aphasia or non-dominant hemisphere signs (depends on side) | ○ Contralateral sensory loss
○ Contralateral hemianopia | ○ Contralateral weakness of leg and shoulder shrug
○ Urinary incontinence | ○ Ipsilateral transient monocular blindness (amaurosis fugax) |
| ➤ Cortical sensory loss | | | |
| ➤ Perforating artery | | | |
| ➤ Internal capsule infarction: UMN face UMN arm > leg | | | |
| ➤ Left-sided <ul style="list-style-type: none"> ○ Aphasia | | | |
| ➤ Right-sided <ul style="list-style-type: none"> ○ Neglect of left space ○ Lack of awareness of deficit ○ Apathy ○ Impersistence | | | |



- Basilar artery
 - Bilateral motor weakness
 - Diplopia
 - Ophthalmoplegia

Abbreviation: ACA, anterior cerebral artery; ICA, internal carotid artery; MCA, middle cerebral artery; PCA, posterior cerebral artery; UMN, upper motor neuron lesion

Adapted from: Talley NJ, et al. *MacLennan & Petty Pty Limited*, 2003, Table 10.22, page 418; Filate W, et al. *The Medical Society, Faculty of Medicine, University of Toronto* 2005, Table 18, page 171.


Useful background: Performance Characteristics for aspiration after stroke

| Finding | PLR | NLR |
|--|-----|------|
| ➤ Neurologic examination | | |
| ○ Drowsiness | 3.4 | 0.5 |
| ○ Absent pharyngeal sensation | 2.4 | 0.03 |
| ➤ Other tests | | |
| ○ Water swallow test | 3.2 | 0.4 |
| ○ Oxygen desaturation 0—2 min after swallowing | 3.6 | 0.8 |

Note that several signs are not presented because their PLR was < 2: abnormal voluntary cough, dysphonia, dysarthria, abnormal sensation face and tongue, tongue weakness, bilateral cranial nerve signs, abnormal gag reflex

Abbreviation: NS, not significant; likelihood ratio (LR) if finding present=positive LR (PLR); LR if finding absent=negative LR (NLR).

Adapted from: McGee SR. *Saunders/Elsevier* 2007, Box 56.1, page 699.



Sen N out – Sensitive test; when negative, rules ot disease

Sp P in – Specific test; when positive, rules in disease




Useful background: Unilateral cerebral hemispheric disease

| Finding | PLR | NLR |
|-----------------------|------|-----|
| ➤ Arm rolling test | 21.7 | NS |
| ➤ Pronator drift | 10.3 | 0.1 |
| ➤ Finger tapping test | 6.6 | 0.3 |
| ➤ Babinski response | 19.0 | 0.6 |
| ➤ Hyperreflexia | 5.8 | 0.4 |

Abbreviation: NLR, negative likelihood ratio; PLR, positive likelihood ratio

Note that hemianopia and hemisensory disturbance are not included since had a PLR < 2.

Adapted from: McGee SR. *Saunders/Elsevier* 2007, Box 57-1, page 726



Sen N out – Sensitive test; when negative, rules out disease

Sp P in – Specific test; when positive, rules in disease

“There are three constants in life... change, choice
and principles”

Stephen Covey



- Perform a focused physical examination to determine the site of pathology causing a person's motor defect.

Localizing Features of Motor Lesions

- Cerebral cortex
 - Flaccid weakness
 - Flexors and extensors equally affected ("global weakness")
 - Cortical sensory loss may be present

- Internal capsule
 - Spastic weakness.
 - Hemianopia
 - Extensors more affected than flexors.
 - Distal limb muscles more affected than proximal muscles. Arm is greater than leg, if leg is greater than arm, suspect ant. Cerebral stem
 - Paralysis of head and eye movements so that patient looks away from the weak limbs

- Brain Stem
 - Crossed hemiplegia, i.e. ipsilateral cranial nerve palsy with contralateral limb palsy.

- Cord lesion
 - Flaccid
 - Flexors more affected than extensors
 - Lower motor neurone lesion

- Root & Peripheral Nerve
 - Peripheral nerve lesions usually affect both motor and sensory function in muscles and skin supplied by the nerve. The following is a rough guide to the muscles supplied by clinically important motor nerve roots

| | |
|---------|---|
| C5 & 6 | Biceps, deltoid |
| C7 & 8 | Triceps |
| C7 | Finger extensors |
| C8 | Finger flexors |
| T1 | Small muscles of hand |
| L2 & 3 | Adductors |
| L3 & 4 | Quadriceps |
| L4 & 5 | Dorsi flexors |
| L5 & S1 | Hamstrings |
| S1 & 2 | Plantar flexors & small muscles of feet |



Useful background: Cardiac risks for cerebral infarction (CVA) or transient ischemic attack (TIA)

Proven Possible

- Rhythm
 - Atrial fibrillation
 - Paroxysmal atrial fibrillation
 - Sustained atrial fibrillation
- Valve defect
 - Mechanical valve
 - Rheumatic valve disease
- Valve infection
 - Infectious endocarditis
 - Nonbacterial thrombotic endocarditis
- Lumen
 - Intracardiac thrombus
- Wall
 - Intracardiac mass (eg. atrial myxoma, papillary fibroelastoma)
 - Dilated cardiomyopathy
- Vessels
 - Recent (within 1 month) myocardial infarction

Possible cardiac risks

- Rhythm
 - Sick sinus syndrome
 - Spontaneous echocardiographic contrast
- Valve defect
 - Calcification of mitral annulus
- Valve infection
- Lumen
- Wall
 - Patent foramen ovale with or without atrial septal aneurysm
 - Hypokinetic or a kinetic left ventricular segment



- Vessels
 - Atherosclerotic debris in the thoracic aorta
 - Myocardial infarction 2-6 month earlier

Adapted from: Ghosh AK. *Mayo Clinic Scientific Press* 2008, page 773.

Useful background: Subarachnoid Hemorrhage

| Finding | PLR | NLR |
|-----------------------------------|------|-----|
| ➤ Neck stiffness | 10.3 | 0.4 |
| ➤ Neurological findings not focal | 5.9 | 0.4 |
| ➤ Seizures | 2.2 | NS |

Abbreviation: NS, not significant; NLR, negative likelihood ratio; PLR, positive likelihood ratio

Adapted from: McGee SR. *Saunders/Elsevier* 2007, Table 23.1, page 281.

Useful background: The National Institutes of Health Stroke Scale^a

| Item | Response |
|--------------------------------------|--|
| 1a. Level of consciousness | 0=Alert
1= Not alert
2= Obtunded
3=Unresponsive |
| 1b. level of consciousness questions | 0= Answers both correctly
1= Answers 1 correctly
2= Answers neither correctly |
| 1c. Level of consciousness commands | 0= performs both tasks correctly
1= Performs 1 task correctly
2= Performs neither task |
| 2. Gaze | 0= Normal
1= Partial gaze palsy
2= Total gaze palsy |
| 3. Visual fields | 0= No visual loss
1= Partial hemianopsia
2= Complete hemianopsia
3= Bilateral hemianopsia |



| Item | Response |
|-------------------------------------|---|
| 4. Facial palsy | 0= Normal
1= Minor paralysis
2= Partial paralysis
3= Complete paralysis |
| 5. Motor arm
a. Left
b. Right | 0= No drift
1= Drift before 5 s
2= Falls before 10s
3= No effort against gravity
4= No movement |
| 6. Motor leg
a. Left
b. Right | 0= No drift
1= Drift before 5 s
2= Falls before 5 s
3= No effort against gravity
4= No movement |
| 7. Ataxia | 0= Absent
1= One limb
2= Two limbs |
| 8. Sensory | 0= Normal
1= Mild loss
2= Severe loss |
| 9. Language | 0= Normal
1= Mild aphasia
2= Severe aphasia
3= Mute or global aphasia |
| 10. Dysarthria | 0=Normal
1= Mild
2= Severe |
| 11. Extinction/inattention | 0= Normal
1= Mild
2= Severe |

^aThe actual form for recording the data contains detailed instructions for the use of the scale. This is available at

www.ninds.nih.gov/doctors/NIH_stroke_Scale.pdf .

An online course for provider education is available at

www.ninds.nih.gov/doctors/stroke_scale_training.htm

b Score= sum of scores from each item.



The NIH stroke scale, as published in Simel D L, et al. *JAMA* 2009, Table 48-2, page 630.

Useful background: Bamford clinical classification of stroke

- Total anterior circulation syndrome
 - Unilateral motor deficit of face, arm and leg
 - Homonymous hemianopia
 - Higher cerebral dysfunction (e.g. aphasia, neglect)

- Parietal anterior circulation syndrome

Any two of the following features:

 - Unilateral motor and/or sensory deficit
 - Ipsilateral hemianopia or higher cerebra dysfunction
 - Higher cerebral dysfunction alone, or isolated motor and/or sensory deficit restricted to one limb or to the face

- Posterior circulation syndrome

One or more of the following features:

 - Bilateral motor or sensory signs not secondary to brainstem compression by a large supratentorial lesion
 - Cerebellar signs, unless accompanied by ipsilateral motor deficit (see ataxic hemiparesis)
 - Unequivocal diplopia with or without external ocular muscle palsy
 - Crossed signs, for example left facial and right limb weakness
 - Hemianopia alone or with any of the four items above

- Lacunar syndrome
 - Pure motor stroke:
 - Unilateral, pure motor deficit
 - Clearly involving two of three areas (face, arm and leg)
 - With the whole of any limb being involved
 - Pure sensory stroke:
 - Unilateral pure sensory symptoms (with or without signs)
 - Involving at least two of three areas (face arm and leg)
 - With the whole of any limb being involved
 - Ataxic hemiparesis
 - Ipsilateral cerebellar and corticospinal tract signs
 - With or without dysarthria
 - In the absence of higher cerebral dysfunction or a visual field defect
 - Sensorimotor stroke:
 - Pure motor and pure sensory stroke combined (i.e. unilateral motor or sensory signs and symptoms)



- In the absence of higher cerebral dysfunction or a visual field defect

Stroke is characterized by rapidly progressive clinical symptoms and signs of focal, and at times global, loss of cerebral function lasting more than 24 hours or leading to death, with no apparent cause other than that of vascular origin.

Bamford clinical classification of stroke, as published: Baliga RR. *Saunders/Elsevier 2007*, page 127.

- Perform a focused physical examination to determine if a lesion affects functions of the dominant cerebral hemisphere.
 - Dominant hemisphere
 - Right-left orientation
 - Finger identification
 - Calculation
 - Non-dominant hemisphere
 - Facial recognition
 - Awareness of body and space
 - Drawing ability
 - Topographic ability
 - Construction
 - Dressing
 - Motor persistence

Source: Baliga RR. *Saunders/Elsevier 2007*, page 150.

- Perform a focused physical examination to determine the presence of parietal lobe dysfunction.
 - ↓ accurate localization (of touch, position, joint sense and temperature appreciation)
 - ↓ two-point discrimination
 - Astereognosis
 - Dysgraphesthesia
 - ↓ Sensory attention
 - Attention hemianopia, homonymous hemianopia, or lower quadrantic hemianopia

Source: Baliga RR. *Saunders/Elsevier 2007*, page 150.



Clinical gem: Transient Ischemic Attack (TIA)

- A TIA is a stroke syndrome with neurological symptoms lasting from a few minutes to as long as 24 hours followed by complete functional recovery. A RIND (reversible ischemic neurological deficit) is a condition in which a person has neurological abnormalities similar to acute completed stroke, but the deficit disappears after 14 to 36 hours, leaving few or no detectable neurological sequelae.
- The symptoms include:
 - Intention tremor (29%)
 - Hypotonia
 - Dysdiadochokinesia (47-69%)
 - Arm drift (44-69%)
 - Rebound
 - Balance
 - Rhomberg's test, Pull test
 - Gait- Normal gait, Toe walking, Heel walking, Tandem gait, Ataxia
 - Reflexes reduced

Values in brackets represent mean or range of common findings

Adapted from: Jugovic PJ, et al. *Saunders/ Elsevier* 2004, page 165; Talley NJ, et al. *MacLennan & Petty Pty Limited* 2003, page 431; McGee SR. *Saunders/Elsevier* 2007, Table 61.1, page 198.

- Take a directed history of differentiated between a carotid or vertebralbasilar transient ischemic attack (TIA).
- Carotid TIA
 - Hemiparesis
 - Aphasia or transient loss of vision in only one eye (amaurosis fugax)
- Vertebralbasilar TIA
 - Vertigo, dysphagia, ataxia, drop attacks (at least two of these should occur together)
 - Bilateral or alternating weakness or sensory symptoms
 - Sudden bilateral blindness in patients aged over 40 years

Source: Baliga RR. *Saunders/Elsevier* 2007, page 122.



Useful background: Oxfordshire classification of subtypes of cerebral infarction

- Total anterior circulation infarction syndrome (TACS)
- IC/MCA- A combination of new higher cerebral dysfunction (ie dysphasia, dyscalculia, visuospatial disorder); homonymous visual field defect; and ipsilateral motor or sensory deficit of at least 2 areas of the face, arm and leg.
- Partial anterior circulation infarction syndrome (PACS)
- MCA- Only 2 of the 3 components of the TACS syndrome are present with higher cerebral dysfunction alone or with a motor/sensory deficit more restricted than those classified as LACS (ie confined to 1 limb or to face and hand, but not to the whole arm).
- Lacunar infarction syndrome (LACS)
- Penetids- Pure motor stroke, pure sensory stroke, sensorimotor stroke, or ataxic hemiparesis.
- Posterior circulation infarction syndrome (POCS)
- Ventriculosis basilar- Any of the following
 - Ipsilateral cranial nerve palsy with contralateral motor or sensory deficit
 - Bilateral motor or sensory deficit
 - Disorder of conjugate eye movement
 - Cerebellar dysfunction without ipsilateral long tract deficit (ie ataxic hemiparesis)
 - Isolated homonymous visual field defect.

Oxfordshire classification, as published in Simel DL, et al. *JAMA* 2009, Box 48-1, page 634.

"Action is the foundational key to all success"

Pablo Picasso



- Perform a focused physical examination to determine the location of lesions causing sensory loss.

| Location of lesion | Distribution of sensory loss | Examples of causes |
|--|--|---|
| ➤ Cortical (parietal) | <ul style="list-style-type: none"> ○ Able to recognize all primary modalities but localizes them poorly ○ Loss of secondary modalities | - Stroke, cerebral tumour, trauma |
| ➤ Brainstem | <ul style="list-style-type: none"> ○ Pain and temperature: ipsilateral face, contralateral body | - Demyelination (young), brainstem stroke (older) |
| ➤ Thalamic sensory loss | <ul style="list-style-type: none"> ○ All modalities; contralateral hemisensory loss (face, body) and pain–dysesthesia (e.g. burning feeling) | - Stroke, cerebral tumour, MS, trauma |
| ➤ Spinal cord | <ul style="list-style-type: none"> ○ Depends on level of lesion and complete vs. partial lesion | - Trauma, spinal cord compression by tumour, cervical spondylitis, MS |
| ➤ Medulla involving descending nucleus of spinal tract of the fifth nerve and ascending spinothalamic tract (lateral medullary lesion) | | |
| ➤ Root or roots | <ul style="list-style-type: none"> ○ Confined to single root or roots in close proximity; commonly C5, 6,7 in arm and L4, 5, S1 in leg | - Compression by disc prolapse |
| ➤ Peripheral nerve | <ul style="list-style-type: none"> ○ Distal glove and stocking deficit | - Diabetes mellitus, alcohol related B12 deficiency, drugs |



| Location of lesion | Distribution of sensory loss | Examples of causes |
|--------------------|---|---|
| ➤ Single nerve | ○ Within distribution of single nerve; commonly median, ulnar, peroneal, lateral cutaneous nerve to the thigh | - Entrapment, most commonly in diabetes, mellitus, carpal tunnel syndrome, rheumatoid arthritis, and hypothyroidism; multiple (mononeuritis multiplex) = vasculitis |
| ➤ Multiple nerves | ○ Mononeuritis
○ Multiplex, from involvement of multiple nerves | - Vasculitis |

Abbreviations: MS, multiple sclerosis

Adapted from: Filate W, et al. *The Medical Society, Faculty of Medicine, University of Toronto* 2005, Table 16, page 168.

SO YOU WANT TO BE A NEUROLOGIST!

Q. From the physical examination, how would you be able to differentiate between an obstruction of Heubner's (medial striate) artery, and a more distal occlusion of the anterior cerebral artery?

- A.
- Obstruction of Heubner's artery (anterior damage to the limb of internal capsule and extrapyramidal nuclei)
 - Contralateral weakness and spasticity in the upper body
 - Obstruction of ACA
 - Contralateral flaccid weakness of the leg

An alcoholic is a person who drinks more than his physician! Don't believe it. TRUST, BUT VERIFY

Grandad



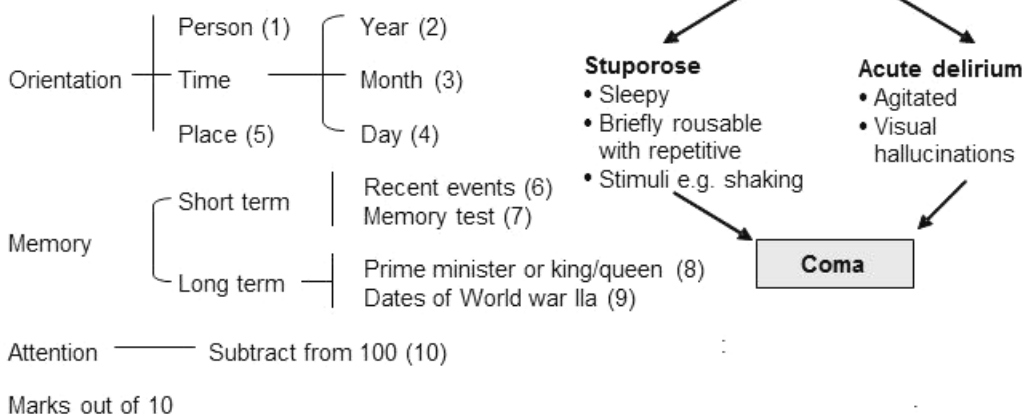
Useful background: Mini – mental test for confusion

Acute confusional states and coma

Altered/ fluctuating conscious level

Mini mental test score – continuum

Test for confusion



Adapted from: Davey P. *Wiley-Blackwell* 2006, page 138.

Useful background: Delirium

- Sudden onset of
 - Confusion
 - Disorientation
 - Restlessness

- Causes
 - Infection
 - In or outside of CNS (asymptomatic or symptomatic urinary tract infection is a common output in the elderly)
 - Ischemia (CVA)
 - Trauma
 - Toxins/drugs eg., alcohol
 - Metabolic
 - Hypoglycemia
 - Hypocalcemia
 - Hyponatremia
 - Hypoxia
 - Hepatic failure
 - Renal failure



- Others
 - Korsakow's psychosis
 - Puerperal psychosis
 - Post-seizure confusion

Useful background: Dementia

- Slow loss of
 - Short-term memory
 - Intellect (reasoning and making correct judgements)
 - Understanding new ideas
 - Social awareness
- Inattention
 - Loss of hygiene and aspects of personal care
- Confusion
- Delusions
- Affect
 - Depression
 - Anxiety
 - Mania
- Perform a focused physical examination to determine the cause of a patient's coma as arising from the cerebral cortex or brainstem.
- Definition: Coma is a condition in which there is diffuse, bilateral dysfunction of the cortex due to disease in either the cortex or in the reticularis activating system (RAS) in the brainstem.
- Cortical coma
 - All four layers of the brainstem are normal on examination
- Brainstem coma (cortex is dysfunctional because of defect in RAS of brainstem)
- 1) Thalamus (first and upper most)
 - Response to painful stimulus to supraorbital ridge, nail bed, or to the sterna
 - Decorticate posture
 - Mild dysfunction of thalamus
 - Ipsilateral arms



- Flexion ipsilateral
- Legs
 - Extension
 - Internal rotation (de-cortication hand points to heart [cor])
- Decerebratic posture
 - Moderately severe dysfunction of thalamus
 - Arms
 - Ipsilateral extension
 - Legs
 - Ipsilateral extension
 - Internal rotation
- Severe thalamic damage
 - No response to painful stimulation, or
 - Bending of knees from a spinal reflex

Source: Mangione S. *Hanley & Belfus* 2000, page 422.

2) Midbrain (second layer)

- Pupillary reflex
 - Midposition (neither pin-point or dilated)
 - Fixed (nonresponsive light, ipsilateral and contralateral)

3) Pons

- Pupillary light reflex
 - Bilateral small pupils
 - React very slightly to light
- Oculocephalic reflex (aka “doll’s eye reflex”)
 - Loss of the function of the medial longitudinal fasciculus (MLF), which connects CN III in the midbrain to CN VI in the upper pons
 - Loss of oculocephalic reflex on the ipsilateral side
 - MLF is surrounded by RAS, so dysfunction of MLF is a surrogate marker to damage to the RAS. Both eyes move to the opposite side eyes fixed in midline
 - Awake
 - Rotating head
 - Loss of MLF/RAS
 - Comatose, preserved MLF /RAS
 - Rotating head
- Corneal reflex
- Abnormal breathing
 - Cheyne-Stokes respiration
 - Progressive increase in depth \pm frequency of breathing, followed by a short interval of apnea



- Apneustic breathing deep inspiration – breath holding – rapid expiration

4) Medulla (fourth and lower most layer)

- Ataxic ventilation
 - Irregular irregularity of breathing, with fluctuation and hypoventilation / apnea
- Apnea test
 - Loss of integrity of cardiopulmonary function
 - Loss of ability to take a spontaneous breath
 - Death is associated with a loss of all brainstem function

- Take a directed history to detect disease of the frontal, parietal or temporal lobe, or the motor cortex.

| Frontal lobe | Motor cortex | Parietal lobe | Temporal lobe |
|----------------|------------------------|-------------------------------|---------------------------------|
| ➤ Forethought | ○ UMN | ○ Spatial disorientation | ○ Hallucinations |
| ➤ Consequences | hemiplegia | | ○ Illusions |
| ➤ Apathy | ○ Jacksonian epilepsy | ○ Aproxia | ○ Receptive dysphasia |
| ➤ Dementia | | ○ Agnesia | |
| ➤ Grasp reflex | ○ Expressive dysphasia | ○ Perceptual rivalry | ○ Altered memory, coma |
| ➤ Ataxia | | ○ Rec. dysphasia | ○ Upper temporal quadrantanopia |
| ➤ Akinesia | | ○ Homonymous hemianopia | |
| ➤ Asphasia | | ○ Jacksonian sensory epilepsy | |

Abbreviation: UMN, upper motor neuron

Adapted from: Talley NJ, et al. *MacLennan & Petty Pty Limited* 2003, Table 10.4, page 353.



- Perform a focused physical examination for coma.

➤ Determine Glasgow coma scale (GCS)

| Response | Score |
|--|-------|
| ➤ Eye opening | |
| ○ Spontaneous | 4 |
| ○ On your verbal command ('open your eyes') | 3 |
| ○ In response to painful stimulus | 2 |
| ○ No response | 1 |
| ➤ Motor response | |
| ○ Correct response to 'show me two fingers' | 6 |
| ○ Localises painful stimulus and tries to stop it | 5 |
| ○ Withdraws from painful stimulus to fingernail | 4 |
| ○ Abnormal flexor response of forearms, wrists and fingers | 3 |
| ○ Abnormal extensor response of arms and legs | 2 |
| ○ No response | 1 |
| ➤ Verbal response to the question: What year is this? | |
| ○ Correct year | 5 |
| ○ Wrong year | 4 |
| ○ Words but no year | 3 |
| ○ Incomprehensible sounds | 2 |
| ○ No response | 1 |

➤ Total Points

Glasgow Coma Scale points

| | |
|----------|---|
| 14-15 = | 5 |
| 11-13 = | 4 |
| 8 - 10 = | 3 |
| 5 - 7 = | 2 |
| 3- 4 = | 1 |

- Take a directed history for delirium.

➤ Definition

- Acute onset, with fluctuating course
- Inattention
- Disorganised thinking
- Altered level of consciousness
- Diagnosis of delirium requires the presence of 1 and 2 and either 3 or 4.



➤ Clinical

- Initial screen
 - Assesses hearing/vision
 - Assesses orientation (person, place, time)
 - Elicits chief complaint
- Description of symptoms
 - Onset, duration, and course of current complaint(s)
 - Palliating/provoking factors
 - Limitations in functioning (ADLs, IADLs)
- Depression symptoms
 - Assesses depression symptoms (low mood, anhedonia, sleep disturbance, etc)
 - Assesses suicidality and homicidality
- Anxiety symptoms
 - Anxiety symptoms (phobias, obsessions, compulsions, etc)
- Perception disturbances
 - Psychotic symptoms (hallucinations, delusions, ideas of reference etc)
- Personality and behavioral disturbances
 - Changes in personality
 - Behavioral abnormalities (apathy, agitation, odd behaviors, etc)
- Past and family medical history
 - Hx of alcohol/drug abuse
 - Medications and Hx of adverse drug reactions
 - Hx of psychiatric illness
 - Hx of other metabolic or systemic illness(s)
- Collateral history from family member
 - Elicits concerns
 - Confirms history
 - Inquiries about safety, home fire risks, driving, wandering

➤ Causes

- Drugs
 - Sedative- hypnotics
 - Anticholinergic agents
 - NSAIDs (nonsteroidal anti inflammatory drug)
 - Adrenergic blockers
 - Antipsychotic agents
- Metabolic disturbances
 - Hyperglycemia
 - Hypoglycemia
 - Hypercalcemia
- Hypoxia
- Hypotension



- Perform a focused physical examination for meningitis (the numbers in brackets represent values for sensitivity)
 - General
 - Jolt accentuation of headache
 - Myalgia
 - Fever (87%)
 - Altered mental status (69%)
 - Eye
 - Papilledema
 - CNS
 - Focal neurological signs (9%) (eg, cranial nerve palsy; 21%)
 - Seizures (13%)
 - Subarachnoid hemorrhage
 - Acute bacterial meningitis
 - Cervical fusion
 - Spondylitis
 - Parkinson's disease
 - Increased intracranial pressure (with impending tonsillar herniation)
 - Meningeal signs
 - Stiff neck with passive motion (80%)
 - Chin toward chest
 - Kernig's sign, Brudzinski's sign (61%)
 - Skin
 - Petechial rash (13%)
 - CVS
 - ↓ PR
 - ↑ SBP
 - Differential

*Note: the sensitivity is 46% for the classic triad (fever, neck stiffness, headache), also note that fever and altered mental status are less frequent with subarachnoid hemorrhage than with acute bacterial meningitis.

Abbreviation: PR, pulse rate; SBP, systolic blood pressure

Adapted from: Jugovic PJ, et al. *Saunders/ Elsevier* 2004, pages 138 and 139; Simel D, et al. *JAMA* 2009, Table 30-5, 30-1, page 396; McGee SR. *Saunders/Elsevier* 2007, Table 23-1 and Box 23-1, page 280 and 281; Talley NJ, et al. *MacLennan & Petty Pty Limited* 2003, page 349.



What is “the best”? The two “best” clinical tests for the presence of a subarachnoid hemorrhage are: neck stiffness, and neurological findings which are not focal. Recall that neck stiffness is also common in persons with meningitis, and they will much more often have fever.

➤ Subarachnoid hemorrhage

| Finding | PLR | NLR |
|---------------------------------|------|-----|
| ➤ Neck stiffness | 10.3 | 0.4 |
| ➤ Neurologic findings not focal | 5.9 | 0.4 |
| ➤ Seizures | 2.2 | NS |

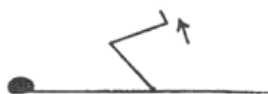Note that age < 60 years is not listed, since its PLR is < 2.

Abbreviation: NLR, negative likelihood; PLR, positive likelihood ratio.

Adapted from: McGee SR. *Saunders/Elsevier* 2007, Box 23- 1, page 281.

Differentiate between four similar signs

1. **Kernig's sign.** To detect meningeal irritation




Straightening leg with hip flexed produces pain and spasm of hamstrings

2. **Brudzinski's sign.** To detect meningeal irritation



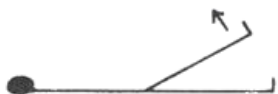
Flexing neck produces flexion of lower limbs

3. **Thomas's test.** To detect fixed flexion deformity of the hip – joint



Eliminating lumbar lordosis produces flexion of the affected hip

4. **Straight – leg raising test.** To detect lesions of sciatic nerve or its spinal roots



Straight – leg raising produces pain below the normal full excursion

Adapted from: Burton JL. *Churchill Livingstone* 1971, page 90; McGee SR. *Saunders/Elsevier* 2007, Figure 23.1, page 278.



- Take a directed history to distinguish communicating from and obstructive (non-communicating) hydrocephalus.
- Impaired mental state, gait as well as urinary problems, plus
- Obstructive hydrocephalus also shows
 - Nausea and vomiting
 - Lethargy
 - Headache
 - Visual changes

Source: Mangione S. *Hanley & Belfus* 2000, page 762.

SO YOU WANT TO BE A NEUROLOGIST!

Q1. What are the typical neurological lesions associated with leptomeningeal lesions?

- A1. ➤ Cerebral
- Headache
 - Seizures
 - Focal neurologic signs
- Cranial nerve
- Any cranial nerve can be affected, especially CN III, IV, VI, and VII
- CN VII is often affected in Lyme disease
- Radicular (radiculoneuropathy or radiculomyelopathy) - neck and back pain as well as radicular pain and spinal cord signs

Source: Ghosh AK. *Mayo Clinic Scientific Press* 2008, page 762.

Q2. We all know that meningitis will cause meningismus, symptoms of headache, photophobia and nuchal rigidity. But what other non-musculoskeletal (i.e. neurological) conditions may cause a stiff neck?

- A2. ○ Intracerebral bleed
- Posterior fossa tumor



SO YOU WANT TO BE A NEUROLOGIST!

Q. Many conditions may increase intracranial pressure (e.g. hemorrhagic stroke, brain abscess or tumor with cerebral), and cause "coning" (nastral-candal herniation of the uncus of the temporal lobe, followed by compression of the brainstem). Your question: trace the signs which display the layer-by-layer loss of function which occur with the progression of coning.

- A.
- Ipsilateral cerebral posturing
 - Decortication, then
 - Decerebration
 - Loss of painful stimuli
 - Ipsilateral dilated pupil
 - Ipsilateral loss of oculo cephalic reflex ("doll's head")
 - Corneal reflex tests become positive
 - Contralateral paratonic muscle resistance, and positive contralateral plantar extensor ("Babinski") reflex.

Source: Mangione S. *Hanley & Belfus* 2000, page 429.

Syncope and Dizzyness

Useful background: Major causes of syncope

- Definition-- is a transient loss of consciousness with spontaneous recovery
- Cardiogenic syncope
 - Structural heart disease
 - Coronary artery disease
 - Rhythm disturbance
 - Vasovagal
 - Carotid sinus hypersensitivity
 - Dysrhythmia e.g. AF, BBB
 - Orthostatic hypotension
 - After exercise
 - Coronary artery disease, previous myocardial infarction
 - Structural heart disease
 - Left ventricular dysfunction
 - Congestive heart failure
- Neurologic
 - In patients who present with a prodrome (e.g. nausea, diaphoresis), a neurocardiogenic mechanism is likely.
 - Patients who experience rapid recovery (less than 5-10 minutes) rarely have neurologic cause for syncope and are most unlikely to



have syncope due to seizure or 'brain hypoperfusion' because recovery in such circumstances takes hours.

- For cases in which recovery from syncope is rapid and no residual neurologic signs or symptoms are present, detailed (and expensive) neurologic evaluation should be avoided.

- Metabolic
- Psychiatric
- Situational
- Lung
 - Tussive
 - Valsalva maneuver
 - Sneeze
- GI
 - Deglutition
 - Defecation
 - Glossopharyngeal neuralgia
 - Postprandial
- GU
 - Micurition
- Miscellenous
 - Oculovagal
 - Instrumentation
 - Diving

Adapted from: Hauser SC, et al. *Mayo Clinic Gastroenterology and Hepatology Board Review*. 3rd Review, page 90; Shen W-K, et al. Syncope: mechanisms, approach, and management. In: Low PA, ed. Little, *Brown and Company* 1993, pages 605-640.

- Take a directed history to determine the cause of a patient's dizziness.
 - Physiological
 - Motion sickness
 - Space sickness
 - Height vertigo
 - Psychological
 - Acute anxiaety
 - Agoraphobia (fear & avoidance of being in public places)
 - Chronic anxiety
 - Eye
 - High magnification & lens implant
 - Imbalance in extraocular muscles
 - Oscillopsia



- Balance
 - Brain stem, cerebellar or temporal cortical lesions
 - Pontine infraction or haemorrhage
 - Vertebro-basilar insufficiency
 - Basilar artery migraine
 - Temporal lobe epilepsy
 - Disseminated sclerosis
 - Tumours
 - 'Benign post traumatic positional vertigo', etc
 - Vestibular lesions
 - Physiological
 - Labyrinthitis
 - Meniere's
 - Drugs eg quinine, salicylates, alcohol
 - Otitis media
 - Motion sickness
 - Vestibular nerve lesions
 - Acoustic neuroma
 - Drugs eg streptomycin
 - Vestibular neuronitis
 - Disequilibrium
 - Lesions of basal ganglia, frontal lobes, & white matter
 - Hydrocephalus
 - Cerebellar dysfunction
 - Ear
 - Vertigo
 - Peripheral
 - Central
- CVS
 - Orthostatic hypotension
 - Vasovagal attacks
 - Impaired cardiac output
 - Hyperventilation

➤ Multisensory dizziness

Adapted from: Hauser SC, et al. *Mayo Clinic Gastroenterology and Hepatology Board Review*. 3rd Review, Table 19.13, page 763; Burton JL. *Churchill Livingstone* 1971, page 76.



Multiple Sclerosis

- Definition: “Multiple sclerosis (MS) is a chronic neurologic disorder characterized by targeted destruction of central nervous system (CNS) myelin, as well as axonal degeneration and loss. (Namaka M, et al. Chapter 25. In: Therapeutic Choices. Grey J, Ed. 6th Edition, *Canadian Pharmacists Association*: Ottawa, ON, 2011, page 308).
 - It is speculated that there is an autoimmune response to an unknown foreign molecule, (viral infection, dietary or hormonal risk factor) which has a structure similar to a component of myelin, leading to an initial focal inflammatory phase, followed by more diffuse inflammatory and immune-mediated destruction of myelin.
 - There are four clinical presentations of MS
 - RRMS (relapsing remitting; commonest form, ~90%)
 - PPMS (primary progressive)
 - SPMS (secondary progressive)
 - PRMS (progressive relapsing)
 - 80% present with a clinically isolated syndrome (are initial acute “attack”)
 - RRMS (65% → SPMS)
- Demographics
 - Prevalence in CDN / USA is ~ 150/10⁵
 - W (women) 2x > M (men)
 - M are more likely to have the more severe primary progressive form
- Take a directed history and perform a focused physical examination for multiple sclerosis (MS).
- Definition
 - Demyelination causing remissions and relapses of: weakness, incoordination, pain, paraesthesias, urinary urgency, impotence
 - Steinberg’s triad: history of incontinence of bladder, impotence and constipation
- Diagnostic criteria
 - Poser’s criteria: a history of two episodes of neurological deficit and objective clinical signs of lesions at more than one site within the central nervous system establishes the diagnosis of definite multiple sclerosis



- In the presence of only one clinical sign, the demonstration of an additional lesion by laboratory tests – such as evoked potentials, MRI, CT or urological studies – also fulfils the criteria
- A diagnosis of probable multiple sclerosis is defined as either two attacks with clinical evidence of one lesion, or one attack with clinical evidence of two lesions.

➤ Clinical course

- Relapsing-remitting: episodes of acute worsening with recovery and a stable course between relapses.
- Secondary progressive: gradual neurological deterioration with or without superimposed acute relapse in a patient who previously had relapsing-remitting multiple sclerosis.
- Primary progressive: gradual, almost continuous neurological deterioration from the onset of symptoms
- Progressive relapsing: gradual neurological deterioration from the onset symptoms but with subsequent superimposed relapses
- Variation of MS
 - Optic neuritis alone
 - Optic neuritis plus a single episode of transverse myelitis

Adapted from: Baliga RR. *Saunders/Elsevier* 2007, pages 175 to 178.

SO YOU WANT TO BE A NEUROLOGIST!

Q. What are the prognostic markers that predict more severe multiple sclerosis?

- A.
- Progressive disease from the onset of symptoms.
 - Frequent relapses in the first two years.
 - Motor and cerebellar signs at presentation to neurologist.
 - Short interval between the first two relapses.
 - Male gender.
 - Poor recovery from relapse.
 - Multiple cranial lesions on T2-weighted MRI at presentation.

Source : Baliga RR. *Saunders/Elsevier* 2007, page 178.



Useful background: Multiple sclerosis

Intellectual loss ("dementia") in long standing MS


> Eye

- **Optic neuritis**
 - Acute phase
 - Central visual field defect
 - 'Scoloma' – 'like cotton wool'
 - Discomfort – worse on eye movement
 - Often normal fundoscopy
 - Usually recovers in 10-20 days
 - Chronic phase
 - Fundoscopy shows optic atrophy i.e. very pale disc
 - Visual loss often minor i.e. colour vision
- Horner syndrome

> Motor weakness

- Due to pyramidal tract damage (in spinal cord or higher)
- ↓ Arm extension
- ↓ Leg flexion
- Spasticity i.e. tone ('clasp knife') pattern
- Increased reflexes ± clonus ± upgoing plantar
- Wasting

> Cerebellar signs

Axial FLAIR showing MS lesions 

> Brain stem involvement

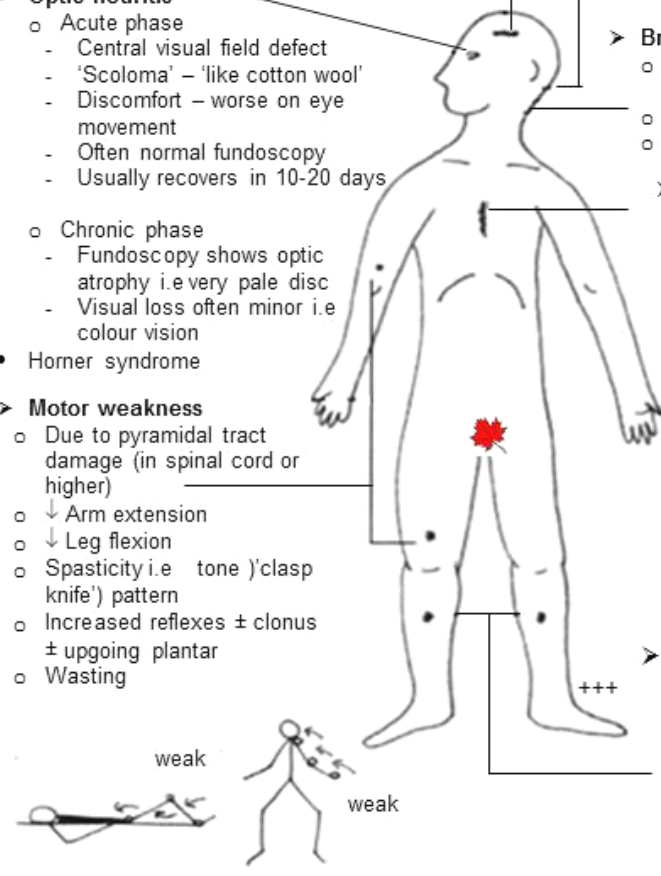
- Dysconjugate eye gaze due to internuclear ophthalmoplegia
- Trigeminal neuralgia - like syndrome
- Recurrent facial nerve palsy

> Spinal cord

- Gradual onset spastic para – or tetraparesis
- Acute 'transverse myelitis' – leads to flaccid paralysis in acute phase, spasticity in chronic phase
- ↓ sensation
 - Joint position
 - Pain/ temperature
- Dorsal column damage → abnormal gait (sensory ataxia) due to loss of position sense
- Lhermitte phenomena bending neck forward → electric shock passing along spine

> Sensory loss

- Difficult to describe – anesthesia or paresthesia (i.e. altered sensation)
- If isolated symptom, differential diagnosis is hyperventilation, or peripheral neuropathy
- Can occur anywhere in the body



Adapted from: Davey P. *Wiley-Blackwell* 2006, page 374.

"Goals in writing are dreams with deadlines"
Brian Tracy



Neurofibromatosis

- For an excellent background to help you to take a directed history and perform a focused physical examination for neurofibromatosis, please see: Baliga RR. *Saunders/Elsevier* 2007, page 196 to 198.

THIS IS FOR THE NEUROLOGY RESIDENT

Q1. What is myasthenic crisis?

A1. Exacerbation of MG, especially bulbar and respiratory involvement, leading to need for ventilation.

Q2. What is cholinergic crisis?

A2. Excessive sensitivity to cholinergics in MG, such as in myasthenic crisis, with excessive salivation, confusion, lacrimation, miosis, pallor and collapse.

Q3. In the person with neurofibromatosis, what is a Lisch nodule?

A3. Lisch nodules are melanocytic hamartomas, well-defined, dome-shaped elevations projecting from the surface of the iris and are clear to yellow and brown.

Q4. In the context of the parietal lobe, what is Gerstmann's syndrome?

- A4.
- Confusion of the right and left side of the body
 - Lack of ability to identify the figures
 - Acalculia

Useful background: Causes of benign intracranial hypertension (Pseudotumor cerebri)

➤ CNS

- Addison's
- Head injury
- Sagittal sinus thrombosis

➤ Endocrine

- Hypoparathyroidism
- Obesity



- Blood
 - Anemia
 - Polycythemia
- Drugs
 - Chlortetracycline, nalixide acid, oral contraceptive agents
 - Change in steroid dosage
- GU
 - Pregnancy
 - Menarche

Adapted from Davies: IJT. *Lloyd-Luke (medical books) LTD 1972, page 286.*

Temporal Arteritis

- Take a directed history for arteritis.
- Systemic
 - Fever, weight loss, fatigue, anorexia
- Head
 - Scalp tenderness
 - Temporal headache
 - Ocular symptoms: Blindness, Diplopia
 - Ptosis
 - Jaw or tongue claudication
 - Mononeuritis multiplex
- Skin lesions
 - Palpable purpura
 - Necrotic ulcers
 - Livedo reticularis
 - Urticaria
 - Nodules and digital infarcts
 - Acute/chronic necrotizing angiitis
 - Erythema nodosum
 - Nodular vasculitis
- MSK



- Anthralgia or arthritis (eg. rheumatoid arthritis, Sjogren's, DS, SLE, scleroderma)
- Myalgia or prominent fibrositis
 - Polymyalgia rheumatico
 - Dermatomyositis
 - Polyarteritis nodosa
 - Wegener's granuloma
 - Aortic arch syndrome

- Cardiac
 - Hypertension

- Infection
 - Extension of inflammation from cellulitis, abscess
 - Sepsis, septic emboli
 - Cutaneous arteritis during infective rash (meningococemia, typhus)
 - Syphilis
 - Tuberculosis

- Pulmonary abnormalities
 - Pulmonary hemorrhage
 - Pulmonary nodules with cavities
 - Dry cough

- GI/GU
 - Abdominal pain
 - Intestinal hemorrhage
 - High liver enzymes, low serum albumin
 - Abnormal renal sediment

- Nonspecific indicators of inflammation
 - Anemia, eosinophilia, thrombocytosis, low levels of albumin, elevated erythrocyte sedimentation rate (ESR)

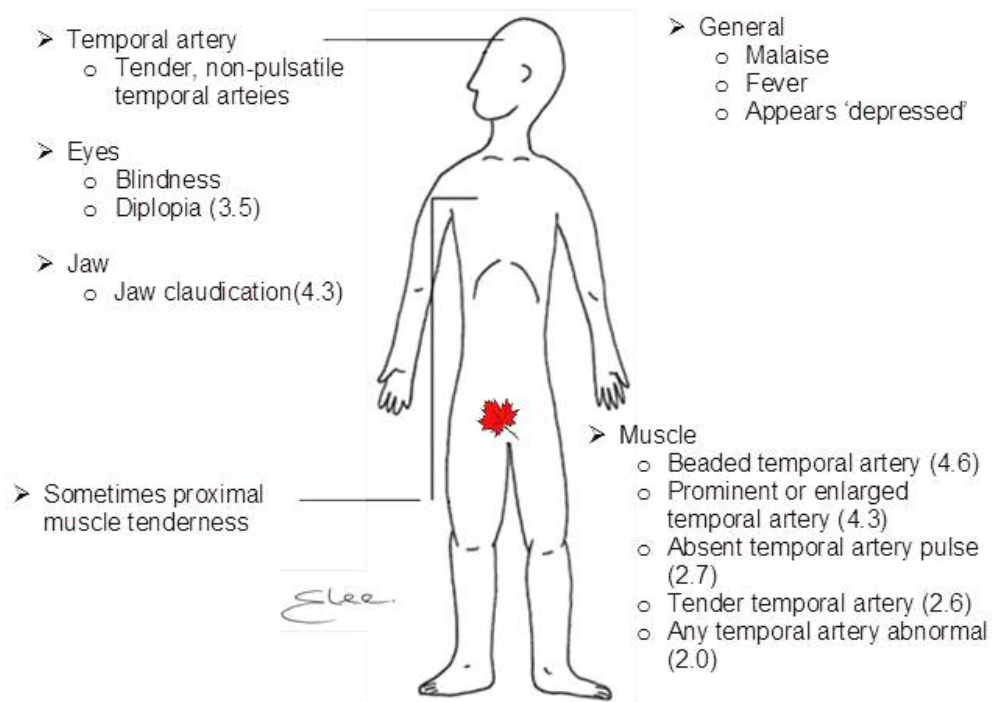
or

- Four of the 5 following criteria for diagnosis
 - Tender, swollen temporal artery
 - Blindness
 - Jaw claudication
 - Polymyalgia rheumatica symptoms
 - Rapid response to corticosteroids



Adapted from: Ghosh AK. *Mayo Clinic Scientific Press* 2008, Table 24-14, page 988.

Useful background: Temporal arteritis



*Note: the numbers show in brackets represent the values of the positive likelihood ratios (PLR). Note that value of the PLR is ≤ 2 for scalp tenderness, optic atrophy, ischemic neuropathy, signs of anemia, or any value of \uparrow ESR.

Adapted from: Davey P. *Wiley-Blackwell* 2006, page 412; Simel DL, et al. *JAMA* 2009, Table 49-5, 49-7, page 654 and 649.



A Little Tip

- The four features of a headache which increase the possibility of temporal arteritis are a temporal location of any headache in a Caucasian with any abnormality of the temporal artery (large, absent, tender) plus an d elevated ESR.

Source: Simel DL, et al. *JAMA* 2009, Table 49-4, page 648 and Table 49-6, page 649.

CT of head

Circumstances when computed tomography (CT) or magnetic resonance imaging (MRI) are preferred for neurologic Imaging

| CT | MRI |
|------------------------------|--|
| ➤ Suspected acute hemorrhage | ○ Subacute & chronic hemorrhage |
| ➤ Skull fractures | ○ Ischemic stroke |
| ➤ Meningiomas | ○ Posterior fossa & brainstem tumor & lesion |
| ➤ Hydrocephalus | ○ Diagnosis of multiple sclerosis |
| | ○ Evaluation of spinal cord |

Abbreviation: SSRI, selective serotonin reuptake inhibitor

Adapted from: Ghosh AK. *Mayo Clinic Scientific Press* 2008, Table 19.2, page 749.

Useful background: Neurological complications of diabetes mellitus

- Cerebellum
 - Cerebral disturbance due to hyper- or hypo glycaemia
- Cranial nerves
 - Isolated cranial nerve lesions
- Spinal column
 - Diabetic pseudotabes
 - Diabetic amyotrophy
- Peripheral nerves



- Asymptomatic loss of ankle jerks and vibration sense, with decreased motor conduction-velocity
 - Painful subacute neuritis, usually in lower limbs
 - Mononeuritis multiplex
 - 'Insulin neuritis' during stabilization
- Autonomic
 - Visceral disturbances due to autonomic involvement
 - Miscellaneous/ mixed
 - Mixed syndromes

Adapted from: Burton JL. *Churchill Livingstone* 1971.

Useful background: Characteristics of paraneoplastic neurological degeneration associated tumours.

- Tumours are often difficult to detect.
- Tumours are histologically identical to tumours that develop in patients without paraneoplastic neurological degeneration (PND), except that many tumours have evidence of immune infiltration. (immunogenic tumors)
- Patients often have improved prognosis relative to those with comparable but non-immunogenic tumours (anti-Hu paraneoplastic syndrome, Lambert-Eaton myasthenic syndrome and some paraneoplastic cerebellar degeneration).
- Spontaneous regression is rare.
- Presence of antitumour immune response predicts improved prognosis (Hu syndrome)
- Tumours are associated with circulating PND-antigen-specific killer T-cells (paraneoplastic cerebellar degeneration).

Source: Davey P. *Wiley-Blackwell* 2006, page 361.

Useful background: For an excellent outline of the clinical varieties of neurosyphilis, please see: Burton J.L. *Churchill Livingstone* 1971, page 88.

- No mass effect (does not enhance with contrast)
 - PML- Progressive multifocal leukoencephalopathy
 - Patchy areas of low attenuation on CT. MRI twice as sensitive. Not contrast enhanced and mass effect is absent. Lesions are



bilateral, asymmetrical usually periventricular and subcortical. May have a normal CT or MRI.

- HIV- HIV encephalopathy. Subcortical and cortical atrophy, non enhancing, symmetrical and bilateral. Usually associated with dementia but no focal motor or sensory deficit.

Useful background: For an excellent background on how to take a directed history of chronic disease, please see Jugovic P.J., et al. *Saunders/ Elsevier*, 2004, page 203.

- A directed history of insomnia: Jugovic PJ, et al. *Saunders/ Elsevier* 2004, pages 51 to 53.
- Give a differential diagnosis of difficulty initiating or maintaining sleep.
 - Transient stress reactions or adjustment reactions
 - Psychiatric disorders (depression, anxiety)
 - Restless leg syndrome
 - Psychophysiological insomnia
 - Drug and /or alcohol abuse
 - Disturbances of sleep wake cycle
 - Sleep related respiratory disorders
- Give a differential diagnosis of a patient having trouble with maintaining wakefulness: Jugovic PJ, et al. *Saunders/ Elsevier* 2004, page 52.

SO YOU WANT TO BE A NEUROLOGIST!

Q1. What is the difference between TIA and reversible ischemic neurological deficit (RIND)?

- A1.
- TIA is a stroke syndrome with neurological symptoms lasting from a few minutes to as long as 24 hours, followed by complete functional recovery.
 - RIND is a condition in which a person has neurological abnormalities similar to acute completed stroke, but the deficit disappears after 14 to 36 hours, leaving few or no detectable neurological sequelae.

Source: Jugovic PJ, et al. *Saunders/ Elsevier* 2004, page 150.

Q2. What is the physical sign which is considered to be pathognomonic of a tumor of the frontal lobe?

A2. The “grasp” reflex



SO YOU WANT TO BE A NEUROLOGIST!

Q. In the context of looking at the anatomy of the oropharynx, what abnormalities are you looking for in the uvula?

- A.
- Absence
 - Congenital
 - Surgical - UPPP (uvulopalatinopharyngoplasty) for obstructive sleep apnea
 - Bifid
 - Occult cleft palate
 - Normal variant

SO YOU WANT TO BE A NEUROLOGIST!

Q1. A patient is thought to possibly have Parkinsonism, but striatonigral degeneration, Shy-Drager syndrome, and olivopontocerebellar atrophy needs to be excluded. Perform a focused physical examination to diagnose the patient's type of multisystem atrophy.

- Striatonigral degeneration
 - Resembles Parkinson's disease, but without tremor
 - Does not respond to anti-Parkinson medications
- Shy- Drager syndrome:
 - Parkinsons disease plus autonomic neuropathy (especially postural hypertension)
 - Impotence
 - Bladder disturbances
- Olivopontocerebellar atrophy
 - Extrapyramidal signs plus cerebellar ataxia
 - Autonomic neuropathy plus anterior horn cell degeneration

Adapted from: Baliga RR. *Saunders/Elsevier* 2007, page 245.



Q2. Name three neurological conditions in which bladder disturbances are rare.

- A2.
- Motor neuron disease
 - Subacute combined degeneration
 - Peripheral neuritis
 - Extrapyrarnidal disease

Q3. Canada is a multicultural country, and many different languages are spoken. When asking the patient to “say something” for you to access if there are abnormally transmitted voice sounds, what can you ask the non-English language speakers to say?

A3. All five vowel sounds (A, E, I, O, U) become “a”, so pick words with vowels.

Source: Mangione S. *Hanley & Belfus* 2000, page 331

Q4. In the context of the frontal lobe of the cerebral cortex, what is the Foster Kennedy syndrome?

A4. Optic atrophy on the side of compression of the optic nerve by the frontal lobe, and papilledema of the opposite eye resulting from increased intracranial pressure.

Q5. What are the physical findings found in a person with Pick’s presenile dementia?

A5. That’s right: Good answer – Same findings as disturbed function of the frontal lobe of the cerebral cortex

SO YOU WANT TO BE A NEUROLOGIST!

Q1. Why are the upper portions of the body affected less than the lower body by a vascular lesion of the middle cerebral artery (which supplies the internal capsule)?

A1. The fibers which supply the lower portion of the body are in the posterior portion of the internal capsule, and are supplied by only one vessel, whereas the fibers which supply the upper portion of the body are in the anterior portion of the internal capsule, which has a dual blood supply.

Q2. Do you wish to be really mean? What are the methods of eliciting deep pain?

- A2
- Abadie’s sign – the loss of pain sense in the Achilles tendon.
 - Biernacki’s sign – the absence of pain on pressure on the ulnar nerve.
 - Royal College Sign – too many questions on neurology.
 - Pitres’ sign – loss of pain on pressure on the testes.
 - Haenel’s sign – analgesia to pressure on the eyeballs.

Source: Baliga RR. *Saunders/Elsevier* 2007, page 201.



A3. A peripheral nerve lesion.

Q4. What conditions demonstrate an up - going plantar reflex but absent knee reflexes?

- A4. Friedreich's ataxia
 Multiple sclerosis
 Peripheral neuropathy in a stroke patient.
 Motor neuron disease.
 Conus medullaris-cauda equina lesion.
 Tabes dorsalis
 Subacute combined degeneration of the spinal cord

Q5. What are the causes of absent knee and ankle jerks, with an extensor plantar response?

- A5. Sub-acute combined degeneration
 Syphilitic tabo-paresis
 Friedreich's ataxia
 Motor neurone disease

Source: Burton JL. *Churchill Livingstone* 1971, page 88.

Q6. What is cerebellar speech?

A6. Slow irregular speech, with sudden changes in speed and volume

SO YOU WANT TO BE A NEUROLOGIST!

Q1. The signs of foramen magnum pressure cone caused by increased pressure in the foramen magnum may be mimicked by what bony conditions?

- A1. Invagination of the base of the skull into the upper cervical spine, from
 - Congenital anomaly
 - Osteomalacia
 - Paget's disease
 Fusion of the cervical vertebrae
 - Congenital anomaly (aka Klippel-Feil deformity)

Q2. What dysarthrias may be of psychological origin?

A2. Stuttering and stammering



Q3. What are the differences between receptive and expressive aphasia?

A3. Aphasia is an acquired disturbance of language

- Receptive aphasia (sensory, fluent or Wernicke's aphasia)
 - Lesion in temporal or parietal lobe
 - Jumbled words
 - Difficulty naming objects
 - Poor comprehension of spoken or written words
- Expressive aphasia (motor, nonfluent or Brocca's aphasia)
 - Lesion in frontal lobe
 - Good comprehension of spoken or written words
 - Slow, monosyllabic sentences

Q4. What is dysarthria, and what are its causes?

A4. Dysarthria is the poor articulation of words

- Causes
 - Brain
 - Injury
 - Muscles of phonation
 - Paralysis
 - Spasticity
 - Emotional stress

Q5. In the context of examining the uvula, what is Mueller's sign

A5. Rhythmic pulsatile movement of uvula seen in chronic aortic regurgitation

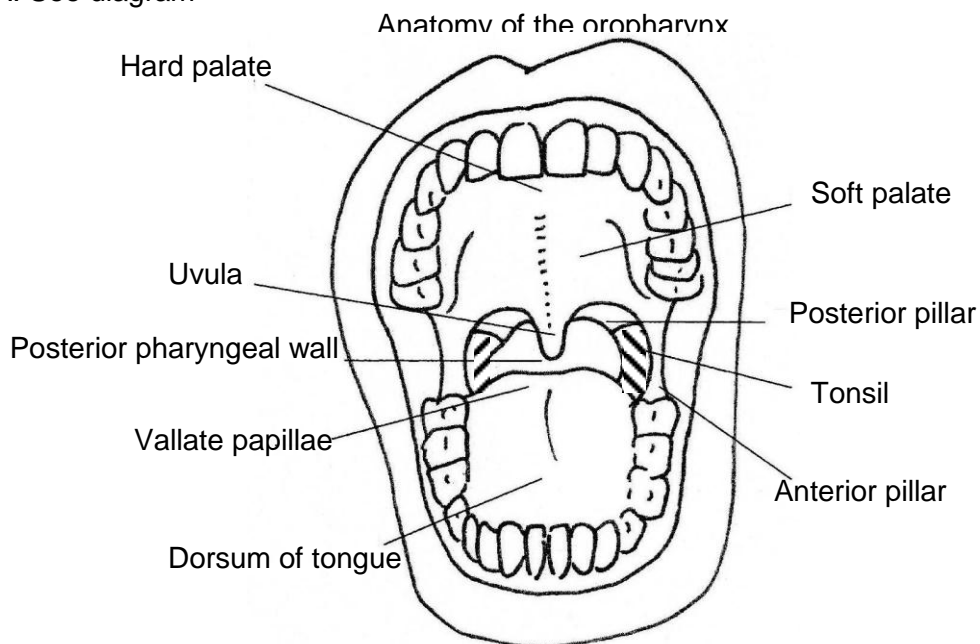
Adapted from: Mangione S. *Hanley & Belfus* 2000, page 123.



SO YOU WANT TO BE A NEUROLOGIST!

Q. When you ask the patient to say "Ahh", what structures are you looking at?

A. See diagram



Source: Mangione S. *Hanley & Belfus* 2000, page 123.



RESPIROLOGY



Table of Contents

| | Page |
|--|-------------|
| Questions in Respirology Chapter | 367 |
| Commonly used terms | 370 |
| Chest examination | 372 |
| Tracheal deviation | 388 |
| Cough | 389 |
| Hemoptysis | 392 |
| Consolidation, collapse, effusion, fibrosis | 392 |
| Clubbing | 404 |
| Granulomatous lung disease | 411 |
| Pulmonary fibrosis | 413 |
| Pneumonia | 417 |
| Influenza | 424 |
| Airflow obstruction and Asthma | 425 |
| Chronic obstructive pulmonary (lung) disease (COPD) | 436 |
| Carcinoma of the lung | 442 |
| Pulmonary hypertension and Cor pulmonale | 450 |
| Acute respiratory distress syndrome (ARDS) | 453 |
| Deep vein thrombosis | 457 |
| Pneumothorax | 462 |
| Lung abscess | 463 |
| Bronchiectasis | 464 |
| Extrinsic allergic alveolitis (hypersensitivity pneumonitis) | 465 |
| Chest X-ray | 470 |
| Suggested practice case scenarios for OSCE examinations | 495 |



Questions in Respiriology Chapter

1. Give an approach to the auscultation of the breath sounds to determine the nature of underlying lung disease.
2. Perform a focused physical examination for causes of Cheyne-Stoke respiration.
3. Perform a directed physical examination for asymmetry in the expansion of the chest.
4. Perform a directed physical examination of the pulmonary system for tracheal deviation.
5. Take a directed history for cough.
6. Take a directed history of hemoptysis.
7. Perform a focused physical examination for fibrosing alveolitis
8. Perform a directed physical examination of the pulmonary system for consolidation, collapse, effusion, or fibrosis.
9. Give the causes of pulmonary fibrosis
10. Perform a focused physical examination to distinguish between the major causes of dullness at a lung base.
11. Give 3 causes of dullness of the lung base not related to consolidation, cavitation or callable.
12. Perform a focused physical examination to distinguish between the four commonest causes of dullness at the base of the lung.
13. Perform a focused physical examination to distinguish between peripheral versus central cyanosis.
14. Perform a focused physical examination for a pulmonary cavity.
15. Perform a directed physical examination for clubbing.
16. Give a systematic approach to the causes of clubbing.
17. Perform a directed physical examination for sarcoidosis.
18. Perform a focused physical examination for sarcoidosis.
19. Give a systematic approach to the causes of pulmonary fibrosis.
20. Give the typical radiological features of silicosis.
21. Give the typical signs of pulmonary infarction seen on chest X-ray.
22. Perform a focused physical examination for complications of pneumonia.
23. Give a systematic approach to the causes of recurrent pneumonias.

24. Take a directed history for asthma.
25. Perform a focused physical examination for asthma.
26. Take a directed history and perform a focused physical examination for asthma.
27. Take a focused history and perform a directed physical examination for chronic bronchitis.
28. Take a directed history to differentiate between bronchial asthma, chronic bronchitis, and emphysema.
29. Take a directed history for the harmful effects of cigarette smoking.
30. Take a focused history and perform a directed physical examination for bronchiectasis.
31. Perform a focused physical examination for bronchiectasis.
32. Take a directed history and perform a focused physical examination for the effects/complications of smoking.
33. Perform a directed physical examination of the pulmonary system in the patient with suspected mediastinal compression (e.g. carcinoma of the lung).
34. Perform a focused physical examination for lung cancer.
35. Perform a directed physical examination for Pancoast's (superior pulmonary sulcus tumor) syndrome (often from cancer [often non-small cell] of the apex of the lung, infiltrating C8, T1, 2; may also occur with lymphoma, or by spread of lymph node metastases in breast or lung cancer).
36. Give a systematic approach to the non-metastatic, non-pulmonary complications of bronchial cancer.
37. Provide a systematic approach to the tumors which are associated with polycythemia.
38. Give the non- metastatic, extra – pulmonary complications of bronchial carcinoma.
39. Take a directed history and perform a focused physical examination for pulmonary hypertension.
40. Perform a focused physical examination for cor pulmonale
41. Perform a focused physical examination for acute respiratory distress syndrome (ARDS).
42. Take a directed history and perform a focused physical examination to determine the possible presence of a deep vein thrombosis (DVT).



43. Take a focused history for the causes of pneumothorax.
44. Take a focused history for the causes of lung abscess.
45. Take a directed history and perform a focused physical examination for fibrosing alveolitis.
46. Take a focused history and perform a focused physical examination for obstructive sleep apnea (aka Pickwickian Syndrome).
47. Give the typical signs of hyperinflation seen on chest X-ray.
48. Give the distinction between pulmonary fibrosis (PF) vs collapse (C) on a chest X-ray.
49. Give the chest X-ray findings of each of the following
50. Give 15 causes of mediastinal tumors seen on chest X-ray



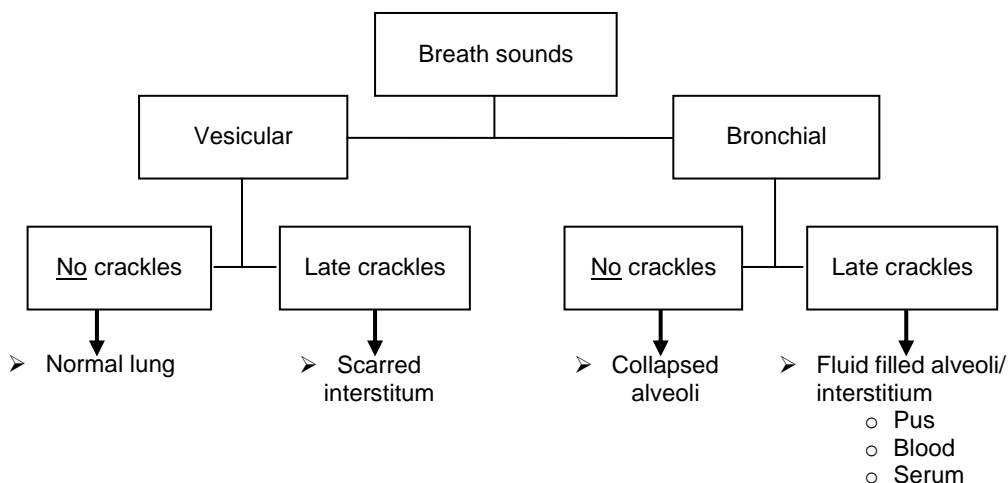
Commonly used terms

- Pectus carinatum-
 - Pigeon chest
- Pectus excavatum
 - Funnel test
- Adventitial sounds
 - Continuous “wheezes”; discontinuous “crackles”
- Inspiratory wheeze
 - Severe airway narrowing
- Stridor
 - Foreign body tumor
 - Gas inhalation
 - Anaphylaxis
 - Epiglottitis
 - Bilateral vocal cord palsy
- Bronchial breath sounds
 - Normal
 - Pneumonia, fibrosis, effusion, collapse
- Broadbent’s sign
 - Systolic retraction of intercostals space, especially seen at the post auxiliary line just below the angle of the scapula, with cardiac hypertrophy or fibrous pericarditis
- Pulsus alternans
 - Strong/weak pulse in CHF
- Sinus arrhythmia
 - ↑HR with inspiration
- Pulsus paradoxicus
 - The normal ↑height of pulse wave with inspiration is lost
- Krönig’s isthmus
 - A posterior band of resonance 2 inches wide across the shoulder from the apex of the lung, which extends 1 inch above the clavicles.
- Distinguish pulmonary rub versus rales



- Present in both phases of respiration, but rub is enhanced by increasing the pressure on the stethoscope (closer to ear), and a rub is not affected by coughing
- Pectoriloquy
 - ↑Intensity of spoken voice
 - Bronchophony - ↑clarity of the spoken voice
- Pursed-lip breathing
 - Pursed lips increase positive pressure in the weakened bronchial airways in emphysema and COPD, thereby helping to prevent the airway trapping
- Kussmaul breathing
 - Rapid, deep breathing due to metabolic-diabetic ketoacidosis, lactic acidosis, uremia
 - Drugs and poisons – methanol, ethylene glycol, ASA, paraldehyde
- When is orthopnea due to lung disease
 - Dyspnea relieved by sitting up is usually due to L-CHF, but may rarely occur with bilateral bullous apical disease, when sitting up improves the ventilation/perfusion matching and gas exchange in the normal lower lung
- Horner's syndrome - apical lung tumor compressing sympathetic nerves in neck, causing myosis, ptosis and anhidrosis
- What are you looking for when you are examining accessory muscles?
 - Motion in scalene muscles (earliest affected), sternocleidomastoid muscles, neck muscles, in drawing of intercostal spaces and supraclavicular fossa
 - Abdominal motion when person inspires.
- What is paradoxical respiration?
 - The abdomen draws inward on inspiration when it normally should move outward due to diaphragm descent
- Position of trachea
 - Palpate the trachea in the suprasternal notch to determine if it is midline
 - Trachea is deviated to *ipsilateral* side in atelectasis, fibrosis, lung collapse
- Give an approach to the auscultation of the breath sounds to determine the nature of underlying lung disease.





Chest examination

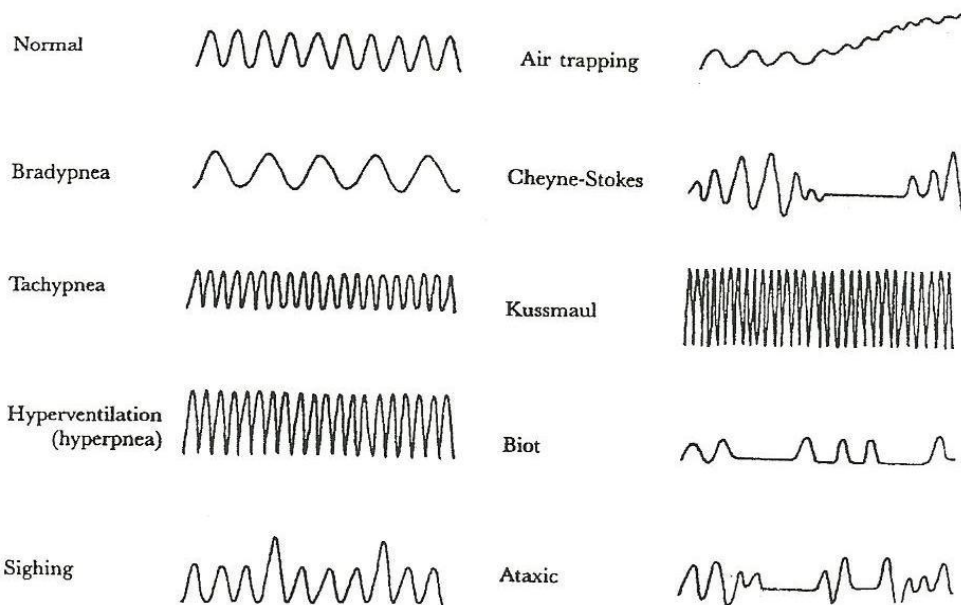
Patterns of Respiration

- Cheyne-Stokes respiration
 - Progressive increase in depth \pm frequency of breathing, followed by an interval of apnea
 - Regularly irregular pattern
- Biot's breathing
 - A series of increase in the depth \pm frequency of breathing, followed by an interval of apnea, without the Cheyne-Stokes regular-irregular pattern

Useful background: Abnormalities in rhythm of respiration.

- Abnormal rhythms of respiration usually result from lesions in the neurogenic control of the respiratory pump.
- They help to localize the site of neurologic lesions. Abnormalities of respiratory rhythm are found in the following sequence from the uppermost to the lower-most neurologic center.
 - Cheyne-Stokes respiration
 - Biot's respiration
 - Apneustic breathing
 - Central hyperventilation
 - Ataxic (agonal) respiration





Adapted from: Mangione S. *Hanley & Belfus* 2000, page 279.

- Perform a focused physical examination for causes of Cheyne- Stoke respiration.
 - All causes of CHF
 - Renal failure
 - Increased intracranial pressure

Inspection: Chest Asymmetry

- Perform a directed physical examination for asymmetry in the expansion of the chest.
 - Inspection
 - Instruct patient to inhale deeply while watching for slow expansion of one hemithorax
 - Pigeon chest, funnel chest
 - Lordosis, kyphosis, gibbus (extreme kyphosis, aka hunchback)
 - Palpation
 - Causes
 - Atelectasis
 - Pleural effusion
 - Severe pneumonia



- Complications
 - Cyanosis, chibbing
 - Asterixis (hypercapnea)

Adapted from: Mangione S. *Hanley & Belfus*, 2000, pages 281 and 282.

Useful background:

- Causes of Platypnea (preference for the breathing in a lying position; caused by a bilateral pulmonary process)
 - Recurrent pulmonary emboli
 - Pleural effusion
 - Bibasilar pneumonia
 - Bibasilar AV shunts
 - ASD
- Tachypnea, increased rate of breathing (>20/min)
 - If present – suggests cardiopulmonary disease (CPD)
 - If absent – argues strongly against CPD
- Hyperpnea (increase rate and depth [tidal volume] of breathing)
- Finding in anion – gap metabolic acidosis (“**MAKE UP** a List”)

Methanol

Uremia

Aspirin

Paraldehyde

Ketoacidosis

Ethylene Glycol ingested

Lactoacidosis

Source: Mangione S. *Hanley & Belfus* 2000, pages 278 to 280.

SO YOU WANT TO BE A RESPIROLOGIST!

Q. What is Behcet’s syndrome?

A. Aphthous ulcers in mouth and genitals, associated with arthritis, uvertis and various neurological disorders

Source: Mangione S. *Hanley & Belfus* 2000, page 67.



Useful background: Types of positional dyspnea

| Type | Possible causes |
|--|--|
| ➤ Orthopnea (dyspnea {SOB, shortness of breath}) | <ul style="list-style-type: none"> ○ Congestive heart failure ○ Mitral valvular disease ○ Severe asthma (rarely) ○ COPD (rarely) ○ Neurological diseases (rarely) |
| ➤ Trepopnea (SOB when lying on one side) | <ul style="list-style-type: none"> ○ Congestive heart failure |
| ➤ Platypnea (SOB when seated) | <ul style="list-style-type: none"> ○ Status post pneumonectomy ○ Neurological diseases ○ Cirrhosis (intrapulmonary shunts) ○ Hypovolemia |


Source: Filate W, et al. *The Medical Society, Faculty of Medicine, University of Toronto* 2005, Table 2, page 282.

Little trick


- Orthopnea
 - Dyspnea at rest
 - Unusual in lung disease, or severe anemia

Breath Sounds

Useful background: normal auscultatory breath sounds



Tubular (tracheal/bronchial)



Bronchovesicular



Vesicular (soft/ muffled)



| Characteristic | Tracheal | Bronchial | Bronchovesicular | Vesicular |
|--------------------|-----------------------|--------------------------|-----------------------|------------------------|
| ➤ Description | Harsh | Air rushing through tube | Rustling, but tubular | Gentle rustling |
| ➤ Intensity | Very loud | Loud | Moderate | Soft |
| ➤ Pitch | Very high | High | Moderate | Low |
| ➤ Insp./exp. Ratio | 1:1 | 1:3 | 1:1 | 3:1 |
| ➤ Normal Location | Extrathoracic trachea | Manubrium sterni | Mainstem bronchi | Peripheral lung fields |

| Respiratory sound | Mechanisms | Origin | Acoustics | Relevance |
|-------------------|---|-----------------------------|---|--|
| ○ Wheeze | - Airway wall flutter (vortex shedding) | - Central and lower airways | - Sinusoid (range 100 to > 1,000 Hz; duration, typically > 80 ms) | - Airway obstruction, flow limitation |
| ○ Rhonchus | - Rupture of fluid films | - Large airways | - Series of rapidly dampened sinusoids (typically < 300 Hz and duration > 100 ms) | - Secretions, abnormal airway collapsibility |
| ○ Crackle | - Airway wall stress-relaxation | - Central and lower airways | - Rapidly dampened wave deflection (duration typically < 20 ms) | - Airway closure, secretions |

Adapted from: Mangione S. *Hanley & Belfus* 2000, page 279 and 297; and Filate W., et al. *The Medical Society, Faculty of Medicine, University of Toronto* 2005, Table 6, page 286.



Useful background: Effect of pulmonary disease on lung sounds

| Respiratory sound | Mechanisms | Origin | Acoustics | Relevance |
|-------------------------|--|---|---|--|
| ➤ Basic sounds | | | | |
| ○ Normal lung sound | - Turbulent flow vortices | - Central airways (expiration), lobar to segmental airway (inspiration) | - Low-pass filtered noise (range < 100 to 1,000 Hz) | - Regional ventilation, airway caliber |
| ○ Normal tracheal sound | - Turbulent flow, flow impinging on airway walls | - Pharynx, larynx, trachea, large airways | - Noise with resonances (range < 100 to > 3,000 Hz) | - Upper airway configuration |

| Lung disease | Breath sounds | Adventitious lung sound |
|----------------------------|------------------------------|------------------------------|
| ➤ Pneumonia | ○ Harsh/ bronchial or absent | ○ Late inspiratory crackles |
| ➤ Atelectasis | | |
| ➤ Pneumothorax | ○ ↓/Absent | ○ None |
| ➤ Emphysema | ○ ↓ | ○ Early inspiratory crackles |
| ➤ Chronic bronchitis | ○ Normal | ○ Wheezes, crackles |
| ➤ Pulmonary fibrosis | ○ Harsh | ○ Inspiratory crackles |
| ➤ Congestive heart failure | ○ ↓ | ○ Inspiratory crackles |
| ➤ Pleural effusion | ○ ↓ | ○ None |
| ➤ Asthma | ○ ↓ | ○ Wheezes |

Source: Mangione S. *Hanley & Belfus* 2000, page 304.



Useful background: Adventitious sounds

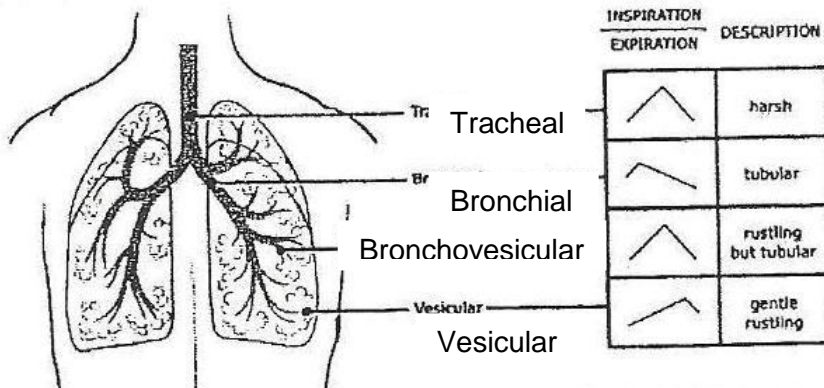
| | Tracheal | Bronchial | Bronchovesicular | Vesicular |
|-----------------------|-----------------------|--------------------------|-----------------------|------------------------|
| Characteristic | | | | |
| ➤ Description | Harsh | Air rushing through tube | Rustling, but tubular | Gentle rustling |
| ➤ Intensity | Very loud | Loud | Moderate | Soft |
| ➤ Pitch | Very high | High | Moderate | Low |
| ➤ Insp./exp. Ratio | 1:1 | 1:3 | 1:1 | 3:1 |
| ➤ Normal Location | Extrathoracic trachea | Manubrium sterni | Mainstem bronchi | Peripheral lung fields |

| Respiratory sound | Mechanisms | Origin | Acoustics | Relevance |
|-------------------|---|-----------------------------|---|--|
| ○ Wheeze | - Airway wall flutter (vortex shedding) | - Central and lower airways | - Sinusoid (range 100 to > 1,000 Hz; duration, typically > 80 ms) | - Airway obstruction, flow limitation |
| ○ Rhonchus | - Rupture of fluid films | - Large airways | - Series of rapidly dampened sinusoids (typically < 300 Hz and duration > 100 ms) | - Secretions, abnormal airway collapsibility |
| ○ Crackle | - Airway wall stress-relaxation | - Central and lower airways | - Rapidly dampened wave deflection (duration typically < 20 ms) | - Airway closure, secretions |

Adapted from: Filate W, et al. *The Medical Society, Faculty of Medicine, University of Toronto* 2005, Table 7, page 286.



Useful background: Patterns of breathing



Illustrated by Heidi Maj

Adapted from: Filate W, et al. *The Medical Society, Faculty of Medicine, University of Toronto* 2005, Figure 4, page 286.

Useful background: Performance characteristics for pulmonary auscultation for breath sounds and vocal resonance

| Finding | PLR |
|--|------|
| ○ Breath sound score | |
| Detecting chronic airflow obstruction | |
| <9 | 10.2 |
| 10-12 | 3.6 |
| ○ Diminished breath sounds | |
| Detecting underlying pleural effusion in mechanically ventilated patient | 4.3 |
| Detecting asthma during methacholine challenge | 4.2 |
| Detecting pneumonia in patients with cough and fever | 2.3 |
| ○ Bronchial breath sounds | |
| Detecting pneumonia in patients with cough and fever | 3.3 |
| ○ Egophony | |
| Detecting pneumonia in patients with cough and fever | 4.1 |

Abbreviation: PLR, positive likelihood ratio

Adapted from: McGee SR. *Saunders/Elsevier* 2007, Box 27.1, page 330.


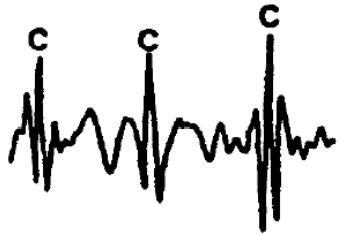


Useful background: Characteristics of crackles in various disorders



| Diagnosis | Mean number of crackles per inspiration | Timing of crackle | Type of crackle |
|-------------------------------|---|----------------------------------|-----------------|
| ○ Pulmonary fibrosis | 6-14 | Late inspiratory (0.5→0.9) | Fine |
| ○ Pneumonia | 3-7 | Paninspiratory (0.3→0.7) | Coarse |
| ○ Chronic airflow obstruction | 1-4 | Early inspiratory (0.3→0.5) | Coarse or fine |
| ○ Congestive heart failure | 4-9 | Late or paninspiratory (0.4→0.8) | Coarse or fine |

Permission granted: McGee SR. *Saunders/Elsevier* 2007, Table 27-3, page 339.

ABNORMAL BREATH SOUNDS

| Recommended ATS Nomenclature | Acoustic Characteristics | Wave form |
|--|--|--|
| ➤ Coarse crackle (aka "coarse rale") | <ul style="list-style-type: none"> ○ Discontinuous interrupted explosive sounds ○ Loud low pitch |  |
| ➤ Fine crackle (aka "fine rale crepitation") | <ul style="list-style-type: none"> ○ Discontinuous, interrupted explosive sounds ○ Less loud than coarse rale, and shorter duration; higher in pitch than coarse rales or crackles |  |



| Recommended
ATS
Nomenclature | Acoustic
Characteristics | Wave form |
|---|---|--|
| ➤ Wheeze
(aka “sibilant
rhonchus”) | <ul style="list-style-type: none"> ○ Continuous sounds ○ Longer than 250 ms, high pitched |  |
| ➤ Rhoncus
(aka “sonorous
rhonchus”) | <ul style="list-style-type: none"> ○ Continuous sounds ○ Longer than 250 ms ○ low pitch ○ snoring sound |  |

Abbreviation: C, Crackles

Adapted from: Mangione S. *Hanley & Belfus* 2000, page 310.

- Normal crackles are usually end-inspiratory and high-pitched, and resemble the late inspiratory crackles of interstitial fibrosis. They usually resolve after a few deep inspirations.
- In healthy persons, crackles represent the reinflation of atelectatic lung units. The greater number of collapsed units, the greater the number of crackles generated. These crackles are generally limited to the posterior lung bases. They occur frequently in people who have been breathing close to their functional residual capacity, and then are suddenly asked to take a deep breath. Because a mild degree of basilar collapse is common in healthy persons breathing shallowly below closing capacity, many basilar airways are collapsed. This collapse leads to the reabsorption of oxygen and further atelectasis. The sudden reopening of these airways on inspiration generates the crackles.

Adapted from: Mangione S. *Hanley & Belfus* 2000, page 317.

Sweet Nothings:

- Posture-induced crackles (PIC) are associated with elevated values of the pulmonary venous compliance. PIC is an independent variable for risk assessment after the number of disease coronary vessels, and increased PCWP (pulmonary capillary wedge pressure).
- A localized persistent rhonchus may indicate underlying lung cancer.

Source: Mangione S. *Hanley & Belfus* 2000, page 323.



Useful background: The role of various techniques of chest examination in the diagnosis of disease - Chest examination findings and disease processes

| Disease | Trachea | Fremitus | Percussion note | Breath sounds | Advential breath sounds | Transmitted Breath sounds |
|---|--------------------------|----------|--------------------------|--|--|---|
| ➤ Normal lung | Midline | Normal | Resonant | Vesicular | Late-inspiratory crackles at bases (resolve with deep breaths) | Absent |
| ➤ Consolidation (pneumonia, hemorrhage) | Midline | ↑ | Dull | Bronchial | Late-inspiratory crackles | + |
| ➤ Pulmonary fibrosis | Midline | Normal | ↑ Resonant | Brocnhovesicular | Late-inspiratory crackles | - |
| ➤ Bronch-iectasis | Midline | Normal | Resonant | Vesicular | Mid-inspiratory crackles | - |
| ➤ Bronchitis | Midline | Normal | Normal to hyper-resonant | Vesicular | Early-inspiratory crackles | - |
| ➤ Emphysema | Midline | | ↓ Hyper-resonant | Diminished vesicular | Usually absent | - |
| ➤ Large pleural effusion | Shifted to opposite side | | ↓/0 Flat | Bronchial immediately above effusion
Absent over effusion | ? Rub above effusion | May be present above effusion
Absent over effusion |
| ➤ Pneumothorax | Shifted to opposite side | | ↓/0 Tympanic | - | - | - |
| ➤ Atelectasis (patent bronchi) | Shifted to same side | ↑ | Dull | Bronchial | - | + |
| ➤ Atelectasis (plugged bronchi) | Shifted to same side | | ↓/0 Dull | - | - | - |



| Disease | Trachea | Fremitus | Percussion note | Breath sounds | Advential breath sounds | Transmitted Breath sounds |
|----------------------|---------|----------|-----------------|----------------|-------------------------|---------------------------------|
| ➤ Status asthmaticus | Midline | | ↓ | Hyper-resonant | Vesicular | Inspiratory/ expiratory wheezes |

Abbreviation: advent, adventitial; trans, transmitted

Adapted from: Mangione S. *Hanley & Belfus* 2000, pages 291-292 and 297.

Useful background:

- Mechanisms causing abnormalities in pO₂ and pCO₂
 - ↓ ventilation - ↑ pCO₂
 - ↓ diffusion - ↓ pO₂
 - Ventilation/ perfusion defects - ↓ pO₂, ↓ pCO₂
 - ↓ compliance
- Causes of decreased compliance
 - Fibrosis
 - Congestion
 - Deformity of chest wall
- Acid-base balance: handling of H⁺
 - In kidney, H⁺ combines with HCO₃⁻, NH₃⁻, NaHPO₄
 - In blood, H⁺ is buffered by HCO₃⁻, PO₄²⁻ or protein (especially reduced hemoglobin)
 - Acid (H⁺) and HCO₃⁻ (H⁺ + HCO₃⁻ → H₂CO₃, AKA carbonic acid) shift the oxygen dissociation curve to the right, causing hemoglobin unload its O₂.
- Movement
 - Chest wall ~ 3 to 5 cm
 - Hemidiaphragm ~ 1 cm
- Cause of late inspiration crackles (produced by reopening small airways in inspiration):
 - Interstitial fibrosis
 - Interstitial edema
 - Pneumonia
 - Pulmonary hemorrhage
 - CHF



- Mid inspiration crackles
 - Usually pathogenomic of bronchiectasis
- Bronchial Breath Sounds
 - Higher and higher-pitch than vesicular breath sounds.
 - Present in areas of airless lungs and patent bronchi (alveolar pneumonia) leading to collapse of alveolar lung tissue, or filling of alveoli with pus, blood or edema fluid, or rarely bronchial breath sounds may be heard over areas of severe fibrosis.
 - Chest X-ray may show air bronchogram (air-filled bronchi against the background of disease, airless, consolidated alveoli (lung parenchyma)).

Source: Mangione S. *Hanley & Belfus* 2000, page 307.

Useful background: Performance characteristics of crackles and wheezes heard on pulmonary auscultation

| Finding | PLR |
|---|------|
| ➤ Crackles | |
| ○ Detecting pulmonary fibrosis in asbestos workers | 5.9 |
| ○ Detecting elevated left atrial pressure in patients with cardiomyopathy | 3.4 |
| ○ Detecting myocardial infarction in patients with chest pain | 2.1 |
| ○ Detecting pneumonia in patients with cough and fever | 1.8 |
| ➤ Early inspiratory crackles | |
| ○ Detecting chronic airflow obstruction in patients with crackles | 14.6 |
| ○ Detecting severe disease in patients with chronic airflow obstruction | 20.8 |
| ➤ Unforced wheezing | |
| ○ Detecting chronic airflow obstruction | 2.8 |
| ➤ Wheezing during methacholine challenge testing | |
| ○ Detecting asthma | 6.0 |

Abbreviation: PLR, positive likelihood ratio

Crackles from pulmonary edema disappear on coughing, while pleural rub does not. Crackles from fibrosing alveolitis do not disappear on coughing, and lessen on leaning forward.

Adapted from: McGee SR. *Saunders/Elsevier* 2007, Box 27.2, page 338.

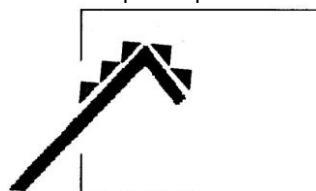

SO YOU WANT TO BE A RESPIROLOGIST!

Q1. Can you distinguish a pleural rub from a crackle, a wheeze and a pericardial rub?

- A1. ➤ A pleural rub
- Present during both inspiration and expiration (never present only in expiration)
 - Does not change with coughing
 - Long, louder, lower-pitched than crackle
 - May be palpable
- A wheeze
- Usually occur in expiration only, whereas rubs are usually heard in both inspiration and expiration, or just in inspiration, but never only in expiration.
- A pericardial rub
- If the rub persists when the breath is held, then (dah!) it is more likely a pericardial than a pleural rub.

Graphic representation



Source: Mangione S. *Hanley & Belfus* 2000, pages 310, 328 and 329.

Q2. How can you suspect if a person's dyspnea is on an hysterical basis?

A2. The breathing is deep, and the person holds their breath after about every six breaths.

SO YOU WANT TO BE A RESPIROLOGIST!

Q. Does pneumonia increase or decrease tactile vocal fremitus (TVF)?

A. It depends in bronchopneumonia (involving bronchi and alveoli, often from H. Influenza, with bronchial mucus plugs), ↑ in alveolar pneumonia (infection in alveoli but bronchial tree leaves bronchi pattern; the infectious fluid in the alveoli plus the air in the bronchi make the TVF increase).

Source: Mangione S *Hanley & Belfus*, 2000, page 288.



SO YOU WANT TO BE A RESPIROLOGIST!

Q1. Are breath sounds reduced when auscultated over a pleural effusion?

- A1. It depends.
- Above the effusion-normal
 - At the margin of the effusion-increased
 - Over the rest of the effusion-reduced

Source: Mangione S. *Hanley & Belfus* 2000, page 305.

Q2. What is the effect of coughing on expiratory crackles?

- A2. Obstructive disease, decreased coarse expiratory crackles restrictive disease, no change with coughing.

Source: Mangione S. *Hanley & Belfus* 2000, page 315.

Q3. Are late inspiratory crackles common in all types of interstitial lung disease?

- A3. Common in Idiopathic Pulmonary Fibrosis (IPF) or Asbestosis (60%), but uncommon in sarcoidosis (18%; upper lobe and peribronchial fibrosis, vs lower lobe and subpleural fibrosis in IPF).

Source: Mangione S. *Hanley & Belfus* 2000, page 317.

Q4. During auscultation of the chest, if you hear crackles or rhonchi, do you ask the patient to cough?

- A4. Why not! Coughing clears the crackles and rhonchi of airflow obstruction caused by extra sounds at air-fluid interfaces of medium-to-large airways.

Q5. What is the cause of a clicking sound which is synchronous with systole?

- A5. Left – side pneumothorax

Q6. How does “Biot breathing” differ from Cheyne – Stokes breathing?

- A6.
- Short periods of irregular breathing (varying rate and depth), Followed by periods of apnea
 - Usually seen in association with meningitis
 - Biot breathing lacks the waxing and waning of Cheyne- Stokes breathing



SO YOU WANT TO BE A RESPIROLOGIST!

Q1. What is respiratory alternans (aka paradoxical respiration, or abdominal paradox)?

A1. Normally with inspiration both chest and abdominal wall rises. With muscular weakness and fatigue, the abdominal wall does not rise.

Q1. In the persons with smoker's face and nicotine staining of fingers, pursed lips and using the accessory muscles of expiration (intercostals muscles), what is Dahl's sign?

A1. Patches of hyperpigmented culluses above both knees from chronic pressure of the elbows on the skin of the legs resulting from sitting up and leaning forward to breath better (orthopnea), placing the elbows near the knees and fixing the position of the shoulder and the neck muscles to improve the contractility of the accessory muscles and improving basilar perfusion and lung mechanics.

Source: Mangione S. *Hanley & Belfus* 2000, pages 277 and 280.

Q2. In what cause of bronchopneumonia is bronchial breathing as well as other physical findings usually absent, or minimal?

A2. Viral bronchopneumonia

Q3. From inspection of the patient, how can you distinguish between cyanosis and met-/ sulphemoglobinemia?

A3. Persons with an excess of these abnormal hemoglobins do not have dyspnea.

PTFs

Q. How can you estimate the value of FEV₁/FVC with your stethoscope?

| A. | FET ₀ | FEV ₁ /FVC |
|--|------------------|-----------------------|
| Auscultate over sternal notch and time how long it takes the patient to take a deep breath and blow out hard. This gives the forced-expiratory time (FET ₀). | >6 sec
<5 sec | ≤ 40%
> 60% |

Source: Mangione S. *Hanley & Belfus* 2000, page 304.

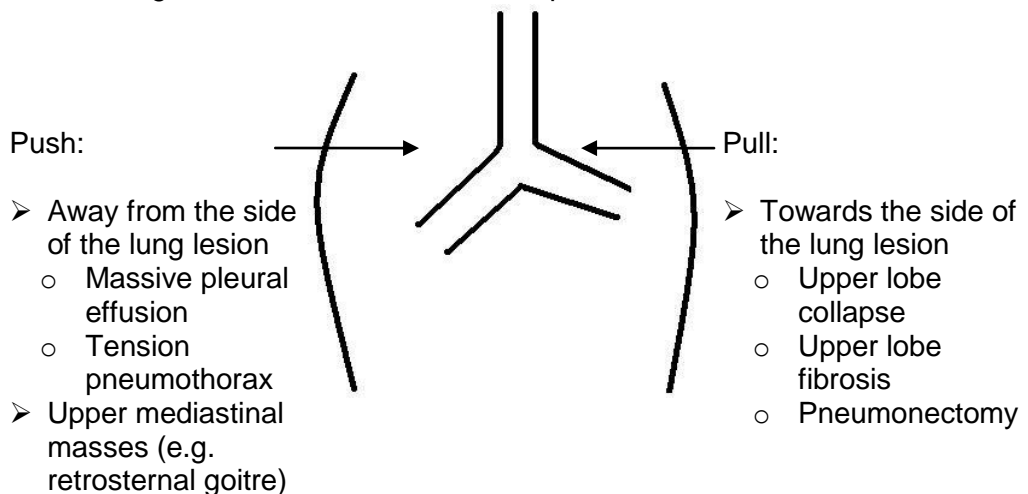


Tracheal deviation

- Perform a directed physical examination of the pulmonary system for tracheal deviation.
 - Lung findings in the affected side
 - ↓ tactile vocal fremitus
 - Dullness
 - ↓ breath sounds
 - Tracheal deviation to the same side as the above lung findings, which is due to the pull effect of atelectasis
 - Tracheal deviation to the normal side of the lung, due to the push effect of pleural effusion

Adapted from: Talley NJ, et al. *Maclennan & Petty Pty Limited 2003*, Table 4.6, page 110; Mangione S. *Hanley & Belfus 2000*, page 287.

Useful background: Causes of tracheal displacement



Adapted from: Talley NJ, et al. *Maclennan & Petty Pty Limited 2003*, page 110.



Cough

Useful background: Description of “Cough”

Cough

➤ Some causes

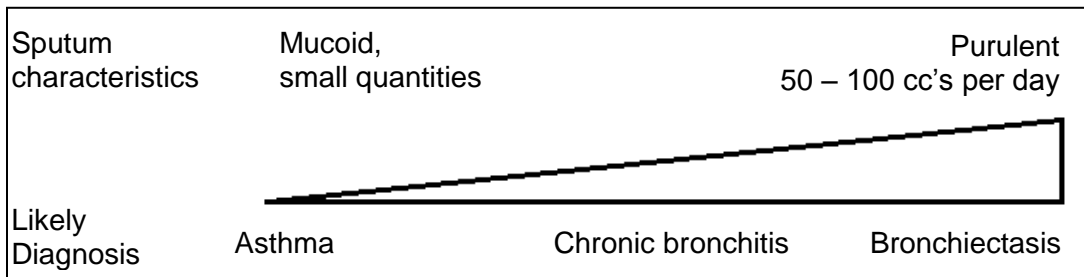
-
- Sound
 - Dry, hacking
 - Viral interstitial lung disease,
 - Tumor
 - Allergies,
 - Anxiety
 - Chronic, productive
 - COPD
 - Bronchiectasis
 - Abscess
 - Pneumonia
 - TB
 - Wheezing
 - Bronchospasm (Asthma, Allergies)
 - Congestive heart failure
 - Barking
 - Epiglottal disease (e.g. “croup”)
 - Stridor
 - Tracheal obstruction
 - Timing
 - Morning
 - Smoking
 - Nocturnal
 - Post-nasal drip
 - Congestive heart failure
 - Asthma
 - Upon eating/ drinking
 - Neuromuscular disease of the upper esophagus (aspiration)

Adapted from: Filate W. et al. *The Medical Society, Faculty of Medicine, University of Toronto 2005*, Table 1, page 281.

Useful background: Sputum

- Onset/ duration, frequency, progression, quantity, colour, consistency, odour, hemoptysis
- Muroid (uninfected) sputum is odourless, transparent, and whitish-gray
- Purulent (infected) sputum contains pus and is often coloured
- Foul-smelling sputum is suggestive of a lung abscess





Adapted from: Filate W., et al. *The Medical Society, Faculty of Medicine, University of Toronto* 2005, page 281.

- Take a directed history for cough.

➤ History

○ Cough

- Acute/chronic (duration)
- Change
- Frequency
- Onset/offset
- Dry or wet
- Sputum
 - Onset/ duration
 - Frequency
 - Progression
 - Quantity
 - Colour
 - Consistency
 - Odour
 - Hemoptysis
 - Mucoid (uninfected) sputum is odourless, transparent, and whitish-gray; small volumes suggest presence of asthma.
 - Purulent (infected) sputum contains pus, is often coloured, and large daily volume (50-1000 cc's) suggests bronchiectasis
 - Foul-smelling sputum is suggestive of a lung abscess

○ Complications

- Fever, chills
- Anorexia, weight loss
- Pleuritic chest pain
- On/off
- Dyspnea (SOB), dyspnea on exertion, (SOBOE), paroxysmal nocturnal dyspnea (PND)



- Causes
 - Smoking (pack years)
 - Lung cancer in family
 - Inhalation work
 - TB exposure
 - Travel
 - Sexual orientation
 - Allergies
 - Drugs
 - COPD, CF, asthma
 - CHF, MI, AF
 - Puffers, Rx
 - Sleep
 - Past history
 - Co-morbid illness (CaL, CF, CRF, cirrhosis)

Abbreviations: AF, atrial fibrillation; CaL, cancer of lung; CF, Cystic fibrosis; CHF, congestive heart failure; MI, myocardial infarctions; CRF, chronic renal failure; COPD, chronic obstructive pulmonary disease; PND, paroxysmal nocturnal dyspnea; Rx, medications; SOB, shortness of breath; SOBOE, shortness of breath on exertion.

Adapted from: Jugovic PJ, et al. *Saunders/ Elsevier* 2004, page 124: Filate W, et al. *The Medical Society, Faculty of Medicine, University of Toronto* 2005, page 281.

Useful background: Chronic Cough: Common Causes, Clinical Features and Investigations

| Common Causes | Clinical Features |
|--|--|
| ➤ Upper airway cough syndrome | <ul style="list-style-type: none"> ○ Postnasal drainage ○ Cobblestoning and mucus in oropharynx ○ Nasal discharge ○ Throat clearing, |
| ➤ Cough variant asthma | <ul style="list-style-type: none"> ○ Typical features of asthma, such as wheezing, often symptoms |
| ➤ ACE inhibitor | <ul style="list-style-type: none"> ○ Dry, non-productive cough ○ Onset hours-months ○ No predisposing factors ○ Class effect of ACE inhibitors |
| ➤ Nonasthmatic eosinophilic bronchitis | <ul style="list-style-type: none"> ○ Often prolonged in postinfectious setting |

Abbreviations: ACE, angiotensin converting enzyme; GI, gastrointestinal



Reproduced with permission: Therapeutics Choices. Sixth Edition. Ottawa, Canada: *Canadian Pharmacist Association* 2012, Table 1, page 633.

Hemoptysis

- Take a directed history of hemoptysis.
 - Nose
 - Bleeding
 - GI
 - Upper GI bleeding
 - CVS
 - Acute L-CHF, severe mitral stenosis
 - Bleeding diathesis
 - Respiratory
 - Infection – bronchitis, bronchiectasis, pneumonia, abscess, TB
 - Infarction
 - Infiltration
 - Ischemia – ruptured blood vessel from coughing; Good pasture’s syndrome
 - Cystic fibrosis
 - Foreign body

Abbreviation: L-CHF, left-sided congestive heart failure

Adapted from Talley NJ, et al. *Maclennan & Petty Pty Limited* 2003, Table 4.2, page 101.

Consolidation, collapse, effusion, fibrosis

Fibrosing alveolitis

- Definition
 - Inflammatory infiltration of alveoli and interstitium
 - Pulmonary acini containing connective tissue matrix proteins
- Perform a focused physical examination for fibrosing alveolitis
- General
 - Central cyanosis
 - Finger clubbing
 - Dyspnea/ tachypnea



- Lung
 - Crackles
 - Bilateral and basal
 - Fine, “velcro-like”
 - End-expiratory
 - Lessen on leaning forward
 - Persist with coughing
- Liver
 - Hepatomegaly chronic liver disease
- Signs of pulmonary hypertension
- Examine for causes
 - Rash (face)
 - SLE
 - DMS
 - SS
 - Mouth
 - Aphthous ulcers
 - IBD
 - Dryness
 - Sjogren syndrome
 - Hands
 - RA
 - SS

Abbreviation: DMS, dermatomyositis; IBD, inflammatory bowel disease; RA, rheumatoid arthritis; SLE, systemic lupus erythomatosis; SS, systemic sclerosis

SO YOU WANT TO BE RESPIROLOGIST!

Q. Pulmonary crackles are caused by many lung conditions, and finger clubbing is caused by many diseases of lung, heart, GI tract, etc. But what four pulmonary conditions are associated with both lung crackles and finger clubbing, and what are the characteristics of the crackles which might help to distinguish the cause?

- A.
- Immune – fibrosing alveolitis (crackles-fine)
 - Infiltrative – bronchogenic lung cancer (localized)
 - Infections – bronchiectasis (course)
 - Industrial – asbestosis



- Perform a directed physical examination of the pulmonary system for consolidation, collapse, effusion, or fibrosis.
- General inspection
 - Contents of sputum cup (blood, pus etc.)
 - Type of cough
 - Rate and depth of respiration, and breathing pattern at rest and after exercise
 - Accessory muscles of respiration
 - Cheyne-Stokes breathing
 - Kussmaul hyperventilation
 - Temperature chart
 - Anemia
 - Obesity (sleep apnea)
 - Weight loss
 - Wasting, infraclavicular region
 - Mental status change (especially in the elderly)
- Face
 - Eyes – Horner’s syndrome (apical lung cancer)
 - Mouth - central cyanosis of tongue
 - Voice – hoarseness (recurrent laryngeal nerve palsy)
 - Skin – pallor
- Neck
 - Nodes
 - Thyromegaly
 - Trachea
 - Jugular venous pressure (CCF, SVC obstruction)
 - Use of accessory muscles
- Hands
 - Nicotine staining (actually from tobacco tar)
 - Clubbing
 - Cyanosis (peripheral)
 - Wasting, weakness – finger abduction and adduction (lung cancer involving the brachial plexus)
 - Wrist tenderness (hypertrophic pulmonary osteoarthropathy)
 - Pulse (tachycardia; pulsus paradoxus)
 - Flapping tremor (CO₂ retention)
 - Warms palms and rapid bounding pulse (CO₂ retention)
- Trachea shift towards lesion
 - Atelectasis, fibrosis, pneumonectomy



➤ Chest

- Inspect
 - Shape of chest and spine
 - Scars
 - Prominent veins (determine direction of flow)
 - Movement of R/L side of chest
 - Barrel-chest shaped
 - Pemberton's sign (SVC obstruction)
 - Radiotherapy marks
- Palpate
 - Rib tenderness
 - Expansion
 - Position of trachea
 - Tactile vocal fremitus (TVF) ('ninety nine')
 - Pemberton's sign (superior vena cava obstruction)
- Percuss
 - Supraclavicular region
 - Dullness or hyperresonance
 - Upper, middle and lower chest on each side, front and back
- Auscultate
 - Breath sounds (vesicular or bronchial)
 - Adventitial sounds (wheeze, crackles, pleural rub; do crackles disappear on coughing? Rub does not).
 - Vocal resonance ("one, one, one"; better than TVF)
 - Murmur of TR
 - Early diastolic Graham Steell murmur
 - P₂, loud ejection click
 - Forced expiratory time (FET, full inspiration to full expiration, over trachea, < 6 seconds is normal)

➤ Other

- Breasts
- Liver
- Spleen
- Lower limbs - edema, cyanosis

*Remember to inspect, palpate, percuss, auscultate in right (R). axilla for R. middle lobe disease

Abbreviations: FET, forced expiratory time; SVO, superior vena cava; TR, tricuspid regurgitation; TVF, tactile vocal fremitus

Adapted from: Talley NJ, et al. *MacLennan & Petty Pty Limited* 2003, Figure 4.8, pages 122 and 123.



- Give the causes of pulmonary fibrosis
 - Idiopathic
 - Diffuse interstitial pulmonary fibrosis
 - Congestion
 - Infection
 - Causes of bronchiectasis
 - TB
 - Sarcoidosis
 - Tumor
 - Alveolar cell carcinoma
 - Lymphangitis carcinomatosa
 - Leukemia
 - Toxins
 - Silicosis
 - Asbestosis
 - Pneumoconiosis (fibrosis due to dust)
 - Berylliosis
 - Fumus
 - Irradiation
 - MSK
 - Rheumatoid arthritis
 - Scleroderma
 - PAN
 - Miscellaneous
 - Wegner granulomatosis
 - Eosinophilic granuloma
 - LS disease
 - HSC disease
 - Good posture syndrome
 - Alveolar microlithiasis/ proteinosis
 - Pulmonary hemosiderosis

Abbreviation: HSC, Hand-Schuller-Christian disease; LS, Letterer-Siwe disease; PAN, polyarteritis nodosa; SLE, systemic lupus erythematosus

Useful facts

- The physical signs of pulmonary fibrosis is the same as for collapse, but chest X-ray of collapse is usually homogenous, where as fibrosis is non-homogeneous.
- Preferential disinflation of lesions on chest X-ray
 - Upper lobe – TB, silicosis, pneumoconiosis
 - Lower lobe – bronchiectasis
 - Bilateral & symmetrical – pneumoconiosis



Useful background: The causes of lung collapse

- Tumor
 - Bronchogenic carcinoma
 - Other intrabronchial tumors (e.g. bronchial adenoma)
- Plugs
 - Asthma
 - Allergic bronchopulmonary aspergillosis
- Infection
 - Extrinsic compression from hilar adenopathy (e.g. primary TB)
 - Tuberculosis

Adapted from: Baliga RR. *Saunders/Elsevier* 2007, page 292.

- Perform a focused physical examination to distinguish between the major causes of dullness at a lung base.
- Pleural effusion: stony, dull note; trachea may be deviated to the opposite side in large effusions
- Pleural thickening: trachea not deviated; breath sounds will be heard
- Consolidation: vocal resonance increased; bronchial breath sounds and associated crackles
- Collapse; trachea deviated to the affected side; absent breath sounds

Adapted from: Baliga RR. *Saunders/Elsevier* 2007, page 252.

- Give 3 causes of dullness of the lung base not related to consolidation, cavitation or callable.
 - Pleural effusion
 - Thickened pleura
 - Paralyzed hemidiaphragm

Useful background: Findings on chest X-ray which suggest pleural thickening

- Hazy, homogeneous, poorly defined opacity
- Opacity not confined to one lobe
- On lateral view – looks smaller because of comparative decrease in thickness when seen in profile.
- Screening – suggests pleural involvement
- Associations – fibrosis, or collapse of underlying lung



Remember: The physical findings in pulmonary fibrosis are the same as in collapse.

- Describe the characteristics and causes of bronchial breathing.
 - “blowing, gap, long expiration”
 - Associated with
 - Consolidation
 - Collapse
 - Cavity
 - Effusion
 - Pneumothorax
- Perform a focused physical examination to distinguish between the four commonest causes of dullness at the base of the lung.

| | Chest wall movement | TVR | Tracheal deviation | Auscultation |
|-------------------------------|---------------------|-----|--------------------|-----------------------------------|
| Pleural effusion | ↓ | ↓ | +/- | ↓ BS |
| Pleural thickening (fibrosis) | Flattening | | Yes | Crackles bronchial breathing |
| Consolidation (pneumonia) | ↓ | ↑ | No | ↑ BS bronchial crackles breathing |
| Collapse (atelectasis) | ↓ | | + | ↓ BS |

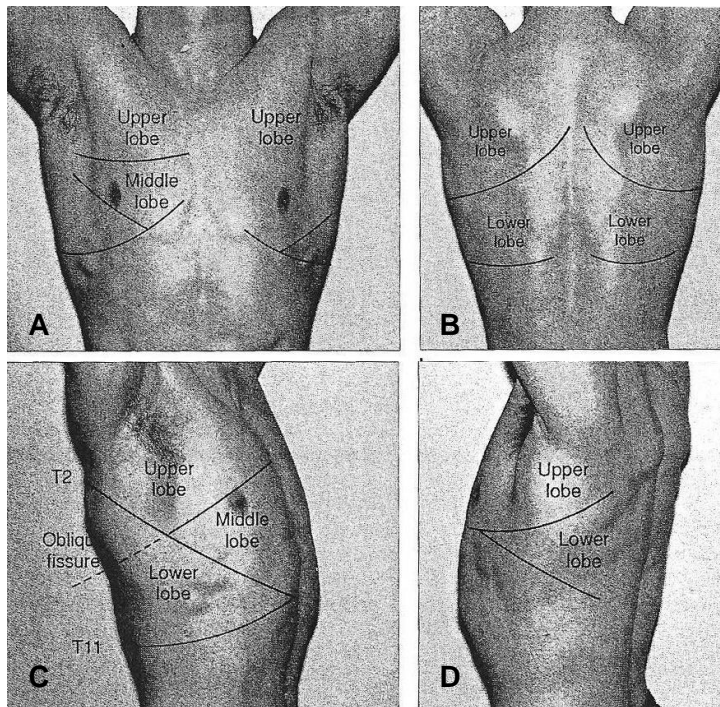
Abbreviation: TVR, tactile vocale resonance; BS, breath sounds

Remember

- Rales
 - ↑ by coughing
 - Arise from
 - Fluid in alveoli
 - Bronchiectasis due to associated collapse and/or consolidation
- Increased vocal resonance (VR)
 - Consolidation
 - Cavitation



Useful background: Surface anatomy for underlying lobes of the lung.



A, anterior; B, posterior; C, lobes of the right lung; D, lobes of the left lung.

Adapted from: Talley NJ, et al. *MacLennan & Petty Pty Limited* 2003, Figure 4.7.2, page 116.

"There is no achievement without goals"

Robert J. McKaine



Useful background: The physical findings in the chest for consolidation, collapse, effusion and fibrosis.

| | Consolidation | Collapse | Effusion | Fibrosis |
|---|--|-------------------|---|---|
| ➤ Inspection | | | | |
| ○ Chest wall movement | ↓ | ↓ | ↓ | ↓
Apical, flattening of chest on the affected side |
| ➤ Palpation | | | | |
| ○ Tactile vocal fremitus (TVF; "E", "1-2-3", "99") (Same as vocal resonance, VR) | ↑ alveolar pneumonia (bronchi patent)
↓ broncho-pneumonia | Alveolar
↑ TVF | ↑ above effusion;
absent over effusion | ↓,
or absent |
| ➤ Displaced trachea | - | Towards collapse | Away from effusion | Towards the fibrosis |
| ➤ Percussion dullness | + | + | * | + |
| ➤ Auscultation | | | | |
| ○ Breath sounds | Bronchial | Broncho-vesicular | Bronchial above fluid,
absent over fluid | ↓ Bronchial |
| ○ Adventitial sounds | Crackles | Crackles | - | Crackles |
| ○ Auscultatory vocal resonance (E-E-E, egophony, whispered pectoriloquy, broncho-phony) | One-One-One; Same as TVF | Same as TVF | Same for TVF | Same as TVF |

Abbreviations: TVF, tactile vocal fremitus; VR (Auscultatory) vocal resonance.

Adapted from: Talley N. J., et al. *MacLennan & Petty Pty Limited* 2003, Table 4.8, page 123.



Useful background: Physical findings – tactile vocal fremitus (TVF)

| Transmission | Possible pathologies |
|------------------------|---|
| ➤ Increased | ○ Consolidation (e.g. pneumonia) |
| ➤ Decreased-unilateral | ○ Atelectasis, bronchial obstruction, pleural effusion, pneumothorax, pleura thickening |
| ➤ Bilateral | ○ Chest wall thickening (muscle, fat), COPD, Bilateral pleural effusion |

- Perform a focused physical examination to distinguish between peripheral versus central cyanosis.

| | Peripheral | Central |
|------------------|--------------|-----------|
| Site | Hands, feet* | Lips |
| Temperature | Cold | warm |
| Clubbing | - | + |
| Effect of cold | Worse | No change |
| pO ₂ | Normal | ↓ |
| pCO ₂ | Normal, or ↓ | ↑ |
| Polycythemia | Yes | No |

*Note: lips may be affected in persons with peripheral cyanosis, but the warm breath will reduce this cyanosis.

Useful Reminders:

- Bronchiectasis
 - Defined by dilation of bronchi
 - Numerous associations
 - Obstruction
 - Infection
 - Fibrosis
 - Rarely congenital
 - Physical findings
 - Collapse, especially of lower lobes
 - Fibrosis
 - Clubbing
 - Crepitations
 - Rhonchi



Describe the typical findings on chest X-ray of the patient with bronchiectasis.

- May be normal, or
 - Fibrosis or collapse (especially at the right heart border)
 - Hilar density
 - Dilated bronchi with “honey comb” appearance” (dilated bronchi seen as rings with clear centres, within an area of fibrosis)
- Perform a focused physical examination for a pulmonary cavity.
 - Pathognomonic signs (usually only seen with a large cavity)
 - Percussion (during height of inspiration, with mouth open) – sounds like a cracked pot.
 - Auscultation – when the patient coughs, a hissing sound is heard
 - Suggestive signs (may be caused by conditions other than cavities).
 - Cavernous breathing
 - Whispered pectoriloquy

Percussion

Useful background: Lung disease caused by occupational exposure

| Exposure | Lung disease |
|--|------------------------|
| ➤ Grain dust, wood dust, tobacco, pollens, many others | ○ Asthma |
| ➤ Asbestos | ○ Pleural mesothelioma |
| ➤ Coal | ○ Pneumoconiosis |
| ➤ Sandblasting and quarries | ○ Silicosis |
| ➤ Industrial dusts | ○ Chronic bronchitis |
| ➤ Birds | ○ Psittacosis |
| ➤ Cotton | ○ Byssinosis |

Source: Filate W, et al. *The Medical Society, Faculty of Medicine, University of Toronto* 2005, Table 3, page 283.



Useful background: Types of percussion notes and pathologic examples

| Percussion note | Pathologic example |
|------------------|--|
| ➤ Dullness | <ul style="list-style-type: none"> ○ Lobar pneumonia ○ pleural effusion ○ hemothorax ○ empyema ○ atelectasis ○ tumor |
| ➤ Resonance | <ul style="list-style-type: none"> ○ Chronic bronchitis |
| ➤ Hyperresonance | <ul style="list-style-type: none"> ○ Emphysema, pneumothorax ○ Asthma |

Useful background: Causes of pleural effusion

- Lung
 - Infections (usually an exudates)
 - Parapneumonic (bacterial) effusions
 - Bacterial empyema
 - Tuberculosis
 - Fungi
 - Parasites
 - Viruses & mycoplasma
 - Neoplasms
 - Primary metastatic lung tumors
 - Lymphoma and leukemia
 - Benign and malignant tumors of pleura
 - Intra-abdominal tumors with ascites
 - Vascular disease
 - Pulmonary embolism
 - Wegener granulomatosis
 - Trauma
 - Hemothorax
 - Chylothorax
 - Miscellaneous
 - Drug induced effusions
- Heart
 - Congestive heart failure
 - Superior vena caval obstruction
 - Constrictive pericarditis



- Liver
 - Cirrhosis with ascites
 - Hypoalbuminemia
 - Salt retaining syndromes
- Kidney
 - Peritoneal dialysis
 - Hydronephrosis
 - Nephrotic syndrome
 - Uremic pleuritis
- GI
 - Intra abdominal diseases
 - Pancreatitis and pancreatic pseudocyst
 - Subdiaphragmatic abscess
 - Malignancy with ascites
 - Esophageal rupture
 - Intra abdominal surgery
- Miscellaneous
 - Meigs Syndrome
 - Myxedema
 - Familial Mediterranean fever

Adapted from: Ghosh AK. *Mayo Clinic Scientific Press* 2008, Table 23-9, page 912.

Clubbing

- Perform a directed physical examination for clubbing.
- Clubbing is a painless focal, usually symmetric enlargement of the connective tissue in the terminal phalanges of the digits of the fingers more than the toes.
- Signs
 - Interphalangeal depth ratio
 - Appearance: Parrot's beak, watch glass, drumstick
 - Schamroth's sign
- CVS
 - Cyanotic congenital heart disease
 - Infective endocarditis
 - Axillary artery aneurysm



- Lung
 - Lung carcinoma (usually not small cell carcinoma)
 - Bronchial arteriovenous aneurysm
 - Chronic suppuration
 - Bronchiectasis
 - Lung abscess
 - Empyema
 - Idiopathic pulmonary fibrosis
 - Cystic fibrosis
 - Asbestosis
 - Pleural mesothelioma (benign fibrous type) or pleural fibroma

- Gastrointestinal
 - Cirrhosis
 - Inflammatory bowel disease (Crohn, ulcerative colitis)
 - Celiac disease

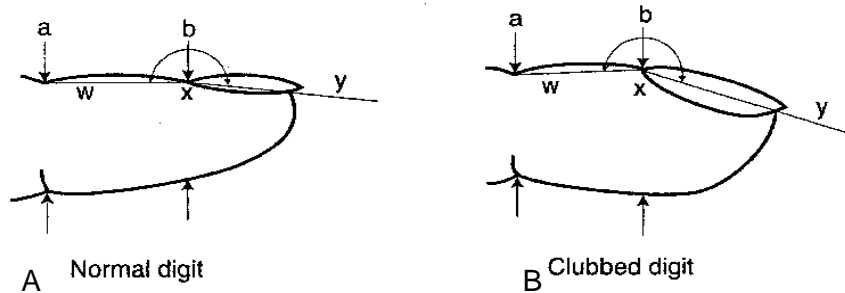
- Endocrine
 - Throtoxicosis
 - Secondary hyperparathyroidism

- Rare
 - Neurogenic diaphragmatic tumors
 - Pregnancy


Adapted from: Talley NJ, et al. *Maclennan & Petty Pty Limited 2003*, Table 3.3, page 36.

- Interphalangeal depth ratio: Measurement of the interphalangeal depth ratio is described in the Figure below. If this ratio exceeds 1, clubbing is present, a conclusion supported by tow observations:
 - The interphalangeal depth ratio of normal persons is 0.895 ± 0.041 , making the threshold of 1.0 more than 2.5 standard deviations above the normal
 - A ratio of 1.0 distinguishes digits of healthy persons from those of patients with disorders traditionally associated with clubbing (such as cyanotic heart disease and cystic fibrosis). For example, studies demonstrate that 75% to 91% of patients with cystic fibrosis have an interphalangeal depth ratio exceeding 1, but only 0% to 1.5% of normal persons do.
 - A disadvantage to using the hyponychial angle is that special equipment is required for precise measurements.





- A : normal digit
- B : Clubbed digit
 - The distal interphalangeal joint is denoted by “a”
 - The junction of the nail and skin at the midline is denoted by “b”
 - The interphalangeal depth ratio is the ratio of the digit’s depth measured at “b” divided by that at “a”
 - The hyponychial angle is the angle “wxy”
 - In the Figure, the depth ratio is 0.9 for the normal digit and 1.2 for the clubbed digit (a ratio >1 indicates clubbing) and the hyponychial angle is 185 degrees for the normal digit and 200 degrees for the clubbed digit (a hyponychial angle > 190 degrees indicates clubbing).



A – Parrot’s beak-accumulation of connective tissue in proximal portion of distal digit

B – Watchglass-connective tissue at base of nail

C – Drumstick-connective tissue at base of nail

➤ Schamroth’s sign?

- Disappearance of the diamond-shaped window normally present when the terminal phalanges of paired digits are juxtaposed.



- Accumulation of connective tissue may occur quickly (<10 days)

Adapted from: Mangione S. *Hanley & Belfus* 2000, pages 482 to 485.

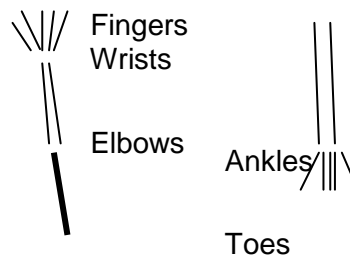


Distinguish between clubbing versus hypertrophic osteoarthropathy.

- Clubbing (sequence of changes)
 - Filling – in of angle between nail and nail bed (“profile sign”)
 - ↑ curvature of nail, longitudinal and horizontal
 - Soft tissue swelling of ends of fingers (“drumstick”)
 - Nails may be smooth, shiney and brittle

- Hypertrophic osteoarthropathy (bilateral, symmetrical periostitis at ends of bone)

- Clubbing plus pain and swelling of



- Note – clubbing associated with cancer of the lungs (especially peripheral cancer) may be painful

- Give a systematic approach to the causes of clubbing.

- Thyroid
 - Myxedema
 - Exophthalmic ophthalmoplegia

- Heart
 - Cyanotic congenital heart diseases
 - Subacute bacterial endocarditis (SBE)

- GI/ hepatobiliary
 - Inflammatory bowel diseases (IBD)
 - Biliary cirrhosis

- Familial

- Idiopathic



SO YOU WANT TO BE A RESPIROLOGIST!

Q1. Other than form the family history, how can you distinguish familial from non-familial clubbing.

- A1. Familial clubbing is
- Asymmetrical
 - Increases with ageing

Q2. What is the cause of unilateral clubbing of the right hand?

A2. Aneurysm of the thoracic aorta

Q3. What is hypertrophic pulmonary osteoarthropathy?

- A3.
- Hypertrophic pulmonary osteoarthropathy is digital clubbing with periostosis (Marie-Bamberger syndrome)
 - A systemic disorder of bones, joints, and soft tissues most commonly associated with an intrathoracic neoplasm (usually bronchogenic carcinoma but also lymphomas and metastatic cancers).
 - Periosteal new-bone proliferation that accompanies digital clubbing, especially prominent in the long bones of the extremities.
 - Other features of symmetric arthritis-like changes in one or more joints (ankles, knees, wrists, and elbows); coarsening of the subcutaneous tissue in the distal portions of arms and legs (and occasionally the face); neurovascular changes in hands and feet (with chronic erythema, paresthesias, and increased sweating).
 - Associations may be seen in
 - Cystic fibrosis,
 - Brochiectasis,
 - Chronic empyema,
 - Lung abscesses (all typically associated with clubbing),
 - Pulmonary interstitial fibrosis

Source: Mangione S. *Hanley & Belfus* 2000, page 485.



SO YOU WANT TO IMPRESS YOUR STAFF!

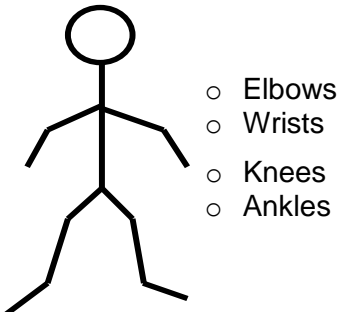
Q. In the context of clubbing and bone pain as well as tenderness, what other physical signs suggest hypertrophic pulmonary osteoarthropathy (HPO)?

- A.
- Pretibial skin
 - Shiny
 - Warm
 - Red
 - Thickened
 - Sweating

 - Hands and feet
 - Sweating
 - Warmth
 - Paresthesias
 - Clubbing, but note: not always associated with clubbing

 - Systemic
 - Sweating
 - Warmth
 - Paresthesias

 - Joints
 - Symmetrical
 - Arthritis-like changes in wrists, elbows, knees, ankles

 - Subcutaneous tissue – coarsening in
 - Hands
 - Feet
 - Face
- 
 - Elbows
 - Wrists
 - Knees
 - Ankles
- Causes
 - Lung
 - Bronchogenic cancer
 - Metastatic lung cancer
 - Mesothelioma
 - Bronchiectasis
 - Lung abscess
 - Chronic empyema
 - Cystic fibrosis - Note: HPO almost never occurs with pulmonary interstitial fibrosis
 - CVS
 - Infected aortic bypass graft
 - Liver
 - Cirrhosis

 - Clinical course
 - HPO often resolves with cure of associated condition



SO YOU WANT TO BE A RESPIROLOGIST!

Q. In which condition is clubbing associated with pulmonary crackles?

- A.
- Bronchogenic carcinoma (crackles are localized)
 - Bronchiectasis (coarse crackles)
 - Asbestosis
 - Fibrosing alveolitis (fine, end-expiratory, not disappearing on coughing, but disappear on leaning forward)

Source: Baliga RR. *Saunders/Elsevier* 2007, page 282.

SO YOU WANT TO IMPRESS YOUR STAFF!

Q. Under what circumstances is clubbing of the digits painful?

- A. When digital clubbing is associated with periostosis, periosteal formation of new bone, and hypertrophy (hypertrophic pulmonary osteoarthropathy, [HPO], aka Marie-Bamberger syndrome)
- The diagnosis of HPO is may be suspected clinically, but is confirmed by the radiological demonstration of periostosis.

SO YOU WANT TO IMPRESS YOUR STAFF!

Q1. Examine the dorsal portion of the fingers for bulimia.

A1. Abrasions, excoriations or calluses suggest chronic trauma on the fingers against the teeth as the sufferer repeatedly attempts to induce vomiting.

Q2. From the physical examination, what will suggest that the person's clubbing is the familial congenital form?

- A2.
- The person's heritage is often African
 - All the signs of clubbing; the loss of the sublingual angle is common, but the presence of ballottement is less 50.



Granulomatous lung disease

- Perform a directed physical examination for sarcoidosis.
 - Lung
 - Hilar lymph adenopathy
 - Skin
 - Erythema nodosum
 - Lupus pernio
 - Ophthalmologic
 - Uveitis
 - Keratoconjunctivitis
 - Sjorgrens syndrome
 - Cardiac
 - Conduction defects
 - Valvular insufficiency
 - Cardiomyopathy
 - Cor pulmonale,
 - Arthritic
 - In 10 to 15% most common in ankles and knees. Axial skeleton spared
 - Renal
 - Nephrolithiasis
 - Hypercalcemia
 - Nephrocalcinosis
 - Membrane nephropathy
 - Liver
 - Granuloma (in 86%)
 - Cholestasis
 - Post- necrotic cirrhosis
 - Neurologic
 - Peripheral neuropathy
 - Lymphocytic meningitis
 - Diabetes insipidus
 - Mononeuritis multiplex
 - Cranial nerve palsies
 - Endocrine
 - Thyroid nodules
 - Infertility
 - Hypogonadism

Adapted from: Talley N J, et al. *Maclennan & Petty Pty Limited* 2003, page 129-130; Davey P. *Wiley-Blackwell* 2006, pages 198 and 199.



- Perform a focused physical examination for sarcoidosis.
- General
 - Fever
- CNS (may occur without signs elsewhere of sarcoidosis)
 - Neuropathy
 - Local deposit, or
 - Mononeuritis multiplex
 - Bilateral cranial nerve VII disease
 - Meningeal infiltration
- Eye
 - Uveitis
 - Ketatoconjunctivitis sicca
- Skin
 - Erythema nodosum
 - Non-specific infiltrates
- Lung
 - Bilateral hilar lymphadenopathy
 - Mottling of lung
 - Linear streaks
 - Pleural effusions do not occur
- Liver/ spleen/ nodes
 - Hepatosplenomegaly
 - Lymphadenopathy
- Hematology
 - Spleen/ nodes – granulomas
- Bone and joints
 - Cyst
 - Hypercalcemia
 - Terminal phalanges of hands
 - Arthralgia
- Renal
 - Calculi
 - Nephrocalcinosis



Useful background: Grading of sarcoidosis

| Grade | Abnormality (% cases) | % Resolution |
|-------|--|--------------|
| 0 | Normal | - |
| 1 | BHL (65%) | 80% |
| 2 | BHL and pulmonary infiltrate (22%) | 50% |
| 3 | Pulmonary infiltrate without BHL (13%) | 25% |

Abbreviations: BHL, Bilateral hilar lymphadenopathy

Source: Davey P. *Wiley-Blackwell* 2006, page 198.

Pulmonary fibrosis

- Give a systematic approach to the causes of pulmonary fibrosis.

➤ Idiopathic

➤ Infection

- Bronchiectasis
- Cystic fibrosis
- Tuberculosis
- Granulomatous diseases
 - Sarcoidosis
 - Wegener's granuloma

➤ Infiltration

- Alveolar cell carcinoma
- Lymphangitis carcinomatosa
- Leukemia

➤ Immune (collagen-vascular)

- Rheumatoid arthritis
- Scleroderma
- SLE (systemic lupus erythematosus)
- PAN (polyarteritis nodosa)

➤ Toxins/ drugs

- Silicosis
- Asbestosis
- Irradiation
- Bergliosis
- Vomitus
- Fumes
- Sulfonamides



- Phenytoin
- Nitrofurantoin
- Busulphan
- Histocytosis
 - Letterer – Siwe’s disease
 - Hand – Schuller – Christian disease
- Lung
 - Pulmonary hemosiderosis
- Kidney
 - Goodpasture’s syndrome
 - Alveolar proteinosis
 - Alveolar microlithiasis

Adapted from: Davies IJT. *Lloyd-Luke* 1972, page 128.

Useful background: Causes of pulmonary fibrosis (diffuse lung disease)

- Idiopathic
 - Idiopathic pulmonary fibrosis- usual interstitial pneumonia (IPF-UIP)
 - Nonspecific interstitial pneumonia (NSIP)
 - Bronchiolitis obliterans with organizing pneumonia/cryptogenic organizing pneumonia (BOOP/COP)
 - Eosinophilic lung disease
 - Lymphocytic interstitial pneumonia (LIP)
 - Alveolar microlithiasis
 - Lymphangiomyomatosis (LAM)
 - Langerhans cell histiocytosis/eosinophilic granulomatosis
 - Pulmonary alveolar proteinosis
 - Acute respiratory distress syndrome/acute lung injury
- Infections
 - TB
 - Mycosis
 - Varicella
 - Psittacosis
- Pneumoconiosis
 - Coal dust
 - Silicon
 - Asbestos
 - Benylum
 - Iron
 - Kaolin
 - Cadmium



- Nickel
- Chromium
- Talc
- Byssinosis
- Bagassosis
- China-clay
- Aluminium
- Hypersensitivity
 - Farmers lung
 - Bird fancier's lung
 - Pituitary snuff-taker's lung
 - Mushroom workers lung
 - Paprika splitters lung
 - Silo fillers disease
 - Workers in gas works
- Fibrosing Alveolitis
 - Rheumatoid lung
 - Desquamative interstitial pneumonitis
- Aspiration
- Cardiac
 - Pulmonary edema
 - Mitral stenosis ossification
 - Multiple pulmonary infarcts
 - Uramic lung
- Neoplastic
 - Alveolar cell carcinoma
 - Lymphangitis carcinomatosa
- Miscellaneous
 - Sarcoidosis
 - Systemic sclerosis
 - SLE
 - Radiation
 - Histiocytosis X
 - Xanthomatosis
 - Biliary cirrhosis
 - Paraquat poisoning
 - Prolonged busulphan therapy

Adapted from: Burton JL. *Churchill Livingstone* 1971, page 29; Talley NJ, et al. *Maclennan & Petty Pty Limited* 2003, page 127; Ghosh AK. *Mayo Clinic Scientific Press* 2008, Table 23-11, page 917.



- Give the typical radiological features of silicosis.
 - Multiple nodules composed of concentric layers of fibrosis
 - Most prominent in upper lobes
 - Reticulation
 - Bullous emphysema
 - Pleural thickening
 - Possible associated signs of
 - TB
 - Hilar adenopathy
 - Complications of
 - Cor pulmonale
 - Pneumothorax

- Pneumoconiosis
 - Fibrosis of lungs due to dust
 - Focal emphysema
 - Progressive massive fibrosis
 - Especially in upper lobes
 - Often cavitate and calcify
 - Often progresses to cor pulmonale

Useful background: Poor prognostic factors in patients with community-acquired pneumonia (CAP)

- Age over 65 years
- Coexisting conditions such as cardiac failure, renal failure, chronic obstructive pulmonary disease, malignancy
- Clinical features: respiratory rate > 30 per min, hypotension (systolic blood pressure < 90 mmHg or diastolic pressure < 60 mmHg), temperature > 38.3°C, impaired mental status (stupor, lethargy, disorientation or coma), extrapulmonary infection (e.g. septic arthritis, meningitis)
- Investigations: hematocrit < 30%, white cell count < 4000 or > 30 000 per mm³, azotemia, arterial blood gas < 60 mmHg while breathing room air, chest radiograph showing multiple lobe involvement, rapid spread or pleural effusion.
- Microbial pathogens: *Staph. Aureus*, *Legionella*, *Strep. pneumoniae*

Adapted from: Baliga RR. *Saunders/Elsevier* 2007, pages 273 and 281; McGee SR. *Saunders/Elsevier* 2007, Box 27-2.



- Give the typical signs of pulmonary infarction seen on chest X-ray.
 - Opacity
 - Round, triangular or linear
 - Maybe absent, especially with middle lobe collapse
 - May be absent for the first 24 hours after onset of pleuritic chest pain
 - Pleural effusion
 - Elevation of hemidiaphragm

Pneumonia

Community-acquired pneumonia (CAP) has a wide spectrum of severity, and the risks of morbidity and mortality may be estimated and stratified based on the need for hospitalization, IRVS (intensive respiratory or vasomotor support, or risk of death:

- PSI (pneumonia-specific severity of illness) score
 - Predicts need for hospital admission
- SMRT-CO
 - Predicts risk of death
- CURB-65
 - Predicts risk of death

Note: for CAP who require hospitalization, the MR (mortality rate) is 10% for those requiring admission to ICU, the MR is 40%

Useful background: Criteria to determine hospital admission in the patient with pneumonia

- Any of the below should result in admission:
 - Respiratory rate >28/min
 - Systolic BP <90 mmHg or 30 mmHg below baseline
 - Delirium
 - Hypoxia: Oxygen sat <90% or pO₂ of <60 mmHg on room air
 - Unstable co-morbid illness e.g.: renal failure, CHF
 - Lobar multi pneumonia
 - Pleural effusion >1cm, and has features of a complicated parapneumonic effusion
- The British Thoracic Society severity score is based on four criteria.

CURB

 - **C**onfusion
 - **U**rea > 7mmol/L
 - **R**espiratory rate > 30/min* (without underlying lung disease)
 - **B**lood pressure <60 mmHg diastolic or systolic <90 mmHg



Mortality with no features is 2.4%, with one feature 8%, with two 23%, with three 33% and all four features, 83%.

Source: McGee SR. *Saunders/Elsevier* 2007, page 354.

Useful background: Complications of pneumonia

- General
 - Septicemia
 - Multi-organ failure
 - Hemolytic syndrome
 - Death

- Lung
 - Lung abscess
 - Empyema
 - Adult respiratory distress syndrome

- Kidney
 - Renal failure
 - Glomerulonephritis

- Atypical pneumonia
 - Typical pneumonia is caused by pneumococcus (*Streptococcus pneumoniae*)
 - Atypical pneumonia is caused by *Mycoplasma*, *Legionella*, *Chlamydia*, *Coxiella*, etc.
 - The clinical picture in atypical pneumonia is dominated by constitutional symptoms, such as fever and headache, rather than by respiratory symptoms

- CNS - central and peripheral nervous systems

- Heart - pericarditis, myocarditis

- Liver – hepatitis

- Blood
 - Disseminated intravascular coagulation (DIC)
 - Autoimmune hemolytic anemia

- MSK
 - Arthralgia and arthritis



➤ Skin

- Non-specific rash
- Erythema multiforme
- Stevens-Johnson syndrome

Adapted from: Baliga RR. *Saunders/Elsevier* 2007, page 272.

Useful background: Pneumonia-specific Severity of Illness (PSI) Score

| | Points assigned |
|---|----------------------|
| ➤ Patient characteristic | |
| ○ Males | Age (years) |
| ○ Females | Age (years) minus 10 |
| ○ Nursing home resident | 10 |
| ➤ Comorbid illness | 30 |
| ○ Neoplastic disease | 20 |
| ○ Liver disease | 10 |
| ○ Heart failure | 10 |
| ○ Cerebrovascular disease | 10 |
| ○ Renal disease | 10 |
| ➤ Physical examination findings | |
| ○ Altered mental status | 20 |
| ○ Respiratory rate ≥ 30 breaths/min | 20 |
| ○ Systolic blood pressure < 90 mm Hg | 20 |
| ○ Temperature $< 35^{\circ}\text{C}$ or $\geq 40^{\circ}\text{C}$ | 15 |
| ○ Pulse ≥ 125 beats/min | 10 |
| ➤ Laboratory findings | |
| ○ Arterial pH < 7.35 | 30 |
| ○ Blood urea nitrogen > 11 mmol/L | 20 |
| ○ Sodium < 130 mmol/L | 20 |
| ○ Glucose ≥ 14 mmol/L | 10 |
| ○ Hematocrit $< 30\%$ | 10 |
| ○ Partial pressure of arterial oxygen < 60 mm Hg | 10 |
| ○ Pleural effusion | 10 |

Reproduced with permission: Therapeutics Choices. Sixth Edition. Ottawa, Canada: *Canadian Pharmacist Association* 2012, Table 2, page 1396.



- Perform a focused physical examination for complications of pneumonia
- Skin
 - Rash
 - EM
 - S-JS
- Lung
 - Abscess
 - Empyema
 - ARDS
- Heart
 - Pericarditis
 - Myocarditis
- Blood
 - Septicemia
 - Hemolysis – hemolytic syndrome
 - DIC – autoimmune*
- Organ failure
 - Glomerulonephritis*
 - Renal failure
- MSK
 - Arthralgia/ arthritis*
- CNS, PNS
- Death
 - Hepatitis*

*typical extrapulmonary signs of atypical mycoplasma pneumonia

Abbreviations: ARDS, adult respiratory distress syndrome; CNS, central nervous system; DIC, disseminated intravascular coagulation; EM, erythema multiforme; PNS, peripheral nervous system; S-JS, Stevens-Johnson syndrome

“You are never too old to set another goal or to dream a new dream”

C.S. Lewis



Useful background: Performance characteristics of physical examination for pneumonia.

The PLRs for crackles and wheezes for the diagnosis of pneumonia are each < 2.0

| Finding | PLR |
|-----------------------------|-----|
| ➤ General appearance | |
| ○ Cachexia | 4.0 |
| ➤ Vital signs | |
| ○ Temperature > 37.8°C | 2.0 |
| ○ Respiratory rate > 28/min | 2.0 |
| ➤ Lung findings | |
| ○ Percussion dullness | 3.0 |
| ○ Diminished breath sounds | 2.3 |
| ○ Bronchial breath sounds | 3.3 |
| ○ Egophony | 4.1 |

Abbreviation: PLR, positive likelihood ratio

Adapted from: McGee SR. *Saunders/Elsevier* 2007, Box 29.1, page 352.

- Remember
 - At an early stage of pneumonia, before consolidation occurs there may be
 - Mottling
 - Homogeneous opacity
 - Homogeneous opacity may be caused by
 - Homogeneous opacity
 - Collapse
 - effusion
 - Deviation of heart or trachea excludes uncomplicated pneumonia
 - Bronchopneumonia is usually bilateral

Useful background: Predictors of hospital mortality of pneumonia

| Finding | PLR |
|-------------------------------------|------|
| ➤ General appearance | |
| ○ Abnormal mental status | 2.8 |
| ➤ Vital signs | |
| ○ Respiratory rate > 30/min | 2.1 |
| ○ Systolic blood pressure < 90 mmHg | 10.0 |
| ○ Heart rate > 100/min | 2.1 |
| ○ Hypothermia | 3.5 |

Abbreviation: PLR, positive likelihood ratio

Adapted from: McGee SR. *Saunders/Elsevier* 2007, Box 29.2, page 355.



Useful background: Multivariate findings for adult pneumonia

Add points for the presence of findings as follows:

Rhinorrhea= 2 points; sore throat= -1; night sweats = 1; myalgias = 1;
sputum all day= 1; respiratory rate > 25/min=2; temperature $\geq 37.8^{\circ}\text{C}$
(100°F) = 2

| Threshold score | LR |
|-----------------|------|
| ≥ 3 | 14 |
| ≥ 1 | 5.0 |
| ≥ -1 | 1.5 |
| < -1 | 0.22 |

Score= $-3.095 + 1.214 (\text{cough}) + 1.007 \times (\text{fever}) + 0.823 \times (\text{crackles})$

Each variable is coded as 1 if present, 0 if absent

Probability of pneumonia = $1/(1 + e^{\text{score}})$

Source: Simel DL, et al. *JAMA* 2009, Table 40-5, page 536.

Useful background: As the number of findings increases, the probability of pneumonia increases

Count the number of findings present; absence of asthma; temperature $\geq 37.8^{\circ}\text{C}$ (100°F); heart rate > 100/min; decreased breath sounds; crackles

| Number of Findings | Probability, % (baseline prevalence 5%) |
|--------------------|---|
| 5 | 50 |
| 4 | 25 |
| 3 | 20 |
| 2 | 3 |
| 1 | 1 |
| 0 | <1 |

Source: Simel DL, et al. *JAMA* 2009, Table 40-6, page 536.



- Causes of slow resolution or recurrence of pneumonia

- Bronchial obstruction

- Neoplasm
- Aspiration of foreign body

- General

- Antibiotic
- Decreased host resistance
- Cachexia
- Agranulocytosis
- Immunoglobulin defects etc

- Lung

- Formation of abscess, empyema or serous effusion
- Other causes of pulmonary fibrosis

- Pharynx

- Pharyngeal pouch with 'spilling'

Adapted from: Burton JL. *Churchill Livingstone* 1971, page 28; Baliga RR. *Saunders/Elsevier* 2007, page 272.

- Give a systematic approach to the causes of recurrent pneumonias.

- Lung

- Aspiration
- Obstruction
 - Adenoma
 - Carcinoma
 - Foreign body
 - Compression of bronchus
- Bronchiectasis (of the infected lobe)
- Pulmonary embolism with infarctions

- Metabolic

- Diabetes

- Immune deficiency

SO YOU WANT TO BE A RESPIROLOGIST!

Q. In the setting of the patient with a lung collapse, what is Brock's syndrome?

A. Brock's syndrome is lung collapse due to compression of the right middle lobe bronchus by an enlarged lymph node, often from TB.

Source: Baliga RR. *Saunders/Elsevier* 2007, page 292.



! Trick Question !

Why may the middle lobe collapse and disappear in some persons suffering from a pulmonary infarction?

- The right middle bronchus may collapse, the middle lobe may collapse, and retract towards the hilum
- The remaining normal lung lobes may dilate (compensatory emphysema) and obscure the collapsed middle lobe.

Influenza

Useful background: Recommended Recipients of Seasonal Influenza Immunization

- Persons at high risk for influenza-related complications
 - Adults and children ≥ 6 month of age with chronic cardiac or respiratory disorders (includes asthma, bronchopulmonary dysplasia, cystic fibrosis and COPD) requiring regular medical follow-up
 - All residents of nursing homes and other long-term care facilities
 - All persons ≥ 65 y of age
 - Adults and children ≥ 6 month of age with any of the following chronic disorders:
 - Diabetes mellitus or other metabolic disorder
 - Cancer
 - Immunosuppression (due to underlying disease or treatment)
 - Renal disease
 - Anemia
 - Hemoglobinopathies
 - Children and adolescents (6 month-18 year of age) requiring chronic ASA therapy
 - Pregnant women (all trimesters)
 - Health children 6-23 months
- Persons capable of transmitting influenza to those at high risk of influenza-related complications
 - Health care workers and other personnel (e.g., volunteers, housekeeping staff) who have significant contact with those in the above-mentioned high-risk groups, regardless of the practice setting



- Adults and children ≥ 6 months of age who are household contacts of those at high risk of influenza-related complications. This includes household contacts of children < 6 month old who are at high risk of complications from influenza but for whom there is no currently licensed vaccine. Pregnant women should be immunized if they are expected to deliver during influenza season; they will become household contacts of their newborn.
- Those providing regular child care to children age 0-23 month, whether in or out of the home
- Other
 - People who provide essential community services, e.g., police officers and fire fighters
 - People who are in direct contact with avian influenza-infected poultry during culling operations
- Additional considerations in 2010-2011
 - Persons who are morbidly obese (BMI ≥ 40)
 - Aboriginal peoples
 - Healthy children 2-4 y of age

Reproduced with permission: Therapeutics Choices. Sixth Edition. Ottawa, Canada: Canadian Pharmacist Association 2012, Table 1, page 1382.

Airflow obstruction and Asthma

Name Change: The postnasal drip syndrome is now called UACS (upper airway cough syndrome).

Asthma

- Definition: “Asthma is a respiratory disorder characterized by
 - Paroxysmal or persistent [respiratory] symptoms
 - Dyspnea
 - Chest tightness
 - Wheezing
 - Sputum



- Cough
- Variable airflow limitation
- Airway inflammation
- Airway hyper-responsiveness

Source: Mc Cormack DG, et al. Chapter 51. In: Therapeutic Choices. Grey J, Ed. 6th Edition, *Canadian Pharmacists Association*: Ottawa, ON, 2011, page 671

Useful background:

- Wheezing on maximal forced exhalation
 - A sensitivity of only 57% and a specificity of only 37% for airflow obstruction.
 - A forced expiratory maneuver aimed at “unmasking silent bronchospasm” should not be relied on for the clinical diagnosis of airflow obstruction.
- Wheezing that occurs only in exhalation
 - Not as severe as wheezing that occurs both in exhalation and inspiration.
 - Longer expiratory wheezes reflect worse obstruction than shorter expiratory wheezes.
- Wheezes are not perfect diagnostic findings and are less valuable than crackles.

Source: Mangione S. *Hanley & Belfus* 2000, page 327.

Useful background: Differential diagnosis of wheezing

- Larynx
 - Laryngeal edema
 - Laryngo-, trachea-, or bronchomalacia
 - Vocal cord dysfunction
- Trachea
 - Stenosis or compression
 - Foreign body
 - Central airway tumors
 - Aspiration
 - Vascular ring affecting trachea



- Heart
 - Cardiac failure Asthma
 - Chronic obstructive pulmonary disease
 - Bronchorrheal states (such as chronic bronchitis, cystic fibrosis, bronchiectasis)
 - Hypersensitivity pneumonitis
 - Pulmonary edema
 - Forced expiration in normal subjects

- Lung
 - Pulmonary embolism
 - Carcinoid syndrome
 - Löffler syndrome
 - Bronchiectasis
 - Tropical eosinophilia
 - α -1 Antiprotease deficiency
 - Immotile cilia syndrome
 - Bronchopulmonary dysplasia
 - Bronchiolitis (including bronchiolitis obliterans), croup
 - Cystic fibrosis
 - Infections (croup, whooping cough, laryngitis, tracheobronchitis)

- Ribs
 - Chondromalacia/ polychondritis

- CNS
 - Hyperventilation syndrome
 - Facitious (including psychophysiological vocal cord adduction)

Adapted from: Ghosh AK. *Mayo Clinic Scientific Press* 2008, Table 2-5, page 15.

Sweet Nothing: Not all that wheezes is “asthma”.

- Take a directed history for asthma.

- Wheezing
 - Acute/chronic (duration)
 - Onset/offset
 - Cough, sputum
 - Fever, chills
 - Aspiration
 - Cardiac disease



- Personal history of eczema, hay fever
- Immunizations
- Family history of asthma, allergies, eczema, hay fever
- Complications
 - ER visits
 - Hospital admissions, ICU, intubation
 - Use of beta-blockers
 - Medications, including Tablets, inhalers, ASA, steroids
- Causes
 - Seasonal allergies – pollens, foods, animals, medications
 - Upper respiratory infection
 - Medications
 - Family history of other pulmonary conditions
 - Exercise
 - Cold weather
 - Smoke - first/second hand
 - Stress
 - Gastroesophageal reflux disease

Adapted from: Filate W, et al. *The Medical Society, Faculty of Medicine, University of Toronto* 2005, page 290; Jugovic PJ, et al. *Saunders/ Elsevier* 2004, page 107.

- Perform a focused physical examination for asthma.
- Physical examination
 - General
 - Ability to speak (inability to complete a sentence in one breath)*
 - Restlessness
 - Altered mental status, confusion, coma*
 - Fatigue, exhaustion*
 - Vital signs (RR, HR, BP, O₂ saturation)
 - Pulsus paradoxus
 - Cyanosis
 - Cardiology
 - PR > 110 bpm*
 - ↓ PR, ↓ BP*
 - Respiratory
 - RR > 25/min*
 - ↓ RR (poor respiratory effort)*
 - Cyanosis*
 - Barrel chest
 - Cough



- Accessory muscle use
- Air entry
- Wheezes and location
- Crackles and location
- Percussion – hypertympanic
- Prolonged expiration
- Clubbing
- Peak expiratory flow rate less than 50% of predicted or best*
- Focus of infection
 - Rhinorrhea, coryza
 - Pharynx
 - Tympanic membrane
 - Cardiovascular examination
 - Abdominal examination
 - Skin examination – rash

*denotes severe asthmatic attack (risk stratification)

Adapted from: Jugovic PJ, et al. *Saunders/ Elsevier* 2004, page 108; McGee SR. *Saunders/Elsevier* 2007, page 338; Baliga RR. *Saunders/Elsevier* 2007, page 260.

- Take a directed history and perform a focused physical examination for asthma.
- History
 - Cough/ wheeze recurrent
 - Worse at night emotion, or after exercise
 - Improvement with bronchodilators
 - Tightness of chest
 - Fever
 - Yellow sputum
 - Past history
 - Atopy (hay fever, eczema)
 - Nasal polyps
 - Rhinitis
- Physical
 - Inspection
 - Wheezing
 - Dyspnea
 - Use of accessory muscles of respiration
 - Sputum
 - RR > 25/min*
 - Fatigue*
 - Confusion, drowsiness, coma*
 - Cyanosis*



- Palpation
 - PR > 110 bpm*
 - ↓ PR, ↓ SBP*
 - Pulsus paradoxus (not useful to predict severity of asthmatic attack)
 - Auscultation
 - Bilateral, scattered wheezes
 - Silent chest*
 - Signs of complications
 - PHT/ CHF (cor pulmonale)
- Distinguish from other causes of widespread narrowing of airways resulting in wheezing
- Lung
 - COPD
 - PE
 - Tumor
 - Heart
 - L-CHF
 - Immune
 - ELD
 - PAN

*signs of severe – life threatening asthma

Abbreviation: ELD, eosinophilic lung disease; L-CHF, left-sided congestive heart failure; PAN, polyarteritis nodosum; PE pulmonary embolus; PHT, pulmonary hypertension; PR, pulse rate; RR, respiratory rate; SBP, systolic blood pressure

Useful background: Performance characteristics of pulsus paradoxus predicting severe asthma

| Finding | Sensitivity (%) | Specificity (%) | PLR | NLR |
|--------------------|-----------------|-----------------|------|-----|
| ➤ Pulsus Paradoxus | | | | |
| ○ 10 mm Hg | 52-68 | 69-92 | 2.7 | 0.5 |
| ○ 20 mm Hg | 19-39 | 91-100 | 8.2 | 0.8 |
| ○ 25 mm Hg | 16 | 99 | 22.6 | 0.8 |

Abbreviations: NLR, negative likelihood ratio; PLR, positive predictive ratio

Source: McGee SR. *Saunders/Elsevier* 2007, Box 13.2, page 131.



Useful background: Definitions

- Chronic bronchitis is cough with mucoid expectoration for at least 3 months in a year for 2 successive years.
- Emphysema is the abnormal permanent enlargement of the airway distal to the terminal respiratory bronchioles with destruction of their walls. (Clinical, radiological and lung function tests give an imprecise picture in an individual case, but a combination of all these features gives a reasonable picture)
- The term COPD encompasses chronic obstructive bronchitis (with obstruction of small airways) and emphysema (with destruction of lung parenchyma, loss of lung elasticity, and closure of small airways). Most patients also have mucus plugging

Source: Baliga RR. *Saunders/Elsevier* 2007, page 262.

SO YOU WANT TO BE A RESPIROLOGIST!

Q1. In the context of the patient with asthma, what is “Loeffler’s syndrome”?

- A1.
- Loeffler’s syndrome is comprised of
 - Asthma (airway reactivity)
 - Fever
 - Eosinophilia
 - Abnormal chest X-ray (transient, migratory pneumonitis; remember that persons with uncomplicated asthma will have a normal chest X-ray)
 - Loeffler’s syndrome may be associated with
 - Polyarthritis
 - Allergic asthma
 - Allergic skin disease
 - Infections: mycoses, parasites
 - Drugs (e.g. Sulfa’s, penicillin)

BREATH SOUNDS

Q2. How can you differentiate between chronic bronchitis or asthma versus emphysema by listening to the patient’s breath sounds heard at the mouth (BSM) with the unaided ear, i.e. without using a stethoscope?

A2. In chronic bronchitis and asthma, there is a positive relation between the loudness of BSM and the FEV₁, or PEF (peaked expiratory flow rate), whereas in asthma, BSM, becomes softer as airflow obstruction worsens. Thus, the intensity of BSM is not increased in all persons with COPD.

Source: Mangione S. *Hanley & Belfus* 2000, page 304.



- Take a focused history and perform a directed physical examination for chronic bronchitis.
 - General
 - Sputum pot full
 - Pursed lip
 - O₂ mask/ respirator
 - Cyanosis of lips/ tongue
 - Neck
 - Inspection
 - Use of accessory muscles of respiration (sternocleidomastoids, scaleni and trapezi)
 - ↑ JVP
 - Palpation
 - Tracheal deviation
 - ↓ distance (< 3 fingers' breadth) between the cricoid cartilage and suprasternal notch
 - Lungs
 - Inspection
 - Barrel-shaped
 - ↑ RR
 - Dyspnea
 - Chest expansion
 - Palpation
 - Apex beat
 - ↓ Chest expansion
 - Tactile vocal fremitus
 - Percussion
 - Hyper-resonance
 - Auscultation
 - ↓ breath sounds
 - Vocal resonance
 - Forced expiratory time > 6 seconds indicates airflow obstruction
 - CVS
 - ↑ PR
 - Bounding pulse
 - ↓ heart dullness
 - Displaced apex beat
 - ↑ P₂
 - Abdomen
 - ↓ liver dullness
 - Palpable liver (not necessarily enlarged)
 - Hands
 - Warm palms
 - Tar staining
 - No clubbing

Abbreviations: RR, respiratory rate; PR, pulse rate



Adapted from: Baliga RR. *Saunders/Elsevier* 2007, pages 261 and 262.

SO YOU WANT TO BE A RESPIROLOGIST!

Q. Is Campbell's sign specific for COPD?

A. Tracheal descent with inspiration ("tracheal tug", aka Campbell's sign) is caused by any cause of chronic airflow obstruction, and not just COPD.

Source: Mangione S. *Hanley & Belfus* 2000, page 287.

SO YOU WANT TO BE A RESPIROLOGIST!

Q. Under what conditions does the auscultation of vesicular breath sounds not signify reduced air flow (e.g., in COPD)?

- A.
- Normal thickness of the chest wall
 - Normal pleura (no fluid or air)
 - Normal function of respiratory muscles
 - Reduced/distant breath sounds suggest COPD, as also do vesicular breath sounds. Breath sounds of normal intensity mean that the FEV1 is normal or near normal.
 - Auscultation of the breath sound intensity (BSI) at the bedside (reduced intensity) correlates with FEV1, FEV1/FVC, and distribution of ventilation – a poor person's pulmonary function test – because of airtrapping and destruction of lung parenchyma in COPD
 - In COPD (asthma, chronic bronchitis), the intensity of breath sounds heard at the mouth without the use of a stethoscope increases: with airway obstruction, intensity at mouth increases, over the chest diseases.

Source: Mangione S. *Hanley & Belfus* 2000, page 302.



- Take a directed history to differentiate between bronchial asthma, chronic bronchitis, and emphysema.

| Differential feature | Bronchial asthma | Chronic bronchitis ("blue bloater") | Emphysema ("pink puffer") |
|-----------------------------|------------------|-------------------------------------|---------------------------|
| ➤ Onset | 70% < 30 y | >50 y | ≤ 60 y |
| ➤ Cigarette smoking | 0 | ++++ | ++++ |
| ➤ Pattern | Paroxysmal | Chronic, progressive | Chronic, progressive |
| ➤ Dyspnea | 0 to ++++ | + to ++++ | +++ to ++++ |
| ➤ Cough | 0 to +++ | ++ to ++++ | + to +++ |
| ➤ Sputum | 0 to ++ | Profuse, mucopurulent | scanty |
| ➤ Atopy | 50% (adult) | 15% | 15% |
| ➤ Infections | ↑ Symptoms | ↑↑↑ Symptoms | ↑ Symptoms |
| ➤ Cyanosis | --- | ++ | -- |
| ➤ Hyperinflation | --- | + | ++ |
| ➤ Cor Pulmonale | --- | +++ frequent, remittent | + (pre-terminal) |
| ➤ Respiratory drive | --- | ↓ | ↑ |
| ➤ Polycythemia | --- | +++ | + |
| ➤ Chest x ray, vessels | --- | --- | ↓ |
| ➤ Arterial PCO ₂ | --- | ↑ | |
| ➤ Alveolar gas transfer | --- | --- | ↓ |

Adapted from: Ghosh, AK. *Mayo Clinic Internal Medicine Review*. 8th Edition. page 902; Baliga RR. *Saunders/Elsevier*, 2007, page 2; Burton JL. *Churchill Livingstone* 1971, page 26.



Useful background: Operational characteristics of clinical feature in emergency department patients with history of asthma or COPD

| Finding | PLR | NLR |
|-----------------------------------|-----|------|
| ➤ Initial clinical judgment | 9.9 | 0.65 |
| ➤ History | | |
| ○ Atrial fibrillation | 4.1 | 0.74 |
| ○ Coronary artery bypass grafting | 2.8 | 0.92 |
| ○ Myocardial infarction | 2.2 | 0.84 |
| ○ Diabetes mellitus | 2.0 | 0.85 |
| ○ Coronary artery disease | 2.0 | 0.67 |
| ➤ Physical examination | | |
| ○ S3 (ventricular filling gallop) | 57 | 0.83 |
| ○ JVP | 4.3 | 0.65 |
| ○ Lower extremity edema | 2.7 | 0.41 |
| ○ Lung rales | 2.6 | 0.39 |
| ○ Hepatic congestion | 2.4 | 0.91 |
| ➤ Chest radiograph | | |
| ○ Edema | 11 | 0.68 |
| ○ Cardiomegaly | 7.1 | 0.54 |
| ○ Pleural effusion(s) | 4.6 | 0.78 |
| ➤ Electrocardiogram | | |
| ○ Atrial fibrillation | 6.0 | 0.73 |
| ○ Ischemic ST-T waves | 4.6 | 0.83 |
| ○ Q waves | 3.1 | 0.84 |
| ○ BNP _≥ 100 pg/mL | 4.1 | 0.09 |

Abbreviations: BNP, brain natriuretic peptide; NLR, negative likelihood ratio, PLR, positive likelihood ratio

Note that some clinical features are not shown here because their likelihood ratio is < 2. These include history of angina, hypertension, symptoms of orthopnea, fatigue, nocturnal cough, enlarged heart, wheezing, chest X-ray showing pneumonia, hyperinflation or normal.

Adapted from: Simel DL, et al. *JAMA* 2009, Table 16-9, page 203.



Chronic obstructive pulmonary (lung) disease (COPD)

Useful background

Definition

- Chronic obstructive bronchitis
 - Productive cough for at least 3 months a year for 2 successive years
 - Obstruction of small airways
- Emphysema
 - Abnormal, permanent dilation of the pulmonary airway distal to the terminal respiratory bronchioles destruction of the walls (↓ lung parenchyma)
 - ↓ lung elasticity
 - Closure of small airways
 - Mucus plugging
- COPD
 - Includes chronic bronchitis and emphysema
- Bronchiectasis
 - Chronic, necrotizing infection of bronchi and beonchioles
 - Abnormal, permanent dilation of airways

Useful background: Characteristic results of pulmonary function tests in obstructive and restrictive lung diseases

| | | Obstructive | Restrictive |
|--------------------|-------------|-------------|-------------|
| Lung volumes | VC | ↓ | ↓ |
| | FRC | ↑ | ↓ |
| | RV | ↑ | ↓ |
| | TLC | ↑ or N | ↓ |
| Flow rates | FEV 1.0 | ↓ | ↓ or N |
| | FEV 1.0/FVC | ↓ | ↑ or N |
| | FEF 50% VC | ↓ | ↑ or N |
| | FEF 25% VC | ↓ | ↑ or N |
| Diffusion capacity | DCco | ↓ or N | ↓ or N |

Source: Davey P. *Wiley-Blackwell* 2006, page 198.



Useful background: Operating characteristics of clinical history for COPD

| Item | PLR | NLR |
|--|------|------|
| ➤ Smoking history | | |
| ○ ≥ 70 vs. < 70 pack yrs | 8.0 | 0.63 |
| ➤ Sputum production $\geq \frac{1}{4}$ cup | 4 | 0.84 |
| ➤ Symptoms of chronic bronchitis | 3.0 | 0.78 |
| ➤ Wheezing | 3.8 | 0.66 |
| ➤ Exertional dyspnea | | |
| ○ Grade 4 vs. 3 or less | 3.0 | 0.98 |
| ○ Any vs. none | 2.2 | 0.83 |
| ➤ Wheezing | 36 | 0.85 |
| ➤ Barrel chest | 10 | 0.90 |
| ➤ Decreased cardiac dullness | 10 | 0.88 |
| ➤ Match test | 7.1 | 0.43 |
| ➤ Rhonchi | 5.9 | 0.95 |
| ➤ Hyperresonance | 4.8 | 0.73 |
| ➤ Forced expiratory time, sec | | |
| >9 | 4.8 | |
| 6-9 | 2.7 | |
| <6 | 0.45 | |
| ➤ Subxiphoid cardiac apical impulse | 4.6 | 0.94 |
| ➤ Pulsus paradoxus (> 15 mm Hg) | 3.7 | 0.62 |
| ➤ Decreased breath sounds | 3.7 | 0.70 |

Abbreviation: PLR, positive likelihood ratio; NLR negative likelihood ratio

Adapted from: Simel DL, et al. *JAMA* 2009 Chapter 13, Table 13-2, page 152, and Table 13-3, page 154.

SO YOU WANT TO BE RESPIROLOGIST!

Q. A patient with COPD has an incision on one side of their chest. What surgical procedures play a role in the care of the COPD patient?

- A.
- Bullectomy
 - Partial resection (lung-volume reduction)
 - Lung transplantation (including single lung transplant)



Useful background: Performance characteristics of physical examination for COPD

| Clinical features | PLR | NLR |
|--|------|-----|
| ➤ Inspection | | |
| ○ Maximum laryngeal height <4 cm | 3.6 | 0.7 |
| ○ Hoover's sign | 4.2 | 0.5 |
| ➤ Palpation | | |
| ○ Subxiphoid cardiac impulse | 7.4 | NS |
| ➤ Percussion | | |
| ○ Absent cardiac dullness left lower sternal border | 11.8 | NS |
| ○ Hyperresonance upper right anterior chest | 5.1 | NS |
| ➤ Auscultation | | |
| ○ Breath sound score | | |
| ≤9 | 10.2 | ... |
| 10-12 | 3.6 | ... |
| ○ Early inspiratory crackles | 14.6 | NS |
| ○ Any unforced wheeze | 2.8 | 0.8 |
| ➤ Ancillary tests | | |
| ○ Forced expiratory time | | |
| ≥9 seconds | 4.1 | ... |
| ➤ 2 out of the following 3 findings present: | 25.7 | 0.3 |
| ○ 70 pack years or more of smoking | | |
| ○ Self-reported history of chronic bronchitis or emphysema | | |
| ○ Decreased breath sounds | | |

Abbreviation: NLR, negative likelihood ratio; NS, not significant; PLR, positive likelihood ratio

Note that some of the clinical features are not shown here, because their PLR is < 2. These include: laryngeal descent >3 cm, diaphragm excursion percussed <2 cm, breathing sound score ≥ 13 and force expiratory time ≤ 9 second.

Adapted from: McGee SR. *Saunders/Elsevier* 2007, Box 30-1, page 361.



- Take a directed history for the harmful effects of cigarette smoking.
- CNS
 - Autonomic: transient stimulation, followed by depression of all ganglia
 - CNS: stimulation, especially respiratory, vasomotor and emetic centres
 - Antidiuretic: (due to ADH release)
 - Tobacco amblyopia
- CVS
 - Rise in BP, tachycardia, cutaneous vasoconstriction
 - Tobacco angina
 - Atrial extrasystoles
 - Myocardial ischemia
 - Buerger's disease
- Lung
 - Post-operative pneumonia
 - Bronchitis
 - Bronchus (increased carcinoma incidence)
- GI
 - Esophagus (increased carcinoma incidence)
 - Cirrhosis incidence increased (Probably due to associated alcoholism)
- Kidney
 - Prostate (increased carcinoma incidence)
 - Bladder (increased carcinoma incidence)
- Endocrine
 - Adrenal: discharges adrenaline
 - Hypoglycemia
- Fetus (pregnant mother smoking)
 - ↓fetal growth
 - ↑perinatal mortality rate

Adapted from: Burton JL. *Churchill Livingstone* 1971, page 27.



Q. Give the spirometry criteria for COPD.

- A. ○ $FEV_1 < 80\%$ of the predicted value, taken after bronchodilator; plus
 ○ $FEV_1 / FVC < 0.70$

- Take a focused history and perform a directed physical examination for bronchiectasis.

- History

- General

- Intermittent fever and night sweats
- Weight loss

- Lungs

- Cough with copious purulent sputum
- Recurrent hemoptysis
- History of recurrent chest infections
- History of associated lung disease

- Physical examination

- Lungs

- Copious purulent expectoration
- Collapse
- Fibrosis
- Pneumonia
- Bilateral coarse, late, inspiratory crackles

- Spine

- Possible kyphoscoliosis

- Hands

- Finger clubbing

- Spleen

- Possible splenomegaly (amyloidosis)

Adapted from: Baliga RR. *Saunders/Elsevier* 2007, page 266.



- Perform a focused physical examination for bronchiectasis.
- Inspection
 - Sputum
 - Purelent
 - Sometime bloody
 - Evidence of weight loss
 - Kyphoscoliosis
 - Finger clubbing
- Plapation, percussion, auscultation
 - Bilateral, coarse crackles on inspiration
 - Signs of
 - Pneumonia
 - Fibrosis
 - Collapse
 - Effusion
 - Pneumothorax
 - Chest incision
 - One lobe or segment
 - Commonly LLL and lingual

Abbreviation: LLL, left lower lobe

SO YOU WANT TO BE RESPIROLOGIST!

Q. A patient presents with chronic intermittent cough and hemoptysis, but no sputum. There is a past history of pulmonary TB. In reveals disease in the high resolution CT upper lobes. What is this called?

A. 'dry' bronchiectasis, aka bronchiectasis sicca.

- Take a directed history and perform a focused physical examination for the effects/complications of smoking.
- CNS
 - Stem of respiration, vasomotor, emetic centers
 - Tobacco amblyopia
 - Stimulates, then depresses all ganglia
 - Release of Adrenaline from adrenal gland
- Lung
 - Cancer
 - Bronchitis



- Post-op pneumonia
- Heart
 - Nicotine → ↑ HR, ↑BP
 - Cutaneous vasoconstriction
 - Ischemia
 - Buerger's
 - Tobacco angina, extrasystoles
- GI
 - ↑ CA esophagus, stomach, colon
 - ↑ mortality of from PUR, ↑ incidence of cirrhosis
 - Worsening of Crohn's disease (improvement of UC!!!)
- GU
 - ↑ Ca prostate, bladder
 - Release of ADH
- Fetus
 - ↓ fetal growth, ↑ perinatal mortality rate

Adapted from: Burton JL. *Churchill Livingstone*, 1971, page 27.

Carcinoma of the lung

- Causes of mediastinal tumors
 - Lymphadenopathy
 - Reticulosis
 - Sarcoidosis
 - Infective (especially TB)
 - Metastasis
 - Heart
 - Aneurysm
 - Tumor
 - Pericardial cysts
 - Aorta
 - Unfolding
 - Aneurysm
 - Coarctation
 - Esophagus
 - Hiatus hernia
 - Corkscrew
 - Achalasia
 - Enterogenous cyst
 - Neoplasm
 - Thyroid
 - Retrosternal goiter
 - Cysts



- Dermoid
- Teratoma
- Hydatid cysts
- Bronchial cysts
- Tumors
 - Thymoma
- Diaphragm
 - Diaphragmatic hernia
 - Lung herniation
 - Mesothelioma
 - Lipoma

Adapted from: Burton JL. *Churchill Livingstone* 1971, page 34.

- Perform a directed physical examination of the pulmonary system in the patient with suspected mediastinal compression (e.g. carcinoma of the lung).
- Many patients have no signs
- General
 - Anorexia
 - Weight loss
 - Cachexia
 - Fever
 - Fatigue
 - Night sweats
- CNS
 - Mediastinal nerve compression (sympathetic, left recurrent laryngeal, phrenic nerve)
 - Cortex – dementia
 - Peripheral neuropathy (polyneuropathy, subacute sensory neuropathy)
 - Polymyositis; progressive muscle weakness (Eaton-Lambert syndrome)
 - Retinal blindness (small cell carcinoma)
 - Subacute cerebellar degeneration
 - Polymyositis
 - Cortical degeneration.
- Eyes
 - Exophthalmos
 - Conjunctival redness, venous dilation in the fundi



- Face
 - Plethora
 - Cyanosis
 - Periorbital edema

- Neck
 - JVP is raised but not pulsatile
 - Thyroid (large retrosternal goiter) may be supraclavicular lymphadenopathy
 - Metastases

- Chest
 - Superior vena caval obstruction
 - The face is plethoric and cyanosed with periorbital edema
 - The eyes may show exophthalmos, conjunctival injection, and venous dilatation in the fundi
 - Metastases
 - Effusion
 - Hemoptyses
 - Lobar collapse or volume loss
 - Pneumonia
 - Fixed inspiratory wheeze
 - Tender ribs (secondary deposits of tumor in the ribs)

- Mediastinal compression
 - Trachea
 - Stridor – respiratory distress
 - Nerve compression
 - Sympathetic nerves - myosis, ptosis, anhidrosis, (Horner's syndrome)
 - Left recurrent laryngeal nerve compression– hoarseness
 - Phrenic nerve-unilateral absent breath sounds; percussion dullness at affected based, with no inspiratory changes (paralysis of diaphragm)
 - Superior Vena Cava (SVC)
 - Pemberton's sign for SVC obstruction – lift arms, wait 1 minute for facial plethora, cyanosis, inspiratory stridor, non-pulsative elevation of JVP
 - Also eyes, face, neck as above

- Skin
 - Wasting of small muscles of hands
 - Clubbing
 - Tar staining of fingers
 - Radiation marks



- Membranous glomerulonephritis
- Acanthosis nigricans
- Dermatomyositis (rare)
- Liver metastases
- Bone metastases
- Endocrine
 - Adrenal metastases
 - Hypercalcaemia, due to secretion of parathyroid hormone like substances, occurs in squamous cell carcinoma
 - Hyponatraemia-antidiuretic hormone is released by small (oat) cell carcinomas
 - Ectopic ACTH syndrome (small cell carcinoma)
 - Carcinoid syndrome (small cell carcinoma)
 - Gynecomastic (gonadotrophins)
 - Hypoglycemia (insulin like peptide from squamous cell carcinoma).
 - Dermatomyositis
 - Acanthosis nigricans
 - Herpes zoster
 - Atrial fibrillation
 - Pericarditis
 - Non-bacterial thrombotic endocarditis
 - Aortic aneurysm (rare)
 - Thyrotoxicosis
 - ↑ADH (↓Na)
 - ↑PTH (↑Ca²⁺)
 - ↑ACTH (hypokalemic alkalosis, Cushing's syndrome)
 - ↑Gonadotropins (gynecomastia)
 - ↑serotonin, carcinoid syndrome
- Hematological features
 - Migrating venous thrombophlebitis
 - Disseminated intravascular coagulation
 - Anemia
 - TTP
- Kidney
 - Nephritic syndrome (membranous glomerulonephritis)

Abbreviations: DIC, disseminated intravascular coagulopathy; TTP, thrombotic thrombocytopenic purpura

Adapted from: Talley NJ, et al. *MacLennan & Petty Pty Limited* 2003, pages 128-129; Davey P. *Wiley-Blackwell* 2006, page 212; Burton JL. *Churchill Livingstone*, 1971, pages 33 and 34, Baliga RR. *Saunders/Elsevier* 2007, page 274.



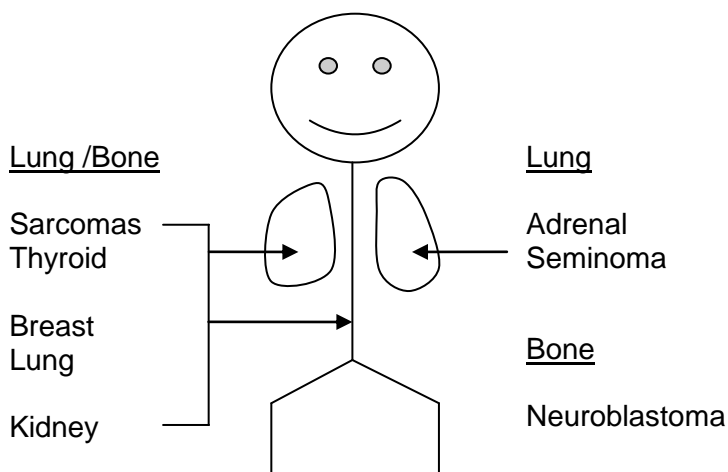
- Perform a focused physical examination for lung cancer.
 - General inspection
 - Cough
 - Dyspnea
 - Weight loss (cachexia)
 - Purpura (TTP)
 - Hemoptysis
 - Fatigue
 - Palor (anemia)
 - Voice hoarseness
 - Head & neck
 - Eye – Horner’s syndrome
 - Lymphadenopathy
 - SVC obstruction
 - Cushing’s syndrome
 - Metastases
 - Chest
 - Heart
 - Pericardial tamponade
 - Atrial fibrillation
 - Pericarditis
 - Endocarditis (non-bacterial, thrombotic)
 - Thrombophlebitis migrans
 - Lung
 - Effusions
 - Consolidation
 - Collapse
 - Marks from/ for radiation treatment
 - Breasts
 - Gynecomastia
 - Skin/ MSK
 - Clubbing
 - Hypertrophic osteoarthropathy
 - Cigarette stains on fingers
 - Dermatomyositis
 - Acanthosis nigrans
 - Herpes zoster
 - CNS/ PNS
 - CNS
 - Encephalomyelitis
 - Dementia
 - Cerebellar
 - Degeneration



- Muscle
 - Myopathy (proximal)
 - Neuropathy (sensory)
 - Myoclonus
- PNS
 - Polyneuropathy

Abbreviation: CNS, central nervous system; PNS, peripheral nervous system; SVC, superior vena cava; TTP, thrombotic thrombocytopenic purpura

Useful background:



Adapted from: Burton JL. *Churchill Livingstone*, 1971, page 34.

- Perform a directed physical examination for Pancoast's (superior pulmonary sulcus tumor) syndrome (often from cancer [often non-small cell] of the apex of the lung, infiltrating C8, T1, 2; may also occur with lymphoma, or by spread of lymph node metastases in breast or lung cancer).
 - Shoulder pain radiating in the ulnar distribution in the arm
 - Numbness of digits #4,5
 - Weakness of hand muscles innervated by ulnar nerve
 - Radiologic destruction of ribs #1,2
 - Horner's syndrome

Adapted from: Davey P. *Wiley-Blackwell* 2006, page 212.



Useful background: causes of chest pain in persons with bronchial cancer

- Pleurisy
 - Infiltration of intercostals nerves
 - Erosion/ infiltration of ribs
- Give a systematic approach to the non-metastatic, non-pulmonary complications of bronchial cancer.
 - Endocrine
 - Cushing's syndrome
 - Hypercalcemia
 - SIADH (syndrome of inappropriate ADH)
 - Carcinoid
 - Hypo-/ hyperglycemia
 - Thyrotoxicosis
 - Acromegaly
 - Gynecomastia
 - Hematology
 - RBC aplasia
 - Polycythemia
 - Hypercoagulable state
 - Hemolytic anemia
 - Neurology (10% of bronchial cancers present with CNS involvement)
 - Benign
 - Dementia
 - Encephalomyelitis
 - Meningitis
 - Cerebellum
 - Cord
 - Corticospinal tract
 - Posterior root ganglion
 - Nerves
 - Neuropathy
 - Mononeuritis multiplex
 - Motor neuron disease
 - Muscle
 - Myopathy
 - Myasthenia
 - Skin
 - Dermatomyositis
 - Osteorathropathy
 - Acanthosis migrains
 - Xeroderma
 - Dermatitis herpetiformis



- Urticaria
- Exfoliation
- Tylosis palmars
- Erythema multiforme
- GI
 - Idiopathic malabsorption
- MSK
 - Dermatomyositis
 - Thrombophlebitis
 - Pulmonary osteoarthropathy

Adapted from: Davies IJT. *Lloyd-Luke (medical books) LTD 1972*, page 136, 137 and 315.

- Provide a systematic approach to the tumors which are associated with polycythemia.
 - CNS
 - Cerebellar hemangiomas
 - Lung
 - Bronchial carcinoma
 - Liver
 - Hepatocellular cancer
 - Kidney
 - Benign tumors
 - Renal cell cancer
 - Adrenal
 - Hyperplasia/ carcinoma
 - Pheochromocytoma
 - GU
 - Ovarian tumors
 - Uterine fibroids
- Give the non- metastatic, extra – pulmonary complications of bronchial carcinoma.
 - Endocrine
 - Cushing syndrome
 - Hypercalcemia
 - SIADH
 - Hypo-/ hyperglycemia
 - Thyrotoxicosis
 - Acromegaly
 - Gynecomastia
 - Skin
 - Acanthosis nigricans
 - Dermatitis herpetiformis
 - Urticaria
 - Erythema multiforme
 - Irritation, exfoliation
 - Tylosis palmaris
 - Hematology
 - Red cell aplasia
 - Polycythemia
 - Hemolytic anemia
 - Neurological
 - Dementia
 - Encephalomyelitis
 - Cerebellum



- MSK
 - Dermatomyositis
 - Thrombophlebitis
 - Pulmonary osteoarthropathy
- GI
 - Enteropathy
- Spinal cord
- Corticospinal tract
- Posterior rectal ganglia
- Neuropathy
- Mononeuritis multiplex
- Myopathy
- Motor neuron disease
- Myasthenia gravis

Adapted from: Davies IJT. *Lloyd-Luke (medical books) LTD 1972*, pages 136, 137 and 315.

SO YOU WANT TO BE A RESPIROLOGIST!

Q. Metastases to the lung are usually seen as a few large deposits. From what primary tumors are the metastases to the lung usually multiple and small?

- A. Lung metastasis from primary cancers of
- Bronchus
 - Stomach

Pulmonary hypertension and Cor pulmonale

Useful background: Cor Pulmonale

- Definition: Cor pulmonale is right ventricular enlargement due to the increase in afterload that occurs in diseases of the lung, chest wall or pulmonary circulation.
- Causes
 - Obstructive lung disease
 - COPD
 - Chronic asthma
 - Restrictive lung disease
 - Intrinsic
 - interstitial fibrosis
 - lung resection
 - Extrinsic
 - Obesity
 - muscle weakness
 - kyphoscoliosis
 - high altitude
 - Vascular disorders
 - Pulmonary emboli
 - Vasculitis (small pulmonary arteries)
 - ARDS
 - Primary pulmonary hypertension

Adapted from: Baliga RR. *Saunders/Elsevier 2007*, page 270.



- Take a directed history and perform a focused physical examination for pulmonary hypertension.
- Definition
 - Systolic pulmonary artery (PA) pressure (SPAP) > 30 mm Hg
 - When SPAP > 50 mm Hg, symptoms occur
- History
 - SOB/OE, fatigue, chest pain (in 50%, from RV ischemia)
- Physical
 - General
 - ↑RR (respiratory rate)
 - Peripheral cyanosis (↓ cardiac output [CO])
 - Cold extremities (↓ CO)
 - Hoarseness (PA compression of L. recurrent laryngeal nerve)
 - Dyspnea at rest, centrally cyanosis
 - Tar staining of the fingers
 - Heart
 - ↓ pulse volume (↓CO)
 - ↑ JVP both 'a' and 'v' waves are seen, 'v' waves being prominent if there is associated tricuspid regurgitation
 - RV heave, gallop
 - Palpable P₂, loud P₂ (forceful valve closure due to ↑ SPAP)
 - Systolic ejection click (PA dilated)
 - S₄
 - Pulmonary ejection murmur (PA dilation with turbulent flow)
 - Pulmonary regurgitation (PA dilation)
 - Lung
 - R-CHF (cor pulmonale)
 - Bilateral wheeze, and other signs of COPD
 - Pansystolic murmur of tricuspid regurgitation
 - Early diastolic Graham Steell murmur in the pulmonary area
 - Abdomen
 - Look for signs of hepatomegaly
 - Legs
 - Pedal edema
 - Causes
 - Lung
 - Obstruction
 - Pulmonary emboli, blood clots, fat globules, tumor particles
 - COPD
 - Obstructive sleep apnea
 - Pulmonary fibrosis (interstitial lung disease)
 - Vasoconstriction secondary to hypoxia



- High altitude
- Chronic bronchitis
- Kyphoscoliosis
- Upper respiratory tract obstruction
- Heart
 - L-CHF
 - Pulmonary venous hypertension (MS, atrial myxoma, cor triatriatum)
 - Congenital heart disease, L-R shunt (ASD, VSD, PPA)
- Spine
 - Kyphoscoliosis
- Ideopathic (primary)

Abbreviations: L-CHF, Left-sided congestive heart failure; R-CHF, Right-sided congestive heart failure; CO, Cardiac output; PA, pulmonary artery; SPAP, systolic pulmonary artery pressure; COPD, Chronic obstructive pulmonary disease; RR, Respiratory rate; PA, Pulmonary artery

Adapted from: Baliga RR. *Saunders/Elsevier* 2007, pages 269 and 270.

- Perform a focused physical examination for cor pulmonale.

- General
 - Dyspnea at rest
 - Cyanosis, central
 - Fatigue
 - ↑ BMI (obesity)
- Neck
 - Kyphoscoliosis
 - ↑ JVP
 - 'a' & 'v' waves on JVP
 - ↑ v waves with TR
- Chest
 - Chest wall
 - Barrel – shaped
 - L. parasternal heave
 - Lung
 - Signs of
 - COPD
 - Chronic asthma
 - Fibrosis
 - Resection
 - Heart
 - ↑ P2
 - Ejection click
 - TR (pansystolic murmur)
 - Graham Steell murmur



- Abdomen
 - Hepatomegaly
 - RUQ
 - Tender
 - Murmur
 - Thrill (TR)
- Legs
 - Edema

Abbreviation: BMI, body mass index; JVP, jugular venous pressure; TR, tricuspid regurgitation

Acute respiratory distress syndrome (ARDS)

- Perform a focused physical examination for acute respiratory distress syndrome (ARDS).

| Disorder | Cause |
|-----------------|---|
| ➤ Shock | ○ Any cause |
| ➤ Sepsis | ○ Lung infections, other bacteremic or endotoxic states |
| ➤ Trauma | <ul style="list-style-type: none"> ○ Hypotension, especially if prolonged, or with trauma ○ The systemic inflammatory response syndrome (SIRS) ○ Obstetric causes: amniotic fluid embolism, pre eclampsia ○ High altitude related lung injury ○ Head injury, lung contusion, fat embolism ○ Gastric, near-drowning, tube feeding, Inhaled- O₂, smoke |
| ➤ Aspiration | <ul style="list-style-type: none"> ○ Blood transfusions (especially if massive), leukoagglutinin, DIC (disseminated intravascular coagulation), thrombotic thrombocytopenic purpura ○ Pancreatitis, uremia ○ Narcotics, barbiturates, aspirin, “street drugs” |
| ➤ Hematologic | <ul style="list-style-type: none"> ○ Chemicals-paraquat ○ Irritant gases- NO₂, CO₂, SO₂, NH₃ ○ Radiation, air embolism, altitude |
| ➤ Metabolic | |
| ➤ Drugs | |
| ➤ Toxic | |
| ➤ Miscellaneous | |



- Appropriate setting
 - Pulmonary injury, shock, trauma
 - Acute event
 - Clinical respiratory distress, tachypnea
- Diffuse pulmonary infiltrates on chest radiography
 - Interstitial or alveolar pattern (or both)
- Hypoxemia
 - PaO₂/FiO₂ ratio <150
- Exclude
 - Chronic pulmonary disease accounting for the clinical features
 - Left ventricular failure (most series require pulmonary artery wedge pressure <18 mm Hg)

Abbreviations: ARDS, Acute respiratory distress syndrome; BOOP, Bronchiolitis obliterans organizing pneumonia; COP, cryptogenic organizing pneumonia; FiO₂, fraction of inspired oxygen

Adapted from: Davey P. *Wiley-Blackwell* 2006, Table 105.1, page 211; Ghosh AK. *Mayo Clinic Scientific Press* 2008, Table 4-14 and Table 4-15, page 159.

Useful background: Causes of hypoventilation and hypercapnic respiratory failure

- | | |
|--|---|
| <ul style="list-style-type: none"> ➤ Central nervous system <ul style="list-style-type: none"> ○ Drugs ○ Hyperthyroidism ○ Ondine curse ○ Brainstem injury ○ Metabolic alkalosis ➤ Chest wall disorders <ul style="list-style-type: none"> ○ Kyphoscoliosis ○ Rib fractures ○ Pain ○ Flail chest ○ Respiratory muscle disease ➤ Spinal cord & peripheral nervous system <ul style="list-style-type: none"> ○ Lesion at C3 to C5 ○ Neuropathy ○ Trauma | <ul style="list-style-type: none"> ➤ Diaphragm disorders <ul style="list-style-type: none"> ○ Rupture, myopathy ➤ Muscular dysfunction <ul style="list-style-type: none"> ○ Muscular dystrophies ○ Guillain-Barre syndrome ○ Myasthenia gravis ○ Amyotrophic lateral sclerosis ○ Malnutrition ○ Acidosis ○ Hypoxemia ○ Anemia ○ Low cardiac output ○ Steroids ○ Aminoglycosides ○ Calcium channel blockers ○ Post paralytic condition ○ Detraining, atrophy, overuse fatigue ○ Increased workload |
|--|---|



Respiratory Failure

Useful background: Categorization of hypercapnia ($\uparrow PaO_2$)

| Cause | Example | VE | VD/VT | A-a gradient |
|--|---|-------------|-------------|--------------|
| ➤ Defective central control of breathing | <ul style="list-style-type: none"> ○ Drug overdose ○ Most causes of coma | ↓ | Normal | Normal |
| ➤ Neuro-muscular disease | <ul style="list-style-type: none"> ○ ALS ○ Spinal cord lesions ○ Myasthenia gravis ○ Guillian-Barre | ↓ | Normal or ↑ | Normal or ↑ |
| ➤ Chest wall disease | <ul style="list-style-type: none"> ○ Kyphoscoliosis ○ Large effusions | ↓ | Normal or ↑ | Normal or ↑ |
| ➤ Primary lung disease | <ul style="list-style-type: none"> ○ COPD | Normal or ↑ | ↑ | ↑ |

Abbreviations: ALS, amyotrophic lateral sclerosis; COPD, chronic obstructive pulmonary disease; VE, minute ventilation; VD, dead space; VT, tidal volume

Permission granted: Davey P. *Wiley-Blackwell* 2006, page 198.

“Success is not final, failure is not fatal:
It is the courage to continue that counts”

Winston Churchill



Useful background: Perform a focused physical examination for causes of disorder of ventilation

- Hypoventilation (hypercapnic respiratory failure)

- Hyperventilation

➤ CNS/Cord

- Respiratory centre depression
- Anxiety
- Raised intracranial pressure
- Hypercapnia
- Brainstem injury
- Spinal cord and peripheral nervous system
- Lesion at C3 to C5
- Neuropathy
- Amyotrophic lateral sclerosis
- Post-paralytic condition
- Atrophy
- Overuse fatigue

➤ Drugs

- Causing ↓ cardiac output
- Steroids
- Aminoglycosides

➤ Lung

- Respiratory muscle disease
- Limited thoracic movement
- Kyphoscoliosis
- Elevated diaphragm, emphysema
- Limited lung movement
- Pleural effusion
- Pneumothorax
- Lung disease
- Obstruction in upper or lower respiratory tract
- Atelectasis, pneumonia
- Trauma

➤ CNS

- Anxiety, hysteria, pain
- CNS lesions: meningitis, encephalitis, trauma, CVA

➤ Drugs

- Salicylates, analeptics, adrenaline

➤ Lung

- Pulmonary reflexes: irritant gases, atelectasis, pneumothorax
- Artificial ventilation



- Hypoventilation (hypercapnic respiratory failure)
 - Hyperventilation
-
- Metabolic
 - Hypothyroidism
 - Metabolic alkalosis
 - Acidosis
 - Malnutrition
 - Muscle disease
 - Muscular dysfunction
 - Muscular dystrophies
 - Guillain-Barre syndrome
 - Myasthenia gravis
- Metabolic
 - Hyperthyroidism
 - Increased metabolism: hyperthyroidism, fever
 - Anoxia
 - Metabolic acidosis
 - Hypotension

Adapted from: Ghosh AK. *Mayo Clinic Scientific Press* 2008, Table 4-8, page 154 and Table 4.14 and 4.15, page 159; Burton JL. *Churchill Livingstone* 1971, page 24.

Deep vein thrombosis

Note that a number of historical features are not given points for the calculation of the wells score for DVT; these include:

- Stasis – immobilization, right-sided heart failure, obstruction, shock
- Hypercoagulability, estrogen use, pregnancy, neoplasms, tissue trauma, nephritic syndrome, deficiency of antithrombin III, protein C or S
- Endothelial damage – venulitis, trauma
- Symptoms suggesting pulmonary emboli (dyspnea, pleuritic chest pain, and hemoptysis)

| Pretest probability | Sensitivity (%) | Specificity (%) | Positive LR | Probability of DVT (%) |
|---------------------|-----------------|-----------------|-------------|------------------------|
| ➤ Low (0) | 2-21 | 36-77 | 0.2 | 5 |
| ➤ Moderate (1-2) | 13-39 | ... | NS | 17 |
| ➤ High (≥ 3) | 38-87 | 71-96 | 5.2 | 53 |

Abbreviation: NS, not significant.

Adapted from: Hauser SC, et al. *Mayo clinic Gastroenterology and Hepatology Board Review. 3rd Review*, page 617; Simel, DL, et al. *JAMA* 2009, Table 18-14, page 246.



Useful background: Likelihood ratios for pulmonary embolus for the combination of clinical probability estimate with the D- dimer result

| Clinical probability | D-dimer | |
|------------------------------------|----------|-----|
| ➤ Any probability | Abnormal | 1.7 |
| ➤ Low (<15%) to moderate (15%-35%) | Normal | 0 |

CI, confidence interval; LR, likelihood ratio

Source: Simel, DL, et al. *JAMA* 2009, Table 43-3, page 575

- Take a directed history and perform a focused physical examination to determine the possible presence of a deep vein thrombosis (DVT).

Wells Scoring Scheme for pretest probability of deep vein thrombosis

| Clinical Feature | Points |
|--|--------|
| ➤ Risk factors | |
| ○ Active cancer | 1 |
| ○ Paralysis, paresis or recent plaster immobilization of the lower extremities | 1 |
| ○ Recently bedridden > 3 days or major surgery within 4 weeks | 1 |
| ➤ Signs | |
| ○ Localized tenderness along the distribution of the deep venous system | 1 |
| ○ Entire leg swollen | 1 |
| ○ Asymmetric calf swelling (>3 cm difference, 10 cm below tibial tuberosity) | 1 |
| ○ Asymmetric pitting edema | 1 |
| ○ Collateral superficial veins (nonvaricose) | 1 |
| ➤ Alternative diagnosis | |
| ○ Alternative diagnosis as likely or more likely than deep venous thrombosis | -2 |
| <hr/> | |
| Total | |

*Interpretation of score: High probability if 3 points or more, moderate probability if 1 or 2 points and low probability if 0 points or less.

Source: Hauser SC, et al. *Mayo Clinic Gastroenterology and Hepatology Board Review. 3rd Review*, page 617.



Useful background: Simplified Wells Scoring System

| Findings in the simplified Wells Scoring system | Score |
|---|-------|
| ➤ Clinical signs/symptoms of DVT of the leg (minimum of leg swelling and pain with palpation of the deep veins) | 3.0 |
| ➤ No alternate diagnosis that is as likely as or more likely than a pulmonary embolus | 3.0 |
| ➤ Heart rate > 100/min | 1.5 |
| ➤ Immobilization or surgery in the last 4 weeks | 1.5 |
| ➤ History of DVT or PE | 1.5 |
| ➤ Hemoptysis | 1.0 |
| ➤ Cancer actively treated in the past 6 months | 1.0 |

Abbreviations: DVT, Deep Vein thrombosis; PE, pulmonary embolism
 Category scores determined by the sum of the individual scores: low, <2; moderate, 2-6; high, >6.

Source: Simel DL, et al. *JAMA* 2009 Chapter 43, Table 43-12, page 575.

Useful background: Probability of deep vein thrombosis after first determining the clinical probability and then obtaining the D dimer result

| Clinical probability estimates ^a | | Probability of DVT after applying D dimer Result to the clinical probability estimate, % | | |
|---|----------|--|-----------------------------|-----------------------|
| | | High probability (~50%) | Moderate Probability (~20%) | Low probability (~5%) |
| ➤ High sensitivity D-dimer | Positive | 63 | 25 | 11 |
| | Negative | 8.6 | 1 | 0.5 |
| ➤ Moderate sensitivity D-dimer | Positive | 67 | 34 | 17 |
| | Negative | 19 | 4.4 | 0.9 |

Abbreviation: DVT, Deep vein thrombosis

a Values in the Table use the exact summary pretest probability estimates, but a clinician might simplify by remembering that a high probability is about 50%, moderate probability 20% and low probability 5%.

Source: Simel DL, et al. *JAMA* 2009, Table 18-15, page 246.



Pulmonary Embolism

Useful background: ECG changes in pulmonary embolism. These include:

- Sinus tachycardia
- Tall R wave in lead VI
- S1, S2, S3 syndrome (S waves in limb leads I, II and III)
- S1, Q3, T3 syndrome (S in limb lead I and Q wave and inverted T wave in limb lead III)

Source: Baliga RR. *Saunders/Elsevier* 2007, page 257.

Useful background: ventilation – perfusion scan

| | Ventilation | Perfusion |
|-------------|-------------|-----------|
| ○ PE | N | ↓ |
| ○ Pneumonia | ↓ | ↓ |

Abbreviation: PE, pulmonary embolus; N, normal

Useful background: Modified Wells criteria for pre test probability of pulmonary embolism

| Clinical feature | Points |
|--|--------|
| ➤ Clinical symptoms of DVT | 3.0 |
| ➤ Other diagnosis less likely than PE | 3.0 |
| ➤ Heart rate > 100 | 1.5 |
| ➤ Immobilization > 3 days or surgery in past 4 weeks | 1.5 |
| ➤ Previous PE or DVT | 1.5 |
| ➤ Hemoptysis | 1.0 |
| ➤ Malignancy (current or recent) | 1.0 |
| | Total |

| Interpretation: Score | Probability of PE |
|-----------------------|-------------------|
| >6.0 | High |
| 2-6 | Moderate |
| <2.0 | Low |

Source: Likelihood of Pulmonary embolism according to scan category and clinical probability in PIOPED study *JAMA* 1990; 263:2753



| Simplified clinical model | Score |
|---|-------|
| ○ Active cancer (treatment ongoing or within previous 6 months or palliative) | 1 |
| ○ Paralysis, paresis, or recent plantar immobilization of lower extremity | 1 |
| ○ Recently bedridden for >3 days or major surgery within 4 weeks | 1 |
| ○ Localized tenderness along the distribution of the deep venous system | 1 |
| ○ Entire leg swelling | 1 |
| ○ Calf swelling >3cm, compared to other calf (10cm below tibial tuberosity) | 1 |
| ○ Pitting edema (greater in symptomatic leg) | 1 |
| ○ Collateral superficial veins (nonvaricose) | 1 |
| ○ Alternate diagnosis as likely or greater than DVT | -2 |
| | Total |

Useful background: EBM- carotid artery stenosis and deep vein thrombosis

- Gold standard for diagnosing DVT is venography, however it is invasive. Compression ultrasonography is highly sensitive, specific for detecting proximal DVTs and is less invasive.
- A simplified clinical model was generated to stratify individuals into pre test categories of low (score <0), moderate (score 1-2), or high risk (score >3) for DVT. Combining this with compression ultrasonography determined positive likelihood ratios.
- In patients with TIA, a carotid bruit indicated the presence of a >50% stenosis of the carotid artery (confirmed by carotid angiography) with 29% sensitivity and 88% specificity.

Source: Likelihood of Pulmonary embolism according to scan category and clinical probability in PIOPED study *JAMA* 1990; 263:2753.

Useful background: Hypoxemic respiratory failure

- Effective gas exchange requires adequate alveolar ventilation for the elimination of carbon dioxide, oxygen uptake across the alveolar-capillary membrane, and the delivery of oxygen to tissues.
- *Hypoxemia* may result from the following:
 - Decrease in the inspired partial pressure of oxygen (e.g., at high altitude, including air travel or interruption of oxygen supply)
 - Hypoventilation



- Ventilation-perfusion (V/Q) mismatch
- Shunt
- Diffusion barrier
- Hypoxemia due to hypoventilation is characterized by an increased PaCO₂, decreased PaO₂, and a normal A-a gradient. (estimation of the alveolar-arterial [A-a] gradient for oxygen is essential in analyzing the cause of hypoxemia)

Source: Ghosh AK. *Mayo Clinic Scientific Press* 2008, Table 4-7, page 153.

Pneumothorax

- Take a focused history for the causes of pneumothorax.
- Traumatic
- Iatrogenic
 - Thoracentesis, thoracic surgery
 - Artificial pneumothorax
 - Cervical surgery, stellate block etc
- Spontaneous
 - Localized air space disorder
 - Congenital bullae
 - Localized emphysema
 - Acquired cysts, etc
 - Generalized emphysema
 - Secondary to specific lung disease
 - Congenital
 - COPD (emphysematous bulla)
 - Diffuse cystic disease (CF)
 - Bronchiectasis; eosinophilic granuloma; tuberose sclerosis,
 - Silicosis
 - Infection
 - TB
 - Lung abscess
 - Malignancy
 - Hydatid cysts
 - Secondary to spontaneous mediastinal emphysema
 - Asthma
 - Labour
 - Straining at stool
 - Rapid decompression of divers



- Associated with menstruation
 - Endometriosis

Adapted from: Burton JL. *Churchill Livingstone* 1971, page 32; Baliga RR. *Saunders/Elsevier* 2007, page 287.

Lung abscess

- Take a focused history for the causes of lung abscess.
 - Aspiration
 - CNS
 - Coma, anesthesia, alcoholic debauch
 - Mouth
 - Oral or pharyngeal sepsis
 - Pharyngeal pouch
 - Esophageal obstruction, trachesophageal fistula
 - Drowning
 - Foreign body
 - Lung disease
 - Infection
 - TB
 - Straphylococcal
 - Friedlander's (klebsiella)
 - Actinomycosis
 - Entameba histolytica, and other fungi
 - Secondary infection of pulmonary infarct
 - Septic emboli due to pyemia
 - Parasites, eg schistosomiasis
 - Infiltration
 - Necrotic bronchial carcinoma
 - Benign tumor
 - Ideopathic
 - Pulmonary fibrosis (interstitial lung disease)
 - Inherited/ aquired cysts
 - Miscellaneous
 - Arteritis
 - Mucoviscidosis

Adapted from: Burton JL. *Churchill Livingstone* 1971, page 30.



Bronchiectasis

Useful background: Diseases associated with bronchiectasis

General clinical features

- Cystic fibrosis
 - Due to malfunction of the gene coding for the CF transmembrane conductance regulator (CFTR) protein. Usually diagnosed at a young age
 - Lung disease often dominates the clinical pictures.
 - Malabsorption very common; cirrhosis, azoospermia, etc

- Kartageners syndrome
 - Due to mutation in gene coding for dynein protein
 - Ciliary dysmotility, resulting in sinusitis, situs inversus, infertility in men

- Young's syndrome
 - Triad of bronchiectasis, rhinosinusitis and decreased fertility (obstructive azoospermia) due to abnormally viscous mucus

- Immune defects
 - IgA deficiency: repeated respiratory tract infections, 25% develop autoimmune conditions (e.g. RA, SLE, celiac disease) IgM deficiency
 - Recurrent infancy/childhood infections with encapsulated organisms. Later on, autoimmune illnesses and malignancy

- Allergic bronchopulmonary aspergillosis (ABPA)
 - Usually complicates long standing asthma, leading to worsening of asthma symptoms
 - Transient pulmonary infiltrates on CXR
 - Often with eosinophilia

- Rheumatoid arthritis
 - Bronchiectasis can occur before overt arthritis, though more common during overt RA

- Alpha-1 antitrypsin deficiency
 - Chest disease, especially in smokers, at a young age.
 - Symptomatic liver disease (cirrhosis) occurs at a young age

- Marfan's syndrome
 - Family history of premature sudden cardiac death, due to aortic dissection
 - Aortic root enlargement; dissection
 - Tall, joint hypermobility, lens dislocation

Permission granted: Davey P. *Wiley-Blackwell* 2006, page 195.



! Trick Question !

Q. When bronchiectasis is caused by fibrosis from previous TB, in which lobes does the recurrent pneumonia usually occur?

A. Upper lobes

SO YOU WANT TO BE A RESPIROLOGIST, OR A CARDIOLOGIST!

Q. Your patient has rhonchi and prolonged expiration, and you suspect bronchitis, but the chest X-ray is abnormal. What conditions are likely associated with her/ his bronchitis?

- A.
- Emphysema
 - Bronchiectasis
 - Pleural thickening

Extrinsic allergic alveolitis (hypersensitivity pneumonitis)

Useful background: Causes of pulmonary eosinophilia and vasculitis

- Lung
 - Asthma
 - ABPA
 - Chronic eosinophilic pneumonia
- Drugs
- Infection
 - Parasites
 - Loffler's Syndrome (eosinophilia transient CXR infiltrate lasting 4-6 weeks, often related to bugs, parasites or worms)
- Connective tissue disorders

Abbreviations: ABPA, Allergic bronchopulmonary aspergillosis; CXR, Chest x-ray

Adapted from: Davey P. *Wiley-Blackwell* 2006, page 204.



Useful background

- Distinguishing between acute and chronic extrinsic allergic alveolitis (EAA)

| | Acute | Chronic |
|-----------------------|------------------------------|-----------------|
| ➤ WBC, ESR | ○ Ground glass | ○ May be normal |
| ➤ Chest x ray | ○ Multiple nodules | ○ Fibrosis |
| ➤ CT chest | | ○ Fibrosis |
| ➤ ABG | ○ Type 1 respiratory failure | |
| ➤ Lung function tests | ○ Restrictive defect | ○ 50-60% |
| ➤ Steroid response | ○ 80-90% | ○ Very poor |
| ➤ Prognosis | ○ Very good | ○ Poor |

Abbreviations: ABG, Arterial blood gases; EAA, Extrinsic allergic alveolitis

Source: Davey P. *Wiley-Blackwell*, 2006, page 200.

- Pulmonary eosinophilic disorders
- Löffler's syndromes
- Transient pulmonary infiltrates
 - Peripheral eosinophilia
 - Associated with parasitic infections, drug allergies and exposure to inorganic chemicals (such as nickel carbonyl)
- Course is benign and respiratory failure almost unknown
- Eosinophilia in asthmatics
 - The most common cause is allergic bronchopulmonary aspergillosis
- Tropical eosinophilia which is secondary to filarial infection (*Wuchereria bancrofti* or *W. malayi Brug*)
- Churg Strauss syndrome
 - Diagnosis requires four of the following features
 - Asthma
 - Eosinophilia greater than 10%
 - Mononeuropathy or polyneuropathy
 - Paranasal sinus abnormality
 - Non-fixed pulmonary infiltrates visible on chest x-ray
 - Blood vessels with extravascular eosinophils found on biopsy



Chronic eosinophilia pneumonia

- Chronic debilitating illness characterised by malaise, fever, weight loss and dyspnea. The chest radiograph shows a peripheral alveolar filling infiltrate predominantly in the upper lobes (the graphic negative of pulmonary edema)

Source: Baliga RR. *Saunders/Elsevier* 2007, page 273.

Useful background: Causes of Fibrosing alveolitis

- Primary
- Secondary
 - Rheumatoid arthritis
 - Systemic lupus erythematosus
 - Scleroderma
 - Dermatomyositis
 - Chronic extrinsic allergic alveolitis

Source: Davey P. *Wiley-Blackwell* 2006, page 202.

Useful background: Investigations to distinguish between acute and chronic Fibrosing Alveolitis

| | Acute | Chronic |
|-----------------------------|----------------------|--|
| ➤ Lung function test defect | ○ Restrictive defect | ○ Restrictive defect |
| ➤ Chest x ray | ○ Ground glass | ○ Honey comb |
| ➤ CT scan | ○ 'Alveolitis' | ○ 'fibrosis' |
| ➤ ABG | ○ Type 1 failure | ○ Early: normal at rest, ↓ pO ₂ on exercise |
| ➤ RF/ANA | | ○ Late: type I failure |
| | | ○ 30-50% |

Abbreviations: RF/ANA, Rheumatoid factor/antinuclear antibody; ABG, arterial blood gases

Source: Davey P. *Wiley-Blackwell* 2006, page 202.



- Take a directed history and perform a focused physical examination for fibrosing alveolitis.
- History
 - Progressive exertional dyspnea (90%)
 - Chronic cough (74%)
 - Arthralgia/ arthritis (19%)
 - Obtain a drug history (amiodarone, nitrofurantoin and busulfan)
- Physical examination
 - Chest
 - Bilateral, basal, fine, end-inspiratory crackles which disappear or become quieter on leaning forwards
 - The “velco-like” crackles do not disappear on coughing (unlike those of pulmonary edema)
 - Tachypnea (in advanced cases)
 - Hands (for rheumatoid arthritis, systemic sclerosis) - Clubbing
 - Face (for typical rash of SLE, heliotropic rash of dermatomyositis, typical facies of systemic sclerosis, lupus pernio of sarcoid)
 - Central cyanosis
 - Mouth (for aphthous ulcers of Crohn disease, dry mouth of Sjögren’s syndrome)
 - CVS
 - Signs of pulmonary hypertension: ‘a’ wave in the JVP, left parasternal heave and P₂
 - Examine patient for conditions which have similar pulmonary changes
 - Rheumatoid arthritis, SLE, dermatomyositis, chronic active hepatitis, ulcerative colitis, systemic sclerosis
 - Pneumoconiosis
 - Granulomatous disease; sarcoid, TB
 - Chronic pulmonary edema
 - Radiotherapy
 - Lymphangitis carcinomatosa
 - Extrinsic allergic alveolitis: farmer’s lung, bird fancier’s lung

Adapted from: Baliga RR. *Saunders/Elsevier* 2007, page 281; McGee SR. *Saunders/Elsevier* 2007, Box 27-2.



Useful background: Causes of pulmonary eosinophilia

| Disease | Investigations |
|------------------------------|---|
| ➤ Eosinophilic pneumonia | <ul style="list-style-type: none"> ○ Segmental bilateral peripheral ground glass infiltrates on CT ○ Restrictive lung function |
| ➤ Hypereosinophilic syndrome | <ul style="list-style-type: none"> ○ Eosinophilia $<20 \times 10^9/L$ ○ Pulmonary infiltrates and effusions ○ Myocardial infiltration and CHF |
| ➤ Churg-Strauss syndrome | <ul style="list-style-type: none"> ○ \uparrow IgE ○ pANCA (positive in 50%) ○ Pulmonary infiltrates ○ Pleural effusion ○ Vasculitis on biopsy (multisystem disease) |

Adapted from: Davey P. *Wiley-Blackwell* 2006, page 204.

- Take a focused history and perform a focused physical examination for obstructive sleep apnea (aka Pickwickian Syndrome).
 - General
 - Daytime fatigue
 - Headache, particularly in the morning
 - Poor quality of life
 - Sleep
 - Daytime somnolence
 - Unrefreshing sleep
 - Snoring
 - CNS
 - Poor concentration
 - Lung
 - Shortness of breath
 - GI
 - Gastroesophageal reflux disease
 - Feet
 - Swelling of feet



- Family history
 - Family history of obesity
- Physical examination
 - Habitus
 - Head and neck
 - Lung
 - CVS
 - R-CHF
 - Pulmonary hypertension
 - Systemic hypertension

Adapted from: Baliga RR. *Saunders/Elsevier* 2007, pages 290 and 291.

Chest X-ray

Useful background: Chest X-ray

- Features that differentiate between the left and right hemidiaphragms in a lateral film
 - The right hemidiaphragm is usually higher than the left
 - The left hemidiaphragm is silhouetted out by the heart
 - The gastric air bubble is below the left hemidiaphragm
 - The right ribs are usually magnified since they are farther away from the film than the left ribs, so the right hemidiaphragm is the hemidiaphragm that meets the right ribs.
- An apical lordotic view is useful when the right clavicle and first rib hinder visualization on the PA film
 - Air-space disease
 - A pathological process affecting primarily the alveoli.
 - The radiological findings are Acinar shadows; air bronchograms; silhouette sign
 - Fluid (e.g., pulmonary edema); pus (e.g., pneumonia); cells (e.g., lung cancer); blood (e.g., hemorrhage); proteins (e.g., alveolar proteinosis)
 - Interstitial lung disease
 - A pathological process affecting primarily the interstitium of the lung. The radiological findings include a reticular pattern (net-like), a nodular pattern (nodules), or both
 - A differential diagnosis includes Pulmonary edema; military tuberculosis; pneumoconiosis; sarcoidosis

Adapted from: Jugovic PJ, et al. *Saunders/ Elsevier* 2004, pages 199 to 202.



Silhouette sign (actually, the “loss of silhouette”)

- The loss of normally appearing interfaces
- Causes
 - RML consolidation – loss of right heart border
 - Lingula consolidation – loss of left heart border
 - Anterior segment of left upper lobe – loss of aortic arch

Source: Jugovic PJ, et al. *Saunders/ Elsevier* 2004, page 201.

- What is the typical pulmonary lobe in which disease occurs?
 - Upper – TB
 - Lower – bronchiectasis
 - Bilateral, symmetrical - pneumoconiosis

Useful background: Systematic approach to reading a PA and lateral chest x-ray

- General
 - Date, name, age, sex
 - State types of studies PA and lateral
 - Obtain previous films for comparison
 - Quality of film
 - rotation
 - exposure
 - inspiration
 - any obvious abnormalities
- Bones and joints (fractures, arthritis)
 - Anterior and posterior ribs
 - Vertebral column
 - Clavicles
 - Scapulae
- Soft tissues (calcifications, subcutaneous emphysema)
 - Axillae
 - Breast shadows (e.g., mastectomy)
 - Pleura
 - Major and minor fissures
 - Costovertebral angles
- Diaphragm
 - Level
 - Right and left hemidiaphragm
 - Abdominal free air
- Heart
 - Size (shouldn't be > 50% the size of the cardiothoracic ratio)
 - Calcifications
 - Atrial/ventricular enlargement



- Mediastinum
 - Position of trachea, aortic arch, right heart border
- Hila
 - Size
 - Compare right and left hilum
 - Upward/downward displacement
- Lung parenchyma
 - Nodules
 - Parenchymal density
 - Vascular abnormalities (e.g., redistribution)
- Abdomen
 - Free air
 - Gastric air bubble

Adapted form: Jugovic PJ, et al. *Saunders/ Elsevier* 2004, pages 199 to 202.

- Give the typical signs of hyperinflation seen on chest X-ray.
 - Lung fields – hyperlucent
 - AP chest diameter - ↑
 - Retrosternal translucent area - ↑
 - Diaphragms
 - Low
 - Flat
 - ↓ movement on ins-/ expiration
 - Pulmonary vessels – splaying (↑ angles of bifurcation)
 - Bronchi – “tram lines” because of contrast with areas of hyperinflation

Remember, the physical examination for lung collapse and fibrosis are the same. But, the chest X-ray findings are different. How?

| | Fibrosis | Collapse |
|-------------------------------------|--------------------|----------|
| ➤ Distribution | Lobar or segmental | |
| ➤ Homogeneous opacification | No | Yes |
| ➤ Mediastinal shift | Yes | Yes |
| ➤ Crowding of ribs on affected side | Yes | Yes |
| ➤ Multiple cavities | Yes | Yes |



- Give the distinction between pulmonary fibrosis (PF) vs collapse (C) on a chest X-ray.

| | PF | C |
|---------------------------------|------------------|-----|
| ○ Homogeneous | No | Yes |
| ○ Distribution | Lobar/ segmental | |
| ○ Shift of mediastinum | Yes | No |
| ○ Crowded ribs on affected side | Yes | No |
| ○ Multiple cavities | Yes | No |

- Give the chest X-ray findings of each of the following

➤ Silicosis

- Nodules
 - Well – defined
 - Concentric layers of fibrosis
- Reticulation (nodules plus reticulation gives a stellate appearance)
- Pleural fibrosis
- Bullus/ focal emphysema
- Lymphadenopathy
- Changes of associated – TB
- Changes of associated – pneumoconiosis

➤ Pneumoconiosis

- Poorly defined nodules
- Focal emphysema
- Upper zone nodules coalesce to form
- Progressive massive fibrosis (PMF)
- Cor pulmonale is commonly associated
- Silicosis also commonly associated
- No bullous emphysema
- No lymph node enlargement
- Coplan's syndrome – in men who already have or will in the future develop rheumatoid arthritis, the chest X-ray of pneumoconiosis may be atypical

➤ Asbestosis

- Lung lower lobes
 - Fine mottling
 - Diffuse changes
- Pleura/ pericardium
 - Thickening (plaques)
 - Fuzzy outline
- Associated
 - Mesothelioma
 - Adenocarcinoma, peripheral



Give 15 causes of mediastinal tumors seen on chest X-ray

- Esophagus
 - Hiatus hernia
 - Corkscrew esophagus (congenital elongation)
 - Achalasia
 - Enterogenous cyst
 - Neoplasm
- Aorta
 - Unfolding
 - Aneurysm
 - Coarctation
- Retrosternal goiter
- Thymoma
- Lymphadenopathy
 - Reticulosis
 - Sarcoidosis
 - Infective (especially TB)
 - Metastasis
- Lung cysts
 - Dermoid
 - Teratoma
 - Hydatid cysts
 - Bronchial cysts
- Cysts
 - Pericardial cysts
 - Cardiac aneurysm or tumour
- Miscellaneous (rare)
 - Mesothelioma
 - Lipoma
 - Sympathetic neuroma

Adapted from: Burton JL. *Churchill Livingstone* 1971, page 34.

SO YOU WANT TO BE A RESPIROLOGIST!

Q. In the context of a pleural effusion seen on a lateral chest X-ray, what is "Ellis's S-shaped line"?

A. Ellis's S-shaped line is an S-shaped line seen in the axilla of a patient with an effusion which is encapsulated or associated with air.



The “ABCs” of Reading a Chest X-Ray

- A** – airway (midline, no obvious deformities, no paratracheal masses).
- B** – bones and soft tissue (no fractures, subcutaneous emphysema).
- C** – cardiac size, silhouette, and retrocardiac density normal.
- D** – diaphragms (right above left by 1cm to 3cm, costophrenic angles sharp, diaphragmatic contrast with lung sharp).
- E** – equal volume 9count ribs, look for mediastinal shift).
- F** – fine detail (pleura and lung parenchyma).
- G** – gastric bubble (above the air bubble one shouldn't see an opacity of any more than 0.5cm width).
- H** – hilum (left normally above right by up to 3cm, no larger than a thumb), hardware (in the intensive care unit: endotracheal tube, central venous catheters).

Source: Talley NJ, et al. *Maclennan & Petty Pty Limited* 2003, page 132.

! Trick Question !

Q1. Give the most common causes of ring shadows (small translucent areas with white margins) seen on chest X-ray

- A1.
- Bullae
 - Cavities
 - Cysts
 - Localized pneumothorax

Q2. From a chest X-ray, how can you distinguish between the homogeneous opacity caused by a collapsed basal segment of the lung, and the heart border?

- A2.
- The border of a collapsed segment may be sharp and straight
 - The heart border follows a straight line



SO YOU WANT TO BE A PEDIATRIC RESPIROLOGIST!

Q1. In the context of an abnormal chest X-ray in a child, what is Harrison's sulcus, and what are its causes?

- A1.
- Definition – Harrison's sulcus a groove which is directed downwards and outwards over the anterior chest wall
 - Causes
 - Rickets
 - Chronic chest infection

Q2. What are the skin manifestations of sarcoidosis?

- A2.
- Small, non-scaling, skin-coloured, dome-shaped papules, usually on face and neck
 - If lesions coalesce, nodules and plaque form on the trunk and extremities

Source: Baliga RR. *Saunders/Elsevier* 2007, page 437.

Q3. In the context of deep vein thrombosis (DVT), what is Virchow triad?

- A3.
- Damage to the vessel wall
 - Trauma
 - Hypoxic blood
 - Drugs
 - Infection
 - Cholesterol
 - ↓ blood flow
 - ↑ blood coagulability

Source: Baliga RR. *Saunders/Elsevier* 2007, pages 100 and 101.

Q4. In the context of deep vein thrombosis (DVT), what is Virchow triad?

- A4.
- Damage to the vessel wall
 - Trauma
 - Hypoxic blood
 - Drugs
 - Infection
 - Cholesterol
 - ↓ blood flow
 - ↑ blood coagulability

Source: Baliga RR. *Saunders/Elsevier* 2007, pages 100 and 101.



! Trick Question !

Q1. Under what circumstances does pleural thickening become calcified?

A1. Pleural thickening becomes calcified when there is associated serous or purulent effusion.

Q2. Under what circumstances is a haze, homogenous opacity on chest X-ray have a well-defined border?

A2. When it is due to collapse, rather than pleural thickening.

Q3. In the context of a collapsed lung, what is Brock's syndrome?

A3. Brock's syndrome is a collapsed R. middle lobe due to compression of the R. middle lobe bronchus by an enlarged lymph node.

Q4. What is the difference between mottling and military mottling on a chest X-ray?

- A4.
- Mottling is multiple, discrete semi-confluent shadows, < 5 mm.
 - Military mottling is multiple, discrete, bilateral shadows, < 2 mm.

SO YOU WANT TO BE A RESPIROLOGIST!

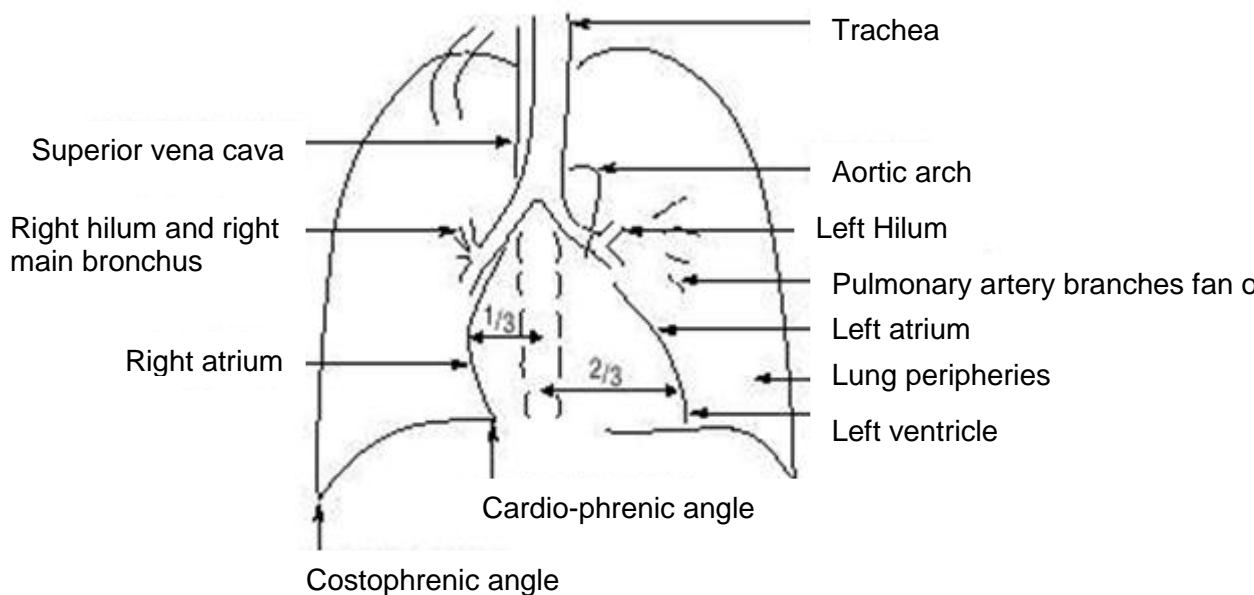
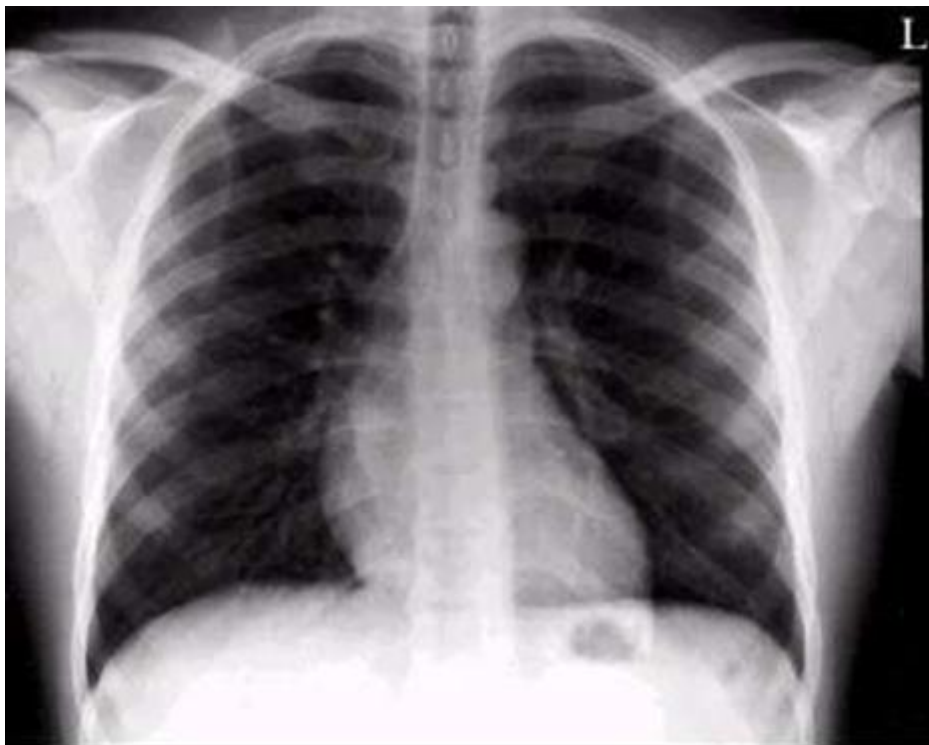
Q. What are the skin manifestations of sarcoidosis?

- A.
- Small, non-scaling, skin-coloured, dome-shaped papules, usually on face and neck
 - If lesions coalesce, nodules and plaque form on the trunk and extremities

Source: Baliga RR. *Saunders/Elsevier* 2007, page 437.



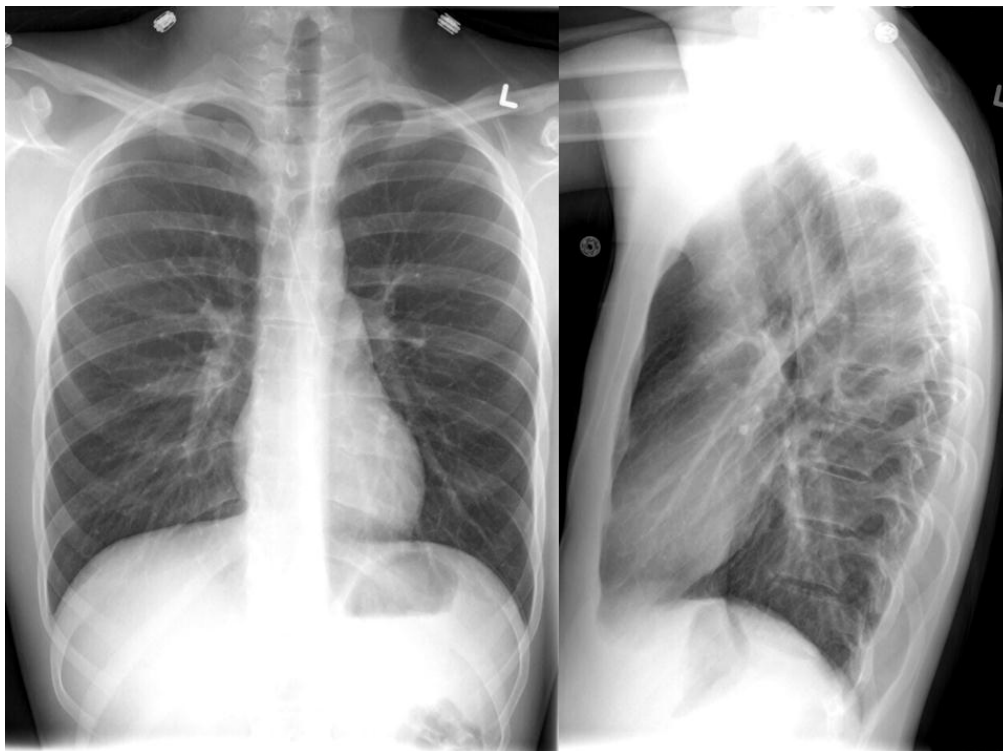Clinical Anatomy



Provided through the courtesy of: Dr. A. Leung



Useful background: An example of a normal chest x-ray (CHR)

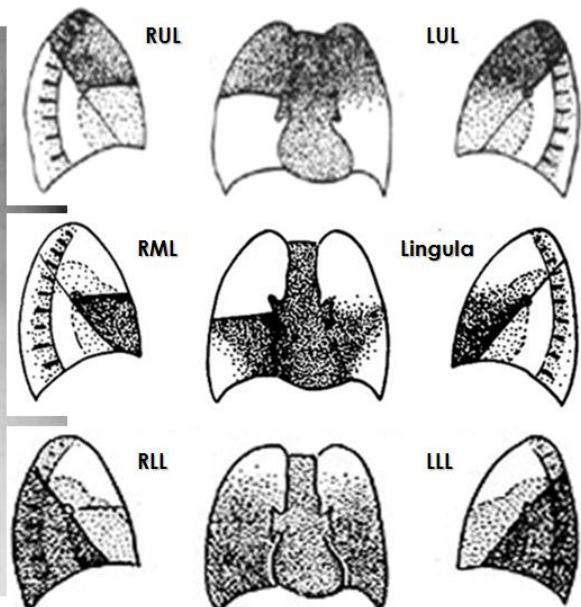
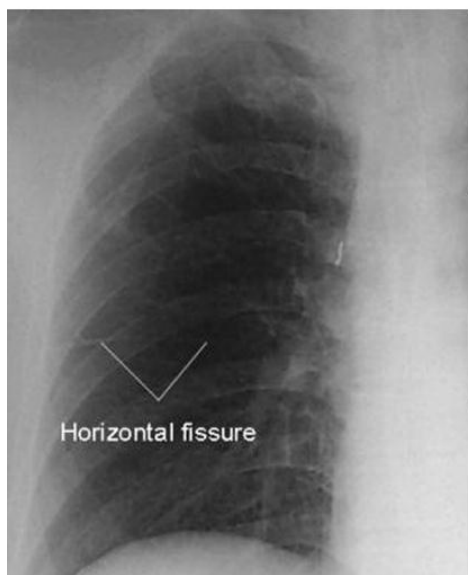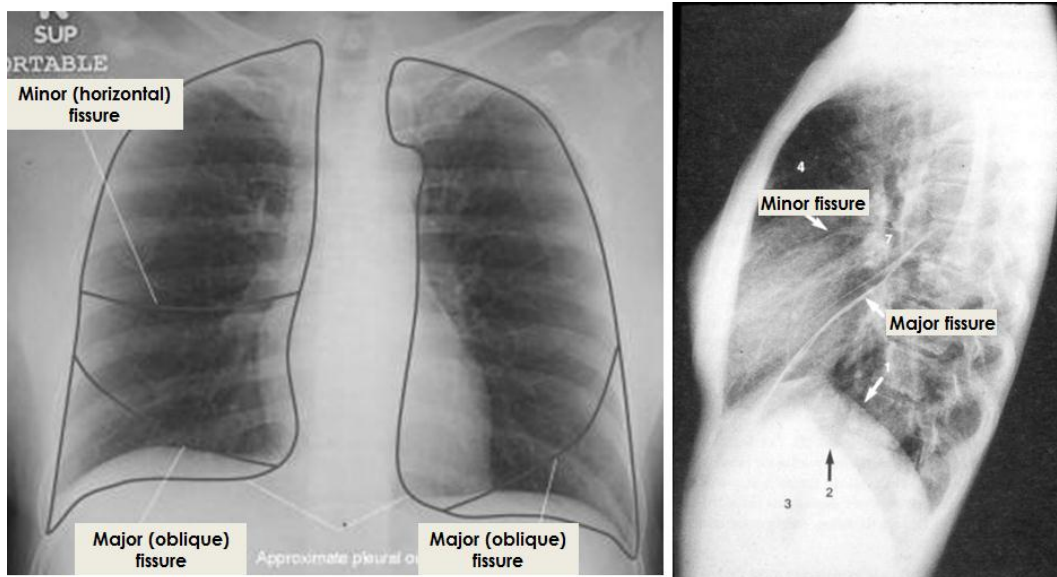


- Male patient. CXR.
- PA and lateral views.
- No date or name available.
- The film is technically adequate.
- Cardiac-thoracic ratio approximately 30%.
- No obvious cardiac chamber enlargement. Right and left hilar contours preserved.
- No obvious lymphadenopathy, vessel enlargement, or masses.
- Normal AP window.
- Contour of descending aorta normal.
- Sharp costophrenic angles.
- Lung volumes preserved with normal lung markings.
- No obvious lung lesions or consolidative changes.
- Soft tissue and bony structures normal.
- Right hemidiaphragm slightly elevated.
- Gastric bubble noted inferior to left hemidiaphragm.
- Final interpretation: normal CXR.



Useful background: lung fields on inspiration, lobes and fissures.

- Adequate inspiration - should be able to see the lung fields well: 6-8 anterior, 9-11 posterior; penetration: should be able to see the spine behind the heart.
- Pay careful attention to the pulmonary lobes and fissures



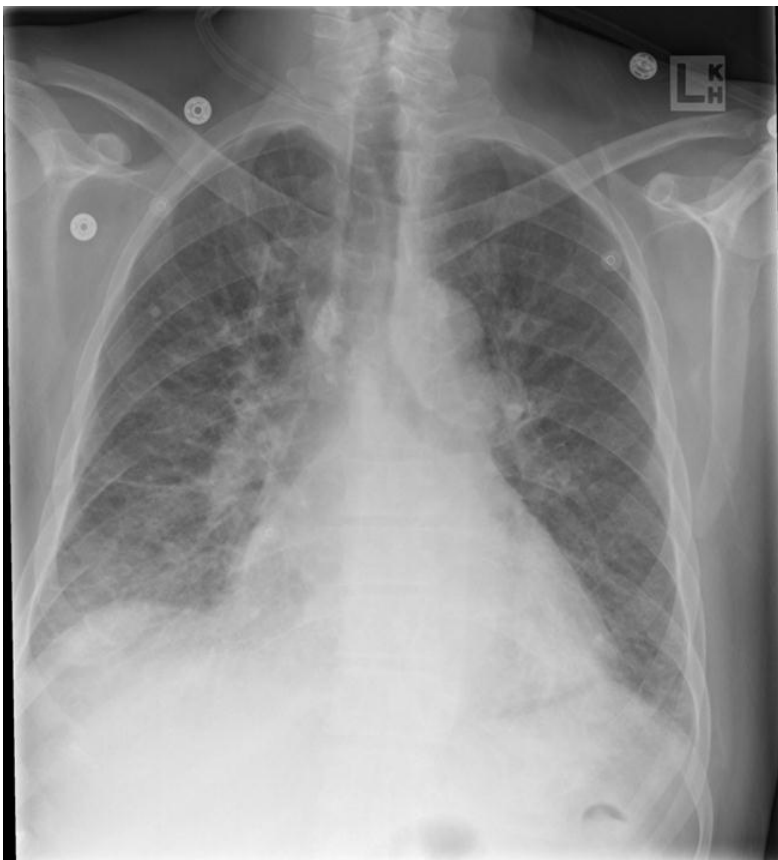Provided through the courtesy of: Dr. A. Leung



Case studies

Case one: Please describe the findings, give a differential, and state your most likely diagnosis.

- 75 year old man in ER with dyspnea



- Interstitial and airspace changes
- Cardiomegaly
- Ill-defined bronchovascular markings
- Peribronchial cuffing;
- Small pleural effusions
- Fissural fluid and thickening

Final diagnosis: pulmonary interstitial edema

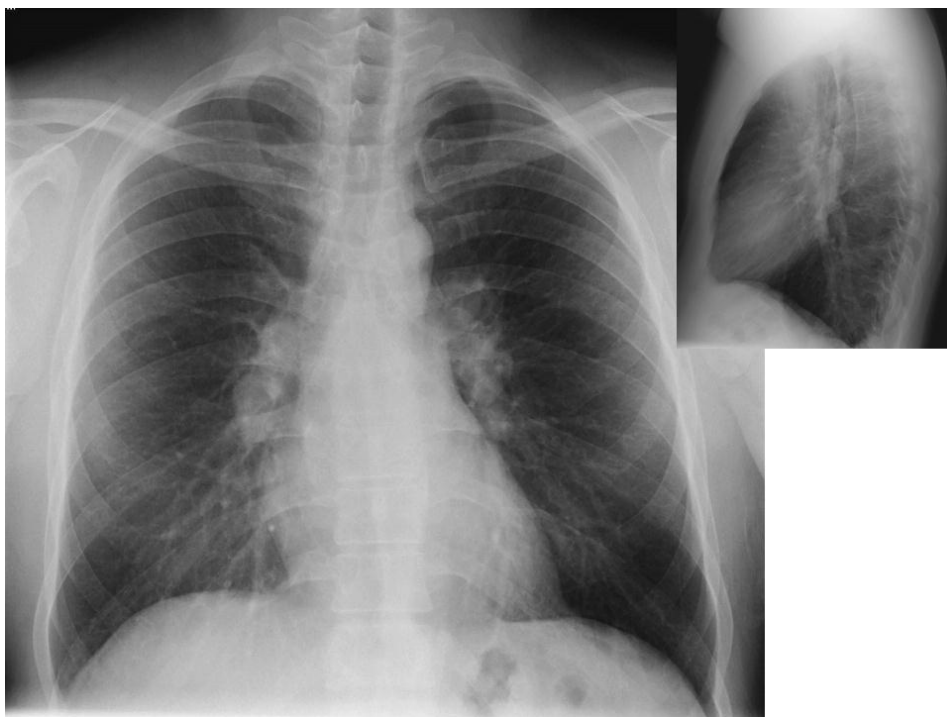

Case two: Please describe the findings, give a differential, and state your most likely diagnosis.

- Chest x-ray finding in the patient with congestive heart failure (CHF)
- Kerley B & A septal lines
- Fissure lines
- Pleural effusions
- Peribronchial cuffing
- Consolidative changes (bat-wings appearance)
- Vascular redistribution (cephalization)
- Cardiomegaly
- Ddx pulmonary edema:
 - HF, sepsis, renal failure, ARDS, lymphangitis carcinomatosa, CHF

Case three: Please describe the findings, give a differential, and state your most likely diagnosis.

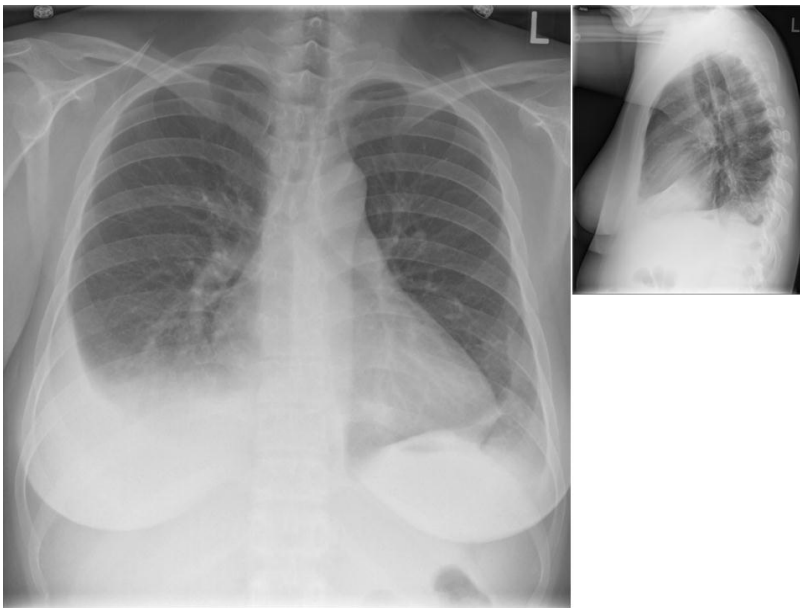- 29 year old with asthma presenting with dry cough



- Differential diagnosis of lymphadenopathy seen on chest x-ray
 - Sarcoidosis
 - TB
 - Cancer (mets and lymphoma)
 - Silicosis
 - Pulmonary hypertension

Case four: Please describe the findings, give a differential, and state your most likely diagnosis.

- 60 year old with worsening exertional dyspnea

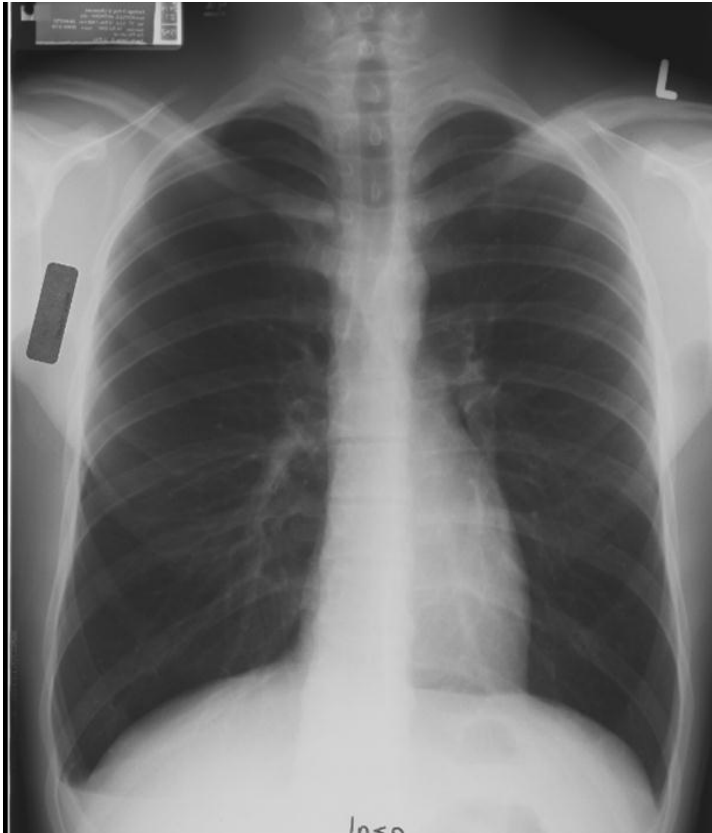


- Chest x-ray findings suggestive of pleural effusions
 - Blunted costophrenic angle
 - Opacification of diaphragm
 - Usually dependent, mobile, “meniscus” sign
 - Lateral view more sensitive
 - Supine: hazy ‘veiling’
- Differential diagnosis
 - Volume overload states (CHF, cirrhosis, renal failure)
 - Parapneumonic effusion from pneumonia
 - Infections (empyema)
 - Malignancy (especially with isolated left-sided effusions)
 - Pancreatitis
 - Hypothyroidism



Case five: Please describe the findings, give a differential, and state your most likely diagnosis.

- 17 year old with asthma presenting with sudden dyspnea

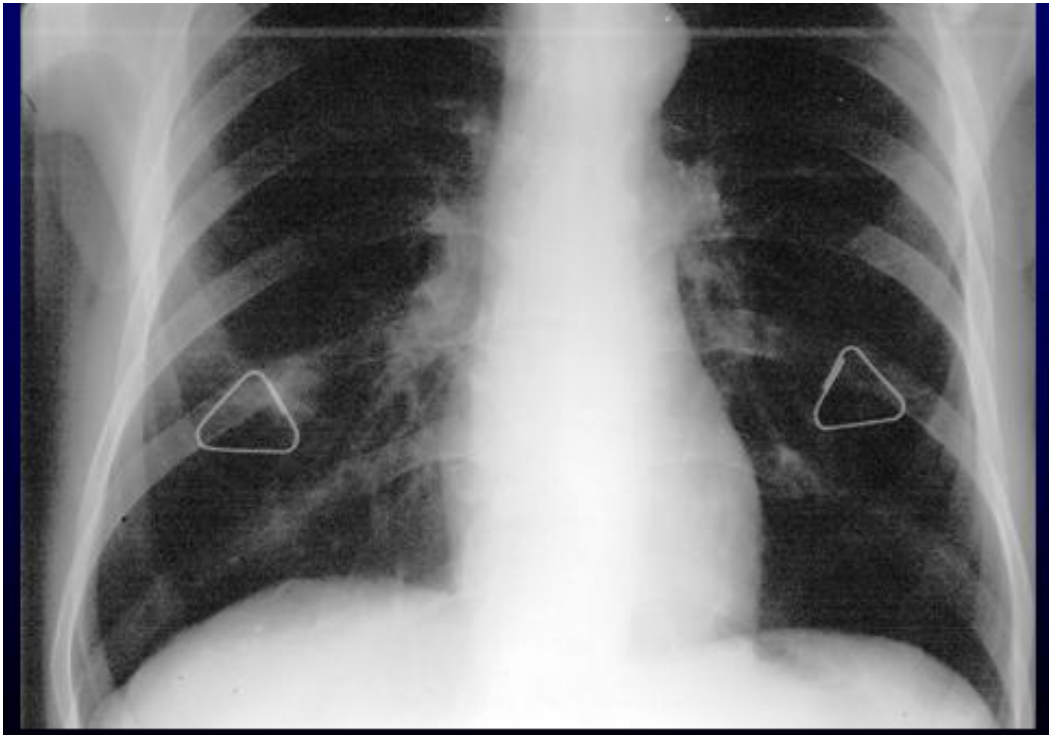


- Chest x-ray findings suggestive of pneumothorax
 - Beware the normal CHX:
 - Always suspect a pneumothorax when you're given an x-ray on an exam that initially looks normal. With your finger, draw a very careful line around the pleural edges. Look for the following:
 - Pleural reflection **line**, no lung markings beyond
 - Sign of tension: mediastinal shift
 - Pneumothoraces "pop-up" commonly on exams:
 - Young, thin & slim men with asthma...
 - Older men with a history of emphysema...
 - Mechanically ventilated patients with acute hypoxia...



Case six: Please describe the findings, give a differential, and state your most likely diagnosis.

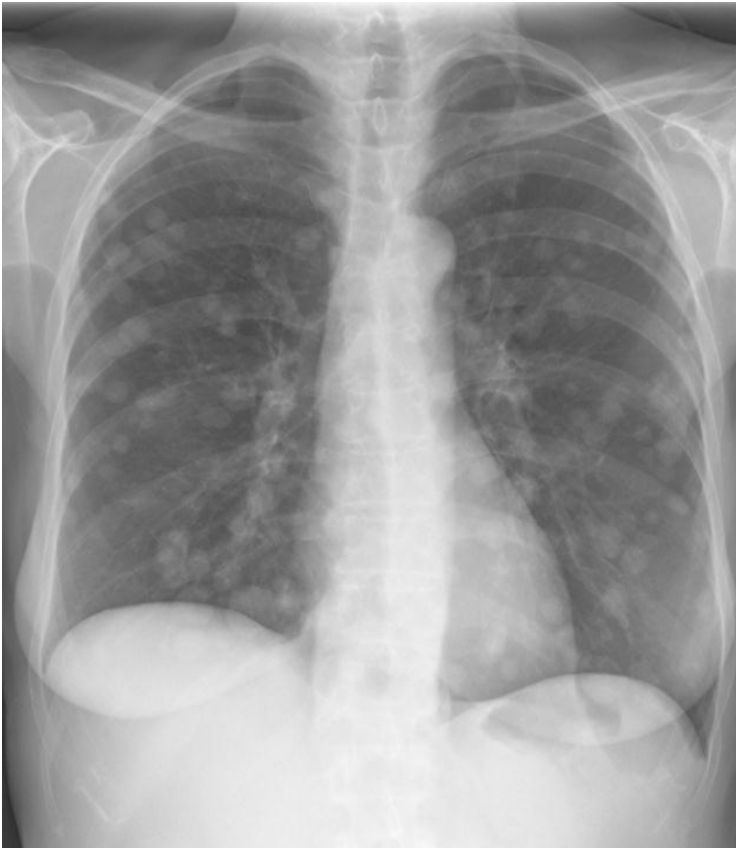- Asymptomatic 40 year old 25 pack year smoker



- Lung nodules' seen on chest x-ray
 - Size & doubling time (< 30 days or > 2 years = good)
 - Borders (round & smooth = likely good; spiculated = likely bad)
 - Cavitation (necrosis)
 - Calcification (central/complete = TB/histoplasma; popcorn = benign)
 - Vascular markings (AVM)
 - Associated lesions/lymphadenopathy/collapse
 - Nodules < 3 cm; masses \geq 3 cm in diameter



Case seven: Please describe the findings, give a differential, and state your most likely diagnosis.

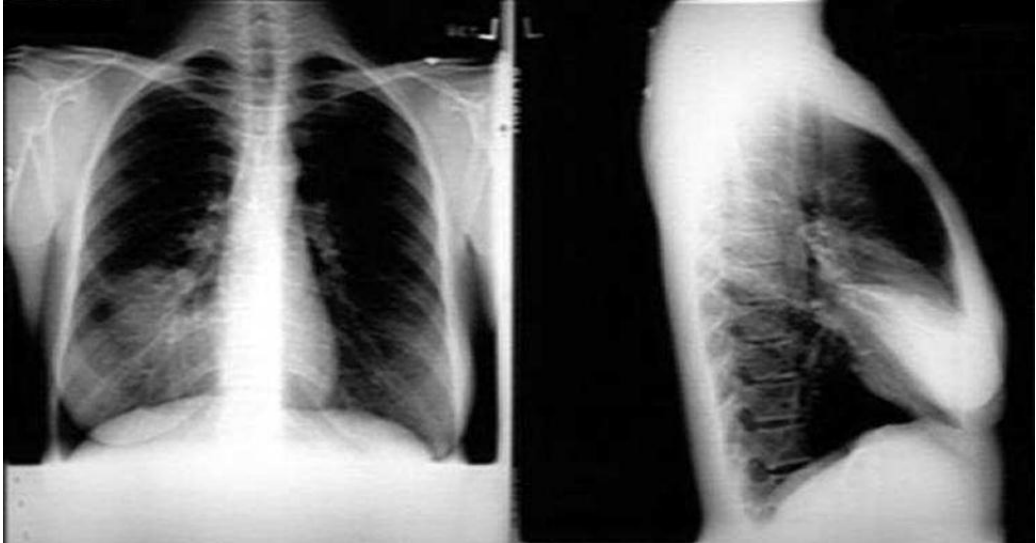


- Multiple lung nodules seen on chest x-ray
 - Neoplastic
 - Benign (hamartomas, cysts)
 - Malignant (mets, lymphoma, Kaposi's sarcoma, bronchoalveolar cancer)
 - Infectious
 - Granulomas (TB, histoplasmosis)
 - Septic emboli
 - Viral pneumonias (measles, chickenpox)
 - Non-infectious, non-malignant
 - Rheumatoid nodules
 - Sarcoid
 - Wegener's granulomatosis
 - Infarcts
 - Round atelectasis



Case eight: Please describe the findings, give a differential, and state your most likely diagnosis.

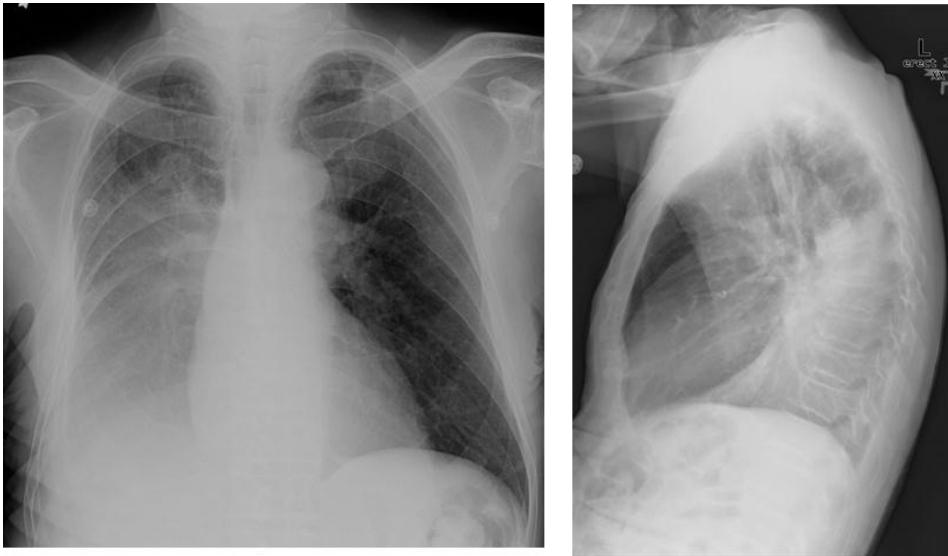- 50 year old with 3 day history of fever and chills, with productive cough



- Chest x-ray findings suggestive of right middle lobar consolidation
 - RML: abutment of major/minor fissures, silhouettes right heart border; easiest to identify on lateral view
- Differential diagnosis:
 - Infection
 - Aspiration
 - Tumor-mass
 - Tuberculosis
 - Interstitial pneumonia
 - Consolidation does not usually cause volume loss, unlike atelectasis; look at the fissure lines and surrounding structures for help (diaphragm and mediastinal structures)
 - Look for air bronchograms
- Chest x-ray findings suggestive of RML collapse
 - Right-sided volume loss
 - Hazy mid thoracic density obscuring right heart border
 - Wedge-shaped opacity on lateral film often not seen on frontal view except for volume loss with inferior displacement of minor fissure



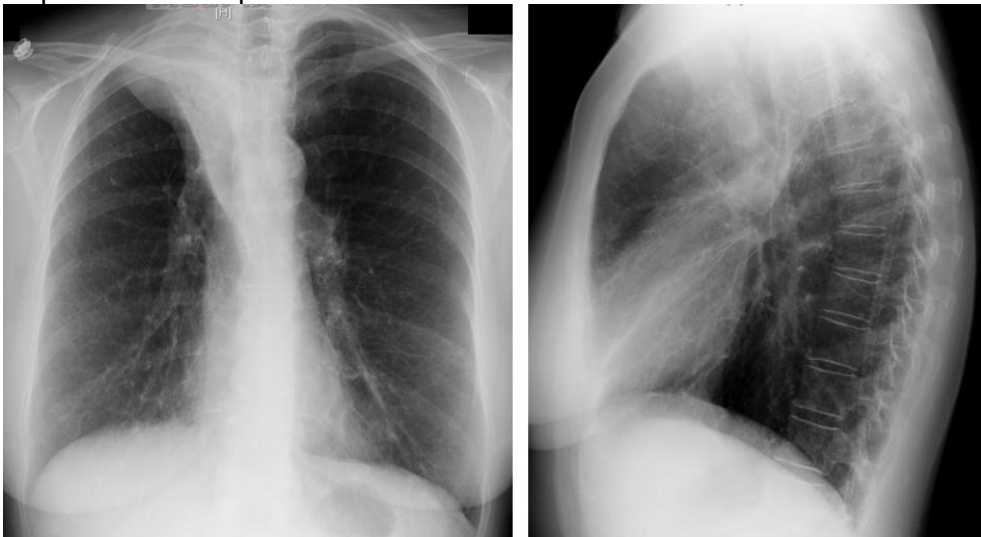➤ and worsens



- Chest x-ray findings suggestive of RLL collapse and effusion
 - Lower and posterior zone opacity
 - Posterior displacement of major fissure
 - The right heart border is not obscured
 - The medial diaphragm is obscured

Case nine: Please describe the findings, give a differential, and state your most likely diagnosis.

- 70 year old with bronchiectasis presents with cough, dyspnea and pleuretic chest pain

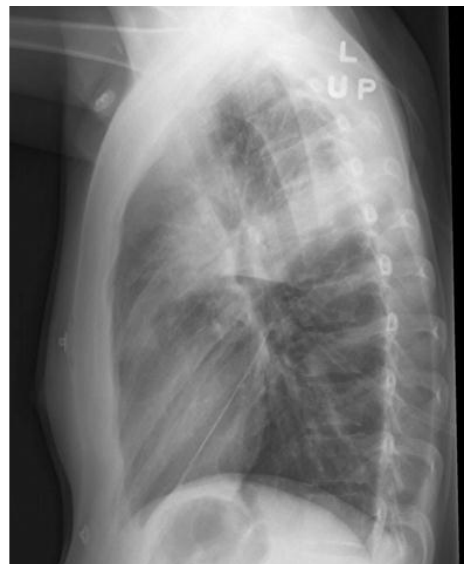
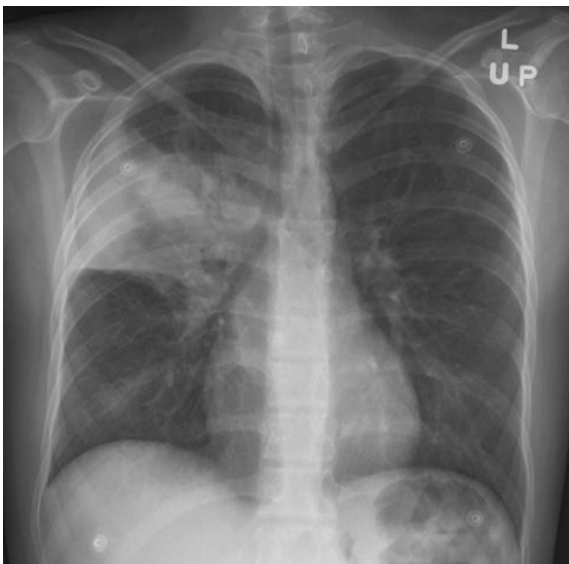

Chest x-ray findings suggestive of right upper lobar disease collapse

- Collapse
 - Elevation of minor fissure and right hilum
 - Wedge-shaped opacity at right lung apex
- Sometimes, you'll see the "Golden S sign" if there is a mass causing the RUL collapse
- Consolidation
 - Normal position of minor fissure

Case ten: Please describe the findings, give a differential, and state your most likely diagnosis.

➤ 30 year old with a 4 day history of cough and dyspnea



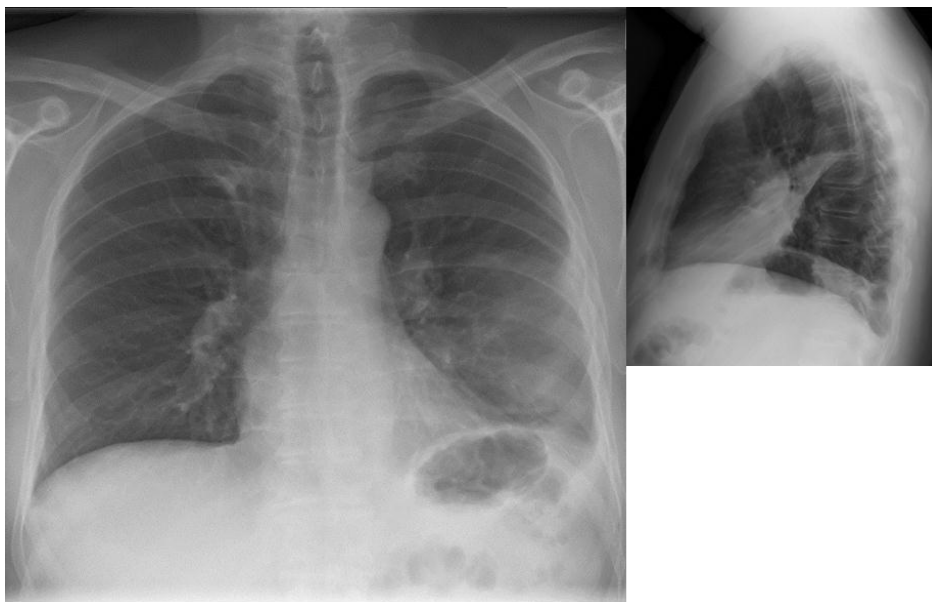
➤ Things to remember about right lobar consolidation

- RML
 - Silhouettes right heart border
 - Easiest to see on lateral view
- RLL
 - Difficult to differentiate from RML consolidation on PA film
 - Cardiac silhouette preserved
- RUL
 - Look for triangle in right apex

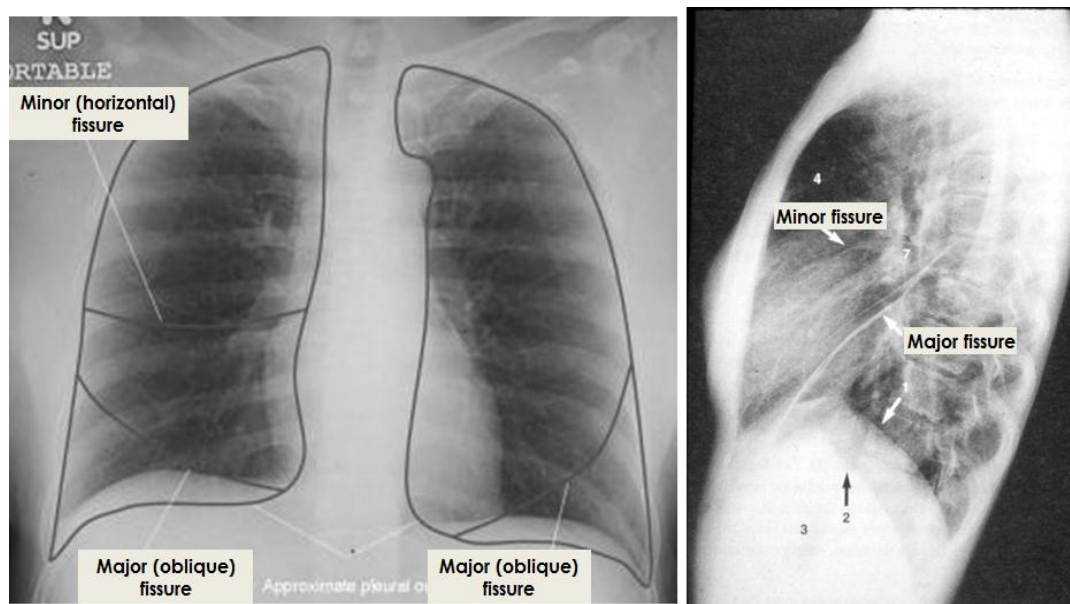


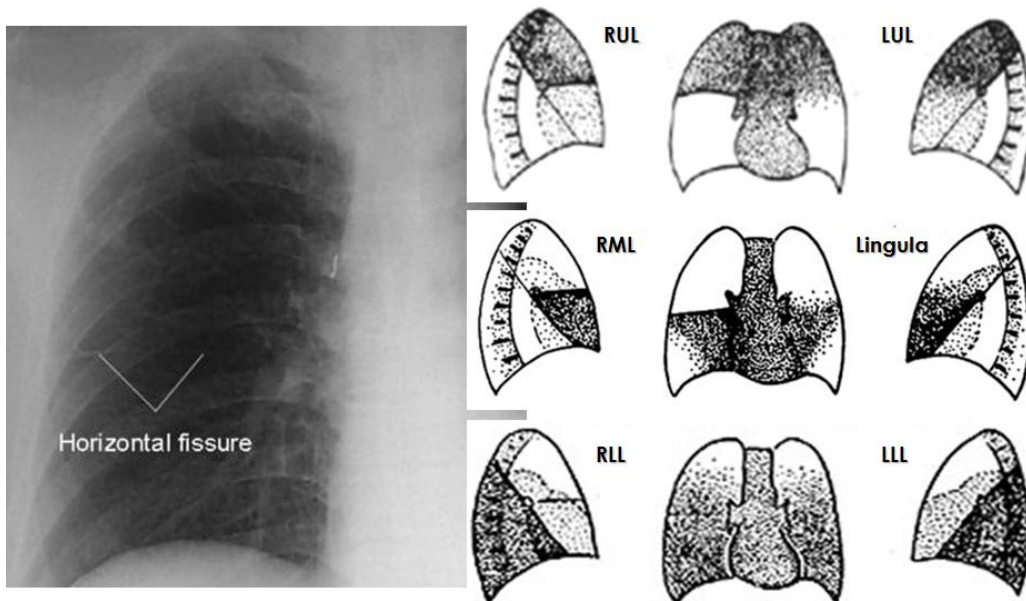
Case eleven: Please describe the findings, give a differential, and state your most likely diagnosis.

- 65 year old with a 10 day history of productive cough, dyspnea and pleuritic chest pain



- Pay careful attention to the pulmonary lobes and fissures

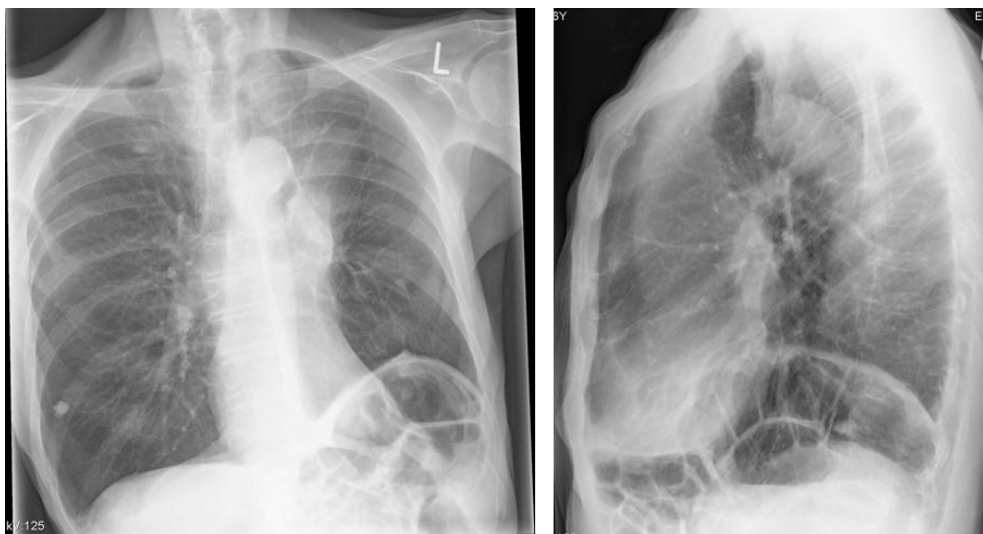




- This patient has lingular consolidation
 - Lingular consolidation
 - Small left pleural effusion
 - Azygos lobe fissure

Case twelve: Please describe the findings, give a differential, and state your most likely diagnosis.

- 80 year old with a 50 year pack history presenting with fever, night sweats and weight loss



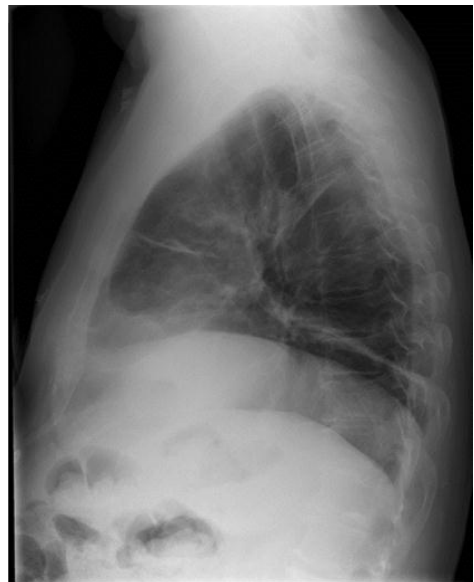
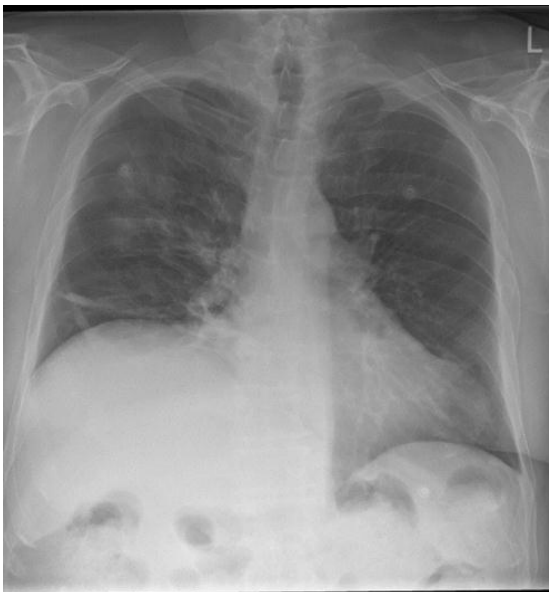Chest x-ray findings suggestive of LUL collapse

- The toughest one to diagnose.
- PA
 - Volume loss (elevation of L hemidiaphragm)
 - Luftsichel sign (LUL has retracted medially and superiorly. The hyperinflated LLL produces a crescent of lucency along the mediastinum and aortic knuckle)
- Lateral
 - Anterior displacement of major fissure (// to sternum)
- Golden S sign
 - Obstructing hilar mass (RUL or LUL)

(This man most likely has lung cancer with secondary LUL collapse)

Case thirteen: Please describe the findings, give a differential, and state your most likely diagnosis.

- 55 year involved in a MVA accident one year ago, when his CHX was normal



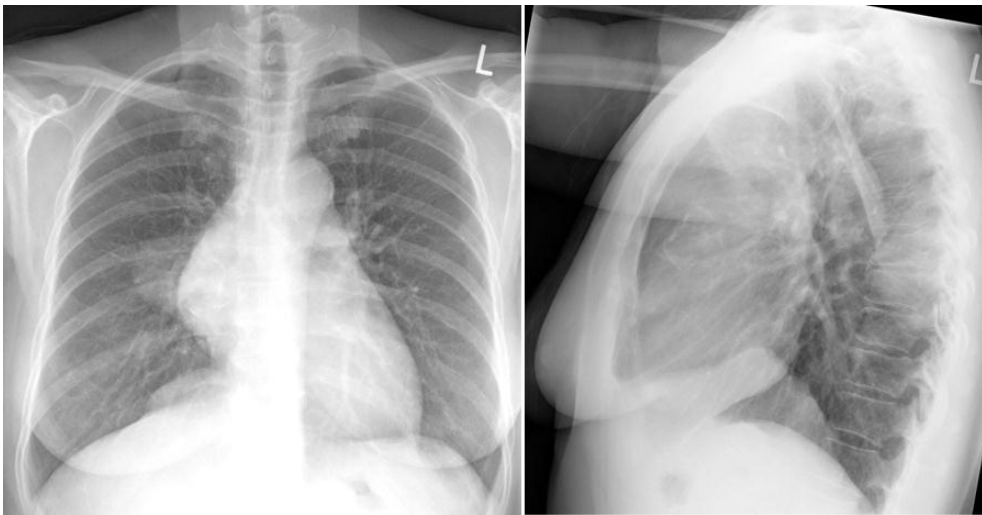
- Chest x-ray findings suggestive of elevation of a hemidiaphragm
 - Normal R hemidiaphragm is $\frac{1}{2}$ ICS higher than L in 90%
 - DDX of elevated hemidiaphragm: The right hemidiaphragm is elevated



- Differential diagnosis
 - Diaphragmatic paralysis
 - Eventration of the diaphragm (R:L = 5.1)
 - Atelectasis
 - Subpulmonic effusion
 - Abdo disease (subphrenic abscess, liver mass, hernia)
 - Diaphragmatic rupture

Case fourteen: Please describe the findings, give a differential, and state your most likely diagnosis.

- “Routine” chest x-ray in a 55 year old asymptomatic woman with treated myasthenia gravis



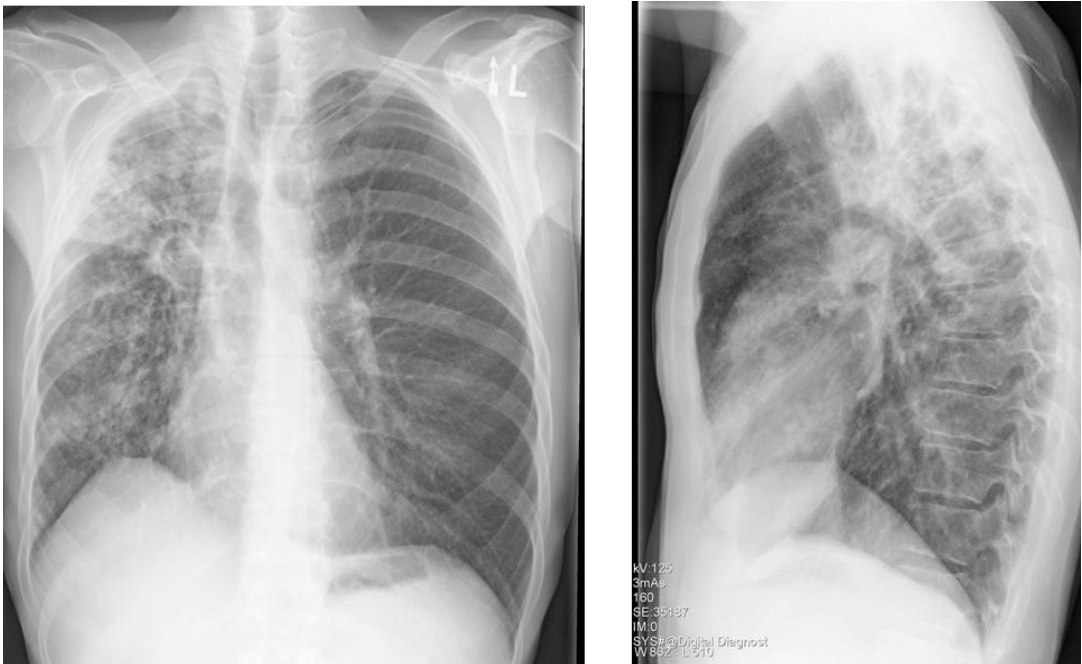
- Chest x-ray findings suggestive of anterior mediastinal masses
- If you are given an x-ray showing an anterior mediastinal mass, comment on:
 - Shape
 - Associated lung lesions (nodules, masses)
 - Surrounding structures (obscures ascending aorta, retrosternal airspace)
- Differential diagnosis (6 T's)
 - Thymoma
 - Thymic hyperplasia
 - Thyroid
 - Teratoma
 - Terrible lymphoma
 - Tumor

This lady also has a posterior mediastinal mass: final Dx turned out to be metastatic malignant thymoma.



Case fifteen: Please describe the findings, give a differential, and state your most likely diagnosis.

- 50 year old homeless man with productive cough, decreased LOC and wasting



- Chest x-ray findings suggestive of apical fibrosis
 - Right sided volume loss with apical fibrosis
 - Right sided lung nodule with central cavitation
 - Right sided mediastinal lymphadenopathy
- Differential diagnosis
 - Active TB
 - Talcosis
 - Sarcoidosis
 - Fibrosis secondary to recurrent pneumonias



Suggested practice case scenarios for OSCE examinations

| Primary Stem | Secondary Stem | Diagnosis |
|----------------|--|--|
| ➤ Dyspnea | <ul style="list-style-type: none"> ○ Post operative ○ Six week post acute MI ○ With fever & productive cough in young person ○ With fever & productive cough in demented person ○ With fever in MHSM ○ With purulent sputum and clubbing ○ Acute onset in elderly person with palpitations ○ Fever and pleural effusion ○ Advanced COPD ○ Young person ○ Exertional in young person | <ul style="list-style-type: none"> - Pulmonary embolism - CHF - Community acquire pneumonia - Aspiration Pneumonia - Pneumocystis - Bronchiectasis/Cystic fibrosis - Atrial fibrillation - Parapneumonic effusion/empyema - Cor Pulmonale - Primary pulmonary HTN - Myocarditis |
| ➤ Hemoptysis | <ul style="list-style-type: none"> ○ With fever in Asian immigrant ○ Chronic smoker ○ Chronic Smoker ○ With fever, epistaxis & renal failure | <ul style="list-style-type: none"> - TB - Ca Lung - Bronchitis - Wegeners |
| ➤ Abnormal CXR | <ul style="list-style-type: none"> ○ Young female with hot nodules in legs | <ul style="list-style-type: none"> - Sarcoidosis |
| ➤ Chest X-ray | <ul style="list-style-type: none"> ○ Solitary pulmonary nodule in 68 yr old | <ul style="list-style-type: none"> - Ca Lung |

Source: Kindly provided by Dr. P Hamilton (U of Alberta)



RHEUMATOLOGY



Table of Contents

| | Page |
|---|-------------|
| Questions in Rheumatology Chapter | 499 |
| Introduction | 502 |
| Hands and Wrists | 514 |
| Elbows | 531 |
| Shoulder | 533 |
| Spine | 543 |
| Hips | 550 |
| Knees | 554 |
| Ankles | 561 |
| Feet | 563 |
| Gout and pseudo-gout | 563 |
| Rheumatoid arthritis | 568 |
| Osteoarthritis | 582 |
| Pressure Ulcer | 588 |
| Ankylosing spondylitis (AS) | 589 |
| Systemic lupus erythematosus | 597 |
| Scleroderma | 601 |
| Raynaud's phenomenon | 602 |
| Vasculitis/Arteritis | 605 |
| Polymyalgia rheumatica-like syndromes | 609 |
| Aseptic necrosis of the bone | 611 |
| Charcot's joint | 611 |
| Arthropathy | 613 |
| Miscellaneous | 618 |
| Suggested practice case scenarios for OSCE examinations | 625 |



Questions in Rheumatology Chapter

1. Take a directed history for a musculoskeletal (MSK) disorder.
2. Perform a focused physical examination to determine the causes of a patient's motor or sensory neuropathy.
3. Perform a focused physical examination of the joints of the upper and lower body and from the abnormal articular findings, give the most likely diagnosis.
4. Take a directed history for the common side effects of nonsteroidal anti-inflammatory drugs.
5. Perform a focused physical examination of the hand to distinguish between rheumatoid arthritis (RA) and osteoarthritis (OA).
6. Perform a focused physical examination for carpal tunnel syndrome. (actually, Tinel's sign is the reproduction of symptoms any nerve; e.g. Tinel's sign may be positive over ulnar nerve at the medial side of the elbow).
7. Give a systematic approach to localized areas of translucent bone.
8. Give a systematic approach to localized areas of calcified bone (periostitis).
9. Perform a focused physical examination of the wrist for rheumatoid arthritis.
10. Perform a directed physical examination of the hands for acromegaly, Marfan's syndrome, and Turner's syndrome.
11. Perform a focused physical examination of the elbow.
12. Take a directed history and a focused physical examination for features differentiating diseases affecting the elbow.
13. Perform a focused physical examination of the elbow to distinguish between "tennis" and golfer's elbow.
14. Perform a focused physical examination of the shoulder.
15. Perform a focused physical examination for causes of shoulder pain.
16. Perform a focused physical examination for shoulder syndromes.
17. Take a directed history of back pain.
18. Perform a focused physical examination of back pain.
19. Perform a focused physical examination for gluteal muscle weakness.
20. Perform a directed physical examination of the knee.
21. Perform a focused physical examination of the ankle.
22. Perform a focused physical examination of the feet.



23. Perform a focused physical examination for complications of RS.
24. Perform a focused physical examination which would help to distinguish BS from S-JS.
25. Give the radiological features of Gout
26. Perform a focused physical examination of extra – articular complications of rheumatoid arthritis (RA).
27. Perform a focused physical examination for rheumatoid arthritis (RA), and its complications.
28. Give non-MSK (musculoskeletal) associations of rheumatoid arthritis (RA).
29. Give the radiological features of Rheumatoid arthritis.
30. In both rheumatoid arthritis (RA) and osteoarthritis (OA), there is slow insidious onset of progressive disease, exacerbations, and the development of limitations in motion. Take a directed history and perform focused physical examination to distinguish RA from OA.
31. Perform a focused physical examination for diseases that may have positive rheumatoid factor.
32. Perform a focused physical examination for non-articular signs of rheumatoid arthritis.
33. Give a systematic approach to the causes of sacroiliitis.
34. Perform a focused physical examination for dermatomyositis/ polymyositis.
35. Perform a focused physical examination for the causes of spondyloarthritis.
36. Juvenile chronic arthritis (still disease) may be pauciarticular and polyarticular. Define still disease and its two major forms. Perform a focused physical examination for juvenile chronic arthritis and its complications.
37. Perform a focused physical examination for ankylosing spondylitis.
38. Take a directed history for ankylosing spondylitis.
39. Take a directed history for Ankylosing Spondylitis
40. Give the distinction between peripheral arthritis vs. sacroiliitis in Crohn disease (CD) and ulcerative colitis (UC).
41. Perform a focused physical examination for primary vs secondary osteoarthritis.
42. Give the radiological features of Ankylosing spondylitis
43. Perform a focused physical examination for psoriatic arthritis.



44. Perform a focused physical examination to distinguish psoriatic arthritis (PA) from rheumatoid arthritis (RA).
45. Perform a focused physical examination for erythema multiforme.
46. Perform a focused physical examination for systemic lupus erythematosus (SLE) and its complications.
47. Perform a focused physical examination for skin, CNS and systemic changes in SLE..
48. Perform a focused physical examination for scleroderma and its complications.
49. Take a directed history and perform a focused physical examination for secondary Raynaud phenomenon (not related to drug use).
50. Perform a directed physical examination for Raynaud's phenomenon (white->blue->red fingers/toes in response to cold temperature).
51. Give the causes of arteritis.
52. Take a directed history and perform a focused physical examination for systemic vasculitis.
53. Give 7 syndromes which may mimic vasculitis (ie, the differential diagnosis of vasculitis)
54. Take a directed history and perform a focused physical examination for causes of polymyalgia rheumatica-like syndromes.
55. Perform a focused physical examination to distinguish PMR from the other causes of polymyalgia-rheumatica (PMR) – like syndromes.
56. Take a directed history of the cause of aseptic necrosis of the bone. (acronym: ASEPTIC).
57. Perform a directed physical examination for Charcot's joint (neuroarthropathy).
58. Perform a focused physical examination of Charcot joint
59. Give the radiological features of Osteo-arthrosis
60. Perform a focused physical examination for patterns of arthropathy.
61. Perform a focused physical examination for polymyositis/ dermatomyositis.
62. Perform a focused physical examination for Marfan's syndrome.
63. Perform a focused physical examination for common types of leg ulcers.



Introduction

- Take a directed history for a musculoskeletal (MSK) disorder.

➤ Joints

- Pain and stiffness
- Weight-bearing, activity, time of day
- Swelling and deformity
- Motor
 - Weakness, instability, falls
- Sensation
 - Functional assessment
- Gait

➤ Extra-articular

- Dry mouth
- Dry, red eyes
- Ulcers
- Raynaud's phenomenon
- Rash
- Fatigue, weight loss, fever
- Diarrhea

*hip pain may be referred to knee or lower thigh

Adapted from: Talley NJ, et al. *MacLennan & Petty Pty Limited 2003*, Table 8.1, page 252.

Useful background: Definition of abnormal physical findings in MSK system.

| Physical finding | Definition of Abnormal Finding |
|-------------------------------------|---|
| | <ul style="list-style-type: none"> • MOTOR EXAMINATION |
| ➤ Weak thumb abduction | ○ Weakness of resisted abduction, i.e., movement of the thumb at right angles to the palm ^a |
| ➤ Thenar atrophy | ○ A concavity of the thenar muscles when observed from the side |
| | <ul style="list-style-type: none"> • SENSORY EXAMINATION |
| ➤ Hypalgesia | ○ Diminished ability to perceive painful stimuli applied along the palmar aspect of the index finger when compared with the ipsilateral little finger |
| ➤ Diminished 2 point discrimination | ○ Diminished ability to identify correctly the number of points using callipers whose points are set 4-6 mm apart, comparing the index with little finger |



| Physical finding | Definition of Abnormal Finding |
|---------------------------------|---|
| ➤ Abnormal vibratory sensation | ○ Diminished ability to perceive vibratory sensations using a standard vibrating tuning fork (128 or 256 Hz), comparing the distal interphalangeal joint of the index finger to the ipsilateral fifth finger |
| ➤ Abnormal monofilament testing | ○ Using a Semmes Weinstein monofilament applied to the pulp of the index finger, the patient's threshold is greater than the 2.83 monofilament <ul style="list-style-type: none"> • OTHER TEST |
| ➤ Square wrist sign | ○ The anteroposterior dimension of the wrist divided by the mediolateral dimension equals a ratio of greater than 0.70 when measured with calipers at the distal wrist crease |
| ➤ Closed fist sign | ○ Paresthesias in the distribution of the median nerve when the patient actively flexes the fingers into a closed fist for 60 s |
| ➤ Flick sign | ○ When asking the patient, "what do you actually do with your hand(s) when the symptoms are at their worst?" the patient demonstrates a flicking movement of the wrist and hand, similar to that used in shaking down a thermometer |
| ➤ Tinel sign | ○ Paresthesias in the distribution of the median nerve when the clinician taps on the distal wrist crease over the median nerve |
| ➤ Phalen sign | ○ Paresthesias in the distribution of the median nerve when the patient flexes both wrists 90° for 60 seconds |
| ➤ Pressure provocation test | ○ Paresthesias in the distribution of the median nerve when the examiner presses with his/her thumb on the palmar aspect of the patient's wrist at the level of the carpal tunnel for 60 s |
| ➤ Tourniquet test | ○ Paresthesias in the distribution of the median nerve when a blood pressure cuff around the patient's arm is inflated above systolic pressure for 60 seconds |

^a Most clinicians define weakness as muscle power less than that of the companion muscle in contralateral hand (which has the disadvantage of



assuming that the opposite hand has normal strength), or that of a standard of normal strength based on the experience of examining many normal individuals.

Adapted from: Simel DL, et al. *JAMA* 2009 Table 10-1, page 112; RCE, Table 10.1, page 112.

- Perform a focused physical examination to determine the causes of a patient's motor or sensory neuropathy
 - Motor
 - Immune
 - Guillian-Barre's Syndrome
 - Idiopathic
 - Perineal muscular atrophy
 - Metabolic
 - Porphyria
 - Drugs
 - Lead toxicity
 - Dapsone toxicity
 - Organophosphorous poisoning
 - Sensory
 - Metabolic
 - Diabetes mellitus
 - Drugs
 - Alcoholism
 - Infection
 - Leprosy
 - Nutrition
 - Deficiency of B₁₂ and B₁
 - Renal
 - Chronic renal failure

Adapted from: Baliga RR. *Saunders/Elsevier* 2007, page165.

"What is not started today is never finished tomorrow"

Johann Wolfgang von Goethe



- Perform a focused physical examination of the joints of the upper and lower body and from the abnormal articular findings, give the most likely diagnosis.

| Finding | Diagnosis |
|--|--|
| ➤ Shoulder | |
| ○ Inspection | |
| - Flattening of rounded lateral aspect of shoulder | - Anterior dislocation |
| ➤ Elbow | |
| ○ Inspection | |
| - Swelling over anterior elbow | - Glenohumeral synovitis; synovial cyst |
| - Localized cystic swelling over olecranon | - Olecranon bursitis |
| - Swelling obscures paraolecranon grooves | - Elbow synovitis |
| - Nodules over extensor surface of ulna | - Gouty tophi; rheumatoid nodules |
| ○ Palpation | |
| - Elbow pain and tenderness over lateral epicondyle | - Lateral epicondylitis ('tennis elbow') |
| - Elbow pain and tenderness over medial epicondyle | - Medial epicondylitis ('golfers elbow') |
| ➤ Wrists and carpal joints | |
| ○ Inspection | |
| - Firm, painless cystic swelling, often located over volar or dorsal wrist | - Ganglion (synovial cyst) |
| - Thickening of palmar aponeurosis, causing flexion deformity of MCP joints (4 th finger > 5 th finger > 3 rd finger) | - Dupuytren's contracture |

"The impossible is often the untried"

Jim Goodwin



| Finding | Diagnosis |
|---|--|
| - Abnormal prominence of distal ulna | - Subluxation of ulna (from chronic inflammatory arthritis, especially rheumatoid arthritis) |
| - | - |
| - Non-pitting swelling proximal to wrist joint, sparing joint itself; associated clubbing of digits | - Hypertrophic osteoarthropathy |
| ➤ Fingers | |
| ○ Inspection | |
| - Loss of normal knuckle wrinkles | - PIP or DIP synovitis |
| - Loss of 'hills and valleys' between metacarpal heads | - MCP synovitis |
| - Ulnar deviation at metacarpophalangeal joints | - Chronic inflammatory arthritis |
| - Swan neck deformity (flexion contracture at MCP joint, hyperextension of PIP joint, flexion of DIP joint) | - Chronic inflammatory arthritis, especially rheumatoid arthritis |
| - Boutonniere deformity (flexion of PIP, hyperextension of DIP) | - Detachment of central slip of extensor tendon to PIP, common in rheumatoid arthritis |
| - Osteophytes: Heberden's nodes at DIP, Bouchard's nodes at PIP | - Osteoarthritis |
| - Mallet finger: flexion deformity of DIP | - Detachment of extensor tendon from base of distal phalanx or fracture |
| - 'Telescoping' or 'opera glass hand'; shortening of digits and destruction of IP joints | - 'Arthritis mutilans' in rheumatoid or psoriatic arthritis |
| ○ Palpation | |
| - Flexion and extension of digits causes snapping or catching sensation in palm | - Trigger finger (flexor tenosynovitis) |



| Finding | Diagnosis |
|--|--|
| <ul style="list-style-type: none"> - Finkelstein's test: pain when patients makes fist with fingers over thumb and bends the wrist in an ulnar direction | <ul style="list-style-type: none"> - Tenosynovitis of long abductor and short extensor of thumb ('De Quervain's stenosing tenosynovitis') |
| <ul style="list-style-type: none"> ➤ Hip <ul style="list-style-type: none"> ○ Inspection <ul style="list-style-type: none"> - Trauma, hip externally rotated - Trauma, hip internally rotated - Pelvic tilt (imaginary line through the anterior iliac spines is not horizontal) ○ Palpation <ul style="list-style-type: none"> - Hip pain, tenderness localized over greater trochanter - Hip pain, tenderness localized over middle third of inguinal ligament, lateral to femoral pulse - Hip pain and tenderness localized over ischial tuberosity | <ul style="list-style-type: none"> - Femoral neck fracture; anterior dislocation - Posterior dislocation - Scoliosis; anatomic leg length discrepancy; hip disease - Trochanteric bursitis - Iliopsoas bursitis - Ischiogluteal bursitis ('Weaver's bottom') |
| <ul style="list-style-type: none"> ➤ Knee <ul style="list-style-type: none"> ○ Inspection <ul style="list-style-type: none"> - Localized tenderness and swelling over patella - Generalized swelling of popliteal space - Genu varum and genu valgum ○ Palpation <ul style="list-style-type: none"> - Knee pain and tenderness localized over medial aspect of upper tibia - Distressed reaction if patella moved laterally ('apprehension test') | <ul style="list-style-type: none"> - Prepatellar bursitis ('Housemaid's knees') - Baker's cyst (enlarged semimembranosus bursa, which communicates with knee joint) - Anserine bursitis - Recurrent patellar dislocation |



| Finding | Diagnosis |
|---|---------------------------------|
| ➤ Ankle and feet | |
| ○ Inspection | |
| - Flattening of longitudinal arch | - Pes planus |
| - Abnormal elevation of medial longitudinal arch | - Pes cavus |
| - Outward angulation of great toe with prominence over medial 1 st MTP joint (bunion) | - Hallux valgus |
| - Hyperextension of MTP joints and flexion of PIP joints | - Hammer toes |
| ○ Palpation | |
| - Nodules with Achilles tendon | - Tendon xanthoma |
| - Foot pain, localized tenderness over calcaneal origin of plantar fascia | - Plantar fasciitis |
| - Foot pain, localized tenderness over plantar surface of MT heads | - Metatarsalgia |
| - Forefoot pain, tenderness between 2 nd or 3 rd toes or between 3 rd and 4 th toes | - Morton's interdigital neuroma |
| - Ankle pain, dysesthesias of sole, aggravated by forced dorsiflexion and eversion of foot | - Tarsal tunnel syndrome |

Abbreviations: DIP, distal interphalangeal; MCP, metacarpophalangeal; MT, metatarsal; MTP, metatarsophalangeal; PIP, proximal interphalangeal

Permission granted: McGee SR. *Saunders/Elsevier* 2007, Table 53-2, page 627.

- Take a directed history for the common side effects of non-steroidal anti-inflammatory drugs.

➤ CNS

- Delirium/ confusion
- Headache
- Dizziness
- Blurred vision
- Mood swings
- Aseptic meningitis



- Pulmonary
 - Pulmonary infiltrates
 - Non-cardiac pulmonary edema (aspirin toxicity)
 - Anaphylaxis
 - Bronchospasm
 - Nasal polyps

- GI
 - Nausea, vomiting
 - Abdominal pain
 - ↑/↓ Bowel movement
 - Iron deficiency anemia
 - Peptic ulcer disease
 - Colitis
 - Hemorrhage from diverticulae

- Kidney
 - ↓ renal blood flow
 - ↓ glomerular filtration rate
 - ↑creatinine clearance
 - Purpura
 - Interstitial nephritis
 - Papillary necrosis
 - Nephrotic syndrome
 - Hyperkalemia
 - Type IV renal tubular acidosis
 - Fluid retention

- Blood
 - Bone marrow suppression
 - Agranulocytosis
 - Aplastic anemia
 - Platelet-aggregating defect

- Skin
 - Dermatitis
 - Urticaria
 - Erythema multiforme
 - Exfoliative syndromes (toxic epidermal necrolysis)
 - Oral ulcers

- Drug interactions
 - ↑ hemostatic effect of warfarin
 - ↑ antihypertensive effect of diuretics, beta -blockers, angiotensin-converting enzyme inhibitors



- Influence drug metabolism
 - Methotrexate (high doses only)
 - Lithium
 - Oral hypoglycemic agents

Source: Ghosh AK. *Mayo Clinic Scientific Press* 2008, Table 24-21, page 999.

Useful background: Activities of daily living (ADL) and instrumental activities of daily living (IADL)

| ADL | IADL |
|--|--|
| <ul style="list-style-type: none"> ○ Bathing ○ Dressing ○ Use of toilet ○ Mobility ○ Continence ○ Feeding self | <ul style="list-style-type: none"> ○ Use of telephone ○ Shopping ○ Meal preparation ○ Housekeeping ○ Laundry ○ Transportation ○ Taking medicine ○ Money management |

Source: Ghosh AK. *Mayo Clinic Scientific Press* 2008, Table 13-8, page 571.

Useful background: Abnormal articular findings and implied diagnosis

| Finding | Diagnosis |
|--|---|
| <ul style="list-style-type: none"> ➤ Fingers <ul style="list-style-type: none"> ○ Inspection <ul style="list-style-type: none"> - Loss of normal knuckle wrinkles - Loss of "hills and valleys" between metacarpal heads - Ulnar deviation at metacarpophalangeal joints - Swan neck deformity (flexion contracture at MCP joint, hyperextension of PIP joint, flexion at DIP joint) - Bouteniere deformity (flexion of PIP, hyperextension of DIP) | <ul style="list-style-type: none"> - PIP or DIP synovitis, MCP synovitis - Chronic inflammatory arthritis - Chronic inflammatory arthritis, especially rheumatoid arthritis - Detachment of central slip of extension tendon to PIP, common in rheumatoid arthritis |



| Finding | Diagnosis |
|---|---|
| - Osteophytes: Heberden's nodes at DIP, Bouchard's nodes at PIP | - Osteoarthritis |
| - Mallet fingers: flexion deformity of DIP | - Detachment of extensor tendon from base of distal phalanx or fracture |
| - "Telescoping" or "opera glass hand"; shortening of digits and destruction of IP joint | - Arthritis mutilans, in rheumatoid or psoriatic arthritis |

➤ Wrists

- Inspection
 - Firm, painless cystic swelling, often located over volar or dorsal wrist
 - Ganglion (synovial cyst)
 - Thickening of palmar aponeurosis, causing flexion deformity of MCP joints (4th finger > 5th finger > 3rd finger)
 - Dupuytren's contracture
 - Abnormal prominence of distal ulna
 - Subluxation of ulna (from chronic inflammatory arthritis, especially rheumatoid arthritis)
 - Non-pitting swelling proximal to wrist joint sparing joint itself, associated clubbing of digits
 - Hypertrophic osteoarthropathy
- Special tests
 - Flexion and extension of digits causes snapping or catching sensation in palm
 - Trigger finger (flexor tenosynovitis)
 - Finkelstein's test: pain when patient makes fist with fingers over thumb and bends the wrist in an ulnar direction
 - Tenosynovitis of long abductor and short extensor of thumb, or "De Quervain's stenosing tenosynovitis")



| Finding | Diagnosis |
|---|---|
| ➤ Elbows | |
| ○ Inspection | |
| - Localized cystic swelling over olecranon | - Olecranon bursitis |
| - Swelling obscures patellolecranon grooves | - Elbow synovitis |
| - Nodules over extensor surface of ulna | - Gouty tophi; rheumatoid nodules |
| ○ Palpation | |
| - Elbow pain and tenderness over lateral epicondyle | - Lateral epicondylitis (“tennis elbow”) |
| - Elbow pain and tenderness over medial epicondyle | - Medial epicondylitis (“golfer’s elbow”) |
| ➤ Shoulder | |
| ○ Inspection | |
| - Flattening of rounded lateral aspects of shoulder | - Anterior dislocation |
| - Swelling over anterior aspect | - Glenohumeral synovitis; synovial cyst |
| ➤ Hip | |
| ○ Inspection | |
| - Trauma, hip externally rotated | - Femoral neck fracture; anterior dislocation |
| - Trauma, hip internally rotated | - Posterior dislocation |
| - Pelvic tilt (imaginary line through the anterior iliac spine is not horizontal) | - Scoliosis; anatomic leg-length discrepancy; hip disease |
| ○ Palpation | |
| - Hip pain, tenderness localized over greater trochanter | - Trochanteric bursitis |
| - Hip pain, tenderness localized over middle third of inguinal ligament, lateral to femoral pulse | - Iliopsoas bursitis |



| Finding | Diagnosis |
|---|---|
| - Hip pain and tenderness localized over ischial tuberosity | - Ischiogluteal bursitis (“Weaver’s bottom”) |
| ➤ Knee | |
| ○ Inspection | |
| - Localized tenderness and swelling over patella | - Prepatellar bursitis (“housemaid’s knees”) |
| - Generalized swelling of popliteal space | - Baker’s cyst (enlarged semimembranosus bursa, which communicates with knee joint) |
| - Genu varum and genu valgum | - Anserine bursitis |
| ○ Palpation | |
| - Knee pain and tenderness localized over medial aspect of upper tibia | - Recurrent patellar dislocation |
| - Distressed reaction if patella moved laterally (“apprehension test”) | |
| ➤ Ankle and feet | |
| ○ Inspection | |
| - Flattening of longitudinal arch | - Pes planus |
| - Abnormal elevation of medial longitudinal arch | - Pes cavus |
| - Outward angulation of great toe with prominence over medial 1 st MTP joints (bunion) | - Hallux valgus |
| - Hyperextension of MTP joints and flexion of PIP joints | - Hammer toes |
| ○ Palpation | |
| - Nodules within Achilles tendon | - Tendon xanthoma |
| - Foot pain, localized tenderness over calcaneal origin of plantar fascia | - Plantar fasciitis |
| - Foot pain, localized tenderness over plantar surface of MT heads | - Metatarsalgia |

Permission granted: McGee SR. *Saunders/Elsevier* 2007, Table 53-2, pages 625 to 627.



Useful background: Upper limb movements and their respective myotomes.

| Movement | Myotome |
|--|---------|
| ➤ Neck | |
| ○ Flexion | ○ C1-C2 |
| ○ Side flexion | ○ C3 |
| ➤ Shoulder | |
| ○ Elevation | ○ C4 |
| ○ Abduction | ○ C5 |
| ➤ Elbow | |
| ○ Elbow flexion and/or wrist extension | ○ C5 |
| ○ Elbow extension and/or wrist flexion | ○ C7 |
| ➤ Fingers | |
| ○ Thumb extension and/or ulnar deviation | ○ C8 |
| ○ Abduction and/or adduction of hand intrinsic | ○ T1 |

Source: Filate W, et al. *The Medical Society, Faculty of Medicine, University of Toronto* 2005, Table 12, page 138.

Hands and Wrists

Useful background: Normal range of motion of joints

| Joint | Flexion/ extension (degrees) | Abduction/ adduction (degrees) | Rotation (degrees) |
|-------------------------------------|--|--|--|
| ➤ Shoulder | ○ 180 | ○ 180 (abduction)
○ 45 (adduction across body) | ○ 90 (internal rotation)
○ 90 (external rotation) |
| ➤ Elbow | ○ 150 (humero-ulnar) | | ○ 180 (radiohumeral) |
| ➤ Wrist and carpal joints | ○ 70 (wrist extension)
○ 80-90 (palmar flexion) | ○ 50 (ulnar deviation)
○ 20-30 (radial deviation) | |
| ➤ Fingers (MCP, PIP and DIP joints) | ○ 90 (MCP)
○ 120 (PIP)
○ 80 (DIP) | ○ 30-40 (MCP combined abduction/adduction) | |



| Joint | Flexion/ extension (degrees) | Abduction/ adduction (degrees) | Rotation (degrees) |
|------------------|---|--|--|
| ➤ Hip | <ul style="list-style-type: none"> ○ 10-20 (extension) ○ 120 (flexion, knee flexed) | <ul style="list-style-type: none"> ○ 40 (abduction) ○ 25 (adduction) | <ul style="list-style-type: none"> ○ 40 (internal rotation) ○ 45 (external rotation) |
| ➤ Knee | <ul style="list-style-type: none"> ○ 130 | | |
| ➤ Ankle and feet | <ul style="list-style-type: none"> ○ 45 (plantar flexion) ○ 20 (dorsiflexion) | | <ul style="list-style-type: none"> ○ 30 (inversion) ○ 20 (eversion) |

Permission granted: McGee SR. *Saunders/Elsevier* 2007, Table 53-1, page 624.

Useful background: Causes of wasting of small muscles of hand

➤ CNS/ PNS

- Cord (C8, T1)
 - Motor neurone disease
 - Tumour
 - Syringomyelia
 - Meningovascular disease
 - Cord compression
- Roots
 - Cervical spondylosis
 - Neurofibroma etc
- Brachial plexus
 - Klumpke paralysis
 - Cervical rib etc
- Ulnar or median nerve lesions

➤ MSK

- Arthritis of hand or wrist
- Disuse atrophy
- Muscle diseases

Adapted from: Burton JL. *Churchill Livingstone* 1971, page 86.



Useful background: Common deformities of the hand

| Name of deformity | | Associations |
|---------------------------|--|--|
| ➤ Mallet finger/thumb | ○ A flexed DIP caused by damage to the extensor tendon | - Trauma or RA |
| ➤ Swan neck deformity | ○ A flexed DIP and hyperextended PIP | - RA but has many other causes |
| ➤ Boutonniere deformity | ○ A hyperextended DIP and flexed PIP | - Trauma or RA |
| | ○ Occurs when the central slip of the extensor tendon detaches from the middle phalanx | |
| ➤ Dupuytren's contracture | ○ Flexion deformity of the fingers at the MCP and IPs associated with nodular thickening in the palm and fingers | - Diabetes, epilepsy, alcoholism and hereditary tendencies |
| ➤ Heberden's nodes | ○ Hard dorsolateral nodules of DIPs, often associated with a deviation of the distal phalanx | - OA |
| ➤ Bouchard's nodes | ○ Similar to Heberden's nodes, but affects the PIPs | - OA |

Adapted from: Filate W, et al. *The Medical Society, Faculty of Medicine, University of Toronto* 2005, page 135.

"Knowledge speaks, but wisdom listens"

Jimi Hendrix



- Perform a focused physical examination of the hand to distinguish between rheumatoid arthritis (RA) and osteoarthritis (OA).

| Sign | RA | OA |
|---------------------------|----|----|
| ➤ PIP | + | + |
| ➤ DIP | | + |
| ➤ Swan-neck deformity* | + | |
| ➤ Deviation | | |
| ○ Ulnar *** | + | |
| ○ Lateral | | + |
| ➤ Boutonniere deformity** | + | |

*Swan-neck deformity extension at PIP and DIP

** Boutonniere deformity PIP joint, fixed flexion; DIP joint, extension

*** ulnar deviation at the metacarpal phalangeal joints

Source: Mangione S. *Hanley & Belfus* 2000, page 20.



Mallet finger



Mallet thumb

- A flexed DIP caused by damage to the extensor tendon
- Interpretation of trauma or RA



Swan – neck deformity

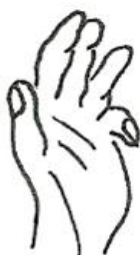- A flexed DIP and hyperextended PIP
- Interpretation of RA, but has many other causes





Boutonniere deformity

- Hyperextended DIP and flexed PIP
- Occurs when the central slip of the extensor tendon detaches from the middle phalanx
- Trauma or RA
- Ulnar deviation
- Deformity



Dupuytren's contracture



Heberden's nodes and Bouchard's nodes

See

Adapted from : Filate W, et al. *The Medical Society, Faculty of Medicine, University of Toronto* 2005, Figure 2, page 135.

"The real voyage of discovery consists not in seeking new lands but seeing with new eyes"

Marcel Proust



Useful background: More deformities

| Site | Location of MSK disorder |
|---|--|
| ➤ Finger | |
| ○ Loss of normal knuckle wrinkles | - PIP or DIP synovitis |
| ○ Loss of “hills and valleys” between metacarpal heads | - MCP synovitis |
| ○ Ulnar deviation at metacarpophalangeal joints | - Chronic inflammatory arthritis |
| ○ Swan-neck deformity (flexion contracture at MCP joint, hyperextension of PIP joint, flexion of DIP joint) | - Chronic inflammatory arthritis, especially rheumatoid arthritis |
| ○ Boutonniere deformity (flexion of PIP, hyperextension of DIP) | - Detachment of central slip of extensor tendon to PIP, common in rheumatoid arthritis |
| ○ Mallet finger: flexion deformity of DIP | - Detachment of extensor tendon from base of distal phalanx or fracture |
| ○ “Telescoping” or “opera glass hand”: shortening of digits and destruction of IP joints | - “Arthritis mutilans”, in rheumatoid or psoriatic arthritis |
| ➤ Proximal and distal interphalangeal joints | |
| ○ Spindle-shaped deformity of finger (tenosynovites, especially in psoriatic arthritis) | |
| ○ Tophi (gout) | |
| ○ Wasting of small muscles of the hand | |
| ○ Heberden’s nodes – bony nodules at DIP joints (OA) | |
| ○ Bouchard’s nodes – long nodules at PIP joints(OA) | |
| ○ Deformity of thumb | |
| ○ Ulnar deviation of thumb | |
| ➤ Wrists and carpal joints | |
| ○ Ganglion (synovial cyst): | - Firm, painless cystic swelling, often located over volar or dorsal wrist |

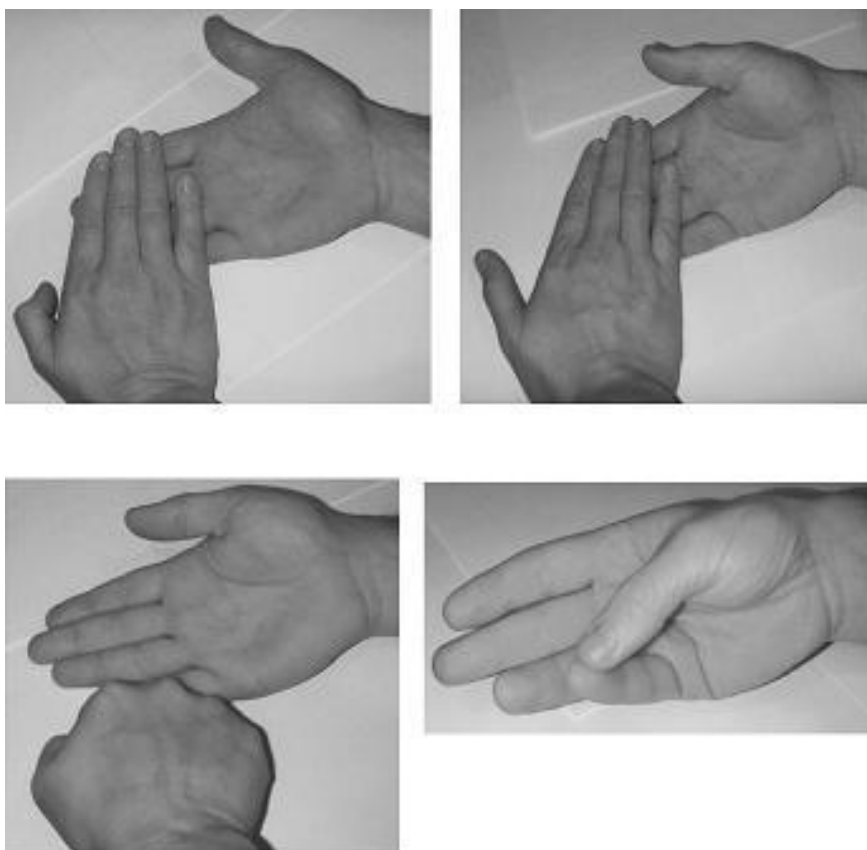


| Site | Location of MSK disorder |
|---|--|
| ○ Dupuytren's contracture: | - Thickening of palmar aponeurosis, causing flexion deformity of MCP joints (4 th finger > 5 th finger > 3 rd finger) |
| ○ Subluxation of ulna (from chronic inflammatory rthritis, especially rheumatoid arthritis): | - Abnormal prominence of distal ulna |
| ○ Hypertrophic osteoarthropathy: | - Non-pitting swelling proximal to wrist joint, sparing joint itself; associated clubbing of digits |
| ➤ Special tests | |
| ○ Trigger finger (flexor tenosynovitis): | - Flexion and extension of digits causes snapping or catching sensation in palm |
| ○ Tenosynovitis of long abductor and short extensor of thumb, or "De Quervain's stenosing tenosynovitis": | - Finkelstein's test: pain when patient makes fist with fingers over thumb and bends the wrist in an ulnar direction |
| ➤ Elbows | |
| ○ Subcutaneous nodules | |
| ○ Psoriatic rash | |
| ➤ Palpation – (Feel and move passively and actively) | |
| ➤ Hands | |
| ○ Tenderness or pain | |
| ○ Synovitis | |
| ○ Effusions | |
| ○ Range of movement | |
| ○ Crepitus | |
| ○ Subluxation | |
| - Hand function | |
| - Grip strength | |
| - Key grip (abduction of thumb) | |
| - Opposition strength | |
| - Practical ability | |
| ▪ Button and unbutton clothes | |
| ▪ Pincer movement | |
| ▪ Writing | |



- Palms
 - Scars, palmar erythema, pale palmar creases (anemia)
 - Wasting of thenar and hypothenar eminence
 - Palmar tendon crepitus
 - Erythema
 - Thickening of palmar fascia (Dupuytren's contracture)
- Wrists
 - Synovitis
 - Effusions
 - Range of movement
 - Crepitus
 - Carpal tunnel syndrome tests

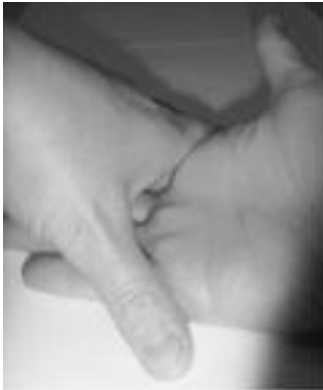Useful background: Thumb movements



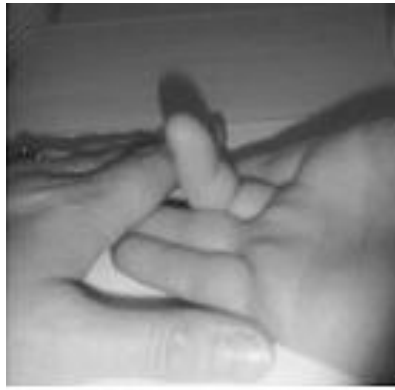Adapted from: Talley NJ, et al. *Maclennan & Petty Pty Limited* 2003, Figure 8.10, page 267.



Useful background: Testing the superficial and profundus flexor tendons



Flexor profundus



Flexor superficialis



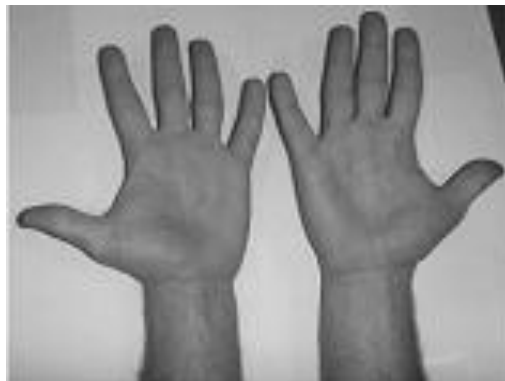The key grip

Adapted from: Talley N. J., et al. *MacLennan & Petty Pty Limited* 2003, page 268.

Useful background: MCP and IP joint movements



Flexion



Extension



Abbreviations: DIP, distal interphalangeal joint; IP, interphalangeal joint; MCP, metacarpopharyngeal joint; MT, metatarsal; OA, osteoarthritis; PIP, proximal interphalangeal joint; RA, rheumatoid arthritis.

Adapted from: Talley NJ, et al *MacLennan & Petty Pty Limited* 2003, Figure 8.1, page 269; Filate W, et al. *Medical Society, Faculty of Medicine* 2005, Table 7, page 135, pages 124 and 125; and McGee SR. *Saunders/Elsevier* 2007, Table 53-2, pages 626 and 627.

Useful background: Normal ranges of wrist motion

| Movement | Normal range of motion |
|--------------------|---|
| ➤ Flexion | 75° |
| ➤ Extension | 75° |
| ➤ Radial deviation | 20° |
| ➤ Ulnar deviation | 35° |
| ➤ Supination | 80° from vertical (with pencil grasped in hand) |
| ➤ Pronation | 75° from vertical (with pencil grasped in hand) |

Source: Filate W, et al. *The Medical Society, Faculty of Medicine, University of Toronto* 2005, page 133.

Useful background: Normal ranges of hand motion

| Movement | Normal range of motion |
|--------------|---|
| ➤ Flexion | 145° |
| ➤ Extension | 0° |
| ➤ Supination | 80° from vertical (with pencil grasped in hand) |
| ➤ Pronation | 75° from vertical (with pencil grasped in hand) |

Source: Filate W, et al. *The Medical Society, Faculty of Medicine, University of Toronto* 2005, page 132.



Useful background: Nerve supply of the hand

| Nerve | Sensory | Motor |
|---------------------------------|--|--|
| • Motor and sensory | | |
| ➤ Radial | ○ Dorsum of first webspace | ○ Extension of fingers, thumb, and wrist |
| ➤ Ulnar | ○ Dorsal tip of small finger
○ Palmar surface of small finger/ medial ring finger | ○ Finger abduction and adduction of ring and small finger
○ DIP flexion of fingers
○ Opposition of small finger
○ Wrist flexion |
| ➤ Median | ○ Dorsal tip of index/ middle/ lateral half of ring finger
○ Palmar surface of index/ middle/ lateral half of ring finger | ○ Thumb IP flexion
○ Index/ middle finger flexion
○ Wrist flexion |
| • Motor | | |
| ➤ Posterior interosseous branch | | ○ Extension of thumb |
| ➤ Anterior interosseous branch | | ○ Flexion of index/ middle finger |
| ➤ Lateral terminal branch | | ○ Opposition of thumb |

Adapted from: Filate W, et al. *The Medical Society, Faculty of Medicine, University of Toronto* 2005, Table 9, page 136.

Useful background: Distribution of arthritis in the hand and wrist

| Joint | Osteoarthritis | Rheumatoid arthritis |
|---------|----------------|----------------------|
| ➤ DIP | ○ Very common | - Rare |
| ➤ PIP | ○ Common | - Very common |
| ➤ MCP | ○ Rare | - Very common |
| ➤ Wrist | ○ Rare | - Very common |

*Osteoarthritis will sometimes affect only the carpometacarpal joint of the thumb

Abbreviations: MCP, metacarpophalangeal; PIP, proximal interphalangeal; DIP, distal interphalangeal

Source: Filate W., et al. *The Medical Society, Faculty of Medicine, University of Toronto* 2005, Table 10, page 136.



Useful background: Normal ranges of motion

| Digit | Joint | Range of motion |
|--------------------------------------|-------|---|
| ➤ Fingers | MCPs | 0-90° |
| | PIPs | 0-100° |
| | DIPs | 0-80° |
| ➤ Thumb | MCP | 5° extension; 55° flexion |
| | IP | 20° extension; 80° flexion |
| ➤ Wrist and carpal joints | | 70° (wrist extension) |
| | | 80°-90° (palmar flexion) |
| | | 50° (ulnar deviation) |
| | | 20°-30° (radial deviation) |
| ➤ Fingers (MCP, PIP, and DIP joints) | | 90° (MCP) |
| | | 120° (PIP) |
| | | 80° (DIP) |
| | | 30°-40° (MCP, combined abduction/adduction) |

Abbreviations: DIP, distal interphalangeal joint; IP, interphalangeal joint; MCP, metacarpopharyngeal joint; MT, metatarsal; OA, osteoarthritis; PIP, proximal interphalangeal joint; RA, rheumatoid arthritis.

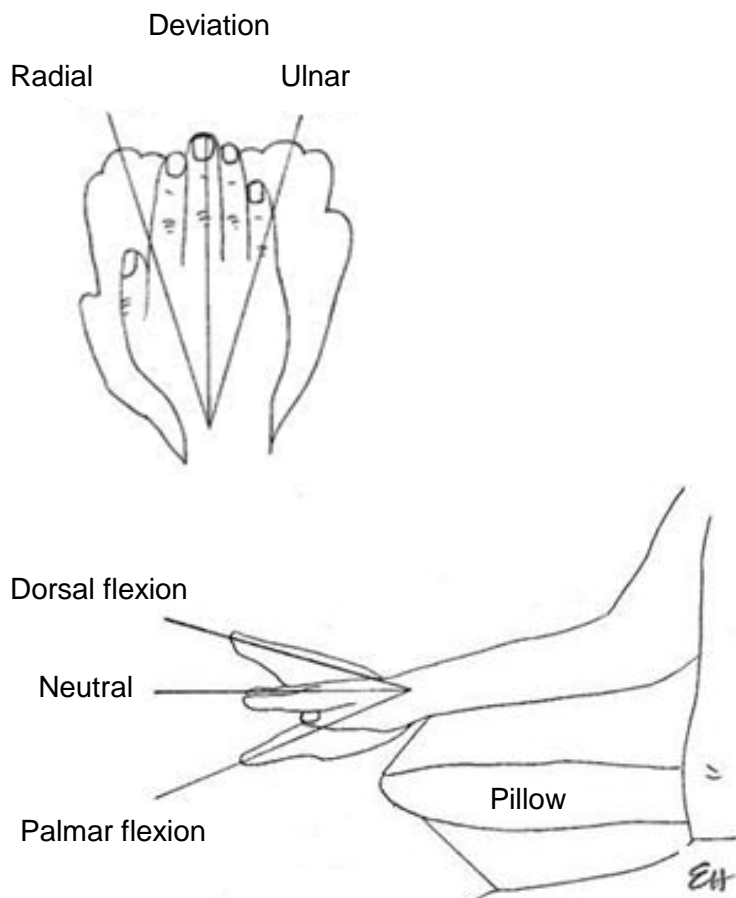
Special tests

- For intact flexor digitorum superficialis: restrict motion of 3 out of 4 fingers by holding down distal phalanges with the dorsum of the patients hand (palm up) rested on a table; ask the patient to flex the free finger and look for PIP flexion
- For intact flexor digitorum profundus; hold down both the proximal and middle phalanges and ask the patient to flex fingers; look for DIP flexion

Adapted from: Filate W, et al. *The Medical Society, Faculty of Medicine, University of Toronto* 2005, pages 133, and 136.



Useful background: Wrist movements



Adapted from: Talley NJ, et al. *MacLennan & Petty Pty Limited* 2003, Table 8.7, page 264.

- Perform a focused physical examination for carpal tunnel syndrome. (actually, Tinel's sign is the reproduction of symptoms any nerve; eg, Tinel's sign may be positive over ulnar nerve at the medial side of the elbow)
 - Tinel's sign – symptoms reproduced by pressure on median nerve at wrist.
 - Phalen's sign – symptoms reproduced by flexing wrists and holding dorsal sides together for 1 minute.
 - Sensory loss on thenar half of palm.

Adapted from: Mangione S. *Hanley & Belfus* 2000, page 463



What is “the best”? There are no “best” clinical tests of physical examination for carpal tunnel syndrome, since the likelihood of each of the above tests is < 2 .

Useful background

- Carpal tunnel syndrome
- Katz hand diagram
 - Classic or probable hand diagram has a sensitivity of 64% and a specificity of 73%
- Hypalgesia in the median nerve territory
 - Pooled studies yielded PLR, 3.1; NLR, 0.7
- Weak thumb abduction
 - Pooled studies yielded PLR, 1.8; NLR, 0.5

Note: Several traditional findings of Carpal Tunnel Syndrome were found to have little or no diagnostic value including: nocturnal paresthesia; Phalen and Tinel signs; thenar

- Operating characteristics of clinical examination for Carpal Tunnel Syndrome (CTS). Note that: the PLR for all of these are < 2.0 , making each of the physical signs of limited value

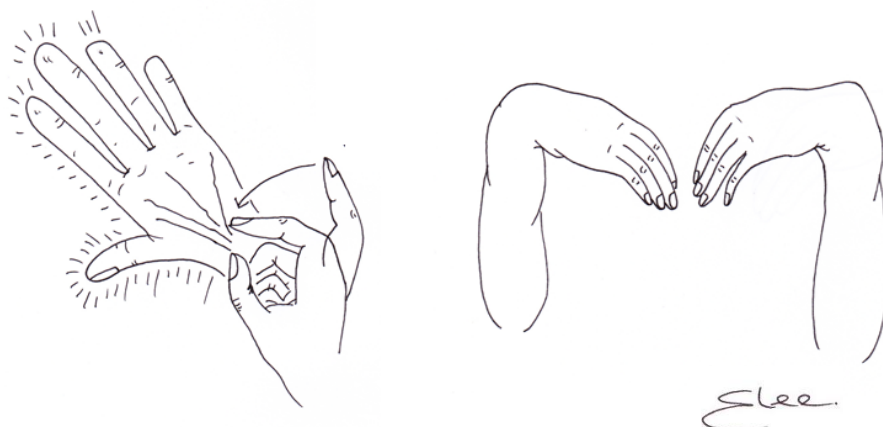
| Physical sign | PLR | NLR |
|-----------------------------------|-----|------|
| ➤ Tinel sign | 1.5 | 0.82 |
| ➤ Phalen test | 1.3 | 0.74 |
| ➤ Provocation tests | 1.1 | 0.89 |
| ➤ Multivariate model | 1.7 | 0.39 |
| ➤ Flick or Tinel | 1.5 | 0.79 |
| ➤ Phalen or Tinel | 1.5 | 0.81 |
| ➤ Flick | 1.4 | 0.85 |
| ➤ Flick or Phalen | 1.3 | 0.82 |
| ➤ Abnormal monofilament in digits | 1.2 | 0.11 |

Abbreviations: CI, confidence interval, PLR, positive likelihood ratio; NLR, negative likelihood ratio.

Adapted from: Simel DL, et al. *JAMA* 2009, Table 10-5, page 123; Filate W, et al. *The Medical Society, Faculty of Medicine, University of Toronto* 2005, page 134.



Useful background: Tinel's sign (left) and Phalen's sign (right)

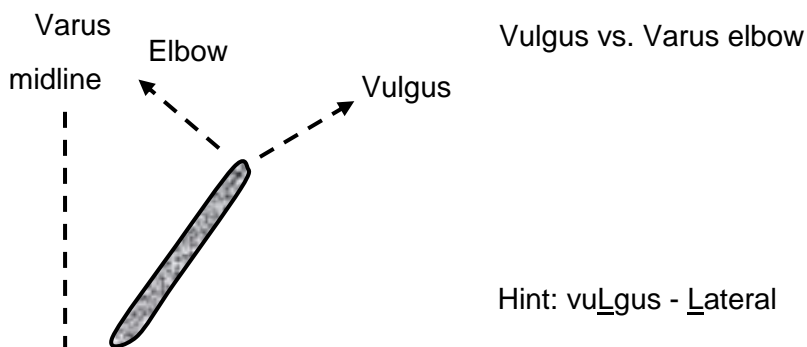


Adapted from: Mangione S. *Hanley & Belfus* 2000, page 465.

- Give a systematic approach to localized areas of translucent bone.
 - Cysts
 - Fluid
 - Fibrous tissue
 - Tumor
 - Multiple bones, fibrous tissue in cyst; "poly osteotic fibrous dysplasia"
 - Leukemia
 - Metastases
 - Thyroid
 - Bronchus
 - Breast
 - Kidney
 - Myeloma
 - Sarcoidosis
 - Histiocytosis X
- Give a systematic approach to localized areas of calcified bone (periostitis).
 - Subperiosteal bleeding
 - Trauma
 - Hemophilia
 - Leukemia
 - Associated with fracture
 - Bone infections
 - Tumors – primary, secondary
 - Pulmonary osteo-arthropathy



- Perform a focused physical examination of the wrist for rheumatoid arthritis.
 - Tendon of extensor carpi ulnaris – swelling
 - Radial ulnar ligaments – protrusion and instability of distal ulna from lax ligaments.
 - Carpal rows
 - Subluxation to dorsal side
 - Bayonet deformity



Adapted from: Mangione S. *Hanley & Belfus* 2000, pages 463, 468 and 472.

- Perform a directed physical examination of the hands for acromegaly, Marfan's syndrome, and Turner's syndrome.
 - Acromegaly – enlarged distal portion of body, with hands shaped like shovels (spades).
 - Marfan's
 - Arachnodactyly: long, thin, "spider-like" fingers
 - Marfan's thumb sign is positive normally, when the thumb is extended into the palm and the remaining 4 fingers are curled over the thumb, the fist covers the thumb; in Marfan's, the end of the thumb sticks out beyond the fifth finger (ulnar) end of the fist, Marfan's thumb sign is also positive with the hypermobile joints in Ehlers-Danlos syndrome.
 - Turner's syndrome
 - A short, inwardly dimpled fourth knuckle
 - Also seen in pseudohypoparathyroidism, and in 10% of otherwise normal persons.



SO YOU WANT TO IMPRESS YOUR STAFF!

Q1. When a person's fingers are exposed to the cold, they may become pale, then blue from the arterial vasospasm and ischemia, then with redness from reperfusion. This latter phase from a decline in the spasm and therefore ischemia may be associated with pain and paresthesia as well as the redness. In some persons (20%) no cause/ association may be found, and this progression of white-blue-red is called Reynaud's disease (i.e., Reynaud's phenomenon, with no known underlying disorder. However, the Reynaud's phenomenon may proceed a number of conditions.

- Perform a focused physical examination for the causes of Raynaud's phenomenon.

- A1. ➤ MSK
- Rheumatoid arthritis
 - Scleroderma
 - Systemic lupus erythematosus
 - Mixed connective disease
 - Dermatomyositis
 - Polymyositis
- Hematological disorders
- Cryoglobulinemia
 - Polycythemia
 - Monoclonal gammopathy
- Arterial
- Compression
 - Thoracic outlet syndrome
 - Carpal tunnel syndrome
 - Artherosclerosis
 - Vasculitis
 - Prinzmetal angina
- Drugs and toxins
- Endocrine disorders
- Hypothyroidism
 - Acromegaly
 - Addison's disease
- Pulmonary disorders
- Idiopathic pulmonary hypertension
- Neurological
- Reflex sympathetic dystrophy
- Life style
- Occupational use of percussion or vibratory tools (e.g. a jack hammer)

Q2. Young persons may be diagnosed with coarctation of the aorta, whereas in older persons aortic disease may be from dissection or obstruction from atherosclerosis. What abnormalities found on physical examination will suggest these diseases of the aorta?

- A2. ○ Asymmetry - R. vs L.arm } - Pulse strength, timing
 - Arm vs Leg } - Systolic blood pressure



SO YOU WANT TO IMPRESS YOUR STAFF!

- Q. Dupuytren's contracture (DC) is caused by thickening and flexure contraction of the palmar tendons, usually of the 4th and 5th digit (never the 1st digit, ie thumb). We all know that DC is associated with alcoholism (~40%) or alcoholic liver disease (~40%), but what other GI or non-GI conditions are commonly associated with DC?
- A. ➤ Other GI conditions
- Peptic ulcer disease
 - Cholecystitis
- Non GI conditions
- Lung – tuberculosis
– smokers
 - CNS – epilepsy
 - Endocrine – diabetic retinopathy

Elbows

Useful background: Normal ranges of motion

| Movement | Normal range of motion |
|--|------------------------|
| ➤ Forward flexion | ○ 165° |
| ➤ Backward extension | ○ 60° |
| ➤ Abduction | ○ 170° |
| ➤ Adduction | ○ 50° |
| ➤ External rotation (with elbows at sides) | ○ 70° |
| ➤ Internal rotation (with shoulder abducted to 90° & elbow flexed) | ○ 70° |

Source: Filate W, et al. *The Medical Society, Faculty of Medicine, University of Toronto* 2005, page 129.

- Perform a focused physical examination of the elbow.
- Inspection
 - Olecranon bursitis:
 - Localized cystic swelling over olecranon
 - Elbow synovitis:
 - Swelling obscures para-olecranon grooves
 - Gouty tophi; rheumatoid nodules:
 - Nodules over extensor surface of ulna



- Palpation
 - Lateral epicondylitis (“tennis elbow”): - Elbow pain and tenderness over lateral epicondyle
 - Medial epicondylitis (“golfer’s elbow”): - Elbow pain and tenderness over medial epicondyle
- Active Movement Normal range of movement (ROM)
 - Flexion - 145°
 - Extension - 0°
 - Supination - 80° from vertical (with pencil grasped in hand)
 - Pronation - 75° from vertical (with pencil grasped in hand)
 - Rotation - 180° (radio humeral)

Adapted from: Filate W, et al. *The Medical Society, Faculty of Medicine, University of Toronto* 2005, Table 3, page 132; McGee SR. *Saunders/Elsevier* 2007, Table 53-2, page 627.

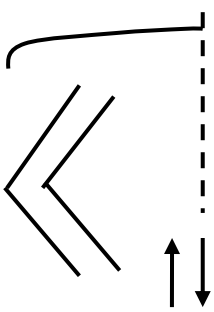
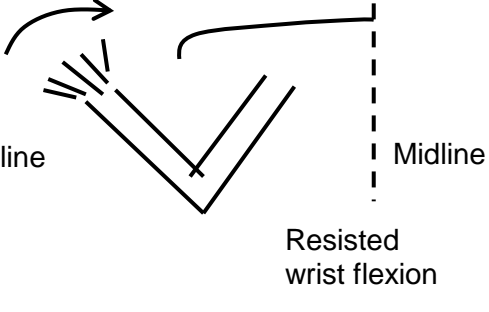
- Take a directed history and a focused physical examination for features differentiating diseases affecting the elbow.

| Clinical feature | Rheumatoid arthritis | Psoriatic arthritis | Acute gout | Osteo-arthritis | Lateral epicondylitis |
|------------------|---|--|---|-----------------------|-----------------------|
| ➤ Age | ○3-80 | ○10-60 | ○30-80 | ○50-80 | ○20-60 |
| ➤ Pain onset | ○Gradual | ○Gradual | ○Abrupt | ○Gradual | ○Gradual |
| ➤ Stiffness | ○Very common | ○Common | ○Absent | ○Common | ○Occasional |
| ➤ Swelling | ○Common | ○Common | ○Common | ○Common | ○Absent |
| ➤ Redness | ○Absent | ○Uncommon | ○Common | ○Common | ○Absent |
| ➤ Deformity | ○Flexion contractures, usually bilaterally
○Subcutaneous nodules | ○Flexion contractures, usually bilaterally
○Psoriatic nails | ○Flexion contractures, only in chronic state
○Gout tophi | ○Flexion contractures | ○None |

Permission granted: Filate W, et al. *The Medical Society, Faculty of Medicine, University of Toronto* 2005, Table 4, page 132.

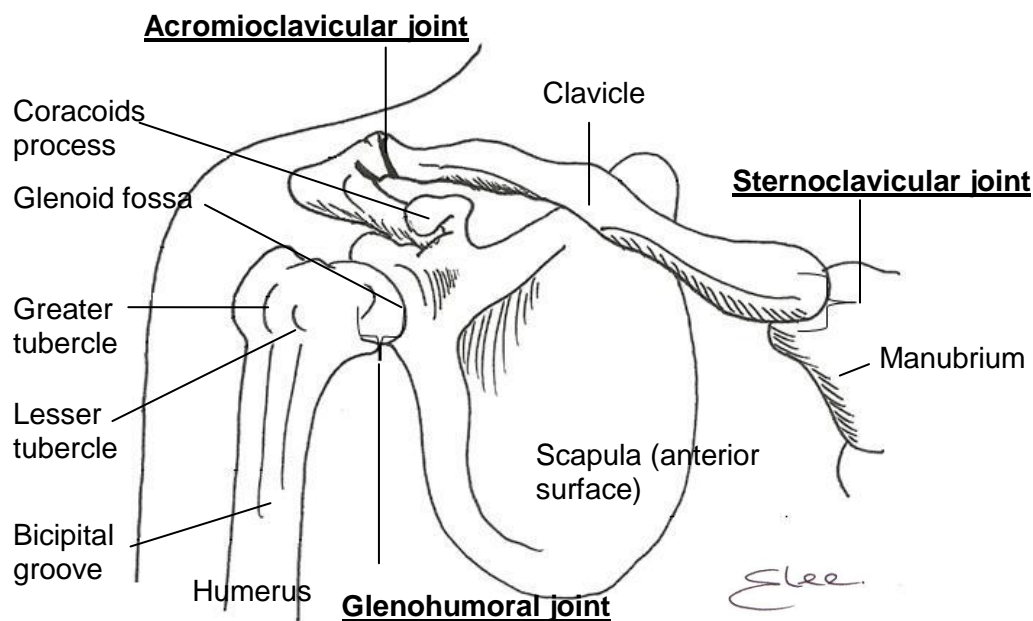


Perform a focused physical examination of the elbow to distinguish between “tennis” and golfer’s elbow.

| | Tennis | Golf |
|-------------------------|---|--|
| ○ Aka | - Lateral epicondylitis | - Lateral epicondylitis |
| ○ Site of injury | - Proximal attachment of the extensor muscles of the forearm | - Flexor attachment of muscles of forearm |
| ○ Pain, tenderness | - Lateral epicondyle | - Medial epicondyle |
| ○ Examination technique |  |  |

Shoulder

Useful background: Anatomy of the shoulder

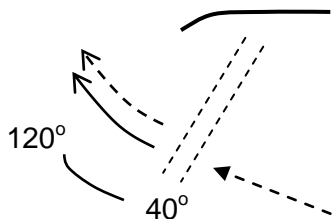


Adapted from: Filate W, et al. *The Medical Society, Faculty of Medicine, University of Toronto* 2005, Figure 1, page 129.



In the context of a painful shoulder, what is the painful arc sign?

- Tears of
 - Supraspinatus
 - (partial) rotator cuff



- Glenohumeral arthritis
- No active abduction from midline (0°): complete rotator cuff tear

Useful background: Common conditions that affect the shoulder.

- Rotator cuff tendon tear
- Rotator cuff tendinitis
- Frozen shoulder
- Biceps tendinitis
- Impingement syndrome
- Subscapular bursitis
- Glenohumeral osteoarthritis
- Acromioclavicular strain

Source: Jugovic PJ, et al. *Saunders/ Elsevier* 2004, page 184.

Useful background: Shoulder instability or labrum lesion

- Instability
 - The relocation test and the anterior release test are the most useful in diagnosing anterior instability.
 - Relocation test: PLR, 6.5
 - Anterior release test: PLR, 8.3.
 - The sulcus sign for inferior instability has a sensitivity of 31% and a specificity 89%
 - The apprehension test is of limited value due to low specificity.

Useful background: The shoulder

- The impingement syndrome is the impingement of the supraspinatus tendon between the greater tuberosity of the head of the humerus and the undersurface of the acromion and acromioclavicular joint. There is a painful arc felt between 90° and 130° , and tenderness with palpation of the rotator cuff. The impingement syndrome is often due to osteophytes under the acromion



- The apprehension test is used to identify anterior shoulder dislocations. The patient's affected arm is abducted and externally rotated until a look of apprehension is noted if the shoulder is dislocatable. The shoulder has a "squared off" appearance, with reduction of internal rotation and possible loss of sensation and contraction over the lateral deltoid muscle. The causes of posterior shoulder dislocation include:
 - Epileptic seizures
 - Ethanol intoxication,
 - Electrolution/electroshock therapy
 - Encephalitis.
- Perform a focused physical examination of the shoulder.
 - Inspection
 - Swelling
 - Flattening aspect of shoulder; anterior dislocation
 - Erythema
 - Swelling over anterior aspect; glenohumeral synovitis; synovial cyst
 - Assymetry/atrophy
 - Deformity
 - Skin changes
 - Palpation
 - Tenderness
 - Temperature
 - Edema
 - Crepitus
 - Biceps groove
 - Subdeltoid bursa
 - Passive and active movement
 - Normal ranges of motion (ROM)

| Movement | Normal ROM |
|--|------------|
| ➤ Forward flexion | 165° |
| ➤ Backward flexion | 60° |
| ➤ Abduction | 170° |
| ➤ Adduction | 50° |
| ➤ External rotation (with elbows at sides) | 70° |
| ➤ Internal rotation (with shoulder abducted to 90° & elbow flexed) | 70° |



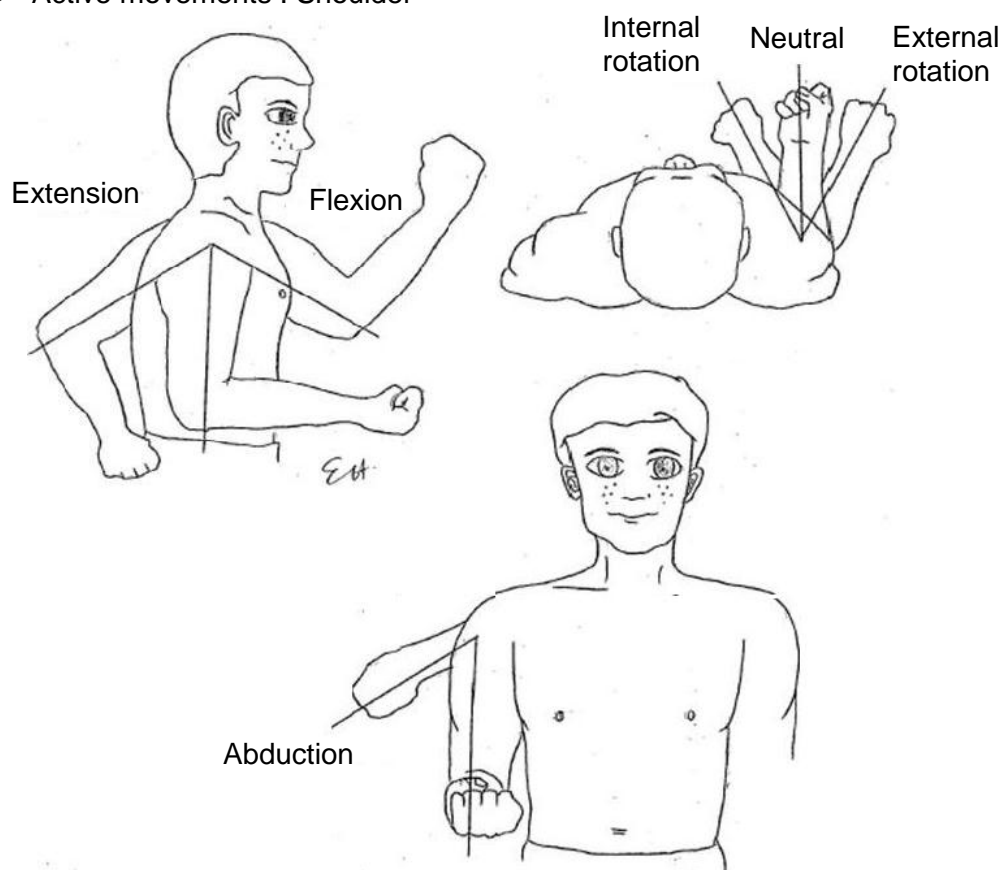
One way to test for limitations of passive motion is to ask the patient to bend over and try to touch his or her toes. In those with normal shoulder passive motion, the arms dangle toward the floor.

Abbreviation: ACJ, acromioclavicular joint; ROM, ranges of motion

Adapted from: McGee SR. *Saunders/Elsevier*, 2007, Table 53-3, page 629; Filate W, et al. *The Medical Society, Faculty of Medicine, University of Toronto*, 2005, Table 1, page 129.

Useful background:

➤ Active movements : Shoulder

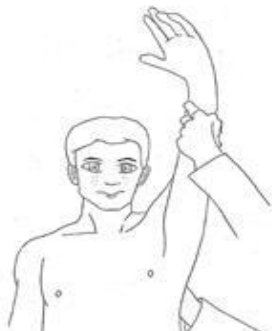

Adapted from: Talley NJ, et al. *MacLennan & Petty Pty Limited* 2003, page 271.

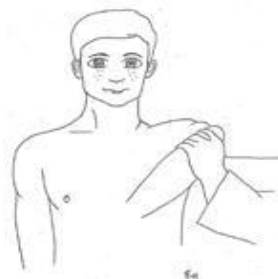

➤ Passive movements

Neer impingement sign



Hawkins impingement sign

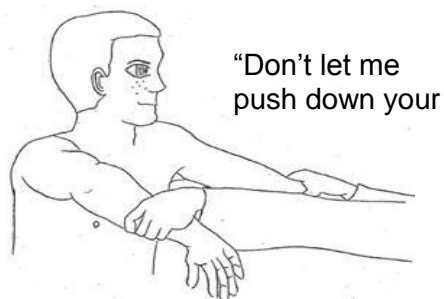


Adapted from: McGee SR. *Saunders/Elsevier* 2007, Figures 53-1 and 53-2, pages 630 and 631.

Yergason's sign



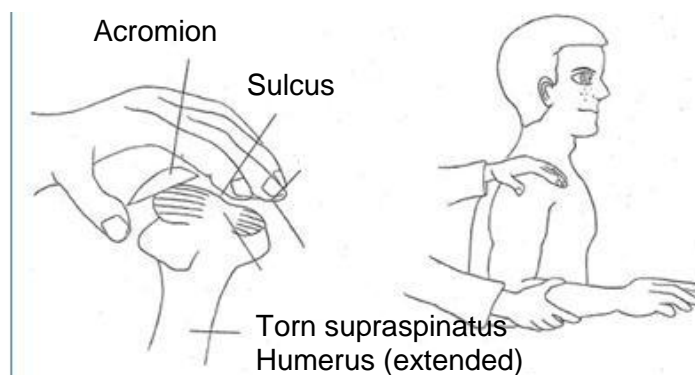
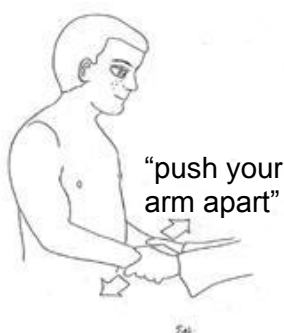Supraspinatus test



The "supraspinatus test" is also known as the "empty can" or "Jobe" test.

Adapted from: McGee SR. *Saunders/Elsevier* 2007, Figures 53-3 and 53-4, pages 631 to 633.

➤ Special tests



Adapted from: McGee SR. *Evidence Saunders/Elsevier* 2007, Figures 53-5 and 53-6, pages 634 and 635.



- Range of motion
 - Active and passive ROM for
 - Flexion/extension
 - Abduction/adduction
 - Internal/external rotation
- Special maneuvers
 - Apprehension test

Source: Filate W., et al. *The Medical Society, Faculty of Medicine, University of Toronto* 2005, Table 1, page 129.

Useful background: Common clinical conditions of the shoulder

| Condition | Clinical features |
|-----------------------------|--|
| ➤ Rotator cuff tendinitis | <ul style="list-style-type: none"> ○ Shoulder pain on activity ○ Sharp pain on elevation of arm into overhead position ○ History of chronic usage (e.g. throwing, swimming) or trauma |
| ➤ Rotator cuff tear/rupture | <ul style="list-style-type: none"> ○ Sharp pain after trauma ○ Pain over greater tuberosity ○ Characteristic shoulder shrug ○ Pain on attempted abduction ○ Weakness on external rotation |
| ➤ Bicipital tendinitis | <ul style="list-style-type: none"> ○ Generalized anterior tenderness over long head of biceps ○ Pain, especially at night ○ Reproduction of anterior shoulder pain during resistance to forearm supination |

Adapted from: Filate W, et al. *The Medical Society, Faculty of Medicine, University of Toronto*, 2005, Table 2, page 131.

Impress the staff Rheumatologist!

- Shoulder pain (radiating down the arm to the elbow) when combing one's hair, putting on a coat or reaching into a back pocket, indicates supraspinatus inflammation.
- Diffuse shoulder pain upon moving the humerus posteriorly (without radiation to the arm) indicates infraspinatus inflammation.

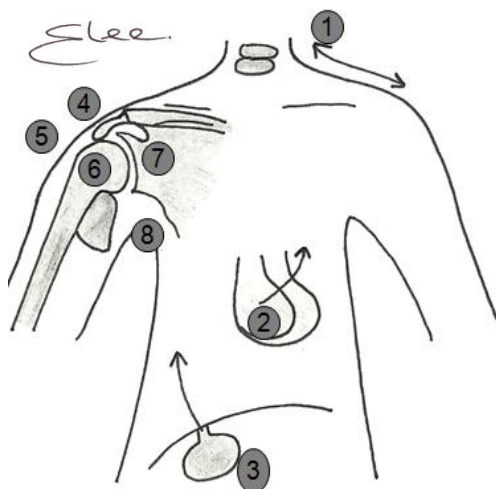
Source: Filate W, et al. *The Medical Society, Faculty of Medicine, University of Toronto* 2005, page 130.



- Perform a focused physical examination for causes of shoulder pain.

Useful background: Pain in the shoulder

- Referred pain
 1. Cervical spine
 - Up to neck
 - +/- down into forearm + hand
 2. Myocardial infarction
 3. Diaphragmatic irritation
- Local causes
 4. Points of shoulder: ACJ joint arthritis
 5. Supraspinatus tendinitis (painful mid-arc)
 - Capsular syndromes
 - Acute bursitis
 - Subacromial syndromes
 6. Subacromial bursitis
 7. Glenohumeral arthritis
 8. Bicipital tendinitis



“Science, like good diagnosis, represents incremental progress of small steps taken slowly on solid ground.”

Grandad



| Palpation diagnosis | Finding/ Range of passive motion |
|---|--|
| <ul style="list-style-type: none"> ➤ Capsular syndromes <ul style="list-style-type: none"> ○ Adhesive capsulitis ○ Glenohumeral arthritis ➤ Acute bursitis ➤ Acromioclavicular joint (ACJ) pain | <ul style="list-style-type: none"> - All motions limited (especially external rotation and abduction) - Abduction limited - Normal - Tenderness of ACJ, especially - Tenderness with compression of ACJ - Pain worse during adduction of arm across body |
| <ul style="list-style-type: none"> ➤ Subacromial syndromes <ul style="list-style-type: none"> ○ Rotator cuff tendonitis | <ul style="list-style-type: none"> - Shoulder pain on activity - Sharp pain on elevation of arm into overhead position - History of chronic usage (e.g. throwing, swimming) or trauma - Sharp pain after trauma - Pain over greater tuberosity - Characteristic shoulder shrug and pain on attempted abduction |
| <ul style="list-style-type: none"> ○ Rotator cuff tear | <ul style="list-style-type: none"> - Painful arc - Weakness on external rotation - Hawkin's impingement sign - Neer's impingement sign - Supraspinatus test - Atrophy - Weakness - Infraspinatus weakness, atrophy - Dropped arm test - Palpable tear |
| <ul style="list-style-type: none"> ➤ Bicipital tendinitis | <ul style="list-style-type: none"> - Generalized anterior tenderness over long head of biceps - Associated with pain, especially at night - Hallmark is reproduction of anterior shoulder pain during resistance to forearm supination |

Abbreviation: ACJ, acromioclavicular joint

Adapted from: Jugovic PJ, et al. *Saunders/ Elsevier* 2004, page 183; McGee SR. *Saunders/Elsevier* 2007, Table 53-3, page 629.



Useful background:

- Tests for anterior shoulder instability
 - Anterior apprehension test – limited value due to low specificity
 - Relocation test
 - With patient supine, patient's arm is passively abducted to 90°, elbow is flexed to 90° and arm is externally rotated 90°. Examiner applies downward (posterior) pressure to humeral head. Relief of symptoms of apprehension or pain is a positive result.
 - PLR, 6.5
 - Anterior release test
 - The relocation test is performed, and the examiner's hand is suddenly removed from the proximal humerus. Expression of apprehension or pain is a positive result.
 - PLR, 8.3

- Test for inferior shoulder instability (Sulcus sign)
 - The patient stands or sits with the arm by the side and shoulder muscles relaxed
 - The arm is pulled vertically downward.
 - The presence of a sulcus sign (indentation between acromion and humeral head) is suggestive of inferior shoulder instability
 - Sensitivity, 31%; specificity, 89%

- Tests for anterior shoulder instability
 - With the patient supine, the arm is abducted to 90° and the humerus is maximally internally rotated.
 - Examiner applies downward (posterior) pressure to humeral head
 - Apprehension by the patient is a positive result and indicates posterior instability

- Labrum lesion: sensitivities of $\geq 83\%$, specificities of $\geq 90\%$
 - The biceps load I and II tests
 - The pain provocation test
 - The internal rotation resistance strength test

Adapted from: Filate W, et al. *The Medical Society, Faculty of Medicine, University of Toronto* 2005, pages 129 and 130.

Useful background: Performance characteristics for detecting rotator cuff tendonitis and tear

Neither the Neer's nor the Hawkins's impingement sign, the supraspinatus test causing pain, infraspinatus weakness, or the painful arc sign are clinically significant to diagnose rotator cuff tendonitis or rotator cuff tear, or have a positive likelihood ratio (PLR) > 2.0 .



| Finding | PLR |
|---|------|
| ➤ Detecting rotator cuff tendonitis | |
| ○ Yergason's sign | 2.8 |
| ➤ Detecting rotator cuff tear-individual findings | |
| ○ Age | |
| - ≥ 60 years | 3.2 |
| ○ Supraspinatus atrophy | 2.0 |
| ○ Infraspinatus atrophy | 2.0 |
| ○ Supraspinatus weakness | 2.0 |
| ○ Dropped arm test | 5.0 |
| ○ Palpable tear | 10.2 |
| ➤ Detecting rotator cuff tear – Combined findings | |
| - 3 findings | 48.0 |
| - 2 findings | 4.9 |

*Note: findings with PLR < 2 are outlined, include

- Neer's impingement sign
- Hawkin's impingement sign
- Supraspinatus testing causes pain
- Infraspinatus weakness
- Painful arc

Adapted from: McGee SR. *Saunders/Elsevier* 2007, Box 53-1, pages 636 and 637.

What's "the best"? The "best" clinical test for the presence of rotator cuff tendonitis is a positive Yergason's sign; The "best" clinical tests for the presence of a rotator cuff tear are a palpable tear, a positive dropped arm test, and age ≥ 60 years.

SO YOU WANT TO BE A RHEUMATOLOGIST!

- Q. Examination of the shoulder demonstrates a painful arc, suggesting a subacromial syndrome. Perform a focused physical examination to distinguish rotator cuff tear from tendonitis.
- A.
- Tear – weak cuff muscle strength
 - Tendonitis – normal cuff muscle strength



- Perform a focused physical examination for shoulder syndromes

| Syndrome | Location of pain | Range of passive motion | Other findings |
|---|---------------------|---|---|
| <ul style="list-style-type: none"> ➤ Capsular syndromes <ul style="list-style-type: none"> ○ Adhesive capsulitis ○ Glenohumeral arthritis | - Outer arm | - Limited (all motions limited, especially external rotation and abduction) | |
| <ul style="list-style-type: none"> ➤ Acute bursitis | - Outer arm | - Limited (Abduction especially limited) | |
| <ul style="list-style-type: none"> ➤ Acromioclavicular pain | - Point of shoulder | - Normal | - Tenderness of acromioclavicular joint |

Spine

- Take a directed history of back pain.
- History
 - Case – pain
 - How, when, where, why, what is quality of life
 - Complications
 - Fever, chills, night sweats
 - Anorexia, weight loss
 - Fatigue
 - Bowel bladder symptoms (retention, incontinence)
 - Nerve compression (sensory, motor, erectile dysfunction)
 - Scanda equine syndrome
- Causes
 - Joint
 - Inflammation, seropositive, seronegative
 - Bone
 - Infection, osteomyelitis, TB, immunosuppression
 - Inflammation
 - Pancreatitis, prostatitis, endometriosis, pyelonephritis
 - Malignancy
 - 1°, 2° (pancreas, prostate)
 - Metabolic
 - Osteoporosis, Paget's, fracture
 - Blood vessels
 - AAA rupture

Adapted from: Jugovic PJ, et al. *Saunders/ Elsevier*, 2004, page 110.



Useful background: Red flags that may indicate potential serious etiology of low back pain.

- Age > 50 years
- History of recent bacterial infections, malignancies, trauma, or inflammatory disease
- Bowel or bladder dysfunction
- Saddle anesthesia
- IV drug use
- Chronic disease
- Neurological deficits

Source: Jugovic P.J., et al. *Saunders/ Elsevier* 2004, page 113.

Useful background: “Red Flag” symptoms/signs in assessment of low back pain

| Condition | Symptoms/Signs |
|------------------------------|--|
| ➤ Cancer | <ul style="list-style-type: none"> ○ Age >50 ○ Previous cancer history ○ Unexplained weight loss ○ Failure to improve after 1 month therapy |
| ➤ Cauda Equina Syndrome | <ul style="list-style-type: none"> ○ Acute urinary retention or overflow incontinence ○ Loss of anal sphincter tone/fecal incontinence ○ Perineal numbness ○ Change in sexual function ○ Weakness of legs |
| ➤ Epidural abscess | <ul style="list-style-type: none"> ○ Intravenous drug abuse or sources of infection ○ Local or radicular pain unrelieved by position change ○ Fever ○ Sensory loss ○ Paraparesis or quadriparesis ○ Bowel/bladder impairment |
| ➤ Herniated Nucleus Pulposus | <ul style="list-style-type: none"> ○ Positive SLR (leg pain at <60°) ○ Weak dorsiflexion of ankle (L4-5) or great toe (L5-S1 or L4-5) ○ Reduced ankle reflex (L5-S1) ○ Reduced light touch in L4, L5 or S1 dermatomes of foot/leg |



| Condition | Symptoms/Signs |
|--|---|
| ➤ Spinal Fracture/Compression Fracture | <ul style="list-style-type: none"> ○ Age >50 ○ Female gender ○ Major trauma ○ Pain and tenderness ○ Distracting painful injury ○ Also consider a history of osteoporosis or corticosteroid use |
| ➤ Spinal Osteomyelitis | <ul style="list-style-type: none"> ○ Intravenous drug abuse ○ Sources of infection (e.g., skin, teeth, urinary tract or indwelling catheter) ○ Fever ○ Vertebral tenderness |

Abbreviations: MRI = magnetic resonance imaging; SLR = straight leg raising

Reproduced with permission: Therapeutics Choices. Sixth Edition. Ottawa, Canada: *Canadian Pharmacist Association* 2012, Table 1, page 1095.

- Perform a focused physical examination of back pain.
 - Inspection
 - Symmetry; deformity
 - Lordosis
 - Kyphosis
 - Scoliosis
 - Trauma, scars
 - Inflammation
 - Edema
 - Palpation
 - Tenderness
 - Spinous processes
 - Paraspinal
 - Range of motion
 - Flexion, extension, lateral flexion, rotation
 - Chest expansion
 - Nerve compression
 - Straight leg raising
 - (L4,5; S1,2,3)
 - L4 medial calf, knee jerk, squat and rise
 - L5 first web space, heel walk
 - S1 lateral foot, ankle jerk, toe walk
 - Pulses/bruits
 - Femoral, popliteal, dorsalis pedis

Source: Jugovic PJ, et al. *Saunders/ Elsevier* 2004, pages 111 and 112.

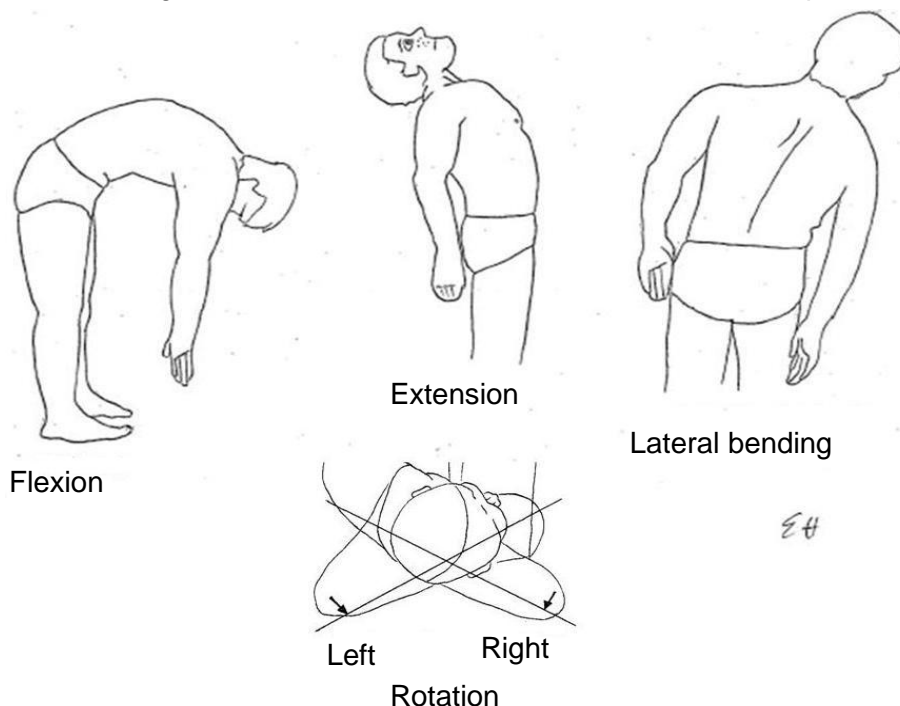


Useful background: Cervical spine movements and their respective myotomes

| Movement | Myotome |
|--|---------|
| ➤ Neck flexion | C1-C2 |
| ➤ Neck side flexion | C3 |
| ➤ Shoulder elevation | C4 |
| ➤ Shoulder abduction | C5 |
| ➤ Elbow flexion and/ or wrist extension | C5 |
| ➤ Elbow extension and/ or wrist flexion | C7 |
| ➤ Thumb extension and/ or ulnar deviation | C8 |
| ➤ Abduction and/ or adduction of hand intrinsics | T1 |

Source: Filate W, et al. *The Medical Society, Faculty of Medicine, University of Toronto* 2005, page 138.

Useful background: Active movements of the thoracolumbar spine



Adapted from: Talley NJ, et al. *MacLennan & Petty Pty Limited* 2003, Figure 8.22, page 277.



Useful background:

- Active movements of the cervical spine and their normal range of motion.

| Maneuver | Normal ROM |
|--|------------|
| ➤ Flexion (“touch your chin to your chest”) | ➤ 80-90° |
| ➤ Extension (“put your head back”) | ➤ 70° |
| ➤ Side flexion* (“touch each shoulder with your ear without raising your shoulders) | ➤ 20-45° |
| ➤ Rotation* (“turn your head to the left and right”; Look for symmetrical movements) | ➤ 70-90° |

Abbreviation: ROM, range of motion.

Source: Filate W, et al. *The Medical Society, Faculty of Medicine, University of Toronto* 2005, Table 11, page 138.

Common causes of kyphoscoliosis

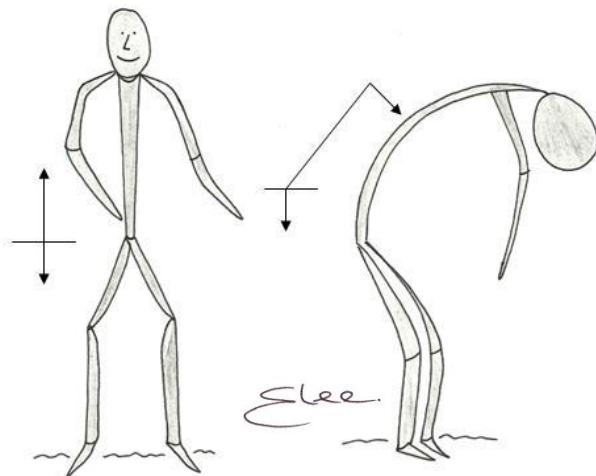
- Idiopathic
- Rib cage
 - Thoracoplasty
 - Empyema
- Connective tissue
 - Marfan syndrome
 - Ehlers-Danlos syndrome
 - Morquio syndrome
- Spine
 - Osteoporosis
 - Osteomalacia
 - Vitamin D-resistant rickets
 - Tuberculous spondylitis
 - Neurofibromatosis
- Neuromuscular
 - Muscular dystrophy
 - Poliomyelitis
 - Cerebral palsy
 - Friedreich ataxia

Adapted from: Mangione S. *Hanley & Belfus* 2000, page 283.



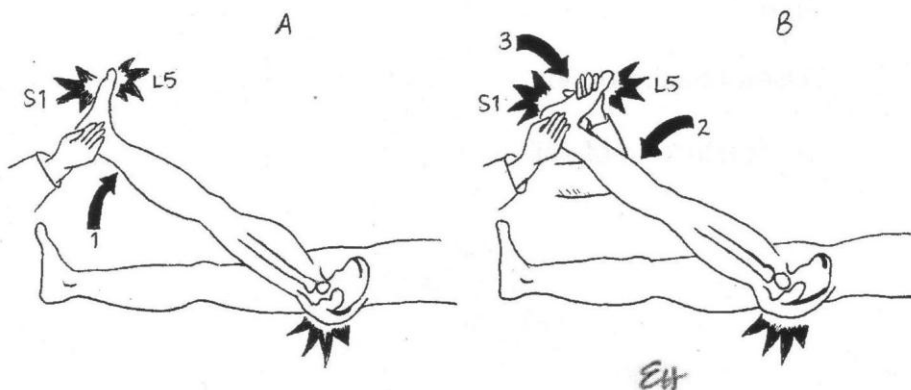
Useful background: Special tests of back movement

➤ Restriction of spinal movement



| Movement and instructions | ROM | |
|---|--------|--------|
| | T | L |
| ➤ Forward flexion: ("Bend forward and touch your toes") | 20-45° | 40-60° |
| ➤ Extension: (Arch your back") | 25-45° | 20-35° |
| ➤ Side flexion: ("Slide your hand down your leg") | 20-40° | 15-20° |
| ➤ Rotation: (twist toward each side") | 35-50° | 3-18° |
| ➤ Chest expansion: (with a tape measure) | > 5 cm | N/A |
| ➤ Schober's test <ul style="list-style-type: none"> ○ In health an increase from 15 to 22 cm is seen on forward flexion measured above (10 cm standing) and below (5 cm) a line drawn between the dimples of Venus. ○ In those with decreased spinal flexibility the distance measured increases to < 22 cm. | | |
| ➤ Lumbar vertebral fractures <ul style="list-style-type: none"> ➤ A rib-pelvis distance value < 2 fingerbreadths had a good sensitivity (87%) and moderate specificity (47%) for lumbar vertebral fracture ➤ Straight leg raising test for lumbar disc herniation | | |





- Diagnostic value of this straight-leg raising test in detecting lumbar disc herniation may lie primarily in ruling out its presence, because sensitivity (0.8) is far greater than specificity (0.4).
- However, the crossed **straight** leg raise test (positive result = reproduction of contralateral pain with elevation and abduction of unaffected leg) identified lumbar disc herniation with a sensitivity of 25% and a specificity of 90% in patients with sciatica.

Adapted from: Filate W, et al. *The Medical Society, Faculty of Medicine, University of Toronto* 2005, Table 13, page 140; Figure 3, page 142 and 143.

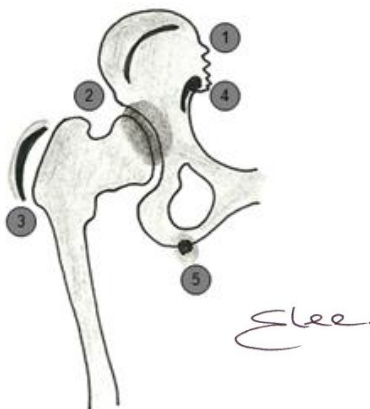- Causes of lower back symptoms
 - Degenerative
 - Disk herniation
 - Infiltrative
 - Primary, metastatic
 - Inflammatory
 - Seronegative/spondyloarthropathies
 - Prostatitis, endometriosis, pyelonephritis, pancreatitis
 - Infectious
 - Osteomyelitis, TB
 - Metabolic
 - Osteoporosis with fractures
 - Osteomalacia
 - Paget's disease
 - Compression
 - Cauda equine syndrome
 - Abdominal aortic aneurysm
 - Neurological deficits of cauda equine syndrome
 - Saddle anesthesia
 - Decreased anal tone or perianal sensory loss
 - Fecal incontinence
 - Urinary retention
 - Severe or progressive neurological deficit



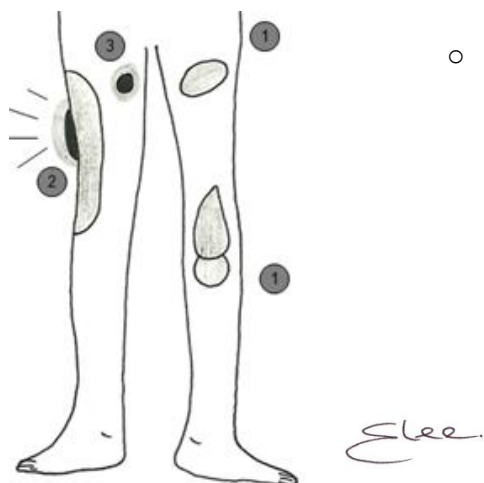
Adapted from: Filate W, et al. *The Medical Society, Faculty of Medicine, University of Toronto* 2005, page 137; Jugovic PJ, et al. *Saunders/ Elsevier* 2004, page 110.

Hips

Useful background: Pain in the hip



- Structures giving rise to pain around the hip and buttocks
 1. Sacro-iliac joint
 2. Hip joint (OA, RA, sepsis)
 3. Trochanteric bursa (overuse, mechanical imbalance)
 4. Ischiogluteal bursa (posterior)
 5. Insertion of adductor tendon



- Patterns of pain around the hip
 1. Intrinsic hip or knee joint pain
 2. Trochanteric bursitis
 3. Adductor tendinitis

- Compensatory postures that might be seen in an examination of the hip if there is:
 - A scoliotic deformity - flexion of the longer leg
 - An abduction deformity - flexion of ipsilateral knee
 - An adduction deformity - flexion of contralateral knee
 - A flexion deformity - exaggerated lordosis.

Source: Jugovic PJ, et al. *Saunders/ Elsevier* 2004, page 171.



Useful background:

- Radiation of pain (Where is the pain felt in the following conditions?)
 - Osteoarthritis → to groin
 - Bursitis → superior margin of the greater trochanter
 - Sacroiliitis → sacroiliac joint
- Compensatory postures of the lower leg, knee or spine if there are associated deformities
 - A scoliotic deformity - flexion of the longer leg
 - An abduction deformity - flexion of ipsilateral knee
 - An adduction deformity - flexion of contralateral knee
 - A flexion deformity - exaggerated lordosis.

Adapted from: Jugovic PJ, et al. *Saunders/ Elsevier* 2004, page 171.

Useful background:

- Maneuvers for the hip and normal range of motion

| Maneuver | Normal ROM |
|---|--|
| ○ Flexion – with patient lying supine, have patient pull knee to chest; knee is also flexed | - 120° |
| ○ Extension – with patient lying on side, palpate the ASIS and PSIS and have patient fully extend the leg until pelvis shifts | - 15° |
| ○ Abduction – place one hand on the contralateral ASIS and with the other hand, grasp the heel and abduct the patient's leg until the pelvis shifts | - 40° |
| ○ Adduction – place one hand on the ipsilateral ASIS and with the other hand, grasp the heel and adduct the patient's leg until the pelvis shifts | - 25° |
| ○ Rotation – flex knee and hip to 90°, grasp the lower leg and move medially (external rotation) and laterally (internal rotation) | - External rotation in ext -35°
- External rotation at 90°
- Flex -45°
- Internal rotation in ext: -45° |
| ○ Or with patient lying supine with the leg fully extended, roll the leg medially and laterally | - Internal rotation at 90°
- Flex -45° |

Abbreviation: ROM; range of motion

Source: Filate W, et al. *The Medical Society, Faculty of Medicine, University of Toronto* 2005, page 145.



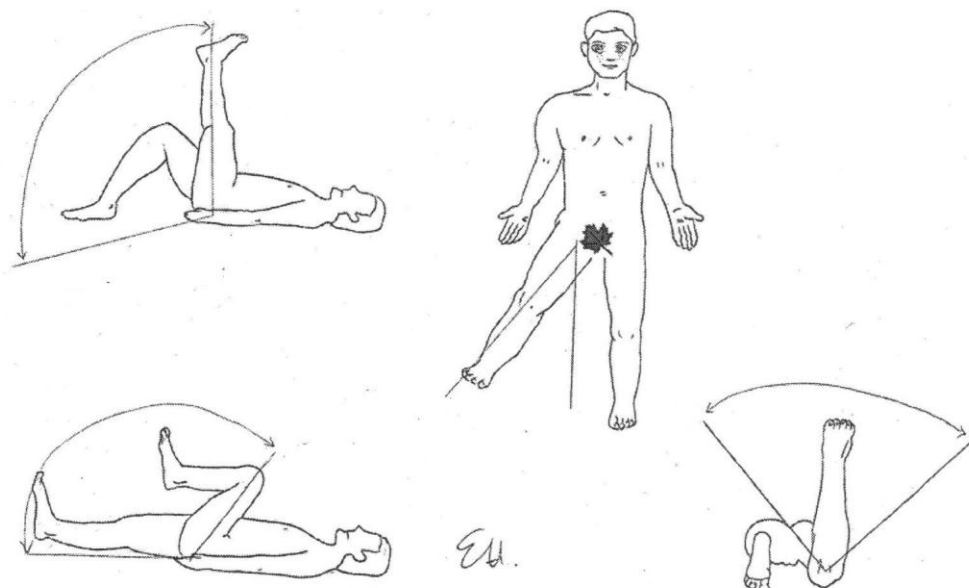
Useful background: Lower limb movements and their respective myotomes

| Lower limb movement | Myotome |
|--|---------|
| ➤ Hip flexion | ○ L2 |
| ➤ Knee extension | ○ L3 |
| ➤ Ankle dorsiflexion | ○ L4 |
| ➤ Great toe extension | ○ L5 |
| ➤ Ankle plantar flexion, ankle eversion, hip extension | ○ S1 |
| ➤ Knee flexion | ○ S2 |

Source: Filate W, et al. *The Medical Society, Faculty of Medicine, University of Toronto* 2005, Table 14, page 141.

Useful background:

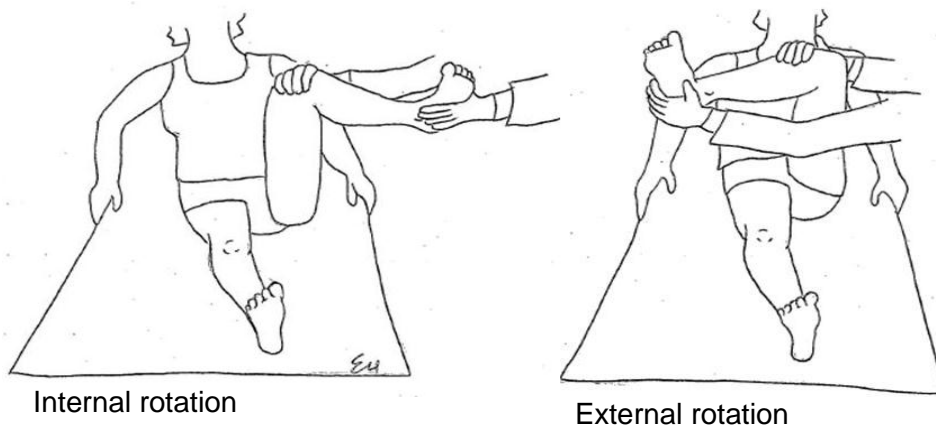
- Normal ROM of hip



Adapted from: Talley NJ, et al. *MacLennan & Petty Pty Limited* 2003, Figure 8.23, page 279.



Useful background: Internal and external rotation of the hip



Adapted from: Talley NJ, et al. *MacLennan & Petty Pty Limited* 2003, Figure 4, page 145; and Filate W, et al. *The Medical Society, Faculty of Medicine, University of Toronto* 2005, page 145.

SO YOU WANT TO BE A RHEUMATOLOGIST!

Q1. In the context of a screening physical examination for hip disease, what is the FABER maneuver?

A1. The FABER maneuver is the movement of the hip so that it is Flexed, ABducted, and Externally Rotated. The lateral aspect of the leg should then be able to lay.

Q2. In the context of redness and swelling of the calf of one leg, what is the “crescent sign”, and what diagnosis does it suggest?

A2. If there is crescent-shaped bruising of the calf from the medial to the lateral malleolus, they likely have pseudothrombophlebitis from a ruptured cyst.

Q3. While on a camping trip in Europe, a gentleman develops an annular rash. He returns home to North Overshore, and six weeks later he develops. What is the likely etiology?

- A3.
- Lyme disease, and the confirmatory test is an antibody titre against *Borrelia burgdorferi*.
 - A painful knee joint and a unilateral facial nerve (CN VII) palsy six weeks after developing an annular rash after a camping trip in Europe



- Perform a focused physical examination for gluteal muscle weakness.
 - Trendelenburg's sign (TS)
 - Stand on one leg, the pelvis on the other side normally becomes elevated
 - TS is positive with lack of elevation or sagging of buttock.
 - Trendelenburg's gait
 - Weakness/ paralysis of gluteal muscles causing awaddling gait (common in progressive muscular dystrophy)

Adapted from: Mangione S. *Hanley & Belfus* 2000, page 472.

Knees

Useful background: The common causes of a painful knee joint

- Musculoskeletal
 - Rheumatoid arthritis
 - Osteoarthritis
 - Gout
 - Pseudogout
- Infection
 - Viral infection
 - Septic arthritis
 - *Borrelia burgdorferi*
- Metabolic
 - Gout
 - Pseudogout
- Hematology
 - Hemophilia
- Trauma

Adapted from: Baliga RR. *Saunders/Elsevier* 2007, pages 344 and 345.

SO YOU WANT TO BE A RHEUMATOLOGIST!

Q. In the context of a painful knee joint, what is Lyme disease?

A. Lyme disease causes painful knee, skin rash and unilateral CN VII (facial nerve) paralysis due to an infection with *Borrelia burgdorferi*



- Perform a directed physical examination of the knee.
- Inspection
 - For symmetry, deformity, genu valgum or varum, rubor, swelling, quadriceps, atrophy (assess with tape)
 - Skin bruising and any abnormal movements used to compensate for pain/stiffness in knee joint
 - Assess gait
 - Assess standing, feet together (hip, knee, ankle in straight line)
- Palpation – Flex knee for best assessment
 - Joint line and along course of medial and lateral collateral ligaments, tibial tubercle and intrapatellar tendon, bursal areas including anserine, prepatellar and infrapatellar popliteal fossa (for cyst, etc)
 - Tenderness at 90°, 180°
 - Flexion, 135°; extension, 0°
 - Warmth
 - Popliteal fossa Baker's cyst
 - Swelling of patella
 - Crepitation
 - Knee should be flexed for best assessment
 - Effusions
 - Temperature
 - Wipe test
 - Ballotment
 - Fluid displacement sign
 - Patellar tap
 - Bulge sign/fluid displacement sign
 - Balloon sign.fluctuation test
- Active and passive ROM: flexion/extension
- Stability (ligaments)
 - Anterior and posterior cruciate draw test
 - Collateral and medial collateral ligament stability
- Provocative tests
 - Meniscal tests (McMurray's/Apley's), as well as apprehension test and femoral-patellar grind test
 - Anterior drawer test (anterior cruciate ligament)
 - Pivot shift test

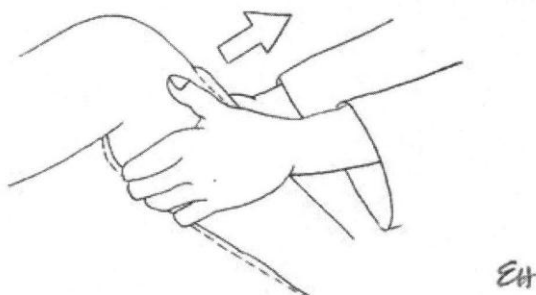
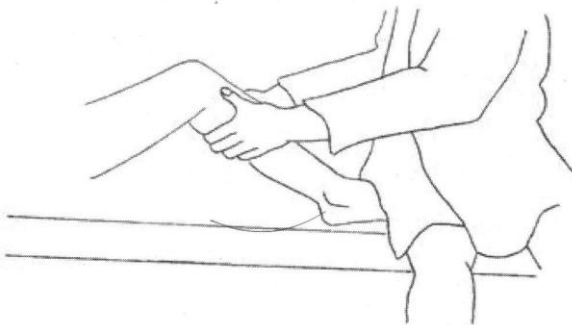


- Posterior drawer test (posterior cruciate ligament)
 - Stability of lateral and medial collateral ligaments
- Menisci
- Crouch compression test

Adapted from: Filate W, et al. *The Medical Society, Faculty of Medicine, University of Toronto* 2005, page 147; Jugovic PJ, et al. *Saunders/ Elsevier* 2004, page 175; McGee SR. *Saunders/Elsevier* 2007, Table 53.2, pages 626 and 627.

What is “the best”? The three “best” clinical tests for osteoarthritis of the knee in a person with chronic pain are bony enlargement, varus (not valgus)

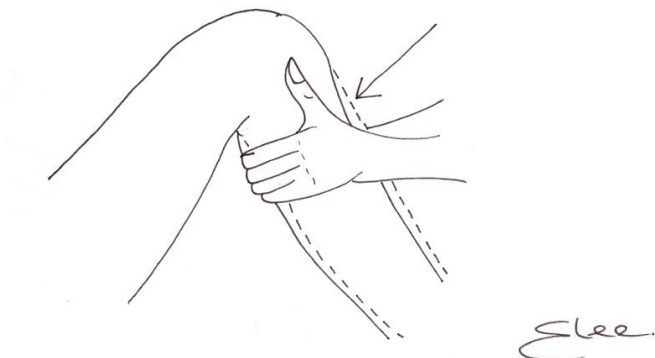
- Anterior drawer sign



Adapted from: McGee SR. *Saunders/Elsevier* 2007, Figure 53.7, page 641.



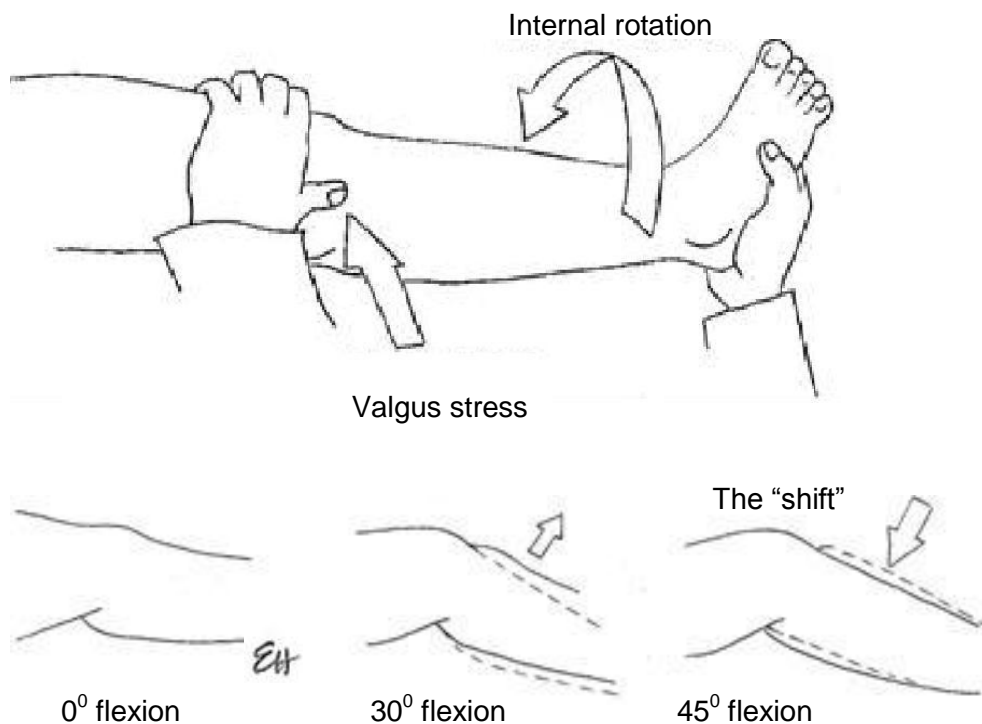
- Posterior anterior drawer sign



With the patient positioned as for the anterior drawer sign, the clinician pushes posteriorly on the patient's upper calf. In the PCL-deficient knee, this force reveals an abnormal posterior tibial movement (arrow) with a soft endpoint

Adapted from: McGee SR. *Saunders/Elsevier* 2007, Figure 53.11, page 646.

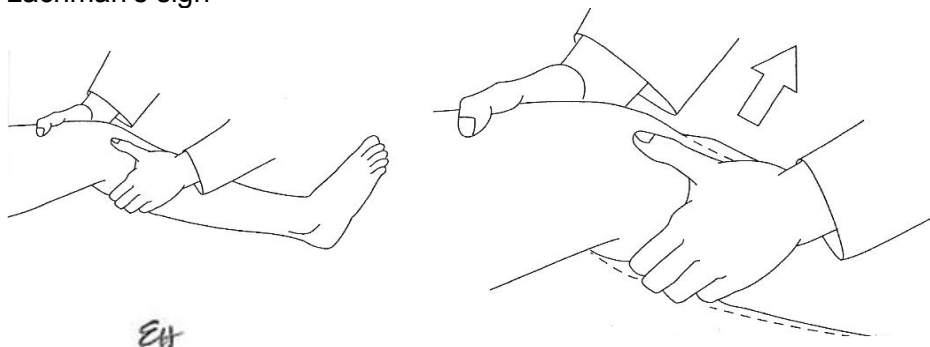
- Pivot shift sign



Adapted from: McGee SR. *Saunders/Elsevier* 2007, Figure 53.9, page 643.

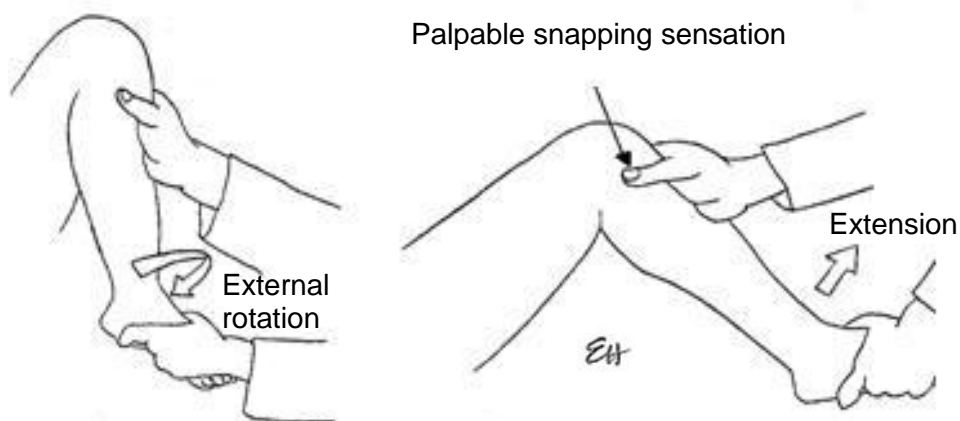


Lachman's sign



Adapted from: McGee SR. *Saunders/Elsevier* 2007, Figure 53.8, page 642.

- The McMurray test



Adapted from: McGee SR. *Saunders/Elsevier* 2007, Figure 53.2, page 647.

Useful background: Performance characteristics of physical examination for detecting anterior cruciate ligament rupture or tear

| Finding | PLR |
|--|------|
| ➤ Detecting anterior cruciate ligament rupture or tear | |
| ○ Lachman's sign | 17.0 |
| ○ Anterior drawer sign | 11.5 |
| ○ Pivot shift sign | 8.0 |
| ➤ Detecting meniscal injury | |
| ○ McMurray sign | 8.2 |
| ○ Block to full extension | 3.2 |

Abbreviation: PLR, positive likelihood ratio

Note that joint line tenderness does not have significant values for PLR/ NLR.

Adapted from: McGee SR. *Saunders/Elsevier* 2007, Box 53-4, page 651.



What is “the best”? The three “best” clinical tests for the presence of an anterior cruciate ligament tear are a positive Lachman’s sign, anterior drawing sign, and pivot shift sign.

What is “the best”? The three “best” tests of physical examination for clinically significant knee fracture are an inability to flex the knee beyond 90°, inability to bear weight, and tenderness at the head of the fibula.

Useful background: Performance characteristics of physical examination for clinically significant knee fracture.

| Finding | LR+ |
|---|-----|
| ○ Age \geq 55 years | 3.0 |
| ○ Joint effusion | 2.5 |
| - Limitation of knee flexion; | |
| ▪ Not able to flex beyond 90 degrees | 2.9 |
| ▪ Not able to flex beyond 60 degrees | 4.7 |
| ○ Isolated tenderness of patella | 2.2 |
| ○ Tenderness at head of fibula | 3.4 |
| ○ Inability to bear weight, immediately and in emergency department | 3.6 |
| ➤ Combined findings | |
| ○ Ottawa knee rule* positive | 1.7 |

* Ottawa rule for knee fracture: A knee radiograph is indicated (and the rule is positive) if any of the following are present:

- Age 55 years or older
- Tenderness at head of fibula
- Isolated tenderness of patella (no bone tenderness of knee other than patella)
- Inability to flex to 90 degrees



- Inability to bear weight both immediately and in the emergency department (4 steps); unable to transfer weight twice onto each lower limb regardless of limping
- Ecchymosis does not have significant values for PLR/-

Abbreviation: PLR, positive likelihood ratio

Adapted from: McGee SR. *Saunders/Elsevier* 2007, Box 53-3, page 649, Table 53-4, page 639.

Useful background: Performance characteristics of tests for osteoarthritis of knee in patients with chronic pain

| Finding | PLR |
|--|------|
| ➤ Individual findings | |
| ○ Morning stiffness <30 minutes | 3.0 |
| ○ Bony enlargement | 11.8 |
| ○ Varus deformity | 3.4 |
| ➤ Combined findings | |
| At least 3 out of 6: | 3.1 |
| ○ Age > 50 years | |
| ○ Stiffness < 30 minutes | |
| ○ Crepitus | |
| ○ Bony tenderness along margins of joint | |
| ○ Bone enlargement | |
| ○ No palpable warmth | |

Valgus deformity does not have a significant PLR values for osteoarthritis of the knee, nor does crepitus on passive movement (PLR, 2.1) or a palpable increase in the temperature of the knee.

Adapted from: McGee SR. *Saunders/Elsevier* 2007, Box 53-2, page 648.



Ankles

- Perform a focused physical examination of the ankle.

| Finding | Diagnosis |
|---|---------------------------------|
| ➤ Inspection | |
| - Flattening of longitudinal arch | ○ Pes planus |
| - Abnormal elevation of medial longitudinal arch | ○ Pes cavus |
| - Outward angulation of great toe with prominence over medial 1 st MTP joint (bunion) | ○ Hallux valgus |
| - Hyperextension of MTP joints and flexion of PIP joints | ○ Hammer toes |
| ➤ Palpation | |
| - Nodules within Achilles tendon | ○ Tendon xanthoma |
| - Foot pain, localized tenderness over calcaneal origin of plantar fascia | ○ Plantar fasciitis |
| - Foot pain, localized tenderness over plantar surface of MT heads | ○ Metatarsalgia |
| - Forefoot pain, tenderness between 2 nd or 3 rd toes or between 3 rd and 4 th toes | ○ Morton's interdigital neuroma |
| - Ankle pain, dysesthesias of sole, aggravated by forced dorsiflexion and eversion of foot | ○ Tarsal tunnel syndrome |

Printed with permission: McGee SR. *Saunders/Elsevier* 2007, Table 53-2, page 627.

➤ Active Movement: Normal ROM

| Joint | Flexion/extension | Rotation |
|------------------|-------------------------|-------------------|
| ○ Ankle and feet | - 45° (plantar flexion) | ➤ 30° (inversion) |
| | - 20° (dorsiflexion) | ➤ 20° (eversion) |

Abbreviations: DIP, distal interphalangeal; MCP, metacarpophalangeal; MT, metatarsal; PIP, proximal interphalangeal

Source: McGee SR. *Saunders/Elsevier* 2007, Table 53-1, page 624.



Useful background: Performance characteristics for ankle and midfoot fracture*

| Finding | PLR | NLR |
|--|-----|-----|
| ➤ Detecting ankle fracture | | |
| ○ Tenderness over posterior lateral malleolus | 2.4 | 0.4 |
| ○ Tenderness over posterior medial malleolus | 4.8 | 0.6 |
| ○ Inability to bear weight immediately after injury | 2.6 | 0.5 |
| ○ Inability to bear weight 4 steps in the emergency room | 2.5 | 0.3 |
| ➤ Detecting midfoot fracture | | |
| ○ Tenderness at the base of the 5 th metatarsal | 2.9 | 0.1 |
| ○ Ottawa foot rule | 2.1 | 0.1 |

Note: Some clinical findings are deleted because their PLR is < 2. These include: Ottawa ankle rule, tenderness of navicular bone, and inability to bear weight immediately, and inability to bear weight 4 steps in the emergency room.

Adapted from: McGee SR. *Saunders/Elsevier* 2007, Box 53-5, page 654.

SO YOU WANT TO BE A RHEUMATOLOGIST!

Q. What is the difference between Trousseau's syndrome, Trousseau's sign and Chvostek's sign?

- A.
- Trousseau's syndrome
 - Migratory, superficial or deep thrombophlebitis
 - Associated with carcinoma
 - Or lung, breast, stomach or pancreas or prostate
 - Trousseau's sign
 - Carpopedal spasm, extension of the body, and spirotonos finger extensors and wrist flexors (aka obstetrician's hand, or main d'accoucheur).
 - Due to low Ca^{2+} , Mg^{2+} , PO_4^{2-} ; alkalemia
 - Chvostek's sign
 - For muscle hyperexcitability; (from Ca^{2+} , Mg^{2+} , PO_4^{2-} ; alkalemia)
 - Sensitivity of 27%; false positive rate of 4-29% in adult (i.e. "worthless")



Feet

- Perform a focused physical examination of the feet.
- Inspection
 - For skin rash, scars
 - At the nails for changes of psoriasis
 - At the forefoot for hallux valgus, clawing and crowding of the toes (rheumatoid arthritis)
 - At the callus over the metatarsal heads which may occur in subluxation
 - At both the arches of the foot, in particular medial and longitudinal (flat foot, pes cavus)
- Palpate
 - Ankles for synovitis, effusion, passive movements at the subtalar joints (inversion and eversion) and talar joint (dorsiflexion and plantar flexion); remember that tenderness on movement is more important than the range of movement
 - Metatarsophalangeal joints for tenderness
 - Individual digits, for synovial thickening
 - Bottom of heel, for tenderness (plantar fasciitis), and Achilles tendon for nodules.

Adapted from: Baliga RR. *Saunders/ Elsevier* 2007, page 334-335; Filate W, et al. *The Medical Society, Faculty of Medicine, University of Toronto* 2005, page 151.

Gem, Pearl, Tid-Bit and Non-sense

Notwithstanding that “there are never” nevers in medicine, RA never involves the DIP joints.

Gout and pseudo-gout

- Definition: “Gout is a disease in which monosodium urate monohydrate (MSU) crystals deposit in joints, soft tissue such as cartilage, tendons and bursa, or in renal tissues such as glomeruli, the interstitium and tubules”.
 - The deposition of MSU crystals “...can result in gouty arthritis, tophi, nephropathy or uric acid nephrolithiasis” (Kapur S and Kraag G, et al. Chapter 44. In: *Therapeutic Choices*. Grey J, Ed. 6th Edition, *Canadian Pharmacists Association: Ottawa, ON, 2011, page 1011*).
 - MSU tophi may cause joint deformities and destruction, and tophi in the cardiac conduction system may lead to dysarrhythmias.



Useful background

➤ Distinguishing between gout and pseudo-gout

| Crystalline arthritis | Sex distribution | Joint involvement | Crystal | Crystal characteristics |
|--|------------------|--|-----------------------|--|
| Gout* | Male > female | Asymmetrical distal joints, especially great toe | Uric acid | Long, needle-shaped negative birefringence |
| Calcium pyrophosphate deposition disease (pseudo-gout) | Female > male | Proximal joints, especially knee and wrist | Calcium pyrophosphate | Rectangular, positive birefringence |

* *Examine ears, olecranon bursae and Achilles tendons for tophi.*

Source: Ghosh AK. *Mayo Clinic Scientific Press* 2008, Table 10-3, page 385.

➤ Causes of hyperuricemia

- Primary gout
- Chronic renal failure
- ↑ Production
- ↓ Excretion
 - Chronic renal failure
 - Hyperparathyroidism
 - Ketosis and lactic acidosis
- Increased cell turnover
 - Polycythemia
 - Leukemia
 - Reticulosis
 - Myelosclerosis
 - Psoriasis
- Drugs
 - Salicylates (in low doses)
 - Thiazides and furosemide
 - Pyrazinamide
- High purine diet and alcohol
- Down's syndrome
- Metabolic
 - Obese
 - Hypertensive patients
- Congenital
 - Lesch-Nyhan syndrome (congenital mental deficiency, choreo-athetosis and lip chewing)

Adapted from: Burton JL. *Churchill Livingstone* 1971, page 116.



- Knees
 - Hips, sacroiliac joints and spine
- GU
 - Non-specific urethritis, hematuria, sterile pyuria
 - Circinate balanitis
- Skin
 - Keratoderma blennorrhagica, nail dystrophy

Source: Burton JL. *Churchill Livingstone* 1971, page 114.

Clinical Challenge

A young man recovers from an episode of non-gonococcal urethritis, iritis, and bilateral pain and tenderness (“arthritis”) of the knees and ankles. Reiter syndrome (RS) is suspected.

- Perform a focused physical examination for complications of RS.
 - MSK
 - Calcaneal spur – calcification of plantar fascia
 - Plantar fasciitis
 - Tendonitis
 - Arthritis – usually knees & ankles
 - Skin (palms, soles of feet)
 - Psoriasis – like lesions (specifically, keratoderma blennorrhagia)
 - Ulcer on penis (aka circinate balanitis)
 - GU
 - Ulcer on penis (aka circinate balanitis)
 - Heart
 - Aortitis
 - Myocarditis
 - Pericarditis
 - Clinical features of Stevens-Johnson syndrome
 - Eye
 - Conjunctivitis, corneal ulcers, uveitis
 - Mouth
 - Oral bullae and hemorrhagic crusting
 - Skin
 - Maculopapular or bullous erythema multiforme
 - GI
 - Diarrhea
 - Lung
 - Bronchitis, pneumonitis



- Kidney/GU
 - Urethritis, balanitis, vulvovaginitis
 - Renal lesions, diarrhea, polyarthritis, otitis media
- General
 - Constitutional symptoms and high fever
- Clinical features of Behcet's syndrome
 - CNS
 - Meningoencephalitis
 - brain-stem syndromes
 - Eyes
 - Conjunctivitis or uveitis
 - Mouth
 - Buccal ulcers with a red areola
 - Skin
 - Cutaneous pustules, dermal nodules
 - Kidney/GU
 - Genital ulcers
 - Veins
 - Thrombophlebitis
 - CVS/lung
 - Rarely cardiac and pulmonary lesions

Adapted from: Burton JL. *Churchill Livingstone* 1971, page 114.

- Your colleague disagrees with your clinical diagnosis of Reiter syndrome, and because of the arthritis, urethritis and eye changes, suggests that the correct diagnosis is likely either Behcet syndrome (BS) or Stevens – Johnson syndrome (S-JS).
- Perform a focused physical examination which would help to distinguish BS from S-JS.

| | BS | S-JS |
|-----------------------|----|--------------------|
| ○ Iritis | + | - (conjunctivitis) |
| ○ Stomatitis | + | - |
| ○ Genital ulcers | + | - |
| ○ Vasculitis | + | - |
| ○ Peripheral neuritis | + | - |
| ○ Diarrhea | + | + |
| ○ Fever | - | + |
| ○ Erythema multiforme | - | + |
| ○ Renal disease | - | + |



What is “the best”? The “best” clinical test of physical examination for ankle and midfoot fracture is tenderness over the posterior medial malleolus.

Give the radiological features of Gout

- Punched out erosions of joint margins
- Erosions occur beyond joint capsule
- Spotted appearance of carpals
- Cartilage loss
- No osteoporosis or new bone formation

Source: Burton JL. *Churchill Livingstone* 1971, page 113.

Rheumatoid arthritis

- Definition: Rheumatoid arthritis (RA) is a systemic autoimmune disease manifesting primarily as a symmetric and erosive poly arthritis” (Hazlewood G and Bykerk VP. In: *Therapeutic Choices*. Grey J, Ed. 6th Edition, *Canadian Pharmacists Association*: Ottawa, ON, 2011, page 1040).
- Points of interest
 - Persons with RA have an increased risk of
 - Cardiovascular disease and cardiovascular mortality
 - Infections
 - Lymphoma
 - Osteoporosis
 - Only 30% of patients diagnosed with RA have a positive serum RF (rheumatoid factor) at the time of their initial presentation with symptoms.
 - A negative RF “....does not exclude the possibility of rheumatoid arthritis

Useful background: Evaluation of disease activity and damage of rheumatoid arthritis

- Subjective
 - Degree of joint pain (scored /10 on ascending pain scale)
 - Duration of morning stiffness (in minutes or hours)
 - Degree of fatigue (scored /10)
 - Physician and patient global assessment of disease activity
 - Limitation of function



- Physical examination
 - Number of actively inflamed/swollen joints
 - Mechanical joint problems
 - Loss of motion
 - Crepitus
 - Instability
 - Malalignment and/or deformity
 - Extra-articular manifestations including
 - Dry eyes
 - Nodules
 - Pulmonary findings
 - Carpal tunnel syndrome

- Laboratory
 - Erythrocyte sedimentation rate/C-reactive protein level: monitor every 1-2 months
 - Rheumatoid factor titre/anti-CCP antibody: at baseline
 - Complete blood cell count: monitor during most therapies every 1-3 months
 - Creatinine level: monitor at least twice per year
 - Urinalysis at baseline and during an annual visit
 - Synovial fluid analysis if available: at baseline to exclude other conditions or sepsis

- Imaging
 - Radiographs of hands and feet and selected involved joints annually and as indicated
Consider joint ultrasound or, if available, MRI to identify subclinical erosions if radiographs normal in the first year

Reproduced with permission: Therapeutics Choices. Sixth Edition. Ottawa, Canada: Canadian Pharmacist Association 2012, Table 1, page 1041.



Useful background:

- American Rheumatism Association (ARA) criteria for rheumatoid arthritis (RA)
 - Morning stiffness for at least 1 hour for duration of 6 weeks or more
 - Swelling of at least three joints for 6 weeks or more
 - Swelling of wrist, metacarpophalangeal or proximal interphalangeal 6 weeks or more
 - Symmetry of swollen joint areas for 6 weeks or more
 - Subcutaneous nodules
 - Positive rheumatoid factor
 - Radiographic features typical of rheumatoid arthritis, i.e. erosions periarticular osteopenia.

When four or more of the above criteria are met, there is 93% sensitivity and 90% specificity for the diagnosis of rheumatoid arthritis.

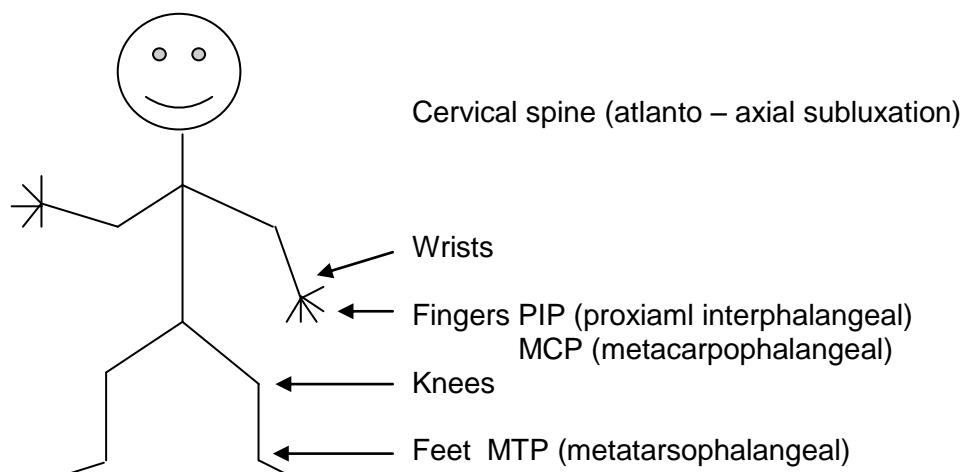
Adapted from: Baliga RR. *Saunders/Elsevier* 2007, page 339.

- Perform a focused physical examination of extra – articular complications of rheumatoid arthritis (RA).
 - Eyes
 - Keratoconjunctivitis sicca (KS)
 - Sjogren syndrome (KS, plus xerostomia)
 - Scleromalacia (including scleromalacia perforans)
 - Scleritis
 - Episcleritis
 - Skin
 - Nodules
 - Flexor and extensor tendons
 - Especially of hands, sacrum, heel (Achilles tendon)
 - Vasculitis
 - Infarction of nail folds
 - Lung
 - Rheumatoid nodules
 - Caplan syndrome rheumatoid nodules at periphery of lung fields
 - Fibrosing alveolitis
 - Pleural effusion
 - Spleen
 - Splenomegaly
 - Felty syndrome (splenomegaly and hypersplenism, usually in a seropositive RA patient)

From: Baliga RR. *Saunders/Elsevier* 2007, page 336.



Common site of joint disease in RA



➤ Causes of deforming polyarthropathy

- Rheumatoid arthritis
- Psoriatic arthritis
- Ankylosing spondylitis
- Reiter's disease
- Chronic tophaceous gout
- Osteoarthritis
- Lyme arthritis)

➤ Causes of arthropathy plus nodules

- Rheumatoid arthritis
- Systemic lupus erythematosus
- Rheumatic fever
- Sarcoidosis

Adapted from: Talley NJ, et al. *MacLennan & Petty Pty Limited* 2003, Table 8-8, page 261 and Table 8-10, page 269.

- Perform a focused physical examination for rheumatoid arthritis (RA), and its complications.
- Poor general health
 - Weight loss
 - Pale
 - Depression and social problems



➤ Joints

- Metacarpophalangeal (MCP) joints
 - Synovitis
 - Effusions
 - Low range of movement
 - Crepitus
 - Subluxation, deformity
 - Boutonniere deformity (fixed flexion of PIP and extension of DIP, due to protrusion of the PIJ through ruptured extensor tendon)
 - Z deformity (thumb IPJ hypertension and fixed flexion and of subluxation of MCJ)
 - Tendon rupture
- Arms
 - Entrapment neuropathy (e.g. carpal tunnel)
 - Subcutaneous nodules
- Elbow, shoulder joint
 - Axillary nodes
 - Baker's synovial cyst
- Back, hips, knees

➤ Lower limbs

- Ulceration (vasculitis)
- Calf swelling (ruptured synovial cyst)
- Peripheral neuropathy
- Mononeuritis multiplex
- Pressure sores
- Infected ulcers (from nodules)
- Cord compression

➤ Joint complications

- Deformity, subluxation
- Pyoarthrosis
- Tendon rupture (due to attrition or nodules)
- Nerve compression (due to tenosynovial swelling)
- Cord or root compression (due to cervical subluxation)
- Baker's synovial cyst
- Acute rupture of synovial sac (especially in knee)
- Hoarseness, due to crico-artenoid arthritis
- Deafness, due to arthritis of auditory ossicles

➤ MSK

- Osteoporosis
- Muscle atrophy



- Eye
 - Episcleritis
 - Scleritis
 - Scleromalacia perforans, scleromalacia
 - Uveitis
 - Sjogren's syndrome
 - Pyoderma gangrenosa

- Face
 - Eyes – dry eyes (Sjögren's), scleritis, episcleritis, scleromalacia perforans, uveitis, Sjogren's syndrome, anemia, cataracts (steroids, chloroquine)
 - Fundi – hyperviscosity
 - Face – parotid enlargement (Sjögren's),
 - Mouth – dryness, ulcers, dental caries
 - Temporomandibular joint (crepitus)
 - Hoarseness (crico-arytenoid arthritis)
 - Ears – deafness (arthritis of auditory ossicles)

- Neck
 - Cervical nodes
 - Swan neck (hyperextension at PIJ [subluxation], and fixed flexion deformity of DIJ [tendon shortening])
 - Thyroiditis

- Skin
 - Pressure sores and infected ulcers (due to nodules)

- Heart/CVS
 - Pericardial effusion
 - Pericarditis
 - Arteritis
 - Aortic regurgitation
 - Rheumatoid granuloma of heart
 - Murmurs from rheumatic heart disease

- Lung
 - Pleuritis, pleural effusion
 - Nodules in lung or pleura
 - Fibrosing alveolitis
 - Caplan's syndrome in pneumoconiosis
 - Fibrosis
 - Infarction
 - Infection
 - Arteritis



- Arteritis
 - Digital ischemia
 - Raynaud's syndrome
 - Leg ulcers
 - Mesenteric ischemia
 - Arteritis of lungs, kidneys, liver
 - Peripheral and autonomic neuropathy
 - Amyloidosis
 - May develop renal vein thrombosis

- Abdomen
 - Mesenteric ischemia
 - Arteritis of kidneys, liver
 - Splenomegaly
 - Pernicious anemia
 - Subfertility
 - Renal/ vein thrombosis
 - Character and distribution of deformities
 - Contractures, hyperextension, ulnar deviation (late finding), abnormal posture, nodules, muscular atrophy
 - Bony swelling
 - Soft tissue swelling, redness or rash, palmar erythema, fingernail or finger tuft abnormalities, Dupuytren's contractures
 - Range of motion (ROM)
 - Active
 - Passive, to include:
 - Making fist
 - Grip strength
 - Wrist flexion/extension
 - Finger flexion/extension
 - Opposition of thumb and 5th finger/thumb and index finger
 - Abdomen
 - Splenomegaly (e.g. Felty's syndrome)
 - Inguinal nodes

- Functional assessment in rheumatoid arthritis
 - Class 1: Normal functional ability
 - Class 2: Ability to carry out normal activities, despite discomfort or limited mobility of one or more joints
 - Class 3: Ability to perform only a few of the tasks of the normal occupation or of self-care
 - Complete or almost complete incapacity with the patient confined to wheelchair or to bed



- Other
 - Urine: protein, blood (drugs, vasculitis, amyloidosis)
 - Rectal examination (blood)
 - Complications of therapy
- Felty's syndrome (Splenomegaly, RA and leucopenia)
 - Complications of therapy
 - Associated auto-immune disease
 - PA
 - Thyroiditis
 - Hemolytic anemia
 - Subfertility (prior to development of arthritis)
 - Amyloidosis
 - SLE
 - Chronic brucellosis
 - CNS-posterior and anterior neuropathy
 - Nerve entrapment
 - Eye-keratoconjunctivitis sicca
 - Uveitis
 - Corneal ulceration
 - Cytoid bodies
 - Thyroiditis
 - Skin-infection
 - Ulcers
 - Bone marrow-normochromic normocytic anemia
 - Pernicious anemia
 - Hemolytic anemia
 - Lymphadenopathy
 - Splenomegaly
 - Lung-fibrosis
 - Pleural effusion
 - Nodules
 - Caplans
 - Kidney-proteinuria
 - Amyloid
 - Decreased fertility

Adapted from: Burton JL. *Churchill Livingstone* 1971, page 115; Baliga RR. *Saunders/Elsevier* 2007, page 338; Talley NJ, et al. *Maclennan & Petty Pty Limited* 2003, Table, 8.31, page 286; Jugovic PJ, et al. *Saunders/ Elsevier* 2004, pages 146 and 147.



Clinical Gems: No!

- No osteoporosis or new bone formation with gout
- No ankylosis with osteoarthritis
- No sclerosis or new bone formation with rheumatoid arthritis

- Give non-MSK (musculoskeletal) associations of rheumatoid arthritis (RA).

RA is usually symmetrical, involving the proximal interphalangeal and metacarpophalangeal (MCP) joints in the hands, the wrist joints, the tarsal and metatarsophalangeal (MTP) joints in the small joints of the upper cervical spine

- General
 - Recurrent fevers, with or without infections
 - Weight loss
- CNS
 - Neuropathy
- Hematology
 - Lymphadenopathy
 - Other cytopenias besides leukopenia
 - Felty's syndrome (classic triad)
 - Rheumatoid arthritis
 - Leukopenia
 - Splenomegaly
- Skin
 - Skin hyperpigmentation
 - Lower extremity ulcers
 - Vasculitis
- Age / mouth
 - Keratoconjunctivitis sicca
 - Xerostomia

Adapted from: Ghosh AK. *Mayo Clinic Scientific Press* 2008, Table 24-4, page 978.

- Give the radiological features of Rheumatoid arthritis.
 - Osteoporosis
 - Cartilage loss
 - Marginal and surface erosions
 - Subluxations, dislocations and carpal ankylosis
 - No sclerosis or new bone formation

Source: Burton JL. *Churchill Livingstone* 1971, page 113.



In both rheumatoid arthritis (RA) and osteoarthritis (OA), there is slow insidious onset of progressive disease, exacerbations, and the development of limitations in motion. Take a directed history and perform focused physical examination to distinguish RA from OA.

| | Rheumatoid Arthritis * | Osteoarthritis |
|-------------------------|---|---|
| ➤ Process | <ul style="list-style-type: none"> ○ Chronic inflammation of synovial membranes ○ Secondary erosion of adjacent cartilage and bone ○ Damage to ligaments and tendons | <ul style="list-style-type: none"> ○ Degeneration and progressive loss of cartilage within the joints ○ Damage to underlying bone, ○ Formation of new bone at the margins of the cartilage |
| ➤ Common locations | <ul style="list-style-type: none"> ○ Hands (PIP, MCP), ○ Feet (MCP) ○ Wrists ○ Elbows ○ Knees ○ Ankles ○ Cervical sprue | <ul style="list-style-type: none"> ○ Knees, hips, hands, wrists (DIP, sometimes PIP), ○ Cervical and lumbar spine ○ Joints that were previously injured or diseased |
| ➤ Pattern of spread | <ul style="list-style-type: none"> ○ , progresses to other joints while persisting in the initial ones (symmetrically additive) | <ul style="list-style-type: none"> ○ Additive; however, only one joint may be involved |
| ➤ Swelling | <ul style="list-style-type: none"> ○ Swelling of synovial tissue in joints or tendon sheaths' ○ Subcutaneous nodules | <ul style="list-style-type: none"> ○ Effusions in the joints (especially in the knees) ○ Bony enlargement |
| ➤ Joint inflammation | <ul style="list-style-type: none"> ○ Common | <ul style="list-style-type: none"> ○ Uncommon |
| ➤ Stiffness | <ul style="list-style-type: none"> ○ Prominent, often for an hour or more in the mornings, also after inactivity | <ul style="list-style-type: none"> ○ Frequent ○ Usually 5-10 min) in the morning and after inactivity |
| ➤ General symptoms | <ul style="list-style-type: none"> ○ Weakness ○ Fatigue ○ Weight loss ○ Fever | <ul style="list-style-type: none"> ○ Usually absent |
| ➤ Radio-graphic changes | <ul style="list-style-type: none"> ○ Symmetric narrowing of joint space | <ul style="list-style-type: none"> ○ Asymmetric narrowing of joint space ○ Osteophytes ○ Subchondral sclerosis ○ Cystic changes |

Abbreviations: DIP, distal interphalangeal; MCP, metacarpophalangeal; OA, osteoarthritis; PIP, proximal interphalangeal; RA, rheumatoid arthritis

Adapted from: Jugovic PJ, et al. *Saunders/ Elsevier* 2004, pages 147 and 148.



Useful background: Causes of pyoderma gangrenosum

- MSK
 - Rheumatoid arthritis
 - Seronegative arthritis associated with gastrointestinal symptoms
- GI
 - IBD (Ulcerative colitis, Crohn's disease)
 - Chronic active hepatitis
- Hematology
 - Acute and chronic myeloid leukemia
 - Myelocytic leukemia
 - Hairy cell leukemia
 - Polycythemia rubra vera
 - Multiple myeloma
 - IgA monoclonal gammopathy

Source: Baliga RR. *Saunders/Elsevier* 2007, page 467.

- Perform a focused physical examination for non-articular signs of rheumatoid arthritis.
 - CNS
 - Peripheral neuropathy
 - Nerve entrapment
 - Eye
 - Keratoconjunctivitis sicca
 - Uveitis
 - Corneal ulceration
 - Cystoids bodies
 - Scleromalacia perforans
 - Vocal cords
 - Involvement of crico-arytenoid
 - Endocrine
 - Thyroiditis
 - Infertility
 - Renal
 - Proteinuria
 - Amyloid
 - Skin
 - Infection
 - Ulcers
 - Raynaud's phenomenon



- Heart
 - Pericardial effusions
 - Arteritis
 - Nodules
 - Cardiomyopathy
 - Aortic regurgitation
- Lung
 - Pleural effusion
 - Nodules
 - Fibrosis
- Bone marrow
 - Anemina – normochromic – hypochromic – macrocytic (B12, PA)
 - Lymphadenopathy
 - Splenomegaly
- Give a systematic approach to the causes of sacroiliitis.
- MSK
 - Ankylosing spondylitis (rheumatoid spondylitis)
 - Juvenile rheumatoid arthritis
 - Psoriasis
- GI
 - IBD
- Infection
 - Reiters
 - TB
 - Whipples
 - Brucellosis

Definitions

- Palindromic rheumatism
 - Recurrent acute attacks of arthritis of periarticular structures
 - No permanent joint deformity
 - Seronegative
- Felty's syndrome
 - Rheumatoid arthritis
 - Splenomegaly
 - Leucopenia



- Stevens – Johnson syndrome
 - Fever
 - Conjunctivitis
 - Erythema multiforme
 - Pneumonitis
 - Diarrhea
 - Renal disease
 - Urethritis
- Perform a focused physical examination for dermatomyositis/ polymyositis.
 - Muscle
 - Weak
 - Tender
 - Atrophic
 - Limb girdles
 - Proximal limb muscles
 - Skin
 - Redness of face, chest, arms, dorsum of fingers
 - Photosensitivity
 - Associated cancers
 - Lung
 - Breast
 - Stomach
 - Ovary

SO YOU WANT TO BE RHEUMATOLOGIST!

Q. Skin and muscle symptoms and signs develop in a middle aged person, who has

- Skin
 - Redness
 - Dorsum of fingers
 - Face, chest, arms
 - Light sensitivity
- Muscle (myositis)
 - Limb girdles
 - Usually proximal limb muscle
 - Rarely distal limbs

You make a clinical diagnosis of dermatomyositis. The person also has unintentional weight loss which tumors of the chest and abdomen may have preceded this diagnosis?

- A.
 - Chest
 - Breast
 - Lung
 - Abdomen
 - Stomach
 - Ovary



Sjögren's syndrome

This syndrome occurs in rheumatoid arthritis, and also with other connective tissue diseases.

- Classic triad
 - Arthritis (typically episodic polyarthritis)
 - Dry eyes
 - Dry mouth

- Physical examination
 - Dry eyes: conjunctivitis, keratitis, corneal ulcers (rarely vascularisation of the cornea)
 - Dry mouth
 - Arthritis
 - Chest: infection secondary to reduced mucus secretion, pleurisy or interstitial pneumonitis
 - Kidneys; renal tubular acidosis or nephrogenic diabetes insipidus
 - Genital tract: atrophic vaginitis
 - Pseudolymphoma: lymphadenopathy and splenomegaly, which may rarely progress to a true (usually non-Hodgkin's) lymphoma

- Other features
 - Constitutional features: fatigue, malaise, myalgia
 - Raynaud phenomenon
 - Cutaneous vasculitis
 - CNS abnormalities
 - Cerebritis, CNS vasculitis
 - Stroke
 - Multiple sclerosis-like illness
 - Peripheral neuropathy
 - Sensory
 - Autonomic
 - Heart aortic regurgitation

Adapted from: Ghosh AK. *Mayo Clinic Scientific Press* 2008, Table 24.5, page 978; Talley NJ, et al. *MacLennan & Petty Pty Limited* 2003, Table 8.7, page 256.



Osteoarthritis

- Perform a focused physical examination for the causes of spondyloarthritis.
- Seropositive conditions (rheumatoid factor [RF] positive)
 - Musculoskeletal
 - Rheumatoid arthritis
 - Sjögren syndrome
 - Systemic lupus erythematosus (SLE)
 - Scleroderma
 - Heart
 - Subacute bacterial endocarditis (SBE)
 - Lung
 - Idiopathic pulmonary fibrosis
 - Blood
 - Mixed cryoglobulinemia
 - Infections
 - Infectious mononucleosis
 - Influenza
 - Chronic active hepatitis
 - Vaccinations
 - Tuberculosis
 - Syphilis
 - Malignancy
 - Malignancies

SO YOU WANT TO BE A RHEUMATOLOGIST!

Q. What are the poor prognostic factors for RA?

- A.
- Systemic features: weight loss, extra-articular manifestations
 - Insidious onset
 - Rheumatoid nodules
 - Presence of rheumatoid factor more than 1 in 512

Source: Baliga RR. *Saunders/Elsevier* 2007, page 339.



SO YOU WANT TO BE A RHEUMATOLOGIST!

Q1. What causes arthritis plus nodules?

- A1.
- Rheumatoid arthritis
 - Systemic lupus erythematosus (rare)
 - Rheumatic fever (Jaccoud's arthritis) (very rare)
 - Granulomas- e.g. sarcoid (very rare)

Source: Talley NJ, et al. *Maclennan & Petty Pty Limited* 2003, page 269.

Q2. A nodule is palpated at the extensor surface of the elbow. How can you differentiate between a rheumatoid nodule and a gouty tophus on physical examination?

A2. You can't! usually aspiration or biopsy is needed, unless the gouty tophus drains to the surface.

Q3. So you thought I was going to ask you to examine the patient for typical deformities in the hand of a person with rheumatoid arthritis. Well, please examine for the rheumatoid foot.

- A3.
- Pes planus – inward rotation of the medial malleolus
 - Loss of anterior arch – wide front part of foot
 - Hallux valgus – bending of the big toe towards the second toe
 - Cock-up deformities of the toes – flexion of the IP joint of the toes
 - Dropped metatarsal heads - subluxation of the metatarsal heads

SO YOU WANT TO BE A RHEUMATOLOGIST!

Q. A patient with rheumatoid arthritis (RA) is found to have splenomegaly. What are the causes of splenomegaly in this patient which are related to the RA?

- A.
- Adult – Felty syndrome
 - Child – Still's disease
 - Amyloidosis
 - Associated SLE
 - Beucellosis



SO YOU WANT TO BE A "RHEUM –WITH- A -VIEW" (Rheumatologist)!

Q. What is palindromic rheumatoid arthritis?

- A. ○ Acute recurrent arthritis, usually affecting one joint, with symptom-free intervals of days to months between attacks

Source: Baliga RR. *Saunders/Elsevier* 2007, page 345.

SO YOU WANT TO BE A RHEUMATOLOGIST!

Q1. What are the radiological signs of osteomalacia) loss of mineral from bone, with normal protein matrix)

- A1. ○ Milkman fracture (aka looser zone) – tongue of radiotranslucency extending from the surface into the bone
- Usually seen upper end of femur or humerus, or lower end of tibia
- Bending of bones
- Later, features of osteoporosis
- Cortex thinning sclerosis of cortex
- Thinning (translucency) of bone
- ↓ number of trabeculae
- Sclerosis of remaining trabeculae
- Axial bones affected more than peripheral bones

Q2. Paget disease usually causes sclerotic lesions, but the exception may be the skull. What are the bony changes in the skull in Paget disease?

- A2. ○ Well circumscribed area of translucency (rarefaction) (aka osteoporosis circumscripta)
- Platybasia-indentation of the soft skull by vertebral column (odontoid process of the axis > 5 mm above chamberlain's line [Chambalain's line is a straight line drawn backwards from the hard palate to 5 mm above the odontoid process])

SO YOU WANT TO BE A RHEUMATOLOGIST!

Q. How does sacroilitis of psoriatic arthritis differ from ankylosing spondylitis?

- A. In psoriatic arthritis, the syndesmophytes are usually from the internal and anterior surfaces of the vertebral bodies, and not from the margins of the bodies as is usually the case in ankylosing spondylitis

Source Baliga RR. *Saunders/Elsevier* 2007, page 343.



- Seronegative (rheumatoid factor [RF] negative; commonly an asymmetrical arthritis)
- Ankylosing spondylitis
 - Sacroiliac joints and spine
 - Hips, knees and shoulders
 - Psoriatic arthritis
 - Terminal interphalangeal joints
 - Sacroiliac joints
 - Rheumatoid pattern
- Reiter's syndrome
 - Sacroiliac joints and spine
 - Hips
 - Knees
 - Ankles, and most of the joints of the feet
- Infections
 - Sarcoidosis
 - Infectious mononucleosis
 - Influenza
 - Chronic active hepatitis
 - Vaccinations
 - Tuberculosis
 - Syphilis
 - Brucellosis
 - Leprosy
 - Salmonellosis
 - Malaria
 - Kala-azar
 - Schistosomiasis
 - Filariasis
 - Trypanosomiasis
- Miscellaneous
 - Hypergammaglobulinemic purpura
 - Asbestosis

Adapted from: Ghosh AK. *Mayo Clinic Scientific Press* 2008, Table 24-2, page 975; Talley NJ, et al. *Maclennan & Petty Pty Limited* 2003, Table 8-4, page 253.



SO YOU WANT TO BE A RHEUMATOLOGIST!

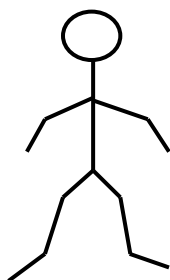
Q1. In the context of osteoarthritis (OA), how do you distinguish between Heberden's and Bouchard's nodes.

A1. ○ Painless nodules – DIP, Heberden's nodes (DIP, HeberDen)
PIP, Bouchard's nodes

Q2. OK. Now distinguish between Bouchard's nodes, which usually occur in OA, and Haygarth's nodes, which usually occur in rheumatic disorders such as rheumatoid.

A2. ○ Haygarth's nodes are inflammatory and thus painful and tender, not painless and degenerative, as are Bouchard's nodes in OA

○ These nodes affect



○ Occiput

○ Elbows

○ Middle & proximal PIP joints

○ Knees

○ Ankles

Q3. In the context of reddish lesions on the palms of the hands or soles of the feet, distinguish between Janeway lesions and Osler's nodes.

A3. Janeway lesions are small and non-tender whereas, Osler's nodes are swollen, tender. Janeway lesions arise from septic emboli or sterile vasculitis in endocarditis (with or without bacteremia, gonococcal sepsis, or lupus (SLE)).

Q4. In the context of bony swellings in a patient with osteoarthritis, what is the difference between Heberden and Bouchard nodes?

A4. Heberden TIP joints (terminal interphalangeal joints)
Bouchard PIP joints (proximal interphalangeal joints)



Juvenile chronic arthritis

- Juvenile chronic arthritis (still disease) may be pauciarticular and polyarticular. Define still disease and its two major forms. Define still disease and its two major forms. Perform a focused physical examination for juvenile chronic arthritis and its complications.
- Definition of Still disease
 - Arthritis of unknown cause for 6 weeks or longer
 - Associated with daily temperature spikes to 39.4°C (103°F) for at least 2 weeks
 - With or without maculopapular rash
- Pauciarticular (~ 75%)
 - ≤ 4 or fewer joints
- Polyarticular (~25%)
 - ≥ 5 joints involved
 - Usually upper cervical apophyseal, carpometacarpal and terminal interphalangeal joints
 - Fusion of jaw, resulting in a
 - Fusion of cervical spine
 - Micrognathia
 - Receding chin
 - Splenomegaly and lymph adenopathy
- Complications of juvenile chronic arthritis
 - General
 - Lethargy, anorexia and irritability
 - Growth failure
 - MSK
 - Sacrolitis (more commonly seen in boys)
 - Joint contractures
 - Joint failure
 - Eye
 - Iritis and anterior uveitis (more commonly seen in girls)
 - Chronic anterior uveitis
 - Hematology
 - Anemia
 - Amyloidosis
 - Splenomegaly

Adapted from: Baliga RR. *Saunders/Elsevier* 2007, page 351.



Pressure Ulcer

Useful background: Staging of pressure ulcers

- Stage I
 - Nonblanchable erythema of intact skin, usually over a bony prominence.
 - In darker skin types, discolouration, warmth, edema or induration may be indicator. The area may be painful, firm, soft, warmer or cooler than adjacent skin.

- Stage II
 - Partial-thickness skin loss involving the epidermis, dermis or both
 - Clinically, this presents as
 - An abrasion
 - Intact or ruptured blister
 - Shallow erosion with a red-pink wound bed

- Stage III
 - Full-thickness ulceration
 - Subcutaneous fat may be visible, but none, tendon or muscle are not exposed.
 - Presents as a deep crater that may have undermining of adjacent tissue.

- Stage IV
 - Full-thickness ulceration with exposed
 - Bone
 - Tendon
 - Fascia
 - Muscle
 - Joint capsule
 - Often includes undermining and tunneling.
 - Slough (yellow, tan, gray, green or brown) or eschar (tan, brown or black) may be present, and may cover the base of the ulcer. A pressure ulcer cannot be accurately staged until enough slough and/or eschar has been removed to expose the base of the wound.
 - Pressure ulcers do not necessarily progress in order, nor do they heal by reverse staging.

Reproduced with permission: Therapeutics Choices. Sixth Edition. Ottawa, Canada: *Canadian Pharmacist Association* 2012, Table 1, page 1162.



Useful background: Select risk/causative factors for pressure ulcers

| Local | Systemic |
|--|--|
| <ul style="list-style-type: none"> ○ Pressure, especially overlying bony prominences ○ Dry skin ○ Excessive moisture ○ Friction ○ Shearing forces | <ul style="list-style-type: none"> ○ Circulatory disturbance ○ Malnutrition ○ Prolonged immobilization, e.g., <ul style="list-style-type: none"> - Fractures - Spinal cord injury - Stroke - Major surgery ○ Sensory deficit ○ Smoking |

Reproduced with permission: Therapeutics Choices. Sixth Edition. Ottawa, Canada: *Canadian Pharmacist Association* 2012, Table 2, page 1163.

Ankylosing spondylitis (AS)

Useful background: Remember:

- The four 'A's of ankylosing spondylitis: anterior uveitis, pulmonary apical fibrosis, aortic regurgitation, Achilles tendonitis
- Psoriasis and Reiter's syndrome can also cause sacroiliitis

Source: Baliga RR. *Saunders/Elsevier* 2007, pages 340 and 341.

- Perform a focused physical examination for ankylosing spondylitis.

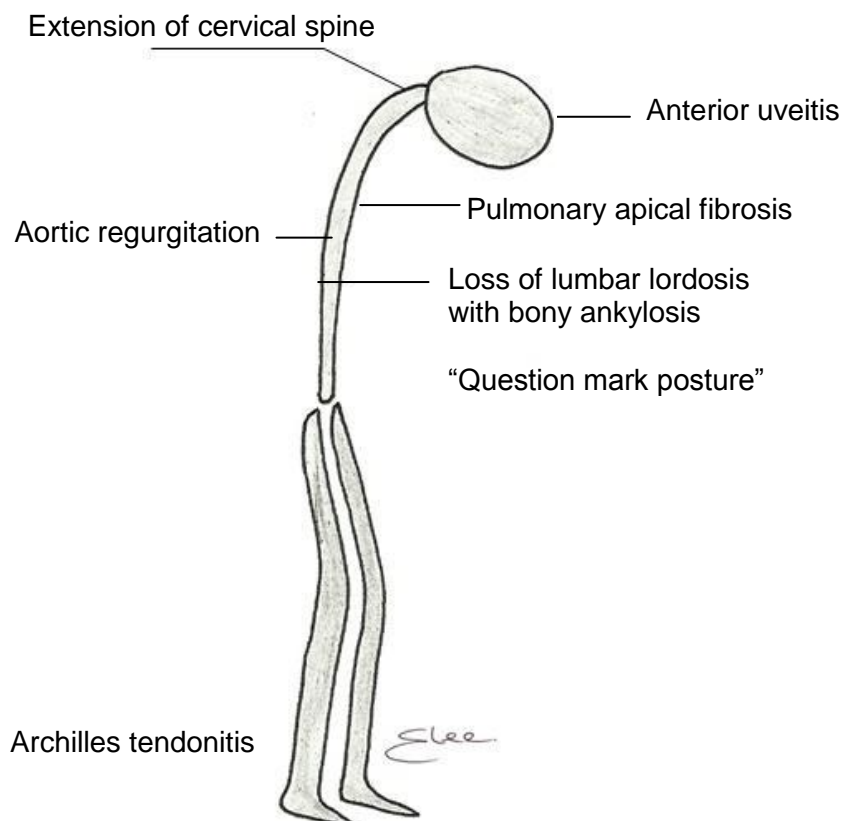
Useful background:

- The back, sacroiliac joints, and hips
 - Loss of lumbar lordosis and thoracic kyphosis
 - Severe flexion deformity of the lumbar spine (rare)
 - Tenderness of the lumbar vertebrae
 - Reduction of movement of the lumbar spine in all directions (whole body turns)
 - Tenderness of the sacroiliac joints
 - Late involvement of cervical spine, with grating sensations on movement of neck
 - Occiput-to-wall distance (inability to make contact when heel and back are against the wall indicates upper thoracic and cervical limitation)



- 'Question mark' posture (loss of lumbar lordosis, fixed kyphoscoliosis of the thoracic spine with compensatory extension of the cervical spine)
- Protuberant abdomen
- Perform Schober's test- this involves marking points 10 cm above and 5 cm below a line joining the 'dimple of Venus' on the sacral promontory. An increase in the separation of less than 5cm during full forward flexion indicates limited spinal mobility
- Finger-floor distance (a simple indicator but is less reliable because good hip movement may compensate for back limitation)
- Chest expansion at nipple line < 5 cm (costovertebral involvement)
- Sacroiliac tenderness

➤ Postural change in advanced AS, 'question mark posture'



-
- Distal arthritis occurs in up to 30% of patients and may precede the onset of the back symptoms. Small joints of the hand and feet are rarely affected.



- Legs/ Feet
 - Achilles tendonitis
 - Plantar fasciitis
 - Cauda equine compression (rare lower limb weakness)
 - Loss of sphincter control
 - Saddle sensory loss
- Lungs
 - Decreased chest expansion (<5 cm, suggesting costo-vertebral involvement)
 - Pulmonary apical fibrosis, cavities
 - Mild restrictive lung disease
- Heart
 - Aortic regurgitation
- The eyes
 - Acute iritis (recurrent) – painful red eye in 10-15%
- CNS
 - Tetraplegia
- GI
 - Ulcerative colitis or Crohn's disease
 - Hepatosplenomegaly, amyloidosis
- GU
 - Renal enlargement (amyloidosis)
 - Proteinuria

Adapted from: Baliga RR. *Saunders/Elsevier* 2007, page 341; Talley NJ, et al. *Maclennan & Petty Pty Limited* 2003, page 289; Ghosh AK. *Mayo Clinic Scientific Press* 2008, Table 24-25, page 1009.

- Take a directed history for ankylosing spondylitis.
- Back stiffness and back pain-worse in the morning, improves on exercise and worsens on rest
- Symptoms in the peripheral joints (in 40%), particularly shoulders and knees.
- Onset of symptoms is typically insidious, and in the third to fourth decade
- Extra- articular manifestations:
 - Red eye (uveitis)
 - Diarrhea (GI involvement)
 - Aortic regurgitation



- Pulmonary apical fibrosis (worse in smokers)
- Causes of sacro-iliitis
 - Musculoskeletal
 - Ankylosing spondylitis
 - Reiter's disease
 - Psoriatic arthritis
 - Juvenile rheumatoid arthritis
 - IBD
 - Ulcerative colitis and Crohn's disease
 - Infection
 - TB
 - Brucellosis
 - Whipple's disease

Adapted from: Burton JL. *Churchill Livingstone* 1971, page114.

- Take a directed history for Ankylosing Spondylitis
 - Morning stiffness
 - Improves with exercise
 - Onset before age 40
 - Begins slowly
 - Pain persisting > 3 months
- Performance characteristics:
 - If ≥ 4 of the above historical points are positive, the sensitivity is 95% and specificity is 85%.
 - However, because of the low prevalence, the positive predictive value is still poor.

SO YOU WANT TO BE RHEUMATOLOGIST!

Q. A young man with low back pain is suspected as having sacro-ileitis. On examination, ankylosing spondylitis (AS) is diagnosed. What are the GI, MSK and infections disease associated with AS?

- A.
- GI
 - Crohn disease
 - Ulcerative colitis
 - Whipple disease
 - MSK
 - Juvenile rheumatoid arthritis
 - Psoriatic arthritis
 - Reiter disease
 - Infections
 - TB
 - Brucellosis



- Give the distinction between peripheral arthritis vs. sacroiliitis in Crohn disease (CD) and ulcerative colitis (UC)

| | Peripheral arthritis | Sacroiliitis |
|--|---|--|
| ➤ Frequency of involvement | ○ CD > UC (10% vs. 5%) | ○ CD > UC (30% vs. 10%) |
| ➤ Relationship to B27 | ○ 25% of type I arthritis
○ Type II unrelated | ○ ~ 100% of B27 positive IBD patients develop sacroiliitis |
| ➤ Relationship to IBD disease extent/activity | ○ Yes (type I), no (type II)
○ Coincident bowel/joint flares in ~65% of type I, not in type II | ○ No
○ May even precede bowel symptoms |
| ➤ Responsive to DMARD (sulfasalazine first choice) | ○ Yes | ○ No |
| ➤ Responsive to bowel resection | ○ UC, yes, CD no | ○ Neither CD or UC |

Note: both peripheral arthritis and sacroiliitis may cause an exacerbation of IBD when used to treat the associated peripheral vs axial arthropathy.

Adapted from: Davey P. *Wiley-Blackwell* 2006, page 405.

Useful background: Utility of the Clinical Examination for Herniated Disk or Cancer among

Patients with Back Pain

| Test | PLR | NLR |
|--|----------|-----------|
| ➤ Sit-to-stand test for upper lumbar herniation | 26 | 0.35 |
| ➤ Nocturnal pain for cancer-induced back pain | 1.7 | 0.17 |
| ➤ Crossed straight-leg raise for disk herniation | 1.6-5.8 | 0.59-0.90 |
| ➤ Ipsilateral straight-leg raise for disk herniation | 0.99-2.0 | 0.04-0.5 |

Abbreviation: NLR, negative likelihood ratio; PLR, positive likelihood ratio

Source: Simel DL, et al. *JAMA* 2009, Table 7-8, page 86



- Perform a focused physical examination for primary vs secondary osteoarthritis.

| | Primary | Secondary |
|-----------------------------|---|---|
| ➤ Symmetrical | | |
| ➤ Many joints | ○ Many | ○ Few |
| ➤ Previously damaged joints | ○ No | ○ Yes |
| ➤ Fingers affected | ○ Yes | ○ No |
| ➤ Sites affected | <ul style="list-style-type: none"> ○ Distal (Heberden's nodes) and proximal (Bouchard's nodes) interphalangeal joints, and metacarpophalangeal (MCP) joints of the thumbs ○ Acromioclavicular joints ○ Small joints of the spine (lower cervical and lumbar) ○ Knees, ○ Metatarsophalangeal (MTP) joints of the great toes | <ul style="list-style-type: none"> ○ Hip ○ Knees ○ Intervertebral disc |

Adapted from: Talley NJ, et al. *MacLennan & Petty Pty Limited* 2003, Table 8.4, page 253.

- Give the radiological features of Ankylosing Spondylitis
 - Bilateral erosive SI disease (with later sclerosis)
 - Erosion in intervertebral facets and costo-vertebral joints
 - Calcified spinal ligaments
 - Erosion in limb joints (especially hips)
 - Irregularity of weight bearing surfaces

Source: Burton JL. *Churchill Livingstone* 1971, page 113.



SO YOU WANT TO BE A RHEUMATOLOGIST!

- Q. In the context of ankylosing spondilitis, what is the normal chest expansion, what is the Schober test?
- A.
- Normal chest expansion is 5 cm (2")
 - Schober test – 10 cm. above the dimples of venus, flex forward maximally, the extension should by 5 cm (10cm → 15cm).

Psoriatic arthritis

- Perform a focused physical examination for psoriatic arthritis.
- Arthritis (in only 5% of persons with psoriasis)
 - Asymmetrical terminal joint involvement
 - Monoarticular and oligoarticular arthritis of the hands and feet.
 - May occur with psoriatic nail changes
 - Symmetrical joint involvement (most common like rheumatoid arthritis, but seronegative)
 - Arthritis mutilans (destructive polyarthritis, with telescoping of digits)
- Nail changes (nails involved in 80% of persons with associated arthritis)
 - Pitting, onycholysis, ridging, hyperkeratosis, discoloration
 - Psoriatic, reddish plaques, with silvery scales and well-defined edges (most prominent on elbows [extensor surfaces], scalp, submammary and umbilical regions)

Adapted from: Baliga RR. *Saunders/Elsevier* 2007, page 343; Talley NJ, et al. *Maclennan & Petty Pty Limited* 2003, page 290.

Useful background: The radiological features of psoriatic arthritis

- 'Fluffy' periostitis
- Destruction of small joints
- 'Pencil and cup' appearance
- Osteolysis, ankylosis and telescoping in arthritis mutilans
- Non marginal syndesmophytes in spondylitis (*Q J Med* 1977;46:411)

Adapted from: Baliga RR. *Saunders/Elsevier* 2007, page 343.



- Perform a focused physical examination to distinguish psoriatic arthritis (PA) from rheumatoid arthritis (RA).

| | PA | RA |
|---|---------------|---------------------------------|
| ○ Interphalangeal joints | All IP joints | Distal IP joint rarely affected |
| ○ Joint space | AT | Narrow |
| ○ Joint destruction | | Yes |
| ○ Loss of joint | | Yes |
| ○ Necrotic deformity | No | Yes |
| ○ Erosions of joint surface | | Yes |
| ○ Thickened periarticular structures (aka spurring) | | Yes |
| ○ Rheumatoid nodules | No | Yes |
| ○ Decalcification of bone | | Yes |
| ○ Nail changes | Yes | No |

- Perform a focused physical examination for erythema multiforme.

➤ Definition

- Target-shaped lesions, usually over the limbs
- Three concentric zones of colour change – a central, dark, purple area or blister surrounded by a pale, edematous round zone which in turn is surrounded by a peripheral rim of erythema <red-white-blue
- Pleomorphic eruption with macules, papules and bullae

➤ Causes

- Infections (herpes simplex, mycoplasma, streptococci)
- Drug hypersensitivity (sulphonamides, penicillin, barbiturates, salicylates, antimalarials)
- Collagen vascular disorder (SLE, dermatomyositis, periarteritis nodosa)
- Malignancy (carcinomas and lymphomas)
- Multiple myeloma
- Idiopathic – in 50% of cases no cause may be found

➤ Complications

- Stevens-Johnson syndrome (as erythema multiforme major)
 - Fever and mucous membrane involvement (usually oral cavity, eye and genital), in addition to the eruptions of erythema multiforme

Adapted from: Baliga RR. *Saunders/Elsevier* 2007, pages 423 and 424.



Systemic lupus erythematosus

Useful background: Systemic lupus erythematosus (SLE) is a prototype autoimmune disease affecting 1 in 1000-2000 individuals, predominantly young women in their reproductive years. For research purposes, the American College of Rheumatology has developed criteria for the diagnosis of SLE.

Useful background: Criteria for the Diagnosis of SLE^a

| Criteria | Comment |
|-------------------------------------|---|
| ➤ Malar “butterfly” rash | ○ Rashes occur in 70% of individuals, often photosensitive |
| ➤ Photosensitivity | ○ Rash on sun exposure |
| ➤ Discoid rash | ○ Plaques |
| ➤ Mucosal ulcers | |
| ➤ Arthritis | ○ Occurs in up to 80% |
| ➤ Serositis, pleuritis/pericarditis | ○ Occurs in up to 50% |
| ➤ Kidney Involvement | ○ Proteinuria >0.5 g/day or cellular casts, occurs in up to 40% |
| ➤ Central nervous system | ○ Seizures
○ Psychosis (15%) in the absence of drugs or metabolic causes |
| ➤ Hematologic | ○ Antibodies to white blood cells (leukopenia), platelets (thrombocytopenia) and/or
○ Red blood cells (hemolytic anemia) |
| ➤ Immunologic | ○ Antibodies to DNA, phospholipids (anticardiolipin, lupus anticoagulant) and/or Smith nuclear antigen (anti-Sm) |
| ➤ Antinuclear antibodies (ANA) | ○ Abnormal titers of ANA in the absence of drugs known to be associated with drug-induced lupus |

^a For diagnosis at least 4 of 11 criteria are required.

Reproduced with permission: Therapeutics Choices. Sixth Edition. Ottawa, Canada: *Canadian Pharmacist Association* 2012, Table 1, page 1057.



- Definition: Systemic lupus erythematosus (SLE) is an autoimmune disorder due to the loss of tolerance to nuclear antigens and the development of autoantibodies, leading to a spectrum of localized or systemic disease, affecting the skin, joints, CNS, kidneyneys, as well as the hematological system, and serositis, pleuritis and pericarditis.

Useful Background: Examples of autoantibodies in SLE

| | Prevalence | Operating characteristics and clinical associations |
|---|------------|---|
| ○ ANA (antinuclear antibodies) | 90% | <ul style="list-style-type: none"> - Sensitive +++ - Not specific |
| ○ Antibodies to histones | 80% | <ul style="list-style-type: none"> - Seen in idiopathic as well as drug-induced SLE |
| ○ Antibodies to nature DNA | 60% | <ul style="list-style-type: none"> - Specific +++ - Linked to renal involvement |
| ○ Antibosies to SSA / R _o and SSB / La | 30% | <ul style="list-style-type: none"> - Linked to <ul style="list-style-type: none"> ▪ Photosensitivity of skin ▪ Drug eyes ▪ Neonatal complications (e.g. congenital complete heart block) |
| ○ Antiphospholipid antibodies | 30% | <ul style="list-style-type: none"> - Linked to <ul style="list-style-type: none"> ▪ Thrombosis ▪ Complications in pregnancy (preeclampsia, loss of fetus) |

- Perform a focused physical examination for systemic lupus erythematosus (SLE) and its complications.

➤ General appearance

- Cushingoid
- Weight
- Altered mental state
- Fever

➤ Head

- Hair: Alopecia, lupus hairs
- Eyes – scleritis, cytooid lesions
- Mouth – ulcers, infection

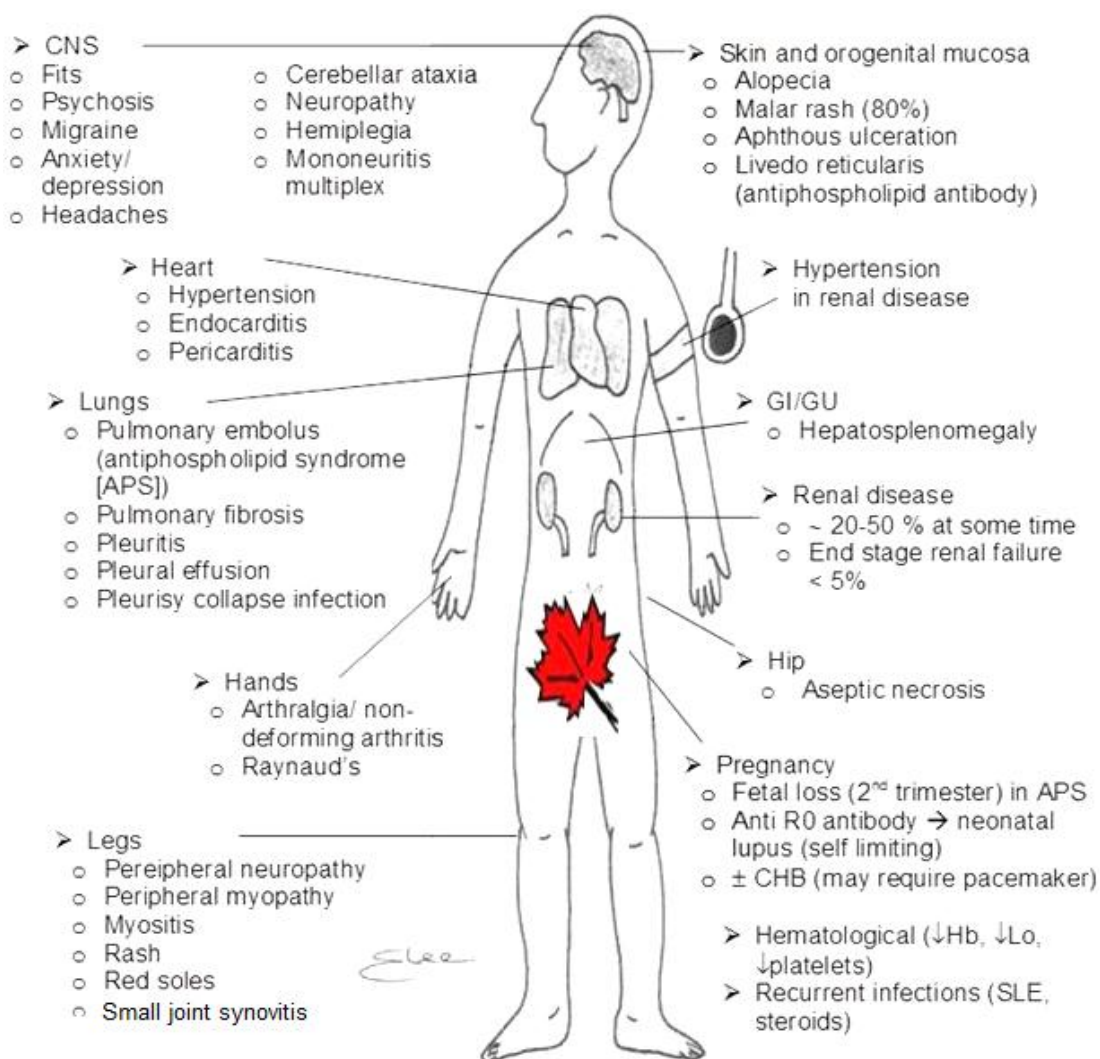


- Butterfly rash
- Cranial nerve lesions
- Cervical lymph adenopathy

➤ Arms

- Livedo reticularis
- Purpura
- Proximal myopathy (active disease or result steroid treatment)

Useful background: Physical examination for systemic lupus erythematosus.



Adapted from: Davey P. *Wiley-Blackwell* 2006, page 409 and Talley NJ, et al. *Maclennan & Petty Pty Limited* 2003, Figure 8.37, page 292.



Useful background: Diagnostic criteria for SLE. Four out of eleven criteria present at any time is required for diagnosis of SLE.

| Clinical | Laboratory |
|--|---|
| <ul style="list-style-type: none"> ➤ Skin <ul style="list-style-type: none"> ○ Malar rash ○ Photosensitive rash ○ Discoid lupus rash ○ Mucosal aphthous ulceration ○ Photo sensitivity ➤ CNS <ul style="list-style-type: none"> ○ Neurological involvement ○ Seizures or psychosis ➤ Kidney <ul style="list-style-type: none"> ○ Proteinuria or casts ➤ Serositis: Pleuritis or pericarditis ➤ Arthritis <ul style="list-style-type: none"> ○ Nonerosive ➤ Mouth <ul style="list-style-type: none"> ○ Oral ulcers | <ul style="list-style-type: none"> ➤ Hematological abnormalities <ul style="list-style-type: none"> ○ Immunological abnormalities ○ ANA positive (95%) ○ Hemolytic anemia ○ Leukopenia ○ Thrombocytopenia ○ Positive LE cell ○ Anti-DNA antibody ○ False-positive |

Adapted from: Davey P. *Wiley-Blackwell* 2006, page 410, Table 204.1; Baliga RR. *Saunders/Elsevier* 2007, page 467.

- Perform a focused physical examination for skin, CNS and systemic changes in SLE.
 - CNS
 - Neuropsychiatric symptoms
 - Seizures
 - Skin
 - Skin rash (butterfly rash* on face) in sun-exposed areas
 - Livedo reticularis
 - Alopecia
 - Raynaud's phenomenon
 - Follicular plugging
 - Scales
 - Telangiectasia
 - Scarring (bridge of the nose and cheeks)



- Mouth ulcers
 - Bleeding from gums
 - Excessive menstrual bleeding
 - Purpura (due to thrombocytopenia)
 - Cushingoid due to steroids
- Systemic
- Hypertension, edema (suggesting renal involvement)
 - Fever
 - Lymph adenopathy

Scleroderma

- Perform a focused physical examination for scleroderma and its complications.
- General appearance
- 'Bird-like' facies
 - Weight-loss (malabsorption)
 - Fever
- Head
- Hair - alopecia – hair loss
 - Eyes – loss of eyebrows, anemia, dryness (Sjögren's), difficulty opening eyes
 - Mouth – difficulty smiling, raising forehead skin
 - Ischemia, end of nose
 - Pigmentation
 - Telangiectasia
 - Neck muscles – wasting and weakness
- Chest
- Tight skin
 - Heart – cor pulmonale, pericarditis, congestive heart failure, hypertension (renal involvement)
 - Lungs – fibrosis, reflux aspiration pneumonitis, chest infections, alveolar cell carcinoma, vasculitis
- GI/GU
- Dysphagia
 - Delayed gastric emptying (succussion splash)
 - Malnutrition (small bowel bacterial overgrowth [diarrhea, malabsorption])
 - Wide-mouthed colonic diverticulae
 - Proteinuria



- Arms
 - Edema (early) or skin thickening and tightening
 - Pigmentation
 - Vitiligo
 - Proximal myopathy
- Hands
 - CRST syndrome – calcinosis, Raynaud's (atrophy distal tissue pulp), sclerodactyly and telangiectasia
 - Dilated capillary loops in nailfolds
 - Small joint arthropathy and tendon crepitus
 - Fixed flexion deformity
 - Hand function
- Legs
 - Skin lesions
 - Vasculitis
 - Small joint arthropathy
 - Patellar crepitus

Adapted from: Talley NJ, et al. *MacLennan & Petty Pty Limited* 2003, Figure 8.39, page 295.

Raynaud's phenomenon

Useful background: Causes of Raynaud's phenomenon

- Definition: Paroxysmal digital ischemia, usually accompanied by pallor and cyanosis and followed by erythema (white-blue-red).
- General
 - Malnutrition and cachexia
- Collagen vascular' disease
 - Systemic sclerosis
 - Polyarteritis
 - SLE
 - RA
 - Sjogren's
 - Dermatomyositis
 - Raynaud's disease
- MSK
 - Cervical spondylosis
 - Paralysis or disuse of a limb
 - Cervical rib, hyperabduction syndrome



- Blood
 - Embolus, thrombosis or stenosis
 - Arteriosclerosis
 - Increased blood agglutination
 - Cold agglutinins
 - Dysproteinaemias
 - Cryoglobulinemia
 - Macroglobulinemia
 - Hyperglobulinemia
 - Polycythaemia, leukemia
 - Reflex vasoconstriction
- Infection
- Trauma
 - Cold injury
 - Frost bite
 - Trench foot
 - Vibrating machinery
 - Injury (Volkmann's ischemia)
- Toxin
 - Toxins: ergot, heavy metals, tobacco
- Drugs – (the P's e.g. penicillin, phenothiazines, phenylbutazone, propylthiouracil, and many others)
- Allergy
 - Allergic granulomatosis

Adapted from: Burton JL. *Churchill Livingstone* 1971, page 110; Talley N. J., et al. *MacLennan & Petty Pty Limited* 2003, Table 8.12, pages 299 and 300.

- Take a directed history and perform a focused physical examination for secondary Raynaud phenomenon (not related to drug use).
 - MSK disease
 - Sclerodactyly
 - Carpal tunnel syndrome
 - Telangiectasis
 - Pulmonary fibrosis
 - Lesions from digital ischemia
 - Endocrine
 - Hypothyroidism
 - Vascular diseases
 - Occupational hazards
 - E.g. jack hammer

Abbreviation: MSK, musculoskeletal



SO YOU WANT TO BE A RHEUMATOLOGIST!

Q. In the context of the Raynaud phenomenon, explain what is the Allen test.

- A.
- Clench the hand and compress both the radial and the ulnar arteries
 - Release just one, then second compression on an artery

- Perform a directed physical examination for Raynaud's phenomenon (white->blue->red fingers/toes in response to cold temperature).
- Reflex
 - Raynaud's disease (idiopathic)
 - Vibrating machinery injury (jackhammer use)
 - Cervical spondylosis
 - Shoulder hand syndrome
 - Causalgia
- Connective tissue disease
 - Scleroderma (90-100%), CRST syndrome, mixed connective tissue disease (90-100%)
 - Systemic lupus erythematosus (SLE;15%)
 - Polyarteritis nodosa (PAN)
 - Rheumatoid arthritis (10%)
 - Polymyositis
 - Sjogren's
 - Dermatomyositis
 - Aortic arch syndrome (Takayasu's)
- Arterial disease
 - Thoracic outlet obstruction
 - Embolism or thrombosis
 - Buerger's disease (thromboangiitis obliterans)
 - Trauma – vibration-induced
- Hematological disease
 - Polycythemia (increased blood viscosity)
 - Leukemia
 - Dysproteinemia (cryo-, macro-, hyperglobulinemia)
- Neurological
 - Paralysis
 - Disuse of limb
- Drugs/Poisons
 - Beta-blockers, ergotamine, bleomycin, vinyl chloride



- Cold Injury
- Malnutrition, cachexia

Adapted from: Talley NJ, et al. *MacLennan & Petty Pty Limited* 2003, Table 8.6, page 255; and Ghosh AK. *Mayo Clinic Scientific Press* 2008, Table 24-33, page 1017.

Vasculitis/Arteritis

- Give 20 causes of arteritis
- MSK
 - Rheumatic and collagen vascular diseases
 - Rheumatoid arthritis
 - Sjogren syndrome
 - Ankylosing spondylitis
 - Rheumatic fever
 - Henoch- Schonlein purpura
 - SLE
 - Dermatomyositis
 - Systemic sclerosis
 - *Polyarteritis nodosa* and related disorders
 - Polyarteritis nodosa (20% associated with HBV infection)
 - Cranial arteritis
 - Aortic arch syndrome (incl. Takayashu disease)
 - Polymyalgia rheumatica (giant cell arteritis)
 - Wegener's granuloma and lethal midline granuloma
 - Allergic granulomatosis (Churg)
 - Hypersensitivity angiitis (Zeek)
- Hematological disease
 - Cryoglobulinemia
 - Paraproteinemia
 - Behcet syndrome
- Infection
 - During rash of meningococemia, scarlatina, typhus fever
 - Extension of perivascular inflammation (e.g., cellulites, abscess, meningitis)
 - Septicemia, septic emboli



Ulceration

- *Endarteritis obliterans*
 - Any chronic ulcer (e.g., peptic ulcer, ulcerative colitis)
 - Syphilis
 - TB
 - Buerger syndrome
 - HBV
 - Cutaneous vasculitis
 - Henoch-schonlein purpura
 - Erythema nodosum
 - Nodular vasculitis
 - Erythema induratum
 - Malignant atrophic papulosis
- Drugs
-

Adapted from: Burton JL. *Churchill Livingstone* 1971, page 111.

- Take a directed history and perform a focused physical examination for systemic vasculitis
- General
- Fever
 - Fatigue
 - Weight loss
- CNS
- Seizures
 - Cerebrovascular accident
 - Mononeuritis multiplex
 - Peripheral neuropathy (mononeuritis multiplex)
- Eye/
sinuses
- Retinal hemorrhage
 - Necrotizing (hemorrhagic) sinusitis
- CVS
- Coronary artery disease
- Lung
- Interstitial pneumonitis
 - Hemoptysis
 - Pulmonary infiltrates or nodules
- MSK
- Myalgia
 - Arthralgia
 - Arthritis



- GU
 - Focal necrotizing glomerulonephritis
 - Abnormal renal sediment
 - Hypertension
 - Testicular pain
- GI
 - Ischemic bowel
- Skin
 - Palpable purpura
 - Livedo reticularis
 - Cutaneous infarctions
 - Nodules
 - Ulcerations

Adapted from: Ghosh AK. *Mayo Clinic Scientific Press* 2008, Table 18-2, page 695, and Table 24-14, page 988.

- Chapel Hill consensus on the nomenclature of systemic vasculitis
 - Large-vessel vasculitis
 - Giant cell (temporal) arteritis
 - Takayasu arteritis
 - Medium-size vessel vasculitis
 - Classic polyarteritis nodosa
 - Kawasaki disease
 - Small-vessel vasculitis
 - Microscopic polyangiitis*
 - Wegener granulomatosis*
 - Churg-Strauss syndrome*
 - Henoch-Schönlein purpura
 - Essential cryoglobulinemic vasculitis
 - Cutaneous leukocytoclastic vasculitis
 - Anti-glomerular basement membrane disease
- Other causes of small – vessel vasculitis
 - Systemic vasculitis
 - Polyarteritis (primary and secondary)
 - Takayasu arteritis
 - Serum sickness
 - Goodpasture syndrome
 - Nonsystemic
 - Hypocomplementemic urticarial vasculitis
 - Leukocytoclastic vasculitis related to:
 - Rheumatoid arthritis
 - Sjögren syndrome
 - Systemic lupus erythematosus



- Other connective tissue diseases
 - Drug-induced and postinfectious angitis
 - Malignancy-associated vasculitis
 - Inflammatory bowel disease
 - Organ transplant-associated vasculitis
 - Hypergammaglobulinemic purpura of Waldenström

* Strongly associated with antineutrophil cytoplasmic autoantibody (ANCA).

Chapel Hill consensus nomenclature, quoted in Ghosh AK. *Mayo Clinic Scientific Press* 2008, Table 18-1, page 695, and adapted from Table 24.18, page 994.

- Give 7 syndromes which may mimic vasculitis (i.e. the differential diagnosis of vasculitis)
 - CVS
 - Cardiac myxoma with embolization
 - Infective endocarditis
 - Atheroembolism: cholesterol or calcium emboli
 - Arterial coarctation or dysplasia
 - Blood
 - Thrombotic thrombocytopenic purpura
 - Antiphospholipid syndrome
 - MSK
 - Pseudoxanthoma elasticum
 - Ehlers-Danlos type 4
 - Infection
 - Infectious angitis
 - Lyme disease
 - Rickettsial infection
 - HIV infection

Abbreviation: HIV, human immunodeficiency virus

Adapted from: Ghosh AK. *Mayo Clinic Scientific Press* 2008, Table 24-13, page 988.



Polymyalgia rheumatica-like syndromes

Polymyalgia Rheumatica and Giant-Cell Arteritis

➤ Definition:

- “Polymyalgia rheumatic (PMR) and giant-cell arteritis (GCA) are related conditions that affect elder individuals and may reflect 2 ends of a spectrum of the same disease.....
- PMR is characterized by aching and stiffness in the muscle groups of the neck, pectoral and pelvic girdles and thighs.....characterized pathologically by low grade synovitis of the proximal joints...with proximal muscle tenderness but not weakness.
- GCA is a chronic vasculitis of large and medium-sized arteries with a predominance for the cranial branches of the arteries originating from the aortic arch” characterized pathologically by granulomatous inflammation with giant cells affecting arterial walls. (Hanley JG, et al. In: Therapeutic Choices. Grey J, Ed. 6th Edition, *Canadian Pharmacists Association*: Ottawa, ON, 2011, page 1002).
- Common symptoms include headache, jaw claudication and vessel loss.
- About 20% of PMR patients develop GCA concurrently or subsequent to the diagnosis of PMR; conversely,
 - About 50% of GCA → PMR

➤ Definition: “Fibromyalgia is characterized by chronic widespread pain, increased tenderness at specific points known as “tender points”, fatigue, headache and unrefreshing sleep. Mood disorder such as depression or anxiety are commonly associated with fibromyalgia” (Finestone AM, et al. In: Therapeutic Choices. Grey J, Ed. 6th Edition, *Canadian Pharmacists Association*: Ottawa, ON, 2011, page 983).

- Take a directed history and perform a focused physical examination for causes of polymyalgia rheumatica-like syndromes.

➤ MSK

- Fibromyalgia (FMN)
- Polymyalgia rheumatica (PMR)
- Seronegative rheumatoid arthritis (SRA)
- Polymyositis
- Systemic vasculitis
- Systemic lupus erythematosus (SLE)
- Polyarticular osteoarthritis
- Osteomalacia (OA)
- Remitting seronegative, symmetric synovitis and peripheral edema



- Metabolic
 - Hypo-/Hyperthyroidism
 - Hyperparathyroidism
- Infection
 - Infectious endocarditis
- Infiltration
 - Paraneoplastic syndromes
 - Systemic amyloidosis
- Mental health
 - Depression

Adapted from: Ghosh AK. *Mayo Clinic Scientific Press* 2008, Table 24-11, page 987.

PMR, FMN, SRA and polymyositis may cause pain, tenderness, and morning stiffness. In FMN the ESR is normal, and there is response to steroids in SRA and there usually is a response to steroids.

Useful background: Differential Diagnosis of Polymyalgia Rheumatica (PMR)

| Diagnosis | Distinguishing Features From PMR |
|------------------------|--|
| ➤ Myositis | <ul style="list-style-type: none"> ○ Muscle weakness on physical examination ○ ↑ CPK ○ Abnormalities on EMG and muscle biopsy |
| ➤ Fibromyalgia | <ul style="list-style-type: none"> ○ Usually seen in younger patients ○ Widespread pain and tenderness at a significant number of soft tissue sites ○ Not limited to the shoulders and hips ○ Normal ESR and CRP |
| ➤ Rheumatoid Arthritis | <ul style="list-style-type: none"> ○ Synovitis distal to the wrist and ankle ○ Seropositivity for rheumatoid factor (RF) ○ Consider an-CCP antibodies if RF negative ○ Inadequate response to low-dose prednisone therapy ○ Radiographic erosions |
| ➤ Malignancy | <ul style="list-style-type: none"> ○ As directed by clinical examination, laboratory evaluation (e.g., iron deficiency anemia) and lack of response to conventional therapy ○ The incidence of malignancy is not increased in PMR or GCA |

Abbreviations: anti-CCP = anti-cyclic citrullinated peptide; CPK = creatine phosphokinase; CRP = C-reactive protein; EMG = electromyography; ESR = erythrocyte sedimentation rate

Reproduced with permission: Therapeutics Choices. Sixth Edition. Ottawa, Canada: *Canadian Pharmacist Association* 2012, Table 1, page 1004.



- Perform a focused physical examination to distinguish PMR from the other causes of polymyalgia-rheumatica (PMR) – like syndromes.

| Characteristic | PMR | FMN | SRA | Polymyositis |
|------------------------|---|-----------------|-----------|-----------------|
| ➤ Age | > 50 yrs | Usually >50 yrs | Any age | Any age |
| ➤ Physical examination | Hip, shoulder girdle tenderness and limited ROM | Tender points | Synovitis | Muscle weakness |

Abbreviations: CPK, creatine phosphokinase; ESR, erythrocyte sedimentation rate; FMN, fibromyalgia; N, normal; PMR, polymyalgia rheumatica; RA, rheumatoid arthritis; ROM, range of motion; SRA, seronegative rheumatoid arthritis.

Adapted from: Ghosh AK. *Mayo Clinic Scientific Press* 2008, Table 24-11, page 987.

Aseptic necrosis of the bone

- Take a directed history of the cause of aseptic necrosis of the bone. (acronym: **ASEPTIC**).
- Alcohol, arterosclerotic vascular disease
- Steroids, sickle cell anemia (Gaucher storage disease)
- Emboli (fat, cholesterol)
- Postradiation necrosis
- Trauma
- Idiopathic
- Connective tissue disease (especially SLE), caisson disease

Abbreviations: SLE, systemic lupus erythematosus

Source: Ghosh AK. *Mayo Clinic Scientific Press* 2008, Table 24-7, page 982.

Charcot's joint

- Perform a directed physical examination for Charcot's joint (neuroarthropathy).
- Chronic, progressive, degenerative arthropathy arising from loss of sensory innervations of joint
 - Early redness, heat, swelling, tenderness;



- Late enlargement of affected joint with crepitus, deformity, swelling and instability (usually hypermobile joint)
- Associated muscle atrophy (compare joint with the normal contralateral joint)
- Feet and ankles affected commonly, from peripheral neuropathy and local injury
- May be complicated by osteomyelitis from skin ulcers
- Decreased sensation (position and vibration, pain and temperature)
- Conditions associated with the development of Charcot's joint
 - Diabetes mellitus
 - Tabes dorsalis
 - Syringomyelia
 - Myelomeningocele
 - Leprosy

Adapted from: Baliga RR. *Saunders/Elsevier* 2007, pages 349 and 350.

SO YOU WANT TO BE RHEUMATOLOGIST!

Q. In the context of severe osteoarthropathy associated with impaired sensation to pain (Charcot arthropathy), what are the radiological changes?

- A.
- Osteoarthropathy
 - Calcification
 - Synovium
 - Intra articular base bodies
 - Differentiate clinically from similar picture causes by repeated injection of steroids into the joint

- Perform a focused physical examination of Charcot joint
- Definition: "a chronic, progressive arthropathy resulting from a disturbance in the sensory innervation of the joint"
- Joint
 - Warm, swollen, tender
 - Enlarged
 - Crepitus
 - ↑ mobility
- Cause of sensory loss to the affected joint
 - Metabolic
 - Diabetes
 - Degenerative
 - Syringomyelia (dissociated sensory loss)
 - Myelomeningocele



- Infections
 - Syphilis
 - Leprosy

Arthropathy

- Give the radiological features of Osteo-arthrosis
 - New bone formation
 - Osteophytes
 - Peri-articular ossicles
 - Loose bodies
 - Cartilage loss (often confined to weight bearing surface)
 - Sclerosis and subchondral cavitation
 - Subluxation of hip, shoulder, terminal IP joints
 - No ankylosis

Source: Burton JL. *Churchill Livingstone* 1971, page 113.

Useful background: Causes of hypermobile joints

- Marfans
- Ehlers-Danlos
- Osteogenesis imperfecta
- Inflammatory polyarthritis (e.g. RA)
- Charcot's arthropathy
- Homocystinuria
- Hyperlysinemia
- Idiopathic

Source: Burton JL. *Churchill Livingstone* 1971, page 113.

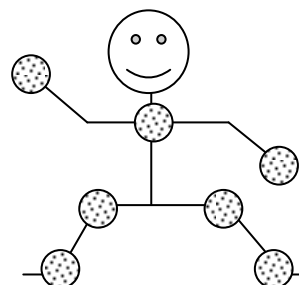
Useful background: Patterns of polyarthropathy

- Primary osteoarthrosis
 - Symmetrical, affecting many joints
 - Knees
 - Great toes and thumbs, MP joints
 - Fingers: terminal IP joints
 - Acromio-clavicular joints
 - Small joints of spine



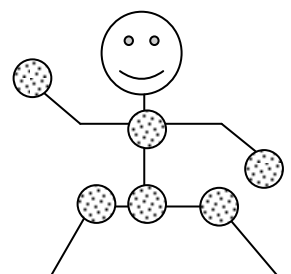
- Secondary osteoarthritis
 - Asymmetrical, affecting weight bearing joints
 - Knee
 - Hip
 - Intervertebral discs

- Rheumatoid Arthritis
 - Hands: intercarpal joints, MP joints and proximal IP joints
 - Feet: tarsal and lateral MP joints
 - Knees
 - Small joints of cervical spine and subacromial bursae

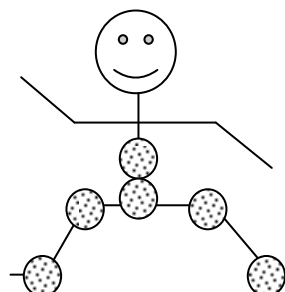


- Psoriasis
 - Hands, terminal IP joints
 - Sacro-iliac joints
 - 'Rheumatoid' pattern

- Ankylosing spondylitis
 - Spine both sacro-iliac joints
 - Knees, shoulders, wrists



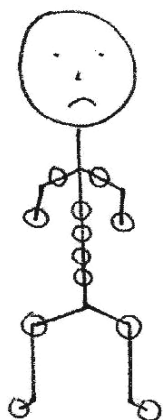
- Reiter's
 - Ankles and all joints of feet
 - Knees
 - Hips, sacro-iliac joint and spine



Adapted from: Burton JL. *Churchill Livingstone* 1971, page 112.



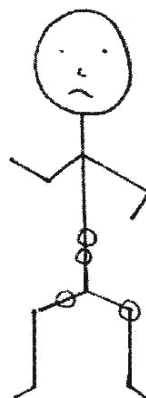
- Perform a focused physical examination for patterns of arthropathy.



Primary osteoarthritis

Symmetrical, affecting many joints

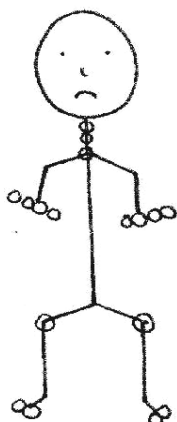
- Knees
- Great toes and thumbs: MP joints
- Fingers: terminal IP joints
- Acromio-clavicular joints
- Small joints of spine



Secondary osteoarthritis

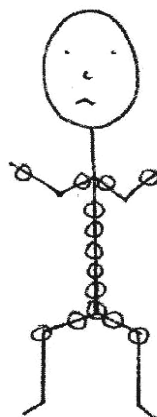Asymmetrical, affecting weight bearing joints:

- Knees
- Hips
- Intervertebral discs



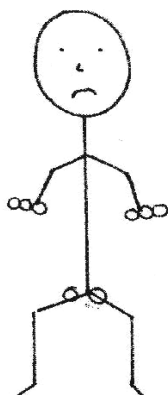
Rheumatoid arthritis

- Hands: intercarpal joints, MP joints and proximal IP joints
- Feet: tarsal and lateral MP joints
- Knees
- Small joints of cervical spine and subacromial bursae



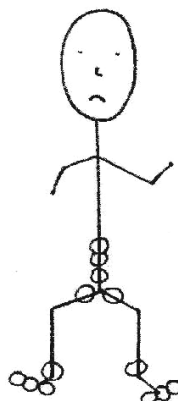
Ankylosing spondylitis

- Spine and both sacro-iliac joints
- Knees, shoulders, wrists



Psoriasis

- Hands, terminal IP joints
- Sacro-iliac joints
- 'Rheumatoid' pattern



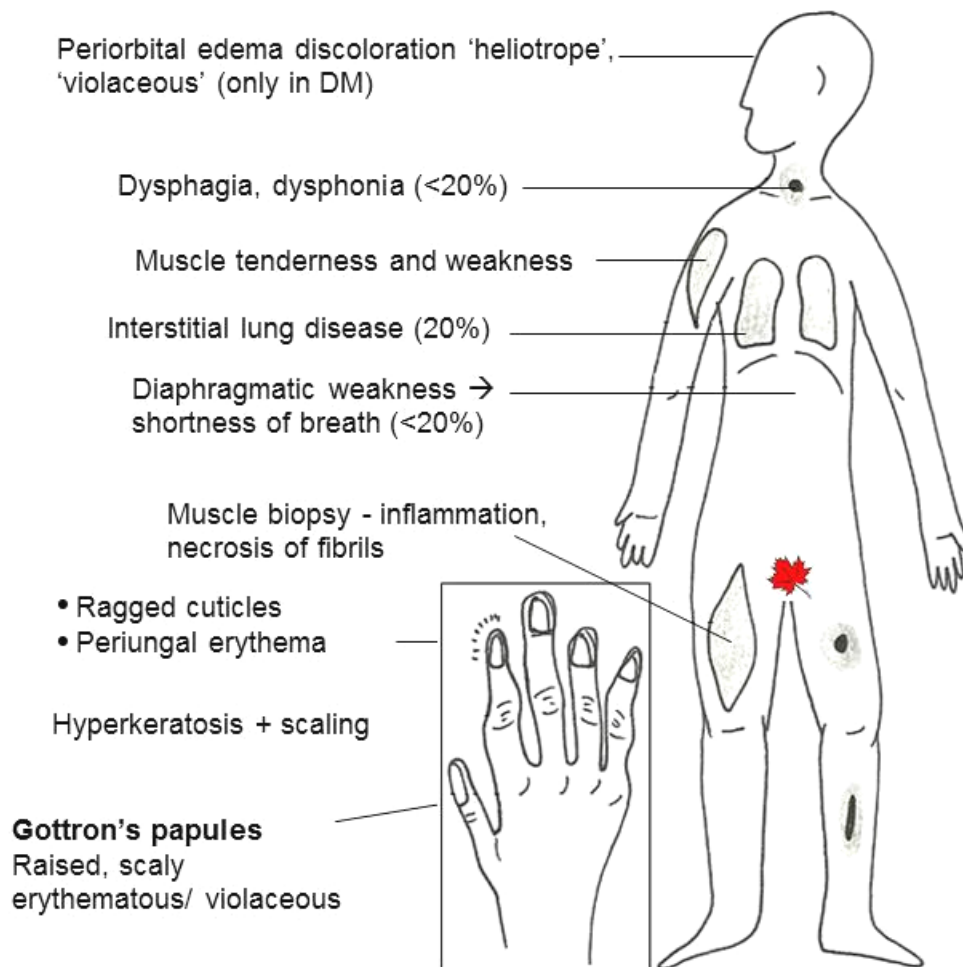
Reiter's

- Ankles and all joints of feet
- Knees
- Hips, sacro-iliac joint and spine

Source: Burton JL. *Churchill Livingstone* 1971, page 112.



- Perform a focused physical examination for polymyositis/ dermatomyositis.



Adapted from: Davey P. *Wiley-Blackwell* 2006, page 412.

Useful background: Key features of inflammation

➤ Symptoms

- Stiffness: worst in the early morning, or after prolonged inactivity, progressively easing as the day goes on
- Pain: inflammatory pain is usually present at rest as well as on movement
- Both are greatly relieved by non-steroidal anti-inflammatory drugs (NSAIDs)



- Examination
 - Overlying skin is warm and may be red
 - Tenderness is elicited all across the joint line
 - Swelling is fluid in nature, demonstrated by shifting the fluid within the joint cavity (the bulge or balloon sign)
 - Pain is elicited throughout the range of both active and passive movement

- Laboratory tests
 - Acute phase reactants raised (e.g. ESR and C-reactive protein)

Source: Davey P. *Wiley-Blackwell* 2006, page 114.

- Perform a focused physical examination for Marfan's syndrome.

- Skin
 - Small papules in the neck (Miescher elastoma)
- Heart
 - Mitral valve prolapse
 - Aortic aneurysm
 - Aortic regurgitation
- Chest
 - Pectus excavatum
 - Cystic lung disease
- Hands - for hypermobile joints and spidery fingers or arachnodactyly. Confirm by:
 - Thumb sign – asking the patient to clench his thumb in his fist; the thumb should not exceed the ulnar side of the hand in normal subjects but because of hypermobility and laxity of the joint in Marfan's disease it protrudes beyond his clenched fingers
 - Wrist sign – put the patient's fingers around his other wrist; normal subjects cannot overlap the thumb and little finger around the wrist but in Marfan's syndrome the little finger will overlap by at least 1 cm in 80%
- Head
 - Long-headedness (dolichocephalic, with bossing of frontal eminences and prominent supraorbital ridges)
- Eyes
 - Iridodonesis or ectopia lentis (subluxation upwards)
 - Thick spectacles
 - Blue sclera
- Palate
 - High-arched palate
- Spine
 - Scoliosis
 - Kyphosis
- Limbs
 - Long arms and leg
 - Arm span (A) longer than the length (H) ($A:H > 1.05$)
- Long legs

Adapted from: Baliga RR. *Saunders/Elsevier* 2007, pages 580 and 581.



Miscellaneous

Useful background: Interesting trivia

- Where is the pain felt in the following conditions?
 - Osteoarthritis – radiation of pain to groin
 - Bursitis – pain over the superior margin of the greater trochanter
 - Sacroiliitis – pain localizing to sacroiliac joint
- Describe true and apparent leg lengths and what the discrepancies in these lengths suggest.
 - True leg length – distance between anterior superior iliac spine to medial malleolus. Differences in length suggest hip joint pathology.
 - Apparent leg length – distance between umbilicus and medial malleolus. Differences in length suggest a pelvic tilt, possibly resulting from adduction abnormality.

Source: Jugovic PJ, et al. *Saunders/ Elsevier* 2004, page 171.

- Clinical Gems:
 - Reiter's Disease
 - "Calcaneal spur" (calcification of plantar fascia-highly suggestive of diagnosis)
 - Plantar fasciitis
 - Tendonitis
 - Periostial calcification

Source: Burton JL. *Churchill Livingstone* 1971. page 114.

- Trivia
 - Giant cell or temporal arteritis.
 - Wegener's granulomatosis.
 - Senile arteritis (polymyalgia rheumatic).
 - Takayasu's disease.

Source: Burton JL. *Churchill Livingstone* 1971, page 114.

TO YOU WANT TO BE A WANT A BE!

Q. In the context of pain along the radial side of the wrist, what is Finkelstein's sign?

- A.
- Tenosynovitis of tendons of the thumb passing over the radius bone causes pain
 - The pain is reproduced by placing the thumb in the palm of the hand, and wrapping the fingers around the thumb.
 - The wrist is deviated to the ulnar side.



Useful background

- Active movements of the cervical spine and their normal range of motion

| Maneuver
Thoracic and lumbar | Normal range of motion | |
|---|------------------------|--------------|
| | Thoracic spine | Lumbar spine |
| ➤ Forward flexion: ('Bend forward and touch your toes')* | 20-45° | 40-60° |
| ➤ Extension: ('Arch your back') | 25-45° | 20-35° |
| ➤ Side flexion: ('slide your hand down your leg')** | 20-40° | 15-20° |
| ➤ Rotation: ('rotate toward each side') | 35-50° | 3-18° |
| ➤ Chest expansion: (difference between rest and full inspiration) | Normal is > 5cm | N/A |

*With forward flexion

- The distance from the fingers to the ground is measured; the majority of patients can reach the ground within 7cm.
- Other methods are:
 - The examiner first measures the length of the spine from the C7 spinous process to the T12 spinous process with the patient standing.
 - The patient is then asked to bend forward, and the spine is measured again- a 2-7 cm difference in tape measure length is considered normal.

**With side flexion, distance from fingertips to floor is measured and compared with the other side- should be same

Adapted from: Filate W, et al. *The Medical Society, Faculty of Medicine, University of Toronto* 2005, page 140.

- Perform a focused physical examination for common types of leg ulcers.

| Feature | Type of Ulcer | | |
|-----------------|----------------------|--|--------------|
| | Venous | Arterial | Neurotrophic |
| ➤ Onset, trauma | +/- | + | + |
| ➤ Course | Chronic | Progressive | Progressive |
| ➤ Location | Medial aspect of leg | Toe, heel, lateral , posterior aspect of leg, foot | Plantar |



SO YOU WANT TO BE A RHEUMATOLOGIST!

Q1. How is the diagnosis for Marfan's syndrome made?

- A1.
- With family history: features from 2 systems
 - Without a family history
 - Skeletal features (including pectus carinatum or excavatum, reduced lower upper-lower segment ratio, arm-span-to-height ratio > 1.05, scoliosis and reduced elbow extension)
 - Involvement of at least two other systems and one of the major criteria
 - Ectopia lentis
 - Dilation of the aortic root or aortic dissection
 - Lumbosacral dural ectasia by CT or MRI

Q2. The skeletal phenotype of homocystinuria is similar to Marfan's syndrome. How are the two distinguished on physical examination.

- A2.
- In homocystinuria the lens is dislocated downwards (and there is homocystine in the urine).

Source: Baliga RR. *Saunders/Elsevier* 2007, page 581.

Q3. Sclerotic lesions are detected on plain X-ray of the bones. Give 5 causes of an increase in bone density.

- A3.
- Metastatic disease
 - Primary
 - Prostate
 - Breast
 - Reticulosis
 - Site
 - Uretelic
 - Pelvis
 - Rarely effects long bones
 - Myelofibrosis
 - Chronic osteomyelitis
 - Paget disease
 - Localized or wide spread
 - Deformity (unlike metastases, in Paget disease the deformity does not grow also the surface of the bone)
 - Platybasia skull is indented by vertebral column
 - Sclerosis is the usual finding except in the skull where Paget disease shows an area of decreased bone density which is well circumscribed (aka osteoporosis circumscripta)
 - Avascular bone necrosis
 - Osteopetrosis (aka "marble bone disease", or Albers-Schonberg disease")
 - Fluorosis
 - Bone cyst
 - Localized area of translucency surrounded by a rim of sclerosis



SO YOU WANT TO BE RHEUMATOLOGIST!

Q1. Osteoporosis is the less of the protein matrix of the bone, whereas osteomalacia is the loss of mineral from the bone. What are the radiological signs of osteomalacia?

- A1.
- Bending of bones
 - Radiolucency extending from the surface into the bone
 - Aka Milkman fracture, or looser zone
 - Usually seen in upper end of femur and humerus, or lower end of tibia

Q2. What are the radiological signs of osteoporosis?

- A2.
- Cortex
 - Thinning (translucency of bone)
 - Sclerosis
 - Trabeculae
 - Decreased
 - Remaining trabeculae show sclerosis
 - Translucency (thinning) of bone
 - Affects particularly the spinal column

Q3. Chronic renal disease may cause secondary hyperparathyroidism (renal osteodystrophy). What are the radiological changes seen in hyperparathyroidism?

- A3.
- Skull
 - Mottling (aka "pepper- post skull")
 - Jaw
 - Multiple bone cysts (aka von Reckling hausen disease, or osteitis fibrosa cystic)
 - Teeth
 - Loss of lamina dura
 - Fingers/ femoral necks
 - Cortex becomes fragmented from subperiosteal erosions
 - Ectopic calcification
 - Changes of osteomalacia (e.g. Milkman fracture, bending of bones)

Q4. While osteoporosis may affect some bones more than others, those bones which are affected have a generalized translucency of the bone. Give 5 causes of localized translucency of bone.

- A4.
- Close to areas of arthritis
 - Bone cysts
 - Leukemia
 - Secondary bone tumors (metastases)
 - Metastases
 - Myeloma wide spread, well defined
 - Thyroid, lung, breast, kidney, irregular multiple translucent areas
 - Primary bone tumors
 - Histiocytosis X



Chronic Fatigue Syndrome

- Definition: “Chronic fatigue syndrome (CFS), also known as myalgic encephalomyelitis or myalgic encephalopathy (ME), is characterized by persistent and unexplained fatigues in sever impairment in daily function.
 - CFS is defined by “.....symptoms, disability and exclusion of medical and psychiatric conditions that could explain the fatigues”.

(Ken K, et al. Chapter 44. In: Therapeutic Choices. Grey J, Ed. 6th Edition, *Canadian Pharmacists Association: Ottawa 2011, page 995*).

SO YOU WANT TO BE A RHEUMATOLOGIST!

Q1. In the context of the diabetic patient, what is the significance of the prayer sign?

- A1.
- Prayer sign- inability to oppose the flexor surfaces of the PIPs
 - Diabetic stiff hand syndrome
 - Flexion contracture and limited flexion of PIP joints
 - Positive prayer sign
 - Waxy, thick skin over the fingers

Q2. In the context of diffuse swelling of a finger, what are the non-traumatic causes of a sausage-shaped digit.

- A2.
- Psoriatic arthritis
 - Sarcoidosis

Source: Mangione S. *Hanley & Belfus 2000, page 462*

SO YOU WANT TO BE A RHEUMATOLOGIST!

Q1. De Quervain’s disease

- A1.
- Tenosynovitis involving abductor policis longus and extensor pollicis brevis
 - Patient complains of weakness of grip and pain at the base of the thumb which is aggravated by certain movements of the wrist

Q2. Finkelstein test

- A2.
- Ask the patient to flex thumb and close the fingers over it’ then attempt to move the hand into ulnar deviation
 - Excruciating pain with this maneuver occurs in De Quervain’s tenosynovitis

Adapted from: Filate W, et al. *The Medical Society, Faculty of Medicine, University of Toronto 2005 ECE, page 137*.



SO YOU WANT TO BE A RHEUMATOLOGIST!

Q1. What is Behcet syndrome?

A1. Aphthous ulcers in mouth and genitals, associated with arthritis, uveitis and various neurological disorders

Source: Mangione S. *Hanley & Belfus* 2000, page 67.

Q2. When a person fingers are exposed to the cold, they may become pale, then blue from the arterial vasospasm and ischemia, then with redness from reperfusion. This latter phase from a decline in the spasm and therefore ischemia may be associated with pain and paresthesia as well as the redness. In some persons (20%) no cause/ association may be found, and this progression of white-blue-red is called Reynaud disease (i.e., Reynaud phenomenon, with no known underlying disorder. However, the Reynaud phenomenon may proceed a number of conditions.

A2. Perform a focused physical examination for the causes of Raynaud phenomenon.

- MSK
 - Rheumatoid arthritis
 - Scleroderma
 - Systemic lupus erythematosus
 - Mixed connective disease
 - Dermatomyositis
 - Polymyositis
- Hematological disorders
 - Cryoglobulinemia
 - Polycythemia
 - Monoclonal gammopathy
- Arterial
 - Compression
 - Thoracic outlet syndrome
 - Carpal tunnel syndrome
 - Artherosclerosis
 - Vasculitis
 - Prinzmetal angina
- Drugs and toxins
- Endocrine disorders
 - Hypothyroidism
 - Acromegaly
 - Addison disease
- Pulmonary disorders
 - Idiopathic pulmonary hypertension
- Neurological
 - Reflex sympathetic dystrophy
- Life style
 - Occupational use of percussion or vibratory tools (e.g., a jack hammer)



Suggested practice case scenarios for OSCE examinations

| Primary Stem | Secondary Stem | Diagnosis |
|---------------------------|---|--|
| ○ Monoarticular arthritis | ○ Podagra | - Gout, septic arthritis, hemarthrosis, pseudogout |
| | ○ Knee post op | - Pseudogout |
| | ○ With fever | - Septic |
| ○ Leg swelling | ○ Acute onset with pain | - Bakers Cyst |
| | ○ Following travel | - DVT |
| | ○ With fever | - Cellulitis |
| ○ Polyarticular arthritis | ○ Young woman with palmar rash | - Juvenile Rheumatoid arthritis |
| | ○ 40 yr old female, symmetrical small joint | - Rheumatoid arthritis |
| | ○ Knees | - Osteoarthritis |
| | ○ With facial rash & anemia | - SLE |

Source: Kindly provided by Dr. P Hamilton (University of Alberta)

"A pessimist sees the difficulty in every opportunity;
An optimist sees the opportunity in every difficulty."

Sir Winston Churchill



MISCELLANEOUS



Table of Contents

| | Page |
|------------------------------------|-------------|
| Questions in Miscellaneous Chapter | 629 |
| Fever | 630 |
| Viral infections | 639 |
| Sepsis | 642 |
| Sexual transmitted disease | 643 |
| Care of the elderly | 643 |
| Lifestyle issues | 644 |
| Abuse | 646 |



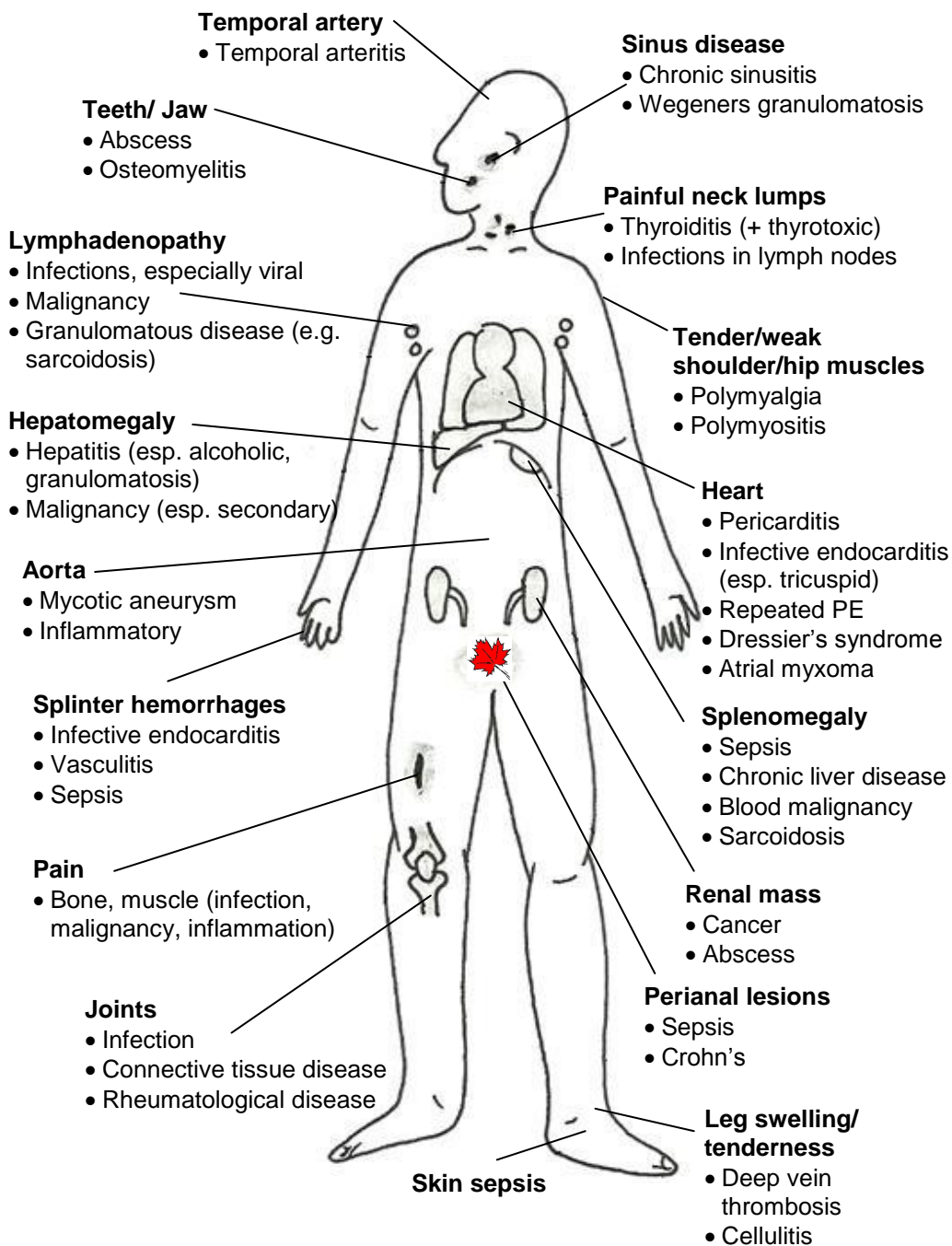
Questions in Miscellaneous Chapter

1. Perform a focused physical examination for fever of unknown origin.
2. Give 5 conditions which in the patient with fever of unknown origin, a bone marrow may be useful to diagnose.
3. Take a directed history and perform a focused physical examination for postoperative (post-op) fever.
4. Perform a directed physical examination for fever and infection in a patient in hospital.
5. Perform a directed physical examination for flushing.
6. Take a directed history for functional assessment in the elderly.
7. Take a directed history of lifestyle issue.
8. Give 4 complications of rapid weight loss.



Fever

- Perform a focused physical examination for fever of unknown origin.



Adapted from: Davey P. *Wiley-Blackwell* 2006, page 70.



Performance Characteristics for Patients with Fever

| Physical examination | PLR | NLR |
|----------------------------------|-----|-----|
| ➤ Indwelling lines and catheters | | |
| ○ Urinary catheter | 2.4 | NS |
| ○ Central venous line | 2.0 | NS |

Abbreviation: NLR, negative likelihood ratio; PLR positive likelihood ratio

Note that numerous findings are not listed here, because their PLR is < 2. These include: Temperature ≥ 38.5 °C, tachycardia, respiratory rate > 20/min, hypotension, acute abdomen and confusion or depressed sensorium.

Adapted from: McGee SR. *Saunders/Elsevier* 2007, Box 16-2, page 180.

Useful background: Common causes of fever of unknown origin

- Infections
 - Abscess
 - Mycobacteria
 - Endocarditis
- Neoplasms
 - Lymphoma
 - Solid tumors (gastrointestinal tract, liver, renal cell, sarcoma)
 - Leukemia, and other hematological tumors
 - Atrial myxoma
 - Inflammatory - IBD, connective-tissue diseases
 - Vascular – pulmonary emboli
 - Iatrogenic – drug-induced (malignant hypertrophy)
 - Congenital – familial Mediterranean fever
- Connective tissue disease
 - Temporal arteritis/polymyalgia rheumatica
 - Polyarteritis nodosa
 - Systemic lupus erythematosus (SLE)
 - Still's disease

Adapted from: Jugovic PJ, et al. *Saunders/ Elsevier* 2004, pages 37 to 39.

- Give 5 conditions which in the patient with fever of unknown origin, a bone marrow may be useful to diagnose.
 - Malignancy
 - Leukemia
 - Lymphoma
 - Bone cancer



- Infection
 - TB
 - Malaria
 - Kala- azar
 - Brucellosis
- Take a directed history and perform a focused physical examination for postoperative (post-op) fever.
 - Wound
 - Inflammation
 - Leakage
 - IV site
 - Cellulitis
 - Limbs
 - Thrombophlebitis
 - Medications / Blood products
 - Medications (previous / new)
 - Blood product reactions
 - Allergies
 - Lung
 - Atelectasis
 - Aspiration
 - Pneumonia
 - Pulmonary embolus
 - GI
 - Ileus
 - Perforation
 - Abscess
 - UTI

Adapted from: Jugovic PJ, et al. *Saunders/ Elsevier* 2004, pages 76 to 78.

Useful background:

- Post-operative risk factors /complications
 - Age > 50 years
 - Pre-existing cognitive dysfunction
 - Depression perioperative derangements
 - > 5 prescribed medications postoperatively
 - Use of anti-cholinergics preoperatively
 - Cardiopulmonary bypass
 - ICU setting

Source: Jugovic PJ, et al. *Saunders/ Elsevier* 2004, page 69.



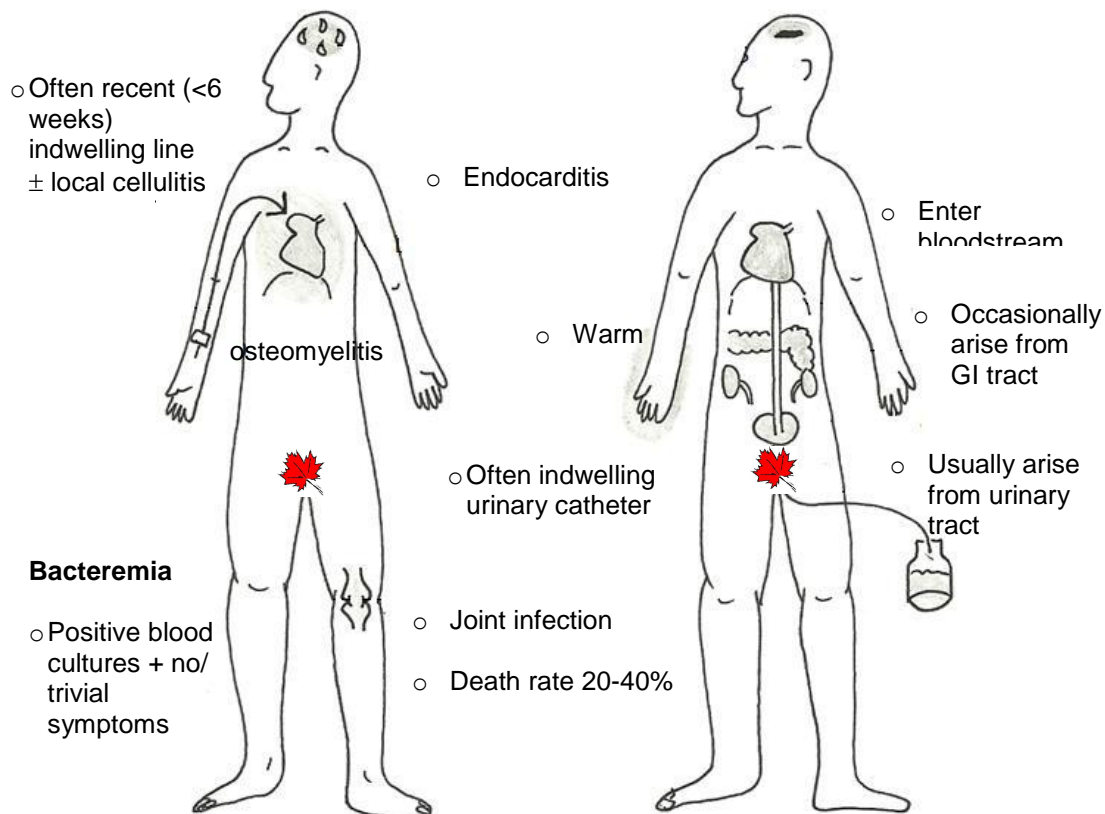
- Perform a directed physical examination for fever and infection in a patient in hospital.

Staphylococcus aureus

- Fever often $>40^{\circ}\text{C}$
- Unwell
- Often no specific symptoms/signs

Gram negative septicemia

- Confusion/ delirium often prominent
- Septic shock in 25-40%
- Fever
- Hypotension
- Tachypnea \rightarrow ARDS



Adapted from: Davey P. *Wiley-Blackwell* 2006, page 68.

“We need to move forward our decisions:
we must operationalize”
Grandad



- Performance characteristics of prognosis of clinical findings in fever > 39°C.

| Finding | PLR | NLR |
|---|------|-----|
| ➤ Temperature > 39 °C | | |
| ○ Predicting hospital mortality in patients with pontine hemorrhage | 23.7 | 0.4 |
| ➤ Hypothermia | | |
| ○ Predicting hospital mortality from pump failure in patients with congestive heart failure | 6.7 | NS |
| ○ Predicting hospital mortality in patients with pneumonia | 3.5 | NS |
| ○ Predicting hospital mortality in patients with bacteremia | 3.3 | NS |

Abbreviation: NLR, negative likelihood ratio; NS, not significant; PLR positive likelihood ratio

Adapted from: McGee SR. *Saunders/Elsevier* 2007, Box 16-3, page 182.

Useful background: The presence of a skin rash in the patient with fever helps to narrow the likely conditions causing a fever. Causes of fever and rash include:

- Specific
 - Vesicobullous
 - Herpes viruses (particularly varicella zoster virus)
 - Coxsackie
 - Enterovirus
 - Mycoplasma
 - Petechia, purpura or skin hemorrhage
 - Meningococcal septicemia
 - Staphylococcus aureus
 - Viral hemorrhagic fevers
 - Typhus
 - Leptospirosis
 - Gram-negative septicemia
 - Nodular rash
 - Erythema nodosum
 - Diffuse generalized erythema
 - Scalded skin syndrome
 - Toxic shock syndrome
 - Usually due to staphylococcal colonization of tampons
 - Symptoms during or shortly after menstruation
 - Fever, hypotension, shock
 - Scarlet skin eruption
 - Desquamation
 - Multi organ failure
 - Maculo-papular rashes



- Non-specific
 - Drug reaction
 - Infection
 - Self-limiting viral infections
 - HIV seroconversion
 - Dengue fever

Adapted from: Davey P. *Wiley-Blackwell* 2006, page 72.

Septic Shock

- CNS
 - Delirium
- Lung
 - ARDS (acute respiratory stress syndrome)
 - Pneumothorax (from mechanical ventilation)
 - Aspiration pneumonitis / pneumonia
 - Pleural effusions
 - Nosocomial pneumonia
 - PE (pulmonary embolism)
- Heart
 - Pericardial effusions
- Kidney
 - Acute renal failure
 - pH, fluid and electrolyte disturbances
- Blood
 - DIC (disseminated intravascular coagulation)
 - Thrombocytopenia
 - DVT (deep vein thrombosis), +/- PE
- GI tract
 - Malnutrition
 - Stress ulceration
 - Gastroparesis
 - Hepatic dysfunction
 - ↑ risk of drug AEs (adverse effects, from ↓ hepatic metabolism of certain drugs)



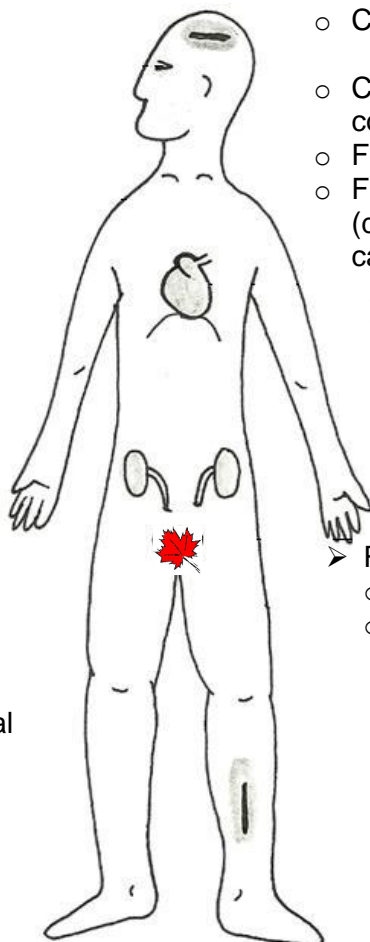
Useful background: The septic patient

➤ Skin

- IV line site infections
- Needle tracks
- Leg ulcers or pressure sores
- Boils or cellulitis
- Petechial rash (meningococcal disease)

➤ Legs

- Poor peripheral perfusion



➤ CNS

- Meningitis
- Cerebral abscess
- Change in level of consciousness
- Focal neurological signs
- Fungal emboli in retina (disseminated candidemia)

➤ Heart

- Hypotension
- Endocarditis
- New murmurs
- Embolic lesions

➤ Rectum

- Abscess
- Enterobacteriaceae

➤ GU

- Toxic shock syndrome

Adapted from: Davey P. *Wiley-Blackwell* 2006, page 296.

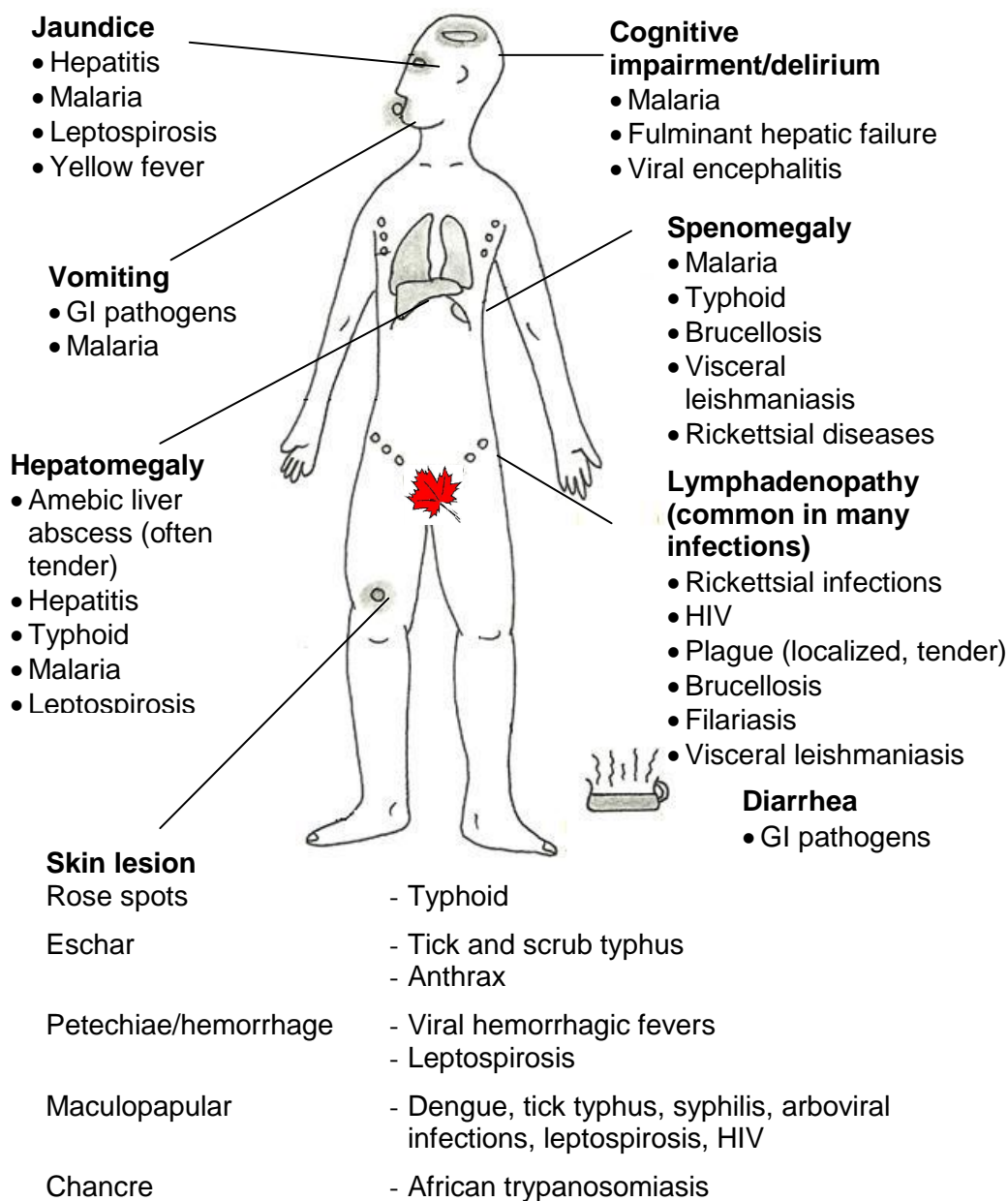
Useful background: Reasons why a senior may have urinary incontinence (“DRIP”)

- Delirium/diabetes mellitus (hyperglycemia)
- Restricted mobility/retention
- Infections (UTI)/Impaction of stool
- Psychological/pills (long acting sedatives, diuretics, anticholinergic agents)

Source: Jugovic PJ, et al. *Saunders/ Elsevier* 2004, page 30.



Useful background: Fever in the returned traveler



Adapted from: Davey P. *Wiley-Blackwell*, 2006 page 76.



- Perform a directed physical examination for flushing.
- Anxiety
- Skin disease
 - Acne
 - Rosacea
 - Photosensitive dermatitis
- Drugs
 - Alcohol
 - Ca²⁺ channel blockers
- Food
 - Scombroid poisoning
- Tumor
 - Carcinoid tumors
 - Medullary thyroid cancer
 - Systemic mastocytosis

Note that skin conditions or self-limiting infections may cause sweating without flushing

Adapted from: Davey P. *Wiley-Blackwell* 2006, page 54.

- Bacteremia in febrile patients

| Risk Factors | PLR | NLR |
|-------------------------------|-----|-----|
| ➤ Renal failure | 4.6 | 0.8 |
| ➤ Hospitalization for trauma | 3.0 | NS |
| ➤ Intravenous drug use | 2.9 | NS |
| ➤ Previous stroke | 2,8 | NS |
| ➤ Poor functional performance | 3.6 | 0.6 |
| ➤ Rapid fatal disease (<1 mo) | 2.7 | NS |

Abbreviation: NLR, negative likelihood ratio; PLR positive likelihood ratio

Note that some clinical features are not included, because their PLR was < 2. These include: age 50 years or more and diabetes mellitus.

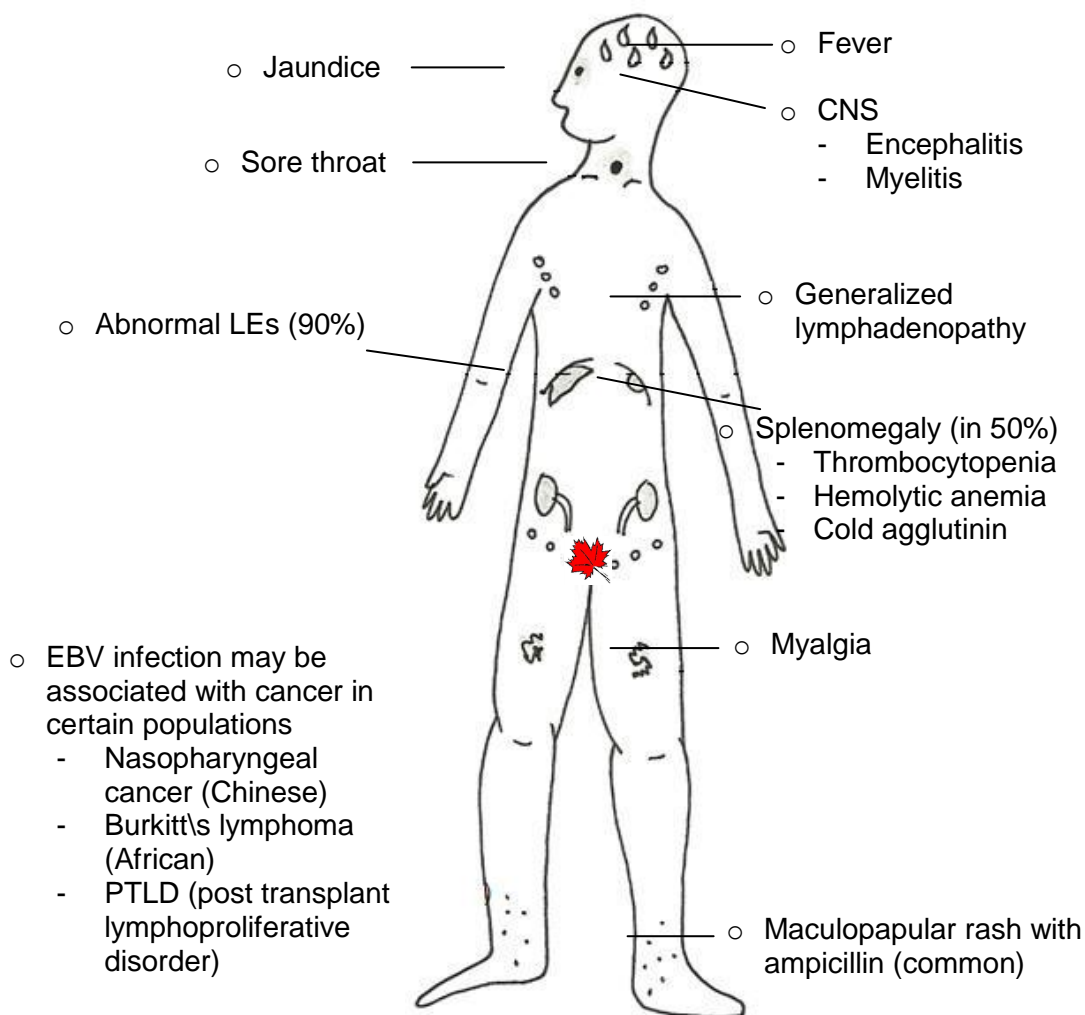
Adapted from: McGee SR. *Saunders/Elsevier* 2007, Box 16-2, page 180.



Viral infections

Useful background: Three viral infections at a glance

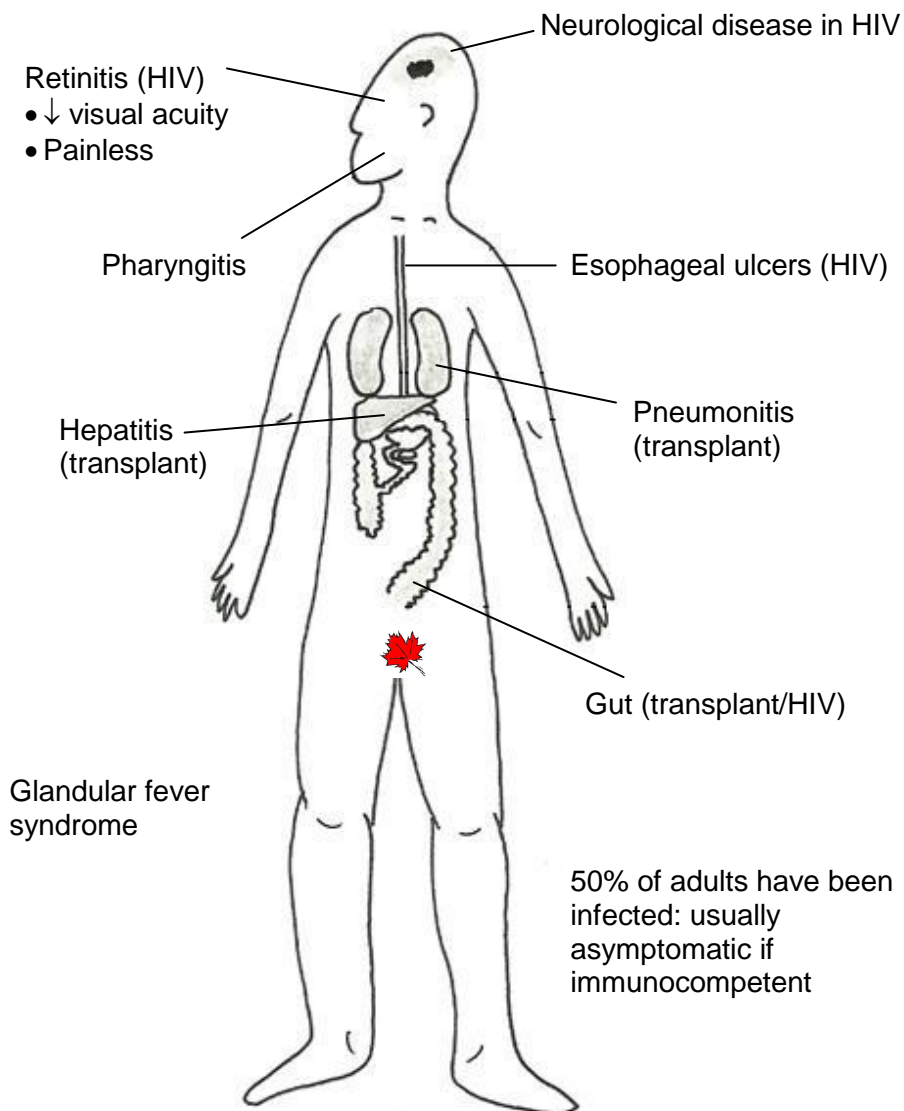
➤ Epstein Barr virus (EBV)



Adapted from: Davey P. *Wiley-Blackwell* 2006, page 298.



➤ Cytomegalovirus (CMV)

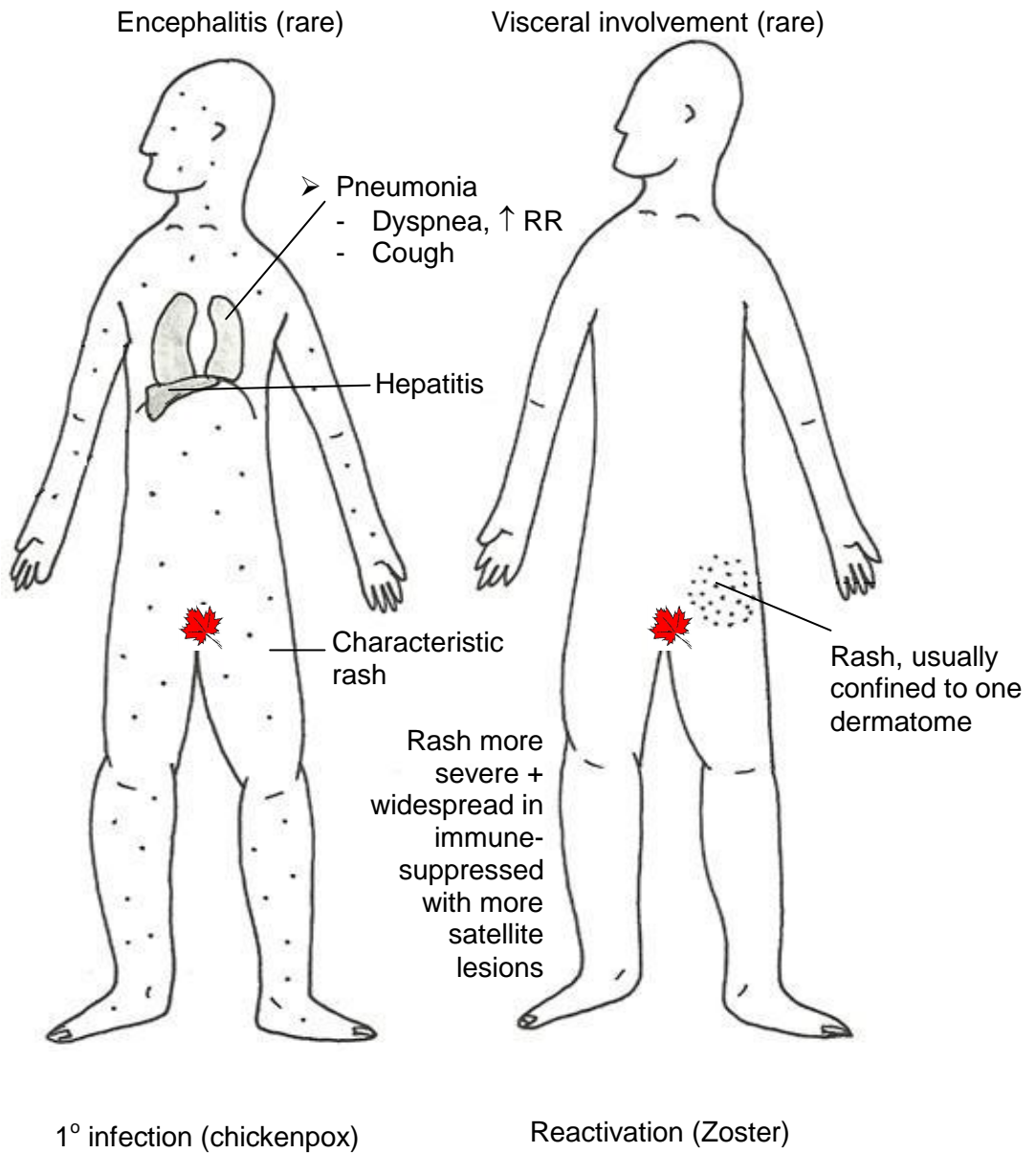


Adapted from: Davey P. *Wiley-Blackwell* 2006, page 298.

“
 In private practice Fee-For-Service, ‘you eat what
 you kill’ ”



➤ Varicella zoster virus (VZV)



Adapted from: Davey P. *Wiley-Blackwell* 2006, page 298.



Sepsis

Useful background: Classification of Sepsis, Severe Sepsis and Septic Shock

| Clinical Staging | Diagnostic Criteria |
|------------------|---|
| ➤ Sepsis | <ul style="list-style-type: none"> ○ Clinical evidence suggestive of infection plus: ○ Signs of a systemic inflammatory response to infection (≥ 2 of the following): ○ Tachypnea (>20 breaths/min or $\text{PaCO}_2 < 32$ mm Hg [< 4.3 kPa]) ○ Tachycardia (>90 beats//min) ○ Hyperthemia ($>38^\circ$ C) ○ WBC $> 12 \times 10^9$ Cells/L, or $< 4 \times 10^9$ Cells/L, or $>10\%$ immature (band) forms |
| ➤ Severe sepsis | <ul style="list-style-type: none"> ○ Sepsis with hypotension (systolic blood pressure <90 mmHg or a 40 mm Hg decrease from baseline in the absence of other causes) ○ Organ dysfunction and perfusion abnormalities such as: <ul style="list-style-type: none"> – Oliguria: <0.5 mL/kg for at least 1 h in patients with urinary catheters – \uparrowPlasma lactate ($>$normal upper limit) – Altered mental status |
| ➤ Septic shock | <ul style="list-style-type: none"> ○ Severe sepsis as defined above, despite adequate fluid resuscitation ○ Note: patients who are on pressor agents may not be hypotensive |

Reproduced with permission: Therapeutics Choices. Sixth Edition. Ottawa, Canada: Canadian Pharmacist Association 2012, Table 1, page 1490.



Sexual transmitted disease

- For an excellent background for how to take a directed history for STD (sexually transmitted disease), see: Jugovic PJ, et al. *Saunders/ Elsevier* 2004, pages 89 and 90.

Useful background: Sexually transmitted pathogens and the disease which each causes.

- Chlamydia trachomatis (chlamydia)
- Neisseria gonorrhoeae (gonorrhoea)
- Herpes simplex virus (HSV; herpes)
- Hepatitis B and C (hepatitis)
- Human Immunodeficiency Virus (HIV/AIDS)
- Treponema pallidum (syphilis)
- Human papilloma virus (genital warts)

Source: Jugovic PJ, et al. *Saunders/ Elsevier* 2004, page 90.

Useful background: Complications of sexually transmitted diseases in females.

- Acute salpingitis
- Pelvic inflammatory disease
- Infertility
- Ectopic pregnancies
- Arthritis
- Conjunctivitis
- Urethritis
- Fitz-Hugh-Curtis syndrome GC/ (chlamydial infection of the liver capsule)

Source: Jugovic PJ, et al. *Saunders/ Elsevier* 2004, pages 90 and 91.

Care of the elderly

- Take a directed history for functional assessment in the elderly.
- Activities of daily living (ADL)
 - Transfers out of bed
 - Going to the toilet
 - Eating
 - Dressing
 - Getting around the home
 - Bathing
 - Food preparation
 - Stairs
 - Walking



Lifestyle issues

- Take a directed history of lifestyle issue.
- **HPI – L DOCC SPARC CIP**
 - **Location**
 - Where is the chief complaint experienced?
 - **Duration**
 - How long does the chief complaint last?
 - **Onset**
 - When did the chief complaint start?
 - **Course**
 - What are the changes in the chief complaint over time?
 - **Character**
 - Describe the quantity and quality of the chief complaint
 - **Severity**
 - Grade the chief complaint on a scale from 0 (no pain) to 10 (worst pain the patient can image) both for its time of onset and the present
 - **Palliating/ provoking**
 - What makes the chief complaint better and worse?
 - **Associated S&S**
 - What are the signs and symptoms presenting as a complex with the chief complaint?
 - **Risk factors**
 - What are the factors known to enhance chances of having the chief complaint?
 - **Constitutional signs**
 - Fever, chills, night sweats, changes in sleep, energy level, weight, and appetite
 - **Causation**
 - What does the patient think the cause is?
 - **Impact on the patient**
 - How has the illness affected the patient?
 - **Patient's action**
 - What has the patient done for the complaint (s)?
- **PMH- SHIAMS**
 - **Surgeries**
 - Type, when, outcome (s)
 - **Hospitalizations**
 - Condition, when hospitalized, outcome (s)
 - **Illnesses**
 - In adults, always ask about HTN, DM, Hx of cancer, as well as duration and treatments



- **Allergies**
 - Drugs, descriptions of reaction (s), MedAlert? EpiPen?
- **Medications**
 - Types and dosing
- **Sins**
 - Smoking/ alcohol/ drug use

➤ Family history

➤ Causes

➤ Complications

Abbreviations: HPI, history of present illness; PMH, past medical history

Source: Jugovic PJ, et al. *Saunders/ Elsevier* 2004, pages 5 to 9.

Useful background: Reasons for falls in seniors.

➤ Physiologic

- ↓ visual acuity
- ↓ night vision
- ↓ sensory awareness, touch
- ↑ body sway, ↓ righting mechanisms

➤ Pathologic

- Cardiac
 - Myocardial infarction
 - Orthostatic hypotension
- Neurological
 - Stroke
 - TIA
 - Dementia
 - Parkinsons disease
- Metabolic
 - Hypoglycemia
 - Anemia
 - Dehydration
- MSK
 - Arthritis
 - Muscle weakness
- Drug induced
 - Diuretics
 - Antihypertensives
 - Sedatives
 - Analgesics

Abbreviations: MSK, musculoskeletal; TIA, transient ischemic attack

Adapted from: Jugovic PJ, et al. *Saunders/ Elsevier* 2004, page 35.



Useful background: People who have suffered sexual abuse as children may experience “sexual abuse accommodation syndrome”.

- Secrecy and silence
- Helplessness and vulnerability
- Entrapment and accommodation
- Delayed, conflicted, and unconvincing disclosure
- Retraction

Source: Jugovic PJ, et al. *Saunders/ Elsevier* 2004, pages 86 to 88.

Useful background: Suggested practice case scenarios for OSCE examinations

| Primary Stem | Secondary Stem | Diagnosis |
|----------------------|--|---|
| ➤ Weight loss | ○ With tremor, tachycardia, heat intolerance | - Thyrotoxicosis |
| ➤ Pregnancy | ○ Hypertension (HTN) | - HTN in pregnancy |
| | ○ Palpations, poor weight gain | - Thyrotoxicosis |
| | ○ Excess weight gain & polyuri | - Diabetes |
| | ○ With dyspnea & a murmur | - Mitral stenosis |
| | ○ Previous abortion & DVT | - Lupus
Anticoagulant |
| | ○ RVQ tenderness, jaundice | - HAV, ABV, HVC, AFLP
- The SPIKES approach to breaking bad news |
| ➤ Perioperative care | ○ Aortic ejection murmur | - Aortic stenosis |
| | ○ Diabetes mellitus | |
| | ○ Steroid dependent | |
| | ○ DVT prophylaxis | |
| | ○ Risk assessment | |

Source: Kindly provided by Dr. P Hamilton; Jugovic PJ, et al. *Saunders/ Elsevier* 2004, page 196.

- For an excellent background of:
 - A directed history for physical abuse, please see: Jugovic P.J., et al. *Saunders/ Elsevier* 2004, pages 73 and 74.



- A directed history for sexual abuse, please see: Jugovic P.J., et al. *Saunders/ Elsevier*, 2004, pages 86 and 87.
 - Reasons why the abused often fail to speak out about their mistreatment and kinds of elder abuse, please see: Jugovic PJ, et al. *Saunders/ Elsevier* 2004, page 209.
- Give 4 complications of rapid weight loss.

Increased risk of

- Infection
- Acidosis
- Electrolyte abnormalities
- Poor wound healing
- Depression of bone marrow

Useful background

- Pulse rate (PR) and fever (PR normally increases 8 bpm for each 1°C increase in body temperature)
 - Lower pulse than expected for temp'
 - Typhoid fever
 - Brucellosis
 - Meningitis
 - Higher pulse than expected for temp'
 - Polyarteritis (in fact, fever may be only slight)
- Fever plus purpura
 - Septicemia
 - Hematological disorder
 - Hemorrhagic exanthemas
 - Remittent
 - Temperature raised throughout the day
 - Difference between maximum and minimum temp' is >2°F
 - Intermittent
 - High peaks with return to normal at some point each day
 - Suggests abscess, septicemia, malaria
 - Continuous
 - Temperature raised throughout the day
 - Difference between maximum and minimum temp' is < 2°F
 - Suggests
 - SBE
 - Viral pneumonia
 - Military TB
 - Typhoid fever



Drug to Avoid in Pregnancy-Teratogenic

- Certain
 - Coumadin
 - Methotrexate
 - Misoprostol
 - Thalidomide

- Possible
 - Diazepam
 - Fluconazole
 - Statins

Diav-Citrin O and Koren G. Appendix II. In: Therapeutic Choices. Grey J, Ed. 6th Edition, *Canadian Pharmacists Association: Ottawa*, 2011, page 1722 to 1724.

Warning

Use of alcohol in any amounts is not compatible with pregnancy or breastfeeding.



INDEX

Note: Page references to Parts One and Two of the text are preceded by I: and II: respectively.

A

A wave, **I:38**

abnormalities, **I:40**

Abadie's sign, **II:361**

Abdomen

pain in, **I:421–422**

in patient inspection for cardiac disease, **I:14**

tumours and polyps, **I:436–442**

Abdominal aorta, **I:433–434**

Abdominal aortic aneurysm (AAA), **I:226**

performance characteristics of auscultation and palpation for, **I:433**

triad for ruptures, **I:434**

Abdominal masses

anterior wall, **I:428**

focused physical examination to determine causes, **I:426–427**

Abdominal X-ray, **I:551–553**

causes of calcification, **I:552**

directed examination, **I:551–552**

Abdominojugular reflux abnormalities, **I:36**

Abducens nerve (CN VI), **II:33**

eye movements and, **II:74–96**

gaze defects, **II:81**

lesion of, physical examination for, **II:85**

palsy/paralysis, **II:86**

conditions causing, **II:88**

structures in proximity to, **II:90**

syndromes associated with, **II:89**

Abduction of thumb, testing for, **II:224**

Aberrant regeneration of CN III (AR III), **II:89**

and Argyll Robertson pupils distinguished, **II:61**

Abetalipoproteinemia, **I:465**

Abnormal sensation, lesions causing, **II:241–242**

Abrasion, corneal, **II:83**

Abscess, of lung, focused history for, **II:463**

Absence seizures, **II:29, 301**

Absent light reflex, in coma patients, **II:57**

Abuse

DSM approach to, **II:646**



- sexual, **II:647**
- substance. See Substance abuse
- Acanthosis, glycogenic, vs. candidiasis, **I:390**
- Acanthosis nigricans, **I:571**
- Accessory muscles, of respiration, **II:387**
 - examining, **II:371**
- Accessory nerve (CN XI), **II:33, 119**
- Accommodation, **II:93**
 - abnormal pupil reaction to, **II:61**
 - convergence reflex, **II:75**
- Acetaminophen, interactions with warfarin, **I:603**
- Achalasia, **I:369–370**
 - associated with Chagas disease, **I:370–373**
 - associated with degenerative neurological disorders, **I:372**
 - distinguishing between subtypes, **I:371**
 - in loss of inhibitory ganglion nerve, **I:372**
- Acid pocket, in GERD, **I:382**
- Acid-base balance, disorders, **I:673**
- Acidosis
 - lactic, **I:573**
 - directed history for causes, **I:670–671**
 - metabolic, **I:674–675, 676**
 - respiratory, **I:673, 676, 678–679**
- Acquired myopathy, **II:262**
- Acromegaly, **I:19, 341**
 - increased risk of colorectal cancer, **I:496**
 - physical examination for, **II:529**
 - X-ray changes, **I:342**
- Acromioclavicular joint, **II:533**
 - pain in, **II:543**
- Action tremor, **II:269, 294, 296–297**
- Activities of daily living (ADL), **II:305, 510, 643**
- Acute abdomen
 - analgesia for, **I:429**
 - in leukemia patient, **I:561**
- Acute cholecystitis, **I:545–546**
- Acute coronary syndromes (ACS), **I:44–54**
 - history of clinical features, **I:48**
 - quality measures, **I:269**
- Acute deep vein thrombosis, **I:62**
- Acute diverticulitis, **I:493**
- Acute fatty liver of pregnancy (AFLP), **I:542**
- Acute interstitial nephritis, **I:651–653**
- Acute respiratory distress syndrome (ARDS), physical examination for, **II:453–454**



- Acyanotic congenital heart disease, **I:250**
- Acyanotic cyanose tardive, focused physical examination for, **I:253–255**
- Addison's disease
 - directed history for causes, **I:315**
 - focused physical examination for, **I:315–316, 317**
 - systematic approach to causes, **I:316**
- Adenocarcinoma, **I:368**
- Adenoma, **I:536**
- Adie's pupil, **II:61, 62, 63, 93**
- Adipose tissue, distribution in Cushing's syndrome, **I:322**
- Adrenal disease, **I:315–322**
- Aerchicerebellum, in ataxia, **II:169**
- Age, conditions affecting visual appearance of, **II:649**
- Agnosia, **II:14**
- Agranulocytosis, **I:624**
- "Ahh," in visual inspection of oral cavity, **II:364**
- Air trapping, **II:373**
- Airflow obstruction, **II:425–442**. *See also* Asthma
 - breath sounds in, disease differentiation, **II:431**
- Airways, narrowing of, wheezing and, **II:430**
- Alcohol
 - abuse, **I:498–501**
 - dependency, **I:498**
 - and esophageal cancer, **I:394**
 - withdrawal, physical examination for, **I:500**
- Alcoholic binge, **I:82**
- Alcoholic cerebellar degeneration, **II:164**
- Aldosterone, effects of salt intake on, **I:647**
- Aldrich lines, **I:529**
- Alkalosis
 - metabolic, **I:676, 680**
 - respiratory, **I:673–674, 676**
- ALL AGES mnemonic, **I:611–612**
- Allen test, **II:604**
- Allergic bronchopulmonary aspergillosis (ABPA), bronchiectasis in, **II:464**
- Allergic gastroenteropathy, laboratory features, **I:376**
- Allergic granulomatous angitis, **I:580**
- Allgrove syndrome, **I:317**
- Allodynia, **I:422**
- Alpha-1 antitrypsin deficiency, bronchiectasis in, **II:464**
- Alternative remedies, interactions with warfarin, **I:603**
- Altitudinal central field defect, **II:40**
- Alvarado clinical decision rule, **I:424, 425**
- Alveolitis
 - extrinsic allergic. *See* Extrinsic allergic alveolitis



- fibrosing. See Fibrosing alveolitis
- Amaurosis fugax, **II**:42, 43, 321
 - upper limbs tests in, **II**:322
- Amebiasis, **I**:489
- Amenorrhea, **I**:338–339
- American Rheumatism Association (ARA) criteria, for rheumatoid arthritis, **II**:570
- American Society of Anesthesiologist Classification of Anesthetic Mortality, **I**:266–269
- Amiodarone, interactions with warfarin, **I**:603
- Amylase, high concentration, **I**:557
- Amyloid of GI tract and heart, **I**:470
- Amyloidosis, **I**:589
- Amyotrophic lateral sclerosis (ALS), **II**:179
 - motility disorders, **I**:587
 - oropharyngeal dysphagia in, **I**:364
- Analgesia, for acute abdomen, **I**:429
- Anasarca, **I**:664
- Anemia
 - "best" test for, **I**:613
 - comparisons of hypochromic microcytic, **I**:621
 - directed history of, **I**:613–614
 - focused physical examination for, **I**:613–614, 620
 - megaloblastic, **I**:471
 - performance characteristics, **I**:621
 - pernicious, **I**:614
 - sideroblastic, **I**:617
- Anesthesia
 - dissociated. See Dissociated anesthesia, spinal cord
 - hysterical, physical examination for, **II**:237
- Angiectasia (AE)
 - angiographic signs of, **I**:477
 - vs. hereditary hemorrhagic telangiectasia, **I**:415
- Angina, functional classification, **I**:48
- Angioedema, hereditary, **I**:451
- Angiography, **I**:446
- Angiorectasias lesion, **I**:474
- Anion-gap metabolic acidosis, **II**:374
- Anisocoria
 - cause of, physical examination for, **II**:41, 56, 93–94
 - in coma patients, **II**:57
 - definition, **II**:56
 - in iritis, **II**:88
 - physical examination for cause, **II**:41
- Ankle, **II**:561–562



- abnormal articular findings in, **II:513**
- fracture
 - "best" clinical test for, **II:568**
 - performance characteristics, **II:562**
 - normal range of motion in, **II:515, 561**
 - physical examination for, **II:508, 561**
- Ankle jerks, absent, **II:363**
- Ankylosing spondylitis (AS), **I:19, II:585, 589–595**
 - advanced, postural change in, **II:590–591**
 - arthropathy patterns in, **II:615**
 - conditions associated with, **II:592**
 - directed history for, **II:591–592**
 - four "A's," **II:589**
 - performance characteristics, **II:592**
 - physical examination for, **II:589–590**
 - and psoriatic arthritis differentiated, **II:584**
 - radiological features, **II:594**
- Annular pancreas, vs. pancreas divisum, **I:547**
- Annular rash, **II:553**
- Anorexia, early causes in HCT, **I:593**
- Anorexia nervosa, **I:567**
- Anserine gait, **II:272**
- Anterior cell syndrome, spinal cord, **II:179**
- Anterior cerebral artery (ACA), **II:30**
 - cerebral occlusion location, neurological examination for, **II:323**
 - in common stroke syndromes, **II:319**
 - occlusion, **II:30, 335**
- Anterior cord syndrome, **II:173**
 - physical examination for, **II:180**
- Anterior cruciate ligament (ACL) rupture/tear
 - "best" clinical tests for, **II:559**
 - performance characteristics for, **II:558**
- Anterior ischemic optic neuropathy (AION)
 - directed history for, **II:54**
 - focused physical examination for, **II:54**
- Anterior release test, for shoulder instability, **II:541**
- Anterior spinal artery, obstructed base of, **II:317–318**
- Antibiotics
 - for endocarditis prophylaxis in dental procedures, **I:242**
 - interactions with warfarin, **I:603**
- Antidepressants, interactions with warfarin, **I:603**
- Antiepilepsy drugs (AEDs), contraception method in female and, **II:304**
- Antifungals, interactions with warfarin, **I:603**
- Anti-inflammatory agents, interactions with warfarin, **I:603**
- Antineutrophil cytoplasmic autoantibody (ANCA), **II:608**



- Anti-pituitary antibodies (APA), **I:484**
- Antiplatelet agents, interactions with warfarin, **I:603**
- Antral gastritis, **I:442**
- Aorta
 - abdominal, **I:433–434**
 - diseases, **I:224–231**. *See also* Coarctation of aorta
 - combined with mitral valve disease, **I:157**
 - in fever of unknown origin, **II:630**
 - thoracic dissection, performance characteristics of clinical findings for, **I:227**
- Aortic aneurysm
 - abdominal, **I:226**
 - murmurs from, vs. aortic stenosis murmur, **I:226**
 - saccular, focused physical examination for, **I:225–226**
- Aortic dissection
 - focused physical examination to distinguish valvular aortic regurgitation from, **I:228**
 - performance characteristics, **I:230**
- Aortic regurgitation (AR), **I:85, 135, 196–209**
 - cardiac phases for diagnosis and severity, **I:202**
 - causes, **I:197–198**
 - Duroziez's maneuver sensitivity for, **I:207**
 - early diastolic murmur, **I:206**
 - focused physical examination for, **I:199–200**
 - likelihood ratios of physical examination for detecting, **I:204–205**
 - murmurs, **I:133**
 - performance characteristics, **I:203–204**
 - physical examination for, **I:196–197**
 - physical examination to assess severity, **I:199, 203**
 - signs, **I:208**
 - symptoms and finding on exam, **I:198**
 - systolic murmur with diastolic murmur in, **I:206**
- Aortic sclerosis, vs. aortic stenosis, **I:161**
 - physical examination to distinguish murmur, **I:161**
- Aortic stenosis, **I:79, 128, 149, 152–158, 163**
 - vs. aortic sclerosis, **I:161**
 - complications, **I:165**
 - focused physical examination for, **I:152–153**
 - murmurs, **I:133, 134**
 - vs. murmur of mitral regurgitation, **I:180**
 - systolic, **I:154**
 - physical examination
 - to assess severity, **I:153**
 - detection accuracy, **I:157**
 - to distinguish between systolic murmur of pulmonary stenosis and, **I:159–160**



- to distinguish from HOCM, **I:164**
- to distinguish murmur from hypertrophic cardiomyopathy, **I:162**
- distinguishing murmur in aortic stenosis/sclerosis, **I:161**
- S₂ information on, **I:113**
- supraventricular vs. ventricular, bronchial pulse in, **I:161**
- syncope in, **I:158**
- Aortic valve disease, causes of mitral valve disease combined with, **I:160**
- Aortic valve prosthetic, **I:165**
- Aortitis, syphilitic, focused physical examination for, **I:225–226**
- Aphasia, receptive vs. expressive, **II:362**
- Apical beat, **I:43–44, 101**
- Aplasia anemia, **I:618**
- Apley test, **II:555**
- Apolipoprotein B, **I:465**
- Apoptosis, **I:397**
- Appendicitis, **I:423–430**
 - "best" clinical tests for, **I:425**
- Apprehension test, **II:535, 538, 541**
- Apraxia, **II:14**
- Apraxic "magnetic" gait, **II:273**
- Arcus senilis (AS), **I:53**
- Argon plasma coagulation, **I:408**
- Argyll Robertson pupil (ARP), **II:50, 93, 94**
 - and aberrant regeneration of CN III distinguished, **II:61**
 - abnormal reaction to light, **II:61**
 - causes, **II:62**
 - physical examination for, **II:50–51**
 - clinical features, **II:50**
 - neuroanatomy, **II:50**
 - "reversed," **II:41**
- Arm
 - peripheral nerves of, sensory branches, **II:230**
 - segmental innervation of muscles, **II:218, 222**
- Arrhythmia, **I:88–97**
 - transient supraventricular, **I:82**
- Arterial insufficiency, **I:62**
 - physical examination to distinguish between venous and, **I:69**
 - vs. venous, **I:61**
- Arterial occlusive disease (AOD)
 - in extremities, grading system, **I:71**
 - grading system for lower extremity, **I:59**
- Arterial pulse, **I:72**
 - abnormal patterns, **I:76**
- Arterial ulcers, **I:56**
- Arteries



- left anterior descending vs. right coronary disease, **I:50**
- main diseases affecting, **I:83**
- Arteriolar ulcers, **I:56**
- Arteriovenous (AV) lesion, **I:474–475**
- Arteritis. *See also* Vasculitis
 - causes, **II:605–606**
 - giant-cell, **II:609**
 - temporal, **II:354–357**
 - headache/facial pain in, **II:133, 137**
- Arthralgia, migratory, causes of, **II:565**
- Arthritis. *See also* Osteoarthritis
 - distribution in hand and wrist, **II:524**
 - juvenile chronic, **II:587**
 - preipheral, sacroilitis vs., **II:593**
 - psoriatic. *See* Psoriatic arthritis
 - rheumatoid. *See* Rheumatoid arthritis (RA)
- Arthropathy, **II:613–617**
 - patterns of, physical examination for, **II:615**
- Arthropathy plus nodules, causes of, **II:571, 583**
- Articulation
 - abnormal findings
 - in ankle and foot, **II:513**
 - in elbow, **II:512**
 - in elbows, **II:512**
 - in fingers, **II:510–511**
 - in hip, **II:512–513**
 - in knee, **II:513**
 - in shoulder, **II:512**
 - in wrists, **II:511**
 - cranial nerve involvement in, **II:116**
 - disorders of, causes, **II:118**
- Asbestosis, radiographic findings in, **II:473**
- Ascites, **I:520–523**
- ASEPTIC mnemonic, **II:611**
- Aseptic necrosis of bone, **II:611**
- Aspiration, after stroke, performance characteristics for, **II:324**
- Astasia abasia, **II:291**
- Astereogenesis, **II:194, 266**
- Asterix, **II:298**
- Asthma, **II:425–426**
 - bronchial, in respiratory disease differentiation, **II:434**
 - chest examination techniques in, **II:383**
 - directed history for, **II:427–428, 429**
 - in emergency department patients, operational characteristics, **II:435**
 - Loeffler's syndrome, **II:431**



- physical examination for, **II**:428–430
- Asymptomatic hypertension, **I**:643
- Ataxia, **II**:270
 - causes, **II**:163
 - cerebellar and sensory ataxia distinguished, **II**:165, 292
 - Friedreich's, **II**:292
 - limb, **II**:164, 170
 - sensory and cerebellar ataxia distinguished, **II**:165
 - truncal, **II**:164
- Ataxic gait, **II**:164, 270–271
- Ataxic paraparesis, causes, **II**:167
- Ataxic respiration, **II**:373
- Atelectasis, chest examination techniques in, **II**:382
- Atherosclerotic disease, chronic renal failure and, **I**:42
- Athetoid movements, **II**:266, 293
 - physical examination for cause, **II**:296
- Atonic seizures, **II**:29, 301
- Atrial fibrillation (AF), **I**:89
 - congenital disorders with, **I**:261
 - focused physical examination for, **I**:89–90
 - and MS murmur, **I**:148
- Atrial septal defect (ASD), **I**:152, 254
 - focused physical examination to distinguish secundum and primum, **I**:246–247
- Atrial-esophageal fistula, **I**:400
- Atrioventricular dissociation, performance characteristics, **I**:83
- At-risk drinking, **I**:498
- Atrophic glossitis, **I**:358
- Atrophy, **II**:250
 - dentatorubral pallidoluysian, **II**:292
 - multiple system, **II**:289
 - optic, causes, **II**:71
 - peroneal muscular, **II**:220
- Aura
 - in epileptic seizure, **II**:299
 - migraine with and without, **II**:135–136
- Austin Flint murmur, **I**:135, 173, 191, 208
- Autoimmune hypopituitarism, **I**:484
- Automimmune hepatitis (AIH), **I**:541
- Automimmune pancreatitis, **I**:562
- Autonomic neuropathy, **II**:234, 237
- Autosomal dominant polycystic kidney disease (ADPKD), **I**:677
- Axilla, directed history and focused physical examination of lymph nodes, **I**:612
- Axillary lymphadenopathy, **I**:607



- Axonotmesis, **II**:232
- Azathioprine (AZA)
 dosing and metabolism, **I**:451
 prediction of toxicity, **I**:487
- Azure half-moons in nail beds, **I**:528
- B**
- B cell small intestinal lymphoma, **I**:454
- Babinski sign, **II**:147
- Bacillary peliosis hepatitis, **I**:573
- Back movement, special tests of, **II**:548–549
- Back pain
 causes, **II**:543
 clinical examination for herniated disk or cancer in, **II**:593
 directed history for, **II**:543
 in low back
 red flags for, **II**:544
 symptoms of, causes, **II**:544–545, 549–550
 physical examination for, **II**:545
 in sacroiliitis, **II**:592
- Bacteremia
 in febrile patient, **II**:638
 in hospitalized patient, **II**:633
- Bacterial conjunctivitis, **II**:83
- Bacterial contamination, transition to infection, **I**:431
- Bacterial endocarditis, **I**:231–243
 focused physical examination for, **I**:237–238
 embolization, **I**:232–234
 Modified Duke Criteria for, **I**:235–237, 243
 risk stratification, **I**:238–239
 subacute
 focused physical examination for, **I**:241
 Roth spots vs. other retinal lesions, **I**:240
- Bacteriocins, **I**:489
- Balance, assessment in cerebellar disorders, **II**:170
- Ballet's sign, **I**:291, 314
- Balloon tamponade, **I**:413
 tube types for bleeding esophageal varices, **I**:414
- Bariatric surgery, **I**:417–420, 509
 approximate rates of improvement, **I**:420
 EGD recommendation prior to, **I**:419
 mechanisms of benefit, **I**:417
 NIH consensus criteria for qualifying, **I**:418
 surgical complications, **I**:417
- Barium enema examination, of rectum, **I**:480



- Barium esophagogram, narrowing of esophagus cause, **I:384**
- Barrett epithelium (BE), **I:366**
 molecular biology in progression of esophageal mucosa to, **I:365**
 peptides link to, **I:385**
 risk of progression, **I:367**
- Basal acid output (BAO), sensitivity of measurement in ZES diagnosis, **I:407**
- Basilar artery
 cerebral occlusion location, neurological examination for, **II:323**
 in common stroke syndromes, **II:319**
 ischemia of, physical examination for, **II:320**
- Beau's lines, **I:528**
- Becker muscular dystrophy, **II:249, 262**
 physical examination for, **II:254**
- Beck's triad, **I:221**
- Behçet's syndrome, **I:471, 583–584, II:374**
 clinical features, **II:567**
 definition, **II:624**
 and Stevens-Johnson syndrome distinguished, **II:567**
- Bell's palsy, **II:106**
 causes, **II:109**
 unilateral, differential diagnosis, **II:107**
- Bell's phenomenon, **II:106, 109**
- Belly button, examining, **I:513**
- Benedikt's syndrome, **II:111, 169**
- Benign recurrent cholestasis (BRC), molecular defects causing, **I:532**
- Benzodiazepines
 avoiding in FAP/IBS, **I:430**
 withdrawal, **I:501**
- Bereavement, tasks of, **II:646**
- Bernstein test, performance characteristics, **I:363**
- Berry's sign, **I:292**
- β -blockers, vs. EVBL, for esophageal variceal bleeding prophylaxis, **I:391–392**
- Bicipital tendinitis, of shoulder, **II:538**
- Biernacki's sign, **II:361**
- Bifid pulse, **I:72**
- Bigeminal pulse, **I:21**
- Biliary cirrhosis, **I:546**
- Biliary tree, **I:563–564**
- Billewicz diagnostic index, for hypothyroidism, **I:305**
- Billroth II surgery, **I:443**
- Biot's breathing, **II:372, 373, 386**
- Black esophagus, in immune-suppressed patient, **I:389**
- Bladder disturbances, **II:361**
- Bleeding



- disorders, **I:600–603**
- lower GI, **I:473–477**
- Blindness
 - cortical, determination, **II:43**
 - gradual, causes, **II:42**
 - monocular, **II:319, 321, 323**
 - sudden, causes, **II:37**
 - physical examination for, **II:38**
- Blood cultures, pulmonary stenosis and, **I:158**
- Blood loss
 - likelihood of hypovolemia caused by, **I:668**
 - predicting severity causing hypovolemia, **I:63**
 - vital signs and acute, **I:416**
- Blood pressure
 - in arms
 - legs vs., **I:87, 177, 209**
 - right vs. left, **I:227**
 - non-pharmacologic therapies to reduce, **I:647**
 - peripheral pulse and, **I:84**
- Blood vessels, effects of diabetes on, **I:86**
- "Blue bloater." See Chronic bronchitis
- Blue rubber blue nevus (BRBN) syndrome, **I:443**
- Blue sclera, **II:49, 67**
- Body appearance, in patient inspection for cardiac disease, **I:10**
- Body mass index, **I:283–284**
 - denial of increased, **I:321**
 - and obesity, **I:568**
- Boerhaave syndrome, vs. Mallory-Weiss syndrome, **I:410**
- Bone
 - aseptic necrosis, **II:611**
 - calcified, systematic approach to, **II:528**
 - density, causes of increase in, **II:621**
 - malignant tumour metastasis to, **II:447**
 - translucent
 - causes, **II:622**
 - systematic approach to, **II:528**
- Bone marrow biopsy, in fever in of unknown origin, **II:631–632**
- Bone marrow transplant (BMT), **I:532**
- Bone X-ray, sclerotic lesions on, **II:621**
- Bonnevie-Ullrich syndrome, **I:261**
- Borders, on chest X-ray
 - collapsed segment vs. heart on, **II:475**
 - homogenous opacity, **II:477**
- Borrelia burgdorferi*, **II:553, 554**
- Boston sign, **I:313**



- Bouchard's nodes, **II**:516, 518, 586
- Boutonniere deformity, **II**:516, 518, 519
- Brachial plexus
 lesions
 vs. nerve root compression, history and physical examination for, **II**:228
 neurological cause, physical examination for, **II**:212
 trunk damage, physical examination for, **II**:212
- Brachial pulse, cause of unequal, **I**:84
- Bradyarrhythmias, **I**:88
- Bradycardia, physical examination for causes, **I**:95–96
- Bradykinesia, tests for, **II**:286
- Bradypnea, **II**:373
- Brain, base of, arteries of, **II**:313
- Brain tumour, headache/facial pain associated with, **II**:136
- Brainstem. *See also* Medulla; Midbrain; Pons; Thalamus
 anatomy, **II**:138–140, 146
 aterial occlusion in, **II**:161
 compression, **II**:160
 disease of, physical examination for, **II**:146–147
 findings in UMN weakness, **II**:20
 involvement in multiple sclerosis, **II**:352
 lesion, physical examination for, **II**:147, 157
 locked-in state, physical examination for, **II**:148
 sensory syndrome involving injury to, **II**:180
 structures (clinically important), **II**:149
 tracts in, **II**:150
- Branham sign, **I**:77
- Breast-feeding, by women with IBD, **I**:488
- Breath sounds, **II**:375–376
 abnormal (adventitious), **II**:370, 378, 380–381
 in airflow obstruction, disease differentiation, **II**:431
 auscultation for, **II**:371–372
 bronchial, **II**:370, 384
 in disease processes, **II**:382–383
 effect of pulmonary disease on, **II**:377
 pleural rub distinguished from other, **II**:385
 vesicular, auscultation, **II**:433
- Breathing. *See also* Respiration
 bronchial, **II**:387
 Kussmaul, **I**:22, **II**:371, 373
 patterns, **II**:372, 379
 pursed-lip, **II**:371
- British Thoracic Society severity score criteria, for pneumonia, **II**:417
- Brittle nails, **I**:529
- Broadbent's sign, **I**:222, **II**:370



- Brockenbrough-Braunwalk-Morrow (B-B-M) sign, **I**:160
- Brock's syndrome, **II**:423, 477
- Bronchial cancer
 chest pain in, causes, **II**:448
 complications of, non-metastatic
 extra-pulmonary, **II**:449–450
 non-pulmonary, **II**:448–449
- Bronchiectasis, **II**:401, 436
 chest examination techniques in, **II**:382
 diseases associated with, **II**:464
 "dry," **II**:441
 focused history for, **II**:440
 physical examination for, **II**:440–441
 tuberculosis and, **II**:465
 X-ray findings in, **II**:402
- Bronchiectasis sicca, **II**:441
- Bronchitis
 chest examination techniques in, **II**:382
 chronic. See Chronic bronchitis
 conditions associated with, **II**:465
- Bronchopneumonia, **II**:387
- Brown-Sequard syndrome, **II**:179, 185
 physical examination for, **II**:180, 209–210
- Brudzinski's sign, **II**:345
- Bruit in neck, causes, **I**:295
- Buerger's test for PVD, **I**:21, 60
- Bulbar palsy, and pseudobulbar palsy distinguished
 directed history for, **II**:154, 160
 physical examination for, **II**:106, 118, 120, 154, 160
- Bulimia, examination of digits for, **II**:410
- Bulimia nervosa, **I**:567
- Bursitis
 acute, **II**:543
 pain in, **II**:618
- C**
- C wave, **I**:38
- CAGE questionnaire on drinking behavior, **I**:498
- Caged ball valves, **I**:122
- Calcification, on abdominal X-ray, causes, **I**:552
- Calcium
 disorders, **I**:326–335
 serum concentrations and hypoparathyroidism, **I**:334
- Campbell's sign, **I**:21, 293, **II**:433
- Campylobacter, infection in HIV-AIDS, **I**:572



- Cancer. *See* Carcinoma; *specific cancers*
- Candidiasis
 esophageal, conditions predisposing to development, **I:389**
 vs. glycogenic acanthosis, **I:390**
- Capillary refill time, and hypovolemia, **I:65**
- Capsular syndrome, **II:543**
- Carcinoid crisis, **I:463–464**
- Carcinoid syndrome, **I:468, 470, 472**
 focused physical examination for, **I:461**
- Carcinoid tumours
 diagnosis, **I:459**
 gastrointestinal, **I:460–461**
 treatment, **I:464**
- Carcinoma. *See also specific cancers*
 after intestinal transplantation, **I:465**
 of lung, **II:442–450**. *See also* Mediastinal compression
 causes, **II:442–443**
 physical examination for, **II:446–447**
 of thyroid, **I:292**
- Cardarelli's sign, **I:293**
- Cardiac disease
 clinical circumstances as congenital, **I:262**
 focused patient inspection for, **I:10**
- Cardiac murmurs. *See* Heart murmurs
- Cardiac risk stratification, **I:266–269**
 focused history to determine, **I:266**
- Cardiac tamponade
 acute, physical examination for, **I:217–218**
 focused physical examination for, **I:144, 221, 223**
 to distinguish between pericarditis and, **I:219–220**
 pulsus paradoxus and, **I:81**
- Cardiology, exam questions, **I:xvii–xxiii, 3–9**
- Cardiomegaly, pulmonary edema and, **I:35**
- Cardiomyopathy, **I:209–213**
 causes, **I:210–211**
 classification, **I:212**
 hypertrophic, physical examination for, **I:209–210**
- Cardiotoxic drugs, **I:26**
- Cardiovascular accident (CVA), GI complications in, **I:588**
- Cardiovascular risk, increased, **I:325–326**
- Cardiovascular system, patient history for disease of, **I:14–15**
- Carditis, as criteria for rheumatic fever diagnosis, **I:147**
- Carnet sign, **I:425**
- Carotid artery
 internal. *See* Internal carotid artery (ICA)



- ischemia of, physical examination for, **II**:319–320
- stenosis, **II**:322–323
 - diagnostic imaging in, **II**:461
- Carotid artery pulse, physical examination to distinguish between jugular venous pulse and, **I**:218
- Carotid bruit, **I**:42, 83, 141, **II**:322–323, 461
 - causes, **I**:35
- Carotid shudder, **I**:41
- Carotid waveforms, physical examination to distinguish between JVP and, **I**:43
- Carpal joints
 - deformities, **II**:519–520
 - normal range of motion, **II**:514, 525
 - physical examination for, **II**:505–506
- Carpal tunnel syndrome, **II**:234, 527–528
 - causes, **II**:226
 - physical examination for, **II**:227
 - testing in, **II**:527
- Carvalho's sign, **I**:178
- Castell spot, **I**:627
- Castell's sign, **I**:627, 629
- Cataplexy, and coma distinguished, **II**:336
- Cataract, **II**:69–70
 - causes, **II**:66
- Catecholamine-secreting tumour, focused physical examination for, **I**:318
- Cauda equina claudication syndrome, **II**:185–186
- Cauda equina syndrome, **II**:173
 - and cauda equina claudication syndrome distinguished, **II**:185–186
 - physical examination for, **II**:183–184
 - subtypes, **II**:211
- Cavernous hemangioma, **I**:443
- Cavernous sinus
 - cranial nerve lesions in, **II**:106
 - thrombosis, **II**:317
- Celiac disease, **I**:484
 - severe, risk factors for, **I**:486
- Central artery, palpation to differentiate aortic stenosis types, **I**:162
- Central cord syndrome, **II**:173, 179
 - physical examination for, **II**:180
- Central cyanosis, **I**:253
- Central nervous system (CNS)
 - constipation and, **I**:481
 - disorders involving. *See under* Neurological disorders
 - lesion localization in, **II**:17
 - in systemic lupus erythematosus, **II**:599, 600



- Central venous pressure (CVP), **I**:36–44
 - assessing from left internal jugular vein, **I**:42
 - difficulty accessing, **I**:36
 - evaluation, **I**:34
- Cerebellar artery thrombosis, posterior inferior, physical examination for, **II**:121
- Cerebellar ataxia gait, **II**:270
- Cerebellar lesion, unilateral, physical examination for, **II**:167
- Cerebellar speech, **II**:362
- Cerebellopontine angle, cranial nerve lesions in, **II**:106
 - directed history for, **II**:108
 - physical examination for, **II**:106, 108
- Cerebellum
 - anatomy, **II**:162
 - disorders. *See also* Ataxia
 - causes, **II**:162–163
 - physical examination for, **II**:170
- Cerebral arteries, **II**:312
 - in common stroke syndromes, **II**:319
 - occlusion, **II**:30–31
- Cerebral cortex
 - arteries, **II**:312
 - lobes, **II**:24, 25
 - motor and sensory areas in, **II**:24, 25
- Cerebral hemisphere
 - disease of, directed history and focused physical examination for, **II**:24
 - findings in UMN weakness, **II**:20
 - sensory syndrome involving injury to, **II**:180
 - unilateral disease of, performance characteristics in, **II**:325
- Cerebral infarction, types of, **II**:333
- Cerebral vascular disease, **II**:312–335
- Cerebral vertigo, **II**:112
- Cerebrovascular accident (CVA)
 - cardiac risks for, **II**:327–328
 - directed history for, **II**:313–314
 - Oxford classification for, **II**:333
 - physical examination for, **II**:314
 - occlusion site, **II**:315–316
 - risk for, **II**:320–321
- Cervical lymphadenopathy, focused physical examination for, **I**:606
- Cervical myelopathy, **II**:195
- Cervical osteophyte, **I**:403
- Cervical rib syndrome, **II**:186–188
 - neurological cause of, physical examination for, **II**:212
- Cervical spine



- movements, **II**:546, 547
 - range of motion, **II**:619, 620
- myotomes, **II**:176, 546
- Cervical spondylosis, **II**:182, 200
 - headache/facial pain associated with, **II**:136
- Cervical sympathetic pathway, to eye, **II**:55–56
- CHADS₂ score, **I**:89
- Chagas disease, achalasia associated with, **I**:370–373
- Chapel Hill consensus, on systemic vasculitis nomenclature, **II**:607
- Charcot-Marie-Tooth (CMT) disease
 - gait in, **II**:271–272
 - motility disorders in, **I**:587
 - physical examinations for
 - in peripheral nerve degeneration, **II**:239
 - in peroneal muscular neuropathy, **II**:239
- Charcot's joint, **II**:234
 - definition, **II**:612
 - physical examination for
 - directed, **II**:611–612
 - focused, **II**:612–613
- Charcot's triad, Reynold's Pentad modification, **I**:563
- Chest
 - examination techniques, **II**:382
 - expansion, **II**:595
 - asymmetric, physical examination for, **II**:373–374
 - in pulmonary system inspection, **II**:395
- Chest pain
 - in achalasia patient, **I**:374
 - in bronchial cancer patients, **II**:448
 - directed history for, **I**:47
 - esophagus-related, **I**:377
 - non-cardiac, GERD vs., **I**:383
 - PQRSTU-A mnemonic, **I**:47
 - right upper quadrant, **I**:446
 - causes, **I**:421
 - signs of other causes, **I**:18
- Chest X-ray, **II**:470–474
 - ABCs of reading, **II**:475
 - abnormal, in child, **II**:476
 - case studies, **II**:481–494
 - change suggesting esophageal cancer, **I**:401
 - clinical anatomy on, **II**:478–480
 - in hyperinflation, **II**:472
 - in lung collapse, **II**:472
 - mediastinal tumours seen on, causes, **II**:474



- mottling vs. miliary mottling, **I:551**
- mottling vs. miliary mottling on, **II:477**
- normal, **II:479**
- in patent ductus arteriosus, **I:259**
- in pulmonary fibrosis, **II:472–473**
- systemic approach to reading, **II:471–472**
- Cheyne-Stokes respiration, **II:372, 373, 386**
- Childhood coarctation, **I:225**
- Chloride channel activator, **I:482**
- Cholecystitis, acute, **I:545–546**
- Choledochal cyst, **I:563**
- Cholestasis, **I:532–533**
 - performance characteristics for diagnostic imaging studies, **I:533**
- Cholestatic jaundice, in pregnancy, **I:532**
- Cholesterol embolization, **I:443**
- Cholinergic crisis, **II:260, 353**
- Chordate tendinae rupture, physical examination to distinguish murmur from papillary muscle dysfunction, **I:172**
- Chorea, **II:294**
 - causes, physical examination for, **II:296, 297–298**
 - hematological abnormalities associated with, **II:292**
- Choreiform movements, **II:266, 293**
- Choroid pigmentation, **II:47**
- Choroidosis, on fundoscopic examination, **II:52, 67**
- Chromium deficiency, complications, **I:566**
- Chronic arterial insufficiency, **I:62**
- Chronic arthritis, juvenile, **II:587**
- Chronic bronchitis, **II:431**
 - history for
 - directed, in respiratory disease differentiation, **II:434**
 - focused, **II:432**
 - obstructive, **II:436**
 - physical examination for, **II:432**
- Chronic disease, directed history of, **II:359**
- Chronic fatigue syndrome (CFS), **II:623**
- Chronic obstructive pulmonary disease (COPD), **II:431, 436–442**
 - clinical history, **II:437**
 - in emergency department patients, operational characteristics, **II:435**
 - physical examination for, performance characteristics, **II:438**
 - spirometry criteria for, **II:440**
 - surgical procedures for, **II:437**
- Churg-Strauss syndrome (CSS), **I:470, 580, 581**
 - diagnosis of, **II:466**
- Chvostek's sign, **II:562**
- Chymosin (rennin), effects of salt intake on, **I:647**



- Cigarette smoking, harmful effects/complications of, directed history for, **II:439, 441–442**
- Circle of Willis, arteries of, **II:313**
occlusion sites, **II:315**
- Circulating autoantibodies, assessing, **I:455**
- Circulation infarction syndromes, classification of, **II:330**
- Circumduction gait, **II:273**
- Cirrhosis, **I:518–519**
biliary, **I:546**
esophageal varices in, **I:391**
focused physical examination for, **I:518**
palpable spleen in, **I:630**
splenic artery aneurysm risk in pregnancy, **I:392**
transient elastography for diagnosis, **I:523**
variceal bleeding risk in pregnancy, **I:393**
- Claude's syndrome, **II:111**
- Claudication, **I:55**
- Claw hand, causes, **II:232**
- Clicks, **I:116**
in mitral valve prolapse, **I:184**
vs. other heart sounds, **I:125**
- Clonus, **II:208, 209**
- Closed fist sign, **II:503**
- Clostridium difficile*, clinical course in SOT, **I:506**
- Clubbing, **II:404–410**
causes, **II:407**
and crackles association, **II:393, 410**
familial
congenital, **II:410**
and non-familial distinguished, **II:408**
hypertrophic pulmonary osteoarthropathy vs., **II:407**
interphalangeal depth ratio in, **II:405–406**
in patent ductus arteriosus, **I:259**
physical examination for, **II:404–405**
Schamroth's sign in, **II:406**
of toes, **I:224**
in PDA, **I:264**
unilateral, causes, **II:408**
- Cluster headache, **II:136**
- CN (cranial nerves). See Cranial nerves (CN); *individually named nerves*
- Coagulation defects, **I:602**
- Coagulation factor, causes of acquired deficiencies, **I:602**
- Coarctation of aorta, **I:253–254, II:530**
in childhood, **I:225**
commonest causes of death of patient with, **I:225**



- complications, **I**:231, 261
- in fever of unknown origin, **II**:630
- fundal findings, **I**:229, 260
- and notching of ribs, **I**:224
- physical examination in adult, **I**:230–231
- and systemic hypertension, **I**:225
- types, **I**:229, 260
- Cogan's syndrome, **I**:582
- Cognitive impairment, in returned traveler, **II**:637
- Cold-induced esophageal pain, mechanism of, **I**:376
- Collapse, of lung. *See* Lung collapse
- Collapsing pulse, **I**:74, 84
 - causes, **I**:205
- Collet-Sicard syndrome, **II**:129
- Colon, **I**:473–497
 - constipation, **I**:478–480
 - fecal incontinence, **I**:478
 - infections, **I**:489–490
 - lower GI bleeding, **I**:473–477
 - obstruction/pseudo-obstruction, **I**:490
- Colon transit time (CTT), **I**:480
- Colonic diverticula, **I**:476
- Colonic polyp syndrome, **I**:493
- Colonic ulceration, mucosal biopsies from, **I**:492
- Colonoscopy, **I**:473, 475
- Color blindness, congenital, **II**:93
- Colorectal cancer (CRC), **I**:496–497
 - directed history for screening, **I**:496
 - hereditary nonpolyposis, **I**:494
 - in patient with ZES, **I**:405
 - screening, quality measures, **I**:269
- Coma
 - and cataplexy distinguished, **II**:336
 - causes, **II**:338–340
 - differential diagnosis, **II**:343
 - directed history for, **II**:340
 - hyperosmolar non-ketotic, **I**:280
 - physical examination for, **II**:341
- Combined anterior horn cell pyramidal tract syndrome, **II**:179
- Community-acquired pneumonia (CAP)
 - prognostic factors, **II**:416
 - quality measures, **I**:269
- Compartmentalized esophageal pressurization, **I**:371
- Complex partial seizures, **II**:28–29, 301
- Compression



- of lumbar discs, **II:223–224**
- of spinal cord. See Spinal cord compression
- Computed tomography (CT), of head, **II:357**
 - indications for, **II:306**
- Concomitant strabismus, **II:87**
- Conduction delays, **I:88**
- Condyloma acuminatum, viral infection associated with, **I:572**
- Confusion
 - assessment, **II:336**
 - mini-mental test for, **II:337**
- Congenital heart disease
 - anatomic classification, **I:243–265**
 - chest X-ray finding in common causes, **I:245**
 - clinical findings of causes associated with cyanosis, **I:252–253**
 - commonest types, **I:262**
 - physiological classification based on cyanosis, **I:250–251**
- Congestive heart failure (CHF), **I:19–36**
 - associated symptoms, **I:15**
 - causes, **I:24**
 - circumstances prompting hospitalization, **I:27, 31**
 - focused physical examination for, **I:27**
 - Framingham criteria for clinical diagnosis, **I:25**
 - NYHA functional classification, **I:25**
 - performance characteristics of physical examination, **I:28**
 - quality measures, **I:269**
 - signs, **I:17**
- Coning, progression of, **II:347**
- Conjugate deviation of eye, spasms of, **II:90**
- Conjunctivitis, **II:72**
 - bacterial, **II:83**
 - vs. keratitis, differentiating between, **II:85**
- Consolidation, of lung. See Pulmonary consolidation
- Constipation, **I:478–480**
 - causes related to MS, **I:587**
 - in hypothyroidism, **I:480**
- Constricted visual field, **II:40**
- Constrictive pericarditis
 - causes, **I:216, 222–223**
 - focused physical examination for, **I:221**
 - physical examination for, **I:217, 218–219**
- Context breath testing, **I:454**
- Contraception method, in female on antiepilepsy drugs, **II:304**
- Conus medullaris, cauda equina syndrome and, **II:173**
 - differentiation, **II:212**
- Coordination of gait, **II:170**



- Coordination test, in extrapyramidal disease, **II:282**
- Copper deficiency, complications, **I:566**
- Cor bovinum, **I:34**
- Cor pulmonale
 - causes, **II:450**
 - physical examination for, **II:452–453**
- Cornea, ulcer/abrasion of, **II:83**
- Corneal reflex, **II:72, 97**
 - neuroanatomy, **II:11**
 - reticular activating system and, **II:161**
- Coronary artery disease
 - history to determine risk factors, **I:46**
 - performance characteristics, **I:223**
- Corrigan's neck pulsation, **I:208**
- Corrigan's sign, **I:208**
- Cortical areas, disease detection in, directed history for, **II:340**
- Cortical blindness, determination of, **II:43**
- Cortical stroke, **I:386**
- Corticospinal inhibition, loss of, physical examination for, **II:208–209**
- Cotton-wool spots, retinal, **II:45**
 - causes, **II:46**
- Couer de sabot, and tetralogy of Fallot, **I:265**
- Cough/Coughing, **II:389–392**
 - during auscultation of chest, **II:386**
 - causes, **II:391**
 - clinical features, **II:391**
 - described, **II:389**
 - directed history for, **II:390–391**
 - effect on expiratory crackles, **II:386**
 - sputum in, **II:389–390**
- Courvoisier's sign, **I:544**
- Cowen sign, **I:314**
- Coxalgic gait, **II:275**
- Crackles, **II:376, 378, 383–384**
 - characteristics in various disorders, **II:380**
 - and clubbing association, **II:393, 410**
 - expiratory, effect of coughing on, **II:386**
 - in healthy persons, **II:381**
 - late inspiratory, cause, **II:383**
 - mid inspiratory, **II:384**
 - normal, **II:381**
 - and pleural rub distinguished, **II:385**
 - posture-induced, **II:381**
 - pulmonary auscultation performance characteristics, **II:384**
- Cramps, muscle, **II:257**



- Cranial nerves (CN). *See also individually named nerves*
 areas supplied by, **II:32–33**
 eye movements and, **II:74**
 in focused physical examination of nervous system, **II:21, 35**
 medial longitudinal bundle, **II:33**
 multiple abnormalities of, syndromes associated with, **II:141**
 nuclei, **II:35**
 palsies of, conditions causing, **II:111**
- Creatinine clearance, **I:663**
- "Crescent sign," **II:553**
- Cricopharyngeal bar, neurological conditions associated with, **I:377**
- Crohn disease (CD), **I:447–451, 470**
 with HBV, therapeutic management, **I:467**
 peripheral arthritis vs. sacroiliitis in, **II:593**
- Cronkhite-Canada syndrome, **I:494–495, 497**
- Crossed adductor reflex, **II:208**
- Cryptococcus*, in small bowel biopsy, **I:467**
- Cryptosporidium*, **I:452, 563**
- Cullen's sign, **I:434, 544**
- CURB mnemonic, **II:417**
- Cushing disease, **I:321**
- Cushing syndrome, **I:19, 321**
 adipose tissue distribution, **I:322**
 focused physical examination for, **I:320**
 performance characteristics, **I:319**
 systematic approach to causes, **I:318–319**
- Cyanose tardive, **I:253**
- Cyanosis, **II:387**
 causes, **I:253**
 development in patent ductus arteriosus, **I:259**
 of left hand, **I:225**
 of legs, **I:224**
 peripheral vs. central, **II:401**
 of toes, in PDA, **I:264**
- Cyanosis tardive, **I:262**
- Cyanotic heart disease
 causes in infants, **I:265**
 congenital, **I:250–251, 253–255**
- Cystic duct, stones in, **I:546, 547**
- Cystic fibrosis (CF), **I:507**
 bronchiectasis in, **II:464**
 liver transplant in treatment, **I:506**
- Cystic neoplasms, vs. pseudocysts in pancreas, **I:549**
- Cysts, **I:556–557**
 pancreatic, **I:546**



Cytomegalovirus (CMV) infection, **II**:640
vs. HSV esophagitis, **I**:390

D

Dahl's sign, **II**:387

Dalrymple sign, **I**:313

Darier sign, **I**:404

Dark-colored spots, retinal, **II**:47

D-dimer, and deep vein thrombosis probability, **II**:458, 459

De Musset's sign, **I**:208

De Quervain's disease, **II**:520, 623

De Weese test, **I**:60

Deafness

causes, **II**:114

tests evaluating, **II**:114–115

Deep tendon reflexes (DTR)

changes in, **II**:217

grading power, **II**:244

interpreting, **II**:243

L5 lesions and, **II**:230

of LMN and UMN lesions, **II**:19

Deep vein thrombosis (DVT), **I**:49, **II**:457–459

diagnostic imaging in, **II**:461

directed history for, **II**:458–459

physical examination for, **II**:458–459

post-test probability, **II**:459

pretest probability, **II**:457–458

Wells scoring schemes for, **II**:458–459

Virchow triad in, **II**:476

Defecation reflex, spinal cord injury and, **I**:588

Defecatory disorders, **I**:480–481

Deforming polyarthropathy, causes of, **II**:571

Degenerative neurological disorders, achalasia associated with, **I**:372

Deglutitive inhibition, **I**:372

Dehydration, **I**:664, 668–669

Delirium

causes, **II**:337–338, 342

and dementia differentiation, **II**:311

directed history for, **II**:341–342

onset signs, **II**:337

performance characteristics for, **II**:312

in returned traveler, **II**:637

Delphian node, **I**:607

Dementia, **II**:304–312

causes, **II**:304–305



- physical examination for, **II:308–310**
- site, **II:307–308**
- characteristics, **II:338**
- and delirium differentiation, **II:311**
- differential diagnosis, **II:310–311**
 - history for, **II:311**
- directed history for, **II:309–310**
- performance characteristics for, **II:312**
- Pick's presenile, **II:361**
- stages, **II:305**
- DEMENTIA** mnemonic, **II:307**
- Dental procedures, antibiotic regimen for endocarditis prophylaxis in, **I:242**
- Dentatorubral pallidoluysian atrophy, **II:292**
- Dermatitis enterohepatica, from zinc deficiency, **I:472**
- Dermatomes, sensory. *See* Sensory dermatomes
- Dermatomyositis
 - GI complications, **I:580**
 - physical examination for, **II:580, 616**
 - signs and symptoms, **II:580**
- Descending perineum syndrome, **I:480**
- Dextrocardia
 - abnormalities associated with, **I:261**
 - acquired vs. congenital, **I:256**
 - focused physical examination for, **I:256**
 - physical examination to distinguish between situs inversus, dextroversion and levoverion, **I:244**
- Dextroversion, **I:265**
 - physical examination to distinguish between dextrocardia, situs inversus and levoverion, **I:244**
- Diabetes mellitus, **I:275–283**
 - causes/associated conditions, **I:275–276**
 - complications, **I:276–277**
 - definition, **I:287**
 - directed history for, **I:275**
 - effects on blood vessels, **I:86**
 - EMG studies, **I:587**
 - neurological complications, **II:357–358**
 - peripheral neuropathy in, **II:234, 236, 246**
 - risk and management, **I:278–279**
 - risk factors, **I:277–278**
 - skin lesions in, **I:282**
- Diabetes of gut, **I:587**
- Diabetic foot, **I:287**
 - focused physical examination for, **I:281**
 - performance characteristics of clinical tests, **I:281**



- Diabetic ketoacidosis (DKA), **I:280**
 - focused physical examination for differentiating HONC and, **I:282**
- Diabetic nephropathy
 - focused physical examination for, **I:279**
 - types, **I:638**
- Diabetic neuropathy, findings in, **II:47**
- Diarrhea, **I:465–472**
 - chronic, **I:468**
 - directed history for, **I:483–484**
 - in HIV-AIDS, **I:572**
 - drug-induced, **I:572**
 - in returned traveler, **II:637**
 - unexplained chronic, **I:452**
 - in VIPoma syndrome, **I:558**
- Diastolic blood pressure, **I:84**
- Diastolic dysfunction (DD), **I:21**
 - in myocardial disease, **I:212**
 - vs. systolic dysfunction, **I:30**
- Diastolic murmurs, **I:135, 186–187**
 - of mitral stenosis, **I:195**
 - selected features, **I:188**
 - systolic murmurs in aortic regurgitation with, **I:206**
- Diastolic normal heart sounds, **I:120**
- Diastolic rumble, **I:182**
 - in mitral regurgitation, **I:180**
- Dicrotic pulse, **I:72, 73, 74**
- Diet, and diverticular disease, **I:475**
- Dieulafoy lesion, **I:408**
- Diffuse esophageal spasm, vs. spastic achalasia, **I:374**
- Diffuse large B cell lymphomas (DLBCL), vs. gastric maltoma, **I:438**
- Digit. See Finger
- Diplopia, causes of, **II:81, 86–87**
 - physical examination for, **II:86–87**
- Disseminated intravascular coagulation (DIC), causes, **I:601**
- Dissociated anesthesia, spinal cord
 - diseases causing, **II:184**
 - types, **II:184–185**
- Distal contractile integrity (DCI), **I:387**
- Distal esophageal spasm (DES), **I:373–374**
 - vs. nutcracker esophagus, **I:377**
- Divergent strabismus, **II:87**
- Diverticular disease, diet and, **I:475**
- Diverticulitis, acute, **I:493**
- Diverticulum
 - bleeding, **I:473**



- esophageal, **I**:387–388
- Dizziness, directed history for, **II**:348–349
- "Doll's eye" reflex, **II**:161
- Dorsal column, sensory loss attributed to, **II**:176
- Dorsal midbrain syndrome, **II**:32
- Double-peak pulses, **I**:72
- Drawer sign
 - anterior, **II**:556, 559
 - posterior, **II**:557
- Dressler's syndrome, **I**:49, 51
- Drink, and esophageal cancer, **I**:394
- DRIP mnemonic, **II**:636
- Drug-induced liver injury (DILI), **I**:503
- Drugs
 - acute nephritis from, **I**:652–653
 - to avoid in late stage kidney disease, **I**:660–661
 - dose reduction in renal impairment, **I**:649–650
 - dysglycemia from, **I**:283
 - effects on murmurs, **I**:126
 - and esophageal cancer, **I**:395
 - exacerbating congestive heart failure, **I**:26
 - GI, in renal impairment, **I**:649
 - high-risk at hospital discharge, **I**:54
 - interactions with warfarin, **I**:603
 - liver injury, in HIV-AIDS treatment, **I**:573
- Drusen deposits, in retina, **II**:45–46
- DSM mnemonic, **II**:646
- Duane's syndrome, **II**:89
- Duchenne's muscular dystrophy, **I**:20, **II**:249, 253, 262
- Duckett Jones criteria, for rheumatic fever diagnosis, **I**:146–147
- Dullness (percussion note), **II**:403
 - at lung base
 - major causes distinguished, **II**:397, 398
 - unrelated to consolidation, cavitation or collapse, **II**:397
- Duodenum, NET (carcinoid tumours) in, **I**:462
- Duplication cyst (DC), **I**:443
 - pathological association, **I**:440
- Dupuytren's contracture, **I**:523, 546, **II**:516, 518, 520
 - conditions associated with, **II**:531
- Duroziez's double murmur, **I**:205
 - vs. "false positive" Duroziez's sign, **I**:207
- Duroziez's maneuver, sensitivity for aortic regurgitation, **I**:207
- Duroziez's sign, **I**:208
- Dysarthria, **II**:14, 125–126, 270, 363
 - causes, **II**:126, 363



- physical examination for, **II**:118, 127–128
- in cerebellar disorders, **II**:164
- Dysdiadochokinesis, **II**:270
 - in cerebellar disorders, **II**:164, 170
- Dysfunctional papillary muscle, mitral regurgitation murmur from, **I**:169
- Dysglycemia, drugs causing, **I**:283
- Dyskinesia
 - tardive, **II**:290
 - upper body, **II**:283
- Dyslipidemias, **I**:323–326
- Dysmetria, **II**:270
- Dyspepsia
 - proton pump inhibitors for, **I**:404
 - Rome criteria, **I**:376
 - uninvestigated vs. functional, **I**:376
- Dysphagia, **I**:360–364
 - approach to person with, **I**:362
 - development, **I**:401
 - differential diagnosis of odynophagia and, in AIDS, **I**:569
 - histological changes, **I**:366
 - lump in throat vs., **I**:375
 - oropharyngeal, **I**:363
 - vs. esophageal causes, **I**:386
 - neuromuscular disorders associated with, **I**:364
 - pharyngeal, **I**:403
- Dysphasia, **II**:15–16, 123–124
 - conductive, **II**:127
 - history and physical examination for, **II**:126–127
 - nominal, **II**:127
- Dysphonia, **II**:16, 128
- Dysplasia, **I**:368
- Dyspnea, positional, **II**:375
- Dysrhythmias, **I**:89–97
- Dyssynergia
 - in cerebellar disorders, **II**:164, 170
 - pelvic, **I**:478
- Dystonia, **II**:294
- Dystrophia myotonica. See Myotonic dystrophy

E

Eales' disease, **II**:43

Ear

- hearing tests and, **II**:112–115
- neurological disorders of, CN VIII involvement in, **II**:112–113
- Eaton-Lambert syndrome, and myasthenia gravis differentiation, **II**:259



- Echolalia, **II:16**
- Ectopic pregnancy, **I:434**
- Edema, **I:664**
 - optic nerve head, **II:53**
 - peripheral, causes, **I:66–71**
 - physical examination to differentiate types of regional, **I:69**
 - pulmonary, **I:35**
 - venous, vs. lymphedema, **I:68**
- Effusion, in lung. See Pleural effusion
- Ehlers-Danlos syndrome, **I:472**
- Eisenmenger complex, **I:262**
 - Eisenmenger syndrome vs., **I:257**
- Eisenmenger syndrome, **I:263**
 - vs. Eisenmenger complex, **I:257**
 - focused physical examination for, **I:257–259**
- Ejection click, **I:144**
- Ejection sound, **I:116, 118**
- Ejection systolic murmur, **I:182**
- Elbow, **II:531–533**
 - abnormal articular findings in, **II:512**
 - deformities, **II:520**
 - normal range of motion, **II:514, 531**
 - physical examination for, **II:505, 531–532**
 - in disease differentiation, **II:532**
 - "tennis" vs. golfer's, **II:533**
- Elderly
 - care, **II:643**
 - falls in, reasons for, **II:645**
 - urinary incontinence causes in, **II:636**
- Electrocardiogram (ECG), for myocardial infarction vs. pericardial effusion, **I:222**
- Electrolyte disorders, **I:664**
- Ellis's S-shaped line, **II:474**
- Ellis-van Creveld syndrome, **I:20**
- Embolism, pulmonary, **II:460–462**
 - ECG changes in, **II:460**
 - probability
 - modified Wells criteria for, **II:460**
 - simplified clinical model, **II:461**
 - ventilation–perfusion scan and, **II:460**
- Emergency department patients
 - operational characteristics
 - asthma, **II:435**
 - chronic obstructive pulmonary disease, **II:435**
 - performance characteristics in CHF, **I:22**



- Emphysema, **II**:431, 436
 chest examination techniques in, **II**:382
 and respiratory disease differentiation, **II**:434
 "Empty can" (supraspinatus) test, **II**:537
 Endarteritis obliterans, **II**:606
 Endocarditis. *See also* Bacterial endocarditis
 antibiotic regimen for prophylaxis in dental procedures, **I**:242
 bacterial, **I**:231–243
 valve disease predisposing to, **I**:241–242
 Endocrine system, in lung cancer, physical examination for, **II**:445
 Endocrinology, exam questions, **I**:xxiii–xxv, 273–274
 Endometriosis, **I**:495, 497
 End-organ damage, from systemic hypertension, **I**:639
 Endoscopic hemostatic therapy (EHT), **I**:408
 example of effective, **I**:409
 Endoscopic ultrasound (EUS)
 of benign vs. malignant GIST, **I**:439
 of gastric submucosal tumours, **I**:439
 and submucosal gastric tumours, **I**:440
 Endoscopy, intraoperative complications, **I**:592
 Enroth sign, **I**:314
 Enteric bacteria, infection in HIV-AIDS, **I**:572
 Enteric neurons, and constipation, **I**:481
 Enterochromaffin-like (ECL) cell carcinoid tumours, **I**:439
 Enterocolitis, neutropenic, **I**:548
 Enteropathy-type intestinal cell lymphoma (EITL), **I**:456–457
 Enteroscopy, **I**:412
 Entrapment syndromes
 cervical rib, **II**:186–188
 nerve, **II**:182
 Eosinophilia
 causes, **I**:621–622
 pulmonary. *See* Pulmonary eosinophilia
 Eosinophilic esophagitis, **I**:403
 Eosinophilic folliculitis, **II**:646
 Epilepsy, **II**:16
 seizure types in, **II**:29, 299
 Epiphrenic diverticulum (ED), **I**:388
 Epithelial cells, of esophagus, sign of damage, **I**:380
 Epitrochlear lymphadenopathy, **I**:607
 Epstein Barr virus (EBV) infection, **I**:523, **II**:639
 Erythema marginatum, as criteria for rheumatic fever diagnosis, **I**:147
 Erythema multiforme, physical examination for, **II**:596
 Erythrophagocytosis, in Kupffer cell, **I**:586
Escherichia coli O157:H7 infection, **I**:490



- Esophageal adenocarcinoma
 - peptides link to, **I:385**
 - risk of developing after therapy for BE, **I:367**
- Esophageal band ligation (EBL), for bleeding esophageal varices, **I:413**
- Esophageal bolus obstruction, **I:375**
- Esophageal intramural pseudodiverticular (EIP), **I:388**
- Esophageal spastic contraction, **I:371**
- Esophageal variceal band ligation (EVBL), vs. β -blockers, for esophageal variceal bleeding prophylaxis, **I:391–392**
- Esophagitis
 - CMV vs. HSV, **I:390**
 - eosinophilic, **I:403**
- Esophagogastroduodenoscopy (EGD)
 - clinical endpoints for second-look, **I:412**
 - recommendation prior to bariatric surgery, **I:419**
- Esophagogram, barium, **I:384**
- Esophagus, **I:360–403**
 - achalasia, **I:369–370**
 - balloon tamponade tubes for bleeding varices, **I:414**
 - black, **I:389**
 - cancers, **I:393–403**
 - chest X-ray change suggesting, **I:401**
 - diagnostic imaging test for staging, **I:402**
 - FDG PET/CT role in restaging, **I:400**
 - risk factors, **I:394–398**
 - therapeutic modalities for early, **I:398–399**
 - candidiasis, conditions predisposing to development, **I:389**
 - chemicals buffering intracellular pH, **I:382**
 - chest pain related to, **I:377**
 - complaints after heart/lung transplant, **I:574**
 - distal esophageal spasm, **I:373–374**
 - distention, **I:376**
 - diverticulum, **I:387–388**
 - dysphagia, **I:360–364**
 - epithelial cells, sign of damage, **I:380**
 - foreign bodies in, **I:375**
 - gastroesophageal reflux disorder, **I:375**
 - genetic instability of mucosa, **I:368**
 - hiatus hernia, and GERD, **I:381**
 - HIV-AIDS involvement, **I:570**
 - newer tests of function, **I:385**
 - normal effect of CCK on muscle, **I:372**
 - peristaltic dysfunction, **I:382**
 - pill esophagitis, **I:369**
 - segments, **I:371**



- sensation, **I**:379
- tumours, **I**:393–403
- varices, **I**:391–393
- Esotropia, **II**:86
- Essential tremor, **II**:297
- Estrogen therapy, contraindications to, **I**:339
- Estrogen-associated cholestasis (EAC), molecular defects causing, **I**:532
- Evidence-based medicine (EBM), carotid artery stenosis and deep vein thrombosis, **II**:461
- Exam questions. *See under* Objective standardized clinical examination (OSCE)
- Exercise, effect on tachyarrhythmias, **I**:95
- Exophthalmos, **II**:81, 91
 - causes, **I**:313
- Exposure, occupational, lung disease caused by, **II**:402
- External jugular vein, distinguishing from internal, **I**:36
- Extra-articular complications, of rheumatoid arthritis, **II**:570
- Extramedullary cord lesion, focused physical examination for, **II**:31
- Extramedullary hematopoiesis, vs. myeloid metaplasia, **I**:624
- Extrapyramidal disease, **II**:128, 278–292
 - physical examination for, **II**:281–284
- Extremities
 - arterial occlusive disease, grading system, **I**:71
 - directed history and focused physical examination for vascular disease, **I**:57–58
 - in patient inspection for cardiac disease, **I**:13–14
- Extrinsic allergic alveolitis (EAA), **II**:465–470
 - acute vs. chronic forms, **II**:466
- Exudates, retinal, **II**:45, 46
- Exudative phase, in hypertensive retinopathy, **II**:44
- Eye
 - abnormalities of, causes, **II**:69–70
 - cervical sympathetic pathway to, **II**:55–56
 - conjugate deviation of, spasms, **II**:90
 - fibers from, **II**:36
 - in multiple sclerosis, **II**:352
 - neurological disorders of, CN II involvement in, **II**:36–73
 - pain in, causes, **II**:49, 83
 - in patient inspection for cardiac disease, **I**:12–13
 - physical examination, **II**:36
 - visual symptoms and related disease states, **II**:69
- Eye movements, **II**:74–81
 - absent or abducted, **II**:91
 - disorders of neurological origin in, **II**:74–94
 - translational neuroanatomy, **II**:74–77



Eyebrows, thinning of, **I:294**

F

FABER maneuver, **II:553**

Face

neurological problems, **II:99–112**

pain. *See* Facial pain

in patient inspection for cardiac disease, **I:11**

Facial nerve (CN VII), **II:33, 98–106**

anatomy, **II:99**

disorders

clinical manifestations, **II:102–103**

physical examination for, **II:101–102**

forehead wrinkling and, **II:109**

lesions of, physical examination for, **II:99–101**

motor component, **II:98**

palsy. *See* Paralysis, facial

reflexes involving, **II:102, 110**

sensory component, **II:98, 110**

Facial pain. *See also* Headache

causes

directed history for, **II:137–138**

physical examination for, **II:105**

forms, **II:133**

Facial weakness/paralysis. *See also* Paralysis, facial

physical examination for cause, **II:103–105**

UPM vs. LMN, **II:103**

Facioscapulohumeral muscular dystrophy, **II:249, 253, 263**

Faecalibacterium prausnitzii, **I:489**

Fallot's pentatoly, **I:265**

Falls in elderly, reasons for, **II:645**

False-localizing sign

for hemiplegia, **II:156**

lower motor neuron, **II:90**

Familial fundic gland polyps, **I:441**

Familial hypokalemic paralysis, clinical features of, **II:248**

Familial Mediterranean fever (FMF), **I:451, 582, 584**

Fasciculations

causes, physical examination for, **II:238**

upper limb motor system and, **II:207**

FAST rating, in dementia, **II:305–306**

Fasting gastrin concentration, in ZES, **I:406**

Fecal incontinence, **I:478**

Felty's syndrome, **I:543, II:575, 579**

Fetus, beta-blocker impact on, **I:393**



Fever

in hospitalized patient, **II:633**

performance characteristics, **II:631**

prognostic, **II:634**

plus purpura, **II:648–649**

postoperative, **II:632**

pulse rate and, **II:648**

with rash, causes, **II:634–635**

in returned traveler, **II:637**

of unknown origin

bone marrow biopsy in, **II:631–632**

causes, **II:631**

physical examination for, **II:630**

FEV₁/FVC value, estimating with stethoscope, **II:387**

Fibrillation

atrial, **I:89**

focused physical examination for, **I:89–90**

ventricular, **I:89**

Fibromyalgia

definition, **II:609**

and polymyalgia rheumatica distinguished, **II:610**

Fibrosing alveolitis

acute vs. chronic forms, **II:467**

causes, **II:267**

definition, **II:392**

directed history for, **II:468**

physical examination for, **II:392–393, 468**

Fibrosis. See Cystic fibrosis; Pulmonary fibrosis

Finger

abnormal articular findings in, **II:510–511**

deformities, **II:519**

dorsal portion, bulimia and, **II:410**

normal range of motion, **II:514, 525**

physical examination for, **II:506–507**

sausage-shaped, non-traumatic causes, **II:623**

Finger nails, **I:528–529**

Finger-nose test, in cerebellar disorders, **II:164, 166, 170**

Finger-nose-finger test, **II:166**

Finkelstein sign, **II:618**

Finkelstein's test, **II:507, 520, 623**

Fisher's one and a half syndrome, **II:91**

Fissures of lung, X-ray view on inspiration, **II:480**

Fistula

conditions associated with non-healing, **I:448**

indicators of spontaneous closure, **I:447**



- "Fixed" pupil, **II:63**
- Flexor tendons, superficial and profundus, **II:522, 525**
- Flick sign, **II:503**
- Fluency, of speech, **II:124**
- Fluids
 - disorders, **I:664**
 - drugs causing retention, **I:26**
- Fluorodeoxyglucose, **I:438**
- Flushing, physical examination for, **II:638**
- F-NETs, types of inherited, **I:439**
- Focal gastritis, causes, **I:441**
- Focal nodular hyperplasia, **I:536**
- Focal seizures
 - motor, **II:299**
 - sensory, **II:299, 302**
- Folliculitis, eosinophilic, **II:646**
- Folstein mini mental status exam, **II:310**
- Food, and esophageal cancer, **I:394**
- Foot
 - abnormal articular findings in, **II:513**
 - diabetic
 - focused physical examination for, **I:281**
 - performance characteristics of clinical tests, **I:281**
 - normal range of motion, **II:515**
 - physical examination for, **II:508, 563**
 - in rheumatoid arthritis, **II:583**
- Foot drop
 - differentiating causes, **II:244**
 - in high stepped gait, **II:267, 271**
 - physical examination in, **II:207, 247**
- Foramen magnum pressure cone, **II:156–157, 363**
- Forehead wrinkling, facial nerve (CN VII) and, **II:109**
- Foreign bodies, in esophagus, **I:375**
- Foster Kennedy syndrome, **II:361**
- Foville's syndrome, **II:34, 89, 174**
- Fracture
 - of ankle and midfoot
 - "best" clinical test for, **II:568**
 - performance characteristics, **II:562**
 - blow-out, of orbit, **II:90**
 - of knee
 - "best" clinical tests for, **II:559**
 - Ottawa rule for knee, **II:559–560**
 - performance characteristics for, **II:559**
 - milkman type, **II:584**



- spinal, likelihood ratios of physical examination for detecting, **I:332**
- Friction rubs, **I:524**
 - pericardial, **I:213–214**
- Friedreich's ataxia, **I:20, 82**
 - directed history and physical examination for, **II:213**
 - Harding's criteria for, **II:214**
- FRIEND mnemonic, **I:448**
- Frontal lobe, **II:24, 25**
 - disease detection in
 - directed history for, **II:28**
 - focused physical examination for, **II:26**
 - Foster Kennedy syndrome and, **II:361**
 - tumour, **II:359**
- Fulminant colitis, infectious organisms in AIDS/HIV leading to, **I:492**
- Functional abdominal pain syndrome (FAPS), **I:429–430**
- Functional Assessment Staging Tool (FAST) rating, in dementia, **II:305–306**
- Functional dyspepsia, vs. uninvestigated dyspepsia, **I:376**
- Fundic gland polyps (FGP), **I:440–441**
- Fundic varices, anatomical basis for isolated, **I:392**
- Fundoscopic examination
 - choroidosis and retinitis distinguished, **II:52, 67**
 - ocular blood vessels distinguished, **II:68**
 - for papilledema, **II:52**
- Fundus, in hypertensive retinopathy, focused physical examination of, **II:44–45**

G

- Gag reflex, loss of, **I:386**
- Gait, **II:170, 266–277**
 - assessment in cerebellar disorders, **II:164**
 - disorders of, physical examination, **II:268–269**
 - physiological components, **II:267**
 - types, **II:267–268**
- Gallavardin phenomenon, **I:182, 259**
- Gallbladder, **I:544–546**
 - complaints after heart/lung transplant, **I:574**
 - performance characteristics for palpation, **I:544**
 - polyps, **I:546**
- Gallop rhythm, **I:115**
- Gallstone ileus, likely sites of obstruction, **I:545**
- Gallstone pancreatitis, elevation in serum ALT or AST, **I:550**
- Gallstones, development in pregnancy, **I:545**
- Gargner syndrome, **I:493**
- Gastric acid suppression, **I:367**
- Gastric air bubble, absent, **I:363**



- Gastric antral vascular ectasia (GAVE), I:408
- Gastric body, *H. pylori* infection of, I:404
- Gastric bypass procedures, I:419
- Gastric cancer, I:442
 - supraclavicular node from metastasis from, I:363
 - types, I:462
- Gastric maltoma, I:436–437
 - vs. DLBCL (diffuse large B cell lymphomas), I:438
 - non-response to *H. pylori* eradication, I:438
- Gastric volvulus, I:378
- Gastrin
 - fasting concentration in ZES, I:406
 - physiology, I:405
- Gastrinoma triangle, I:405
- Gastritis, focal, causes, I:441
- Gastroenterology, exam questions, I:xxv–xxix, 349–352
- Gastroenteropathy, allergic, laboratory features, I:376
- Gastroesophageal reflux disorder (GERD), I:375
 - earliest cellular marker, I:382
 - esophageal hiatus hernia and, I:381
 - vs. non-cardiac chest pain, I:383
 - peptides link to, I:385
 - to treat life-style changes, I:384
- Gastrointestinal carcinoid tumours, I:460–461
- Gastrointestinal fistulas, in Crohn disease, I:447
- Gastrointestinal (GI) bleeding
 - lower. See Lower GI bleeding
 - occult, I:518
 - performance characteristics of radiological imaging, I:475
 - upper. See Upper gastrointestinal bleeding (UGIB)
- Gastrointestinal lymphomas, I:436
- Gastrointestinal neuroendocrine tumours (GI NETs)
 - cytosolic markers for poorly differentiated, I:462
 - gene point mutations and chromosomal gains and losses, I:463
 - peptides secreted by, I:461
- Gastrointestinal stromal tumour (GIST), I:437, 457–463
 - EUS of benign vs. malignant, I:439
 - IHC stains for distinguishing, I:458
- Gastrointestinal system/tract
 - amyloid, I:470
 - cancers, I:455
 - complaints after heart/lung transplant, I:574
 - disorders, dermatological conditions, I:571
 - drugs in renal impairment, I:649
 - involvement in leukemia, I:561



- manifestations of systemic disease, **I:576–578**
- neuromuscular diseases affecting, **I:587**
- in primary amyloidosis, **I:589**
- in systemic lupus erythematosus, **II:599**
- Gating disorders, **I:567**
- Gaze
 - cardinal positions, **II:79**
 - defects of CN III, IV, and VI, **II:81**
- Gegenhalten, **II:290**
- Generalized seizures, **II:299, 302**
- Genetic achalasia syndrome, **I:369–370**
- Genitourinary system, in systemic lupus erythematosus, **II:599**
- Geographical tongue, **I:358**
- Gerhardt's syndrome, **II:89**
- Gerstmann's syndrome, **II:353**
- GI liver alcohol, **I:501**
- Giant-cell arteritis (GCA), **II:609**
- Giardiasis, **I:468, 469**
 - diagnosis, **I:452**
- Gifford's sign, **I:291, 314**
- Give DAD some RUM mnemonic, **II:235**
- Glabellar tap test, **II:287**
- Glasgow coma scale, **II:341**
- Glaucoma, acute angle closure
 - examination for, **II:52–53, 553**
 - red eye and, **II:83**
- Glenohumeral joint, **II:533**
- Globus
 - lump in throat vs. dysphagia, **I:375**
 - neurological conditions associated with, **I:377**
- Glomerular filtration rate (GFR), **I:663**
- Glomus tumour, **I:439**
- Glossitis, atrophic, **I:358**
- Glossopharyngeal nerve (CN IX), **II:33, 116–117, 119**
 - disorder fo, physical examination for, **II:122**
- Glucagon, for esophageal food-associated obstruction, **I:375**
- Glucagonoma, **I:472, 555, 562**
 - clinical features, **I:556**
 - common clinical presentations, **I:553**
- Glucose control, **I:275**
- Gluten sensitive enteropathy, megaloblastic anemia in, **I:471**
- Glycogenic acanthosis, vs. candidiasis, **I:390**
- Go to the WARDS, PLeaCe mnemonic, **II:238, 246**
- Goiter, **I:295–299**
- Golfer's elbow, **II:533**



- Gottron's papules, **II**:616
 Gout, **II**:563–568
 definition, **II**:563
 elbow in, **II**:532
 and pseudo-gout distinguished, **II**:564
 radiological features, **II**:568
 Gouty tophus, rheumatoid nodule vs., **II**:583
 Gradenigo's syndrome, **II**:89, 90
 Graft-versus-host disease (GVHD)
 complaints after heart/lung transplant, **I**:574
 jaundice due to, **I**:532
 Graham Steell murmur, **I**:135, 190, 208, 262
 Gram-negative septicemia, in hospitalized patient, **II**:633
 "Grand mal" seizures, **II**:29
 Granulomatous lung disease, **II**:411–413
 "Grasp" reflex, **II**:359
 Graves' disease, **I**:294, 295
 physical examination for, **I**:298–299
 to distinguish other thyroid enlargement causes from, **I**:307–308
 vs. toxic nodular goitre, **I**:297–298
 treatment in pregnancy, **I**:299
 Grey-Turner's sign, **I**:434, 544
 Grief
 bereavement tasks and, **II**:646
 classic stages, **II**:646
 feelings experienced in, **II**:646
 Grove sign, **I**:314
 Growth factors, and esophageal cancer, **I**:396
 Guillain-Barré syndrome, **II**:234
 physical examination for, **II**:192, 244
 Gum hypertrophy, **I**:356
 Gynecomastia, **I**:335–337
 directed history and focused physical examination for, **I**:336
 systemic approaches to causes, **I**:337
 Gyrus, pre- and postcentral, **II**:24, 25

H

- Haenel's sign, **II**:361
 Halitosis, **I**:355–358
 Hallucination, illusion vs., **II**:343
 Hamartoma, **I**:398
 Hamartomatous syndromes, **I**:495
 Hamman's sign, **I**:22, 124
 Hand, **II**:514–529
 arthritis distribution in, **II**:524



- common deformities, **II:516–518**
- cutaneous sensory innervation of, physical examination for, **II:226**
- cyanosis of left, **I:225**
- deformities, **II:520**
- nerve supply, **II:524**
- normal range of motion in, **II:523**
- peripheral nerves of, physical examination for, **II:240**
- radiological erosion in, causes, **II:565**
- small muscle wasting
 - causes, **II:190, 515**
 - physical examination for, **II:224–225**
- thumb abduction, testing for, **II:224**
- Hard exudates, retinal, **II:45**
 - causes, **II:46**
- Hard knobbly liver, causes, **I:512**
- Harrison's sulcus, **II:476**
- Hartmann's pouch, **I:546**
- Hashimoto's thyroiditis, **I:301**
- Hawkins impingement sign, **II:537, 541**
- Haygarth's nodes, **II:586**
- Head
 - CT, **II:357**
 - indications for, **II:306**
 - MRI, **II:357**
- Head injury, GI complications in, **I:588**
- Headache, **II:132–137**
 - characteristics, **II:134, 135–137**
 - history taking for, **II:134–135**
 - mechanisms, **II:132–133**
 - normal neuroimaging findings in, **II:137**
- Hearing loss, tests evaluating, **II:114–115**
- Heart. *See also* Congenital heart disease
 - amyloid, **I:470**
 - in fever of unknown origin, **II:630**
 - focused physical examination for
 - in disease state, **I:16–19**
 - systemic hypertension, **I:644**
 - in systemic lupus erythematosus, **II:599**
 - transplantation, GI symptom after, **I:574**
- Heart block
 - physical examination for causes, **I:95–96**
 - suspecting complete, **I:91**
- Heart failure, factors exacerbating, **I:26**
- Heart murmurs, **I:126–145**
 - from aortic aneurysm, vs. aortic stenosis murmur, **I:226**



- of aortic stenosis and aortic regurgitation, **I:133**
 - causes of continuous, **I:130**
 - characteristics, **I:140**
 - diagrams, **I:127–128**
 - directed history for cause, **I:136**
 - dynamic maneuvers
 - to change, **I:128–129**
 - to determine nature, **I:143**
 - effect of inspiration on, **I:211**
 - ejection systolic, **I:182**
 - Gold, Silver, Bronze and Tin rules, **I:126–127**
 - grades, **I:131**
 - mid-diastolic, **I:193**
 - mitral regurgitation, **I:181**
 - vs. murmur of aortic stenosis with calcification, **I:180**
 - in patent ductus arteriosus, **I:251**
 - performance characteristics for physical examination, **I:138**
 - pulmonary ejection systolic, **I:141**
 - and pulsus tardus, **I:79**
 - Still's, **I:140**
 - systolic, **I:149–152**
 - of ventricular septal defect, **I:247, 249**
- Heart sounds, I:102–114**
- in aortic regurgitation, **I:197**
 - causes of reversed splitting of S_1 , **I:106**
 - causes of wide and fixed splitting of S_1 , **I:105**
 - disease processes associated with, **I:104–105**
 - focused physical examination for, **I:109**
 - maneuvers to improve auscultation, **I:139**
 - miscellaneous, **I:116**
 - of non-valvular origin, **I:133**
 - pathological, **I:115–125**
 - performance characteristics of S_3 and S_4 , **I:119**
 - prosthetic valve, **I:122**
 - S_1 , **I:103**
 - cardiac abnormalities impacting, **I:109**
 - S_2 , **I:103**
 - background, **I:107–108**
 - cardiac abnormalities impacting, **I:109–110**
 - and cause and severity of AS, **I:154**
 - causes of split, **I:106**
 - focused physical examination for wide splitting, **I:111–112**
 - importance in aortic stenosis, **I:155**
 - pathophysiological explanation for cause of widely split, **I:113**
 - physical examination for causes of fixed splitting, **I:108**



- physical examination of splitting for associated abnormalities, **I:112–113**
- significance of short interval between OS and, **I:194**
- soft, **I:114**
- splitting during expiration, **I:114**
- S₃, I:117**
 - timing and production mechanism, **I:121**
- S₄, I:117**
 - disappearance, **I:122**
 - gallop, **I:166**
 - intensity, and CHF, **I:123**
 - timing and production mechanism, **I:121**
- special positions and maneuvers for optimal auscultation, **I:102**
- systolic and diastolic normal, **I:120**
- of valvular origin, **I:134**
- Heartburn, **I:363**
 - in achalasia patient, **I:373**
 - definition, **I:376**
- Heat cramps, **II:143**
- Heat exhaustion, **II:143**
- Heat stroke, **II:144**
- Heberden's nodes, **II:516, 518, 586**
- Heel-knee-shin test, **II:166**
- Heel-shin test, **II:166, 170**
- Heinz bodies, **I:618**
- Helicobacter pylori* infection, **I:408**
 - of gastric body, **I:404**
 - gastric maltoma non-response to eradication, **I:438**
 - MALT associated with, **I:468**
- HELLP syndrome, focused physical examination for, **I:523**
- Hemangioma, **I:536**
 - cavernous, **I:443**
- Hematologic malignancies, and liver involvement, **I:585**
- Hematology
 - exam questions, **I:xxix, 599**
 - practice case scenarios, **I:634**
 - red blood cells, **I:613–621**
 - white blood cells, **I:621–625**
- Hematopoietic cell transplantation (HCT), **I:503–504**
 - early causes of anorexia and vomiting, **I:593**
 - GI complications, **I:575**
- Hemianopia
 - binasal, **II:44**
 - bitemporal, **II:40**
 - causes, **II:44**
 - homonymous



- causes, **II:44**
- with macular sparing, **II:40**
- Hemiballismus, **II:292**
- Hemiplegia
 - crossed, **II:157–158, 174**
 - causes, **II:34, 212**
 - false-localizing sign for, **II:156**
 - forms, **II:155**
 - internal capsule lesion vs. brainstem lesion causing, **II:34**
 - spastic, gait in, **II:273**
 - UMN-associated, **II:111**
- Hemochromatosis, hereditary, **I:543**
- Hemolytic anemia, directed history for causes, **I:618–620**
- Hemolytic jaundice, **I:546**
- Hemoptysis, directed history for, **II:392**
- Hemorrhage
 - conjunctival, **II:83**
 - pulmonary, chest examination techniques in, **II:382**
 - retinal. *See* Retinal hemorrhage
 - splinter, in fever of unknown origin, **II:630**
 - subarachnoid. *See* Subarachnoid hemorrhage
 - subconjunctival, **II:83**
- Hemorrhagic colitis, antibiotic for, **I:490**
- Hemosuccus pancreaticus, **I:564**
- Henoch-Schölein purpura, **I:581, 582**
- Hepatic bruit, **I:524**
- Hepatic calcification, causes of radiological, **I:552–553**
- Hepatic granulomas, as sarcoidosis complication, **I:540**
- Hepatic hemangioma, **I:538**
- Hepatic mass, **I:536–538**
- Hepatitis, automimmune, **I:541**
- Hepatitis A virus (HAV), **I:535**
- Hepatitis B virus (HBV), **I:534, 535**
 - in AIDS patients, **I:570**
- Hepatitis C virus (HCV), **I:534–535**
 - interaction with HIV, **I:571**
 - lichen planus associated with, **I:543**
- Hepatitis D virus (HDV), **I:535**
- Hepatitis E virus (HEV), **I:535**
- Hepatocellular cancer (HCC), **I:524–528**
 - paraneoplastic syndromes associated with, **I:524**
 - risk factors, **I:525**
 - screening and diagnosis, **I:526–527**
- Hepatocellular disease, palpable spleen in, **I:630**
- Hepato-jugular reflex, **I:85**



- Hepatomegaly
 in fever of unknown origin, **II**:630
 in returned traveler, **II**:637
 splenomegaly and, **I**:632
- Hepatorenal syndrome (HRS), **I**:521
- Hepatosplenic T cell lymphoma, **I**:585
- Hepatosplenomegaly, **I**:510–513
 causes, **I**:510
 focused physical examination for, **I**:511
- Hereditary angioedema (HA), **I**:451
- Hereditary hemochromatosis, **I**:543
- Hereditary hemorrhagic telangiectasia (HHT), **I**:411
 vs. angiectasia, **I**:415
- Hereditary nonpolyposis colorectal cancer (HNPCC), **I**:494
- Hereditary peroneal muscular neuropathy, **II**:241
 Charcot-Marie-Tooth disease in, **II**:239
- Hernia/Herniation
 abdominal, **I**:428
 hiatal, of esophagus, **I**:381
 lumbar spine disc, **II**:548–549
 uncus, **II**:159–160
- Herpes simplex virus (HSV), vs. CMV esophagitis, **I**:390
- Heterochromia, in Horner's syndrome, **II**:49
- Heubner's artery, **II**:30
- Heyde syndrome, **I**:477
- 5-HIAA, tryptophan metabolism to, **I**:459
- Hiatus hernia, of esophagus, and GERD, **I**:381
- High stepped gait, **II**:267, 271. *See also* Foot drop
- Higher-resolution esophageal pressure (HREP) manometry, **I**:385–386
- Highly active antiretroviral therapy (HAART), for HIV, **I**:569
- Hill's sign, **I**:203, 208
- Hinchey grading system, **I**:493
- Hip, **II**:550–553
 abnormal articular findings in, **II**:512–513
 examination of, compensatory postures seen in, **II**:550
 maneuvers, **II**:551
 internal and external rotation, **II**:553
 normal range of motion, **II**:515, 551, 552
 pain in, **II**:550, 551
 physical examination for, **II**:507
 in systemic lupus erythematosus, **II**:599
- Hirschprung disease, **I**:478, 542
- Hirsutism, **I**:340
- Histoplasmosis, **I**:572
- History of present issue (HPI), **II**:644



- HIV/AIDS, **I**:569–570
- diarrhea causes in, **I**:572
 - drug-induced liver injury, **I**:573
 - eosinophilic folliculitis in, **II**:646
 - esophagus involvement, **I**:570
 - HCV interaction with, **I**:571
 - infectious organisms leading to fulminant colitis, **I**:492
- Hodgkin lymphomas, **I**:436, 585
- hepatic involvement, **I**:527
- Hoffman finger flexion reflexes, **II**:208
- Holiday heart syndrome, **I**:82
- Holmes' rebound phenomenon, in cerebellar disorders, **II**:164
- Holmes-Adie pupil, focused physical examination for, **II**:63, 64
- Homocystinuria, **I**:20
- and Marfan syndrome distinguished, **II**:621
- Homonymous hemianopia (HN). See Hemianopia, homonymous
- Homonymous quadrantanopia, **II**:40
- causes, **II**:44
- Hormone producing cancers, **I**:343
- Horner's syndrome, **II**:94, 371
- causes, **II**:58, 60
 - congenital
 - vs. acquired causes, **II**:49
 - and non-congenital distinguished, **II**:60
 - intermittent, **II**:60
 - ipsilateral, **II**:60
 - lesion localization in, **II**:59
 - neurological signs, **II**:58
 - non-neurological signs, **II**:58
 - oculosympathetic pathway in, **II**:95
 - physical examination for, **II**:57–58
 - signs and symptoms, **II**:58
 - translational neuroanatomy for, **II**:59
- Hospitalization
- of congestive heart failure patient, **I**:27, 31
 - of pneumonia patient, criteria for, **II**:418
- Hover sign, **I**:425
- Howel-Evans syndrome, **I**:400
- Howell-Jolly bodies, **I**:617
- Huebner's artery, obstruction of, **II**:335
- Hughlings Jackson syndrome, **II**:129
- Human papillomavirus (HPV), **I**:572
- endoscopic finding of esophagitis, **I**:389
- Hydrocephalus, **II**:346
- Hydromyelia



- clinical features, **II**:200
- physical examination for, **II**:214–215
 - and syringomyelia differentiated, **II**:199
- Hyperaldosteronism, effects of salt intake in, **I**:647
- Hyperalgesia, **I**:422
- Hyperbilirubinemia, **I**:531
- Hypercalcemia, directed history for causes, **I**:327–328
- Hypercapnia (increased PaO₂), categorization of, **II**:455
- Hypercapnic respiratory failure
 - causes, **II**:454
 - physical examination for, **II**:456–457
- Hyperchlorhydria, from mastocytosis, **I**:404
- Hyperdynamic circulation, mechanisms causing, **I**:519
- Hypergastrinemia, **I**:405
- Hyperglucagonemia, **I**:555
- Hyperinflation, radiographic findings in chest, **II**:472
- Hyperkinetic apical movement, **I**:190
- Hyperkinetic arterial pulse, **I**:190
- Hyperkinetic heart syndrome, physical examination for, **I**:86–87
- Hyperkinetic pulse, **I**:74, 75
 - vs. pulsus parvus et tardus, **I**:77
- Hyperlipidemia, **I**:322–326
 - directed history to determine causes of secondary, **I**:322–323, 324
- Hypermobile joints
 - causes, **II**:613
 - in Marfan syndrome, **II**:617
- Hypernatremia, **I**:670
 - development in gastric outlet obstruction, **I**:441
 - focused physical examination for, **I**:671
- Hyperosmolar non-ketotic coma (HONC), **I**:280
 - focused physical examination for differentiating diabetic ketoacidosis and, **I**:282
- Hyperparathyroidism, **I**:631
 - neurological changes associated with, **I**:335, **II**:67
 - radiological signs, **I**:335, **II**:622
- Hyperpigmentation, focused physical examination for disorders associated with, **I**:316
- Hyperpnea. *See* Hyperventilation
- Hyperresonance (percussion note), **II**:403
- Hypersensitivity pneumonitis. *See* Extrinsic allergic alveolitis
- Hypersplenism, causes, **I**:625
- Hypertension, **I**:639–647
 - benign intracranial, **II**:229, 253–254
 - and coarctation of aorta, **I**:225
 - directed history for causes, **I**:641–642



- physical examination for
 - directed, **I**:640–641, 645–646
 - of heart, **I**:644
- portal. *See* Portal hypertension
- pseudohypertension vs. pseudohypotension, **I**:647
- pulmonary. *See* Pulmonary hypertension
- Hypertensive retinopathy
 - complications, **II**:45
 - focused physical examination of fundus for, **II**:44–45
- Hypertensive vertigo, **II**:112
- Hyperthyroidism
 - causes, **I**:306–307, 312–313
 - complications, **I**:311–312
 - focused physical examination for, **I**:308–310
 - in MEN-1-ZES, parathyroidectomy for, **I**:407
 - performance characteristics of physical findings, **I**:310
 - Wayne index for, **I**:312
- Hypertonicity, of LMN and UMN lesions, **II**:19
- Hypertrophic cardiomyopathy, **I**:128
 - characteristics of physical examination for detecting, **I**:163
 - complications, **I**:184
 - heart murmurs, **I**:134
 - physical examination for, **I**:209–210
 - distinguishing murmur from aortic stenosis, **I**:162
- Hypertrophic obstructive cardiomyopathy (HOCM), complications, **I**:163
- Hypertrophic pulmonary osteoarthropathy (HPO), **II**:407, 408
 - clubbing vs., **II**:407
 - physical findings in, **II**:409
- Hypertrophy, retinal pigment epithelial, **II**:47
- Hyperuricemia, causes, **II**:564
 - secondary hyperuricemia, **I**:333–334
- Hyperventilation, **II**:373, 374
 - physical examination for, **II**:456–457
- Hyphema, vs. hypopyon, **II**:91
- Hypoadrenalism
 - directed history for causes, **I**:315
 - focused physical examination for, **I**:317
- Hypocalcemia
 - correcting, **I**:566
 - directed history for causes, **I**:327–328
- Hypochloremic metabolic alkalosis, development in gastric outlet obstruction, **I**:441
- Hypochlorhydria, in VIPoma syndrome, **I**:558
- Hypochromic anemia
 - causes, **I**:618



- microcytic, **I**:621
- Hypoglossal nerve (CN XII), **II**:33, 118
 - defects and lesions of, disorders associated with, **II**:118–119
 - jugular foramen syndrome and, **II**:119, 129
- Hypoglycemia, **I**:284–287
 - complications, **I**:286
 - directed history and focused physical examination for, **I**:285–286
- Hypokalemia
 - causes, **I**:672
 - development in gastric outlet obstruction, **I**:441
 - symptoms, **I**:638
 - in VIPoma syndrome, **I**:558
- Hyponatremia, **I**:522, 665–667
- Hypoparathyroidism
 - causes, **I**:328–329
 - serum calcium and phosphate concentrations and, **I**:334
- Hypopituitarism, causes, **I**:340–341
- Hypopyon, hyphema vs., **II**:91
- Hypotension
 - orthostatic, **I**:63–66
 - performance characteristics, **I**:66, 416
- Hypothalamus
 - anatomy, **II**:141–142
 - disease
 - causes, **II**:142
 - directed history for, **II**:142
 - physical examination for, **II**:143
- Hypothyroidism, **I**:299–306
 - "best" clinical tests for, **I**:280
 - Billewicz diagnostic index, **I**:305
 - causes, **I**:301, 304–305
 - constipation in, **I**:480
 - focused physical examination for, **I**:302–303
 - performance characteristics, **I**:304
 - from pituitary failure vs. failure of thyroid, **I**:291
 - subclinical, **I**:300
 - systematic approach to causes, **I**:306
 - thinning of eyebrows, **I**:294
 - thyroid-stimulating hormone as indicator, **I**:300
- Hypoventilation
 - hypercapnia and. *See* Hypercapnic respiratory failure
 - hypoxemia caused by, **II**:462
- Hypovolemia, **I**:63–66, 664, 668–669
 - physical examination for, **I**:416, 664
 - directed, **I**:65



- Hypovolemic shock, causes, **I**:64, 65
 Hypoxemia, causes of, **II**:461–462
 Hysterical anesthesia, physical examination for, **II**:237
- I**
- ICU-type patient, GI complications, **I**:590–591
 Idiopathic autonomic neuropathy, GI complications, **I**:588
 Idiopathic intrahepatic cholestasis (IIC) syndrome, **I**:527
 Idiopathic subaortic stenosis, **I**:163
 IHC stains, for distinguishing GISTs, leiomyosarcomas, and schwannomas, **I**:458
- Illusion. hallucination vs., **II**:343
 Immune defects, bronchiectasis and, **II**:464
 Immune reconstitution syndrome, **I**:572
 Immune-suppressed patient, black esophagus in, **I**:389
 Immunization, for influenza, recommended recipients, **II**:424–425
 Immunodeficiency, **I**:561
 Immunoglobulins, **I**:633–634
 deficiency, approach to causes, **I**:630
 Immunoproliferative small intestinal disease (IPSID), **I**:456, 468
 Immunosuppression, **I**:487
 Impingement syndrome, **II**:534
 Incontinence
 fecal, **I**:478
 urinary, causes in elderly, **II**:636
 Increased intracranial pressure
 headache/facial pain associated with, **II**:136
 history and physical examination for, **II**:155–156
 translational neuroanatomy and, **II**:156
 Infants, cyanotic heart disease causes, **I**:265
 Infarction
 cerebral, **II**:333
 circulation syndromes, classification of, **II**:330
 lacunar syndrome. See Lacunar infarction syndrome (LACS)
 myocardial. See Myocardial infarction (MI)
 pulmonary. See Pulmonary infarction
 Infective endocarditis. See Bacterial endocarditis
 Inferior vena cava, obstruction, vs. portal hypertension, **I**:513
 Inflammation of joints, features of, **II**:616–617
 Inflammatory bowel disease, **I**:485
 Inflammatory polyradiculoneuropathy, physical examination for, **II**:244
 Influenza, **II**:424–425
 Infracristal ventricular septal defect, **I**:249, 263
 Inhibitory ganglion nerve (IGN), achalasia in loss, **I**:372
 Innervation, of muscles, **II**:218–220



- of hand, physical examination for, **II**:226
- segmental, **II**:218, 222–223
- Inotropes, negative, **I**:26
- Insomnia, **II**:359
- Instrumental activities of daily living (IADL), **II**:305, 510
- Insulin resistance, **I**:509
- Insulinoma
 - common clinical presentations, **I**:553
 - test sensitivity for detecting, **I**:559
- Intention tremor, **II**:294, 296
 - in cerebellar disorders, **II**:164, 170
- Interferon, **I**:515
- Internal carotid artery (ICA)
 - cerebral occlusion location, neurological examination for, **II**:323
 - in common stroke syndromes, **II**:319
 - occlusion, **II**:317
- Internal jugular vein, distinguishing from external, **I**:36
- International Diabetes Federation, classification of metabolic syndrome, **I**:325
- Internuclear ophthalmoplegia, **II**:92
- Interosseous nerve branches, in hand, **II**:524
- Interphalangeal depth ratio, in clubbing, **II**:405–406
- Interphalangeal joint (IP)
 - deformities, **II**:519
 - movements, **II**:522
 - normal range of motion, **II**:525
- Interstitial renal fibrosis, causes, **I**:653
- Intervertebral disk, prolapsed/protruded
 - nerve roots affected by, **II**:200
 - physical examination for, **II**:182–183
 - upper motor neuron and, **II**:230
- Intestinal lymphangiectasias, **I**:466
- Intra-abdominal abscess (IAA), **I**:431–432
 - diagnostic imaging findings, **I**:432
- Intracranial hypertension, benign, causes, **II**:353–354
 - physical examination for, **II**:229
- Intracranial pressure
 - cranial nerve involvement and, **II**:90
 - increased. See Increased intracranial pressure
- Intraductal papillary mucinous neoplasm (IPMN), **I**:556
- Intramedullary cord lesion, focused physical examination for, **II**:31
- Inverted knee reflex, **II**:208
- Involuntary movements, **II**:266–267, 278–298
 - physical examination for, **II**:295
- Iodine deficiency
 - complications, **I**:566



hypothyroidism and, **I**:301
 Iritis, acute, **II**:83
 Irregular pulse, distinguishing between causes, **I**:91
 Irritable bowel syndrome (IBS), **I**:495
 avoiding narcotics and benzodiazepines in, **I**:430
 diagnostic criteria, **I**:486
 mesalazine for, **I**:488
 probiotics and, **I**:489
 symptoms that cannot be explained by, **I**:486–487
 visceral pain transmission to CNS, **I**:422
 Ischemia, **I**:485
 chronic vs. acute, **I**:59
 mesenteric, **I**:445–446
 Ischemic colitis, IBS associated with, **I**:489
 Ischemic heart disease (IHD), causes, **I**:51
 Ischemic stroke, risk for, **II**:320–321
Isospora, in small bowel biopsy, **I**:467

J

Jacksonian epilepsy, **II**:302
 Janeway lesions, **I**:235, **II**:586
 Jaundice, **I**:523, 531, 532–533
 hemolytic, **I**:546
 in returned traveler, **II**:637
 Jaw, in fever of unknown origin, **II**:630
 Jaw jerk, **II**:97
 in loss of corticospinal inhibition, **II**:208
 translational anatomy, **II**:98
 Jejunal aspirate (JA), **I**:453–454
 Jellink sign, **I**:314
 Jendrassik's sign, **I**:291, 314
 "Jobe" (supraspinatus) test, **II**:537
 Joffroy's sign, **I**:291, 314
 Joints. *See also individually named joints*
 abnormal articular findings in, **II**:510–513
 in fever of unknown origin, **II**:630
 hypermobile, causes, **II**:613
 inflammation of, features, **II**:616–617
 normal range of motion, **II**:514–515
 physical examination for, **II**:505–507
 upper motor neuron disease and, physical examination for, **II**:218–220
 Jones criteria, for rheumatic fever diagnosis, **I**:146–147
 Jugular foramen syndrome
 directed history for, **II**:120–121
 hypoglossal nerve (CN XII) and, **II**:119



- physical examination for, **II**:120–121
- UMN vs. LMN lesions in, distinguished, **II**:120
- Jugular vein
 - distended, **I**:85
 - distinguishing external from internal, **I**:36
- Jugular venous pulse (JVP), **I**:19, 35, 36–44
 - elevation
 - causes, **I**:39
 - due to superior vena caval obstruction, **I**:214
 - physical examination for causes, **I**:20–21
 - evaluation, **I**:34
 - normal range, **I**:36
 - physical examination
 - to distinguish between carotid artery pulse and, **I**:218
 - to distinguish between carotid waveforms and, **I**:43
 - physiology of ascents and descents, **I**:38
- Jump sign, **I**:425
- Juvenile chronic arthritis, **II**:587

K

- Kaposi sarcoma, **I**:573
- KARMEL mnemonic, **I**:675
- Kartagener's syndrome, **I**:261
 - bronchiectasis in, **II**:464
- Kehr sign, **I**:426
- Keratitis vs. conjunctivitis, differentiating between, **II**:85
- Kernig's sign, **II**:345
- "Key grip," **II**:522
- Kidney. *See also* Renal *entries*
 - acute failure
 - directed history for causes, **I**:654–655
 - physical examination for causes, **I**:655–656
 - autosomal dominant polycystic kidney disease, **I**:677
 - basic details, **I**:638–639
 - chronic failure, **I**:590
 - atherosclerotic disease and, **I**:42
 - causes, **I**:653–654
 - definition, **I**:663
 - directed history for causes, **I**:656–657
 - focused physical examination for, **I**:658–660
 - medications to avoid in late stage, **I**:660–661
 - risk factors, **I**:661–662
 - stages, **I**:660
 - GI drugs in impairment, **I**:649
 - renal calculi, **I**:648–649



unilateral palpable disease, **I:677**
 unusual features of postoperative transplant, **I:575**
 Kinetic tremor, **II:294, 296–297**
 Klinefelter syndrome, **I:20**
 Knee, **II:554–560**
 abnormal articular findings in, **II:513**
 fracture
 Ottawa rule for, **II:559–560**
 performance characteristics for, **II:559**
 normal range of motion, **II:515**
 osteoarthritis
 "best" clinical tests for, **II:556**
 performance characteristics for, **II:560**
 pain in, causes, **II:554**
 physical examination for, **II:507, 555–556**
 Knee jerks
 absent, **II:363**
 in cerebellar disorders, **II:170**
 Knie sign, **I:314**
 Knobbly liver with umbilication, **I:546**
 Knock, vs. other heart sounds, **I:125**
 Kocher sign, **I:313**
 Kohlmeier-Degos disease, **I:582**
 Krönig's isthmus, **II:370–371**
 Kupffer cell, erythrophagocytosis in, **I:586**
 Kussmaul breathing, **I:22, II:371, 373**
 Kussmaul's sign, **I:22, 37, 41, 218**
 Kyphoscoliosis, causes, **II:547**

L

L DOCC SPARC CIP mnemonic, **II:644**
 Labrum lesion, of shoulder, **II:534, 541**
 Labyrinth disease, physical examination for, **II:112**
 Lachman's sign, **II:558, 559**
 Lactic acidosis, **I:573**
 directed history for causes, **I:670–671**
 Lactulose hydrogen breath test, pathogenesis of double peak, **I:454**
 Lacunar infarction syndrome (LACS), **II:333**
 in stroke, **II:330–331**
 Landolfi's sign, **I:202**
 Laryngocele, demonstrating, **I:151, 292**
 Lasègue's sign, **II:343**
 Lateral epicondylitis, elbow in, **II:532**
 Lateral medulla, of brain
 ischemic event involving, physical examination for, **II:153**



- lesion of, dissociated anesthesia and, **II:185**
- Lateral medullary syndrome (LMS), **II:176**
 - lesion location in, **II:161**
 - physical examination for, **II:158–159**
- Laxatives, **I:482**
 - abuse, **I:484**
- Left anterior descending artery (LAD), vs. right coronary artery, **I:50**
- Left bundle branch block (LBBB), vs. RBBB, **I:114**
- Left-sided congestive heart failure (L-CHF)
 - causes, **I:24**
 - diagnosis, **I:29**
 - physical examination to distinguish between R-CHF and, **I:32–33**
- Leg
 - cyanosis, **I:224**
 - edema
 - cause in lower leg, **I:67**
 - causes of bilateral, **I:68**
 - length of, true vs. apparent, **II:618**
 - LMN signs in, causes, **II:238**
 - peripheral nerves of, sensory branches, **II:221**
 - physical examination to determine cause of pain, **I:55**
 - segmental innervation of muscles, **II:218, 223**
 - swelling/tenderness of, in fever of unknown origin, **II:630**
 - in systemic lupus erythematosus, **II:599**
 - ulcers
 - directed history for, **I:56**
 - physical examination for, **II:619–620**
- Leiomyoma, **I:439**
- Leiomyosarcomas, IHC stains for distinguishing, **I:458**
- Leptomeningeal lesions, **II:346**
- Leptospirosis, **I:543**
- Leukemia, **I:560, 585**
 - GI tract involvement, **I:561**
- Leukocytosis, causes, **I:623**
- Leukonychia, **I:519, 529**
- Levoversion, **I:265**
 - physical examination to distinguish between dextrocardia, situs inversus and dextroversion, **I:244**
- Lewy bodies, **I:372**
- Lichen planus, associated with HCV, **I:543**
- Lifestyle issues, directed history for, **II:644–645**
- Light, abnormal pupil reaction to, **II:61**
- Light reflex, **II:75**
 - absent in coma patients, **II:57**
 - corneal, **II:72, 97, 111**



- pupillary, **II**:92–93
- Light-colored spots, retinal, **II**:45–46
- Light-near dissociation (LND), **II**:65, 94
- Limb girdle muscular dystrophy, **II**:249, 253, 263
 - physical examination for, **II**:255
- Lipoma, **I**:439
- Lisch nodule, **II**:353
- Liver, **I**:498–543. *See also* Hepatic and Hepato- entries
 - alcohol abuse, **I**:498–501
 - assessing size, **I**:523
 - biopsy, **I**:586
 - changes in systemic infection, **I**:591
 - of jaundiced post-operative patient, **I**:531
 - drug-induced injury, in HIV-AIDS treatment, **I**:573
 - dysfunction in patients with systemic infections, **I**:591
 - hard knobbly, causes, **I**:512
 - hematologic malignancies involving, **I**:585
 - jaundice, **I**:523
 - palpable, **I**:511
 - causes, **I**:176
 - in primary amyloidosis, **I**:589
 - sarcoidosis features on biopsy, **I**:540–541
 - transplantation, **I**:502
- Liver disease
 - acute and chronic, **I**:513–518
 - likelihood ratios for findings in, **I**:518–519
 - recurring after liver transplant, **I**:505
- Liver granulomas, **I**:538–541
 - causes, **I**:538–539
- LMN signs, in legs, causes, **II**:238
- "LOAF" muscles, innervation of, **II**:221
- Lobes
 - cerebral cortex, **II**:24
 - lung
 - disease sites in, **II**:471
 - surface anatomy for, **II**:399
 - X-ray view on inspiration, **II**:480
- Locally-acting laxatives, **I**:482
- Locked-in state, **II**:343
 - physical examination for, **II**:148
- Loeffler's syndrome, **II**:431
- Lower esophageal sphincter relaxation (LESR), **I**:379
 - drugs inducing transient, **I**:384
 - vs. LES, **I**:381
- Lower GI bleeding, **I**:473–477



- angiography, disadvantages, **I:476**
- predictors of severe, **I:474, 477**
- Lower limb
 - bilateral pyramidal lesion, **II:169**
 - compensatory postures in, **II:551**
 - movements of, myotomes and, **II:552**
- Lower motor neuron (LMN)
 - in facial weakness, **II:103**
 - false-localizing sign, **II:90**
 - lesions
 - abnormal tone and, **II:211**
 - anatomical basis for, **II:205**
 - common causes, **II:217**
 - physical examination for, **II:206**
 - motor pathway involvement, **II:19–20**
 - deep tendon reflexes, **II:19**
 - hypertonicity, **II:19**
 - UMN vs. LMN lesions, physical examination for determining, **II:19, 99–101, 110, 263**
 - and upper motor neuron compared, **II:204, 217**
- Lubricants, **I:482**
- Lumbar discs, compression of, **II:223–224**
- Lumbar spine, tests involving
 - for disc herniation, **II:548–549**
 - for vertebral fractures, **II:548**
- Lung. *See also* Pulmonary *entries*
 - abscess of, focused history for, **II:463**
 - base of, dullness at. *See* Dullness (percussion note), at lung base
 - carcinoma, **II:442–450**
 - causes, **II:442–443**
 - physical examination for, **II:446–447**
 - fibrosis. *See* Pulmonary fibrosis
 - lobes of, surface anatomy for, **II:399**
 - malignant tumour metastasis to, **II:447, 450**
 - radiographic views. *See* Chest X-ray
 - in systemic lupus erythematosus, **II:599**
 - transplantation, GI symptom after, **I:574**
- Lung cancer
 - metastasis, **I:551**
 - paraneoplastic syndromes from small cell, **I:403**
- Lung collapse, **II:392–404**
 - Brock's syndrome and, **II:423, 477**
 - causes, **II:397**
 - physical examination for, **II:394–395**
 - physical findings for, **II:400**



- radiographic findings in, **II**:472–473
 - Lung disease
 - breath sounds differentiating, **II**:217
 - case studies in, **II**:481–494
 - diffuse. See Pulmonary fibrosis
 - granulomatous, **II**:411–413
 - interstitial, late inspiratory crackles in, **II**:386
 - obstructive. See Chronic obstructive pulmonary disease (COPD);
Obstructive lung disease
 - occupational exposure causing, **II**:402
 - restrictive. See Restrictive lung disease
 - Lung sounds. See *also* Breath sounds
 - effect of pulmonary disease on, **II**:377
 - in normal lung, **II**:382
 - Lupus nephropathy, types, **I**:639
 - Lutembacher complex, **I**:262
 - Lutembacher's syndrome, **I**:193, 257
 - Lyme disease, **II**:553, 554
 - Lymph nodes
 - directed history and focused physical examination in neck/axilla, **I**:610, 612
 - drainage, **I**:608–610
 - generalized enlargement, **I**:605
 - of head, neck and axilla, **I**:606
 - Lymphocytic gastritis, **I**:443
 - Lymphadenopathy, **I**:604–605
 - ALL AGES mnemonic for approach to patient, **I**:611–612
 - causes, **I**:609–610
 - in fever of unknown origin, **II**:630
 - in returned traveler, **II**:637
 - regional, **I**:607
 - Lymphangiectasias, intestinal, **I**:466
 - Lymphedema, vs. venous edema, **I**:68
 - Lymphocytosis, **I**:624
 - Lymphomas, **I**:468–472
 - gastrointestinal, **I**:436
 - small bowel, **I**:454–457
 - classifying, **I**:456
 - Lymphoproliferative disorder, **I**:466
 - post-transplantation, **I**:457
- M**
- M band, causes, **I**:634
 - Machado-Joseph disease, **II**:292
 - Machinery murmur, **I**:208
 - Macrocytic anemia, causes, **I**:613



Macroglobulinemia, **I**:633
 Macula, blood supply to, **II**:43
 Macular degeneration, types of, **II**:48
 Magnetic resonance imaging (MRI), of head, **II**:357
 MAKE UP a List mnemonic, **II**:374
 Malabsorption, **I**:465–472
 Maladie de Roger, **I**:263
 Malaria, palpable spleen in, **I**:630
 Malignancy
 metastasis to lung and bone, **II**:447
 and polymyalgia rheumatica distinguished, **II**:610
 Malignant hypertension, **I**:639
 Malignant hypertensive emergency, **I**:643
 focused history for complications, **I**:646
 Malignant hyperthermia, **II**:144
 Mallet finger/thumb, **II**:516, 517, 519
 Mallory-Weiss (MW) syndrome, **I**:388
 bleeding from tear, **I**:408
 vs. Boerhaave syndrome, **I**:410
 Malnutrition, **I**:565–567
 pretest probability for presence, **I**:567
 MALT lymphoma (marginal T-cell lymphoma), **I**:468
 Mammary soufflé, **I**:142
 Manganese deficiency, complications, **I**:566
 Manometry, rectal, **I**:478
 MANTRELS mnemonic, **I**:424
 Marche à petits pas, **II**:291
 Marcus Gunn pupil, **II**:61, 64, 93
 translational neuroanatomy for, **II**:65
 Marfan syndrome, **I**:20, 151
 bronchiectasis in, **II**:464
 diagnosis, **II**:621
 and homocystinuria distinguished, **II**:621
 physical examination for, **II**:529, 617
 Marie-Bamberger syndrome, **II**:408
 Mastocytosis, **I**:406
 hyperchlorhydria from, **I**:404
 Maxinkonski's sign, **I**:256
 McBurney's point tenderness, **I**:423, 425
 McMurray test, **II**:555, 558
 Means-Lerman scratch sound, **I**:309
 Meckel diverticulum, rule of two's relating to, **I**:414
 Meckel's scan, for GI bleeding, **I**:475
 Medial lemniscus, **II**:35
 Medial longitudinal bundle, **II**:33



- Medial medulla, of brain, ischemic event involving, physical examination for, **II:154**
- Medial medullary syndrome, **II:161**
- Medial striate artery, **II:30**
- Median nerve
- compression in carpal tunnel, **II:227, 234**
 - defects of, and ulnar nerve defects distinguished, **II:231**
 - in hand, **II:524**
 - lesion, loss of pain sensation and, **II:240**
 - muscle innervation by, **II:221**
- Mediastinal compression, in lung cancer, physical examination for, **II:443–445**
- Mediastinal tumours, on X-ray, causes of, **II:474**
- Medulla
- anatomy, **II:139**
 - ischemic event involving, physical examination for, **II:153**
 - lesion, **II:161**
 - pyramidal fibers and, **II:155**
 - tracts in, **II:168**
- Medullary syndromes, medial, **II:141**
- Mees lines, **I:529**
- Megaloblastic anemia, in gluten sensitive enteropathy, **I:471**
- MELD score, for predicting mortality rate after liver transplant, **I:502**
- Melena, **I:410**
- Melkersson-Rosenthal (MR) syndrome, **I:451**
- Ménétrier's disease, **I:441, 442**
- Meningeal irritation, and sciatic nerve lesion distinguished, physical examination for, **II:343**
- Meningitis
- headache/facial pain in, **II:133, 136**
 - physical examination for, **II:344**
 - subarachnoid hemorrhage and, **II:345–347**
- Meniscal tests, **II:555–556**
- MEN-1-ZES, proton pump inhibitors impact in, **I:405**
- Mesalazine, for irritable bowel syndrome, **I:488**
- Mesenteric ischemia, **I:445–446**
- Mesenteroaxil volvulus, **I:378**
- Metabolic acidosis, **I:674–675, 676**
- Metabolic alkalosis, **I:675, 676, 680**
- Metabolic bone disease, **I:326–335**
- causes, **I:332**
- Metabolic syndrome, International Diabetes Federation classification, **I:325**
- Metacarpophalangeal joint (MCP)
- movements, **II:522**
 - normal range of motion, **II:525**



- Metaplasia, **I**:368
- Methemoglobinemia, **II**:387
- Microaneurysms, retinal artery, causes, **II**:72
- Microangiopathic antiphospholipid-associated disorder, **I**:485
- Micronutrient deficiencies, complications, **I**:566
- Midbrain
 - anatomy, **II**:138–139
 - ischemic event involving, physical examination for, **II**:152
 - pyramidal fibers and, **II**:155
- Mid-diastolic murmur, **I**:193
- Middle cerebral artery (MCA), **II**:30
 - cerebral occlusion location, neurological examination for, **II**:323
 - in common stroke syndromes, **II**:319
 - ischemia of, physical examination for, **II**:319–320
 - lesion of, upper and lower body effects, **II**:361
 - occlusion, **II**:30
- Midfoot fracture
 - "best" clinical test for, **II**:568
 - performance characteristics, **II**:562
- Midsystolic murmurs, **I**:134
- Migraine
 - with aura, **II**:135
 - types, **II**:133
 - without aura, **II**:136
- Migratory arthralgia, causes of, **II**:565
- Miliary mottling, **II**:477
- Milkman fracture, **II**:584
- Millard-Gubler syndrome, **II**:89, 174
- Milroy's disease, **I**:67
- Mini-mental test for confusion, **II**:337
- Miosis
 - causes, **II**:41
 - in Horner's syndrome, **II**:57
- Mirizzi syndrome, **I**:547
- Mitral facies, **I**:148
- Mitral murmur
 - absence, and mitral regurgitation, **I**:184
 - diastolic, ventricular septal defect and, **I**:263
- Mitral opening snap, vs. split P₂, **I**:122
- Mitral regurgitation, **I**:128, 134, 168–174
 - causes, **I**:171, 173–174
 - characteristics, **I**:173
 - diagnosis, **I**:182
 - in absence of murmur, **I**:170
 - cardiac phases for, **I**:202



- from dysfunctional papillary muscle, **I:169**
- focused physical examination for
 - distinguishing between tricuspid regurgitation murmur and, **I:174**
 - in severity assessment, **I:170, 173**
- mitral area murmur absence and, **I:184**
- vs. mitral valve prolapse or papillary muscle dysfunction, **I:183**
- murmurs, **I:181**
 - vs. murmur of aortic stenosis with calcification, **I:180**
 - physical examination for severity, **I:186**
- physical examination for, **I:168, 172**
- severity assessment, **I:181**
 - cardiac phases for, **I:202**
 - focused physical examination in, **I:170**
- Mitral stenosis, **I:135, 187, 188–196**
 - causes, **I:193**
 - diastolic murmurs, **I:195**
 - murmur simulating, causes of, **I:193**
 - performance characteristics of other cardiac findings in, **I:190**
 - physical examination for, **I:190**
 - pregnancy effect on, **I:195**
 - severe, findings suggesting, **I:194**
 - tapping apex beat in, **I:192, 193**
- Mitral valve
 - normal area, **I:189**
 - prosthetic, **I:165**
- Mitral valve disease
 - causes of aortic valve disease combined with, **I:160**
 - combined with aortic disease, **I:157**
- Mitral valve myxoma, **I:118**
- Mitral valve prolapse (MVP), **I:128, 134, 177, 179–180, 184**
 - vs. mitral regurgitation or papillary muscle dysfunction, **I:183**
- Mixed connective tissue damage (MCTD), **I:580, 581**
- Mixed cryoglobulinemia, **I:583**
- Möbius sign, **I:291, 314**
- Möbius syndrome, **II:89**
- Modified Duke Criteria
 - bacterial endocarditis definition according to, **I:235–237**
 - for infective endocarditis diagnosis, **I:243**
- Monocytosis, causes, **I:623**
- Mononeuritis multiplex, **II:234, 236**
 - causes, **II:238, 246**
 - conditions causing, **II:244**
- Moon facies, **I:322**
- Mortality rate predictors
 - after liver transplant, MELD score for, **I:502**



- from lower GI bleed, **I:473–474**
- in pneumonia, **II:418, 421**
- Moschcowitz's syndrome, **I:632**
- Motor cortex, **II:24, 25**
 - disease detection in, focused physical examination for, **II:25–26**
- Motor defect, physical examination for pathology site, **II:326**
- Motor function
 - in cerebellar disorders, **II:164**
 - in spinal cord compression, **II:196–197**
- Motor lesions, localizing features of, **II:326**
- Motor neuron
 - lower. See Lower motor neuron (LMN)
 - upper. See Upper motor neuron (UMN)
- Motor neuron damage/disease (MND), **II:260–266**. See also Bulbar palsy; Pseudobulbar palsy
 - clinical features, **II:248**
 - LMN vs. UMN lesions, physical examination for determining, **II:19**
 - physical examination for, **II:261**
 - in adult, **II:265**
 - UMN nerve root disease, physical examination for, **II:218–220**
- Motor neuropathy, causes of, **II:245**
 - physical examination for, **II:504**
- Mottling, on chest X-ray, **II:477**
- Mouth
 - focused physical examination for, **I:353–355**
 - pigmented lesions, **I:357**
 - causes, **I:356**
 - visual examination, **II:364**
- Movement
 - abnormalities, **II:266**
 - disorders, **II:266–267**
 - physical examination, **II:268–269**
- Mucosa associated lymphoid tissue, **I:436–437**
- Muehrcke's lines, **I:528**
- Mueller's sign, **I:208, II:363**
- Multiple endocrine neoplasia (MEN-1), carcinoid tumours associated with, **I:469**
- Multiple myeloma, **I:585, 633**
- Multiple sclerosis (MS), **II:350–352**
 - and constipation, **I:481**
 - GI symptoms, **I:587**
 - prognostic markers for, **II:351**
- Multiple system atrophy (MSA), **II:289**
- Murphy's sign, **I:544**
- Muscle(s)



- innervation, **II**:177, 218–220
 - by median nerve, **II**:221
 - segmental
 - of arm, **II**:218, 222
 - of leg, **II**:218, 223
 - by ulnar nerve, **II**:221
- movement from, **II**:177
- stretch reflex. *See* Stretch reflexes, of muscle
- wasting. *See* Muscle wasting/weakness
- Muscle cramps, **II**:257
- Muscle disease, **II**:248–256. *See also individually named diseases*;
 - Neuromuscular disease
 - classification, **II**:249–250
 - definitions used in, **II**:249
 - neuromuscular causes of weakness in, **II**:262
 - physical examination for, **II**:249
- Muscle wasting/weakness
 - characteristic gaits in, **II**:276
 - disorders causing, **II**:18
 - distribution, **II**:147, 247, 251
 - in fever of unknown origin, **II**:630
 - of gluteal muscles, physical examination for, **II**:554
 - in hand
 - causes, **II**:515
 - physical examination for, **II**:224–225
- Muscular atrophy, peroneal, **II**:220
- Muscular dystrophy
 - classification, **II**:253
 - forms, **II**:249, 262–263
 - motility disorders, **I**:587
 - myocardial involvement, **I**:160
 - oropharyngeal dysphagia in, **I**:364
 - physical examination for, **II**:254–255
- Muscular neuropathy, peroneal
 - Charcot-Marie-Tooth disease in, **II**:239
 - hereditary, **II**:241
- Musculoskeletal (MSK) system. *See also individually named joints*; Joints
 - abnormal physical findings in, definitions, **II**:502–503
 - disorder
 - deformities associated with, **II**:519–521
 - directed history for, **II**:502
- Myasthenia gravis, **II**:258–260
 - clinical features, **II**:248
 - and Eaton-Lambert syndrome differentiation, **II**:259
 - motility disorders, **I**:587



- oropharyngeal dysphagia in, **I:364**
- other conditions mimicked by, **II:260**
- physical examination for, **II:258–259**
- Myasthenic crisis, **II:260, 353**
- Myelitis, transverse. *See* Transverse myelitis
- Myelofibrosis, with myeloid metaplasia, **I:624**
- Myeloid disorders, chronic, **I:625**
- Myeloid leukamoid reaction, causes, **I:623–624**
- Myeloid metaplasia, vs. extramedullary hematopoiesis, **I:624**
- Myelopathy, cervical, **II:195**
- Myocardial disease, abnormal diastolic function in, **I:212**
- Myocardial infarction (MI)
 - clinical features increasing probability, **I:52**
 - ECG for, vs. pericardial effusion, **I:222**
 - NSTEMI (non-ST segment elevation), **I:44**
 - rare coronary artery causes, **I:46**
- Myoclonic seizures, **II:29**
- Myoclonus, **II:16, 267, 294**
- Myopathy
 - acquired, **II:262**
 - proximal. *See* Proximal myopathy
 - secondary, **II:250**
- Myositis, **II:250**
 - and polymyalgia rheumatica distinguished, **II:610**
- Myotomes
 - cervical spine movements and, **II:176, 546**
 - distribution, muscle groups for testing, **II:177**
 - lower limb movements and, **II:552**
 - upper limb movements and, **II:514**
- Myotonic dystrophy, **II:254**
 - clinical features, **II:248, 256**
 - oropharyngeal dysphagia in, **I:364**
 - physical examination for, **II:251, 254**

N

- Nail pitting, **I:529**
- Narcotics, avoiding in FAP/IBS, **I:430**
- NAS (NAFLD activity score), **I:509**
- Nasogastric tube aspirate, **I:410**
- National Institutes of Health (NIH) stroke scale, **II:328–329**
- Nausea, **I:377–378**
- Near-light dissociation (NLD), **II:65**
- Neck
 - lymph nodes in, directed history and focused physical examination, **I:610, 612**



- masses in, pediatric vs. adult, **I:605**
- painful lumps, in fever of unknown origin, **II:630**
- stiffness, causes of, **II:344, 345, 346**
- veins in, performance characteristics of inspection, **I:39**
- "Neck compression test," **II:231**
- Necrolytic migratory erythema (NME), **I:555**
- Neer impingement sign, **II:537, 541**
- Nelson's syndrome, **I:321**
- Neocerebellum, in ataxia, **II:169**
- Nephritis, acute interstitial, **I:651–653**
- Nephrocalcinosis, causes of radiologically visible, **I:650–651**
- Nephrology
 - exam questions, **I:xxix–xxx, 637**
 - practice case scenarios, **I:680**
- Nephrotic syndrome, **I:650–651**
- Nerve compression
 - brachial plexus lesion vs., **II:228**
 - at lumbosacral spine, **II:191**
- Nerve entrapment syndromes, **II:182**
- Nerve root disease, symptom of, **II:232**
- Nerve roots, spinal cord, **II:171–198**
 - C5–T1 damage, physical examination for, **II:224**
 - lesion characteristics, **II:177–178**
 - lesion localization, **II:171–172, 175**
 - meningeal root and meningeal irritation distinguished, physical examination for, **II:343**
 - muscle innervation and, **II:218–220**
 - upper motor neuron disease and, physical examination for, **II:218–220**
- Nerves
 - in spinal cord
 - motor pathway for, **II:18**
 - sensory pathway for, **II:18**
 - thickened, causes, **II:245**
- Nervous system
 - autonomic, **II:237**
 - central. See Central nervous system (CNS)
 - focused physical examination, **II:21**
 - hepatic encephalopathy impact, **I:519**
 - peripheral. See Peripheral nervous system (PNS)
- Neuritis
 - optic, causes, **II:70–71**
 - retrobulbar, and papilledema distinguished, **II:68**
- Neuroanatomy
 - CNS lesion localization, **II:17**
 - spinal cord, **II:17**



- motor and sensory pathways in, **II:18**
- translational, **II:35–37**
 - eye movement, **II:74–77**
- Neuroarthropathy, **II:611–612**. *See also* Charcot's joint
- Neuroendocrine tumours, **I:554–556**
 - common clinical presentations, **I:553**
 - gastrointestinal, **I:460–461**
- Neurofibromatosis, **II:353–354**
 - Lisch nodule in, **II:353**
- Neuroleptic malignant syndrome (NMS), **II:144**
 - differential diagnosis, **II:307**
 - physical examination for, **II:306–307**
- Neurological disorders
 - of CNS
 - directed history for, **II:23**
 - lesion localization for, **II:17**
 - physical examination for, **II:19**
 - remission/relapse, **II:154**
 - degenerative, achalasia associated with, **I:372**
 - of PNS, directed history for, **II:23**
- Neurological examination, **II:13, 22**
- Neurological history, **II:13, 22**
- Neurology, exam questions, **II:xvi–xxv, 3–12**
- Neuromuscular disease, **II:216–224, 248–257**. *See also individually named diseases; Muscle disease*
 - classification, **II:249–250**
 - clinical features, **II:248**
 - weakness in, common etiologies, **II:261**
- Neuromuscular junctions
 - diseases, **II:251**
 - weakness and, **II:262**
- Neuropathy
 - autonomic, **II:234, 237**
 - carcinomatous
 - physical examination for causes, **II:229**
 - types, **II:190**
 - hereditary peroneal muscular, **II:241**
 - motor, **II:245**
 - peripheral. *See* Peripheral neuropathy
- Neuropraxia, **II:232**
- Neurosyphilis, **II:358–359**
- Neurotmesis, **II:232**
- Neurotrophic ulcers, **I:56**
- Neutropenia, **I:622–623**
- Neutropenic enterocolitis, **I:548**



New York Heart Association, congestive heart failure functional classification, I:25

Niacin deficiency, I:469
 complications, I:566

Nixon method of splenomegaly detection, I:628

Nodular regenerative hyperplasia (NRH), I:527–528, 540, 543

Nodule, rheumatoid, gouty tophus vs., II:583

Nonalcoholic fatty liver disease (NAFLD)
 pathogenesis, I:508
 serum levels of ALT and AST, I:509

Non-Hodgkin lymphomas, I:436, 585

Non-sideropenic anemia, I:618

Non-ST segment elevation acute coronary syndrome, I:49

Non-ST segment elevation myocardial infarction (NSTEMI), I:44

Nonsteroidal antiinflammatory drugs (NSAIDs), side effects of, directed history for, II:508–510

Noonan's syndrome, I:159, 261

Norwalk virus, I:469

Nothnagel's syndrome, II:111

Nutcracker esophagus, I:377

Nutrition, I:565–568

Nystagmus/vertigo, II:86, 270
 causes, II:86, 116
 physical examination for, II:131
 in cerebellar disorders, II:164, 170
 forms, II:80
 lesion localization in, II:79, 95–96, 129–130
 phasic, II:132
 rotatory, II:132
 vertical, II:132
 vestibular, II:130

O

O to W mnemonic, for patient history, I:10–19

Obesity, I:283–284, 567–568
 alterations in serum vitamin levels, I:568
 and body mass index, I:568
 denial, I:321
 and esophageal cancer, I:394
 protein/calorie malnutrition, I:568
 risk of GERD, peptides link to, I:385

Objective standardized clinical examination (OSCE)
 exam questions
 cardiology, I:xvii–xxiii, 3–9
 endocrinology, I:xxiii–xxv, 273–274



- gastroenterology, I:xxv–xxix, 349–352
- hematology, I:xxix, 599
- miscellaneous, II:xxx, 629
- nephrology, I:xxix–xxx, 637
- neurology, II:xvi–xxv, 3–12
- respirology, II:xxv–xxvii, 367–369
- rheumatology, II:xxvii–xxx, 499–501
- practice case scenarios for
 - hematology, I:634
 - miscellaneous, I:594–595, II:495
 - nephrology, I:680
 - respirology, II:495
 - rheumatology, II:625
- Obstructive lung disease. *See also* Chronic obstructive pulmonary disease (COPD)
 - cor pulmonale caused by, II:450
 - results of pulmonary function tests in, II:436
- Obstructive sleep apnea, I:676, II:469–470
- Obturator sign, I:424
- Occipital lobe, disease detection in, directed history for, II:28
- Occipital seizures, II:299
- Occiput, migraine involving, II:133
- Occlusion
 - arterial
 - anterior spinal, II:179
 - in brainstem, II:161
 - cerebral, neurological examination for location, II:323–324
 - in common stroke syndromes, II:319
 - retinal artery, II:45
 - venous, retinal vein, II:45
- Occupational exposure, lung disease caused by, II:402
- Octreotide, to close intestinal fistulas, I:447
- Oculomotor nerve (CN III), II:32
 - aberrant regeneration, II:61, 89
 - eye movements and, II:74–94, 74–96
 - gaze defects, II:81
 - lesion of, physical examination for, II:78, 80
 - muscles groups supplied by, II:91
 - palsy, II:76–77, 91
 - conditions causing, II:81–82, 88
 - syndromes associated with, II:111
- Odynophagia, differential diagnosis of dysphagia and, in AIDS, I:569
- Ogilvie syndrome, I:490
- Olfactory nerve (CN I), II:32
 - translational neuroanatomy, II:35–36



- Oliver's sign, **I**:293
- Olivopontocerebellar atrophy, **II**:360
- Onycholysis, **I**:309
- Opening snap, **I**:116, 118
 - in mitral stenosis, **I**:192
 - circumstances when not occurring, **I**:195
 - implication of loss, **I**:194
- Opera glass hand, **II**:519
- Ophthalmoplegia, internuclear, **II**:92
- Optic atrophy, causes, **II**:71
- Optic disk, physical findings of, **II**:73
- Optic nerve (CN II), **II**:32
 - damage to, cortical blindness and, **II**:43
 - eye disorders involving, **II**:36–73
 - translational neuroanatomy, **II**:36
- Optic neuritis
 - causes, **II**:70–71
 - in multiple sclerosis, **II**:352
- Optic tract damage, cortical blindness and, **II**:43
- Oral cavity, visual examination of, **II**:364
- Oral mucosa, white spots on, **I**:358
- Orbit
 - blow-out fracture, **II**:90
 - migraine involving, **II**:133
- Organ transplantation, post-transplantation lymphoproliferative disorder, **I**:457
- Organoaxial volvulus, **I**:378
- Orogenital mucosa, in systemic lupus erythematosus, **II**:599
- Oropharyngeal dysfunction (OPD), gag reflex loss in diagnosis, **I**:386
- Oropharyngeal dysphagia, **I**:363
 - assessment for esophageal disease, **I**:374
 - vs. esophageal dysphagia, **I**:386
 - neuromuscular disorders associated with, **I**:364
- Oropharynx, uvula abnormalities and, **II**:360
- Orthopnea, **I**:34, **II**:375
 - in lung disease, **II**:371
- Orthostatic hypotension, **I**:63–66
- Ortner's syndrome, **I**:193, 194, 195
- Osler's nodes, **I**:235, **II**:586
- Osler-Weber-Rendu disease, **I**:411
- Osmotic laxatives, **I**:482
- Osteoarthritis, **II**:582–586
 - elbow in, **II**:532
 - in hand and wrist, **II**:524
 - of knee



- "best" clinical tests for, **II:556**
- performance characteristics for, **II:560**
- pain in, **II:618**
- pharyngeal dysphagia and, **I:403**
- primary, **II:615**
 - physical examination for, **II:594**
- radiological features, **II:613**
- and rheumatoid arthritis distinguished, **II:577**
- secondary, **II:614, 615**
- Osteoarthropathy, hypertrophic pulmonary, **II:407, 408**
 - clubbing vs., **II:407**
 - physical findings in, **II:409**
 - vs. thyroid acropachy, **I:292**
- Osteomalacia, **II:584**
 - radiological signs, **II:622**
 - systematic approach to causes, **I:331**
- Osteophyte, cervical, **I:403**
- Osteoporosis, **II:622**
 - directed history for causes, **I:330**
 - likelihood ratios of physical examination for detecting, **I:332**
 - radiological signs, **II:622**
 - systematic approach to causes, **I:330–331**
- Ottawa rule, for knee fracture, **II:559–560**
- Ovarian tumours, **I:546**

P

- PACE mnemonic, **II:262**
- Pacemaker syndrome, **I:94**
- Paget's disease, **I:472, 542, II:584**
- Pain. *See also* Headache
 - abdominal, **I:421–422**
 - acromioclavicular, **II:543**
 - in bursitis, **II:618**
 - in chest. *See* Chest pain
 - deep, methods for eliciting, **II:361**
 - in digital clubbing, **II:410**
 - in eye, **II:49, 83**
 - facial, causes
 - directed history for, **II:137–138**
 - physical examination for, **II:105**
 - in fever of unknown origin, **II:630**
 - in hip, **II:550, 551**
 - involuntary vs. malingering, differentiating, **I:422**
 - in knee, causes, **II:554**
 - in osteoarthritis, **II:618**



- in osteoarthropathy, **II:612**
- referred, **II:132, 539**
- in sacroiliitis, **II:618**
- in shoulder, **II:534, 538**
 - causes of, physical examination for, **II:539**
 - palpation diagnosis, **II:540**
- in spine, **II:543–550**. *See also* Back pain
- suggestive of disease at nerve root, **II:232**
- Paleocerebellum, in ataxia, **II:169**
- Palindromic rheumatism, **II:579**
 - rheumatoid arthritis, **II:584**
- Palm of hand, deformities of, **II:521**
- Palpable apical impulse, characteristics of size and position, **I:102**
- Palpable liver, **I:511**
- Palpitations
 - directed history for, **I:98**
 - focused physical examination for, **I:99**
 - precordial, **I:99–102**
- Palsy. *See also* Paralysis
- Bell's, **II:106–107**
- bulbar and pseudobulbar (multiple), **II:106, 107, 118, 154**
- common peroneal nerve (lateral popliteal nerve), **II:244**
- cranial nerve involvement in
 - abducens nerve (CN VI), **II:45, 88**
 - facial nerve (CN VII). *See* Paralysis, facial
 - multiple, causes, **II:106, 107, 118**
 - oculomotor nerve (CN III), **II:76–77, 81–82, 88, 91**
 - trochlear nerve (CN IV), **II:88**
- ulnar nerve, physical examination for, **II:227–228**
- Pancoast's syndrome, physical examination for, **II:447**
- Pancreas, **I:547–562**
 - cancers, **I:562**
 - complaints after heart/lung transplant, **I:574**
 - pseudocysts vs. cystic neoplasms, **I:549**
 - sarcoidosis, **I:562**
 - systemic lupus erythematosus affecting, **I:471**
 - tumours, **I:553–555**
- Pancreas divisum, vs. annular pancreas, **I:547**
- Pancreatic cysts, **I:546**
- Pancreatic endocrine tumours (PETs), **I:554–556**. *See also* Neuroendocrine tumours
 - history, **I:438**
 - prognostic factors, **I:559**
 - therapy, **I:560**
- Pancreatitis, **I:547–550**



- automimmune, **I:562**
- chronic, systematic approach to causes of, **I:548–549**
- drugs causing, **I:550**
- Ranson prognostic criteria acute, **I:548**
- in SOT, **I:506**
- Pancytopenia, causes, **I:622**
- Pansystolic murmurs, **I:134, 150**
- Pantothenic acid deficiency, complications, **I:566**
- Papillae of tongue, **I:358**
- Papillary defect, relative afferent. See Marcus Gunn pupil
- Papillary muscle, dysfunctional
 - mitral regurgitation from, **I:169**
 - vs. mitral valve prolapse/regurgitation, **I:183**
 - physical examination to distinguish chordae tendineae rupture murmur from, **I:172**
- Papilledema
 - causes, **II:52**
 - funduscopic examination for, **II:52**
 - and papillitis distinguished, **II:55, 70**
 - and retrobulbar neuritis distinguished, **II:68**
- Papillitis
 - focused ocular examination for, **II:53–54, 54**
 - and papilledema distinguished, **II:55, 70**
- Pappenheimer bodies, **I:617**
- Paracentesis induced circulatory disorder (PICD), **I:521**
- Paradoxical respiration, **II:371, 387**
- Paralysis. See *also* Palsy
 - facial, **II:553, 554**
 - lesion localization in, **II:101, 110**
 - physical examination for cause, **II:103–105**
 - familial hypokalemic, clinical features, **II:248**
 - Todd's, **II:302**
- Paraneoplastic lung tumour, **I:455**
- Paraneoplastic syndromes, **I:343, 402**
 - from lung small cell cancer, **I:403**
- Paraparesis, spastic and ataxic, causes, **II:167**
- Paraplegia, **II:173**
 - physical examination for, **II:318**
- Paraplegia-in-extension, **II:199**
- Paraplegia-in-flexion, **II:199**
- Parathyroid disorders, **I:326–335**
- Parathyroidectomy, for hyperthyroidism in MEN-1-ZES, **I:407**
- Paratonia, **II:290**
- Parietal lobe, **II:24, 25**
 - disease detection in



- directed history for, **II:27–28, 340**
- focused physical examination for, **II:26–27**
- dysfunctional, physical examination for, **II:331**
- Gerstmann's syndrome and, **II:353**
- Parinaud's syndrome, **II:32**
- "Parkinson plus syndromes," **II:289**
 - differential diagnosis, **II:291**
- Parkinsonian gait, **II:272**
- Parkinsonian syndrome, types of, **II:281**
- Parkinsonism, **II:278–292**
 - atherosclerotic, and Parkinson's disease distinguished, **II:285**
 - hemiparkinsonism, **II:280**
 - physical examination for, **II:280**
 - pseudoparkinsonism, **II:280**
 - signs in, **II:278**
 - suspected, likelihood ratios for, **II:287–289**
 - true, **II:279–280**
- Parkinson's disease
 - achalasia associated with, **I:372**
 - and atherosclerotic Parkinsonism distinguished, **II:285**
 - "best" clinical tests in, **II:286**
 - causes, **II:279**
 - and constipation, **I:481**
 - differential diagnosis, **II:290–291**
 - features/manifestations, **II:278–279, 285**
 - oropharyngeal dysphagia in, **I:364**
 - "Parkinson plus syndromes" in, **II:289, 291**
 - tremor, **II:295**
- Parotid gland, enlarged, causes, **I:360**
- Partial anterior circulation infarction syndrome (PACS), **II:333**
- Partial (localized) seizures, **II:28–29, 299, 301, 302**
- Past medical history (PMH), **II:644–645**
- Patent ductus arteriosus (PDA), **I:254–255**
 - congenital cardiac lesions dependent on, **I:264**
 - continuous murmur, **I:264**
 - cyanosis development, **I:259**
 - physical examination for, **I:251–252**
- Patent foramen ovale (PFO), **I:254**
- Patient history, O to W mnemonic, **I:10–19**
- Pectoriloquy, **II:371**
- Pectus carinatum, **II:370**
- Pectus excavatum, **II:370**
 - straight back/pectus excavatum, **I:142**
- Peliosis hepatitis, **I:542**
- Pelvic dyssynergia, **I:478**



- Pemberton's sign, **I**:287, 297, 314
- Penesophageal compression achalasia, **I**:371
- Peptic ulcers, somatostatin/octreotide for rebleeding risk reduction, **I**:410
- Percussion
 - in chronic bronchitis, **II**:432
 - in lung disease due to occupational exposure, **II**:402
 - in pulmonary system inspection, **II**:395
- Percussion notes, types and pathologic examples of, **II**:403
- Perianal lesions, in fever of unknown origin, **II**:630
- Pericardial diseases, **I**:213–215
- Pericardial effusion
 - causes, **I**:220
 - ECG for, vs. myocardial infarction, **I**:222
 - focused physical examination to distinguish, **I**:144
 - vs. pericardial rub, **I**:214
 - pericardial rub causes not progressing to, **I**:222
- Pericardial knock, **I**:116
- Pericardial rub, **II**:385
 - causes not progressing to pericardial effusion, **I**:222
 - focused physical examination to distinguish, **I**:144
- Pericarditis, **I**:215–224
 - directed history for causes, **I**:216
 - focused physical examination to distinguish between cardiac tamponade and, **I**:219–220
- Perioperative care, practice case scenario in, **II**:650
- Peripheral arteries
 - disease diagnosis, **I**:77
 - palpating both sides on body, **I**:79
- Peripheral cyanosis, **I**:253
- Peripheral edema, **I**:664
 - causes, **I**:66–71
- Peripheral nerves, **II**:150–151, 224–230
 - of hand, physical examination for, **II**:240
 - sensory branches
 - in arm, **II**:230
 - in leg, **II**:221
- Peripheral nervous system (PNS)
 - disorders of, directed history for, **II**:23
 - sensory dermatomes of, **II**:231
- Peripheral neuropathy, **II**:233–248
 - autonomic, **II**:234, 237
 - causes, **II**:235, 256
 - in diabetes mellitus, **II**:234, 236, 246
 - motor, causes, **II**:235–236, 245
 - physical examination for, **II**:235–236, 246–247



- and radiculopathy distinguished, **II:232**
- sensorimotor, **II:234**
- sensory, **II:234**
 - causes, **II:236, 246**
- thickened nerve plus, conditions causing, **II:244**
- Peripheral pulses, **I:71–87**
 - blood pressure and, **I:84**
 - contours, **I:73**
 - in mitral regurgitation, **I:180**
- Peripheral vascular disease, **I:54–62**
 - "best" tests for diagnosing, **I:59**
 - directed history and focused physical examination for, **I:57–58**
 - performance characteristics of physical examination, **I:60**
 - signs and causes, **I:85–86**
- Peritonitis, **I:423–430**
 - "best" clinical tests for, **I:428**
 - performance characteristics of findings suggesting, **I:425**
 - spontaneous bacterial, management strategy for preventing recurrent, **I:430**
- Pernicious anemia, focused physical examination for, **I:614**
- Peroneal muscular atrophy, **II:220**
- Peroneal muscular neuropathy, hereditary, **II:241**
 - Charcot-Marie-Tooth disease in, **II:239**
- Perseveration, **II:16**
- Personal activities of daily living (PADL), **II:305**
- Perthe's test, **I:54–55**
- "Petit mal" seizures, **II:29**
- Phalen sign, **II:503, 526, 528**
- Pharyngeal dysphagia, **I:403**
- Pheochromocytoma, focused physical examination for, **I:318**
- Phlebitis, superficial, **I:62**
- Phosphate, serum concentrations and hypoparathyroidism, **I:334**
- Physiologic tremor, **II:297**
- Pick's presenile dementia, **II:361**
- Pickwickian syndrome, **I:20, 676, II:469–470**
- Pill esophagitis, **I:369**
- Pillow sign, **I:439**
- Pilocarpine eye drops, effects of, **II:62**
- "Pink puffer." See Emphysema
- Pin-point pupils, **II:90**
- Pinprick testing, in uppr limb sensory loss, **II:239–240**
- Pioglitazone (TZD), benefits and adverse effects, **I:509**
- Pitre's sign, **II:361**
- Pituitary disease, **I:340–342**
- Pivot shift sign, **II:557, 559**
- Plantar reflex, up-going, **II:362**



- Plantar response, **II**:157
- Plasma anion gap, **I**:674–675
- Platelet-derived growth factor receptor-alpha (PDGFRA), **I**:458
- Platypnea, **II**:374, 375
- Pleural effusion, **II**:392–404
 - breath sounds in, **II**:386
 - causes, **II**:403–404
 - chest examination techniques in, **II**:382
 - physical examination for, **II**:394–395
 - physical findings for, **II**:400
- Pleural rub, **II**:385
 - focused physical examination to distinguish, **I**:144
 - and other breath sounds distinguished, **II**:385
- Pleural thickening
 - calcification, **II**:477
 - X-ray findings suggestive, **II**:397
- Pneumatosis cystoides intestinalis (PCI), **I**:466, 497
- Pneumobilia, causes, **I**:544
- Pneumoconiosis, radiographic findings in, **II**:416, 473
- Pneumonia, **II**:417–423
 - chest examination techniques in, **II**:382
 - chronic eosinophilia, **II**:267
 - community-acquired, **II**:269, 416
 - complications, **II**:418–419
 - physical examination for, **II**:420
 - findings in
 - multivariate, in adults, **II**:422
 - probability and, **II**:422
 - from fistula between esophagus and respiratory tree, **I**:401
 - hospital mortality predictors in, **II**:418, 421
 - hospitalization in, criteria for, **II**:417
 - physical examination for, performance characteristics, **II**:421
 - probability, **II**:422
 - recurrent, causes, **II**:423
 - severity score for, **II**:419
 - slow resolution/recurrence, **II**:423
 - tactile vocal fremitus and, **II**:385
- Pneumonia-specific Severity of Illness (PSI) Score, **II**:419
- Pneumonitis, hypersensitivity. *See* Extrinsic allergic alveolitis
- Pneumothorax, **II**:264–265, 386
 - chest examination techniques in, **II**:382
 - focused history for causes, **II**:462–463
- PODS mnemonic, **II**:262
- Polyarteritis nodosa (PAN), **I**:581
- Polyarthritis, as criteria for rheumatic fever diagnosis, **I**:147



- Polyarthropathy
 - deforming, causes, **II:571**
 - patterns, **II:613–614**
- Polycystic kidney disease, autosomal dominant, **I:677**
- Polycythemia
 - approach to tumours in, **II:449**
 - causes, **I:616–617**
- Polyglandular syndrome, **I:317**
- Polymyalgia rheumatica (PMR)
 - definition, **II:609**
 - differential diagnosis, **II:610**
 - and other polymyalgia rheumatica-like syndromes distinguished, **II:611**
- Polymyalgia rheumatica-like syndromes
 - directed history for, **II:609–610**
 - focused physical examination for, **II:609–610**
 - and polymyalgia rheumatica distinguished, **II:611**
- Polymyositis
 - GI complications, **I:580**
 - physical examination for, **II:580, 616**
- Polymyositis-dermatomyositis, **I:579**
- Polyyps, **I:493–495**
 - abdominal, **I:436–442**
- Polyradiculoneuropathy, inflammatory, physical examination for, **II:244**
- Pons
 - anatomy, **II:140**
 - ischemic event involving, physical examination for, **II:152–153**
- Portal hypertension
 - focused physical examination for signs, **I:517**
 - nodular regenerative hyperplasia associated with complications, **I:540**
 - obstruction, vs. inferior vena cava, **I:513**
 - possible explanations, **I:518**
 - splenomegaly and hepatomegaly in, **I:632**
- Portal hypertensive gastropathy (PHG), patterns in EGD, **I:409**
- Poser's criteria, for multiple sclerosis diagnosis, **II:350–352**
- Positional dyspnea (SoB), **II:375**
- Post polypectomy bleeding (PPB), risk factors, **I:476**
- Post seizure phenomena, **II:299**
- Postcentral gyrus, **II:24, 25**
- Posterior cerebral artery (PCA)
 - aneurysm, **II:91**
 - cerebral occlusion location, neurological examination for, **II:323**
 - in common stroke syndromes, **II:319**
 - ischemia of, physical examination for, **II:320**
 - occlusion, **II:171, 316–317**
 - supply to macula, **II:43**



- Posterior circulation infarction syndrome (POCS), **II:333**
- Posterior column syndrome, **II:179**
- Posterior column tract, **II:193**
 - fiber pathways, **II:191**
 - lesions of, physical examination for, **II:193–194**
- Posterior root ganglial conditions, **II:200**
- Posterolateral column syndrome, spinal cord, **II:179**
- Post-ictal seizures, **II:299**
- Postnasal drip syndrome, **II:425**
- Postoperative period
 - fever in, **II:632**
 - risk factors/complications in, **II:632–633**
- Post-transplantation lymphoproliferative disorder (PTLD), **I:457**
- Postural dizziness, **I:669**
- Postural hypotension, **I:63**
- Postural tremor, **II:294, 296–297**
- Posture, **II:266–277**
 - sustained abnormal, **II:294**
- Posture-induced crackles (PIC), **II:381**
- PQRST mnemonic, for headache/facial pain assessment, **II:134**
- PQRSTU-A mnemonic, for chest pain, **I:47**
- Prayer sign, **II:623**
- Precentral gyrus, **II:24, 25**
- Precordial vibratory murmur (Still's murmur), **I:140**
- Precordium, physical examination for, **I:43, 132**
 - focused, **I:137, 144**
- Precordium-basal systolic thrill, **I:156**
- Pre-eclampsia, **I:269**
- Pregnancy
 - appendectomy during, **I:423**
 - asymptomatic bacteria/urinary tract infection, complications, **I:639**
 - cholestatic jaundice in, **I:532**
 - drugs to avoid in, **II:650**
 - ectopic, **I:434**
 - effect on mitral stenosis, **I:195**
 - gallstone development in, **I:545**
 - Grave's disease treatment in, **I:299**
 - improvement of pre-existing conditions in, **II:649**
 - practice case scenario in, **II:647**
 - rheumatic fever and, **I:148**
 - splenic artery aneurysm risk in, **I:392**
 - in systemic lupus erythematosus, **II:599**
 - variceal bleeding risk in cirrhosis, **I:393**
 - ventricular septal defect with, **I:263**
- Presenile dementia, **II:361**



- Pressure cone
 - foramen magnum, **II**:156–157
 - temporal, **II**:155–156
- Pressure sores, grading, **I**:61
- Pressure ulcer
 - risk/causative factors for, **II**:589
 - staging, **II**:588
- Pretectal syndrome, **II**:32
- Pretibial myxedema, thyroid disorders associated with, **I**:294
- Primary biliary cirrhosis (PBC), **I**:541
- Primary sclerosing cholangitis (PSC), **I**:541
- Probiotics
 - for *C. difficile* infection, **I**:506
 - for irritable bowel syndrome, **I**:489
- Problem drinking, **I**:498
- Proctitis, infectious causes, **I**:492
- Progestin therapy, contraindications to, **I**:339
- Prokinetics, **I**:482
- Prolapsed vertebral disc, **II**:182–184
 - physical examination for, **II**:182–183
- Proprioception, posterior column pathways and, **II**:191
- Propylthiouracil (PTU), **I**:299
- Prosthetic heart valve
 - focused physical assessment for, **I**:165–166
 - heart sounds and, **I**:122
- Protein/calorie malnutrition, symptoms/signs in obesity, **I**:568
- Proteins, synthesis by liver, **I**:540
- Proteinuria, causes, **I**:672
- Proton pump inhibitors, **I**:405, 409
 - for dyspepsia, **I**:404
- Provocative/Provocation tests
 - of knee, **II**:555–556
 - secretin, **I**:407
- Proximal myopathy
 - causes, **II**:256, 262–263
 - gait in, **II**:275
- Pruritus, **I**:530
 - focused physical examination for, **I**:514
- Pseudoachalasia, postsurgical, causes, **I**:370
- Pseudobulbar palsy, and bulbar palsy distinguished
 - directed history for, **II**:154, 160
 - physical examination for, **II**:106, 118, 154, 160
- Pseudoclaudication, **I**:55
- Pseudo-Cushing's syndrome, **I**:321
- Pseudocysts, in pancreas, vs. cystic neoplasms, **I**:549



- Pseudo-gout, and gout distinguished, **II**:563–568
- Pseudohypertension, vs. pseudohypotension, **I**:647
- Pseudohypoparathyroidism, serum calcium and phosphate concentrations and, **I**:334
- Pseudohypotension, vs. pseudohypertension, **I**:647
- Pseudo-pseudohypoparathyroidism, serum calcium and phosphate concentrations and, **I**:334
- Pseudotumour cerebri, causes of, **II**:353–354
physical examination for, **II**:229
- Pseudoxanthoma elasticum (PXE), **I**:472
- Psoas sign, **I**:424, 425
- Psoriasis, arthropathy patterns in, **II**:615
- Psoriatic arthritis
and ankylosing spondylitis differentiated, **II**:584
elbow in, **II**:532
physical examination for, **II**:595
radiological features, **II**:595
and rheumatoid arthritis distinguished, **II**:596
- Psychogenic vertigo, **II**:112
- Ptosis
bilateral, physical examination for, **II**:79
causes, **II**:57, 91
focused physical examination for, **II**:57
in Horner's syndrome, **II**:57–58
oculomotor nerve (CN III) and, **II**:78–79
unilateral, physical examination for, **II**:57, 79
- Pulmonary cavity, physical examination for, **II**:402
- Pulmonary consolidation, **II**:392–404
physical examination for, **II**:394–395
physical findings for, **II**:400
- Pulmonary disease
case studies in, **II**:481–494
effect on lung sounds, **II**:377
- Pulmonary edema, **I**:35
- Pulmonary ejection systolic murmur, **I**:141
- Pulmonary embolism. See Embolism, pulmonary
- Pulmonary eosinophilia
causes, **II**:465, 469
disorders, **II**:466–467
- Pulmonary fibrosis, **II**:392–404, 413–417
causes, **II**:396, 414–415
systematic approach to, **II**:413–414
chest examination techniques in, **II**:382
physical examination for, **II**:394–395
physical findings in, **II**:396, 398, 400



- radiographic findings in, **II**:472–473
- Pulmonary hypertension, **II**:450–453
 - auscultatory performance physical examination for, **I**:112
 - causes, **II**:451–452
 - directed history for, **II**:451
 - physical examination for, **II**:451–452
- Pulmonary hypertrophic osteoarthropathy, vs. thyroid acropachy, **I**:292
- Pulmonary infarction, **II**:424
 - X-ray findings in, **II**:417
- Pulmonary lobes. *See* Lobes, lung
- Pulmonary regurgitation, **I**:208
- Pulmonary rub, rales vs., **II**:370–371
- Pulmonary stenosis, **I**:134, 149, 158–168
 - accessing severity, **I**:167
 - causes, **I**:159
 - physical examination to distinguish between systolic murmur of aortic stenosis and, **I**:159–160
 - types, **I**:222
- Pulmonary system, physical examination of
 - for consolidation, collapse, effusion, or fibrosis, **II**:394–395
 - for mediastinal compression, **II**:443–445. *See also* Carcinoma, of lung
 - for tracheal deviation, **II**:388
- Pulmonary systolic murmur, ventricular septal defect and, **I**:263
- Pulmonary vasculitis, causes of, **II**:465
- Pulse
 - arterial, **I**:72
 - irregular, causes, **I**:91
 - peripheral, **I**:71–87
 - radial
 - absent, **I**:77
 - unequal, **I**:84
- Pulse pressure
 - abnormally widened, **I**:86
 - influence on palpation of rapid arterial upstroke, **I**:78
- Pulse rate (PR)
 - fever and, **II**:648
 - right radial artery vs. left, **I**:227
 - variation in arms, **I**:79
- Pulsus alternans, **I**:22, 73, 74, 81, **II**:370
- Pulsus bisferiens, **I**:72, 73, 74, 80, 81, 163–164
- Pulsus paradoxus, **I**:22, 72, 73, 74, 85, **II**:370
 - as asthma predictor, **II**:430
 - and cardiac tamponade, **I**:81
 - physical examination for, **I**:76
 - reversed, **I**:80



- Pulsus parvus, **I:81**
 mechanisms for development, **I:78**
 vs. pulsus parvus et tardus, **I:78**
- Pulsus parvus et tardus, **I:74, 75, 84**
 vs. hyperkinetic pulse, **I:77**
- Pulsus tardus, and cardiac murmurs, **I:79**
- Pupil(s). *See also* Adie's pupil; Argyll Robertson pupil; Marcus Gunn pupil
 abnormal reaction to light/accommodation, **II:61–64**
 contracted, cause, **II:51**
 dilated, cause, **II:51**
 eccentric. non-neurological cause, **II:41**
 "fixed," **II:63**
 Holmes-Adie, **II:63, 64**
 near-light and light-near dissociation distinguished, **II:65**
 pin-point, **II:90**
 unequal. *See* Anisocoria
- Pupillary light reflex, **II:92–93**
- Purging bulimia nervosa, **I:567**
- Purpura, **I:632**
 causes, **I:602**
 fever plus, **II:648–649**
- Pursed-lip breathing, **II:371**
- Pyjamas sign, **I:491**
- Pyoderma gangrenosum, **II:578**

Q

- Quadrantanopia, homonymous, **II:40**
 causes, **II:44**
- Quadriplegia, **II:173**
- Quality measures, in clinical cardiac condition, **I:269**
- Queen Anne's sign, **I:294**
- "Question mark posture," in ankylosing spondylitis, **II:590**
- Quincke's sign, **I:208**

R

- Radial nerve
 in hand, **II:524**
 lesion, loss of pain sensation and, **II:239–240**
- Radial pulse
 absent, **I:77**
 unequal, **I:84**
- Radiculopathy, **II:201–204, 231–234**
 cervical
 diagnosing in patients with neck and arm pain, **II:202**
 physical examination for, **II:201–202**



- "Spurling test" in, **II:202**, 231
- lumbosacral
 - "best" tests fo, **II:202**
 - diagnosing in sciatica patients, **II:203–204**
 - performance characteristics for, **II:203**
 - and peripheral neuropathy distinguished, **II:232**
- Radionuclide scan, for GI bleeding, **I:475**
- Raeder's paratrigeminal syndrome, **II:108**
- Rales, pulmonary rub vs., **II:370–371**
- Ramsay-Hunt syndrome, **II:103**
- Range of motion (ROM), normal in joints, **II:514–515**, 525
 - ankle, **II:515**, 561
 - foot, **II:515**
 - hand, **II:523**
 - hip, **II:515**, 551, 552
 - knee, **II:515**
 - shoulder, **II:535–536**, 538
 - spine, **II:548**
 - cervical spine, **II:547**, 619, 620
 - wrist, **II:523**, 525
- Rapid alternating movements test, **II:166**
- Rapid arterial upstroke
 - causes, **I:80**
 - influence of pulse pressure on, **I:78**
- Rapid ventricular contraction, physical examination for causes, **I:72**
- Rash
 - annular, **II:553**
 - fever with, causes, **II:634–635**
 - in varicella zoster virus infection, **II:641**
- Raymond's syndrome, **II:89**
- Raynaud's disease, **I:62**
- Raynaud's phenomenon, **II:602–605**
 - causes, **II:602–603**
 - physical examination for
 - directed, **II:604–605**
 - focused, **II:530**, 624
 - secondary
 - directed history for, **II:603**
 - focused physical examination for, **II:603**
- Reactive arthritis, **I:582**
- Rebound phenomenon, in cerebellar disorders, **II:164**
- Rebound tenderness, **I:544**
- Rectal manometry, **I:478**
- Rectal tenderness, **I:423**
- Rectal varices, blood supply, **I:476**



- Rectum
 barium enema examination, **I**:480
 palpable mass, causes, **I**:429
- Red blood cells, **I**:613–621
 sickle, **I**:586
- Red eye
 causes, **II**:73, 82–83
 conjunctivitis vs. uveitis, **II**:72
- Red half-moons in nail beds, **I**:528
- Red spots, retinal, causes of, **II**:46
- Refeeding syndrome, **I**:566
- Referred pain, **I**:426, **II**:132, 539
- Reflexes
 absent, in cerebellar disorders, **II**:164, 362
 absent knee, **II**:174, 198, 211, 362
 deep tendon. *See* Deep tendon reflexes (DTR)
 involving facial nerve (CN VII), **II**:102, 110
 in loss of corticospinal inhibition, **II**:208
 pendular, in cerebellar disorders, **II**:164
 in spinal cord compression, **II**:196
 in spinal cord disorders, **II**:173, 174
 stretch. *See* Stretch reflexes, of muscle
 up-going plantar, **II**:206, 265
 vestibulo-ocular, **II**:114
- Reflux laryngitis, laryngoscopic finding, **I**:383
- Refractory ascites, management strategy for, **I**:521
- Refsum's disease, **II**:292
- Regional edema, physical examination to differentiate types, **I**:69
- Regional lymphadenopathy, **I**:607
- Reiter's syndrome, **II**:618
 arthropathy patterns in, **II**:615
 clinical features, **II**:565–566, 585
 complications of, physical examination for, **II**:566
- Relapse, neurological conditions and, **II**:154
- Relative afferent papillary defect. *See* Marcus Gunn pupil
- Relocation test, for shoulder instability, **II**:541
- Remission, neurological conditions and, **II**:154
- Renal calculi, **I**:648–649
- Renal disease, in systemic lupus erythematosus, **II**:599
- Renal fibrosis, interstitial, causes, **I**:653
- Renal mass, in fever of unknown origin, **II**:630
- Rennin, effects of salt intake on, **I**:647
- Resonance (percussion note), **II**:403
- Respiration. *See also* Breathing disorders



- hypercapnia. See Hypercapnic respiratory failure
- hyperventilation. See Hyperventilation
- hypoxemia, **II**:461–462
- effects on murmurs, **I**:126
- patterns, **II**:372, 379
- rhythm abnormalities in, **II**:372–373
- Respiratory acidosis, **I**:673, 676, 678–679
- Respiratory alkalosis, **I**:673–674, 676
- Respiratory alternans (paradoxical respiration), **II**:371
- Respiratory failure
 - hypercapnic. See Hypercapnic respiratory failure
 - hypoxemia, **II**:461–462
- Respirology
 - case studies, **II**:481–494
 - exam questions, **II**:xxv–xxvii, 367–369
 - practice case scenarios, **II**:495
 - terms commonly used, **II**:370–371
- Resting tremor, **II**:294, 296
- Restless legs syndrome (RLS), **II**:277–278
- Restrictive lung disease
 - cor pulmonale caused by, **II**:450
 - results of pulmonary function tests in, **II**:436
- Retained antrum syndrome, **I**:443
- Reticular activating system (RAS), functional testing of, **II**:161
- Retinal artery
 - microaneurysms of, causes, **II**:72
 - occlusion, **II**:45
 - and retinal vein distinguished, **II**:54
- Retinal damage, cortical blindness and, **II**:43
- Retinal hemorrhage, causes, **II**:66–67
 - physical examination for, **II**:42
- Retinal lesions, **II**:45–46
 - red, **I**:240
- Retinal pigment epithelial hypertrophy, **II**:47
- Retinal vein
 - occlusion, **II**:45
 - and retinal artery distinguished, **II**:54
- Retinitis, on fundoscopic examination, **II**:52, 67
- Retinitis pigmentosa, **II**:47
 - causes, **II**:55, 71
- Retrobulbar neuritis, and papilledema distinguished, **II**:68
- Reversed pulsus paradoxus, **I**:80
- Reversible ischemic neurological deficit (RIND), **II**:332
 - and TIA differentiation, **II**:359
- Reynolds lines, **I**:529



- Rheumatic arthritis, **I**:543
- Rheumatic fever, **I**:146–149
- Rheumatic heart disease, **I**:146–149
- Rheumatoid arthritis (RA), **II**:368–380
- American Rheumatism Association criteria for, **II**:570
 - arthropathy patterns in, **II**:615
 - bronchiectasis in, **II**:464
 - common sites for, **II**:571
 - disease activity and damage evaluation in, **II**:568–569
 - elbow in, **II**:532
 - of foot, physical examination for, **II**:583
 - functional assessment in, **II**:574–575
 - in hand and wrist, **II**:524
 - non-musculoskeletal associations, **II**:576
 - physical examination for, **II**:571–574
 - extra-articular complications, **II**:570
 - non-articular signs, **II**:578–579
 - and osteoarthritis distinguished, **II**:577
 - and polymyalgia rheumatica distinguished, **II**:610
 - prognostic factors for, **II**:582
 - and psoriatic arthritis distinguished, **II**:596
 - radiological features, **II**:576
 - Sjögren's syndrome in, **II**:581
 - splenomegaly in, **II**:583
 - therapeutic complications in, **II**:575
 - of wrist, physical examination for, **II**:529
- Rheumatologic disease, **I**:576–578
- Rheumatology
- exam questions, **II**:xxvii–xxx, 499–501
 - practice case scenarios, **II**:625
- Rhonchus, **II**:376, 378, 381
- Riboflavin deficiency, complications, **I**:566
- Ribs, notching
- causes, **I**:229
 - coarctation of aorta and, **I**:224
- Right bundle branch block (RBBB), vs. LBBB, **I**:114
- Right coronary artery (RCA), vs. left anterior descending artery, **I**:50
- Right upper quadrant (RUQ) pain, **I**:446
- causes, **I**:421
- Right-sided congestive heart failure (R-CHF)
- causes, **I**:24
 - physical examination for causes, **I**:31
 - physical examination to distinguish between L-CHF and, **I**:32–33
- Rigidity
- in extrapyramidal disease, **II**:283



- muscle spasticity vs., **II:277, 290**
- Ring shadows, on chest X-ray, **II:475**
- Rinne test, **II:114, 115**
 - likelihood ratios for, **II:115–116**
- Rivera-Carvalho maneuver, **I:178**
- Rome criteria, for dyspepsia, **I:376**
- Rosenbach's sign, **I:291, 314**
- Rotator cuff tear/rupture, **II:538**
 - "best" clinical test for, **II:542**
 - detecting, performance characteristics for, **II:541–542**
 - and rotator cuff tendonitis distinguished, **II:542**
- Rotator cuff tendonitis, **II:538**
 - "best" clinical test for, **II:542**
 - performance characteristics for, **II:541–542**
 - and rotator cuff tear distinguished, **II:542**
- Rotavirus, immunization, **I:487**
- Roth spots, **I:240**
- Roussy-Levy disease, **II:292**
- Rovsing's sign, **I:423, 425**
- Royal College sign, **II:361**
- Rub, vs. other heart sounds, **I:125**
- Ruptured chordae tendineae (RCT), mitral regurgitation murmur from, **I:169**

S

- Saccular aneurysm of aorta, syphilitic aortitis with, focused physical examination for, **I:225–226**
- Sacroiliitis
 - and ankylosing spondylitis differentiated, **II:584**
 - back pain in, **II:592**
 - causes, **II:592**
 - systematic approach to, **II:579**
 - in Crohn disease, and peripheral arthritis distinguished, **II:593**
 - pain in, **II:618**
- Sagittal sinus thrombosis (SST), **II:317**
- Salivary glands, **I:359**
 - causes of bilateral swelling, **I:363**
- Salmonella* infection, in HIV-AIDS, **I:572**
- Salt intake, effect on aldosterone and rennin in hyperaldosteronism, **I:647**
- Saphenous veins, assessing competence, **I:54–55**
- Sarcoidosis
 - complications of hepatic granulomas, **I:540**
 - features on liver biopsy, **I:540–541**
 - grading, **II:413**
 - of pancreas, **I:562**
 - physical examination for, **II:411–412**



- skin manifestations, **II:476**
- Scalenus anterior (cervical rib) entrapment syndrome. See Cervical rib syndrome
- Scanning dysarthria, in cerebellar disorders, **II:164**
- Schamroth's sign, **II:406**
- Schmidt syndrome, **I:317, II:129**
- Schober's test, **II:548, 590, 595**
- Schwannomas, **I:439**
 - IHC stains for distinguishing, **I:458**
- Sciatic nerve, lesion of, and meningeal irritation distinguished, physical examination for, **II:343**
- Scissor gait, **II:267**
- Sclera, blue, **II:49, 67**
- Scleroderma, physical examination for, **II:601–602**
- Sclerosis, causes, **I:631**
- Sclerotic lesions, in bone X-rays, **II:621**
- Sclerotic phase, in hypertensive retinopathy, **II:44**
- Scotoma
 - arcuate, **II:40**
 - central, **II:40**
 - causes, **II:48**
- Secondary myopathy, **II:250**
- Secretin provocation test, **I:407**
- Secretion stimulation test, **I:405**
- Seizures, **II:299–304**
 - abnormal imaging studies in, **II:302–303**
 - causes, **II:300, 303**
 - clinical features, **II:28–29**
 - directed history for, **II:301–302**
 - in epilepsy, **II:299**
 - types, **II:28–29, 299**
- Selenium deficiency, complications, **I:566**
- Seniors. See Elderly
- Sensation, abnormal, lesions causing, **II:241–242**
- Sensory ataxia gait, **II:271**
- Sensory cortex, **II:24, 25**
- Sensory dermatomes, **II:189–191**
 - lower limb, physical examination for, **II:190**
 - of peripheral nervous system, **II:231**
 - upper limb, physical examination for, **II:190**
- Sensory loss
 - attributed to spinothalamic tract or dorsal column, **II:176**
 - in multiple sclerosis, **II:352**
 - physical examination for lesion location causing, **II:172–173, 178, 334–335**
 - upper limb lesion and, **II:239–240**



Sensory modalities, spinal cord lesions involving, **II:172–173**
 Sensory neuropathy, causes, physical examination for, **II:504**
 Sensory syndromes, **II:238**
 Sepsis, classification of, **II:642**
 Sepsis-associated cholestasis (SAC), molecular defects causing, **I:532**
 Septic shock, **II:635–636**
 classification, **II:642**
 Septicemia, in hospitalized patient, **II:633**
 Severe sepsis, classification of, **II:642**
 Sexual abuse accommodation syndrome, **II:647**
 Sexually transmitted disease
 complications in females, **II:643**
 pathogens in, **II:643**
 SHIAMS mnemonic, **II:644–645**
Shigella infection, in HIV-AIDS, **I:572**
 Shock, septic, **II:635–636**
 Shortness of breath (SoB), **II:375**
 Shoulder, **II:533–543**
 abnormal articular findings in, **II:512**
 anatomy, **II:533**
 common conditions, **II:534, 538**
 movements
 active, **II:536**
 passive, **II:537**
 special tests involving, **II:537**
 normal range of motion, **II:514, 535–536**
 painful, **II:534, 538**
 causes of, physical examination for, **II:539**
 palpation diagnosis, **II:540**
 physical examination for, **II:505, 535–536**
 referred pain to, **I:426**
 Shoulder instability, **II:534**
 anterior and inferior, tests for, **II:541**
 Shoulder pad sign/syndrome, **II:620**
 Shoulder syndromes, physical examination for, **II:543**
 SHOVE mnemonic, **II:22**
 Shy-Drager syndrome, **II:360**
 Sickle red blood cells, **I:586**
 Sideroblastic anemia, causes, **I:617**
 Sideropenic anemia, **I:618**
 Sighing, **II:373**
 Silhouette sign, on chest X-ray, **II:470–471**
 Silicosis, radiological findings in, **II:416, 473**
 Simple partial seizures, **II:28–29, 301**
 Sinus arrhythmia, **I:22, II:370**



- Sinus bradycardia, directed history for causes, **I:92**
- Sinus disease, in fever of unknown origin, **II:630**
- Sinus impulses, in Wolff-Parkinson-White syndrome, **I:94**
- Sinus tachycardia, **I:91**
- Sinusitis, headache/facial pain associated with, **II:137**
- Sinusoidal obstructive syndrome (SOS), **I:504–505**
- Situs inversus, **I:265**
 - physical examination to distinguish between dextrocardia, dextroversion and levoverision, **I:244**
- Sjögren's syndrome, **I:578, II:581**
- Skin
 - in patient inspection for cardiac disease, **I:13**
 - in systemic lupus erythematosus, **II:599, 600–601**
- Skin lesions
 - in diabetes mellitus, **I:282**
 - in returned traveler, **II:637**
- Skull
 - bony changes in Paget disease, **II:584**
 - causes of mottling, **I:631–632**
 - radiographic punctate translucencies causes, **I:329**
 - translucencies in vault, **I:631**
- Sleep, esophageal function changes during, **I:382**
- Sleep apnea, obstructive, **I:676, II:469–470**
- Slow transit constipation (STC), **I:479**
- Small bowel, **I:444–472**
 - bull's eye lesion, **I:455**
 - Crohn disease, **I:447–451**
 - infection, **I:452–454**
 - Isospora* and *Cryptococcus* on biopsy, **I:467**
 - lymphomas, **I:454–457**
 - classifying, **I:456**
 - mesenteric ischemia, **I:445–446**
 - obstruction, **I:444–445**
 - focused physical examination for, **I:445**
 - transplantation, **I:464–465**
- Small intestinal bacterial overgrowth (SIBO), **I:453–454**
- Smoking. See Cigarette smoking; Tobacco
- Smooth muscle, and constipation, **I:481**
- Snap, vs. other heart sounds, **I:125**
- Sodium, drugs causing retention, **I:26**
- Soft exudates, retinal. See Cotton-wool spots, retinal
- Softeners, **I:482**
- Solid organ transplantation (SOT), **I:503–504**
 - C. difficile* clinical course in, **I:506**
- Solitary rectal ulcer syndrome (SRUS), **I:480**



- Somatostatin/octreotide, for risk reduction of peptic ulcer rebleeding, **I:410**
- Somatostatinoma, **I:470**
 approximate sensitivities of diagnostic imaging, **I:558–561**
 common clinical presentations, **I:553**
- Somatostatinoma syndrome, **I:559**
- Space occupying lesion, headache/facial pain and, **II:133**
- Spasm
 conjugate deviation of eye, **II:90**
 esophageal, **I:373–374**
 sphincter of Oddi, **I:564**
- Spastic achalasia, vs. diffuse esophageal spasm, **I:374**
- Spastic hemiplegia, gait in, **II:273**
- Spastic paraparesis, **II:197**
 causes, **II:167**
 physical examination for, **II:186–187**
- Spasticity, **II:248**
 gait in, **II:275**
 muscle rigidity vs., **II:277, 290**
- Speech
 cerebellar, **II:362**
 in cerebellar disorders, **II:170**
 components, **II:122**
 disorders, **II:122–128**. *See also individually named disorders*
 in disorders of articulation, **II:118**
 fluent vs. non-fluent, **II:124**
- Sphincter of Oddi (SOD)
 dysfunction, **I:531**
 spasm, **I:564**
- Spike and dome pulse, **I:72, 81**
- Spina bifida, closed, physical examination for, **II:198**
- Spinal accessory nerve (CN XI), **II:33, 117–118**
- Spinal artery, anterior
 occlusion, **II:179**
 thrombosis, **II:196**
- Spinal canal, lesion below T10 level, physical examination for, **II:211–212**
- Spinal column
 and constipation, **I:481**
 GI complications in, **I:588**
- Spinal cord
 degeneration of, subacute combined, **II:195**
 physical examination for, **II:198**
 diseases involving. *See Spinal cord disease*
 findings in upper motor neuron weakness, **II:20**
 hemisection. *See Brown-Sequard syndrome*
 lesion localization, focused physical examination for, **II:171–172**



- dissociated anesthesia and, **II:184–185**
- intramedullary vs. extramedullary, **II:31, 158**
- motor pathway in, **II:18**
- in multiple sclerosis, **II:352**
- nerve roots and, **II:171–198**
- sectional anatomy, **II:17**
- sensory pathway in, **II:18**
- subacute combined degeneration in, **II:174, 179**
- total transection and incomplete compression distinguished, **II:175**
- transverse section, **II:171**
- Spinal cord compression
 - causes, **II:181, 197–198**
 - incomplete, and total cord transection distinguished, **II:175**
 - lumbosacral, **II:191**
 - motor and reflex changes in, **II:196–197**
 - physical examination for, **II:181**
- Spinal cord disease
 - cognitive impairment in, **II:195**
 - dermatomes in, physical examination for
 - lower limb, **II:190**
 - upper limb, **II:190**
 - dissociated anesthesia and, **II:184–185**
 - symptoms suggestive, **II:200**
 - types, **II:195–196**. *See also individual diseases*
- Spinal cord syndromes, **II:174**
 - types, **II:179**
- Spinal cord transection, **II:179, 199**
 - and incomplete cord compression distinguished, **II:175**
- Spinal pathways, **II:172**
- Spine
 - cervical, movements, **II:546, 547**
 - fracture, likelihood ratios of physical examination for detecting, **I:332**
 - pain in, **II:543–550**. *See also Back pain*
 - thoracolumbar, active movements, **II:546**
- Spinocerebellar degeneration, **II:292**. *See also Friedreich's ataxia*
- Spinothalamic tract, **II:194**
 - lateral, **II:168, 194**
 - sensory loss attributed to, **II:176**
- Spirometry criteria, for COPD, **II:440**
- Spleen
 - examination, **I:626–629**
 - palpation, **I:628**
 - performance characteristics
 - for detecting enlarged, **I:629**
 - for palpation in various disorders, **I:630**



- Splenic artery aneurysm, risk in pregnancy, **I:392**
- Splenic vein thrombosis (SVT), **I:392, 562**
 diagnosis, **I:413**
- Splenomegaly, **I:625–634**
 causes, **I:625–626**
 clinical detection, **I:626**
 in fever of unknown origin, **II:630**
 hepatomegaly and, **I:632**
 Nixon method of detection, **I:628**
 in returned traveler, **II:637**
 in rheumatoid arthritis, **II:583**
- Splinter hemorrhages, **I:529**
 in fever of unknown origin, **II:630**
- Spondyloarthritis, **II:582**
- Spondylosis, cervical. See Cervical spondylosis
- Spontaneous bacterial peritonitis (SBP), management strategy for preventing recurrent, **I:430**
- Sporadic fundic gland polyps, **I:441**
- "Spurling's test," **II:231**
- Sputum, **II:389–390**
- Squamous cell carcinoid, viral infection associated with, **I:572**
- Square wrist sign, **II:503**
- Staphylococcus aureus* infection, in hospitalized patient, **II:633**
- Stapled transanal rectal resection (STARR), **I:479**
- Status asthmaticus, chest examination techniques in, **II:383**
- Status epilepticus, **II:301–302, 304**
- Stauffer syndrome, **I:532**
- Steele-Richardson-Olszewski disease, **II:289**
- Stellwag's sign, **I:291, 314**
- Sternoclavicular joint, **II:533**
- Steroids, informed consent for use, **I:448–450**
- Stethoscope, in FEV₁/FVC value estimation, **II:387**
- Stevens-Johnson syndrome
 and Behçet's syndrome distinguished, **II:567**
 clinical features, **II:566–567**
 definition, **II:580**
- Stiff neck, causes of, **II:344, 345, 346**
- Still disease, cause of death in adult-onset, **I:531**
- Still's murmur (precordial vibratory murmur), **I:140**
- Stimulant laxatives, **I:482**
- Stomach, **I:404–434**
 cell types of endocrine tumours, **I:442**
 complaints after heart/lung transplant, **I:574**
 hypersecretion, gastrin and ZES, **I:404–407**
 treatment of premalignant conditions in, **I:440**



- Stool osmotic gap (SOG), **I**:452–453
- Strabismus, **II**:87
- Straight back/pectus excavatum, **I**:142
- Straight-leg raising test, **II**:345, 549
- Stress-immune response, mediators, **I**:422
- Stress-related mucosal injury (SRMI), **I**:408
- Stretch reflexes, of muscle, **II**:220, 243
grading scale for, **II**:21
- Striatonigral degeneration, **II**:360
- Stridor, **II**:370
- Stroke. *See also* Cerebrovascular accident (CVA)
aspiration after, performance characteristics for, **II**:324
Bamford clinical classification, **II**:330–331
forms, **II**:321
ischemic, **II**:320–321
NIH stroke scale, **II**:328–329
stratifying risk, **I**:89
warning signs, **II**:320
- Stroke syndromes, **II**:332. *See also* Cerebrovascular accident (CVA);
Transient ischemic attack (TIA)
common forms, **II**:319
- Subacute bacterial endocarditis, **I**:240
focused physical examination for, **I**:241
- Subacute combined degeneration, spinal cord, **II**:195
physical examination for, **II**:198
- Subaortic stenosis, idiopathic, **I**:163
- Subarachnoid hemorrhage, **II**:328
"best" clinical tests for, **II**:345
headache/facial pain in, **II**:133, 136, 137
meningitis and, **II**:345–347
- Subclinical hypothyroidism, **I**:300
- Submucosal gastric tumours, and EUS, **I**:440
- Substance abuse
alcohol, **I**:498–501
laxatives, **I**:484
- Substance withdrawal, directed history and focused physical examination for,
I:501
- Subvalvular aortic stenosis, palpation to differentiate, **I**:162
- Sudden blindness, causes of, **II**:37
physical examination for, **II**:38–39
- Suker sign, **I**:314
- Sulcus sign, in shoulder instability, **II**:541
- Sulphemoglobinemia, **II**:387
- Summation gallop, **I**:125
- Superficial phlebitis, **I**:62



- Superior mesenteric artery embolism (SMAE), **I:445**
- Superior orbital fissure syndrome, **II:108**
- Superior vena caval obstruction
 directed history and focused physical examination for, **I:268**
 jugular venous pulse elevated due to, **I:214**
- Supracristal ventricular septal defect, **I:249, 263**
- Supraspinatus test, **II:537**
- Supravalvular aortic stenosis
 palpation to differentiate, **I:162**
 physical examination to distinguish from aortic stenosis, **I:164**
- Supraventricular aortic stenosis, vs. ventricular, bronchial pulse in, **I:161**
- Supraventricular tachycardia, **I:93**
- Surface anatomy, for lobes of lung, **II:399**
- Swan neck deformity, **II:516, 517, 519**
- Swelling, optic nerve head, **II:53**
- Sydenham chorea, **I:148**
- Sylvian Aqueduct syndrome, **II:32**
- Syncope
 in aortic stenosis, **I:158**
 causes, **II:145, 347–348**
 in aortic stenosis, **I:155**
 directed history and focused physical examination for, **I:53**
- Syndrome of inappropriate antidiuretic hormone (SIADH), causes, **I:666**
- Syphilis, clinical features suggesting aortic regurgitation due to, **I:200–201**
- Syphilitic aortitis, with saccular aneurysm of aorta, focused physical examination for, **I:225–226**
- Syringobulbia. See Hydromyelia
- Syringomyelia, **II:179, 199**
 conditions similar to, **II:216**
 and hydromyelia differentiated, **II:199**
 physical examination for, **II:180, 214–215**
- Systemic disease
 gastrointestinal manifestation, **I:576–578**
 hepatic dysfunction in patients with, **I:591**
- Systemic hypertension. See Hypertension
- Systemic lupus erythematosus (SLE), **I:294, 578–583, II:597–601**
 definition, **II:598**
 diagnostic criteria for, **II:597, 600**
 GI complications, **I:579**
 pancreas affected by, **I:471**
 physical examination for, **II:598–599, 600–601**
 vasculitis in, **I:581**
- Systemic vascular resistance, maneuvers affecting, **I:129**
- Systolic blood pressure, **I:84**
- Systolic bruit, conditions causing, **I:225**



Systolic dysfunction (DS)
 vs. diastolic dysfunction, **I:30**
 pathophysiology, **I:21**
 Systolic ejection murmur, causes, **I:154**
 Systolic murmurs, **I:149–152, 177**
 aortic stenosis and, **I:154**
 with diastolic murmur in aortic regurgitation, **I:206**
 direct history and focused physical examination for evaluating, **I:139**
 likelihood of aortic stenosis as cause, **I:157**
 physical examination for severity, **I:186**
 pulmonary ejection, **I:141**
 ratios of individual findings for identifying, **I:130**
 Systolic normal heart sounds, **I:120**
 Systolic regurgitation, **I:160**

T

T cell small intestinal lymphoma, **I:454**
 Tabes dorsalis, **II:179**
 physical examination for, **II:187–188**
 Tachyarrhythmias, **I:88**
 exercise and vagal stimulation effect, **I:95**
 Tachycardia
 directed history for causes, **I:92**
 sinus, **I:91**
 supraventricular, **I:93**
 ventricular, **I:89**
 performance characteristics, **I:83**
 Tachypnea, **II:373, 374**
 Tactile vocal fremitus (TVF), **II:385**
 physical findings in, **II:401**
 Tamponade. See Cardiac tamponade
 Tapping apex beat, in mitral stenosis, **I:192, 193**
 Tardive dyskinesia, **II:290**
 Target cell, **I:618**
 Tart cell, **I:617**
 Taussing-Bing syndrome, **I:246**
 Teeth
 dental procedures and, antibiotic regimen for endocarditis prophylaxis,
I:242
 in fever of unknown origin, **II:630**
 Telangiectasias, **I:519**
 Telescoping, of fingers, **II:519**
 Telomerase, **I:397–398**
 Telomeres, **I:397–398**
 Temporal arteritis, **II:354–357**



- headache/facial pain in, **II**:133, 137
- Temporal artery, in fever of unknown origin, **II**:630
- Temporal lobe, **II**:24, 25
 - disease detection in
 - directed history for, **II**:28, 340
 - focused physical examination for, **II**:27
 - seizures, **II**:299
- Temporal pressure cone, **II**:155–156
- Tendon reflexes, **II**:208
- Tendons
 - flexor digitorum profundus, testing, **II**:522, 525
 - flexor digitorum superficialis, testing, **II**:522, 525
 - reflexes. *See* Deep tendon reflexes (DTR)
- "Tennis" elbow, **II**:533
- Tenosynovitis, De Quervain's stenosing, **II**:520, 623
- Tension headache, **II**:134
- Teratogenicity, in pregnancy, **II**:650
- Terminal nerve branches, in hand, **II**:524
- Terry's nails, **I**:528
- Tetralogy of Fallot, **I**:20
 - and couer de sabot, **I**:265
 - focused physical examination for, **I**:255–256
- Thalamus, sensory syndrome involving injury to, **II**:180
- Thiamine deficiency, **I**:543
 - complications, **I**:566
- Thickening
 - nerves, causes of, **II**:245
 - pleural, X-ray findings suggestive of, **II**:397
- Third nerve palsy, **II**:76–77
 - conditions causing, **II**:81–82
- Thomas's test, **II**:345
- Thoracic aortic dissection
 - performance characteristics of clinical findings for, **I**:227
 - sensitivity of findings, **I**:228
- Thoracolumbar spine, active movements of, **II**:546
- Thorax, in patient inspection for cardiac disease, **I**:14
- Throat, globus lump vs. dysphagia, **I**:375
- Thrombocytopenia, directed history for, **I**:600
- Thromboembolism, physical examination for risk factors, **I**:91
- Thrombolysis in myocardial infarction (TIMI) Risk Score, **I**:44
- Thrombophilias, inherited and acquired, **I**:600–601
- Thrombosis
 - anterior spinal artery, **II**:196
 - cavernous sinus, **II**:317
 - deep vein, **I**:49, **II**:457–459



- posterior inferior cerebellar artery, physical examination for, **II:121**
- sagittal sinus, **II:317**
- Thrombotic thrombocytopenic purpura (TTP), **I:632**
- Thumb
 - abduction of, testing for, **II:224**
 - movements, **II:520**
 - normal range of motion, **II:525**
- Thyroglossal cyst, vs. thyroid lesion, **I:151, 292**
- Thyroid acropachy, **I:294**
 - vs. pulmonary hypertrophic osteoarthropathy, **I:292**
- Thyroid cancer, **I:292**
 - and diarrhea, **I:465**
 - risk factors, **I:301–302**
- Thyroid disease, **I:287**
 - directed history for, **I:288–289**
 - focused physical examination for, **I:290**
- Thyroid gland
 - lesion vs. thyroglossal cyst, **I:151, 292**
 - performance characteristics for palpation, **I:291**
 - weight of normal, **I:297**
- Thyroid goitre, compression complications, **I:297**
- Thyroid hormone deficiency, **I:299**
- Thyroid nodule, **I:295–299, 301–302**
 - directed history and focused physical examination for, **I:295–296**
- Thyroid ophthalmopathy, focused physical examination for, **I:310**
- Thyroid-stimulating hormone (TSH), as hypothyroidism indicator, **I:300**
- Thyroid-stimulating immunoglobulins, **I:299**
- Thyromegaly, and unilateral proptosis, ophthalmopathy causes, **I:294**
- Thyrotoxicosis
 - causes, **I:293**
 - focused physical examination for patient with, **I:313–314**
- Tic, **II:267, 293**
- Tilt test, **I:65**
- Tilting disc valves, **I:122**
- Tinel sign, **II:503, 526, 528**
- Tobacco. *See also* Cigarette smoking
 - and esophageal cancer, **I:394**
- Todd's paralysis, **II:302**
- Toes
 - clubbing, **I:224**
 - cyanosis and clubbing, **I:264**
- Tone
 - abnormal, characteristics, **II:211**
 - changes in, causes, **II:217**
 - sustained abnormal, **II:294**



- Tongue, **I**:358
 enlarged, causes, **I**:357
- Tonic pupil. See Adie's pupil
- Tonic-clonic seizures, **II**:29, 301
- Tooth. See Teeth
- Total anterior circulation infarction syndrome (TACS), **II**:333
- Tracheal deviation
 causes, **II**:388
 physical examination for, **II**:388
 position, **II**:371
- Tractus solitarius, **II**:34
- Transection, of spinal cord. See Spinal cord transection
- Transient elastography, for cirrhosis diagnosis, **I**:523
- Transient ischemic attack (TIA)
 cardiac risks for, **II**:327–328
 carotid artery stenosis in, **II**:462
 carotid vs. vertebrobasilar, directed history determining, **II**:332
 described, **II**:332
 directed history for, **II**:313–314
 physical examination for, ischemia of arteries, **II**:319–320
 and RIND differentiation, **II**:359
 symptoms, **II**:332
- Transient supraventricular arrhythmias, **I**:82
- Transjugular intrahepatic portosystemic shunt (TIPS), **I**:518
- Transplantation
 bone marrow, **I**:532
 heart, GI symptom after, **I**:574
 hematopoietic cell, **I**:503–504
 early causes of anorexia and vomiting, **I**:593
 GI complications, **I**:575
 liver, **I**:502
 liver disease recurring after, **I**:505
 lung, GI symptom after, **I**:574
 small bowel, **I**:464–465
 solid organ, **I**:503–504
C. difficile clinical course in, **I**:506
- Transverse myelitis, physical examination for, **II**:244
- Traube's sign, **I**:208
- Traube's space, **I**:627
 dullness, **I**:629, 632
- Tremor, **II**:266, 293–298
 action, **II**:269
 in extrapyramidal disease, **II**:283
 of Parkinson's disease, **II**:295
 physical examination for, **II**:296–297



- types, **II**:294
- Trendelenburg's gait, **II**:274–275, 554
- Trendelenburg's sign (TS), **II**:554
- Trendelenburg's test, **I**:54–55
- Trepopnea, **II**:375
- Tricuspid regurgitation, **I**:134, 174–178
 - focused physical examination for, **I**:175, 176–177
 - murmurs, **I**:178
 - focused physical exam to distinguish between mitral regurgitation murmur and, **I**:174
 - physical examination for severity, **I**:186
- Tricuspid stenosis, **I**:187, 196
- Tricuspid valve myxoma, **I**:118
- Tricuspid valve prolapse, **I**:184
 - focused physical examination for, **I**:185
- Trigeminal nerve (CN V), **II**:33, 34, 96
 - masseter muscle and, **II**:110
- Trigger finger, **II**:520
- Trochlear nerve (CN IV), **II**:32
 - eye movements and, **II**:74–94, 74–96
 - gaze defects, **II**:81
 - lesion of, physical examination for, **II**:84
 - palsy of, conditions causing, **II**:88
- Troisier's ganglion, **I**:607
- Troisier's node, **I**:363
- Tropical sprue, **I**:469, 471
- Trouser sign, **I**:491
- Trousseau's sign, **II**:562
- Trousseau's syndrome, **II**:562
- TRPV1 (vanilloid receptor 1), **I**:383
- Trypanosoma cruzi*, **I**:373
- Tryptophan, metabolism to 5-HIAA, **I**:459
- Tuberculosis, bronchiectasis and, **II**:465
- Tubular excretory function, **I**:638
- Tubular reabsorption function, **I**:638
- Tumours. *See also specific tumours*
 - associated with paraneoplastic neurological degeneration, **II**:358
 - malignant, metastases to lung and bone, **II**:447
- Tuning fork tests, **II**:113, 114
 - likelihood ratios for, **II**:115–116
- Tunnel vision, causes of, **II**:43–44
- Turcot syndrome, **I**:494
- Turner's syndrome, **I**:20, 244, 261
 - physical examination for, **II**:529
- Tylosis, **I**:400, 403



Typhlitis, **I**:548, 575

U

Ulcerative colitis (UC), **I**:491

peripheral arthritis vs. sacroiliitis in, **II**:593

Ulcer/Ulceration

arteriolar, **I**:56

corneal, **II**:83

of leg

lower leg, directed history for, **I**:56

physical examination for, **II**:619–620

neurotrophic, **I**:56

pressure, **II**:588–589

solitary rectal ulcer syndrome, **I**:480

venous, **I**:56

Ulnar nerve

defects of, and median nerve defects distinguished, **II**:231

in hand, **II**:524

lesions of, and T1 root lesions distinguished, **II**:231

muscle innervation by, **II**:221

Ulnar nerve palsy, physical examination for, **II**:227–228

Ultrasound. *See* Endoscopic ultrasound (EUS)

Uncus herniation, **II**:159–160

Unilateral cerebral hemispheric disease, performance characteristics in, **II**:325

Unilateral palpable kidney disease, **I**:677

Unilateral proptosis

cause of unequal, **I**:292

and thyromegaly, ophthalmopathy causes, **I**:294

Uninvestigated dyspepsia, vs. functional dyspepsia, **I**:376

Upper airway cough syndrome (UACS), **II**:425

Upper gastrointestinal bleeding (UGIB), **I**:408–416

in HIV-AIDS, **I**:572–573

hospitalization for, **I**:410

non-variceal, **I**:411

splenic vein thrombosis leading to, **I**:413

Upper limbs

motor system of. physical examination for, **II**:206–207

movements of, myotomes and, **II**:514

Upper motor neuron (UMN), **II**:20. *See also* Pseudobulbar palsy

deep tendon reflexes, **II**:19

disc protrusion and, **II**:230

in facial weakness, **II**:103

hypertonicity, **II**:19

lesions



- abnormal tone and, **II**:211
 - anatomical basis for, **II**:205
 - physical examination for, **II**:206
 - LMN vs. UMN lesions, physical examination for determining, **II**:99–101, 110, 263
 - and lower motor neuron compared, **II**:204, 217
 - motor pathway involvement, **II**:19–20
 - nerve root disease, physical examination for, **II**:218–220
 - weakness
 - diagnostic approach to, **II**:264
 - localizing signs in, **II**:20
 - Uremia, focused physical examination for, **I**:662–663
 - Urinary incontinence
 - causes in elderly, **II**:636
 - risk factors, **I**:678
 - Urinary tract infection (UTI), **I**:650
 - in pregnancy, **I**:639
 - Ursodeoxycholic acid (UDCA), **I**:533
 - Uveitis, **II**:72
 - causes, **II**:37–38
 - Uvula
 - abnormalities, **II**:360
 - Mueller's sign and, **II**:363
- V
- V wave, **I**:38
 - Vaccination, while on azathioprine, **I**:487
 - Vagal stimulation, effect on tachyarrhythmias, **I**:95
 - Vagus nerve (CN X), **II**:33, 117
 - disorder fo, physical examination for, **II**:122
 - Valgus deformity, **II**:560
 - Valsalva maneuver, **I**:183, 478
 - Valvular aortic regurgitation, focused physical examination to distinguish aortic dissection from, **I**:228
 - Valvular aortic stenosis
 - impulse, **I**:163–164
 - palpation to differentiate, **I**:162
 - Valvular heart disease
 - chest X-ray for, **I**:159
 - performance characteristics for physical examination, **I**:138
 - predisposing to endocarditis, **I**:241–242
 - S₃ and, **I**:123
 - Variceal bleeding, risk in pregnant woman in cirrhosis, **I**:393
 - Varicella zoster virus (VZV) infection, **II**:641
 - Varices, **I**:391–393



- endoscopic treatment, **I:412**
- fundic, anatomical basis for isolated, **I:392**
- Vascular defects, **I:602**
- Vascular disorders, cor pulmonale caused by, **II:450**
- Vascular endothelial growth factor (VEGF), role in angioectasia, **I:475**
- Vasculitis, **I:62**. *See also* Arteritis
 - cutaneous, **II:606**
 - nonsystemic, causes, **II:607–608**
 - pulmonary, causes, **II:465**
 - syndromes mimicking, **II:608**
 - systemic
 - causes, **II:605–606, 607**
 - directed history for, **II:606–607**
 - nomenclature for, **II:607**
 - physical examination for, **II:606–607**
 - small-vessel, **II:607**
- Vasoconstrictive phase, in hypertensive retinopathy, **II:44**
- Vasopressin
 - blocker, **I:522**
 - mechanism of action, **I:522**
- Veno-occlusive disease (VOD), **I:504–505**
- Venous edema, vs. lymphedema, **I:68**
- Venous hum, **I:133, 142**
- Venous insufficiency, **I:62**
 - vs. arterial, **I:61**
 - physical examination to distinguish between arterial and, **I:69**
- Venous obstruction, **I:62**
- Venous return, maneuvers affecting, **I:129**
- Venous ulcers, **I:56**
- Venous waveforms, abnormalities, **I:40**
- Ventilation, disorders of. *See* Hypercapnic respiratory failure; Hyperventilation
- Ventricular aortic stenosis, vs. supraventricular, bronchial pulse in, **I:161**
- Ventricular fibrillation, **I:89**
- Ventricular septal defect (VSD), **I:134, 152**
 - focused physical examination for, **I:247–250**
 - hemodynamic severity, and size, **I:260**
 - murmurs, **I:247**
 - pansystolic, **I:260**
 - types, **I:249, 263**
- Ventricular tachycardia, **I:89**
 - performance characteristics, **I:83**
- Ventriolosis basilar, **II:333**
- Verbigeration, **II:16**
- Verner-Morrison syndrome, common clinical presentations, **I:553**



- Vernet's syndrome, **II:129**
- Vertigo. *See also* Nystagmus/vertigo
 forms, **II:112**
 translational anatomy and, **II:113**
- Vestibulocochlear nerve (CN VIII), **II:33, 112–113**
 acoustic branch, **II:113**
 translational neuroanatomy, **II:112**
- Vestibulo-ocular reflex, **II:114**
- Vibration, posterior column pathways and, **II:191**
- Villaret's syndrome, **II:29**
- VIPoma, **I:470**
 characteristics, **I:558**
 clinical features of syndrome, **I:557**
 common clinical presentations, **I:553**
- Viral infections, **II:639–641**
- Virchow's node, **I:363, 607**
- Virchow's triad, **I:49**
- Virchow's triad, in DVT, **II:476**
- Visual field defects
 causes, **II:37**
 CN II involvement in, signs and symptoms, **II:41**
- Visual field lesions, **II:40**
 anterior and chiasmal, conditions caused by. *See individual conditions*
- Visual fields, physical examination of
 internal carotid artery occlusion, **II:317**
 posterior cerebral artery occlusion, **II:316–317**
- Visual pathways, **II:39**
- Visual symptoms, and related disease states, **II:69**
- Vital signs, and acute blood loss, **I:416**
- Vitamin A, overconsumption, **I:542**
- Vitamin B12 deficiency, causes, **I:615**
- Vitamins
 alterations in serum levels in obesity, **I:568**
 deficiencies, complications, **I:566**
- Vocal resonance, pulmonary auscultation for, performance characteristics,
II:379
- Voice and vowel sounds, assessment in non-English speakers, **II:361**
- Volume depletion, **I:664**
- Volvulus, gastric, **I:378**
- Vomiting, **I:377–378**
 early causes in HCT, **I:593**
 in returned traveler, **II:637**
- Von Graefe sign, **I:314**
- Vowel sounds, assessment in non-English speakers, **II:361**



W

- Waddling gait, **II**:268
- Wakefulness, **II**:359
- Waldenstrom macroglobulinemia, **I**:633, 634
- Walking, structures involved in, **II**:270. *See also* Gait
- Wallenberg's syndrome, **II**:158–159
- Warfarin, drug interactions with, **I**:603, 631
- Water, total body volume in male, **I**:669
- Waterhammer pulse, **I**:74
- Watson's syndrome, **I**:159
- Wayne index for hyperthyroidism, **I**:312
- Weakness
 - facial
 - physical examination for cause, **II**:103–105
 - UPM vs. LMN, **II**:103
 - of limbs, power grading system for, **II**:265
 - motor, in multiple sclerosis, **II**:352
 - in muscle. *See* Muscle wasting/weakness
 - neuromuscular
 - common etiologies, **II**:261
 - physical examination for, **II**:261–262
 - proximal, causes, **II**:262–263
 - upper motor neuron, localizing signs in, **II**:20
- Weber test, **II**:114, 115
 - likelihood ratios for, **II**:115–116
- Weber's syndrome, **II**:111, 174
- Wegener's granulomatosis, **I**:582, 583
- Weight loss
 - practice case scenario in, **II**:647
 - rapid, complications, **II**:648
- Wells scoring scheme, for deep vein thrombosis, **II**:458–459
 - simplified, findings in, **II**:459
- "Wheelchair sign," in Parkinson's disease, **II**:287–289
- Wheeze/Wheezing, **II**:370, 376, 378, 385, 426
 - differential diagnosis, **II**:426–427, 430
 - pulmonary auscultation performance characteristics, **II**:384
- Whipple disease, **I**:467
- Whispered voice test, **II**:112
 - likelihood ratios for, **II**:115–116
- White blood cells, **I**:621–625
- Williams' syndrome, **I**:159
- Willis, circle of. *See* Circle of Willis, arteries of
- Wilson disease, **I**:542
- Windsox diverticula, **I**:379
- Wolff-Parkinson-White syndrome



- sinus impulses in, **I**:94
- supraventricular tachycardia in, **I**:93
- World Health Organization, classification of overweight and obesity, **I**:283–284
- Wrinkling of forehead, facial nerve (CN VII) and, **II**:109
- Wrisberg, nervus intermedius and, **II**:98, 110
- Wrist, **II**:514–529
 - abnormal articular findings in, **II**:511
 - arthritis distribution in, **II**:524
 - deformities, **II**:519–520, 521
 - movements, **II**:526
 - normal range of motion, **II**:514, 523
 - physical examination for, **II**:505–506
 - rheumatoid arthritis of, physical examination for, **II**:529

- X
- X descent, abnormalities, **I**:40

- Y
- Y descent, **I**:38
 - abnormalities, **I**:40
- Yellow nail syndrome, **I**:529
- Yergason's sign, **II**:537
 - in rotator cuff tendinitis, **II**:542
- Young's syndrome, bronchiectasis in, **II**:464

- Z
- Zenker diverticulum, **I**:387
 - role of surgery in, **I**:384
- Zieve syndrome, **I**:500
- Zinc deficiency
 - complications, **I**:566
 - dermatitis enterohepatica from, **I**:472
- Zollinger-Ellison Syndrome (ZES), **I**:406–407
 - clinical features suggesting, **I**:554
 - colorectal carcinoma in patient with, **I**:405
 - diagnosis, **I**:407
 - sporadic, **I**:407

