



The Asian Pacific Association for the Study of the Liver



APASL Oncology 2022

APASL Single Topic Conference

"Liver Cancer : Clinical and Basic Research"

Program & Abstracts

Term: September 1-3, 2022

City: Takamatsu, Kagawa, Japan

Onsite-Venue: Hotel Clement Takamatsu

President: Tsutomu Masaki, M.D.

Professor and Chairman,
Department of Gastroenterology and Neurology,
Faculty of Medicine, Kagawa University





APASL Oncology 2022 in Takamatsu

“Liver Cancer : Clinical and Basic Research”

Hybrid Meeting (Onsite-Venue: JR Hotel Clement Takamatsu)

September 1-3, 2022

Table of Contents

Welcome Message

Invited Guest Speakers / Chairs

Organizing Committee

Conference Information

On-Site Venue

Instruction for Oral Presentation

Instruction for Chairs

Instruction for Poster Presentation

Awards / Contact

Sponsors and Support Organization

Program at a Glance

Scientific Program

Abstracts: Special Lectures, President Lecture

Abstracts: Workshops

Abstracts: Sponsored Seminars

Abstracts: Oral Free Papers

Abstracts: Poster Free Papers

Welcome Message



Dear Colleagues,

On behalf of the Organizing Committee, we would like to welcome you to the Asian Pacific Association for the Study of the Liver APASL Oncology 2022, which will be held on September 1-3, 2022 in Takamatsu, Japan as a hybrid-

style meeting.

The scientific program will consist of invited lectures, plenary sessions, symposia, and free papers on significant developments on the theme of “Liver Cancer : Clinical and Basic Research”. The program will also provide the latest information and fresh ideas for hepatologists and oncologists in this area.

We have invited 140 guest speakers from overseas and Japan, and received 260 abstracts for free papers accepting all categories of Hepatology and Oncology. We anticipate a large number of attendants, which will stimulate active discussions.

APASL Oncology 2022 will combine the physical event at The Hotel Clement Takamatsu, Japan in the “Shikoku” Island which located in the west- south part of Japan, with a Virtual Meeting platform for a unique experience bringing both the in-person and virtual community together. Webcast video presentations will be connected with physical presentations and sessions including virtual interactions, live commentary, online chat and discussion.

A delegation of experts from all over the world is expected to attend this conference. We are sure that this will provide an excellent opportunity for those of us in the Asian Pacific region to share the latest views, values, experience, and practice, and greatly contribute to this field.

We are looking forward to seeing you soon in our charming city Takamatsu or through the online webinar.

With warmest regards,

A handwritten signature in black ink that reads "Tsutomu Masaki". The signature is written in a cursive, flowing style.

Tsutomu Masaki M.D.
President, APASL Oncology 2022
(APASL Single Topic Conference in Takamatsu)
Professor and Chairman
Department of Gastroenterology and Neurology,
Faculty of Medicine, Kagawa University

Invited Guest Speakers/Chairs/Scientific Committee

Invited Guests/Speakers/Chairs/Scientific Committee from Overseas

Dr. Oidov Baatarkhuu (Mongolia)	Dr. Young Nyun Park (Korea)
Dr. Wan-Long Chuang (Taiwan)	Dr. Diana A. Payawal (Philippines)
Dr. Massimo Colombo (Italy)	Dr. Teerha Piratvisuth (Thailand)
Dr. Ian H. Cua (Philippines)	Dr. Shiv K. Sarin (India)
Dr. A. Kadir Dokmeci (Turkey)	Dr. Manoj K. Sharma (India)
Dr. Rino Gani (Indonesia)	Dr. Ting Ting Shi (China)
Dr. Hasmik Ghazinyan (Armenia)	Dr. Gamal Shiha (Egypt)
Dr. Saeed Hamid (Pakistan)	Dr. Jose Sollano (Philippines)
Dr. Ji-Dong Jia (China)	Dr. Tung-Hung Su (Taiwan)
Dr. Jia-Horn Kao (Taiwan)	Dr. Tawesak Tanwandee (Thailand)
Dr. George Lau (China)	Dr. Jin Mo Yang (Korea)
Dr. Cosmas R. Lesmana (Indonesia)	Dr. Hong You (China)
Dr. Han-Chieh Lin (Taiwan)	Dr. Lai Wei (China)
Dr. Chun-Jen Liu (Taiwan)	Dr. Ming-Lung Yu (Taiwan)
Dr. Mamun-Al Mahtab (Bangladesh)	Dr. Man-Fung Yuen (China)
Dr. Rakhi Maiwall (India)	

In alphabetical order

Invited Guests/Speakers/Chairs/ Scientific Committee from Japan

Dr. Masanori Abe	Dr. Takeshi Hatanaka	Dr. Ichiro Ishimaru
Dr. Hiroshi Aikata	Dr. Etsuro Hatano	Dr. Kiyoaki Ito
Dr. Norio Akuta	Dr. Yoichi Hiasa	Dr. Takanori Ito
Dr. Kuniaki Arai	Dr. Takuto Hikichi	Dr. Yoshihito Ito
Dr. Shinichi Ariizumi	Dr. Hayato Hikita	Dr. Takao Itoi
Dr. Yasuhiro Asahina	Dr. Takashi Himoto	Dr. Hideki Iwamoto
Dr. Masanori Atsukawa	Dr. Keisuke Hino	Dr. Namiki Izumi
Dr. Kazuaki Chayama	Dr. Atsushi Hiraoka	Dr. Satoru Kakizaki
Dr. Akihiro Deguchi	Dr. Masashi Hirooka	Dr. Hideki Kamada
Dr. Hirayuki Enomoto	Dr. Masao Honda	Dr. Yoshihiro Kamada
Dr. Nobuyuki Enomoto	Dr. Hirofumi Ichida	Dr. Tatsuo Kanda
Dr. Hideki Fujii	Dr. Akio Ido	Dr. Shuichi Kaneko
Dr. Koji Fujita	Dr. Yuji Iimuro	Dr. Yoshihito Kano
Dr. Hiroaki Fujiwara	Dr. Masafumi Ikeda	Dr. Tatsuya Kanto
Dr. Junji Furuse	Dr. Kenichi Ikejima	Dr. Kazuya Kariyama
Dr. Satoru Hagihara	Dr. Atsushi Imagawa	Dr. Naoya Kato
Dr. Keisuke Hamamura	Dr. Kento Imajo	Dr. Tsunetaka Kato
Dr. Kazuhiro Hanasaki	Dr. Atsushi Irisawa	Dr. Norifumi Kawada
Dr. Ken Haruma	Dr. Hiroyuki Isayama	Dr. Takumi Kawaguchi
Dr. Kiyoshi Hasegawa	Dr. Masatoshi Ishigami	Dr. Hirofumi Kawamoto

Dr. Yusuke Kawamura	Dr. Kazuhiko Nakao	Dr. Akinobu Takaki
Dr. Miwa Kawanaka	Dr. Daisuke Namima	Dr. Taro Takami
Dr. Tomokazu Kawaoka	Dr. Naoshi Nishida	Dr. Hajime Takatori
Dr. Hideki Kobara	Dr. Akira Nishiyama	Dr. Tadatoshi Takayama
Dr. Takashi Kobayashi	Dr. Kazuhiro Nouse	Dr. Tetsuji Takayama
Dr. Takahiro Kodama	Dr. Shuntaro Obi	Dr. Haruhiko Takeda
Dr. Yuzo Kodama	Dr. Hironori Ochi	Dr. Tsuyoshi Takeda
Dr. Tomomi Kogiso	Dr. Sadahisa Ogasawara	Dr. Tetsuo Takehara
Dr. Shigehiro Kokubu	Dr. Chikara Ogawa	Dr. Hideyuki Tamai
Dr. Atsumasa Komori	Dr. Keiichi Okano	Dr. Atsushi Tanaka
Dr. Kazuyoshi Kon	Dr. Takamasa Ohki	Dr. Junko Tanaka
Dr. Masatoshi Kudo	Dr. Yoshihiro Okita	Dr. Shinji Tanaka
Dr. Yotaro Kudo	Dr. Tomomi Okubo	Dr. Yasuhito Tanaka
Dr. Kensuke Kumamoto	Dr. Hiroyuki Okuyama	Dr. Joji Tani
Dr. Hidekatsu Kuroda	Dr. Masao Omata	Dr. Makiko Taniai
Dr. Kazutaka Kurokohchi	Dr. Masafumi Ono	Dr. Keisuke Tateishi
Dr. Masayuki Kurosaki	Dr. Makoto Oryu	Dr. Ryosuke Tateishi
Dr. Teiji Kuzuya	Dr. Minoru Oshima	Dr. Shuji Terai
Dr. Shin Maeda	Dr. Motoyuki Otsuka	Dr. Takeshi Terashima
Dr. Shinya Maekawa	Dr. Kyouko Oura	Dr. Yoshio Tokumoto
Dr. Tsutomu Masaki	Dr. Issei Saeki	Dr. Katsutoshi Tokushige
Dr. Yoko Matsuda	Dr. Ryotaro Sakamori	Dr. Tetsu Tomonari
Dr. Takanori Matsui	Dr. Naoya Sakamoto	Dr. Hidenori Toyoda
Dr. Yasunori Minami	Dr. Naoki Sasahira	Dr. Kaoru Tsuchiya
Dr. Masaki Miyazawa	Dr. Shinpei Sato	Dr. Akihito Tsuji
Dr. Satoshi Mochida	Dr. Shuichiro Shiina	Dr. Koichi Tsuneyama
Dr. Kenichi Morikawa	Dr. Masahito Shimizu	Dr. Akemi Tsutsui
Dr. Kousaku Morimoto	Dr. Junichi Shindoh	Dr. Yoshiyuki Ueno
Dr. Asahiro Morishita	Dr. Ken Shirabe	Dr. Kazuomi Ueshima
Dr. Akio Moriya	Dr. Yohei Shirakami	Dr. Yuzo Umeda
Dr. Kei Moriya	Dr. Goki Suda	Dr. Takeji Umemura
Dr. Mitsuhiko Moriyama	Dr. Katsutoshi Sugimoto	Dr. Takahiro Yamasaki
Dr. Masaru Muraoka	Dr. Yoshio Sumida	Dr. Tatsuya Yamashita
Dr. Hiroaki Nagamatsu	Dr. Fumitaka Suzuki	Dr. Takumi Yanagita
Dr. Sumiko Nagoshi	Dr. Tomohiro Tada	Dr. Hiroshi Yatsuhashi
Dr. Hayato Nakagawa	Dr. Toshifumi Tada	Dr. Osamu Yokosuka
Dr. Yousuke Nakai	Dr. Kazuto Tajiri	Dr. Masashi Yoneda
Dr. Masao Nakajima	Dr. Yasutsugu Takada	Dr. Hirohito Yoneyama
Dr. Nobuhiro Nakamoto	Dr. Koichi Takaguchi	Dr. Hideo Yoshida
Dr. Yasunari Nakamoto	Dr. Hirokazu Takahashi	Dr. Hitoshi Yoshiji
Dr. Makoto Nakamuta	Dr. Sho Takahashi	Dr. Hiroshi Yotsuyanagi

In alphabetical order

Organizing Committee

Local Organizing Committee

Honorary President: Dr. Masao Omata
President: Dr. Tsutomu Masaki
Vice-President: Dr. Naoya Kato
Treasurer: Dr. Kazuaki Chayama
Treasurer: Dr. Namiki Izumi
Treasurer: Dr. Shuhei Nishiguchi

Treasurer: Dr. Norifumi Kawada
Treasurer: Dr. Yasuhito Tanaka
Treasurer: Dr. Yoichi Hiasa
Treasurer: Dr. Koichi Takaguchi
Secretary General: Dr. Joji Tani

APASL Steering Committee

Chairman of Steering Committee: Dr. Shiv Kumar Sarin (India)
President: Dr. Han Chieh Lin (Taiwan)
Immediate Past President: Dr. Jin Mo Yang (Korea)
President Elect: Dr. Shuichiro Shiina (Tokyo)
Secretary General-cum-Treasurer: Dr. Manoj K Sharma (India)
Past Presidents:

Dr. Laurentius A. Lesmana (Indonesia)	Dr. Darrell Crawford (Australia)
Dr. Jose Sollano (Philippines)	Dr. A. Kadir Dokmeci (Turkey)
Dr. Masao Omata (Japan)	Dr. Osamu Yokosuka (Japan)
Dr. Dong Jin Suh (Korea)	Dr. Jinlin Hou (China)
Dr. George Lau (China)	Dr. Barjesh Chander Sharma (India)
Dr. Ji Dong Jia (China)	Dr. Diana A. Payawal (Philippines)
Dr. Teerha Piratvisuth (Thailand)	Dr. Rino Gani (Indonesia)
Dr. Jia-Horng Kao (Taiwan)	Dr. Tawesak Tanwandee (Thailand)

APASL Executive Council

Assistant Secretary: Dr. Hong You (China)

Executive Councils:

Dr. Gulnara Aghayeva (Azerbaijan)	Dr. Simone Strasser (Australia)
Dr. Chun-Jen Liu (Taiwan)	Dr. Yaman Tokat (Turkey)
Dr. Mamun-Al-Mahtab (Bangladesh)	Dr. Yoshiyuki Ueno (Japan)
Dr. Rakhi Maiwall (India)	

Conference Information

Registration Fee and Category

	Early Bird until July 31, 2022	Pre-Registration until August 25, 2022	On Site
APASL Member*	JPY 20,000	JPY 25,000	JPY 30,000
Non-Member	JPY 30,000	JPY 35,000	JPY 40,000
Trainee / Resident**	JPY 15,000	JPY 20,000	JPY 25,000
Accepted Abstract Submitter	JPY 15,000	JPY 20,000	JPY 25,000
Accompanying Person	JPY 5,000	JPY 5,000	JPY 5,000
Online Attendants	JPY15,000	JPY20,000	JPY25,000

JPY=Japanese Yen

*APASL Members who have paid 2022 Membership Fee can apply for discounted registration fee.

*Registration for viewing of On-demand Presentation is available until September 30, 2022.

Online Participation (Style: Zoom Webinar)

- The conference program will be presented as a hybrid style meeting.
- Attendants are able to enter the webinar through Zoom <https://zoom.us/join> with the ID and Password of which they have been informed by the conference secretariat. * For Speakers/Chairs, the secretariat sends an individual invitation link to enter the webinar.
- The lectures will be delivered live or by recorded video. After the presentation, the discussion (Q&A) time will be held according to the moderator's instructions. Online viewers are able to send textual questions to the Q&A column, and the onsite participants may ask questions using the microphone in the conference room. We anticipate your active discussions.
- After the conference term, the recorded lectures and discussion will be distributed on-demand from the presentation page of APASL Oncology 2022 Website <http://www.apaslsc-takamatsu2022.org/>
The viewing period of the on-demand presentation is scheduled to be from September 9, 2022 through September 30, 2022. The secretariat will receive the questions by e-mail during the on-demand delivery period and will forward them to each speaker.

[Precautions]

- The organizer cannot handle problems such as computer operation, internet connection, video and audio connection. Please solve such problems by yourself. We recommend the following environment.
 - We would appreciate it if you could use a PC with as much memory as possible (CPU i5 or more, memory 8 Giga or more).
 - Please connect to the Internet via a wired LAN line as much as possible.
 - To transfer or share the ID and password, recording of screens and images is strictly prohibited.
 - The internet fee at this online conference will be borne by each attendant.
- We cordially solicit your understanding and cooperation.

Onsite Registration/PC Pre-view Hours

September 1 (Thursday)	7:30-18:00 (JST)
September 2 (Friday)	7:30-18:00 (JST)
September 3 (Saturday)	7:30-12:00 (JST)

Onsite-Venue

JR Hotel Clement Takamatsu (Hybrid Style Meeting)

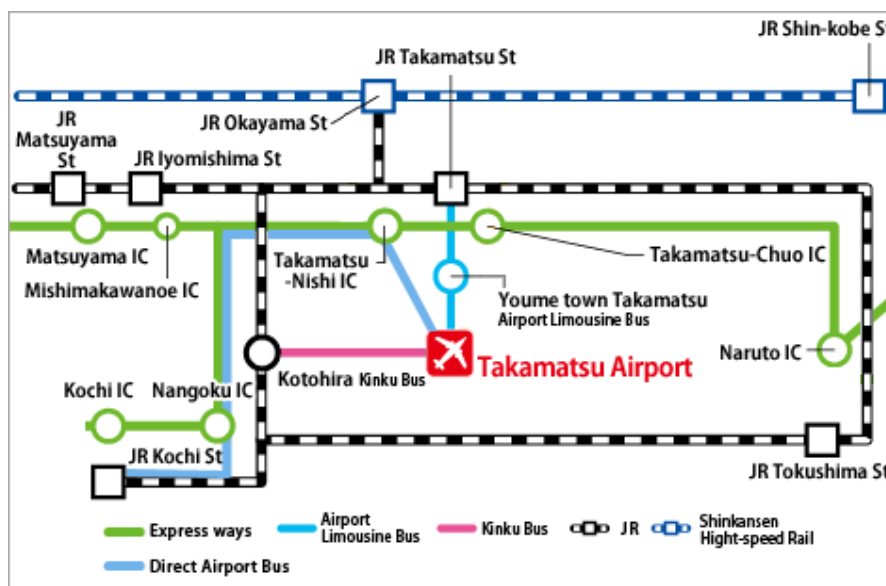
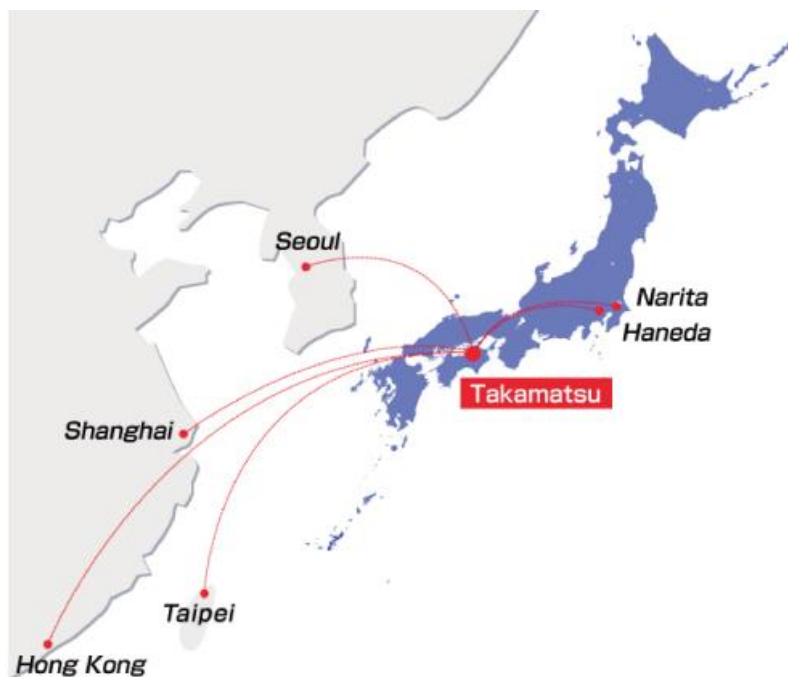Address: 1-1 Hamano-cho, Takamatsu-shi, Kagawa-ken, 760-0011, Japan

Tel: +81 (0) 87-811-1111

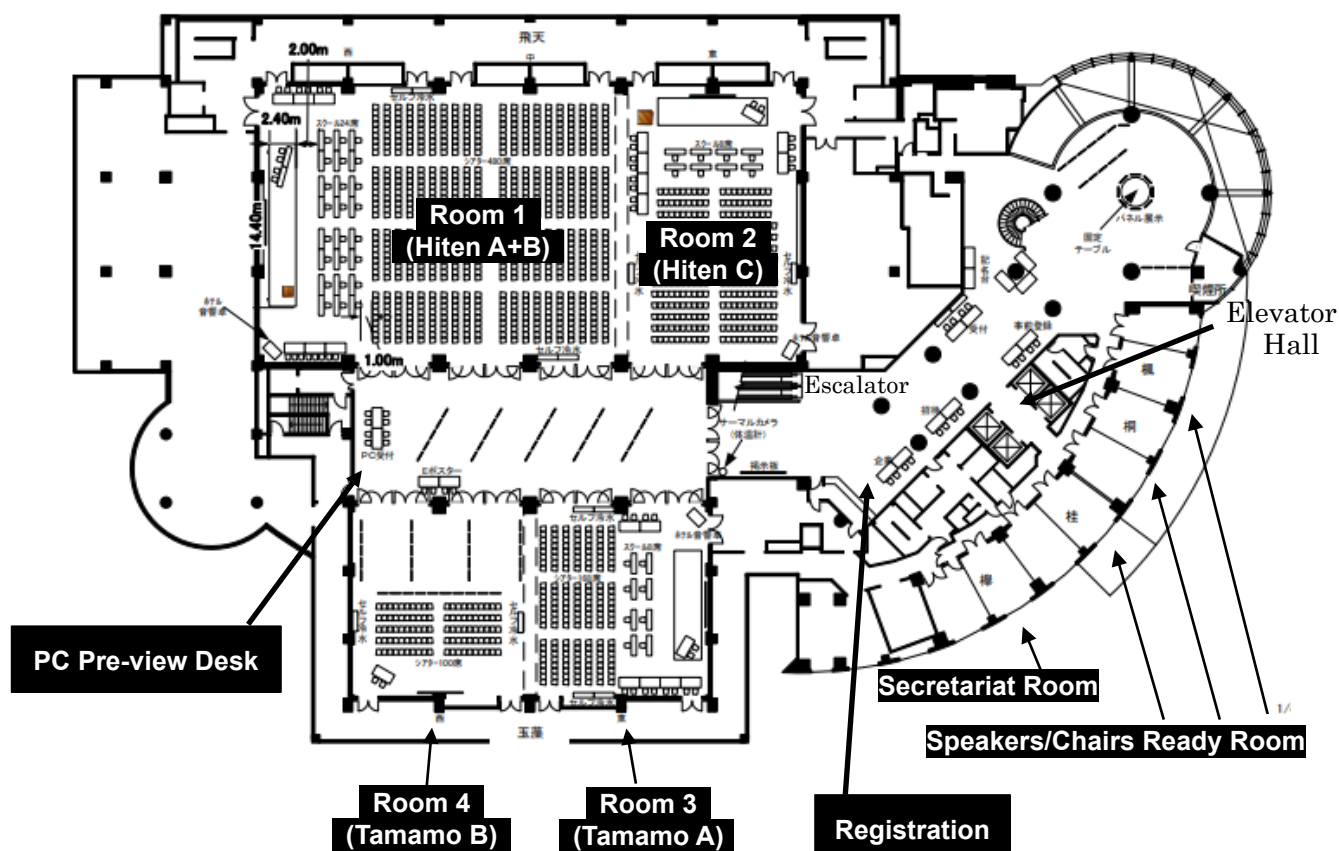
URL: <https://www.jrclement.co.jp/takamatsu/en/>



Location: Domestic flight: 1 hour 20 min. flight from Tokyo Haneda Airport to Takamatsu Airport
International flight: There are direct flights from Seoul, Shanghai, Hong Kong and Taipei to Takamatsu Airport. The time table is available at following URL.
<https://www.takamatsu-airport.com/en/timetable/int.php#group01>
From Takamatsu Airport to the conference venue, JR Hotel Clement Takamatsu:
45 min. ride by Airport Bus / 30 min. ride by Taxi



Floor Plan: 3F, JR Hotel Clement Takamatsu



Scientific Program will be held at the following rooms.

Room 1 (Hiten A+B), 3rd Floor: Special Lectures, Workshops

Room 2 (Hiten C), 3rd Floor: Workshops

Room 3 (Tamamo A), 3rd Floor: Workshops, Plenary Sessions

Room 4 (Tamamo B), 3rd Floor: Oral Free Papers, Poster Free Papers

Registration: Foyer, 3rd Floor

Poster Session: Room 4 (Tamamo B) and Foyer, 3rd Floor

Secretariat Room: “Keyaki”, 3rd Floor

Speakers/Chairs Ready Room: “Katsura” “Kiri” “Kaede”, 3rd Floor

Cloak: Foyer, 3rd Floor

PC Preview Desk: In front of Room 1 (Hiten A+B)

About new coronavirus infection prophylaxis

We hereby present our guidelines on coronavirus infection measures for onsite participants and cordially request your understanding and cooperation on this matter.

- Please wear your mask at all times, especially when visiting the venue.
- At the venue entrance, we will conduct temperature checks and sanitization.
- Anyone that records a temperature reading of more than 37.0 degrees will be refused entry to the venue.
- The following preventive measures against infection will be taken in the venue.
 - Temperature check, sanitization, mask wearing
 - Periodical indoor ventilation
 - Alcohol sterilization of items such as desks, chairs, doorknobs etc.
 - Setting acrylic boards
 - Maintenance of social distancing when moving around the venue

Instruction for Oral Presentation

The conference program will be presented as a hybrid style meeting.

- An invitation email containing information about the login will be sent to the presenters/moderators through the Zoom system. The login URL will be included in the invitation email.
- We would appreciate it if you could conduct a test connection ahead of the conference.
- Presentation time:
 - Workshop sessions' each presentation time is 13 minutes.
 - Keynote lectures' each presentation time is 15 minutes.
 - Oral Free Paper's each presentation time is 7-8 minutes (5-6 minutes presentation, 2 minutes discussion).
- After presentation, the discussion time (a question-and-answer session) will be held according to the moderator's instructions.

[For those who will participate at the onsite venue]

- Please complete your registration of presentation data at the Data Pre-View Desk until 1 hour before your presentation time.
- Please be seated at the "next speaker's seat" at least 10 minutes before your presentation. The seat will be located forward near the podium.
- The slides which you have submitted in advance for the presentation are prepared on the computer of the podium. Please operate the slides by yourself. Please note that the presenter tool is not available.
-

[For those who will attend online]

- Please join Zoom at least 20 minutes before your session begins.
- Please turn on the microphone and the camera only when you are speaking.
- The moderator will introduce the presenter at the beginning of each presentation.
- Then, the secretariat will start the presentation video. (In principle, you do not have to share your presentation by yourself.)
- After finishing the presentation, online viewers will send textual questions to the Q & A column, so please follow the moderator's instructions and answer those questions.
- The following environment is recommended.
 - Create the image resolution in XGA (1024 x 768).
 - Microsoft PowerPoint (2019) can be used as the application software.
 - The fonts that come standard with Microsoft PowerPoint, Times, Arial are recommended.

[Precautions]

- Do not post, modify, distribute or reproduce copyrighted material, trademarks, portrait rights or other property rights in any way without the prior written consent of the owners of these property rights.

- Regarding citations, please specify the source of the citation.
- Please exert caution regarding the protection of personal information such as name, age, surgery date, etc. This could lead to the identification of an individual.

Instruction for Chairs

The conference program will be presented as a hybrid style meeting.

- An invitation email that contains information about the login will be sent to the presenters/moderators through the Zoom system. The login URL will be included in the invitation email.
- At the real time webinar, the recorded lecture will be presented, and speakers/chairs are requested to join the discussion time. The presentation and Q & A session will be delivered live.
- After presentation, the discussion time (a question-and-answer session) will be held according to the moderator's instructions. The online viewer will send questions in the Q & A column. The onsite participants will ask questions using the microphone at the conference hall.
- After the conference, the recorded video will be posted on the on-demand presentation page.

[For Chairs who will participate at the onsite conference venue]

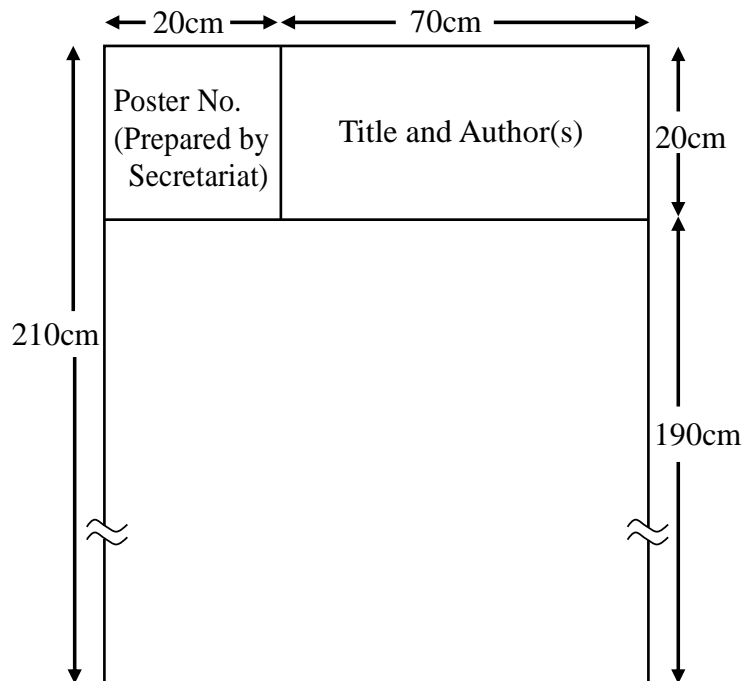
Please be seated at the "next chair's seat" at least 10 minutes before the session will start. The seat will be located forward near the stage.

[For Chairs who will attend online]

- Please join Zoom at least 20 minutes before your session begins.
- Please turn on the microphone and the camera only when you are speaking. Please mute the microphone otherwise.
- Please introduce the presenter at the beginning of each presentation. Then, the secretariat will start the presentation video, or the speaker will start his/her presentation on-site.
- After finishing the presentation, please turn on the microphone and camera again. Online viewers will send textual questions to the Q&A column, and the onsite participants will ask questions using the microphone in the conference room. So please convey those questions and moderate the discussion.
- The following environment is recommended.
 - Create the image resolution in XGA (1024 x 768).
 - Microsoft PowerPoint (2019) can be used as the application software.
 - The fonts that come standard with Microsoft PowerPoint, Times, Arial are recommended.

Instruction for On-Site Poster Presentation

Poster Panel



Instruction for E-Poster Presentation

If you have any questions, please contact the secretariat below.

Contact: APASL Oncology 2022 Takamatsu Congress Secretariat
c/o Academia Support Japan

Email: info@apaslstc-takamatsu2022.org

Tel: +81-3-6380-0102 Fax: +81-3-6380-0103

URL <http://www.apaslstc-takamatsu2022.org>

Awards

Excellent papers will be awarded as “Presidential Award” or “Investigator Award”.

Awarding Ceremony: The Awardees of Free Papers will be presented during 19:30-20:30 (Japan Standard Time) on September 2 (Friday).

Presidential Award

“APASL Oncology 2022 Takamatsu Presidential Award” will be awarded to whom performed the most excellent presentation in APASL Oncology 2022 Takamatsu to encourage to further their research and progress.

Investigator Award

The purpose of the “APASL Oncology 2022 Takamatsu Investigator Award” is to praise outstanding examples of excellence amongst those involved in research training in the early stages of their career.

Travel Award

“APASL Oncology 2022 Takamatsu Travel Award” will be awarded to whom performed the excellent presentation traveling to the onsite venue in APASL Oncology 2022 Takamatsu.

Travel Award-Overseas (for overseas attendees who attend on-site)

Travel Award-Domestic (for domestic attendees who attend on-site)

Contact

APASL Oncology 2022 Takamatsu Scientific Secretariat

Department of Gastroenterology and Neurology,

Faculty of Medicine, Kagawa University, Japan

APASL Oncology 2022 Takamatsu Congress Secretariat

c/o Academia Support Japan

Email: info@apaslstc-takamatsu2022.org

Tel: +81-3-6380-0102 Fax: +81-3-6380-0103

APASL Central Office (APASL Secretariat-Tokyo)

Asian Pacific Association for the Study of the Liver [APASL]

1-24-7-920, Shinjuku, Shinjuku-ku, Tokyo, 160-0022 Japan

Email: apasl_secretariat@apasl.info

Tel: +81-3-5312-7686 Fax: +81-3-5312-7687

Memo

A series of horizontal dashed lines for writing.


Sponsors and Support Organization

The Organizing Committee of the APASL Oncology 2022 Takamatsu would like to express sincere gratitude to the following sponsors and organizations for supporting this conference.

Platinum Sponsor



AbbVie GK



Chugai Pharmaceutical Co., Ltd.

St. Martin's Hospital

Gold Sponsors



AI Medical Service Inc.



Eisai Co., Ltd.



Gilead Sciences K.K. Medical Affairs



MSD K.K.



Otsuka Pharmaceutical Co., Ltd.

Gold Sponsors

Artificial Dialysis Center Miyano
Kagawa Institute of Adult Medicine
Kinashi Obayashi Hospital
Mirai Hospital
Utazu Hospital
Zentsuji Maeda Hospital

In alphabetical order

Silver Sponsors

Asahikasei Pharma Co., Ltd.	Kagawa Saiseikai Hospital
Bayer Yakuhin, Ltd.	Kaisei Hospital
Centurion Medical Products Corp.	Kaken-Techno Co., Ltd.
Clinic Ikeda	Kato Hospital
Daiichi Sankyo Company, Limited	Kawauchi Hospital
Daikou Medical Center	KKR Takamatsu Hospital
FUJIFILM Corporation	Koujinkai Medical Corporation
Fujita Hospital	Kuwaya hospital
Hamamoto Clinic	Matsubara Hospital
Hito Medical Center	Medtronic Japan Co., Ltd.
Igawa Clinic	Mikamo Tanaka Hospital
Iwamoto Hospital	Miura Clinic
Iwasa Hospital	Miyarisan Pharmaceutical Co., Ltd.
Iwasaki Hospital	Mizobuchi Clinic
Japan Lifeline Co., Ltd.	Nakabayashi Hospital
Jinjukai Yoshida Hospital	Oguni Hospital
Kagawa Inoshita Hospital	Ohnishi Hospital
Kagawa Rosai Hospital	Okamura Isshindo Hospital

Olive Takamatsu Medical Clinic	Sysmex Corporation
Olympus Marketing, Inc.	Taisho Pharmaceutical Co., Ltd.
Osaka Hospital	Takabatake Hospital
Ritsurin Hospital	Takamatsu Heiwa Hospital
Sakakibara Heart Institute of Okayama	Takeda Pharmaceutical Company Limited
Sanko Hospital	Tsumura & Co.
Shikoku Chuken, Inc.	Win International Co., Ltd.
Siemens Healthineers Japan	Yashima General Hospital
Sumitomo Pharma Co., Ltd.	

In alphabetical order

Bronze Sponsors

Aska Pharmaceutical Co., Ltd.	Marugame Medical Center
Astellas Pharma Inc.	Morikawa Hospital
Date Hospital	Oka Hospital
EA Pharma Co., Ltd.	Osaka Hospital
Eli Lilly Japan K.K.	Sanuki Municipal Hospital
Kowa Company, Limited	Shodoshima Central Hospital
Kumegawa Hospital	Terumo Corporation
Maeda Hospital	Taiho Pharmaceutical Co., Ltd.

In alphabetical order

Support Organizations

The Japan Society of Hepatology
Takamatsu Convention Bureau

In alphabetical order

Program at a Glance **Day 1: September 1 (Thursday) 2022**

September 1 (Thursday)				
8:00	Room 1	Room 2	Room 3	Room 4
	8:30-8:40 Opening Ceremony			
	8:40-9:00 Opening Lecture			
9:00				
	9:10-10:40 Workshop 1 Carcinogenesis Post HCV Eradication	9:10-10:40 Workshop 2 Epidemiology of HCC in Asia	9:10-10:43 Workshop 3 MicroRNA and Gene Mutation in Liver Cancer (including HCC, CCC and Metastatic Liver Cancer)	9:10-10:00 Oral Free Papers 1
10:00				10:20-11:10 Oral Free Papers 2
	10:50-12:20 Workshop 4 Carcinogenesis Post HCV Eradication	10:45-12:20 Workshop 5 HBV Management - Protection for HCC Occurrence	10:50-12:20 Workshop 6 MicroRNA and Gene Mutation in Liver Cancer (including HCC, CCC and Metastatic Liver Cancer)	11:30-12:20 Oral Free Papers 3
11:00				
	12:30-13:30 Luncheon Seminar 1 (Chugai Pharmaceutical Co., Ltd.)	12:30-13:30 Luncheon Seminar 2 (Gilead Sciences K.K. Medical Affairs)		
13:00				
	13:50-14:30 President Lecture			
14:00				
	14:40-16:10 Workshop 7 Treatment of Early-Stage Hepatocellular Carcinoma	14:40-16:10 Workshop 8 Portal Hypertension-Associated Endoscopic Diagnosis and Therapy	14:40-16:10 Workshop 9 Molecular Mechanisms of Liver Cancer (including HCC, CCC and Metastatic Liver Cancer)	14:40-15:30 Oral Free Papers 4
15:00				
	16:20-17:50 Workshop 10 Treatment of Intermediate-stage Hepatocellular Carcinoma	16:20-17:50 Workshop 11 Diagnosis of HCC	16:20-17:50 Workshop 12 Molecular Mechanisms of Liver Cancer (including HCC, CCC and Metastatic Liver Cancer)	15:40-16:40 Oral Free Papers 5
16:00				
				16:50-18:00 Oral Free Papers 6
17:00				
18:00				

*E-Poster is available at website <https://www.apaslsc-takamatsu2022.org/index.html> during the conference term.

Program at a Glance **Day 2: September 2 (Friday) 2022**

September 2 (Friday)				
	Room 1	Room 2	Room 3	Room 4
8:00	8:00-9:00 Morning Seminar 1 (Otsuka Pharmaceutical Co., Ltd.)	8:00-9:00 Morning Seminar 2 (Asahi Kasei Pharma Corporation)		
9:00	9:10-10:40 Workshop 13 Treatment of Advanced Hepatocellular Carcinoma	9:10-10:40 Workshop 14 Treatment Strategies for Liver Cirrhosis	9:10-10:40 Workshop 15 Biomarker Research on Liver Cancer for Clinical Applications (including HCC, CCC and Metastatic Liver Cancer)	Poster Free Papers (Viewing)
10:00	10:50-12:20 Workshop 16 Treatment of Advanced Hepatocellular Carcinoma	10:50-12:20 Workshop 17 Treatment of Intermediate-stage Hepatocellular Carcinoma	10:50-12:20 Workshop 18 Biomarker Research on Liver Cancer for Clinical Applications (including HCC, CCC and Metastatic Liver Cancer)	
11:00	12:30-13:30 Luncheon Seminar 3 (AbbVie GK)	12:30-13:30 Luncheon Seminar 4 (Eisai Co., Ltd. / MSD K.K.)		
12:00	13:50-14:30 Special Lecture 1			
13:00	14:40-16:10 Workshop 19 Treatment of Intermediate-stage Hepatocellular Carcinoma	14:40-16:10 Workshop 20 Recent Advance in Endoscopic Biliary Drainage for Unresectable Malignant Hilar Biliary Obstruction	14:40-16:10 Workshop 21 Molecular Mechanisms of Liver Fibrosis	
14:00	16:20-17:50 Workshop 22 Treatment of Early-Stage Hepatocellular Carcinoma	16:20-17:50 Workshop 23 Recent Advance in Treatment Strategy for Intrahepatic Cholangiocarcinoma	16:20-17:50 Workshop 24 Molecular Mechanisms of Liver Fibrosis	
15:00				
16:00				
17:00				
18:00	18:30-19:30 Poster Workshop (at Room 4 and Foyer, 3rd Floor) 19:30-20:30 Awarding Ceremony (at Room 1)			

*E-Poster is available at website <https://www.apaslsc-takamatsu2022.org/index.html> during the conference term.

Program at a Glance **Day 3: September 3 (Saturday) 2022**

September 3 (Saturday)				
	Room 1	Room 2	Room 3	Room 4
8:00				
8:00-9:00	Morning Seminar 3 (AI Medical Service Inc.)	Morning Seminar 4 (Takeda Pharmaceutical Co., Ltd.)		
9:00				
9:10-10:40	Workshop 25 Lifestyle-related Diseases and HCC	Workshop 26 Treatment of Advanced Hepatocellular Carcinoma	Workshop 27 Molecular Mechanisms of Liver Cancer (including HCC, CCC and Metastatic Liver)	Poster Free Papers (Viewing)
10:00				
10:50-11:10	Special Lecture 2			
11:00				
11:20-12:50	Workshop 28 Lifestyle-related Diseases and HCC	Workshop 29 Treatment Strategies for Liver Cirrhosis	Plenary Session	
12:00				
12:50-13:00	Closing Ceremony			
13:00				

*E-Poster is available at website <https://www.apaslsc-takamatsu2022.org/index.html> during the conference term.

APASL Oncology 2022 Takamatsu

“Liver Cancer: Clinical and Basic Research”

Scientific Program



Scientific Program

Day 1: September 1 (Thursday) 2022

Room 1

8:30-8:40 Opening Ceremony

Opening Remarks: Dr. Tsutomu Masaki, President of APASL Oncology 2022 Takamatsu

8:40-9:00 Opening Lecture

Chair: Dr. Tsutomu Masaki

Opening & Congratulatory Remarks: “Mission of APASL”

Dr. Masao Omata (Japan)

9:10-10:40 Workshop 1: Carcinogenesis Post HCV Eradication

Chairs: Dr. Han-Chieh Lin (Taiwan) / Dr. Kazuaki Chayama (Japan) /

Dr. Naoya Sakamoto (Japan)

9:10-9:25 WS1-1 Keynote Lecture

Carcinogenesis Post HCV Eradication

Dr. Fumitaka Suzuki (Japan)

9:25-9:38 WS1-2

Pathogenesis and Characteristics of HCC development after HCV Cure

Dr. Ming-Lung Yu (Taiwan)

9:38-9:51 WS1-3

Post-SVR Events, compared to the APASL HCV Guidelines 2019 of Virus-Eradicated Patients by DAA on How to Monitor HCC Occurrence and HBV Reactivation

Dr. Tatsuo Kanda (Japan)

9:51-10:04 WS1-4

Exploring the Total Transcriptome Profile of the Liver after HCV Eradication

Dr. Haruhiko Takeda (Japan)

10:04-10:17 WS1-5

Overall (Liver and Other Organ) Cancer Incidence and Overall Survival after SVR; A Prospective Study on 651 Consecutive Cases

Dr. Shuntaro Obi (Japan)

10:17-10:30 WS1-6

Clinical Significance of Serum AFP after Eradication of Hepatitis C Virus in Patients with Severe Fibrosis-suppression of Inflammation, Improvement of Liver Function, and Hepatocarcinogenesis

Dr. Masatoshi Ishigami (Japan)

10:30-10:40 Discussion Time

10:50-12:20 Workshop 4: Carcinogenesis Post HCV Eradication

Chairs: Dr. Jin Mo Yang (Korea) / Dr. Nobuyuki Enomoto (Japan) / Dr. Tatsuya Kanto (Japan)

11:00-11:15 WS4-1 Keynote Lecture

Hepatocellular Carcinoma after Hepatitis C Viral Eradication

Dr. Yasuhiro Asahina (Japan)

11:15-11:28 WS4-2

Evolving Concepts of HCC Surveillance in the Era of Growing Patients with a Sustained Virological Response (SVR)

Dr. Massimo Giuseppe Colombo (Italy)

11:28-11:41 WS4-3

HCC Risk Stratification after Achieving HCV Eradication

Dr. Gamal Shiha (Egypt)

11:41-11:54 WS4-4

Preoperative M2BPGi Predicts Short-term and Long-term Outcome after Hepatic Resection for HCC in Patients Who Achieved SVR

Dr. Norifumi Harimoto (Japan)

11:54-12:07 WS4-5

Previous Liver Cancer History Produces a 13-fold Difference in Carcinogenesis, the Strongest Predictor: a 5-year Prospective Study on 651 SVR Patient in a Single Institute

Dr. Shuntaro Obi (Japan)

12:07-12:20 Discussion Time

12:30-13:30 Luncheon Seminar 1 (Sponsored by Chugai Pharmaceutical Co., Ltd.)

Chair: Dr. Kiyoshi Hasegawa (Japan)

Future Prospects for Hepatocellular Carcinoma Treatment Through Immune Control

Dr. Nobuhiro Nakamoto (Japan)

Recent Advances in Systemic Therapy for Unresectable Hepatocellular Carcinoma ~Atezolizumab Plus Bevacizumab Therapy in Real-World Practice~

Dr. Kaoru Tsuchiya (Japan)

13:50-14:30 President Lecture

Chair: Dr. Masao Omata (Japan)

Hepatocellular Carcinoma and MicroRNAs

Dr. Tsutomu Masaki (Japan)

14:40-16:10 Workshop 7: Treatment of Early-stage Hepatocellular Carcinoma

Chairs: Dr. Kazuhiro Nouso (Japan) / Dr. Koichi Takaguchi (Japan) /

Dr. Tadatoshi Takayama (Japan)

14:40-14:55 WS7-1 Keynote Lecture

Treatment of Early-stage Hepatocellular Carcinoma by Image-guided Ablation

Dr. Shuichiro Shiina (Japan)

14:55-15:08 WS7-2

Combination Therapy PEI and RFA (PEI-RFA) for the Treatment of HCC

Dr. Kazutaka Kurokohchi (Japan)

15:08-15:21 WS7-3

Percutaneous Radiofrequency Ablation in Early-stage Hepatocellular Carcinoma

Dr. Shinpei Sato (Japan)

15:21-15:34 WS7-4

Challenging Precise Ablation: Imaging Navigation Techniques with Contrast Enhanced US and Fusion Imaging

Dr. Yasunori Minami (Japan)

15:34-15:47 WS7-5

Radiofrequency Ablation for the Treatment of Early-stage HCC

Dr. Kazuya Kariyama (Japan)

15:47-16:00 WS7-6 Special Comment

Early Hepatocellular Carcinoma as an Entity of Surgical Cure

Dr. Tadatoshi Takayama (Japan)

16:00-16:10 Discussion Time

16:20-17:50 Workshop 10: Treatment of Intermediate-stage Hepatocellular Carcinoma

*Chairs: Dr. Diana A. Payawal (Philippines) / Dr. Masatoshi Ishigami (Japan) /
Dr. Masayuki Kurosaki (Japan)*

16:20-16:33 WS10-1

Update on Treatment of Intermediate-stage Hepatocellular Carcinoma

Dr. George Lau (China)

16:33-16:46 WS10-2

Systemic Therapy for Intermediate Stage Hepatocellular Carcinoma

Dr. Tomokazu Kawaoka (Japan)

16:46-16:59 WS10-3

Prognostic Prediction by Methylated-SEPT9 Assay in Patients with Intermediate-stage Hepatocellular Carcinoma Receiving Molecular Targeted Agents

Dr. Issei Saeki (Japan)

16:59-17:12 WS10-4

Impact of Early Lenvatinib Administration on Survival in Patients with Intermediate-stage

Dr. Toshifumi Tada (Japan)

17:12-17:25 WS10-5

Effectiveness of Porous Glass Membrane-pumping Emulsification Device in Transarterial Chemoembolization for Solitary Hepatocellular Carcinoma

Dr. Norihiro Imai (Japan)

17:25-17:50 Discussion Time

Day 1: September 1 (Thursday) 2022

Room 2

9:10-10:40 Workshop 2: Epidemiology of HCC in Asia

Chairs: Dr. Wan-Long Chuang (Taiwan) / Dr. Junko Tanaka (Japan) / Dr. Hiroshi Yatsuhashi (Japan)

9:10-9:23 WS2-1

Immunotherapy for CHB and Beyond

Dr. Mamun-Al Mahtab (Bangladesh)

9:23-9:36 WS2-2

Epidemiology, Genotype Distribution, Management of Viral Hepatitis and HCC in Mongolia

Dr. Oidov Baatarkhuu (Mongolia)

9:36-9:49 WS2-3

Epidemiological Aspects of HCC Prevention in Asia-Pacific

Dr. Manoj K. Sharma (India)

9:49-10:02 WS2-4

Epidemiology of Liver Cancer in Thailand

Dr. Tawesak Tanwandee (Thailand)

10:02-10:15 WS2-5

Changing Viral Etiology of Hepatocellular Carcinoma in Taiwan

Dr. Wan-Long Chuang (Taiwan)

10:15-10:28 WS2-6

Changing Epidemiology of Hepatocellular Carcinoma in Japan

Dr. Ryosuke Tateishi (Japan)

10:28-10:40 Discussion Time

10:45-12:20 Workshop 5: HBV Management -Protection for HCC Occurrence

Chairs: Dr. Jia-Horng Kao (Taiwan) / Dr. Yasuhito Tanaka (Japan) /

Dr. Hiroshi Yotsuyanagi (Japan)

10:45-11:00 WS5-1 Keynote Lecture

Effect of KIR-HLA Pairs on Hepatocellular Carcinoma in Patients with Chronic Hepatitis B

Dr. Takeji Umemura (Japan)

11:00-11:13 WS5-2

Primary Prevention of HBV-related HCC

Dr. Jia-Horng Kao (Taiwan)

11:13-11:26 WS5-3

HCC Caused by Hepatitis Delta Virus Infection in Asia-Pacific

Dr. Saeed Hamid (Pakistan)

11:26-11:39 WS5-4

Trends of Hepatitis B Virus Genotype Distribution in Chronic Hepatitis B Patients in Japan

Dr. Kiyooki Ito (Japan)

11:39-11:52 WS5-5

The Prediction Model of HBV-HCC During Anti-viral Therapy

Dr. Hong You (China)

11:52-12:05 WS5-6

A Novel Prediction Model of HCC Development in Chronic Hepatitis B Patients Under Antiviral Therapy

Dr. Takanori Suzuki (Japan)

12:05-12:18 WS5-7 Special Comment

HBV Management -protection for HCC Occurrence

Dr. Atsushi Tanaka (Japan)

12:30-13:30 Luncheon Seminar 2 (Sponsored by Gilead Sciences K.K. Medical Affairs)

Chair: Dr. Norifumi Kawada (Japan)

Role of Medical AI for the Management of Liver Disease in the Era of Viral Elimination- Development of AI-aided US Diagnosis for Focal Liver Lesions –

Dr. Naoshi Nishida (Japan)

14:40-16:10 Workshop 8: Portal Hypertension-associated Endoscopic Diagnosis and Therapy

Chairs: Dr. Shiv Kumar Sarin (India) / Dr. Hideki Kobara (Japan) / Dr. Hajime Takatori (Japan)

14:40-14:55 WS8-1 Keynote Lecture

Endoscopic Treatment for Esophageal and Gastric Varices in Japan

Dr. Takuto Hikichi (Japan)

14:55-15:08 WS8-2

Gel-immersion Endoscopic Ultrasound for Esophageal Varices

Dr. Tsunetaka Kato (Japan)

15:08-15:21 WS8-3

Endoscopic Glue Injection Therapy for Gastric Varices

Dr. Takumi Yanagita (Japan)

15:21-15:34 WS8-4

The Efficacy of Same-day EVL Just Preceding ESD for Early Esophageal Cancer Complicated with Esophageal Varix

Dr. Takanori Matsui (Japan)

15:34-15:47 WS8-5

Changes in Endoscopic Findings of Portal Hypertension Due to Splenectomy and Partial Splenic Artery Embolization

Dr. Masaki Miyazawa (Japan)

15:47-16:00 WS8-6 Special Comment

Advanced Role of Endoscopic Ultrasound for Portal Hypertension

Dr. Atsushi Irisawa (Japan)

16:00-16:10 Discussion Time

16:20-17:50 Workshop 11: Diagnosis of HCC

Chairs: Dr. Hiroshi Aikata (Japan) / Dr. Yoichi Hiasa (Japan) / Dr. Akinobu Takaki (Japan)

16:20-16:33 WS11-1

Moleculopathological Spectrum between Hepatocellular Carcinoma and Intrahepatic Cholangiocarcinoma

Dr. Young Nyun Park (Korea)

16:33-16:46 WS11-2

Validation Trial to Diagnose Liver Tumors by LI-RADS Criteria

Dr. Masashi Hirooka (Japan)

16:46-16:59 WS11-3

Comparison of Modified CEUS LI-RADS with Sonazoid and CT/MRI LI-RADS for Diagnosis of Hepatocellular Carcinoma

Dr. Katsutoshi Sugimoto (Japan)

16:59-17:12 WS11-4

Diagnose of HCC and for Evaluation of RFA Therapeutic Effect Using Workstation

Dr. Chikara Ogawa (Japan)

17:12-17:25 WS11-5

The Usefulness of Ultrasound Elastography in Predicting Long-term Prognosis and the Appearance of Hepatocellular Carcinoma

Dr. Leona Osawa (Japan)

17:25-17:38 WS11-6

The Utility of Mannose-binding Lectin 2 Loss in the Progression and Diagnosis of Hepatocellular Carcinoma

Dr. Dong Thanh Le (Japan)

17:38-17:50 Discussion Time

Day 1: September 1 (Thursday) 2022

Room 3

9:10-10:43 Workshop 3: MicroRNA and Gene Mutation in Liver Cancer (including HCC, CCC and Metastatic Liver Cancer)

Chairs: Dr. Shin Maeda (Japan) / Dr. Hayato Nakagawa (Japan) / Dr. Keisuke Tateishi (Japan)

9:10-9:25 WS3-1 Keynote Lecture

Genomic and Molecular Profiling-Based Personalized Medicine for Liver Cancer

Dr. Hayato Nakagawa (Japan)

9:25-9:38 WS3-2

Dynamics of Circulating miR-122 Predict Liver Cancer and Mortality in Patients with Histopathologically Confirmed NAFLD

Dr. Norio Akuta (Japan)

9:38-9:51 WS3-3

Galectin-9 Suppresses the Growth of Hepatocellular Carcinoma via Apoptosis in Vitro and in Vivo

Dr. Koji Fujita (Japan)

9:51-10:04 WS3-4

Examination of NASH -related Liver Carcinogenesis from Non -developed Fibrosis

Dr. Satoru Hagiwara (Japan)

10:04-10:17 WS3-5

Clinical Utility of Comprehensive Genomic Profiling in Patients with Hepatocellular Carcinoma

Dr. Shun Ishido (Japan)

10:17-10:30 WS3-6

Effect of Nimbolide on miRNAs 21, 145, and 221 Expressions and Tight Junction Integrity in an Experimental Liver Cancer

Dr. Balasubramaniyan Vairappan (India)

10:30-10:43 WS3-7

Comparison of Clonality of HCC Arising before and after DAA

Dr. Kenji Amemiya (Japan)

10:50-12:20 Workshop 6: MicroRNA and Gene Mutation in Liver Cancer (including HCC, CCC and Metastatic Liver Cancer)

Chairs: Dr. Takao Itoi (Japan) / Dr. Asahiro Morishita (Japan) / Dr. Yoshiyuki Ueno (Japan)

10:50-11:03 WS06-1

The Suppression Role of Aspirin in Hepatocellular Carcinoma Cells Partially by microRNA Alterations

Dr. Ting Ting Shi (China)

11:03-11:16 WS6-2

Serum microRNA-125a-5p as a Potential Biomarker of HCV-associated Hepatocellular Carcinoma

Dr. Kyoko Oura (Japan)

11:16-11:29 WS6-3

TERT Promotor Mutation in Serum cfDNA Predicts Non-viral Liver Cancer with Fatty Liver Disease

Dr. Norio Akuta (Japan)

11:29-11:42 WS6-4

In Vitro Study on the Function of Sloan Kettering Institute Gene in Suppression of Intrahepatic Cholangiocarcinoma Growth

Dr. Etsushi Kawamura (Japan)

11:42-11:55 WS6-5

Circulating microRNA-1246 as a Possible Biomarker for Early Tumor Recurrence of Hepatocellular Carcinoma

Dr. Makoto Chuma (Japan)

11:55-12:08 WS6-6

Validation of Genomic Analysis and EOB-MRI (RER)

Dr. Kenji Amemiya (Japan)

12:08-12:20 WS6-7

A New Therapeutic Strategy Using Circulating MicroRNA that Predicts Drug Resistance of Atezolizumab + Bevacizumab for the Treatment of Advanced Hepatocellular Carcinoma

Dr. Asahiro Morishita (Japan)

14:40-16:10 Workshop 9: Molecular Mechanisms of Liver Cancer (including HCC, CCC and Metastatic Liver Cancer)

Chairs: Dr. Shuichi Kaneko (Japan) / Dr. Shinji Tanaka (Japan)

14:40-14:55 WS9-1 Keynote Lecture

Molecular and Immunological Mechanisms of Liver Cancer; Preclinical Studies for Clinical Application

Dr. Shinji Tanaka (Japan)

14:55-15:08 WS9-2

Multionics Profiling Identifies the Link between Intratumoral Steatosis and Immune-exhausted Immunotherapy-susceptible Tumor Immune Microenvironment in HCC

Dr. Takahiro Kodama (Japan)

15:08-15:21 WS9-3

Molecular Mechanisms Underlying Lenvatinib Treatment in Sorafenib-Resistant Hepatocellular Carcinoma Cells

Dr. Ting Ting Shi (China)

15:21-15:34 WS9-4

Examination of NASH -related Liver Carcinogenesis from Non -developed Fibrosis

Dr. Satoru Hagihara (Japan)

15:34-15:47 WS9-5

Autophagy and Metabolic Reprogramming Regulated by PKC λ /t in Hepatocellular Carcinoma

Dr. Yotaro Kudo (Japan)

15:47-16:00 WS9-6

Interplay between Metabolism and Epigenetics in Biliary Epithelial Cells Induced by Mutant IDH1

Dr. Hiroaki Fujiwara (Japan)

16:00-16:10 Discussion Time

16:20-17:50 Workshop 12: Molecular Mechanisms of Liver Cancer (including HCC, CCC and Metastatic Liver Cancer)

Chairs: Dr. Yoshihito Ito (Japan) / Dr. Naoya Kato (Japan) / Dr. Kazuhiko Nakao (Japan)

16:20-16:35 WS12-1 Keynote Lecture

Molecular Mechanisms of Liver Cancer

Dr. Shuichi Kaneko (Japan)

16:35-16:48 WS12-2

Inflammation in Hepatocellular Carcinoma-Mechanisms and Therapeutic Targets

Dr. Rakhi Maiwall (India)

16:48-17:01 WS12-3

Role of Metastatic Tumor Antigen 1 in HBV-related HCC

Dr. Chun-Jen Liu (Taiwan)

17:01-17:14 WS12-4

Serum miRNAs Predicting Sustained HBs Antigen Reduction 48 Weeks after Pegylated Interferon Therapy in HBe Antigen-Negative Patients

Dr. Koji Fujita (Japan)

17:14-17:27 WS12-5

Hepatoma-derived Growth Factor as a Potential Target Molecule for the Treatment of Hepatocellular Carcinoma

Dr. Hirayuki Enomoto (Japan)

17:27-17:40 WS12-6

Sustained Hepatocyte p53 Activation Induces Non-Cell Autonomous Liver Carcinogenesis

Dr. Hayato Hikita (Japan)

17:40-17:50 Discussion Time

Day 2: September 2 (Friday) 2022

Room 1

8:00-9:00 Morning Seminar 1 (Sponsored by Otsuka Pharmaceutical Co., Ltd.)

Chair: Dr. Koichi Takaguchi (Japan)

Total Therapeutic Management of Liver Disease

Dr. Atsushi Hiraoka (Japan)

9:10-10:40 Workshop 13: Treatment of Advanced Hepatocellular Carcinoma

Chairs: Dr. Masafumi Ikeda (Japan) / Dr. Shuntaro Obi (Japan) / Dr. Tatsuya Yamashita (Japan)

9:10-9:23 WS13-1

Immunotherapy for Advanced Hepatocellular Carcinoma

Dr. Kazuomi Ueshima (Japan)

9:23-9:36 WS13-2

Impact of Viral Burden and Trajectory of Hepatocellular

Dr. Hasmik Ghazinyan (Armenia)

9:36-9:49 WS13-3

Combination of Systemic and Locoregional Therapy in Advanced Hepatocellular Carcinoma

Dr. Kaoru Tsuchiya (Japan)

9:49-10:02 WS13-4

The Role of Hepatic Arterial Infusion Chemotherapy Using 5-FU in the Era of Cancer Immunotherapy

Dr. Kuniaki Arai (Japan)

10:02-10:15 WS13-5

The CRAFTY Score Predicts Prognosis of Hepatocellular Carcinoma Patients Receiving Atezolizumab and Bevacizumab: A Multicenter Retrospective Study

Dr. Takeshi Hatanaka (Japan)

10:15-10:28 WS13-6

Real-World Outcome of Cabozantinib in Patients with Unresectable Hepatocellular Carcinoma

Dr. Tsubasa Nobusawa (Japan)

10:28-10:40 Discussion Time

10:50-12:20 Workshop 16: Treatment of Advanced Hepatocellular Carcinoma

Chairs: Dr. Ryosuke Tateishi (Japan) / Dr. Akihito Tsuji (Japan) / Dr. Joji Tani (Japan)

10:50-11:03 WS16-1

Treatment of Advanced Hepatocellular Carcinoma

Dr. Rino Gani (Indonesia)

11:03-11:16 WS16-2

Management of HCC Patients with Portal Vein Thrombosis

Dr. Shiv K Sarin (India)

11:16-11:29 WS16-3

Recently Proven Evidence of Hepatic Arterial Infusion Chemotherapy for Hepatocellular Carcinoma

Dr. Takeshi Terashima (Japan)

11:29-11:42 WS16-4

Hepatic Arterial Infusion Chemotherapy for Long-term Prognosis in Patients with Advanced Hepatocellular Carcinoma Involving Vascular Invasion

Dr. Hiroaki Nagamatsu (Japan)

11:42-11:55 WS16-5

The Outcome of the Patients Treated with First-line Systemic Therapy According to Functional Hepatic Reserve

Dr. Shinsuke Uchikawa (Japan)

11:55-12:08 WS16-6

The Survival Rate and the Recurrence Pattern of Hepatocellular Carcinoma After Orthotopic Liver Transplantation

Dr. Masahiko Sue (Japan)

12:08-12:20 Discussion Time

12:30-13:30 Luncheon Seminar 3 (Sponsored by AbbVie GK)

Chair: Dr. Hitoshi Yoshiji (Japan)

Real-world Direct-acting Antivirals Treatment for Chronic Hepatitis C Patients with Chronic Kidney Disease in Japan

Dr. Masanori Atsukawa (Japan)

Real-World Evidences of Systemic Therapy for Hepatocellular Carcinoma

Dr. Masayuki Kurosaki (Japan)

13:50-14:30 Special Lecture 1

Chair: Dr. Tsutomu Masaki (Japan)

Development of a Therapeutic Vaccine for Familial Adenomatous Polyposis

Dr. Akira Nishiyama (Japan)

14:40-16:10 Workshop 19: Treatment of Intermediate-stage Hepatocellular Carcinoma

Chairs: Dr. Masatoshi Kudo (Japan) / Dr. Mitsuhiro Moriyama (Japan) / Dr. Ken Shirabe (Japan)

14:40-14:53 WS19-1

Treatment Challenges in Intermediate Stage of HCC in the Era of Systemic Therapy

Dr. Cosmas Rinaldi A Lesmana (Indonesia)

14:53-15:06 WS19-2

The Treatment Strategy for HCCs that had Equal to Intermediate-stage Intra-Hepatic Tumor Status with or without Extrahepatic Spread in the Era of Molecular-targeted Agents

Dr. Yusuke Kawamura (Japan)

15:06-15:19 WS19-3

Treatment Strategy of Systemic drug Therapy for Intermediate Hepatocellular Carcinoma Aiming Curative Conversion Therapy

Dr. Tetsu Tomonari (Japan)

15:19-15:32 WS19-4

Clinical Outcomes of Atezolizumab plus Bevacizumab in Patients with BCLC B Stage Hepatocellular Carcinoma

Dr. Teiji Kuzuya (Japan)

15:32-15:45 WS19-5

The Role of MTAs for HCC with BCLC-B

Dr. Kazuto Tajiri (Japan)

15:45-15:58 WS19-6

Relationship between Early Bevacizumab Interruption and Clinical Outcome of Atezolizumab plus Bevacizumab for Advanced Hepatocellular Carcinoma

Dr. Takeshi Hatanaka (Japan)

15:58-16:10 Discussion Time

16:20-17:50 Workshop 22: Treatment of Early-stage Hepatocellular Carcinoma

Chairs: Dr. Teerha Piratvisuth (Thailand) / Dr. Atsumasa Komori (Japan) /

Dr. Shuichiro Shiina (Japan)

16:20-16:35 WS22-1 Keynote Lecture

Treatment of Early Stage Hepatocellular Carcinoma

Dr. Namiki Izumi (Japan)

16:35-16:48 WS22-2

Examination of Prognosis by Age in HCC in Early Stage-significance of RFA by Age

Dr. Hironori Ochi (Japan)

16:48-17:01 WS22-3

Microwave Thermosphere Ablation for Early-stage Hepatocellular Carcinoma

Dr. Hideyuki Tamai (Japan)

17:01-17:14 WS22-4

Prognostic Impact of Postoperative Complications in Patients Undergoing Hepatic Resection for Hepatocellular Carcinoma

Dr. Junichi Arita (Japan)

17:14-17:27 WS22-5

The Role of Repeated RFA in the Long-Term Survival of Hepatocellular Carcinoma

Dr. Makoto Moriyama (Japan)

17:27-17:50 Discussion Time

Day 2: September 2 (Friday) 2022

Room 2

8:00-9:00 Morning Seminar 2 (Sponsored by Asahi Kasei Pharma Corporation)

Chair: Dr. Keiichi Okano (Japan)

Treatment Strategies for Acute Cholangitis

Dr. Hideki Kamada (Japan)

9:10-10:40 Workshop 14: Treatment Strategies for Liver Cirrhosis

Chairs: Dr. Jose Sollano (Philippines) / Dr. Ian H. Cua (Philippines) /

Dr. Satoru Kakizaki (Japan) / Dr. Shigehiro Kokubu (Japan)

9:10-9:23 WS14-1

Roles of Levocarnitine on the Survival of Patients Who Undergo Cell-free and Concentrated Ascites Reinfusion Therapy: A Preliminary Study

Dr. Akio Moriya (Japan)

9:23-9:36 WS14-2

Our Potent Strategies for Inhibiting the Progression of Hepatic Fibrosis in Patients with Autoimmune Liver Disease

Dr. Kei Moriya (Japan)

9:36-9:49 WS14-3

Usefulness of Vitamin D Measurement and Effectiveness of Vitamin D Supplementation

Dr. Tomomi Okubo (Japan)

9:49-10:02 WS14-4

Transition of Treatment Selection for Primary Liver Cancer and Decompensated Cirrhosis in Multiple Admissions: Analysis of a Nationwide Registry for Advanced Liver Diseases (REAL)

Dr. Kazuya Okushin (Japan)

10:02-10:15 WS14-5

Persistent Cryoglobulinemia after Antiviral Treatment is Associated with Advanced Fibrosis in Chronic Hepatitis C

Dr. Batbold Batsaikhan (Mongolia)

10:15-10:40 Discussion Time

10:50-12:20 Workshop 17: Treatment of Intermediate-stage Hepatocellular Carcinoma

Chairs: Dr. George Lau (China) / Dr. Namiki Izumi (Japan) / Dr. Keisuke Hino (Japan)

10:50-11:05 WS17-1 Keynote Lecture

Treatment of Intermediate-stage Hepatocellular Carcinoma

Dr. Masatoshi Kudo (Japan)

11:05-11:18 WS17-2

Treatment of Intermediate-stage Hepatocellular Carcinoma

Dr. Lai Wei (China)

11:18-11:31 WS17-3

A Predictive Marker for Intermediate-Stage Hepatocellular Carcinoma Patients with Transarterial Chemoembolization Refractory

Dr. Takanori Ito (Japan)

11:31-11:44 WS17-4

Treatment for Intermediate Stage Hepatocellular Carcinoma Patients Consisting of Diverse Conditions

Dr. Sadahisa Ogasawara (Japan)

11:44-11:57 WS17-5

Therapeutic Outcome of Atezolizumab and Bevacizumab Treatment for BCLC Intermediate Stage HCC Patients Classified as beyond up to Seven Criteria: A Multicenter Analysis

Dr. Takeshi Hatanaka (Japan)

11:57-12:20 Discussion Time

12:30-13:30 Luncheon Seminar 4 (Sponsored by Eisai Co., Ltd. / MSD K.K.)

Chair: Dr. Junji Furuse (Japan)

Importance of Keeping the Balance between Therapeutic Effects and Adverse Events in Lenvatinib for HCC ~Refinement of Administration Schedule and Combination with Trans-Arterial Therapy~

Dr. Hideki Iwamoto (Japan)

The Dawn of New Surgical Strategy for Advanced Hepatocellular Carcinoma

Dr. Junichi Shindoh (Japan)

14:40-16:10 Workshop 20: Recent Advance in Endoscopic Biliary Drainage for Unresectable Malignant Hilar Biliary Obstruction

Chairs: Dr. Hiroyuki Isayama (Japan) / Dr. Hideki Kamada (Japan) / Dr. Yousuke Nakai (Japan)

14:40-14:55 WS20-1 Keynote Lecture

History and Advance in the Endoscopic Treatment of Malignant Hilar Biliary Strictures

Dr. Hirofumi Kawamoto (Japan)

14:55-15:08 WS20-2

Endoscopic Biliary Drainage for Long-term Follow-up for Unresectable Malignant Hilar Biliary Obstruction: Side-by-Side vs. Stent-in-Stent

Dr. Daisuke Namima (Japan)

15:08-15:21 WS20-3

Retrospective Evaluation of Slim Fully Covered Self-Expandable Metallic Stent for Unresectable Malignant Hilar Biliary Obstruction

Dr. Sho Takahashi (Japan)

15:21-15:34 WS20-4

Optimal Biliary Drainage for Unresectable Malignant Hilar Biliary Obstruction based on measuring Liver Volume using 3D Image Analysis System

Dr. Kousaku Morimoto (Japan)

15:34-15:47 WS20-5

A Comparative Study of Bilateral Stenting for Hilar Malignant Biliary Obstruction: SIS above the Papilla vs SBS across the Papilla

Dr. Rintaro Fukuda (Japan)

15:47-16:10 Discussion Time

16:20-17:50 Workshop 23: Recent Advance in Treatment Strategy for Intrahepatic Cholangiocarcinoma

Chairs: Dr. Etsuro Hatano (Japan) / Dr. Keiichi Okano (Japan) / Dr. Naoki Sasahira (Japan)

16:20-16:33 WS23-1

A Review of Recent Advances in Chemotherapy for Intrahepatic Cholangiocarcinoma

Dr. Tsuyoshi Takeda (Japan)

16:33-16:46 WS23-2

Precision Medicine for Intrahepatic Cholangiocarcinoma

Dr. Hiroyuki Okuyama (Japan)

16:46-16:59 WS23-3

What is Best Indication for Surgery of Intrahepatic Cholangiocarcinoma?

Dr. Shunichi Ariizumi (Japan)

16:59-17:12 WS23-4

Efficacy of Surgical Management for Recurrent Intrahepatic Cholangiocarcinoma

Dr. Yuzo Umeda (Japan)

17:12-17:25 WS23-5

Preoperative Chemotherapy for the Patients with Advanced Intrahepatic Cholangiocarcinoma with Lymph Node Metastasis

Dr. Masao Nakajima (Japan)

17:25-17:38 WS23-6

Clinical Utility of Comprehensive Genomic Profiling in Advanced Liver Cancers

Dr. Yoshihito Kano (Japan)

17:38-17:51 WS23-7

Efficacy of New FP Therapy for Unresectable Advanced Intrahepatic Cholangiocarcinoma

Dr. Hiroto Ota (Japan)

Day 2: September 2 (Friday) 2022

Room 3

9:10-10:40 Workshop 15: Biomarker Research on Liver Cancer for Clinical Applications including HCC, CCC and Metastatic Liver Cancer

Chairs: Dr. Tung-Hung Su (Taiwan) / Dr. Masao Honda (Japan) / Dr. Shinya Maekawa (Japan)

9:10-9:23 WS15-1

Clinical Indications for Liquid Biopsy Using Cell Free DNA Content in the Pharmacotherapy of Advanced Hepatocellular Carcinoma

Dr. Masaru Muraoka (Japan)

9:23-9:36 WS15-2

Prediction of Liver Fibrosis and Carcinogenesis by Body Comparison Analysis by Bioelectrical Impedance Analysis

Dr. Hirohito Yoneyama (Japan)

9:36-9:49 WS15-3

Changes in Serum Growth Factors during Lenvatinib Predict the Post Progressive Survival in Patients with Unresectable Hepatocellular Carcinoma

Dr. Zijian Yang (Japan)

9:49-10:02 WS15-4

Liquid Biopsy Test Based on Methylated SEPT9 for Surveillance of NonBnonC Hepatocellular Carcinoma

Dr. Issei Saeki (Japan)

10:02-10:15 WS15-5

Selection of Anti-PD-1 Antibody Effective Group Using Tumor Immunological Microenvironment

Dr. Masahiro Morita (Japan)

10:15-10:28 WS15-6

SERUM IP-10/CXCL10 is a Useful Predictor for Post-DAA Treatment Liver Function and HCC Development in HCV Patients

Dr. Shinya Maekawa (Japan)

10:28-10:40 Discussion Time

10:50-12:20 Workshop 18: Biomarker Research on Liver Cancer for Clinical Applications (including HCC, CCC and Metastatic Liver Cancer)

Chairs: Dr. Yasunari Nakamoto (Japan) / Dr. Taro Takami (Japan) / Dr. Tetsuo Takehara (Japan)

10:50-11:03 WS18-1

Analysis of Biomarkers Related Treatment Response for HCC

Dr. Goki Suda (Japan)

11:03-11:16 WS18-2

Phosphorylation of hTERT at Threonine 249 is a Novel Tumor Biomarker of Aggressive Cancer with Poor Prognosis in Multiple Organs

Dr. Juanjuan Ye (Japan)

11:16-11:29 WS18-3

Clinical Significance of Genetic Differentiation between MC and IM in Multinodular HCCs

Dr. Yuji Iimuro (Japan)

11:29-11:42 WS18-4

Change in α -fetoprotein Level as a Predictor of Response for Patients who Received Ramucirumab Therapy

Dr. Yutaka Yasui (Japan)

11:42-11:55 WS18-5

Peripheral Blood Immune Checkpoint Molecules in the Treatment of Advanced Hepatocellular Carcinoma

Dr. Yutaka Yasui (Japan)

11:55-12:08 WS18-6

Posthepatectomy Liver Failure can be Predicted by Combination of the ALBI Score and Liver Resection Percentage

Dr. Kazuhiro Takahashi (Japan)

12:08-12:20 Discussion Time

14:40-16:10 Workshop 21: Molecular Mechanisms of Liver Fibrosis

Chairs: Dr. Sumiko Nagoshi (Japan) / Dr. Masahito Shimizu (Japan) /

14:40-14:55 WS21-1 Keynote Lecture

Recent Advances in the Mechanism of Liver Fibrosis

Dr. Norifumi Kawada (Japan)

14:55-15:08 WS21-2

Impact on Portal Hypertension in Patients with Cirrhosis Associated with Hepatitis C after Achieving a Sustained Virologic Response

Dr. Yoshio Tokumoto (Japan)

15:08-15:21 WS21-3

Steatotic and Fibrotic Liver and Related Conditions in Senescence-accelerated Mice

Dr. Yohei Shirakami (Japan)

15:21-15:34 WS21-4

Therapies Using Mesenchymal Stem Cell and Their Small Extracellular Vesicle for Liver Cirrhosis

Dr. Atsunori Tsuchiya (Japan)

15:34-16:10 Discussion Time

16:20-17:50 Workshop 24: Molecular Mechanisms of Liver Fibrosis

Chairs: Dr. Satoshi Mochida (Japan) / Dr. Shuji Terai (Japan)

16:20-16:35 WS24-1 Keynote Lecture

Molecular Mechanism of Liver Fibrosis ~ Possible Involvement of Neovascularization and Gut-liver Axis ~

Dr. Hitoshi Yoshiji (Japan)

16:35-16:48 WS24-2

The Potential of Soluble CD14 in Discriminating Nonalcoholic Steatohepatitis from Nonalcoholic Fatty Liver Disease

Dr. Kenichi Morikawa (Japan)

16:48-17:01 WS24-3

The Usefulness of Hepatic Shear Wave Velocity for Noninvasive Prediction of Esophageal Varices in Patients with Chronic Liver Diseases

Dr. Shouichi Namikawa (Japan)

17:01-17:14 WS24-4

Supplementation of Five Amino Acids Promotes Myoblast Differentiation in Cirrhotic Condition in Vitro

Dr. Masaaki Mino (Japan)

17:14-17:27 WS24-5

Estimation of Liver Fibrosis with Machine Learning Using Ultrasonography

Dr. Shinya Nishida (Japan)

17:27-17:50 Discussion Time

Day 3: September 3 (Saturday) 2022

Room 1

8:00-9:00 Morning Seminar 3 (Sponsored by AI Medical Service Inc.)

“The Impact of AI on Tomorrow’s Endoscopic Medicine”

Chair: Dr. Masahito Shimizu (Japan)

Current Status and Future of AI in Digestive Disease

Dr. Yuzo Kodama (Japan)

Taking on the World with Japanese Endoscopic AI

Dr. Tomohiro Tada (Japan)

Special Comment Dr. Tetsuji Takayama (Japan)

9:10-10:40 Workshop 25: Lifestyle-related Diseases and HCC

Chairs: Dr. Takumi Kawaguchi (Japan) / Dr. Makoto Nakamuta (Japan) /

Dr. Katsutoshi Tokushige (Japan)

9:10-9:23 WS25-1

Serum Mac-2 Binding Protein is a Useful Prediction Biomarker for the Development of Hepatocellular Carcinoma and Colorectal Cancer in Patients with NAFLD

Dr. Yoshihiro Kamada (Japan)

9:23-9:36 WS25-2

Effects of Fat and Sugar on HCC Development in Hepatitis B Disease

Dr. Man-Fung Yuen (China)

9:36-9:49 WS25-3

Clinical Characteristics of NAFLD-related HCC in Japan

Dr. Yoshio Sumida (Japan)

9:49-10:02 WS25-4

Characteristics of Fatty Liver Disease-related Hepatocellular Carcinoma and Genetic Background in Japan

Dr. Tomomi Kogiso (Japan)

10:02-10:15 WS25-5

Clinical Characteristics of Hepatocellular Carcinoma in Biopsy-confirmed NAFLD: Sub-analysis of CLIONE in Asia

Dr. Hideki Fujii (Japan)

10:15-10:28 WS25-6

A Bird's-eye View on Lifestyle Disease Across Specialties; Construction of Integrated Real-World Data across Organs and Clinical Departments

Dr. Hitoshi Mochizuki (Japan)

10:28-10:40 Discussion Time

10:50-11:10 Special Lecture 2

Chair: Dr. Akira Nishiyama (Japan)

Novel Diagnostic Imaging System by Casually Watching Over Peoples with Invisible Lights for Non-invasive Blood Glucose Sensors

Dr. Ichiro Ishimaru (Japan)

11:20-12:50 Workshop 28: Lifestyle-related Diseases and HCC

Chairs: Dr. Kenichi Ikejima (Japan) / Dr. Masafumi Ono (Japan) / Dr. Masashi Yoneda (Japan)

11:20-11:35 WS28-1 Keynote Lecture

MAFLD Enhances Clinical Practice for HCC in the Asia-Pacific Region

Dr. Takumi Kawaguchi (Japan)

11:35-11:48 WS28-2

Glycine Intake Ameliorates Steatohepatitis and Prevents Liver Carcinogenesis in Hepatocyte-specific Pten-deficient Mice

Dr. Kazuyoshi Kon (Japan)

11:48-12:01 WS28-3

Characteristics of Patients with Hepatocellular Carcinoma that Developed following a Diagnosis of Nonalcoholic Steatohepatitis by Liver Biopsy

Dr. Miwa Kawanaka (Japan)

12:01-12:14 WS28-4

Gut Microbiota and NASH-related Hepatocellular Carcinoma

Dr. Takashi Kobayashi (Japan)

12:14-12:27 WS28-5

SGLT2 Inhibitor Suppressed Proliferation of Hepatocellular Carcinoma via Regulation of Metabolic Reprogramming and Tumor-Releasing Chemokines/Cytokines: A Metabolomic and Proteomic Analysis

Dr. Dan Nakano (Japan)

12:27-12:40 WS28-6 Special Comment

What Can We Do Now for the Management of Nonalcoholic Fatty Liver Disease to Prevent Hepatocellular Carcinoma?

Dr. Hirokazu Takahashi (Japan)

12:40-12:50 Discussion Time

12:50-13:00 Closing Ceremony

Dr. Tsutomu Masaki, President of APASL Oncology 2022 Takamatsu

Day 3: September 3 (Saturday) 2022

Room 2

8:00-9:00 Morning Seminar 4 (Sponsored by Takeda Pharmaceutical Co., Ltd.)

Chair: Dr. Makoto Oryu (Japan)

Positioning of Vonoprazan and Its Safety - Seven Years of Clinical Experience in Japan

Dr. Ken Haruma (Japan)

9:10-10:40 Workshop 26: Treatment of Advanced Hepatocellular Carcinoma

Chairs: Dr. Yuji Iimuro (Japan) Dr. Kazuhiro Hanazaki (Japan) / Yasutsugu Takada (Japan)

9:10-9:23 WS26-1

Clinical Impact of the Changes of Skeletal Muscle during Atezolizumab Plus Bevacizumab Therapy in Patients with Unresectable Hepatocellular Carcinoma

Dr. Hiroaki Matsumoto (Japan)

9:23-9:36 WS26-2

Impact of Renal Failure in Patients Treated with Atezolizumab / Bevacizumab Combination Therapy for Unresectable Hepatocellular Carcinoma

Dr. Hitomi Takada (Japan)

9:36-9:49 WS26-3

Use of Ramucirumab for Various Treatment Lines in Real-World Practice of Patients with Advanced Hepatocellular Carcinoma

Dr. Naoya Kanogawa (Japan)

9:49-10:02 WS26-4

Real-life Potential of Cabozantinib in Patients with Advanced Hepatocellular Carcinoma

Dr. Hiroaki Kanzaki (Japan)

10:02-10:15 WS26-5

Hepatic Arterial Infusion Chemotherapy New-FP for Hepatocellular Carcinoma with Major Portal Vein Tumor Thrombus

Dr. Hideki Iwamoto (Japan)

10:15-10:40 Discussion Time

11:20-12:50 Workshop 29: Treatment Strategies for Liver Cirrhosis

Chairs: Dr. A. Kadir Dokmeci (Turkey) / Dr. Kazutaka Kurokochi (Japan) /

Dr. Hidenori Toyoda (Japan)

11:20-11:33 WS29-1

Analysis of Factors Associated with the Prognosis of Cirrhotic Patients Who were Treated with V2-receptor Antagonist for Hepatic Edema

Dr. Akemi Tsutsui (Japan)

11:33-11:46 WS29-2

The Usefulness of Tolvaptan as a Treatment of Hepatic Edema among Decompensated Cirrhotic Patients

Dr. Takamasa Ohki (Japan)

11:46-11:59 WS29-3

L-carnitine Reduces Hospital Admissions in Patients with Hepatic Encephalopathy

Dr. Joji Tani (Japan)

11:59-12:12 WS29-4

Prediction of Esophagogastric Varices Using Splenic Stiffness Measurement by MR Elastography

Dr. Kento Imajo (Japan)

12:12-12:25 WS29-5

The Efficacy of a Sodium Glucose co-transporter-2 (SGLT2) Inhibitor for the Treatment of Nonalcoholic Steatohepatitis and Liver Fibrosis

Dr. Asahiro Morishita (Japan)

12:25-12:50 Discussion Time

Day 3: September 3 (Saturday) 2022

Room 3

9:10-10:40 Workshop 27: Molecular Mechanisms of Liver Cancer (including HCC, CCC and Metastatic Liver)

Chairs: Dr. Jidong Jia (China) / Dr. Akio Ido (Japan) / Dr. Motoyuki Otsuka (Japan)

9:10-9:23 WS27-1

The Roles of BMP9 in Cancer Stemness and Angiogenesis of Hepatocellular Carcinoma

Dr. Kouki Nio (Japan)

9:23-9:36 WS27-2

Novel GPC3xCD3 (NILK-2501) and GPC3xCD28 (NILK-3801) κλ Bispecific Antibodies for Next Generation Immunotherapy of GPC3-expressing Cancer

Dr. Dirk Hose (Switzerland)

9:36-9:49 WS27-3

Abnormal Osmolyte and Water Balance in Hepatocellular Carcinoma Rats

Dr. Kento Kitada (Japan)

9:49-10:02 WS27-4

The Dichotomous Role of SCAP/SREBP Pathway in Pathogenesis of NASH and NASH-related HCC

Dr. Satoshi Kawamura (Japan)

10:02-10:15 WS27-5

Pancreatic KrasG12D Mutation Increases Hepatocellular Carcinoma Development from NASH in Mice Model

Dr. Seita Kataoka (Japan)

10:15-10:28 WS27-6

Deficiency of the Mismatch Repair Gene MSH2 Promotes Hepatocarcinogenesis in Chronic Hepatitis

Dr. Shigeharu Nakano (Japan)

10:28-10:40 Discussion Time

11:20-12:25 Plenary Session

Chairs: Dr. Akio Moriya (Japan) / Dr. Chikara Ogawa (Japan)

11:20-11:33 PL-1

In-Hospital Exercise Improved Frailty in Patients with Hepatocellular Carcinoma

Dr. Ryuki Hashida (Japan)

11:33-11:46 PL-2

ATF3 is Involved in Regulating ACSL4 Expression to Promote Ferroptosis in Intrahepatic Cholangiocarcinoma

Dr. Zihan Li (Japan)

11:46-11:59 PL-3

Clinical Features and Risk Factors of Hepatocellular Carcinoma Rising from Alcohol-related Liver Disease

Dr. Makiko Taniai (Japan)

11:59-12:12 PL-4

Prognosis of Hepatocellular Carcinoma after Confirmation of Overall Survival and Death - A 15-year Fixed Point Observation

Dr. Ritsuko Yokouchi (Japan)

12:12-12:25 PL-5

Dietary Fat Composition Affects Hepatic Angiogenesis and Lymphangiogenesis in HCV Core Gene Transgenic Mice

Dr. Zhe Zhang (Japan)

Oral Free Papers

Day 1: September 1 (Thursday) 2022

Room 4

9:10-10:00 Oral Free Papers 1: Liver Cancer Basic and Clinical Study 1

Chairs: Dr. Masashi Hirooka (Japan) / Dr. Tomokazu Kawaoka (Japan)

9:10-9:18 O1-1 #10209

Up-regulation of the Epithelial Mesenchymal Transition Genes in a Chemically Induced-hepatocellular Carcinoma Rat Model

Dr. Vichununt Kerdput (Thailand)

9:18-9:26 O1-2 #10093

CHI3L1 Detects over 12% of AFP/AFP-L3/DCP Triple Negative HCC Cases and the Four-biomarker Panel Offers Much Improved Performance for HCC Diagnosis

Dr. Biaoyang Lin (USA)

9:26-9:34 O1-3 #10232

Evaluation of Remnant Liver Volume on Postoperative Liver Failure in Right Hemihepatectomy for Hepatocellular Carcinoma

Dr. Chikato Koga (Japan)

9:34-9:42 O1-4 #10161

Validity of 5-5-500 Criteria from the Viewpoint of Microvascular Invasion in Hepatectomy Cases

Dr. Kohei Ogawa (Japan)

9:42-9:50 O1-5 #10015

Atezolizumab plus Bevacizumab in Patients with Unresectable Hepatocellular Carcinoma: A Single-center Experience

Dr. Akio Moriya (Japan)

9:50-9:58 O1-6 #10068

Therapeutic Response of Atezolizumab plus Bevacizumab Therapy for Unresectable Hepatocellular Carcinoma: A Single Center Experience

Dr. Tomohiro Nishikawa (Japan)

10:20-11:10 Oral Free Papers 2: Liver Cancer Basic and Clinical Study 2

Chairs: Dr. Masanori Abe (Japan) / Dr. Yasunori Minami (Japan)

10:20-10:28 O2-1 #10223

Pathological Complete Response for Unresectable Locally Advanced Hepatocellular Carcinoma by Conversion Surgery Following a Good Response of Atezolizumab plus Bevacizumab Treatment

Dr. Yoichiro Uchida (Japan)

10:28-10:36 O2-2 #10241

Tace in Bangladesh-Long Term Follow Up

Dr. Md. Fazal Karim (Bangladesh)

10:36-10:44 O2-3 #10127

Characteristics and Background of Hepatocellular Carcinoma from Non-viral Hepatitis in Our Hospital

Dr. Koji Yamashita (Japan)

10:44-10:52 O2-4 #10083

Prognostic Factors after Curative Treatments for Milan Criteria Hepatocellular Carcinoma in Child-Pugh A: When should We Consider Nutritional Intervention?

Dr. Atsushi Hiraoka (Japan)

10:52-11:00 O2-5 #10263

Association of ACRBP Gene Polymorphism (+26A/G) to Liver Cancer and Diabetes Leads to Novel Biomarker Discovery

Dr. Md Shariful Islam (USA)

11:00-11:08 O2-6 #10264

Treatment Strategy for the Multiple Colorectal Liver Metastasis

Dr. Tomoyuki Abe (Japan)

11:30-12:20 Oral Free Papers 3: Case Report 1 / Others

Chairs: Dr. Akihiro Deguchi (Japan) / Dr. Takashi Himoto (Japan)

11:30-11:38 O3-1 #10150

Sarcomatous Change after Spontaneous Regression of Hepatocellular Carcinoma

Dr. Hisanori Muto (Japan)

11:38-11:46 O3-2 #10169

Endobarrier: A Patient-covering Negative Pressure Box to Contain Aerosol and Droplet Generation during Esophagogastroduodenoscopy in the COVID-19 Era

Dr. Shintaro Fujihara (Japan)

11:46-11:54 O3-3 #10081

The use of Endo Barrier for Prevention of COVID-19 Infection Enables Upper Gastrointestinal Endoscopy with High Patient Satisfaction

Dr. Atsushi Imagawa (Japan)

11:54-12:02 O3-4 #10156

Hepatic Visceral Larva Migrans Diagnosed Clinically as Cholangiolocarcinoma

Dr. Mako Koseki (Japan)

12:02-12:10 O3-5 #10234

The Effect Inhalation Aromatherapy of Cardamom on the Chemotherapy-induced Nausea and Vomiting in Cancer Patients

Dr. Leyla Halimi (Iran)

12:10-12:18 O3-6 #10233

Compare Aromatherapy with Essential Oils of Lavender and Rose on Sleep Quality in Patients Undergoing Chemotherapy

Dr. Leyla Halimi (Iran)

14:40-15:30 Oral Free Papers 4: Non HCC Liver Diseases 1

Chairs: Dr. Kei Moriya (Japan) / Dr. Ryosuke Tateishi (Japan)

14:40-14:48 O4-1 #10094

The Prevalence of Hepatitis B Virus Infection among the Pregnant Women and Their Newborn Babies in Siem Reap Province, Cambodia

Dr. Bunthen E (Japan)

14:48-14:56 O4-2 #10031

Effect of Pegylated Interferon Alfa-2a in HBeAg-negative Chronic Hepatitis B during and 48 Weeks after Off-treatment Follow-up: The Limitation of Pre-treatment HBsAg Load for the Seroclearance of HBsAg

Dr. Shima Mimura (Japan)

14:56-15:04 O4-3 #10032

Predictors of Therapeutic Efficacy of Pegylated Interferon Alpha-2a Therapy in HBeAg-negative Chronic Hepatitis B with Nucleos(t)ide Analog: 1-year Follow-up after Treatment

Dr. Shima Mimura (Japan)

15:04-15:12 O4-4 #10051

Sero-epidemiological Study on HBV and HCV Infection in Elderly Care Facility Staff and Residents in Japan

Dr. Aya Sugiyama (Japan)

15:12-15:20 O4-5 #10260

Association of Type 2 Diabetes and Hepatitis C Virus Infection in Pakistani Population: A Meta-Analysis

Dr. Sher Zaman Safi (Malaysia)

15:20-15:28 O4-6 #10170

Age-dependent Sex Difference of Non-alcoholic Fatty Liver Disease in TSOD and db/db Model Mice

Dr. Erdenetsogt Dungubat (Japan)

15:40-16:40 Oral Free Papers 5: Case Report 2

Chairs: Dr. Tetsu Tomonari (Japan) / Dr. Joji Tani (Japan)

15:40-15:48 O5-1 #10204

Two Cases of Hepatocellular Carcinoma with Radical Resection after Lenvatinib Administration followed by Conversion Surgery

Dr. Masahiko Honjo (Japan)

15:48-15:56 O5-2 #10125

A Case of Conversion Surgery for Initially Unresectable Hepatocellular Carcinoma with Tumor Shrinkage after Atezolizumab plus Bevacizumab Therapy

Dr. Yusuke Seki (Japan)

15:56-16:04 O5-3 #10205

A Case of Sustained Complete Response by Sorafenib Therapy Following TAE Therapy for the Rupture of Giant Hepatocellular Carcinoma

Dr. Ken Sato (Japan)

16:04-16:12 O5-4 #10190

Two Cases of Local Ablation for Hepatocellular Carcinoma in the Caudate Lobe; An Emerging Technique with Using Guided Needle under Computed Tomography

Dr. Sae Yumita (Japan)

16:12-16:20 O5-5 #10187

A Successful Treatment for Hepatocellular Carcinoma in a Patient with Hemophilia A Using Laparoscopic Radiofrequency Ablation

Dr. Rie Goka (Japan)

16:20-16:28 O5-6 #10200

Clinical Evaluation of Liver Metastasis in Ovarian Cancer

Dr. Amar Ranjan Singh (India)

16:28-16:36 O5-7 #10201

Growing Teratoma Syndrome Affecting Hepato-renal Space

Dr. Harshita Dubey (India)

16:50-18:00 Oral Free Papers 6: Liver Cancer Basic and Clinical Study 2 / Non HCC Liver Diseases 2

Chairs: Dr. Koichi Tsuneyama (Japan) / Dr. Takahiro Yamasaki (Japan)

16:50-16:58 O6-1 #10265

Latent Transforming Growth Factor-Beta Binding Protein 1 as A Molecular Diagnostic Marker for Hepatocellular Carcinoma in Egyptian Patients

Dr. Mohamed Abdel Samiee (Egypt)

16:58-17:06 O6-2 #10266

Circulating Hypermethylated RASSF1A as a Marker of Hepatocellular Carcinoma in Chronic HCV Patients

Dr. Mohamed Abdel Samiee (Egypt)

17:06-17:14 O6-3 #10023

A Comparative Proteomic Analysis of Extracellular Vesicles Associated with Lipotoxicity

Dr. Yasuhiko Nakao (Japan)

17:14-17:22 O6-4 #10270

Establishment of the Japan Academy of Tumor Ablation (JATA)

Dr. Shuichiro Shiina (Japan)

17:22-17:30 O6-5 #10143

Microwave Thermosphere Ablation for Primary Hepatocellular Carcinoma within Milan Criteria

Dr. Jumpei Okamura (Japan)

17:30-17:38 O6-6 #10240

Chronic Hepatitis C Patients with Advanced Liver Fibrosis are More Likely to Have Persistent Cryoglobulinemia after Antiviral Treatment

Dr. Batbold Batsaikhan (Mongolia)

17:38-17:46 O6-7 #10009

Clinical Characteristics of the Nutritional and Dietary Factors Associated with Skeletal Muscle Index in Patients with Nonalcoholic Fatty Liver Disease

Dr. Takashi Himoto (Japan)

17:46-17:54 O6-8 #10082

The Prevalence of Portopulmonary Hypertension and the Clinical Characteristics of the Patients with High Right Ventricular Systolic Pressure in Liver Transplant Candidates

Dr. Ryoko Hayashi (Japan)

Poster Free Papers

Day 2: September 2 (Friday) 2022

Room 4 & Foyer, 3rd Floor 18:30-

Poster Free Papers 1: “Epidemiology of HCC in Asia”

Chair: Dr. Makiko Taniai (Japan)

18:30-18:37

P1-1 #10064 Onsite Poster

Risk Analysis of Hepatocellular Carcinoma Development in non-B non-C Cirrhotic Patients

Dr. Ryota Masuzaki (Japan)

P1-2 #10113 E-Poster

Mortality Rates and Risk Factors in 1425 Japanese Patients with Decompensated Hepatitis C Virus-Related Cirrhosis

Dr. Shunichiro Fujiyama (Japan)

P1-3 #10155 E-Poster

Promoting Hepatitis Virus Screening for Workers by Using Nudge Theory Can Help Detect Carriers Who are Unaware of Their Infection and Require to Therapy for Hepatocellular Carcinoma

Dr. Masaaki Korenaga (Japan)

18:37-18:44

P1-4 #10168 Onsite Poster

Etiological Transitions in Patients with Liver Cirrhosis and Hepatocellular Carcinoma: A Single-center Study from an Institution Located in a District with a High Prevalence of Viral Hepatitis

Dr. Hirayuki Enomoto (Japan)

P1-5 #10252 E-Poster

Epidemiological and Clinical Characteristics of Hepatocellular Carcinoma in Kazakhstan

Dr. Arailym Maikenova (Kazakhstan)

Poster Free Papers 2: “Viral Hepatitis-related HCC -HCV-related HCC”

Chair: Dr. Tatsuo Kanda (Japan)

18:30-18:37

P2-1 #10054 Onsite Poster

The Analysis of Survival Prognosis and Cause of Death after Sustained Virologic Response

Dr. Satoshi Miuma (Japan)

P2-2 #10071 E-Poster

New Simple Clinical Score to Predict Hepatocellular Carcinoma after Sustained Viral Response with Direct-acting Antivirals

Dr. Makoto Morita (Japan)

P2-3 #10077 E-Poster

Liver Stiffness is a Useful Predictor for Exacerbation of Esophagogastric Varices after Hepatitis C Virus Eradication by Direct-acting Antivirals

Dr. Yuko Nagaoki (Japan)

18:37-18:44

P2-4 #10130 Onsite Poster

Successful Retreatment of Direct-acting Antiviral Therapy against Hepatitis C Virus Infection in a Patient Who Underwent a Liver Transplant from HLA-matched Sibling Donor

Dr. Tatsuo Kanda (Japan)

18:44-18:51

P2-5 #10135 Onsite Poster

Risk Factors Contributing to Occurrence and Recurrence of Hepatocellular Carcinoma after the Eradication of Hepatitis C Virus by Direct-acting Antivirals

Dr. Masakuni Tateyama (Japan)

P2-6 #10142 E-Poster

Dysregulation of the Intestinal Microbial Communities among Chronic Hepatitis C Patients with Hepatocellular Carcinoma

Dr. Takako Inoue (Japan)

Poster Free Papers 3: “Viral Hepatitis-related HCC -HCV/HBV-related HCC”

Chair: Dr. Hidekatsu Kuroda (Japan)

18:30-18:37

P3-1 #10149 Onsite Poster

During the Chemotherapy against Lung Cancer in Patients with HCV and Decompensated Cirrhosis, DAA could Support Sufficient Lung Cancer Treatment

Dr. Tatsuo Kanda (Japan)

P3-2 #10203 E-Poster

Risk of HCC Development following Achievement of SVR in Patients with Cirrhosis Receiving DAA Therapies for HCV

Dr. Yoshihito Uchida (Japan)

P3-3 #10236 E-Poster

Assessment of Impaired Glomerular Filtration Function in Chronic Hepatitis C Patients

Dr. Batbold Batsaikhan (Mongolia)

P3-4 #10267 E-Poster

Relation of Phosphatase and Tensin Homolog Gene Polymorphism with Hepatocellular Carcinoma among Hepatitis C Infected Patients

Dr. Mohamed Abdel Samiee (Egypt)

P3-5 #10056 E-Poster

Influence of Hepatitis B Virus Genotypes on Expression of Viral Antigen and Host Cytokines

Dr. Shiheng Xu (China)

P3-6 #10134 E-Poster

Clinical Utility of Droplet Digital PCR for HBV cccDNA Quantification

Dr. Sanae Hayashi (Japan)

Poster Free Papers 4: “MicroRNA and Gene Mutation in Liver Disease”

Chair: Dr. Takahiro Kodama (Japan)

18:30-18:37

P4-1 #10020 Onsite Poster

Effects of Lenvatinib on the Cell Cycle and Related microRNA Profiling in Hepatocellular Carcinoma Cells

Dr. Mai Nakahara (Japan)

P4-2 #10030 E-Poster

Construction of miRNA-mRNA Pairs Reveals Potential Regultaory Axis for Hepatocellular Carcinoma Cell Transfected with HBV

Dr. Qi Yin (China)

18:37-18:44

P4-3 #10033 Onsite Poster

Profile of microRNAs Associated with Aging in Rat Liver

Dr. Shima Mimura (Japan)

18:44-18:51

P4-4 #10041 Onsite Poster

The Analysis of Circulating Tumor DNA in Advanced Hepatocellular Carcinoma Treated with Lenvatinib

Dr. Yasutoshi Fujii (Japan)

P4-5 #10044 E-Poster

Interferon-treated Macrophage-derived Exosomes Inhibit HBV-related Hepatocellular Carcinoma Cell Migration through miRNA-106b-3p

Dr. Shiheng Xu (China)

Poster Free Papers 5: “MicroRNA and Gene Mutation in Liver Disease”

Chair: Dr. Hayato Hikita (Japan)

18:30-18:37

P5-1 #10084 Onsite Poster

Identification of microRNA-96-5p as a Postoperative Prognostic microRNA Predictor in Non-viral Hepatocellular Carcinoma

Dr. Takeshi Matsui (Japan)

18:37-18:44

P5-2 #10105 Onsite Poster

Antitumor Effect of Regorafenib on MicroRNA Expression in Hepatocellular Carcinoma Cell Lines

Dr. Kei Takuma (Japan)

18:44-18:51

P5-3 #10146 Onsite Poster

Comprehensive Analysis of Circulating microRNAs as Predictive Biomarkers for Sorafenib Therapy Outcome in Hepatocellular Carcinoma

Dr. Tomoki Kono (Japan)

P5-4 #10225 E-Poster

Candidate MicroRNA Can be Predictive Markers for The Incidence of Hepatocellular Carcinoma in Patients with Chronic Hepatitis B after Administration of Nucleos(t)ide Analog

Dr. Hideaki Takahashi (Japan)

Poster Free Papers 6: “Treatment of Liver Disease -Treatment of Liver Cirrhosis”

Chair: Dr. Masanori Atsukawa (Japan)

P6-1 #10024 E-Poster

Angiotensin II Receptor Blockers Potentiates the Protective Effect of Branched Chain Amino Acids on Liver Cirrhosis Related Skeletal Muscle Atrophy

Dr. Soichi Takeda (Japan)

18:30-18:37

P6-2 #10040 Onsite Poster

Therapeutic Effects of Rifaximin and L-carnitine Combination Therapy on Skeletal Muscle Atrophy in Cirrhotic Rats

Dr. Koji Murata (Japan)

P6-3 #10070 E-Poster

Spleen Volume is a Risk for Treatment Refractoriness with Platelet Transfusion and Lusutrombopag in Chronic Liver Disease Patients with Thrombocytopenia

Dr. Makoto Morita (Japan)

P6-4 #10076 E-Poster

Efficacy and Safety of Edoxaban for the Treatment of Portal Vein Thrombosis in Patients with Liver Cirrhosis

Dr. Yuko Nagaoki (Japan)

P6-5 #10080 E-Poster

The Role of Chitinase-3 Like 1 on Age-related Liver Fibrosis Progression

Dr. Norihisa Nishimura (Japan)

18:37-18:44

P6-6 #10090 Onsite Poster

Usefulness of Contrast-enhanced Computed Tomography for the Management of Gastroesophageal Varices during Systemic Chemotherapy for Hepatocellular Carcinoma

Dr. Kisako Fujiawara (Japan)

Poster Free Papers 7: “Treatment of Liver Disease -Treatment of Liver Cirrhosis”

Chair: Dr. Takamasa Ohki (Japan)

18:30-18:37

P7-1 #10097 Onsite Poster

Use of Peritoneovenous Shunt and Cell-free and Concentrated Ascites Reinfusion Therapy for the Management of Refractory Ascite

Dr. Akihiro Deguchi (Japan)

P7-2 #10128 E-Poster

The Efficacy of Combined Treatment of Bezafibrate and Ursodeoxycholic Acid was Reduced in Patients with Primary Biliary Cholangitis at Advanced Stage

Dr. Atsushi Tanaka (Japan)

P7-3 #10137 E-Poster

Rifaximin and Lubiprostone Mitigate Liver Fibrosis Development by Repairing Gut Barrier Function in Diet Induced Rat Steatohepatitis

Dr. Masahide Enomoto (Japan)

P7-4 #10151 E-Poster

Efficacy and Safety of Administration of Zinc Acetate Hydrate to Patients with Refractory Hepatic Encephalopathy

Dr. Masashi Nishiyama (Japan)

P7-5 #10184 E-Poster

Miglustat Prevents and Ameliorates Liver Fibrosis by Inhibiting the TGF- β /Smad pathway

Dr. Terunao Iwanaga (Japan)

18:37-18:44

P7-6 #10245 Onsite Poster

The Association between Sarcopenia and Oxidative Stress in Patients with Hepatocellular Carcinoma

Dr. Kohei Oda (Japan)

Poster Free Papers 8: “Treatment of Liver Disease -Treatment of Early HCC”

Chair: Dr. Teiji Kuzuya (Japan)

18:30-18:37

P8-1 #10055 Onsite Poster

Which of the Curative Treatments is Appropriate for Initial Recurrence within Early-stage Hepatocellular Carcinoma after Curative Treatments: Resection or Ablation?

Dr. Hideko Ohama (Japan)

18:37-18:44

P8-2 #10057 Onsite Poster

A Clinical Issue in Aging Society: Up to What Age Can We Consider Performing Ablation?

Dr. Yoshiko Fukunishi (Japan)

18:44-18:51

P8-3 #10078 Onsite Poster

Comparison of Ablation Area and Change in Functional Liver Reserve after Radiofrequency Ablation for Hepatocellular Carcinoma Using the Arfa and VIVA Systems

Dr. Hiroaki Takaya (Japan)

P8-4 #10075 E-Poster

Efficacy of Combined Electric-field and C-plane Imaging for Ultrasound-Ultrasound Fusion Imaging for Monopolar Radiofrequency Ablation

Dr. Ryo Yano (Japan)

P8-5 #10112 E-Poster

Hepatic Resection versus Particle Therapy for Single Hepatocellular Carcinoma as An Initial Treatment: A Multicenter Propensity Score Matched Analysis

Dr. Satoshi Omiya (Japan)

18:51-18:58

P8-6 #10152 Onsite Poster

The Role of Stereotactic Body Radiotherapy for Hepatocellular Carcinoma

Dr. Nozomi Miyake (Japan)

18:58-19:05

P8-7 #10154 Onsite Poster

Effect of Surgical Margin 0mm for Recurrence-free Survival after R0 Laparoscopic Liver Resection for Hepatocellular Carcinoma

Dr. Yukihiro Watanabe (Japan)

Poster Free Papers 9: “Treatment of Liver Disease -Treatment of Early HCC/Intermediate-stage HCC”

Chair: Dr. Takeshi Hatanaka (Japan)

18:30-18:37

P9-1 #10165 Onsite Poster

The Efficacy and Safety of Microwave Ablation for Patients with Hepatocellular Carcinoma

Dr. Kazuki Ohya (Japan)

18:37-18:44

P9-2 #10191 Onsite Poster

The Usefulness of Increasing the Power Output Linearly during RFA for Hepatocellular Carcinoma

Dr. Norihiro Nishijima (Japan)

18:44-18:51

P9-3 #10213 Onsite Poster

Significance of Laparoscopic Liver Resection for Post-RFA Recurrence of Hepatocellular Carcinoma

Dr. Masayasu Aikawa (Japan)

P9-4 #10074 E-Poster

Chemoem Bolization with or without Radiofrequency Ablation: Outcomes in BCLC-B Hepatocellular Carcinoma

Dr. Ryo Yano (Japan)

P9-5 #10091 E-Poster

Risk Factors for Immune-mediated Hepatotoxicity in Patients with Cancer Treated with Immune Checkpoint Inhibitors: A Systematic Review and Meta-analysis

Dr. Jiahui Pan (China)

P9-6 #10092 E-Poster

Efficacy and Safety of PD-1/PD-L1 Inhibitors in Advanced Hepatocellular Carcinoma: A Systematic Review and Meta Analysis

Dr. Yuwei Liu (China)

Poster Free Papers 10: “Treatment of Liver Disease - Treatment of Intermediate-stage HCC”

Chair: Dr. Yusuke Kawamura (Japan)

18:30-18:37

P10-1 #10145 Onsite Poster

Clinical Effect of Lenvatinib-TACE Therapy in Patients with BCLC-intermediate Stage Hepatocellular Carcinoma

Dr. Seiichi Mawatari (Japan)

18:37-18:44

P10-2 #10148 Onsite Poster

Early Predictors of Response and Survival in Atezolizumab/Bevacizumab Combination Therapy

Dr. Norikazu Tanabe (Japan)

18:44-18:51

P10-3 #10185 Onsite Poster

Factors Contributing to Response to Systemic Sequential Therapy for Intermediate Stage Hepatocellular Carcinoma

Dr. Yumi Kosaka (Japan)

P10-4 #10197 E-Poster

Initial Treatment Strategy for Intermediate Stage Hepatocellular Carcinoma Based on Up-to-7 Criteria

Dr. Noboru Takata (Japan)

18:51-18:58

P10-5 #10208 Onsite Poster

Usefulness of Lenvatinib in Combination with TACE for Patients with Intermediate Stage Hepatocellular Carcinoma

Dr. Akira Fuchigami (Japan)

18:58-19:05

P10-6 #10250 Onsite Poster

New Technology to Detect of Tumor-feeding Branches and Simulate Embolization Area of Hepatocellular Carcinoma with Synapse Vincent during Transcatheter Arterial Chemoembolization

Dr. Kazutoshi Fuke (Japan)

Poster Free Papers 11: “Treatment of Liver Disease - Treatment of Advanced HCC”

Chair: Dr. Takeshi Terashima (Japan)

P11-1 #10010 E-Poster

Association between Skeletal Muscle Volume Loss during Lenvatinib Treatment and Prognosis in Unresectable Hepatocellular Carcinoma: A Multicenter Study in Tohoku, Japan

Dr. Masashi Fujita (Japan)

P11-2 #10045 E-Poster

Prediction of Serious Adverse Events in Advanced Hepatocellular Carcinoma Treated with Lenvatinib by Intestinal Permeability

Dr. Yuki Fujimoto (Japan)

P11-3 #10046 E-Poster

Systematic Review of Adjuvant External Beam Radiotherapy for Hepatocellular Carcinoma following Hepatectomy

Dr. Qiao Ke (China)

18:30-18:37

P11-4 #10047 Onsite Poster

Clinical Outcome of Chemoradiation Therapy Using One-shot Cisplatin Via Hepatic Arterial Infusion for Hepatocellular Carcinoma with Macrovascular Invasion: A Single-arm Retrospective Cohort Study

Dr. Kensuke Naruto (Japan)

P11-5 #10061 E-Poster

Usefulness of Combined Atezolizumab Plus Bevacizumab Therapy as the Second Line Treatment for Patients with Unresectable Hepatocellular Carcinoma

Dr. Shinpei Yamaba (Japan)

Poster Free Papers 12: “Treatment of Liver Disease - Treatment of Advanced HCC”

Chair: Dr. Sadahisa Ogasawara (Japan)

18:30-18:37

P12-1 #10063 Onsite Poster

Comparison of Atezolizumab + Bevacizumab and Lenvatinib as Primary Therapy by Propensity Score Matching

Dr. Shuntaro Obi (Japan)

18:37-18:44

P12-2 #10087 Onsite Poster

The Benefit of Kinase Inhibitors Combined Therapy with Transarterial Chemoembolization or Hepatic Arterial Infusion for Hepatocellular Carcinoma Patients with Early Recurrence after Resection

Dr. Meidai Kasai (Japan)

18:44-18:51

P12-3 #10088 Onsite Poster

Locoregional Therapies for First Occurrence of Hepatocellular Carcinoma: A Single Center Experience

Dr. Yoshiaki Matsumura (Japan)

18:51-18:58

P12-4 #10109 Onsite Poster

Initial Experience of Atezolizumab Plus Bevacizumab for unresectable Hepatocellular Carcinoma: A Retrospective, Real-world Study Conducted in Japan

Dr. Tadashi Namisaki (Japan)

18:58-19:05

P12-5 #10114 Onsite Poster

Analysis of Post-progression Treatment on Atezolizumab plus Bevacizumab Combination Therapy for Patients with Unresectable Hepatocellular Carcinoma

Dr. Yuwa Ando (Japan)

P12-6 #10121 E-Poster

Comparison of Atezolizumab plus Bevacizumab and Lenvatinib in Terms of Efficacy and Safety as Primary Systemic Chemotherapy for Hepatocellular Carcinoma

Dr. Kazuki Maesaka (Japan)

Poster Free Papers 13: “Treatment of Liver Disease - Treatment of Advanced HCC”

Chair: Dr. Kaoru Tsuchiya (Japan)

18:30-18:37

P13-1 #10122 Onsite Poster

Clinical Issue of Systemic Therapies for Unresectable Advanced Hepatocellular Carcinoma at Municipal Hospital in Japan

Dr. Shintaro Takaki (Japan)

18:37-18:44

P13-2 #10133 Onsite Poster

Stereotactic Body Radiation Therapy for Primary and Recurrent Early-stage Hepatocellular Carcinoma

Dr. Shigeki Yano (Japan)

18:44-18:51

P13-3 #10158 Onsite Poster

Trends in Outcomes of Molecular Targeted Therapy in Hepatocellular Carcinoma Patients with Major Vascular Invasion

Dr. Michihisa Moriguchi (Japan)

18:51-18:58

P13-4 #10174 Onsite Poster

Clinical Relevance of the Pretreatment Hepatic Reserve in Stereotactic Body Radiotherapy for Hepatocellular Carcinoma with Regard to Prognosis

Dr. Yasuhide Motoyoshi (Japan)

18:58-19:05

P13-5 #10189 Onsite Poster

Serious Adverse Events in Atezolizumab plus Bevacizumab Therapy: A Single Center Experience

Dr. Takuya Kihara (Japan)

19:05-19:12

P13-6 #10192 Onsite Poster

Hyperprogressive Disease (HPD) and the Importance of Early Radiological Assessment in the Treatment with Atezolizumab plus Bevacizumab for Advanced Hepatocellular Carcinoma Patients

Dr. Miyuki Nakagawa (Japan)

Poster Free Papers 14: “Treatment of Liver Disease - Treatment of Advanced HCC”

Chair: Dr. Issei Saeki (Japan)

18:30-18:37

P14-1 #10193 Onsite Poster

Effects on Survival of Adverse Event on Atezolizumab Bevacizumab for Hepatocellular Carcinoma: A Multicenter Study by the Japan Red Cross liver Study Group

Dr. Shintaro Takaki (Japan)

P14-2 #10198 E-Poster

Results of Living Donor Liver Transplantation for Hepatocellular Carcinoma: A Single Center Experience in Vietnam

Dr. Hieu Le Trung (Viet Nam)

P14-3 #10215 E-Poster

Therapeutic Efficacy of Nivolumab Plus Sorafenib Therapy in Patients with Unresectable Hepatocellular Carcinoma

Dr. Ching-Sheng Hsu (Taiwan)

P14-4 #10238 E-Poster

Long-term Survival by the Maintenance of Liver Functional Reserve in a Patient with the Ovarian and Peritoneal Progression of Hepatocellular Carcinoma: A Case Report

Dr. Takeshi Yokoo (Japan)

18:37-18:44

P14-5 #10251 Onsite Poster

New Fusion Technology Called Colorized Fusion

Dr. Takuya Toda (Japan)

P14-6 #10254 E-Poster

Examination of Cases of Stereotactic Body Radiotherapy for Hepatocellular Carcinoma at Our Hospital

Dr. Tomotaka Yazaki (Japan)

Poster Free Papers 15: “Mechanism of HCC”

Chair: Dr. Ryotaro Sakamori (Japan)

18:30-18:37

P15-1 #10021 Onsite Poster

Blockade of Angiotensin-II Augments the Responsiveness of Human Liver Cancer Cells to Lenvatinib

Dr. Kosuke Kaji (Japan)

18:37-18:44

P15-2 #10060 Onsite Poster

The Relationship between the Expression of Tumor Microenvironment-related Genes and the Gene Mutations of Hepatocellular Carcinoma from TCGA Data

Dr. Yoshinari Asaoka (Japan)

18:44-18:51

P15-3 #10065 Onsite Poster

Study Aimed to Elucidate Mechanism of Maintaining Sarcomatoid Hepatocellular Carcinoma Features

Dr. Ryo Morisue (Japan)

18:51-18:58

P15-4 #10106 Onsite Poster

Telmisartan Inhibits Hepatocellular Carcinoma Cell Proliferation in Vitro by Inducing Cell Cycle Arrest

Dr. Kyoko Oura (Japan)

18:58-19:05

P15-5 #10107 Onsite Poster

Characterization and Cisplatin Effect of Lenvatinib-resistant Hepatocellular Carcinoma Cells

Dr. Sae Hamaya (Japan)

Poster Free Papers 16: “Mechanism of HCC”

Chair: Dr. Kenichi Morikawa (Japan)

P16-1 #10108 E-Poster

Study on Validity of Biomarkers DKK1 in Diagnosis and Posttreatment Monitoring of Hepatocellular Carcinoma

Dr. Hieu Le Trung (Viet Nam)

P16-2 #10131 E-Poster

Immunological Changes in Atezolizumab plus Bevacizumab Administration for Hepatocellular Carcinoma

Dr. Hidenari Nagai (Japan)

18:30-18:37

P16-3 #10136 Onsite Poster

Telomerase Reverse Transcriptase Promoter Mutations in Human Hepatobiliary, Pancreatic, and Gastrointestinal Cancer Cell Lines

Dr. Ono Masahiro (Japan)

18:37-18:44

P16-4 #10211 Onsite Poster

IL-33 Released from Senescent Hepatic Stellate Cells Promotes Obesity-associated Hepatocellular Carcinoma

Dr. Ryota Yamagishi (Japan)

P16-5 #10218 E-Poster

Alteration of the Tumor Microenvironment by Pharmacological Inhibition of EZH2 in Hepatocellular Carcinoma

Dr. Junjie Ao (Japan)

Poster Free Papers 17: “Cholangiocarcinoma”

Chair: Dr. Kensuke Kumamoto (Japan)

18:30-18:37

P17-1 #10166 Onsite Poster

Galectin9 Suppresses Cholangiocarcinoma Cell Proliferation by Inducing Apoptosis but not Cell Cycle Arrest

Dr. Kiyoyuki Kobayashi (Japan)

18:37-18:44

P17-2 #10194 Onsite Poster

2-Oxoglutarate Cooperates with Aspartate β -Hydroxylase to Enhance Cholangiocarcinoma Resistance to Chemotherapy by Modulating DNA Damage Response Signaling Pathways

Dr. Katsuya Nagaoka (Japan)

P17-3 #10212 E-Poster

Mechanism of Gemcitabine-induced Suppression of Human Cholangiocellular Carcinoma Cell Growth

Dr. Yuka Toyota (Japan)

18:44-18:51

P17-4 #10216 Onsite Poster

Inhibition of the YAP and FOXM-1/AURKA Axis by Verteporfin Induces Cell Cycle Arrest and Apoptosis in Human Cholangiocarcinoma Cells

Dr. Ryohei Tarumoto (Japan)

18:51-18:58

P17-5 #10258 Onsite Poster

Preoperative Risk Factors for Intrahepatic Cholangiocarcinoma after Curative Resection

Dr. Yasuhisa Ando (Japan)

Poster Free Papers 18: “Biomarker of HCC”

Chair: Dr. Koji Fujita (Japan)

18:30-18:37

P18-1 #10016 Onsite Poster

Evaluating the Role of Hepatobiliary Phase of EOB-MRI in Predicting Treatment Impact of Atezolizumab plus Bevacizumab on Unresectable Hepatocellular Carcinoma

Dr. Ryu Sasaki (Japan)

18:37-18:44

P18-2 #10052 Onsite Poster

Predictive Usefulness of PET-CT for Recurrence and Overall Survival of Hepatocellular Carcinoma Patients

Dr. Fujimasa Tada (Japan)

18:44-18:51

P18-3 #10100 Onsite Poster

Albumin Platelet Product as a Novel Score for Liver Fibrosis Stage and Prognosis

Dr. Koji Fujita (Japan)

P18-4 #10111 E-Poster

Follistatin is a Useful Biomarker Predicting the Effect of Lenvatinib for the Treatment of Hepatocellular Carcinoma with Extrahepatic Spread

Dr. Takuya Adachi (Japan)

18:51-18:58

P18-5 #10119 Onsite Poster

Epiregulin is a Mediator for Lipopolysaccharide-induced Hepatocarcinogenesis Via the Promotion of Tumor Neovascularization

Dr. Takahiro Kubo (Japan)

18:58-19:05

P18-6 #10163 Onsite Poster

A High Expression of SHROOM4 was Associated with a Favorable Prognosis in HCC Patients

Dr. Hirayuki Enomoto (Japan)

Poster Free Papers 19: “Biomarker of HCC”

Chair: Dr. Yohei Shirakami (Japan)

18:30-18:37

P19-1 #10171 Onsite Poster

A Novel Serum Biomarker, Clusterin could be an Early Predictor of Response to Sorafenib in Patients with Advanced Hepatocellular Carcinoma

Dr. Satoshi Narahara (Japan)

P19-2 #10199 E-Poster

Low-fat Skeletal Muscle Mass is a Prognostic Factor in Patients with Hepatocellular Carcinoma Who Receive Systemic Therapy

Dr. Yoji Ishizu (Japan)

P19-3 #10210 E-Poster

Potential of Ultra-highly Sensitive Immunoassays for HBsAg and Core-related Antigens in Patients with or without Development of Hepatocellular Carcinoma after HBsAg Seroclearance

Dr. Fumitaka Suzuki (Japan)

P19-4 #10221 E-Poster

Diagnostic Value of FibroScan in Patients with Hepatocellular Carcinoma

Dr. Zeng Xianghua (China)

18:37-18:44

P19-5 #10222 Onsite Poster

The Combination of Skeletal Muscle Mass and Intramuscular Adipose Tissue Predicts Prognosis in Patients with Hepatocellular Carcinoma

Dr. Masatsugu Ohara (Japan)

18:44-18:51

P19-6 #10228 Onsite Poster

Serum Zinc Levels are Associated not only with Serum Albumin Levels but also with Hemoglobin Levels, and Zinc Supplementation Improves Serum Albumin and Hemoglobin Levels

Dr. Seigo Abiru (Japan)

P19-7 #10268 E-Poster

Artificial Intelligence Based on Serum Biomarkers Predicts the Efficacy of Lenvatinib for Unresectable Hepatocellular Carcinoma

Dr. Po-Yao Hsu (Taiwan)

Poster Free Papers 20: “Lifestyle-related Disease and HCC - Basic”

Chair: Dr. Yoshihiro Kamada (Japan)

18:30-18:37

P20-1 #10005 Onsite Poster

Glycine Prevents Steatohepatitis-related Carcinogenesis in Hepatocyte-specific Phosphatase and Tensin Homolog-deficient Mice

Dr. Kazuyoshi Kon (Japan)

18:37-18:44

P20-2 #10039 Onsite Poster

The Effect of Elobixibat on Tumorigenesis in the NASH Mice Model

Dr. Kenta Yamamoto (Japan)

18:44-18:51

P20-3 #10043 Onsite Poster

Combined Bioinformatics on the Tumor Promoting Inter-cellular Network in Obesity-associated Liver Tumor Microenvironment

Dr. Yoshiki Nonaka (Japan)

P20-4 #10048 E-Poster

Regular Exercise Suppresses Obesity Associated Liver Cancer through Activating Pgc-1 α - Kynurenine Degrading Pathway

Dr. Vu Thuong Huyen (Japan)

18:51-18:58

P20-5 #10177 Onsite Poster

An Attempt to Establish a Murine Model for Non-alcoholic Fatty Liver Disease-related Hepatocarcinoma Using Diabetic Mice

Dr. Masato Nakamura (Japan)

P20-6 #10183 E-Poster

Prevention of Skeletal Muscle Atrophy in Cirrhotic Rats by Combination Therapy with Rifaximin and L-Carnitine

Dr. Koji Murata (Japan)

Poster Free Papers 21: “Lifestyle-related Disease and HCC - Clinical”

Chair: Dr. Hirokazu Takahashi (Japan)

18:30-18:37

P21-1 #10007 Onsite Poster

Real world Efficacy and Safety of Pemafibrate in Patients with Metabolic Dysfunction-associated Fatty Liver Disease

Dr. Shuji Matsumura (Japan)

18:37-18:44

P21-2 #10141 Onsite Poster

HbA1c, 5.8% or higher, is Most Useful Indicator for Recommendation of Ultrasonography to Detect NAFLD

Dr. Miwa Tatsuta (Japan)

18:44-18:51

P21-3 #110147 Onsite Poster

Short-Term Effects of Nalmefene as Needed Use in Alcoholism with or without Cirrhosis in the Northern Part of Tokyo, Japan

Dr. Tatsuo Kanda (Japan)

18:51-18:58

P21-4 #110159 Onsite Poster

Evaluation of the Iliopsoas Muscle Using SYNAPSE 3D

Dr. Takushi Manabe (Japan)

18:58-19:05

P21-5 #110162 Onsite Poster

Influence of Alcohol Consumption and Gender in Detecting Fatty Liver Using Fatty Liver Index (FLI)

Dr. Takako Nomura (Japan)

19:05-19:12

P21-6 #10178 Onsite Poster

Prediction of Liver Fibrosis and Carcinogenesis by Body Comparison Analysis by Bioelectrical Impedance Analysis

Dr. Hirohito Yoneyama (Japan)

19:12-19:21

P21-7 #10231 Onsite Poster

Automated Fibrosis Phenotyping of Liver Tissue from Non-tumor Lesions of Patients with and without Hepatocellular Carcinoma after Liver Transplantation for Non-alcoholic Fatty Liver Disease

Dr. Hisamitsu Miyaaki (Japan)

Poster Free Papers 22: “Case Report”

Chair: Dr. Minoru Oshima (Japan)

18:30-18:37

P22-1 #10029 Onsite Poster

Atezolizumab plus Bevacizumab-induced Evans Syndrome in Advanced Hepatocellular Carcinoma: A Case Report

Dr. Masanori Fukushima (Japan)

18:37-18:44

P22-2 #10050 Onsite Poster

A Case of Splenic Infarction Developed after Administration of Atezolizumab and Bevacizumab for Hepatocellular Carcinoma

Dr. Fumiya Suzuki (Japan)

18:44-18:51

P22-3 #10062 Onsite Poster

A Case of an ir-AE (Idiopathic Thrombocytopenic Purpura: ITP) Development during the Treatment of Another ir-AE (Liver Dysfunction)

Dr. Tatsuo Horie (Japan)

P22-4 #10067 E-Poster

Two Cases that Suspected Immune Check-point Inhibitor-associated Liver Dysfunction

Dr. Yuko Kuwae (Japan)

18:51-18:58

P22-5 #10072 Onsite Poster

Two Cases of Huge Hepatocellular Carcinoma Successfully Treated by Conversion Hepatectomy after Systemic Chemotherapy

Dr. Hiroaki Naruse (Japan)

18:58-19:05

P22-6 #10085 Onsite Poster

Tezolizumab and Bevacizumab for Unresectable Combined Hepatocellular and Cholangiocarcinoma: A Case Report

Dr. Yuki Tamura (Japan)

Poster Free Papers 23: “Case Report”

Chair: Dr. Hiroyuki Okuyama (Japan)

18:30-18:37

P23-1 #10089 Onsite Poster

Sinusoidal Obstruction Syndrome Developed during the Treatment of RA (Case Report)

Dr. Nao Sogo (Japan)

P23-2 #10123 E-Poster

Staged Carbon Ion Radiotherapy might be a Promising Treatment for Ruptured HCC after Hemostasis

Dr. Hiroki Tojima (Japan)

P23-3 #10126 E-Poster

Clostridium Perfringens Infection with Gas Forming Liver Abscess after Transarterial Chemoembolization for Hepatocellular Carcinoma

Dr. Yoshihito Yoshida (Japan)

P23-4 #10138 E-Poster

Immune Checkpoint Inhibitor-related Pneumonia in Unresectable Hepatocellular Carcinoma: Two Fatal Cases under Atezolizumab plus Bevacizumab

Dr. Kei Endo (Japan)

P23-5 #10160 E-Poster

Conversion Surgery for Hepatocellular Carcinoma after the Anti-PD-L1 Antibody Therapy: Report of a Case

Dr. Hiroto Kayashima (Japan)

P23-6 #10179 E-Poster

Combined Hepatocellular-Cholangiocarcinoma Patients for Whom Drug Therapy with Lenvatinib was Effective: A Case Report

Dr. Takahiro Osuga (Japan)

18:37-18:44

P23-7 #10202 Onsite Poster

A Case of Primary Hepatic Angiosarcoma Successfully Treated Using Atezolizumab + Bevacizumab

Dr. Maho Egusa (Japan)

Poster Free Papers 24: “Case Report”

Chair: Dr. Yoshihiro Okita (Japan)

18:30-18:37

P24-1 #10235 Onsite Poster

A Case of Multiple Metastatic Liposarcoma with a Giant Liver Metastasis Resected in Combination with Multidisciplinary Therapy

Dr. Ikuhiro Kita (Japan)

18:37-18:44

P24-2 #10253 Onsite Poster

A Case Report of Oral Cancer Patient with Liver Metastasis Who Obtained Complete Response by Nivolumab Therapy

Dr. Sena Tsukamoto (Japan)

18:44-18:51

P24-3 #10256 Onsite Poster

A Rare Case of Hepatocellular Carcinoma and Cholangiolocellular Carcinoma with Simultaneous Onset of Nonalcoholic Steatohepatitis in the Background and Metachronous Recurrence after Surgery

Dr. Masaru Muraoka (Japan)

18:51-18:58

P24-4 #10262 Onsite Poster

A Case of High-Frequency Microsatellite Instability Intrahepatic Cholangiocarcinoma in Which Pembrolizumab was Remarkably Effective for Early Postoperative Recurrence

Dr. Hiroyuki Matsukawa (Japan)

18:58-19:05

P24-5 #10011 Onsite Poster

Galectin-9: An Anti-cancer Molecule for Gallbladder Carcinoma

Dr. Tomoko Tadokoro (Japan)

19:05-19:12

P24-6 #10014 Onsite Poster

Study of Drug-induced Liver Injury (DILI) in Our Hospital

Dr. Akemi Tsutsui (Japan)

19:12-19:19

P24-7 #10069 Onsite Poster

Impact of ERCC1 on the Outcomes of Chemotherapy against Advanced Biliary Tract Cancer: An Ancillary Study of the Japan Clinical Oncology Group Randomized Phase III trial (JCOG1113)

Dr. Yasunari Sakamoto (Japan)

Poster Free Papers 25: “Others”

Chair: Dr. Hirohito Yoneyama (Japan)

P25-1 #10073 E-Poster

Actionable Mutations of Malignant Biliary Tumors can be Detected in Archived Biliary Cytology Specimens

Dr. Hiroshi Ohyama (Japan)

P25-2 #10120 E-Poster

Endoscopic Biliary Drainage “EBD” Versus Percutaneous Transhepatic Biliary Drainage “PTBD” for the management of hilar biliary obstruction

Dr. Yasmin Omar (Egypt)

18:30-18:37

P25-3 #10124 Onsite Poster

The Usefulness of Endoscopic Ultrasound-guided Biliary Drainage (EUS-BD) for benign Bile Duct Jejunal Anastomotic Stricture after Biliary Tract Cancer Surgery

Dr. Mako Ushio (Japan)

18:37-18:44

P25-4 #10132 Onsite Poster

Proposal for Infection Prevention Using Disposable Aluminum Covers in Nerve Conduction Study; What we Tried to do at the Beginning of the COVID-19 Pandemic

Dr. Tadayuki Takata (Japan)

18:44-18:51

P25-5 #10139 Onsite Poster

Endoscopic Treatment Results for Biliary Stricture after Liver Transplantation

Dr. Naotaka Kugiyama (Japan)

18:51-18:58

P25-6 #10167 Onsite Poster

A Study of ERCP Complications in Patients with Cirrhosis in Our Hospital

Dr. Ryota Nakabayashi (Japan)

18:58-19:05

P25-7 #10269 Onsite Poster

Cytotoxic Lesions of the Corpus Callosum Associated with COVID-19 Vaccination: A Case Report

Dr. Rie Kawakita (Japan)

APASL Oncology 2022 Takamatsu

“Liver Cancer: Clinical and Basic Research”

Abstracts

Opening Lecture, Special Lectures

President Lecture





Dr. Masao Omata

President, Yamanashi Central and Kita Hospitals

Professor Emeritus, The University of Tokyo

Japan

**Opening & Congratulatory Remarks to
Prof. Masaki (Chairman of APASL STC)**

“Mission of APASL”

Since inauguration of APASL in 1978, we have organized bi- and annual meetings for 31 times for the last 44 years. Furthermore, we started STC (Single Topic Conference) from 2006 and held 37 times for the last 16 years.

Principal aims of these meeting is to promote the latest scientific advancement, exchange of information and the development of consensus in the Hepatology, particularly in the topics of infections of HBV and HCV infection. Because of recent past effort, treatment for the patients with these infections have been much improved. In fact, what we have accomplished for the last 43 years are to promote HBV vaccination program and the development of nearly 100% cure of HCV infection.

On the contrary, care for patients with advanced HCC, alcoholic liver disease, NASH, autoimmune liver disease and advanced HCC need much to be improved.

Moreover, as the new series of the APASL official meeting, the “APASL Oncology” meeting has been launched from last year, focusing particularly on the study of “Hepatic Oncology”. We anticipate active discussion with experts in various field to enlighten us on the most recent Asia-Pacific data in epidemiology, diagnostics, treatment, and all of “Oncology”.

Professor Masaki, one of the leading Hepatologists in Japan, has devoted most of his research life to the study of liver diseases. In particular, he started research on hepatocellular carcinoma in the early 1990s and is currently involved in clinical research and treatment of gastrointestinal and liver diseases together with many young doctors. I understand we received an extremely large number of abstracts for this year’s conference, and I strongly believe it will be a great success.



Dr. Akira Nishiyama

Department of Pharmacology,
Kagawa University Medical School, Kagawa, Japan

Development of a Therapeutic Vaccine for Familial Adenomatous Polyposis

Patients with familial adenomatous polyposis (FAP) have familial activation of the Wnt/ β -catenin pathway associated with *APC* gene mutations and develop adenomatous polyposis and colorectal cancer multifocally. The only prophylactic/therapeutic modality currently available is total colectomy during young age, and hence a decline in QOL is becoming a serious issue. If total removal of the large intestine in early life can be avoided, there are highly beneficial effects, such as improved therapeutic efficacy through improved adherence and reduction of medical expenses. This is the world's first study to attempt medical treatment for familial adenomatous polyposis, which requires complete removal of the large intestine in early life as the only life-saving means. No competitors are expected, since the proposal is based on POC developed through previous basic experiments conducted by the applicant him/herself. We have recently developed therapeutic orphan vaccine targeting on "Protein X" that can suppress activation of the Wnt/ β -catenin system induced by *APC* gene mutations, which are the causes of FAP. An exploratory study using a mouse model of FAP determined the carriers of the vaccine and identified two with strong therapeutic potential. In addition, one vaccine was prototyped by using an adjuvant of which the clinical application was anticipated. Preliminary studies in monkeys showed a significant increase in antibody titers, but no adverse effects, including local irritation, were observed. With these results, we have Research Science strategy consultation with PMDA (Pharmaceutical and Medical Devices Agency), and determined the protocol for the preclinical studies. Meanwhile, an evaluation method for ATP6ap2 in human tissues was also established, and it was proven that ATP6ap2 was indeed markedly up-regulated in polyp tissues of FAP patients. In addition, we have completed the research and selection of a contractor for synthesis and formulation of the API (Active Pharmaceutical Ingredient). The following studies are currently underway: 1. CMC (manufacturing, characterization, specification, and stability studies) necessary for early exploratory clinical trials; 2. Toxicity and safety pharmacology pre-clinical studies in both mice and monkeys; 3. Investigation of mechanism of action to be described in investigator's brochure; 4. Preparation for clinical trials: finalization of clinical trial protocols. The ultimate expected therapeutic effect is the prevention of severe disease resulting from avoidance of total colorectal resection by suppression of polyp growth in familial adenomatous colitis, and the dramatic improvement in patients' QOL.



Dr. Ichiro Ishimaru

Faculty of Engineering and Design, Kagawa University, Japan

Novel Diagnostic Imaging System by Casually Watching Over Peoples with Invisible Lights for Non-invasive Blood Glucose Sensors

We are aiming to realize the casually watching healthcare-system with infrared rays. The mid-infrared passive spectroscopic imaging device built into an AI speaker measures blood glucose levels of several peoples around a dining table simultaneously. Smartwatches are effective methods for wearable health monitoring devices. However, elevated blood glucose levels are of concern about an hour after eating while people are relaxing off their watches. Therefore, blood glucose levels are measured from spectral intensities by extracting human regions or face and arm regions from images observed from a distance. These individual blood glucose data are managed on the web, and dietary advice can be announced from AI speakers. For outdoor activities, smartwatches are used to measure blood glucose levels and manage integrated health data on the web.

We propose the new method for measuring blood glucose levels in bodies by passive spectroscopic imaging of mid-infrared light emitted from body heat. Thermal imaging cameras so-called thermography, what convert mid-infrared light intensity into temperature based on Planck's law, display heat images. We had successfully developed the mid-infrared passive spectroscopic imaging system using an uncooled microbolometer array sensor. By the passive spectroscopic imaging of mid-infrared light emitted from human bodies, we had successfully detected specific glucose-induced emission peaks whose wavelength were 9.25 and 9.65 μm .

Furthermore, the proposed method had been developed into the pea-sized line one-shot spectral imager that could be mounted on a smartphone. This system consists of only three small optics, an objective lens, a relative-inclined phase shifter and a cylindrical imaging lens whose diameter are about 5mm. In the future work, we will realize the continuous glucose monitoring device built into AI speakers and smartphones.



Dr. Tsutomu Masaki

Department of Gastroenterology and Neurology,
Faculty of Medicine, Kagawa University, Japan

Hepatocellular Carcinoma and MicroRNAs

MicroRNAs are small RNA molecules involved in the regulation of gene expression and play an important role as biomarkers for cell proliferation, carcinogenesis or therapeutic response to disease. In recent years, the number of patients with non-viral hepatocellular carcinoma with a background of lifestyle-related diseases has been increasing. Major lifestyle-related diseases include diabetes, hypertension, and atherosclerosis. The antidiabetic drug metformin, the antihypertensive drug ARB, and the antiplatelet drug aspirin have anti-tumor effects for many types of cancer, including hepatocellular carcinoma. In addition, microRNA molecules associated with the antitumor effects of these lifestyle drugs would be presented.

We would also like to mention microRNAs involved in anticancer drug resistance and in the negative HBs antigen of hepatitis B.

APASL Oncology 2022 Takamatsu

“Liver Cancer: Clinical and Basic Research”

Abstracts

Workshops, Plenary Session





Dr. Fumitaka Suzuki

Department of Hepatology, Toranomon Hospital, Japan

Carcinogenesis Post HCV Eradication

Recent developments of direct-acting antiviral agents (DAAs) for chronic hepatitis C virus (HCV) infection have drastically increased the number of patients achieving a sustained virological response (SVR) worldwide. Indications of all-oral interferon (IFN)-free DAA regimens have markedly widened because of their excellent efficacy and safety profiles. However, it is expected that the number of patients with compensated liver cirrhosis who achieve SVR will increase, but this will add the problem of monitoring the patients over a long period of follow up. We reported previously that in patients with higher Fibrosis-4 (Fib-4) index score, DAA reduced the 5-year cumulative hepatocellular carcinoma (HCC) development rate, and that the HCC risk rate after SVR was similar regardless of whether the latter was achieved by DAA or interferon (IFN)-based regimens. The aim of this presentation is to determine the risk factors (for example, male sex and the presence of esophageal varices) of HCC and the cumulative HCC rates after SVR with IFN or DAAs therapy. Moreover, we show the long-term survival rate after HCC in patients treated with IFN or DAAs therapy and the whole mortality rate not limited to liver-related mortality.



Dr. Ming-Lung Yu

Kaohsiung Medical University, Kaohsiung, Taiwan

Pathogenesis and Characteristics of HCC Development after HCV Cure

Chronic hepatitis C (CHC) is one of the major causes of hepatocellular carcinoma (HCC) globally. Successful anti-HCV therapy by achieving a sustained virological response (SVR, undetectable HCV RNA 12–24 weeks after antiviral therapy) has greatly decreased the risk of HCC development. However, a substantial group of patients remains at risk of HCC occurrence. Recent advance in IFN-free all oral directly-acting antiviral agents (DAA) regimens has greatly improved the efficacy and safety in the treatment of almost all HCV patients. With widely extended eligibility of DAA regimens, we are able to cure thousands of HCV patients, and subsequently, the number of post-SVR HCC is expected to increase thereafter. It is thus important to understand the pathogenesis and characteristics as well as long-term outcomes of HCC developed after HCV eradication.

In this session, I will address the incidence of and factors associated with HCC development after HCV eradication. With increasing number of HCV-related HCC developed after viral eradication, we are able to evaluate the difference in patient characteristics, tumor presentation, responses to therapeutic modalities for HCC, and overall survival between the patients who developed HCC before and after HCV eradication. Recent study disclosed that patients with high genetic risk score of hepatic fat accumulation, combining variants in PNPLA3, MBOAT7, TM6SF2, and GCKR (glucokinase regulator) are at risk of HCC after SVR by DAAs. The data suggests that hepatic fat (i.e., lipotoxicity) promotes HCC in this setting and may represent a target for chemoprevention. Notably, HCV infection could lead to epigenetic changes in H3K27ac which are associated increased expression of SPHK1 with liver cancer risk and may persist after SVR by antiviral therapy. Understanding the mechanisms and characteristics of post-SVR HCC could improve the risk stratification and might help us to identify potential targets to prevent or treat HCC developing after HCV cure.



Dr. Tatsuo Kanda

Division of Gastroenterology and Hepatology,
Department of Medicine, Nihon University School of Medicine, Tokyo,
Japan

Post-SVR Events, compared to the APASL HCV Guidelines 2019 of Virus-Eradicated Patients by DAA on How to Monitor HCC Occurrence and HBV Reactivation

Because direct-acting antiviral (DAA) against hepatitis C virus (HCV) treatment for chronic HCV infection could lead to dynamic immunological changes immediately after treatment with DAA, attention should be paid to the occurrence of hepatocellular carcinoma (HCC) and hepatitis B virus (HBV) reactivation in patients with co-infection in short term, although sustained virological response (SVR) could result in the restoration of immunological homeostasis and prevent HCC from occurring in long term. We have reported that HCC occurrence was more often observed in patients with previous HCC history. Therefore, in APASL HCV guidelines 2019, we recommend the following: in patients with previous HCC history, surveillance at 4-month intervals for HCC by the combination of ultrasonography (US) and tumor markers should be performed. In patients without previous HCC history, surveillance at 6- to 12-month intervals for HCC including US has been recommended until the long-term DAA treatment effects, especially for the resolution of liver fibrosis, are confirmed. For patients infected with both HCV and HBV, careful attention should be paid to HBV reactivation for 24 weeks post-treatment. Other post-SVR events should also be discussed.



Dr. Haruhiko Takeda

Department of Gastroenterology and Hepatology
Kyoto University Hospital, Japan

Exploring the Total Transcriptome Profile of the Liver after HCV Eradication

Hepatocellular carcinoma (HCC) developing after hepatitis C virus (HCV) eradication is a serious clinical concern. However, molecular basis for the hepatocarcinogenesis after sustained virologic response (SVR) remains unclear. Especially, it should be clarified why liver cancers develop even after the clearance of HCV as a carcinogen and who develops HCC after achieving SVR.

Recent comprehensive genomic analyses have unveiled that the noncancerous inflamed liver tissues possess a lot of genetic aberrations, including cancer-related somatic mutations, suggesting a certain oncogenic potential exist in the chronic hepatitis tissues. Based on these findings, liver tissues after SVR are inferred to have some oncogenic potential. Therefore, we have examined the transcriptomic profiling of post-SVR nontumour liver tissues to unveil the oncogenic potential after HCV clearance.

We conducted the comprehensive transcriptome analysis using 90 RNA-sequencing datasets, consisting of noncancerous liver tissues including post-SVR, HCV-positive and normal livers. Comparative analysis demonstrated that cell cycle- and mitochondrial function-associated pathways were altered in HCV-positive livers and most of these alterations were recovered in post-SVR livers. On the other hand, some cancer-related pathways upregulated in the HCV-positive livers were also overexpressed in the post-SVR livers. The persistent upregulation of carcinogenesis-associated gene clusters after viral clearance was reconfirmed in *in vitro* experiments. Among them, *CYR61* and co-expressed oncogenic genes including those in EGFR pathway are overexpressed after HCV eradication. Using these top-enriched differentially expressed genes, we explored novel serum biomarkers to predict the hepatocarcinogenesis after SVR. We found the elevated serum *Cyr61* protein was significantly associated with early carcinogenesis after receiving direct-acting antiviral therapy.

In conclusion, some cancer-related transcriptional profiles including the upregulation of cell proliferation pathway caused by chronic HCV infection can be sustained even after viral clearance. Elevated serum *Cyr61* levels could be a potential predictive biomarker for the early occurrence of HCC after SVR. Novel analytical methods, such as single-cell analysis, on larger cohorts could elucidate more detailed transcriptional profiling of liver tissues and establish predictive biomarkers for hepatocarcinogenesis after SVR.



Dr. Shuntaro Obi

Teikyo University Chiba Medical Center,
Internal Medicine, Japan

Overall (Liver and Other Organ) Cancer Incidence and Overall Survival after SVR; A Prospective Study on 651 Consecutive Cases

Background: Hepatitis C treatment with DAA can lead to a safe and high rate of Sustained Virological Response (SVR). Even when SVR is achieved, the risk of liver cancer does not completely disappear, and continuous liver cancer surveillance is recommended. However, it is not clear how long the patient should be followed. Furthermore, the incidence of all organ malignancies and life expectancy, including have not been elucidated.

Methods: From July 2013 to December 2021, we conducted a prospective study of 651 SVR cases, including 50 cases from two registry trials 3 and 4 in Japan. The primary endpoint was development of all malignancies, and secondary endpoints were overall survival. The carcinogenicity rate during follow-up was calculated using the man-year method, and risk factors were analyzed. For the secondary endpoint of overall survival, the survival rate of all eligible patients was calculated. Sex- and age-matched standardized mortality ratios (SMR) were used to compare the general population with the study cohort.

Results: The overall median observation period was 5.44 years. 107 malignancies occurred in 99 patients during the follow-up. The incidence of all malignancies was 3.94/100 person-years. The breakdown of malignant tumors that occurred was 55 cases of hepatocellular carcinoma (HCC) in 55 patients and 52 cases of malignant tumors of other organs (non-HCC) in 49 patients (duplicate cancer occurred in 3 cases), of which 5 cases in 5 patients had both HCC and non-HCC. The incidence of HCC was 1.94/100 person-years. On the other hand, the incidence of non-HCC was 1.81/100 person-years. Risk factors for the development of HCC were history of liver cancer, gender, and albumin. Risk factors for the development of non-HCC were γ -GTP. The prognosis of patients who achieved SVR, 1-year, 3-year and 5-year survival rates from the start of DAA treatment were 99.2%, 96.3% and 94.2%, respectively. Furthermore, the prognosis of SVR cases proved non-inferior to the standardized mortality ratios of the Japanese population.

Conclusions: A prospective study of overall malignancy development and overall survival in patients who achieved SVR revealed that other organ malignancies occur as frequently as hepatocellular carcinoma. Therefore, follow-up of patients who have achieved SVR should focus not only on hepatocellular carcinoma but also on malignancies of other organs, and lifelong follow-up is necessary.



Dr. Masatoshi Ishigami

Department of Gastroenterology and Hepatology,
Nagoya University Graduate School of Medicine, Nagoya, Japan

Clinical Significance of Serum AFP after Eradication of Hepatitis C Virus in Patients with Severe Fibrosis-suppression of Inflammation, Improvement of Liver Function, and Hepatocarcinogenesis

Masatoshi Ishigami, Takashi Honda, Yoji Ishizu, Norihiro Imai, Takanori Ito, Kenta Yamamoto,
Hiroki Kawashima

Department of Gastroenterology and Hepatology, Nagoya University Graduate School of Medicine,
Nagoya, Japan

Background: In this study, we investigated clinical significance of baseline serum AFP levels in HCV-positive patients with severe fibrosis after eradication of virus by DAA treatment.

Methods: We investigated 173 HCV-positive patients with Fib4 index ≥ 3.25 who achieved SVR by DAA treatment between September, 2014 and April, 2020 in our institute. We investigated the factors associated with improvement of liver function (Δ ALBI ≤ -0.5 at 1 year after end of treatment), compared the dynamic change according to baseline serum AFP levels (≥ 10 ng/ml and < 10 ng/ml), and analyzed the proportion of Δ ALBI ≤ -0.5 among the divided groups based on AFP and serum ALT (Group A: AFP ≤ 10 and ALT ≤ 50 , Group B: AFP ≤ 10 and ALT ≥ 50 , Group C: AFP ≥ 10 and ALT ≤ 50 , and Group D: AFP ≥ 10 and ALT ≥ 50). And also, we investigated the difference in the incidence of HCC among those with baseline AFP ≤ 10 and AFP ≥ 10 .

Results: Higher AFP (HR: 1.033, 95% CI: 1.011-1.055, P = 0.003) was one of the statistically significant independent factors associated with Δ ALBI ≤ -0.5 . Patients with AFP ≥ 10 ng/mL showed significant improvement of ALBI score from baseline to 48 weeks after treatment compared to those with AFP ≤ 10 ng/mL (P ≤ 0.001). The proportions of Δ ALBI ≤ -0.5 were 9.8% (Group A), 10.7% (Group B), 24.1% (Group C), and 45.3% (Group D), respectively (P ≤ 0.001). The incidence of HCC after SVR was not statistically different among patients with pretreatment AFP ≤ 10 ng/mL and those with AFP ≥ 10 ng/mL (P = 0.187).

Conclusions: Pretreatment serum AFP levels might be a useful marker for predicting the improvement of liver function after eradication of virus in patients with severe fibrosis independent of hepatocarcinogenesis.



Dr. Mamun-Al Mahtab

Interventional Hepatology Division, Department of Hepatology
Bangabandhu Sheikh Mujib Medical University, Dhaka, Bangladesh

Immunotherapy for CHB and Beyond

Although we have good number of oral antivirals for treating hepatitis B virus (HBV) infection, these are not free from limitations. These have to be administered for years together and sometimes lifelong. Premature discontinuation or non-compliance can lead to fatal viral flare and may even induce liver failure. They are not free from adverse events and most importantly compliance does not ensure liver disease progression free survival. Therefore need for a therapy of finite duration and free from side effects that will ensure cessation of disease progression off treatment in majority of the cases, is long felt. NASVAC, a novel immunotherapy against HBV, is one such drug which fulfills many of these criteria, having successfully passed a phase-III clinical trial and proven to be safe and effective in controlling HBV and halting liver disease progression upto 3 years off treatment. This drug, which is already approved by the regulatory authorities of a number of countries, is currently undergoing human trial in Japan and there is existing literature to support the hypothesis that NASVAC may be a promising therapy for HBV related hepatocellular carcinoma also.



Dr. Oidov Baatarkhuu

Mongolian National University of Medical Sciences

Mongolian Academy of Medical Sciences, Mongolia

Epidemiology, Genotype Distribution, Management of Viral Hepatitis and HCC in Mongolia

Viral hepatitis B and C are one of the major causes of liver cirrhosis and liver cancer in Mongolia. 90-95% of HCC patients in Mongolia are related with HCV and HBV co-infections and occurring in 69 cases per 100,000 people per year¹.

Most patients had advanced HCC – 88 (45.1%) in stage III and 57 (29.2%) in stage IV. The risk factors associated with HCC development were history of acute hepatitis, chronic hepatitis, and the presence of liver cirrhosis. Of these, the presence of liver cirrhosis was the strongest risk factor. In Mongolia, over 60% of patients had a tumor size more than 5 cm. Single tumors were only found in 15%.²⁻⁴

In 2020, A total of 2145 new cases of liver cancer were recorded, which accounts for 32 % of the total new cancer cases. Compared to the region, the incidence rate of liver cancer was higher in the eastern aimags than the country average, the rate was 13.2 per 10 000 population⁵.

The risk factors associated with HCC development were history of acute hepatitis, chronic hepatitis and the presence of liver cirrhosis. Of these, the presence of liver cirrhosis was the strongest risk factor. The most common etiology for HCC in our patients was HCV infection which is 46%, HBV infection -34%, co-infection B and C -14% and alcohol which is 6.0%. According to the results of our study over 60% of patients had tumor size more than 5 cm. Single tumors was only found in 15%. The mean AFP level was 196 ng/ml. In 18.5% distant metastasis existed. Regarding tumor stage, there was no patient with stage 1. In addition the most patients with HCC were diagnosed in advanced stage. In Mongolia HCC treatment modality is very limited. According to the results of our study, 14% of patients received surgical resection, and their survival was the best. 11.8% of patients received RFA and their survival was 11 months. About 55% of patients received TACE and their median survival was 17 months. The prognosis for patients with supportive care was very poor with a median survival of 5 months. Regarding cause of death, about 50% patients died of HCC progression and the others died of liver failure or GI bleeding. Regarding early detection of HCC in Mongolia, AFP is available in all hospitals except inter-soum and soum's hospitals.



Dr. Manoj K. Sharma

Department of Hepatology and Liver Transplantation
Institute of Liver & Biliary Sciences, New Delhi, India

Epidemiological Aspects of HCC Prevention in Asia-Pacific

Liver related deaths contribute to variable proportion of overall deaths in Asia-Pacific (<3% to >6% across various countries). Liver cancer accounts for 40% of liver related death in Asia-Pacific. Asia-Pacific contributes to 2/3rd of global liver disease related deaths, 3/4th of liver cancer related deaths and 80% of HBV related liver cancer deaths. Worldwide Age standardized incidence and mortality rates of liver cancer are highest in East Asia.

There are various risk factors for liver cancer, HBV, HCV, alcohol, NASH being common ones. Age standardized incidence of liver cancer due to HBV, Alcohol and NAFLD are highest in East Asia (China, North Korea and Taiwan) and has been increasing across all regions of Asia-Pacific. Age standardized incidence of liver cancer due to HCV highest in the high-income Asia-Pacific countries (Brunei, Japan, Singapore and South Korea) and has been increasing across all regions of Asia-Pacific. Strategies to prevent HCC include: Primary prevention against new cases of viral hepatitis, and secondary prevention of HCC in susceptible individuals.

Most important interventions of primary prevention include HBV immunization, reduce aflatoxin exposure, reduce alcohol use and reduce NAFLD/obesity. Most important secondary prevention measures include treating viral hepatitis.

Universal hepatitis B vaccination has resulted in dramatic reduction in incident cases of chronic hepatitis B and HCC in children and adolescents, as found in Taiwan. There is a lower liver cancer risk with antiviral therapy in chronic hepatitis B (including patients with even normal to minimally elevated ALT and no cirrhosis). Similarly HCV eradication induced by direct-acting antiviral agents reduces the risk of hepatocellular carcinoma. The WHO's Global Health Sector Strategy on viral hepatitis (2016) aims for elimination of viral hepatitis as a major public health threat by 2030 (i.e., 90% reduction in incidence and 65% in mortality) compared with a 2015 baseline.

Measures taken to decrease aflatoxin exposure (like hand sorting, sun drying, drying on mats, storage in natural fiber bags, use insecticides etc.) can lead to increase in the number of individuals with undetectable aflatoxin albumin adducts.

The Political Declaration of the High-level Meeting of the United Nations General Assembly on the Prevention and Control of Non-Communicable Diseases (NCDs) mandated the development of a global monitoring framework, including indicators, and a set of voluntary global targets for the prevention and control of NCDs. Following the declaration, WHO developed a global monitoring framework to enable global tracking of progress in preventing and controlling major NCDs.

Global alcohol action plan 2022-2030 is being formulated to strengthen the implementation of the "Global Strategy to Reduce the Harmful Use of Alcohol".



Dr. Tawesak Tanwandee

Division of Gastroenterology, Department of Medicine, Mahidol University by Faculty of Medicine Siriraj Hospital, Thailand

Epidemiology of Liver Cancer in Thailand

Liver cancer is among the most common cancer in Thailand, age-standardized rate per 100,000 of about 33.8 in male and 12.9 in female which is the most common cancer in male and the fourth most common cancer in female. Every year, there are about 25,000 new cases of liver cancer, however Thailand is unique since only about 50% of primary liver cancer are hepatocellular carcinoma (HCC) and another 50% are cholangiocarcinoma (CCA). Causes of hepatocellular carcinoma in Thailand including hepatitis B (80%), hepatitis C (15%), whereas cause of cholangiocarcinoma mostly related to *Opisthorchis viverrini* infestation. Most of liver cancer patients present at late stage, HCC in Thailand only 25.6% present as BCLC stage 0 or A and about 25.6% present as BCLC stage D. Implementation of hepatitis B vaccination has markedly reduced the prevalence of hepatitis B in people age below 30 years to less than 1% together with the availability of hepatitis B and C treatment has reduced long-term complication including liver cirrhosis and hepatocellular carcinoma but it takes sometimes to observe significant reduction of HCC. HCC screening through cost-effective in Thailand context but implementation is still limited. Ultrasound plus alfa-fetoprotein every 6 months is recommended for HCC surveillance. Multiple tumor markers panels are available but still is not reimbursed. Diagnosis and treatment of HCC is according to international guidelines.

Most cases of CCA also present at late stage with obstructive jaundice or mass symptom. These patients usually from north and northeast of Thailand. Use of ultrasound as surveillance method has been used for CCA surveillance but benefit is in doubt. Prevention of CCA by treating liver fluke is still problem since re-infection is common due to culture of eating raw freshwater fishes. Diagnosis of CCA can be done by using tissue diagnosis either direct biopsy or endoscopic retrograde endoscopic collection of tissue in bile. Use of tumor markers are limited and treatment of CCA is still problematic in advanced stage.

In conclusion, liver cancer is common in Thailand both HCC and CCA. Most cases present at late stage of disease with limit options of treatment. Prevention of causes like hepatitis B and C is the key for reduction of HCC but for CCA is still problematic.



Dr. Wan-Long Chuang

Hepatobiliary Division, Department of Internal Medicine,
Kaohsiung Medical University Hospital, Taiwan

Changing Viral Etiology of Hepatocellular Carcinoma in Taiwan

Taiwan is a hyperendemic country of hepatitis B virus (HBV) and hepatitis C virus (HCV) infection. Because HBV and HCV infection could lead to chronic hepatitis, liver cirrhosis and hepatocellular carcinoma (HCC), HCC becomes one of the major health problems in Taiwan. The HBV accounted for 80 to 85% in the causes of HCC, while HCV infection was found in 10 to 20% of HCC patients in 1990s. Universal hepatitis B vaccination was launched in 1984, and the national viral hepatitis therapy and surveillance program was conducted since 2003. The pegylated interferon and nucleos(t)ide analogs were reimbursed for chronic HBV infection and the pegylated interferon combined with ribavirin was provided for chronic HCV infection (all oral direct acting antiviral agents were reimbursed from 2017). The incidence and mortality of HCC decreased in recent 10 years. There was a continuous decline in age- and sex-adjusted rate ratios of HCC mortality and HCC incidence for birth cohorts born after implementation of the HBV vaccination program. Treatments for chronic HBV infection and chronic HCV infection are associated with lower incidence of HCC. The prevalence of HBsAg decreases approximately to 50 % and the prevalence of anti-HCV is about 40% to 50% in HCC patients after 2010s. Taiwan government aims to eliminate the HCV infection before 2025. The incidence and mortality of HCC will be further decreased in the near future.



Dr. Ryosuke Tateishi

Department of Gastroenterology,
The University of Tokyo Hospital, Japan

Changing Epidemiology of Hepatocellular Carcinoma in Japan

Primary liver cancer is the sixth most common cancer and the third most common cause of cancer death globally. Hepatocellular carcinoma (HCC) is the most common pathological type, accounting for 70% to 85% of liver cancers, followed by intrahepatic cholangiocarcinoma. The incidence of HCC shows a tremendous geographic diversity; the high incidence area accumulated in Asia, mainly due to the high prevalence of chronic hepatitis B in Asian countries. The only exception is Japan, where hepatitis C has been the leading cause of HCC. The trend in the incidence of HCC also shows diversity; Japan experienced a rapid increase in liver cancer from the 1970s to the 1990s, followed by a decline from the 2000s, while China experienced a gradual increase until recently. The declining incidence of HCC in Japan reflects the decreasing population with active chronic hepatitis C virus (HCV) infection due to the prevention of horizontal transmission and antiviral therapy. Because the high prevalent population is accumulated in the elderly in Japan, the natural decrease due to aging also contributed to the rapid decline in hepatitis C-related HCC. The hepatitis B virus (HBV) vaccination for newborns has contributed to the remarkable decrease in HBV carriers in the younger generation and will also contribute to the decreasing incidence of HBV-related HCC. Instead of decreasing the number of HBV and HCV-related HCC, increasing non-viral HCC is observed. In Japan, the crude incidence of non-viral HCC increased five times in the last two decades. Although the direct cause of the rapid increase in non-viral HCC is still to be elucidated, it is speculated that the increasing obese population, type 2 diabetes, and fatty liver disease are correlated. An increasing trend of fatty liver disease is also observed in Asian countries, which may contribute to an increase in non-viral HCC in Asian countries.



Dr. Hayato Nakagawa

Department of Gastroenterology and Hepatology, Mie University
Japan

Genomic and Molecular Profiling-Based Personalized Medicine for Liver Cancer


Recent technological advances in genomics and bioinformatics have enabled stratification of cancer patients, which has led to the development of personalized medicine. However, in hepatocellular carcinoma, there are very limited biomarkers to predict therapeutic efficacy due to the lack of targetable mutations as well as inter-tumor heterogeneity, and personalized medicine is currently under development. But recently, some promising genomic and clinicopathological features for predicting therapeutic efficacy have been reported. On the other hand, in intrahepatic cholangiocarcinoma, there are a number of driver mutations that are potential therapeutic targets and several drugs have been approved based on genetic abnormalities including as FGFR2 and IDH1. Thus, I will discuss the current status and future prospects for personalized medicine in liver cancer.

**Dr. Norio Akuta**

Hepatology, Toranomon Hospital, Japan

Dynamics of Circulating miR-122 Predict Liver Cancer and Mortality in Patients with Histopathologically Confirmed NAFLD

It is unclear whether the relationships between changes in fibrosis and circulating miR-122 dynamics might influence the prognosis of NAFLD. This study investigates the impact of serum miR-122 dynamics and histological changes on the incidence of liver cancer and mortality in 81 NAFLD patients who underwent serial liver biopsies. The median interval between the first and second liver biopsies was 2.9 years. Fibrosis stage scores indicated progression, no change, and improvement (a decrease of one point or more) in 21.0%, 56.8%, and 22.2% of patients, respectively. There were 64 patients in the high-risk group who had no improvement in stage scores. Among these, miR-122 levels were significantly lower in 7 patients with liver cancer than those of 54 patients who had no liver cancer at the second liver biopsy. The cumulative rates of liver cancer were significantly higher in cases with miR-122 ratios < 0.5 (serum miR-122 level at second biopsy to that at first biopsy) than those with ratios ≥ 0.5 . The cumulative survival rates in cases with miR-122 ratios < 0.5 tended to be lower than those with ratios ≥ 0.5 . Of 64 high-risk patients, 39 indicated stage 2 or greater (severe fibrosis stage) at the first liver biopsy and also showed similar results of cumulative liver-cancer and survival rates. In conclusion, longitudinal examination of serial liver biopsies indicated that circulating miR-122 dynamics might be useful in predicting the prognosis for NAFLD patients with severe fibrosis stage and no improvement of stage scores.



Dr. Koji Fujita

Department of Gastroenterology and Neurology, Faculty of Medicine,
Kagawa University, Japan

Galectin-9 Suppresses the Growth of Hepatocellular Carcinoma via Apoptosis in Vitro and in Vivo

Galectin-9, a soluble β -galactoside-binding animal lectin, evokes apoptosis in various human cancer cell lines. The galectin-9 antitumor effect against hepatocellular carcinoma (HCC) is, however, unknown. We investigated whether galectin-9 suppresses HCC growth in vitro and in vivo. We assessed the antitumor effect of galectin-9 on HCC cells by conducting WST-8 assay in vitro and xenograft model analysis in vivo. Galectin-9-induced apoptosis was evaluated by FACS and ELISA in vitro and by TUNEL stain in vivo. Cell cycle alteration was profiled by FACS. Caspases were profiled by colorimetry. MicroRNAs related to the galectin-9 antitumor effects were determined using microarrays, and their antitumor effect was confirmed in a transfection study in vitro. The expression levels of the target proteins of the miRNAs extracted above were analyzed by western blot analysis. To summarize the results, galectin-9 inhibited the growth of the HCC cell lines HLE and Li-7 in vitro and Li-7 in vivo inducing apoptosis. Cell cycle turnover was not arrested in HLE and Li-7 cells in vitro. miR-1246 was similarly extracted both in vitro and in vivo, which sensitized Li-7 cells to apoptosis when transfected into the cells. DYRK1A, a target protein of miR-1246 was downregulated in Li-7 cells. Caspase-9 was upregulated in Li-7 cells in vitro and in vivo. In conclusion, galectin-9 inhibited the growth of HCC cells by apoptosis, but not cell cycle arrest, in vitro and in vivo. miR-1246 mediated signals of galectin-9, possibly through miR-1246-DYRK1A-caspase-9 axis. Galectin-9 might be a candidate agent for HCC chemotherapy.



Dr. Satoru Hagiwara

Department of gastroenterology and hepatology,
Kindai University Faculty of Medicine, Japan

Examination of NASH -related Liver Carcinogenesis from Non -developed Fibrosis

Satoru Hagiwara, Naoshi Nishida, Masatoshi Kudo
Kindai University Faculty of Medicine, Japan

Purpose: In recent years, NASH-related liver cancer (NASH-HCC) based on obesity and diabetes has increased, and the number of carcinogenes from liver fibrosis non-developed examples is not common. In this study, we examined in connection with the presence or absence of fibrous development of Nash-HCC liver liver and the change in the cancer and background liver.

Method: In the surgical specimen, 16 cases in which the background liver could be diagnosed with NASH and pathological diagnosis was analyzed. The Stage 3 or more of the Brunt classification is classified as fibrous and less than the Stage 1 as a non -fibrous (n = 8). They used frozen tissue to detect any somatic mutation, with 409 cancer -related gene target sequences and TERT Promoter A comprehensive methylation analysis was performed using a frozen tissue to detect epigenomic mutation.

Results: As for somatic gene mutations, 11 types of mutations (number of mutations per single background liver = 1.4) were observed in both groups regardless of whether fibrosis progressed or not in the background liver tissue, and the clonality of these mutant alleles was There was a clear increase in the corresponding cancerous area. In the background liver, the methylation profile in the background liver was very different from the simple fatty liver, but the methylation profile of the fibrosis and the non -advanced group of fibrosis overlapped.

Conclusion: In NASH patients, there is accumulation of genetic abnormalities and abnormal methylation even in cases where fibrosis does not progress.



Dr. Shun Ishido

Department of Gastroenterology and Hepatology,
Musashino Red Cross Hospital, Tokyo, Japan

Clinical Utility of Comprehensive Genomic Profiling in Patients with Hepatocellular Carcinoma

Kaoru Tsuchiya, Yutaka Yasui, Kenta Takaura, Naoki Uchihara, Keito Suzuki, Yuki Tanaka, Haruka Miyamoto, Michiko Yamada, Hiroaki Matsumoto, Tsubasa Nobusawa, Taisei Keitoku, Shohei Tanaka, Chiaki Maeyashiki, Nobuharu Tamaki, Yuka Takahashi, Hiroyuki Nakanishi, Masayuki Kurosaki, Namiki Izumi

The department of Gastroenterology and Hepatology, Musashino Red Cross Hospital, Tokyo, Japan

Background: Clinical sequencing in tissue and blood specimens has been covered by health insurance since Mar 2021 in Japan. However, its clinical utility in unresectable hepatocellular carcinoma (HCC) remains unknown. We investigated the clinical utility of comprehensive genomic profiling in real-world practice.

Methods: We reviewed the clinical course in unresectable HCC patients tested with Foundation One CDx or Foundation One Liquid between February 2021 and May 2022 at our institution.

Results: Six patients underwent Foundation One CDx or FoundationOne Liquid. The median age of the patients was 63 years, and 4 were male. Background liver disease was HBV/HCV/NBNC in 2 cases each. The treatment line at the time of clinical sequencing was 4th (n=2), 5th (m=1), and 6th - line (n=3), respectively. The samples were from liver tumor biopsy (n=2), surgical specimens of bone metastases (n=2), and blood (n=2). The median number of therapeutic target gene mutations was 4 (2-4). Clinically meaningful oncogene mutations were detected in all cases. CTNNB1 mutations were observed in 3 of 6 patients. No one could participate in the clinical trial. Three of the six patients were due to renal dysfunction or low platelet counts. The expert panel revealed that regorafenib was candidate in 1 patient. One patient showed TMB-high (20 Muts/Mb), and pembrolizumab was administered according to the result.

Conclusions: Our study showed the clinical usefulness of comprehensive genomic profiling in unresectable HCC in real-world practice. The best timing of comprehensive genomic profiling in unresectable HCC patients should be discussed in the future to provide more personalized treatment.



Dr. Balasubramaniyan Vairappan

Jawaharlal Institute of Postgraduate Medical Education and Research,
India

Effect of Nimbolide on miRNAs 21, 145, and 221 Expressions and Tight Junction Integrity in an Experimental Liver Cancer

Balasubramaniyan Vairappan, Victor Mukherjee, Amit Ram
Jawaharlal Institute of Postgraduate Medical Education and Research

Background: Hepatocellular carcinoma (HCC) is the most common form of fatal malignancies, but the molecular genetic mechanism of this disease remains ambiguous. MicroRNAs are becoming increasingly popular in cancer research and are dysregulated in cancer, acting as oncogenes and tumor suppressors. We aimed to elucidate the role of nimbolide in regulating specific microRNAs (21, 145, and 221) and hepatic tight junction integrity in an experimental HCC.

Methods: Diethyl nitrosamine and N-nitrosomorpholine induced HCC mice were administered Nimbolide (6mg/kg b.wt.), a tetranotriterpenoid from the neem tree orally for four weeks following induction of HCC at 28 weeks.

Results: We found significantly increased expressions of miR21a-5p (30-fold) and 221-3p (10-fold) in HCC liver. Treatment with nimbolide to HCC mice significantly decreased the miRs 21a-5p and 221-3p expressions. However, miR145 did not alter between groups. Moreover, hepatic tight junction-associated proteins like claudin-2, zonula occludens (ZO) -1 associated nucleic acid-binding protein (ZONAB) and occludin were significantly decreased whilst significantly increased hepatic expression of claudin-1 and claudin-5 were noted in HCC. The epithelial-mesenchymal transition (EMT) marker E-cadherin hepatic expression was decreased along with increased CDK4, PCNA, Bcl-xL, and N-cadherin protein expressions in HCC mice. Nimbolide treatment to HCC mice positively regulated the above indices.

Conclusion: Our novel data suggested that nimbolide supplementation to HCC mice ameliorated miRs 21a-5p & 221-3p expressions and improved tight junction integrity, thus the tumor growth and severity in HCC mice. Indeed, our further in vitro study would confirm miRs 21a-5p and 221-3p association with specific tight junction proteins in HCC.



Dr. Kenji Amemiya

Genome Analysis Center, Yamanashi Central Hospital,
Yamanashi, Japan

Comparison of Clonality of HCC Arising before and after DAA

Kenji Amemiya¹, Yosuke Hirotsu², Shuntaro Obi², Hitoshi Mochizuki¹, Masao Omata^{3,4}

¹Genome Analysis Center, Yamanashi Central Hospital, Yamanashi, Japan

²Internal medicine, Teikyo university Chiba medical center, Chiba, Japan

³Department of Gastroenterology, Yamanashi Prefectural Central Hospital, Yamanashi, Japan

⁴University of Tokyo, Tokyo, Japan

Aim: Oral administration of anti-HCV drugs has completely changed the liver disease paradigm. We prospectively observed HCC occurrences after SVR at a single institute. Among the basal risk factors, we found that “prior history of HCC” showed strongest predictor, sometimes up to 37 times, and thus APASL guidelines recommend a follow-up interval of within 4 months. (APASL HCV guidelines of virus-eradicated patients by DAA on how to monitor HCC occurrence and HBV reactivation. 2019; 13:649-661). However, this could be easily interpreted as due to residual tumor caused by inadequate treatment. Therefore, we analyzed the HCC tumor before and after DAA.

Methods: We prospectively followed 645 consecutive patients who achieved SVR after DAA. DNA was extracted from respected specimens and genomic analysis was performed on a 72-gene in house HCC panel (285,470 bp). Driver mutations were annotated with OncoKB.

Results: Of the 645 patients, 40 (6%) had HCC before DAA. Of these, we were able to analyze paired 8 nodules (before DAA, 4 nodules and after DAA 4 nodules) from 3 patients who developed HCC after DAA. None of them showed the same "clones"

Conclusion: Analysis of genomic profiling showed that all HCCs after DAA treatment were multicentric in origin. It was suggested that remnant tumor was not a factor for the high risk.



Dr. Yasuhiro Asahina

Department of Gastroenterology and Hepatology,
Tokyo Medical and Dental University, Japan

Hepatocellular Carcinoma after Hepatitis C Viral Eradication

Hepatocellular carcinoma (HCC) is a leading cause of cancer related mortality worldwide, and hepatitis C virus (HCV) is one of the greatest etiological risk factors for HCC development. Chronic HCV infection involves hepatocarcinogenesis directly and indirectly, which include persistent liver inflammation with an impaired antiviral immune response, genetic and/or epigenetic change, viral protein-mediated oxidative stress, and deregulation of proliferative and anti-apoptotic cellular signalling pathways. Co-factors such as hepatitis B virus, alcohol, metabolic syndrome, iron load, and aging also involve hepatocarcinogenesis. Anti-viral treatment for HCV has dramatically improved by the development of direct-acting antiviral agents (DAAs), and a sustained virologic response (SVR) rate has become approximately 100% with DAAs. Along with DAAs developments, incidence of HCC has been decreased. However, HCC still develop after eradication of HCV with incidence ranges from 2.3% to 8.8% at 5 years after SVR and from 3.1% to 11.1% at 10 years after SVR. In this regard, it is a very important to identify risk factors for HCC development after SVR, and to develop more effective surveillance strategy for HCC. Even after achieving SVR, periodic screening for HCC should be continued based on the currently known identified risk factors such as age, male sex, fibrosis progression, alcohol intake, hepatic steatosis, and diabetes as well as post-treatment biomarkers. Analyses of our prospective databases of chronic hepatitis C patients who were treated with DAAs identified AFP and WFA+ Mac-2 binding protein (M2BPGi) as the pre-cancerous biomarkers for assessing the risk of HCC occurrence and recurrence after SVR, and demonstrated these constitute a helpful screening biomarker for enclosure of the risk patients. In future, it is required to explore the mechanism of carcinogenesis after SVR, to develop more precise biomarkers predicting carcinogenesis after SVR, and to undertake new measures based on these findings. Advancement of both basic and clinical research in this field is strongly anticipated.



Dr. Massimo Giuseppe Colombo

Liver Center San Raffaele Hospital Milan, Italy

Evolving Concepts of HCC Surveillance in the Era of Growing Patients with a Sustained Virological Response (SVR)

The excess risk of hepatocellular carcinoma (HCC) that remains following pharmacological eradication of hepatitis C virus (HCV) makes biannual surveillance with abdominal ultrasound (US) recommended by all societies in patients with a pretreatment significant liver disease. In this setting, surveillance improves early detection of HCC and reduces cancer related mortality. However, there are nuances between recommendations with respect to screening strategies, particularly with add on of serum alfa-fetoprotein, second level imaging with abbreviated MRI, and screening beyond the classical target of cirrhosis. While SVR reduces HCC risk by 80% (Beng 2017), the annual risk spans from 0.24 in non cirrhotics to 1.22 in cirrhotics classified by non invasive tests (NIT). (Ioannou 2019) Onset of de-novo HCC is predicted by pre-treatment unmeasured non malignant nodules at CT or MR (Sangiovanni 2020), male sex, diabetes and disease severity. (Degasperi 2020; Auderau 2020) Recurrence and mortality after SVR are better than in viremic patients. (Toyoda 2018 and 2021) but remained high in a single patient data meta analysis in EU and Asia (Sabena 2021). By modelling, surveillance is cost effective in patients with cirrhosis, bridging fibrosis (Metavir F3) or FIB-4 >3.24 (Zangneh 2019). EASL/AASLD recommends screening in cirrhosis (histology or NIT) only, whereas APASL recommends surveillance in older patients, those with cirrhosis (even if regressed) or with diabetes.



Dr. Gamal Shiha

Internal Medicine, Gastroenterology and Hepatology Unit, Mansoura university, Mansoura, Egypt

Founder and CEO, Egyptian Liver Research Institute and Hospital (ELRIAH), Egypt

HCC Risk Stratification after Achieving HCV Eradication

Background and Aim: Many HCC risk prediction scores were developed to guide HCC risk stratification and identify CHC patients who either need intensified surveillance or may not require screening. There is a need to compare different scores and their predictive performance in clinical practice. We aim to compare the newest HCC risk scores evaluating their discriminative ability, and clinical utility in a large cohort of CHC patients.

Patients and Methods: The performance of the scores was evaluated in 3075 CHC patients who achieved SVR following DAAs using Log rank, Harrell's c statistic, also tested for HCC-risk stratification and negative predictive values.

Results: HCC developed in 212 patients within 5 years follow-up. Twelve HCC risk scores were identified and displayed significant Log rank ($p \leq 0.05$) except Alonso-Lopez TE-HCC, and Chun scores ($p=0.374$, $p=0.053$, respectively). Analysis of the remaining ten scores revealed that ADRES, GES pre-post treatment, GES algorithm and Watanabe (post-treatment) scores including dynamics of AFP, were clinically applicable and demonstrated good statistical performance; Log rank analysis analysis <0.001 , Harrell's C statistic (0.66–0.83) and high negative predictive values (94.38–97.65%). In these three scores, the 5 years cumulative IR in low risk groups be very low (0.54–1.6), so screening could be avoided safely in these patients.

Conclusion: ADRES, GES (pre- and post-treatment), GES algorithm and Watanabe (post-treatment) scores seem to offer acceptable HCC-risk predictability and clinical utility in CHC patients. The dynamics of AFP as a component of these scores may explain their high performance when compared to other scores



Dr. Norifumi Harimoto

Division of Hepatobiliary and Pancreatic Surgery,
Department of General Surgery, Gunma University, Maebashi, Japan

Preoperative M2BPGi Predicts Short-term and Long-term Outcome after Hepatic Resection for HCC in Patients Who Achieved SVR

Norifumi Harimoto, Takaomi Seki, Kouki Hoshino, Ryo Muranushi, Kei Hagiwara,
Norihiro Ishii, Mariko Tsukagoshi, Akira Watanabe, Kenichiro Araki, Ken Shirabe
Division of Hepatobiliary and Pancreatic Surgery, Department of General Surgery, Gunma University,
Maebashi, Japan

Purposes: Many studies reported that when SVR for HCV is achieved, even with liver cirrhosis, the liver carcinogenic rate decreases and prognosis improves. Recently, Mac2-binding protein glycosylation isomer (M2BPGi) was developed as a reliable and non-invasive marker for assessing liver fibrosis. This was a retrospective study to investigate whether M2BPGi affects short-term and long-term outcome of hepatocellular carcinoma (HCC) after hepatic resection in patients who achieved a sustained virological response (SVR)

Methods: We retrospectively reviewed the clinicopathological factors from 52 patients who underwent hepatectomy for HCC after achieving SVR. The best cut-off value of M2BPGi was investigated using receiver operating characteristic (ROC) curves and the area under the curve (AUC) was calculated. We divided all patients into high M2BPGi and low M2BPGi groups and analyzed the clinicopathological, short-term and long-term outcomes.

Results: High M2BPGi (>1.42 , $n=13$) was significantly associated with lower serum albumin, higher ICGR15, higher AST, higher ALT, large blood loss, ALBI grade2, open hepatectomy, amount of postoperative ascites and postoperative complication (CD grade \geq IIIa) compared with low M2BPGi (≤ 1.42 , $n=39$). Independent predictors of postoperative complication were High M2BPGi and ALBI grade 2. Univariate analysis identified high M2BPGi, ALBI grade2, histological microvascular invasion, histological intrahepatic metastasis and large tumor size as associated with reduced recurrence-free survival. And also, univariate analysis identified high M2BPGi, ALBI grade2, AFP >100 ng/ml, PIVKAI >100 mAU/ml, and large tumor size as associated with reduced overall survival.

Conclusions: This retrospective analysis indicated that preoperative M2BPGi is a useful biomarker to predict the short-term and long-term outcome of SVR-HCC after hepatic resection.



Dr. Shuntaro Obi

Internal Medicine, Teikyo University Chiba Medical Center,
Chiba, Japan

Previous Liver Cancer History Produces a 13-fold Difference in Carcinogenesis, the Strongest Predictor: a 5-year Prospective Study on 651 SVR Patient in a Single Institute

Shuntaro Obi^{1,2}, Kenji Amemiya³, Yousuke Hirotsu³, Hitoshi Mochizuki^{1,3}, Masao Omata^{1,4}

¹Department of Gastroenterology, Yamanashi Prefectural Central Hospital, Yamanashi, Japan.

²Internal Medicine, Teikyo university Chiba medical Center, Chiba, Japan.

³Genome Analysis Center, Yamanashi Central Hospital, Yamanashi, Japan.

⁴University of Tokyo, Tokyo, Japan

Purpose: Oral administration of anti-HCV drugs has completely changed the paradigm of liver disease. We prospectively observed hepatocellular carcinoma carcinogenesis after SVR at a single institute.

Methods: SVR was achieved after DAA (Direct Acting Antiviral) in 651 patients between 2013 and 2020. The initial 50 patients were enrolled as the two prospective trials (Mizokami/Omata et al. Lancet Infect Dis & JVH) and remaining 601 were consecutively enrolled afterwards.

Results: SVR was achieved in all 651 patients. The median follow-up period was 5.4 years, and HCC occurred in 55 patients (8%) during the follow-up period, with an incidence rate of 1.94 per 100 patient-years. Twenty of the 39 patients (51%) with a previous history of HCC developed HCC, with an incidence rate of 16.5 per 100 patient-years. On the other hand, 35 of 612 patients (6%) without a history of HCC developed HCC, with a rate of 1.3 per 100 person-years. No other parameters including Fib-4 and liver stiffness (Elastography) could not be strong predictions once the history of previous HCC was included.

Conclusion: Rate of HCC occurrence with previous history of HCC was 16.5 per 100, compared with 1.3 for those without a difference of about 13-fold. Genome Profile specimens have shown. The possibility of remnants HCC (even though clinically not apparent) or other unknown potential other than fibrosis could be thought and now in under investigation.



Dr. Takeji Umemura

Department of Gastroenterology and Hepatology,
Shinshu University School of Medicine, Japan

Effect of KIR-HLA Pairs on Hepatocellular Carcinoma in Patients with Chronic Hepatitis B

Natural killer (NK) cells normally respond to tumor cells and virally infected cells by killing them via the innate immune system. However, the functional impairment of NK cells has been observed in hepatocellular carcinoma (HCC). The NK-cell phenotype is partially mediated through the binding of killer cell immunoglobulin-like receptors (KIR) with human leukocyte antigen (HLA) class I ligands. This study evaluated the involvement of KIR-HLA pairs in HCC development in patients with chronic hepatitis B virus (HBV) infection. A total of 280 Japanese HBV cases were retrospectively enrolled. After KIR, HLA-Bw, and HLA-C typing, associations between HLA, KIR, and KIR-HLA combinations and HCC development were evaluated. The proportion of KIR2DS3 was significantly higher in patients with HCC than in those without (30.8% vs. 14.9%; OR: 2.53, $p = 0.015$). Multivariate analysis revealed the factors of male gender (HR: 2.93, 95% CI: 1.31-6.57; $p = 0.009$), age > 65 years (HR: 2.87, 95% CI: 1.35-6.12; $p = 0.006$), and KIR2DS3 positive (HR: 2.90, 95% CI: 1.28-6.58; $p = 0.011$) as independent risk factors for developing HCC. The findings suggest KIR3DS3 may be associated with the development of HCC in patients with chronic hepatitis B. HBV-associated patients with the risk factors of male gender, age > 65 years, and KIR3DS3 may require careful surveillance for HCC onset.


**Dr. Jia-Horng Kao**

Graduate Institute of Clinical Medicine, National Taiwan University

College of Medicine

Department of Internal Medicine, National Taiwan University Hospital,
Taiwan**Primary Prevention of HBV-related HCC**

Ample evidence indicates an etiological association of persistent hepatitis B virus (HBV) infection with hepatocellular carcinoma (HCC). The incidence of HCC is extremely high in HBV hyperendemic areas. For example, in adult patients chronically infected with HBV, the annual risk of developing HCC varies between about 0.5% in the absence of cirrhosis and 2-3% in the presence of compensated cirrhosis if left untreated. Preventive strategies of HBV-related HCC can be divided into primary, secondary and tertiary prevention. The goal of primary prevention is preventing susceptible individuals from acute HBV infection. Hepatitis B vaccination is the most cost-effective measure of primary prevention of HBV-related HCC. For HBV, maternal or vertical transmission during the perinatal period and horizontal transmission in early life are the major transmission routes. In Taiwan, 40% of HBV patients were born to HBsAg-positive mothers and 85%-95% of newborns with HBV exposure became persistent HBV infection. In 2015, universal infant HBV vaccination has been implemented in 180 countries worldwide. Among these countries, Taiwan is the first one to launch a nationwide universal hepatitis B vaccination programme since 1984. With successful implementation, the HBV infection rate (anti-HBc positivity) decreased from 38% to 4.6% in children. The HBsAg seropositive rate in infants and children remarkably declined up to 90% in 2012. Similarly, the reduction in HBsAg positivity in children was also observed in other countries after the implementation of universal hepatitis B immunisation. In addition to prevent HBV infection of infants, hepatitis B vaccination also reduced liver cancer in children, teenagers and young adults. After the implementation of HBV vaccination programme in Taiwan, the incidence of HCC in children decreased from 0.92 per 100,000 in the unvaccinated cohort to 0.23 per 100,000 in the vaccinated birth cohorts. A population-based analysis from Taiwan Cancer Registry revealed that the changes in incidence rates and trends of HCC stratified by age group were obvious during 2003-2011. A slight increasing annual incidence (1.3%) was observed for elderly people, in contrast to annual incidence decreasing (16.6%) for children. These encouraging data from Taiwan and other countries provide the convincing evidence that universal HBV vaccination notably reduces HBsAg prevalence and HCC incidence in vaccinated subjects. Furthermore, HBV-related HCC can be primarily prevented by HBV vaccination and hepatitis B vaccine is indeed the first cancer preventive vaccine in the human history.



Dr. Saeed Hamid

Professor, Department of Medicine, Aga Khan University, Karachi, Pakistan

HCC Caused by Hepatitis Delta Virus Infection in Asia-Pacific

HDV infection is the severest form of chronic viral hepatitis known to humans. It leads to rapidly progressive liver disease that often culminates in end-stage liver disease and liver cancer. Although now recognized as a global infection of importance, there is wide variation in prevalence of HDV infection mainly due to lack of adequate and accurate testing. Asia Pacific region has few hot spots of HDV infection that contribute to the overall burden of HDV globally.

Adverse liver related outcomes that increase with HDV infection include the development of liver cirrhosis (2-3 fold) and HCC (3-6 fold). Cumulative probability of developing HCC increases to 15% at 20% years of follow up. In some hot spots, such as Mongolia, this frequency may even be higher particularly in younger patients. Certain mutated oncologic signal pathways and driver genes are found in the Mongolian cohort, which may explain this higher frequency. In addition, HDV induces specific DNA methylation processes, leading to HCC.



Dr. Kiyooki Ito

Department of Gastroenterology,
Aichi Medical University School of Medicine,
Nagakute, Japan

Trends of Hepatitis B Virus Genotype Distribution in Chronic Hepatitis B Patients in Japan

Background: Hepatitis B virus (HBV) is one of the most prevalent chronic viral infections that causes chronic hepatitis B (CHB), cirrhosis, and hepatocellular carcinoma (HCC). In Japan, genotypes B and C account for most of acute and chronic cases of hepatitis. However, previous studies showed that the prevalence of genotype A in CHB gradually increased every 5 years. We have conducted a nationwide survey to comprehensively investigate the trends of HBV genotype distribution in CHB patients in Japan.

Methods: 4,421 CHB patients were recruited between 2015 and 2016. Clinical characteristics and distribution of CHB patients among different age groups and genotypes in 2015-2016 was compared with those in 2000-2001, 2005-2006, and 2010-2011.

Results: The percentages of genotype A, B, C, and D were 4.0%, 16.2%, 79.1%, and 0.7%, respectively. While the overall percentage of CHB patients with genotype A did not change in the past five years, CHB with genotype A increased in young adults. On the other hand, the peak distribution of CHB with genotypes B and C, two genotypes with the largest patient population, has shifted to an older age group. In genotype A, liver disease does not appear to be advanced in most patients. However, one patient developed HCC at a relatively younger age (45-49 years old). Among patients infected with genotype B, the prevalence of cirrhosis and HCC was higher in patients over 60 years of age. On the other hand, in patients with genotype C, liver disease progressed to cirrhosis and HCC at a relatively younger age.

Conclusions: In Japan, the peak distribution for CHB with genotypes B and C advanced to an older age group while CHB with genotype A expanded in a younger age group. In the future, the number of patients with genotype B may decrease because of the relatively low proportion of patients in younger and middle-age groups. On the other hand, the number of patients with genotypes A and C may not decrease because the prevalence of genotypes A and C remains high in younger and middle-age groups. Therefore, for patients with genotype C, it is necessary to perform continuous examinations, such as ultrasonography, enhanced CT, or enhanced MRI to detect HCC in its early stages.



Dr. Hong you
Liver Research Center
Beijing Friendship Hospital,
Capital Medical University, China

The Prediction Model of HBV-HCC During Anti-viral Therapy

To assess comparative performance of 14 hepatocellularcarcinoma(HCC) prediction models in chronic hepatitis B (CHB) patients using on-treatment values at different timepoints.

Based on a nationwide prospective cohort of 986 treatment-naïve CHB patients undergoing entecavir therapy with every 26-week follow-up, 14 HCC risk scores were calculated using on-treatment values at week 26, 52, 78, and 104, respectively. Model performance predicting 3-year HCC was assessed using time-dependent area under the receiver operating characteristic curve (AUC) and calibration index. Model cutoffs were validated through common diagnostic accuracy measures.

During median 4.7-year follow-up, 56 (7.5%) developed HCC. Discrimination using on-treatment values within first 2 years was generally acceptable for most models (AUCs ranging from 0.68 to 0.81), except for REACH-B, NGM-HCC, and PAGE-B, although AUCs slightly decreased from week 26 to 104. Of these, REAL-B, CAMD, GAG-HCC, AASL-HCC, LSM-HCC, mPAGE-B, and mREACH-BII showed highest discrimination with AUCs ranging from 0.76 to 0.81, 0.72 to 0.76, 0.70 to 0.76, and 0.71 to 0.74 when reassessment at week 26, 52, 78, and 104, respectively. With reassessment within first 2 years, both REAL-B and CAMD calibrated well (Brier score ranging from 0.037 to 0.052). Of 9 models reporting cutoffs, REAL-B, AASL-HCC, and mPAGE-B using on-treatment values could identify 30%–40% of patients as low risk with minimal HCC incidence in the low-risk group (0.40% [REAL- B]–1.56% [mPAGE-B]).

In this undergoing antiviral treatment CHB cohort, most HCC prediction models performed well even using on-treatment values during first 2 years, particularly REAL-B, AASL-HCC, CAMD, and mPAGE-B model.



Dr. Takanori Suzuki

Department of Gastroenterology and Metabolism, Nagoya City University
Graduate School of Medical Sciences, Nagoya, Japan

A Novel Prediction Model of HCC Development in Chronic Hepatitis B Patients Under Antiviral Therapy

Takanori Suzuki¹, Kentaro Matsuura¹, Yoshihito Nagura¹, Kei Fujiwara¹, Hiromi Kataoka¹,
Yasuhito Tanaka²

¹Department of Gastroenterology and Metabolism, Nagoya City University Graduate School of Medical
Sciences, Nagoya, Japan

²Department of Gastroenterology and Hepatology, Faculty of Life Sciences, Kumamoto University,
Kumamoto, Japan

Background and Aim: It is known that administration of nucleos(t)ide analogue (NA) for chronic hepatitis B (CHB) suppresses development of hepatocellular carcinoma (HCC), but not completely suppress HCC. We investigate the risk factors for development of HCC in CHB patients under NA therapy, and propose a novel HCC prediction model.

Methods: We enrolled 299 CHB patients who started administration of NA at our hospital between January 2000 and March 2022. The median observational period was 100 months.

Results: HCC was developed in 32 patients who were older and had higher ratio of liver cirrhosis (LC), higher levels of HBsAg, AFP, FIB-4 index and M2BPGi, lower levels of platelet counts, compared to those without HCC. Multivariate analysis revealed that higher levels of FIB-4 index and M2BPGi at administration of NA were significant risk factors for HCC development. We set the cut-off value of FIB-4 index as 1.73 and that of M2BPGi as 1.73, using ROC analysis. If levels of FIB-4 index or M2BPGi were ≥ 1.73 , we set as a score of 1, and we stratified all the patients into 3 groups according to the total score (0, 1, 2). The cumulative incidence rates of HCC (5, 10 years) were 0, 0% in score 0 group, 3.3, 9.7% in score 1 group, and 15.5, 24.8% in score 2 group.

Discussion and Conclusion: The prediction model based on FIB-4 index and M2BPGi enables us to extract patients with high risk of HCC development under NA therapy.




Dr. Atsushi Tanaka

Department of Medicine, Teikyo University School of Medicine,
Japan

HBV Management -Protection for HCC Occurrence

Although the risk for HCV-induced hepatocarcinogenesis has been significantly reduced with anti-HCV DAA treatment followed by eradication of HCV, HBV-induced HCC occurrence has not been decreased over time even though various NAs are currently available. Clinical practice guidelines recommend that NAs are administered for HBV-related cirrhosis, or HBV-related chronic hepatitis with high ALT and high serum HBV-DNA; but it is likely that more aggressive use of NAs may be required to significantly reduce occurrence of HCC in HBV-infected patients, based on the assessment of risk factors for development of HCC. The risk factors for HCC in patients infected with HBV include older age, male sex, high-viral load, advanced fibrosis, comorbidities (alcohol consumption or non-alcoholic steatohepatitis), a family history of HCC, and those who have these risk factors may be needed to be treated with NAs for protection for HCC occurrence, even though out of treatment indication described above. Those with mild or intermittent elevation of ALT, low platelet counts, moderate or advanced fibrosis are also candidates for NA treatment. Furthermore, it should be determined how intensive monitoring for HCC development with imaging studies should be performed in these patients.



Dr. Ting Ting Shi

Department of Gastroenterology and Neurology,
Faculty of Medicine, Kagawa University

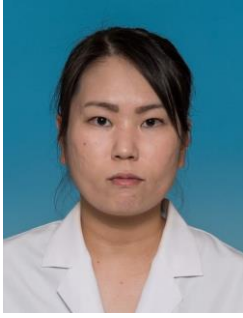The Suppression Role of Aspirin in Hepatocellular Carcinoma Cells Partially by microRNA Alterations

Background/Objective: Hepatocellular carcinoma (HCC) is an important source of cancer-related mortality worldwide. Aspirin, a classical nonsteroidal anti-inflammatory drug (NSAID), is known to inhibit cell proliferation in various cancer cells. Moreover, the randomized clinical trials suggest the evidence that aspirin is linked to a lower risk of HCC development and improved the survival rate of patients. The aim of the present study is to investigate the underlying mechanism of aspirin on HCC.

Methods: Seven HCC-derived cell lines were used for analyzing the effects of aspirin on cell proliferation, cell cycle, and apoptosis. MicroRNAs were analyzed by the microRNA array chip. The results were validated in vivo using a nude mouse model of Huh-7 xenograft models.

Results: Aspirin exhibited an anti-proliferative effect on all HCC cells. Moreover, aspirin induced G0/G1 cell cycle arrest, increased the early apoptotic cells, upregulated the levels of microRNA-137 and inhibited epidermal growth factor receptor (EGFR) activation. Furthermore, overexpression of miR-137 decreased the cell proliferation ability and EGFR expression of Huh-7 cells. Aspirin therefore upregulated miR-137 levels, inhibiting EGFR expression, activation and decreasing cell proliferation ability. In vivo results showed that aspirin reduced the growth of xenograft tumors in nude mice.

Conclusion: In conclusion, aspirin inhibited the growth of HCC cells partially by cell cycle arrest, apoptosis and alteration of microRNA expression.



Dr. Kyoko Oura

Department of Gastroenterology and Neurology,
Faculty of Medicine, Kagawa University, Kagawa, Japan

Serum microRNA-125a-5p as a Potential Biomarker of HCV-associated Hepatocellular Carcinoma

Background: During diagnosis of early stage hepatocellular carcinoma (HCC), single or small lesions are difficult to identify using screening ultrasonography, and conventional tumor markers are frequently negative. MicroRNAs (miRNAs) are small non-coding RNAs that suppress the translation of target mRNAs and exert significance as biomarkers. The aim of the present study was to use samples of patients with HCC and those with other liver diseases caused by hepatitis C virus (HCV) infection to investigate the expression profile of serum miRNAs, and identify a miRNA that can serve as a HCC biomarker.

Methods: Initially, changes in 2,555 miRNAs between pre- and post-curative treatment serum from 12 patients with early stage HCC were examined using microarray analysis. The serum levels of miR-125a-5p in 40 individuals with HCV-associated chronic hepatitis (CH), liver cirrhosis (LC) or HCC were measured using reverse transcription-quantitative polymerase chain reaction.

Results: five miRNAs, including miR-125a-5p, miR-423-5p, miR-1247, miR-1304 and miR-3648, were identified to be downregulated following curative treatment in patients with HCC. Among these, miR-125a-5p was identified to be similarly decreased following treatment in all patients. Additionally, the expression levels of miR-125a-5p were significantly upregulated in patients with HCC in the early and advanced stages of disease, compared with patients with CH or LC ($P < 0.05$).

Conclusion: Serum miR-125a-5p fluctuates depending on the presence of HCC, and may serve as a noninvasive biomarker to aid in diagnosing early carcinogenesis in HCV-associated chronic liver diseases.



Dr. Norio Akuta

Hepatology, Toranomon Hospital, Japan

TERT Promotor Mutation in Serum cfDNA Predicts Non-viral Liver Cancer with Fatty Liver Disease

TERT promoter mutations are the most frequent genetic alteration in liver cancer. However, it remains unclear whether TERT C228T in serum cfDNA is useful for the diagnosis of liver cancer with non-viral fatty liver disease (FLD). This retrospective cohort study examined 274 Japanese patients who had a confirmed diagnosis of primary liver cancer. We investigated the factors associated with TERT C228T and AFP levels in serum samples. Serum TERT C228T was detected using a highly sensitive method based on wild-type blocking PCR. Multivariate analysis identified the etiology of FLD, vascular invasion, and non-cirrhosis as determinants of TERT C228T-positive liver cancer. The determinants of AFP-abnormal liver cancer identified were female gender, etiology of HBV, larger tumor diameter and number, poorly differentiated HCC, vascular invasion, and cirrhosis. Rates of positive TERT C228T in FLD were significantly higher than those of HBV and HCV. Conversely, rates of abnormal AFP in FLD were significantly lower than those of HBV and HCV. Viral suppression of HBV/HCV and alcohol intake did not affect TERT C228T, but AFP was significantly reduced by viral suppression. The rates of positive TERT C228T were significantly lower in HCV patients with viral clearance than those of FLD patients. In conclusion, our results highlight the importance of serum TERT C228T rather than AFP for the detection of non-viral FLD-related liver cancer. TERT C228T is a tumor marker that might not be influenced by inflammation.



Dr. Etsushi Kawamura

Department of Hepatology, Graduate School of Medicine,
Osaka Metropolitan University, Japan

In Vitro Study on the Function of Sloan Kettering Institute Gene in Suppression of Intrahepatic Cholangiocarcinoma Growth

Etsushi Kawamura¹, Tsutomu Matsubara², Hideto Yuasa², Hayato Urushima², Shogo Tanaka³, Shigekazu Takemura³, Sawako Uchida-kobayashi⁴, Masaru Enomoto¹, Y-h Taguchi⁵, Kazuo Ikeda², Shuhei Nishiguchi¹, Norifumi Kawada¹

¹Department of Hepatology, Graduate School of Medicine, Osaka Metropolitan University

²Department of Anatomy and Regenerative Biology, Graduate School of Medicine, Osaka Metropolitan University

³Department of Hepato-Biliary-Pancreatic Surgery, Graduate School of Medicine, Osaka Metropolitan University

⁴Department of Premier Preventive Medicine, Graduate School of Medicine, Osaka Metropolitan University

⁵Department of Physics, Chuo University

Background: We started the present study to explore the gene expression profile associated with tumor growth in human intrahepatic cholangiocarcinoma (CC), with the aim of discovering new therapeutic targets.

Methods: To identify differentially expressed microRNAs, we conducted microRNA and mRNA microarrays in 24 human surgically resected hepatobiliary tumors including 10 CCs and their serum exosomes, followed by in silico screening. We used human intrahepatic CC cell line OZ for analyses of the extracted gene function.

Results: 24 types of microRNAs were extracted by computational analysis of microarray data. Among them, it was predicted that the combination of microRNA-3648 and its target, the Sloan Kettering Institute gene (SKI) mRNA, is the strongest relationship. Described below are the results of the analysis using OZ cells. As the prediction, microRNA-3648 overexpression suppressed SKI protein expression. SKI overexpression upregulated cyclin-dependent kinase inhibitor p21 protein expression and activated transgenic p21-luciferase. SKI overexpression suppressed the proliferation of this cells and the nuclear expression of the chromatin licensing and DNA replication factor 1 protein required for G1/S transition.

Conclusions: These data showed the involvement of SKI in p21 transcription and suggest that SKI-p21 signaling causes cell cycle arrest in G1 and suppresses intrahepatic CC cells growth. This signaling can be a therapeutic target.



Dr. Makoto Chuma

Gastroenterological Center, Yokohama City University Medical Center,
Japan

Circulating microRNA-1246 as a Possible Biomarker for Early Tumor Recurrence of Hepatocellular Carcinoma

Makoto Chuma¹, Hidenori Toyoda², Juntaro Matsuzaki⁴, Yoshimasa Saito⁵, Atsuyuki Maeda³, Koji Ogawa⁶, Hideki Yokoo⁷, Akito Nozaki¹, Kazushi Numata¹, Akinobu Taketomi⁷, Takashi Kumada², Naoya Sakamoto⁶, Shin Maeda⁸

¹Gastroenterological Center, Yokohama City University Medical Center

²Departments of Gastroenterology and Hepatology, Ogaki Municipal Hospital, Ogaki Japan ³Departments of Surgery, Ogaki Municipal Hospital, Ogaki Japan

⁴Departments of Gastroenterology, Keio University

⁵Division of Pharmacotherapeutics, Keio University Faculty of Pharmacy

⁶Departments of Gastroenterology and Hepatology, Hokkaido University Hospital, Sapporo Japan

⁷Departments of Gastroenterological Surgery I, Hokkaido University Hospital, Sapporo Japan ⁸Department of Gastroenterology, Yokohama City University, Yokohama, Japan

Aims: Identification of new biomarkers to predict the aggressiveness of HCC is an important clinical issue. Since miRNAs are involved in cancer biology, certain distinctive serum miRNAs could be useful for cancer diagnosis and prognosis. We investigated the prognostic potential of miR-1246 in sera from patients with HCC.

Methods: The expression of miR-1246 was evaluated using real-time quantitative PCR testing of 132 serum samples (111 samples from HCC patients, 10 samples from chronic hepatitis (CH) or liver cirrhosis (LC) patients, and 10 samples from controls).

Results: Serum miR-1246 levels were significantly upregulated in HCC patients compared with healthy controls ($P < 0.01$) and CH or LC patients ($P < 0.01$). Moreover, serum miR-1246 levels were significantly upregulated in patients with early recurrence (within 12 months after hepatectomy) ($n=33$, 156.4 ± 82.9) than in patients without early recurrence ($n=78$, 14.08 ± 15.4 ; $P < 0.01$). Serum miR-1246 showed a receiver-operating characteristic curve (ROC) area of 0.769, with 83.7% specificity and 54.9% sensitivity in discriminating HCC patients with early recurrence from HCC patients without early recurrence. Serum miR-1246 levels correlated with histological grade ($P=0.036$) and portal vein invasion ($P= 0.021$). Moreover, the multivariable analysis indicated that serum miR-1246 level was an independent risk factor for overall survival (HR 6.134, 95% CI 2.858-13.165, $P < 0.01$).

Conclusions: These data indicate that serum miR-1246 has strong potential as a novel diagnostic and prognostic biomarker in HCC.



Dr. Kenji Amemiya

Genome Analysis Center, Yamanashi Central Hospital,
Yamanashi, Japan

Validation of Genomic Analysis and EOB-MRI (RER)

Kenji Amemiya¹, Yosuke Hirotsu¹, Shuntaro Obi², Hitoshi Mochizuki¹, Masao Omata^{3,4}

¹Genome Analysis Center, Yamanashi Central Hospital, Yamanashi, Japan

²Internal medicine, Teikyo university Chiba medical center, Chiba, Japan

³Department of Gastroenterology, Yamanashi Prefectural Central Hospital, Yamanashi, Japan

⁴University of Tokyo, Tokyo, Japan

Aim: It has been reported that RER value of EOB-MRI can identify abnormalities in WNT/ β -catenin pathway. We reevaluated the utility of RER value using genomic profiles as a reference, using solitary and multiple nodules (synchronous occurrences) from our institution.

Methods: We extracted DNA from 49 patients with 75 nodules (solitary: 29 patients with 29 nodules, multiple: 20 patients with 46 nodules) from FFPE tissues. Genomic profiles were identified using in-house HCC panels (72 SMGs: 59,016 aa) containing Wnt/ β catenin pathway (CTNNB1, APC, NCOR1, AXIN1, FGF19). We compared the genomic profiles and RER quantitative values.

Results: Genomic abnormality of Wnt/ β catenin pathway were seen in 16/75 (21%) (CTNNB1: 11, APC: 2, NCOR1: 2, AXIN1: 1 case). Genomic abnormality of other pathway (non Wnt/ β catenin) detected in 59/75 (79%). The median of RER quantitative values with aberrant Wnt/ β catenin pathway were 0.89 (0.54-1.69). The median of RER quantitative values with aberrant other pathway (non-Wnt/ β catenin) were 0.70 (0.39-1.06). With a cutoff of $0.9 \leq \text{RER}$, Wnt/ β catenin aberrant group were above the level in 8/16 (50%), whereas in 7/59 (12%) in the other. However, the majority (69/75, 89%) were RER range of 0.5 and 1.2 and overlapped between the two groups.

Conclusion: As a surrogate of genomic abnormality, it is tempting to use RER. However, it give very ambiguous values in the majority (85%). The cases, eight (11%) cases, although small in number, like fairly high ($\text{RER} > 1.2$) or fairly low ($\text{RER} < 0.5$) could be utilized clinically.



Dr. Asahiro Morishita

Department of Gastroenterology and Neurology,
Kagawa University, Japan

A New Therapeutic Strategy Using Circulating microRNA that Predicts Drug Resistance of Atezolizumab+Bevacizumab for the Treatment of Advanced Hepatocellular Carcinoma

Background: Atezolizumab+bevacizumab (atezo+bev) therapy was indicated for unresectable hepatocellular carcinoma (HCC) as the first combined immunotherapy. Compared with existing molecular-targeted drugs, significant prolongation of OS and PFS was observed in atezo+bev therapy. However, there are not a few cases with poor effect, and therefore, the timing of switching to conventional molecular-targeted drugs is important. Therefore, there is an urgent need to develop a biomarker for early determination of atezo+bev resistance.

Aim: The aim of this study is to analyze circulating microRNA (cmRNA) as a biomarker for early diagnosis of treatment resistance of atezo+bev.

Methods: For unresectable hepatocellular carcinoma with Child-Pugh A performed at our hospital, 5 cases with CR/PR and 6 cases with PD on atezo+bev were registered. CmiRNAs from serum were analyzed using digital PCR before and after administration of atezo+bev.

Results: In patients with hepatocellular carcinoma, serum microRNAs before atezo+bev treatment formed different clusters in CR/PR and PD cases, and 10 significantly different microRNA candidates ($P<0.05$) and 5 significantly different microRNA candidates ($P<0.01$) were involved in the therapeutic effect. These microRNA candidates were confirmed by real time RT-PCR. In the pre-treatment serum, we found five microRNA candidates involved in atezo+bev resistance.

Discussion: There was significant variation in several microRNAs involved in resistance in the serum prior to atezo+bev administration, and quantification of these molecules in the pre administration specimens was considered necessary to select other molecularly targeted agents.

Conclusion: MicroRNAs were indicated to be critical biomarkers for diagnosing resistance to atezo+bev.



Dr. Shuichiro Shiina

Department of Gastroenterology, Juntendo University, Japan

Treatment of Early-stage Hepatocellular Carcinoma by Image-guided Ablation

Ablation is potentially curative, minimally invasive and easily repeatable for recurrence. RFA is still the most chosen treatment of small liver malignancy, because RFA has been well-studied in clinical practice. The new-generation MWA system incorporating antenna cooling and high-power generation has attracted attention. It can create a more predictable ablation zone and a larger ablation volume in a shorter procedure time. Many high-volume centers have introduced new-generation MWA for liver tumor ablation in Japan. However, the MWA antenna has some problems: 1) more difficult to insert into the liver, 2) can be seen less clearly by US, 3) more fragile. Many studies failed to show that new-generation MWA is superior to RFA in terms of local control and overall survival. In MWA, clinical data have been insufficient compared with those of RFA.

There has been keen competition between surgical resection and ablation for HCC for almost 40 years. In 2021, SURF trial revealed that overall survival and recurrence-free survival were not significantly different between surgical resection and RFA. SURF trial was a multicenter randomized controlled trial in which 49 major centers in Japan enrolled patients with good hepatic function and primary HCC of ≤ 3 cm, and ≤ 3 nodules during the 6-year period of 2009-2015. The registered patients were followed for at least 5 years. As the result of SURF trial and other comparative studies, the revised Japanese clinical practice guidelines in 2021 treat hepatic resection and ablation equally for early HCC patients.

Education is important to acquire skills and knowledge for successful ablation because ablation is highly operator-dependent. The skills and outcomes are very different from operator to operator. Before the pandemic of COVID-19, we had domestic and international training programs for intermediate and advanced doctors and ablation club (hands-on seminars) for young doctors. These were activities to exchange knowledge and experience and standardize the procedure. During the pandemic, we cannot get together. Since August 2020, we have conducted Japan Ablation Webinar 8 times, with 1,566 participants. We have also conducted International Ablation Webinar 4 times, with 1,272 participants.

We have established Japan Academy of Tumor Ablation (JATA) this year. There are two triggers. One is that SURF trial revealed that there is no difference in OS and RFS between hepatectomy and ablation. The other is that ablation for lung, bone and soft tissue and kidney cancers will be reimbursed with health insurance from September 2022 in Japan.



Dr. Kazutaka Kurokohchi

Department of Internal Medicine Meiwa Hospital, Japan

Combination Therapy PEI and RFA (PEI-RFA) for the Treatment of HCC

Early detection and treatment is important for cancer treatment and this is also true in the treatment of liver cancer as well. RFA therapy is effective for liver cancer detected at an early stage. When I was a member of Department of gastroenterology in Kagawa University in 1999, I performed the first RFA treatment for HCC in Kagawa Prefecture, one of the earliest in Japan. In the process of performing numerous RFA treatments since then, it became necessary to develop a less invasive and more effective treatment for aging patients with liver cancer. We developed combination therapy of PEI and RFA (PEI-RFA) and reported it for the first time in the world (Int J Oncol 21: 611-615, 2002, Int J Oncol 21: 841-846, 2002). It has been turned out that PEI-RFA is more effective with less energy and shorter treatment time.

In addition, it is able to increase the ablated volume by increasing the amount of ethanol injected in the PEI-RFA, therefore, in some cases unfortunately found to be larger than 2 cm in diameter. PEI-RFA may be effective for mass reduction of HCC as a preliminary step to the recent molecular targeted therapy and immunotherapy for liver cancer.

We would like to summarize PEI-RFA that I have originally developed and reported for the first time in the world.



Dr. Shinpei Sato

Sato Clinic, Kyoundo Hospital, Liver Unit, Japan

Percutaneous Radiofrequency Ablation in Early-stage Hepatocellular Carcinoma

Radiofrequency ablation (RFA) is a minimally invasive treatment widely performed for the treatment of liver neoplasms. Recently, resulting of long prognosis has made by ablation in the clinical practice. In Japan, JSH consensus statements and recommendations 2021, Resection and RFA are equally recommended as first-line therapy in patients of less than 3cm, 3 nodules HCC in the result of a head-to-head randomized controlled trial (SURF trial).

We introduced adjustable RFA electrode needle (VIVARF system) which became usable from 2015 in order to improve therapeutic results of RFA. In 125 patients with liver cancer. The 5-year survival rate of RFA at our institution is 70%. Although local recurrence rate after curative RFA is as low as 6.0%, the intrahepatic distant metastasis is as high as 70% at 5 years. Complications were skin burned in 4.2% due to cause by needle damage from induction needle. We use a variety of techniques such as artificial pleural effusion, artificial ascites, under sedation to improve the effectiveness of our treatments. After the treatment, the prevention of intrahepatic distant recurrence by direct-acting antivirals (DAAs) is very important.

In this session, I would like to talk about recent progress in RFA of early stage HCC.



Dr. Yasunori Minami

Department of Gastroenterology and Hepatology,
Kindai University Faculty of Medicine, Japan


Challenging Precise Ablation: Imaging Navigation Techniques with Contrast Enhanced US and Fusion Imaging

Local ablative therapy has evolved as an alternative to surgical resection for early stage hepatocellular carcinoma (HCC). Radiofrequency ablation (RFA) or microwave ablation (MWA) is an efficient local hyperthermic ablative therapy, and technical success of percutaneous ablation therapy requires correct targeting via an imaging technique. However, multiple treatment sessions are often required for small HCCs, which are poorly defined on B-mode US. In that difficult situation, it has become more challenging to obtain high local controllability in ablation therapy. Then, we have two approaches in ablation therapy, contrast enhanced US (CEUS) guidance or fusion imaging guidance, for small HCCs with poor conspicuity.

CEUS gains the signal intensity from blood vessels at capillary level through the administration of microbubble contrast agents and can depict tumor vascularity sensitively and accurately. Therefore, CEUS can increase the detectability of small HCCs compared to B-mode US and is very useful for localizing invariable HCCs. Especially, the technique called defect reperfusion imaging makes it possible to depict B-mode ill-defined HCC. Either locally recurrent HCCs or new HCCs undetectable on the B-mode US can benefit from CEUS guided ablation therapy.

Fusion imaging can provide cross sectional images of volume data on CT/MRI corresponding to the angle of the transducer in the magnetic field. This imaging technique displays a real-time synchronized multiplanar CT/MR image in the same slice of the US plane. Thus, CT/MRI-US fusion image guidance can support targeting an HCC nodule, especially for nodules demonstrated on CT/MRI, but not on US. Recently, the advances of fusion imaging have made it possible to visualize the ablative margin on US. By an overlay of preoperative and postoperative US, the tumor image could be projected onto the white ablation zone in real-time. US-US overlay fusion can show the ablative margin during the procedure and be proposed as a feasible guidance method in RFA therapy with a safety margin.

These imaging navigation techniques with contrast enhanced US and fusion imaging can support the achievement of sufficient safety margins in RFA therapy and reduce the risk of local tumor progression.



Dr. Kazuya Kariyama

General Medical Director, Department of Gastroenterology,
Okayama City Hospital, Japan

Radiofrequency Ablation for the Treatment of Early-stage HCC

Introduction: The recommended treatment for early-stage HCC is unequivocally hepatectomy or ablation. We have performed RFA for 3400 sessions and 7000 nodules since 2001. In this study, we retrospectively evaluated RFA in our hospital.

Methods: Subjects were HCC patients who had undergone RFA at our hospital since 2001. Prognosis, factors related to prognosis, problems, and measures to solve these problems were reviewed.

Results: Subjects were 655 patients who underwent initial RFA at our hospital. Median age 71 years, male 70.5%, HBsAg positive 11.0%, HCVAb positive 60.6%, Child-Pugh A/B/C (%); 458 (69.9)/167 (25.5) 30 (4.6), BCLC-0/A/B/C/D (%); 166 (25.3)/284 (43.4)/106 (16.2) / 79 (12.1) / 20 (3.1). Median number of tumors was 1 (1-20), median tumor diameter was 20 (7-200) mm, and MST/5-year survival was 8.8 years/64.8% for patients within Milano criteria (N=459) and 3.8 years/37.9% for patients without Milano criteria (N=196). The local recurrence rate was 16.8% for patients within the Milano criteria and 19.8% for those without the criteria at 5 years. Of the total 3,400 sessions, 180 nodules were located in the caudate lobe. The following treatment modalities were used as therapeutic support: (1) back-application of contralateral plate, (2) artificial ascites, (3) artificial pleural effusion, (4) RFA with ENBD cooling, (5) fusion imaging, and (6) contrast-enhanced ultrasound puncture.

Conclusion: The results of RFA for early-stage HCC were good, and it was considered the first choice for treatment. However, it is difficult to treat all nodules by conventional ultrasound imaging alone, so the use of various devices is of utmost importance.



Dr. Tadatoshi Takayama

Vice-President, Nihon University,

Professor of Surgery, Nihon University School of Medicine, Japan

Early Hepatocellular Carcinoma as an Entity of Surgical Cure

Early hepatocellular carcinoma (HCC) is defined as a well-differentiated cancer containing Glisson's triad, but it remains unknown whether this lesion is curable. We prospectively studied 70 patients who had diagnosis of a single HCC 2cm or less in diameter (Stage T1), underwent curative resection and long-term follow-up.

Based on typing system, the tumors were assigned as early HCC (n=15), overt HCC (n=52), and non-HCC

tumor (n=3). In these two groups, the 5-year rates of overall survival were 93% and 54% (p=0.01), and those

of recurrence-free survival were 47% and 16% (p=0.05), respectively. Early HCC is a distinct entity with a

high rate of surgical cure, corresponding to "Stage 0" cancer in other organs.



Dr. Takuto Hikichi

Department of Endoscopy, Fukushima Medical University Hospital, Japan

Endoscopic Treatment for Esophageal and Gastric Varices in Japan

Introduction: Endoscopic treatment of esophageal and gastric varices has been developed and is now well established. In this lecture, I describe the endoscopic treatment of esophageal and gastric varices in Japan, focusing on the treatment strategy at Fukushima Medical University Hospital.

Esophageal Varices: Endoscopic treatment of esophageal varices (EVs) includes endoscopic injection sclerotherapy (EIS) and endoscopic variceal ligation (EVL). EVL is more widespread worldwide because it is simpler than EIS and has no risk due to sclerosants. However, EVL has a higher recurrence rate than EIS. Therefore, EIS is still considered more important in Japan. Sclerosants include ethanolamine oleate (EO) and polidocanol (aethoxysklerol: AS), but AS is the most commonly used sclerosant worldwide. AS has a weak sclerosing effect on EVs and some literatures have reported to be less effective than EVL in preventing recurrence. In contrast, EO is used as an intravascular injection especially in Japan, because of its superior sclerosing effect. The combination EO and AS, which is performed extravascular injection of AS following intravascular EO injection, is the standard treatment for EIS in Japan. In addition, when used in combination with argon plasma coagulation, it provides additional recurrence prevention. By the way, regarding the EVL, the combination of AS with extravascular injection can also be effective in preventing recurrence of EVL.

Gastric varices: Endoscopic treatment of gastric varices (GVs) differs between Sarin's classification of gastroesophageal varices (GOV) and isolated gastric varices (IGV). CA is used not only in cases of bleeding but also as prophylactic treatment. Moreover, a combination of CA and EO is used in Japan. Recently, endoscopic ultrasound-guided GV treatment, coil deployment, has also begun to be performed.

Conclusion: Endoscopic treatment of EVs and GVs is minimally invasive and effective.



Dr. Tsunetaka Kato

Department of Endoscopy, Fukushima Medical University Hospital,
Fukushima, Japan

Gel-immersion Endoscopic Ultrasound for Esophageal Varices

Introduction: Endoscopic ultrasound (EUS) for esophageal varices (EVs) can assess the diameters of EVs but also hemodynamics in the EV site such as perforating veins (Pv), peri-esophageal veins (Peri-v), and para-esophageal veins (Para-v). These veins have been shown to be involved in EV development and post-treatment recurrence. In addition, EUS assessment of local EV hemodynamics before endoscopic treatment, endoscopic injection sclerotherapy (EIS) and endoscopic variceal ligation (EVL), is beneficial to select the appropriate treatment. However, it is difficult to obtain sufficient EUS images with the conventional water-filling EUS method (WF-EUS) due to insufficient water stagnation in the esophagus. Additionally, water may cause aspiration pneumonia if it flows back into the mouth. To overcome these issues, we have recently performed gel immersion EUS (GI-EUS).

GI-EUS: GI-EUS requires a two-channel endoscope. First, a 20-MHz ultrasound probe is inserted into the left forceps channel and a 14 Fr catheter into the right forceps channel. Next, endoscopic gel is injected through the 14-Fr catheter into the esophagus lumen at the lower esophagus. Then, EUS observation started. During EUS observation, gel was added as necessary. In GI-EUS, not only EVs but also Pv and Peri/Para-v were well evaluated by stable gel retention in the esophagus. No serious adverse events have been observed to date.

Conclusion: GI-EUS for EVs have sufficient image quality while maintain safety. Therefore, GI-EUS is useful in assessing local hemodynamics before and after endoscopic treatment of EVs.



Dr. Takumi Yanagita

Department of Gastroenterology, School of Medicine, Fukushima Medical University, Japan

Endoscopic Glue Injection Therapy for Gastric Varices

Background: Gastric varices (GV) have been treated using glue, n-butyl-2-cyanoacrylate (NBCA), since 2013. We therefore examined the effectiveness of the endoscopic NBCA-glue injection therapy for GVs.

Methods: We retrospectively evaluated treatment outcomes and cumulative non-bleeding recurrence rates in 70 GV cases (14 emergent cases and 56 elective/prophylactic cases) who underwent glue injection therapy between October 2013 and March 2022. The NBCA/EO combination method is that 75% NBCA is injected into the GV with a 23G puncture needle to replace the GV with a template, and the blood supply is embolized with EO for elective/prophylactic cases. In emergent cases with GV bleeding, 75% NBCA was injected near the bleeding point to stop bleeding, and the NBCA/EO method was performed simultaneously if the patient's condition is stable. If the patient's condition was not stable, the NBCA/EO method was performed several days later.

Results: The localization of GV, according to the Salin's classification, was IGV1 in 9 cases, GOV1 in 5 cases, and GOV2 in 56 cases. The success rate of emergent case was 92.9% (13/14). The median number of treatment sessions was 1 (1-3), and the median NBCA dose was 3.0 mL (1.0-9.0). One patient who could not be stopped bleeding died of liver failure due to hemorrhage. There were no severe adverse events associated with NBCA/EO method. The median number of treatment sessions in elective/prophylactic cases was 1 (1-3), the median NBCA dose was 4.1 mL (1.0-17.5), and the median EOI dose was 2.0 mL (0-18.5). Two patients had NBCA outflow into the intrahepatic portal vein but were followed up because they had no symptoms. The cumulative nonbleeding recurrence rate was 90.0% at 1 year and 80.7% at 3 and 5 years, excluding those who failed to stop bleeding.

Conclusion: Endoscopic NBCA-glue injection therapy for GVs achieves sufficient treatment outcomes and safety.



Dr. Takanori Matsui

Department of Gastroenterology and Neurology,
Kagawa University, Japan

The Efficacy of Same-day EVL Just Preceding ESD for Early Esophageal Cancer Complicated with Esophageal Varix

Background: Recently, the rate of alcoholic liver cirrhosis has been increasing year by year. Alcohol consumption is also a major risk factor for esophageal cancer, and esophageal varix (EV) due to alcoholic cirrhosis is often associated with esophageal cancer in heavy drinkers. Early esophageal cancer complicated by EV is often treated with ESD after endoscopic treatment for varix to prevent bleeding, however, fibrosis due to treatment can be a problem. Then, we evaluated the efficacy and safety of two cases of EV-complicated early esophageal cancer who underwent EVL immediately before ESD.

Case1: Male in his 70s. Undergoing treatment for liver cirrhosis due to hepatitis C, routine upper gastrointestinal endoscopy (EGD) revealed a 15 mm large IIB lesion near the EV (LmF1CbRC1), which was diagnosed as SCC on biopsy. EVL was performed for EV on the same day as ESD, and ESD was performed consecutively. Almost no intraoperative bleeding and good progress without complications.

Case2: Male in his 60s. Alcoholic cirrhosis, after EV treatment. EGD performed for follow-up of EV revealed a 20 mm large IIA lesion near the EV (LmF1CbRC0), which was diagnosed as SCC on biopsy. EVL was performed for EV on the anorectal sides of the tumor and ESD was performed consecutively. Almost no intraoperative bleeding and good progress without complications.

Conclusion: The results showed that EVL immediately preceding ESD is effective because it allows ESD to be performed without intraoperative bleeding and without fibrosis.



Dr. Masaki Miyazawa

Kanazawa University Hospital, Department of Gastroenterology, Japan

Changes in Endoscopic Findings of Portal Hypertension Due to Splenectomy and Partial Splenic Artery Embolization

Background and Aim: Esophagogastric varices (EGV), portal hypertensive gastropathy (PHG), and gastric antral vascular ectasia (GAVE) associated with portal hypertension (PHT) are all risky lesions of gastrointestinal bleeding. Both splenectomy (Sp) and partial splenic artery embolization (PSE) are treatments that reduce the risk of gastrointestinal bleeding by reducing portal pressure. Here we examined changes in endoscopic findings before and after Sp and PSE.

Methods: The subjects were PHT patients who underwent Sp or PSE at our hospital from April 2012 to March 2021 and obtained pre- and post-treatment endoscopic findings. Patients with non-cirrhosis and after hepatobiliary pancreatic surgery were excluded. We investigated the relationship between changes in EGV/PHG/GAVE findings before and 1 year after treatment and clinical data. For endoscopic findings, we evaluated changes in the form and red color sign of EGV, and a change in the McCormack classification of PHG.

Results: We enrolled 21 and 24 patients who underwent Sp and PSE, respectively. Patients whose purpose of treatment was decrease in portal pressure was significantly higher in the Sp group than in the PSE group (71.4% vs 20.8%, $p = 0.003$). In terms of background factors, the PSE group tended to have more males ($p = 0.058$), more patients with higher Child-Pugh score ($p = 0.059$), and a higher prevalence of HCC ($p = 0.059$) than the Sp group. In term of treatment effect, the Sp group had a significantly higher rate of increase in platelet count ($p < 0.001$), and a higher incidence of post-treatment portal vein thrombosis (PVT) ($p=0.012$) than the PSE group. The inhibitory effect of EGV was observed in 28 patients (62.2%) in all, which was affected by the therapeutic effect on post-treatment PVT (81.8% in successful cases vs 25% in poor cases, $p = 0.013$). Exacerbation of PHG was observed in 4 patients (8.9%) in all, which was affected by the presence of pre-treatment PVT (33.3% in cases with PVT vs 5.1% in cases without PVT, $p = 0.024$) and treatment procedure (0% in the Sp group vs 16.7% in the PSE group, $p = 0.050$).

Discussion: Although Sp and PSE are expected to improve endoscopic findings of PHT, there is a risk of exacerbation in cases with PVT before and after treatment. The appropriate management for PVT was considered important.



Dr. Atsushi Irisawa

Department of Gastroenterology,
Dokkyo medical University School of Medicine, Japan

Advanced Role of Endoscopic Ultrasound for Portal Hypertension

Endoscopic treatment is widely used as the first-line treatment for esophageal varices, and its usefulness is also recognized for gastric varices. In the endoscopic treatment of esophagogastric varices, understanding the hemodynamics of portal venous system, including varices, is extremely important for safe and effective treatment.

Endoscopic ultrasonography (EUS) can visualize the collaterals inside and outside the esophageal and gastric wall non-invasively and is a beneficial modality for understanding local hemodynamics. Based on the information obtained by EUS, it is possible to select a treatment method according to the hemodynamics of individual collaterals, that is, personalized treatment for esophagogastric varices. In the esophageal varices, peri-esophageal collateral veins and perforating veins connecting between varices and collaterals outside the esophageal wall are the factors of recurrence after treatment. Therefore, if these vessels are found on EUS, treatment aimed at eliminating them should be performed.

On the other hand, with the progress of Interventional EUS in recent years, treatment using EUS has been developed and implemented for portal hypertension. Since the treatment of gastric varices using coils and cyanoacrylate under EUS guidance was reported in 2010, it has been spreading mainly in Europe and the United States. As this method performs treatment in real-time using EUS images as a guide, it is possible to approach the gastric varices reliably. It is easy to understand whether blood flow could be controlled using color Doppler after coil deployment. In addition, as the coil diameter to be used is selected according to the diameter of the varices measured by EUS, there is no risk of outflow of the indwelling coil to general circulation. In 2014, the author developed the EUS-guided coil deployment with sclerotherapy using ethanolamine oleate to treat gastric varices with reference to the sclerotherapy technique for esophageal varices. The author believes that this treatment is safe and effective. Other approaches to portal hypertension using EUS, such as intrahepatic portosystemic shunt and portal vein stent placement under EUS, are being investigated. EUS-guided treatment for portal hypertension is expected to be generalized in the near future.



Dr. Shinji Tanaka

Department of Molecular Oncology, Graduate School of Medicine, Tokyo Medical and Dental University, Japan

Molecular and Immunological Mechanisms of Liver Cancer; Preclinical Studies for Clinical Application

Diversity is one of the hallmarks of malignancies. Since liver cancer has diverse backgrounds such as viral-infectious, metabolic and immunological diseases and/or abnormalities, various analyses such as genomics, epigenomics, transcriptomics, metabolomics and proteomics have been performed using clinical specimens. Recent progress in molecular targeted drugs including multi-kinase inhibitors and immune checkpoint inhibitors has demonstrated substantial survival improvement in patients with advanced liver cancer, but it remains as a challenging issue to discover surrogate markers for precisely distinguishing responders and non-responders. Genome-based medicine has changed cancer treatment from empirical use of cytotoxic agents to theoretical use of molecular targeted drugs in various types of cancer, while not in liver cancer due to almost lack of druggable targets. Integrated genomic and transcriptomic analysis reveal that liver cancer is divided into three major molecular and immunological subtypes; the highly metastatic subtype carrying TP53 mutation, MYC pathway activation and immune exhaustion (MS1), the subtype carrying CTNNB1 mutation and immune exclusion (cold tumor; MS2), and the subtype complicated with metabolic syndrome and immune evasion (MS3). Based on distinctive molecular and immunological features, an increasing number of studies provide evidence for the close correlation between the subtype and the response to molecular targeted drugs using both of clinical data and preclinical models. At the same time as such development in genome-based medicine, remarkable innovations in genome-editing technology including CRISPR/Cas9 system are accelerating. The integration of comprehensive genome editing technology, such as multiplex genome editing methods that simultaneously introduce multiple genomic aberrations, and barcode sequencing technologies has led to the development of in vivo screening methods have made it possible to reproduce the preclinical model mimic to each subtype individually. Immunocompetent subtype models reflect molecular characteristics and tumor immune microenvironment of the subtypes and help us to evaluate the efficacy of single and combination therapies and understand the molecular and immunological mechanisms underlying vulnerability and resistance to them. Thus, the consensus classification and relevant preclinical models could accelerate the establishment of predictive biomarkers and the development of subtype-specific therapies. In this lecture, we would like to introduce the post-genomic studies and have a lively discussion on what it can bring to the treatment of liver cancer.



Dr. Takahiro Kodama

Department of Gastroenterology and Hepatology,
Osaka University Graduate School of Medicine, Japan

Multiomics Profiling Identifies the Link between Intratumoral Steatosis and Immune-exhausted Immunotherapy-susceptible Tumor Immune Microenvironment in HCC

Takahiro Kodama, Hiroki Murai, Tetsuo Takehara

Department of Gastroenterology and Hepatology, Osaka University Graduate School of Medicine

Background: Immunotherapy has become the first-line therapy for hepatocellular carcinoma (HCC), but its efficacy remains limited. To identify immunotherapy-susceptible HCC, we profiled the tumor immune microenvironment (TIME) of nonviral HCC via multiomics.

Methods: Using tumor tissues in 113 nonviral HCC patients, We performed RNA-seq, cancer genome sequencing of 69 genes with recurrent genetic alterations reported in HCC, lipomics of free fatty acids, and spatial transcriptomics with Visium. Intratumoral abundances of immune cell types were estimated by CIBERSORT analysis of transcriptomic data.

Results: Nearest template prediction analysis of tumor transcriptomes identified 38 percent of HCC as an immune class characterized by strong intratumoral immune cell infiltration, a high frequency of intratumoral steatosis and a low frequency of CTNNB1 mutations. Steatotic HCC, which accounts for 23% of nonviral HCC cases, presented an immune-enriched but immune-exhausted TIME characterized by T-cell exhaustion, M2 macrophage and cancer-associated fibroblast (CAF) infiltration, high PD-1/PD-L1 expression, and TGF- β signaling activation. Spatial transcriptome analysis of steatotic HCC suggested that M2 macrophages and CAFs may be in close proximity to exhausted CD8⁺ T cells in the TIME with high TGF- β level. Lipidomics revealed the increase in palmitic acid in steatotic HCC. An in vitro study showed that palmitic acid-induced lipid accumulation in HCC cells upregulated PD-L1 and TGF- β expression and promoted immunosuppressive phenotypes of cocultured macrophages and fibroblasts. Steatotic HCC patients, confirmed by chemical-shift MR imaging, had significantly longer PFS with atezolizumab and bevacizumab treatment.

Conclusions: Multiomics identified the link between intratumoral steatosis and immune-exhausted immunotherapy-susceptible TIME in nonviral HCC.



Dr. Ting Ting Shi

Department of Gastroenterology and Neurology,
Faculty of Medicine, Kagawa University

Molecular Mechanisms Underlying Lenvatinib Treatment in Sorafenib-Resistant Hepatocellular Carcinoma Cells

Background/Objective: Hepatocellular carcinoma (HCC) is the most common primary liver cancer, with an increasing incidence over the past few decades in various populations; it is one of the major causes of cancer-related deaths worldwide. For a long time, sorafenib has been used as first-line systemic therapy for advanced HCC, and resistance to sorafenib remains a significant issue. A clinical trial showed that the median survival time of lenvatinib was not inferior to that of sorafenib. To explore the possible advantage of lenvatinib and the underlying mechanisms in overcoming sorafenib-resistance in HCC we developed sorafenib-resistant cell lines and performed in vitro and in vivo experiments.

Methods: Two human HCC cell lines, Huh-7 and Hep-3B, were used to establish sorafenib resistance and analyze the effect of lenvatinib on cell proliferation, cell cycle, apoptosis, invasion, and the regulation of microRNAs.

Results: Lenvatinib suppressed sorafenib-resistant HCC cell proliferation mainly by inducing G1 cell cycle arrest through ERK signaling. Hep-3B sorafenib-resistant cells showed partial cross-resistance to lenvatinib, possibly due to the contribution of poor autophagic responsiveness. Moreover, microRNA alterations may contribute to the inhibition of sorafenib-resistant HCC cell growth and angiogenesis. Overall, the findings suggest that the underlying mechanism of lenvatinib in overcoming sorafenib resistance in HCC involves FGFR4-ERK signaling.

Conclusion: Lenvatinib may be a suitable second-line therapy for unresectable HCC patients who have developed sorafenib resistance and express FGFR4.



Dr. Satoru Hagiwara

Department of Gastroenterology and Hepatology,
Kindai University Faculty of Medicine, Japan

Examination of NASH -related Liver Carcinogenesis from Non -developed Fibrosis

Purpose: In recent years, NASH-related liver cancer (NASH-HCC) based on obesity and diabetes has increased, and the number of carcinogenes from liver fibrosis non-developed examples is not common. In this study, we examined in connection with the presence or absence of fibrous development of Nash-HCC liver and the change in the cancer and background liver.

Method: In the surgical specimen, 16 cases in which the background liver could be diagnosed with NASH and pathological diagnosis was analyzed. The Stage 3 or more of the Brunt classification is classified as fibrous and less than the Stage 1 as a non -fibrous (n = 8). They used frozen tissue to detect any somatic mutation, with 409 cancer -related gene target sequences and TERT Promoter A comprehensive methylation analysis was performed using a frozen tissue to detect epigenomic mutation.

Results: As for somatic gene mutations, 11 types of mutations (number of mutations per single background liver = 1.4) were observed in both groups regardless of whether fibrosis progressed or not in the background liver tissue, and the clonality of these mutant alleles was There was a clear increase in the corresponding cancerous area. In the background liver, the methylation profile in the background liver was very different from the simple fatty liver, but the methylation profile of the fibrosis and the non -advanced group of fibrosis overlapped.

Conclusion: In NASH patients, there is accumulation of genetic abnormalities and abnormal methylation even in cases where fibrosis does not progress.



Dr. Yotaro Kudo

Department of Gastroenterology,
Graduate School of Medicine, The University of Tokyo, Japan

Autophagy and Metabolic Reprogramming Regulated by PKC λ 1 in Hepatocellular Carcinoma

Background: Hepatocellular carcinoma (HCC) results from chronic tissue damage associated with oxidative stress caused by the generation of reactive oxygen species (ROS). Our understanding of the signaling and metabolic pathways that lead to ROS generation and HCC is fragmentary. Autophagy and metabolic reprogramming are currently considered vulnerabilities in different types of cancer. Obesity is associated with autophagy inhibition, which leads to the accumulation of the p62 and activates pro-tumorigenic signaling pathways. The PB1 domain in p62 is interesting because it promotes the binding of p62 to other PB1 domain-containing molecules such as the atypical protein kinase Cs (PKC λ 1 and PKC ζ) involving activation of signaling pathways. The roles of PKC λ 1 in cancer have been proposed to be context-dependent and need to be clarified in each type of cancer.

Objectives: In this study, we address the function of PKC λ 1 in HCC and provide novel mechanistic evidence that PKC λ 1 is a negative regulator of autophagy through metabolic reprogramming.

Methods: Mice with the hepatocyte-specific deletion of PKC λ 1 (*Prkci^{fl/fl}; Alb-Cre*) were subjected to a diethylnitrosamine (DEN)/high-fat diet (HFD) protocol to assess the impact of PKC λ 1 depletion on HCC development and progression. Distinct pathways in the mutant liver were identified by RNA-sequencing. Metabolism, oxidative stress, and autophagy in PKC λ 1-deficient hepatocytes were examined. PKC λ 1 interactome profiling was achieved by the proximity-dependent biotin identification approach. The clinicopathological and prognostic significance of PKC λ 1 in HCC patients was examined.

Results: Mice with selective deletion of PKC λ 1 in hepatocytes (*Prkci^{fl/fl}; Alb-Cre*) presented chronic liver injury and developed aggressive HCC under DEN/HFD protocol. The mutant liver showed enriched gene signatures corresponding to oxidative phosphorylation (OXPHOS), fatty acid metabolisms and oxidation (FAO), and ROS. PKC λ 1-deficient hepatocytes displayed increased OXPHOS, FAO, and autophagy. We found that PKC λ 1 directly binds to and phosphorylates LC3, reducing p62-LC3 binding and autophagy activity. Increased OXPHOS and ROS were critical for hepatocyte proliferation, apoptosis, and cancer cell invasion *in vitro* and *in vivo*. HCC cells transplanted in *Prkci^{fl/fl}; Alb-Cre* mice developed larger primary tumors and metastatic lesions. These results suggest that PKC λ 1-deficient hepatocytes are pro-tumorigenic in a cell-autonomous and non-cell-autonomous manner. Analyses of liver tissues from HCC patients demonstrated that low PKC λ 1 expression in non-tumor liver tissue is a significant predictor of poorly differentiated HCC. Furthermore, low PKC λ 1 expression in the non-tumor liver was significantly associated with late recurrence, supporting the human relevance of our present studies in mice.

Conclusion: We identified PKC λ 1 as a critical suppressor of autophagy and oxidative metabolism.



Dr. Hiroaki Fujiwara

Division of Gastroenterology, The Institute of Medical Science,
Asahi Life Foundation, Japan

Interplay between Metabolism and Epigenetics in Biliary Epithelial Cells Induced by Mutant IDH1

Recurring mutations of isocitrate dehydrogenase (IDH) 1 and 2 genes are frequently found in intrahepatic cholangiocarcinoma (ICC), especially in patients without liver flukes or viral hepatitis as well-known risk factors for ICC. Wild-type IDHs convert isocitrate to α -ketoglutarate (α -KG), and mutant IDHs produce the specific oncometabolite D-2-hydroxyglutarate (2-HG) from α -KG, which inhibits α -KG dependent dioxygenases including the demethylases of DNA and histones. IDH mutations commonly observed in the early stage of malignant tumors, however, their biological roles in the biliary tumorigenesis still remain unclear. In this study, we aimed to reveal the functional significance of mutant IDH1 in biliary epithelial cells using intrahepatic biliary organoids (IBOs) generated from a normal murine liver. IBOs expressed biliary marker genes including cytokeratin 7 and 19, but not hepatocyte marker genes such as transthyretin and aldolase B. By lentiviral transduction, we established IBOs expressing human wild-type IDH1 (wt-IBOs) and mutant IDH1 (mut-IBOs), respectively. The specific production of 2-HG was confirmed in mut-IBOs with the altered levels of global histone methylation. Compared to wt-IBOs, mut-IBOs exhibited enhanced organoid-forming efficiency with the activation of glycolysis. The glycolytic inhibitor 2-deoxy-D-glucose suppressed the formation of both wt- and mut-IBOs. From the analysis of microarray gene expression data, we focused on the upregulation of platelet isoform of phosphofructokinase-1 (PFKP), which is a rate-limiting glycolytic enzyme, in mut-IBOs. Chromatin immunoprecipitation assays revealed a significant increase in histone H3 lysine K4 trimethylation as an active transcriptional mark on the promoter region of *Pfcp* in mut-IBOs compared to wt-IBOs. Knockdown of the *Pfcp* gene cancelled the enhanced organoid formation induced by mutant IDH1. Remarkably, the frequency of high PFKP expression was higher in patients with IDH-mutant ICC than in those with IDH-wildtype ICC (80.9% vs. 42.5%, $p < 0.01$, respectively). Our findings provide insight into the metabolic rewiring through epigenetic alteration caused by mutant IDH1 in biliary epithelial cells.

**Dr. George Lau**

¹Humanity and Health Clinical Trial Centre, Humanity and Health Medical Group, HKSAR, China

²Liver Diseases & Transplant Centre, The Fifth Medical Centre of Chinese PLA General Hospital, Beijing- Humanity & Health Medical Group, HKSAR, China

Update on Treatment of Intermediate-stage Hepatocellular Carcinoma

Intermediate stage hepatocellular carcinoma (HCC), mostly due to chronic hepatitis B infection, remains the most important clinical burden in Asia-Pacific region. In accordance to Barcelona Clinic Liver Cancer (BCLC) staging system, intermediate stage (stage B) HCC includes multiple tumorous lesions confined to the liver without vascular invasion in a patient with persevered liver functions (Child-Pugh A or B) and good performance status (PS 0). Currently, with the use of Trans-Arterial Chemo-Embolization (TACE) with or without drug-eluting bead (TARE), an improved 2-years survival could be obtained. In selected cases, liver transplantation has also been offered to those “down-staged” to the Milan, University of California San Francisco (UCSF) or Up-to-Seven criteria. However, the disease-free and overall survival in these cases remain unclear. Disappointingly, with the rapid development and approval of tyrosine kinase inhibitors (TKIs) as systemic therapy for advanced HCC, its combinations with TACE have so far failed to provide beneficial clinical outcomes. Nonetheless, in a pooled results from 2 phase 3 studies (REACH and REACH-2), median OS for ramucirumab versus placebo was 13.7 versus 8.2 months; HR (95%): 0.43 (0.23–0.83) for intermediate HCC with prior sorafenib therapy. Additionally, in a recent proof-of-concept study which included 642 consecutive patients with multinodular intermediate-stage HCC exceeding the up-to-seven criteria with Child–Pugh A liver function, who usually do not benefit from TACE, lenvatinib provides a more favorable outcome than TACE. Recently, the phase 3 HIMALAYA study demonstrated that a single priming dose of tremelimumab, an anti-cytotoxic T-lymphocyte-associated protein 4 (CTLA-4) antibody plus once-monthly durvalumab, a programmed cell death ligand 1 (PD-L1) antibody, significantly improved overall survival at 36 months compared with sorafenib for patients with advanced unresectable HCC (30.7% vs 20.2%). In the coming future, with the renewed understanding of the immune tumor microenvironment, new innovative approaches, such as addition to TACE with durvalumab plus bevacizumab (EMERALD 1), lenvatinib plus pembrolizumab (LEAP 012), atezolizumab plus caboznatinib (COSMIC 312), nivolumab plus ipilimumab (CheckMate 74 W) and nivolumab (TACE 3) are expected to come into play. On the other hand, more personalized approach with the aid of different scoring system and new biomarkers are expected to further improve the management and even “cure” of our patients with intermediate stage HCC.



Dr. Tomokazu Kawaoka

Department of Gastroenterology and Metabolism,
Hiroshima University Hospital, Japan

Systemic Therapy for Intermediate Stage Hepatocellular Carcinoma

Objective: We investigated the treatment results of lenvatinib and atezolizumab + bevacizumab combination therapy (Atezo + Bev) as drug therapy for Intermediate stage hepatocellular carcinoma (HCC).

Subjects and Methods: Subjects were Intermediate stage liver HCC, TACE refractory /unsuitable, Child-Pugh 5-7, for PS 0-1 . lenvatinib in 140 cases, and Atezo + Bev in 72 cases. In each regimen, the response rate (ORR), progression free survival (PFS), and median survival time (MST) were examined according to up to 7 criteria. In the case of lenvatinib, we also examined on-demand TACE and conversion cases for curative treatment.

Result:

1. Lenvatinib

Up to 7 in (n = 52) / out (n = 88) Separately, the ORR is RECIST 32/21% and mRECIST 55/45%. PFS 12/7 months. MST was up to 7 in cases with / without on demand TACE: not reached / 25 months (p = 0.0001), up to 7 out cases with / without on demand TACE: 44/14 months (p = 0.0001) .

After the introduction of lenvatinib, the total number of conversion cases (surgery 1 case, RFA 7 cases, SBRT 1 case) to curative treatment was 9 cases (6%), up to 7 in 6 cases (11%), up to 7 out. In 3 cases (3%), the 3-year survival rate of conversion cases was 100%, which was significantly longer than that of 40% of non-conversion cases (p = 0.014).

2. Atezo + Bev

By up to 7 in (n = 11) / out (n = 61), ORR RECIST 18/24%, mRECIST 36/37%, PFS 8 / 5M, and OS did not reach each other.

Conclusion: Lenvatinib treatment for Intermediate stage HCC may further improve prognosis by on-demand TACE and conversion to curative treatment. In the future, it will be necessary to study of Atezo + Bev on long-term.



Dr. Issei Saeki

Department of Gastroenterology and Hepatology,
Yamaguchi University Graduate School of Medicine, Japan

Prognostic Prediction by Methylated-SEPT9 Assay in Patients with Intermediate-stage Hepatocellular Carcinoma Receiving Molecular Targeted Agents

Background: In recent years, the induction of systemic therapy has shifted to the intermediate stage, and patients with intermediate hepatocellular carcinoma (HCC) are often treated with molecular targeted agents (MTA). A biomarker is necessary for selecting effective patients. We have developed a liquid biopsy test using a highly sensitive methylated-SEPT9 (m-SEPT9) assay for the early diagnosis of HCC (Hepatology Commun. 2020). As this assay enables a quantum of methylated DNA, any optimal cutoff value can be set.

We investigated whether m-SEPT9 is a predictive biomarker of clinical outcome in MTA treatment for intermediate and advanced HCC.

Methods: We retrospectively enrolled 146 HCC patients (BCLC-B/C: 53/93 patients) treated with lenvatinib or sorafenib from three hospitals in Japan. Various clinical parameters, including m-SEPT9, were analyzed as predictive factors for progression-free survival (PFS) and overall survival (OS).

Results: Median PFS and median survival time were 6.0 and 21.7 months, respectively, in BCLC-B group and those were 9.2 and 12.8 months, respectively, in BCLC-C group. The cutoff value of AFP was set at 400 ng/mL, and that of m-SEPT9 was set at the median value, which was 300 copies/mL in BCLC-B group and 350 copies/mL in BCLC-C group, respectively. Only m-SEPT9 was a significant predictor of PFS on multivariate analysis in BCLC-B group, but it was not a significant OS parameter. In contrast, multivariate analysis showed that macrovascular invasion, AFP, and m-SEPT9 were independent predictors of OS in BCLC-C group and only AFP was a significant predictor of OS.

Conclusion: Liquid biopsy test based on m-SEPT9 assay can be a predictive biomarker of clinical outcome not only in patients with BCLC-C receiving MTA but also those with BCLC-B receiving MTA.



Dr. Toshifumi Tada

Department of Internal Medicine, Japanese Red Cross Himeji Hospital,
Japan

Impact of Early Lenvatinib Administration on Survival in Patients with Intermediate-stage

Background and Aim: Transarterial chemoembolization (TACE) is recommended for patients with intermediate-stage hepatocellular carcinoma (HCC). In this study, we investigated the impact of early lenvatinib administration in patients with intermediate-stage HCC, especially those with tumors beyond the up-to-7 criteria.

Methods: A total of 208 patients with intermediate-stage HCC whose initial treatment was early lenvatinib administration (n=32) or TACE (n=176) were enrolled. Multivariate overall survival analysis was performed in this cohort. In addition, the impact of early lenvatinib administration on survival in patients with HCC beyond the up-to-7 criteria was clarified using inverse probability weighting (IPW) analysis.

Results: The overall cumulative survival rates at 6, 12, 18, and 24 months were 94.4%, 79.9%, 65.8%, and 50.1%, respectively. Multivariate analysis with Cox proportional hazards modeling showed that HCC treatment with lenvatinib (hazard ratio [HR], 0.199; 95% confidence interval [CI], 0.077–0.517; $p < 0.001$), α -fetoprotein ≥ 100 ng/mL (HR, 1.687), Child-Pugh class B disease (HR, 1.825), and beyond the up-to-7 criteria (HR, 2.016) were independently associated with overall survival. The 6-, 12-, 18-, and 24-month cumulative survival rates were 96.0%, 90.4%, 65.7%, and 65.7%, respectively, in patients treated with lenvatinib, and 94.1%, 78.5%, 65.3%, and 48.4%, respectively, in patients who received TACE ($p < 0.001$). In addition, univariate analysis with Cox proportional hazards modeling adjusted by IPW showed that lenvatinib therapy was significantly associated with overall survival in patients with HCC beyond the up-to-7 criteria (HR, 0.230; 95% CI, 0.059–0.904; $p = 0.035$).

Conclusions: Lenvatinib may be a suitable first-line treatment for patients with intermediate-stage HCC beyond the up-to-7 criteria.



Dr. Norihiro Imai

Department of Gastroenterology and Hepatology,
Nagoya University Graduate School of Medicine, Aichi, Japan

Effectiveness of Porous Glass Membrane-pumping Emulsification Device in Transarterial Chemoembolization for Solitary Hepatocellular Carcinoma

Norihiro Imai, Masatoshi Ishigami, Yosuke Inukai, Shinya Yokoyama, Kenta Yamamoto,
Takanori Ito, Yoji Ishizu, Takashi Honda, Hiroki Kawashima
Department of Gastroenterology and Hepatology,
Nagoya University Graduate School of Medicine, Aichi, Japan

Background: The porous glass membrane-pumping emulsification device (GMD) enables the formation of a high-percentage water-in-oil emulsion with homogeneous and stable droplets. Although the GMD is expected to improve the therapeutic effects of transarterial chemoembolization (TACE) for hepatocellular carcinoma (HCC), its effectiveness in the management of solitary HCC remains unclear.

Methods: Patients treated for solitary (< 5 cm) HCC between 2020 and 2022 were retrospectively reviewed. A total of 46 patients who could not undergo liver resection and were unsuitable for radiofrequency ablation were included. Among these, 22 patients underwent TACE using a GMD (GMD-TACE group), and 24 underwent stereotactic body radiotherapy using a robotic radiosurgery system (SBRT group). The local control rates were compared between the two groups.

Results: The median HCC tumor size was 24 mm (range 12-50 mm) in the GMD-TACE group and 22 mm (range 8-39 mm) in the SBRT group; however, the difference between the groups was not significant. There were no significant differences in age, etiology, liver function test results, and Child-Pugh scores between the two groups. The rate of local control at 6 months after treatment was 100% in both groups. Although the 1-year local control rate was higher in the SBRT group (92.3%) than in the GMD-TACE group (81.8%), there was no significant difference in the log-rank test ($P = 0.6541$). No major treatment-related complications were observed in either group during the observation period.

Conclusion: TACE using GMD could be considered an effective treatment option for the management of solitary HCC.




Dr. Young Nyun Park

Department of Pathology, Yonsei University College of Medicine, Korea

Moleculopathological Spectrum between Hepatocellular Carcinoma and Intrahepatic Cholangiocarcinoma

Primary liver cancers (LCs), including hepatocellular carcinoma (HCC) and intrahepatic cholangiocarcinoma (iCCA), are derived from common developmental lineage, conferring a molecular spectrum between them. Recently, iCCA is classified into small duct and large duct types, and small duct type iCCA shows clinical similarities including risk factors for HCC. To elucidate the moleculopathological spectrum, we performed an integrative analysis of transcriptome profiles associated with the patients' radio-pathologic features. We identified four LC subtypes (LC1-LC4) from RNA-Seq profiles, revealing an intermediate subtypes between HCC and iCCA. LC1 is a typical HCC characterized by active bile acid metabolism, TERT promoter mutations, and high uptake of gadoxetic acid in MRI (typical MRI feature for HCC). LC2 is an iCCA-like HCC characterized by expression of the progenitor cell-like trait, TP53 mutations, and rim arterial-phase hyperenhancement in MRI (atypical MRI feature for HCC). LC3 is an HCC-like iCCA, mainly small duct type, associated with HCC-related etiologic factors including hepatitis B virus, high BMI (> 25kg/m²), diabetes mellitus. LC4 was further subclassified into LC4-small duct type and LC4-large duct type according to the pathological features, which exhibited distinct genetic variations (e.g., KRAS, IDH1/2 mutation, and FGFR2 fusion), and prognostic outcomes. Glucose and lipid metabolism was more up-regulated in LC3 than LC4. Tumor stroma was different between LC3 and LC4, and LC3 showed more mature stroma in contrast that LC4 revealed predominantly immature stroma. Immune status was more active in LC3, whereas it was exhausted in LC4. In conclusion, this integrated view of the moleculo-pathological spectrum of LCs can identify subtypes associated with transcriptomic, genomic, and radio-pathologic features, providing new mechanistic insights into the heterogeneous LC progression.



Dr. Masashi Hirooka

Department of Gastroenterology and Metabology, Ehime University
Graduate School of Medicine, Japan

Validation Trial to Diagnose Liver Tumors by LI-RADS Criteria

Backgrounds: LI-RADS® was created to standardize the reporting and data collection of CT and MR imaging for hepatocellular carcinoma (HCC). Recently, LI-RADS was gained attention because LI-RADS are consistent with and integrated into the American Association for the Study of Liver Diseases (AASLD) 2018 hepatocellular carcinoma (HCC) clinical practice guidance. However, there are few reports that have been verified LI-RADS. We aimed to assess diagnose with LI-RADS from image findings and examine whether the diagnosis made is appropriate.

Methods: The number of cases was 159 nodules in 159 cases in 3 facilities. There were 81 cases (50.9%) of the high risk group (HBV carrier or cirrhosis case) in LI-RADS. In addition, we examined cases other than the high risk group in LI-RADS in this study. We categorized into US-1 (Negative), US-2 (Subthreshold), US-3 (Positive) with ultrasound (US) LI-RADS. Furthermore, we analyzed cases diagnosed as malignant tumors by CT / MRI but no malignant findings (LR-4 or 5) in US LI-RADS. Conversely, the proportion of cases with benign tumors diagnosed as malignant in US LI-RADS was calculated.

Results: There were no cases equivalent to US-1 in this study. There were 4 cases of US-2, of which 2 non-malignant tumors, 1 hepatocellular carcinoma (highly differentiated) and 1 metastatic liver tumor were included. Both hepatocellular carcinoma and metastatic liver tumor were LR-3 on the basis of CT / MRI, and the diagnosis was different from that of US diagnosis (1.3%). Conversely, two non-malignant tumors were CT / MRI findings of LR-5 (1.3%), malignant tumors could not be denied and one case had hepatectomy. The cases of US-3 were 121 cases of hepatocellular carcinoma, 19 cases of intrahepatic bile duct cancer, 2 cases of mixed type liver cancer, 10 cases of metastatic liver tumor, and 3 cases of other malignant tumors. 10 cases of hepatocellular carcinoma (6.3%) and 4 cases of metastatic liver tumors (2.5%) were judged as LR-3 by CT / MRI, and diagnosis was different between US and CT / MRI.

Conclusion: Except for a few cases, US LI - RADS generally performed adequate diagnosis. Further upgrading to contrast enhanced US LI-RADS which corresponds to perflutane will further improve diagnostic accuracy.



Dr. Katsutoshi Sugimoto

Department of Gastroenterology and Hepatology, Tokyo Medical University, Japan

Comparison of Modified CEUS LI-RADS with Sonazoid and CT/MRI LI-RADS for Diagnosis of Hepatocellular Carcinoma

Aim: To compare the diagnostic performance based on the modified CEUS LI-RADS, which includes Kupffer-phase findings as a major imaging feature, with that of CT and MRI (CT/MRI) LI-RADS for liver nodules in patients at high risk of HCC.

Methods: A total of 120 patients with 120 nodules were included in this retrospective study. The median size of the lesions was 20.0 mm (interquartile range, 14.0-30.8 mm). Of these lesions, 90.0% (108 of 120) were confirmed as HCCs, 6.7% (8 of 120) were intrahepatic cholangiocarcinomas, 1.7% (2 of 120) were metastases, and 1.7% (2 of 120) were dysplastic nodules. All nodules were diagnosed histopathologically. Each nodule was categorized according to the modified CEUS LI-RADS and CT/MRI LI-RADS version 2018. The diagnostic performance and inter-modality agreement of each criterion was compared.

Results: The inter-modality agreement for the modified CEUS LI-RADS and CT/MRI LI-RADS was slight agreement ($\kappa=0.139$, $P=.015$). The diagnostic accuracies of HCCs for the modified CEUS LR-5 and CT/MRI LR-5 were 70.0% (95% confidence interval [CI]: 61.0%, 78.0%) vs. 70.8% (95% CI: 61.8%, 78.8%) ($p=0.876$), respectively. The diagnostic accuracies of non-HCC malignancies for the modified CEUS LR-M and CT/MRI LR-M were 84.2% (95% CI: 76.4%, 90.2%) vs. 96.7% (95% CI: 91.7%, 99.1%) ($p=.002$), respectively.

Conclusions: The diagnostic performance for HCCs on the modified CEUS LR-5 and CT/MRI LR-5 are comparable. In contrast, CT/MRI LR-M has better diagnostic performance for non-HCC malignancy than that of the modified CEUS LR-M.



Dr. Chikara Ogawa

Department of Gastroenterology and Hepatology, Takamatsu Red Cross Hospital, Japan

Diagnose of HCC and for Evaluation of RFA Therapeutic Effect Using Workstation

There is a large dependence on the operator of TACE and RFA. Using workstation, 3D volume analyzer system, the disparity become very small.

It is common for surgery to use workstation for simulation of operations in the world. But I believe that there are more useful opportunities for internal medicine using workstation for example virtual US, sarcopenia, TACE and RFA etc.

We usually use workstation to diagnose and treat of HCC at our hospital. Virtual US, colorized fusion, differentiation of sarcopenia, prediction of embolization volume and identification of feeding vessels of TACE, simulation and navigation of RFA, workstation has many useful possibilities.

In my hospital, we use three workstations and today I'll explain the most famous workstation, Synapse 3D in more detail. VINCENT, called SYNAPSE 3D internationally is the 3D volume analyzer system produced by FUJIFILM Medical Co., Tokyo, Japan.

Work station SYNAPSE 3D is commonly used in many hospitals all over Japan. In my hospital, Synapse 3D can access through LAN cable or wifi access points to all our over 300 chart PCs anytime, anywhere in the US room, outpatient's room, and the ward without having to record the data on DVD.

Unfortunately, I do not have time to talk about everything, so I'll just present to diagnose of HCC and evaluation of RFA therapeutic effect using workstation today.



Dr. Leona Osawa

First Department of Internal Medicine, University of Yamanashi,
Yamanashi, Japan

The Usefulness of Ultrasound Elastography in Predicting Long-term Prognosis and the Appearance of Hepatocellular Carcinoma

Leona Osawa, Yuichiro Suzuki, Koji Yamashita, Yasuyuki Komiyama, Natsuko Nakakuki, Hitomi Takada, Suguru Muraoka, Mitsuki Sato, Shinya Maekawa, Nobuyuki Enomoto
First Department of internal Medicine, University of Yamanashi, Yamanashi, Japan

Background: Ultrasound elastography (VCTE) has been reported to be useful in screening for liver fibrosis. However, its long-term prognosis and correlation with incidence of Hepatocellular carcinoma (HCC) are not clear. We investigated the prognostic value of VCTE in predicting long-term outcome and incidence of HCC.

Method: In 501 patients with chronic liver disease who underwent VCTE from April 2010 to May 2011 at our hospital, we investigated the correlation between VCTE values and prognosis and incidence of HCC.

Results: The central observation period from the date of VCTE measurement was 6.72 years. When comparing the prognosis between the high and low VCTE groups (cut off: 11.8kPa), the high group had a 10-year survival rate of 41.2%, compared to 88.8% in the low group ($p < 0.001$). Comparing HCC incidence rates, the 10-year carcinogenesis rate for the high group was 28.6% compared to 7.4% in the low group ($p < 0.001$). Next, factors associated with the appearance of HCC were analyzed using the COX proportional hazards model. In univariate analysis, age, sex, albumin level, $AST > 40$ U/ml, $AFP > 6$ mg/dL, and $VCTE > 11.8$ kPa were predictors of HCC incidence. Multivariate analysis using these factors showed that age (HR: 1.57, 95%CI: 1.08-8.95, $p < 0.001$), gender (HR: 2.91, 95%CI: 1.18-7.20, $p = 0.021$), $AFP > 6$ mg/dL (HR: 3.84, 95%CI: 1.65-8.95), VCTE value > 11.8 kPa (HR: 3.13, 95%CI: 1.33-7.33, $p = 0.009$) were independent factors.

Conclusion: Ultrasound elastography is useful for predicting prognosis and the appearance of HCC in patients with chronic liver disease, even in the long term.



Dr. Dong Thanh Le

The Department of Medicines, Kanazawa University, Kanazawa, Japan

The Utility of Mannose-binding Lectin 2 Loss in the Progression and Diagnosis of Hepatocellular Carcinoma

Dong Thanh Le, Hiep Canh Nguyen, Zihan Li, Kenta Takahashi, Yasunori Sato, Kenichi Harada
The Department of Medicines, Kanazawa University, Kanazawa, Japan

Distinguishing hepatocellular carcinoma (HCC) from its mimickers remains challenging. Mannose-binding lectin 2 (MBL2) is reported as a highly specific protein expressed on normal hepatocytes. Decreased expression of MBL2 in HCC tissues has been recorded. However, the utility of MBL2 in diagnosing HCC has not been evaluated. In this study, we examined the expression pattern of MBL2 in HCC. A total of 74 HCC and 2 hepatocellular adenoma (HCA) cases were collected. Tumor MBL2 staining was evaluated as loss, decreased, or over-expression compared to that on the liver background. We also estimated the percentage of MBL2-loss area for each case. Strong MBL2 expression was found on normal hepatocytes (100% cases) but not on bile ducts. In HCC tissue, all but one (73/74, 98.6%) cases showed decreased MBL2 expression, with a mean percentage of MBL2 loss area being 76.5%, and 33/74 (44.6%) cases showing complete MBL2 loss. MBL2 expression was correlated with the degree of tumor cell differentiation, with mean percentages of tumor areas showing MBL2-loss in well, moderately, and poorly differentiated cases, being 40.8%, 72.5%, and 100%, respectively. Interestingly, 2/2 cases of HCA were MBL2 over-expressed. These results suggested that decreased MBL2 expression plays an essential role in HCC progression; additionally, loss of MBL2 staining could be used to support HCC diagnosis.



Dr. Shuichi Kaneko

Department of Information-Based Medicine Development, Kanazawa University, Japan

Molecular Mechanisms of Liver Cancer

As in other cancers, the molecular mechanisms of liver cancer have been vigorously investigated. Hanahan and Weinberg reported in 2000 in *Cell*, "The Hallmarks of Cancer," that cancer is established by a combination of six characteristics, including proliferation, angiogenesis, and invasion. In 2011, they reported "The Hallmarks of Cancer: The next generation," adding energy metabolism, immunity, inflammation, and genomic instability and mutation. Thus, cancer has important characteristics, and these characteristics are formed by different cells in cancer tissue. These characteristics also differ temporally and spatially during development of cancer. In late-stage hepatocellular carcinoma, which is the target of current drug therapy, classification based on the molecular mechanisms is seen here and is important in relation to the efficacy of treatment.



Dr. Rakhi Maiwall
ILBS, India

Inflammation in Hepatocellular Carcinoma -Mechanisms and Therapeutic Targets

Hepatocellular carcinoma (HCC) is the fifth leading cause of cancer and third leading cause of cancer-related death globally. It occurs as a result of different etiologies including viral hepatitis, alcohol associated and non-alcoholic fatty liver disease. These diseases are associated with chronic inflammation which drives the development of fibrosis. Inflammation causes tumorigenesis primarily by inducing epithelial cell death. The pro-inflammatory cytokines tumor necrosis factor- α and interleukin-6 and downstream targets of nuclear factor kappa ($\text{NF-}\kappa\text{B}$), signal transducer and activator of transcription 3, c-Jun N-terminal kinase (JNK) drive inflammation-associated HCC. The liver also has mechanisms of self-defense mediated by the immune cells including natural killer (NK) and natural killer T-cells (NKT) cells which clear the pathogen load derived from the gut. The chronic inflammation drives increase in the regeneration of the hepatocytes and cell proliferation. The inflammation also induces the production of reactive oxygen species which causes damage to the deoxyribonucleic acid and induces genomic mutations. At the same time, the chronic inflammation also induces alterations in the hepatic immune system. This includes infiltration of myeloid-derived suppressor cells (MDSCs), production of immunosuppressive protumorigenic cytokines, the translocation of gut-derived pathogens and promotion of senescence. These changes are exaggerated in patients with cirrhosis. A role of toll-like receptor (TLR) particularly TLR-4 and TLR-9 has been shown to be associated with poor prognosis in patients with HCC. The accumulation of ectopic lymphoid like-structures is also associated with a worse prognosis in HCC. Hepatic stellate cells also cause HCC development by causing the shift of macrophages and monocytes from an inflammatory (M1) to an immunosuppressive phenotype (M2) which promotes tumorigenesis. Amongst the microRNAs, miR-122 and miR-21 level have been considered as potential biomarkers for HCC. Targetting the hepatic immune system is used for managing HCC. In the current era, the advent of immunotherapy has revolutionized in the management of HCC. The immune check point inhibitors work by inhibiting tumor immunity.



Dr. Chun-Jen Liu

Hepatitis Research Center and Department of Internal Medicine
National Taiwan University College of Medicine and Hospital, Taiwan
(ROC)


Role of Metastatic Tumor Antigen 1 in HBV-related HCC

Accumulating evidence shows that metastatic tumor antigen 1 (MTA1) is involved in carcinogenesis of many cancers. MTA1 protein is a major component of the nucleosome remodeling and histone deacetylase (NuRD) complex. It contains several functional domains, including the BAH domain, the egl-27 and MTA1 homology domain 2 and the Swi3, Ada2, NCoR, and TFIIB domain for a variety of biological activities. It has been reported that MTA1 protein contributes to the process of carcinogenesis through modulating the expression of, or interacting with, the proteins involved in transformation, anchorage independence, invasion, epithelial-mesenchymal transition, migration, and metastasis.

However, studies on the clinicopathological features and implications of MTA1 overexpression in patients with HCC are scant. Previous studies have demonstrated that MTA1 overexpression is associated with postoperative recurrence, microvascular invasion, and poor prognosis in patients with HCC, particularly in patients with hepatitis B virus (HBV)-associated HCC (HBV-HCC). We thus first aimed to clarify the relationship between the expression of total MTA1 and MTA1dE4 in HBV-HCC and various clinicopathological features. Furthermore, we examined whether MTA1 and MTA1dE4 possesses any predictive value for clinical outcomes of patients with HBV-HCC receiving curative resection (Li YT et al, *Hepatology* 2019).

After documentation of the clinical value of MTA1 and MTA1dE4 in HBV-HCC, we then explored the mechanism through which MTA1 contributed to hepatocarcinogenesis. Both nuclear and cytoplasmic overexpression of MTA1 contributes to hepatocarcinogenesis. Most studies have focused on nuclear MTA1 whose function is mainly a chromatin modifier regulating the expression of various cancer-promoting genes. By contrast, the molecular mechanisms of cytoplasmic MTA1 in carcinogenesis remain elusive. Here, we conducted *in vitro* and *in vivo* studies and revealed a novel role of MTA1 in posttranscriptional gene regulation during hepatocarcinogenesis (Li YT et al, *Hepatology* 2022).

Currently, we have only serum AFP for the identification of subjects with underlying HCC and for the prediction of post-resection HCC recurrence. However, HCC recurrence will still occur even in patients with normal serum AFP, indicating the predictive value of serum AFP is not satisfactory. Complementary with serum AFP, our findings help identification of subjects with HCC recurrence who have normal serum AFP. These findings will be beneficial to risk population in Taiwan. Our study findings also revealed a novel function of MTA1 in hepatocarcinogenesis through modulation of the target gene expression not only at the transcriptional level but also at the posttranscriptional stage.



Dr. Koji Fujita

Department of Gastroenterology and Neurology, Faculty of Medicine,
Kagawa University, Japan

Serum miRNAs Predicting Sustained HBs Antigen Reduction 48 Weeks after Pegylated Interferon Therapy in HBe Antigen-Negative Patients

Koji Fujita¹, Shima Mimura¹, Hisakazu Iwama², Mai Nakahara¹, Kyoko Oura¹, Tomoko Tadokoro¹,
Joji Tani¹, Asahiro Morishita¹, Takashi Himoto³, Tsutomu Masaki¹

¹Department of Gastroenterology and Neurology, Kagawa University, Japan ²Life Science Research Center, Kagawa University, Japan ³Kagawa Prefectural University of Health Sciences, Japan

The therapeutic goal for hepatitis B virus (HBV) infection is HBs antigen (HBsAg) seroclearance, which is achieved through 48-week pegylated interferon (Peg-IFN) therapy. This study aimed to identify predictive biomarkers for sustained HBsAg reduction by analyzing serum microRNAs. Twenty-two consecutive chronic HBV infection patients negative for HBe antigen (HBeAg) with HBV-DNA levels < 5 log copies/mL, alanine aminotransferase (ALT) < 100 U/L, and compensated liver functions, were enrolled. The patients were subcutaneously injected with Peg-IFN α -2a weekly for 48 weeks (treatment period), followed by the 48-week observation period. HBsAg 1-log drop relative to baseline levels recorded at the end of the observation period was considered effective. Sera were obtained at weeks 0 and 24 during the treatment period analyzed for microRNAs. The microRNA (miRNA) antiviral activity was evaluated in vitro using Huh7/sodium taurocholate cotransporting polypeptide (NTCP) cells. As a result, six patients achieved the HBsAg 1-log drop after the observation periods. Comparison of serum microRNA levels demonstrated that high miR-6126 levels at week 24 predicted HBsAg 1-log drop. Furthermore, miR-6126 reduced HBsAg in culture medium supernatants and intracellular HBV-DNA quantities in Huh7/NTCP cells. In conclusion, high serum miR-6126 levels during Peg-IFN therapy predicted the HBsAg 1-log drop 48 weeks after the completion of therapy. In vitro assays revealed that miR-6126 was able to suppress HBsAg production and HBV replication.



Dr. Hirayuki Enomoto

Division of Hepatobiliary and Pancreatic Disease, Hyogo Medical University, Japan

Hepatoma-derived Growth Factor as a Potential Target Molecule for the Treatment of Hepatocellular Carcinoma

Background/Aims: Hepatocellular carcinoma (HCC) is a common malignant disease with an unfavorable prognosis. Although several new drugs have been developed, there is no definitive therapy against HCC, and new treatment strategies for HCC are warranted. HDGF (Hepatoma-derived growth factor) is a novel growth factor which is involved in the progression of HCC. We have reported that HDGF is highly expressed in the HCC tissues, and the expression level of HDGF is an independent prognostic factor for the disease-free and overall survival in patients with HCC. The purpose of this study is to examine whether HDGF can be a potential target molecule for the treatment of HCC.

Methods: (1) We generated the stably HDGF-overexpressed or HDGF-silenced hepatoma cell lines by the introduction of HDGF cDNA or sh-RNA, and examined the effects of the increased or reduced HDGF expression on the proliferation of hepatoma cells. (2) We investigated the effects of the exogenous and endogenous overexpression of HDGF on the proliferation and tubular formation of HUVEC (human umbilical vein endothelial cells) in vitro. (3) We examined whether the introduction of HDGF cDNA can induce the VEGF expression.

Results: (1) Introduction of HDGF cDNA stimulated the proliferation of hepatoma cells, whereas reduction of HDGF by sh-RNA suppressed the growth of the hepatoma cells. (2) Administration of recombinant HDGF significantly increased the cellular number of HUVEC in vitro, and HDGF-treated HUVEC formed longer vessel-like tubes in vitro than those formed by PBS-treated control cells. (3) HDGF induced VEGF expression through the activation of the VEGF promoter.

Conclusions: HDGF is a unique molecule which has dual characteristics; one as a growth stimulating factor on hepatoma cells and the other as an angiogenic factor. The angiogenic activity of HDGF seems to depend on two mechanisms; one is its direct effect on the proliferation of endothelial cells, while the other is the induction of VEGF. HDGF is therefore considered to be a potential target molecule for the treatment of HCC.



Dr. Hayato Hikita

Department of Gastroenterology and Hepatology,
Graduate School of Medicine, Osaka University, Osaka, Japan

Sustained Hepatocyte p53 Activation Induces Non-Cell Autonomous Liver Carcinogenesis

Hayato Hikita, Yuki Makino, Kanji Fukumoto, Takahiro Kodama, Ryotaro Sakamori,
Tomohide Tatsumi, Tetsuo Takehara

Department of Gastroenterology and Hepatology, Graduate School of Medicine,
Osaka University, Osaka, Japan

In hepatocytes of various chronic hepatitis, p53 is frequently activated. However, its impact of liver carcinogenesis remains unclear, and we examined it in the present study. We hepatocyte-specifically deleted *mdm2*, which degrades p53, in mice with hepatocyte specific activation of *Kras* (L-*Kras*G12D mice). *Mdm2* deletion increased expressions of p53 downstream genes, enhanced hepatocyte apoptosis, and emerged cellular senescence-associated secretory phenomenon (SASP) and hepatic progenitor cells (HPCs) in L-*Kras*G12D mice. It also promotes liver carcinogenesis, and *mdm2* gene was retained in the developed tumors. HPCs were isolated from non-tumor areas of *mdm2*-deficient and *mdm2*-wild L-*Kras*G12D mice to produce organoids followed by subcutaneously transplantation into immunocompromised mice. Organoids from *Mdm2*-deficient L-*Kras*G12D mice, but not *Mdm2*-wild L-*Kras*G12D mice, formed xenograft tumors. The xenograft tumor growth was suppressed by acyclic retinoids, which induces HPC cell differentiation and apoptosis. Those *mdm2* deletion-induced liver phenotype in L-*Kras*G12D mice were abolished when p53 was further deleted.

Hepatocyte-specific *mdm2* deletion in mice without *Kras* mutation also increased expressions of p53 downstream genes in livers and emerged hepatocyte apoptosis, SASP and HPCs. It also caused liver tumors in which the *Mdm2* genes was retained.

In liver samples from patients with chronic liver disease, expression of p53 downstream genes, including p21, increased compared to those of patients without chronic liver disease. SASP and HPCs were also detected in them. Patients with high-p21 expression had higher rates of subsequent hepatocarcinogenesis than those with low-p21 expression.

In conclusion, p53 activation in hepatocytes induces non-cell autonomous liver carcinogenesis.



Dr. Kazuomi Ueshima

Department of Gastroenterology and Hepatology,
Kindai University Faculty of Medicine, Japan

Immunotherapy for Advanced Hepatocellular Carcinoma

The recent advances in chemotherapy for hepatocellular carcinoma are remarkable. Atezolizumab plus Bevacizumab as an immune therapy has become available, and another immunotherapy: Durvalumab plus Tremelimumab, is expected to be available shortly. However, the appropriate use of these two immunotherapies has not yet been determined. Atezolizumab plus Bevacizumab not only blocks immune checkpoints but also improves the microenvironment in cancer. In addition, this combination therapy has a long-lasting antitumor effect with mild toxicity. However, the anti-VEGF effect induced by Bevacizumab brings several problems such as proteinuria, cardiovascular events, or bleeding. On the other hand, Durvalumab plus Tremelimumab has a tricky antitumor effect without toxicity induced by the anti-VEGF effects. In the HIMALAYA study, we had many CR cases, super responders certainly exist in this combination therapy from our experience, and these CR cases have been tumor-free with drug-free for more than four years. This combination therapy has more super responders than the other drugs. Even with extrahepatic metastasis, this therapy can bring patients with HCC into a cured state compared to other drugs. However, this regimen has a higher PD rate and immune toxicity induced by the anti-CTLA-4 effect. I would like to speak about the appropriate use of these two immunotherapies from the viewpoint of the immune microenvironment and the side effects.



Dr. Hasmik Ghazinyan
Nikomed Medical Center, Armenia

Impact of Viral Burden and Trajectory of Hepatocellular

Background and Aims: Armenia is the country with the highest incidence of primary liver cancer (PLC) between the Atlantic Ocean and China. According to the most recent estimates of GLOBOCAN, incidence in Armenia is above 13 cases/ 10^5 in men and above 6.5/ 10^5 in women.

We intend to provide detailed description of PLC risk factors in Armenia.

Methods: A series of 77 patients were diagnosed with PLC. Demographic data, risk factors, histology, PLC work-up, symptoms and biological variables were collected at the time of diagnosis.

Results: HCC was found in the majority of cases of PLC (95,6%) while tumors appeared in patients with cirrhosis in all of cases. The sex ratio of this series was (M/F=3.9) with the mean age of patients (56.9 ± 11.4 years). Among 77 patients with PLC viral risk factors were found in 50 patients (65%): HCV was the main risk factor in 39 cases (78%). Among these 39 cases 4 patients were diagnosed with HCC after treatment with Direct Antiviral Agents (DAA), mainly within 1 year after DAA administration. HBV as a risk factor was diagnosed in 11 (22%) cases.

We noticed massive sexual dimorphism for causal factors and age onset. The mean age for men was 55.5 ± 7.6 , while for women 62.2 ± 8.6 . Male patients were at higher risk in regards with precipitating factors such as alcohol consumption, smoking, presence of tattoos. Alcohol consumption promoted early HCC onset ($p=0.007$), median age in group with alcohol consumption was 55 versus 63 in group without alcohol consumption. Tobacco consumption was also associated with early HCC onset ($p=0.007$), since median age in smoking patients was 57 while in non-smokers group it was 62. Tattoos were another precipitating factor for HCC early onset ($p=0.003$) with median ages in patients with and without tattoos 54.8 ± 7.8 years and 60.8 ± 7.6 years respectively.

Conclusion:

**The dramatic increase of HCC incidence in Armenia is primarily due to the spread of HCV infection*

**HCV entered in a population presumably already predisposed to liver tumors by the high prevalence of obesity and lifestyle toxic factors (alcohol, tobacco)*



Dr. Kaoru Tsuchiya

Department of Gastroenterology and Hepatology,
Musashino Red Cross Hospital, Japan

Combination of Systemic and Locoregional Therapy in Advanced Hepatocellular Carcinoma

Background: Six molecular targeted therapies for unresectable hepatocellular carcinoma (HCC) have been approved in Japan. Recently, the efficacy and safety of a combination of systemic and locoregional therapy in patients with intermediate HCC were reported. We investigated the efficacy and safety of the combination therapy of systemic and locoregional therapy in patients with advanced HCC.

Method: A total of 60 patients who had BCLC stage C HCC and received lenvatinib (LEN) at our institution between Apr 2018 and Jan 2022 was included. Tumor assessments in accordance with modified RECIST were done using dynamic CT or MRI every 6-12 weeks. The clinical course in each patient was investigated retrospectively.

Results: The median age of the patients was 74 years. The median ALBI score was -2.25, and 48% of the patients were modified ALBI grade 2b. Line of treatment was 1st (n=38), 2nd (n=6), and 3rd (n=16). Extrahepatic metastasis was observed in 41 patients, and 26 had major vascular invasion (MVI). The median observation period was 10.8 months. The median overall survival (OS) was 15.1 months, and the median progression-free survival (PFS) was 4.8 months in all patients. TACE was performed during LEN therapy in 15 patients, and radiation therapy for the intrahepatic lesion was performed in 1 patient with peritoneal metastasis. The median OS and PFS of the LEN-TACE group were 38.4 and 14.7 months, and the median observation period was 21.0 months. Among the patients treated with LEN-TACE, 61% of patients could receive other molecular targeted therapies after LEN-TACE. The independent factors associated with OS in all patients were MVI (HR 0.24, 95%CI 0.06-0.91, p=0.04) and TACE during LEN (HR 0.16, 95%CI 0.04-0.64, p=0.009). Extrahepatic metastasis, pretreatment AFP, pretreatment ALBI score, and the relative dose intensity (RDI) over the first four weeks of LEN were not significant factors associated with OS in this cohort.

Conclusion: The combination therapy of lenvatinib and locoregional therapy in advanced HCC showed better clinical outcomes than the patients who participated in the phase III trial of LEN. Further investigation about the timing and kinds of locoregional therapies, including TACE, ablation, and radiation, should be performed.



Dr. Kuniaki Arai

Department of Gastroenterology, Kanazawa University Hospital,
Japan

The Role of Hepatic Arterial Infusion Chemotherapy Using 5-FU in the Era of Cancer Immunotherapy

Background: To evaluate the role of hepatic arterial infusion chemotherapy (HAIC) with 5-FU (5-fluorouracil) in advanced hepatocellular carcinoma (HCC) patients.

Methods: HCC patients treated with 5-FU HAIC between January 2003 and December 2021 were retrospectively evaluated for clinical background, antitumor efficacy, and prognosis according to Child-Pugh (C-P) B score, cTACE, systemic therapy, and major vascular invasion (MVI).

Results: In 455 patients, 67 years old, 77% males, and 183/218/54 patients with C-P classification A/B/C. The objective response rate (ORR) was 24.2%, median progression-free survival (mPFS) was 4.1 months, and median overall survival (mOS) was 9.9 months. The mOS of 28.4 months for responders was significantly better than that of 6.6 months for non-responders ($P < 0.0001$). In 218 C-P B patients, the ORR/mPFS/mOS was 20.6%/3.9 months/7.4 months. The ORR/mPFS/mOS by C-P score was 24.2%/4.7 months/9.9 months for 7 points, 22.5%/4.1 months/7.4 months for 8 points, and 12.5%/1.8 months/5.3 months for 9 points, respectively. The ORR/mPFS/mOS was 27.2%/4.5 months/11.8 months in 125 patients with prior cTACE and 23.0%/3.7 months/8.7 months in the 330 patients without prior cTACE, respectively (n.s.). In 97 patients after systemic therapy, the ORR/mPFS/mOS was 20.6%/3.8 months/8.0 months. In 134 patients with positive MVI, the ORR/mPFS/mOS was 14.1%/2.3 months/4.7 months, and 19.1%/2.6 months/6.2 months in the 97 patients with intrahepatic lesions only.

Conclusion: In the era of cancer immunotherapy, 5-FU HAIC should be considered as a treatment option for patients after second-line therapy, C-P B patients who are not eligible for systemic therapy, and patients with MVI having a poor prognosis.



Dr. Takeshi Hatanaka

Department of Gastroenterology,
Gunma Saiseikai Maebashi Hospital, Japan


The CRAFTY Score Predicts Prognosis of Hepatocellular Carcinoma Patients Receiving Atezolizumab and Bevacizumab: A Multicenter Retrospective Study

Background: This study aimed to investigate the utility of C-reactive protein (CRP) and alpha-fetoprotein (AFP) in immunotherapy (CRAFTY) score in hepatocellular carcinoma (HCC) patients receiving atezolizumab and bevacizumab (Atez/Bev).

Methods: This retrospective cohort study included a total of 297 patients receiving Atez/Bev from September 2020 to November 2021 at 17 different institutions and hospital groups in Japan. Patients with $\text{AFP} \geq 100$ ng/mL and those with $\text{CRP} \geq 1$ mg/dL were assigned a CRAFTY score of 1 point.

Results: The median age of all patients was 73.0 (68.0-78.0) years and 243 patients (81.8%) were men. The PS was 0, 1, and 2 in 238 (80.1%), 49 (16.5%), and 10 patients (3.4%), respectively. The etiology of chronic liver diseases was HCV, HBV, alcohol, NAFLD, and others in 99 (33.3%), 50 (16.8%), 57 (19.2%), 60 (20.2%), and 31 (10.4%) patients, respectively. The Child-Pugh score was 5, 6, and ≥ 7 in 183 (61.6%), 96 (32.3%), and 18 patients (6.1%), respectively. The median ALBI score was calculated to be -2.43 (-2.70 to -2.13) and the mALBI grades were 1, 2a, 2b, and 3 in 115 (38.7%), 76 (25.6%), 104 (35.0%), and 2 patients (0.7%), respectively. One hundred sixty-nine (56.9%) and 128 patients (43.1%) received Atez/Bev as a front line and later line treatment, respectively. The BCLC stage was classified as early, intermediate, advanced, and terminal in 17 (5.7%), 121 (40.7%), 155 (52.2%), and 4 patients (1.3%), respectively. The patients were assigned CRAFTY scores of 0 points ($n=147$ [49.5%]), 1 point ($n=111$ [37.4%]), and 2 points ($n=39$ [13.1%]). $\text{AFP} \geq 100$ ng/mL and $\text{CRP} \geq 1.0$ mg/dL were significantly associated with progression-free survival (PFS) and overall survival (OS). The median PFS in the CRAFTY score 0, 1, and 2 groups was 11.8 months (95% confidence interval [CI] 6.4-not applicable [NA]), 6.5 months (95% CI 4.6-8.0), and 3.2 months (95% CI 1.9-5.0), respectively ($p < 0.001$). The median OS in patients with CRAFTY score 0, 1 and 2 was not reached, 14.3 months (95% CI 10.5-NA), and 11.6 months (95% CI 4.9-NA), respectively. The percentage of patients with grade ≥ 3 liver injury, any grade of decreased appetite, any grade of proteinuria, any grade of fever, and any grade of fatigue was lowest in patients with a CRAFTY score of 0, followed by patients with CRAFTY scores of 1 and 2.

Conclusions: The CRAFTY score is simple and could be useful for predicting therapeutic outcomes and treatment-related adverse events.



Dr. Tsubasa Nobusawa

Department of Gastroenterology and Hepatology,
Musashino Red Cross Hospital, Japan

Real-World Outcome of Cabozantinib in Patients with Unresectable Hepatocellular Carcinoma

Hiroaki Matsumoto¹, Kaoru Tsuchiya¹, Hiroyuki Nakanishi¹, Yuka Hayakawa², Yutaka Yasui¹, Naoki Uchihara¹, Keito Suzuki¹, Yuki Tanaka¹, Haruka Miyamoto¹, Shun Ishido¹, Michiko Yamada¹, Taisei Keitoku¹, Tsubasa Nobusawa¹, Mayu Higuchi¹, Kenta Takaura¹, Shohei Tanaka¹, Chiaki Maeyashiki¹, Nobuharu Tamaki¹, Masayuki Kurosaki¹, Namiki Izumi¹

¹Department of Gastroenterology and Hepatology, Musashino Red Cross Hospital, Tokyo, Japan

²Department of Gastroenterology and Hepatology, Tokyo medical dental university, Tokyo, Japan

Background: Cabozantinib (CAB) therapy for unresectable hepatocellular carcinoma (u-HCC) has been approved since Nov 2020 in Japan. In this study, we investigated the efficacy and safety of CAB in real-world practice.

Methods: A total of 31 u-HCC patients who received CAB between Jan 2021 and Jun 2022 at our institution were included. Tumor assessments in accordance with RECIST ver1.1 were done using dynamic CT or MRI within 4-8 weeks and every 8-10 weeks thereafter. Adverse events (AEs) were graded according to the CTCAE ver5.0.

Results: The median age was 74 years, and 22 patients were Child-Pugh A. BCLC stage A/B/C were 0/ 10/ 21 patients, and 27 patients were previously received atezolizumab and bevacizumab. As 2nd or 3rd-line, 15 patients received CAB. The median follow-up duration was 9.2 months, and the median PFS was 4.8 months in all patients. The one-year survival rate was 61%. The objective response rate (ORR) and disease control rate (DCR) was 8.7% and 95.7%. The median 4W-relative dose intensity (RDI) was 35%, and there was no significant difference in PFS between 4W-RDI <30% (n=7) and ≥30% (n=17) (7.4 months vs. 4.8 months, p=0.97). AEs were observed in all patients, requiring dose reduction in 21 patients (68%) and discontinuation in 18 patients (58%). The rate of molecular targeted therapies after CAB was 72.2%. In a multivariate analysis, hypertension during CAB was the only significant factor associated with OS (HR 0.23, 95% CI 0.05-0.97, P=0.04).

Conclusions: CAB showed similar efficacy and safety in real-world practice compared to the clinical trials.



Dr. Akio Moriya

Department of Gastroenterology, Mitoyo General Hospital, Japan

Roles of Levocarnitine on the Survival of Patients Who Undergo Cell-free and Concentrated Ascites Reinfusion Therapy: A Preliminary Study

Patients with liver cirrhosis often develop carnitine deficiency, which relates to various symptoms caused by liver cirrhosis. Carnitine is involved in lipid transport through the mitochondrial membrane and, especially in the liver, promotes ammonia metabolism. Therefore, levocarnitine is often used as a therapeutic agent for hepatic encephalopathy.

Cell-free and concentrated ascites reinfusion therapy (CART) is a therapeutic option against refractory ascites. We evaluated clinical outcomes of CART procedures in 53 patients with cirrhosis and found that levocarnitine administration was a significant factor associated with mortality (hazard ratio, 0.34; 95% confidence interval, 0.15-0.76) besides ALBI score (3.43 per 1 increase, 1.55-7.57) and concurrent malignant disease (2.35, 1.18-4.68). In a comparison of 21 patients with and 21 without levocarnitine, matched according to propensity score, median survival tended to be longer in the levocarnitine group (99 days vs. 51 days, $P = 0.06$). Most patients receiving levocarnitine were treated for hepatic encephalopathy and they were still more likely to develop hyperammonemia or overt encephalopathy than those without levocarnitine administration (2.91, 1.48-5.70). However, there was a trend toward longer survival in the levocarnitine group with hepatic encephalopathy than in the non-levocarnitine group without hepatic encephalopathy. The results suggest that levocarnitine treatment has prognostic benefits that transcend hepatic encephalopathy and levocarnitine-associated encephalopathy improvement.

We hypothesized that levocarnitine administration may complement the loss of carnitine due to CART. To prove it, we measured carnitine levels in the blood, ascites, and post-filtration collection fluid in patients who underwent CART and found that carnitine levels in ascites were similar to those in serum ($r = 0.9987$, $P < 0.001$), and that a large part of the carnitine was lost in CART, depending on the concentration of ascites. The amount of carnitine lost in CART can be adequately replaced by a single dose of levocarnitine at the standard dose, considering the bioavailability of carnitine, which is estimated to be around 14-18%.

When patients are already with carnitine deficiency, even a small loss of carnitine due to CART may have an impact on prognosis. Thus, carnitine supplementation no doubt prevents further carnitine deficiency. On second thought, the prognostic improvement might be due to the administration of much more levocarnitine than the amount lost in CART. Whether levocarnitine contributes to improved prognosis with or without CART remains to be determined in future analyses, which may elucidate that levocarnitine is a key drug in the management of decompensated liver cirrhosis.



Dr. Kei Moriya

Department of Gastroenterology, Nara Prefecture General Medical Center,
Japan

Our Potent Strategies for Inhibiting the Progression of Hepatic Fibrosis in Patients with Autoimmune Liver Disease

Kei Moriya^{1,2}, Yukihiisa Fujinaga², Masahide Enomoto², Yuki Tsuji², Koh Kitagawa², Norihisa Nishimura², Kosuke Kaji², Hideto Kawaratani², Tadashi Namisaki², Hideki Matsuo¹, Masakazu Uejima¹, Youya Matsuo¹, Yusuke Komeda¹, Yoshiki Tamada¹, Kuniaki Ozaki¹, Junichi Hanatani¹, Daisuke Kaya¹, Soichiro Saikawa¹, Shinsaku Nagamatsu¹, Hitoshi Yoshiji²

¹Department of Gastroenterology, Nara Prefecture General Medical Center


²Department of Gastroenterology, Nara Medical University

Background: Primary biliary cholangitis (PBC) and autoimmune hepatitis (AIH) have seen a threefold increase in the number of patients over the past 20 years. It has been reported that oxidative stress in hepatocytes is involved in liver fibrosis and hepatocarcinogenesis and that antioxidant activity via the Nrf2/Keap1 pathway is impaired in PBC. However, no research has elucidated whether activation of this pathway actually improves the condition of PBC. Therefore, we are currently conducting a prospective interventional clinical study in which PBC patients are treated with a Nrf2-activating agent. Additionally, we have completed another clinical study on the effects of long-term administration of zinc in AIH patients and report the results of the study.

Methods: Thirty-eight AIH patients with written consent and in clinical remission were treated with polaprezinc for 24 months.

Results: Serum zinc levels in the good responders increased significantly by 50% after 24 months of treatment ($P < 0.001$). Type 3 procollagen and type 4 collagen 7S also showed a downward trend. Conversely, type 4 collagen 7S increased in the poor responders, and a significant difference was observed between the two groups ($P = 0.049$). Additionally, there was a significant difference between the two groups in the amount of change in type 3 procollagen ($P = 0.043$). No patients dropped out due to medication-related adverse events.

Conclusion: In seeking to improve the pathogenesis of autoimmune liver disease, medical interventions related to the suppression of oxidative stress and the amelioration of fibrosis via metal metabolism may be effective, and may consequently affect long-term life expectancy.



Dr. Tomomi Okubo

Nippon Medical Chiba Hokusoh Hospital, Japan

Usefulness of Vitamin D Measurement and Effectiveness of Vitamin D Supplementation

Aim: This study was aimed to investigate the relationship between serum Vitamin D levels and sarcopenia in chronic liver diseases including liver cirrhosis patients and investigate the effects of Vitamin D supplementation on skeletal muscle in chronic liver disease including HCC patients.

Methods: Study 1; Serum 25(OH)D were measured in 375 patients with chronic liver disease, and the relationship between sarcopenia and vitamin D was examined. Study2; Fifty-five patients were divided into two groups: a Vitamin D group (25 patients) and a follow-up group (30 patients), and the effect of Vitamin D administration was examined. Study 3; Examined changes over time in vitamin D levels, muscle mass, and grip strength in 30 patients treated with systemic drug therapy for multiple HCCs. This study was approved by the Ethics Committee and the Certified Clinical Research Review Board.

Results: Study 1: Overall, 32.4% (67/207) of patients were diagnosed with sarcopenia in liver cirrhosis. Multivariate analysis showed that older age ($p=8.18 \times 10^{-5}$, OR=1.06, 95%CI=1.03-1.09), low serum 25(OH)D ($p=1.28 \times 10^{-6}$, OR=1.15, 95%CI=1.09-1.21) and Child-Pugh grade B and C ($p=4.73 \times 10^{-3}$, OR=3.28, 95%CI=1.24-7.46) were independent factors associated with sarcopenia. Study 2; Vitamin D levels increased significantly in the vitamin D group after 1 year ($p=1.23 \times 10^{-5}$). The Vitamin D group showed a significant increase in skeletal muscle mass compared to the follow-up group at 12 months ($p=1.08 \times 10^{-4}$). Study 3; Vitamin D levels were lower in all patients at 6 months of treatment compared to baseline ($p=5.06 \times 10^{-3}$). The decrease in skeletal muscle mass was significant in patients with Vitamin D level less than 16 ng/mL.

Conclusion: Measurement of Vitamin D is useful in the diagnosis of sarcopenia, and in the treatment of HCCs, patients with low Vitamin D levels at baseline should be noted for loss of muscle mass. The results also suggest that Vitamin D supplementation may be useful in the maintenance of skeletal muscle mass.



Dr. Kazuya Okushin

¹Department of Gastroenterology, ²Department of Infection Control and Prevention,
Graduate School of Medicine, The University of Tokyo, Tokyo, Japan

Transition of Treatment Selection for Primary Liver Cancer and Decompensated Cirrhosis in Multiple Admissions: Analysis of a Nationwide Registry for Advanced Liver Diseases (REAL)

Kazuya Okushin^{1,2}, Ryosuke Tateishi¹, Arata Takahashi^{3,5}, Koji Uchino¹, Ryo Nakagomi¹, Takuma Nakatsuka¹, Tatsuya Minami¹, Masaya Sato¹, Mitsuhiro Fujishiro¹, Kiyoshi Hasegawa⁴, Yuichiro Eguchi⁶, Tatsuya Kanto⁷, Shoji Kubo⁸, Hitoshi Yoshiji⁹, Hiroaki Miyata^{3,5}, Namiki Izumi¹⁰, Masatoshi Kudo¹¹, Kazuhiko Koike^{1,12}

¹Department of Gastroenterology, Graduate School of Medicine, The University of Tokyo, Tokyo, Japan, ²Department of Infection Control and Prevention, Graduate School of Medicine, The University of Tokyo, Tokyo, Japan, ³Department of Healthcare Quality Assessment, Graduate School of Medicine, The University of Tokyo, Tokyo, Japan, ⁴Hepato-Biliary-Pancreatic Surgery Division, Artificial Organ and Transplantation Division, Department of Surgery, Graduate School of Medicine, The University of Tokyo, Tokyo, Japan, ⁵Department of Health Policy and Management, School of Medicine, Keio University, Tokyo, Japan ⁶Liver Center, Saga University Hospital, Saga University, Saga, Japan, ⁷The Research Center for Hepatitis and Immunology, National Center for Global Health and Medicine, Chiba, Japan, ⁸Department of Hepato-Biliary-Pancreatic Surgery, Osaka Metropolitan University Graduate School of Medicine, Osaka, Japan ⁹Department of Gastroenterology, Nara Medical University, Kashihara, Nara, Japan, ¹⁰Department of Gastroenterology and Hepatology, Musashino Red Cross Hospital, Musashino, Japan, ¹¹Department of Gastroenterology and Hepatology, Kindai University Faculty of Medicine, Osaka-Sayama, Japan, ¹²Kanto Central Hospital, Tokyo, Japan

Background: Patients with decompensated cirrhosis often experience frequent exacerbations that need hospitalization. This study aims to clarify the characteristics of patients with liver cirrhosis in a newly developed nationwide registry for advanced liver diseases (REAL) that can store data on multiple admissions for primary liver cancer and decompensated cirrhosis in Japan.

Methods: We retrieved patients' data initially diagnosed with decompensated cirrhosis between April 2018 and January 2021 from the registry. Decompensation was defined as ascites, hepatic encephalopathy, rupture of esophageal varices, or a Child-Pugh score of 7 or higher. We analyzed patients' characteristics, including age, sex, background etiology, laboratory data, and symptoms and treatment modalities for each admission.

Results: The study enrolled 3,055 patients with 5,409 admissions. The mean ages at initial diagnosis were 69 ± 10 . The etiology was HBV in 6.4%, HCV in 21.3%, and non-B, non-C in 61.7%. Primary liver cancer was complicated in 18.8%. We further analyzed treatment allocation in the second (n=972), third (n=460), and fourth or later (n=922) admissions in addition to the initial treatment. In addition to loop diuretics and aldosterone antagonists, vasopressin receptor 2 antagonists increased with the number of hospitalizations, reaching 57.2% for the fourth and subsequent hospitalizations. Regarding the treatment for encephalopathy, rifaximin or carnitine supplementation also increased linearly with repeated hospitalizations.

Conclusions: The analysis demonstrated the change in treatment selection for decompensated cirrhosis in Japan. Newly introduced drugs for cirrhosis were widely used in clinical practice in Japan.



Dr. Batbold Batsaikhan

Department of Internal Medicine, Institute of Medical Sciences,
Mongolian National University of Medical Sciences, Mongolia

**Persistent Cryoglobulinemia after Antiviral Treatment is Associated with
Advanced Fibrosis in Chronic Hepatitis C**

Batbold Batsaikhan¹, Gantogtokh Dashjams¹, Ankhzaya Batsaikhan¹, Ganchimeg Dondov¹,
Badamjav Tegshjargal¹, Bayar Davaa¹, Tulгаа Lonjid¹, Chia-Yen Dai²

¹Department of Internal Medicine, Institute of Medical Sciences, Mongolian National University of Medical
Sciences

²Kaohsiung Medical University Chung-Ho Memorial Hospital

Background: The presence of the circulating serum cryoglobulinemia detected in 40–60% of HCV infected patients. Some researchers reported that cryoglobulinemia is associated with advanced liver fibrosis in chronic hepatitis C (CHC) patients. Careful monitoring of mixed cryoglobulinemia and mixed cryoglobulinemia related vasculitis, chronic kidney manifestations during and after antiviral treatment were suggested in CHC patients.

Methods: We have conducted the multicenter study enrolling patients with CHC referred to Kaohsiung Medical University Hospital, a tertiary Medical Center and two regional hospitals from 2005 to 2016. Sustained virological response (SVR) was defined as negative HCV RNA at 6 months after cessation of treatment. The liver biopsy was obtained from all patients and four indexes of fibrosis (FIB4) was calculated to describe advanced fibrosis.

Results: Totally 148 patients who have checked serum cryoglobulinemia after antiviral therapy were enrolled in this study. The factors associated with the persistent cryoglobulinemia in SVR patients were advanced fibrosis (56.2%, $p < 0.011$) and low platelet count (137.3 ± 56.3 10⁹L, $p < 0.012$) respectively. Multivariate analysis revealed that the fibrosis stage (OR 1.93, 95% CI 1.02–3.65, $p < 0.041$) and platelet count (OR 0.98, 95% CI 0.96–0.99, $p < 0.041$) significantly associated with persistent cryoglobulinemia in hepatitis C virus cured patients.

Conclusion: Our study shows an independent association between persistent cryoprecipitate and advanced fibrosis after antiviral therapy in CHC patients.



Dr. Masaru Muraoka

Department of Gastroenterology University of Yamanashi Hospital,
Japan

Clinical Indications for Liquid Biopsy Using Cell Free DNA Content in the Pharmacotherapy of Advanced Hepatocellular Carcinoma

Purpose: Liquid biopsy is a noninvasive method for predicting early response to drug therapy for advanced hepatocellular carcinoma (HCC). The amount of tumor-derived cell free DNA (cfDNA) may reflect tumor necrosis, and we investigated the association between the amount of cfDNA and clinical course in the treatment of HCC.

Methods: Thirty-five patients treated with Tyrosine kinase inhibitor (TKI) in 2018-2020 (Lenvatinib/Sorafenib: 29/6, mean age: 69.5, male/female: 33/2) and 12 patients treated with immune checkpoint inhibitors (ICI) in 2021 (treated by Atezolizumab + Bevacizumab, mean age: 69.5 years, male/female: 10/2) were included. The tumor-associated gene was the TERT promoter C228 mutation, and mutation-positive cfDNA (mutant DNA) was quantified by digital PCR. The changes in mutant DNA levels before (Pre), 1 week after treatment (Peak), and 1-3 weeks after treatment (Last) were examined.

Results: Mutant DNA was detected in 67.6% of TKI cases and 75% of ICI cases. We defined the case in which mutant DNAs increase within 1 week as Responder. Responders in TKI cases were observed in 85.7% of PR, 62.5% of SD, and 0% of PD in the first CT after treatment, and the response of mutant DNA within 1 week was significantly associated with treatment response.

Responder in ICI cases was observed in 66.7% of PR cases, 25% of SD cases, and 0% of PD cases (NS.).

Conclusion: Changes in tumor-derived mutant DNA levels after drug treatment of HCC may be a good predictor of treatment response.



Dr. Hirohito Yoneyama

Department of Gastroenterology and Neurology, Faculty of Medicine,
Kagawa University, Japan

Prediction of Liver Fibrosis and Carcinogenesis by Body Comparison Analysis by Bioelectrical Impedance Analysis

Background: Body mass index (BMI) is a measure of obesity, and is greatly involved in the onset of impaired glucose tolerance (IGT) and NAFLD. However, in clinical practice, there are so-called “hidden obesity type” which has high body fat percentage even though BMI is normal, and cases with low muscle mass and liver disorder even if the body fat percentage is normal. Therefore, it is considered important to measure body composition in medical treatment of NAFLD. The present study aims to investigate the relationship between parameters obtained by body composition measurement and the progression of liver fibrosis in NAFLD.

Methods: We measured the body composition such as body fat percentage, muscle mass per body weight (muscle percentage), BMI, etc. of NAFLD patients by the bioelectrical impedance analysis (BIA). Fib-4 index was also measured in all cases and correlations with various parameters obtained by BIA were examined.

Results: BMI, body fat percentage, and muscle mass had no significant correlation with Fib-4 Index on their own. However, classifying the body type into nine groups with a combination of the degree of body fat and muscle percentage (high, medium, low) shows that Fib-4 indexes in the groups with high-fat/medium-muscle and high-fat/high-muscle were significantly higher than that of the standard group (medium-fat/medium-muscle). Particularly in the high-fat/high-muscle group, the Fib-4 index tended to increase markedly with age.

Conclusions: Body composition measurements and body type determination by BIA method are considered to be useful for predicting the progress of liver fibrosis and carcinogenesis in NAFLD patients.



Dr. Zijian Yang

Department of Gastroenterology and Hepatology, Graduate School of Medicine,
Hokkaido University, Sapporo, Japan

Changes in Serum Growth Factors during Lenvatinib Predict the Post Progressive Survival in Patients with Unresectable Hepatocellular Carcinoma

Zijian Yang¹, Goki Suda¹, Osamu Maehara², Masatsugu Ohara¹, Sonoe Yoshida¹, Shunichi Hosoda¹,
Yoshimasa Tokuchi¹, Koji Ogawa¹, Shunsuke Ohnishi², Naoya Sakamoto¹

¹Department of Gastroenterology and Hepatology, Graduate School of Medicine, Hokkaido University,
Sapporo, Japan

²Laboratory of Molecular and Cellular Medicine, Faculty of Pharmaceutical Sciences, Hokkaido University

Background: In this study, we firstly revealed that the pattern of developing resistance to lenvatinib varies and determines the prognosis of patients with unresectable hepatocellular carcinoma (HCC) by analyzing the changes in growth factors during lenvatinib for unresectable HCC.

Methods: The sequential changes in serum growth factors during lenvatinib for unresectable HCC were evaluated in 58 patients using complete clinical data, and preserved serum was used to investigate changes in FGF-19, ANG-2, HGF, VEGF, and EGF. Patients with a complete response (CR), partial response (PR), and stable disease (SD) were evaluated for growth factor changes between the best response and progressive disease (PD) points, classified based on these changes, and evaluated by post progression survival (PPS).

Results: A total of 8, 24, 18, and 8 patients showed CR, PR, SD, and PD, respectively. Multivariate analysis revealed that age, relative dose intensity, and baseline ANG-2 were significantly associated with treatment response. Growth factor changes between the best response and PD points revealed that patients could be classified into four groups based on the EGF, ANG-2, and HGF changes. Although patient characteristics at baseline and PD, their response to lenvatinib, and PFS were similar among those groups, patients with an increase in all growth factors had significantly shorter PPS (median PPS was 553, 323, and 316 versus 173 days in groups 1-4 $p = 0.032$).

Conclusion: The evaluation of changes in growth factors during lenvatinib could predict treatment response and PPS and could be used for the determination of salvage therapy.



Dr. Issei Saeki

Department of Gastroenterology and Hepatology, Yamaguchi University
Graduate School of Medicine, Yamaguchi, Japan

Liquid Biopsy Test Based on Methylated SEPT9 for Surveillance of NonBnonC Hepatocellular Carcinoma

Issei Saeki¹, Takahiro Yamasaki², Yutaka Suehiro², Yurika Yamauchi¹, Norikazu Tanabe¹, Takashi Oono¹,
Tsuyoshi Ishikawa¹, Taro Takami¹

¹Department of Gastroenterology and Hepatology, Yamaguchi University Graduate School of Medicine,
Yamaguchi, Japan

²Department of Oncology and Laboratory, Yamaguchi University Graduate School of Medicine, Yamaguchi,
Japan

Background: Recently, the incidence of non-viral HCC (N-HCC) has increased, whereas N-HCC surveillance remains a problem. Tumor markers, such as low positive rate of AFP and drug effects (eg. warfarin) on DCP, experience issues. We developed a liquid biopsy test using a highly sensitive methylation-SEPT9 (m-SEPT9) assay to diagnose HCC.

Objective: We investigated the diagnostic ability of m-SEPT9 in N-HCC, and its combined effect with the existing markers of AFP and DCP.

Methods: We enrolled 60 patients with N-HCC between 2015 and 2018 (T group). We set a cutoff for m-SEPT9 which was beneficial in N-HCC diagnosis. We analyzed 72 patients with N-HCC between 2019 and 2021 (V group) and validated the diagnostic ability. We calculated the positivity rate with AFP/DCP/m-SEPT9. The AFP and DCP cutoff values were 20 ng/mL and 40 mAU/mL, respectively.

Results: The cutoff was calculated using ROC analysis with 100 copies/mL (AUC, 0.383; sensitivity, 71.7%; specificity, 85.2%). The sensitivity of AFP, DCP, and m-SEPT9 was 43.3%, 75.0%, 71.7%, respectively, in the T group, and 41.7%, 69.4%, and 72.2%, respectively, in the V group. m-SEPT9 increased the sensitivity by approximately 10% in both the T and V groups. 4) In 38 patients with early-stage HCC (BCLC-0/A), the sensitivity of AFP, DCP, and m-SEPT9 was 15.6%, 44.7%, and 52.6%, respectively. The combination of AFP and DCP showed 50.0% sensitivity, whereas the addition of m-SEPT9 increased it to 68.4%.

Conclusion: m-SEPT9 is beneficial in N-HCC diagnosis, and, it contributes to high detection of early-stage HCC when combined with DCP.



Dr. Masahiro Morita

Department of Gastroenterology and Hepatology,
Kindai University, Osaka, Japan

Selection of Anti-PD-1 Antibody Effective Group Using Tumor Immunological Microenvironment

Masahiro Morita, Naoshi Nishida, Masatoshi Kudo
Department of Gastroenterology and Hepatology, Kindai University, Osaka, Japan

Introduction: In previous studies, anti-PD-1 monotherapy was as low as 20%. Identifying subgroups that respond well to ICIs is important. We studied the prognostic factors for anti-PD-1 antibody treatment based on the molecular and immunological features of HCC.

Methods: Patients who were administered anti-PD1 antibody for advanced HCC at Kindai University Hospital were included. Clinicopathological backgrounds and anti-tumor responses were examined in 34 cases where tumor tissues before treatment were available. Transcriptome analysis was performed using 40 HCC samples obtained from surgical resection, and immune status was compared between 20 HCCs with activating mutations in β -catenin and those without the mutations using transcriptome-based immunogram.

Results: Negative staining of β -catenin/ glutamate synthetase (GS), combined positive score (CPS) of PD-L1 ≥ 1 , and high degree of CD8+ TILs were significantly associated with longer survival in both PFS and OS. The combination of these factors well stratified the survival of the patients on anti-PD-1 antibody in both PFS and OS ($p < .0001$ and $p = .0048$ for PFS and OS, respectively). In addition, the immunogram revealed that tumor-carrying mutations in β -catenin showed downregulation of immune-related genes, especially in those related to interferon- γ response.

Discussion/Conclusion: The combined score including Wnt/ β -catenin activation, CPS of PD-L1, and degree of CD8+ TILs in HCC is informative for predicting the response to ICI in HCC cases. Constitutive activation of β -catenin can induce an immune cold phenotype with downregulation of immune-related genes, and immunohistochemistry-based evaluation is beneficial for identifying the subgroup that shows a good response to ICI.



Dr. Shinya Maekawa
University of Yamanashi, Japan

SERUM IP-10/CXCL10 is a Useful Predictor for Post-DAA Treatment Liver Function and HCC Development in HCV Patients

Shinya Maekawa, Ryo Katoh, Leona Osawa, Yasuyuki Komiyama, Natsuko Nakakuki, Masaru Muraoka, Yuichiro Suzuki, Mitsuaki Sato, Yasuhiro Nakayama, Taisuke Inoue, Nobuyuki Enomoto
University of Yamanashi

Background: With the advent of DAA therapy, sustained virological response (SVR) can be achieved even in patients with decompensated cirrhosis (dLC). However, SVR does not always improve liver function, and hepatocellular carcinoma (HCC) still develops after SVR.

Methods: Serum IP-10/CXCL10 levels were measured in 47 patients receiving DAA therapy, and their changes during the therapy were examined. 15 patients were chronic hepatitis (CH), 17 were compensated cirrhosis (cLC) (CP-A) and 15 were dLC (CP-B or C).

Results: All patients achieved SVR. In CH patients, average IP-10 level was 367 pg/ml, 102 pg/ml and 68pg/ml respectively at baseline, at end-of-therapy (EOT) and at 12 weeks after SVR (SVR12), and was decreased upon DAA therapy ($P<0.001$). In cLC patients, IP-10 was respectively 215 pg/ml, 91 pg/ml and 77 pg/ml, and was decreased upon DAA therapy ($P<0.001$) while it was 283 pg/ml, 131 pg/ml and 182 pg/ml in dLC patients and there was no evident decrease ($P= 0.55$). When dLC patients were further classified depending on the difference in CP score improvement at SVR12, a significant decrease in IP-10 was observed after treatment in those with improvement ($P=0.023$) while a significant increase was observed in those without improvement ($P=0.016$). Finally, when we classified the 47 patients into two groups according to the IP-10 increase/decrease at SVR12, those with increase showed significant high HCC occurrence compared to those without ($p<0.001$)

Conclusion: IP-10/CXCL10 dynamics reflected liver function and HCC development after DAA therapy, indicating IP-10/CXCL10 dynamics is an important predictor of prognosis.



Dr. Rino Gani

Division of Hepatobiliary, Department of Internal Medicine Faculty of Medicine University of Indonesia Cipto Mangunkusumo Hospital, Jakarta, Indonesia

Treatment of Advanced Hepatocellular Carcinoma

Many patients of hepatocellular carcinoma (HCC) are unfortunately diagnosed at an advanced stage, precluding curative therapy with surgery. For this advanced HCC, non-surgical management for HCC includes locoregional intra-arterial therapy, systemic treatment with multi-kinase inhibitors, and immunotherapy.

Significant improvement of survival was shown in patients with locally advanced HCC and Child-Pugh A or B cirrhosis treated with TACE as compared with best supportive care, with relative risk of death reduction more than 50%. TACE with drug-eluting beads (DEB-TACE) and trans-arterial radio-embolization (TARE) are alternative intra-arterial locoregional therapies for HCC. TARE has a better TTP compared to TACE but improvement of OS was not shown.

Multikinase inhibitor or tyrosine kinase inhibitor (TKI) has long been implemented in the management of HCC. Sorafenib an inhibitor of platelet-derived growth factor receptor (PDGFR), vascular endothelial growth factor receptor (VEGFR), rearrange during transfection (RET), and C-kit, is the first multi-kinase inhibitor proved to be beneficial in unresectable, advanced-stage HCC. This substance may work best in the absence of extrahepatic spread, HCV-related HCC and low neutrophil-to-lymphocyte ratio. Lenvatinib, an inhibitor of epidermal growth factor receptor (EGFR), fibroblast growth factor receptor (FGFR), VEGFR, PDGFR, RET, and C-kit prove to be non-inferior to Sorafenib in unresectable HCC.

Immunotherapy for HCC have been progress extensively. Two pathways that are widely studied were 1/programmed death-ligand 1 (PD-1/PD-L1) pathway and cytotoxic T-lymphocyte-associated antigen 4 (CTLA-4) pathway. Pembrolizumab study (Keynote-224 trial) anti-PD-1 monoclonal antibody, an objective response was observed in 18 of 104 sorafenib-experienced patients (17%), however, the OS and PFS was not met.

Combination therapy of TACE and sorafenib or lenvatinib have been applied with promising results. However, the combine treatment may be only for patients with good liver function as well kidney function. Immunotherapy combination with multikinase inhibitor have also been studied. Currently, atezolizumab and bevacizumab combination that prove to be better than sorafenib alone has been put as first line therapy for unresectable HCC with certain criteria. Other combination in this kind is pembrolizumab combine with lenvatinib that may give promise better than lenvatinib alone.

Second line treatment that already studied (after sorafenib) were the use of regorafenib, ramucirumab and pembrolizumab and radiotherapy with the varying results. Other kind of treatment such as hepatic artery infusion, stereotactic body radiation therapy may be use with varying results.

Several option are available in the treatment of advanced HCC. A thorough discussion with multidiscipline approach is needed to put one treatment as well the strategy of follow up for a particular patient.



Dr. Shiv K Sarin

Department of Hepatology, Institute of Liver and Biliary Sciences, New Delhi, India

Management of HCC patients with Portal Vein Thrombosis

Portal vein tumor thrombosis (PVTT) is present in 10%-40% of HCC at the time of diagnosis, and is an adverse prognostic factor. Patients with PVTT usually have an aggressive disease course, poor hepatic functional reserve, limited treatment options and higher recurrence rates. Among untreated HCC patients with PVTT, the median overall survival has been reported as 2 to 4 months. The PVTT results in disordered hepatic and portal blood flow and associated impairment of liver function, heat-sink effects of blood flow in the area of PVTT, risk of recurrence and spread of tumor being in the blood vessels

There is no consensus on the management of HCC with PVTT. Treatment varies in different centres and includes partial hepatectomy with en bloc resection of PVTT in second-order branches and distal branches (Vp1/Vp2), locoregional therapy including trans-arterial radio embolization (TARE), stereotactic body radiation therapy (SBRT), transarterial chemoembolization (TACE), immunotherapy alone, or, a combination of therapies. A proper patient selection is the key to good outcome. High levels of prothrombin induced in vitamin K absence (PIVKA II) with or without alfa-feto protein has been found to be a good marker of portal vein invasion. The current BCLC staging system categorizes HCC patients with PVTT as advanced stage and recommends systemic therapy with Sorafenib/Lenvatinib as first line therapies. However, sorafenib is associated with only marginal benefits among patients with PVTT and in Lenvatinib studies, patients with main portal trunk invasion were excluded. We have used high dose of Vitamin K, which induces apoptosis and cell cycle inhibition, including the MAPK pathway for HCC with PVT. In a series of 60 patients, a combination of high dose of vitamin K (VK1) given for 6 days with sorafenib was found to be more effective (VK1) than sorafenib alone in advanced HCC patients with PVTT being present in 73%. PIVKA II reduction was seen in 94% patients (median PIVKA II reduction from 74 ng/ml to 4.5 ng/ml). This therapy can be given up to Child B 7 patients who were not candidates for other local therapies.

Although traditionally PVTT has been considered contraindication to liver transplantation or surgical resection, in specialized units, partial hepatectomy with en bloc resection of PVTT in second-order has been shown to offer significant benefits in selected patients. However, the risk of recurrence within two years can be as high as 44%. LT should not be done in VP3 or VP4 lesions. Locoregional therapies are no more considered an absolute contraindication for PVTT. TARE has been shown to provide partial or complete response in upto 70-90% patients, with complete regression of tumor in nearly half, with survivals reaching similar to that achieved in patients without PVT. The success rate with stereotactic body radiotherapy (SBRT) has been found to be equally good in achieving actuarial overall survival in responders and non-responders close to 15 and 7 months. After SBRT, the patients can be taken up for TACE, TARE or immunotherapy. Liver transplantation has also been successfully carried out in patients with VP1 or 2 tumor thrombus after successful local therapies, including TARE and SBRT, though the overall long-term survival remains to be seen. The role of immune check point inhibitors Atezolizumab and bevacizumab in improving the overall survival is quite promising. Recently encouraging results have been shown with these agents even in patients with Child B patients with PVTT.

Management of portal hypertension and variceal bleeding also is a major challenge in these patients. All patients with PVTT should be placed on beta-blockers as primary prophylaxis for variceal bleeding. In those with active bleeding, variceal band ligation or cyanoacrylate glue therapy should be offered. In those with uncontrolled bleed, or those with refractory ascites, a TIPS stent placement should be considered.

A personalized and multidisciplinary management is desirable for achieving 50% two year survival in patients of HCC with PVTT.



Dr. Takeshi Terashima

Department of Gastroenterology, Kanazawa University Hospital, Japan

Recently Proven Evidence of Hepatic Arterial Infusion Chemotherapy for Hepatocellular Carcinoma

Hepatic arterial infusion chemotherapy (HAIC) has been used for advanced hepatocellular carcinoma (HCC) under clinical practice. Recently, some randomized phase III trials have demonstrated the survival benefit of HAIC using FOLFOX regimen in advanced stage and neoadjuvant setting. A phase II trial, LEOPARD, was conducted to evaluate the efficacy and safety of lenvatinib in combination with HAIC using cisplatin, and revealed high objective response rate as assessed by the modified RECIST and RECIST were 64.7 (95 % CI 46.5-80.3) % and 45.7 (28.8-63.4) %, respectively. The median progression-free survival and overall survival were 6.3 months and 17.2 months, respectively. The combination therapy was well-tolerated and no new safety signals were identified. Afterward, we introduced the combination therapy to 26 patients with advanced HCC under clinical practice. Although immunotherapy consisting of atezolizumab and bevacizumab has currently been established as a standard of care for advanced HCC, lenvatinib and other molecular targeted agents as well as HAIC still has an important role to play as subsequent or alternative treatment in the long-term prognosis of patients. I will introduce the clinical trial results and our experience under clinical practice as described above, and hope to have an opportunity for discussing some issues of HAIC for patients with HCC.



Dr. Hiroaki Nagamatsu

Department of Gastroenterological Imaging and Interventional Oncology,
Juntendo University, Japan

Hepatic Arterial Infusion Chemotherapy for Long-term Prognosis in Patients with Advanced Hepatocellular Carcinoma Involving Vascular Invasion

Introduction: Hepatic arterial infusion chemotherapy (HAIC) is not listed in the guidelines in EASL and AASLD as a treatment option for advanced stage HCC. Recently, there are some papers showing the usefulness of hepatic arterial infusion chemotherapy for hepatocellular carcinoma. In 2021, New FP therapy (NFP) was reported to have a longer prognostic effect than sorafenib in advanced hepatocellular carcinoma with intrahepatic lesions. Here, we will introduce the NFP method and treatment results, and the treatment ideas for performing NFP at our hospital.

Objectives: We show the performance of NFP in our hospital.

Subjects: All patients received HAIC via the reservoir system. After chemolipiodolization, the patients were treated with CDDP 50 mg followed by 5-FU 1,250 mg via a balloon pump for 3 days (NFP). We perform this treatment schedule twice during hospitalization. Complications of the treatment with implantable reservoirs include gastrointestinal ulcers, port infections, and cerebral infarction. Currently, we perform 2 courses using the temporary indwelling catheter system via the left brachial artery, and then we remove the temporary reservoir. We repeat this treatment 3 to 5 times with an interval of about 1 month. There are no cases of ulcer formation, infection or cerebral infarction in our hospital. We aim for cancer free by performing conversion therapy when PR or CR is obtained by NFP. We performed NFP on 245 patients with advanced with vascular invasion.

Results: There is almost no deterioration liver function. A total of 169 patients (69%) responded to NFP therapy, of which 71 patients achieved cancer-free outcome. NFP alone, 34 patients; NFP +Hr, 30 patients; NFP+RFA, 3 patients; NFP +RT, 4 patients). Median OS (MST) after HAIC in all patients was 18 months. MST in patients who responded was 27 months, and in patients who achieved cancer-free outcome, it was extended to 60 months. The 5-year survival rate for patients who could undergo hepatectomy was 63%.

Conclusions: NFP can be performed safely in our institution. NFP has a high response rate and contributes to improve or maintain liver function by controlling PVTT. The main advantage of NFP is that if it responds, it becomes cancer free with conversion therapy and long-term survival is possible.



Dr. Shinsuke Uchikawa

The Department of Gastroenterology and Metabolism,
Hiroshima University Hospital, Hiroshima, Japan

The Outcome of the Patients Treated with First-line Systemic Therapy According to Functional Hepatic Reserve

Background: We assessed the outcome of first-line systemic therapy by functional hepatic reserve.

Methods: The patients (n=697) with unresectable Hepatocellular carcinoma who were treated with sorafenib or lenvatinib as first-line systemic therapy in our and affiliated hospitals from May 2007 to September 2021 were enrolled. They had Child-Pugh A or B liver function and ECOG Performance status was 0 or 1.

Results: The number of patients with Child-Pugh 5/6/7/8/9 were 270/132/63/29/8 in sorafenib group and 115/6/212/6/0 in lenvatinib group. In the patients treated with sorafenib, the MST of the patients with Child-Pugh 5, 6, 7 and 8/9 were 12.1, 9.0, 7.9 and 4.3 months. In the patients who received lenvatinib, the MST of the patients with Child-Pugh 5, 6, 7, and 8/9 were 33.4, 18.8, 8.7 and 7.2 months. In sorafenib group, the MST of Child-Pugh 8/9 patients was significantly shorter ($p<0.001$). In lenvatinib group, the MST of Child-Pugh 5 patients was significantly ($p<0.001$) longer. And there was no difference between patients with Child-Pugh 6 and 7 in both groups. The MST of patients with mALBI grade 1,2a,2b and 3 were 17.6, 12.5, 10.1 and 5.1 months. The MST of the patients with mALBI 3 was significantly shorter ($p<0.001$). Of the patients with Child-Pugh 7 liver function, 9.3 % had mALBI 3 liver function.

Conclusions: It was suggested that the patients with Child-Pugh 7 liver function excepting for mALBI 3 may be tolerated with molecular targeted agents.



Dr. Masahiko Sue

Department of Gastroenterology and Hepatology, Okayama University,
Faculty of Medicine, Dentistry and Pharmaceutical Sciences, Japan

The Survival Rate and the Recurrence Pattern of Hepatocellular Carcinoma After Orthotopic Liver Transplantation

Background: Orthotopic liver transplantation (OLT) is accepted as treatment for advanced stage hepatocellular carcinoma (HCC) with decompensated liver cirrhosis. In Japan, the 5-5-500 rule is adapted as inclusion criteria for OLT including deceased donor OLT. The validation of this criteria is under estimation. The objective of the present study was to investigate the real-world experience of OLT for HCC.

Methods: We recruited 104 HCC patients who received OLT. One of them showed slow growing HCC and could receive deceased donor OLT. The overall survival rate (OS) and progression free survival (PFS) were analyzed and investigated the recurred patients to characterize the recurrence.

Results: The patients were male dominant as 79 cases (76%), median age of 56-year-old. The background liver diseases were HCV 59 (57%), HBV 27 (26%), Alcohol 8 (7.7%), NASH 8 (7.7%), and the others 2 (1.9%). The 5 year OS were 79.2%, 10 year OS were 73.2%, The reason for death were liver failure 10, recurrence of HCC were 7 (two of them were complicated with cholangiocellular carcinoma). The recurrence of HCC were 10 cases, while three of them received curative treatment. The over Milan cases were 22 with 7 (32%) of them recurred. The over 5-5-500 cases were 12 with 5 (41.6%) of them recurred. Two of the five recurred cases received curative therapy.

Conclusion: The 5-5-500 criteria could broaden indication for HCC patients nearly 10 % of them. However, the recurrence rate was higher than the Milan criteria that should be managed as soon as possible.



Dr. Masatoshi Kudo

Department of Gastroenterology and Hepatology,
Kindai University Faculty of Medicine, Japan

Treatment of Intermediate-stage Hepatocellular Carcinoma

TACE has been the standard of care for intermediate-stage HCC until recently. However, this was based on evidence from a meta-analysis of 6 randomized controlled trials in which patients treated with TACE were compared with patients who did not receive therapy. Although 6 effective drugs are currently available, the data are insufficient to determine whether TACE or upfront systemic therapy followed by selective TACE, ablation, or resection after tumor necrosis and/or shrinkage has a greater overall survival (OS) benefit.

LEN-TACE sequential therapy was developed in proof-of-concept studies based on the marked prolongation of OS in patients with intermediate-stage HCC beyond the up-to-seven criteria. OS was 37.9 months with upfront lenvatinib with subsequent selective TACE versus 21.3 months with TACE alone, indicating that LEN-TACE sequential therapy significantly improved OS (HR, 0.48; 95% CI, 0.16–0.79; $p < 0.01$). PFS, ORR per mRECIST, and preservation of liver function were also favorable in the lenvatinib-treated group. In addition, 5 of 30 patients (17%) who received LEN-TACE sequential therapy achieved cancer-free drug-free status, indicating that this therapy can potentially achieve cure in patients with intermediate-stage HCC beyond the up-to-seven criteria. The results were reproduced in many other clinical studies, and LEN-TACE sequential therapy has become a well-established approach for TACE-unsuitable intermediate-stage HCC in Japan.

An ORR of 44% per RECIST v1.1 was achieved using Atezo/Bev combination therapy in patients with intermediate-stage HCC. This means that nearly one in two of these patients can potentially achieve curative conversion. Thus, in patients with intermediate-stage HCC receiving Atezo/Bev combination therapy, curative conversion must be implemented as soon as possible without hesitation upon achieving a sufficiently deep response instead of continuing the systemic therapy until progressive disease; real cure is not expected at this point. A pathological CR is rarely achieved with systemic treatment alone (e.g., lenvatinib or Atezo/Bev); residual viable cancer is often found when resection is performed in patients who seemed to achieve CR according to mRECIST. In such cases, recurrence is most likely to occur when the systemic therapy is discontinued; to prevent this, curative conversion must be implemented whenever possible, even if imaging findings indicate CR or deep response. Of note, in patients who undergo resection as conversion surgery, bevacizumab needs to be discontinued at least 4–6 weeks before the procedure to prevent bleeding event, whereas a 3-week interval is sufficient when performing ablation or curative TACE. In either case, ABC conversion can be achieved in approximately 20–30% of patients with intermediate-stage HCC.

WS17-2



Dr. Lai Wei

Hepatopancreatobiliary Center, Beijing Tsinghua Changgung Hospital
School of Clinical Medicine, Tsinghua University, Beijing, China

Treatment of Intermediate-stage Hepatocellular Carcinoma

To be announced.

**Dr. Takanori Ito**

Department of Gastroenterology and Hepatology, Nagoya University
Graduate School of Medicine, Nagoya, Japan

A Predictive Marker for Intermediate-Stage Hepatocellular Carcinoma Patients with Transarterial Chemoembolization Refractory

Background/Aims: Patients with intermediate-stage hepatocellular carcinoma (HCC) who are refractory to transarterial chemoembolization (TACE) have a poor prognosis. With the development of systemic treatment for unresectable HCC (uHCC), including immune checkpoint inhibitors, accurate diagnostic biomarkers to predict the state of unsuitable for TACE are needed. This study aimed to establish a simple predictive scoring system for determining TACE unsuitable status.

Methods: From 1998 to 2015, 196 patients with intermediate-stage uHCC with Child-Pugh A (score 5:6 = 108:88) who underwent TACE as the initial treatment were enrolled. Tumor burden in baseline (Milan criteria-out, up-to-7 in/out, and up to-11 in/out: 0–2 points) and modified albumin-bilirubin grade (mALBI) 1/2a or 2b (0–1 point) were added to determine the score for TACE unsuitable (CITRUS-MICAN(CM) score; low <2 and high ≥ 2). Additionally, a tumor marker (TM) score, in which alpha-fetoprotein (AFP) was ≥ 100 ng/mL, fucosylated AFP $\geq 10\%$, and des-gamma-carboxy prothrombin (DCP) ≥ 100 mAU/mL (each 1 point) (total 0, 1, or ≥ 2 points), was used for additionally evaluating tumor malignancy potential.

Results: Median age in the enrolled patients was 72 years and 85.2% were male. The average ALBI score was -2.44 (mALBI grade 1:2a:2b = 73:52:71). Median survival time (MST) was better for low compared to high CM score (42.0 vs. 26.4 months, $P = 0.002$). A 2-step evaluation with the combination of CM and TM scores showed an MST of 43.2 months for low CM/TM score 0/1 (rank-A) and 39.6 months for low CM/TM score ≥ 2 (rank-B2), while it was 46.8 months for high CM/TM score 0 (rank-B1), 28.8 months for high CM/TM score 1 (rank-B2), and 22.8 months for high CM/TM score ≥ 2 (rank-C). For rank-A cases ($n = 51$), MST was 43.2 months, while it was 46.8 months for rank-B1 ($n = 12$), 31.2 months for rank-B2 ($n = 82$), and 22.8 months for rank-C ($n = 51$) ($P = 0.001$).

Conclusion: The results of this study showed that rank-C indicates TACE unsuitable status. For rank-A patients, good response for improving prognosis with TACE can be expected, while the status of TACE refractory during the clinical course should be carefully assessed so as to anticipate the appropriate timing for switching to systemic therapy in patients with rank-B1 and -B2.



Dr. Sadahisa Ogasawara

Department of Gastroenterology, Graduate School of Medicine, Chiba University, Japan

Treatment for Intermediate Stage Hepatocellular Carcinoma Patients Consisting of Diverse Conditions

Intermediate stage hepatocellular carcinoma (HCC) is composed of the patients population without both macrovascular invasion (MVI) and extrahepatic metastasis (EHM), and with the exception of early stage HCC which is considered a common indication of curative treatments (surgical resection and local ablation). TACE is recommended as the standard treatment for intermediate stage HCC patients in guidelines worldwide, based on a meta-analysis comparing TACE and BSC demonstrated in the early 2000s. As sorafenib was established as a standard systemic therapy in the late 2000s, the new treatment strategy was proposed in which patients undergoing TACE with intermediate stage were conversion to sorafenib at a suitable point before MVI or EHM appeared, namely before progression to advanced stage (so called TACE refractory). In the late 2000s, with the emergence of novel systemic therapies with high response rates, a new treatment strategy was proposed to select systemic therapy prior to TACE in limited patients in intermediate stage HCC (so called TACE suitable). Currently, atezolizumab plus bevacizumab is positioned as the standard care in advanced HCC. In the future, other combined immunotherapies will become available in real world practice. In intermediate stage HCC, several phase 3 trials of the combination of TACE and immunotherapies are ongoing, and the results of these trials will be revealed soon. On the other hand, there is a patient population in intermediate stage HCC with excellent prognosis in which curative treatments is achieved with surgical resection or local ablation instead of TACE. Not a few patients are able to be converted to curative treatment as TACE has provided tumor control. As such, intermediate stage HCC is a diverse patient population with a variety of tumor conditions as well as a number of different treatment strategies to be selected. Several subclassifications for intermediate stage HCC, including “up to seven criteria”, have been proposed. However, none of them clearly contrast tumor conditions and recommended treatment. In this talk, I will discuss the latest concepts of treatment strategy and future prospects for the treatment of intermediate stage HCC.



Dr. Takeshi Hatanaka

Department of Gastroenterology, Gunma Saiseikai Maebashi Hospital,
Japan

Therapeutic Outcome of Atezolizumab and Bevacizumab Treatment for BCLC Intermediate Stage HCC Patients Classified as Beyond Up to Seven Criteria: A Multicenter Analysis

Background/Aim: Although systemic therapy is recommended for patients with multiple intermediate stage unresectable hepatocellular carcinoma (u-HCC) classified as beyond the up-to-7 criteria (UT-7 out/multiple) as a transcatheter arterial chemoembolization (TACE) unsuitable condition, few reports have examined the therapeutic efficacy of atezolizumab plus bevacizumab combination therapy (Atez/Bev) in such cases. This study aimed to elucidate the therapeutic response of Atez/Bev in u-HCC patients classified as UT-7 out/multiple.

Material/Methods: From September 2020 to September 2021, 95 u-HCC Japanese patients classified as UT-7 out/multiple/Child-Pugh A were enrolled from 21 institutions. Therapeutic response was retrospectively evaluated using Response Evaluation Criteria in Solid Tumors (RECIST), ver. 1.1 and modified RECIST (mRECIST).

Results: The median age was 76 years, with being male of 73 (76.8%) patients. The etiology of liver diseases was HCV, HBV, alcohol, and others in 25 (26.3%), 13 (13.7%), 20 (21.1%), and 37 (38.9%) patients, respectively. The Child-Pugh score was 5, and 6 points in 68 (71.6%), and 27 (28.4%) patients, respectively. The median albumin-bilirubin score was -2.56 (-2.25 to -2.76), and modified albumin-bilirubin grade (mALBI grade) was classified as 1, 2a, and 2b in 44 (46.3%), 22 (23.2%), and 29 (30.5%) patients, respectively. The maximum tumor size was 3.0 (2.2–5.0) cm and the tumor number was 2, 3, 4, 5, and ≥ 6 in 5 (5.3%), 6 (6.3%), 1 (1.1%), 4 (4.2%), and 79 (83.2%) patients, respectively. TNM stage was graded as II:III in 17 (17.9%), and 78 (82.1%) patients, respectively. Atez/Bev was given as first-line treatment to 52 (54.7%) patients. Objective response rate (ORR)/disease control rate (DCR) at six weeks of RECIST and mRECIST were 17.7%/84.7% and 42.5%/86.2%, respectively. Median PFS was 8.0 months, with median observation period of 6.0 months. The percentage of the Child-Pugh A/mALBI grade 1 or 2a at baseline, 3, 6, and 9 weeks, were 100%/69.4%, 89.8%/57.3%, 94.8%/65.3%, and 91.4%/60.0%, respectively. Among the development of adverse events (any-grade, $>10\%$) during the present observation period, general fatigue was most frequently observed ($n=22$, 23.2%), followed by urine protein ($n=20$, 21.1%), appetite loss ($n=19$, 20.0%), and hypertension ($n=13$, 13.7%).

Conclusion: Atez/Bev treatment showed favorable therapeutic response with less influence on hepatic function, suggesting it as a useful therapeutic option for patients with such condition.



Dr. Goki Suda

Hokkaido University Hospital, Japan

Analysis of Biomarkers Related Treatment Response for HCC

Background: Recent advances have dramatically changed the Hepatocellular carcinoma (HCC) treatment landscape. In addition to sorafenib, lenvatinib, regorafenib, cabozantinib, ramucirumab, and the VEGF inhibitor bevacizumab plus the PD1-1 inhibitor atezolizumab have been approved for systemic therapy in patients with unresectable HCC. While the biomarker related those treatment response for HCC have been not clarified well. Recently, it is reported that *CTNNB-1* mutations could cause resistance to immune checkpoint inhibitors. (1) We analyzed the EOB-MRI images as biomarkers for detecting *CTNNB-1* mutations in unresectable HCC, in addition, (2) we analyzed the biomarkers related early PD in bevacizumab plus atezolizumab for unresectable HCC.

Methods:

- (1) We analyzed the prevalence, characteristics, response to lenvatinib, and *CTNNB-1* mutation frequency in unresectable HCC with iso-high intensity in the hepatobiliary phase of EOB-MRI.
- (2) Patients with unresectable HCC who were treated with atezolizumab plus bevacizumab and had baseline preserved serum (n = 68) were screened. They were classified according to their PD six weeks after treatment initiation (early PD; n = 13). Of these, four patients each with and without early PD were selected for cytokine array and genetic analyses.

Results (1) In 52 patients with unresectable HCC treated with lenvatinib, the prevalence of iso-high intensity in the hepatobiliary phase of EOB-MRI was 13%. All patients had multiple HCCs, and 3 patients had multiple HCCs with iso-high intensity in the hepatobiliary phase of EOB-MRI. Lenvatinib response to progression-free survival and overall survival were similar between patients with or without iso-high intensity in the hepatobiliary phase of EOB-MRI. Of 7 patients (3 and 4 patients with unresectable HCC with or without iso-high intensity in the hepatobiliary phase of EOB-MRI) who underwent genetic analyses, 2 (67% 2/3) patients with HCC with iso-high intensity in the hepatobiliary phase of EOB-MRI had a *CTNNB-1* mutation, while all 4 patients with HCC without iso-high intensity in the hepatobiliary phase of EOB-MRI did not have *CTNNB-1* mutation.

(2) Cytokine array data revealed that baseline MIG (CXCL9), ENA-78, and RANTES differed substantially between patients with and without early PD. Subsequent analysis in the validation cohort revealed that baseline CXCL9 was significantly lower in patients with early PD than that in patients without early PD.

Conclusion: To optimized the therapeutic options for unresectable HCC, further analysis should be required.



Dr. Juanjuan Ye

Oncology Pathology, Department of Pathology and Host-Defense, Faculty of Medicine, Kagawa University, Japan

Phosphorylation of hTERT at Threonine 249 is a Novel Tumor Biomarker of Aggressive Cancer with Poor Prognosis in Multiple Organs

Recent evidence indicates that RNA-dependent RNA polymerase (RdRP) activity of human telomerase reverse transcriptase (hTERT) regulates expression of target genes and is directly involved in tumor formation in a telomere-independent manner. Non-canonical function of hTERT has been considered as a therapeutic target for cancer therapy. We have previously shown that hTERT phosphorylation at threonine 249 (p-hTERT), which promotes RdRP activity, is an indicator of an aggressive phenotype and poor prognosis in liver and pancreatic cancers, using two cohorts with small sample sizes with polyclonal p-hTERT antibody. To clarify the clinical relevance of p-hTERT, we developed a specific monoclonal antibody and determined the diagnostic and prognostic value of p-hTERT in cancer specimens using a large cohort. A monoclonal antibody for phosphorylated hTERT (p-hTERT) at threonine 249 was developed and validated. The antibody was used for the immunohistochemical staining of formalin-fixed, paraffin-embedded specimens from 1523 cases of lung, colon, stomach, pancreatic, liver, breast, and kidney cancers. We detected elevated p-hTERT expression levels in cases with a high mitotic activity, high pathological grade, and high nuclear pleomorphism. Elevated p-hTERT expression was an independent prognostic factor for lung, pancreatic, and liver cancers. Furthermore, p-hTERT expression was associated with immature and aggressive features, such as adenosquamous carcinoma (lung and pancreas), invasive type of cancer (lung), high serum alpha-fetoprotein level (liver), and triple-negative status (breast). In conclusion, RdRP activity indicated by p-hTERT expression predicts aggressive cancer phenotypes in various types of cancer. Thus, p-hTERT is a novel biomarker for the diagnosis of aggressive cancers with a poor prognosis.



Dr. Yuji Iimuro

Department of Surgery, Yamanashi Central Hospital, Yamanashi, Japan

Clinical Significance of Genetic Differentiation between MC and IM in Multinodular HCCs

Hepatocellular carcinoma (HCC) often appears as multifocal lesions at diagnosis. In this situation, differentiation between multicentric occurrence (MC) and intrahepatic metastasis (IM) is clinically important. However, such differentiation based on clinical images or pathological features is sometimes unclear, and genetic differentiation has recently been applied for multifocal HCCs. Meanwhile, genetic differentiation employing whole-genome sequencing (WGS) or whole-exome sequencing (WES) is time- and cost-consuming procedure, and is currently difficult to be applied in clinical practice. We aimed to elucidate significance of clinical use of targeted sequencing for this purpose.

We have performed targeted sequencing of HCC genome using in-house panel covering 72 significantly mutated genes employing next-generation sequencer in our institute, and have analyzed 163 HCC nodules from 90 patients who underwent surgical resection so far. Among 90 patients, we focused on 29 patients with multifocal nodules at surgery, and analyzed clinical significance of genetic differentiation between MC and IM, prospectively observing post-surgical prognosis.

Recurrence-free survival (RFS) and overall survival (OS) tended to be better in MC patients, while recurrence was often detected even in MC patients. In IM cases, recurrence after surgery relatively early, and tumor-free status can be hardly achieved after recurrence-treatment. Meanwhile, in MC patients, recurrence was relatively late and tumor-free status was achieved in many cases even after recurrence due to curative treatment. These results suggest that repeated curative treatment possibly improve OS in MC patients, while additional treatment such as immunotherapy and use of TKIs is required to improve prognosis after surgery in IM patients.

Genetic differentiation in multinodular HCCs using our in-house panel has important clinical significance, and possibly help decision-making in treatment.



Dr. Yutaka Yasui

Department of Gastroenterology, Musashino Red Cross Hospital, Japan

Change in α -fetoprotein Level as a Predictor of Response for Patients who Received Ramucirumab Therapy

Background: Ramucirumab has shown its effectiveness as a second-line agent after sorafenib in hepatocellular carcinoma (HCC) patients whose α -fetoprotein was ≥ 400 ng/mL. This study aims to elucidate ramucirumab efficacy in a real-world setting, including its predictors for the response.

Methods: Seventy-nine hepatocellular carcinoma (HCC) patients were retrospectively analyzed. Overall survival and progression-free survival were analyzed using the Kaplan-Meier method.

Results: Median overall survival (OS) of the total cohort was 7.5 months (m). Progression-free survival in the 2nd- and 3rd- or later line therapies was 3.2 m and 3.2 m, respectively. Nine patients achieved an AFP decrease of over 20% at week four, whereas AFP increased by less than 20% in 19 patients. Patients without over 20% increase in AFP at week 4 showed significantly longer PFS than those with over 20% increase (median PFS 3.8 vs. 2.3 months, $p = 0.02$). Among 63 patients who were followed up after ramucirumab, 35 (55.6%) received subsequent treatment. Patients who received subsequent treatment after radiological progression had longer survival than those who did not (10.2 months vs. 6.8 months, $p = 0.005$). Patients with baseline mALBI grade 1/2a had a significantly higher probability of subsequent treatment than patients with mALBI 2b/3 (83.3% vs. 44.4%, $p = 0.006$). On the contrary, development of ascites was observed significantly more frequent in modified albumin-bilirubin (mALBI) 2b/3 patients than in mALBI 1/2a patients (54.5% vs. 25.0%, $p = 0.03$).

Conclusions: Change in AFP was a valuable predictor for the response in patients who received ramucirumab therapy.



Dr. Yutaka Yasui

Department of Gastroenterology and Hepatology,
Musashino Red Cross Hospital, Japan

Peripheral Blood Immune Checkpoint Molecules in the Treatment of Advanced Hepatocellular Carcinoma

Background: Immune checkpoint molecules in peripheral blood have been reported as biomarkers for immune checkpoint inhibitors treatment for lung cancer or malignant melanoma. However, the significance of these molecules in the systemic therapy of hepatocellular carcinoma remains unclear.

Methods: We enrolled 66 patients who received atezolizumab plus bevacizumab combination therapy (Ate+Bev). We investigated soluble PD-1 (sPD-1), PD-L1 (sPD-L1), and CTLA-4 (sCTLA-4) at baseline and 3-6 weeks after starting the treatment. Correlation of continuous variables was analyzed using Spearman's rank correlation, and progression free survival (PFS) was analyzed using Kaplan-Meier method and COX proportional hazard model.

Results: The median age of patients was 73 years, 46 (79%) were male, and 31 (53%) received Ate+Bev as the first-line therapy. Baseline sPD-1, sPD-L1, and sCTLA-4 was not significantly different among treatment lines (first line vs. second or later line), etiology (viral vs. non-viral), and BCLC stage (stage B vs. stage C). Baseline immune checkpoint molecules did not correlate with radiological response. When we compared pre and post treatment values, sPD-1 significantly increased from baseline to post-treatment (from 274 to 356 pg/ml, $p<0.001$). while sPD-L1 significantly decreased. The 11 patients whose sPD-1 increased by 1.6-fold or greater between baseline and post treatment had significantly shorter PFS than those without increase (4.1 months vs. 7.1 months, $p=0.02$).

Conclusion: In Ate + Bev treated patients, pre-treatment sPD-1 was a predictive marker for discontinuation of adverse events, suggesting that pre- and post-treatment sPD-1 elevation may be a predictive biomarker for efficacy.



Dr. Kazuhiro Takahashi

Department of GI and HBP Surgery, Japan

Posthepatectomy Liver Failure can be Predicted by Combination of the ALBI Score and Liver Resection Percentage

Background: Posthepatectomy liver failure (PHLF) is a feared complication after partial hepatectomy and a major cause of postoperative death. The aim of this study was to make a system using the albumin-bilirubin (ALBI) score and liver resection percentage for predicting severe PHLF.

Methods: Between January 2002 and September 2021, 369 hepatocellular carcinoma (HCC) patients who underwent partial hepatectomy were enrolled. Medical-image analysis software was applied postoperatively to simulate hepatectomy. The hepatic resection percentage was calculated as follows: $\{\text{postoperatively reconstructed resected specimen volume (ml)} - \text{tumor volume (ml)}\} / \text{total functional liver volume (ml)} \times 100$. Multivariate analysis was performed to identify risk factors for PHLF grade B/C. A heatmap for predicting grade-B/C PHLF was created with the combination of ALBI score and liver resection percentage.

Results: Thirty-nine patients developed grade-B/C PHLF; 2 of these patients (5.1%) died. Multivariate analysis demonstrated high ALBI score and high liver resection percentage were independent predictors of PHLF {odds ratio (OR)=11.10; OR=1.07}. With a threshold of PHLF probability of 50% in the heatmap, partial hepatectomy was performed for 352 patients meeting our criteria (95.3%) and 333 patients meeting the Makuuchi criteria (90.2%). The positive predictive value and negative predictive value for PHLF were 65% and 92% for our system and 33% and 95% for Makuuchi criteria.

Conclusion: Our system increases the number of hepatectomy candidates and is useful for deciding the surgical indications and determining the upper limit of the liver resection percentage corresponding to each patient's liver function reserve, that could prevent PHLF and yield better postoperative outcomes.



Dr. Cosmas Rinaldi A Lesmana

Hepatobiliary Division, Department of Internal Medicine,
Dr. Cipto Mangunkusumo National General Hospital, Medical Faculty
Universitas Indonesia, Jakarta, Indonesia

Treatment Challenges in Intermediate Stage of HCC in the Era of Systemic Therapy


Hepatocellular carcinoma (HCC) is the most common type of liver cancer in all over the world. This cancer is considered challenging to be managed as most of patients come in the late stage. Hepatitis virus infection such as hepatitis B virus (HBV), and hepatitis C virus (HCV) are the main cause of HCC, even though non-alcoholic fatty liver disease (NAFLD) has become an emerging risk factor for HCC development. The treatment strategy would also depend on the late conditions other than liver cirrhosis based, such as portal vein thrombosis, large tumour size, low or normal AFP level, and the presence of extrahepatic metastases.

Based on Asia Pacific Association for The Study of The Liver (APASL) clinical practice guideline on HCC management, the treatment strategy has been classified based on the tumour number and size, vascular invasion, resectability, Child-Pugh (CP) score, and the presence of extrahepatic metastases. In our experience, most of HCC patients would be in unresectable condition, with large tumour size and/or multifocal condition. This condition is known as the intermediate stage, where loco-regional therapy is the main treatment of choice. However, in the multifocal HCC with some satellite nodules and the presence of vascular invasion, the treatment strategy might be changed in the first-line. Systemic treatment has been introduced first time by the first agent, sorafenib. Based on our multicentre experience, this drug has been associated with survival benefit. However, the treatment effectiveness has not reached the high satisfaction despite many side effects experienced by most of the patients where finally the drug dose need to be reduced or stopped.

Recently, new agent, Lenvatinib has been shown to be more effective in controlling the disease and reduce the cancer cells' progression. It works at more receptors which are associated with tumour angiogenesis, and tumour growth control. Based on clinical study, it showed longer median overall survival, longer time to progression, and significant tumour size reduction. However, the major drawback is the drug side effects which sometimes lead the patients to the worse clinical conditions.

Another new player known as immunotherapy has also become the treatment of choice in comparable with systemic treatment.

In conclusion, HCC treatment strategy in the intermediate stage has a big challenge in daily practice as it would need a comprehensive assessment before the right treatment decision.



Dr. Yusuke Kawamura

Hepatology, Toranomon Hospital, Japan

The Treatment Strategy for HCCs That had Equal to Intermediate-stage Intrahepatic Tumor Status with or without Extrahepatic Spread in the Era of Molecular-targeted Agents

BCLC intermediate-stage disease is quite heterogeneous, and can be further subclassified using the Up-to-7 criteria and Child-Pugh score. A recent report suggested that TACE is preferred for patients with tumors within the Up-to-7 criteria who have good liver function. Moreover, in patients who exceed the Up-to-7 criteria and have a high tumor burden, upfront molecularly targeted therapy followed by TACE has been reported to be a useful treatment option in various clinical studies and by the current AASLD guidelines. However, the importance of intrahepatic tumor control in patients with extrahepatic tumor spread has also been reported.

Since the recent introduction of lenvatinib, encouraging results have been reported regarding a highly synergic effect with TAC and high treatment efficacy in patients with oncologically aggressive HCC.

However, the efficacy of subsequent treatments (e.g., TACE) for various tumor and patient conditions (e.g., presence/absence of extrahepatic spread and liver function) after initiation of lenvatinib remains clear. Therefore, in this session, we evaluated the efficacy of subsequent treatment following lenvatinib-based therapy in patients with HCC with intrahepatic target nodules equal to the intermediate-stage with/without extrahepatic spread and various degrees of liver function as determined by modified albumin-bilirubin (mALBI) grade.



Dr. Tetsu Tomonari

Department of Gastroenterology and Oncology, Tokushima University
Graduate School of Biomedical Sciences, Tokushima, Japan


Treatment Strategy of Systemic drug Therapy for Intermediate Hepatocellular Carcinoma Aiming Curative Conversion Therapy

Aim: In recent years, systemic therapies with high response rates have been approved for treatment of unresectable hepatocellular carcinoma (u-HCC), and new treatment strategies aiming for cancer free have been proposed. In this study, we retrospectively analyzed u-HCC patients with lenvatinib (LEN) and atezolizumab plus bevacizumab (Atezo+Bev) who were eligible for conversion therapy aiming at curative treatment.

Methods: Two hundred one patients (LEN/Atezo+Bev 115/87) who received LEN or Atezo+Bev from March 2018 to February 2022, 13 patients (LEN/Atzo+Bev 7/6) who were eligible for curative conversion therapy were included. Antitumor efficacy was analyzed by RECIST ver1.1.

Result: The median age of LEN patients was 70 years, mALBI Grade 1/2a/2b 25/25/30, BCLC stage B/C 41/39, and the treatment line was 1st line/2nd line/3rd line 55/15/10. The objective response rate (ORR) was 35.6%, median progression-free survival (mPFS) was 7.5 months, and median survival (mOS) was 19.2 months. 7 patients were treated with conversion therapy, including hepatectomy/TAE+Ablation/TAE 2/4/1. Of these, 85.7% (6/7) were 1st line, 85.7% (6/7) were mALBI 1+2a, and 100% (7/7) were BCLC-B. The best anti-tumor effect was PR in all cases. There were 5 patients with recurrence, and the median recurrence-free survival was 308 days. 2 patients remained cancer-free with additional ablation, and 3 patients are on sequential treatment with multi-targeted therapy. The conversion therapy group had significantly better mOS ($p < 0.01$). The median age of Atezo+Bev patients was 71 years, mALBI Grade 1/2a/2b 23//31/33, BCLC stage A/B/C 4/29/54, and treatment line was 1st line/2nd line/3rd line/4th line/5th line 46/16/12/8, The ORR was 18.3% with a median PFS of 7.8 months. Six patients were eligible for conversion therapy, hepatectomy/ablation/TAE 1/3/2. 1st line cases were 83.3% (5/6), mALBI 1+2a 83.3% (5/6), BCLC-B 83.3% (5/6). All patients were PR cases with the best anti-tumor effect. There were no recurrent cases at the time of the abstract.

Discussion: Both LEN and Atezo+Bev, the transition rate to curative conversion therapy was high in 1st line and mALBI 1+2a cases, as well as in successful cases. The conversion rate was also high in BCLC-B cases. In BCLC-B cases, it is likely important to develop a treatment strategy aiming curative conversion therapy.



Dr. Teiji Kuzuya

Department of Gastroenterology and Hepatology,
Fujita Health University, Japan

Clinical Outcomes of Atezolizumab plus Bevacizumab in Patients with BCLC B Stage Hepatocellular Carcinoma

Objective: The purpose of this study was to evaluate the efficacy and safety of atezolizumab + bevacizumab (Atz/Bev) in patients with BCLC stage B hepatocellular carcinoma (HCC).

Methods: Of the 95 patients who started Atz/Bev at our institution between October 2020 and May 2022, 36 patients with BCLC stage B HCC were included. Median age; 76 years (48-90), male/female; 30/6, HBV/HCV/NBNC; 6/6/24, PS 0/1; 31/5, HCC size<5cm/>5cm; 25/11, HCC number <4/>4; 10/26, Child-Pugh score 5/6; 23/13, Atz/Bev treatment line (1st/2nd); 24/12, respectively. Contrast-enhanced CT images were taken at baseline and 6 weeks after Atz/Bev administration, and every 6-9 weeks thereafter.

Results: The objective response rate (ORR) at 6 weeks and best ORR were 27.8% and 47.2% for RECIST and 52.8% and 63.9% for modified RECIST (mRECIST), respectively. The disease control rate (DCR) at 6 weeks and best DCR were 88.8% and 88.8% for both RECIST and mRECIST, respectively. Median TTP by RECIST was 384 days and median OS was not reached. Three patients who achieved PR by RECIST received TACE and were Atz/Bev-free. There were 5 immune-related adverse events (2 PMR, 1 MG, 1 colitis, 1 dermatitis). Of 16 patients who were determined to have PD of Atz/Bev, 14 patients received sequential treatment.

Conclusions: Our results suggest that the combination of atezolizumab and bevacizumab may be safe and effective in the treatment of BCLC stage B HCC.



Dr. Kazuto Tajiri

The Third Department of Internal Medicine, Faculty of Medicine,
University of Toyama, Japan

The Role of MTAs for HCC with BCLC-B

Emergence of effective systemic chemotherapies such as molecular target agents (MTAs), immune checkpoint inhibitors and their combination has been changing the strategy of HCC treatment. In HCC with BCLC-B stage, systemic chemotherapies have been replacing TACE especially in patients with TACE-refractory or TACE-unsuitable. Anti-tumor effect of novel systemic therapies is comparable to that of the first TACE by professional radiologist. However anti-tumor effect of these systemic therapies is not still so high and specific adverse events are found, and therefore some consideration is required to acquire longer overall survival (OS) during the management. In sorafenib treatment, the first MTA approved for advanced HCC as the 1st line treatment, post-progression survival (PPS) is an important factor to achieve OS prolongation. In sorafenib treatment, higher correlation was found between PPS and OS as compared with that between progression-free survival (PFS) and OS ($r=0.834$, $p<0.001$ versus $r=0.546$, $p<0.001$, respectively) (Terashima T, et al. *Hepatol Res* 2016). Lenvatinib, the second MTA approved for advanced HCC as the 1st line, also showed higher correlation between PPS and OS as compared with that between PFS and OS ($r=0.872$, $p<0.001$ versus $r=0.504$, $p=0.009$, respectively) by 26 cohorts from 22 studies previously published. In atezolizumab plus bevacizumab treatment, also showed higher correlation between PPS and OS as compared with that between PFS and OS ($r=0.945$, $p<0.001$ versus $r=0.830$, $p=0.003$, respectively) although the difference is decreased. Thus PPS is essential during systemic therapies for HCC to achieve OS prolongation, and the importance could be increased in BCLC-B because longer OS is estimated. Real-world data in Japanese nationwide study showed that PPS in BCLC-B is longer than that in BCLC-C among patients treated with lenvatinib and the difference is evident in patients with MTA naïve and good hepatic reserve function (Tsuchiya K, et al. *Cancers* 2021). Our data with HCC patients treated with sorafenib or lenvatinib as the 1st line treatment at our institution also showed longer PPS is found in BCLC-B patients, and implied that sequential therapy with multiple MTAs contribute to the PPS prolongation. In earlier BCLC-B patients, more aggressive treatment with locoregional therapies might be preferable.

In conclusion, recent advancement of systemic therapies has been changing the strategy for HCC patients with BCLC-B. Accurate evaluation of intrahepatic tumor progression and maintenance of good hepatic reserve are required for optimal treatment in BCLC-B.



Dr. Takeshi Hatanaka

Department of Gastroenterology, Gunma Saiseikai Maebashi Hospital,
Japan
RELPEC/HCC48


Relationship between Early Bevacizumab Interruption and Clinical Outcome of Atezolizumab plus Bevacizumab for Advanced Hepatocellular Carcinoma

Background: The present study focused on relationship between early bevacizumab (Bev) interruption and the clinical outcome of atezolizumab plus bevacizumab (Atez/Bev).

Methods: This retrospective study included 239 advanced hepatocellular carcinoma (HCC) patients receiving Atez/Bev from September 2020 and June 2021 at 16 different institutions in Japan. We conducted a nine-week landmark analysis to investigate the association of Bev interruption due to adverse events with the therapeutic efficacy.

Results: The median age was 73.0 (68.0-80.0) years old, with 195 (81.6%) men. The objective response rate was significantly higher in patients without Bev interruption than in those with it (34.5% vs. 17.3%, $p=0.038$). The median progression-free survival (PFS) was 6.5 months (95% confidence interval [CI] 4.5-9.7) and 9.0 months (95% CI 7.1-not applicable) in patients with and without Bev interruption, respectively, with statistical significance ($p=0.021$). The 12-month overall survival (OS) rates in patients with and without Bev interruption were 49.4% (CI 27.7%-67.9%) and 82.2% (95% CI 70.3%-89.6%), respectively, showing a significant difference ($p=0.004$). The presence of Bev interruption was a significant factor associated with the PFS ($p=0.021$), and OS ($p=0.008$). A multivariate analysis showed that mALBI 2b ($p<0.001$) and later-line treatment ($p=0.018$) were unfavorable factors associated with Bev interruption. Liver injury, appetite loss, protein urea, and ascites or hepatic edema were more frequently found in patients with Bev interruption than in those without it.

Conclusions: Early Bev interruption was an unfavorable factor associated with the PFS and OS. The good liver function and treatment settings may be associated with maintaining Bev treatment.



Dr. Hirofumi Kawamoto

Department of Internal Medicine, Kawasaki Medical School General Medical Center, Japan

History and Advance in the Endoscopic Treatment of Malignant Hilar Biliary Strictures

It was sometimes difficult for even the endoscopists with great expertise to attain the effective endoscopic biliary decompression in the patients with malignant hilar biliary strictures, because most endoscopic devices limited these employments to the lower biliary diseases. Ineffective decompression can induce intractable cholangitis in these patients, which should be avoided especially in the surgical candidates. Therefore, careful strategy is mandatory to carry out this hard mission. In the former time, some endoscopist maintained that it was enough to decompress only the unilateral lobe, because most patients could survive with 30% or more liver volume where a enable catheter or a stent could be placed. However, as far as better prognosis can be attained in the patients whose liver volume is secured as much as possible, we have to keep in mind that bilateral lobe decompression is preferred especially in the patients who are not amenable to surgical therapy.

To achieve more favorable decompression, the knowledge of hilar anatomy, excellent devices, and competency are necessary. In recent years, many superb devices have been developed. The guidewires and metallic stent with thin introducer are good examples. Regarding the introducer that loads a metallic stent, its thickness has become 5.4 Fr from 7Fr for recent 20 years. These devices enable us to deploy multiple stents more easily. However, without the knowledge of hilar anatomy, wrong placement of biliary stent can happen, which induces intractable cholangitis or impossible deployment of a second stent. The hilar anatomy is not easy to learn at the beginning. But this knowledge is very useful to deploy three or more biliary stents precisely.

Transpapillary approach using duodenoscope is sometimes difficult in the treatment of the patients with malignant hilar biliary strictures even with recent novel devices. In such a case, interventional EUS is another optional approach. Employing this procedure, stents can be placed without passing through the tumor stenosis. Therefore, it can be employed in combination with transpapillary approach. Certainly, it can be employed solely. Due to this technical and device advancement, we can now manage this difficult morbidity more effectively than ever.



Dr. Daisuke Namima

Department of Gastroenterology & Neurology, Faculty of Medicine,
Kagawa University, Japan

Endoscopic Biliary Drainage for Long-term Follow-up for Unresectable Malignant Hilar Biliary Obstruction: Side-by-Side vs. Stent-in-Stent

Background: Endoscopic drainage of unresectable malignant hilar biliary obstruction (UMHBO) often requires either side-by-side (SBS) or stent-in-stent (SIS) techniques. In this study, we compared the short-term and long-term results of the SBS and SIS methods.

Methods: This was a single-center retrospective review of 28 patients who underwent endoscopic biliary an uncovered self-expanding metal stenting for unresectable MHBO from October 2014 to April 2022. Patients underwent endoscopic retrograde cholangiopancreatography and stenting using either the SBS or SIS technique.

Results: There were no significant differences between groups in technical and functional success (SBS vs. SIS, 95 vs. 86 %, respectively), mean procedure time (72 vs. 110 min), RBO rate (55 vs. 50 %), TRBO (143 vs. 136 days), early complications (24 vs. 14 %), late complications (10 vs. 14 %). There were no significant differences in reintervention success rates (98 vs. 86 %), but the mean procedure time for reintervention was significantly shorter for SBS than for SIS (31 vs. 58 min; $p < 0.001$).

Conclusions: Our results showed no significant difference in clinical outcomes such as success rate or RBO between SBS and SIS technique for UMHBO. However, SBS technique may be superior to the SIS technique in terms of reintervention.



Dr. Sho Takahashi

Department of Gastroenterology, Graduate School of Medicine, Juntendo University, Tokyo, Japan

Retrospective Evaluation of Slim Fully Covered Self-expandable Metallic Stent for Unresectable Malignant Hilar Biliary Obstruction

Background: The optimal approach to management of malignant hilar biliary obstruction (MHBO) is unclear. A slim fully covered self-expandable metallic stent (SFCSEMS), which is exchangeable, easy to insert, and facilitates re-intervention, was retrospectively evaluated. The most common adverse event (AE) is segmental cholangitis caused by obstruction of the biliary branch.

Methods: Unresectable MHBO patients received a 6-mm-diameter SFCSEMS in a side-by-side fashion from December 2016 to September 2021 in Juntendo University Hospital. The clinical results were retrospectively evaluated.

Results: We evaluated 54 patients with unresectable MHBO (cholangiocarcinoma, $n = 18$; gallbladder cancer, $n = 11$; pancreatic cancer, $n = 8$; hepatocellular carcinoma, $n = 2$; and metastatic cancer, $n = 15$); the Bismuth classifications were II ($n = 11$), III ($n = 17$), and IV ($n = 26$). The technical and clinical success rate was 100% and 92.5%, respectively. The mean procedure time was 76.3 minutes, and two ($n = 35$) or three ($n = 19$) SFCSEMS were placed. The incidence of recurrent biliary obstruction (RBO) was 35.1% (sludge, $n = 9$; overgrowth, $n = 8$; migration, $n = 2$) and the time to RBO (TRBO) was 181 days. The rate of AEs other than RBO was 11.1% (4 mild-pancreatitis, 1 segmental cholangitis, and 1 cholecystitis). Removal was successful in 19 cases and the second stents included SFCSEMS ($n = 6$), plastic stent (PS; $n = 11$), other SEMS ($n = 1$), and an endoscopic ultrasound-guided hepaticogastrostomy (EUS-HGS) ($n = 1$). SFCSEMS as a second stent showed a significantly lower RBO (16.7% vs. 81.8%, $p = 0.0364$) and longer TRBO (undefined vs. 86 days; $p = 0.0617$) than PS.

Conclusions: Endoscopic placement of SFCSEMS for unresectable MHBO was effective and feasible, and its ability to be exchanged reduced the number of endoscopic procedures.



Dr. Kosaku Morimoto

Department of Gastroenterology,
Okayama University Hospital, Japan

Optimal Biliary Drainage for Unresectable Malignant Hilar Biliary Obstruction Based on Measuring Liver Volume using 3D Image Analysis System

Background: Drainage >50% of the total liver volume (TLV) contributed to the improvement of prognosis in patients with high-grade malignant hilar biliary obstruction (HMBO). Recently, 3D image analysis system on CT has been used, and accurate liver volume can be calculated.

Methods: Among 127 patients who underwent endoscopic drainage with self-expandable metallic stents (SEMSs) for unresectable MHBO at Okayama University Hospital from April 2003 to December 2020, 90 patients who received chemotherapy after SEMS placement were retrospectively reviewed. The median age was 70 years, and 56% were male. Bismuth classification was type I:3, II:11, IIIa:10, IIIb:4, and IV:62. Total liver volume (TLV) and drained liver volume (DLV) were measured using SYNAPSE VINCENT (Fujifilm). The primary endpoint was to evaluate the optimal DLV for prolonging survival.

Results: The median TLV was 1121 mL (range:673-2032), and the median DLV was 86% (range:50-100). SEMSs placement were two: 42, three: 40, and four: 8, and bilateral drainage was performed in 78% of the patients. When analyzing the survival times by DLV, the median survival times were 118 days in 50-69%, 286 days in 70-79% and 450 days in over 80%, respectively, and over 80% DLV group had a significantly longer survival time than the other groups (log-rank, $p<0.01$). In multivariate analysis for survival factors, over 80% drainage was associated with prolonged survival (HR:0.39, 95%CI:0.17-0.89, $p=0.03$).

Conclusion: In HMBO patients who received chemotherapy, over 80% DLV was contributed to long survival.



Dr. Rintaro Fukuda

Department of Gastroenterology,
Japanese Red Cross Medical Center, Tokyo, Japan.

A Comparative Study of Bilateral Stenting for Hilar Malignant Biliary Obstruction: SIS above the Papilla vs SBS across the Papilla

Background and Aims: Although endoscopic transpapillary drainage for unresectable hilar malignant biliary obstruction (HMBO) is a well-established procedure, it is still controversial whether partially stent-in-stent (pSIS) method and side-by-side (SBS) method is superior to one another. A novel uncovered metallic stent (UMS) with a 6-Fr tapered delivery system was recently developed. We aimed to compare the pSIS method using slim-delivery UMSs (Slim group), conventional UMSs (Conventional group), and the SBS across the papilla method (SBS group).

Methods: Clinical outcomes of multiple UMSs placement for unresectable HMBO were retrospectively studied. The endpoints were technical/clinical success rates, stenting time (from guidewire placement to completion of stent deployment), early adverse events (AEs), recurrent biliary obstruction (RBO), and time to RBO (TRBO).

Results: A total of 111 patients with HMBO (24 SBS and 87 pSIS [56 Conventional and 31 Slim groups]) were enrolled. Technical/clinical success rates were 96%/96% in SBS, 100%/91% in Conventional, and 97%/97% in Slim groups, respectively. Early AE rates were higher in SBS group (46%) than Conventional/Slim groups (21%/10%) ($P=0.007$). RBO rates were not significantly different between the three groups (SBS [46%], Conventional [47%], and Slim [29%] groups [$P=0.31$]). Median TRBO were 284 days in SBS, 169 days in Conventional, and 259 days in Slim groups ($P=0.66$), respectively. In a multivariate analysis, Slim group was associated with shorter stenting time (regression coefficient estimates: -11.4 , $P=0.04$).

Conclusions: In endoscopic transpapillary drainage using UMSs, early AE rates were higher in SBS group and pSIS using slim-delivery UMSs allowed shorter stenting time with comparable TRBO.



Dr. Norifumi Kawada

Professor of Medicine Chairman, Department of Hepatology Graduate School of Medicine Osaka Metropolitan University, Japan

Recent Advances in the Mechanism of Liver Fibrosis

Molecular analysis of hepatic fibrogenesis along chronic liver disease (CLD) caused by hepatitis virus infection, non-alcoholic steatohepatitis, etc. has progressed with regard to both fibrosis progression and regression. Liver fibrosis is basically controlled by the activation of hepatic stellate cells (HSCs), which undergo differentiation into myofibroblast (MFB)-like cells under the stimulation with transforming growth factor- β in an autocrine loop or by a variety of peptide mediators and reactive oxygen species generated from damaged hepatocytes, non-parenchymal cells and/or environmental conditions. Hepatic MFBs can originate not only from HSCs but also from portal fibroblasts, mesothelial cells and mesenchymal cells recruited from bone-marrow or, possibly, by cholangiocytes through epithelial-mesenchymal transition, and are the source of type I and III collagens deposited in fibrotic septum. Fate of activated MFBs determines the regression of liver fibrosis after the eradication of pathogens: it is generally accepted that regression of liver fibrosis happens clinically in patients who achieve a sustained viral response after the eradication of HCV by direct-acting antiviral agents (DAAs) or whose HBV viral level is well controlled by using nucleot(s)ide analogues. Fate of activated MFBs include apoptosis, senescence, and inactivation. Recently, we demonstrated the promising ability of globins, such as cytoglobin and neuroglobin, in inducing the inactivation of HSCs by radical scavenging functions and by inducing interferon signaling. Taken together, the scenario in a progression and regression of CLD may rely on a long-standing story of activation and de-activation of HSCs/MFBs in response to hepato-toxins and inflammatory reactions among non-parenchymal cells.



Dr. Yoshio Tokumoto

Department Community Medicine,
Ehime University Graduate School of Medicine, Japan

Impact on Portal Hypertension in Patients with Cirrhosis Associated with Hepatitis C after Achieving a Sustained Virologic Response

Aim: We aimed to investigate the impact of sustained virologic response (SVR) by direct-acting antivirals (DAAs) on the esophagogastric varices (EGV) in Japanese hepatitis C patients with cirrhosis.

Methods: We included 328 patients (54% male, mean age 69.0 years) with cirrhosis after achieving SVR by DAAs, who underwent endoscopic examinations both prior and after antiviral therapy. EGV worsening was defined as an increase in varices form or varices bleeding. EGV improvement was defined as a decrease or a disappearance in varices form.

Results: During the median observation period of 30 months, EGV worsening was seen in 70 cases. The history of ascites retention (hazard ratio (HR) = 1.86; 95% CI 1.26-2.75), serum albumin before DAA therapy (HR = 0.43; 95% CI 0.24-0.78), and MELD score before DAA therapy (HR = 1.11; 95% CI 1.02-1.20), as independent factors that contributed to the EGV worsening. EGV was improvement among patients with EGV prior DAA therapy was seen in 24 cases. Body mass index (BMI) (HR=0.85; 95%CI 0.74-0.98), and platelet counts ($\times 10^4/\mu\text{L}$) (HR=1.07; 95%CI 1.01-1.14) as independent factors that contributed to EGV improvement. Using these predictors (worsening factor: -1 point, improvement factor: +1 point), new scoring system (total: -3 to 2 points) for predicting EGV findings after SVR was established. In worsening group (≤ -2 points), 1- and 2-year cumulative EGV worsening rate was 59.8% and 69.9%. In improvement group (2 points), 1-year cumulative rate of EGV improvement was 30.5%.

Conclusion: Portal hypertension and liver function prior DAA treatment may influence whether EGV worsening or improvement after achieving SVR.



Dr. Yohei Shirakami

Department, Institution Department of Gastroenterology, Gifu University
Graduate School of Medicine, Japan

Steatotic and Fibrotic Liver and Related Conditions in Senescence-accelerated Mice

In recent years, the loss of skeletal muscle mass, known as sarcopenia, has attracted significant attention. Liver diseases, including non-alcoholic steatohepatitis (NASH), are associated with skeletal muscle atrophy; however, the mechanism behind their association has not been fully elucidated. In the present study, the effects of senescence and NASH on the skeletal muscle and the interaction between the liver and muscle were investigated using a diet-induced NASH model in senescence-accelerated mice (SAM). A total of four groups of SAM and its control mice were fed either an NASH-inducing or control diet. In the SAM/NASH group, the histopathology of NASH, including steatosis and fibrosis, was significant and skeletal muscles were also markedly atrophied. The expression of the ubiquitin ligases in the muscle was significantly increased with muscle atrophy, while that of *Tnfa* was not significantly different. In contrast, the hepatic *Tnfa* expression and serum TNF-alpha levels were significantly increased in the SAM/NASH group. These results suggest that steatotic and fibrotic liver-derived TNF-alpha promotes muscle atrophy, which is exacerbated with aging. The findings of this study revealed an aspect of liver-muscle interaction and might lead to developing treatments for sarcopenia associated with liver diseases.



Dr. Atsunori Tsuchiya

Division of Gastroenterology and Hepatology, Niigata University, Japan

Therapies Using Mesenchymal Stem Cell and Their Small Extracellular Vesicle for Liver Cirrhosis

Background: Cirrhosis is a disease in which the ability to improve fibrosis and hepatocytes regeneration gradually declines as the disease progresses. There is currently no treatment other than liver transplantation that effectively improves these conditions. However, basic studies have revealed a mechanism of fibrosis improvement centered on macrophages. This article introduces the basic clinical studies we have conducted to improve fibrosis in cirrhosis.

Basic Study: We found that mesenchymal stem cells (MSCs) migrate to the lungs and act as conducting cells. MSCs induce macrophages that act as working cells in the liver into anti-inflammatory and tissue-repairing macrophages to produce tissue repair in liver cirrhosis. We also observed that exosomes of MSCs play an important role in this process. In particular, we found that small extracellular vesicles (sEVs) produced a high therapeutic effect similar to that of MSCs after the latter's stimulation with Interferon-gamma.

Clinical and Translational Study: We are currently proceeding a Phase II trial of adipose tissue-derived allogeneic MSCs for hepatitis C virus (HCV) and Non-Alcoholic SteatoHepatitis (NASH)-related decompensated cirrhosis (Phase II), and HCV, hepatitis B virus, NASH- and Alcohol-related compensated cirrhosis (Phase II). We are now accumulating results in cell therapy. For sEV therapy, we are observing sEVs' in-vivo dynamics, developing mass culture and mass collection methods, and developing mass protein concentration techniques in sEVs for clinical development.

Conclusions: Based on our understanding of the mechanisms of cirrhosis amelioration, we are developing and will continue to develop next-generation therapies for cirrhosis.



Dr. Namiki Izumi

Gastroenterology and Hepatology, Musashino Red Cross Hospital,
Japan

Treatment of Early Stage Hepatocellular Carcinoma

Early stage hepatocellular carcinoma (HCC) is defined as nodule number of 3 or less and size with 3cm or smaller, based on BCLC staging and Japan Society of Hepatology (JSH) guideline. When the patients have good liver function of Child-Pugh A or B, curative treatment such as surgical resection or ablation including radiofrequency ablation (RFA) or microwave coagulation (MCT) should be chosen as the first line treatment. However, which treatment of surgical resection or ablation should be chosen has been discussed for a long time.

In Japan, nationwide randomized controlled trial to compare the overall survival (OS) and the recurrence-free survival (RFA) between the patients treated with surgical resection and RFA (SURF trial) with early stage of HCC having 3 or less numbers and 3cm or smaller HCC nodules with Child-Pugh A or B was carried out since 2011, including more than 100 centers from all over Japan. The patients who agreed to RCT were randomly assigned either to be treated by surgical resection of RFA, and 5 year OS and 3 year RFA were analyzed. The patients who did not agreed to RCT were included in a parallel cohort study.

In RCT, 308 patients were included, and RFS was analyzed in 2019. 3 year RFA was similar between the patients treated be surgical resection and RFA. Moreover, 5 year OS was also quite similar between the two groups in SURF trial. From these results, surgical resection and ablation are equally recommended to the patients with early stage of HCC in JSH guideline.

In Japan, ablation including RFA and MCT should be done until safety margin of 5mm all around the original HCC nodules, evaluated by contrast-enhanced CT scan. For the accurate puncture of RFA or MCT needle, we use virtual ultrasonography using contrast-enhanced CT scan or MRI. We also use contrast-enhanced ultrasonography to detect the viable region of HCC nodules. Using these techniques, we usually perform complete ablation of the HCC nodules in Japan.



Dr. Hironori Ochi

Center for Liver-Biliary-Pancreatic Disease,
Matsuyama Red Cross Hospital, Ehime, Japan

Examination of Prognosis by Age in HCC in Early Stage-significance of RFA by Age

Aim: RFA is a minimally invasive treatment for HCC. Therefore, it can be applied to patients of a wide range of ages. The purpose of this study was to clarify the significance of treatment with RFA in HCC at early stage by age, based on prognosis and cause of death by age.

Method: The study included 1086 in early stage cases out of 1212 cases treated with RFA for initial HCCs from January 2006 to December 2020 at two institutions. We divided the 1086 cases into the following groups, <70 years old (Group A, n=486), 70 to 80 years old (Group B, n=398), ≥80 years old (Group C, n=196). In addition, factors related to survival prognosis in each of the three groups were analyzed by Cox proportional hazards analysis.

Result: There were no significant differences in ALBI score, tumor diameter, number of tumors, AFP between the three groups. The proportion of Group C patients with a performance status (PS) of 3 or higher (9.3%) was significantly higher than that of Group A (1.0%) and B (3.5%) ($p<0.001$).

The median survival time (months) for Groups A, B, and C were 115.1, 96.9, and 65.5, respectively, all significantly different in each group (log-rank test, $p<0.05$). The proportion of deaths due to liver disease was 71.6%, 64.2%, and 30.6% in Groups A, B, and C, respectively, while non-liver disease accounted for 28.4%, 35.8%, and 69.4%, with non-liver disease significantly more common in Group C ($p<0.001$).

Factors related to survival deterioration are were mALBI grade2b or 3 ($p<0.001$, HR 2.69) in Group A, mALBI grade2b or 3 ($p=0.009$, HR 3.07) in Group B, $PS\geq 3$ ($p=0.019$, HR2.46) and mALBI grade2b or 3 ($p=0.009$, HR1.87) in Group C.

Conclusion: In the Early stage, the median survival of untreated HCC has been reported to be 13.4 months (Clinical Gastroenterology and Hepatology 2017;15:273-281). Based on this, the results of this study suggest that there is a prognostic prolongation effect in all age groups. However, in patients older than 80 years, the most common cause of death is death from non-liver disease, and PS is also a prognostic factor, so the indication for treatment should be determined based on background other than liver.



Dr. Hideyuki Tamai

Department of Hepatology, Wakayama Rosai Hospital, Japan

Microwave Thermosphere Ablation for Early-stage Hepatocellular Carcinoma

The current standard care for early-stage hepatocellular carcinoma (HCC) is percutaneous radiofrequency ablation (RFA). However, the local tumor progression (LTP) after RFA depends on the tumor location. For example, as enough safe margin cannot be obtained in RFA for perivascular or subcapsular tumor, RFA for these tumors has a high risk of incomplete ablation. Although microwave ablation (MWA) can generate higher temperature than RFA, meta-analyses comparing MWA versus RFA until 2016 demonstrated that the local tumor progression rate was similar between MWA and RFA. In July 2017, the next-generation MWA system using thermosphere technology (Emprint™, Covidien, Boulder, CO, USA), which has overcome the disadvantage of conventional MWA such as small and teardrop shaped ablation zone, was approved for use in Japan. This microwave thermosphere ablation (MTA) system can produce a spherical and larger ablation zone in shorter time than RFA. In our hospital, MTA was introduced in December 2017, and RFA was fully replaced by MTA from September 2018. The retrospective cohort study was conducted to elucidate whether MTA could safely improve outcome compared to RFA. Our study analyzed 513 patients with 630 HCCs (≤ 3 cm) who were performed by percutaneous RFA (174 patients, 214 HCCs) or MTA (339 patients, 416 HCCs) between January 2016 and March 2020. As a result, median ablation time was significantly shorter for MTA (240 seconds) than for RFA (721 seconds; $P < 0.001$). A significant difference in 3-year LTP rate was evident between groups (RFA vs. MTA, 3-year, 22% vs. 8%, $P < 0.001$). In comparison of LTP curves between RFA and MTA in subcapsular HCCs, a significant difference was evident between groups (RFA vs. MTA, 3-year, 30% vs. 7%, $P < 0.001$). However, comparing LTP rate between RFA and MTA for perivascular HCCs, no significant difference was evident between groups (RFA vs. MTA, 3-year, 23% vs. 13%, $P = 0.269$). Multivariable analysis revealed ablation procedure and tumor diameter as independent factors contributing to local tumor progression (MTA; $P < 0.001$; hazard ratio, 0.565; 95% confidence interval, 0.437–0.731). In patients with primary HCC, a significant difference in overall survival was evident (RFA vs. MTA, 3-year, 77% vs. 95%, $P = 0.029$). Ablation procedure and Child-Pugh score were independent factors contributing to survival. The total complication rate was significantly lower for MTA (8%) than for RFA (14%, $P < 0.05$), particularly for bile duct injury (3% vs. 9%, respectively; $P < 0.05$). In conclusions, MTA for early-stage HCC could provide safer, more curative treatment in a shorter ablation time.



Dr. Junichi Arita

Hepato-Biliary-Pancreatic Surgery Division, The University of Tokyo,
Tokyo, Japan

Prognostic Impact of Postoperative Complications in Patients Undergoing Hepatic Resection for Hepatocellular Carcinoma

Background: Prognostic impact of occurrence of postoperative complication has been reported in patients with various gastrointestinal malignancies.

Methods: A retrospective study using 1009 consecutive patients undergoing initial hepatic resection of histologically diagnosed hepatocellular carcinoma between 2002 and 2021. Patients undergoing liver transplantation were excluded from the study.

Results: The mean was 66.4 years, and 793 patients were male. HBs-Ag and HCV-Ab was positive in 218 and 433 patients, respectively. ICG-R15 was -10% in 357 patients, 10-20% in 402 patients, 20-30% in 132 patients, and 30%- in 57 patients. The tumor number was multiple in 317 patients. Major hepatectomy was performed in 230 patients. In whole patients, the 5-year and 10-year OS rate was 65.4% and 46.9%, respectively. Postoperative complication of Clavien-Dindo grade (C-D) 2, 3, 4, and 5 was noted in 250, 91, 7, and 1 patients, respectively. C-D grade 3 or higher and C-D grade 2 or higher were associated with worse OS; 5-year OS rate of positive vs. negative were 53.1% vs. 66.6% ($P<0.001$), and 57.9% vs. 69.4% ($P<0.001$), respectively. Multivariate analysis of OS using Cox regression model identified C-D grade 3 or higher (HR=1.85, 95%CI 1.23-2.76, $P=0.003$), gender, portal hypertension, serum DCP, BMI, non-curative resection, blood loss, macroscopic portal venous invasion, and tumor differentiation as independent prognostic factors. Occurrence of bile leakage was not associated with OS.

Conclusion: The occurrence of postoperative complications after resection of hepatocellular carcinoma is associated with a poor long-term outcomes.



Dr. Makoto Moriyama

The Department of Gastroenterology,
School of Medicine, University of Tokyo, Tokyo, Japan


The Role of Repeated RFA in the Long-Term Survival of Hepatocellular Carcinoma

Background: Considering that most patients with hepatocellular carcinoma (HCC) experience tumor recurrence even after radiological complete ablation, repeated ablation for recurrent tumors has an essential role in the long-term survival of HCC.

Methods: The current study enrolled 1,613 patients (age 69.0 ± 9.0 years, male/female 1007/606, HBV/HCV/non-B non-C 177/1159/277) with treatment-naive HCC who underwent radiofrequency ablation (RFA) with a complete radiological response at our department between 1999 and 2015. On each tumor recurrence, treatment modality and presence or absence of radiological complete response were investigated. The Kaplan-Meier method was used to estimate the duration from the n th recurrence to the $n+1$ th recurrence, where residual tumor after treatment was censored.

Results: During the observation period, 1st, 2nd, 3rd, and 4th recurrences were observed in 1179, 854, 596, and 392 patients, respectively. Each recurrence was curatively treated with RFA or microwave coagulation in 88.5%, 85.6%, 80.7%, and 83.7% of patients, respectively. 737 patients (45.7%) developed locally-uncontrollable recurrence. The median time to failure to local control was 6.8 years, with a median of 12.8, 6.22, and 7.26 years for HBV, HCV, and NBNC patients, respectively. The median time to 1st, 2nd, 3rd, and 4th recurrence was 1.85, 1.09, 0.8 and 0.79 years. The 3-, 5-, and 10-year overall survival rates were 82.1%, 63.9%, and 31.2%, with significantly better survival rates ($p < 0.05$) for HBV patients.

Conclusions: Most patients who received RFA for initial treatment achieved long-term survival as a result of repeated treatment with complete response.



Dr. Tsuyoshi Takeda

Cancer Institute Hospital of Japanese Foundation for Cancer Research,
Japan

A Review of Recent Advances in Chemotherapy for Intrahepatic Cholangiocarcinoma

Biliary tract cancer (BTC) is an aggressive and heterogeneous group of malignancies including intrahepatic cholangiocarcinoma (ICC), extrahepatic cholangiocarcinoma, gallbladder cancer, and ampullary cancer. ICC is the second most common primary liver cancer that arises from the biliary tract epithelium with a rising incidence in recent years. While surgical resection is considered the only curative treatment, a majority of patients are diagnosed at an advanced stage precluding surgery. Several randomized controlled trials have recently evaluated the role of adjuvant chemotherapy in BTC with positive results in some studies. Systemic chemotherapy is the mainstay for the treatment of advanced cases and recurrent cases. Although gemcitabine plus cisplatin combination remains the standard first-line chemotherapy regimen worldwide, gemcitabine, cisplatin plus S1 triplet or gemcitabine plus S1 combination is also considered alternative first-line chemotherapy regimens in Japan. FOLFOX was recently shown to increase the overall survival of patients who progressed after gemcitabine plus cisplatin combination, albeit with limited benefit.

Recent advances in technology including next generation sequencing have enabled better understanding of the genomic landscape of BTC and highlighted the genetic differences between ICC and other types of BTC. Novel therapeutic targets have been identified especially for ICC, including FGFR2 fusions, IDH1/2 mutations, and BRAF mutations. Despite the low frequency of each genetic alteration, targeted therapy directed against these actionable mutations have shown promising results in recent clinical trials. Immunotherapy is another promising treatment under investigation. Although single-agent immune checkpoint inhibitors showed limited efficacy in previous clinical trials, the addition of the anti-PD-L1 agent durvalumab to gemcitabine plus cisplatin combination showed a significant survival benefit. Other types of immune checkpoint inhibitors in combination with conventional cytotoxic chemotherapy is under investigation in multiple clinical trials.

In this review we provide an overview of recent advances in chemotherapy for BTC with a focus on ICC.



Dr. Hiroyuki Okuyama

Department of Medical Oncology, Kagawa University Hospital, Japan

Precision Medicine for Intrahepatic Cholangiocarcinoma

Intrahepatic cholangiocarcinoma (ICC) is a highly lethal hepatobiliary neoplasm. If the tumors cannot be resected surgically, chemotherapy should be considered. However, few drugs are effective for ICC, and the efficacy of chemotherapy is limited. Standard first-line chemotherapy is gemcitabine plus cisplatin, but the median overall survival was only 11.7 months.

In recent years, many driver genes have been identified and a lot of molecular targeted drugs have been developed. Moreover, next-generation sequencing (NGS) technology have enabled to analyze a lot of gene alterations of cancer cell at once quickly and inexpensively. These advances in technology and drugs have improved the prognosis of cancer patients.

For example, a large number of driver genes in non-small cell lung cancer have been identified and more than 10 different drugs are used according to the gene profile.

In Japan, two comprehensive genome profiling (CGP) tests (OncoGuide™ NCC Oncopanel System and FoundationOne® CDx) were approved by the Ministry of Health, Labor and Welfare in Japan in 2019, and these developments are promoting precision medicine for cancer. Furthermore, CGP testing using blood samples (FoundationOne® Liquid CDx) was approved in 2021, and we are now able to provide precision medicine to patients with cancer for whom tissue samples cannot be obtained.

Although effective molecular-target agent had not been developed for ICC for long time, pembrolizumab for microsatellite instability high solid tumor in 2018, and pemigatinib, FGFR inhibitor was approved for FGFR2 fusion-positive cholangiocarcinoma last year in Japan. In our institution, we experienced cases in which ICC with these genetic alterations were successfully treated with molecular-targeted drugs. Other several gene alterations, such as IDH1, BRCA1/2, BRAF and ERBB2, have been identified as potential therapeutic targets in biliary tract cancers, including ICC, and some clinical trials are now performed. Although many new drugs are expected to improve patient outcomes in the future, there are many problems which should be solved. We present the current status of precision medicine for ICC, including our own experience.



Dr. Shunichi Ariizumi

Department of Surgery, Institute of Gastroenterology, Tokyo Women's Medical University, Japan


What is Best Indication for Surgery of Intrahepatic Cholangiocarcinoma?

Background/Aim: Intrahepatic cholangiocarcinoma (ICC) is a fatal disease because of frequent recurrence and mortality despite curative surgery. The optimal indication of hepatectomy and adjuvant therapy after hepatectomy for ICC has not been evaluated in detail.

Materials and Methods: We retrospectively studied 224 patients with ICC who underwent hepatectomy between 2000 and 2019. Prognostic factors for overall survival (OS) and recurrence-free survival (RFS) were evaluated by univariate and multivariate analysis. A total of 127 patients were treated with adjuvant therapy (62 patients with chemotherapy and 65 patients with immunotherapy) after hepatectomy, and 97 patients were treated with hepatectomy alone.

Results: Intrahepatic metastasis (IM), lymph node metastasis (LNM) of ICC, and adjuvant chemotherapy were significant prognostic factors for OS and RFS on multivariate analysis. Adjuvant immunotherapy was significant prognostic factor for OS on multivariate analysis. In 127 patients with neither IM nor LNM, the 5-year OS and RFS rates were significantly higher in 36 patients with adjuvant chemotherapy (81% and 57%) and in 34 patients with adjuvant immunotherapy (68% and 50%) than in 57 patients with hepatectomy alone (45% and 33%). In 50 patients with LNM and no IM, the 5-year OS rate was significantly higher in 14 patients with adjuvant chemotherapy (42%) and in 20 patients with adjuvant immunotherapy (47%) than in 16 patients with hepatectomy alone (8%). In other patient groups, there were no significant differences in OS and RFS rates among adjuvant therapy groups and hepatectomy alone.

Conclusion: ICC with neither IM nor LNM is the optimal indication for hepatectomy and adjuvant therapy after surgery.



Dr. Yuzo Umeda

Department of Gastroenterological Surgery, Okayama University Graduate School of Medicine, Dentistry, and Pharmaceutical Sciences, Japan

Efficacy of Surgical Management for Recurrent Intrahepatic Cholangiocarcinoma

Background: Intrahepatic cholangiocarcinoma (ICC) is the second most common primary liver malignant tumor of the liver, in which surgery has been regarded as a potentially curative treatment. However, recurrence after surgery for ICC is common, with a reported recurrence rate of 50–79%. Re-evaluation of treatment modalities for ICC recurrence appears worthwhile; we will discuss the efficacy of surgical management for recurrent ICC based on the multi-institutional database.

Material and Methods: A total of 345 cases of ICC who underwent hepatectomy with curative intent in 17 institutions were retrospectively analyzed, focusing on recurrence patterns and treatment modalities for recurrent ICC.

Results: Overall 5-year recurrence-free survival rate was 28.5%, respectively. Recurrences (n = 223) were classified as early (recurrence at \leq 1 year, n = 131) or late (recurrence at $>$ 1 year, n = 92). Median survival time was poorer for early recurrence (16.3 months) than for late recurrence (47.7 months, $p < 0.0001$). Treatment modalities for recurrence comprised surgical resection (n = 28), non-surgical treatment (n = 134), and BSC (n = 61).

Median and overall 1-/5-year survival rates after recurrence were 39.5 months and 84.6%/36.3% for surgical resection, 14.3 months and 62.5%/2.9% for non-surgical treatment, and three months and 4.8%/0% for BSC, respectively ($p < 0.0001$). Multivariate analysis identified early recurrence (Hazard ratio [HR] 1.39), simultaneous intra- and extrahepatic metastases compared with intrahepatic-only recurrence (HR 1.65), and surgical resection of recurrence compared with BSC (HR 0.06, $p < 0.001$) or non-surgical treatment (HR 0.46) as independent prognostic factors for post-recurrence survival. Regardless of the relapse timing, surgical resection's superiority over other treatment modalities was evident ($p < 0.0001$). In late recurrence, surgical resection resulted in long-term survival almost equivalent to that seen in no-recurrence cases.

Conclusions: In cases with recurrence, the path of surgical resection should always be explored to improve prognosis. However, even if recurrences seem resectable, careful decision-making may be mandatory.



Dr. Masao Nakajima

Department of Gastroenterological, Breast and Endocrine Surgery,
Yamaguchi University Graduate School of Medicine, Japan

Preoperative Chemotherapy for the Patients with Advanced Intrahepatic Cholangiocarcinoma with Lymph Node Metastasis

Background: Even after curative resection, the prognosis of the patients with an advanced intrahepatic cholangiocarcinoma with lymph node metastasis (IHCC+LN) is extremely poor; therefore, the development of multidisciplinary treatment is urgently needed. Recently, the usefulness of neoadjuvant chemotherapy (NAC) has been reported mainly for the patients with pancreatic cancer, and it may also be useful for biliary tract cancer. Herein, we'll report the therapeutic results of NAC for IHCC+LN patients since 2017.

Methods: Seven patients with advanced intrahepatic cholangiocarcinoma with preoperative suspicion of lymph node metastasis were planned to undergo multidisciplinary treatment in our department. Lymph nodes with a short diameter ≥ 10 mm and with higher FDG accumulation than the surrounding tissue on PET-CT scan were defined as positive for lymph node metastasis. Patients were administered NAC with 3 courses of GCS therapy, and the operation was performed for the patients without disease progression after NAC.

Result: The median tumor diameter was 6.2 cm, and the median number of tumors was 1, 5 patients had mass-forming and 3 had peripheral types tumor, and no serious adverse events occurred during NAC. All patients showed decreased tumor marker and decreased FDG accumulation in both of the main lesion and metastatic lymph nodes after NAC. In particular, 5 patients showed loss of FDG accumulation in lymph nodes. 6 out of 7 patients underwent surgery, and R0 resection was achieved in all patients. Histopathologically, 5 out of 6 patients had lymph nodes metastasis. There was no perioperative mortality, postoperative complications (\geq CD grade 3a) were observed in 5 patients, and median postoperative hospital stay was 63 days. Of 6 patients who underwent radical resection, 5 had experienced recurrence with distant metastasis (median RFS: 7.2 months), 3 died of the disease, and the median survival time from induction of chemotherapy were 63.3 months.

Conclusion: Multidisciplinary treatment for the patients with IHCC+LN is safe and feasible. Although this is a small number of cases, IHCC+LN patients with FDG accumulation in the lymph nodes are highly likely to have distant metastases. For achieving further improvement of surgical outcomes, the development of more aggressive multimodality treatment and careful consideration of surgical indications are essential.



Dr. Yoshihito Kano

Department of Clinical Oncology Tokyo Medical and Dental University,
Japan

Clinical Utility of Comprehensive Genomic Profiling in Advanced Liver Cancers

Comprehensive genomic profiling (CGP) using next-generation sequencing (NGS) in a clinical setting provides the information regarding cancer-related genetic aberrations and therefore is expected to be useful for precision medicine. However, clinical utility of CGP remains unknown in solid cancers including advanced liver cancers such as hepatocellular carcinoma (HCC) and cholangiocellular carcinoma (CCC) in Japan. Here, we introduce a hospital-based study to investigate the clinical utility of CGP including liquid biopsy in HCC and CCC. In HCC, the most common gene alteration was TERT promotor alteration followed by inactivation of TP53 and activation of CTNNB1 as major variants. There was no patient who received with targeted therapy because of tumor progression and poor performance status in HCC. On the other hand, inactivation of TP53 and KRAS mutation were detected in CCC. Especially, we could detect FGFR2-fusion and TMB-high in CCC by liquid biopsy and they were treated with FGFR inhibitor and PD1 inhibitor, respectively. Although larger sample size will be required in future studies, these results indicate the clinical utility of CGP in liver cancers in Japan



Dr. Hiroto Ota

Gastroenterology, Juntendo University, Tokyo, Japan

Efficacy of New FP Therapy for Unresectable Advanced Intrahepatic Cholangiocarcinoma

Hiroto Ota, Hiroaki Nagamatsu, Ko Tomishima, Hiroyuki Isayama
Gastroenterology, Juntendo University, Tokyo, Japan

Background: We evaluated Hepatic arterial infusion chemotherapy (HAIC) of New FP (NFP; a fine-powder cisplatin suspended with lipiodol plus 5-fluorouracil) for unresectable Intrahepatic Cholangiocarcinoma (ICC).

Methods: Unresectable ICC received NFP consisted of 50 mg CDDP (Days 1, 8) followed by 1500 mg 5-FU every 2 months, were compared with gemcitabine+cisplatin (GC) treated cases.

Results: We enrolled NFP in 11 and GC in 15 (Median age: 64(23-81)/67(47-83), male/female: 8/3, 6/9, stage III/IVa/IVb/postoperative-recurrence (1/4/5/1, 0/2/13/0)). The mean treatment courses in the NFP and GC groups were 4 (1.5 -10) and 5.7 (1 -14) and median observation period was 362.5/151days. PR rate of NFP group (72.7%) was significantly higher than GC group (13.3%) ($p = 0.004$) with time to best response (171/82days). Median tumor shrinkage of NFP group (37.1%) was higher than GC group (11.4%). In NFP group, Grade \geq 3 hepatic dysfunction was observed in all cases, but all improved within 1 week, 2 cases were discontinued NFP because of Grade 3 aggravation of bilirubin and occurrence of biloma. In GC group, Grade 4 neutropenia occurred in 2, Grade 2 renal impairment in 8, Grade 3 anorexia in 1, and vasculitis in 1. Nine patients (57.1%) had difficulty in continuing treatment due to adverse events.

Conclusion: New FP was feasible for unresectable ICC and showed high PR rate and tumor shrinkage effect. Large prospective study was required to confirm these results and make new treatment strategies for unresectable ICC including New FP.



Dr. Hitoshi Yoshiji

Department of Gastroenterology, Nara Medical University, Japan

Molecular Mechanism of Liver Fibrosis

~ Possible Involvement of Neovascularization and Gut-liver Axis ~

As well as hepatic stellate cells, various cells are known to be involved in liver fibrosis. Vascular endothelial cells have been reported to undergo phenotypic changes during fibrosis. Angiogenesis through interaction between vascular endothelial cells and hepatic stellate cells plays an important role in the development of liver fibrosis. Angiogenesis increases with fibrosis in human chronic liver diseases. Inhibition of VEGF signaling, a major angiogenic factor, markedly suppresses hepatic fibrosis. Since combined treatment with different mechanistic anti-angiogenic agents exerted potent beneficial effects, we examined several combinatorial treatments of clinically used agents at clinically comparable low doses on the liver fibrosis and angiogenesis to evaluate the feasibility of a future clinical application. I will show some of our data and recent pieces of literature to discuss the pivotal role of neovascularization and angiogenesis-targeted liver fibrosis therapy. The second issue is the role of Gut-Liver Axis in the liver fibrosis development. Several reports have shown that Gut-Liver Axis plays a pivotal role in the progression of chronic liver diseases, including liver fibrogenesis. A leaky gut may be the cutting edge for the passage of toxins, antigens, or bacteria into the body, and may play a pathogenic role in chronic liver diseases such as advanced liver cirrhosis and its complications. Plasma endotoxin (EX) levels have been admitted as a surrogate marker of disturbance of the gut-liver axis; bacterial translocation and close relations of endotoxemia to hyperdynamic circulation, portal hypertension, renal, cardiac, pulmonary, and coagulation disturbances have been reported. Bacterial overgrowth, increased intestinal permeability, failure to inactivate EX, and activated innate immunity are all likely to play a role in the pathological states of bacterial translocation. A therapeutic approach to the management of the gut-liver axis by several approaches such as antibiotics, probiotics, synbiotics, and their combinations may improve the clinical course of cirrhotic patients. Suppression of the gut-liver axis has been shown to exert an-anti fibrotic and anti-hepatocarcinogenesis process. In this session, I also review the current knowledge and future perspectives on the role of the gut-liver axis in liver fibrosis development especially focused on the pivotal role of EX with some of our recent data.



Dr. Kenichi Morikawa

Internal Medicine, Maruyama Park Clinic, Sapporo, Hokkaido, Japan

The Potential of Soluble CD14 in Discriminating Nonalcoholic Steatohepatitis from Nonalcoholic Fatty Liver Disease

Background and Aims: Although various noninvasive markers and prediction formulae for nonalcoholic steatohepatitis (NASH) have been reported, they are of value only in the diagnosis of the advanced fibrosis stage of NASH. In this study, we evaluated soluble CD14 (sCD14) as a diagnostic marker for discriminating NASH from nonalcoholic fatty liver disease (NAFLD) using an animal model and clinical specimens.

Methods: Serum sCD14 levels were measured in samples derived from mice with diet-induced NASH and patients using an enzyme-linked immunosorbent assay. Our cohort enrolled 126 patients with liver needle biopsy-proven NAFLD.

Results: The intestinal defense mechanism in NASH model mice was altered as a consequence of the unique gut environment. Elevated serum levels of sCD14 were observed in mice with diet-induced NASH, and the condition of the liver was exacerbated as a result of exposure to gut-derived endotoxin. We confirmed that the serum sCD14 levels in NAFL patients significantly differed from those in NASH patients. The area under the curve for distinguishing between NAFL and NASH was 0.891. Moreover, we found that serum sCD14 levels were weakly correlated with the inflammation grade based on the NAFLD activity score (NAS), the grade of fibrosis according to the Brunt fibrosis classification, and a positive correlation with the grade of ballooning based on NAS in patients with NAFLD.

Conclusion: sCD14 could be a useful pathophysiological marker and diagnostic adjunct distinguishing NASH from NAFLD. The use of sCD14 may allow the screening and identification of high-risk groups for NASH development and support early therapeutic interventions.



Dr. Shouichi Namikawa

Second Department of Internal Medicine, University of Fukui, Tokyo, Japan

The Usefulness of Hepatic Shear Wave Velocity for Noninvasive Prediction of Esophageal Varices in Patients with Chronic Liver Diseases

Background: Upper gastrointestinal endoscopy is the standard for the diagnosis of esophageal varices; however, it is highly invasive. Shear wave ultrasound elastography (SWE) is a noninvasive diagnostic method for patients with chronic liver disease (CLD). In this study, we investigated the usefulness of hepatic shear wave velocity (V_s) for predicting liver cirrhosis and esophageal varices.

Methods: V_s values were measured by point SWE (pSWE) in 71 patients with liver disease, using the Hitachi HI VISION Ascendus scanner between 2017 and 2019. The liver fibrosis was evaluated by liver biopsy (F0/F1/F2/F3/F4; n=7/14/21/19/10). Liver fibrosis-related markers were measured in peripheral blood. 45 patients were evaluated for esophageal varices by endoscopy.

Results: The median V_s values for liver fibrosis grades F0/F1/F2/F3/F4 were 1.18/1.34/1.39/1.80/2.12 m/s. The AUC of V_s was 0.890, indicating a better indicator for cirrhosis (F4) as compared to blood markers such as platelets/M2BPGi/hyaluronic acid/type IV collagen 7S/FIB-4 index (0.812/0.730/0.784/0.807/0.790). Esophageal varices were present in 10 out of the 45 patients. The AUC for predicting esophageal varices by V_s was 0.901, indicating higher accuracy compared to blood markers. Furthermore, in patients with advanced liver fibrosis (F3+F4), there was no difference in blood markers, while V_s value was increased in patients with esophageal varices ($P<0.05$).

Conclusion: The hepatic shear wave velocity of pSWE was shown to be more accurate than blood liver fibrosis-related markers in predicting cirrhosis and esophageal varices. In patients with CLD, a noninvasive test using V_s values of pSWE was suggested to be useful to predict cirrhosis and esophageal varices.



Dr. Masaaki Mino

The Research Center for Hepatitis and Immunology, National Center for Global Health and Medicine, Chiba, Japan


Supplementation of Five Amino Acids Promotes Myoblast Differentiation in Cirrhotic Condition in Vitro

Background: In patients with liver cirrhosis, supplementation of branched-chain amino acids has been proven to maintain skeletal muscle volume, thereby preventing sarcopenia. However, it is still unknown whether more appropriate formula of amino acids (AAs) exists for the invigoration of skeletal muscle. We thus aim to explore the best formula of AAs impacting on the differentiation of myoblast in the conditioned medium simulating AA environment of liver cirrhosis.

Methods: We evaluated the differentiation capacity of myoblast (primary human myoblast and C2C12) under healthy control medium (HCM) or advanced cirrhotic medium (ACM: Hepatology 2009) added with various combination and concentration of AAs. Myotube area, diameter and fusion index were measured to assess differentiation by fluorescent microscopy. AAs consumption in cell lines (C2C12, 3T3-L1 and sv40 immortalized hepatocyte) were measured by high-performance liquid chromatography. The expression of myoblast differentiation marker (MyoD, Myogenin and MYH), mTOR and p-S6K were determined by western blotting.

Results: Myotube area, diameter, fusion index and the expression of MYH in myoblast in ACM were decreased compared to HCM. Among 20 AAs, 8 AAs were consumed during the differentiation of C2C12. The addition of single AA out of 5 AAs to ACM increased the expression of MYH in a dose dependent manner. Co-supplementation of specific concentration of 5 AAs significantly increased the expression of MYH and p-S6K in myoblast in ACM.

Conclusions: Five AAs formula promotes the differentiation of myoblast under the ACM condition, showing the possibility of novel muscle-oriented approach by AA supplementation for patients with liver cirrhosis.



Dr. Shinya Nishida

Shinyurigaoka General Hospital, Japan

Estimation of Liver Fibrosis with Machine Learning Using Ultrasonography

Shinya Nishida, Kento Imajo, Nobuyoshi Kawamura, Shigehiro Kokubu
Shinyurigaoka General Hospital

Background: Liver fibrosis is one of the most important predictors in chronic liver diseases. We have several ways to assume the severity of fibrosis, but each has its merits and demerits from the viewpoint of its convenience and invasiveness. The purpose of this study is to develop AI estimating liver stiffness from B-mode ultrasonography image of liver and evaluate its efficacy.

Method: We have reviewed the data of 93 patients who had been taken abdominal MRI with MR elastography (MRE), and abdominal ultrasonography within 3 months. They were divided into two groups, 78 patients as training data, and 15 patients as test data. The values of MRE were object variables and the ultrasonography images of liver were explanatory variables and regression analysis with convolutional neural networks was performed. In analysis, Python 3.7, Keras were used.

Results: Median measured MRI in the training data was 2.37 (1.5-16.6) kPa, same as that in the test data 2.34 (1.9-4.84) kPa. 30 epochs of learning were performed. Median estimated values with AI in the training data was 2.4 (1.72-3.2) kPa, and correlation coefficient between measured values and estimated values was 0.577.

Conclusions: We suggested that it is possible to estimate liver stiffness from ultrasonography images. The number of cases was small, and it was expected that increasing cases will improve the accuracy of AI.



Dr. Yoshihiro Kamada

Departments of Advanced Metabolic Hepatology, Osaka University
Graduate School of Medicine, Japan

Serum Mac-2 Binding Protein is a Useful Prediction Biomarker for the Development of Hepatocellular Carcinoma and Colorectal Cancer in Patients with NAFLD

We have demonstrated that Mac-2 binding protein (M2BP) is a useful biomarker for NAFLD, particularly NAFLD fibrosis prediction. In the present study, we investigated the prognostic value of M2BP in NAFLD patients. A total of 506 biopsy-confirmed NAFLD patients from 2002 to 2013 (NAFLD cohort) and health check-up received subjects (n=2,122; check-up cohort) were enrolled in this study. Serum M2BP levels were significantly increased with the liver fibrosis progression in NAFLD cohort. Using ROC analysis, we set the fibrosis predicting cutoff values as 1.80 (F1), 2.21 (F2), and 2.24 $\mu\text{g}/\text{mL}$ (F3). In the fatty liver subjects from the check-up cohort (n=1,291), the serum Mac-2bp levels were $>1.80 \mu\text{g}/\text{mL}$ in 38.6 % of the subjects (n=498), and $>2.24 \mu\text{g}/\text{mL}$ in 24.6 % of the subjects (n=318). Among NAFLD cohort, 353 patients were available for follow-up for more than 100 days and showed no liver-related events at the time of entry. Liver-related events were defined as hepatocellular carcinoma (HCC), decompensation, and gastroesophageal varices with variceal treatment. The mean follow-up duration of all the subjects was $2,716 \pm 1621$ days (102-7,483 days). Eighteen patients developed new liver-related events (HCC: 8; decompensation: 11; varices: 8). Twenty four patients developed new cancers in other organs. The median serum M2BP level was $1.603 \mu\text{g}/\text{mL}$, and we divided our cohort into two groups according to the serum M2BP level [M2BP low group (M2BP Low), M2BP high group (M2BP Hi)]. The incidence of HCC was significantly higher in M2BP Hi (n=8) than in M2BP Low (n=0). The incidence of liver-related events was significantly higher in M2BP Hi (n=16) than in M2BP Low (n=2). The incidences of death and cancer in other organs were not different between the groups. Interestingly, the incidence of colorectal cancer was significantly higher in M2BP Hi (n=5) than in M2BP Low (n=0).

Conclusion: M2BP is a useful biomarker to predict liver-related events, particularly HCC. Additionally, M2BP is a potential predictive biomarker of colorectal cancer development.



Dr. Man-Fung Yuen

Department of Medicine, School of Clinical Medicine, Queen Mary Hospital, The University of Hong Kong, China

Effects of Fat and Sugar on HCC Development in Hepatitis B Disease

Chronic hepatitis B (CHB) and non-alcoholic fatty liver disease (NAFLD) are the two most common chronic diseases affecting the liver. They are highly associated with the development of hepatocellular carcinoma (HCC). Diabetes mellitus (DM) has also been shown to be independently associated with the development of HCC. The interactions between CHB and NAFLD and DM are complex and their concomitant existence may affect the incidence of HCC in patients with CHB. While the presence of hepatic steatosis is associated with a higher chance of HBsAg seroclearance which is associated with a lower risk of HCC, the hepatic steatosis induced fibrosis and cirrhosis would however, increase the HCC risk in patients with CHB. Studies so far revealed conflicting results on whether the presence of hepatic steatosis would increase or decrease the HCC risk. A recent meta-analysis showed that hepatic steatosis would increase the rate of cirrhosis and HCC development in CHB patients.

Unlike NAFLD, the role of DM on HCC development in CHB patients is more affirmative. The increased risk ratios of HCC development were consistently shown in many studies. Recently, there is a study further showing that the glycemic burden of CHB patients with type 2 DM was associated with a proportionally increase in the HCC risk. CHB patients with longer duration of DM, higher levels of HbA1c and longer time to reach the target HbA1c were associated with significantly higher risks of HCC development compared to their counterparts. These risks were more pronouncedly increased in CHB patients with cirrhosis.

While viral suppression by antiviral agents is very vital to reduce HCC risk for CHB patients, other common HCC causing factors including NAFLD and DM also need stringent control in order to minimize the HCC risk for CHB patients.



Dr. Yoshio Sumida

Department of Hepatology and Pancreatology
Aichi Medical University of Medicine, Japan

Clinical Characteristics of NAFLD-related HCC in Japan

The prevalence of non-viral HCC which is associated with obesity, type 2 diabetes, and alcohol is increasing in Japan. About 25% of adult Japanese population is now suffering from NAFLD. A polymorphism in PNPLA3 has been shown to have significant effects on the development of NAFLD, NASH, the progression of fibrosis, incidence of HCC, and liver-related mortality. PNPLA3 G alleles are prevalent in Japan, South Korea, Taiwan, and Mexico. The cumulative hepatocarcinogenesis rate of 238 Japanese patients with biopsy-proven NAFLD was examined according to PNPLA3 SNP. GG homo carriers were shown to have significantly higher hepatocarcinogenesis rates than C allele carriers. In Japan, GG homo carriers were observed in 21% of health checkup examinees (n=920), 37% of NAFLD patients (n=509), and 59% of NAFLD-related HCC (n=58). In 2022, Japan Study Group of NAFLD (JSG-NAFLD) reported clinical outcomes in 1,398 adults with biopsy-proven NAFLD in Asia (CLIONE-ASIA study). Incidence of HCC (/1,000 person-year) is 1.7 in stage 0/1 (n=780), 4.5 in stage 2 (n=394), 14.2 in stage 3 (n=198), and 16.9 in stage 4 (n=26). Liver-related events were associated with fibrosis progression. Thus, NAFLD patients with advanced fibrosis (stage 3/4) should be identified among a large population of NAFLD. In contrast to virus-associated HCC, however, 20%–50% of NAFLD-HCC develop without underlying cirrhosis. In sub-analysis of CLIONE-ASIA study, NAFLD patients with high NITs (FIB-4 index or NAFLD fibrosis score) were at higher risk of liver-related mortality and events, including incident HCC. Those patients should receive HCC surveillance. Simple NITs are useful for stratifying at risk of incident HCC in NAFLD. It remains to be resolved whether determination of PNPLA3 SNP may help us do HCC surveillance.



Dr. Tomomi Kogiso

Institute of Gastroenterology, Department of Internal Medicine, Tokyo Women's Medical University (TWMU), Japan

Characteristics of Fatty Liver Disease-related Hepatocellular Carcinoma and Genetic Background in Japan

Aim: The incidence of non-alcoholic fatty liver disease (NAFLD) has been increasing in Japan, however, there is no effective surveillance strategy for hepatocellular carcinoma (HCC) in NAFLD patients. Here, we evaluated the characteristics of Japanese patients with NAFLD-HCC and considered the risk factors including genetic background.

Methods: We enrolled 547 Japanese patients with biopsy-confirmed NAFLD (1990–2019): 254 males (46.4%); median age (53 [10-84] years); advanced fibrosis 174 (33%); diabetes, n = 274 (50%); dyslipidemia, n = 375 (69%); and hypertension, n = 300 (55%). We analyzed the survival and new-onset HCC rates for hepatic fibrosis, and genetic background of PNPLA3 and HSD17B13.

Results: NAFLD-HCC was observed in 28 cases (5%). Comparing to the patients with HCC and non-HCC, HCC was frequently observed in men (HCC 21 cases, 75% vs. non-HCC 254 cases, 49%), older age (65 vs. 52 years), complication of diabetes (22 cases, 79% vs. 252 cases, 49%), especially the insulin users and hypertension (26 cases, 93% vs. 274 cases, 53%). HCC patients had PNPLA3 GG/GC, however, there was not significant difference in HSD17B13 risk allele. Risk factors for HCC onset after adjustment of age, gender, and complication of diabetes, were pathological findings of advanced fibrosis and mild inflammation in the liver. The incidence of HCC at 10 years was 20.1% in the advanced fibrosis group.

Conclusions: NAFLD-HCC was observed in elderly men and insulin users. Since genetic background can influence the NAFLD-HCC development, it is necessary of HCC surveillance including genetic background.



Dr. Hideki Fujii

Osaka Metropolitan University, Japan

Clinical Characteristics of Hepatocellular Carcinoma in Biopsy-confirmed NAFLD: Sub-analysis of CLIONE in Asia

Background: A recent study indicated that nonalcoholic fatty liver disease (NAFLD) and nonalcoholic steatohepatitis (NASH) are becoming the leading causes of hepatocellular carcinoma (HCC). Since NAFLD-related HCC can develop in individuals both with and without cirrhosis, the development of an early HCC detection method for use in patients with NAFLD represents an unmet clinical need.

Methods: We used a dataset from the CLIONE (Clinical Outcome Nonalcoholic Fatty Liver Disease) study conducted in Asia (Clin Gastroenterol Hepatol. 2022, in press), which includes 1398 NAFLD patients who underwent liver biopsy between 1994 and 2020. Liver biopsy specimens were digitized, pathologically diagnosed, and histologically scored using the NASH Clinical Research Network system. Demographic, clinical, laboratory, and pathological data were collected.

Results: During a median follow-up period of 4.6 years (range, 0.3–21.6 years), 37 patients developed HCC. Patients who developed HCC were significantly older age (mean age; 61.9 vs. 54.3 years, $P=0.001$), higher percentage of diabetes mellitus (59% vs. 36%, $P=0.005$), lower value of ALT (63.0 vs. 88.7 U/L, $P=0.011$), lower value of platelet count (136 vs. 223 $\times 10^9/L$, $P<0.001$), than those who did not. Furthermore, patients who developed HCC had significantly higher rates of NASH (95% vs. 66%, $P<0.001$), and advanced fibrosis (46% vs. 15%, $P<0.001$) than those who did not. Using a cutoff baseline platelet counts of 192 $\times 10^9/L$, adjusted hazard ratio of developing HCC in the high platelet group versus the low platelet group was 14.4 (95% confidence interval, 5.03–41.3; $P<0.001$), adjusting for age, sex, and histological NASH.

Conclusion: Platelet count at liver biopsy may predict the development of HCC.



Dr. Hitoshi Mochizuki

Department of Gastroenterology, Yamanashi Prefectural Central Hospital,
Japan

A Bird's-eye View on Lifestyle Disease Across Specialties; Construction of Integrated Real-World Data across Organs and Clinical Departments

Background: We have been working on the computerization of medical operation of the National Database of Medical Receipts (NDB) and the Diagnostic Procedure Classification (DPC) database.

Methods: We analyzed HIS (Hospital Information Network) data obtained via DWH (Data Ware House) for patient background, time-series laboratory data (number of patients with blood sampling including lifestyle-related disease-related tests, etc.), and the results of the analysis.

Results: All the collected data to be integrated and analyzed as follows; the number of collected blood samples were from patients with lifestyle-related diseases was 99,932. In addition, genome panel test data (number of consent obtained: 7930, analyzed samples: 10747, analyzed bases: 4.5 trillion bases/9 years), cancer registry data (26783/16 years), MSI-IHC/NGS (1442/2 years), immuno-checkpoints data (503 patients, 6902 times/7 years), and others (73934 patients who were tested for hepatitis B/C virus/ 10 years) were accumulated. Although the data format differs from each other, the inhouse programming of the data allows for flexible operation and immediate response to new searches. In addition, we are currently attempting to analyze thought processes and medical practices by text mining from electronic medical record descriptions. Data on lifestyle-related disorders (DM and MAFLD) will be presented in the meeting.

Conclusion: These efforts will gain a bird's-eye view of humans across diseases and departments, and to grasp the "real" Real World Data, thereby creating the Real-World Evidence needed by clinicians and patients.



Dr. Hiroaki Matsumoto

Department of Gastroenterology and Hepatology,
Musashino Red Cross Hospital, Tokyo, Japan

Clinical Impact of the Changes of Skeletal Muscle during Atezolizumab Plus Bevacizumab Therapy in Patients with Unresectable Hepatocellular Carcinoma

Background: Sarcopenia is associated with clinical outcomes in HCC. We investigated the changes in muscle volume during atezolizumab plus bevacizumab (Atezo+Bev) for unresectable HCC (u-HCC).

Method: The patients with u-HCC treated with Atezo+Bev as first-line systemic therapy were included. The skeletal muscle mass index (SMI) was calculated from the skeletal muscle area at the L3 level of the lumbar vertebrae by CT. Pre-sarcopenia was defined as an L3 SMI value \leq of 42 and 38 cm²/m² for men and women. SMI decrease was calculated as the subtraction between before and 6 to 14 weeks after the administration of the agents.

Results: Between Oct 2020 and May 2022, 50 patients received Atezo+Bev as first-line at our institution. There was no significant difference in progressive free survival (PFS) between the patients with (n=19) and without pre-sarcopenia (n=31). SMI changes were analyzed in 33 patients. The median PFS was 6.1 and 8.5 months in the patients with (n=19) and without SMI decrease (n=14). In the patients without SMI decrease, the median PFS was significantly longer than patients with SMI decrease (p=0.013). Extrahepatic metastasis (p=0.0072), SMI decrease (p=0.023), BCLC stage C (p=0.044), CRP (p=0.032) were significantly associated with PFS in univariate analysis, and SMI decrease was an only significant factor in multivariate analysis (HR5.8, p=0.025).

Conclusion: The SMI decrease at 6 to 14 weeks was significantly associated with PFS in patients treated with Atezo+Bev, while pretreatment pre-sarcopenia was not a significant factor. Monitoring muscle volume during immunotherapy would be meaningful in clinical practice.



Dr. Hitomi Takada

First Department of Internal Medicine, University of Yamanashi,
Japan

Impact of Renal Failure in Patients Treated with Atezolizumab / Bevacizumab Combination Therapy for Unresectable Hepatocellular Carcinoma

Background: It has been pointed out that interstitial nephritis and drug-induced nephropathy by PD-1/PD-L1 antibody drug, and proteinuria after administration of VEGF inhibitors may occur. However, there are many unclear points about the renal failure in unresectable HCC (u-HCC) patients treated with atezolizumab/bevacizumab (AB) therapy.

Methods: Blood and urine tests were performed in 33 u-HCC patients treated with AB therapy baseline and every 3 weeks thereafter. The relationship between renal function and prognosis after the start of AB therapy was investigated in this study.

Results: Baseline renal function and urinary findings were eGFR grade 1/2/3a/3b 8/16/8/1 cases according to CGA classification, proteinuria detected by dipstick test -/±/1+/2+/3+ 11/7/11/4 cases. The overall survival of patients with 1+ or higher by dipstick test at baseline was shorter than that of the group showing -/± (p=0.031). There were many cases of renal disorder risk drug use in cases with 1+ or higher. The survival of the group with deterioration of eGFR grade was shorter than that of the group without (p = 0.048). The survival of the group with deterioration of eGFR grade without urinary protein of 2g/gCre or higher was shorter than that of the other groups (p = 0.0073). In patients whose eGFR worsened without an increase in urinary protein, there were many cases with daily salt intake of 10 g or more, renal disorder risk drug use, and a history of arteriosclerosis.

Conclusion: In cases treated with AB therapy for u-HCC, review of lifestyle and oral medication may lead to improved prognosis.



Dr. Naoya Kanogawa

Department of Gastroenterology, Graduate School of Medicine, Chiba University, Chiba, Japan

Use of Ramucirumab for Various Treatment Lines in Real-World Practice of Patients with Advanced Hepatocellular Carcinoma

Background: Ramucirumab was shown to be effective as a second-line treatment after sorafenib in patients with advanced hepatocellular carcinoma (HCC) with alpha-fetoprotein levels >400 ng/mL in a worldwide phase 3 trial. Ramucirumab is used in patients pretreated with various systemic therapies in clinical practice. We retrospectively examined the treatment outcomes of ramucirumab administered to advanced HCC patients after diverse systemic therapies.

Methods: Data were collected from patients with advanced HCC who received ramucirumab at three institutions in Japan. Radiological assessments were determined according to both Response Evaluation Criteria in Solid Tumours (RECIST) version 1.1 and modified RECIST and the Common Terminology Criteria for Adverse Events version 5.0 was used to assess adverse events.

Results: A total of 37 patients treated with ramucirumab between June 2019 and March 2021 were included in the study. Ramucirumab was administered as second, third, fourth, and fifth-line treatment in 13 (35.1%), 14 (37.8%), eight (21.6%), and two (5.4%) patients, respectively. Most patients (29.7%) who received ramucirumab as a second-line therapy were pretreated with lenvatinib. The median progression-free survival of patients treated with ramucirumab was 2.7 months (95% confidence interval, 1.6–7.3). There were no notable adverse events and no significant changes in albumin bilirubin score during ramucirumab treatment.

Conclusion: Although ramucirumab is used for various lines of treatment other than second-line immediately after sorafenib, its safety and efficacy were not significantly different from the findings of the REACH-2 trial.



Dr. Hiroaki Kanzaki

Department of Gastroenterology, Graduate School of Medicine, Chiba University, Chiba, Japan

Real-life Potential of Cabozantinib in Patients with Advanced Hepatocellular Carcinoma

Introduction: Based on this phase 3 CELESTIAL trial, cabozantinib was approved for second-line systemic therapy for advanced hepatocellular carcinoma (HCC). However, in clinical practice, where multiple regimens are approved for advanced HCC, cabozantinib is also used in patients who differ from the population of the phase 3 trial. Therefore, the present study aimed to evaluate the safety and efficacy of cabozantinib administration in real-life setting for patients with advanced HCC.

Methods: We retrospectively collected data of patients with advanced HCC who received cabozantinib in 3 institutions in Japan between September 14, 2018, and November 30, 2021. **Results:** At the time of cabozantinib administration, 5 (21.7%) were Child-Pugh class B. Six patients (26.0%) had obtained 2 systemic therapy lines before initiation of cabozantinib and 12 (52.2%) patients had at least 3 previous therapy lines. Ten patients (43.5%) had dose reductions and 14 patients (60.9%) had dose interruption. The most frequently occurring Adverse Events (AE) were aspartate aminotransferase increased (73.9%), alanine aminotransferase increased (65.2%), and hypoalbuminemia (52.2%). The most common grade 3 or higher AE was palmar-plantar erythrodysesthesia (13.1%). According to RECIST, we found an overall response rate of 4.4% and a disease control rate of 56.6%.

Conclusion: In the present study, patients with impaired liver function and those treated in the third-line or later could be also adequately managed with appropriate dose reduction and interruption with careful follow-up.



Dr. Hideki Iwamoto

Division of Gastroenterology, Department of Medicine, Kurume University School of Medicine, Fukuoka, Japan

Hepatic Arterial Infusion Chemotherapy New-FP for Hepatocellular Carcinoma with Major Portal Vein Tumor Thrombus

Background: Major portal vein tumor thrombus (PVTT) is a critical tumor condition in hepatocellular carcinoma (HCC), determining the optimal treatment is an unmet medical need. We aimed to compare the efficacy of hepatic arterial infusion chemotherapy (HAIC) regimens New-FP (fine-powder cisplatin suspended with lipiodol and 5-fluorouracil) and sorafenib for major PVTT-HCC.

Methods: We retrospectively collected the data from 1,709 patients with HCC who were initially treated with New-FP or sorafenib (March 2009 to June 2019). Among them, 291 patients were major PVTT-HCC (New FP; n=177, sorafenib; n=114). Overall survival and prognostic factors were assessed after propensity score matching (PSM, n=each 78).

Results: After PSM, there were no significant differences between two groups. The median survival time (MST) of New-FP and sorafenib was 13 and 6 months, respectively ($p < 0.0001$). Sorafenib, AFP over 400 ng/ml, presence of EHS, presence of PVTT into the portal trunk, tumor size over 5 cm, and over 65 years were independent poor prognostic factors. The response rate of New FP for major PVTT-HCC was 73% (CR 16.6%, PR 56.4%). The MST of the responder and non-responder of New FP was 23 and 6 months, respectively ($p = 0.0043$). The MST of patients who achieved a complete response with New-FP (16.6%) was 59 months.

Conclusion: New-FP showed significant efficacy for major PVTT-HCC. Even in the era of systemic treatment, HAIC using New-FP is a promising modality for patients with advanced HCC.



Dr. Kouki Nio

Department of Gastroenterology, Kanazawa University Hospital,
Japan

The Roles of BMP9 in Cancer Stemness and Angiogenesis of Hepatocellular Carcinoma

Kouki Nio¹, Taro Yamashita², Hikari Okada³, Tatsuya Yamashita¹, Shuichi Kaneko³, Eishiro Mizukoshi¹

¹Department of Gastroenterology, Kanazawa University Hospital

²Department of General Medicine, Kanazawa University Hospital

³Department of Information-Based Medicine Development, Kanazawa University Graduate School of Medical Science

Background: The malignant nature of hepatocellular carcinoma (HCC) is closely related to the presence of cancer stem cells (CSCs). In addition, angiogenesis is considered a key player in HCC development. Bone morphological protein 9 (BMP9), a transforming growth factor-beta superfamily member, has recently been reported in the development of liver diseases and angiogenesis. Here, we show the crucial role of BMP9 in HCC development to activate cancer stemness and angiogenesis, and the efficacy of BMP receptor inhibitor to inhibit BMP9 signaling.

Methods: HCC tissue specimens and HCC patient serum samples were analyzed to the correlation of BMP9 expression with patient prognosis. The roles of BMP9 on the regulation of CSCs and angiogenesis and the anti-tumor effect of BMP receptor inhibitors were investigated using HCC cell lines and HCC xenograft mouse models.

Results: Patients with high BMP9 expression in HCC tissue specimens or serum showed a poorer prognosis. In HCC cell lines, BMP9 promoted cell proliferation, invasive and migratory ability, and epithelial cell adhesion molecule (EpCAM) expression via ID1 activation. In addition, BMP9 activated HIF-1 alpha and VEGFA expression and VEGFA secretion via ID1 activation. The BMP receptor inhibitors K02288 and LDN-212854 repressed the promotion of CSC properties and angiogenesis via the inhibition of BMP9 signaling. In vivo, LDN-212854 successfully suppressed tumor growth with the suppression of CSCs and angiogenesis.

Conclusion: BMP9 activates EpCAM-positive CSC properties and angiogenesis in HCC. Thus, targeting BMP9 signaling could be a therapeutic option for malignant HCC.



Dr. Dirk Hose
Lam Kap Bio Group

Novel GPC3xCD3 (NILK-2501) and GPC3xCD28 (NILK-3801) $\kappa\lambda$ Bispecific Antibodies for Next Generation Immunotherapy of GPC3-expressing Cancer

Anja Seckinger¹, Eric Hatterer², Vanessa Buatois², Sara Majocchi², Valery Moine², Lise Nouveau², Bruno Daubeuf², Franck Gueneau², Krzysztof Masternak², Yves Poitevin², Giovanni Magistrelli², Pauline Malinge², Limin Shang², Nicolas Fischer², Klaus Strein¹, Walter Ferlin², Dirk Hose¹


¹LamKap Bio Group, ²Light Chain Bioscience (LCB) - Novimmune S.A.

Background: Glypican-3 (GPC3) is expressed on most hepatocellular cancers (HCC). Co-engaging GPC3 on HCC cells and CD3 on T-cells by GPC3xCD3 bispecific antibodies activates the latter to destroy GPC3-positive cancer cells. Clinical activity is, however, limited, in part by dose-limiting toxicities like cytokine release syndrome (CRS), steep dose-response curve, and low therapeutic margin. Combination of a GPC3xCD3 of medium potency with GPC3-targeted CD28-costimulation shall increase activity, allow better titratable dose response and, when sequentially given, reduce CRS-risk. We present here preclinical data for the combination of NILK-2501/NILK-3801.

Methods: Antibodies were generated using LCB's fully human $\kappa\lambda$ -body platform based on a common heavy chain and on one κ and one λ light chain, determining specificity and affinity. Superagonistic activity was excluded using T-cell proliferation and activation assays. T-cell dependent cytotoxicity (TDCC) was assessed in vitro using 3 HCC-lines and non-malignant primary hepatocytes with hPBMCs. In vivo testing (xenograft NSG/hPBMC model) is ongoing.

Results: NILK-2501/NILK-3801-combination induces TDCC in all HCC cell lines tested. NILK-3801 shifts NILK-2501 concentration response to a lower EC50 and an increased Emax, including GPC3-low expressing lines (e.g., Hep3B). Neither NILK-2501 monotherapy nor the combination induces killing of normal hepatocytes. Compared to the highly active GPC3xCD3 bispecific antibody benchmark alone, NILK-2501/NILK-3801 dosing conveys equal activity at reduced cytokine release. In vivo data will be presented at the meeting.

Conclusions: NILK-2501/NILK-3801-combination treatment is highly active, including GPC3 low-expressing cell lines. Activity is maintained while it allows well tailorable dose response with reduced cytokine release. Compounds are currently in extensive pre-clinical assessment.



Dr. Kento Kitada

Department of Pharmacology, Faculty of Medicine,
Kagawa University, Japan

Abnormal Osmolyte and Water Balance in Hepatocellular Carcinoma Rats

Background: The number of cancer survivors who develop the cardiovascular disease is increasing. However, the effects of cancer on body osmolyte and water balance remain to be determined. In this study, we evaluated the body osmolyte and water content in rats with hepatocellular carcinoma.

Methods: 4-week-old male Wistar rats were treated with diethylnitrosamine, a carcinogenic drug, to induce hepatocellular carcinoma. We administered diethylnitrosamine for 8 weeks and the rats were allowed to recover for 3 weeks, and then samples were collected.

Results: Hepatocellular carcinoma rats exhibited significant decreases in body weight, total body sodium, potassium, and water content. However, hepatocellular carcinoma rats showed significantly higher relative tissue sodium, potassium, and water content per tissue dry weight than control rats. These changes in sodium and water balance in hepatocellular carcinoma rats were significantly associated with 24-hour urinary aldosterone excretion and the urea osmolyte-driven water conservation but not plasma albumin concentration. Supplementation of 0.25% salt in drinking water suppressed body weight loss accompanied by sodium and water retention in hepatocellular carcinoma rats, which was suppressed by treatment with a mineralocorticoid receptor antagonist.

Conclusion: These findings suggest that hepatocellular carcinoma induces body mass loss in parallel with osmolytes and water retention and that the abnormal osmolyte and water balance is mediated by aldosterone secretion and urea accumulation. Osmolyte and water accumulation at the tissue level may be a causative factor for ascites and edema formation in liver failure.



Dr. Satoshi Kawamura

Department of Gastroenterology,
The University of Tokyo, Tokyo, Japan

The Dichotomous Role of SCAP/SREBP Pathway in Pathogenesis of NASH and NASH-related HCC

Satoshi Kawamura¹, Yuki Matsushita¹, Shigeyuki Kurosaki¹, Mitsuhiro Fujishiro¹, Hayato Nakagawa^{1,2}

¹Department of Gastroenterology, The University of Tokyo, Tokyo, Japan, ²Department of Gastroenterology and Hepatology, Mie University, Mie, Japan

Enhanced de novo lipogenesis mediated by sterol regulatory element-binding proteins (SREBPs) is thought to be involved in nonalcoholic steatohepatitis (NASH) pathogenesis. In this study, we assessed the impact of SREBP inhibition on NASH and liver cancer development in murine models. Unexpectedly, SREBP inhibition via deletion of the SREBP cleavage-activating protein (SCAP) in the liver exacerbated liver injury, fibrosis, and carcinogenesis despite markedly reduced hepatic steatosis, which was like burned-out NASH. Liver injury and carcinogenesis were markedly ameliorated by restoring SREBP function. Whole-exome and RNA sequencing of tumor samples suggested that an inflammatory microenvironment including activation of CCL24-CCR3 axis played a key role in enhanced carcinogenesis. Furthermore, transcriptome and lipidome analyses using liver samples revealed that SCAP/SREBP pathway inhibition altered the fatty acid (FA) composition of phosphatidylcholines due to both impaired FA synthesis and disorganized FA incorporation into phosphatidylcholine via lysophosphatidylcholine acyltransferase 3 (LPCAT3) downregulation, which led to endoplasmic reticulum (ER) stress and liver injury. Supplementation of phosphatidylcholines significantly improved liver injury and ER stress induced by SCAP deletion. Human NAFLD liver transcriptome analysis showed that the activity of SCAP-SREBP-LPCAT3 axis was found inversely associated with liver fibrosis severity and lipid synthesis pathway was significantly downregulated in patients with HCC compared to those without HCC. Taken together, both excessive and insufficient SREBP activation may result in NASH disease progression, and downregulation of SREBP pathway in advanced stage NASH potentially promotes HCC development via the disturbance of phospholipid metabolism.



Dr. Seita Kataoka

Department of Gastroenterology and Hepatology, Kyoto Prefectural University of Medicine, Kyoto, Japan

Pancreatic KrasG12D Mutation Increases Hepatocellular Carcinoma Development from NASH in Mice Model

Seita Kataoka¹, Atushi Umemura², Yuya Seko¹, Kanji Yamaguchi¹, Michihisa Moriguchi¹, Yoshito Itoh¹
¹Department of Gastroenterology and Hepatology, Kyoto Prefectural University of Medicine, Kyoto, Japan,
²Department of Pharmacology, Kyoto Prefectural University of Medicine, Kyoto, Japan

NAFLD is the leading etiology of chronic liver disease and the risk of developing HCC. Hyperglycemia, a risk factor for NAFLD, induces KRAS mutations in pancreatic cells, so NAFLD and pancreatic Kras mutations can be combined. This study aims to determine the impact of pancreatic Kras mutation on NASH. MUP-uPA mice (MUP mice) model was used as the NASH model. The conditional KrasG12D model (KC mice) was used as the pancreatic Kras mutation model.: MUP mice, KC mice (progeny from a cross between LSL-KrasG12D and PDX-1/Cre mice), and MUP-KC mice (progeny from a cross between KC mice and MUP mice) were fed the HFD diet until 24 weeks of age for analysis. HCC was developed in 33/34 MUP-KC mice, 6/45 MUP mice, and 1/14 cases in KC mice, with a significantly higher rate in MUP-KC mice. In the RNA analysis by NGS, 100 genes were significantly upregulated in KrasG12D mutation mice (MUP-KC and KC mice) compared to MUP mice, and pathways involved in inflammation were prominent, and 52 of these genes were transcriptional targets of STAT3. In western blotting analysis, STAT3 phosphorylation of the non-cancer area was significantly enhanced in MUP-KC mice. Cytokine antibody array analysis of portal vein blood showed that cytokines that appear due to pancreatic inflammatory changes, such as REG3G, were detected. Pancreatic Kras mutations increased phosphorylation of STAT3 in the liver, which may promote the development of HCC in NASH and its augmentation by increased cell proliferative capacity of HCC.



Dr. Shigeharu Nakano

Department of Gastroenterology and Hepatology, Kyoto University, Kyoto, Japan

Deficiency of the Mismatch Repair Gene MSH2 Promotes Hepatocarcinogenesis in Chronic Hepatitis

Shigeharu Nakano, Atsushi Takai, Masayuki Ueno, Takahiko Ito, Mari Teramura, Masako Mishima, Eriko Iguchi, Haruhiko Takeda, Yuji Eso, Takahiro Shimizu, Hiroshi Seno
Department of Gastroenterology and Hepatology, Kyoto University, Kyoto, Japan

Background: Hepatocellular carcinoma develops on the basis of chronic inflammation. Previously, we have reported that inflammatory stimulation reduced the expression of the mismatch repair gene MSH2 in hepatocytes, which may contribute to carcinogenesis. In this study, we aimed to elucidate the mechanisms of MSH2 in the process of inflammatory hepatocarcinogenesis.

Methods: The oncogenic function of MSH2 under chronic inflammation was evaluated in mouse model with hepatocyte-specific MSH2 deletion (AlbCre/Msh2fl/fl) treated with 0.02% thioacetamide.

Results: AlbCre/Msh2fl/fl treated with 0.02% thioacetamide mouse developed more liver tumors than wild type control (60% vs 24%). Whole exome sequencing revealed that more mutations were identified in tumors in AlbCre/Msh2fl/fl than control group (20.7 vs 8.3 per nodule). The proportion of dMMR-associated signatures was high in AlbCre/Msh2fl/fl, whereas no common cancer driver mutations could be detected. Transcriptome analysis of nontumor liver tissues revealed that several oncogenic pathways were activated in AlbCre/Msh2fl/fl. Integrated analysis of transcriptome in liver tissues of AlbCre/Msh2fl/fl and liver cancer cell lines with MSH2 knockdown revealed that E2F2 expression was commonly increased in liver tissues and cells with Msh2 downregulation.

Conclusion: MSH2 may play a protective role in hepatocarcinogenesis via not only DNA repair but regulation of cell proliferation.



Dr. Takumi Kawaguchi

Division of Gastroenterology, Department of Medicine, Kurume University School of Medicine, Japan

MAFLD Enhances Clinical Practice for HCC in the Asia-Pacific Region

Fatty liver is now becoming a major cause of hepatocellular carcinoma (HCC) in the Asia-Pacific region. The prevalence of fatty liver-related HCC is estimated to further increase in this region. In addition, HCC often occurs in patients with non-cirrhotic fatty liver and tends to be diagnosed at an advanced stage. Therefore, a new strategy is required for screening fatty liver-related HCC.

Recently, an international expert panel proposed a new definition of fatty liver disease, metabolic dysfunction-associated fatty liver disease (MAFLD). MAFLD is not simply a renaming of non-alcoholic fatty liver disease. One feature of MAFLD is that metabolic dysfunction is a requirement for diagnosis. Several studies including a meta-analysis have demonstrated that MAFLD better identifies patients with fatty liver and significant hepatic fibrosis, which is a potent risk factor for HCC. Moreover, accumulated evidence demonstrated that obesity, type 2 diabetes mellitus, and metabolic syndrome are risk factors for HCC in patients with fatty liver, all included in the MAFLD definition.

Another feature is that MAFLD is independent of other etiology for liver disease and the amount of alcohol intake. Therefore, MAFLD allows us to examine the impact of the fatty liver on the incidence of HCC in patients with hepatitis B virus/hepatitis C virus infection. MAFLD also enables us to examine the impact of fatty liver on the incidence of HCC in patients with moderate drinking. Thus, MAFLD may be useful to examine the synergetic effect of co-existing fatty liver and other risk factors for HCC, which are highly prevalent in the Asia-Pacific region.

Recently, the etiological difference in immunotherapy for HCC is an important theme and non-viral HCC may be less responsive to immunotherapy. Non-viral HCC is not the same as MAFLD-related HCC. However, 85% of patients with non-viral HCC have at least one risk factor for MAFLD, suggesting that MAFLD is the dominant etiology for non-viral HCC. Although evidence is still lacking, MAFLD may be better to be categorized as an etiological cause of HCC, especially in the immunotherapy era.

In this session, I summarize the regional characteristics of HCC. Then, I mention the advantages of MAFLD for improving clinical practice for patients with HCC in the Asia-Pacific region.



Dr. Kazuyoshi Kon

Department of Gastroenterology,
Juntendo University School of Medicine, Japan

Glycine Intake Ameliorates Steatohepatitis and Prevents Liver Carcinogenesis in Hepatocyte-specific Pten-deficient Mice

Nonalcoholic steatohepatitis (NASH) can develop hepatocellular carcinoma (HCC); however, the mechanism remains unclear and no preventive method for NASH-related HCC has been established. Although glycine is an amino acid with an extremely simple structure, it has been shown to have various therapeutic effects such as suppression of excessive immune response. In this study, we investigated the effect of glycine on NASH-related liver carcinogenesis using hepatocyte-specific phosphatase and tensin homolog deleted on chromosome 10 deficient mice (Alb-Cre^{flox/flox}, Pten KO), which have a pathological future very similar to NASH-related HCC. Male Pten KO aged 11 to 17 weeks-old were fed 5% glycine-containing diet or control diet for 2 to 24 weeks. Alb-Cre (-)^{flox/+} or Alb-Cre (-)^{+/+} mice were used as controls. Two weeks after the start of the experiment, Pten KO fed a control diet developed steatohepatitis with massive macro-vesicular steatosis, inflammation, and ballooning hepatocytes, and showed significant elevation of serum AST and ALT levels. The glycine diet dramatically suppressed these pathological findings peculiar to steatohepatitis, and completely prevented elevation of serum AST and ALT levels. In the liver tissue of Pten KO, an increase in oxidative stress evaluated by 4HNE staining was enhanced, and the expression of the inflammatory cytokine TNF α was increased. The mechanism was that the expression of the antioxidants catalase and SOD1 was decreased in the liver tissue of Pten KO, and glycine diet prevented the enhancement of oxidative stress and the expression of TNF α . In the liver carcinogenic stage 24 weeks after the start of the experiment, steatohepatitis in Pten KO was further exacerbated and developed multiple liver tumors. When the number of tumors of 2 mm or more was counted, almost no tumor formation was observed in the liver of Pten KO fed a glycine diet. Liver tissue of Pten KO mice fed a glycine diet produced more than 2-fold expression of IFN γ and 4-fold or more upregulation of IL12b as compared with Pten KO. Furthermore, the number of CD8-positive cells in liver tissue increased in Pten KO fed glycine, suggesting that enhanced antitumor immunity by glycine suppressed hepatic tumorigenesis in Pten KO. In conclusion, glycine acts as an anti-inflammatory agent for steatohepatitis by suppressing oxidative stress and inflammatory cytokines, and activates antitumor immunity during tumorigenesis in the process of steatohepatitis-related liver carcinogenesis.



Dr. Miwa Kawanaka

Department of General Internal Medicine 2, Kawasaki Medical Center,
Kawasaki Medical School, Japan

Characteristics of Patients with Hepatocellular Carcinoma that Developed Following a Diagnosis of Nonalcoholic Steatohepatitis by Liver Biopsy

Background: In recent years, the number of nonalcoholic steatohepatitis (NASH) / nonalcoholic fatty liver disease (NAFLD)-related hepatocellular carcinoma (HCC) cases has increased worldwide. However, in many cases it is unclear whether the carcinogenesis is actually caused by the underlying NASH/NAFLD. Therefore, we conducted this study to investigate the characteristics of patients who developed HCC after a diagnosis of NASH by liver biopsy.

Methods: Among the 781 patients diagnosed with NAFLD by liver biopsy at Kawasaki Medical Center from April 1996 to 2022, 18 of the 549 patients who could be followed for more than half a year developed HCC and were enrolled in this study. We investigated the participants' background factors (age, gender, body mass index, and the presence of lifestyle-related diseases), blood tests, liver tissue findings, and PNPLA3 gene polymorphisms.

Results: The median observation period after NAFLD liver biopsy was 6.5 years (0.5–24 years). The cumulative carcinogenic rates of HCC were 2.4%, 4.8%, and 5.4% at 5, 10, and 15 years, respectively, with an incidence of 4.5 per 1,000 person-years. NAFLD-related HCC tended to occur in older individuals (122,000 per 1,000 person-years over 65 years) ($P = 0.0001$) and in those with diabetes (8.4 per 1,000 person-years) ($P = 0.0031$). In liver tissue, HCC carcinogenesis was more common in patients with advanced fibrosis (63.7 per 1,000 person-years) ($P < 0.001$), but it was not associated with grade or steatosis. The PNPLA gene polymorphisms were GG (8.3 per 1,000 person-years) and CG (3.9 per 1,000 person-years), but there were no cases of HCC carcinogenesis from PNPLA3 CC. In HCC carcinogenic cases, platelet and albumin levels were lower and the fibrosis-4 (FIB4) index, hyaluronic acid, and type 4 collagen 7S were higher than those in non-HCC carcinogenic cases. The multivariate Cox proportional hazards analysis showed the factors involved in HCC during NAFLD liver biopsy were diabetes and an FIB4 index ≥ 2.61 . Fibrosis did not progress in most of the male patients with HCC between the ages of 60 and 70 years, while in female patients, cirrhosis was observed after the age of 70 years.

Conclusion: The onset of HCC after a diagnosis of NASH by liver biopsy often presents with advanced fibrosis. In NAFLD cases, screening for HCC carcinogenesis is necessary in patients with diabetes and an FIB4 index ≥ 2.67 .



Dr. Takashi Kobayashi

Department of Gastroenterology and Hepatology, Yokohama City University Graduate School of Medicine, Japan

Gut Microbiota and NASH-related Hepatocellular Carcinoma


The multiple parallel hits theory has been proposed as the pathogenesis of NAFLD, and intestinal permeability has been focused on as one of the factors. We have reported that the amount of *Faecalibacterium prausnitzii* (FP) in stool negatively correlates with liver fibrosis in NAFLD by analyzing human feces, and that FP is involved in intestinal permeability by the lactulose mannitol test.

In this study, we investigated the effect of oral FP administration on NASH in mice. NASH model mice were generated by feeding 8-week-old C57BL/6J mice a high-fat, high-fructose, high-cholesterol diet for 20 weeks. FP or Vehicle was orally administered to these mice for 20 weeks starting at the age of 8 weeks. The FP group showed improved intestinal permeability compared to the Vehicle group, and both liver steatosis and fibrosis were also improved.

We also investigated the suppressive effect of FP on NASH-related hepatocellular carcinoma. B6C3F1 male mice were fed a high-fat, high-fructose, high-cholesterol diet from 5 weeks of age, and diethylnitrosamine was injected intraperitoneally to develop a NASH-related hepatocellular carcinoma model. FP (group F) was orally administered for 12 weeks from 24 weeks of age when hepatocarcinogenesis was observed, and the total tumor volume and other parameters were compared with those in the group that received vehicle (group C).

Group F showed improved intestinal permeability compared to group C, with significantly fewer liver tumors and significantly smaller total tumor volume. Although inflammatory cytokines such as TNF- α and IL-1 β were significantly lower in the mRNA analysis of the liver in group F compared to group C, there were no significant differences in the pathological findings of NASH such as liver steatosis and liver fibrosis in this model. In terms of tumor immunity, flow cytometry showed significantly more tumor-infiltrating CD8-positive T cells in group F compared to group C.

It was shown that FP, which acts on intestinal permeability, ameliorates NASH and suppresses NASH-related hepatocellular carcinoma. The mechanism may involve not only improvement of NASH but also alteration of tumor immunity. In recent years, drugs that improve intestinal permeability, such as lubiprostone, have been reported to improve liver steatosis, and it is expected that the improvement of intestinal permeability will also inhibit liver cancer.



Dr. Dan Nakano

Division of Gastroenterology, Department of Medicine, Kurume University
School of Medicine, Japan

SGLT2 inhibitor Suppressed Proliferation of Hepatocellular Carcinoma via Regulation of Metabolic Reprogramming and Tumor-releasing Chemokines/cytokines: A Metabolomic and Proteomic Analysis

Background: The proliferation of hepatoma is regulated by metabolic reprogramming. Sodium-glucose cotransporter 2 (SGLT2), an anti-diabetic agent, is recently reported to affect not only glucose metabolism but also cell proliferation. We investigated the expression of SGLT2 in human HCC tissues and the effect of SGLT2i on the suppression of hepatoma cells and its mechanism.

Methods: Human study: Human tissues of HCC were used in this study. These tissues were stained by an antibody for SGLT2. In vitro study: Hep3B was double-stained by an antibody for SGLT2 and mitochondria. A metabolomic and proteomic analysis evaluated intracellular metabolite and enzyme levels in Hep3B after the treatment (n=5). The difference in metabolites and enzyme levels between the SGLT2i and Control groups were analyzed by Wilcoxon signed-rank test.

Results: Human study: Human tissues of hepatocellular carcinoma were explained SGLT2. In vitro study: SGLT2 occurred in mitochondria of Hep3B cells. In a metabolomic analysis, there was a significant increase in metabolites associated with beta-oxidation activity, and beta-hydroxybutyrate levels in the SGLT2i group than in the Control group (530 ± 14 vs 854 ± 68 arbitrary unit). In proteomic analysis, one fatty acid enzyme, Stearoyl-CoA desaturase was significantly downregulated in the SGLT2i group compared to the control group (90.82 ± 5.18 vs 68.71 ± 5.07 P=0.0003).

Conclusion: Expression of SGLT2 was observed in human HCC tissue. Furthermore, we revealed that SGLT2i suppressed the proliferation of hepatoma cells with the regulation of fatty acid metabolism in mitochondria in hepatoma cells. Thus, SGLT2i may suppress the proliferation of hepatoma cells via the regulation of metabolic reprogramming.



Dr. Hirokazu Takahashi

Liver Center, Saga University Hospital, Japan

What Can We Do Now for the Management of Nonalcoholic Fatty Liver Disease to Prevent Hepatocellular Carcinoma?

Lifestyle-related disease strongly associates with pathogenesis of chronic liver disease and hepatocellular carcinoma (HCC). Particularly, nonalcoholic fatty liver disease (NAFLD) is the most popular chronic liver disease and considered as hepatic manifestation of lifestyle-related disease including obesity, metabolic syndrome, diabetes and dyslipidemia. Recent clinical and experimental studies identified that liver fibrosis is most significant risk for liver-related mortality and occurrence of HCC in NAFLD. To date, there is no established pharmacological therapy for NAFLD, whereas the optimization of the pharmacological therapy for concomitant lifestyle-related disease is important to improve the prognosis and hepatic outcome of NAFLD, probably including HCC. Moreover, effect of lifestyle modification such as diet therapy and exercise therapy on pathogenesis and prognosis of NAFLD should be determined. Prevention, surveillance and management of HCC in NAFLD is the urgent issue to be discussed. Management of lean and normal body weight NAFLD is also important issue, particularly in Asia.



Dr. Akemi Tsutsui

Department of Hepatology,
Kagawa Prefectural Central Hospital, Japan

Analysis of Factors Associated with the Prognosis of Cirrhotic Patients Who were Treated with V2-receptor Antagonist for Hepatic Edema

Background: We conducted a retrospective, multi-center collaborative study to identify the prognostic factors and clarify whether on-treatment factors, including conventional diuretic dosages and short-term response to tolvaptan (V2-receptor antagonist), affect the long-term prognoses in cirrhotic patients with hepatic edema.

Methods: Patients were initially instructed to receive salt-restricted diet therapy and conventional diuretics. When the BW of the patients remained unchanged on treatment, tolvaptan was orally administered at a dosage of 7.5 mg/day. Short-term responders to tolvaptan were defined as patients with BW loss of ≥ 1.5 kg from baseline to day 7.

Results: Patients consisted of 266 males and 141 females, with the median age of 68 years. The frequency of short-term responders to tolvaptan was 59.7%. In the Cox regression analysis, short-term response to tolvaptan, average dosages of furosemide and spironolactone during tolvaptan, Child-Pugh classification, and presence of hepatocellular carcinoma were independent factors associated with 1-year survival. The 1-year and long-term cumulative survival rates in short-term responders were significantly higher than those in non-responders ($P = 0.011$ and 0.010 , respectively). The long-term cumulative survival rates in patients who received a mean dosage of spironolactone < 23 mg/day during tolvaptan treatment period were significantly higher than those receiving a mean dosage of ≥ 23 mg/day ($P = 0.001$).

Conclusion: This study suggests that the short-term response to tolvaptan and low dosages of conventional diuretics during tolvaptan treatment improve the 1-year and long-term survival rates in cirrhotic patients with hepatic edema, irrespective of liver and kidney function and the presence of hepatocellular carcinoma.



Dr. Takamasa Ohki

Department of Cyber Knife and Hepatology,
Shioda Memorial Hospital, Japan


The Usefulness of Tolvaptan as a Treatment of Hepatic Edema among Decompensated Cirrhotic Patients

Backgrounds: For treatment of hepatic ascites, furosemide and spironolactone are generally used, but renal dysfunction and hyponatremia often occur in these patients. Tolvaptan (TLV), a selective oral vasopressin V2-receptor antagonist, which was approved for refractory hepatic edema and ascites (HEA) in Japan in 2013, is known to be effective without causing such adverse events. In this seminar we will show you our real clinical outcomes of TLV including HEA patients with advanced hepatocellular carcinoma (HCC).

Patients and Methods: We enrolled 192 decompensated cirrhotic patients with or without advanced HCC HEA using TLV between October 1st 2012 and September 31 2021. Patients were administered TLV 3.75-15.0 mg once daily. We defined the improvement of HEA as weight loss for more than 1.5 kg based on the Japanese treatment guideline of HEA. We divided the patients into two groups according to the improvement of HEA and compared the patients' backgrounds and OS between the two groups. We also analyzed the factors which contributed to the improvement of HEA and OS using multivariate analysis.

Results: Of the 192 patients, 126 patients (65.6%) were responder. The proportions of Child-Pugh class C and advanced HCC patients were significantly higher in non-responder group (43.7% vs. 69.7%, and 34.1% vs. 63.6%, each $P < 0.01$, respectively). Logistic regression multivariate analysis showed that Child-Pugh class C (OR: 0.39 $P = 0.043$), diluted urine (OR: 1.04 per 1%, $P < 0.01$), and first 24 hours urine volume after administration of TLV (OR: 1.21 per 100 mL) as independent factors related to the improvement of HEA. Presence of advanced HCC did not retain statistically significance. The median survival time was 119 days. Cox proportional hazard multivariate analysis showed that responder (HR: 0.56, $P = 0.011$), advanced HCC (HR: 3.36, $P < 0.01$), and sodium level (0.92 per 1mEq/L, $P < 0.01$), as independent factors related to OS.

Conclusions: TLV was useful for HEA among decompensated cirrhotic advanced HCC. Although presence of advanced HCC was not related to response, it was related to poor prognosis. In this program, I will show the whole data of TLV with case report.



Dr. Joji Tani

Department of Gastroenterology and Neurology,
Faculty of Medicine, Kagawa University, Japan

L-carnitine Reduces Hospital Admissions in Patients with Hepatic Encephalopathy

Aim: Hepatic encephalopathy is a common neuropsychiatric complication in patients with acute liver failure and advanced cirrhosis. The aim of this study was to determine whether oral L-carnitine administration reduces the blood ammonia concentration and number of hospital admissions for hepatic encephalopathy in patients with advanced cirrhosis.

Methods: Of 413 patients with hepatic encephalopathy treated with oral L-carnitine supplementation from April 2012 to March 2021, we enrolled 223 patients excluding exclusion criteria. We analyzed blood ammonia concentration, number of hospital admissions, and prognosis to determine how effective L-carnitine was in achieving mid-term to long-term suppression of recurrent hepatic encephalopathy.

Results: Median blood ammonia concentrations at the start, 1 week, 12 weeks, 24 weeks, and 48 weeks were 125, 98, 88.5, and 83 $\mu\text{g/dL}$, respectively. Blood ammonia concentrations 12 week, 24 weeks, and 48 weeks after L-carnitine administration were significantly lower than those at the start ($P < 0.0001$, respectively). The median ammonia normalization time after carnitine administration was 101 days. Initial carnitine dose was an independent factor in multivariate analysis. The median ammonia normalization time was 63 days for those with more than 1500 mg and 147 days for those with less than 1500 mg ($P=0.014$). During the 2 years prior to oral L-carnitine administration, the enrolled patients were hospitalized a total of 183 times for hepatic encephalopathy. However, during the 2 years following oral L-carnitine administration, they were admitted a total of 62 times for hepatic encephalopathy ($P < 0.001$). The median survival time was 31.6 months. The median survival time was significantly prolonged in patients with no history of hepatic encephalopathy ($P=0.0323$), no HCC ($P=0.0206$), and ALBI grade 1+2 ($P < 0.001$), respectively. Child-Pugh scores before and after oral L-carnitine administration differed significantly, whereas liver reserve function, nutritional status, and muscle index did not change significantly.

Conclusions: High-dose oral L-carnitine administration is effective and free of adverse effects in patients with hyperammonemia and reduces the number of hospital admissions for hepatic encephalopathy.



Dr. Kento Imajo

Department of Gastroenterology, Shin-yurigaoka General Hospital,
Kanagawa, Japan

Prediction of Esophagogastric Varices Using Splenic Stiffness Measurement by MR Elastography

Rupture of esophagogastric varices (EGV) associated with portal hypertension in patients with cirrhosis can be fatal, and their management is important. Esophagogastroduodenoscopy (EGD) is a reliable but invasive method for the diagnosis of EGV. In this study, we measured splenic stiffness measurement (SSM) and liver stiffness measurement (LSM) using MRE and investigated whether they are useful in picking up EGV. 516 patients with chronic liver disease (NAFLD; 212, HBV; 54, HCV; 181, PBC; 20, Alc; 46, IPH; 3) who underwent MRI (3T) and esophagogastroduodenoscopy (EGD) between 2017 and 2021 were enrolled. Diagnostic performance for EGV and high-bleeding risk varices (HRV) were evaluated using ROC curves. We also investigated whether the combined SSM/LSM with Fib4-index improves the avoidance rate for EGD and the positive predictive value (PPV). The AUROCs of SSM or LSM in detecting EGV and HRV were 0.88 (Cutoff; 9.51kPa) and 0.82 (Cutoff; 5.1kPa), and 0.85 (Cutoff; 10.1kPa) and 0.79 (Cutoff; 5.38kPa), respectively. The sensitivity (Se) and specificity (Sp) of SSM/LSM for EGV were 76.7%/75.3% and 89.8%/82.5%, respectively. On the other hand, the Se and Sp of SSM/LSM for HRV were 78.6%/75.0% and 76.8%/75.7%, respectively. In addition, the combined use of the Fib4-index also resulted in a further reduction in the number of EGV required and an improved PPV. MRE-SSM had superior diagnostic performance for the diagnosis of the presence of EGV and HRV compared with MRE-LSM. Furthermore, the addition of Fib4-index was found to be cost-beneficial.



Dr. Asahiro Morishita

Department of Gastroenterology and Neurology,
Faculty of Medicine, Kagawa University, Kagawa, Japan

The Efficacy of a Sodium Glucose co-transporter-2 (SGLT2) Inhibitor for the Treatment of Nonalcoholic Steatohepatitis and Liver Fibrosis

Asahiro Morishita, Tsutomu Masaki

Department of Gastroenterology and Neurology, Faculty of Medicine, Kagawa University, Kagawa, Japan

Background/Aim: SGLT2 inhibitors are a new type of glucose-lowering drugs for the treatment of type 2 diabetes mellitus. These mechanism of action is independent for pancreatic β -cell function and insulin resistance. Nonalcoholic steatohepatitis (NASH) is becoming an important public health concern and associated with insulin resistance and other metabolic risk factors such as type 2 diabetes mellitus, obesity, and dyslipidaemia. So far, various kinds of drugs have been used for the treatment of NASH, but these trials resulted in poor outcomes. The aim of this study is to determine therapeutic effects of SGLT2 inhibitors in NASH using Stelic Animal Model (STAM) mice, a validated animal model for NASH and liver fibrosis.

Methods: Eight-week-old male STAM mice were divided into 2 experimental groups and fed as follows: 1) high-fat diet (HFD) (control group); 2) HFD mixed with 16.7g/mouse/day of ipragliflozin, SGLT2 inhibitor (SGLT2I group). After 4 weeks, mice were sacrificed and blood samples and livers were collected. Livers were subjected to clinical parameters, histological study, mRNA and protein expressions for multiple genes, and microRNA analysis.

Results: SGLT2 inhibitor significantly decreased transaminases but not alkaline phosphatase. Histological examination revealed marked reduction of steatosis, ballooning, and inflammation in SGLT2I group. In addition, mice treated with SGLT2 inhibitor developed smaller area of liver fibrosis following fibrosis-related mRNA up-regulations. Furthermore, as for microRNA profiles, 15 microRNAs were up-regulated, and 16 microRNAs were down-regulated significantly in livers of SGLT2I group ($P < 0.05$). Unsupervised hierarchical clustering analysis showed that SGLT2I group clustered separately from control group.

Conclusion: SGLT2 inhibitor improved the clinical and histological development of NASH and liver fibrosis, and, thereby, might be a potential therapeutic medication for the treatment of liver fibrosis.



Dr. Ryuki Hashida

Department of Orthopedics Surgery,
Kurume University School of Medicine, Japan

In-Hospital Exercise Improved Frailty in Patients with Hepatocellular Carcinoma

Background: Frailty is associated with the survival and activities of daily living of patients with hepatocellular carcinoma (HCC). Recently, we have developed in-hospital exercise program for patients with HCC. We aimed to investigate the effects of in-hospital exercise on frailty in patients with HCC.

Methods: This was a multi-center observational study. Patients with HCC were classified into exercise (n=114) and non-exercise (n=67) groups. The exercise group was treated with a mixture of aerobic and resistance exercises (20–40 min/day, median four days). Frailty was assessed using the liver frailty index (LFI). Factors for changes in LFI were examined by multivariate and decision-tree analyses. The factors were also examined after propensity score matching.

Results: There was no significant difference in the prevalence of prefrail/frail between the two groups (79.8%/71.6%, $p=0.3368$). During hospitalization, LFI was significantly improved in the exercise group compared to the non-exercise group (delta LFI -0.17 vs. -0.02 , $p=0.0119$). In multivariate analysis, exercise (odds ratio (OR) 2.38, 95% confidence interval (CI) 1.240–4.570, $p=0.0091$) and females (OR 2.09; 95% CI, 1.062–4.109; $p=0.0328$) were identified as independent factors for the improvement of LFI. In the decision-tree analysis, exercise was identified as an initial classifier associated with the improvement of LFI. After propensity score matching, delta LFI in the exercise group was significantly lower than in the non-exercise group (delta LFI -0.2 vs. -0.03 , $p=0.0122$).

Conclusion: We demonstrated that in-hospital exercise improved frailty in patients with HCC. Thus, in-hospital exercise may be beneficial for improving physical function in patients with HCC.



Dr. Zihan Li

Department of Human Pathology,
Kanazawa University, Kanazawa, Japan

ATF3 is Involved in Regulating ACSL4 Expression to Promote Ferroptosis in Intrahepatic Cholangiocarcinoma

Zihan Li, Hiep Nguyen Canh, Kenta Takahashi, Dong Le Thanh, Yasunori Sato, Kenichi Harada
Department of Human Pathology, Kanazawa University, Kanazawa, Japan

Cell death mechanisms other than apoptosis in intrahepatic cholangiocarcinoma (iCCA) remain poorly clarified. Ferroptosis, distinct from apoptosis, is a regulated cell death caused by the accumulation of iron-based lipid reactive oxygen species, in which inhibition of glutathione peroxidase 4 (GPX4) plays a vital role. Meanwhile, acyl-CoA synthetase long-chain family member 4 (ACSL4) is also an essential driver of ferroptosis. Recent studies have shown that the regulative function of activating transcription factor 3 (ATF3) is in the progress of ferroptosis. In this study, we examined the presence of ferroptosis in iCCA by immunohistochemistry (IHC) staining for the ATF3, GPX4, and ACSL4. We collected a total of 69 surgical iCCA cases. Based on the degree of IHC staining, the cases were divided into strong positive, weak positive, and negative groups. To explore the regulation of ATF3, strong ATF3 positive regions in the samples were selected to detect the degree of GPX4 and ACSL4 co-expression. ATF3 expression was found in 92.75% (64/69) of iCCAs, with strong positivity mainly found in necrotic areas identified on HE staining. ACSL4 shows strong and diffuse positivity in 18/69 (26.09%) cases. In ATF3 strong positive areas, 85.11% (160/188) was also strongly positive and 13.83% (26/188) weakly positive for ACSL4. The figures for GPX4 were 47.87% (90/188) and 48.94% (92/188), respectively. These results suggest that ferroptosis is a common cell death mechanism in iCCA. ATF3 may be involved in regulating ACSL4, but not GPX4 expression, to promote ferroptosis.



Dr. Makiko Taniai

Internal Medicine, Institute of Gastroenterology, Tokyo Women's Medical University, Japan

Clinical Features and Risk Factors of Hepatocellular Carcinoma Rising from Alcohol-related Liver Disease

Makiko Taniai, Yuri Ogasawara, Kentarou Horiuchi, Tomomi Kogiso, Katsutoshi Tokushige
Internal Medicine, Institute of Gastroenterology, Tokyo Women's Medical University, Japan

Aims: In Japan, non-viral HCCs including with alcohol-related liver disease (ALD) are dramatically increasing. Obesity and type 2 diabetes mellitus (T2DM) have been shown to be risk factors for HCC. However, the pathogenesis for HCC in ALD is unclear. We conducted a clinicopathological study to clarify risk factors for developing HCC in ALD.

Methods: In these 30 years, 768 patients diagnosed as ALD without known other liver disease were enrolled to this study. To compare groups with or without HCC, we performed case-control study using logistic regression analysis and cohort study in ALD patients without HCC at starting point of observation by Cox Model. About the cases after 2014, we evaluated the features of microbiota and the presence of sarcopenia using next generation sequencer for stool samples, and defined <2.0 Shannon-Wiener index as severe dysbiosis and the presence of sarcomepia using the criteria of Asian Working group for sarcopenia 2014.

Results: The multivariate logistic analysis for HCC in all ALD patients revealed significant risk factors for HCC were older age, male gender, the presence of cirrhosis, and complication of T2DM, and in only cirrhotic ALD patients, older age, male gender, and severe dysbiosis. No significant genus was found associated with the presence of HCC in ALD about relative abundance. By Cox model, independent risk factors for HCC development were older age, male gender, the presence of cirrhosis, and the absence of sarcopenia.

Conclusion: HCCs mostly developed in ALD patients who had rather good nutrition with severe dysbiosis, and survived for long period.



Dr. Ritsuko Yokouchi

Cancer Center, Yamanashi Prefectural Central Hospital,
Japan

Prognosis of Hepatocellular Carcinoma after Confirmation of Overall Survival and Death - A 15-year Fixed Point Observation

Ritsuko Yokouchi¹, Naho Sato¹, Shuntaro Obi^{2,3}, Hitoshi Mochizuki^{2,4}, Masao Omata^{2,5}

¹Cancer Center, Yamanashi Prefectural Central Hospital, ²Gastroenterology, Yamanashi Prefectural Central Hospital, Yamanashi, Japan, ³Internal Medicine, Teikyo University Chiba Medical Center, Chiba, Japan, ⁴Genome Analysis Center, Yamanashi Prefectural Central Hospital, ⁵University of Tokyo, Tokyo, Japan

Objective: To evaluate and discuss whether the prognosis of liver cancer has improved since the introduction of sorafenib in 2009, and to evaluate and discuss new treatment modalities for advanced liver cancer in the era of combined immunotherapy.

Methods: All cases were classified by UICC (International Union for Cancer Control) stage according to tumor factors at the time of carcinogenesis: 326 were UICC stage I, 189 were stage II, 151 were stage III, and 113 were stage IV. The cancer registration period was divided into three periods: period I 2006-2011 (330 cases), period II 2012-2015 (196 cases), and period III 2016-2020 (253 cases). Median survival time (MST) for each stage was compared after death was confirmed in all cases.

Results: In Period I, the MSTs for UICC Stage I, II, III, and IV were 54.5, 36.9, 9.3, and 2.4 months, respectively. In Period II, The MSTs for UICC Stage I, II, III, and IV were 60.7, 24.6, 14.0, and 4.2 months, respectively. In Period III, the MSTs for UICC Stage I, II, III, and IV were Not reached, Not reached, 19.3, and 7.2 respectively.

Conclusion: In the future, treatment options will become increasingly complex. The pros and cons will be tested in practice with confirmed all-cause mortality data without bias, i.e., without dropouts. We would like to present this data as a reference, and a guide for clinical real-world practice.



Dr. Zhe Zhang

Department of Metabolic Regulation,
Shinshu University School of Medicine, Matsumoto, Japan

Dietary Fat Composition Affects Hepatic Angiogenesis and Lymphangiogenesis in HCV Core Gene Transgenic Mice

Zhe Zhang¹, Pan Diao¹, Xiaojing Wang¹, Takefumi Kimura², Naoyuki Fujimori³, Yasuyuki Ichise⁴, Michiharu Komatsu⁵, Makoto Nakamuta⁶, Jun Nakayama⁷, Naoki Tanaka^{8,9,10}

¹Department of Metabolic Regulation, Shinshu University School of Medicine, Matsumoto, Japan, ²Department of Gastroenterology, Shinshu University School of Medicine, Matsumoto, Japan, ³Department of Gastroenterology, Shinshu Ueda Medical Center, Ueda, Japan, ⁴Digestive Disease Center, Showa Inan General Hospital, Komagane, Japan, ⁵Department of Gastroenterology, Suwa Red Cross Hospital, Suwa, Japan, ⁶Department of Gastroenterology, Kyushu Medical Center, Fukuoka, Japan, ⁷Department of Molecular Pathology, Shinshu University School of Medicine, Matsumoto, Japan, ⁸Department of Global Medical Research Promotion, Shinshu University Graduate School of Medicine, Matsumoto, Japan, ⁹International Relations Office, Shinshu University School of Medicine, Matsumoto, Japan, ¹⁰Research Center for Social Systems, Shinshu University, Matsumoto, Japan

Previous research demonstrated that isocaloric diet rich in trans fatty acid (TFA), saturated fatty acid (SFA), and cholesterol (Chol) promoted hepatic tumorigenesis in hepatitis C virus core gene transgenic (HCVcpTg) mice. Growth factor signaling and ensuing angiogenesis/lymphangiogenesis are key factors in liver tumorigenesis and recent therapeutic targets for hepatocellular carcinoma (HCC). This study aimed to investigate whether the types of dietary fat would give an impact on hepatic angiogenesis and lymphangiogenesis.

Male HCVcpTg mice were treated with a control diet and an isocaloric diet containing 1.5% Chol (Chol diet), diet replacing soybean oil to shortening (TFA diet), or hydrogenated coconut oil (SFA diet). The extent of angiogenesis/lymphangiogenesis and expression of growth factors including fibroblast growth factors (FGF), vascular endothelial growth factors (VEGF), and platelet-derived growth factors (PDGF) in non-tumor liver tissue were assessed by Western blot analysis and immunohistochemistry.

Long-term feeding of SFA and TFA diet to HCVcpTg mice increased the expression of CD31, TEK tyrosine kinase (Tie2), and lymphatic vessel endothelial hyaluronan receptor 1, indicating enhanced angiogenesis/lymphangiogenesis. This promoting effect was correlated with elevated VEGF-C and FGF receptor 2 expression levels in the liver, likely due to enhancing hypoxia-inducible factor (HIF) 1 α . The Chol diet significantly increased the expression of growth factors FGF2 and PDGF subunit B (PDGF-B), without any impact on angiogenesis/lymphangiogenesis.

These results illustrate that diet rich in SFA and TFA, but not Chol, may stimulate hepatic angiogenesis/lymphangiogenesis through the HIF1 α -VEGF-C axis and provide that the importance of dietary fat species for preventing hepatic tumorigenesis.

APASL Oncology 2022 Takamatsu

*“Liver Cancer: Clinical and Basic
Research”*

Abstracts

Sponsored Seminars





Dr. Nobuhiro Nakamoto

Division of Gastroenterology and Hepatology, Department of Internal Medicine, Keio University School of Medicine, Japan

Future Prospects for Hepatocellular Carcinoma Treatment Through Immune Control

Cancer cells proliferate through various mechanisms. Activated cytotoxic T cells (CTLs), which play a central role in the immune response to cancer cells, normally infiltrate the tumor, recognize and kill cells. However, cancer cells escape the immune surveillance mechanism by decreasing the antigen recognition ability of CTLs and changing to immunosuppressive tumor microenvironment. One of the mechanisms is considered to be inactivation of T cells by binding of PD-L1 expressed in cancer cells and PD-1 on T cells. Immune checkpoint inhibitors (ICIs) block the PD-1 / PD-L1 pathway to restore the cancer immune response of T cells and induce apoptosis of cancer cells.

The action of vascular endothelial growth factor (VEGF) is also considered to be the factor in the process of tumor growth. In addition to angiogenesis, it has been reported that VEGF inhibits dendritic cell maturation, induces regulatory T cells (Treg) and myeloid-derived suppressor cells (MDSCs), and suppresses CTL invasion into tumors by FasL expression. VEGF is also known to act as immunosuppressively in the tumor microenvironment.

Hepatocellular carcinoma (HCC) has generally been considered as “cold tumors” with few immune cells infiltrating the tumor and ICIs are less effective. However, it is known that the combined use of the anti-PD-L1 antibody atezolizumab and the anti-VEGF antibody bevacizumab affects the cancer immune response. For example, atezolizumab + bevacizumab has the following effects; (1) maturation of dendritic cells, efficiently priming and activation of T cells, (2) normalization of tumor blood vessels and promotion of tumor invasion of T cells, and (3) inhibiting the activation of MDSCs and Treg, tumor microenvironment changes from immunosuppressive to immune responsive.

In the treatment of HCC, the development and clinical introduction of immunotherapy are progressing, and various treatment methods such as combined use of immunotherapy and TACE are investigated. In addition, the utility of biomarkers such as immune cells, driver gene mutations, and gut bacteria is examined in order to identify patients who can obtain the therapeutic effect of ICIs. In this presentation, we will introduce the future prospects of HCC treatment, focusing on the effect on the tumor microenvironment.



Dr. Kaoru Tsuchiya

Department of Gastroenterology and Hepatology, Musashino Red Cross Hospital, Japan

Recent Advances in Systemic Therapy for Unresectable Hepatocellular Carcinoma ~Atezolizumab Plus Bevacizumab Therapy in Real-world Practice~

The treatment strategy for hepatocellular carcinoma (HCC) is determined by considering the liver function reserve and the degree of tumor progression. In principle, if curative treatment is possible, it's given to priority, and if not possible, the treatment should be decided in consideration of the patient's prognosis and maintenance of QOL. Currently, the drugs expected to response has increased, which has changed treatment strategy. TACE has long been the standard treatment for intermediate stage HCC (BCLC-B), but systemic therapy is recommended for the patients with up-to-seven out and TACE-resistant tumors. In addition, treatments aiming for cure are investigated by combining systemic therapy and locoregional therapy such as TACE.

In systemic therapy for unresectable HCC, immune checkpoint inhibitors have been clinically introduced. In a global phase III IMbrave150 trial comparing atezolizumab + bevacizumab (Atezo+Bev) with sorafenib as first-line treatment, the superior of Atezo+Bev was validated in the primary endpoint, overall survival (OS) and progression-free survival (PFS). The hazard ratio (HR) for OS and PFS by independent review facility (IRF)-assessed RECIST v1.1 were 0.58 ($p=0.0006$), 0.59 ($p<0.0001$), respectively. Based on this result, Clinical Practice Guidelines for Hepatocellular Carcinoma 2021 state that it should confirm the indication of Atezo+Bev, and if there is an indication, Atezo+Bev is recommended. If there is no indication of Atezo+Bev due to comorbidities such as autoimmune diseases, sorafenib or lenvatinib is recommended.

In the updated analysis of the IMbrave150 trial, median OS was 19.2 months in the Atezo+Bev arm and 13.4 months in the sorafenib arm, median PFS by IRF-assessed RECIST v1.1 was 6.9 months and 4.3 months, respectively. The HR for OS and PFS were 0.66, 0.65, respectively. Secondary endpoints, objective response rates by IRF-assessed RECIST v1.1 were 29.8% in the Atezo+Bev arm and 11.3% in the sorafenib arm. In the Atezo+Bev arm, proteinuria (29%) and hypertension (28%) were observed as the most treatment related adverse events, and it should be noted that immune-related adverse events (irAE) such as liver dysfunction and skin disorders. In clinical practice, treatment options are increasing, and it's important to continue treatment while maintaining liver function reserve for long survival. It is considered that the importance of side effect management such as irAE. In this presentation, we will introduce recent treatment strategies for unresectable HCC and management of Atezo+Bev based on clinical experience and new findings.



Dr. Naoshi Nishida

Department of Gastroenterology and Hepatology,
Kindai University Faculty of Medicine, Japan

Role of Medical AI for the Management of Liver Disease in the Era of Viral Elimination—Development of AI-aided US Diagnosis for Focal Liver Lesions—

With the development of diagnosis and treatment of diseases, the data required for medical care are becoming complex, and misinterpretation of information due to human error may result in serious consequences. Human error can be avoided with the support of artificial intelligence (AI). AI models trained with various medical data for diagnosis and management of liver diseases have been applied to hepatitis, fatty liver disease, liver cirrhosis, and liver cancer. Some of these models have been reported to outperform human experts in terms of performance, indicating their potential for supporting clinical practice given their high-speed output.

For the detection and diagnosis of liver tumor, we have developed the AIs for B-mode ultrasonography (US). We constructed four AI models that discriminate four types of liver tumor, cyst, hemangioma, hepatocellular carcinoma, and metastatic tumors: model-1 using 24,675 images, model-2 using 57,145 images, model-3 using 70,950 images, and model-4 using 83,568 images. We also developed the AI that discriminate intrahepatic cholangiocarcinoma from other types of tumors. A convolutional neural network was used for developing computer aided diagnosis (CADx). The diagnostic performances of the AI models and human experts were compared using independent test video images, where the AI models surpassed that of human experts. For computer aided detection (CADe), we used YOLOv5 for real-time detection of liver tumors; the recall, precision, and F-value was more than 0.9. In the B-model video image recorded before RFA procedure, the CADe model successfully detects a small metastasis of HCC in addition to the main tumor. These AI models will help prevent human errors in US diagnosis.



Dr. Atsushi Hiraoka

Gastroenterology center, Ehime Prefectural Central Hospital, Japan

Total Therapeutic Management of Liver Disease

The liver is a central organ that controls metabolic nutrition. Nutritional status generally becomes worse with progression of liver damage. Recent developments of anti-viral drugs have made prognosis of chronic liver disease patients (CLD) patients improved. However, there have been still any complications such as hepatic encephalopathy, sarcopenia, muscle cramp related to metabolism, in CLD patients, especially in liver cirrhosis (LC) patients. Notably, decompensated LC often complicates protein-energy malnutrition (PEM). PEM often relates to sarcopenia or muscle cramp. In addition, harmful alcohol use has become to be a clinical issue in the recent pandemic of COVID-19. In this seminar, I would like to talk about the progressions and issues in the field of complications of CLD including LC in Japan.



Dr. Hideki Kamada

Department Gastroenterology and Neurology, Faculty of Medicine, Kagawa University, Japan

Treatment Strategies for Acute Cholangitis

Acute cholangitis can easily be complicated by sepsis due to increased intrabiliary pressure, and in severe cases may be accompanied by disseminated intravascular coagulation.

Decompression of intrabiliary pressure by biliary drainage is important in the treatment of cholangitis. Management of disseminated intravascular coagulation is also important in severe cases.

In this lecture, I will discuss the technique of endoscopic biliary drainage for acute cholangitis and management of disseminated intravascular coagulation associated with cholangitis.



Dr. Masanori Atsukawa

Gastroenterology and Hepatology, Japan

Real-world Direct-acting Antivirals Treatment for Chronic Hepatitis C Patients with Chronic Kidney Disease in Japan

In Japan, the number of HCV-infected patients is estimated to be 1.5-2 million. The objective of treatment for chronic hepatitis C patients is to eliminate HCV, prevent progression to liver cirrhosis and hepatocellular carcinoma, and improve the prognosis and quality of life. It was recently reported that HCV infection is also associated with death related to multiple organs other than liver disease and early treatment intervention is recommended.

Interferon-free direct-acting antivirals (DAAs) became available in 2014 in Japan ahead of Western countries. Currently, Pibrentasvir/Glecaprevir, Sofosbuvir/Ledipasvir and Sofosbuvir/Velpatasvir±ribavirin are available in Japan. The indications and recommendation of each regimen is decided based on the HCV genotype and presence of decompensated liver cirrhosis.

The median age of Japanese chronic hepatitis C patients is approximately 70 years old. Moreover, a decline in renal function at a high frequency in the elderly was reported. The rate of chronic kidney disease (CKD) patients aged 70 years or older with an estimated glomerular filtration rate (eGFR) <60 mL/min/1.73 m² is approximately 27% in males and 31% in females. In addition, the HCV antibody-positive rate is approximately 5% in hemodialysis patients, being higher than that in the general population, and 60% are considered to have persistent HCV infection. Unfortunately, as the intermediate metabolites of sofosbuvir are metabolized in the kidney, their administration is contraindicated for patients with severe renal impairment in Japan. Therefore, administrable regimens for patients with CKD, including hemodialysis patients, are limited to Pibrentasvir/Glecaprevir.

For Pibrentasvir/Glecaprevir combination therapy, the results of CERTAIN-1 and CERTAIN-2 studies performed as domestic phase 3 studies were previously reported. The rate of SVR to Pibrentasvir/Glecaprevir combination therapy was investigated in patients with severe renal dysfunction and hemodialysis patients in the domestic phase 3 study CERTIN-1, but the number of patients was small.

Thus, we performed a prospective multicenter study, and would like to give a presentation regarding the efficacy and safety of Pibrentasvir/Glecaprevir combination therapy in patients with CKD stage 4 and 5.



Dr. Masayuki Kurosaki

Executive Vice-President of Musashino Red Cross Hospital,
Director of the Department of Gastroenterology and Hepatology,
Musashino Red Cross Hospital, Japan

Real-world Evidences of Systemic Therapy for Hepatocellular Carcinoma

Atezolizumab + Bevacizumab has become a standard of systemic therapy for unresectable hepatocellular carcinoma (HCC). Clinical question remains on the optimal treatment strategy for the intermediate stage HCC where TACE, systemic therapy including multi-kinase inhibitors, and the combination of both could be the choice. Other important questions may be the management of common adverse events such as proteinuria, selection of systemic therapy regimens after progress disease, or the timing of conversion therapy for those with favorable response. These points will be discussed in this presentation.



Dr. Hideki Iwamoto

Kurume University School of Medicine, Division of Gastroenterology,
Department of Medicine / Iwamoto Internal Medicine Clinic, Japan

Importance of Keeping the Balance between Therapeutic Effects and Adverse Events in Lenvatinib for HCC

~Refinement of Administration Schedule and Combination with Trans-Arterial Therapy~

Background: Lenvatinib is an effective and evidenced molecular targeted agent (MTA) with a high response rate for unresectable hepatocellular carcinoma (HCC). On the other hand, lenvatinib is a drug that is difficult to be administered in long term because of the development of adverse events (AEs). Therefore, it is essential for long-term administration of lenvatinib to keep the balance between therapeutic effects and AEs by refinement in lenvatinib treatment.

Material and Methods:

1. We retrospectively assessed the therapeutic effects and AEs of 135 patients treated with lenvatinib and the improvement of tolerability and therapeutic efficacy of 30 patients treated with the weekends-off administration method (5 days-on/2 days-off).
2. We retrospectively assessed the therapeutic effects of 132 patients with intermediate HCC treated with lenvatinib monotherapy (n=79) and lenvatinib combined with trans-arterial therapy (alternating therapy/AT, n=53).

Results:

1. The incidence rates of AEs were 82.1% at any grade and 49.6% at over grade 3. Fatigue was the most important AE which caused dose reduction and discontinuation of treatment. Of the 30 patients who received weekends-off lenvatinib, 66.7% of patients tolerated the AEs and 61.5% of patients revealed improvement in the therapeutic response. The weekends-off lenvatinib significantly prolonged the administration period ($p<0.001$).
2. The patients who could administer AT with lenvatinib and trans-arterial therapy showed significantly longer overall survival than lenvatinib monotherapy (AT: not reached, monotherapy 17.8 months, $p<0.01$). The factors which could administer AT were younger age (under 80 years old) and preserved liver function (modified Albumin-bilirubin grade 1/2a). The median administration period was 466 and 168 days in AT and lenvatinib monotherapy, respectively ($p<0.001$).

Conclusion: These results suggested that refinement of administration schedule and combination therapy between lenvatinib and trans-arterial therapy was promising for long-term administration of lenvatinib.



Dr. Junichi Shindoh

Department of Gastroenterological Surgery, Toranomon Hospital, Japan

The Dawn of New Surgical Strategy for Advanced Hepatocellular Carcinoma

With the introduction of new molecular targeted agents and immune check point inhibitors, an increasing number of patients with advanced hepatocellular carcinoma (HCC) is benefiting from salvage interventions. However, given the complex background of the disease and frequent presence of underlying liver injury, treatment of advanced HCC is rather complex and the treatment principle applied to colorectal liver metastases, for which conversion surgery has been actively performed, is often not applicable to patients with HCC. While successful conversion to curative-intent resection after intensive systemic therapy for advanced HCC has been increasingly achieved, there still remain several unresolved questions, such as the optimal situation for conversion, optimal timing of conversion surgery, and true prognostic advantages of conversion surgery for HCC. In this talk, the theoretical bases for the management of HCC will be revisited and our strategies to maximize the survival outcomes in patients with advanced HCC will be discussed with updated evidence.



Dr. Yuzo Kodama

Professor, Department of Gastroenterology,
Kobe University School of Medicine, Japan

Current Status and Future of AI in Digestive Disease

Owing to the recent advancement in deep learning algorithms, artificial intelligence (AI) has achieved specialist-level diagnostic performance in certain medical fields like gastroenterology.

Within the realm of hepatobiliary and pancreatic neoplasia, an increase in the incidence of pancreatic ductal adenocarcinoma (PDAC) has been reported in recent years. PDAC is associated with a very unfavorable prognosis, as the 5-year overall survival rate (OS) has been reported to be as low as 10%. However, those with localized disease show an improved 5-year OS of 40%, demonstrating the value of early diagnosis.

In clinical settings, major modalities used to diagnose hepatobiliary and pancreatic disease include computed tomography (CT), magnetic resonance imaging (MRI), endoscopic retrograde cholangiopancreatography (ERCP), ultrasonography (US), and endoscopic ultrasonography (EUS). These imaging modalities are used in part because obtaining a biopsy sample is more difficult than in the gastrointestinal tract.

Nevertheless, there are few outstanding issues regarding the interpretation of images collected through the above modalities.

For one, the interpretation of CT or MRI images is usually performed by radiologists. Even among large institutions, receiving the final report from radiology takes time. At small institutions, a radiologist may not be available to interpret the imaging. Furthermore, errors of misdiagnosis or missed diagnosis may occur due to human error or the effects of heavy workload.

Although US is a relatively convenient and non-invasive tool, effective use of US requires a significant level of technical skill and expertise. As such, US remains a highly operator-dependent imaging modality associated with frequent inter-observer differences in diagnostic performance. EUS and ERCP are associated with a similar set of issues.

The use of AI-driven diagnostic tools has the potential to resolve these issues through instant and reproducible image interpretation.

Currently, several AI devices for gastrointestinal endoscopy are being utilized in clinical settings. In technical terms, CT, MRI, and US imaging are considered less complex and information-dense than endoscopic imaging. Consequently, AI can effectively interpret images gathered through these modalities. Furthermore, AI interpretation of these images is aided by the fact that they are typically collected in a standardized fashion and stored using a common Digital Imaging and Communications in Medicine (DICOM) format.

Herein, we summarize recent progress and discuss the prospects of using AI to interpret imaging of hepatobiliary and pancreatic disease.



Dr. Tomohiro Tada

AI Medical Service Inc. Tada Tomohiro,
The Institute of Gastroenterology & Proctology, Japan

Taking on the World with Japanese Endoscopic AI

In recent years, AI's image diagnostic capability has surpassed human beings due to three factors, which are, deep learning (CNN: convolutional neural network), high-performance computer (GPU), and a large amount of digitized image data. In application of AI to gastrointestinal endoscopy, Japanese endoscopists have shown their presence by presenting the world's first achievements one after another.

AI application to detect gastric cancer (GC) was first reported by Hirasawa et al. [1] marking 98.6% sensitivity for cancers with diameter of 6 mm or more. Ishioka et al. applied the system to videos, and the results were similar to those with still images, 94.1% sensitivity. [2] Furthermore, according to Ikenoyama et al, using still images, AI's sensitivity to detect GC was significantly higher than 67 endoscopists with a difference of 26.5% (58.4% vs 31.9%). [3]

Horiuchi et al,[4] and Ueyama et al, [5] reported AI's high accuracy to diagnose GC based on magnifying endoscopy with narrow-band imaging (ME-NBI). Also, Horiuchi et al, reported the sensitivity of AI was 87.4% for ME-NBI videos in diagnosing GC which is equivalent to experts. [6]

Namikawa et al. developed an AI to diagnose gastric ulcer (GU), which could distinguish GC from GU by 99% sensitivity.[7] Nagao et al. reported that AI could predict the invasion depth of GC with 94.5% sensitivity.[8]

In this presentation, I will look back at the past achievements about the endoscopic AI for GC and then introduce you to the latest status of our development. In addition, I will explain the future prospects of endoscopic AI which will prevail around the world.

[1] Hirasawa T et al. Gastric Cancer. 2018;21:653-660.

[2] Ishioka M et al. Dig Endosc. 2019 Mar;31(2):e34-e35.

[3] Ikenoyama Y et al. Dig Endosc. 2020;10.1111/den.13688.

[4] Horiuchi Y et al. Dig Dis Sci. 2020;65(5):1355-1363.

[5] Ueyama H et al. J Gastroenterol Hepatol. 2020;10.1111/jgh.15190.

[6] Horiuchi Y et al. Gastrointest Endosc. 2020;92(4):856-865.

[7] Namikawa K et al. Endoscopy. 2020 ;10.1055/a-1194-8771.

[8] Nagao S et al. Gastrointest Endosc. 2020;92(4):866-873.



Dr. Ken Haruma

Department of General Internal Medicine 2, Kawasaki Medical School
General Medical Center, Japan

Positioning of Vonoprazan and Its Safety - Seven Years of Clinical Experience in Japan

Vonoprazan is a potassium-competitive acid blocker (P-CAB), a new gastric acid secretion inhibitor that competitively inhibits the proton pump and solves the problems associated with conventional Proton Pump Inhibitors (PPIs). Vonoprazan has the following advantages: 1) it is acid-stable and water-soluble, 2) it inhibits the proton pump through a different mechanism of action than conventional PPIs, 3) it has a long half-life in blood and acts rapidly, 4) it is not affected by genetic polymorphisms of metabolic enzymes, 5) it is basic and acid stable and does not require gastric acid to inhibit the proton pump. Therefore, vonoprazan has a strong inhibitory effect on gastric acid secretion. Japan became the first country in the world where vonoprazan has been available for use in medical practice since February 2015, mainly for acid-related diseases. Currently, vonoprazan is covered for gastric ulcer, duodenal ulcer, reflux esophagitis, prevention of recurrence of gastric or duodenal ulcer during low-dose aspirin administration and non-steroidal anti-inflammatory drug administration and *Helicobacter pylori* eradication. As vonoprazan has a stronger inhibitory effect on gastric acid secretion than conventional PPIs, there are concerns about various side effects, mainly gastric tumors, but seven years have already passed since vonoprazan was launched in Japan. In this lecture, the position of vonoprazan in acid-related diseases in Japan and the data accumulated so far on its safety will be presented.

APASL Oncology 2022 Takamatsu

“Liver Cancer: Clinical and Basic Research”

Abstracts

Oral Free Papers



Up-regulation of the Epithelial Mesenchymal Transition Genes in a Chemically Induced-hepatocellular Carcinoma Rat Model

Vichununt Kerdput¹, Ratchadaporn Pramong¹, Udomsri Showpittapornchai¹, Wouter H Lamers², Wisuit Pradidarcheep¹

¹Department of Anatomy, Faculty of Medicine, Srinakharinwirot University, Bangkok, Thailand,

²Tytgat Institute for Liver and Intestinal Research, Amsterdam University Medical Centers, Amsterdam, The Netherlands

Hepatocellular carcinoma (HCC) is a primary liver cancer commonly found in adults. Animal models are commonly used to elaborate the understanding of HCC pathogenesis. Gene expression analysis is a recent approach to gain knowledge on the tumor development and progression. The present study aimed to analyze the molecular pathways using RNA sequencing (RNA-seq) in the HCC rat induced by diethylnitrosamine (DEN) and thioacetamide (TAA). After sacrifice, the liver tissues from the HCC-bearing and control rats were collected. All RNA-seq data were subjected to pathway enrichment analysis, using the Molecular Signatures Database. The RNA-seq data of DEN/TAA-treated rats exhibited the upregulation of 16 hallmark pathways, including epithelial mesenchymal transition (EMT) pathway which showed the most significant ($p < 0.01$). A total of 160 different up-regulated genes in this pathway were identified. Real-time PCR was used to validate the RNA-seq data. It revealed that the EMT-related genes including *Igfbp2*, *Lamc2*, *Col1a1*, *Wnt5a*, and *Edil3* were up-regulated. The strong expression of EMT-involved genes in this HCC rat model might promote the development and progression of HCC tumor area. We propose that the identified genes involving in the EMT pathway provide a new prognostic and diagnostic tool and might be a promising therapeutic target for HCC.

CHI3L1 Detects over 12% of AFP/AFP-L3/DCP Triple Negative HCC Cases and the Four-biomarker Panel Offers Much Improved Performance for HCC Diagnosis

Biaoyang Lin

University of Washington

Background: Chitinase 3 like protein 1(CHI3L1) is liver enriched protein involved in the activation of astrocytes and macrophages in the liver. Here we aim to study whether CHI3L1 have added value to improve HCC diagnosis alone or in combination with AFP, AFP-L3 and DCP.

Methods: We analyzed the serum levels of CHI3L1, AFP, AFP-L3 and DCP for 847 clinically diagnosed HCC cases (The HCC group) and 400 healthy individuals (the healthy group). ROC analysis was conducted for the individual marker and their combinations.

Results: The serum level of each of the four biomarker CHI3L1, AFP, AFP-L3 and DCP was statistically significantly higher in the HCC group compared with the healthy group ($P < 0.001$). ROC analysis showed that the AUC and the Kappa values for diagnosing HCC using CHI3L1 were 0.906 and 0.665 respectively with the optimal cutoff values of 72.68 ng/ml for the dataset, which surpassed the performance of any of the three single biomarkers. The combination of CHI3L1 with AFP, AFP-L3 and DCP further improved the performance with an AUC and the Kappa values of 0.977 and 0.845 respectively. In addition, CHI3L1 alone help to identify 107 cases (12.63%) of AFP, AFP-L3, DCP triple negative HCC cases in 847 cases using the cutoff values of 72.68 ng/ml.

Conclusion: CHI3L1 detects over 12% of AFP/AFP-L3/DCP triple negative HCC cases and the four-biomarker panel using CHI3L1, AFP, AFP-L3 and DCP offers much improved performance for HCC diagnosis.

Evaluation of Remnant Liver Volume on Postoperative Liver Failure in Right Hemihepatectomy for Hepatocellular Carcinoma

Chikato Koga, Masanori Tsujie, Soichichiro Mori, Kentaro Nishida, Akinobu Yasuyama, Masatoshi Nomura, Yukihiro Yoshikawa, Toshinori Sueda, Hiromichi Miyagaki, Mituyoshi Tei, Yusuke Akamaru

Department of Surgery, Osaka Rosai Hospital, Japan

Background/Aim: The future liver remnant is usually calculated as a ratio of the remnant liver volume (RLV) to the total functional liver volume (RLV/TFLV). In liver transplantation, it is generally accepted that the ratio of the graft volume to standard liver volume (SLV) needs to be at least 30% to 40% to fit the hepatic metabolic demands of the recipient. The aim of this study was to compare RLV/TFLV versus RLV/SLV as a predictor of postoperative liver failure after right hemihepatectomy.

Patients and Methods: A total 14 patients with Liver damage A underwent right hemihepatectomy for hepatocellular carcinoma at our hospital from April 2011 to December 2021. CT volumetric measurements of RLV and TFLV were obtained by SYNAPSE VINCENT. SLV was calculated by the Urata's formula. Posthepatectomy liver failure (PHLF) was defined by ISGLS criteria.

Result: The median age of 14 cases was 71 years (49-79), 12 males and 2 females. One case underwent PTPE before surgery. All cases were operated by laparotomy. The median operation time was 256 minutes (131-477) and the bleeding volume was 1528 ml. The weight of the resected liver was 560 g (324-1528). The tumor diameter was 67.5 mm (31-145). PHLF occurred in 7 patients (21.9%); grade B in 5 patients, and grade C in 2 patients. PHLF of grade C was occurred in the only group with the RLV/SLV <40% (p=0.011). RLV/TFLV was not correlated with PHLF (p=1.000).

Conclusion: RLV/SLV was more useful than RLV/TFLV in predicting the postoperative liver failure after right hemihepatectomy.

Validity of 5-5-500 Criteria from the Viewpoint of Microvascular Invasion in Hepatectomy Cases

Kohei Ogawa, Katsunori Sakamoto, Naotake Funamizu, Kei Tamura, Masahiko Honjo,
Mio Uraoka, Mikiya Shine, Yasutsugu Takada
HBP and Breast Surgery, Ehime University, Japan

Introduction: The frequency of recurrence after liver transplantation is high in hepatocellular carcinoma cases with microvascular invasion. In this study, we investigated the relation between microvascular invasion and preoperative data including tumor markers in hepatectomy cases for hepatocellular carcinoma.

Patients and Methods: From October 2003 to December 2021, 190 hepatectomies for HCC excluding re-hepatectomy and cases with macrovascular invasion were enrolled.

Results: Of the 190 cases, 65 (34%) were outside Milan, 58 (31%) were outside 5-5-500, 78 (41%) were outside Kyoto. There were 14 cases (7%) with AFP exceeding 500 ng / ml and 51 cases (27%) with DCP exceeding 400 ng / ml. Microvascular invasion was observed in 51 (27%) of 190 cases. The frequency of microvascular invasion is inside Milan vs outside: 22% vs 35% ($p = 0.055$), inside 5-5-500 vs outside: 23% vs 35% ($p = 0.115$), inside Kyoto vs outside: 22% vs 33% ($p = 0.092$), AFP <500 vs >500: 25% vs 54% ($p = 0.048$), DCP <400 vs >400: 20% vs 44% ($p = 0.001$). Next, the relation between microvascular invasion and tumor marker was examined in only 5-5 cases in order to investigate the usefulness of adding tumor markers to the expansion criteria. The frequency of microvascular invasion was AFP <500 vs >500: 24% vs 63% ($p = 0.027$) and DCP <400 vs >400: 22% vs 42% ($p = 0.032$), with significant difference.

Conclusion: It was suggested that the frequency of microvascular invasion could be reduced by adding tumor markers to selection criteria even tumor size and number was expanded.

Atezolizumab plus Bevacizumab in Patients with Unresectable Hepatocellular Carcinoma: A Single-center Experience

Akio Moriya, Yoshiaki Matsumura, Yusuke Aya, Masaharu Ando

Department of Gastroenterology, Mitoyo General Hospital, Kanonji, Japan

Background: The 2022 update of BCLC recommends the combination of atezolizumab with bevacizumab as a first-line treatment for unresectable hepatocellular carcinoma.

Methods: In a clinical setting, we evaluated background, adverse events, and efficacy in 16 patients (male, 81%; median age, 74 years old) treated with atezolizumab plus bevacizumab for hepatocellular carcinoma.

Results: Among the patients, BCLC stage (A/B/C/D), ECOG PS (0/1), and ALBI grade (1/2/3) were 6%/25%/50%/19%, 69%/31%, and 19%/62%/19%, respectively. HBV, HCV, and non-viral etiologies were 25%, 25%, and 50%, respectively; 44% had extrahepatic metastases (3 in lung, 1 in bone, 1 in extra-regional lymph node, 1 in adrenal gland, and 1 in muscle) and 12% had major vascular invasion. Atezolizumab and bevacizumab was administered as the 1st line systemic chemotherapy in 63%, 2nd line in 25%, and 3rd line in 12%. In 3 patients, the treatment was discontinued after the first course due to serious adverse events (pneumonia, heart failure, or disseminated intravascular coagulation syndrome). Other two patients discontinued after the second course or later due to adverse event; eight patients discontinued due to progressive disease. The response rate was 25% and the disease control rate was 67%. Nine of the discontinued cases received other systemic chemotherapies. Median overall survival was 462 days (95% confidence interval, 365-N.A.) and median time to treatment failure was 63 days (41-127).

Conclusions: The combination of atezolizumab with bevacizumab was useful as a treatment for unresectable hepatocellular carcinoma. Serious adverse events could occur just after the first course.

Therapeutic Response of Atezolizumab plus Bevacizumab Therapy for Unresectable Hepatocellular Carcinoma: A Single Center Experience

Tomohiro Nishikawa¹, Keisuke Yokohama¹, Hiroki Nishikawa¹, Kosuke Ushiro¹,
Masahiro Matsui¹, Hideko Ohama², Akira Asai¹, Shinya Fukunishi¹, Shirou Nakamura¹

¹2nd Department of Internal medicine, Osaka Medical and Pharmaceutical University, Japan,

²Ehime Prefectural Central Hospital, Japan

Background/Aim: Atezolizumab combined with bevacizumab therapy (Atez/Bev) is the approved first-line systemic chemotherapy for unresectable hepatocellular carcinoma (HCC) in our country. This study aimed to elucidate the treatment efficacy and safety in patients with unresectable HCC undergoing Atez/Bev in our hospital.

Methods: A total of 22 patients with unresectable HCC treated with Atez/Bev were analyzed (median age = 76 years, 16 males, etiology B/C/alcohol/other = 4/6/5/7, median ALBI score = -2.39, BCLC-B: C = 7: 15). Seventeen patients received Atez/Bev as an initial systemic chemotherapy. Therapeutic response was retrospectively evaluated using modified Response Evaluation Criteria in Solid Tumors (mRECIST).

Results: Median PFS was 7.8 months (95% confidence interval = 5.1-NA). Objective response rate and disease control rate at 6 or 9 weeks by mRECIST were 10.5% and 84.2%, respectively. Five of the 14 patients whose initial therapeutic response was determined to be SD, had a best tumor response of PR in the subsequent clinical course. In patients with PR, the median time to best therapeutic response was 4.3 months (95% confidence interval = 2.1-10.4). Median ALBI score at baseline, 3, 6 and 9 weeks were -2.39, -2.16 and -2.15, and no significant difference was found during these periods. Grade 3 or 4 adverse events occurred in 11 cases (50.0%). Of these, urine protein (22.3%) was most frequently observed, followed by appetite loss (9.1%), rash (4.5%), thrombocytopenia (4.5%), hepatic encephalopathy (4.5%), and acute subdural hematoma (4.5%).

Conclusion: Atez/Bev for patients with unresectable HCC showed favorable therapeutic response in our hospital.

Pathological Complete Response for Unresectable Locally Advanced Hepatocellular Carcinoma by Conversion Surgery Following a Good Response of Atezolizumab plus Bevacizumab Treatment

Yoichiro Uchida, Satoru Seo, Yuki Masano, Yusuke Kimura, Jiro Kusakabe, Yukinori Koyama, Ken Fukumitsu, Takashi Ito, Takamichi Isii, Koichiro Hata, Etsuro Hatano
Division of Hepato-Biliary-Pancreatic Surgery and Transplantation, Department of Surgery, Graduate School of Medicine, Kyoto University, Kyoto, Japan

We report a case of pathological complete response converted to laparoscopic radical hepatectomy after Atezolizumab plus Bevacizumab treatment for initially unresectable hepatocellular carcinoma (HCC) with hepatic vein tumor thrombus (HVTT). A 74-year-old male with alcoholic hepatitis visited our hospital for liver tumors. With the diagnosis of unresectable HCC (78mm with Vv2 in Segment 3, 24mm in Segment 8 and 6mm in Segment 8), Atezolizumab plus Bevacizumab was administered as systemic therapy. After two courses of chemotherapy, they showed marked shrinkage of tumor (36mm in Segment 3, 11mm in Segment 8 and obscurity in Segment 8) and HVTT with no apparent accumulation in PET scan compared with pretreatment. After additional one more course, we performed laparoscopic lateral segmentectomy for main tumor, and radiofrequency ablation for treated tumor of Segment 8. The stump of hepatic vein was negative finding in pathological diagnosis during surgery. After successful converted to laparoscopic radical hepatectomy, he was discharged from hospital on postoperative day 8 without influencing the perioperative course. A pathological examination revealed complete response without residual viable cells. In conclusion, Atezolizumab plus Bevacizumab treatment may enable downstaging of HCC, and facilitate the possibility for conversion therapy of unresectable locally advanced HCC.

Tace in Bangladesh- Long Term Follow Up

Md. Fazal Karim¹, Faroque Ahmed², Ahmad Sarwar Murshed³, AKM Moinul Hossain⁴, Shuvro Roy Choudhury⁵, Salimur Rahman⁶

¹Sir Salimullah Medical College Mitford Hospital, Dhaka, Bangladesh, ²Department of Hepatology, Dhaka Medical College Hospital, Dhaka, Bangladesh, ³Interventional Oncologist, Anwar Khan Modern Medical College Hospital, Dhaka, Bangladesh, ⁴Department of Radiology, LabAid Specialized Hospital, Dhaka, Bangladesh, ⁵Department of Interventional & Endovascular Radiology, Rabindranath Tagore International Institute of Cardiac Sciences, Kolkata, ⁶Department of Hepatology, Bangabandhu Sheikh Mujib Medical University, Dhaka, Bangladesh

Introduction: Transarterial Chemoembolisation (TACE) is a newly introduced procedure in Bangladesh. Here high dose chemotherapy can be given through hepatic artery to feeding vessel of tumors to restrict tumor blood supply. It is an established treatment modality in treatment of hepatocellular carcinoma.

Methodology: TACE procedure was performed in cases of hepatocellular carcinoma of variable sizes and variable etiology. The patients were of Intermediate Barcelona Clinic Liver Cancer stage (BCLC B) and of Child Pugh stage A or B and performance status of ECOG 0 or 1. Here BCLC stage and Child Pugh stage were used as selection criteria of TACE. These patients were followed up from October 2016 to June 2022.

Result: Total 27 patients (Age range 25-80 years) of both sexes were enrolled in the study. They were followed up for a duration of 5.5 years. Both conventional and DEB TACE were performed. The chemotherapeutic agent used was doxorubicin. No major adverse event other than pain in upper abdomen and fever was encountered. Survival of patients with TACE was not encouraging (14 out of 27 survived up to 6 months after procedure).

Conclusion: No single factor appeared responsible for survival of patients after TACE of hepatocellular carcinoma. Tumor dynamics may be an important factor. So, a different criterion is needed as an selection criteria for TACE.

Characteristics and Background of Hepatocellular Carcinoma from Non-viral Hepatitis in Our Hospital

Koji Yamashita, Yuichiro Suzuki, Leona Osawa, Yasuyuki Koiyama, Natsuko Nakakuki, Hitomi Takada, Masaru Muraoka, Mitsuaki Sato, Shinya Maekawa, Nobuyuki Enomoto
Department of Gastroenterology and Hepatology, University of Yamanashi, Yamanashi, Japan

Background: The proportion of NBNC (non-B and non-C hepatitis) as a cause of hepatocellular carcinoma (HCC) has been increasing and liver fibrosis is a high-risk factor for HCC, so it is important to pick up fibrosis cases.

Methods: We have established an outpatient specializing in fatty liver. In this study, we compared the background factors with HCC patients (n=154), then compared background factors between NBNC-HCC and the non-cancerous NBNC group (n=147) attending the fatty liver outpatient clinic.

Results: In HCC patients who first developed HCC from 2018 to 2020 at our hospital, the mean age was 74 years and 134 (87%) were male. Background liver disease included 88 (57%) NBNC, 48 (31%) hepatitis C (HCV), and 18 (12%) hepatitis B (HBV); the NBNC was significantly older ($p<0.01$) and had lower blood albumin levels ($p=0.03$). NBNC-HCC, compared non-cancerous NBNC, was significantly older ($p<0.01$) and high percentage of males ($p<0.01$), and had impaired liver function and advanced liver fibrosis in various modalities. The best cutoffs of Vibration-Controlled Transient Elastography (VCTE) was 8.1 kPa for men and 16.9 kPa for women, and the best cutoffs of magnetic resonance elastography (MRE) was 3.0 kPa for men and 4.2 kPa for women. The standards for men were similar, while the standards for women were higher than Japanese guidelines.

Conclusion: It is important to inform local medical institutions of the effectiveness of elastography and liver fibrosis marker scoring as a surveillance method for NBNC-HCC and to enclose the high-risk group by referring them to hepatologists.

Prognostic Factors after Curative Treatments for Milan Criteria Hepatocellular Carcinoma in Child-Pugh A: When should We Consider Nutritional Intervention?

Atsushi Hiraoka¹, Hideko Ohama¹, Fujimasa Tada¹, Tomoyuki Ninomiya¹, Yoichi Hiasa²

¹Ehime Prefectural Central Hospital, ²Ehime University, Gastroenterology and Metabology, Japan

Background/Aim: We aimed to elucidate the clinical features that require nutritional intervention for preventing progression of chronic liver disease complications such as portal hypertension (PH) and sarcopenia.

Materials/Methods: Naive 408 hepatocellular carcinoma (HCC) patients with Child-Pugh A, in whom muscle volume loss (MVL) by psoas muscle index (PSI: J Gastroentrol 2015), esophagogastric varices (EGV) (F2/F3/treated were defied as PH), and BTR measurement (<4.4 as amino acid imbalance: AAI) were evaluated, were enrolled [Elderly (>74 years) 146, male-gender 294, HCV: HBV: HCV&HBV: Alcohol: other=256:47:4:44:57, TNM I:II:III=175:201:32, surgery 143]. ALBI score/modified ALBI grade (mALBI) were used for assessment of hepatic function and prognosis was analyzed, retrospectively.

Results: Predictive value of ALBI score for AAI was -2.586 (AUC0.789). AAI was more frequent in patients with PH (n=62) than the other (66.1% vs. 30.1%, P<0.001), as well as in patients with MVL than those without among patients with PH (75.0% vs. 32.9%, P=0.009). Overall survival (OS) of patients with at least one of PH or MVL showed shorter than those without both (MST 79.1-91.3M vs. 140.7M, P=0.003), Although in Cox-Hazard univariate analysis, AAI (HR 1.466, P=0.04) was one of prognostic factors for OS, multivariate analysis showed that elderly (HR 2.42, P<0.001), mALBI 2b (>-2.27) (HR 1.81, P=0.02), MVL (HR 1.55, P=0.04), and PH (HR 1.672, P=0.03) were prognostic factors.

Conclusion: Even in Child-Pugh A, not only in those with at least one of PH or MVL but also in those whose ALBI scores are declining from ALBI grade 1 to mALBI 2b, nutritional intervention should be actively considered.

Association of ACRBP Gene Polymorphism (+26A/G) to Liver Cancer and Diabetes Leads to Novel Biomarker Discovery

Md Shariful Islam

Comparative Biomedical Sciences, University of Wisconsin Madison, USA

Background: This study investigated the relationship between the ACRBP gene and the risk for liver cancer.

Methods: The study was carried out with dry and wet lab approaches to identify the most deleterious SNP (Singlenucleotide polymorphism) and their association for the diagnosis of LC as novel biomarker. With an array of available SNP data on dbSNP we sorted out functional SNPs in ACRBP gene by implementing different authentic computational tools for functional and structural assessment, molecular dynamics, and energy minimization studies.

Results: Out of a total 1008 SNPs in ACRBP, we investigated 198 coding nonsynonymous SNPs(nsSNPs) and observed that 8 of them could be expected to alter the protein's function based on the predictions of both sequence homology based and structural homology based algorithms. By analyzing multiple tools having different perspectives an aggregate result were produced where rs11545745 (Q26R) nsSNP was found to be most likely to exert deleterious effect. 3D model of mutated protein was generated to determine the functional and structural effect of the mutations on ACRBP. Further we have verified rs11545745 polymorphism with liver cancer patients using PCR fragment length polymorphism (PCR-RFLP) method.

Conclusions: Our study suggests that ACRBP functional polymorphisms might possibly be associated with cancer and play a role in the pathogenesis of LC. Our findings indicate that rs11545745 could be a novel biomarker in LC patients diagnosis though detailed study on more LC patients need to be performed.

Treatment Strategy for the Multiple Colorectal Liver Metastasis

Tomoyuki Abe¹, Shintaro Kuroda², Tsuyoshi Kobayashi², Michinori Hamaoka³, Masakazu Hashimoto³, Takashi Onoe⁴, Hiroataka Tashiro⁴, Akihiko Honmyo⁵, Toshihiko Kohashi⁵, Akihiko Oshita⁶, Hironobu Mashima⁶, Koichi Oishi⁷, Hideki Ohdan²

¹Higashihiroshima medical center, ²Department of Gastroenterological and Transplant Surgery, Graduate School of Biomedical and Health Science, Hiroshima University, Hiroshima, Japan,

³Department of Surgery, Hiroshima Prefectural Hospital, Hiroshima, Japan., ⁴Department of

Surgery, Kure Medical Center and Chugoku Cancer Center, Kure, Japan, ⁵Department of Surgery,

Hiroshima City Asa Citizens Hospital, Hiroshima, Japan., ⁶Department of Surgery, Onomichi

General Hospital, Onomichi, Japan., ⁷Department of Surgery, Chugoku Rosai Hospital, Kure, Japan

Objective: Hepatectomy is the most effective treatment for colorectal cancer liver metastasis (CRLM) among various treatment strategies, but it is necessary to establish an optimal treatment policy including perioperative chemotherapy. This time, we compared the surgical results of CRLM in multi institute groups.

Methods: From 2008 to 2019, 305 hepatectomy cases for CRLM performed at 7 institutions participating in the Hiroshima Clinical Tumor Surgery Research Group (HiSCO). The short-term and long-term outcomes were statistically analyzed.

Results: The median age was 66 years. There were 209 males and 96 females. The primary sites were colon cancer in 218 cases and rectal cancer in 87 cases. There were 188 cases of simultaneous liver metastasis and 117 cases of metachronous metastasis. The median tumor diameter was 24 mm, 110 cases located only in one lobe, 195 cases in both lobes, and hepatectomy in 2 or more segments was 75 cases, Overall survival rates at 3 and 5 years were 41.5% and 38.0%, respectively. As for the recurrence-free survival rate, the 3-year recurrence-free survival rate was 21.2% and the 5-year recurrence-free survival rate was 16.1%. There were 79 positive cases of surgical margin, but the recurrence rate was similar to that of negative cases. Neoadjuvant systemic chemotherapy was given to 185 patients, especially cases with 4 or more tumors, preoperative chemotherapy was effective in suppressing recurrence.

Conclusion: In multiple CRLM, preoperative chemotherapy showed the effect of suppressing postoperative recurrence, especially when the number of tumors was 4 or more.

Sarcomatous Change after Spontaneous Regression of Hepatocellular Carcinoma

Hisanori Muto, Yoji Ishizu, Fumitaka Mizuno, Noritaka Matsuda, Takafumi Yamamoto, Yosuke Inukai, Naoki Yoshioka, Kazuyuki Mizuno, Sinya Yokoyama, Kenta Yamamoto, Takanori Ito, Norihiro Imai, Takashi Honda, Tetsuya Ishikawa, Masatoshi Ishigami, Hiroki Kawashima

Department of Gastroenterology and Hepatology, Nagoya University Graduate School of Medicine, Nagoya, Japan

A 59-year-old man receiving entecavir for cirrhosis type B underwent radical RFA for his first HCC. In the 7 years since his initial diagnosis, a total of four RFAs were performed for multicentric recurrence. Three months after his last RFA, multiple intrahepatic recurrences were diagnosed. After two subsequent TACE failed, sorafenib, the only standard systemic chemotherapy at that time, was initiated. After 3 months, sorafenib was discontinued due to progressive disease and another subsequent TACE was also ineffective. Around that time, he started herbal medicine as self-medication. Seven months later, dynamic CT showed obvious regression of the tumor. However, six months later, the patient had an unscheduled visit for abdominal pain, and dynamic CT showed multiple liver tumors, most of which were hypo-enhanced and atypical for HCC. He died after a month due to rapid tumor progression. Autopsy revealed multiple HCC occupying the liver, all of which were accompanied by sarcomatous changes except for one moderately differentiated HCC. Metastases were found in the lungs, pancreas, adrenal glands, vertebral body, rectal cystic fossa, and heart. Although the underlying mechanism of sarcomatous changes in HCC remains unknown, factors such as RFA, TACE, and systemic anticancer therapy may alter the phenotype of the cancer cells or induce selection of a clone with a sarcomatous nature. In the present case, despite the general course of HCC over a decade, it was extremely rare for sarcomatous changes to occur without obvious triggers after spontaneous regression at the end of the course.

Endobarrier: A Patient-covering Negative Pressure Box to Contain Aerosol and Droplet Generation during Esophagogastroduodenoscopy in the COVID-19 Era

Shintaro Fujihara, Hideki Kobara, Noriko Nishiyama, Tsutomu Masaki

Department of Gastroenterology, Kagawa University, Japan

Esophagogastroduodenoscopy (EGD) is an aerosol-generating procedure. We investigated the efficacy of the novel patient-covering negative pressure box system (Endo barrier) (EB) in EGD. 80 consecutive unsedated patients undergoing screening EGD with EB use were prospectively enrolled. 0.3- and 0.5- μ m aerosols were measured before and after EGD with 60 seconds before and after EGD. In addition, adenosine triphosphate (ATP) rapid assay for simulated droplets was used to assess the contamination of the examiner's goggles and vinyl gown before and after EGD. 73 data were available, showing that 0.3- and 0.5- μ m particles during EGD under EB were present in 95.8% (70/73) and 94.5% (69/ 73) patients; there was no significant difference in the total number of 0.3- and 0.5- μ m particles before and after EGD. ATP levels on goggles and gown before and after EGD were within the cutoff value of 150 RLU, and no contamination was found in all cases. EB use during EGD may provide a certain preventive effect against aerosols and droplets, decreasing examiners' exposure to viruses.

The use of Endo Barrier for Prevention of COVID-19 Infection Enables Upper Gastrointestinal Endoscopy with High Patient Satisfaction

Atsushi Imagawa

Imagawa Medical Clinic, Kagawa, Japan

Background: Endo barrier is considered useful in preventing the spread of COVID-19 droplets and aerosols by means of continuous suction during esophagogastroduodenoscopy (EGD). On the other hand, there were concern before the introduction that patients would complain of pressure and suffocation. It is also concerned that the preparation would take longer and be more burdensome on the staff. For these reasons, we investigated patient discomfort and satisfaction with the use of Endo barrier. Furthermore, to assess the degree of burden on the medical staff, the time of installation of this system was measured.

Methods: EGD was carried out for 788 consecutive cases from January 2021 to February 2022, using Endo barrier in all cases. A questionnaire was used to survey patients immediately after the procedure on four points: discomfort (feeling of pressure, breathlessness) and good points (feeling of relief, satisfaction) using the VAS. In addition, the preparation time of the Endo barrier was measured.

Results: The scores for "feeling of pressure" and "breathlessness" felt during the examination were 0.38 ± 1.37 (10: very pressured) and 0.25 ± 1.14 (10: very breathless), respectively. On the contrary, the scores for "feeling of relief" and "satisfaction" were 8.53 ± 2.38 (10: very reassuring) and 8.50 ± 2.39 (10: very satisfied), respectively. Preparation time became possible in about 30 seconds from the fifth month after introduction, and the burden on staff prior to EGD procedure was almost eliminated.

Conclusion: The Endo barrier is an easy-to-implement tool to prevent COVID-19 infection, and both patients and staff are highly satisfied with the device.

Hepatic Visceral Larva Migrans Diagnosed Clinically as Cholangiocarcinoma

Mako Koseki¹, Yusuke Kawamura^{1,4}, Norio Akuta^{1,4}, Masaru Matsumura^{2,4}, Satoshi Okubo^{2,4}, Junichi Shindoh^{2,4}, Keiichi Kinowaki^{3,4}, Toshio Fukusato^{3,5}, Shunichiro Fujiyama^{1,4}, Tetsuya Hosaka^{1,4}, Satoshi Saitoh^{1,4}, Hitomi Sezaki^{1,4}, Fumitaka Suzuki^{1,4}, Yoshiyuki Suzuki^{1,4}, Kenji Ikeda^{1,4}, Yasuji Arase^{1,4}, Masaji Hashimoto^{2,4}, Hiromitsu Kumada^{1,4}

¹Department of Hepatology, Toranomon Hospital, Tokyo, Japan, ²Hepatobiliary-pancreatic Surgery Division, Department of Gastroenterological Surgery, Toranomon Hospital, Tokyo, Japan, ³Department of Pathology, Toranomon Hospital, Tokyo, Japan, ⁴Okinaka Memorial Institute for Medical Research, Toranomon Hospital, Tokyo, Japan, ⁵Department of Pathology, Teikyo University School of Medicine, Japan

Background: Hepatic visceral larva migrans (VLM) is diagnosed mainly on symptoms, mass appearance, laboratory data, and other visceral findings. However, some cases have been reported where the hepatic mass caused by VLM was misdiagnosed as a malignant tumor due to it being the only clinical finding. It is quite difficult to suspect hepatic VLM using images of a liver mass and as a consequence the disease is often underdiagnosed or misdiagnosed as a malignant tumor.

Case: A 36-year-old Japanese male living in Thailand with no signs and symptoms was referred to our hospital for a liver mass suspected of being malignant, identified at a yearly health checkup. After a thorough examination, a single 30 mm low-echo mass with sharply defined vessel penetration in the middle was subsequently diagnosed clinically as cholangiocarcinoma. No other abnormal finding of the body was found, and no metastases were observed. PET/CT was negative. The patient had a laparoscopic hepatic partial resection as part of standard treatment, with pathology indicating a diagnosis of hepatic VLM.

Discussion: This case shows that hepatic visceral larva migrans may sometimes appear very similar to cholangiocarcinoma. Vessel penetration through the mass is not only a characteristic of cholangiocarcinoma, but also a key diagnostic factor of hepatic visceral larva migrans. Most cases of toxocariasis are self-limiting. We should be aware that VLM is a differential diagnosis when image findings appear to look like cholangiocarcinoma with negative PET/CT.

The Effect Inhalation Aromatherapy of Cardamom on the Chemotherapy-Induced Nausea and Vomiting in Cancer Patients

Leyla Halimi

Research Expert at Social Determinants of Health Research Center, Hamadan University of Medical Sciences, Hamadan, Iran

Background: The nonpharmacological methods with antiemetics can reduce the chemotherapy-induced nausea and vomitin. The purpose was to determine the effect Inhalation Aromatherapy of cardamom on the chemotherapy-induced nausea and vomitin in cancer patients.

Methods: A randomized controlled trial was done on 66 cancer patients reported chemotherapy-induced nausea in the hospital and clinic, 2013-2014. The patients were divided randomly into the cardamom-groups or placebo- groups. After formally consent, patients were asked to take three deeply breaths of the distilled water or oil-cardamom pads, twice with five-minute intervals. The patients' nausea intensity measured before intervention, five-minute after first 3-breaths and second 3-breaths. Frequencies of nausea, retching and vomiting were evaluated in the acute phase of chemotherapy after interventions. The effects of the placebo or cardamom inhalations according to the patients' gender and the extent of the emetogenicity of chemotherapy agents were also studied.

Results: The both groups were fairly equal in their demographic attributions and the severity of nausea at baseline. The severity of nausea was significantly lower in the cardamom group patients than the placebo ones at the end of the interventions. The frequency of the patients' nausea, retching and vomiting were the same in both groups in the acute phase. There were no differences between the groups' nausea, retching and vomiting in terms of the patients' gender and the extent of the emetogenicity of chemotherapy agents.

Conclusion: The essential oil of cardamom inhalation aromatherapy is recommended in decreasing the chemotherapy-induced severity of nausea in cancer patients.

Compare Aromatherapy with Essential Oils of Lavender and Rose on Sleep Quality in Patients Undergoing Chemotherapy

Leyla Halimi

Research Expert at Social Determinants of Health Research Center, Hamadan University of Medical Sciences, Hamadan, Iran

Introduction: The incidence of sleep disorders in patients with cancer is three times the general population. The aromatherapy is an inexpensive nursing intervention with fewer side effects than chemical drugs and a feeling of goodness more than ever. In order to investigate the effect of the aromatherapy therapy on sleep quality, the present study aims to compare the aroma of lavender with flower Roses.

Materials and Methods: The Pittsburgh sleep quality questionnaire was completed on the first day of chemotherapy. Intervention in groups was conducted in a chemistry course that lasted at least 3 nights and was performed from the night after chemotherapy. At the end of the intervention, the sleep quality questionnaire was completed again by the patient. the essential oil, and in the placebo group, distilled water is absorbed by the patient by napkin from the night after chemotherapy at 10 o'clock in the evening, and the napkin impregnated with essential oil is exposed to the scent from the evening dress from 10 o'clock to 6 o'clock in the morning. At the end of the intervention, the Petersburg Poverty Quality Questionnaire is completed again.

Results: In all four groups, after the intervention, the quality of sleep score decreased (here less score means better and easier sleep), but the reduction in the group was more than the other three groups.

Conclusion: Rose and lavender aromatherapy with essential oils and essential oil combination can improve sleep quality in patients undergoing chemotherapy

The Prevalence of Hepatitis B Virus Infection among the Pregnant Women and Their Newborn Babies in Siem Reap Province, Cambodia

Bunthen E^{1,2}, Ko Ko¹, Shintaro Nagashima¹, Serge Ouoba^{1,3}, Md. Razeen Ashraf Hussain¹, Kanon Abe¹, Aya Sugiyama¹, Kazuaki Takahashi¹, Tomoyuki Akita¹, Rattana Kim⁴, Vichit Ork⁵, Md Shafiqul Hossain⁶, Junko Tanaka¹

¹Department of Epidemiology, Infectious Disease Control and Prevention, Graduate School of Biomedical and Health Sciences, Hiroshima University, Japan, ²Payment Certification Agency (PCA), Ministry of Health, Phnom Penh, Cambodia, ³Unite de Recherche Clinique de Nanoro (URCN), Institut de Recherche en Science de la Sante (IRSS), Nanoro, Burkina Faso,

⁴National Maternal and Child Health Center (NMCHC), Ministry of Health, Phnom Penh,

Cambodia, ⁵National Immunization Program (NIP), Ministry of Health, Phnom Penh, Cambodia,

⁶Expanded Program on Immunization, World Health Organization Country Office, Cambodia

Background: The HBV mother-to-child transmission (MTCT) in Cambodia. The goal of this study is to examine the HBsAg prevalence among pregnant and the MTCT rate in Siem Reap, Cambodia.

Methods: A hospital-based longitudinal study was conducted in Siem Reap from February 2020 to December 2021. Pregnant women were screened for HBsAg. All newborn babies born to HBsAg+ women and one-four of those born to HBsAg- women were followed-up. Capillary blood, for rapid test and dried blood spot, was obtained from the followed-up newborns at six months old. HBV sero-markers were detected using a chemiluminescent enzyme immunoassay. Genomic homology analysis was performed to confirm MTCT.

Results: We tested 1565 pregnant women, of whom 67 (4.3%) were HBsAg+, with genotype C1 predominant (70.3%). "a" determinant, combination, and double mutation were 24.3%, 2.7%, and 29.7%, respectively. HBeAg+ (41.8%) had significantly high viral load and commonly found in women aged less than 30 years. At six months old, despite receiving fully Hep B vaccine, HBsAg was detected in one (2.86%) of 35 children born to HBsAg+ mothers, whereas none of those (81) born to HBsAg- mothers were identified. The HBsAg+ child was born to HBeAg+ mother with high viral load (5.9 10⁸ copy/ml). The analysis from the pair of HBsAg+ revealed 100% homology sequence in the whole genome.

Conclusion: Our findings illustrated a remaining risk of HBV MTCT, despite being fully vaccinated. Therefore, added to immunization program, screening program linkage to anti-virus prophylaxis treatment and care among pregnant women in Cambodia is needed.

Effect of Pegylated Interferon Alfa-2a in HBeAg-negative Chronic Hepatitis B during and 48 Weeks after Off-treatment Follow-up: The limitation of Pre-treatment HBsAg Load for the Seroclearance of HBsAg

Shima Mimura¹, Koji Fujita¹, Masafumi Ono¹, Kei Takuma¹, Mai Nakahara¹, Kyoko Oura¹, Tomoko Tadokoro¹, Joji Tani¹, Asahiro Morishita¹, Takashi Himoto², Tsutomu Masaki¹

¹Department of Gastroenterology and Neurology, Kagawa University Hospital, Kagawa, Japan,

²Department of Medical Technology, Kagawa Prefectural University of Health Sciences, Kagawa, Japan

Background: Hepatitis B virus (HBV) infection is a major public health problem worldwide. The study aimed to evaluate the efficacy of pegylated interferon (Peg-IFN) alfa-2a treatment for seroclearance of HBs antigen (HBsAg) in HBe antigen (HBeAg)-negative chronic hepatitis B (CHB) patients.

Methods: This retrospective study investigated 16 HBeAg-negative CHB patients who received Peg-IFN alfa-2a weekly for 48 weeks. Thereafter, the patients were followed-up for 48 weeks after the end of therapy. The following criteria were also used for inclusion: HBV-DNA < 5.0 log copies/mL and without nucleot(s)ide analogs.

Results: Four HBsAg-positive cases became HBsAg-negative. The HBsAg levels of the 4 patients who achieved HBsAg seroclearance were lower significantly than that of the non-seroclearance group ($p=0.007$). The mean HBsAg levels in these 4 cases was 68 IU/mL, while the mean HBsAg levels in the non-seroclearance group was 2,114 IU/mL. The mean HBV-DNA levels in the 4 HBsAg seroclearance cases was 2.8 log copies/mL compared to 3.6 log copies/mL in HBsAg-non-seroclearance cases ($p=0.01$).

Conclusion: Cases that are HBeAg-negative, with HBV-DNA levels < 5 log copies/mL, and HBsAg titers < 120 IU/mL cases may achieve HBsAg clearance with Peg-IFN therapy.

Predictors of Therapeutic Efficacy of Pegylated Interferon alpha-2a Therapy in HBeAg-negative Chronic Hepatitis B with Nucleos(t)ide Analog: 1-year Follow-up after Treatment

Shima Mimura¹, Koji Fujita¹, Masafumi Ono¹, Kei Takuma¹, Mai Nakahara¹, Kyoko Oura¹, Tomoko Tadokoro¹, Joji Tani¹, Asahiro Morishita¹, Takashi Himoto², Tsutomu Masaki¹

¹Department of Gastroenterology and Neurology, Kagawa University Hospital, Kagawa, Japan,

²Department of Medical Technology, Kagawa Prefectural University of Health Sciences, Kagawa, Japan

Background: Chronic hepatitis B (CHB) infection is a major health problem worldwide. This study aimed to investigate the long-term changes in HBsAg levels caused by pegylated interferon (Peg-IFN) alfa-2a in HBeAg-negative patients who were treated with nucleos(t)ide analog (NA) and were negative for hepatitis B virus (HBV) DNA, and to investigate the condition of patients whose HBsAg was prone to decrease.

Methods: Patients were observed for 96 weeks (48 weeks of Peg-IFN therapy and 48 weeks of post-treatment follow-up). In this study, responders were defined as those with a 50% or greater decrease in HBsAg levels from baseline at week 96.

Results: From week 16 of Peg-IFN therapy, there was a significant difference in the decrease of HBsAg levels from baseline, between responders and non-responders. At week 16, a significant difference was observed between the responder and non-responder groups at 60% HBsAg levels compared to the baseline. Age at the start of NA use and the duration of NA use until the start of treatment were significant pretreatment factors associated with HBsAg response.

Conclusion: In HBeAg-negative CHB patients who started NA at a younger age and underwent therapy for a prolonged duration, if the HBsAg level is more than 60% lower at 16 weeks after the start of Peg-IFN compared to before, Peg-IFN may have had a significant effect.

Sero-epidemiological Study on HBV and HCV Infection in Elderly Care Facility Staff and Residents in Japan

Aya Sugiyama¹, Yuko Nagaoki², Ko Ko¹, Akemi Kurisu¹, Masayuki Ohisa¹, Khilola Saipova¹, Sayyora Akhmedova¹, Tomoyuki Akita¹, Kazuaki Takahashi¹, Junko Tanaka¹

¹Department of Epidemiology Infectious Disease Control and Prevention, Hiroshima University Graduate school of Biomedical and Health Sciences, ²Mazda Hospital, Mazda Motor Corporation, Japan

Background: In Japan, hepatitis control has been successful, and the remaining HBV and HCV infected people are biased toward the elderly but the infection status and countermeasures at elderly care facilities is unclear. In this study, we conducted a sero-epidemiological study of elderly care facilities with the aim of obtaining epidemiological findings that contribute to measures for hepatitis virus elimination by 2030.

Methods: Of all 464 residents and 705 staff from four elderly care facilities in Hiroshima, 806 (255 residents: average age 85.8 ± 7.8 y, 551 staff: average age 44.6 ± 13.7 y) who wished to participate in this survey were tested for HBV and HCV. A questionnaire survey was also conducted for staff.

Results: Of the 551 staff, none were HBsAg-positive or HCV RNA-positive. The prevalence of HBsAg and HCV RNA in elderly residents (N=255) was 0.4% (95% CI: 0-0.7) and 1.2% (0-2.5), respectively. For those who were found positive, we provided a referral letter and encouraged to see a hepatologist. Of the staff, 6.9% answered that they had a history of HB vaccination and 69.5% have participated in seminar etc. related to infection control so far. The glove wearing rate as a standard precaution was 95.6% for all staff and 98.1% for those who had experienced seminar related to infection control.

Conclusions: There were no HBsAg or HCV RNA-positive staff, and the HBsAg or HCV RNA-positive rate of elderly residents was not high compared to the general elderly Japanese. Standard precaution was well adhered at elderly care facilities in Japan.

Association of Type 2 Diabetes and Hepatitis C Virus Infection in Pakistani Population: A Meta-Analysis

Sher Zaman Safi

Faculty of Medicine, Bioscience and Nursing, MAHSA University Malaysia

Aim: In Pakistan and other developing countries, the available data on the association of T2DM and HCV is limited. We therefore made an attempt to report the association of HCV and diabetes in Pakistani population through this meta-analysis.

Method: HCV and diabetes related studies were identified using various key words, from a number of databases including CINAHL, PubMed, Web of Science and Embase. Using RevMan5, the main outcome was regarded as type 2 diabetes associations with hepatitis c virus infection in Pakistan. Independent analyses were made for HCV in diabetic patients and diabetes cases in hepatitis C virus patients. Using random effect model, odds ratios were calculated with 95% CIs (dichotomous data). I² statistics were used to calculate heterogeneity.

Results: From a total of 53 studies, we finally selected 6 studies for the meta analysis. Using random effects model, hepatitis c virus patients in 3 studies (n = 1,902) demonstrated that HCV is a risk factor in developing diabetes (OR 0.01, 95% CI: 0.00-0.06, I² = 0%; RR 0.01, 95% CI: 0.00-0.07, I² = 0%). The remaining 3 studies (n = 13,710) had reported HCV infections in type 2 diabetic patients and patients with no diabetes. Similarly, our meta-analysis revealed higher prevalence of HCV infections in patients with type 2 diabetes (OR 0.7, 95% CI: 0.17-0.42, I² = 32%; RR 0.30, 95% CI: 0.20-0.46, I² = 32%) as compared to patients with no type 2 diabetes mellitus

Conclusion: Our meta-analysis demonstrates a significant link between HCV and T2DM.

Age-dependent Sex Difference of Non-alcoholic Fatty Liver Disease in TSOD and db/db Model Mice

Erdenetsogt Dungubat¹, Hiroyuki Kusano¹, Ichiro Mori¹, Hirosuke Tawara², Mitsuko Sutoh², Naoki Ohkura³, Masakatsu Takanashi⁴, Masahiko Kuroda⁴, Emiko Udo⁵, Masakazu Souda⁵, Bungo Furusato⁵, Toshio Fukusato⁶, Yoshihisa Takahashi¹

¹Department of Pathology, School of Medicine, International University of Health and Welfare,

²Institute for Animal Reproduction, ³Laboratory of Host Defence, Faculty of Pharma Sciences,

Teikyo University, ⁴Department of Molecular Pathology, Tokyo Medical University, ⁵Cancer

Genomics Unit, Clinical Genomics Center, Nagasaki University Hospital, ⁶General Medical

Education and Research Center, Teikyo University, Japan

Background: According to previous clinical studies, the prevalence of non-alcoholic fatty liver disease (NAFLD) is higher in men than women only during the reproductive age. Animal models of NAFLD that reflect sex differences in humans have not been established. In this study, we examined sex differences in the hepatic lesions of Tsumura Suzuki obese diabetes (TSOD) and db/db mice at different ages, which are representative genetic models of NAFLD.

Methods: Male and female TSOD and db/db mice were fed with a normal diet and tap water ad libitum. Six male and female mice of each strain were sacrificed at the ages of 3 and 9 months, respectively, and serum biochemical, pathological, and molecular analyses were performed.

Results: Serum aspartate aminotransferase (AST) and/or alanine aminotransferase (ALT) levels were significantly higher in male than female mice of these strains only at the age of 3 months. Image analysis of histological slides revealed that the frequency of steatotic and/or fibrotic area was significantly higher in male than female mice in these strains only at the age of 3 months.

Conclusion: Serum AST and ALT levels and hepatic steatosis and fibrosis in TSOD and db/db mice showed age-dependent sex differences consistent with those observed in human NAFLD, suggesting that the TSOD and db/db mice models are suitable for studying age-related sex differences of NAFLD.

Two Cases of Hepatocellular Carcinoma with Radical Resection after Lenvatinib Administration followed by Conversion Surgery

Masahiko Honjo, Katsunori Sakamoto, Kei Tamura, Kyosei Sogabe, Chihiro Ito, Miku Iwata, Akimasa Sakamoto, Takashi Matsui, Mikiya Shine, Mio Uraoka, Tomoyuki Nagaoka, Naotake Funamizu, Kohei Ogawa, Yasutsugu Takada
Hepato-Biliary- Pancreatic and Breast Surgery, Ehime University Graduate School of Medicine, Ehime, Japan

Introduction: Since the efficacy of lenvatinib (LEN) treatment for unresectable hepatocellular carcinoma (HCC) was demonstrated, LEN has played a major role in the multimodal treatment of advanced HCC. In this report, we describe two cases of advanced HCC that were considered unresectable but were successfully treated by radical resection after LEN administration.

Case Presentations: Case 1: A woman in her 70s had previously been infected with hepatitis B virus. Blood tests revealed elevated liver enzyme levels. A large HCC (approximately 10 cm in diameter) was found in the right lobe. The patient underwent multidisciplinary treatment with LEN, TACE and RFA therapy. Approximately 1 year after the initiation of treatment, we performed hepatic extended right lobectomy. Computed tomography on the 85th postoperative day revealed the recurrence of a lung metastasis, and the patient is currently undergoing chemotherapy.

Case 2: A man in his 50s attended a medical checkup that revealed elevated liver enzyme levels. A large HCC approximately 15 cm in diameter was found, which extended over three hepatic areas. The risk of postoperative liver failure was high; thus, LEN was initiated. The tumor shrank; laparoscopic extended left hepatic lobectomy was performed 4 months after the initiation of LEN. The patient is alive and recurrence-free 232 days after surgery.

Conclusion: Currently, the indication for drug therapy is unresectable HCC, but the number of cases with successful conversion after drug therapy is increasing. In the future, preoperative chemotherapy is expected to be prescribed for patients at high risk of early recurrence.

A Case of Conversion Surgery for Initially Unresectable Hepatocellular Carcinoma with Tumor Shrinkage after Atezolizumab plus Bevacizumab Therapy

Yusuke Seki¹, Akihiko Ichida¹, Junichi Arita¹, Maho Takayama¹, Kyoji Ito¹,

Nobuhisa Akamatsu¹, Junichi Kaneko¹, Hirofumi Rokutan², Mariko Tanaka², Kiyoshi Hasegawa¹

¹Hepato-Biliary-Pancreatic Surgery Division, Department of Surgery, Graduate School of

Medicine, The University of Tokyo, ²Department of Pathology, Graduate School of Medicine, The

University of Tokyo, Japan

Background: Recently, atezolizumab plus bevacizumab therapy (atezo+bev) was approved for the first-line treatment of unresectable hepatocellular carcinoma (HCC) due to its high response rate.

Case: A 78-year-old man with alcoholic liver disease was diagnosed as having a 71mm HCC in the liver segments 4 and 8. The serum levels of alpha-fetoprotein (AFP) and des-gamma-carboxy prothrombin (DCP) were 2866 ng/mL and 775 mAu/ml, respectively. The tumor strongly compressed the umbilical portion and the right anterior branch of the portal vein, and the part of the right hepatic vein, requiring a central bisectionectomy for the complete removal, with an estimated resected liver volume of 23% of the total liver volume (TLV). However, because of the impaired hepatic functional reserve with an indocyanine green retention rate at 15min of 28%, the tumor was considered to be unresectable. After 6 courses of atezo+bev, the tumor shrank to 53 mm and the serum levels of AFP and DCP decreased to 2.2 ng/mL and 273 mAu/ml. Since the tumor was considered to be resectable with left medial sectionectomy and the resected liver volume was estimated to be 10% of TLV, conversion surgery was performed. The patient was discharged on postoperative day 10 and HCC recurrence has not been detected as of 3 months after the surgery. Pathologically, the tumor was well to moderately differentiated HCC with components of necrosis, hemorrhage (accounting for about 50% of the entire nodule).

Conclusion: Conversion hepatectomy after atezo+bev could be a favorable treatment option for initially unresectable HCC.

A Case of Sustained Complete Response by Sorafenib Therapy Following TAE Therapy for the Rupture of Giant Hepatocellular Carcinoma

Ken Sato, Yuichi Yamazaki, Hiroki Tojima, Soichiro Shimizu, Tatsuma Murakami,
Yuki Kanayama, Toshio Uraoka
Gunma University Graduate School of Medicine, Japan

Background: Sorafenib become available as a molecularly targeted drug for hepatocellular carcinoma (HCC) for the first time in Japan. However, complete response (CR) is extremely rare.

Case Presentation: A case of 72-years old man, who had alcoholic liver disease and arteriosclerosis obliterans, noticed an epigastric mass and abdominal pain. Two months later, he had abdominal pain again and was referred to our hospital for close inspection. We found that approximately 14 cm HCC occupied in lateral segment with multiple daughter lesions was ruptured. He received emergent transcatheter arterial embolization (TAE). Nine days later, abdominal computed tomography (CT) showed a significant reduction of HCC with partially residual tumors. Then, we started a dose of 400 mg/day sorafenib approximately 5 weeks after TAE. Abdominal CT at about 5 weeks of sorafenib therapy showed a further reduction of HCC with no relapse. We diagnosed CR based on Modified Response Evaluation Criteria In Solid Tumors. Sorafenib therapy has been continued and the recurrence-free survival time reached to 57 months after TAE. He developed popliteal artery embolisms and aggravation of arteriosclerosis obliterans during the treatment and there might be a causal relationship between these adverse events and sorafenib.

Conclusion: Currently, several molecularly targeted drugs/immune checkpoint inhibitors become available for HCC in Japan. In some cases, a good antineoplastic effect by a certain drug might be expected like our case. Thus, we should try to use these drugs in succession with careful consideration of residual liver function if the antitumor effectiveness is insufficient or unexpected.

Two Cases of Local Ablation for Hepatocellular Carcinoma in the Caudate Lobe; An Emerging Technique with Using Guided Needle under Computed Tomography

Sae Yumita, Naoya Kanogawa, Takamasa Ishino, Keita Ogawa, Teruomi Iwanaga, Kisako Fujiwara, Miyuki Nakagawa, Ryuta Kojima, Hiroaki Kanzaki, Keisuke Koroki, Kazufumi Kobayashi, Masato Nakamura, Soichiro Kiyono, Takayuki Kondo, Ryo Nakagawa, Sadahisa Ogasawara, Shingo Nakamoto, Ryosuke Muroyama, Tetsuhiro Chiba, Naoya Kato
Department of Gastroenterology, Graduate School of Medicine, Chiba University, Japan

Background: In radiofrequency ablation (RFA) of hepatocellular carcinoma, lesions in the caudate lobe are known to be one of the most difficult to treat. We report two cases of complete ablation of lesions in the caudate lobe by RFA using a metal external cylinder needle.

Case 1: A patient was 64-year-old male with alcoholic cirrhosis. A lesion in the caudate lobe (32x27mm) was treated with CT-guided RFA (right intercostal approach). But the ablation was insufficient, so CT-guided RFA with a metal external cylinder needle was performed. The procedure is as follows. (1) A 14G metal external cylinder needle is inserted into the abdominal cavity under ultrasonography guidance from the cardiac fossa. (2) Remove the internal needle and guide it to the caudate lobe. (3) CT scan is performed to confirm the needle tip. (4) Insert the 17G electrode needle into the outer tube needle and puncture the tumor under CT guidance. (5) ablation.

Case2: A patient was 83-year-old male with hepatitis C virus. A lesion in the caudate lobe (16x15mm), we performed RFA with this technique. But the safety margin was insufficient on CT after ablation, the position of a metal external cylinder needle was adjusted and additional cauterization was performed by re-puncture. Both Case1 and 2 have been under follow-up for more than one year without local recurrence.

Conclusion: Puncture of lesions in the caudate lobe using a metal external cylinder needle is a useful and safety method.

A Successful Treatment for Hepatocellular Carcinoma in a Patient with Hemophilia A Using Laparoscopic Radiofrequency Ablation

Rie Goka, Kouichi Miura, Naoki Morimoto, Shunji Watanabe, Yoshinari Takaoka, Hiroaki Nomoto, Mamiko Tsukui, Takeshi Fujieda, Hiroshi Maeda, Norio Isoda, Hironori Yamamoto
Division of Gastroenterology, Department of Medicine, Jichi Medical University, Tochigi, Japan

The prevalence of hepatocellular carcinoma (HCC) in patients with hemophilia is high because hepatitis C virus (HCV)-contaminated clotting factors were transfused in the past. However, patients with hemophilia carry a risk of hemorrhagic complications at the treatment. Here we report a successful treatment for HCC in a patient with hemophilia A using laparoscopic radiofrequency ablation. A 48-year-old man with hemophilia and chronic HCV infection had HCC, 20 mm in diameter at segment 8. When he was admitted to our hospital, the severity of hemophilia was moderate with APTT 72.8 sec and coagulation factor VIII 1.6%. We performed laparoscopic radiofrequency ablation after supplementation of Factor VIII. According to the guideline, recombinant FVIII was administered to maintain FVIII level >80% on the operation day and >40% post-operation for 5 days. No bleeding complications occurred during and after the procedure and he was discharged 14 days after the procedure. HCC recurred at segment 7 two years after the initial treatment. We performed laparoscopic radiofrequency ablation again without any events. Although partial hepatectomy is the major procedure to treat HCC developed in patients with hemophilia, we propose laparoscopic radiofrequency ablation as an option of treatment for HCC in patients with hemophilia.

Clinical Evaluation of Liver Metastasis in Ovarian Cancer

Amar Ranjan Singh, Harshita Dubey, Pranay Tanwar

AIIMS, New Delhi, India

Introduction: Metastasis lesions in the liver follow a unique pattern in peritoneal malignancies including ovarian cancer (OC). In OC, if the tumor spreads to the liver from the peritoneum, it is categorized as FIGO stage III, but if there is hematogenous spread to the liver, it is categorized as stage IV of ovarian cancer. Here we discuss a unique case of OC with liver nodules.

Case History: A 37-year-old female presented with loss of appetite, abdominal distension & supraumbilical swelling. CA 125 was 1888.5 IU/L. MRI showed bulky ovaries, ascites, retroperitoneal lymphadenopathy, nodules on omentum on the liver surface. FNAC from nodule confirmed Adenocarcinoma. Considering OC stage 3C, 3# TP regimen followed by suboptimal cytoreductive surgery and 3 # TP regimen were given. After treatment-free interval of 4 months, the follow-up; Clinical, radiological & serological investigations showed progressive disease. After 2# Oral metronomic therapy with CE regimen response was poor. GC regimen was started with D1, D15 plans with good tolerance. Post CT#2; thrombocytopenia & post 3# CT again, no response was seen. Now weekly Paclitaxel was given. As a last option, in case of no response after 2, the BSC regimen (Paclitaxel + Carboplatin +Bevacizumab) remains an option.

Conclusion: This case was categorized as FIGO stage IV A. Liver surface involvement was considered as peritoneal spread. Pre and post debulking surgery chemotherapy with TP regimen is the standard protocol for management.

Growing Teratoma Syndrome Affecting Hepato-renal Space

Harshita Dubey, Amar Ranjan, Pranay Tanwar

AIIMS, New Delhi, India

Background: Growing teratoma syndrome (GTS), rare condition is related to testis or ovary. It is most commonly seen with testicular non seminomatous germ cell tumors. It is characterized by metastasis from mature teratoma. We present a rare case of growing teratoma syndrome in struma ovarii.

Method: Case study

Results: 30-year-old female presented with abdominal distention and adnexal lump. Her CA 125 was 144.9 U/ML along with AFP 212 ng/ml. CA-19.9 and CEA were normal. On CT scan, the adnexal mass measuring 16 x 10 cm was encasing uterus and bilateral ovaries. She underwent left salpingo-oophorectomy. Histopathology showed the mass as struma-ovarii. She was given 4#TP regimen. After 8 months, the size of mass was increasing. Repeat CT showed bilateral adnexal mass with deposits in bowel & omentum. Her CA-125, alfa-fetoprotein and b-HCG were normal. Adnexal mass biopsy stated mature teratoma. Patient was operated again. Histopathology showed mature teratoma with deposits on bowel wall, omentum and anterior abdominal wall (IIIc). Repeat CT scan showed loculated collection of fluid in perisplenic, pelvic and left para colic gutter. Small irregular heterogeneous enhancing calcification was seen at pouch of douglas, anterior wall, peritoneal reflection and hepatorenal space. The patient is asymptomatic and doing well.

Conclusion: GTS should also be considered in ovarian germ cell tumor. Early diagnosis, surgery and monitoring to the response to chemotherapy should be done. Involvement of liver from peritoneal spread is categorized as stage III. Key words : Growing teratoma syndrome, Liver, Metastasis

Latent Transforming Growth Factor-Beta Binding Protein 1 as A Molecular Diagnostic Marker for Hepatocellular Carcinoma in Egyptian Patients

Mohamed Abdel Samiee¹, Olfat M. Hendy², Bishoy El-Aarag³

¹Department of Hepatology and Gastroenterology, National Liver Institute, Menoufia University, Shebin El-Kom, Egypt, ²Clinical and Chemical Pathology, National Liver Institute, Menoufia University, Shebeen El-Kom, Egypt, ³Biochemistry Division, Chemistry Department, Faculty of Science, Menoufia University, Egypt

Background: The latent transforming growth factor-beta binding protein 1 (LTBP-1) is a secreted protein and considers as a part of the extracellular matrix (ECM). We aimed to evaluate the diagnostic role of LTBP-1 as a biomarker to distinguish HCC from cirrhotics.

Methods: our study included 90 individuals; 40 HCC patients, 30 with cirrhosis, 20 healthy volunteers as a control group. The serum level of LTBP-1 and AFP were measured by ELISA.

Results: the level of LTBP-1 was significantly higher in HCC patients than healthy and cirrhotics. There was a significant ($p=0.001$) association between LTBP-1, CLIP and BCLC in HCC patients. LTBP-1 levels were significantly ($p=0.01$) associated to child Pugh grade in patients with cirrhosis and HCC. LTBP-1 showed a better diagnostic performance (AUC=0.970, Sensitivity: 82.50%, Specificity: 96.67%, PPV: 97.06%, NPV: 80.56%) in distinguishing HCC from cirrhosis patients, compared to AFP (AUC=0.810, Sensitivity: 62.50%, Specificity: 93.33%, PPV: 92.59%, NPV: 65.12%). LTBP-1 in HCC patients was significantly ($p=0.001$) associated with CLIP score. There was a significant ($p=0.001$) association between the serum level of LTBP- 1 and BCLC score in HCC patients. The LTBP-1 level was increased with the progress in BCLC score, the level was 46.8 in score 4 against 26.6 in score 0. Conversely, AFP wasn't significantly ($p=0.172$) associated with BCLC score.

Conclusion: taken together, serum LTBP-1 might be a potential serum marker to discriminate HCC from liver cirrhosis patients due to its high sensitivity and specificity, compared to AFP. LTBP-1 might be a promising diagnostic biomarker for HCC.

Circulating Hypermethylated RASSF1A as a Marker of Hepatocellular Carcinoma in Chronic HCV Patients

Mohamed Abdel Samiee¹, Mona Hassona², Mary Naguib², Eman Abdelsameea¹,
Suzanne Estaphan³, Sarah Ismail⁴, Nevine Shafik⁵

¹Department of Hepatology and Gastroenterology, National Liver Institute, Menoufia University, Shebin El-Kom, Egypt, ²Clinical and Chemical Pathology, National Liver Institute, Menoufia University, Shebeen El-Kom, Egypt, ³Physiology Department, Faculty of Medicine, Cairo University, Cairo, Egypt, ⁴Student at Faculty of medicine, Cairo University, Cairo, Egypt, ⁵Clinical Pathology Department, Faculty of Medicine, Cairo University, Cairo, Egypt

Background: Hepatocellular carcinoma (HCC) is a global health problem and the fourth leading cause of cancer-related deaths worldwide. HCC is typically undistinguished initially causing detection of the majority of cases in palliative stages. Thus, in this study, we aimed to assess the role of plasma level of methylated RASSF1A in post hepatitis C virus, (HCV) cirrhotic patients as a non-invasive diagnostic marker for HCC.

Methods: The levels of methylated RASSF1A were determined in plasma of 120 participants who were classified to three groups (40 participants each); HCC patients on top of chronic HCV infection, post HCV cirrhotic patients without HCC in addition to healthy matched age and sex control group. Methylation-sensitive restriction enzyme digestion and real-time quantitative polymerase chain reaction method was used to measure the expression level of RASSF1A.

Results: Patients with HCC exhibited significantly higher levels of circulating hypermethylated RASSF1A than post hepatitis C patients and control groups. In addition, a statistically significant correlation between RASSF1A and the different clinico-pathological parameters was observed. The receiver operating characteristic curves plotted showed that plasma RASSF1A helped in significant differentiation between HCC and cirrhotic patients.

Conclusion: Circulating hypermethylated RASSF1A could be used as a non invasive diagnostic marker for discriminating HCC among post HCV cirrhotic patients and characterizing their progression.

A Comparative Proteomic Analysis of Extracellular Vesicles Associated with Lipotoxicity

Yasuhiko Nakao, Ryu Sasaki, Satoshi Miuma, Hidemitsu Miyaaki

Department of Gastroenterology and Hepatology, Graduate School of Biomedical Sciences, Nagasaki University, Nagasaki, Japan

Extracellular vesicles (EVs) are emerging mediators of intercellular communication in nonalcoholic steatohepatitis (NASH). Palmitate, a lipotoxic saturated fatty acid, activates hepatocellular endoplasmic reticulum stress, which has been demonstrated to be important in NASH pathogenesis, including in the release of EVs. We have previously demonstrated that the release of palmitate-stimulated EVs is dependent on the de novo synthesis of ceramide, which is trafficked by the ceramide transport protein, STARD11. The trafficking of ceramide is a critical step in the release of lipotoxic EVs, as cells deficient in STARD11 do not release palmitate-stimulated EVs. Here, we examined the hypothesis that protein cargoes are trafficked to lipotoxic EVs in a ceramide-dependent manner. We performed quantitative proteomic analysis of palmitate-stimulated EVs in control and STARD11 knockout hepatocyte cell lines. Proteomics was performed on EVs isolated by size exclusion chromatography, ultracentrifugation, and density gradient separation, and EV proteins were measured by mass spectrometry. We also performed human EV proteomics from a control and a NASH plasma sample, for comparative analyses with hepatocyte-derived lipotoxic EVs. Size exclusion chromatography yielded most unique EV proteins. Ceramide-dependent lipotoxic EVs contain damage-associated molecular patterns and adhesion molecules. Haptoglobin, vascular non-inflammatory molecule-1, and insulin-like growth factor-binding protein complex acid labile subunit were commonly detected in NASH and hepatocyte-derived ceramide-dependent EVs. Lipotoxic EV proteomics provides novel candidate proteins to investigate in NASH pathogenesis and as diagnostic biomarkers for hepatocyte-derived EVs in NASH patients.

Establishment of the Japan Academy of Tumor Ablation (JATA)

Shuichiro Shiina¹, Ryosuke Tateishi², Nobuhiro Fukunari³, Tatsuya Yamashita⁴, Yasunori Minami⁵, Haruyuki Takaki⁶, Kazuhiro Nouse⁷, Yuko Takami⁸

¹Department of Gastroenterology, Juntendo University, ²Department of Gastroenterology, The University of Tokyo, ³Department of Thyroid Center, Showa University Northern Yokohama Hospital, ⁴Department of Gastroenterology, The University of Tokyo, ⁵Department of Gastroenterology, Kindai University Hospital, ⁶Department of Radiology, Hyogo College of Medicine, ⁷Department of Gastroenterology, The Okayama City Hospital, ⁸Department of Hepato Biliary Pancreatic Surgery, National Hospital Organization Kyushu Medical Center, Japan

Ablation is a general term for treatments such as ultrasound, CT, and MRI-guided insertions of needle-like applicators into tumors killing it with heat. Radiofrequency and microwave ablations are representative examples while cryoablation and percutaneous ethanol injection are also included.

Ablation has been performed mainly for malignant liver tumors. Ablation has developed through competing with surgery. Results of the SURF trial made public in 2021, showed no superiority of liver resection over radiofrequency ablation in terms of overall survival and recurrence-free survival. The SURF trial is a randomized, controlled trial conducted in 49 institutions in Japan. The institutions enrolled patients with primary HCC of 3cm or smaller with well-functioning livers over a 6-year period from 2009, who were then followed for at least 5 years.

Regarding the results of the SURF trial and other comparative studies, the revised guidelines (The Japanese Clinical Practice Guidelines for HCC) published in 2021 treat hepatic resection and ablation equally for patients with HCC of three or fewer tumors, all 3cm or smaller in diameter.

Currently, cryoablation for small-sized renal cell carcinoma and radiofrequency ablation for adrenal tumors are covered by public health insurance. From September 1st 2022, radiofrequency ablation for lung tumors, renal tumors, and bone and soft tissue tumors will also be covered. In addition, ablation of the thyroid gland is widely performed overseas. Furthermore, ablation is expected to extend to breast cancer. Since ablation is curative, minimally invasive, can easily be repeated for recurrence, and is cost-effective, it is expected to play an increasingly important role in rapidly aging societies.

JATA was established for enhancing cooperation among members along with related institutions. By doing so, we aim to achieve safe and effective performances of all types of ablations in all areas of the body, including the lung, thyroid, kidney, adrenal gland, breast, bone, and soft tissue, as well as the digestive organs. Similar societies include the Asian Conference on Tumor Ablation (ACTA) in Asia, the Taiwan Academy of Tumor Ablation (TATA) in Taiwan and the Korean Society of Image-guided Tumor Ablation (KSITA) in Korea. Japan is the birthplace of ablation such as percutaneous ethanol injection and microwave ablation. We continue to have the responsibility of leading the world in the field of ablation. We hope many will join us to accumulate clinical experience and research results, train future generations and contribute to the further development of ablation.

Microwave Thermosphere Ablation for Primary Hepatocellular Carcinoma within Milan Criteria

Jumpei Okamura, Hideyuki Tamai

Department of Hepatology, Wakayama Rosai Hospital, Wakayama, Japan

Background: In July 2017, the next-generation microwave ablation system using thermosphere technology (Emprint™; Covidien, Boulder, CO, USA) was approved for use in Japan. This microwave thermosphere ablation (MTA) system can produce predictable spherical ablation zone in shorter time than radiofrequency ablation. The aim of the present study was to evaluate the outcomes of MTA for primary hepatocellular carcinoma (HCC) within Milan criteria.

Methods: This is a retrospective cohort study of patients with primary HCC, who underwent percutaneous ultrasound guided MTA between December 2017 and March 2020 in our hospital.

Results: One hundred patients including 111 HCCs were treated by MTA. Median age was 74 years (range 36-90). There were 67 men. Hepatitis B were in 6, Hepatitis C in 44, and non-viral in 50 patients. Median tumor size was 20 mm (8-43). The number of HCCs less than 3cm in diameter were 100, and that of HCCs over 3cm were 11. Cumulative 4-year local tumor progression rate was 17%. Multivariate analyses identified that tumor diameter and alpha-fetoprotein (AFP) were independent factors contributing to local tumor progression. Cumulative 4-year ectopic recurrence rate was 30%. Independent factors contributing to ectopic recurrence was AFP-L3. Cumulative 4-year survival rate was 76%. Independent factors contributing to survival were also only AFP-L3.

Conclusions: Outcomes of MTA for primary HCC within Milan criteria seem favorable. As important factors affecting to outcomes are tumor size and AFP-L3 that reflects tumor malignancy, MTA should be applied to small HCCs without high grade malignancy.

Chronic Hepatitis C Patients with Advanced Liver Fibrosis are More Likely to Have Persistent Cryoglobulinemia after Antiviral Treatment

Batbold Batsaikhan¹, Ganchimeg Dondov¹, Gantogtokh Dashjamts¹, Otgongerel Nergui¹, Ankhzaya Batsaikhan¹, Bayar Davaa¹, Tegshjargal Badamjav¹, Tulгаа Lonjid¹, Chia-Yen Dai²

¹Department of Internal Medicine, Institute of Medical Sciences, Mongolian National University of Medical Sciences, ²Kaohsiung Medical University Chung-Ho Memorial Hospital

Introduction: Treatment of Hepatitis C virus (HCV) infected patients with cryoglobulinemia is indicated the progressive organ threatening disease is present. Patients without cryoglobulinemia symptoms only treated by antiviral treatment recommended by the guideline. In most cases, the successful treatment of HCV improved the cryoglobulinemia symptoms and complications.

Materials and Method: We have conducted the multicenter study enrolling patients with CHC referred to Kaohsiung Medical University Hospital, a tertiary Medical Center and two regional hospitals from 2005 to 2016. The liver biopsy was obtained from all patients and four indexes of fibrosis (FIB4) was calculated to describe advanced fibrosis.

Results: The demographic characteristics of 148 patients who was available to detect serum cryoglobulinemia after antiviral therapy are presented. Fifty-one patients (34.5%) had persistent cryoglobulinemia after the treatment. Ninety-nine patients out of 148 were available for liver biopsy. Other factors such as age, gender, HCV genotype and other HCV related diseases did not have any significant associations with the persistent cryoglobulinemia. PegIFN dose and treatment duration did not have any association. However advanced fibrosis has more influenced to persistent cryoglobulinemia than viral clearance. If we adjusted FIB4 index instead of platelet count, it was not associated with persistent cryoglobulinemia by multivariate analysis.

Conclusion: Our study shows an independent association between advanced fibrosis and persistent cryoprecipitate after antiviral therapy in CHC patients.

Clinical Characteristics of the Nutritional and Dietary Factors Associated with Skeletal Muscle Index in Patients with Nonalcoholic Fatty Liver Disease

Takashi Himoto¹, Keiko Miyatake², Takashi Maeba³, Tsutomu Masaki⁴

¹Department of Medical Technology, Kagawa Prefectural University of Health Sciences,

²Department of Nutrition Management, Ritsurin Hospital, ³Department of Surgery, Ritsurin

Hospital, ⁴Department of Gastroenterology and Neurology, Kagawa University Faculty of Medicine, Japan

Background: We aimed to determine the nutritional and dietary factors associated with muscle volume loss in such patients. Dietary and body components changes produced by a diet intervention were longitudinally investigated.

Methods: Forty-six NAFLD patients (24 males, 22 females) were enrolled. A second diet treatment was performed at 6 months after entry in 19 of the enrolled patients (6 males, 13 females). Body components and dietary nutrients at six months later were compared with those at entry.

Results: Three of the 24 (13%) males and four of the 22 (18%) females fulfilled the criteria for pre-sarcopenia, and one (5%) female NAFLD patient was in the criteria for sarcopenia at baseline. The factors associated with skeletal muscle index in males were body mass index (BMI), insulin-like growth factor-1, total energy intake and lipid intake, but BMI and bone mineral density in females at baseline. The diet intervention decreased the skeletal muscle volume in the 6 males by decreasing the total energy intake via lower protein and lipid intakes, and improved their liver dysfunction. In the 13 females, a decrease in total energy intake via lower carbohydrate and lipid intake did not change the muscle volume.

Conclusion: These results suggest that muscle volume loss is frequently observed in non-obese NAFLD patients. The nutritional and dietary factors that regulate muscle volume loss were distinct between male and female NAFLD patients. The muscle volume of such patients as well as their body weight and liver function should be monitored during diet interventions.

The Prevalence of Portopulmonary Hypertension and the Clinical Characteristics of the Patients with High Right Ventricular Systolic Pressure in Liver Transplant Candidates

Ryoko Hayashi, Tomomi Kogiso, Kentaro Horiuchi, Yuri Ogasawara, Makiko Taniyai, Katsutoshi Tokushige
Institute of Gastroenterology, Department of Internal Medicine, Tokyo Women's Medical University, Tokyo, Japan

Background: Portopulmonary Hypertension (PoPH) is pulmonary artery hypertension associated with portal hypertension and cirrhosis. Severe cases of PoPH are contraindicated for liver transplantation (LT) due to poor prognosis. We investigated the prevalence of PoPH and the clinical characteristics of the patients with high right ventricular systolic pressure (RVSP) in LT candidates.

Methods: During 2011-2021, a total 157 of LT candidates with liver cirrhosis or portal hypertension (81 women [51.6%], median age 52 [18-68] years) were enrolled. Patients were divided and compared to two groups according to the RVSP (mmHg) value of <36 ($n=105$) and >35 ($n=32$) estimated by echocardiogram.

Results: 1) Patients with an RVSP >35 ($n=105$) were significantly observed in females (71.8%, $p=0.02$) and primary biliary cholangitis (25%, $p=0.01$). Three cases (1.9%) were diagnosed with a PoPH, and one of these cases was died due to heart and liver failure, before LT. 2) LT was performed in 19 cases with an RVSP >35 . The 5-years survival rates were 36.1% vs. 34.1% ($p=0.47$) in patient with RVSP value of <36 and >35 in non-LT cases, whereas 85.4% vs. 85.3% in LT cases. There were not significant differences by RVSP value. 3) In a multivariate analysis, the risks of RVSP >35 were high left ventricular ejection fraction ($p=0.02$), brain natriuretic peptide (BNP, $p=0.04$), and absence of gastroesophageal varices ($p=0.04$).

Conclusions: Three cases (1.9%) among LT candidates were diagnosed with PoPH. In LT candidates, it is recommended to check of RVSP before becoming severe condition, especially in cases with elevated BNP.

APASL Oncology 2022 Takamatsu

“Liver Cancer: Clinical and Basic Research”

Abstracts

Poster Free Papers



Risk Analysis of Hepatocellular Carcinoma Development in Non-B Non-C Cirrhotic Patients

Ryota Masuzaki, Naoki Matsumoto, Mai Totsuka, Masayuki Honda, Tomotaka Ishii, Hiroaki Yamagami, Masahiro Ogawa, Tatsuo Kanda, Mitsuhiko Moriyama, Hirofumi Kogure
Department of Internal Medicine, Division of Gastroenterology and Hepatology, Nihon University School of Medicine, Japan

Background and Aims: There has been a dramatic increase in non-B non-C hepatocellular carcinoma (NBNC-HCC) in Japan and other countries. The aim of this study was to evaluate the risk factor of HCC development in non-B non-C cirrhotic patients.

Methods: Between January 1998 and December 2021, a total of 289 cirrhotic patients with HBs Antigen negative and HCV antibody negative cases were included. Those with HCC or past history of it were excluded. Diagnosis of cirrhosis was based on the clinical findings and laboratory features of portal hypertension.

Results: During the follow-up period, HCC developed in 47 patients. The cumulative incidence rates of HCC at one year and two years were 2.5% and 5.2%. Gender male ($P = 0.020$), age > 60 ($P = 0.035$) and AFP $> 10\text{ng/mL}$ ($P = 0.044$) were significant risk factors for HCC development in univariate analysis. Multivariate analysis revealed age > 60 (HR 5.613, 95% CI: 2.245-14.030, $P < 0.001$), AFP $> 10\text{ng/mL}$ (HR 3.207, 95% CI: 1.440-7.142, $P = 0.004$), male gender (HR 2.630, 95% CI: 1.135-6.095, $P = 0.024$) were significant risk factors for HCC development.

Conclusions: Risk factors for NBNC-HCC in cirrhotic patients differed from those in chronic hepatitis patients. Liver function tests were not significant factors in the risk analysis. Non-invasive markers with a wide dynamic range in the cirrhotic stage should be further analyzed.

Mortality Rates and Risk Factors in 1425 Japanese Patients with Decompensated Hepatitis C Virus-Related Cirrhosis

Shunichiro Fujiyama, Norio Akuta, Yusuke Kawamura, Hitomi Sezaki, Tetsuya Hosaka, Satoshi Saitoh, Fumitaka Suzuki, Yoshiyuki Suzuki, Yasuji Arase, Kenji Ikeda, Hiromitsu Kumada
Hepatology, Toranomon Hospital, Tokyo, Japan

Background: Hepatitis C virus (HCV) is the leading cause of liver cirrhosis and hepatocellular carcinoma (HCC) in Japan. We aimed to examine the long-term mortality and HCC rates and associated risk factors in 1425 Japanese patients with decompensated HCV-related cirrhosis.

Methods: Cumulative survival and HCC rates were determined using Kaplan-Meier analysis. Independent risk factors were identified by multivariate analysis.

Results: Median age 68 years, 784 males and 641 females. In total, 62.3%, 41.7%, 4.7%, and 68.3% of the patients had a history of HCC, ascites, hepatic encephalopathy, and esophageal varices, respectively. The 1, 5, 10, and 20 year cumulative overall survival rates in the total cohort was 74.9%, 29.0%, 9.1%, and 1.4%, respectively. The 1, 5, and 10 year cumulative survival rates for patients without HCC were 93.1%, 18.2%, and 4.0%, respectively, and the corresponding cumulative post-decompensation HCC rates were 14.0%, 31.6%, 46.1%, and 66.2%, respectively. The independent risk factors for mortality were older age, Child-Pugh C cirrhosis, the presence of HCC, low estimated glomerular filtration rate, low serum sodium level, low platelet count, and high γ -glutamyl transferase and α -fetoprotein levels for all patients and older age, Child-Pugh C cirrhosis, and low estimated glomerular filtration rate for patients without HCC. Overall, 1035 patients (72.6%) died; the causes of death were liver failure with/without HCC, pneumonia, sepsis, cardiovascular disease, and non-HCC malignancies.

Conclusion: DAAs treatment is possible even for Japanese decompensated HCV-related cirrhosis, and the position of liver cancer treatment in decompensated cirrhosis will become more important as the prognosis of cirrhosis improves.

Promoting Hepatitis Virus Screening for Workers by Using Nudge Theory can Help Detect Carriers Who are Unaware of Their Infection and Require to Therapy for Hepatocellular Carcinoma

Masaaki Korenaga, Tatsuya Kanto

Hepatitis Information Center, The Research Center for Hepatitis and Immunology, National Center for Global Health and Medicine, Ichikawa, Chiba, Japan

Background: In Japan Health Insurance Association, which is belonged to more than 37 million Japanese who are working in Medium and Small Sized Companies, the attendance rates of hepatitis screening were less than 2% even the cost of only \$ 6. The aim of this study was to investigate impact of an intervention by nudge versus a typical message on promoting screening for viral hepatitis and how many of those found to be positive for HCV antibody have been followed up with examinations and hospital treatment.

Methods: More than 1.3 million Japanese workers at Fukuoka branch of the JHIA who wish to get annual general checkup from 2017 to 2019 received client reminders by using nudge theory for an optional hepatitis virus screening. For control subjects, we enrolled general checkup applicants with typical message condition in 2016.

Results: There was a significant difference in viral hepatitis screening attendance rates between the client reminders using nudge theory (n=114,531 8.4%) and the control (n=4,791 1.2%). One thousand seventy-nine workers (0.94%) were positive of HBsAg (0.55%) and HCV Ab (0.38%), respectively. Among them, two hundred forty with positive were confirmed to visit specialists within 6 months after the screening. Seventy-five were treated with direct-acting antivirals and two males (0.8%) in 60s were detected hepatocellular carcinoma.

Conclusion: A simply modifying the client reminders using nudge theory could increase the viral hepatitis screening rates. Promoting hepatitis virus screening for workers can help detect carriers who are unaware of their infection and require to therapy for cancer.

Etiological Transitions in Patients with Liver Cirrhosis and Hepatocellular Carcinoma: A Single-center Study from an Institution Located in a District with a High Prevalence of Viral Hepatitis

Hirayuki Enomoto, Tomoyuki Takashima, Takashi Nishimura, Nobuhiro Aizawa, Naoto Ikeda, Yukihiisa Yuri, Mamiko Okamoto, Kohei Yoshihara, Ryota Yoshioka, Shoki Kawata, Shogo Ota, Ryota Nakano, Hideyuki Shiomi, Hiroko Iijima

Division of Hepatobiliary and Pancreatic Disease, Department of Internal Medicine, Hyogo Medical University, Japan

Background: In Japan, viral hepatitis is the main cause of chronic liver diseases, including liver cirrhosis (LC) and hepatocellular carcinoma (HCC). Due to the availability of highly effective antiviral drugs in combination with anti-hepatitis measures, Japan has become one of the most successful countries in the world with regard to hepatitis virus elimination. A recent nationwide survey has shown that the contribution of viral hepatitis as an etiology of LC is suggested to have been decreasing (J Gastroenterol. 2020;55:353-362). Our institution is located in a district with a markedly high prevalence of viral hepatitis, including a particularly high number of hepatitis virus C (HCV)-infected patients. We thus investigated the details of inpatients, focusing on the contribution of viral hepatitis-related cirrhosis and HCC.

Methods: We classified inpatients of our department into three groups (diagnosed in <2007, 2008-2012, and 2013-2017) and analyzed the changing trends in the etiologies of LC (N=1152) and HCC (N=733).

Results: Regarding the transition in the etiologies of LC, the contribution of viral hepatitis-related cirrhosis decreased from 80.1% to 63.2%. In particular, HCV-related cirrhosis was found to have dropped from 70.2% to 49.4%. Regarding the etiologies of HCC, the contribution of viral hepatitis-related HCC remarkably decreased from 91.8% to 71.3%. HCV-related HCC was found to have also declined from 82.6% to 54.5%.

Conclusion: Our data in daily practice was consistent with the recent nationwide survey regarding the etiologies in LC and HCC, depicting a decreasing trend in viral hepatitis and increasing trend in non-viral liver diseases.

Epidemiological and Clinical Characteristics of Hepatocellular Carcinoma in Kazakhstan

Arailym Maikenova¹, Kamila Zhumagaliyeva¹, Aikerim Sakagan¹, Alma Zhylkaidarova², Alexander Nersesov¹

¹Department of gastroenterology, Asfendiyarov Kazakh National Medical University, Almaty, Kazakhstan, ²Kazakh Institute of Oncology and radiology, Almaty, Kazakhstan

Background: The aim of this study was to characterize the epidemiological and clinical characteristics of hepatocellular carcinoma (HCC) in the Republic of Kazakhstan.

Methods: National Cancer Registry data for the period of 2011-2020 years and results of standard clinical examination of 170 patients admitted to the National Institute of Cardiology and Internal Diseases and to the Medical Center “Evelina” were evaluated.

Results: For the mentioned period, as many as 5070 patients with HCC were listed in the Registry, and it was 13th place of all malignancies. Majority of them (42,2%) had 4th stage of disease, followed by 1-2th (32,2%), 3rd (25,6%) stages and most of them were men (66,5%) aged 50-70 (57,1%) years old. Among 170 patients the main causes of underlying liver disease were hepatitis viruses: HCV (27,5%), HBV (26,5%), HDV (21%). The age was between 50 - 70 years (69,5%), and the middle age was 60±4 years. Males/females ratio was 58,8%/41,2% and varies depending on etiology: 55,3%/44,7% - in HCV, 64,2%/35,8% - in HBV and 40,7%/59,4% - in HDV, 84,5%/15,6% - in alcoholic liver disease, 40%/60 - MAFLD related disease. In the majority of cases HCC was diagnosed in Child-Pugh B class of liver cirrhosis: HCV (51%), HBV (34,5%), HDV (61%), alcoholic liver disease (50%), MAFLD (50%).

Conclusion: HCC in Kazakhstan is characterized 13th place out of all malignancies, predominantly in men aged 50-70 years old. Based on our findings, predominant HCV etiology and prevalence in male patients with Child-Pugh B class of liver cirrhosis.

The Analysis of Survival Prognosis and Cause of Death after Sustained Virologic Response

Satoshi Miura, Yasuhiko Nakao, Masanori Fukushima, Ryu Sasaki, Hisamitsu Miyaaki, Kazuhiko Nakao

Department of Gastroenterology and Hepatology, Nagasaki University Hospital, Nagasaki, Japan

Background: Sustained virologic response (SVR) occurs in many patients with chronic hepatitis C and cirrhosis. Management of patients with SVR is important for increasing survival rates. In this study, we analyzed the prognosis, cause of death, and factors contributing to survival in patients with SVR.

Methods: Of 1,656 patients introduced to IFN-free DAA therapy at 18 institutions between September 2014 and December 2020, 1,373 patients with SVR were enrolled in this study. Factors contributing to survival were analyzed using the Cox proportional-hazards model.

Results: The survival rate of patients with SVR was 94.4% at 3 years and 90.3% at 5 years. Of the 76 deaths, 23 were liver disease-related, 35 were not liver disease-related, and 18 were unknown. Factors contributing to poor prognosis were age ≥ 71 years (RR=3.021, $p < 0.001$) and previous history of hepatocellular carcinoma (HCC) treatment (RR=2.649, $p < 0.001$). The analysis stratified by previous HCC treatment history indicated that age ≥ 71 years only affected survival in patients with SVR with no HCC treatment history (RR=3.044, $p = 0.002$), and only three or more sessions of HCC treatment in those with HCC treatment history (RR=2.395, $p = 0.047$). The main cause of death in patients with no history of HCC treatment was not liver disease-related (60.0%, 27/45), of which malignant neoplasms except for HCC were the most frequent cause of death (59.3%, 16/27).

Conclusions: To improve the survival prognosis of patients with SVR, systemic management with health checkups and cancer screening is necessary.

New Simple Clinical Score to Predict Hepatocellular Carcinoma after Sustained Viral Response with Direct-acting Antivirals

Makoto Morita, Takao Watanabe, Yoshio Tokumoto, Ryo Yano, Yuki Okazaki, Kotaro Sunago, Yoshiko Nakamura, Yusuke Imai, Yohei Koizumi, Osamu Yoshida, Masashi Hirooka, Masanori Abe, Yoichi Hiasa

Department of Gastroenterology and Metabology, Ehime University Graduate School of Medicine, Ehime, Japan

Background: Hepatocellular carcinoma (HCC) sometimes develops even after viral eradication with direct-acting antiviral (DAA) therapy. However, few simple methods have been established to evaluate the risk of HCC after DAA treatment. The aim of this study was to develop a scoring system to predict the occurrence of HCC after DAA treatment.

Methods: A total of 1741 chronic hepatitis C patients without HCC who underwent DAA therapy and achieved a sustained virological response (SVR) were included. We developed a predictive scoring system to estimate HCC occurrence using factors at SVR at 12 weeks after the end of treatment (SVR12).

Results: Multivariate analysis identified male sex (hazard ration (HR) = 2.44; 95% confidence interval (CI) 1.12–5.31, $p = 0.024$), α -fetoprotein (AFP) (HR = 1.05; 95% CI 1.00–1.19, $p = 0.038$), the FIB-4 index (HR = 1.12; 95% CI 1.06–1.18, $p < 0.001$), and albumin (HR = 0.39; 95% CI 0.16–0.92, $p = 0.032$) as independent factors at SVR12 that contributed to the occurrence of HCC after DAA therapy. We constructed a prediction model for HCC occurrence with these four factors that ranged from 0–7 points. No HCC occurrence after DAA therapy was observed in the very low-risk group (0–1 point). Five-year cumulative occurrence rates of HCC were 2.4% in the low-risk group (2–3 points), 6.2% in the intermediate-risk group (4–5 points), and 22.3% in the high-risk group (6–7 points).

Conclusions: Our newly proposed, simple scoring system combining four factors can accurately evaluate the HCC risk at SVR12 with DAA treatment.

Liver Stiffness is a Useful Predictor for Exacerbation of Esophagogastric Varices after Hepatitis C Virus Eradication by Direct-acting Antivirals

Yuko Nagaoki, Michio Imamura, Hiroshi Aikata

Department of Gastroenterology and Metabolism, Graduate School of Biomedical and Health Science, Hiroshima University, Hiroshima, Japan

Aim: We aimed to identify risk factors contributing to the aggravation of esophagogastric varices (EGV) after hepatitis C virus (HCV) eradication with direct-acting antiviral (DAA) therapy.

Methods: 167 consecutive patients who achieved sustained virological response (SVR) by DAA therapy were enrolled.

Results: When these patients were observed over a period of median 69 (range, 3-127) months, EGV was aggravated in 42 (25%) patients despite of SVR. The cumulative 3, 5 and, 8 years aggravation rates were 23%, 25%, and 27%, respectively. Multivariate analysis identified platelet count (Plt) $<11.0 \times 10^4 / \mu\text{L}$ ($P = 0.001$), LSM >18.0 kPa ($P = 0.001$) and diameter of left gastric vein (LGV) >5.0 mm at the time of HCV eradication ($P = 0.001$) as independent risk factors for the aggravation of EGV after SVR. Cumulative aggravation rates with 1, 3 and 5 years were 22%, 76%, and 83% for the diameter of LGV >5.0 mm, LSM >18.0 kPa, and Plt $<11.0 \times 10^4 / \mu\text{L}$, significant aggravation of EGV was observed. On the other hands, patients with LGV <5.0 mm, LSM <18.0 kPa and Plt $>11.0 \times 10^4 / \mu\text{L}$ never developed aggravation of EGV. In addition, we analyzed whether or not LSM were reduced after SVR for patients with aggravation of EGV, although hepatic spare ability were improved, LSM could not reduce until 2 years after SVR.

Conclusion: Our findings suggest that EGV could be aggravated even if SVR were acquired. It is useful for predicting the presence of radical portosystemic collateral vessels, platelet count, and liver stiffness at the end of treatment for EGV aggravation.

Successful Retreatment of Direct-acting Antiviral Therapy against Hepatitis C Virus Infection in a Patient Who Underwent a Liver Transplant from HLA-Matched Sibling Donor

Tatsuo Kanda¹, Reina Sasaki-Tanaka¹, Naoki Matsumoto¹, Tomotaka Ishii¹, Ryota Masuzaki¹, Msahiro Ogawa¹, Shintaro Yamazaki², Osamu Aramaki², Hirofumi Kogure¹, Yukiyasu Okamura²

¹Division of Gastroenterology and Hepatology, Department of Medicine, Nihon University School of Medicine, ²Division of Digestive Surgery, Department of Surgery, Nihon University School of Medicine, Tokyo, Japan

Case: 50s, male. Present Illness: He underwent a liver transplant for his decompensated cirrhosis and hepatitis C virus (HCV) genotype-1b infection from HLA-matched sibling donor 8 years ago. Steroid was used as an immunosuppressant for only 7 days, including the day of surgery. After 1.5 months of transplant, 12-week-treatment of 50 µg weekly peginterferon α-2b plus 600 mg daily ribavirin, following the 12-week-treatment of 100 mg daily HCV NS3/4A inhibitor simeprevir with 50 µg weekly peginterferon α-2b plus 600 mg daily ribavirin was performed for his HCV re-infection, however, his HCV RNA was relapsed after one month of the end of treatment. HCV NS3 Q80L, R155T and D168E were found as resistance-associated mutations. After 2 years of transplant, the 12-week-combination retreatment of HCV NS5B inhibitor sofosbuvir plus HCV NS5A inhibitor ledipasvir were performed. Finally, he achieved sustained virological response (SVR) without hepatitis B virus (HBV) reactivation although he had a history of HBV infection. Although almost 8 years have passed since liver transplant, his HCV RNA and HBV DNA are undetectable, and ultrasound sonography demonstrated no space occupying lesions and no advanced liver fibrosis.

Discussion: After living donor related liver transplant from HLA-matched sibling donor, it is possible stop the immunosuppressants, due to immune tolerance. The present case received direct-acting antiviral therapy against HCV re-infection immediately after transplant, achieved SVR and his postoperative process is going well. Conclusion: It is important to cure HCV re-infection even in a patient with liver transplant from HLA-matched sibling donor as soon as possible.

Risk Factors Contributing to Occurrence and Recurrence of Hepatocellular Carcinoma After the Eradication of Hepatitis C Virus by Direct-acting Antivirals

Masakuni Tateyama, Yoko Yoshimaru, Kentarou Tanaka, Satoshi Narahara, Sotarou Kurano, Hiroki Inada, Takayuki Tokunaga, Katsuya Nagaoka, Takehisa Watanabe, Hiroko Setoyama, Yasuhito Tanaka

Department of Gastroenterology and Hepatology, Graduate School of Medical Sciences, Kumamoto University, Kumamoto, Japan

Objective: To clarify the factors contributing to occurrence of hepatocellular carcinoma (HCC) and the prognosis of the patients infected the hepatitis C virus (HCV) who achieved sustained virological response (SVR) by direct-acting antivirals (DAA) treatment.

Methods: A total of 1110 patients with SVR were enrolled. We analyzed these factors contributing to occurrence of HCC by using cox regression analysis.

Results: Median age is 67.0 years and male numbers are 514. The proportion of liver cirrhosis was 19.7%. During the follow-up period, HCC developed in 60 (9.6%) patients. Significant factors contributing to occurrence of HCC were age (≥ 70 years, hazard ratio (HR) 2.265, $p = 0.005$), AFP (≥ 7.0 ng/mL, HR 3.076, $p < 0.001$), alcohol intake (yes, HR 2.474, $p = 0.003$) and the existence of liver cirrhosis at entry (yes, HR 2.077, $p = 0.017$). Moreover, AFP after 6 months from the end of DAA treatment (≥ 3.0 ng/mL, HR 3.073, $p < 0.001$) was also significant factor. The cumulative incidence rate of HCC was 4.7% at three-year. According to the recurrence of HCC, the cumulative recurrence rate of HCC was 17.7% at one-year and 46.3% at three-year, respectively. The presence of curative treatment was the only significant factor contributing to HCC recurrence (yes, HR 3.559, $p = 0.015$).

Conclusion: Liver cirrhosis and AFP were considered as the risk factors for HCC after SVR. Furthermore, alcohol intake was an additional risk factor for HCC development, suggesting the need to take care of the situation of alcohol intake after SVR.

Dysregulation of the Intestinal Microbial Communities among Chronic Hepatitis C Patients with Hepatocellular Carcinoma

Takako Inoue¹, Jiro Nakayama², Masaya Ohnishi³, Kei Moriya⁴, Hideto Kawaratani⁴, Hisayoshi Watanabe⁵, Yui Funatsu², Masaru Tanaka², Rie Momoda², Yutaka Suzuki³, Etsuko Iio⁶, Kentaro Matsuura⁷, Hitoshi Yoshiji⁴, Yasuhito Tanaka⁸

¹Department of Clinical Laboratory Medicine, Nagoya City University Hospital, Nagoya, Japan,

²Laboratory of Microbial Technology, Division of Systems Bioengineering, Department of Bioscience and Biotechnology, Faculty of Agriculture, Graduate School, Kyushu University, Fukuoka, Japan, ³Department of Computational Biology and Medical Sciences, Graduate School of Frontier Sciences, The University of Tokyo, Kashiwa, Japan, ⁴Third Department of Internal Medicine, Nara Medical University, Kashihara, Japan, ⁵Department of Gastroenterology and Hepatology, Tohoku Central Hospital for Public School Teachers, Yamagata, Japan, ⁶Department of Virology and Liver Unit, Nagoya City University Graduate School of Medical Sciences, Nagoya, Japan, ⁷Department of Gastroenterology and Metabolism, Nagoya City University Graduate School of Medical Sciences, Nagoya, Japan, ⁸Department of Gastroenterology and Hepatology, Faculty of Life Sciences, Kumamoto University, Kumamoto, Japan

Background: The intestinal microbial community in patients with hepatocellular carcinoma (HCC) caused by chronic hepatitis C (CHC) is little known. We investigated gut microbiota and BAs metabolism of CHC patients.

Methods: The gut microbiota and fecal BAs composition from 100 CHC patients including HCC patients were compared with those from healthy individuals. The gut microbiota community was analyzed using 16S ribosomal RNA gene sequencing. Quantification of fecal BAs composition was carried out using the high-performance liquid chromatography tandem mass spectrometry. Whole-transcriptome sequencing (RNA-seq) of BAs metabolism-related genes in the liver were analyzed. For RNA-Seq, 64 CHC were compared with individuals with normal liver. The study protocol was approved by the appropriate institutional ethics review committees.

Results: In CHC patients, as the disease progressed from chronic hepatitis to cirrhosis and HCC, the diversity of intestinal bacteria was significantly reduced, and the relative amount of fecal *Streptococcus* tended to increase. In CHC patients, especially with HCC, fecal deoxycholic acid (DCA) was significantly decreased, therein lithocholic acid or ursodeoxycholic acid became dominant. Under HCV infection, the biosynthesis deficiency of cholic acid (CA), which is generally converted to DCA by gut microbiota, was observed as reduction of transcriptional level of cytochrome P450 8B1, which is a main enzyme in CA biosynthesis in the BA classical pathway.

Conclusions: Among the patients with HCV infection including HCC, the changes of BAs metabolism-related genes expression appear to be associated with gut dysbiosis and BA dysmetabolism. In liver diseases including CHC, these imbalances may drive liver disease progression.

During the Chemotherapy Against Lung Cancer in Patients with HCV and Decompensated Cirrhosis, DAA Could Support Sufficient Lung Cancer Treatment

Tatsuo Kanda, Shinji Shibuya, Shuhei Arima, Masayuki Honda, Tomotaka Ishii, Reina Sasaki-Tanaka, Shini Kanezawa, Ryota Masuzaki, Naoki Matsumoto, Hirofumi Kogure, Masahiro Ogawa
Division of Gastroenterology and Hepatology, Department of Medicine, Nihon University School of Medicine

Case: 70s, male. Past History: 10 years ago, he received laparoscopic partial gastrectomy for early gastric cancer. 6 years ago, he received partial hepatectomy for hepatocellular carcinoma (HCC). He takes telmisartan daily for his hypertension and he has opportunity drinking. HCC has not recurred although he has never received direct-acting antiviral (DAA) treatment for the eradication of hepatitis virus C (HCV) infection.

Present Illness: He diagnosed as lung adenocarcinoma (T1bN2M0IIIB Stage IIIB) with Performance Status (PS) Score 1 and liver cirrhosis. HCV RNA levels and genotype were 3.8 LIU/mL and GT-2a, respectively. His liver tests were as following: AST, 96 IU/L; ALT, 116 IU/L; platelets, 104, 000/ μ L; albumin, 3.8 g/dL; and Child-Pugh, A6. He started to be treated with radiation therapy (60 Gy), combined with chemotherapy [CDDP (80% dose)/VNR (100% dose), CDDP (60% dose)/VNR (80% dose)] for his lung cancer. Two and 3 months later, respectively, he commenced to be treated with durvalumab for lung cancer and combination of sofosbuvir with velpatasvir for decompensated cirrhosis (albumin, 2.9 g/dL). After one month of the commencement of DAA, serum HCV RNA was undetectable and albumin level was 3.5 g/dL. At present, sustained virological response (SVR) achieved and anti-lung cancer treatment continued.

Conclusion: Due to the use of immunosuppressants and/or anticancer agents, liver failure should develop or dose reduction of them be needed in certain cases with cirrhosis and HCV infection. It is possible that sufficient cancer treatment for other organs than liver may be performed after the achievement of SVR.

Risk of HCC Development following Achievement of SVR in Patients with Cirrhosis Receiving DAA Therapies for HCV

Yoshihito Uchida, Shohei Tsuji, Hayoto Uemura, Nabuaki Nakayama, Yukinori Imai, Satoshi Mochida

Department of Gastroenterology & Hepatology, Faculty of Medicine, Saitama Medical University

Aims: To clarify factors associated with occurrence/recurrence of HCC in patients with cirrhosis who had achieved SVR after DAA therapies.

Methods: Factors associated with occurrence/recurrence of HCC were evaluated in 234 patients with cirrhosis, in whom SVR was obtained following DAA therapies at least for 48 weeks before.

Results: During the median observation period for 3.4 years, HCC developed in 36 (20.2%) of 178 HCC-naïve patients, and recurred in 35 (62.5%) of 56 patients with previous therapies for HCC. The cumulative occurrence rates of HCC at 1, 3 and 5 year(s) were 2.3%, 13.3% and 19.5%, respectively. Multivariate analysis identified serum M2BPGi levels at baseline and serum AFP levels at SVR24 as significant factors associated with HCC occurrence within 3 years after SVR, with hazard rates of 1.14 (every 1.00 C.O.I, P=0.0015) and 1.47 (every 1 ng/dL, P=0.0345), respectively. Also, the analysis identified diabetes mellitus as a marginal factor associated with HCC occurrence later than 3 years after SVR, with a hazard rate of 2.72 (P=0.0785). In contrast, the cumulative recurrence rates of HCC at 1, 3 and 5 year(s) were 20.0%, 58.6% and 67.0%, respectively. Multivariate analysis identified age and serum AFP level at SVR48 as significant factors associated with HCC recurrence, with hazard ratios of 1.06 (every 1 year, P=0.0142) and 1.01 (every 1.00 C.O.I, P=0.0228), respectively.

Conclusion: Factors associated with HCC development after achieving SVR in cirrhotic patients with HCV were different between those with or without previous HCC therapies depending on the periods after SVR achievement.

Assessment of Impaired Glomerular Filtration Function in Chronic Hepatitis C Patients

Batbold Batsaikhan, Gantogtokh Dashjamts, Ankhzaya Batsaikhan, Otgongerel Nergui, Ganchimeg Dondov, Tegshjargal Badamjav, Tulгаа Lonjid
Department of Internal Medicine, Institute of Medical Sciences, Mongolian National University of Medical Sciences

Introduction: Approximately 71 million people worldwide are infected with the hepatitis C virus, which causes more than 399,000 deaths from cirrhosis and liver cell cancer. It is controversial that the impaired kidney function in chronic hepatitis C patients, especially in the background of liver fibrosis.

Material and Methods: Patients with chronic hepatitis C virus were referred from two regional hospitals which were Third Central Hospital, Tegsh Huslen Medical Center, from August to October 2020. An estimated glomerular filtration rate in chronic hepatitis C were analyzed by Modification of Diet in Renal Disease equation.

Results There were totally 115 patients enrolled and 54 (46.9%) individuals whose renal glomerular filtration rate was reduced to less than 90 ml/min. In a linear regression analysis, a decrease of renal glomerular filtration rate and the age was a significant correlation. Logistic regression analysis showed that people with hypertension over the age of 52 were 6.4 times more likely to have a lower renal glomerular filtration rate (95% confidence interval 1.3-31.4, $p=0.021$) compared with those without hypertension under the age of 52.

Conclusion: Totally 46.9% of patients with chronic hepatitis C were decreased glomerular filtration rate. This suggests that patients with chronic hepatitis C may be at risk for renal failure. The age of the patient and high blood pressure are contributing factors to the decline in the incidence of low glomerular filtration rate in patients with chronic hepatitis C.

Relation of Phosphatase and Tensin Homolog Gene Polymorphism with Hepatocellular Carcinoma among Hepatitis C Infected Patients

Mohamed Abdel Samiee¹, Iman Eltounsi², Olfat M. Hendy³, Nahla Osman², Amira Shehata², Isis S. El Morsy Bedira³

¹Department of Hepatology and Gastroenterology, National Liver Institute, Menoufia University, Shebin El-Kom, Egypt, ²Clinical Pathology, Faculty of Medicine, Menoufia University, Shebeen El-Kom, Egypt, ³Clinical and Chemical Pathology, National Liver Institute, Menoufia University, Shebeen El-Kom, Egypt

Background: PTEN polymorphisms have been reported to be involved in multiple cancers. There are few reports concerning the linkage between the PTEN gene and liver cancer risk. Our objective was to study the significance of two phosphatase and tensin homolog (PTEN) gene polymorphisms, PTEN IVS4 rs3830675 and rs701848, as a risk factor for hepatocellular carcinoma (HCC) in chronic hepatitis C infected patients.

Methods: The study was conducted on 200 participants. Of them, 80 had proven HCC, 60 were cirrhotic patients with no evidence of focal lesion, and 60 were healthy age matched and sex matched volunteers, enrolled in the study as a control group. PTEN IVS4 rs3830675 and rs701848 assessments by PCR restricted fragment length polymorphism technique were done for all participants.

Results: The frequency of IVS4 rs3830675 (negative negative) genotype in patients with HCC was 56%, which is significantly increased compared with cirrhotic group (11.7%) and control group (10%). The combined dominant model (negative negative/negative positive) was significantly higher than (Positive positive) genotype in patients with HCC compared with cirrhotic and control groups. The PTEN rs701848 polymorphisms (TT, TC, or CC) showed no significant difference among the three studied groups as well as allele distributions (T or C).

Conclusion: PTEN (IVS4 rs3830675) deletion (negative negative) genotype may be a risk factor for HCC in chronic hepatitis C infected patients more than (Positive positive) genotype. However, PTEN polymorphism (rs701848) was of no significance.

Influence of Hepatitis B Virus Genotypes on Expression of Viral Antigen and Host Cytokines

Shiheng Xu^{1,2,3,4}, Li Li¹, Rongxia Zuo^{1,3}, Jianmei Gao^{1,2}, Qi Yin¹, Chenchen Huang¹, Yu Liang^{1,2}, Jing Chen^{1,2}, Tao Shen^{1,2,3,4}

¹Yunnan Provincial Key Laboratory for Clinical Virology, Institute of Basic and Clinical Medicine, The First People's Hospital of Yunnan Province, ²Kunming University of Science and Technology, ³Department of Pulmonary and Critical Care Medicine, The First People's Hospital of Yunnan Province, ⁴Yunnan Province Innovation Team of Intestinal Microecology Related Disease Research and Technological Transformation, the First People's Hospital of Yunnan Province

Background: Genomic heterogeneity of hepatitis B virus (HBV) may contribute to genotype-specific clinical outcomes in HBV-related disease, but the biological characteristics underlying virological differences are not well defined.

Objective: To investigate the viral antigen and cytokine levels in HBV/C2, HBV/B3 and HBV/I1 subgenotypes replicative models.

Methods: Huh7 cells and C57BL/6 mice were transfected with plasmids carrying 1.3-fold the HBV genome of B3, C2 and I1, respectively. Cell supernatant and mouse venous blood from canthus were collected at different time points after transfection, the expression levels of HBV surface antigen (HBsAg), IL-2, IL-4, IL-6, IL-10, TNF- α , IFN- γ and IL17A were detected.

Results: HBsAg in cell supernatant was most abundant for C2 followed by B3, and remotely by I1, which was consistent with HBsAg levels in serum of mice. In the early and middle stages(12-54h), IL-2, IL-6 and TNF- α in cell supernatant were significant higher in I1 than in C2 and B3, and IL-4 was the lowest for I1, IFN- γ levels were not statistically significant difference until the late stage (102h). The expression levels of IL-2, IL-6, TNF- α and IL-4 in mice serum were significantly higher in I1 than in C2 and B3 at the 28th day after transfection, and IL-6, TNF- α , IL-17A, IL-4 and IL-10 were higher in B3 than C2 in the first week after transfection.

Conclusion: Various of cytokines have been shown to depend on HBV-genotypes, thus may in turn to control HBV replication and may contribute to different outcomes of HBV-related disease.

Clinical Utility of Droplet Digital PCR for HBV cccDNA Quantification

Sanae Hayashi¹, Yuji Morine², Mitsuo Shimada², Takehisa Watanabe¹, Yasuhito Tanaka¹

¹Department of Gastroenterology and Hepatology, Faculty of Life Sciences, Kumamoto University, Kumamoto, Japan., ²Department of Surgery, Tokushima University, Tokushima, Japan.

Background: Covalently closed circular DNA (cccDNA) poses the major obstacle to curing chronic HBV infection. Here, we developed a ddPCR assay for the quantitation of HBV cccDNA and its clinical application.

Methods: 1) The performance of cccDNA-specific ddPCR was determined using the total DNA extracted from the liver of patients with HBV. 2) The amount of intrahepatic cccDNA and RPP30 in liver tissues from 20 HBV-related HCC patients was measured using the ddPCR assay. Written informed consent was obtained from each patient and the study protocol conformed to the ethical guidelines of the 1975 Declaration of Helsinki.

Results: 1) ddPCR could accurately detect less than two-fold differences than qPCR ($R^2=0.997$ and $R^2=0.978$, respectively). Remarkably, the levels of cccDNA in the liver of humans were more sensitively detectable from a lower amount of total DNA by ddPCR compared to qPCR. The cccDNA-specific ddPCR assay could detect intrahepatic cccDNA with high specificity. 2) In two HBsAg-positive, HBcrAg-positive patients, the cccDNA levels were 0.00933–0.05081 copies/cell in non-tumor tissues, and 0.93442–1.17975 copies/cell in tumor tissues. In contrast, In the HBsAg-positive, HBcrAg-negative patient, cccDNA was detected weakly at 0.00013 copies/cell in tumor tissue, while it was undetectable in non-tumor tissue. In 17 HBV-resolved HCC patients, 1 patient had detectable the cccDNA levels in the non-tumor tissue, suggesting the risk of de novo HBV-related hepatitis. These data showed that ddPCR could detect cccDNA in tumor and non-tumor tissues.

Conclusions: A sensitive, specific, highly quantitative ddPCR was developed for the measurement of cccDNA in the liver.

Effects of Lenvatinib on The Cell Cycle and Related MicroRNA Profiling in Hepatocellular Carcinoma Cells

Mai Nakahara, Kei Takuma, Kyoko Oura, Tomoko Tadokoro, Koji Fujita, Joji Tani, Asahiro Morishita, Tsutomu Masaki

Department of Gastroenterology and Neurology, Faculty of Medicine, Kagawa University, Japan

Lenvatinib is a receptor tyrosine kinase inhibitor used for treatment of unresectable hepatocellular carcinoma (HCC). Here, we investigated the antitumor effect of lenvatinib in HCC.

Methods: Cell proliferation was examined in four HCC cell lines (HuH-7, Hep3B, Li-7, and PLC/PRF/5) using a Cell Counting Kit-8 assay. Xenografted mouse models were used to assess lenvatinib effects in vivo. Cell cycle analysis, western blotting analysis, and microRNA expression analysis were performed to identify antitumor inhibitory potential of lenvatinib on HCC cells. Lenvatinib suppressed proliferation in HuH-7 and Hep3B cells but not Li-7 and PLC/PRF/5 cells and induced G0/G1 cell cycle arrest and cyclin D1 downregulation in lenvatinib-sensitive cells. Lenvatinib also reduced tumour growth of HuH-7 xenografted mouse models. MiRNA microarrays revealed that lenvatinib altered the expression of miRNAs in HuH7 cells and exosomes. Our results demonstrate the therapeutic potential of lenvatinib and provide molecular mechanistic insights into its anti-tumour effect in HCC.

Construction of MiRNA-mRNA Pairs Reveals Potential Regultaory Axis for Hepatocellular Carcinoma Cell Transfected with HBV

Qi Yin^{1,2}, Shiheng Xu^{1,2}, Li Li¹, Chenchen Huang¹, Yalian Sa¹, Jing Chen¹, Rongxia Zuo^{1,3}, Qian Zhao^{1,2}, Tao Shen^{1,2,3,4}

¹Yunnan Provincial Key Laboratory for Clinical Virology, Institute of Basic and Clinical Medicine, The First People's Hospital of Yunnan Province, ²Kunming University of Science and Technology, ³Pulmonary and Critical Care Medicine Department, The First People's Hospital of Yunnan Province, ⁴Yunnan Province Innovation Team of Intestinal Microecology Related Disease Research and Technological Transformation, The First People's Hospital of Yunnan

Background: Hepatitis B virus (HBV) is one of the high risk factor of hepatocellular carcinoma (HCC). Available evidence revealed the HBV genotype/subgenotype is associated with the different incidence of the HBV-related HCC. In addition, increasing data showed that microRNA(miRNA)-mRNA axis is involved in HCC. However, a comprehensive miRNA-mRNA regulatory network in HBV genotype/subgenotype-related HCC is still absent. This study aimed at identifying HBV C2 and B3 subgenotype-associated miRNA-mRNA pairs.

Method: Huh7 cell stably transfected with recombinant plasimds of pcDNA3.1(+)/HBV-B3 and pcDNA3.1(+)/HBV-C2 were performed mRNA-seq and miRNA-seq, respectively. Diffienetial expression (DE) miRNAs and mRNAs were obtained using DESeq2 package. Protein-protein interaction (PPI) network was constructed using Cytoscape software and candidate Hub gene was identified. DE miRNAs related to hub gene were predicted using target network, and possible miRNA-mRNA regulation axis was predicted using functional analysis.

Results: A total of 490 DE mRNAs and 105 DE miRNAs commonly expressed in Huh7 vs.Huh-7/HBV-B3 and Huh7 vs.Huh-7/HBV-C2 were obtained, respectively. 25 hub genes were identified, including DDX58, which expression was lower in Huh7-HBV positive cells than Huh-7 cell and was related to hepatitis B related pathways. hsa-mir-12136 was predicted as a regulator to DDX58, and its expression was up-regulated in Huh7-B3 and Huh7-C2 than that in Huh7 cells.

Conclusion: This study provide hsa-miR-12136-DDX58 axis as a valuable resource for understanding regulatory mechanisms at the RNA level and might assist in the development of diagnostic and/or therapeutic targets for HCC.

Profile of MicroRNAs Associated with Aging in Rat Liver

Shima Mimura¹, Koji Fujita¹, Masafumi Ono¹, Kei Takuma¹, Mai Nakahara¹, Kyoko Oura¹,
Tomoko Tadokoro¹, Joji Tani¹, Asahiro Morishita¹, Takashi Himoto², Tsutomu Masaki¹

¹Department of Gastroenterology and Neurology, Kagawa University Hospital, Kagawa, Japan,

²Department of Medical Technology, Kagawa Prefectural University of Health Sciences, Kagawa,
Japan

Background: Recent reports suggest that small non-coding microRNAs (miRNAs) play an important role in the regulation of genes involved in various cellular and developmental processes. However, the expression of miRNAs during the aging process remains largely unknown. The aim of the present study was to analyze the miRNA expression profile of rat livers during the aging process.

Methods: The livers of fetal, male Wistar rats aged 3 days-old, 1, 2, 4, 8 and 36 weeks-old were used. Total RNA was extracted from the livers. We analyzed the expression level of 679 rat miRNA probes. In addition, immunohistochemical staining for proliferating cell nuclear antigen (PCNA) was performed.

Results: Several up- and down-regulated miRNAs were identified in the rat liver at 7 different fetal developmental stages and at 36 weeks of age. We observed up-regulation of miR-29a, miR-29c, miR-195 and miR-497, while miR-301a, miR-148b-3p, miR-7a, miR-93, miR-106b, miR-185, miR-450a, miR-539 and miR-301b were down-regulated in the aging rat liver. PCNA positive hepatocytes were decreased with age.

Conclusion: Our findings suggest that these up- and down-regulated miRNAs play an important role in aging by regulating cell cycles that are involved in liver senescence.

The Analysis of Circulating Tumor DNA in Advanced Hepatocellular Carcinoma Treated with Lenvatinib

Yasutoshi Fujii, Atsuahi Ono, C. Nelson Hayes, Shinsuke Uchikawa, Yuji Teraoka, Hatsue Fujino, Takashi Nakahara, Eisuke Murakami, Daiki Miki, Tomokazu Kawaoka, Michio Imamura, Hiroshi Aikata

Department of Gastroenterology and Metabolism, Graduate School of Biomedical & Health Sciences, Hiroshima University, Hiroshima, Japan

Background: There has been a recent surge in interest in predicting biological effects associated with genomic alterations in cancer treatment. Lack of tissue samples for biomarker studies is an endemic problem in advanced hepatocellular carcinoma (HCC). Mutation analysis of circulating tumor DNA (ctDNA) has emerged as an alternative approach for assessing tumor molecular information.

Method: We retrospectively performed ctDNA next-generation sequencing (NGS) analysis in 24 patients with advanced HCC at baseline and 4 weeks after initiation of lenvatinib (LEN).

Results: In total, 131 single nucleotide variants, 17 indels, and 23 copy number variations were detected as somatic alterations in 23 of 24 patients. The most frequently altered genes were TP53 (54%), CTNNB1 (42%), and TERT (42%). The reduction in the mean frequency of variants (VAF_{mean}) after 4 weeks was associated with longer progression-free survival. The specificity and sensitivity of the reduction in VAF_{mean} for predicting partial response were 0.67 and 1.0, which were higher than those of serum alpha-fetoprotein level (0.70 and 0.71). No association between the mutation status at baseline and the effectiveness of LEN was observed. The distribution of clonality was bimodal, and the subclonal/clonal ratio increased after 4 weeks of treatment (0.49 to 0.64).

Conclusion: Our study demonstrated that ctDNA reflected known evolution of HCC and that ctDNA-kinetics during LEN treatment was a useful marker of disease progression. The ability to monitor clonal changes under treatment pressure may lead to the detection of drug-resistant mutations in the long term.

Interferon-treated Macrophage-derived Exosomes Inhibit HBV-Related Hepatocellular Carcinoma Cell Migration Through miRNA-106b-3p

Shiheng Xu^{1,2}, Li Li¹, Jian-qiong Wang³, Chenchen Huang¹, Yalian Sa^{1,2}, Qi Yin^{1,2}, Jing Chen^{1,2}, Rong-xia Zuo^{1,4}, Qian Zhao^{1,2}, Tao Shen^{1,2,4,5}

¹Yunnan Provincial Key Laboratory for Clinical Virology, Institute of Basic and Clinical Medicine, The First People's Hospital of Yunnan Province, ²Kunming University of Science and Technology,

³Department of Clinical Laboratories, The First People's Hospital of Yunnan Province,

⁴Department of Pulmonary and Critical Care Medicine, The First People's Hospital of Yunnan

Province, ⁵Yunnan Province Innovation Team of Intestinal Microecology Related Disease Research and Technological Transformation, the First People's Hospital of Yunnan Province

Background: Previous reports revealed that exosomes from IFN- α -treated liver nonparenchymal cells were rich in antiviral molecules and can transfer of antiviral molecules by hepatocytes internalizing. MicroRNA-106b (miR-106b) has been shown to play a paradoxical role in disease progressing from different studies. However, the specific role of miR106b-3p in hepatocellular carcinoma and the underlying mechanism remains unclear.

Objective: To investigate the expression of miR-106b-3p in Huh7 cells co-cultured with IFN- α -treated macrophage-derived exosomes. To explore the effect of exosomal miR106b-3p on HBsAg expression and cell migration of Huh7-HBV positive cells and the possible mechanism.

Method: Huh7 cell transient transfected with HBV C2 subtype plasmid was co-cultured with IFN- α -treated macrophage-derived exosomes. Cell supernatant were collected and HBsAg level was detected. The migration ability of Huh7 cells with or without HBV was tested using scratch healing test. The expression of miR-106b-3p, the PI3K/AKT signaling pathway-related proteins were assessed by western blot.

Results: Exosomes from IFN- α -treated macrophages suppressed of HBsAg expression in Huh7-HBV/C2 cells. The expression of miR-106-3p in Huh7-HBV/C2 cells was lower than Huh7 cells and was increased when co-cultured with IFN- α -treated macrophage-derived exosomes or miR-106-3p mimics. The migration ability of Huh7-HBV/C2 cells was significantly increased and the PI3K-AKT pathway was activated comparing with Huh7 cell. However, the migration ability and activation of PI3K-AKT pathway can be inhibited by IFN- α -treated macrophage-derived exosomes or miR-106-3p mimics.

Conclusion: Exosomes can transfer IFN- α -related miR-106b-3p from macrophages to HBV-infected hepatocytes to against HBV replication and inhibit HBV-infected hepatocytes migration. This study may be helpful for treatment of HBV-related HCC.

Identification of MicroRNA-96-5p as a Postoperative Prognostic microRNA Predictor in Non-viral Hepatocellular Carcinoma

Takeshi Matsui^{1,2}, Susumu Hamada-Tsutsumi², Yutaka Naito³, Masanori Nojima⁴, Aya Naiki-Ito⁵, Satoru Takahashi⁵, Takahiro Ochiya⁶, Yasuhito Tanaka⁷

¹Center for Gastroenterology Teine-Keijinkai Hospital, ²Department of Virology and Liver unit, Nagoya City University Graduate School of Medical Sciences, ³Tumor Cell Biology Laboratory, The Francis Crick Institute, ⁴The University of Tokyo, Center for Translational Research, The Institute of Medical Science Hospital, ⁵Department of Experimental Pathology and Tumor Biology, Nagoya City University Graduate School of Medical Sciences, ⁶Department of Molecular and Cellular Medicine, Institute of Medical Science, Tokyo Medical University, ⁷Department of Gastroenterology and Hepatology, Faculty of Life Sciences, Kumamoto University

Background: The microRNA clusters, miR-183/96/182 and miR-217/216a/216b, are significantly upregulated in non-viral hepatocellular carcinoma (NBNC-HCC). Here, we investigate the impact of each member of these clusters on the clinical outcome of NBNC-HCC and analyze the antitumor effects of miR-96-5p.

Methods: The association between recurrence-free survival of 111 NBNC-HCC patients and the levels of miR-183-5p, miR-96-5p, miR-182-5p, miR-217-5p, miR-216a-5p, and miR-216b-5p in tumor and adjacent tissues was investigated. The impact of miR-96-5p on apoptosis and invasion of a hepatoma cell line, HepG2, was investigated by cell counting, transwell assay and flow cytometry, respectively.

Results: miR-183-5p, miR-96-5p, miR-182-5p, miR-217-5p and miR-216b-5p were significantly upregulated in tumor tissues compared to the adjacent tissues ($p=0.0005$, $p=0.0030$, $p=0.0002$, $p=0.0011$ and $p=0.0288$, respectively). By multivariate Cox regression analysis, high tumor/adjacent ratios of miR-182-5p ($p=0.007$) and miR-217-5p ($p=0.008$) were associated with poor recurrence-free survival. In contrast, a low tumor/adjacent ratio of miR-96-5p ($p<0.001$) was associated with poor recurrence-free survival. It suggested that further upregulation of miR-96-5p in tumors may have an inhibitory effect on recurrence. Transfection of miR-96-5p mimic significantly induced apoptosis of HepG2 cells, in association with downregulation of NPM1 and a decrease of phosphorylated AKT protein. Interestingly, simultaneous knockdown of the NPM1 and AKT genes induced apoptosis. miR-96-5p also suppressed proliferation and invasion, that inhibited epithelial-to-mesenchymal transition of HCC cells.

Conclusion: miR-96-5p as a tumor suppressor would be valuable to stratify NBNC-HCC patients at high risk of recurrence.

Antitumor Effect of Regorafenib on MicroRNA Expression in Hepatocellular Carcinoma Cell Lines

Kei Takuma, Mai Nakahara, Kyoko Oura, Tomoko Tadokoro, Kouji Fujita, Joji Tani, Asahiro Morishita, Tsutomu Masaki

Department of Gastroenterology and Neurology, University of Kagawa, Kagawa, Japan

Hepatocellular carcinoma (HCC) is the most common primary malignancy of the liver and is one of the leading causes of cancer-related deaths worldwide. Regorafenib, a multi-kinase inhibitor, is used as a second-line treatment for advanced HCC. Here, we aimed to investigate the mechanism of the antitumor effect of regorafenib on HCC and evaluate altered microRNA (miRNA) expression. Cell proliferation was examined in six HCC cell lines (HuH-7, HepG2, HLF, PLC/PRF/5, Hep3B, and Li-7) using the Cell Counting Kit-8 assay. Xenografted mouse models were used to assess the effects of regorafenib in vivo. Cell cycle analysis, western blotting analysis, and miRNA expression analysis were performed to identify the antitumor inhibitory potential of regorafenib on HCC cells. Regorafenib suppressed proliferation in HuH-7 cell and induced G0/G1 cell cycle arrest and cyclin D1 downregulation in regorafenib-sensitive cells. During miRNA analysis, miRNA molecules associated with the antitumor effect of regorafenib were found. Regorafenib suppresses cell proliferation and tumor growth in HCC by decreasing cyclin D1 via alterations in intracellular and exosomal miRNAs in HCC.

Comprehensive Analysis of Circulating microRNAs as Predictive Biomarkers for Sorafenib Therapy Outcome in Hepatocellular Carcinoma

Tomoki Kono¹, Yuki Tai¹, Kohei Tashiro¹, Rie Morita¹, Takayuki Fujimori³, Jitsuko Takano¹, Asahiro Morishita², Makoto Oryu¹, Tsutomu Masaki²

¹Department of Gastroenterology and Endoscopy Internal Medicine, Kagawa Saiseikai Hospital, Kagawa, Japan, ²Department of Gastroenterology and Neurology, Kagawa University Faculty of Medicine, Kagawa, Japan, ³Fujimori Internal Medicine Gastroenterology Clinic, Kagawa, Japan

Hepatocellular carcinoma (HCC) is one of common causes of cancer-related death worldwide. Clinical management has improved the prognosis of early HCC, but that of the advanced HCC remains poor. Sorafenib provided a treatment option for advanced-stage HCC and prolonged the survival and inhibited tumor progression as one of first-line therapy in patients with advanced HCC. In this study, we investigated if specific microRNAs could act as predictive biomarkers of sorafenib effectiveness. Sorafenib inhibited the proliferation of the Li-7, Hep3B, HepG2, and Huh7 liver cancer cell lines (effective group), but not that of the HLE, HLF, and ALEX cancer lines (non-effective group). A miRNA analysis was performed comparing sorafenib-effective and non-effective cells lines as well as serum samples from HCC patients from sorafenib-effective (CR/PR) and non-effective (PD) groups before sorafenib administration and detected 3 differentially-expressed miRNAs that were common among the in vivo and in vitro samples. The increase rate (effective/non-effective) of hsa-miR-30d in the medium was higher than that in the cancer cells. Hsa-miR-30d was highly expressed in the serum and exosomes of HCC patients in the effective group when compared to those of the non-effective group. Additionally, the hsa-miR-30d expression in the medium of cancer cell lines was highly up-regulated in effective group as compared to that in non-effective group. These results suggest that hsa-miR-30d might be secreted by the cancer cells to the serum through the exosomes. Therefore, hsa-miR-30d might serve as a predictive biomarker for the efficacy of sorafenib therapy in HCC.

Candidate MicroRNA Can be Predictive Markers for The Incidence of Hepatocellular Carcinoma in Patients with Chronic Hepatitis B after Administration of Nucleos(t)ide Analog

Hideaki Takahashi¹, Chiaki Okuse³, Norie Yamada^{4,5}, Takeshi Niinuma⁶, Masahiro Ai⁶, Hideki Wakasugi⁷, Noriyuki Akutsu⁷, Hiroshi Yotsuyanagi^{8,9}, Michihiro Suzuki^{2,10}, Hiromu Suzuki⁶, Keisuke Tateishi²

¹Department of Internal Medicine, Division of Gastroenterology, St. Marianna University, School of Medicine, Yokohama Seibu Hospital, ²Department of Internal Medicine, Division of Gastroenterology, St. Marianna University School of Medicine, ³Department of Internal Medicine, Division of General Internal Medicine, St. Marianna University, School of Medicine, ⁴Center for Liver Diseases, Kiyokawa Hospital, ⁵Department of Virology II, National Institute of Infectious Diseases, ⁶Department of Molecular Biology, Sapporo Medical University, ⁷Department of Internal Medicine, Division of Gastroenterology, Sapporo Medical University, ⁸Division of Infectious Diseases, Advanced Clinical Research Center, The Institute of Medical Science, the University of Tokyo, ⁹Division of Infectious Diseases, Advanced Clinical Research Center, the Institute of Medical Science, The University of Tokyo, ¹⁰St. Marianna University School of Medicine

Background and Aims: A subset of CHB patients treated with NA develops HCC even after clinically undetectable DNA followed by improvement of inflammation and fibrosis using nucleos(t)ide analogue (NA). We aimed to unravel the molecular mechanism underlying HCC development after NA treatment, and to identify predictive biomarkers and therapeutic targets.

Patients and Methods: 1) non HCC group. CHB before NA (n=27), after NA (n=14) (>two years), 2) HCC group. CHB before NA (n=15), Tumor (n=16) (NA>two years), Non tumor (n=14) (NA>two years), and 3) 6.NL; Normal Liver (n=5). All patients are men and have chronic hepatitis without liver cirrhosis. Candidate miRNAs were validated for using difference of expression between "CHB before NA between non HCC and HCC", and between "Tumor" and "NL". To validate our findings, we used quantitative RT-PCR assays to measure miRNAs.

Results: (1) In miRNA-expression profiling, the most analogous expression profiling pattern to "NL" was that in "CHB post", and on the other hands the most different expression profiling pattern from "NL" was that in "HCC pre". (2) By performing bioinformatics analysis, we selected a series of 16 miRNAs of which expression was most significantly associated with the HCC incidence. We validated the expression of 13 miRNAs by TaqMan assays, and identified 9 miRNAs as candidate predictors of HCC risk in CHB patients.

Conclusions: Using the "Novel grouping", we could determine the novel miRNAs related to HCC incidence. Our result suggests that candidate miRNAs reflect the risk of HCC and could predict the incidence of HCC in CHB.

Angiotensin II Receptor Blockers Potentiates the Protective Effect of Branched Chain Amino Acids on Liver Cirrhosis Related Skeletal Muscle Atrophy

Soichi Takeda, Kosuke Kaji, Norihisa Nishimura, Masahide Enomoto, Yuki Fujimoto, Koji Murata, Tadashi Namisaki, Takemi Akahane, Hitoshi Yoshiji
Department of Gastroenterology, Nara Medical University

Background: Sarcopenia in patients with cirrhosis implicated in higher rates of mortality. This study investigated the combined effect of angiotensin II receptor blocker (ARB) and branched-chain amino acids (BCAAs) on skeletal muscle atrophy in rats with cirrhosis and steatohepatitis.

Methods: Male F344 rats are fed a choline-deficient l-amino acid-defined (CDAA) diet for 12 weeks and treated with oral ARB and/or BCAAs. Psoas muscle mass index (PMI) by CT scan and muscle strength were measured, and liver and gastrocnemius specimens were collected.

Results: CDAA induced remarkable body weight loss, and ARB, but BCAAs did not prevent these changes. PMI was significantly lower in the CDAA group, and ARB and BCAAs inhibited the CDAA-induced reduction of PMI which were enhanced by combined treatment. Treatment with ARB and BCAAs attenuated hepatic inflammation and fibrosis and improved skeletal muscle atrophy and strength in CDAA-fed rats. Both agents reduced intramuscular myostatin and pro-inflammatory cytokine levels, resulting in inhibition of the ubiquitin-proteasome system through interference with the SMAD and NF- κ B pathways, respectively. ARB also augmented the BCAA-mediated increase of skeletal muscle mass by promoting insulin growth factor-I production and mitochondrial biogenesis. Moreover, ARB decreased the intramuscular expression of TFEB, a transcriptional inducer of ubiquitin ligase.

Conclusions: These results indicate that this regimen could serve as a novel treatment for patients with sarcopenia and liver cirrhosis.

Therapeutic Effects of Rifaximin and L-carnitine Combination therapy on Skeletal Muscle Atrophy in Cirrhotic Rats

Koji Murata, Kosuke Kaji, Norihisa Nishimura, Masahide Enomoto, Yuki Fujimoto, Soichi Takeda, Yuki Tsuji, Yukihisa Fujinaga, Hiroaki Takaya, Hideto Kawaratani, Tadashi Namisaki, Takemi Akahane, Hitoshi Yoshiji

Department of Gastroenterology, Nara Medical University, Kashihara, Nara, Japan

We will investigate whether rifaximin (RFX) can be used in combination with L-carnitine (L-CAR) to enhance the preventive effect on skeletal muscle atrophy. The effects of RFX and L-CAR, administered alone or in combination, were examined in a rat model of liver fibrosis fed a choline-deficient L-amino acid-defined (CDAA) diet for 12 weeks. Liver fibrosis was evaluated by pathology and expression analysis of fibrosis-related genes. Intestinal barrier function was examined using the expression of the tight junction proteins Occludin and ZO-1 as indicators. Furthermore, as evaluation of skeletal muscle, we quantitatively evaluated the amount of iliopsoas muscle in rats using a CT system for small animals and examined pathologically using collected gastrocnemius muscle tissue. In the liver tissues, CDAA-treated rats showed strong development of liver fibrosis corresponding to cirrhosis, and RFX treatment suppressed fibrosis and significantly decreased mRNA expression of Acta2 and Colla1. In addition, in the intestinal tract of CDAA-treated rats, expression of Occludin and ZO-1 were significantly decreased at the protein and mRNA levels, and their expression was significantly improved by RFX treatment. Pathological evaluation of gastrocnemius muscle tissue showed that the combination treatment improved skeletal muscle atrophy. Regarding mitochondrial biosynthesis in gastrocnemius tissue, mRNA expression of Tfam was decreased in CDAA-treated rats, but was significantly improved by L-CAR administration. Combination therapy with RFX and L-CAR may enhance the inhibition of skeletal muscle atrophy in a cirrhotic model of liver cirrhosis compared to monotherapy with each agent.

Spleen Volume is a Risk for Treatment Refractoriness with Platelet Transfusion and Lusutrombopag in Chronic Liver Disease Patients with Thrombocytopenia

Makoto Morita, Masashi Hirooka, Ryo Yano, Yuki Okazaki, Kotaro Sunago, Atsushi Yukimoto, Yoshiko Nakamura, Yusuke Imai, Takao Watanabe, Yohei Koizumi, Osamu Yoshida, Yoshio Tokumoto, Masanori Abe, Yoichi Hiasa
Department of Gastroenterology and Metabology, Ehime University Graduate School of Medicine, Ehime, Japan

Background: Insufficient improvement of platelet counts after platelet transfusion and lusutrombopag administration is a well-recognized issue in some chronic liver disease patients with thrombocytopenia. We aimed to assess the factors for treatment failure after platelet transfusion and lusutrombopag administration.

Method: We enrolled 132 patients in this study. Of these, 33 and 99 were treated with lusutrombopag and blood transfusion, respectively. No patients had received transfusions prior to inclusion in the study. Lusutrombopag 3 mg was orally administered daily for up to 7 days. Median platelet blood transfusion was 10 units (range 10–290 units). Platelet refractory was defined as platelets counts not increasing more than $5.0 \times 10^4/\mu\text{L}$.

Results: Median age was 61.3 years (range 49–86 years). Median volume of spleen was 441.1 mL (range 111.3–1786.0 mL). After lusutrombopag administration, platelet count significantly elevated from $4.0 \times 10^4/\mu\text{L}$ to $6.9 \times 10^4/\mu\text{L}$. After platelet transfusion, platelet count did not increase significantly. Only severe splenomegaly (> 400 mL) was the predictive factor of platelet refractoriness by multivariate analysis.

Conclusion: Platelet counts were expected to increase with lusutrombopag than platelet transfusion. The patients of chronic liver disease with severe splenomegaly were refractory to platelet transfusion or lusutrombopag treatment.

Efficacy and Safety of Edoxaban for the Treatment of Portal Vein Thrombosis in Patients with Liver Cirrhosis

Yuko Nagaoki, Michio Imamura, Hiroshi Aikata

Department of Gastroenterology and Metabolism, Graduate School of Biomedical and Health Science, Hiroshima University, Hiroshima, Japan

Aim: We analyzed the efficacy and safety of edoxaban for the treatment of portal vein thrombosis (PVT) in patients with liver cirrhosis.

Methods: Fifty-one cirrhotic patients with treated PVT were enrolled in this study. All 51 patients were treated with edoxaban, underwent regular clinical follow-up, dynamic CT was carried out at 6 months and 12 months after PVT treatment.

Results: The median volume of PVT at the start of treatment was 4.25 cm³. PVT was localized in the main trunk of portal vein in 45 patients (88%), intrahepatic portal branch in 4 (8%), superior mesenteric vein in 2 (4%). The median PVT volumes measured after 6 and 12 months of treatment were 1.01 cm³ and 0.33 cm³, respectively. After 6 and 12 months, significantly reduced the volume of PVT compared with that at the start of treatment ($P < 0.001$). On the other hand, no significant improvement was observed in Child-Pugh score, ALBI score, and FIB-4 index at 1 year after the start of PVT treatment. Bleeding was observed in 14 cases (27%), including GAVE in 7 cases, rectal varices in 3 cases, and skin bleeding, nasal bleeding, gingival bleeding, and bloody sputum in one case each except for gastrointestinal bleeding. For bleeding, hemostasis and drug suspension could be resumed and continued.

Conclusion: Edoxaban is an effective anticoagulant and could be considered as a treatment option for PVT in cirrhotic patients. However, attention should be paid to gastrointestinal bleeding, which is an adverse event.

The Role of Chitinase-3 Like 1 on Age-related Liver Fibrosis Progression

Norihisa Nishimura, Kosuke Kaji, Takahiro Kubo, Hideto Kawaratani, Tadashi Namisaki,
Takemi Akahane, Hitoshi Yoshiji

Department of Gastroenterology, Nara Medical University, Nara, Japan

Age has been reported as a major risk factor for the progression of liver fibrosis in patients with chronic hepatitis, but the concise mechanisms remain to be elucidated. We hypothesized that changes in gene expression within the aging liver may affect the speed of liver fibrosis progression. We compared gene expression profile in liver specimens obtained from 54 adult donors with no evidence of fibrosis, including 36 over 40 years old and 18 from 18 to 40 years old. Chitinase-3 like 1 (CHI3L1), which is also called YKL40, was identified as the most significant gene differentially expressed in liver tissue. We investigated the major cellular sources of CHI3L1 in the liver and its function using liver tissue specimens and in vitro studies. The expression of CHI3L1 was significantly higher in liver of cirrhotic patients compared to healthy controls. In situ hybridization and immunostaining for CHI3L1 identified hepatocytes as the major producers of CHI3L1 in normal liver and in cirrhotic tissue, wherein hepatocytes adjacent to fibrous septa showed higher CHI3L1 expression than more distal areas. In vitro studies showed that recombinant CHI3L1 promotes cell proliferation and activation of hepatic stellate cells (HSCs) which play a major role on liver fibrosis. These findings collectively suggest that CHI3L1 promotes liver fibrosis development through a direct effect on HSCs and support the role of CHI3L1 in the increased susceptibility of aging livers to fibrosis progression.

Usefulness of Contrast-enhanced Computed Tomography for the Management of Gastroesophageal Varices during Systemic Chemotherapy for Hepatocellular Carcinoma

Kisako Fujiawara, Takayuki Kondo, Sadayoshi Kogure, Sae Yumita, Takamasa Ishino, Keita Ogawa, Teruomi Iwanaga, Miyuki Nakagawa, Hiroaki Kanzaki, Keisuke Koroki, Kazuhumi Kobayashi, Soichiro Kiyono, Masatoshi Nakamura, Naoya Kanogawa, Sadahisa Ogasawara, Shingo Nakamoto, Tetsuhiro Chiba, Jun Kato, Naoya Kato
Department of Gastroenterology, Graduate School of Medicine, Chiba University

Background: Bleeding from gastroesophageal varices (GOV) is one of the lethal complications in advanced hepatocellular carcinoma. In this study, we examined whether contrast-enhanced computed tomography (CECT) can be used to screen for GOV, and we further examined factors associated with GOV bleeding and exacerbations during systemic chemotherapy.

Materials and Methods: This retrospective study included 653 patients who received systemic chemotherapy as first-line treatment for HCC analyzed (1) endoscopic findings versus GOV diameter measured by CECT, (2) GOV bleeding rate and predictors of bleeding after treatment, and (3) GOV worsening rate and predictors of worsening at CECT 3 months after treatment.

Results: (1) Diameter of lower esophageal and gastric fundus vessels on contrast-enhanced CT correlated well with endoscopic variceal findings. (2) Cumulative bleeding rate from GOV was 6.9% at 1 year and 11.7% at 2 years. The presence PVTT, a diameter of lower esophageal vessels >3.1 mm, and diameter of gastric fundus vessels >2.4 mm were the predictive factors for GOV bleeding. (3) After 3 months of treatment, the diameter of the esophageal vessel was significantly worse in 47 patients (N=142) equivalent to F0, 19 patients (N=61) equivalent to F1, and 3 patients (N=18) equivalent to F2. Even if the esophageal varices are equivalent to F0 on CECT, patients with esophageal vessel diameter >1.9 mm or PVTT or Atezolizumab/Bevacizumab treatment were shown to have an exacerbation of esophageal varices after three months.

Conclusion: CECT evaluation of GOV during systemic chemotherapy may help reduce unnecessary EGD and identify patients who need preventive treatment.

Use of Peritoneovenous Shunt and Cell-free and Concentrated Ascites Reinfusion Therapy for the Management of Refractory Ascite

Akihiro Deguchi¹, Joji Tani², Tsutomu Masaki²

¹Department of Gastroenterology, Kagawa Rosai Hospital, ²Department of Gastroenterology and Neurology, Faculty of Medicine, Kagawa University

Background: In the liver cirrhosis patient with refractory ascites, the dietary intake is lowered, and the nutritional state is further deteriorated, which may cause a significant deterioration of the quality of life (QOL). Ascites puncture drainage, cell-free and concentrated ascites reinfusion therapy (CART), peritoneovenous shunt (PV shunt) are often performed for those patients. Here we report the treatment results of PV shunt and CART for refractory ascites patients.

Method: 14 patients (Child-Pugh B: C=11:3) received CART and 11 patients (Child-Pugh B: C=7:4) received PV shunt were enrolled. PV shunts were performed in patients with good renal function (Cr <1.5), which did not fall under the absolute and relative contraindications for PV shunts. In patients with impaired renal function (Cr >1.5), CART was repeated once every two weeks. We investigated the changes in hepatic reserve and the prognosis in these cases.

Results: In CART cases, the average number of treatments was 6.2, the average drainage volume was 8086 ml. 3 cases were found in which the Child-Pugh score deteriorated. Overall survival after the start of CART was 7.8 months. In cases of PV shunt, improvement of hepatic reserve was obtained in cases without shunt trouble. Overall survival after PV shunt was 12.2 months.

Conclusion: PV shunts for refractory ascites can be expected to improve hepatic reserve and prolong the prognosis in cases that have passed without shunt trouble. On the other hand, in CART cases, improvement of hepatic reserve and prognosis cannot be expected, but it may lead to maintenance of QOL.

The Efficacy of Combined Treatment of Bezafibrate and Ursodeoxycholic Acid was Reduced in Patients with Primary Biliary Cholangitis at Advanced Stage

Atsushi Tanaka, Kosuke Matsumoto, Yoshinari Asaoka

Department of Medicine, Teikyo University School of Medicine, Tokyo, Japan

Background and Aims: Previously, we demonstrated that a combination of bezafibrate (BZF) and ursodeoxycholic acid (UDCA) was associated with a reduction of development of hepatocellular carcinoma (HCC) in patients with PBC. On the other hand, we experience in daily clinical practice that response to UDCA and BZF is worse in patients with advanced stage, where development rate of HCC is high. In the current study, we explored baseline covariates which were significantly associated with poor outcome, death or LT, in patients treated with UDCA and BZF.

Method: Baseline covariates included age, sex, presence of symptoms, serum levels of bilirubin, alkaline phosphatase (ALP), and albumin. Primary outcome (liver-related death or LT) was assessed using multivariable adjusted Cox proportional hazard models.

Results: 889 patients were treated with a combination of UDCA and BZF and enrolled in the current study. During 9.9 \pm 6.8 yrs of mean observational period, 16 out of 889 (1.8%) reached primary endpoint (death in 15, LT in 1). By the Cox proportional hazard model, low albumin (<3.5 mg/dL) and high bilirubin (>1.5 mg/dL) at baseline were significantly associated with death or LT; adjusted hazard ratio (aHR) of low albumin was 5.511 (95% confidential interval 1.754-17.315, p=0.003), and aHR of high bilirubin was 9.986 (95% CI 3.097-32.199, p<0.001).

Conclusion: In patients with PBC at advanced stage who had low albumin or high bilirubin at baseline, the risk for death or LT was significantly increased compared to those with normal albumin or bilirubin even with a combination treatment of UDCA and BZF.

Rifaximin and Lubiprostone Mitigate Liver Fibrosis Development by Repairing gut Barrier Function in Diet Induced Rat Steatohepatitis

Masahide Enomoto, Kousuke Kaji, Hitoshi Yoshiji

Department of Gastroenterology, Nara Medical University, Nara, Japan

Background: Although gut-derived lipopolysaccharide (LPS) affects the progression of non-alcoholic steatohepatitis (NASH) pathogenesis, few studies have focused on this relationship to develop treatments for NASH.

Aims: To explore the effects of combination with rifaximin and lubiprostone on NASH liver fibrosis through the modulation of gut barrier function.

Methods: To induce steatohepatitis, F344 rats were fed a choline-deficient L-amino acid-defined (CDAA) diet for 12 weeks and received oral administration of rifaximin and/or lubiprostone. Histological, molecular, and fecal microbial analyses were performed. Barrier function in Caco-2 cells were assessed by in vitro assays.

Results: Combination rifaximin/lubiprostone treatment significantly suppressed macrophage expansion, proinflammatory responses, and liver fibrosis in CDAA-fed rats by blocking hepatic translocation of LPS and activation of toll-like receptor 4 signaling. Rifaximin and lubiprostone improved intestinal permeability via restoring tight junction proteins (TJPs) with the intestinal activation of pregnane X receptor and chloride channel-2, respectively. Moreover, this combination increased the abundance of Bacteroides, Lactobacillus, and Faecalibacterium as well as decreased that of Veillonella resulting in an increase of fecal short-chain fatty acids and a decrease of intestinal sialidase activity. Both agents also directly suppressed the LPS-induced barrier dysfunction and depletion of TJPs in Caco-2 cells.

Conclusion: The combination of rifaximin and lubiprostone may provide a novel strategy for treating NASH-related fibrosis.

Efficacy and Safety of Administration of Zinc Acetate Hydrate to Patients with Refractory Hepatic Encephalopathy

Masashi Nishiyama¹, Shuji Matsumura^{1,3}, Akemi Tsutsui², Tomonori Senoo², Takuya Nagano², Koichi Takaguchi^{1,2}

¹Division of General Medicine Kagawa Prefectural Central Hospital, ²Division of Hepatology Kagawa Prefectural Central Hospital, ³Division of Internal Medicine Kagawa Prefectural Shirotori Hospital

Zinc acetate hydrate (ZAH) can be used as a hypozincemia ameliorating agent. Patients with decompensated liver cirrhosis (LC) developed hypozincemia and may lead to refractory hepatic encephalopathy (RHE). In this study we investigated efficacy and safety of ZAH administration to patients with RHE. Subjects were 44 patients (29 males, 15 females, average age 68 years, LCC 16 cases, LCB1, NASH 5, Alcoholic LC 9 and NBNC LC 13) diagnosed as RHE that cannot be controlled even if using two or more hepatic encephalopathy medicines at our hospital. These patients were treatment with non-absorbable disaccharide 29 cases, non-absorbable antibiotic 23, BCAA preparation 29 and carnitine preparations 12 before zinc administration. ZAH administration was started at 100 mg and continued 3-6 months. We examined the transition of blood test such as liver function test, ammonia, zinc, copper et.al.

Results: Ammonia decreased from 94.8 to 85.5 and 87.8 before or one and three months after administration, zinc increased from 50.7 to 76.7 and 72.4, and copper decreased from 109 to 76.7 and 72.4. ZAH was stopped by itching, hypocupremia occurred in the case of decreased renal function and anemia progression in every one case.

Conclusion: In patients with RHE, we frequently saw hypozincemia and serum zinc was found to increase by administration of ZAH. Almost all cases of RHE patients of blood ammonia concentration decreased. And in the case of impaired renal function, serum copper value decrease and lead to anemia, so it is necessary to check serum copper levels.

Miglustat Prevents and Ameliorates Liver Fibrosis by Inhibiting the TGF- β /Smad Pathway

Terunao Iwanaga¹, Tetsuhiro Chiba¹, Jiaqi Zhang¹, Junjie Ao¹, Na Qiang¹, Yaojia Ma¹, Keita Ogawa¹, Motoyasu Kan¹, Takafumi Sakuma¹, Hiroaki Kanzaki¹, Masato Nakamura¹, Takayuki Kondo¹, Ryo Nakagawa¹, Sadahisa Ogasawara¹, Shingo Nakamoto¹, Jun Kato¹, Tetsuo Kanda², Hitoshi Maruyama³, Hiroyuki Nakamura⁴, Naoya Kato¹

¹Department of Gastroenterology, Graduate School of Medicine, Chiba University, ²Department of Gastroenterology and Hepatology, Nihon University School of Medicine, ³Department of Gastroenterology, Juntendo University School of Medicine, ⁴Graduate School of Pharmaceutical Sciences, Chiba University

Background: TGF- β /Smad pathway is known to be the most important mechanism in pathogenesis of liver fibrosis. It has been reported that ceramide regulates collagen production through the activation of TGF- β /Smad pathway. In this study, we examined whether miglustat, a glucosylceramide synthase inhibitor, has anti-fibrotic effect through the inhibition of TGF- β /Smad pathway.

Methods: Human hepatic stellate cells (HHStECs) were treated with a various concentration of miglustat in the presence of TGF- β in culture. As a fibrosis regression mouse model, C57BL/6 mice were treated with carbon tetrachloride (CCl₄) for 4 weeks, followed by combination with miglustat (100 or 300mg/kg, three times a day) for further 2 weeks. As a fibrosis prevention model, mice were treated with CCl₄ for 2 weeks, followed by combination with miglustat for further 2 weeks.

Results: Miglustat treatment downregulated not only α -smooth muscle actin but also extracellular matrix (ECM) expression in TGF- β -treated HHStECs in a dose-dependent manner. Both phosphorylation and nuclear translocation of Smad2 and 3 were also remarkably suppressed by miglustat treatment in a dose-dependent manner. Sirius-Red staining and hydroxyproline assay of liver samples demonstrated that miglustat improves fibrosis regardless of the degree of fibrosis caused by CCl₄ accompanied by decreased expression of ECM.

Conclusions: Our findings suggest that miglustat have a therapeutic effect on both regression and prevention of liver fibrosis through the inhibition of phosphorylation and nuclear translocation of Smad2 and 3.

The Association between Sarcopenia and Oxidative Stress in Patients with Hepatocellular Carcinoma

Kohei Oda, Seiichi Mawatari, Ohki Taniyama, Ai Toyodome, Sho Ijyuin, Haruka Sakae, Kazuaki Tabu, Kotaro Kumagai, Akio Ido

Digestive and Lifestyle Diseases, Kagoshima University Graduate School of Medical and Dental Sciences, Kagoshima, Japan

Background: Sarcopenia is a factor that defines the prognosis of patients with hepatocellular carcinoma. Oxidative stress has been associated with the pathological progression of chronic liver disease and the progression of sarcopenia. Oxidative stress measurement (OS: Oxidative Stress) using SpotChem can measure the oxidative stress level of the body from serum in a fully automated and simple manner. In this study, we aimed to clarify the significance and effectiveness of OS measurement in patients with hepatocellular carcinoma.

Methods: We analyzed 122 hepatocellular carcinoma patients treated in our department. Musculoskeletal muscle mass was measured using InBody S10, and OS was measured using SpotChem.

Results: Eighty-five patients were male (69.7%), and the median age of the entire group was 74 years, BMI was 23.95, platelet count was $13.6 \times 10^4 \mu\text{L}$, serum AST was 32 U/L, ALT was 22 U/L, γGTP was 49 and albumin was 3.9 g/dL. Sixty-eight patients were cirrhosis (55.7%) and nineteen patients (15.6%) met the diagnostic criteria for sarcopenia. The sarcopenia group had predominantly higher mortality rates, and OS was significantly higher in the sarcopenia group. OS was significantly negatively correlated with musculoskeletal muscle mass, and AST, ALT, γGTP , CRP were significantly positively correlated. On the other hand, OS was not associated with liver reserve capacity or liver fibrosis markers. OS correlated predominantly with liver cancer stage.

Conclusion: OS was associated with sarcopenia in patients with HCC and with the progression of HCC. OS may be a novel biomarker reflecting the pathological progression of HCC patients.

Which of the Curative Treatments is Appropriate for Initial Recurrence within Early-stage Hepatocellular Carcinoma after Curative Treatments: Resection or Ablation?

Hideko Ohama¹, Atsushi Hiraoka¹, Fujimasa Tada¹, Kanako Kato¹, Yoshiko Fukunishi¹, Emi Yanagihara¹, Masaya Kato¹, Hironobu Saneto¹, Hirofumi Izumoto¹, Hidetaro Ueki¹, Yakeaki Yoshino¹, Shogo Kitahata¹, Chie Kawamura¹, Taira Kuroda¹, Yoshifumi Suga¹, Hideki Miyata¹, Tomoyuki Ninomiya¹, Yoichi Hiasa²

¹Gastroenterology Center, Ehime Prefectural Central Hospital, Ehime, Japan, ²Department of Gastroenterology and Metabology, Ehime University Graduate School of Medicine, Ehime, Japan

Background/Aim: Although it is known that radiofrequency ablation (RFA) and surgical resection (SR) have similar therapeutic efficacies for hepatocellular carcinoma (HCC) based on the SURF-trial, there has been no conclusion which treatment is appropriate for initial recurrence within early-stage. This study aimed to elucidate therapeutic efficacies of them in such condition.

Materials/Methods: From 2000 to 2021, 371 patients with initial recurrence within early-stage after curative treatments, who were treated in our hospital, were enrolled (median 72 yrs, male: 269, Child-Pugh A: B=428: 43, median tumor size/number= 1.5cm/1). Those were divided into 2 groups (RFA: SR=335: 36). Early-stage was defined as ≤ 3 cm in diameter and ≤ 3 tumors. Recurrence free survival (RFS) and overall survival (OS) were evaluated, retrospectively.

Results: Although median ALBI score was better in the SR-group than the RFA-group (-2.90 vs. -2.50, $p < 0.01$). there were no significant differences between the groups in RFS [SR vs. RFA=19.1 months (95%CI, 13.2-46.3) vs. 23.7 months (95%CI, 20.4-27.8), $P=0.989$] and OS [87 months (95%CI, 52.1-NA) vs. 74.5 months (95%CI, 60.0-88.1), $p=0.089$], as well as complications (8.3% vs. 9.3%, $p=1$). In sub-analyses according to ALBI grade, significant differences were not observed not only in RFS (ALBI 1/2=28.2/17.5 months vs. 24.0/23.4 months, $p=0.881/0.684$, respectively) but also in OS (ALBI 1/2=78.9/58.9 months vs. 115.3/52.6 months, $p=0.651/p=0.578$, respectively).

Conclusion: As results of the SURF-trial in patients with naïve HCC, our retrospective results also showed no significant differences in OS and RFS between RFA and SR in those with initial recurrence early-stage HCC after curative treatments.

A Clinical Issue in Aging Society: Up to What Age Can We Consider Performing Ablation?

Yoshiko Fukunishi¹, Atsushi Hiraoka¹, Hideko Ohama¹, Fujimasa Tada¹, Tomoyuki Ninomiya¹, Yoichi Hiasa²

¹Ehime Prefectural Central Hospital, Ehime, Japan, ²Ehime University, Department of Gastroenterology and Metabology

Background/Aim: A clinical issue that "Up to What Age Can We Consider Performing Ablation?" for hepatocellular carcinoma (HCC) has been raised in rapid progression of aging society in Japan. We investigated the efficacy and safety of radiofrequency ablation (RFA) in elderly patients with HCC, retrospectively.

Methods: From 2000 to 2021, 1973 naïve HCC patients were diagnosed and treated at our hospital, and were divided into 4 groups according to age (Group A:B:C:D=<65:65-74:75-79:≥80 yrs). Of the 1973, 607 treated with RFA as an initial treatment were enrolled for final analysis, and clinical features were evaluated.

Results: In all patients, C and D groups in 2000 were 7% and 7%, while were 17.4% and 23.2% in 2021. Non-viral HCC were increased with aging (A vs. D=11.5% vs. 30.0%). In the patient treated with RFA, (maximum tumor size: 1.9±0.7cm, tumor number: 1.3±0.6), there were no significant differences in Child-Pugh, TNM, and elevation of AFP (≥100 ng/ml) among 4 groups. The overall survival was shorter in the D group (median survival time: A:B:C:D=95:92:82:50 months, P<0.001). Complication rates were 3.4% to 6.4%, while non-liver related death/unknown cause were increased with aging (A:B:C:D=20.5%:38.3%:38.0%:69.2%, P<0.001).

Discussion: The expected life expectancies (male/female) are reported to be 20/24.9, 12.6/16.3, and 9.4/12.3 yrs at 65, 75 and 80 yrs old by Japanese government, respectively. The overall survival was shorter in the D group, but this is reasonable considering the life expectancy.

Conclusion: RFA can be indicated regardless of age, when the patient is in good general condition.

Comparison of Ablation Area and Change in Functional Liver Reserve after Radiofrequency Ablation for Hepatocellular Carcinoma Using the Arfa and VIVA Systems

Hiroaki Takaya^{1,2}, Tadashi Namisaki¹, Yuki Tsuji¹, Kosuke Kaji¹, Shigeyuki Aizawa²,
Chie Morioka², Ryuichi Noguchi¹, Motoyuki Yoshida², Hitoshi Yoshiji¹

¹Department of Gastroenterology, Nara Medical University, ²Department of Gastroenterology, Nara Prefecture Seiwa Medical center

Radiofrequency ablation (RFA) is recommended in Japan for patients with hepatocellular carcinomas (HCCs) one to three in number and ≤ 3 cm in size. The arfa and VIVA RFA systems are widely used for patients with HCC and this retrospective observational study aims to compare their performances. The study included 367 patients with HCCs one to three in number and ≤ 3 cm in size who underwent RFA using the arfa system (arfa group) or the VIVA system (VIVA group). The Child-Pugh score and the ALBI score after RFA were not different between the arfa group and the VIVA group. With a 3-cm electrode needle, the longest diameter (Dmax) and the shortest diameter (Dmin) were analyzed and found to be greater in the arfa group than in the VIVA group. Furthermore, Dmax with the 2.5-cm electrode needle was greater in the arfa group than in the VIVA group. Statistically significant differences in the ablation areas after RFA were observed between the groups; however, the differences were not considered clinical problem because the differences in the ablation area was only slight (The differences of Dmax and Dmin were 0.2-0.3cm). The Child-Pugh score and the ALBI score after RFA were the same between the groups. Thus, hepatologists can use either of the RFA systems based on their preference.

Efficacy of Combined Electric-field and C-plane Imaging for Ultrasound-Ultrasound Fusion Imaging for Monopolar Radiofrequency Ablation

Ryo Yano, Masashi Hirooka, Makoto Morita, Yuki Okazaki, Kotarou Sunago, Yoshiko Nakamura, Takao Watanabe, Yohei Koizumi, Osamu Yoshida, Yoshio Tokumoto, Masanori Abe, Yoichi Hiasa
Department of Gastroenterology and Metabology, Ehime University Graduate School of Medicine, Ehime, Japan

Objectives: Ablation area cannot be envisaged preoperatively, even by experts. This study aimed to assess the clinical feasibility of combined electric-field (E-field) and coronary (C)-plane simulations for ultrasound-ultrasound (US-US) fusion imaging for radiofrequency ablation.

Subjects and Methods: The study protocols were approved by the institutional ethics committee. Between October 2017 and July 2019, 151 patients with 151 hepatocellular carcinoma (HCC) nodules were enrolled retrospectively (80 patients were treated by monopolar ablation with navigation images and 71 by monopolar ablation without navigation images). The E-field applied to acquire the US-US fusion images was determined from heat source distribution. C-plane was defined as a sagittal plane in relation to the original two-dimensional multiplanar reconstruction images, which was synchronized to B-mode images acquired by virtual US. Positions of each E-field area in the maximum cross-sectional area of the tumor were identified from the C-plane results. Shape of the ablation volume and width of the safety margin were assessed.

Results: Clinical characteristics showed no significant differences between the two groups. The median sphericity was 0.55 with navigation images and 0.42 without navigation images ($P < 0.001$). The rate of achieving a sufficient safety margin (> 5 mm) was significantly higher in the group treated with navigation images (71/80) than the group treated without navigation images (31/71; $p < 0.001$).

Conclusions: Combined use of E-field and C-plane for US-US fusion imaging can be a feasible method to ensure sufficient safety margin during radiofrequency ablation.

Hepatic Resection Versus Particle Therapy for Single Hepatocellular Carcinoma as An Initial Treatment: A Multicenter Propensity Score Matched Analysis

Satoshi Omiya¹, Shohei Komatsu¹, Kazuki Terashima², SungChul Park², Yoshiro Matsuo², Nor Shazrina Sulaiman², Shinichi So¹, Yoshihide Nanno¹, Takeshi Urade¹, Kenji Fukushima¹, Hidetoshi Gon¹, Daisuke Tsugawa¹, Kaori Kuramitsu¹, Tadahiro Goto¹, Hiroaki Yanagimoto¹, Masahiro Kido¹, Hirochika Toyama¹, Sunao Tokumaru², Tomoaki Okimoto², Takumi Fukumoto¹

¹Department of Surgery, Division of Hepato-Biliary-Pancreatic Surgery, Kobe University Graduate School of Medicine, Kobe, Hyogo, Japan, ²Department of Radiology, Hyogo Ion Beam Medical Center, Tatsuno, Hyogo, Japan

Background: Curative treatment for hepatocellular carcinoma (HCC) is limited to hepatic resection (HR), radiofrequency ablation, and liver transplantation, while the position of particle therapy (PT) in the algorithm as a local treatment remains unclear.

Methods: From January 2000 to December 2015, 279 patients who underwent HR and 275 patients those who were treated with PT for single HCC without vascular invasion as an initial treatment were enrolled. A one-to-one propensity score matched (PSM) analysis was performed to evaluate the overall survival (OS) and progression free survival (PFS) after dividing into modified albumin-bilirubin (mALBI) grade 1/2a and 2b/3 group.

Results: The median OS (111 vs. 64 month, $p < 0.0001$) and PFS (37 vs. 26 month, $p = 0.0018$) of patients who underwent HR were significantly better than those of PT. In a PSM cohort with mALBI grade 1/2a, the median OS (130 vs. 85 month, $p = 0.0012$) and PFS (47 vs. 30 month, $p = 0.0036$) of HR were significantly better than that of PT. Meanwhile, in a PSM cohort with mALBI grade 2b/3, there were no significant differences between the median OS (66 vs. 38 month, $p = 0.1978$) and PFS (33 vs. 20 month, $p = 0.7073$) with HR and PT.

Conclusions: HR may be preferable to PT as an initial treatment for patients with single HCC without vascular invasion, especially for those with preserved liver function. Instead, PT can be an acceptable alternative to HR for patients being without surgical indication and/or impaired liver function.

The Role of Stereotactic Body Radiotherapy for Hepatocellular Carcinoma

Nozomi Miyake¹, Hideki Onishi¹, Masahiko Sue¹, Astushi Oyama¹, Takuya Adachi¹, Nozomu Wada¹, Yasuhito Takeuchi¹, Hidenori Shiraha¹, Akinobu Takaki¹

¹Department of Gastroenterology and Hepatology, Okayama University Hospital, Okayama, Japan,

²Department of Gastroenterology and Hepatology, Okayama University Hospital, Okayama, Japan

Background: We conducted a retrospective study to clarify the usefulness and safety of stereotactic body radiotherapy (SBRT) for the patients with early-stage hepatocellular carcinoma (HCC) when standard curative treatments were unfeasible.

Methods: Between June 2012 and October 2019, 47 patients with HCC were treated with SBRT at our institution, and 33 early-stage HCC patients with Child-Pugh class A and Class B without ascites were included in this study. For receiving the SBRT, 60 Gy in 8 fractions was selected for centrally located HCC and 48 Gy in 4 fractions was selected for peripherally located HCC.

Results: The median age was 71 years, 76% patients were the Child-Pugh score of 5, and 79% patients had the prior treatment history for HCC. The median HCC diameter was 18 mm, and 91% patients had solitary HCC. The proportion of centrally located HCC was 61%. The 3-year and 5-year survival rates after SBRT were 67% and 58%, respectively. The 3-year local recurrence rate was 15%, while the 3-year intrahepatic recurrence rate was 66%. Three months after SBRT, 97% of the patients remained to be classified as Child-Pugh class A. All the patients who had recurrences underwent post-SBRT treatments. There were no SBRT-related deaths.

Conclusions: Our study demonstrated that SBRT for HCC was less-invasive treatment and had high local control rate. We therefore conclude that SBRT is an alternative radical treatment option for the patients with early-stage HCC when standard curative treatments are unfeasible.

Effect of Surgical Margin 0mm for Recurrence-free Survival after R0 Laparoscopic Liver Resection for Hepatocellular Carcinoma

Yukihiro Watanabe, Masayasu Aikawa, Tomotaka Kato, Kenichiro Takase, Yuichiro Watanabe, Katsuya Okada, Yasumitsu Hirano, Shinichi Sakuramoto, Kojun Okamoto, Isamu Koyama
Saitama Medical University International Medical Center, Gastroenterological surgery, Saitama, Japan

Background: Surgery has been the most effective approach and curative treatment for HCC. It has been considered that the surgical margin width of 5 mm to 10 mm is mandatory for good prognosis, but wide resection margin is often impossible because of the location of the tumor and the general condition of the patient. The effect of the surgical margin width on recurrence-free survival (RFS) of patients with LLR for HCC remains unknown. The current study was performed to evaluate the relationship SM width and the recurrence free survival in LLR.

Methods: In the study, we used 187patients' data with R0 LLR for HCC conducted between 2011 and 2019, and aimed to examine the influence of SM on the postoperative recurrence. We divided the SM into the following 3 categories: marginal SM group (0mm: n=25), intermediate SM group (0mm < SM < 5mm: n=102), and wide SM group (= >5mm: n=60).

Results: Compared with the marginal group, the HRs (95% CIs) for RFS in the intermediate, and wide groups were 0.93 (0.50_1.74, P = 0.82), and 1.18 (0.61_2.25, P = 0.63), respectively. In 6 patients with the local recurrence, the logistic regression analysis showed that the odds ratio for local recurrence (95% CIs) of the intermediate and wide SM group were 0.39 (0.04_3.59; P=0.26) and 0.79 (0.83_7.55; P=0.75) respectively.

Conclusion: Surgical margin 0mm was not significantly associated with RFS in the multivariate analysis. Surgical margin width appears to have a limited effect on the recurrence of HCC after LLR.

The Efficacy and Safety of Microwave Ablation for Patients with Hepatocellular Carcinoma

Kazuki Ohya, Shintaro Takaki, Yumi Kosaka, Nami Mori, Keiji Tsuji

Department of Gastroenterology/Liver Center, Hiroshima Red Cross Hospital and Atomic-bomb Survivors Hospital

Purpose: To investigate the efficacy and safety of microwave ablation (MWA) for patients with hepatocellular carcinoma (HCC).

Methods: We retrospectively reviewed the data from 54 patients with 57 nodules who received MWA for HCC between January 2018 and December 2021. In our institution, two protocols of MWA were used until now. In protocol 1 (Pro 1), used at introduction period, MWA power was started with 40W and raise each 5W every 30 seconds until 75W and add ablation with 100W when the ablation was insufficient. In protocol 2 (Pro 2), used after introduction period, MWA power was started with 45W and raise 75W and 100W every 1 minute and extend ablation with 100W when the ablation was insufficient. We compared the ablation time and the size of ablation area between Pro 1 and 2.

Results: The median age was 76 (range 38-95) years, 51 nodules had a Child-Pugh grade of A and median nodules size was 14 mm (5-42). The cumulative local recurrence rates at 1 year and 2 years were both 12%. The complications were showed in 31% of patients. Twenty nodules were treated with Pro 1 and 37 nodules were treated with Pro 2. The ablation time was significantly short (240 vs 315 seconds, $p=0.015$) and minimal size of ablation area tended to be larger (22.5 vs 19.5 mm, $p=0.094$) in Pro 2.

Conclusion: MWA showed high efficacy and safety in patients with HCC. We might be able to shorten the ablation time by the improvement of protocol.

The Usefulness of Increasing the Power Output Linearly during RFA for Hepatocellular Carcinoma

Norihiro Nishijima¹, Tsukasa Aihara², Shinichi Ikuta², Toshinari Shiba¹, Genki Takahashi¹, Tetsuya Shinji¹, Takayuki Kitano¹, Noriko Kitano¹, Meidai Kasai², Yoshiki Nando¹, Takayoshi Nakajima², Yoshiyuki Sakai¹, Tomotaro Kawazoe¹, Kazutaka Kurokochi¹, Kiyohiko Kishi¹, Yukio Osaki¹, Naoki Yamanaka¹

¹Department of Internal Medicine, Meiwa Hospital, Hyogo, Japan, ²Department of Surgery, Meiwa Hospital, Hyogo, Japan

Background: Radiofrequency ablation (RFA) is a widely used treatment technique for hepatocellular carcinoma (HCC). In this study, we aimed to investigate the usefulness of increasing power output linearly during RFA by comparing the linear method with the stepwise method in terms of the incidence of the popping phenomenon.

Methods: We enrolled 51 cases of HCC with 62 nodules. Patients were treated with single-puncture RFA using arfa RF ABLATION SYSTEM with linearly increased power output (linear group). For comparison, 63 nodules in 41 cases were treated with single puncture RFA using VIVA RF SYSTEM with stepwise power output (stepwise group). The incidence of the popping phenomenon and the relationship between the occurrence of popping and the local recurrence were examined in both groups.

Results: The incidence rate of the popping phenomenon was significantly lower in the linear group (7 of 62 nodules; 11.3%) than in the stepwise group (19 of 63 nodules; 30.2%) ($p=0.017$). Of the 96 nodules coagulated with a complete ablative margin with single puncture RFA, 11 nodules (11.5%) had local recurrence. Nodules in which the popping phenomenon occurred during RFA procedure had a significantly higher local recurrence rate (6 of 20 nodules; 30%) than nodules without the popping phenomenon (5 of 76 nodules; 6.6%) ($p=0.003$).

Conclusion: Our results suggest that increasing the power output linearly during RFA suppresses the incidence of the popping phenomenon. Suppression of the popping phenomenon might lead to a reduction in local recurrence.

Significance of Laparoscopic Liver Resection for Post-RFA Recurrence of Hepatocellular Carcinoma

Masayasu Aikawa, Yukihiro Watanabe, Yuichiro Watanabe, Kenichiro Takase, Katsuya Okada, Kojun Okamoto, Isamu Koyama
Saitama Medical University, International Medical Center

Background and Aim: Radiofrequency ablation therapy (RFA) for hepatocellular carcinoma (HCC) has almost the same local control ability as hepatectomy if it is small. However difficult or inadequate cauterization is often observed depending on the tumor site. At our hospital, we are actively performing laparoscopic hepatectomy (LLR) even for patients with difficult-to-relapse surgery who have undergone RFA as the first-line treatment for hepatocellular carcinoma due to liver dysfunction. In this report, we investigated the treatment results of LLR for recurrent lesions after RFA.

Methods: Of the 590 LLR patients who underwent LLR from April 2008 to March 2022, 14 patients and 14 lesions who underwent LLR for post-RFA recurrence. All lesions were HCC, age 70 (61-86) years, and the lesion sites were 4 lesions in the outer area, 4 lesions in the inner area, 4 lesions in the anterior area, and 2 lesions in the posterior area. We compared the perioperative results, clinical pathological findings, and clinical course of LLR for post RFA recurrent lesions with those for untreated lesions.

Results: The perioperative findings showed no significant difference from the LLR for untreated lesions. In the pathological margin evaluation, 4 cases (28.5%) had a positive, which tended to be higher than the LLR for untreated lesions. No local recurrence was observed during follow-up, but intrahepatic recurrence at other sites was observed in 3 cases (25%).

Conclusion: LLR for recurrent lesions after RFA is safe and minimally invasive, and is a significant treatment as an arm for local treatment of HCC with liver dysfunction.

Chemoembolization with or without Radiofrequency Ablation: Outcomes in BCLC-B Hepatocellular Carcinoma

Ryo Yano, Masashi Hirooka, Makoto Morita, Yuki Okazaki, Kotarou Sunago, Yoshiko Nakamura, Takao Watanabe, Yohei Koizumi, Osamu Yoshida, Yoshio Tokumoto, Masanori Abe, Yoichi Hiasa
Department of Gastroenterology and Metabology, Ehime University Graduate School of Medicine, Ehime, Japan

Background: The Barcelona Clinic Liver Cancer (BCLC) classification is the most widely used to predict prognoses and determine treatment modalities in hepatocellular carcinoma (HCC). Transcatheter hepatic arterial chemoembolization (TACE) is considered the standard treatment for patients with BCLC-B HCC. However, BCLC-B comprises a highly heterogenous population, and recently it has been reported that radiofrequency ablation combined with transcatheter hepatic arterial chemoembolization (TACE-RFA) yielded better overall survival than TACE in BCLC-B HCC.

Objectives: To clarify the indications for TACE-RFA for patients with HCC beyond the Milan criteria, this study assessed the prognoses of patients with BCLC-B according to substages through treatment in a multicenter study.

Subjects and Methods: The study was approved by the institutional review board at each hospital; 230 patients with intermediate stage HCC who were treated from January 2000 to December 2015 were enrolled. These patients were divided into four classes (B1-B4) per Bolondi classification. Between these substages, the prognosis of TACE-RFA was compared to that of TACE, which is the suggested standard therapy for patients with BCLC-B.

Results: TACE-RFA survival curves were better than those of TACE ($p < 0.001$ for TACE-RFA vs. TACE). In particular, for substages B1 and B2, the overall survival rates of TACE-RFA were significantly higher than those of TACE (B1, $p < 0.001$ for TACE-RFA vs. TACE; B2, $p < 0.015$ for TACE-RFA vs. TACE).

Conclusions: The indications for TACE-RFA may be expanding into BCLC-B HCC. In substages B1 and B2, TACE-RFA may be a better treatment modality than TACE alone.

Risk Factors for Immune-mediated Hepatotoxicity in Patients with Cancer Treated with Immune Checkpoint Inhibitors: A Systematic Review and Meta-Analysis

Jiahui Pan^{1,2}, Yuwei Liu^{1,2}, Xiaozhong Guo¹, Zhaohui Bai^{1,2}, Giovanni Battista Levi Sandri³, Nahum Mendez-Sanchez⁴, Xingshun Qi¹

¹Department of Gastroenterology, General Hospital of Northern Theater Command, Shenyang, China, ²Postgraduate College, Shenyang Pharmaceutical University, Shenyang, China, ³Department of Surgery, Umberto I University Hospital, Rome, Italy, ⁴Liver Research Unit, Medica Sur Clinic & Foundation, Mexico City, Mexico

Introduction: Immune checkpoint inhibitors (ICIs) are effective for the treatment of various cancers, but can lead to immune-mediated hepatotoxicity (IMH). The aim of this study was to analyze the risk factors for IMH in cancer patients treated with ICIs.

Methods: The PubMed, EMBASE, and Cochrane Library databases were searched. Eligible studies should compare the difference between patients who developed and did not develop IMH. Odds ratio (OR) and weighted mean difference (WMD) with 95% confidence interval (CI) were calculated.

Results: Among the 5030 papers initially identified, 13 studies were included. Meta-analyses indicated that age (WMD=-5.200, 95%CI=-7.481 to -2.919), history of ICIs treatment (OR=4.491, 95%CI=2.205 to 9.145), ICIs combination therapy (OR=5.353, 95%CI=1.663 to 17.232), and AST level (WMD=5.039, 95%CI=1.220 to 8.857) were significantly associated with the risk of any grade IMH; and age (WMD=-5.193; 95%CI=-9.669 to -0.718) was significantly associated with the risk of grade ≥ 3 .

Conclusion: This study indicated that young age, history of ICIs treatment, ICIs combination therapy, and high AST level were risk factors for IMH. These findings provide the evidence for identifying patients at a high risk of IMH. Appropriate intervention may be given to prevent from IMH in high-risk patients, thereby enabling ICIs to achieve an expected tumor response.

Efficacy and Safety of PD-1/PD-L1 Inhibitors in Advanced Hepatocellular Carcinoma: A Systematic Review and Meta Analysis

Yuwei Liu, Jiahui Pan, Wentao Xu, Fangbo Gao, Hongyu Li, Xingshun Qi
General Hospital of Northern Theater Command, Shenyang, P.R. China

Objective: Programmed cell death 1 (PD-1) and programmed cell death ligand 1 (PD-L1) inhibitors have been increasingly employed for the treatment of various cancers in clinical practice. This study aimed to systematically evaluate the efficacy and safety of PD-1/PD-L1 inhibitors for advanced hepatocellular carcinoma (HCC).

Design: PubMed, EMBASE, Cochrane library, Web of Science, and Abstracts of American Society of Clinical Oncology proceedings databases were searched. Objective response rate (ORR), disease control rate (DCR), median progression-free survival (PFS), median overall survival (OS), and incidence of adverse events (AEs) and drug withdrawal were pooled. Odds ratio (OR) and hazard ratio (HR) were calculated to analyze the difference in the ORR, DCR, PFS, and OS between groups.

Results: Among the 14902 initially identified papers, 98 studies regarding use of PD-1/PD-L1 inhibitors in advanced HCC were included. Based on different criteria of response in solid tumors, the pooled ORR, DCR, and median PFS was 16-36%, 54-74%, and 4.5-6.8 months, respectively. The pooled median OS was 11.9 months. Compared to multi-target tyrosine kinase inhibitors (TKIs), PD-1/PD-L1 inhibitors monotherapy significantly increased ORR (OR=2.73, $P<0.00001$) and OS (HR=0.97, $P=0.05$), and PD-1/PD-L1 inhibitors combined with TKIs significantly increased ORR (OR=3.17, $P<0.00001$), DCR (OR=2.44, $P<0.00001$), PFS (HR=0.58, $P<0.00001$), and OS (HR=0.58, $P<0.00001$). The pooled incidence of all-grade AEs, grade ≥ 3 AEs, and drug withdrawal was 71%, 25%, and 7%, respectively.

Conclusion: Based on the present systematic review and meta-analysis, PD-1/PD-L1 inhibitors should be the preferred treatment choice for advanced HCC due to their higher antitumor effect and improved outcomes.

Clinical Effect of Lenvatinib-TACE Therapy in Patients with BCLC-Intermediate stage Hepatocellular Carcinoma

Seiichi Mawatari¹, Tsutomu Tamai², Akiko Saisyoji³, Ai Toyodome¹, Ohki Taniyama¹, Sho Ijuin¹, Haruka Sakae¹, Kazuaki Tabu¹, Kohei Oda¹, Kotaro Kumagai¹, Kaori Muromachi², Yasunari Hiramine³, Akihiro Moriuchi⁴, Kazuhiro Sakurai⁴, Akio Ido¹

¹Kagoshima University Graduate School of Medical and Dental Sciences, ²Kagoshima City Hospital, ³Kagoshima Kouseiren Hospital, ⁴Kagoshima Medical Center

Aim: Intermediate-stage BCLC (BCLC-B) patients for whom transcatheter arterial chemoembolization (TACE) is expected to be insufficient have been converted to systemic therapy; however, the clinical effect after systemic therapy is not clear. We aimed to clarify the prognosis of BCLC-B HCC patients who received lenvatinib (LEN) followed by TACE on demand.

Methods: We retrospectively evaluated 101 BCLC-B HCC patients who received LEN at our department and related institutions, and evaluated treatment efficacy using the modified RECIST criteria.

Results: The median age was 72 years (range: 37-92), 78 patients were male, 92 were classified as Child-Pugh A, and LEN was used as the first systemic therapy in 86 patients. The mean duration of administration was 6.6 months. The response and disease control rate were 45.5% and 84.2%, respectively. Median progression-free survival and overall survival (OS) after the initiation of LEN were 6.2 months and 29.1 months, respectively. LEN was discontinued in 95 cases (91.1%); discontinuation was due to disease progression in 57 (59.4%) cases. Among 77 patients (81.1%) switched to post-treatment, 57 (74.0%) underwent TACE. The OS of patients for whom LEN was re-administered after TACE (LEN-TACE) was significantly longer than that of patients who received TACE alone ($p=0.001$) or other drug therapies ($p<0.001$), although there was no difference in the pre-treatment tumor factors or liver function. LEN was administered for approximately 8.8 months after TACE. Those who received LEN-TACE showed a lower rate of discontinuation due to adverse effects ($p=0.032$).

Conclusion: LEN-TACE therapy may prolong the prognosis of HCC.

Early Predictors of Response and Survival in Atezolizumab/Bevacizumab Combination Therapy

Norikazu Tanabe¹, Issei Saeki², Maho Egusa², Natsuko Nishiyama², Tsuyoshi Fujioka², Daiki Kawamoto², Yurika Yamauchi², Tatsuro Nishimura², Takashi Oono², Tsuyoshi Ishikawa², Takahiro Yamasaki³, Taro Takami³

¹Yamaguchi University Hospital Division of Laboratory, Ube, Japan, ²Department of Gastroenterology and Hepatology, Yamaguchi University Graduate School of Medicine, Ube, Japan, ³Department of Oncology and Laboratory Medicine, Yamaguchi University Graduate School of Medicine, Ube, Japan

Background: We experienced a high response with the atezolizumab/bevacizumab combination therapy (Atezo/Bev) for hepatocellular carcinoma (HCC); however, it is important to manage sequential therapies for patients with disease progression appropriately. Therefore, we examined the predictors of patient response and prognosis for Atezo/Bev.

Methods: This retrospective cohort study included 71 patients with imaging evaluations and tumor marker measurements at three weeks after treatment initiation, among the patients who had received Atezo/Bev at our and affiliated institutions by September 2021. We analyzed the contributing factors associated with treatment response and prognosis, including changes in tumor markers.

Results: The median patient age was 75 years, and 55 males (77.4%) were included in our study. Our cohort was characterized by mALBI grade 1/2a/2b/3: 24/12/34/1, BCLC A/B/C: 6/43/22, and a median AFP and DCP of 17 ng/mL and 408.5m AU/mL, respectively. The median progression-free survival was 7.7 months, and the objective response and disease control rates at six weeks were 29.5% and 77.5%, respectively, by RESICT ver.1.1. The contributing factors for objective response were analyzed using a logistic regression analysis, and a decrease in AFP at three weeks (odds ratio 3.3, $p=0.039$) was extracted in the multivariate analyses. Moreover, a decrease in AFP at three weeks (HR 0.3, $p=0.014$) was also a predictive factor for PFS using the Cox proportional hazards model.

Conclusion: For the prognostication of patients with HCC treated with of Atezo/Bev, it is useful to determine the change in AFP at three weeks.

Factors Contributing to Response to Systemic Sequential Therapy for Intermediate Stage Hepatocellular Carcinoma

Yumi Kosaka, Shintaro Takaki, Keiji Tsuji, Nami Mori, Kazuki Oya
Japan Red Cross Society Hiroshima Red Cross A-bomb Hospital

Objective: To investigate factors contributing to improved prognosis in intermediate stage hepatocellular carcinoma (HCC).

Subjects and Methods: Fifty eight patients with BCLC-B stage unresectable HCC, age 76.7 years \pm 6.12, male 47 (81%), Child-Pugh grade A/B 51/7, Sorafenib/Lenvatinib/Atezolizumab+Bevacizumab 29/20/9, who initiated 1st line therapy at our institute from January 2016 to March 2022 included in this retrospective study. After induction of 1st line therapy, therapeutic drug was changed sequentially according to PD, and TACE or RFA was added in case of poor local control. We compared the prognosis with the objective response cases (responder, [OR]CR+PR) and non-response cases (non-responder, SD+PD) were and the factors contributing to response and overall survival (OS) were analyzed.

Results: The follow-up period 18.5 months (M) \pm 11.82. Outcome of all patients was CR in 5, PR in 12, SD in 11, and PD in 30. 17 patients had a response and ORR was 29.8%. While median OS for all patients was 19 M, for responders and non-responder were 56 M and 11 M, respectively (P=0.046). Comparing with characteristics of responders and non-responders in univariate analysis of OS, Alb > 4 g/dL (P=0.018), ALT < 40 (P=0.047), T-Bil < 1.5 mg/dL (P=0.048) and platelets > 150,000 (P=0.043) were significantly more observed in responders, while in multivariate analysis, Alb 4g/dL or higher (HR 4.43 95%CI[1.33-14.7] P=0.0151) was a significant factor contributing to response.

Conclusion: Intermediate stage HCC, patients with Alb 4 g/dL or higher may be expected to respond and have a good prognosis for intermediate HCC.

Initial Treatment Strategy for Intermediate Stage Hepatocellular Carcinoma Based on Up-to-7 Criteria

Noboru Takata, Tatsuya Yamashita, Takeshi Terashima, Kuniaki arai, Eishiro Mizukoshi
Department of Gastroenterology, Kanazawa University Hospital

Purpose: We investigated the initial treatment and prognosis of intermediate stage hepatocellular carcinoma (HCC) patients treated at our department according to up-to-7 criteria.

Subjects: We retrospectively evaluated the clinical background, treatment selection, and prognosis of 181 patients with intermediate stage hepatocellular carcinoma who were initially treated at our hospital between April 2000 and December 2020 according to the up-to-7 criteria.

Results: There were 70 patients with up-to-7 criteria in, 51 (73%) were Child-Pugh A and 19 (27%) were Child-Pugh B. The median survival time (MST) was 49 months. First-line treatment included resection in 13 patients (19%), RFA in 42 patients (60%), and TACE in 15 patients (21%). MST by initial treatment was 61, 55, and 49 months for liver resection, RFA, and TACE, respectively, with no significant difference ($P=0.38$). There were 111 patients with up-to-7 criteria out, 80 (72%) were Child-Pugh A, and 31 (28%) were Child-Pugh B. The MST was 35 months. First-line treatment included resection in 14 (13%), RFA in 21 (19%), TACE in 43 (39%), and systemic chemotherapy in 28 (25%), with MST of 92 / 60 / 33 / 18 months, respectively. Favorable prognostic factors included Child-Pugh A ($P=0.001$), tumor number less than 5 ($P=0.001$), and radical therapy ($P=0.001$).

Conclusion: Among patients with up-to-7 criteria in, more patients underwent resection or RFA as initial treatment. It is necessary to consider the possibility of resection or RFA in the first-line treatment of patients with up-to-7 criteria out.

Usefulness of Lenvatinib in Combination with TACE for Patients with Intermediate Stage Hepatocellular Carcinoma

Akira Fuchigami, Yukinori Imai, Yohei Fujii, Kayoko Sugawara, Yoshihito Uchida, Hiroshi Uchiya, Nobuaki Nakayama, Satoshi Mochida

Department of Gastroenterology & Hepatology Faculty of Medicine, Saitama Medical University
Saitama, Japan

Methods: The subjects were 56 patients with intermediate stage HCC receiving lenvatinib, and were classified into 22 patients with HCC within “up-to 7 criteria” and 34 patients with HCC beyond “up-to 7 criteria”. The mALBI grade was 1, 2a and 2b in 17, 17 and 22 patients, respectively. Forty-nine patients had previously received TACE/TAE before the initiation of lenvatinib, including 13 patients who were subsequently diagnosed as having TACE refractoriness.

Results: Percentages of patients showing therapeutic efficacy of CR, PR, SD and PD were 14%, 48%, 30% and 9%, respectively, following lenvatinib initiation. Twenty-six patients received TACE/TAE at 7-80 weeks after lenvatinib initiation (LEN-TACE group), and percentages of patients showing the efficacy of CR, PR, SD and PD were 10%, 40%, 30% and 20%, respectively; the ORR of TACE/TAE were 71% in patients with HCC within "up-to 7 criteria" and 38% in patients with HCC beyond “up-to 7 criteria” (P=0.16). The cumulative survival rates at 1 and 2 year(s) were 83.0% and 68.7%, respectively, and the rates were significantly higher in patients among LEN-TACE group (94.4% and 81.2%, respectively) than in those among the remaining patients (72.3% and 56.4%, respectively) (P<0.05). Multivariate analysis revealed that mALBI grade 1/2a (OR: 0.16, P<0.05), additional TACE/TAE (OR: 0.20, P<0.05) and serum AFP levels (OR: 0.23, P<0.05) were associated with the outcome of patients.

Conclusions: Lenvatinib therapy followed by TACE/TAE was effective even if the prior therapy was ineffective. The optimal timing of sequential TACE/TAE need to be investigated in future.

New Technology to Detect of Tumor-feeding Branches and Simulate Embolization Area of Hepatocellular Carcinoma with Synapse Vincent during Transcatheter Arterial Chemoembolization

kazutoshi Fuke^{1,2}, Takuya Toda^{1,2}, Takushi Manabe^{1,2}, Chikara Ogawa¹, Mitsushige Shibato¹, Tsutomu Masaki²

¹Department of Gastroenterology and Hepatology, Takamatsu Red Cross Hospital, ²Department of Gastroenterology and Neurology, Faculty of Medicine

Introduction: To evaluate the usefulness of transcatheter arterial chemoembolization (TACE) guidance software that uses the volume analyzer SYNAPSE VINCENT in detecting tumor-feeding branches and simulating embolization area of hepatocellular carcinoma (HCC).

Methods: The application soft of SYNAPSE VINCENT, liver analysis, were used in chemoembolization of 6 patients of 7 HCCs. Detectability of tumor-feeding branches was compared versus that of nonselective digital subtraction angiography (DSA). Embolization area of chemoembolization was evaluated by within one week CT findings after TACE.

Results: The maximal diameter of these tumors ranges 10 to 42mm (mean \pm SD, 20.9 \pm 10.6mm). The average time for detect tumor-feeding branches was 242 seconds. Total time to detect tumorfeeding branches and simulate the embolization area was 384 seconds. All cases could detect all tumor-feeding branches of HCC and expected embolization area of simulation of SYNAPSE VINCENT were almost nearly CT after TACE. The maximal diameter of these tumors ranges 10 to 42mm (mean \pm SD, 20.9 \pm 10.6mm). The average time for detect tumor-feeding branches was 242 seconds. Total time to detect tumorfeeding branches and simulate the embolization area was 384 seconds. All cases could detect all tumor-feeding branches of HCC and expected embolization area of simulation of SYNAPSE VINCENT were almost nearly CT after TACE.

Conclusion: This new technology has possibilities to reduce the amount of radiation exposure and to improve the therapeutic effect of TACE.

Association between Skeletal Muscle Volume Loss during Lenvatinib Treatment and Prognosis in Unresectable Hepatocellular Carcinoma: A Multicenter Study in Tohoku, Japan

Masashi Fujita¹, Kazumichi Abe¹, Hidekatsu Kuroda², Takayoshi Oikawa², Masashi Ninomiya³, Atsushi Masamune³, Kazuo Okumoto⁴, Tomohiro Katsumi⁴, Wataru Sato⁵, Katsunori Iijima⁵, Tetsu Endo⁶, Shinsaku Fukuda⁶, Nobukazu Tanabe⁷, Hiroshi Numao⁸, Yasuhiro Takikawa², Yoshiyuki Ueno⁴, Hiromasa Ohira¹

¹Department of Gastroenterology, Fukushima Medical University School of Medicine, Fukushima, Japan, ²Division of Hepatology, Department of Internal Medicine, Iwate Medical University, Morioka, Japan, ³Division of Gastroenterology, Tohoku University Graduate School of Medicine, Sendai, Japan, ⁴Department of Gastroenterology, Yamagata University Faculty of Medicine, Yamagata, Japan, ⁵Department of Gastroenterology, Akita University School of Medicine, Akita, Japan, ⁶Department of Gastroenterology, Hirosaki University School of Medicine, Hirosaki, Japan, ⁷Department of Gastroenterology, National Hospital Organization Sendai Medical Center, Sendai, Japan, ⁸Department of Gastroenterology, Aomori Prefectural Central Hospital, Aomori, Japan

Sarcopenia is associated with poor prognosis of patients with hepatocellular carcinoma (HCC). We investigated the association of skeletal muscle volume (SMV) and its change in HCC patients taking lenvatinib (LEN). In 130 HCC patients, psoas mass index (PMI) was calculated as the left-right sum of the major \times minor axis of psoas muscle at the third lumbar vertebra, divided by height squared. Patients were classified into two groups (low/normal PMI) based on indices of $<6.0 \text{ cm}^2/\text{m}^2$ for man and $<3.4 \text{ cm}^2/\text{m}^2$ for women. Change in PMI per month during the LEN administration period ($\delta\text{PMI}/\text{m}$) and rate of $\delta\text{PMI}/\text{m}$ from baseline ($\delta\text{PMI}/\text{m}$ rate) were calculated; and patients were classified into two groups (severe/mild atrophy) based on the $\delta\text{PMI}/\text{m}$ rate, as $>1\%$ or $<1\%$, respectively. There was no significant difference in Overall survival (OS) between the low and normal PMI groups at the start of LEN administration. OS was significantly lower in the severe atrophy group than in the mild atrophy group (median; 15.2 vs. 25.6 months, $P = 0.005$). In multivariate analysis, there was significant association between severe atrophy and OS (hazard ratio 1.927, $P = 0.031$). Progressive loss of SMV is a strong predictor of poor prognosis in HCC patients taking LEN.

Prediction of Serious Adverse Events in Advanced Hepatocellular Carcinoma Treated with Lenvatinib by Intestinal Permeability

Yuki Fujimoto, Tadashi Namisaki, Hitoshi Yoshiji

Department of gastroenterology, Nara Medical University

Background: Lenvatinib treatment in patients with advanced hepatocellular carcinoma (a-HCC) is associated with a high rate of serious adverse events (SAEs). We sought to identify predictors of SAEs in lenvatinib treatment.

Methods: Forty-one patients with a - HCC treated with lenvatinib were stratified into two groups:SAE (n = 25) and non-SAE (NSAE) (n = 16). The lactulose-mannitol test (LMT) was performed in a subgroup of 17 patients (LMT subgroup) who were stratified into two groups: SAE (n = 10) and NSAE (n = 7). SAEs were assessed by liver disease etiology and modified albuminem spacebilirubin (m-ALBI) grade. Intestinal permeability (IP) was assessed by zonulin. In the LMT subgroup, IP was assessed using the lactulose-mannitol test (LMR).

Results: Incidence rates of SAEs were higher in patients with alcoholic liver disease (ALD)- and non-alcoholic fatty liver disease (NAFLD)-related HCC than in patients with HCC from other etiologies (p = 0.014). The rates were higher in m-ALBI Grades 2a and 2b than in m-ALBI Grade 1 (p = 0.0104). Serum zonulin levels were significantly higher in the SAE group than in the NSAE group (p = 0.0331) and were independently associated with SAEs (odds ratio,140; 95% confidence interval, 1.66-11800; p = 0.029). The high-zonulin-group (>0.518ng/mL) exhibited more SAEs than the low-zonulin group (<0.518 ng/mL) (p = 0.0166). In the LMT subgroup, LMR was significantly higher in the SAE group than in the NSAE group (p = 0.0172) and higher in ALD- and NAFLD-related HCC than in other etiologies (p = 0.0151).

Conclusion: Serum zonulin levels predict SAEs in patients with a-HCC who are treated with lenvatinib.

Systematic Review of Adjuvant External Beam Radiotherapy for Hepatocellular Carcinoma Following Hepatectomy

Qiao Ke, Lei Wang

Department of Hepatopancreatobiliary Surgery, Mengchao Hepatobiliary Hospital of Fujian Medical University, Fuzhou, Fujian, China,

Department of Radiation Oncology, Fujian Cancer Hospital, Fujian Medical University Cancer Hospital, Fuzhou, Fujian, China

Background: Recurrence is still the main bottleneck of hepatocellular carcinoma (HCC) following hepatectomy. With the development of technique, external beam radiotherapy (EBRT) is being playing an increasing role in the management of HCC, but consensus over adjuvant EBRT following hepatectomy have not been reached.

Methods: A systematic review was conducted according to the guidelines of the Preferred Reporting Items for Systematic Reviews and Meta-Analysis. PubMed, MedLine, Embase, the Cochrane Library, Web of Knowledge were used to screen the eligible studies evaluating the clinical safety and efficacy of EBRT for HCC receiving hepatectomy up to May 1st 2022. The endpoints were disease-free survival (DFS), overall survival (OS), and adverse events (AEs).

Results: Ten studies were eligible, including three randomized controlled trials, one phase II trial, and six retrospective comparative studies. Meta-analysis showed that the pooled hazard ratio (HR) for the median DFS and OS were both in favor of adjuvant EBRT compared with surgery alone, and the advantage of adjuvant EBRT was also confirmed in subgroups stratified by different populations (narrow margin, $P<0.05$; microvascular invasion, $P<0.05$; portal vein tumor thrombus, $P<0.05$; respectively) and study designs (prospective studies, $P<0.05$; retrospective studies, $P<0.05$; respectively). Furthermore, adjuvant EBRT was also found to be superior to adjuvant TACE (both $P<0.05$). In addition, pooled rates of overall AEs and severe AEs were 65.3% and 12.2%, but no fatal AEs were reported.

Conclusion: Adjuvant EBRT could be taken into consideration of HCC patients, especially for those with high risk of recurrence, but it deserves further validation.

Clinical Outcome of Chemoradiation Therapy Using One-shot Cisplatin via Hepatic Arterial Infusion for Hepatocellular Carcinoma with Macrovascular Invasion: A Single-arm Retrospective Cohort Study

Kensuke Naruto, Tomokazu Kawaoka, Yutaro Ogawa, Kei Amioka, Yuki Yoshikawa, Chihiro Kikukawa, Yousuke Suehiro, Kenji Yamaoka, Yuwa Ando, Yumi Kosaka, Shinsuke Uchikawa, Takashi Nakahara, Eisuke Murakami, Atsushi Ono, Takuroo Uchida, Masami Yamauchi, Wataru Okamoto, Shoichi Takahashi, Michio Imamura, Hiroshi Aikata

Department of Gastroenterology, Hiroshima University Hospital, Hiroshima, Japan

Background: Patients with hepatocellular carcinoma (HCC) and macrovascular invasion (MVI) have a poor prognosis. This study aimed to determine if one-shot cisplatin (CDDP) chemotherapy via hepatic arterial infusion (HAI) combined with radiation therapy (RT) prior to systemic chemotherapy could improve the outcomes of these patients.

Methods: This study consisted of 32 HCC patients with the following eligibility criteria: (i) Vp 3/4 and/or Vv 2/3; (ii) received one-shot CDDP via HAI; (iii) received RT for MVI; (iv) a Child-Pugh score ≤ 7 ; and (v) an ECOG-PS score of 0/1. We collected information on patient characteristics and took contrast-enhanced CT at the start of the therapy and every 2-4 months. We evaluated the overall response of the tumor and MVI according to mRECIST. We statically assessed patient data and evaluated overall survival and progression-free survival, appropriately.

Results: The overall response rate at the first evaluation performed a median of 1.4 months after HAI was 16% for the main intrahepatic tumor and 59% for the MVI. The best responses were the same as those of the first-time responses. The duration of median survival was 8.6 months, and progression-free survival of the main intrahepatic tumor was 3.2 months. Predictive factors for overall survival were the relative tumor volume in the liver and the first therapeutic response of MVI. There were no severe adverse events or radiation-induced hepatic complications.

Conclusions: One-shot CDDP via HAI and RT were well tolerated and showed immediate control of MVI. This combination shows potential as a bridging therapy to systemic chemotherapy.

Usefulness of Combined Atezolizumab Plus Bevacizumab Therapy as the Second Line Treatment for Patients with Unresectable Hepatocellular Carcinoma

Shinpei Yamaba, Yukinori Imai, Kayoko Sugawara, Yoshihito Uchida, Yohei Fujii, Hiroshi Uchiya, Nobuaki Nakayama, Satoshi Mochida

Department of Gastroenterology and Hepatology, Saitama Medical University, Saitama, Japan

Aim: To clarify the efficacy of combined atezolizumab plus bevacizumab therapy as the second line treatment for patients with unresectable hepatocellular carcinoma (HCC).

Methods: The subjects were 76 patients with HCC receiving the combined therapy including 32 patients receiving previously molecular targeted agents (MTA). Therapeutic efficacy was evaluated using contrast-enhanced CT performed every 6 weeks according to the mRECIST. Liver function was assessed by albumin-bilirubin (ALBI) score.

Results: The Child-Pugh scores was 5, 6, 7 and 8 in 36, 34, 5 and 1 patient(s), respectively, and modified ALBI grades were 1, 2a and 2b in 27, 15 and 34 patients, respectively at baseline. The BCLC stages of HCC at baseline were A, B and C in 2, 31 and 43 patients, respectively. Percentages of patients manifesting CR/PR/SD/PD (ORR) until 12 weeks of the therapy were 8%/36%/44%/14% (44%) among MTA-naïve patients, and 0%/15%/65%/20% (15%, $P=0.0715$) in MTA-experienced patients. Multivariate logistic regression analysis revealed MTA-naïve/experienced as a significant factor influencing the therapeutic efficacy ($P<0.05$). The mean ALBI scores were aggravated at 6 and 12 weeks compared to those at baseline. The cumulative survival rates at 6 and 12 months were 86% and 74%, respectively, and the rates were not different between MTA-naïve and MTA-experienced patients.

Conclusion: Although ORR was lower in MTA-experienced patients than in MTA-naïve patients, combined atezolizumab plus bevacizumab therapy merits consideration even for MTA-experienced patients, since the survival rates did not differ between both patients.

Comparison of Atezolizumab + Bevacizumab and Lenvatinib as Primary Therapy by Propensity Score Matching

Shuntaro Obi^{1,2,3}, Takamasa Ohki^{4,5}, Hideo Yoshida⁶, Masatoshi Akamatsu⁷, Yuji Kondo³, Takahisa Sato¹, Shinpei Sato^{1,3}, Masao Omata^{2,8}

¹Internal medicine, Teikyo university Chiba medical center, Chiba, Japan, ²Gastroenterology, Yamanashi central hospital, Yamanashi, Japan, ³Gastroenterology and hepatology, Kyoundo hospital of Sasaki institute, Tokyo, Japan, ⁴Hepatology, Shiota memorial hospital, Chiba, Japan, ⁵Gastroenterology, Mitsui memorial hospital, Tokyo, Japan, ⁶Gastroenterology, Japanese Red Cross Medical Center, Tokyo, Japan, ⁷Gastroenterology, JR Tokyo hospital, Tokyo, Japan, ⁸Tokyo University, Tokyo, Japan

Purpose: Guidelines recommend atezolizumab + bevacizumab combination therapy (ATZ-BEV) as the first-line treatment for advanced liver cancer. On the other hand, lenvatinib (LEN), which has excellent antitumor activity and can be administered orally, can also be used as first-line therapy. We aimed to compare the efficacy of ATZ-BEV and LEN in statistically matched patients using propensity score matching.

Methods: We included 209 patients (LEN) and 64 patients (ATZ-BEV) from March 2018 to December 2021. Each case was introduced as primary treatment, and matched on 6 criteria: age, gender, background liver disease, stage, Up-to-7 in or out, and Child-Pugh score. The primary endpoint was progression-free survival (PFS), and the secondary endpoint was adverse events (AEs); factors contributing to PFS were analyzed.

Results: The median age of all 48 patients selected was 74 years, male 43, HCV-related 19, Stage IV 34, and Up to 7 out 41. PFS was significantly different between the ATZ-BEV and LEN groups: 76% vs. 46% at 6 months and 66% vs. 21% at 12 months, respectively. 5 patients in the ATZ+BEV group and 10 patients in the LEN group had Grade 3 or higher AEs, with no significant difference. Factors contributing to PFS were ATZ-BEV, tumor diameter, ALB, PT-INR, and anorexia.

Conclusion: ATZ-BEV as primary treatment had significantly better PFS than LEN. Side effects of general fatigue were more common in the LEN group, and anorexia was a significant factor related to PFS.

The Benefit of Kinase Inhibitors Combined Therapy with Transarterial Chemoembolization or Hepatic Arterial Infusion for Hepatocellular Carcinoma Patients with Early Recurrence after Resection

Meidai Kasai, Tukasa Aihara, Shinichi Ikuta, Yuko Kawanabe, Kazunori Nomura, Noriko Ichise, Masataka Hujikawa, Takayoshi Nakajima, Ryo Okamoto, Yoshihiko Nakamoto, Hidenori Yanagi, Naoki Yamanaka

Department of Surgery, Meiwa Hospital, Hyogo, Japan

Background: Early recurrence after hepatectomy is one of the poor prognostic factors in hepatocellular carcinoma (HCC). Kinase inhibitors, trans-arterial chemoembolization (TACE) and Hepatic Arterial infusion chemotherapy (HAIC) are treatment options in the management of recurrent HCC in the clinical practice. The aim of this retrospective study was to demonstrate the clinical outcomes of the sequential therapy with these treatments as compared to other treatment options for early recurrence of HCC after surgery.

Material and Method: A single-Centre database of 356 patients who underwent hepatectomy as primary treatment for HCC from Jan 2014 and Dec 2020 was reviewed. Of these ,47 patients who have recurred within 6 months after surgery was divided them into two groups: the sequential therapy group of kinase inhibitors and HAIC followed by TACE and the non-sequential therapy group. We retrospectively compared the clinical outcomes including overall survival (OS) between the two groups.

Results: Nineteen patients received the sequential therapy, while 28 patients received the non-combination therapy (TACE or HAIC alone 14 patients, Kinase inhibitors alone:9 patients, others(ablation/radiotherapy): 5 patients (ablation: 2 patients, additional operation:1patient, radiotherapy:1 patient, palliative care:1patient). The patients' liver functions remained comparable between both groups. The median overall survival (OS) was 12.6 months [95% confidence interval (CI), 6.2-13.4 months] for all patients. The median OS was significantly longer in sequential therapy group than non-sequential therapy group (23.3 months [95%CI:9.1-26.8] vs. 8.6 months[95%CI:6.2-13.4], p=0.0417).

Conclusions: Our study showed the sequential therapy with kinase inhibitor and TACE/HAIC can be a beneficial tool for early recurrences.

Locoregional Therapies for First Occurrence of Hepatocellular Carcinoma: A Single Center Experience

Yoshiaki Matsumura, Akio Moriya, Ramo Ebihara, Yusuke Aya, Masaharu Ando
Department of Gastroenterology, Mitoyo General Hospital, Kanonji, Japan

Background: The treatment approach for hepatocellular carcinoma (HCC) varies according to liver function, tumor burden, and performance status (PS). We aimed to demonstrate the efficacy of locoregional therapies.

Methods: Between March 2014 and April 2022, 112 patients underwent locoregional treatment as initial therapy for first occurrence of HCC. After excluding 3 cases with missing components of data, we evaluated the efficacy of the treatment in 109 patients (74 men and 35 women; median age, 75 years old).

Results: The number of patients at BCLC 0, A, B, C, and D was 13, 10, 18, 28, and 40, respectively. We performed conventional transarterial chemoembolization (TACE) in 65 patients, drug-eluting beads TACE in 19, hepatic arterial infusion chemotherapy in 12, bland embolization in 7, and radiofrequency ablation in 6. Forty-six patients (42%) had RECICL TE4b or better in the initial treatment; 65 patients (60%) achieved radical cure after the initial treatment with or without additional procedures. Multivariable analysis revealed that tumor numbers in the liver (odds ratio, 0.67; 95% confidence intervals, 0.50-0.84) and maximum tumor diameter (0.96, 0.94-0.98) were significant factors for radical cure. The median survival was 2009 days. PS (1.62, 1.07-2.45), maximum tumor diameter (1.03, 1.01-1.04), ascites (3.78, 2.08-6.89), and radical cure (0.24, 0.09- 0.62) were significantly positively correlated with mortality.

Conclusion: Locoregional therapies for HCC provided a fair median survival of more than five years in our institute.

Initial Experience of Atezolizumab Plus Bevacizumab for unresectable Hepatocellular Carcinoma: A retrospective, Real-world Study Conducted in Japan

Tadashi Namisaki, Soichi Takeda Takeda, Kosuke Kaji, Koji Murata, Masahide Enomoto, Yuki Fujimoto, Norihisa Nishimura, Hitoshi Yoshiji
Department of Gastroenterology, Nara Medical University

Aim: We evaluated efficacy and toxicity of atezolizumab and bevacizumab (Atez/Bev) in 26 patients with advanced hepatocellular carcinoma (a-HCC) in real-world setting.

Methods: Of 26 patients treated with atezolizumab plus bevacizumab, a total of 23, were enrolled in this retrospective study. Antitumor responses at 6 weeks after starting therapy was assessed using Response Evaluation Criteria in Solid Tumors (RECIST) ver. 1.1 and modified RESIST (mRESIST). The Common Terminology Criteria for Adverse Events (CTCAE - Version 5.0) was used to evaluate the severity of AE of the therapy. Relative changes in hepatic function and nutritional status were evaluated.

Results: The objective response rate (ORR) and disease control rate (DCR) at 6 weeks were 21.7% and 60.9% according to RECIST and were 26.1% and 69.6% according to modified RECIST, respectively. The incidence of any grade and grade 3 adverse events was 65.2% and 21.7%, respectively. Albumin-bilirubin scores and child-pugh score, NLR, skeletal muscle index, did not worsen at 3 and 6 weeks compared to baseline. The ORR according to mRECIST tended to be higher in patients with non viral infection than in those nonviral group. DCR according to RESIST tended to be higher in patients with BCLC A and B stage than in those in stage C.

Conclusion: ATZ + BV has demonstrated the efficacy and safety in patients with aHCC in real-world practice.

Analysis of Post-progression Treatment on Atezolizumab Plus Bevacizumab Combination Therapy for Patients with Unresectable Hepatocellular Carcinoma

Yuwa Ando, Tomokazu Kawaoka, Hiroshi Aikata

Department of Gastroenterology and Metabolism, Hiroshima University Hospital, Hiroshima, Japan

Background: Although Atezolizumab plus Bevacizumab combination therapy (Atezo+Bev) has been approved for patients with unresectable hepatocellular carcinoma (HCC), there are still no reports on the therapeutic effect of post-progression treatment.

Methods: Patients (n=170, 1st line: n=100, Later line: n=70) with unresectable HCC, Child-Pugh score 5 to 7 liver function, and an Eastern Cooperative Oncology Group performance status of 0 or 1 who were treated with Atezo+Bev from September 2020 to March 2022 were enrolled.

Results: Among 170 patients, 69 were judged progressive disease (PD) at the radiological evaluation. There were 46 candidates for post-progression treatment, who had Child-Pugh class A liver function at progression. Multivariate analysis identified modified albumin-bilirubin grade 1 or 2a at Atezo+Bev initiation (odds ratio 15.92, $p = 0.001$) as a significant and independent factor for candidates. After progression on Atezo+Bev, 42 patients were treated with a molecular targeted agent (MTA) as post-progression treatment (lenvatinib: n=33, sorafenib: n = 1; ramucirumab: n = 4, cabozantinib: n=4). The median post-progression survival on Atezo+Bev was 8.4 months. Cox hazard multivariate analysis showed that a relative tumor volume over 50% at the time of progression (hazard ratio [HR] 6.835, $p = 0.0001$), and no switching to MTAs as post-progression treatment (HR 3.601, $p = 0.0013$) were significant prognostic factors.

Conclusion: Among patients with PD on Atezo+Bev, good liver function at introduction was an important and favorable factor related to eligibility for post-progression treatment. In addition, post-progression treatment with MTAs could improve the prognosis for patients who had been treated with Atezo+Bev.

Comparison of Atezolizumab Plus Bevacizumab and Lenvatinib in Terms of Efficacy and Safety as Primary Systemic Chemotherapy for Hepatocellular Carcinoma

Kazuki Maesaka¹, Ryotaro Sakamori¹, Yuki Tahata¹, Akira Doi¹, Masanori Miyazaki², Kazuyoshi Ohkawa³, Satoshi Tanaka⁴, Sadaharu Iio⁵, Yasutoshi Nozaki⁶, Takayuki Yakushijin⁷, Masahide Oshita⁸, Takahiro Kodama¹, Hayato Hikita¹, Tomohide Tatsumi¹, Tetsuo Takehara¹

¹Department of Gastroenterology and Hepatology, Osaka University Graduate School of Medicine,

²Department of Gastroenterology and Hepatology, Osaka Police Hospital, ³Department of Hepatobiliary and Pancreatic Oncology, Osaka International Cancer Institute, ⁴Department of Gastroenterology and Hepatology, National Hospital Organization Osaka National Hospital,

⁵Department of Gastroenterology and Hepatology, Hyogo Prefectural Nishinomiya Hospital,

⁶Department of Gastroenterology and Hepatology, Kansai Rosai Hospital, ⁷Department of Gastroenterology and Hepatology, Osaka General Medical Center, ⁸Department of Gastroenterology and Hepatology, Ikeda Municipal Hospital

Background: Atezolizumab plus bevacizumab and lenvatinib have each shown efficacy as primary systemic chemotherapies for hepatocellular carcinoma (HCC) in clinical trials. However, comparative trials of these two treatments have not been conducted. This study aimed to compare the therapeutic outcomes of these two treatments in real-world settings.

Methods: This prospectively registered multicenter study analyzed 273 patients with HCC who received atezolizumab plus bevacizumab (the Atezo+Beva group; n = 112) or lenvatinib (the Len group; n = 161) as primary systemic chemotherapy. After propensity score matching (PSM), 99 patients were assigned to each group.

Results: After PSM, the median progression-free survival (PFS) was significantly longer in the Atezo+Beva group than in the Len group (9.1 months vs. 5.2 months; p = 0.006). No significant differences were noted between the two groups in terms of median overall survival (not reached vs. 15.3 months; p = 0.275), objective response rates (25.5% vs. 30.5%; p = 0.445), and disease control rates (72.3% vs. 77.9%; p = 0.377) according to the Response Evaluation Criteria in Solid Tumors version 1.1. Albumin-bilirubin scores were maintained during treatment in the Atezo+Beva group but deteriorated over time in the Len group. The rate of discontinuation due to adverse events (AEs) was lower in the Atezo+Beva group than in the Len group (12.1% vs. 23.2%; p = 0.040).

Conclusion: Atezolizumab plus bevacizumab showed prolonged PFS, maintained hepatic reserve, and had lower rates of discontinuation due to AEs compared with that on using lenvatinib as primary systemic chemotherapy for HCC.

Clinical Issue of Systemic Therapies for Unresectable Advanced Hepatocellular Carcinoma at Municipal Hospital in Japan

Shintaro Takaki^{1,2}, Kazuki Ohya², Yumiko Kosaka^{1,2}, Nami Mori², Keiji Tsuji²

¹Department of General Medicine, Hiroshima Red Cross and Atomic Bomb Survivors Hospital,

²Department of Gastroenterology, Hiroshima Red Cross and Atomic Bomb Survivors Hospital

Annuary 2016 to December 2021. Age 77 years old (y.o.), 53 males (65%), Child Pugh A 68 cases (84%), BCLC stage B 63 cases (78%) C 18 cases (22%), Sorafenib 40 cases (49%) Lenvatinib 27 cases (33%), Atezolizumab/Bevacizumab 14 cases (17%). Patients continued sequential therapy as far as possible. We analyzed overall survival (OS), recurrence-free survival (PFS), factors contributing to OS and the cause of discontinuation.

Results: Whereas 11 (13%) cases were still continued 1st line, 23 cases (28%) changed to 2nd line or more treatment sequentially, 44 cases (54%) discontinued. The median OS was 559 days (95% confidence interval [CI] 346-714) and PFS was 186 days (113-274). Factors contributing to OS were PT activity $\geq 80\%$, response cases, and sequential therapy cases (Hazard Ratio 0.27 95%CI 0.104-0.7003 P=0.007). The cause of discontinuation were worsening the remnant liver function (RLF) in 23 cases (52%), worsening Performance Status (PS) due to comorbidities or complications in 18 cases (41%), worsening PS due to bone metastases in 2 cases (5%), and self-discontinuation in 1 case (2%). The mean age of patients discontinued due to worsening RLF and PS were 76 y.o and 82.9 y.o., respectively. The rate of discontinuation due to worsening PS was significantly higher age ≥ 80 y.o. (14 cases, 67%) than < 80 y.o. (6 cases 27%) (P=0.0148).

Conclusion: To maintain RLF and PS are important in order to continue sequential therapy of HCC. Especially PS maintenance is more important for over 80 y.o. patients.

Stereotactic Body Radiation Therapy for Primary and Recurrent Early-stage Hepatocellular Carcinoma

Shigeki Yano¹, Tomokazu Kawaoka¹, Yasushi Nagata², Hiroshi Aikata¹

¹Department of Gastroenterology and Metabolism, Hiroshima University, ²Department of Radiology, Hiroshima University

Background: We retrospectively evaluated the local tumor control, survival and safety of stereotactic body radiation therapy (SBRT) combined with transcatheter arterial chemoembolization for small hepatocellular carcinoma (HCC).

Methods: Patients with small HCC unsuitable for surgical resection or radiofrequency ablation treated with SBRT from December 2008 to December 2021 were retrospectively evaluated.

Results: 291 HCC patients were enrolled in this study. The median of overall survival (OS) was 49 (95% CI, 44-62) months. The local tumor recurrence rate was 2.1% in 5 years. The median of disease-free survival was 17 (95% CI, 14-22) months. Only 3 patients developed grade 3 toxicities by SBRT during follow-up periods. There were 53 patients who underwent repeated SBRT (second 53 cases, third 10 cases, fourth 4 cases, fifth 1 case.). The median follow-up period from the first to the second SBRT was 20 months. The median of OS from the first and second SBRT was 76 (95% CI, 50-102) and 41 (95% CI, 26-52) months, respectively. There was only one case which occurred grade 3 cholangitis after second SBRT, but others didn't have grade 3 toxicity by repeated SBRT. The median albumin-bilirubin (ALBI) score during 1 year after first SBRT was -2.74 to -2.66, and second SBRT was -2.59 to -2.40. ALBI score didn't get worse by repeated SBRT.

Conclusion: SBRT is an effective and safe treatment for primary and recurrent early-stage HCC.

Trends in Outcomes of Molecular Targeted therapy in Hepatocellular Carcinoma Patients with Major Vascular Invasion

Michihisa Moriguchi, Yuya Seko, Yusuke Takahashi, Kento Takeuchi, Kota Yano, Seita Kataoka, Kanji Yamaguchi, Yoshito Itoh

Department of Gastroenterology and Hepatology, Kyoto Prefectural University of Medicine Graduate School of Medical Science, Kyoto, Japan

Aim: In this study, we aimed to examine the treatment results of molecular targeted agents (MTA) for patients with hepatocellular carcinoma (HCC) with advanced vascular invasion, while accounting the changes in era.

Methods: Of the 1,163 patients who received first-line treatment for HCC between June 2009 and September 2019, 180 patients with a Child-Pugh score of A and major vascular invasion (MVI) such as Vp3, Vp4, and Vv3 were retrospectively analyzed.

Results: Upon dividing into Era1 (2009 to 2016, n=126) and Era2 (2017 to 2019, n=54), the overall survival (OS) was significantly prolonged in Era2 (median survival time (MST): Era1, 210 days; Era2, 305 days; p=0.005). There was no difference in the OS between the two upon administration of sorafenib (MST: Era1 (n=126), 210 days; Era2 (n=24), 208 days; p=0.417). In Era2, cases in which lenvatinib was introduced had significantly longer OS than those that used sorafenib (MST: sorafenib (n=24), 208 days; Lenvatinib (n=30), 463 days; p=0.018). Multivariate analysis for Era2 showed the following contributors to OS: AFP (≥ 400 ng/ml: HR, 3.743; p<0.001), Child-Pugh (6: HR, 4.146; p<0.001), and treatment (lenvatinib vs sorafenib: HR, 0.665; p=0.047). The ratios of treatment discontinuation due to adverse events were 37.5% (9/24) and 33.3% (10/30) for sorafenib and lenvatinib, respectively, and no significant differences were observed between the two drugs (p=0.750).

Conclusions: Outcomes of MTA treatment for HCC with a Child-Pugh score of A and MVI improved with era. The improvement in prognosis could be due to the contribution of lenvatinib.

Clinical Relevance of the Pretreatment Hepatic Reserve in Stereotactic Body Radiotherapy for Hepatocellular Carcinoma with Regard to Prognosis

Yasuhide Motoyoshi, Shunsuke Hamasaki, Aya Wakamatsu, Kosuke Matsumoto, Yuki Kugiyama, Tomoyuki Suehiro, Akira Saeki, Shinya Nagaoka, Kazumi Yamasaki, Atsumasa Komori, Hiroshi Yatsuhashi
Department of Hepatology, National Hospital Organization Nagasaki Medical Center, Nagasaki, Japan

Background: Stereotactic radiotherapy (SBRT) for HCC has been reported to be as effective as other locoregional therapies against nodular lesions. Nevertheless, SBRT is a controversial treatment for HCC; it is not recommended by the BCLC 2022 update. Prevention of the deterioration of hepatic reserve due to treatments is of prime importance; SBRT is often indicated for the treatment up to Child-Pugh B7, but the safety in Child-Pugh B7 has not been fully evaluated. Therefore, we examined the prognosis of patients who underwent SBRT for HCC at our hospital according to hepatic reserve.

Method & Result: From 2013 to 2019, SBRT was performed 82 cases as the treatment for single nodular lesions (<5cm) of HCC in the liver (retrospective study). The median observation period after SBRT was 2.42 years. The overall 3-year survival rate after SBRT was 70.1%. The 3-year local recurrence-free survival rate and the 3-year total liver recurrence-free survival rate was 83.1% and 35.4%, respectively. Multivariate analysis for the post-SBRT survival demonstrated ALBI as the only significant variable. The post-SBRT survival rate of mALBI 2b and of 3 was significantly worse than that of mALBI 1 and of 2a (The 3-year survival rate after SBRT 1/2a/2b/3 = 87.5%/91.7%/42.7%/25.0%). Our Child-Pugh B7 cases were almost equivalent to mALBI 2b.

Conclusion: From our experience, local HCC control potential of SBRT was quite acceptable. Nevertheless, selection of eligible patients for SBRT is critical, due to significantly poorer prognosis among mALBI 2b cases than that in mALBI 1 and 2a cases.

Serious Adverse Events in Atezolizumab Plus Bevacizumab Therapy: A Single Center Experience

Takuya Kihara, Takakazu Nagahara, Yukako Matsuki, Takaaki Sugihara, Hajime Isomoto
Department of Gastroenterology and Nephrology, Faculty of Medicine, Tottori University, Tottori,
Japan

Background: Atezolizumab plus bevacizumab combination therapy (Atez/Bev) is now considered a first-line treatment for advanced hepatocellular carcinoma (HCC). We evaluated the safety of Atez/Bev and verified its serious adverse events.

Methods: Twenty-nine patients with advanced HCC treated with Atez/Bev were analyzed. Eleven patients (38%) had Grade 3 or higher adverse events. Of these, rupture of esophageal varices and acute myocardial infarction was observed in one case each; however, these were mainly caused by Bev. On the other hand, there were seven immune-related adverse events (irAEs)(including duplication) [interstitial pneumonia, hypoadrenocorticism, acute kidney injury (AKI), immune-related pancreatic disorders, and type 1 diabetes] in five cases.

Case: Male in his 70s. Atez/Bev was used for recurrence of hilar lymph node metastasis after surgery for HCC. He was complicated by AKI six courses later and underwent a renal biopsy. Histopathology showed acute tubulointerstitial nephritis. Immunohistochemical staining showed a predominant infiltration of CD3+ T lymphocytes consisting of both CD4+ and CD8+ T cells. He was diagnosed as AKI due to irAE and treated with prednisolone 60 mg/day.

Consideration: Atez/Bev requires attention to various adverse events, including irAE, bleeding, and thromboembolism. Although the frequency of irAE-AKI is rare, we need to collaborate with nephrologists as early as possible because appropriate intervention can improve patients' renal function.

Conclusions: Collaboration with multiple disciplines in the hospital is necessary for early diagnosis and treatment of a wide variety of adverse events, including irAEs.

Hyperprogressive Disease (HPD) and the Importance of Early Radiological Assessment in the Treatment with Atezolizumab Plus Bevacizumab for Advanced Hepatocellular Carcinoma Patients

Miyuki Nakagawa¹, Sadahisa Ogasawara¹, Ei Iobayashi², Masamichi Oobu³, Ryouzaku Azemoto³, Norio Itokawa⁴, Masanori Atsukawa⁴, Naoya Kanogawa¹, Tetsuhiro Chiba¹, Naoya Kato¹

¹Department of Gastroenterology, Graduate School of Medicine, Chiba University, Chiba, Japan,

²Department of Gastroenterology, Asahi General Hospital, Asahi, Japan, ³Department of

Gastroenterology, Kimitsu Chuo Hospital, Kisarazu, Japan, ⁴Division of Gastroenterology,

Department of Internal Medicine, Nippon Medical School Chiba Hokusoh Hospital, Inzai, Japan

Objectives: Hyperprogressive disease (HPD) triggered by immune checkpoint blockade has already been reported in other types of malignancies, and is known to occur immediately after the administration. So far, little knowledge regarding to HPD in advanced hepatocellular carcinoma (HCC) treated with atezolizumab plus bevacizumab (Atezo/Bev) is available at this time. In this study, we conducted a detailed analysis of radiological response of patients treated with Atezo/Bev in a real-world clinical practice, and attempted to investigate the incidence of early PD and HPD as well as the factor associated with HPD.

Patients and Methods: We retrospectively collected data of advanced HCC patients who introduced Atezo/Bev from October 2020 to May 2021 in Japan. The observation period was until August 2021. Early PD was defined as PD within 2 months after administration, and HPD was defined as previously reported: tumor growth of more than 50% of PD within 2 months, appearance of two or more new lesions, or appearance of new metastases in other organs.

Results: In this study, 117 patients were collected. The median age of the patients was 73 years (48-89), and 35 patients (29.9%) had HCV and 22 patients (18.8%) had HBV. The median observation period was 6.4 months. Early PD and HPD were observed in 21 patients (17.9%) and 14 patients (66.7% of early PD).

Conclusion: The frequency of early PD was comparable to the results of the IMbave 150 trial. The majority of patients with early PD within 2 months classified as HPD in this study.

Effects on Survival of Adverse Event on Atezolizumab Bevacizumab for Hepatocellular Carcinoma: A Multicenter Study by the Japan Red Cross Liver Study Group

Shintaro Takaki¹, Nami Mori¹, Keiji Tsuji¹, Masayuki Kurosaki², Hironori Ochi³, Hiroyuki Marusawa⁴, Shinichiro Nakamura⁵, Narita Ryoichi⁶, Yasushi Uchida⁷, Takehiro Akahane⁸, Masahiko Kondo⁹, Atsunori Kusakabe¹⁰, Koichiro Furuta¹¹, Haruhiko Kobayashi¹², Hirotaka Arai¹³, Riko Nonogi¹⁴, Takashi Tamada¹⁵, Chitomi Hasebe¹⁶, Kaoru Tsuchiya², Namiki Izumi²

¹Department of gastroenterology, Hiroshima Red Cross and Atomic-bomb survivors Hospital,

²Department of Gastroenterology and Hepatology, Musashino Red Cross Hospital, ³Center for Liver-Biliary-Pancreatic Disease, Matsuyama Red Cross Hospital, ⁴Department of Gastroenterology and Hepatology, Osaka Red Cross Hospital, ⁵Department of Gastroenterology, Himeji Red Cross Hospital, ⁶Department of Gastroenterology, Oita Red Cross Hospital, ⁷Department of Gastroenterology, Matsue Red Cross Hospital, ⁸Department of Gastroenterology, Ishinomaki Red Cross Hospital, ⁹Department of Gastroenterology, Otsu Red Cross Hospital, ¹⁰Department of Gastroenterology, Japanese Red Cross Nagoya Daini Hospital, ¹¹Department of Gastroenterology, Masuda Red Cross Hospital, ¹²Department of Gastroenterology, Japanese Red Cross Okayama Hospital, ¹³Department of Gastroenterology, Maebashi Red Cross Hospital, ¹⁴Department of Gastroenterology, Tokushima Red Cross Hospital, ¹⁵Department of Gastroenterology, Takatsuki Red Cross Hospital, ¹⁶Department of Gastroenterology, Japanese Red Cross Asahikawa Hospital

Purpose: We aimed to describe the real-world efficacy and safety of atezolizumab bevacizumab (ATZ/BV) for hepatocellular carcinoma (HCC). Patients and method This retrospective analysis of a multicenter registry included 268 patients receiving ATZ/BV for unresectable HCC. We evaluated the incidence of adverse effect (AE) and determined effect on survival of AE. Over all survival (OS) and progression free survival (PFS) with each present or absence AE were calculated according to Kaplan meier methods.

Results: Median follow up duration was 185 months (1-504 months) Of 258 patients 224 (83.6%) had any AE, general fatigue 84 (31.3%), nausea/appetite loss 66 (24.6%), proteinuria 66 (24.6%), hypertension 59 (24.6%), AST/ALT elevation 46 (17.2%), ALT elevation 46(17.2%), fever elevate 37 (13.9%), ascites 32 (11.9%), eruption 32 (11.9%) diarrhea 28 (10.4%), hemorrhage 27 (10.1%), loss of plate let count 19 (7.1%), and irAE occurred 31 patients (11.6%). While median (95%CI) OS and PFS were compared with presence or absence of each AE, 462days(431-NA) vs NA (216-NA) (P=0.217), PFS 179days(86-NA) vs 245 (171-329) (P=0.441) for any AE, OS 231 days (112-NA) vs 462 days (431-NA) (P=0.035), PFS 103 (42-NA) vs 251 (182-330) (P=0.0033) for T.Bil elevation, and OS 330 days (172-NA) vs 462 (431-NA) (P=0.0025), PFS 141 (105-283) vs 251 (205-332) (P=0.0518) for AST or ALT elevation. There were no significant difference in any of the other AE.

Conclusion: Although presence of AE during treatment of ATZ/BV for HCC were not associated with prognosis, liver dysfunction could adversely affect to OS and PFS.

Results of Living Donor Liver Transplantation for Hepatocellular Carcinoma: A Single Center Experience in Vietnam

Hieu Le Trung, Thanh Le Van, Quang Vu Van

Dept of HBP and Liver Transplant, 108 Military Central Hospital, Hanoi, Vietnam

Background: To describe the current practice of living donor liver transplantation (LDLT) for hepatocellular carcinoma (HCC), including the patient selection criteria, surgical techniques, postoperative complications, and the results of 108 Military Central Hospital, one of the high-volume centres for LDLT in Vietnam.

Methods: We prospectively analyzed the data on all HCC patients, consecutively performed LDLT from October 2017 to June 2022 in 108 Military Central Hospital. Our centre practices careful selection for HCC patients using the Milan and UCSF criteria, supplemented by alpha-fetoprotein level and the model for end-stage liver disease score. We pioneered in using the extended right lobe graft and the novel hepatic venoplasty technique, which lessen the risk of hyperperfusion and small-for-size syndrome with improved overall recipient survival. Data were collected prospectively and presented as the mean values and ranges.

Results: A total of 57 cases of adult-to-adult LDLT using right lobe graft for HCC treatment were collected. Of our patients, 50,8% met the Milan and UCSF criteria. The 2-year recurrence rate was significantly lower in patients who met Milan than in patients who exceeded the Milan criteria (1.75% vs. 14%). A 5-year overall and disease-free survival rate of 73.5% and 70.3% were achieved. 73,6% of the complications were rated as Clavien I.

Conclusion: LDLT is an ideal treatment for HCC in Vietnam with regard to the critical organ shortage and high demand for transplantation. The single orifice hepatic vein reconstruction in LDLT using right lobe graft is a simple and feasible surgical technique.

Therapeutic Efficacy of Nivolumab Plus Sorafenib Therapy in Patients with Unresectable Hepatocellular Carcinoma

Ching-Sheng Hsu^{1,4,5}, Tzu-Rong Peng², Chao Chuan Wu³

¹Division of Gastroenterology, Department of Internal Medicine, Dalin Tzu Chi Hospital, Buddhist Tzu Chi Medical Foundation, Chia-Yi, Taiwan, ²Department of Pharmacy, Taipei Tzu Chi Hospital, Buddhist Tzu Chi Medical Foundation, New Taipei City, Taiwan, ³Department of Surgery, Taipei Tzu Chi Hospital, Buddhist Tzu Chi Medical Foundation, New Taipei City, Taiwan, ⁴Liver Disease Prevention and Treatment Center, Dalin Tzu Chi Hospital, Buddhist Tzu Chi Medical Foundation, Chia-Yi, Taiwan, ⁵School of Post-Baccalaureate Chinese Medicine, Tzu Chi University, Hualien, Taiwan

Background: Immune checkpoint inhibitor therapy is the backbone of numerous combination regimens for improving the therapeutic response and survival of patients with hepatocellular carcinoma (HCC). We aimed to investigate the therapeutic efficacy of nivolumab plus sorafenib therapy in patients with unresectable HCC.

Methods: Patients with unresectable HCC and receiving sorafenib who were followed up at Taipei Tzu Chi Hospital from January 2016 to December 2020 were selected for this study. We conducted a 1:1 propensity score matching between patients treated with nivolumab plus sorafenib and those treated with sorafenib alone. The primary outcome was overall survival (OS) presented as a hazard ratio calculated using Cox proportional hazards regression models.

Results: Among 72 patients with unresectable HCC and receiving sorafenib, 36 receiving nivolumab plus sorafenib and 36 receiving sorafenib alone were propensity score-matched and included in the analysis. Nivolumab plus sorafenib therapy is an independent predictor of OS in multivariate analysis. The OS at 5 years was 61.1% among those who received nivolumab plus sorafenib and 22.2% among those who received sorafenib alone ($p = 0.002$). The hazard ratio of OS for nivolumab plus sorafenib therapy compared with sorafenib alone was 0.36(95%CI, 0.19-0.70; $p = 0.003$; median OS:3.6 vs. 1.2 years; $p = 0.031$). Furthermore, α -fetoprotein (AFP) determined the therapeutic response of nivolumab plus sorafenib; patients with a baseline AFP < 10 ng/mL and early reduction in AFP had a 100% objective response rate and disease control rate.

Conclusion: In patients with unresectable HCC, nivolumab plus sorafenib resulted in better OS outcomes than sorafenib.

Long-term Survival by the Maintenance of Liver Functional Reserve in a Patient with the Ovarian and Peritoneal Progression of Hepatocellular Carcinoma: A Case Report

Takeshi Yokoo¹, Satoko Motegi², Shun Yamazaki², Ryosuke Nozawa², Rie Azumi², Yuzo Kawata², Kohei Ogawa¹, Toru Setsu², Ken-ichi Mizuno², Koji Nishino³, Hajime Umezu⁴, Hirokazu Kawai⁵, Takeshi Suda⁶, Shuji Terai²

¹Department of Preemptive Medicine for Digestive Diseases and Healthy Active Life, School of Medicine, Niigata University, ²Division of Gastroenterology and Hepatology, Graduate School of Medical and Dental Sciences, Niigata University, ³Department of Obstetrics and Gynecology, Graduate School of Medical and Dental Sciences, Niigata University, ⁴Division of Pathology, Graduate School of Medical and Dental Sciences, Niigata University, ⁵Department of Internal Medicine, Niigata Prefectural Shibata Hospital, ⁶Department of Gastroenterology and Hepatology, Uonuma Institute of Community Medicine Niigata University Hospital

Extrahepatic spread of hepatocellular carcinoma (HCC) is known as a factor of poor prognosis. Herein, we report a case with 11.5-year survival after diagnosis of ovarian and peritoneal progression. A 61-year-old female suffered from HCC in S8 of the liver and underwent sequential therapy of radiofrequency ablation, percutaneous ethanol injection therapy (PEIT), and stereotactic body radiation therapy to the single nodule and its local recurrence in 2007 and 2008. In 2009, her left ovary got swelling to 11 cm in size, and bilateral salpingo-oophorectomy was performed. Because numerous small nodules were additionally detected on the peritoneum during the operation, several peritoneal nodules were also resected as a palliative procedure. Although the pathological diagnosis was HCC, any intrahepatic lesion was not seen at that time. After the surgery, regimens based on 5-fluorouracil were mainly used as systemic chemotherapy. On-demand TACE and PEIT were combined as locoregional treatments after intrahepatic recurrence appeared in 2012. Molecular targeted agents and immune checkpoint inhibitor could not be sufficiently administered due to severe adverse effects. Anti-tumoral therapy could be performed for as long as 11 years, setting appropriate intervals to maintain the liver functional reserve. ALBI score showed only slight deterioration from -2.45 to -2.30 for the initial 10 years. In the last 1 year, intrahepatic lesions became uncontrollable and the ALBI score deteriorated to -1.28 at the end of anti-tumoral therapy. Our case suggested that control and maintenance of intrahepatic lesion and liver functional reserve were necessary to achieve long-term survival under multidisciplinary therapy.

New Fusion Technology Called Colorized Fusion

Takuya Toda^{1,2}, Kazutoshi Fuke^{1,2}, Takushi Manabe^{1,2}, Chikara Ogawa¹, Mitsushige Shibato¹,
Tsutomu Masaki²

¹Department of Gastroenterology and Hepatology, Takamatsu Red Cross Hospital, ²Department of Gastroenterology and Neurology, Faculty of Medicine

This new technology, colorized Fusion, uses SYNAPSE 3D to extract needed DICOM data of CECT, for example portal vein, hepatic vein, tumor and segmentation area in the liver, before US examination. After the extraction, we integrate these DICOM data onto US platform and make colorized reference images during the fusion procedure. This new technology is very useful to understand the segmentation in the liver more easily and visually than usual gray scale US, especially for beginner operators. If we upload the DICOM data before US examination, we can prepare for the procedure of colorized fusion without the patients nearby. Various combinations of DICOM data is possible to perform colorized fusion. For example, we can select 8 parts, segment 2,3,4 and 8, tumor, portal vein, hepatic vein and liver parenchyma. Colorized fusion finds tumor locations and protrusions more visually. Combinations of 3D volume analyzer Synapse 3D and Fusion have many possibilities. Colorized fusion provides us with very high diagnostic confidence and safety performance for RFA.

Examination of Cases of Stereotactic Body Radiotherapy for Hepatocellular Carcinoma at Our Hospital

Tomotaka Yazaki¹, Hiroshi Tobita¹, Masatoshi Kataoka¹, Shunji Ishihara²

¹Department of Hepatology, Shimane University Faculty of Medicine, ²Department of Internal Medicine II, Shimane University Faculty of Medicine

Background: Radiation therapy has long been used for hepatocellular carcinoma (HCC), which is difficult to apply to other treatments, such as cases with portal vein tumor embolism. Recent advances in high-precision radiotherapy technology have proposed stereotactic body radiation therapy (SBRT), which can concentrate doses on tumors while reducing unnecessary doses administered to normal tissues, so that good freedom from local progression (FFLP) have been reported. Here in, we will report on the treatment results of cases in which SVRT treatment was performed for HCC.

Methods: From January 2017 to September 2021, we retrospectively examined 10 patients who received SBRT treatment for HCC.

Results: Median age 75.5 years, male / female = 6/4 cases, HBV / HCV / NBNC = 2/6/2 cases, all lesions were single lesions (BCLC 0/A=8/2), and the median tumor diameter was 15 mm. The median post-treatment observation period was 395 day. Child-Pugh score 5/6 = 8/2 cases. No decrease of the score was observed in all cases after treatment. In addition, no adverse event due to SBRT were observed in all cases. Of the all cases with confirmed outcomes, 2 had ectopic relapsed lesions, but all had no recurrence at the treatment site.

Conclusion: In this study, good FFLP was observed, and no adverse event or decreased hepatic spare ability were observed. SBRT is a relatively new treatment method, and it is considered that it is possible to safely treat lesions that have been considered difficult to treat by local puncture.

Blockade of Angiotensin-II Augments the Responsiveness of Human Liver Cancer Cells to Lenvatinib

Kosuke Kaji, Hirotetsu Takagi, Norihisa Nishimura, Hitoshi Yoshiji
Department of Gastroenterology, Nara Medical University

Molecular targeted therapy with lenvatinib is commonly offered to advanced hepatocellular carcinoma (HCC) patients, although it is often interrupted by adverse effects which require a reduction of the initial dose. Thus, an alternative lenvatinib-based therapy to compensate for dose reduction is anticipated. This study aimed to assess the effect of combination of low-dose of lenvatinib and the angiotensin-II (AT-II) receptor blocker losartan on human HCC cell growth. In vitro studies found that losartan suppressed the proliferation by inducing G1 arrest and caused apoptosis as indicated by the cleavage of caspase-3 in AT-II-stimulated HCC cell lines (Huh-7, HLE, and JHH-6). Losartan attenuated the AT-II-stimulated production of vascular endothelial growth factor-A (VEGF-A) and interleukin-8 and suppressed lenvatinib-mediated autocrine VEGF-A production in HCC cells. Moreover, it directly inhibited VEGF-mediated endothelial cell growth. Notably, the combination of lenvatinib and losartan augmented the cytostatic and angiostatic effects of the former at a low-dose, reaching those achieved with a conventional dose. Correspondingly, HCC tumor xenograft assay showed that oral administration of losartan combined with lenvatinib reduced the subcutaneous tumor burden and intratumor vascularization in BALB/c nude mice. These findings support that this regimen could be a viable option for patients intolerant to standard lenvatinib dosage.

The Relationship between the Expression of Tumor Microenvironment-related Genes and the Gene Mutations of Hepatocellular Carcinoma from TCGA Data

Yoshinari Asaoka, Atsushi Tanaka

Department of Medicine, Teikyo University School of Medicine

Background: Angiogenesis inhibitors and immune checkpoint inhibitors are used in the treatment of advanced hepatocellular carcinoma, both of which target the tumor microenvironment. The data in TCGA (The Cancer Genome Atlas) includes comprehensive data on gene expression and mutations. Genes specifically expressed in cells in the microenvironment can be used to assess the status of the tumor microenvironment, and their association with genetic mutations may be important in predicting therapeutic efficacy.

Methods: Pretreated data from 360 HCC cases were downloaded from the GDAC Firehose browser (<https://gdac.broadinstitute.org>) and analyzed with software R. One or more cases harbored mutations of 14,728 genes and the expression of 20,500 genes could be analyzed. Using expression data, we identified gene sets expressed in immune cells (IC), fibroblasts (FB), and vascular endothelial cells (VEC) by correlation analysis and network analysis. Principal component analysis was performed on each gene set to evaluate the effect of the genetic variants on their respective first principal components by t-test.

Results: Pearson's correlation analysis revealed 541 genes with correlation coefficients of 0.9 or higher. They included 127 genes for IC markers, 23 genes for FB markers, and 8 genes for VEC markers. Principal component analysis of each gene set showed that the gene mutations with the strongest involvement in the first principal component were TTN gene mutation for IC markers, CTNNA1 mutation for FB markers, and TP53 mutation for VEC markers.

Conclusion: In tumor tissues, CTNNA1 mutation related to decreased expression of FB markers, and TP53 mutation related to decreased expression of VEC markers.

Study Aimed to Elucidate Mechanism of Maintaining Sarcomatoid Hepatocellular Carcinoma Features

Ryo Morisue^{1,2}, Toshihiro Suzuki^{3,4}, Motohiro Kojima¹, Tetsuya Nakatsura³

¹Division of Pathology, Exploratory Oncology Research & Clinical Trial Center, National Cancer Center, Chiba, Japan, ²Department of Hepatobiliary and Pancreatic Surgery, National Cancer Center Hospital East, Chiba, Japan, ³Division of Cancer Immunotherapy, Exploratory Oncology Research & Clinical Trial Center, National Cancer Center, Chiba, Japan, ⁴General Medical Education and Research Center, Teikyo University, Tokyo, Japan

Background: We reported sarcomatoid hepatocellular carcinoma (SHC), a hepatocellular carcinoma (HCC) with sarcomatoid changes, has unique features characterized by epithelial-mesenchymal transition (EMT) -associated transcriptome and PD-L1 expression. Our aim is to determine the role of a gene specific to SHC in maintaining such features.

Methods: Whole exome sequence (WES) of freshly obtained SHCs and conventional HCCs (cHCCs) was performed to search for non-synonymous mutations specific to SHC and determined a candidate gene. Target sequence for the gene was performed using FFPE samples. We generated SHC cell line and the gene-knockout cell (SHC-KO) using CRISPR-Cas9 system. Cell morphology was evaluated by phase-contrast microscopy. Epithelial/mesenchymal markers and PD-L1 expression were examined by qRT-PCR, immunoblotting and immunostaining. Next, SCID/Beige xenograft model was developed. The histomorphology was evaluated by HE stains; epithelial/mesenchymal markers and PD-L1 expression were examined by immunohistochemistry.

Results: We determined a candidate gene by WES from two SHCs and five cHCCs. The TCGA database revealed the gene aberrations (nonsynonymous mutations) were found in 2% of HCCs, while our target sequence of gDNA extracted from the sarcomatous region of 17 SHCs showed they were found in 35% of SHCs. In vitro assay showed SHC-KO cells had epithelial-morphology, increased epithelial markers, decreased mesenchymal markers and PD-L1 expression. We found the alveolar/trabecular histology in SHC-KO tumor in vivo. Immunohistochemistry showed increased epithelial marker expression and diminished mesenchymal markers and PD-L1 expression in SHC-KO tumor.

Conclusion: The candidate gene extracted from this study may contribute to the maintenance of EMT and PD-L1 expression in SHC.

Telmisartan Inhibits Hepatocellular Carcinoma Cell Proliferation in Vitro by Inducing Cell Cycle Arrest

Kyoko Oura, Kei Takuma, Mai Nakahara, Tomoko Tadokoro, Koji Fujita, Joji Tani,
Masahumi Ono, Asahiro Morishita, Tsutomu Masaki

Department of Gastroenterology and Neurology, Kagawa University Faculty of Medicine/Graduate School of Medicine

Hepatocellular carcinoma (HCC) is the most common primary malignancy of the liver and the third leading cause of cancer-related death. Telmisartan, a widely used antihypertensive drug, is an angiotensin II type 1 (AT1) receptor blocker (ARB) that might inhibit cancer cell proliferation, but the mechanisms through which telmisartan affects various cancers remain unknown. The aim of the present study was to evaluate the effects of telmisartan on human HCC and to assess the expression of microRNAs (miRNAs). We studied the effects of telmisartan on HCC cells using the HLF, HLE, HepG2, HuH-7 and PLC/PRF/5 cell lines. In our experiments, telmisartan inhibited the proliferation of HLF, HLE and HepG2 cells, which represent poorly differentiated types of HCC cells. However, HuH-7 and PLC/PRF/5 cells, which represent well-differentiated types of HCC cells, were not sensitive to telmisartan. Telmisartan induced G0/G1 cell cycle arrest of HLF cells by inhibiting the G0-to-G1 cell cycle transition. This blockade was accompanied by a marked decrease in the levels of cyclin D1, cyclin E and other cell cycle-related proteins. Notably, the activity of the AMP-activated protein kinase (AMPK) pathway was increased, and the mammalian target of rapamycin (mTOR) pathway was inhibited by telmisartan treatment. Additionally, telmisartan increased the level of caspase-cleaved cytokeratin 18 (cCK18), partially contributed to the induction of apoptosis in HLF cells, and reduced the phosphorylation of ErbB3 in HLF cells. Furthermore, miRNA expression was markedly altered by telmisartan in vitro. In conclusion, telmisartan inhibits human HCC cell proliferation by inducing cell cycle arrest.

Characterization and Cisplatin Effect of Lenvatinib-resistant Hepatocellular Carcinoma Cells

Sae Hamaya, Shintaro Fujihara, Takaaki Mizuo, Ryota Nakabayashi, Kei Takuma, Mai Nakahara, Kyoko Oura, Tomoko Tadokoro, Koji Fujita, Asahiro Morishita, Masafumi Ono, Tsutomu Masaki
Department of Gastroenterology and Neurology, Faculty of Medicine, Kagawa University, Kagawa, Japan

Background: The acquisition of drug resistance to molecularly targeted drugs such as lenvatinib is an important problem in advanced hepatocellular carcinoma (HCC). The purpose of this study was to generate lenvatinib-resistant (LR) HCC cells and to investigate resistance mechanisms and potential drugs that may improve therapy.

Methods: LR cells were generated by long-term culture under lenvatinib exposure; the biological properties of LR cells and the antitumor mechanism of cisplatin were analyzed in vitro.

Result: Activation of ERK signaling and several miRNA changes were observed in LR cells. Cisplatin inhibited cell proliferation in LR cells, and the mechanism was due to G2/M cell cycle arrest via the ATM/ATR-Chk1/Chk2 signaling pathway.

Conclusion: Activation of ERK signaling was characteristic in LR cells. Cisplatin showed antitumor effects in LR cells. Cisplatin-based regimens may provide a post-treatment option for lenvatinib and may contribute to the establishment of new combination therapies as a multidisciplinary treatment for advanced HCC.

Study on Validity of Biomarkers DKK1 in Diagnosis and Posttreatment Monitoring of Hepatocellular Carcinoma

Hieu Le Trung¹, Hai Le Trung²

¹Dept of HBP and Liver Transplant, 108 Military Central Hospital, Hanoi, Vietnam,

²Vietnam Association for the Study of Liver Diseases

Background: Dickkopf-1 (DKK1) recently was reported to be involved in the progress of HCC. The study aims to evaluate validity of DKK1 in diagnosis and post-treatment of HCC/HBV.

Methods: Study on 114 HCC patients at Central Military Hospital (CMH) 108 and Military Hospital (MH) 103 (1/2016-3/2020). DKK1 was analyzed in Department of Microbiology of CMH 108, including using Realtime PCR technique with Taqman probe for level of mRNA DKK1 expression and ELISA technique for serum protein DKK1.

Results: With $DKK1 > 2.15$ ng/mL, the positive rates of serum protein DKK1 were significantly increased when compared with those of AFP. The mean of serum protein DKK1 of HCC was significantly higher than it in liver cirrhosis (LC) patients with $p < 0.05$. Combination between AFP and DKK1 expression will improved positive rates and help more diagnosis in 12.3% of HCC cases. Logistic regression analysis showed the risk of HCC will increased about 18.5 times when $DKK1 > 2.15$ ng/mL. The level of DKK1 expression reduced in patients with > 2 tumors when compare with one tumor and in cases with size > 5 cm when compare with < 5 cm. This correlation was the same with reducing of AFP related with quantity and size of tumor. The level of DKK1 expressions reduced in post-hepatectomy when compare with those before surgery and in time of more than one year when compare with those from 1 to 12 months.

Conclusion: Biomarkers serum protein DKK1 and DKK1 expression have validity in diagnosis and post-treatment monitoring of HCC, especially for AFP-negative patient.

Immunological Changes in Atezolizumab plus Bevacizumab Administration for Hepatocellular Carcinoma

Hidenari Nagai, Kunihide Mouri, Akira Nogami, Hideki Nagumo, Kojiro Kobayashi, Yu Ogino, Takanori Mukozu, Teppei Matsui, Noritaka Wakui, Takahisa Matsuda
Division of Gastroenterology and Hepatology, Toho University Medical Center Omori Hospital

Purpose: The purpose of this study was to clarify the efficacy of Atezolizumab plus Bevacizumab (AtezoBev) therapy for patients with HCC from immunological changes.

Patients: 29 unresectable HCC cases who received AtezoBev therapy were included. Then, after classifying into two groups according to the presence or absence of prior treatment.

Methods: Atezo 1200 mg/body and Bev 15 mg/kg were administered every 3 weeks, and was administered until it was judged to be clinically ineffective. Contrast-enhanced CT examination was performed 6 weeks later, and the therapeutic effect was judged using mRECIST.

Results: AtezoBeva therapy for unresectable HCC tended to be less effective in the previously treated group than in the untreated group. There was no significant change in sMICA before and after treatment in both groups, but that before treatment was significantly higher in the prior treatment group than in the absence of prior treatment. In the absence of prior treatment group, there was a significant increase in IL-6, sIL-2R and TNF-alpha after treatment, and a significant decrease in Treg cells although there was no significant change in Th1/Th2 cell fraction. In the prior treatment group, only sIL-2R showed a significant increase.

Conclusion: AtezoBev therapy for patients with HCC-complicated liver disease can be expected to have an effective immune response in patients without prior treatment, but it may not be expected in patients with prior treatment. In the prior treatment group, CTLs have difficulty recognizing cancer cells due to sMICA.

Telomerase Reverse Transcriptase Promoter Mutations in Human Hepatobiliary, Pancreatic, and Gastrointestinal Cancer Cell Lines

Masahiro Ono, Toshiaki Kono, Daisuke Namima, Naoki Fujita, Hiroki Yamana, Hideki Kamada, Tsutomu Masaki

Department of Gastroenterology and Neurology, University of Kagawa, Kagawa, Japan

The promoter region of the telomerase reverse transcriptase (TERT) gene is a regulatory element capable of affecting TERT expression, telomerase activity, and telomerase length. Mutations within the TERT promoter region are the most common mutation in many cancers. In this study we aimed to characterize the TERT promoter mutation status in hepatobiliary, pancreatic, and gastrointestinal cancer cell lines by digital PCR (dPCR). TERT promoter mutation status was assessed in 13 hepatocellular carcinoma (HCC) lines, six cholangiocarcinoma (CCA) lines, 12 pancreatic cancer lines, 18 gastrointestinal cancer lines, and three healthy control cell lines. C228T promoter mutations were detected in nine HCC cell lines (JHH-6, JHH-5, Li-7, HepG2, Huh-7, HLE, JHH-7, HLF, and JHH-2) and one CCA cell line (SSP-25), and C250T TERT promoter mutations were detected in KYSE850 oesophageal squamous cell carcinoma cell lines. The C228T promoter mutation is specific to liver cancer cell lines among various gastrointestinal cancer cell lines. These data will contribute to future research on tumorigenic mechanisms and clinical use of dPCR to detect mutations.

IL-33 Released from Senescent Hepatic Stellate Cells Promotes Obesity-Associated Hepatocellular Carcinoma

Ryota Yamagishi¹, Fumitaka Kamachi¹, Tomonori Kamiya¹, Yi Cheng¹, Yoshiki Nonaka¹, Norifumi Kawada², Susumu Nakae³, Eiji Hara⁴, Naoko Ohtani¹

¹Department of Pathophysiology, Osaka Metropolitan University, Graduate School of Medicine, Osaka, Japan, ²Department of Hepatology, Osaka Metropolitan University, Graduate School of Medicine, Osaka, Japan, ³Graduate School of Integrated Sciences for Life, Hiroshima University, Higashi-Hiroshima City, Hiroshima, Japan, ⁴Research Institute for Microbial Diseases, Osaka University, Suita, Osaka, Japan

While cellular senescence functions as tumor suppression mechanism, long-term senescent cells produce detrimental secretome, called senescence-associated secretory phenotype (SASP). Although mechanism of SASP factor induction have been intensively studied, it remains unclear whether senescent cells have distinct mechanisms to secrete SASP factors. In this study, using a mouse model of obesity-induced hepatocellular carcinoma (HCC), we show that a SASP factor, IL-33, is induced in senescent hepatic stellate cells (HSCs) in the obesity-associated liver tumor, and is cleaved by chymotrypsin-like elastase family member 1 (CELA1). Moreover, we found cleaved IL-33 is released from senescent HSCs triggered by lipoteichoic acid (LTA), a cell wall component of gram positive bacteria which was accumulated in the liver tissue of high fat diet fed mice, and the release of IL-33 was mediated through cell membrane pores formed by the gasdermin D (GSDMD) N-terminus, which was cleaved by LTA-induced caspase-11. The released IL-33 promoted HCC development through activating ST2-positive Treg cells. Interestingly, cleaved IL-33 and GSDMD N-terminus were also detected in HSCs in human NASH-associated HCC tumor regions, suggesting that similar mechanism could be involved in human liver cancer progression. These results uncover a release mechanism of IL-33 from senescent HSCs, thereby facilitating obesity-associated HCC progression. Our findings could lead to new insights for understanding obesity-associated HCC progression.

Alteration of the Tumor Microenvironment by Pharmacological Inhibition of EZH2 in Hepatocellular Carcinoma

Junjie Ao¹, Tetsuhiro Chiba¹, Na Qiang¹, Tatsuya Kaneko¹, Tadayoshi Kogure¹, Yaojia Ma¹, Jiaqi Zhang¹, Keita Ogawa¹, Motoyasu Kan¹, Terunao Iwanaga¹, Takafumi Sakuma¹, Hiroaki Kanzaki¹, Ryuta Kojima¹, Yuko Kusakabe¹, Masato Nakamura¹, Ryo Nakagawa¹, Ryosuke Muroyama¹, Jun Kato¹, Naoya Mimura², Naoya Kato¹

¹Department of Gastroenterology, Graduate School of Medicine, Chiba University, Japan,

²Department of Transfusion Medicine and Cell Therapy, Graduate School of Medicine, Chiba University, Japan

Enhancer of zeste homolog 2 (EZH2), a core component of polycomb repressive component 2 is overexpressed in a variety of cancers and recognized as a therapeutic target molecule. However, recent studies revealed that EZH2 possesses immunomodulatory functions in the tumor microenvironment (TME). In the present study, we evaluated the impact of EZH2 on TME of hepatocellular carcinoma (HCC) using immunocompetent mouse model. UNC1999, an EZH2 inhibitor, impaired growth of the murine HCC cells (H22 cells) and induced apoptosis in a dose-dependent manner. Although UNC1999 significantly inhibited the growth of H22 cells-derived tumors in non-obese diabetic/severe combined immunodeficiency mice, its anti-tumor effect was diminished in allogenic Balb/c mice. Flow cytometric analyses of TME cells in Balb/c mice demonstrated a significant decrease in the number of IFN γ +CD8⁺ T cells and regulatory T cells and a significant increase in the number of myeloid-derived suppressor cells (MDSCs). Administration of Gr-1 neutralizing antibody concomitant with UNC1999 restored anti-tumor effect accompanied by an increase in the number of CD8⁺ T cells followed by a decrease in the number of MDSCs. Lastly, Chemokine array demonstrated an enhanced expression of chemokines responsible for MDSC recruitment such as C5a, CCL8, and CCL9. In conclusion, our results demonstrated that EZH2 inhibition contributes to attenuation of tumor immunity caused by TME arrangement. Combination therapy with EZH2 inhibitors and agents that reduce MDSCs might represent a novel therapeutic strategy for HCC.

Galectin9 Suppresses Cholangiocarcinoma Cell Proliferation by Inducing Apoptosis but not Cell Cycle Arrest

Kiyoyuki Kobayashi¹, Ryota Nakabayashi², Masahiro Hirata², Toshiaki Kohno², Daisuke Namima², Naoki Fujita², Hiroki Yamana², Hideki Kamada², Masafumi Ono¹, Tsutomu Masaki²

¹Division of Innovative Medicine for Hepatobiliary and Pancreatology, Kagawa University, Kagawa, Japan, ²Department of Gastroenterology and Neurology

Cholangiocarcinoma is the most common biliary malignancy and the second most common hepatic malignancy after hepatocellular carcinoma (HCC). Galectin9 (Gal9) is a tandem repeat type galectin that has recently been shown to exert antiproliferative effects on cancer cells. Therefore, the present study evaluated the effects of Gal9 on the proliferation of human cholangiocarcinoma cells in vitro as well as the microRNAs (miRNAs) associated with the antitumor effects of Gal9. Gal9 suppressed the proliferation of cholangiocarcinoma cell lines in vitro and the growth of human cholangiocarcinoma cell xenografts in nude mice. Our data further revealed that Gal9 increased caspase cleaved keratin 18 (CCK18) levels, and the expression of cytochrome c increased in Gal9 treated cholangiocarcinoma cell lines. These data suggested that Gal9 induced cholangiocarcinoma cell apoptosis via the intrinsic apoptosis pathway mediated by caspase dependent or independent pathways. In addition, Gal9 reduced the phosphorylation of the epidermal growth factor receptor (EGFR), insulin like growth factor and insulin like growth factor1 receptor (IGF-1R), hepatocyte growth factor receptor and fibroblast growth factor receptor 3 (FGFR3). These findings suggest that Gal9 can be a candidate of therapeutic target in the treatment of cholangiocarcinoma.

2-Oxoglutarate Cooperates with Aspartate β -Hydroxylase to Enhance Cholangiocarcinoma Resistance to Chemotherapy by Modulating DNA Damage Response Signaling Pathways

Katsuya Nagaoka¹, Chiung-Kuei Huang², Yasuhito Tanaka¹

¹Department of Gastroenterology and Hepatology, Graduate School of Medicine, Kumamoto University, Kumamoto, Japan, ²Department of Pathology and laboratory medicine, Tulane University, New Orleans, LA, USA

Background and Aim: The prognosis for intrahepatic cholangiocarcinoma (CCA) is very poor and treatment options for unresectable CCA are limited. Aspartate beta-hydroxylase (ASPH) is highly expressed in CCA and promotes tumor growth with 2-oxoglutarate (2-OG) as a cofactor. In this study, we investigated the role of 2-OG and ASPH in chemotherapy resistance and the efficacy of combination therapy with ASPH inhibitors and chemotherapeutic agents.

Methods: Using shRNA-based ASPH-Knockdown or ASPH small molecule inhibitors (SMI) to inhibit ASPH function in CCA, cell proliferation, colony formation, and senescence assays were performed. 2-OG-dependent ASPH enzyme activity, DNA damage, and DNA damage response signals such as ATM and ATR were examined by Western blotting (WB). Rat synergic and mouse xenograft CCA models were adopted to evaluate the impact of 2-OG/ASPH on chemotherapy. The relationship between serum 2-OG levels and chemotherapy efficacy by RECIST was examined in patients with unresectable intrahepatic CCA.

Results: The combination of DNA synthesis inhibition by the chemotherapeutic agent doxorubicin (Dox) and ASPH targeting by shRNA or SMI cooperatively inhibited cell proliferation and cancer cell senescence. Furthermore, CCA patients classified as progressive disease after receiving systemic chemotherapy showed significantly higher serum 2-OG levels than those defined as Stable disease or partial response. The reductive effect of ASPH on DNA damage response signaling was reversed by ATM and ATR inhibitors. Targeting ASPH improved the therapeutic potential of chemotherapy in vivo in two preclinical CCA models.

Conclusion: Targeting ASPH may enhance chemotherapy-induced DNA damage response, improving chemotherapy in CCA patients.

Mechanism of Gemcitabine-induced Suppression of Human Cholangiocellular Carcinoma Cell Growth

Yuka Toyota, Hisakazu Iwama, Joji Tani, Koji Fujita, Tomoko Tadokoro, Asahiro Morishita, Hideki Kamada, Tsutomu Masaki
Department of Gastroenterology and Neurology, Kagawa University, Kagawa, Japan

Although gemcitabine (2',2'-difluorocytidine monohydrochloride) is a common anticancer agent of cholangiocellular carcinoma (CCC), its growth inhibitory effects and gemcitabine resistance in CCC cells are poorly understood. Our aims were to uncover the mechanism underlying the antitumor effect of gemcitabine and to analyze the mechanism regulating *in vitro* CCC cell gemcitabine resistance. In addition, we sought to identify miRNAs associated with the antitumor effects of gemcitabine in CCCs. We examined the ability of gemcitabine to inhibit cell proliferation in three types of human CCC cell lines (HuCCT-1, Huh28, TKKK). We also investigated the effects of gemcitabine on cell cycle-related molecules in CCC cells. In addition, we assessed gemcitabine-mediated changes in angiogenic molecules and activated tyrosine kinase receptors in CCC cells. We used miRNA array chips to comprehensively analyze gemcitabine-induced miRNAs and examined clusters of differentially expressed miRNAs in cells with and without gemcitabine treatment. Gemcitabine inhibited cell proliferation in a dose- and time-dependent manner in HuCCT-1 cells, whereas cell proliferation was unchanged in Huh28 and TKKK cells. Gemcitabine inhibited cell cycle progression in HuCCT-1 cells from G0/G1 to S phase, resulting in G1 cell cycle arrest due to the reduction of cyclin D1 expression. In addition, gemcitabine upregulated the angiogenic molecules IL-6, IL-8, ENA-78 and MCP-1. In TKKK cells, by contrast, gemcitabine did not arrest the cell cycle or modify angiogenic molecules. Furthermore, in gemcitabine-sensitive HuCCT-1 cells, gemcitabine markedly altered miRNA expression. The miRNAs and angiogenic molecules altered by gemcitabine contribute to the inhibition of tumor growth *in vitro*.

Inhibition of the YAP and FOXM-1/AURKA Axis by Verteporfin Induces Cell Cycle Arrest and Apoptosis in Human Cholangiocarcinoma Cells

Ryohei Tarumoto, Takaaki Sugihara, Takuya Kihara, Yukako Matsuki, Tsutomu Kanda, Tomoaki Takata, Takakazu Nagahara, Hajme Isomoto
Department of Gastroenterology and Nephrology, Faculty of Medicine, Tottori University

Background: Cholangiocarcinoma (CCA) is a biliary tract malignancy with increasing incidence and minimal treatment options. Yes-associated protein (YAP) expression is a poor prognostic marker in intrahepatic cholangiocarcinoma. Verteporfin (VP), a light-sensitive substance clinically applied as a treatment for age-related maculopathy, has been shown to act as a light-independent YAP inhibitor. In this study, we examined the therapeutic effect of VP on the human CCA cell line.

Methods: HuCCT-1 was selected as a representative human CCA cell line expressing YAP. VP efficacy on cell viability was evaluated by MTS assay. YAP downstream effectors were evaluated by qRT-PCR and immunoblotting. The cell cycle was measured using a flow cytometer. RNA interference was used for evaluating gene interrelationships. Xenograft model transplanted HuCCT-1 was used for in vivo experiments. Ki67 and TUNEL staining was performed to evaluate cell division and apoptosis. All experiments were performed under light-shielded conditions.

Results: The IC₅₀ of VP was 18 μ M for 48hrs. qRT-PCR and immunoblot analysis showed decreased expression of YAP, FOXM-1, AURKA, CTGF, and Survivin by 20 μ M of VP for 48hrs. Cell cycle analysis revealed G₀/G₁ arrest by VP. YAP and AURKA expression was not affected by each other. In the Xenograft model, tumor growth was predominantly suppressed in the VP group. Cell division was significantly reduced, and apoptosis was significantly increased in VP-treated tumors.

Conclusion: VP inhibited CCA growth and induced apoptosis by suppressing YAP and its downstream effectors. Concurrently, VP suppressed the mitotic kinases AURKA via FOXM-1 and arrested cell division.

Preoperative Risk Factors for Intrahepatic Cholangiocarcinoma after Curative Resection

Yasuhisa Ando, Kensuke Kumamoto, Hiroyuki Matsukawa, Hironobu Suto, Minoru Oshima, Keiichi Okano

Departments of Gastroenterological Surgery, Kagawa, University, Kagawa, Japan

Background: Some inflammatory factors and tumor markers have reportedly been associated with the risk of postoperative recurrence in various cancer types. However, the association between these factors and postoperative recurrence in intrahepatic cholangiocarcinoma (ICC) has not been adequately investigated due to the limited number of cases.

Methods: Therefore, in this study, 16 patients with ICC who underwent surgical resection at Kagawa University Hospital from 2008 to 2021 served as study subjects. Subsequently, risk factors for postoperative recurrence were analyzed based on preoperative clinical factors. Then, while a modified Glasgow prognostic score (mGPS) of > 1 was defined as high mGPS, the cutoff value for continuous variables was defined as the median value. Furthermore, statistical analyses were conducted using the Cox proportional hazards model, comprising univariate methods.

Results: The median age of the study subjects was 63 years (range: 53–81). Additionally, according to the Union for International Cancer Control staging, we observed that four patients had stage I, seven had stage II, three had stage III, two had stage IV. Moreover, while five patients had high mGPS and 11 had low mGPS, their median carcinoembryonic antigen was 3.75 (1.6–56.2) ng/mL, median CA19–9 was 31.5 (6–25825) U/mL, and median SUVmax was 8.4 (0–13.8). Furthermore, univariate analysis showed significantly high mGPS and CA19–9 results that accounted for postoperative recurrence.

Conclusion: As preoperative factors for ICC, this study also established mGPS and CA19–9 as risk factors for postoperative recurrence, suggesting their use as preoperative adjuvant therapy indicators.

Evaluating the Role of Hepatobiliary Phase of EOB-MRI in Predicting Treatment Impact of Atezolizumab Plus Bevacizumab on Unresectable Hepatocellular Carcinoma

Ryu Sasaki, Masanori Fukushima, Satoshi Miuma, Hisamitsu Miyaaki, Kazuhiko Nakao
Department of Gastroenterology and Hepatology, Nagasaki University Graduate School of Biomedical Sciences

Background: Atezolizumab plus bevacizumab therapy has high response rates in patients with unresectable hepatocellular carcinoma (HCC). Hepatobiliary phase of gadoxetic acid-enhanced magnetic resonance imaging (EOB-MRI) has been reported to be useful as an imaging biomarker for detecting β -catenin mutations. We evaluated whether the pretreatment hepatobiliary phase of EOB-MRI could predict the therapeutic effect of lenvatinib and atezolizumab plus bevacizumab.

Methods: This study included 68 patients (lenvatinib group [n = 33] and atezolizumab plus bevacizumab group [n = 35]). Visual assessment and relative enhancement ratio (RER) of the largest HCC lesions were evaluated using the hepatobiliary phase of EOB-MRI.

Results: The hyperintensity type (RER \geq 0.9) was 18.2% in the lenvatinib group and 20.0% in the atezolizumab plus bevacizumab group. In the lenvatinib group, progression-free survival (PFS) was not different between the heterogeneous and homogenous types (p = 0.688) or between the hyperintensity and hypointensity types (p = 0.757). In the atezolizumab plus bevacizumab group, the heterogeneous type had significantly shorter PFS than the homogenous type (p = 0.007), and the hyperintensity type had significantly shorter PFS than the hypointensity type (p = 0.012).

Conclusions: Hepatobiliary phase of EOB-MRI was useful for predicting the therapeutic effect of atezolizumab plus bevacizumab therapy on unresectable HCC.

Predictive Usefulness of PET-CT for Recurrence and Overall Survival of Hepatocellular Carcinoma Patients

Fujimasa Tada¹, Atsushi Hiraoka¹, Hideko Ohama¹, Kanako Kato¹, Yoshiko Fukunishi¹, Emi Yanagihara¹, Masaya Kato¹, Hirofumi Izumoto¹, Hidetaro Ueki¹, Takeaki Yoshino¹, Shogo Kitahata¹, Chie Kawamura¹, Taira Kuroda¹, Yoshifumi Suga¹, Hideki Miyata¹, Tomoyuki Ninomiya¹, Yoichi Hiasa²

¹Gastroenterology Center, Ehime Prefectural Central Hospital, Ehime, Japan, ²Department of Gastroenterology and Metabology, Ehime University Graduate School of Medicine, Ehime, Japan

Background/Aim: Uptake of fluorodeoxyglucose in PET-CT has been reported to be an independent predictor of recurrence after surgical resection for hepatocellular carcinoma (HCC). We aimed to evaluate the predictive ability of preoperative PET-CT for recurrence and survival after resection.

Methods: From 2005 to 2021, 278 patients with naïve HCC who treated with surgical resection as an initial treatment and underwent preoperative PET-CT were enrolled. The ratios between maximum standardized uptake values (SUVmax) of the tumor and the healthy liver (RSUV) 2.0 was defined as a cut-off value for significant elevation of uptake (elevation-RSUV). Correlation between elevation-RSUV and clinical features were analyzed, retrospectively.

Results: The median time-to-recurrence beyond the Milan criteria (mTTRMC-out) of the patients within the Milan criteria (MC) was significantly longer than that of the other (44.6 vs. 17.8 months, $P<0.05$). The mTTRMC-out of the patients without elevation-RSUV (<2.0) was significantly longer than that of the other (43.4 vs. 21.8 months, $P<0.05$). In patients within MC, patients with elevation-RSUV showed higher the 2yrs-recurrence beyond MC rate (25.7%) compared to that of the other (16.9%). As a results, overall survival of the former showed better than that of the other (123.0 vs. 82.5 months, $P<0.05$). On the other hand, there were no significant differences in mTTRMC after curative resection between patients with and without elevation-RSUV not only in within and but also beyond MC patients.

Conclusion: For patients show elevation-RSUV, considering liver transplantation are needed, if possible. In addition, development of effective adjuvant therapies to prevent recurrence.

Albumin Platelet Product as A Novel Score for Liver Fibrosis Stage and Prognosis

Koji Fujita¹, Kazumi Yamasaki², Kyoko Oura¹, Tomoko Tadokoro¹, Joji Tani¹, Asahiro Tadokoro¹, Masafumi Ono¹, Takashi Himoto³, Hiroshi Yatsuhashi², Tsutomu Masaki¹

¹Kagawa University, ²National Hospital Organization Nagasaki Medical Center, ³Kagawa Prefectural University of Health Sciences

Background and aims: Approximately one million deaths annually attributes to cirrhosis, the most progressed status of liver fibrosis. Noninvasive strategies to estimate liver fibrosis stage have already been replacing liver biopsy examination. Purpose of the current study is to formulate and evaluate novel indexes combining two items of peripheral blood examination.

Methods: Japanese patients with HCV or HBV infection, primary biliary cholangitis and autoimmune hepatitis who underwent liver biopsy examinations were enrolled in the study. Correlation of items in complete blood count and liver function test to fibrosis stage was evaluated.

Results: A total of 426 patients including 252 of HCV infected ones were enrolled in the study. Albumin and platelet most strongly correlated to fibrosis stage among blood examination. Albumin platelet product; $\text{Albumin} \times \text{platelet} / 1000$ differentiated fibrosis stage 4 from stage 3 and stage 3 from stage 2 ($p < 0.05$). A cut-off value = 6.395 differentiated advanced fibrosis and stratified hepatocellular carcinoma (HCC)-free survival in the total cohort and HCV-specific cohort. A cut-off value = 4.349 diagnosed cirrhosis and significantly predicted HCC-free survival and overall survival in both cohorts. Multivariate analysis revealed that smaller Albumin platelet product independently contributed to HCC prevalence and overall mortality.

Conclusions: Albumin platelet product is a simple and novel index of liver fibrosis staging in Japanese population. Physician can calculate the product by an electronic calculator or pen calculation in office. The product serve a physician in managing patients with chronic liver disease.

Follistatin is A Useful Biomarker Predicting the Effect of Lenvatinib for the Treatment of Hepatocellular Carcinoma with Extrahepatic Spread

Takuya Adachi¹, Kazuhiro Nouse², Atsushi Oyama¹, Nozomu Wada¹, Yasuto Takeuchi¹, Hideki Onishi¹, Hidenori Shiraha¹, Akinobu Takaki¹

¹Department of Gastroenterology and Hepatology, Okayama University Graduate School of Medicine, Dentistry and Pharmaceutical Sciences, Okayama, Japan, ²Okayama City Hospital

Background: Follistatin (FST) is a pro-angiogenic cytokine and plays an important role in tumor growth and metastasis. The aim of this study is to examine the usefulness of FST as the prognostic biomarker in patients with metastatic HCC treated with lenvatinib.

Methods: We enrolled 60 advanced HCC patients in prospective cohort study, and measured serum FST in 30 HCC patients with extrahepatic spread who were treated with lenvatinib before and at 2 weeks after starting, and evaluated the effects of FST on progression free survival (PFS) and overall survival (OS). We defined FST ratio as the expression at 2 weeks after starting lenvatinib divided by the expression before therapy.

Results: PFS was short with HCV antibody positive, high ALBI-Score, high α -fetoprotein (AFP, >100mAU/mL), and high FST ratio (>0.90). Multivariate analysis with these factors revealed that HCV antibody positive (HR3.30, p=0.030), high ALBI-Score (HR3.92, P=0.0044), high AFP (HR4.22, p=0.010), and high FST ratio (HR4.23, P=0.010) were the independent risk factors for PFS. OS was short with high ALBI-Score, large tumor number (>5), large tumor size (>30mm), high AFP (>100mAU/mL), high FST, and FST ratio (>0.90). Multivariate analysis with these factors revealed that high ALBI-Score (HR3.97, P=0.0034), high AFP (HR16.54, p=0.0078), high FST (HR8.69, P=0.010), and high FST ratio (HR4.74, P=0.036) were the independent risk factors for OS.

Conclusions: FST might be a key marker for predicting the prognosis of HCC patients with extrahepatic spread treated with lenvatinib.

Epiregulin is A Mediator for Lipopolysaccharide-induced Hepatocarcinogenesis via the Promotion of Tumor Neovascularization

Takahiro Kubo, Norihisa Nishimura, Kousuke Kaji, Hitoshi Yoshiji

Department of Gastroenterology of Nara Medical University

Background: Lipopolysaccharides (LPS) has been reported to promote the development of hepatocellular carcinoma (HCC) through the activation of hepatic stellate cells (HSCs). However, the mediators playing a role on LPS-induced hepatocarcinogenesis still remain unclear. We hypothesized that epiregulin (EREG) derived from activated HSCs could be a potential mediator for HCC development accelerated by LPS.

Methods: To investigate the hypothesis, we cultured and co-cultured human HCC cell line (Huh7) and HSCs (LX-2) to identify the effects of EREG on interactions between both of cell lines. Next, we studied the role of EREG on the progression of HCC using xenograft mice model of Huh7 cells mixed with LX-2 cells with/without intraperitoneally LPS injection.

Results: In vitro studies indicated that LPS induced highly production of EREG from LX-2 cells. Stimulation with recombinant EREG protein promoted cell proliferation and migration/invasion activity of Huh7 cells. EREG also increased IL-8 production from Huh7 cells. Huh7 cells in coculture with LX-2 cells showed the similar pattern as that seen in those stimulated by EREG. In xenografted mice model, LPS administration significantly enlarged the size of xenografted tumors and elevated EREG expression in tumors compared to negative controls. In mice with LPS injection, IL-8 expression in tumors was also significantly higher than in those without LPS, and vascularization was increased.

Conclusion: Our data suggested that EREG plays an important role on LPS-induced hepatocarcinogenesis via the acceleration of cancer cell growth and tumor neovascularization via IL8 production.

A High Expression of SHROOM4 was Associated with a Favorable Prognosis in HCC Patients

Hirayuki Enomoto, Takashi Nishimura, Nobuhiro Aizawa, Tomoyuki Takashima, Naoto Ikeda, Yukihiisa Yuri, Mamiko Okamoto, Kohei Yoshihara, Ryota Yoshioka, Shoki Kawata, Shogo Ota, Ryota Nakano, Hideyuki Shiomi, Hiroko Iijima

Division of Hepatobiliary and Pancreatic Disease, Department of Internal Medicine, Hyogo Medical University

Background: We have identified hepatoma-derived growth factor (HDGF), which participates in the progression of hepatocellular carcinoma (HCC). Recently, we determined two HDGF-associated microRNAs (miR-6072 and miR-3137) that were related to the prognosis of HCC patients. We further searched for the target genes of these HDGF-related microRNAs.

Methods: Using the microarray method, we determined the mRNAs that increased (>1.5-fold) or decreased (<0.67-fold) after the administration of HDGF in two hepatoma-derived cell lines (HepG2 and SK-Hep1). Using an open-access databank, we determined the genes that were predicted to be the target genes of both miR-6072 and miR-3137. Finally, we determined a gene that was associated with the prognosis of HCC patients.

Results: Among a total of 1132 genes which were found to be candidate target genes of the two HDGF-related microRNAs, we determined 7 mRNAs that were changed commonly after stimulation with HDGF in the 2 hepatoma-derived cell lines. Using a cancer genomics database with 350 HCC patients, we found that a high expression of the Shroom Family Member 4 (SHROOM4) gene was significantly associated with a favorable prognosis and a better survival ($p=0.003$, 0.0006 and 0.0006 for the 1-, 3- and 5-year survival, respectively).

Conclusion: SHROOM4 was induced by HDGF stimulation; however, a high expression of SHROOM4 was associated with a good prognosis in HCC patients. This is the first report suggesting a negative feedback response to HDGF-stimulated cellular proliferation. In addition, this study is the first regarding the possible association of SHROOM4 with the prognosis of HCC.

A Novel Serum Biomarker, Clusterin could be an Early Predictor of Response to Sorafenib in Patients with Advanced Hepatocellular Carcinoma

Satoshi Narahara, Takehisa Watanabe, Kentaro Tanaka, Hiroki Inada, Takayuki Tokunaga, Yoko Yoshimaru, Katsuya Nagaoka, Hiroko Setoyama, Masakuni Tateyama, Yasuhito Tanaka
Department of Gastroenterology and Hepatology, Graduate School of Medical Sciences, Kumamoto University, Kumamoto, Japan

Background: A growing number of therapeutic agents have been approved for advanced hepatocellular carcinoma (aHCC). This study was aimed to identify serum biomarkers and establish a formula for predicting SFN treatment response.

Methods: 126 patients who received SFN therapy from June 2008 to April 2019 have been enrolled in this study. Treatment response was evaluated at 3 months of SFN initiation by modified RECIST, and patients with progressive disease were classified into Non-Responder (NR), and the others into Responder (R). Proteome analysis was employed using 5 paired serum samples (pre-treatment, 1 month after treatment initiation) from the R and NR groups, followed by confirmation using ELISA with 18 paired samples as a derivation cohort. Then we performed multivariate analysis using assessed proteins and additional clinical parameters.

Results: The change in the concentration of clusterin (sCLU), VCAM1, and AFP were significantly associated with SFN response. NR-index which comprises these proteins was evaluated as a tool for accurately predicting the efficacy of SFN. A derivation cohort revealed that a higher NR-index was significantly associated with shorter PFS (HR=1.990, $p<0.001$) and OS (HR=1.694, $p=0.004$). The same was true for the validation cohort. We also established SFN-resistant HepG2 cells (HepG2-SR) and found that sCLU significantly increased in HepG2-SR following SFN treatment at protein levels and immunofluorescence staining, and phosphorylated mTOR was also upregulated at the protein level. CLU was decreased treated with mTOR inhibitor.

Conclusion: The sCLU-related NR-index are promising clinical tools for the early prediction of SFN resistance in HCC.

Low-fat Skeletal Muscle Mass is a Prognostic Factor in Patients with Hepatocellular Carcinoma who Receive Systemic Therapy

Yoji Ishizu¹, Masatoshi Ishigami¹, Humitaka Mizuno¹, Noritaka Matsuda¹, Takahumi Yamamoto¹, Yosuke Inukai¹, Naoki Yoshioka¹, Kazuyuki Mizuno¹, Hisanori Muto¹, Shinya Yokoyama¹, Takanori Ito¹, Norihiro Imai¹, Takashi Honda¹, Tetsuya Ishikawa², Hiroki Kawashima¹

¹Department of Gastroenterology and Hepatology, Nagoya University Graduate School of Medicine, Japan, ²School of Health Science, Nagoya University Graduate School of Medicine, Japan

Background: Fat deposition in skeletal muscle impairs skeletal muscle function. Therefore, skeletal muscle mass with low fat deposition is an adequate indicator of skeletal muscle mass that reflects skeletal muscle function. However, its prognostic impact in patients with HCC is unknown. This study aimed to clarify the prognostic impact of low-fat skeletal muscle mass in patients with HCC receiving systemic therapy.

Method: One hundred and ninety-nine patients who received systemic therapy for HCC at our hospital from 8/2017-2/2022 were enrolled. Low-fat skeletal muscle mass was assessed using the skeletal muscle area at the L3 level on CT images with CT attenuation of +30 to +150 HU, and skeletal muscle index (SMI) was calculated as the total skeletal muscle area (cm²) divided by the square of the height (m²). The cut-off values for decreased SMI were 25.2 cm²/m² for male and 24.8 cm²/m² for female based on the previous study. Predictors of overall survival was identified using Cox regression models.

Results: Forty-eight percent of patients had decreased low-fat SMI. Patients with decreased low-fat SMI was significantly low survival rate than those without (P = 0.039). Multivariable Cox proportional hazards model showed that, in addition to high ALBI grade and impaired performance status, the presence of decreased low-fat SMI were significant factors associated with poor overall survival (HR 2.18, 95% CI [1.18-4.04], P = 0.013).

Conclusion: Low-fat fat SMI is useful for predicting prognosis in patients with hepatocellular carcinoma who received systemic therapy.

Potential of Ultra-highly Sensitive Immunoassays for HBsAg and Core-related Antigens in Patients with or without Development of Hepatocellular Carcinoma after HBsAg Seroclearance

Fumitaka Suzuki¹, Tetsuya Hosaka¹, Yoshiyuki Suzuki¹, Shunichiro Fujiyama¹,
Yusuke Kawamura¹, Hitomi Sezaki¹, Norio Akuta¹, Satoshi Saitoh¹, Yasuji Arase¹, Kenji Ikeda¹,
Mariko Kobayashi², Hiromitsu Kumada¹

¹Department of Hepatology, Toranomon Hospital, Japan, ²Research Institute for Hepatology,
Toranomon Hospital, Japan

Aims: Hepatitis B surface antigen (HBsAg) seroclearance indicates a functional cure in chronic hepatitis B virus (HBV) infection (CHB). However, several cases of hepatocellular carcinoma (HCC) development have been reported after HBsAg seroclearance. We evaluated the potential of HBsAg and hepatitis B core-related antigen (HBcrAg), measured by the ultra-highly sensitive assays, in cases with HCC development after HBsAg seroclearance.

Methods: We enrolled 17 patients with CHB who achieved HBsAg seroclearance, defined by the conventional assay using Architect HBsAg QT kit (5 HCC patients and 12 non-HCC patients). HBsAg and HBcrAg were measured in their stored serum samples using ultra-highly sensitive assays featuring immunoassay for total antigen including complex via pretreatment (iTACT) technology.

Results: All 5 patients who developed HCC were positive for HBsAg or HBcrAg by iTACT-HBsAg or iTACT-HBcrAg at all follow-up points. HBcrAg levels in the HCC group, using iTACT-HBcrAg, were significantly higher than those in the non-HCC group at HBsAg seroclearance (3.6 LogU/mL (2.8-4.2) vs. 2.6 (<2.1-3.8), $p=0.020$). The best cutoff value of iTACT-HBcrAg for predicting HCC development was 2.7 LogU/mL by receiver operating characteristic curve analysis. The prevalence of HBcrAg >2.7 in the HCC group was significantly higher than that in non-HCC group (100% (5/5) vs. 33% (4/12), $p=0.029$).

Conclusions: Residual low viral antigen might predict HCC development even if HBsAg seroclearance was achieved according to a conventional assay. The results suggest that iTACT assays of HBsAg and HBcrAg would be useful for monitoring CHB patients.

Diagnostic Value of Fibro Scan in Patients with Hepatocellular Carcinoma

Zeng Xianghua

Department of Medical Oncology, Chongqing University Cancer Hospital

Aim: This study was to investigate the diagnostic value by using Liver stiffness measurement (LSM) measured by FibroScan in patients with hepatocellular carcinoma (HCC).

Methods: There were 48 patients with HCC who underwent LSM using FibroScan (Each patient was detected in 5 different sites.) between June 2021 and February 2022 were enrolled in this research. LSM failure defined as zero valid shots (unsuccessful LSM), or the ratio of the interquartile range to the median of 10 measurements (IQR/M) greater than 0.30 plus success rate (SR) less than 60% (unreliable LSM).

Results: The mean age of the patients (42 men, 6 women) was 53.3 years, with a mean body mass index of 22.8. A total of 240 measurements were done and 141 valid values were obtained with failure rates of 41.3%. Among them, there were 19 patients (19.2%) with unsuccessful LSM, 37 patients (37.4%) with SR less than 60%, 59 (59.6%) with IQR/M over 30%. In all the five measurements of each patient, 5 reliable results were got in 10 cases, 4 in 15 cases, 3 in 8 cases, 2 in 7 cases, 1 in 6 cases, and 0 in 2 cases, respectively. LSM values of all the HCC patients were 27.7 (14.1-75.0) kPa.

Conclusion: LSM are often accompanied by a high rate of failure in HCC patients. Nodules in HCC patients lead to the inhomogeneity of liver parenchyma, and thus results of IQR/M rise. FibroScan through multipoint measurement are helpful to screen or identify HCC.

The Combination of Skeletal Muscle Mass and Intramuscular Adipose Tissue Predicts Prognosis in Patients with Hepatocellular Carcinoma

Masatsugu Ohara, Goki Suda, Sonoe Yoshida, Takashi Sasaki, Risako Koya, Shuichi Hosoda, Yoshimasa Tokuchi, Masato Nakai, Takuya Sho, Koji Ogawa, Naoya Sakamoto
Department of Gastroenterology and Hepatology, Hokkaido University Graduate School of Medicine. Japan

Background: The existence of sarcopenia results in poor prognosis in patients with hepatocellular carcinoma (HCC). However, the impact of the combination of skeletal muscle mass and intramuscular adipose tissue content (IMAC) on the prognosis of HCC is unclear.

Method: In this retrospective study, we enrolled 186 patients with HCC whom skeletal muscle mass and IMAC could be evaluated by computer tomography between July 2015 and December 2020 in our hospital. IMAC was used to evaluate the quality of skeletal muscle by analysing CT at the level of umbilicus. Psoas muscle mass index (PMI) was measured using CT at the level of the third lumbar vertebra. We examined the prognosis by dividing the patients into four groups: normal PMI and low PMI, and normal IMAC and high IMAC.

Result: The patients with low PMI and normal IMAC had poor prognosis among four groups ($p < 0.01$). Comparing of the characteristics between patients with low PMI and normal IMAC, and those with low PMI and high IMAC, it was revealed that body mass index ($p < 0.05$) and body fat ratio ($p < 0.05$) were significantly lower in patients with low PMI and normal IMAC.

Conclusion: Low PMI and normal IMAC may be a poor prognostic factor in patients with HCC.

Serum Zinc Levels are Associated not Only with Serum Albumin Levels but Also with Hemoglobin Levels, and Zinc Supplementation Improves Serum Albumin and Hemoglobin Levels

Seigo Abiru^{1,2}, Yuki Kugiyama², Tomoyuki Suehiro², Yasuhide Motoyoshi², Akira Saeki², Shinya Nagaoka², Kazumi Yamasaki², Atsumasa Komori², Hiroshi Yatsuhashi²

¹National Hospital Organization Saga Hospital, ²National Hospital Organization Nagasaki Medical Center

Background and Aim: Zinc deficiency occurs in various diseases including chronic liver disease. We examined the involvement of zinc in clinical laboratory tests and the effects of zinc supplementation on them.

Methods: (Study 1) We analyzed 2254 data from 634 patients without zinc supplementation with chronic liver disease from September 2009 to August 2021. We used multiple linear regression analysis to examine the association between serum zinc level and patients age, sex, laboratory tests. (Study 2) We analyzed changes in albumin, hemoglobin (Hb), and PT% from 3 months before drug administration to 6 months after administration in patients who used polaprezinc, or branched-chain amino acid (BCAA) for 90 days or longer. Patients who received both drugs at the same time were excluded.

Results: (Study 1) In the multiple linear regression analysis, serum albumin, Hb, PT% were strongly correlated with serum zinc levels. (Study 2) Changes in serum albumin levels were analyzed in patients with albumin levels <3.5 g / dl at the start of administration. Similarly, changes in Hb levels were analyzed in patients <11 g / l, and changes in PT% were analyzed in patients <80%. Both polaprezinc and BCAA significantly improved albumin, Hb, and PT% at 3 and/or 6 months after the start of administration.

Conclusion: Serum zinc levels are associated not only with serum albumin levels but also with Hb levels and PT% levels, and zinc supplementation improves them.

Artificial Intelligence Based on Serum Biomarkers Predicts the Efficacy of Lenvatinib for Unresectable Hepatocellular Carcinoma

Po-Yao Hsu¹, Po-Cheng Liang¹, Ming-Ying Lu¹, Yu-Ju Wei^{1,2}, Tyng-Yuan Jang¹, Ming-Lun Yeh¹, Ching-I Huang¹, Yi-Hung Lin¹, Chih-Wen Wang¹, Ming-Yen Hsieh^{1,2}, Nai-Jen Hou^{1,2}, Meng-Hsuan Hsieh¹, Zu-Yau Lin¹, Shinn-Cherng Chen^{1,2}, Chung-Feng Huang¹, Jee-Fu Huang¹, Wan-Long Chuang¹, Chia-Yen Dai¹, Ming-Lung Yu¹

¹Hepatobiliary Division, Department of Internal Medicine, Kaohsiung Medical University Hospital, Kaohsiung Medical University, Kaohsiung, Taiwan. ²Department of Internal Medicine, Kaohsiung Municipal Ta-Tung Hospital, Kaohsiung Medical University, Kaohsiung, Taiwan

Background: Lenvatinib has been effective as the first line systemic therapy for unresectable hepatocellular carcinoma (uHCC). We aimed to investigate the impact of serum biomarkers on the treatment outcomes of patients with uHCC treated with lenvatinib in a real-world setting using an artificial intelligence algorithm.

Methods: Serum biomarkers, including alpha-fetoprotein (AFP), albumin-bilirubin (ALBI) grade, and circulating angiogenic factors (CAFs [i.e., vascular endothelial growth factor, angiopoietin-2, fibroblast growth factor-19 [FGF19], and FGF21]), were measured. Treatment outcomes, including objective response rate (ORR), progression-free survival (PFS), and overall survival (OS), were analyzed in patients with uHCC treated with lenvatinib.

Results: Of 82 patients with uHCC (median 68.5 years; 68.3% male; 82.9% first-line systemic therapy), the median OS and PFS were 12.8 months and 5.3 months, respectively. Of 74 patients with assessable tumor responses, the ORR was 24.3%. An AFP reduction >40% from baseline within 8 weeks after lenvatinib induction was associated with a higher ORR. With baseline biomarkers using a decision tree-based model, we identified patients with high, intermediate, and low ORRs (84.6%, 21.7% and 0%, respectively; odds ratio, 53.04, $p < 0.001$, high versus intermediate/low groups). Based on the decision tree-based survival predictive model, baseline AFP was the most important factor for OS, followed by ALBI grade and FGF21.

Conclusions: Baseline CAFs and early AFP decline were associated with tumor response rates, while the baseline levels of FGF21, AFP, and ALBI grade were factors predictive of OS with lenvatinib by decision tree-based models.

Glycine Prevents Steatohepatitis-related Carcinogenesis in Hepatocyte-Specific Phosphatase and Tensin Homolog-deficient Mice

Kazuyoshi Kon, Kumiko Arai, Akira Uchiyama, Hiroo Fukada, Toshifumi Sato, Maki Morinaga, Kyoko Fukuhara, Reiko Yaginuma, Shunhei Yamashina, Kenichi Ikejima
Department of Gastroenterology, Juntendo University School of Medicine

Background: The prevalence of NASH-related hepatocellular carcinoma (HCC) is increasing worldwide, so there is an urgent need to elucidate the preventive method for NASH-related HCC. Here we investigated the effect of the amino acid glycine on NASH-related HCC using hepatocyte-specific phosphatase and tensin homolog (PTEN)-deficient mice.

Methods: Male Alb-Cre TG (+) PTEN^{flox/flox} mice aged 11-17 weeks were fed a normal diet or a diet containing 5% glycine for 2 or 24 weeks. Wild-type or TG (-) mice fed a normal diet were used as control. Oxidative stress was evaluated by immunohistochemical staining for 4-hydroxynonenal (HNE). Total glutathione level was measured using enzymatic method. The number of liver tumors with a diameter of 2 mm or more was counted. The expression of mRNA in liver tissue was measured by RT-PCR.

Results: PTEN^{flox/flox} mice developed severe steatohepatitis after 2 weeks, and serum ALT levels significantly increased to 163 ± 30 IU/L compared to 41 ± 4 IU/L in control, whereas the glycine-containing diet clearly improved steatohepatitis and significantly reduced serum ALT levels to 23 ± 10 IU/L. The expression of 4HNE was enhanced in the liver of PTEN^{flox/flox} as compared with control, and was suppressed by glycine administration. Total glutathione in the liver tissue of PTEN^{flox/flox} mice was significantly decreased compared to control, which was significantly increased by glycine. After 24 weeks, the liver of PTEN^{flox/flox} developed tumors of 2.6 ± 1.0 , whereas glycine-containing diet completely suppressed tumor formation to 0 ± 0 .

Conclusion: Glycine markedly improved steatohepatitis and inhibited hepatic tumorigenesis in hepatocyte-specific PTEN knockout mice.

The Effect of Elobixibat on Tumorigenesis in the NASH Mice Model

Kenta Yamamoto, Yoshiaki Sugiyama, Takashi Honda, Asuka Kato, Hisanori Muto, Shinya Yokoyama, Takanori Ito, Norihiro Imai, Yoji Ishizu, Masatoshi Ishigami, Hiroki Kawashima
Department of Gastroenterology and Hepatology, Nagoya University Graduate School of Medicine

Background: Nonalcoholic steatohepatitis (NASH) and carcinogenesis have been reported to be associated not only with lipid metabolism but also with bile acids and the microbiome. Ileal bile acid transporter inhibitors are potentially changing the microbiome and bile acids. We evaluated the effect of Elobixibat on tumorigenesis in the NASH mice model.

Methods: Three-week-old male C57BL/6J mice were randomly divided into the following two groups: (1: Control group) choline-deficient high-fat (CDHF) with diethylnitrosamine. (2: Elobixibat group) CDHF with diethylnitrosamine and Elobixibat. All Mice received a one-time intraperitoneal injection of 25 mg/kg diethylnitrosamine. From 8 to 28 weeks old, Control group mice were fed a CDHF diet and Elobixibat group mice were fed a CDHF diet mixed with Elobixibat. Bile acid in the liver tissue and fecal microbiome were analyzed.

Results: Elobixibat reduced the number and size of tumors. The median (min-max) number of tumors on the liver surface was 7.5 (2-14) in the Elobixibat group compared to 18.5 (9-25) in the control group ($p=0.013$). The number of relatively large tumors (over 2 mm) was significantly lower in the Elobixibat group with 4.5 (1-6) compared to 0.5 (0-2) in the control group ($p=0.015$). However, body weight change, serum lipid concentrations, fatty and fibrosis area were not significantly different. About 94.6% of the fecal microbiomes in the Elobixibat group were gram-negative bacteria. Primary bile acids in liver tissue in the Elobixibat group were lower than in the control group.

Conclusion: Elobixibat reduces the incidence of liver tumors by sterilizing gram-positive bacteria in feces.

Combined Bioinformatics on the Tumor Promoting Inter-Cellular Network in Obesity-associated Liver Tumor Microenvironment

Yoshiki Nonaka¹, Ryota Yamagishi², Yi Cheng², Naoko Ohtani²

¹The Department of Pathophysiology, Osaka City University Graduate School of Medicine, ²The Department of Pathophysiology, Osaka Metropolitan University Graduate School of Medicine

The number of obesity-induced hepatocellular carcinomas (HCC) patients has recently been increasing due to the expansion in the obese population worldwide. However, the detailed mechanisms of obesity-induced HCC development have remained unclear, and the elucidation of the mechanism and the identification of the appropriate therapeutic targets are urgently needed. We previously found that the obesity-increased gut bacterial metabolite, deoxycholic acid (DCA), continuously acts on hepatic stellate cells (HSCs) through enterohepatic circulation, thereby inducing cellular senescence and SASP (senescence-associated secretory phenotype), a phenotype that senescent cells produce various secreted factors, in HSCs. Moreover, we found that lipoteichoic acid (LTA), a Gram-positive gut microbial component, acts on HSCs to increase the production of PGE2 that suppresses the anti-tumor immunity, resulting in the HCC progression by creating a tumor-promoting microenvironment. However, the detailed whole landscape of the tumor-promoting microenvironment where a variety of cells are acting on their specific target cells via their secreted factors, has not been clarified yet. In this study, using the single-cell RNA-sequencing data of various cell types isolated from non-tumor and tumor areas in obesity-induced hepatocellular carcinoma in mice, we analyzed the cell fate by pseudotime analysis using Monocle 3, and the cell-cell interactions by interactome analysis using NicheNet in HCC tumors. These analyses confirmed the ligation of PD-L1 to PD-1 on CD8-positive T cells secreting the suppressive cytokine IL-10, suggesting that anti-tumor immunity was strongly suppressed within obesity-induced HCC tumors. We will present further analysis of the inter-cellular networks in HCC tumors in this conference.

Regular Exercise Suppresses Obesity Associated Liver Cancer through Activating Pgc-1 α - Kynurenine Degrading Pathway

Vu Thuong Huyen¹, Ryota Yamagishi², Naoko Ohtani²

¹Department of Pathophysiology, Osaka City University Graduate School of Medicine, ²Department of Pathophysiology, Osaka Metropolitan University Graduate School of Medicine

Background: Recently, the number of patients with non-alcoholic steatohepatitis-associated hepatocellular carcinoma (NASH-associated HCC) has been increasing steadily. Exercise has been recognized a role in prevention and treatment of cancers but the underlying molecular mechanism remains unclear. Kynurenine is overproduced in various types of cancer cells and is recognized as an onco-metabolite that acts as a ligand for transcription factor AhR, suppressing antitumor immunity, promoting cancer progression. Exercise can upregulate Pgc-1 α , a transcriptional coactivator, in the muscles that regulates genes involved in energy metabolism. One of the Pgc-1 α target genes, Kynurenine aminotransferases (KATs) can transfer Kynurenine into Kynurenic acid.

Methods: High fat diet -induced HCC mice were divided into exercise or non-exercise group. In the exercise group, the mice had regular treadmill running 1 hour a day, 5 days per week for 8 weeks (27w-35w old), the tumor number and size were checked. Immune cells from liver were isolated and analyzed by flowcytometry. The expression of genes encoding enzymes on the Tryptophan-kynurenine metabolizing pathway in muscles and liver tissues were investigated by quantitative-PCR.

Results: KAT3 gene expression was significantly increased in the muscles, coinciding with the significant reduction of tumor number and size in the exercise group with no difference in body weight. A series of immune cells for anti- tumor immunity, such as NK, NKT and CD8 T cells, expanded in the livers of the exercise group.

Conclusions: Skeletal muscle-derived KATs induced by exercise may act on liver through the systemic circulation, degrading kynurenine to activate anti-tumor immunity.

An Attempt to Establish a Murine Model for Non-alcoholic Fatty Liver Disease-related Hepatocarcinoma Using Diabetic Mice

Masato Nakamura¹, Takafumi Sakuma¹, Tetsuhiro Chiba¹, Terunao Iwanaga¹, Ryuta Kojima¹, Junjie Ao¹, Yaojia Ma¹, Hiroaki Kanzaki¹, Keisuke Koroki¹, Kazufumi Kobayashi¹, Ryo Nakagawa¹, Naoya Kanogawa¹, Soichiro Kiyono¹, Takayuki Kondo¹, Sadahisa Ogasawara¹, Shingo Nakamoto¹, Ryosuke Muroyama², Jun Kato¹, Takashi Kishimoto³, Naoya Kato¹

¹Department of Gastroenterology, Chiba University, Graduate School of Medicine, Chiba, Japan,

²Department of Molecular Virology, Chiba University, Graduate School of Medicine, Chiba, Japan,

³Department of Molecular Pathology, Chiba University, Graduate School of Medicine, Chiba, Japan

Background: Insulin resistance has been suggested to promote hepatocarcinogenesis in non-alcoholic fatty liver disease (NAFLD). We attempted to establish a murine model for NAFLD-related hepatocarcinoma (HCC) using diabetic mice.

Methods: Male KK-Ay/TaJcl mice, a model of type 2 diabetes, were fed a NAFLD diet (containing high fat, high cholesterol, high fructose, and cholic acid) or a control diet and were evaluated for the development of NAFLD. These mice were kept for up to 38 weeks and examined for the development of liver tumors.

Results: The mice fed a NAFLD diet showed a prominent body weight gain and significant hepatic steatosis. HOMA-IR, an indicator of insulin resistance, remained high. At 4 weeks, histological examination confirmed fatty deposits and infiltration of inflammatory cell in the liver. At 12 weeks, the mice fed a NAFLD diet showed liver fibrosis. At 37-38 weeks, liver nodules were observed in 2 of 7 mice in the control group and 3 of 6 mice in the NAFLD group. Only one nodule in the NAFLD group was a neoplastic lesion.

Conclusion: KK-Ay mice fed a NAFLD diet developed steatohepatitis and liver fibrosis. However, the incidence of liver tumors was low, suggesting that further investigation was needed as a model for HCC.

Prevention of Skeletal Muscle Atrophy in Cirrhotic Rats by Combination Therapy with Rifaximin and L-Carnitine

Koji Murata, Kosuke Kaji, Masahide Enomoto, Soichi Takeda, Yuki Fujimoto, Tadashi Namisaki, Takemi Akahane, Hitoshi Yoshiji

Department of Gastroenterology, Nara Medical University, Kashihara, Nara, Japan

The gut–liver–muscle axis is associated with the development of sarcopenia in liver cirrhosis. This study aimed to illustrate the combined effect of rifaximin and L-carnitine on skeletal muscle atrophy in cirrhotic rats with steatohepatitis. A total of 344 Fischer rats were fed a choline-deficient L-amino acid-defined (CDAA) diet with daily oral administration of rifaximin (100 mg/kg) and/ or L-carnitine (200 mg/kg) and measurements of psoas muscle mass index and forelimb grip strength. After feeding for 12 weeks, blood, liver, ileum, and gastrocnemius muscle tissues were harvested. The effects of L-carnitine on rat myocytes were assessed by in vitro assays. Treatment with rifaximin attenuated hyperammonemia and liver fibrosis in CDAA-fed rats. Moreover, it improved intestinal permeability with restoration of tight junction proteins and suppressed the lipopolysaccharide-mediated hepatic macrophage activation and proinflammatory response. Consequently, rifaximin prevented skeletal muscle mass atrophy and weakness by decreasing intramuscular myostatin and proinflammatory cytokine levels. Moreover, rifaximin cooperatively potentiated the L-carnitine-mediated improvement of skeletal muscle wasting by promoting the production of insulin-like growth factor-1 and mitochondrial biogenesis, resulting in inhibition of the ubiquitin-proteasome system (UPS). The in vitro assays showed that L-carnitine directly attenuated the impairment of mitochondrial biogenesis, thereby, inhibiting the UPS in rat myocytes that were stimulated by lipopolysaccharide or tumor necrosis factor- α . The combination of rifaximin with L-carnitine may provide a clinical benefit for liver cirrhosis-related sarcopenia.

Real World Efficacy and Safety of Pemafibrate in Patients with Metabolic Dysfunction-associated Fatty Liver Disease

Shuji Matsumura^{1,2}, Koichi Takaguchi^{1,3}, Nobuyuki Baba⁴, Akemi Tsutsui³, Tomonori Senoo³, Takuya Nagano³

¹Department of General Practice, Kagawa Prefectural Central Hospital, Kagawa, Japan,

²Department of Internal Medicine, Kagawa Prefectural Shirotori Hospital, Kagawa, Japan,

³Department of Hepatology, Kagawa Prefectural Central Hospital, Kagawa, Japan, ⁴Department of Central laboratory, Kagawa Prefectural Central Hospital, Kagawa, Japan

Background: Metabolic dysfunction-fatty liver disease (MAFLD) is the emerging cause of liver cirrhosis, subsequently hepatocellular carcinoma. Pemafibrate, the selective peroxisome proliferator-activated receptor (PPAR) α modulator, is one of the promising pharmaceutical candidates for the treatment of MAFLD. This retrospective, single-arm study investigated the efficacy and safety of pemafibrate in MAFLD patients with hypertriglyceridemia.

Methods: A total of 46 MAFLD patients who received pemafibrate (oral, 0.1 mg, twice a day) at Kagawa Prefectural Central Hospital between September 2018 and December 2020 were included. All patients were diagnosed with fatty liver disease by ultrasonography and underwent fibroscan studies. The fasting triglyceride (TG) levels were 290.8 ± 265.5 (mean \pm standard deviation (SD)) mg/dl.

Results: The median age was 56 (24 - 80) years old, and 28 patients (61 %) were men. The ALT values at 6 months were significantly lower than that at baseline (ALT: 56.9 ± 39.5 U/L vs. 83.0 ± 48.8 U/L, $p < 0.001$, respectively).

Fasting TG levels were significantly lower at 6 months than at baseline (TG: 128.8 ± 71.5 mg/dl vs. 290.8 ± 265.5 mg/dl, $p < 0.01$, respectively). Regarding patients with liver stiffness over 7.6 kPa at baseline, FAST score and FIB-4 index were significantly improved at six months compared with baseline (FAST score: 0.53 ± 0.22 vs. 0.69 ± 0.21 , $p < 0.05$, FIB-4 index: 2.60 ± 1.01 vs. 3.17 ± 1.28 , $p < 0.01$, respectively). Treatment-related adverse events were not observed.

Conclusions: Pemafibrate treatment may be safe and effective for MAFLD patients with hypertriglycemia

HbA1c, 5.8% or Higher, is Most Useful Indicator for Recommendation of Ultrasonography to Detect NAFLD

Miwa Tatsuta¹, Masafumi Ono², Shungo Kimura¹, Akemi Tomida¹, Mitsuyoshi Kobayashi¹, Joji Tani³, Asahiro Morishita³, Tsuyoshi Maeta⁴, Tsutomu Masaki³

¹Department of Gastroenterology, KKR Takamatsu Hospital, Kagawa, Japan, ²Department of Innovative medicine for Hepatobiliary and Pancreatology, Kagawa University School of Medicine, Kagawa, Japan, ³Department of Gastroenterology and Neurology, Kagawa University School of Medicine, Kagawa, Japan, ⁴Department of Internal medicine, KKR Takamatsu Hospital, Kagawa, Japan

Background: With the recent control of viral hepatitis, the ratio of non-viral liver cancers has increased over time. The purpose of this study was to examine the association between each factor of the metabolic syndrome and NAFLD and to identify the factors that are most strongly associated with NAFLD.

Methods: We studied 6538 participants, who received a health checkup since 2017 to 2018. Participants with an intake more than 20g of alcohol per day or with other chronic liver diseases were excluded. Fatty liver was detected by ultrasonography.

Results: A total of 4310 participants were enrolled, 28.4% of participants had fatty liver. The prevalence of NAFLD was highest in the diabetes mellitus alone group among diseases of the metabolic syndrome. Only in the diabetes mellitus alone group, prevalence of NAFLD was higher than in the non-fatty liver. The prevalence of NAFLD was more than 70% in the combination of dyslipidemia and diabetes mellitus groups. Multivariate analysis showed gender (M/F) (OR 3.93, 95% CI 2.10-7.37) and HbA1c (OR 2.25, 95% CI 1.69-3.01) were considered to be the most strongly associated independent factor for NAFLD. The cutoff value for HbA1c by ROC analysis was 5.8 (sensitivity 57.9%, specificity 72.6%, AUC 0.70).

Conclusions: NAFLD was strongly associated with diabetes mellitus among the metabolic syndromes. HbA1c is most strong factor associated with NAFLD. We strongly recommend abdominal ultrasonography for NAFLD detection in patients with HbA1c 5.8% or higher in general practice and health checkup. This makes it possible to detect NAFLD.

Short-Term Effects of Nalmefene as Needed Use in Alcoholism with or without Cirrhosis in the Northern Part of Tokyo, Japan

Tatsuo Kanda, Shinji Shibuya, Shuhei Arima, Masayuki Honda, Tomotaka Ishii, Reina Sasaki-Tanaka, Shini Kanezawa, Ryota Masuzaki, Naoki Matsumoto, Hirofumi Kogure, Masahiro Ogawa
Division of Gastroenterology and Hepatology, Department of Medicine, Nihon University School of Medicine

Aim: Number of patients with alcoholic liver disease seems to be increasing in Japan. Alcoholism could be treated as needed use by 10 mg nalmefene, opioid system modulator licensed in Japan for the reduction of alcohol consumption. We investigated the short-term effects and adverse events of nalmefene as needed use in alcohol-dependent out-patients with or without cirrhosis in the northern part of Tokyo, Japan.

Patients and Methods: We retrospectively examined total 9 patients (2 alcoholic fatty liver disease and 7 alcoholic cirrhosis; mean age: 55.3 ± 8.4 years; and male/female: 8/1), whom we followed-up at least for one month. All of them received 10 mg nalmefene as needed use. The medical record, laboratory data and imaging data were retrospectively analyzed. Statistical analysis was performed by the Student's t-test or chi-squared test. P-value < 0.05 was considered a statistically significant difference.

Results: Five (55.6%) of 9 patients could continue the treatment. The reason of discontinuation of nalmefene follows as: 2 patients hope; 1 headache; and one systemic urticaria. Of interest, all 9 patients could reduce alcohol consumption, but γ -GT levels of 5 patients did not improve at one month after the commencement of nalmefene. In 3 patients, ascites disappeared.

Conclusion: Nalmefene as needed use may be useful for the reduction of alcohol consumption in certain alcoholism with or without cirrhosis. Further study is required.

Evaluation of the Iliopsoas Muscle Using SYNAPSE 3D

Takushi Manabe¹, Chikara Ogawa¹, Mitsushige Shibatoge¹, Tsutomu Masaki²

¹TAKAMATSU Red Cross Hospital, ²Department Of Gastroenterology & Neurology, Kagawa University, Kagawa, Japan

In recent years, the clinical importance of sarcopenia in patients with liver disease has been recognized. In addition, there are many reports on the diagnosis of sarcopenia. The guidelines for sarcopenia in Japan use the mass of the iliopsoas muscle at the third lumbar vertebra (L3) for measurement. In this study, we evaluated the correlation between the automatically calculated total iliopsoas muscle mass and iliopsoas muscle area at the L3 level and the measurement of area by a simple method using the 3D image volume analysis system SYNAPSE 3D, as well as the reproducibility of the test results and the measurement time by different measurers. The subjects were 14 patients who were hospitalized for liver disease and underwent computed tomography (CT) of the plain from the abdomen to the pelvis. SYNAPSE 3D application "3D Fat Analysis" was used to determine the difference between the psoas muscle area (PMRAC) by automatic calculation and the psoas muscle volume (PMVAC) by automatic calculation performed by skilled and novice technicians. We evaluated the differences in psoas muscle volume (PMVAC) and the time required for each measurement, as well as the correlation between psoas muscle area, PMRAC, and PMVAC using the simplified method. The PMRAC and PMVAC at the L3 level were approximately 13.4 cm² and 13.2 cm², 300.6 cm³ and 301.4 cm³, respectively. The correlation coefficients (R²) were 0.8951 and 0.9987, respectively, indicating a very strong correlation; the time to calculate PMRAC and PMVAC at the L3 level was 96.4 and 94.3 seconds, respectively, with no difference.

Influence of Alcohol Consumption and Gender in Detecting Fatty Liver Using Fatty Liver Index (FLI)

Takako Nomura^{1,2}, Masafumi Ono^{1,3}, Kiyoyuki Kobayashi^{1,3}, Yuzuru Akaiwa¹, Tomohiro Oogi¹, Maki Oogi¹, Kayo Ishikawa¹, Tsutomu Masaki²

¹Department of Gastroenterology and Hepatology, HITO Medical Center, Ehime, Japan,

²Department of Gastroenterology and Neurology, Faculty of Medicine, Kagawa University,

Kagawa, Japan, ³Division of Innovative Medicine for Hepatobiliary and Pancreatology, Faculty of Medicine, Kagawa University, Kagawa, Japan

Background: Fatty liver index (FLI) is recommended as a non-invasive biomarker to detect fatty liver. In this study, we investigated the prediction of fatty liver by FLI, focusing on alcohol consumption and gender differences.

Methods: This study was designed as a single-center, observational cohort study in Japan. All of the subjects who received annual health check-ups evaluated by ultrasonography at HITO Medical Center in Japan from April 2020 to March 2021 were enrolled in this registry (n = 2,038). Fatty liver was diagnosed by abdominal ultrasonography, and the subjects were classified into none and light drinkers (0-19g/day), moderate drinkers (20-59g/day), and heavy drinkers (>60g/day) according to their drinking habits obtained from the questionnaire. The predictive power of fatty liver by FLI was evaluated using the area under receiver operating characteristic curve (AUROC) and 95% confidence interval (CI) by alcohol consumption and by sex.

Results: The AUC (95% CI) of FLI was 0.840 (0.823-0.857) overall, 0.822 (0.801-0.844) for men, 0.864 (0.834-0.895) for women, 0.851 (0.823-0.879) for men who were none and light drinkers, 0.8107 (0.778-0.843) for men who were moderate drinkers, 0.730 (0.6-0.861) for men who were heavy drinkers, 0.856 (0.822-0.889) for women who were none and light drinkers, 0.917 (0.845-0.988) for women who were moderate drinkers, and 0.833 (0.371-1) for women who were heavy drinkers.

Conclusion: FLI was a simple and useful indicator in predicting fatty liver if we noted that the AUC of FLI was reduced for men who were heavy drinkers.

Prediction of Liver Fibrosis and Carcinogenesis by Body Comparison Analysis by Bioelectrical Impedance Analysis

Hirohito Yoneyama¹, Toshiaki Nakatsu², Naohito Uchida², Yuuko Bandou², Asahiro Morishita¹, Joji Tani¹, Koji Fujita¹, Takako Nomura¹, Takashi Himoto¹, Tsutomu Masaki¹

¹Department of Gastroenterology and Neurology, Faculty of Medicine, Kagawa University, Kagawa, Japan, ²Sakaide Saint Martin's Hospital

Background: Body mass index (BMI) is a measure of obesity, and is greatly involved in the onset of impaired glucose tolerance (IGT) and NAFLD. However, in clinical practice, there are so-called "hidden obesity type" which has high body fat percentage even though BMI is normal, and cases with low muscle mass and liver disorder even if the body fat percentage is normal. Therefore, it is considered important to measure body composition in medical treatment of NAFLD. The present study aims to investigate the relationship between parameters obtained by body composition measurement and the progression of liver fibrosis in NAFLD.

Methods: We measured the body composition such as body fat percentage, muscle mass per body weight (muscle percentage), BMI, etc. of NAFLD patients by the bioelectrical impedance analysis (BIA). Fib-4 index was also measured in all cases and correlations with various parameters obtained by BIA were examined.

Results: BMI, body fat percentage, and muscle mass had no significant correlation with Fib-4 Index on their own. However, classifying the body type into nine groups with a combination of the degree of body fat and muscle percentage (high, medium, low) shows that Fib-4 indexes in the groups with high-fat/medium-muscle and high-fat/high-muscle were significantly higher than that of the standard group (medium-fat/medium-muscle). Particularly in the high-fat/high-muscle group, the Fib-4 index tended to increase markedly with age.

Conclusions: Body composition measurements and body type determination by BIA method are considered to be useful for predicting the progress of liver fibrosis and carcinogenesis in NAFLD patients.

Automated Fibrosis Phenotyping of Liver Tissue from Non-tumor Lesions of Patients with and without Hepatocellular Carcinoma after Liver Transplantation for Non-alcoholic Fatty Liver Disease

Hisamitsu Miyaaki, Yasuhiko Nakao, Masanori Fukushima, Ryu Sasaki, Satoshi Miuma, Kazuhiko Nakao

Department of Gastroenterology and Hepatology, Nagasaki University Hospital

Background: Fibrosis is the most important pathological feature in predicting development of Hepatocellular carcinoma (HCC). However, the incidence rate of HCC in patients with non-alcoholic fatty liver disease (NAFLD) is relatively low. We evaluated phenotypic histological features to differentiate HCC from non-HCC in patients with non-tumor lesions of cirrhotic livers.

Methods: Seventeen patients with NAFLD who underwent liver transplantation were enrolled. FibroNest was used to quantify histological phenotypes of non-tumor fibrosis lesions. Quantification included collagen content and structure traits, fiber morphometric traits, and fibrosis architecture traits. Each trait was described by up to seven quantitative fibrosis traits (qFTs). Among the qFTs measured in each specimen, those that described most of the variability between consecutive groups were automatically detected and combined into a normalized Phenotypic Composite Fibrosis Score (Ph-CFS). We trained FibroNest to identify the principal traits that differentiate HCC from non-HCC.

Results: HCC was found in 8 cases and non-HCC in 9 cases. The Ph-CFS significantly differentiated HCC from non-HCC (4.6 vs. 5.9, $p < 0.05$). Individual qFTs for morphometric features including collagen fiber length, width, perimeter, and area denoted significant differences between HCC and non-HCC. The Ph-CFS could be used to distinguish HCC (Ph-FCS < 5.0) from non-HCC (Ph-FCS > 5.0) with 75% sensitivity and 100% specificity.

Conclusion: In patients who underwent liver transplantation, fibrotic histological phenotypes in non-tumor lesions appeared to be different between HCC and non-HCC. Phenotypic analysis of collagen in non-tumor lesions might be an effective and automated method to distinguish HCC from non-HCC on histopathology imaging.

Atezolizumab Plus Bevacizumab-induced Evans Syndrome in Advanced Hepatocellular Carcinoma: A Case Report

Masanori Fukushima, Kazuaki Tajima, Ryu Sasaki, Satoshi Miuma, Hisamitsu Miyaaki, Kazuhiko Nakao

Department of Gastroenterology and Hepatology, Nagasaki University Graduate School of Biomedical Sciences, Nagasaki, Japan

Introduction: The first-line systemic therapy for advanced hepatocellular carcinoma (HCC) has changed from tyrosine kinase inhibitor to atezolizumab plus bevacizumab treatment. Accordingly, the occurrence of immune-related adverse event (irAE) is a major concern in clinical practice. We report a case of irAE-induced Evans syndrome.

Case Presentation: An 86-year-old man was presented with recurrence of HCC on the dissected surface and diaphragm after central bisectionectomy. Therefore, the administration of atezolizumab plus bevacizumab treatment was initiated. After the third course of atezolizumab plus bevacizumab treatment, petechial purpura appeared on the extremities and trunk. The patient's laboratory examinations revealed isolated severe thrombocytopenia without evidence of combined coagulopathy. The patient was diagnosed with immune thrombocytopenic purpura (ITP), and high-dose immunoglobulin therapy and Helicobacter pylori eradication therapy were performed and thrombocytopenia improved. However, 2 weeks after the onset of ITP, laboratory data revealed hemolytic anemia with hemoglobin level of 4.5 g/dL, total bilirubin level of 4.3 mg/dL and lactate dehydrogenase level of 622 IU/L. Both direct and indirect Coombs tests were positive, and the patient was diagnosed with Evans syndrome complicated by ITP and autoimmune hemolytic anemia (AIHA) induced by irAE. After treatment with prednisolone, the hemoglobin level increased and hemolytic findings on blood tests improved.

Conclusion: We experienced a case of Evans syndrome that appeared to be an irAE. Evans syndrome is a syndrome in which AIHA and ITP occur either simultaneously or consecutively. Early recognition of this phenomenon during atezolizumab plus bevacizumab treatment leads to appropriate treatment.

A Case of Splenic Infarction Developed After Administration of Atezolizumab and Bevacizumab for Hepatocellular Carcinoma

Fumiya Suzuki, Taketo Nishina, Ken Nogami, Keita Maki, Kyoko Hoshikawa, Tomohiro Katsumi, Hiroaki Haga, Yoshiyuki Ueno
Yamagata University

Background: Splenic infarction is one of the adverse events associated with atezolizumab/bevacizumab combination therapy for hepatocellular carcinoma. It is reported that splenic infarction was admitted in only 1 case (0.3%) out of 329 patients treated with atezolizumab and bevacizumab in a global phase III study (IMbrave150). We report a case of splenic infarction developed the administration of atezolizumab bevacizumab to a patient with hepatocellular carcinoma (HCC).

Case description: A 59-year-old woman with a history of alcoholic liver disease went to our hospital to dissect the liver dysfunction found in medical examination. The multiple HCC, lung metastases and gastric cancer were found in endoscopy, CT scan and MRI. The mucosal finding of endoscopy in gastric cancer was out of the adaptation of an endoscopic therapy for SM invasion. It was decided to administer atezolizumab and bevacizumab combination therapy for HCC and follow up gastric cancer. She had left lateral abdominal pain on fourteen days after first time chemotherapy. The level of D-dimer was high at 4.98 $\mu\text{g}/\text{mL}$ on Laboratory test. The finding on CT scan was the splenic infarction. She was treated with NASIDs and follow up the abdominal pain after hospitalization.

Discussion: It is reported that the relative risk of arterial thrombotic events of bevacizumab administration are twice, them of VEGF inhibitors VEGF inhibitors administration are three times as high as non-therapy. Therefore, we should pay attention to thrombotic events after administration of atezolizumab and bevacizumab for HCC in cases with high risk of thrombosis.

A Case of an Ir-AE (Idiopathic Thrombocytopenic Purpura: ITP) Development During the Treatment of Another Ir-AE (Liver Dysfunction)

Tatsuo Horie¹, Satoshi Honda^{2,3}, Minekazu Yamaguchi^{2,4}, Miyako Horie¹, Tsunetaka Kijima², Kazuko Masumoto⁵, Shingo Yamagata², Kazutaka Kurokohchi⁶

¹Pharmacy, Oda Municipal Hospital, ²Department of General Medicine, Shimane University Faculty of Medicine, Oda General Medicine Education Center, ³Department of Urology, Oda Municipal Hospital, ⁴Department of Surgery, Oda Municipal Hospital, ⁵Department of Nurse, Oda Municipal Hospital, ⁶Department of General Medicine, Meiwa Hospital

Background: Now, Immunotherapy is effective in many cancers, but many ir-AEs should be noted.

Case: In November 2020, a 68-year-old man had developed IVC invasion, multiple lung metastases, para-aortic LN metastases (cT3bN1M1, MSKCC favorable) from right advanced renal cell carcinoma (clear cell ca.). Pembrolizumab-Axitinib combination therapy was administered and Completed 3 courses. In late January 2021 (day1), AST212U/L, ALT363U/L (G3) were recognized. After sharing information with the attending physician and the chemo team, and ir-AE was suspected, and introduced to the Department of Gastroenterology. Day2, liver biopsy. Day4, after a joint conference, PSL 50mg, ST mixture started. Day11 and Day17, PSL was gradually decreased. Lower limb muscle weakness, lower leg edema, and steroid myopathy were observed. Day18, AST49U/L, ALT145 U/L, introduced to the Department of Dermatology, small erythema (trunk>limbs) with pruritus with no tendency to heal was observed throughout the body. Also, PLT49000/&mu, but DIC was negated. Day21, PLT 15000/&mu, AST58U/L, ALT227U/L. (2) Referral, ITP suspected (ir-AE), PSL 60 mg (1mg/kg) was started, and ST mixture drug was stopped at side effect suspected. Day22-24, mPSL (1000mg) pulse was started. Day23, ir-AE was reaffirmed by the Oncology hematologist. Day24, AST49U/L, ALT242U/L, PLT83000/ &mu. Inspection value improvement tendency. Day25, PSL 80mg, and Pentamidine Isetionate 300mg inhalation started. Day45, PSL was gradually decreased, to 75mg. Day46, discharge.

Conclusions: It is always necessary to keep in mind that other ir-AEs may develop during the treatment of an ir-AE, and it is necessary to share information and treat ir-AEs in a multifaceted manner in many departments.

Two Cases That Suspected Immune Check-point Inhibitor-Associated Liver Dysfunction

Yuko Kuwae, Ikue Noura, Yuto Kaimi, Kaori Sakamoto, Sayaka Tanaka, Masahiko Ohsawa
Department of Pathology, Osaka Metropolitan University Graduate School of Medicine

Background: Hepatic dysfunction due to the treatment of metastatic cancer with immune checkpoint inhibitors (ICI) is a rare condition, but the opportunity to encounter them increases. We experienced two cases of liver dysfunction, which were suspected ICI-associated clinically.

Methods:

Case 1 was a 51-year-old female with malignant melanoma of the posterior neck region, treated with Ipilimumab and Nivolumab combination therapy. She developed Grade 3 hepatic dysfunction two weeks after the first dose of Ipilimumab and Nivolumab.

Case 2 was a 73-year-old male with lung adenocarcinoma (cT4N2M1b, Stage IVA), treated with Nivolumab for regrowth of metastatic region after chemo-radiation therapy. He had discontinued it due to exacerbation of irradiation pneumonitis but developed liver dysfunction about five months after the first dose of Nivolumab administration.

Results: The biopsy specimen of Case 1 showed panlobular hepatitis with microgranulomas, which was consistent with hepatitis associated ICIs. With prednisolone administration, her therapy was continued. She died of cancer. Case 2, however, showed interface hepatitis and severe inflammation with some eosinophils in the portal area rather than lobular hepatitis. He had taken some supplements. Drug other than ICI -induced hepatitis was suspected, and his therapy was continued.

Conclusions: Liver dysfunction due to ICIs is rare. Although some characteristic pathological findings have been reported, it is sometimes difficult to differentiate from other causes, such as drug-induced liver injuries. For the correct diagnosis, consideration of the patients' clinical course and medication history is essential.

Two Cases of Huge Hepatocellular Carcinoma Successfully Treated by Conversion Hepatectomy After Systemic Chemotherapy

Hiroaki Naruse¹, Ai Furusawa¹, Takuya Kaburaki¹, Nozomi Furuichi¹, Atsushi Naganuma¹, Takashi Hoshino¹, Yuhei Suzuki¹, Keitaro Hirai², Ichiro Sakamoto², Tetsushi Ogawa², Takeshi Hatanaka³, Satoru Kakizaki^{1,4}

¹Department of Gastroenterology, National Hospital Organization Takasaki General Medical Center, Gunma, Japan, ²Department of Surgery, National Hospital Organization Takasaki General Medical Center, Gunma, Japan, ³Department of Gastroenterology, Gunma Saiseikai Maebashi Hospital, Gunma, Japan, ⁴Department of Clinical Research, National Hospital Organization Takasaki General Medical Center, Gunma, Japan

Background: Conversion from unresectable to resectable metastatic gastrointestinal cancer is now feasible, termed "conversion therapy". However, conversion therapy for hepatocellular carcinoma (HCC) has not yet been established.

Case Report:

Case 1; A 33-year-old male patient with right hypochondralgia and liver tumor was referred to our hospital. He had a history of surgery for heart malformation. The tumor at the right lobe was 15 cm in diameter with bloody ascites. Transarterial embolization (TAE) achieved hemostasis of the ruptured HCC. Lenvatinib and rivaroxaban were then initiated for HCC and atrial thrombus, respectively. Lenvatinib treatment resulted in a reduction in tumor marker levels and the tumor size. After improvement of atrial thrombus, we finally performed conversion hepatectomy 10 months after starting lenvatinib administration. The tumor was completely removed, and the patient has been doing well without any signs of recurrence.

Case 2; A 77-year-old male patient with chest pain was admitted. The tumor at the right lobe had grown into a lump with adrenal metastases and was 15 cm in diameter. It had invaded the inferior vena cava. Atezolizumab-bevacizumab treatment resulted in a marked decrease in tumor marker levels and tumor staining. After nine courses of atezolizumab-bevacizumab treatment, we decided to perform conversion hepatectomy. The tumor was completely removed, and pathological analyses showed a complete response to atezolizumab-bevacizumab treatment.

Conclusion: While these are rare cases of successful conversion therapy for advanced HCC cases, it may be a promising strategy for cases of unresectable advanced HCC.

Tezolizumab and Bevacizumab for Unresectable Combined Hepatocellular and Cholangiocarcinoma: A Case Report

Yuki Tamura^{1,2}, Naoto Saito¹, Takeshi Hatanaka¹, Yoshiki Tanaka¹, Teruo Yoshinaga¹, Kenji Kashiwabara³, Norio Kubo⁴, Yasuo Hosouchi⁴, Hiroki Tojima⁵, Satoru Kakizaki^{5,6}, Toshio Uraoka⁵

¹Department of Gastroenterology, Gunma Saiseikai Maebashi Hospital, Maebashi, Japan,

²Department of Gastroenterology, National Hospital Organization Takasaki General Medical

Center, Maebashi, Japan, ³Department of Pathology, Gunma Saiseikai Maebashi Hospital,

⁴Department of Surgery, Gunma Saiseikai Maebashi Hospital, ⁵Department of Gastroenterology and Hepatology, Gunma University Graduate School of Medicine, ⁶Department of Clinical Research, National Hospital Organization Takasaki General Medical Center

An 81-year-old man was referred to our hospital for the treatment of liver cancer. He had chronic liver disease due to significant alcoholic consumption. Enhanced computed tomography (CT) showed a liver tumor with marginal enhancement in the arterial phase at 28 mm in diameter in the right hepatic lobe. He initially underwent right hepatic lobectomy. Hematoxylin-eosin staining showed a trabecular-sinusoidal growth pattern, morphologically consistent with hepatocellular carcinoma (HCC), and glandular formations pattern, supportive of cholangiocarcinoma. Immunohistochemical staining showed that the HCC regions were positive for Hepa-para-1, and the cholangiocarcinoma regions were negative for hep-para-1, positive for CK 19, and positive for CD 56. The patient was therefore pathologically diagnosed with combined hepatocellular and cholangiocarcinoma (CHC). Both the HCC and cholangiocarcinoma regions were negative for PD-L1. The microsatellite instability status was also negative. At 13 months after surgical treatment, multiple lymph node metastases were observed. We started atezolizumab plus bevacizumab (Atez/Bev). Enhanced CT after two cycles of therapy showed mild shrinkage of enlarged lymph nodes and the response rate per RECIST was determined to be stable disease. We achieved a 7.5-month progression-free survival without severe adverse events. The patient was still alive at 28 months after the initial hepatic treatment. Atez/Bev might exhibit therapeutic efficacy for CHC patients. Further investigations with a large number of cases are warranted to investigate the efficacy and safety of Atez/Bev for unresectable CHC.

Sinusoidal Obstruction Syndrome Developed During the Treatment of RA (Case Report)

Nao Sogo¹, Akemi Tsutsui², Tomonori Seno², Takuya Nagano², Koichi Takaguchi²,
Nobuhisa Tajiri³, Sawako Ono⁴, Midori Ando⁴, Satoko Nakamura⁴, Yuya Ishii⁵, Shinsuke Baba⁵

¹Clinical Training Center, Kagawa Prefectural Central Hospital, ²Department of Hepatology,
Kagawa Prefectural Central Hospital, ³Department of Radiology, Kagawa Prefectural Central
Hospital, ⁴Department of Pathology, Kagawa Prefectural Central Hospital, ⁵Clinical Laboratory
Center, Kagawa Prefectural Central Hospital

Hepatic sinusoidal obstruction syndrome (SOS) is often reported as complication after bone marrow transplantation. We report a case of SOS that developed during treatment of rheumatoid arthritis.

62-year-old male had been treated for rheumatoid arthritis by his previous doctor. Abdominal distension began in early May. and gradually worsened. In late May, he visited his previous doctor presenting with right-sided abdominal pain, then a large amount of ascites is detected. He was referred to our department for further examination.

Laboratory blood tests showed coagulation disorder and elevation of hepatic enzymes. Contrast-enhanced CT scan showed no portal vein obstruction, but the hepatic veins were not clearly depicted, and the contrast effect on the liver parenchyma was heterogeneous in the late phase, so we suspected blood flow disorder at the hepatic veins.

Because of abnormal coagulation and massive ascites, an echo-guided liver biopsy was considered difficult, so we performed transvenous liver biopsy. Histopathologically, dilatation of the portal vein and sinusoids was observed, and there were scattered collapsed and desquamated areas in the liver parenchyma, which were not conflict with SOS.

We diagnosed SOS according to the new EBMT criteria, and started to administrate defibrotide. Three days after starting treatment, abdominal distention was alleviated. 18 days after the start of treatment, ascites almost disappeared on CT scan. After 21 days of treatment with defibrotide, The patient followed an uneventful course without developing any complications, discharged from the hospital

Staged Carbon Ion Radiotherapy Might be A Promising Treatment for Ruptured HCC After Hemostasis

Hiroki Tojima¹, Souichiro Shimizu¹, Yuki Kanayama¹, Yuichi Yamazaki¹, Ken Sato¹, Satoru Kakizaki^{1,2}, Yuhei Miyasaka³, Kei Shibuya³, Toshio Uraoka¹

¹Department of Gastroenterology and Hepatology, Gunma University Graduate School of Medicine,

²Department of Radiation Oncology, Gunma University Graduate School of Medicine, ³Department of Clinical Research, National Hospital Organization Takasaki General Medical Center,

⁴Department of Radiation Oncology, Gunma University Graduate School of Medicine

Background: Extrahepatic rupture is a life-threatening complication of hepatocellular carcinoma (HCC). Prognosis of ruptured HCC (rHCC) is expected to be improved by staged resection after hemostasis with transcatheter arterial embolization (TAE). Recently, carbon ion radiotherapy is expected as a new curative therapy for HCC. We report a case of rHCC treated with staged carbon ion radiotherapy following TAE.

Case: A 64-year-old man visited the emergency room with a sudden right hypochondriac region pain. He was in a state of shock and plain CT showed a hemorrhagic ascites and a 30mm low density mass protruding from the liver surface (segment 8). An emergency angiography showed a ruptured hepatic mass. The hepatic mass was strongly contrasted in the 1st phase of CTHA and showed a corona enhancement in the 2nd phase, diagnosed as rHCC, and hemostasis was successfully achieved with TAE. The patient's general condition improved and was discharged on the 11th hospital day. The patient had hepatitis C, chronic heart failure, and severe pancytopenia resulting from myelodysplastic syndromes. Hepatic resection was considered high risk due to multiple complications, and carbon ion radiotherapy was performed two months after discharge from the hospital. This patient has been alive 36 months post-treatment without recurrence. In addition, Hepatitis C virus was successfully eliminated using direct-acting antivirals after carbon ion radiotherapy.

Discussion / Conclusion: Carbon ion radiotherapy can provide good local control and is considered a promising treatment for rHCC in case that surgery is unsuitable due to complications.

Clostridium Perfringens Infection with Gas Forming Liver Abscess After Transarterial Chemoembolization for Hepatocellular Carcinoma

Yoshihito Yoshida¹, Hideaki Takahashi¹, Yosuke Igarashi², Kazunari Nakahara², Natsumi Aoyama², Yosuke Satta², Hideatsu Hashimoto², Yohei Noguchi³, Yasumasa Matsuo⁴, Nobuyuki Matsumoto¹, Chiaki Okuse⁵, Ryuta Shigefuku⁶, Michihiro Suzuki³, Keisuke Tateishi²

¹Department of Internal Medicine Division of Gastroenterology, St. Marianna University School of Medicine, Yokohama City Seibu Hospital, Kanagawa, Japan, ²Department of Internal Medicine Division of Gastroenterology, St. Marianna University School of Medicine, ³Department of Internal Medicine Division of Gastroenterology, Kasawaki Municipal Tama Hospital, ⁴Department of Digestive Disease Center, St. Marianna University School of Medicine Toyoko Hospital, ⁵Department of Internal Medicine Division of General Internal Medicine, Kasawaki Municipal Tama Hospital, ⁶Department of Internal Medicine Department of Gastroenterology and Hepatology, Mie University Graduate School of Medicine

Introduction: Transcatheter arterial chemoembolization (TACE) is a risk factor for liver abscess, however there are only several reports of liver abscess caused by Clostridium after treatment for hepatocellular carcinoma (HCC). We report a case of gas-forming liver abscess caused by Clostridium perfringens after TACE.

Case: A 90 year-old Japanese woman had a medical history of chronic heart failure, atrial fibrillation, combined valvular disease, hypertension and type 2 diabetes mellitus. She admitted to our hospital for colonic diverticular hemorrhage. CT on admission detected, by chance, gallstone in the common bile duct and HCC in the segment eight of the liver and liver cirrhosis suspected of associating with nonalcoholic steatohepatitis. After endoscopic treatment for diverticular hemorrhage and gallstone in the common bile duct, we performed TACE to treat HCC. On the fourth day after TACE, she had a high fever with chill, and followed by persistent pain and rapid worsening of her general status next day. Abdominal CT revealed not only favorable lipiodol accumulation but also gas gangrene and rupture in the tumor. In spite of emergency medical care, those severe status eventually led to her death on the same day. Later, because Clostridium perfringens was detected in blood culture, we diagnosed sepsis due to Clostridium perfringens infection after TACE.

Conclusion: Gas-forming liver abscess due to Clostridium perfringens after TACE are not only extremely rare but also have a high mortality rate. Therefore, prompt diagnosis and treatment is required in order to prevent fatal outcome.

Immune Checkpoint Inhibitor-related Pneumonia in Unresectable Hepatocellular Carcinoma: Two Fatal Cases Under Atezolizumab Plus Bevacizumab

Kei Endo, Hidekatsu Kuroda, Tamami Abe, Keisuke Kakisaka, Akio Miyasaka,
Takayoshi Oikawa, Matsumoto Matsumoto
Iwate Medical University School of Medicine

Immune checkpoint inhibitor (ICI)-related pneumonia is rare but potentially life-threatening immune-related adverse event (irAE). We herein report two fatal cases involving patients treated with atezolizumab plus bevacizumab for HCC. In both patients, ICI-related pneumonia was provisionally the cause of death.

Case 1 was an 85-year-old woman with hepatitis B, who developed HCC 6 years previously. After 5 transcatheter arterial chemoembolization (TACE) treatments and systemic chemotherapy with sorafenib and ramucirumab, she was treated with atezolizumab (1200 mg) and bevacizumab (15 mg/kg) every 3 weeks because of multiple intrahepatic recurrences. She was admitted to our hospital on day 18 because of ICI-related pneumonia. She did not respond to steroid treatment and died on the 29th day after the start of ICI treatment.

Case 2 was an 88-year-old woman who developed HCC associated with type C cirrhosis. She underwent 2 radiofrequency ablation treatments, and 2 TACE treatments. The patient was treated with atezolizumab (1200 mg) plus bevacizumab (15 mg/kg) every 3 weeks, because abdominal CT showed multiple intrahepatic and extrahepatic recurrences. After 11 courses of treatment, partial response was confirmed by abdominal CT, but the patient developed ICI-related pneumonia. She did not respond to steroid treatment and died on the 6th day of hospitalization.

Case 1 had preceding interstitial pneumonia and Case 2 had a history of lung cancer surgery. Two cases of ICI-related pneumonia were characterized by a history of lung disease. Our experiences suggest the need for careful monitoring of ICI-related pneumonia in HCC patients, particularly those with pre-existing lung disease.

Conversion Surgery for Hepatocellular Carcinoma After the Anti-PD-L1 Antibody Therapy: Report of A Case

Hiroto Kayashima^{1,2}, Shinji Itoh¹, Yuki Nakayama¹, Katsuya Toshida¹, Yuriko Tsutsui¹, Takahiro Tomiyama¹, Akinari Morinaga¹, Yukiko Kosai¹, Takahiro Tomino¹, Takashi Kurihara¹, Shohei Yoshiya¹, Yoshihiro Nagao¹, Kazutoyo Morita¹, Yosuke Kuroda², Noboru Harada¹, Yo-ichi Yamashita², Tomoharu Yoshizumi¹

¹Department of Surgery and Science, Graduate School of Medical Sciences, Kyushu University, Fukuoka, Japan, ²Department of Surgery, Iizuka Hospital, Iizuka, Japan

Background: Conversion surgery for hepatocellular carcinoma (HCC) has been limited due to the poor response to preoperative treatment. Recently, immune checkpoint inhibitors (ICI) are expected to be used for conversion surgery because of the higher response rate.

Case Presentation: A 71-year-old man with chronic hepatitis B virus infection was diagnosed with bilobar multiple HCCs. His liver function was Child-Pugh A (6) and the ICG 15-min retention test (ICG-r15) was over 50%. He was administrated anti-PD-L1 antibody. Six months after the initiation, secondary hypoadrenocorticism by ICI was recognized and steroid therapy was started. Ten months post-treatment, although HCCs in the right lobe still be remained, HCC in the left lobe could not be detected. His liver function improved to Child-Pugh A (5) and ICG-r15 was improved to 16%. The remnant liver volume of the left lobe accounted for 48% of the total liver volume, therefore, radical right lobectomy was performed using perioperative steroid cover. The operating time was 219 min and the intraoperative blood loss was 165mL, and he was discharged on the 16th postoperative day with no complication. However, he recognized hypoadrenocorticism on the 26th postoperative day and a higher dose of steroid was needed temporarily.

Conclusion: Conversion surgery for HCC after the anti-PD-L1 antibody therapy could be performed safely. The patients with secondary hypoadrenocorticism by ICI might be required careful observation using high-dose and long-term steroid cover.

Combined Hepatocellular-Cholangiocarcinoma Patients for Whom Drug Therapy with Lenvatinib was Effective: A Case Report

Takahiro Osuga, Koji Miyanishi, Junji kato

Department of Medical Oncology, Sapporo Medical University School of Medicine, Sapporo, Hokkaido, Japan

A man in his 70s was referred to our hospital because of a liver tumor. Blood biochemical tests showed elevated levels of AFP, PIVKA-II and CA19-9. EOB-MRI revealed a 95 mm-sized tumor in the liver S7. The tumor showed a heterogeneous hyperintensity in the arterial phase, was slightly washed out from the portal phase, and had a hypointensity in the hepatocellular phase. Post-enlargement segmental resection was performed. The pathological diagnosis was combined hepatocellular-cholangiocarcinoma. Seven months after surgery, multiple liver tumors were found and biopsy revealed combined hepatocellular-cholangiocarcinoma. He started hepatic arterial infusion chemotherapy with cisplatin, but he developed a pulmonary abscess. He recovered from a lung abscess after treatment with antibiotics and received drug therapy with lenvatinib 11 months after surgery. A follow-up after 8 weeks showed a complete response (according to the modified Response Evaluation Criteria in Solid Tumors) and a Partial Response (Response Evaluation Criteria in Solid Tumors version 1.1). To the best of our knowledge, only one case of unresectable combined hepatocellular-cholangiocarcinoma with lenvatinib has been reported so far. In that case, lenvatinib was used as a third-line treatment. This report is the first to describe lenvatinib as a first-line therapy for unresectable combined hepatocellular-cholangiocarcinoma, which resulted in a significant response. This case provides useful information of the choice of appropriate drug treatment in this disease in the absence of randomized controlled trials of drug treatment.

A Case of Primary Hepatic Angiosarcoma Successfully Treated Using Atezolizumab + Bevacizumab

Maho Egusa¹, Yurika Yamauchi¹, Issei Saeki¹, Natsuko Nishiyama¹, Tsuyoshi Fujioka¹, Daiki Kawamoto¹, Tatsuro Nishimura¹, Norikazu Tanabe¹, Takashi Oono¹, Tsuyoshi Ishikawa¹, Takahiro Yamazaki², Taro Takami¹

¹Department of Gastroenterology and Hepatology, Yamaguchi University Graduate School of Medicine, Ube, Japan, ²Department of Oncology and Laboratory Medicine, Yamaguchi University Graduate School of Medicine, Ube, Japan

Case Presentation: A 79-year-old man with chronic hepatitis C developed a hypervascular tumor in the liver five years previously and was diagnosed with hepatocellular carcinoma (HCC). We provided curative treatment with transarterial chemoembolization + radiofrequency ablation. Last year, a hypervascular tumor recurred in segment 6 of the liver with lymph-node metastasis. We diagnosed HCC recurrence and introduced lenvatinib. Because both lesions were controlled for 2 months, partial hepatectomy and lymph-node dissection were performed. The histopathological diagnosis was primary hepatic angiosarcoma (PHA) with lymph-node metastasis. Two months ago, a nodular lesion appeared in the lower lobe of the left lung. We performed thoracoscopic partial lung resection, and the histopathological diagnosis was metastatic HCC. Thereafter, a new hypervascular tumor developed in the left lobe of the liver with enlarged intra-abdominal lymph nodes. We considered prompt intervention appropriate, because of early recurrence after lung resection. Therefore, we introduced atezolizumab + bevacizumab (Atezo/Bev) assuming HCC recurrence. Although the histopathological diagnosis was PHA by a liver tumor biopsy, this tumor and lymph-node metastases surprisingly reduced after two courses of Atezo/Bev.

Conclusion: This is the first report of the effectiveness of Atezo/Bev for PHA. We present this case, with a review of the literature.

A Case of Multiple Metastatic Liposarcoma with A Giant Liver Metastasis Resected in Combination with Multidisciplinary Therapy

Ikuhiro Kita, Yoshihiro Okita, Sena Tsukamoto, Akitsu Murakami, Hiroyuki Okuyama, Akihito Tsuji
Kagawa University Faculty of Medicine

Background: Liposarcoma is the most common soft tissue sarcoma (STS). The basic treatment is surgical resection, with limited evidence for chemotherapy and radiation therapy. Surgical indication of metastasis is unclear and depends on clinician's decision. We report a case of liposarcoma with giant liver metastasis in which long-term survival was achieved by multidisciplinary therapy.

Case: 44-year-old female diagnosed with right femoral myxoid liposarcoma, metastatic to right liver and left adrenal. First, we performed a right pelvic resection while considering subsequent resection of liver metastasis. But it was difficult due to large liver metastasis of approximately 15 cm and poor hepatic reserve, so we performed drug-eluting beads transarterial chemoembolization (doxorubicin: 66 mg/body). While the right liver metastasis stopped growing, another liver metastasis also appeared in lateral segment. We performed systemic chemotherapy (doxorubicin: 75 mg/m²) for 5 cycles, and both lesions were slightly reduced. We confirmed hepatic reserve, and planned extended right hepatectomy and left adrenalectomy after radiofrequency ablation (RFA) for the lateral lesion. Including two other lymph node metastases, all lesions except treated with RFA were removed within 9 months after initial treatment. Subsequently, we resected two metastatic recurrence sites in lower limbs, and no new recurrence has occurred at 24 months from initial treatment.

Conclusion: Myxoid liposarcoma is more sensitive to chemotherapy than other STSs, but not curative. The combination of perioperative chemotherapy and RFA may have contributed to radical resection and long-term survival in this case, suggesting that these are effective treatment options for unresectable liposarcoma.

A Case Report of Oral Cancer Patient with Liver Metastasis Who Obtained Complete Response by Nivolumab Therapy

Sena Tsukamoto, Yoshihiro Okita, Ikuhiro Kita, Akitsu Murakami, Hiroyuki Okuyama, Akihito Tsuji
Department of Clinical Oncology, Kagawa University Faculty of Medicine

Background: It has been reported that it is difficult to obtain the therapeutic effect of immune checkpoint inhibitors (ICIs) on liver metastases, not only in head and neck cancers but also in all carcinomas. On the other hand, there are several reports in non-small cell lung cancer and melanoma that ICI is effective for small liver metastases.

Case: A 59-year-old woman was diagnosed with stage IVA (cT3N2cM0) oral cancer and underwent curative surgery. Pathological diagnosis showed multiple lymph node metastasis and extra nodal extension (pT3N3bM0, stage IVB), so we planned to perform adjuvant chemoradiotherapy (CCRT). She received radiotherapy consisted of 66Gy in 33 daily fractions, combined with 40mg/m² cisplatin weekly. However, only 5 months after CCRT, liver metastasis 20mm in size appeared on computed tomography (CT) scan. We consider it to be platinum-resistant disease, nivolumab was chosen as a palliative chemotherapy. After 3 cycles of nivolumab administration, the liver metastasis had shrunk on CT scan. It could no longer be detected after 8 cycles of nivolumab.

Conclusion: As in this case, ICI was suggested to be effective for liver metastases with low tumor burden.

A Rare Case of Hepatocellular Carcinoma and Cholangiolocellular Carcinoma with Simultaneous Onset of Nonalcoholic Steatohepatitis in the Background and Metachronous Recurrence after Surgery

Masaru Muraoka, Reona Osawa, Yasuyuki Komiyama, Natsuko Nakakuki, Hitomi Takada, Yuichiro Suzuki, Mitsuaki Sato, Shinya Maekawa, Nobuyuki Enomoto
Department of Gastroenterology, University of Yamanashi Hospital. Yamanashi. Japan

The patient, an 82-year-old man with hypertension and diabetes mellitus, was referred to our hospital after CT and MRI revealed liver tumors. A 27 mm tumor on hepatic segment 2 and a 15 mm tumor on hepatic segment 8 were surgically resected. The two tumors developed on nonalcoholic steatohepatitis (NASH) had histologically different features (hepatocellular carcinoma: HCC and cholangiolocellular carcinoma: CoCC). 9 months, 18 months, and 3 years after surgery, the tumor recurred at approximately 10 mm and was treated with radio frequency ablation therapy (RFA), respectively. We determined that the first and second recurrence tumors and the third recurrence tumor were different histological types. The simultaneous occurrence of HCC and CoCC is rare, and the characteristics of the imaging findings at the time of the first and second recurrences will be discussed in detail, along with the literature.

A Case of High-Frequency Microsatellite Instability Intrahepatic Cholangiocarcinoma in Which Pembrolizumab was Remarkably Effective for Early Postoperative Recurrence

Hiroyuki Matsukawa, Yasuhisa Andou, Hironobu Suto, Minoru Oshima, Keiichi OKano
Department of Gastroenterological Surgery, Faculty of Medicine, Kagawa University

Introduction: Chemotherapy for advanced and recurrent biliary tract cancer is limited and difficult to treat. In recent years, there have been some reports of responses to high-frequency microsatellite instability (MSI-high) solid tumors caused by immune checkpoint inhibitors. We report a case in which pembrolizumab was effective for MSI-high biliary tract cancer that recurred early after surgery, with a review of the literature.

Case: A 61-year-old man. Hepatic dysfunction was pointed out by a medical examination, and when he visited our hospital's gastroenterology department and examined it, he was diagnosed with intrahepatic bile duct cancer invading the hepatic hilum. He was referred to our department for the purpose of radical surgical treatment, and underwent hepatic left tisegmentectomy + extrahepatic bile duct resection + regional lymph node dissection (surgery time: 744 minutes, bleeding volume: 1846 ml). The patient was discharged on the 34th day after the operation without liver failure, and the histopathological result was pT3N1M0 pStage IVA (Primary Liver Cancer Handling Regulations 6th Edition). However, two months after the operation, imaging examination revealed recurrence of liver metastasis, bone metastasis, and lymph node metastasis. GEM + CDDP therapy was started as the first-line treatment, but the effect was determined the following month, and the patient was PD. Therefore, a genetic panel test showed MSI-high. After switching to administration of Pembrolizumab, PR was obtained in the second course, and now, 13 months after the operation, the marked shrinkage effect of the tumor is maintained without any immune-related side effects.

Galectin-9: An Anti-cancer Molecule for Gallbladder Carcinoma

Tomoko Tadokoro, Asahiro Morishita, Shintaro Fujihara, Kyoko Oura, Emiko Akashi, Kei Takuma, Mai Nakahara, Koji Fujita, Shima Mimura, Teppei Sakamoto, Takako Nomura, Hisaaki Miyoshi, Hirohito Yoneyama, Takashi Himoto, Tsutomu Masaki
Department of Gastroenterology and Neurology, Kagawa University School of Medicine, Kagawa, Japan

Background: Gallbladder cancer (GBC) is the most common and aggressive type of biliary tract cancer. There are various histological types of GBC, and the vast majority of GBC cases are adenocarcinomas. Conversely, squamous and adenosquamous carcinomas are rare GBC subtypes that are traditionally considered to be more aggressive and to be associated with a poorer prognosis than adenocarcinoma. Galectin-9 (Gal-9), a tandem-repeat-type galectin, has been reported to induce the apoptosis-mediated elimination of various cancers, including hepatocellular carcinoma, cholangiocarcinoma, and hematologic malignancies.

Methods and Results: We investigated the antitumor effects of Gal-9 on GBC in vitro and in vivo. In our in vitro experiments, Gal-9 suppressed cell proliferation in various GBC cell lines but not in the OCUG-1 cell line, which represents a poorly differentiated type of adenosquamous carcinoma. Gal-9 induced the apoptosis of Gal-9-sensitive GBC cells by increasing the levels of caspase-cleaved keratin 18 and phosphorylated p53. However, Gal-9 did not affect the expression of various cell cycle-related proteins. In addition, Gal-9 suppressed tumor growth by implanted human GBC cells in an in vivo xenograft model. Furthermore, Gal-9 induced the phosphorylation of the Ephrin type-B receptor, and the microRNA (miRNA) expression profile was markedly altered by Gal-9. Based on these results, various miRNAs might contribute to the suppression of tumor growth.

Conclusion: Our data reveal that Gal-9 suppresses the growth of GBC, possibly by inducing apoptosis and altering miRNA expression. Thus, Gal-9 might serve as a therapeutic agent for the treatment of GBC.

Study of Drug-induced Liver Injury (DILI) in Our Hospital

Akemi Tsutsui, Tomonori Senoh, Takuya Nagano, Nobuyuki Baba, Koichi Takaguchi

Department of Hepatology, Kagawa Prefectural Central Hospital, Kagawa, Japan

Background: DILI is an important disease that is often experienced in the clinical environment and will continue to occur as long as medical progress continues. Herein, we examined the change in the characteristics of DILI in our hospital as well as liver injury induced by immune checkpoint inhibitors.

Materials and Methods: The subjects were 149 patients reported as DILI in the pharmacy of our hospital. In each patient, the score and type according to the Digestive Disease Week Japan 2004 (DDW-J) scale and causative agents were explored with the first half from 2004 to 2010 and the second half from 2011. Liver function tests, background diseases, and therapeutic agents were examined for 272 patients treated with immune checkpoint inhibitors.

Results: 1. In terms of the drugs that caused liver damage, a tendency was observed for the cases caused by anti-cancer agents to increase and those of anti-microbial agents to decrease in the second half period compared to the first. 2. Regarding liver injury in patients treated with immune checkpoint inhibitors, there were 37 cases with elevated Grade 1 or higher ALT and 52 cases with elevated Grade 1 or higher ALP. Grade 3 or higher liver injury was observed in 3 patients, each showing peculiar histopathological findings.

Conclusion: DILI associated with the treatment of malignant tumors greatly affects prognosis. As drugs of various mechanisms of action have emerged, it has become more important to examine each case in detail and grasp its pathophysiology accurately to formulate an appropriate treatment plan.

Impact of ERCC1 on the Outcomes of Chemotherapy against Advanced Biliary Tract Cancer: An Ancillary Study of the Japan Clinical Oncology Group Randomized Phase III trial (JCOG1113)

Yasunari Sakamoto^{1,2}, Chigusa Morizane², Takuji Okusaka², Junki Mizusawa³, Nobuyoshi Hiraoka⁴, Tomoki Shirota⁵, Makoto Ueno⁶, Masafumi Ikeda⁷, Masato Ozaka⁸, Hironori Yamaguchi⁹, Nobumasa Mizuno¹⁰, Tomohiro Nishina¹¹, Akio Katanuma¹², Yasushi Kojima¹³, Kunihiro Gotoh¹⁴, Keiya Okamura¹⁵, Yasuyuki Kawamoto¹⁶, Kazuya Sugimori¹⁷, Takeshi Terashima¹⁸, Junji Furuse^{6,19}

¹Department of Gastroenterology and Hepatology, International University of Health and Welfare Atami Hospital, Atami, Shizuoka, Japan., ²Department of Hepatobiliary and Pancreatic Oncology, National Cancer Center Hospital, Chuo-ku, Tokyo, Japan., ³Japan Clinical Oncology Group Data Center/Operations Office, National Cancer Center Hospital, Chuo-ku, Tokyo, Japan., ⁴Department of Diagnostic Pathology, National Cancer Center Hospital, Chuo-ku, Tokyo, Japan., ⁵Department of Surgery, Suwa Red Cross Hospital, Suwa, Nagano, Japan., ⁶Department of Gastroenterology, Kanagawa Cancer Center, Yokohama, Kanagawa, Japan., ⁷Department of Hepatobiliary and Pancreatic Oncology, National Cancer Center Hospital East, Kashiwa, Chiba, Japan., ⁸Hepato-Biliary-Pancreatic Medicine Department, Cancer Institute Hospital of Japanese Foundation for Cancer Research, Koto-ku, Tokyo, Japan., ⁹Department of Clinical Oncology, Jichi Medical University, Shimotsuke, Tochigi, Japan., ¹⁰Department of Gastroenterology, Aichi Cancer Center Hospital, Nagoya, Aichi, Japan., ¹¹Department of Gastrointestinal Medical Oncology, National Hospital Organization Shikoku Cancer Center, Matsuyama, Ehime, Japan., ¹²Center for Gastroenterology, Teine Keijinkai Hospital, Sapporo, Hokkaido, Japan., ¹³Department of Gastroenterology, National Center for Global Health and Medicine, Shinjuku-ku, Tokyo, Japan., ¹⁴Department of Surgery, National Hospital Organization Osaka National Hospital, Osaka, Japan., ¹⁵Department of Bilio-Pancreatology, Sapporo-Kosei General Hospital, Sapporo, Hokkaido, Japan., ¹⁶Division of Cancer Center, Hokkaido University Hospital, Sapporo, Hokkaido, Japan., ¹⁷Gastroenterological Center, Yokohama City University Medical Center, Yokohama, Kanagawa, Japan., ¹⁸Department of Gastroenterology, Kanazawa University, Kanazawa, Ishikawa, Japan., ¹⁹Department of Medical Oncology, Kyorin University Faculty of Medicine, Mitaka, Tokyo, Japan.

Background: The global standard chemotherapy for advanced biliary tract cancer (BTC) is gemcitabine plus cisplatin (GC). The JCOG1113 trial demonstrated the noninferiority of gemcitabine plus S-1 (GS) to GC as the primary endpoint of overall survival (OS); however, there is no validated biomarker for prognostic factors of outcome or predictive factors of drug efficacy in BTC patients.

Methods: The following five candidate biomarkers were evaluated via immunohistochemical staining of BTC tumor specimens collected from JCOG1113 participants: ERCC1 (associated with resistance to platinum in other cancers) and fluorouracil metabolism-related enzymes (TS, DPD, TP, and OPRT). Subjects were randomly divided to the training set and the test set, and classified into high- or low- expression groups based on immunostaining results for each biomarker in the training set. Then, the association between those expression status and OS, progression-free survival (PFS) in whole cohort and each treatment arms were examined. Finally, test set reproducibility was investigated.

Results: This ancillary study included 148 out of 354 patients of JCOG1113. Although no interaction was seen between treatment arms in any factors, high ERCC1 associated with poor OS [HR, 2.226 (95% CI: 1.160–4.272), p=0.0161] and PFS [HR, 1.793 (95% CI: 0.945–3.402), p=0.0742] than low ERCC1 in the training set. Similar trends were shown in OS [HR, 1.338 (95% CI: 0.701–2.554), p=0.3778] and PFS [HR, 1.960 (95% CI: 1.039–3.699), p=0.0378] in the test set.

Conclusions: In advanced BTC patients who underwent GC or GS, high ERCC1 expression was suspected to be a poor prognostic factor.

Actionable Mutations of Malignant Biliary Tumors can be Detected in Archived Biliary Cytology Specimens

Hiroshi Ohyama^{1,2}, Naoya Kato¹, Masao Omata^{2,3}

¹Department of Gastroenterology, Graduate School of Medicine, Chiba University, ²Genome Analysis Center, Yamanashi Central Hospital, ³University of Tokyo

Background & Aims: The prognosis of patients with pancreatobiliary cancer is poor and needs to be improved. Genomic profiling of tumors may provide actionable targets for molecular and immunological treatment. However, there are some limitations in obtaining sufficient pancreatobiliary tumor tissue. In this study, we investigated whether archived cytological specimens (ACS) are suitable for genomic profiling to identify oncogenic and drug-matched mutations.

Methods: We constructed an in-house pancreatobiliary cancer panel for targeted sequencing. A total of 80 DNA samples (19 formalin-fixed paraffin-embedded (FFPE) tissues and 61 ACS) from 44 patients with pancreatobiliary disease was analyzed. We compared the genomic profiles of 19 FFPE and 29 ACS from 19 patients with malignancies (Validation Cohort). We then tested 32 ACS from 25 patients (15 malignant and 10 benign) for the ability to discriminate between malignant and benign disorders (Testing Cohort). Finally, we explored whether actionable and drug-matched mutations (Validation and Testing Cohorts) could be identified from ACS.

Results: Oncogenic mutations observed in ACS were identical to those identified in FFPE specimens (73% consistency). Genomic profiling discriminated between malignant and benign disorders using only ACS with 93% accuracy, 91% sensitivity, and 100% specificity. Moreover, actionable and drug-matched mutations were identified in 71% (24/34) and 32% (11/34) of ACS, respectively, and in 79% (15/19) and 21% (4/19) in FFPE samples, respectively.

Conclusions: ACS can be used for the discrimination of malignancy and to detect drug-matched mutations in patients with advanced pancreatobiliary cancer.

Endoscopic Biliary Drainage “EBD” Versus Percutaneous Transhepatic Biliary Drainage “PTBD” for the Management of Hilar Biliary Obstruction

Yasmin Omar, Ashraf Kamel Abugabel, Mohamed Shawky Elwaraki, Mohamed Ashraf Eljaky,
Mahmoud Helmy Allam
National Liver Institute, Menoufia University, Egypt

Background: Various modalities have been used to manage hilar strictures with variable results. The aim is to compare outcomes of biliary drainage by either percutaneous transhepatic biliary drainage "PTBD" or endoscopic biliary drainage "EBD" in patients with malignant biliary obstruction bismuth type I and II.

Methods: This study was a prospective case-control study, conducted on 60 patients subdivided into 2 subgroups: group I "underwent PTBD" and group II "underwent EBD" for biliary drainage. Patients were recruited from the endoscopy and intervention radiology units of the National Liver Institute hospital starting from September 2018 to October 2021.

Results: The baseline bilirubin in groups I and II were " 21.82 ± 10.02 " and " 13.9 ± 9.07 mg/d", which significantly decreased after 12 weeks of procedure " 3.2 ± 3.7 " and " 6.9 ± 5.1 " with a p-value <0.001 and p-value <0.005 retrospectively. There were 41 patients of 60 patients "68.33%" - "underwent successful biliary drainage with decreased serum bilirubin "Seventeen patients "41.5%" underwent ERCP versus 24 patients "58.5%" underwent PTBD". There was no statically significant difference regarding the type of biliary intervention "p value=0.05". Overall survival after 12 months of follow-up: There were 49 "81.7%" cases died and 11 "18.3%" were censored. In Group II, 20/30 "66.7 %" died versus 29/30 "96.7 %" in group I.

Conclusion: both interventions were equally effective in drainage of hilar obstruction bismuth type I and II. PTBD was better in drainage but ERCP was better in survival and quality of life.

The Usefulness of Endoscopic Ultrasound-guided Biliary Drainage (EUS-BD) for Benign Bile Duct Jejunal Anastomotic Stricture after Biliary Tract Cancer Surgery

Mako Ushio, Ko Tomishima, Daishi Kabemura, Hiroto Ota, Taito Fukuma, Sho Takahashi, Yusuke Takasaki, Akinori Suzuki, Koichi Ito, Shigeto Ishi, Toshio Fujisawa, Hiroyuki Isayama
Department of Gastroenterology, Graduate School of Medicine, Juntendo University, Tokyo, Japan

Methods: EUS-HGS was attempted for 29 cases of postoperative bilio-enteric anastomotic stricture from March 2017 to May 2022, and 6 cases who received surgery for malignancies were enrolled. The success rate of the procedure, adverse events, and time to insert POCS were studied retrospectively.

Results: The mean age of the patients was 68.5 years, and the primary diseases were gallbladder cancer (2), hilar bile duct cancer (1), intrahepatic bile duct cancer (1), distal bile duct cancer (1) and liver metastasis of colorectal cancer (1). The success rate of the EUS-HGS procedure was 100% (6/6) without any adverse events. POCS was performed in 5 cases, exclude one case in which malignant stenosis became evident on imaging during the course of the procedure. The average time to first POCS insertion was 65.6 days, and two cases of malignant stenosis were diagnosed. One case of metastatic recurrence was found despite the absence of malignancy on biopsy at POCS. Only one patient was able to undergo stent removal. One patient was still undergoing PS replacement less than one year after PS implantation. Covered metallic stent (SEMS) was replaced in 3 of 4 cases with malignant stricture and metastatic recurrence cases.

Conclusion: Management of post operative bilio-enteric anastomotic stricture in the cases received surgery for hepato-biliary malignancies with EUS-BD was feasible. Both examination of the stricture with POCS and multiple PS for dilation of the stricture were effective. Covered SEMS employed after confirmation of malignancy. Time to POCS insertion should be shortened and further prospective large scale study was warranted.

Proposal for Infection Prevention Using Disposable Aluminum Covers in Nerve Conduction Study; What we Tried to do at the Beginning of the COVID-19 Pandemic

Tadayuki Takata^{1,2}, Hideki Kobara³, Kazushi Deguchi², Tsutomu Masaki³

¹Department of Supportive and Promotive Medicine of the Municipal Hospital, Kagawa University Faculty of Medicine, Kagawa, Japan, ²Department of Neurology, Kagawa University Faculty of Medicine, Kagawa, ³Department of Gastroenterology, Kagawa University Faculty of Medicine, Kagawa

Background: Coronavirus disease (COVID-19), caused by the severe acute respiratory syndrome coronavirus 2 (SARS-CoV-2), has been associated with central nervous system complications and neuromuscular diseases, with some case reports indicating peripheral neuropathy represented by Guillain-Barre syndrome. Therefore, detailed examination of numbness is necessary and should be carried out expeditiously. Nerve conduction study (NCS) is a neurophysiological examination that can detect peripheral neuropathy. At the beginning of the SARS-CoV-2 epidemic, its infectivity was unknown and maximum prevention of infection was necessary; however, in NCS, surface and stimulating electrodes must be in contact with the patient. Many hospitals use disposable surface electrodes and non-disposable stimulating electrodes. We wondered if disposable items could be used with COVID-19-infected patients or patients at risk of infection to prevent the stimulating electrodes from touching the patient directly if peripheral neuropathy was suspected.

Methods: We wrapped each anode and cathode of the stimulating electrode with kitchen aluminum foil and discarded it after use. The stimulating electrode itself was covered with a vinyl bag from the grip to the conductor. Used electrodes were exchanged for new ones for each patient.

Results: There is no significant difference in the stimulating current levels required to induce compound muscle and sensory nerve action potentials with and without aluminum foil, and there are no problems in the NCS.

Conclusion: We suggest this practical method in patients with unknown infections because aluminum is a metal with low electrical resistivity, low-cost and easily available.

Endoscopic Treatment Results for Biliary Stricture after Liver Transplantation

Naotaka Kugiyama¹, Katsuya Nagaoka¹, Shunpei Hashigo¹, Takehisa Watanabe¹, Shinya Ushijima¹, Yukiko Uramoto¹, Motohiro Yoshinari¹, Masakuni Tateyama¹, Taizo Hibi², Yasuhito Tanaka¹

¹Department of Gastroenterology and Hepatology, Kumamoto University Hospital, Kumamoto, Japan, ²Department of Pediatric Surgery and Transplantation, Kumamoto University Hospital, Kumamoto, Japan

Background: Liver transplantation is one of the treatments for hepatocellular carcinoma (HCC), and biliary stricture sometimes occur after transplantation. Endoscopic biliary stenting (EBS) is performed for the strictures, however if the stricture does not improve and regular stent replacement is necessary, there is no clear evidence on stent patency period and replacement timing.

Methods: In 48 patients with biliary stricture after liver transplantation, we evaluated the stricture improvement rate and compared retrospectively the stent patency period between inside stents (IS) and conventional plastic stents (PS). The most common indication for transplantation in 48 patients was associated with HCC (20.8%).

Results: The median interval from liver transplantation to the first EBS (when the stricture occurred) was 234 days (range, 83-5816 days). The stricture improved in 21 patients (44%) on repeat EBS, however, stricture recurrence was observed in 8 patients (38%). In the first EBS, IS were placed in 18 patients and PS in 30 patients. The median patency periods were 369 days (IS) and 154 days (PS) ($p=0.01$), significantly longer for the IS. The one-year acute cholangitis rate was 20% in the IS, significantly lower than the PS (43%, $p=0.04$). Comparing among all EBSs, there were 89 EBSs in the IS and 127 EBSs in the PS. The median stent patency periods were 356 days (IS) and 196 days (PS) ($p=0.009$). The one-year acute cholangitis rate was 17% in the IS.

Conclusions: IS is suitable for patients who require long-term patency because of unimproved stricture. Yearly IS replacement is recommended.

A Study of ERCP Complications in Patients with Cirrhosis in Our Hospital

Ryota Nakabayashi, Hideki Kamada, Masahiro Ono, Toshiaki Kono, Daisuke Namima, Naoki Fujita, Hiroki Yamana, Kiyoyuki Kobayashi, Tsutomu Masaki
Department of Gastroenterology, Kagawa University, Kagawa, Japan

Background: ERCP is an essential procedure in the treatment of biliopancreatic diseases. However, it has the potential to cause complications, and its use should be based on the patient's background. In contrast, it has been reported that patients with cirrhosis have a higher frequency of common bile duct stone complications and an increased risk of complications. We reviewed the incidence of ERCP in cirrhotic patients at our hospital.

Methods: Of the 551 cases of ERCP for CBDS performed at our hospital from April 2018 to March 2022, 495 cases were included, excluding postoperative intestinal cases and 56 cases in which no transpyloric procedure was performed. There were 300 male cases and 195 female cases, with a mean age of 77.1 years.

Results: Of the 495 cases, 16 were cirrhotic and 479 were non-cirrhotic. The breakdown of papillary procedures was EST/EPBD/EPLBD/EBS/post-treatment papillae:7/3/1/5/0 in cirrhotic cases and 173/10/62/94/140 in non-cirrhotic cases. The incidence of ERCP incidentalities was higher in cirrhotic patients ($p < 0.05$): 12.5% (2/16) in cirrhotic patients and 2.5% (12/479) in noncirrhotic patients. Noncirrhotic patients had 4 cases of bleeding, 3 cases of perforation, 3 cases of mild pancreatitis, and 2 other cases.

Conclusion: The risk of accidental injury is higher in patients with cirrhosis. The risk is related to the severity of cirrhosis, and Child C has been reported to be an independent predictor of the risk of ERCP incident. Patients with cirrhosis should be fully informed before undergoing ERCP.

Cytotoxic Lesions of the Corpus Callosum Associated with COVID-19 Vaccination: A Case Report

Rie Kawakita¹, Yuta Chiba¹, Jun Kurimoto¹, Keita Tanimoto^{1,2}, Kazushi Deguchi¹,
Tsutomu Masaki²

¹Department of Neurology, Faculty of Medicine, Kagawa University

²Department of Cardiorenal and Cerebrovascular Medicine, Faculty of Medicine, Kagawa
University

³Department of Gastroenterology, Faculty of Medicine, Kagawa University

Background: Coronavirus disease 2019 (COVID-19) vaccination might adversely affect the nervous system.

Case Report: A 70-year-old female vaccinated with two doses of the COVID-19 vaccine (Pfizer) developed chills and fatigue a few hours after receiving a third dose (Moderna), followed by several episodes of falling. On the 6th day, she developed a fever (39°C). Severe acute respiratory syndrome coronavirus 2 (SARS-CoV-2) real-time reverse transcription polymerase chain reaction test was negative. On the 13th day, she developed enlarged mandibular lymph nodes, sensorineural hearing loss, and unstable gait due to truncal ataxia. Cerebrospinal fluid (CSF) showed protein elevation with pleocytosis and elevated IL6. Blood and CSF screening revealed no abnormalities suggesting viral infection or metabolic derangement. Autoantibodies against aquaporin 4, myelin-oligodendrocyte glycoprotein, and glial fibrillary acidic protein were negative. Magnetic Resonance Imaging (MRI) of the brain revealed hyperintense lesions throughout the corpus callosum on diffusion-weighted and fluid-attenuated inversion recovery images, without contrast enhancement on T1-weighted images. Fluorodeoxyglucose-positron emission tomography and MRI of the spinal cord did not reveal any abnormalities. The CSF and MRI findings were alleviated after immune and symptomatic therapies. However, hearing loss and ataxic gait persisted at 2 months after the onset.

Discussion: Although hearing loss has been occasionally reported among adverse events of COVID-19 vaccination, cytotoxic lesions of the corpus callosum are rare. In this case, the lesions probably occurred by the same mechanism as acute disseminated encephalomyelitis after vaccination, resulting in fever followed by ataxia.