



Comments? Questions?

Email: compendium@medimedia.com

Web: VetLearn.com • Fax: 800-556-3288

CE

Article #2 (1.5 contact hours)

Refereed Peer Review

Surgical Conditions of the Canine Penis and Prepuce

KEY FACTS

- Many penile and preputial abnormalities are hereditary; trauma is the main cause of acquired defects.
- Dogs that have one defect should be examined (especially in the midline) for the presence of other abnormalities.
- Emergency surgery is often required in cases of traumatic abnormalities to treat or prevent urinary dysfunction or reproductive failure.

Aristotle University of Thessaloniki
Thessaloniki, Greece

Lysimachos G. Papazoglou, DVM, PhD, MRCVS
George M. Kazakos, DVM

ABSTRACT: Abnormalities of the canine penis and prepuce may have congenital or acquired causes. Diagnosis is based mainly on physical examination of the external genitalia. Treatment of these abnormalities may require surgical intervention or medical management. Because many of the conditions may be hereditary, normal breeding is discouraged; therefore, surgical treatment (whether emergency or elective) should be aimed at repairing urinary rather than reproductive function.

Congenital and acquired penile and preputial abnormalities have been described in dogs.¹⁻³ Trauma is the main cause of acquired abnormalities. Dogs with congenital or acquired abnormalities may be either asymptomatic or have urinary dysfunction or breeding failure. Dogs that have one defect should be examined thoroughly (especially in the midline) for the presence of others.¹⁻³

Because many penile and preputial defects are hereditary, normal breeding should be discouraged; therefore, surgical intervention of congenital defects should be aimed at correcting or preventing urinary dysfunction rather than restoring reproductive performance. Traumatic abnormalities often require emergency surgery to manage or prevent urinary dysfunction and reproductive failure. Thorough knowledge of the pertinent anatomy and experience with surgical reconstructive and urologic techniques are essential for a successful outcome.

SURGICAL CONDITIONS OF THE PENIS

Paraphimosis

The inability to retract the penis into the preputial cavity results in paraphimosis. In a study of 185 dogs with penile and preputial diseases,⁴ paraphimosis was reported in 7%. Paraphimosis may be attributed mainly to an abnormally small preputial orifice, ineffective preputial muscles, or a hypoplastic prepuce. Other reported causes include trauma, infection, neoplasia, persistent erection, or idiopathic causes.⁵⁻⁹ Paraphimosis is also encountered during sexual excite-

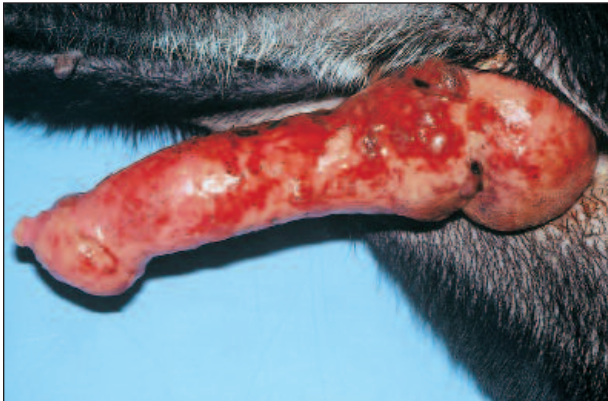

Figure 1—Postcoital paraphimosis in a dog. Note the blood and bumps.

ment (Figure 1) or coitus. The small preputial orifice initially allows protrusion of the penis; but as the penis becomes engorged and swollen the small orifice makes retraction impossible. This may lead to severe edema and congestion as well as dryness and irritation. Consequently, ischemic necrosis and urethral obstruction may occur. Preputial hairs may encircle the protruded penis and form a band that contributes to or causes paraphimosis.³⁻¹⁰

Diagnosis of paraphimosis is made by physical examination. Determining the cause is essential for effective treatment. If the prepuce can be drawn forward to cover the penile protrusion, preputial muscle ineffectiveness may be suspected as the cause.⁶

Medical treatment should be aimed initially at retracting the penis into the preputial cavity. While the dog is under general anesthesia or heavy sedation, cold compresses consisting of hyperosmolar solutions and lubricants should be applied to the penis to reduce the swelling and facilitate retraction into the preputial cavity. If retraction is impossible, surgical enlargement of the prepuce is required. Paraphimosis accompanied by penile necrosis is managed with amputation. Paraphimosis that is attributed to preputial muscle ineffectiveness, preputial hypoplasia, or idiopathic causes is managed with cranial advancement of the prepuce combined with shortening or imbrication of preputial muscles (Figure 2).^{3,5,9,11,12} In a study of six dogs with idiopathic paraphimosis in which preputial muscle ineffectiveness had been implicated as a cause, results of preputial advancement were considered excellent in four dogs when the length of the exposed penis was 1.5 cm or less.⁹ Longer protrusions, however, may also be managed successfully using the same technique. In case of recurrence or if the penis protrudes too far, partial penile amputation or a staged reconstructive technique may be performed to manage the paraphimosis.^{9,13,14}

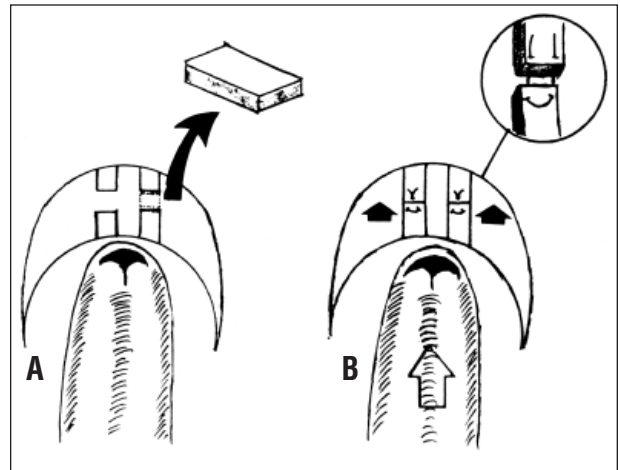


Figure 2—A crescent-shaped piece of skin has been removed cranial to the prepuce, and the preputial muscles have been transected and excised (A). Reapposition is performed using a horizontal mattress suture pattern (B). (From Papazoglou LG: Idiopathic chronic penile protrusion in the dog: A report of six cases. *J Small Anim Pract* 42:510-513, 2001; with permission.)

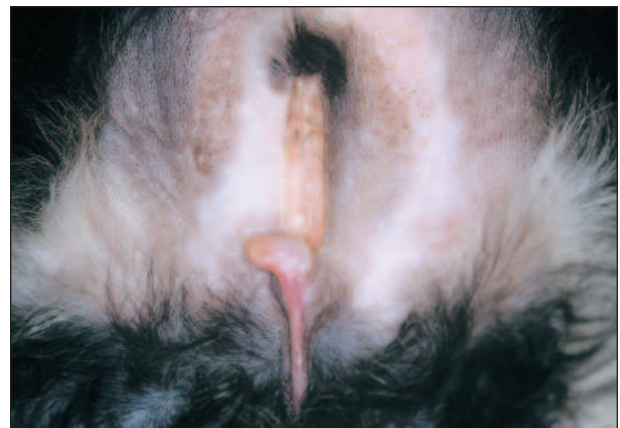

Figure 3—Abnormal preputial fusion in association with glandular hypospadias in a dog.

Hypospadias

Hypospadias is a rare developmental anomaly in both male and female dogs in which the urethral orifice is located ventral and proximal to the normal opening.^{15,16} In male dogs, hypospadias is caused by failure of the urethral folds to fuse when the urethra is formed.^{1,17} This condition is most commonly seen in male dogs with cryptorchidism and, to a lesser extent, with other sexual defects.¹⁶ The etiology of hypospadias seems to be multifactorial in association with inadequate fetal androgen production.¹⁸ Boston terriers reportedly have a familial predisposition to the development of hypospadias.¹⁶ Anatomic classification of

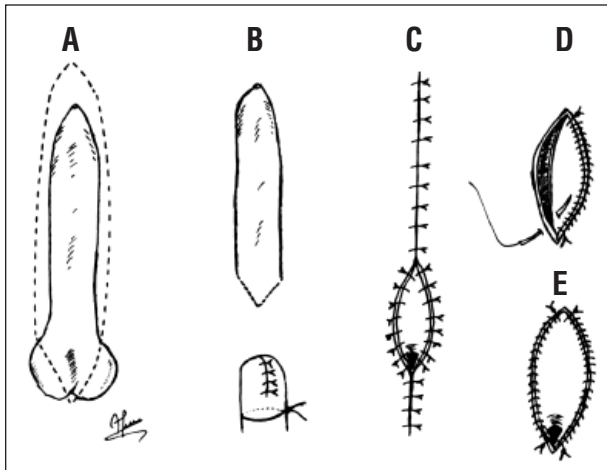


Figure 4—Complete amputation of the external genitalia. The skin around the prepuce and scrotum is incised in an elliptical fashion (A). The penis is amputated proximal to the os penis; and the distal penis, scrotum, and prepuce are excised (B). A ligature is placed around the remaining penis, and the penile stump is closed using a simple interrupted suture pattern. The urethra is incised, and scrotal urethrostomy is performed by apposing urethral mucosa and skin in a simple interrupted pattern with 3-0 or 4-0 nonabsorbable monofilament suture material (C). The urethral mucosa may be sutured to the skin in a simple continuous suture pattern starting at the caudal aspect of the wound (D and E). This pattern may result in decreased postoperative hemorrhage.

hypospadias may be glandular (Figure 3), penile, scrotal, or perineal, depending on the location of the urethral opening.¹⁶ In addition to visual abnormalities, clinical signs include hematuria, dysuria, and urinary incontinence and scalding.

Diagnosis is made by physical examination of the penis and perineum. Surgical correction depends on the severity and location of the lesion.¹⁹ Usually a reasonably sized urethral opening can be seen. Dogs with mild defects may not require surgical correction¹⁹ because the urethra proximal to the abnormal orifice is underdeveloped.⁷ Dogs with severe irritation associated with an abnormally fused prepuce or a hypoplastic penis may need resection of penile and preputial remnants combined with a scrotal or perineal urethrostomy (Figures 4 and 5).^{7,19} In addition, castration is always recommended because of the possible genetic involvement.^{10,18}

Trauma-Related Conditions

In a study of 185 dogs with penis and prepuce conditions,⁴ trauma accounted for 19% of the causes. Penile trauma may result from motor vehicle accidents, animal fights, gunshot injuries, mating attempts, separa-

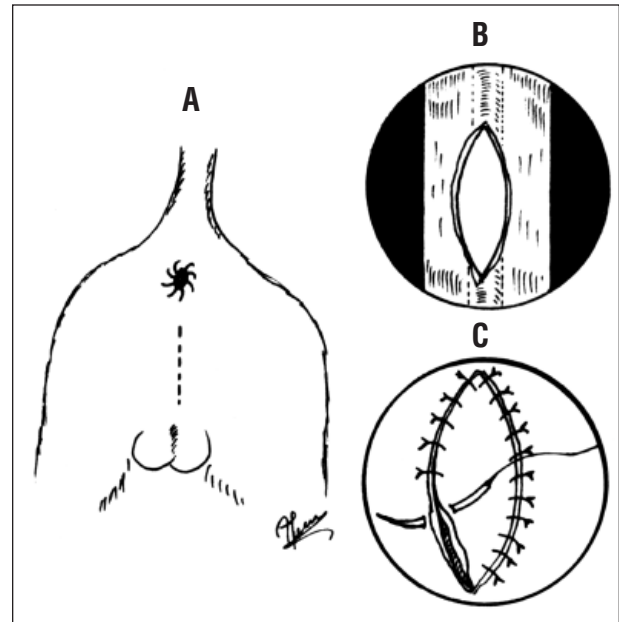


Figure 5—Perineal urethrostomy. The urethra is catheterized and an incision made in the midline approximately 2 to 3 cm dorsal to the scrotum (A). The urethra is incised over the catheter (B), and a urethrostomy is created by apposing urethral mucosa and skin in a simple interrupted suture pattern using 3-0 or 4-0 nonabsorbable monofilament suture material (C).

tion from the copulatory tie, or failing to clear fences when jumping.^{6,17} Penile trauma may lead to hematoma formation and strangulation and extensive necrosis of the penis. Profuse hemorrhage and pain are the predominant clinical signs. Urethral obstruction and fractured os penis can also be seen.^{6,20} Three recent cases²¹ of dogs with corpus cavernosum trauma possibly caused by mating have been reported. All three dogs were presented with signs of hindquarter pain, whereas dysuria was noted in two of the animals.

Minor lacerations should be managed as open wounds. In dogs with major lacerations or persistent hemorrhage during excitement, suturing the tunica albuginea with 4-0 or 5-0 synthetic monofilament absorbable suture material (armed in a taper-cut needle) in a simple continuous or interrupted pattern is recommended.⁷ After surgery, analgesia or antibiotics may be used (if needed) along with an Elizabethan collar. Sedation and avoidance of contact with females are recommended to prevent erection.^{6,7} If penile necrosis occurs, however, partial or complete amputation of the penis should be performed (Figures 4 and 6). If partial penile amputation is performed, preputial shortening may be required to prevent urine pooling in the preputial cavity (Figure 7).¹²

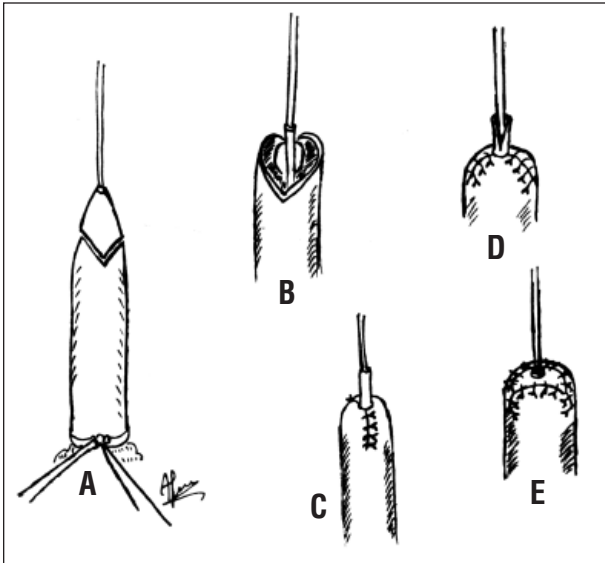


Figure 6—Partial penile amputation. A catheter is placed in the urethra and a Penrose tube is used as a tourniquet and for preputial reflection (A). The penis is incised at a 45° angle. The incision is made down to the os penis dorsally, and the urethra is elevated from the groove of the os penis (B). The os penis along with the amputated part of the penis is removed with a rongeur. The penile stump is closed in a simple interrupted suture pattern (C). The urethra is spatulated (D) and sutured to the penile stump in a simple interrupted suture pattern with 4-0 to 5-0 monofilament absorbable suture material (E).

Tumors

Penile tumors account for 0.24% of all tumors in male dogs²²; transmissible venereal tumors (TVT) and squamous cell carcinomas (Figure 8) are the most common neoplasms of the canine penis.^{10,17} Other penile tumors include fibromas, papillomas, and various mesenchymal tumors.^{6,10,23} Penile tumors usually affect older dogs. In contrast, TVTs occur in young (mean age, 4 to 5 years), free-roaming dogs and are transmitted by contact with genital mucous membranes during coitus.²⁴ Clinical signs include preputial enlargement, serosanguineous or hemorrhagic preputial discharge, licking of the penis and prepuce, hematuria, dysuria, and urethral obstruction.^{7,10}

Diagnosis is based on physical examination and is confirmed by cytology of fine-needle aspirate or impression smear, incisional or excisional biopsy, and histopathology.^{7,17,24} Clinical staging is essential for squamous cell carcinomas because of the metastatic potential.²⁵ Vincristine chemotherapy (0.5 to 0.7 mg/m² IV in four to eight weekly cycles) is very effective in treating TVTs, even in dogs with metastatic disease.^{24,26} Doxorubicin is also effective.²⁴ Radiotherapy is

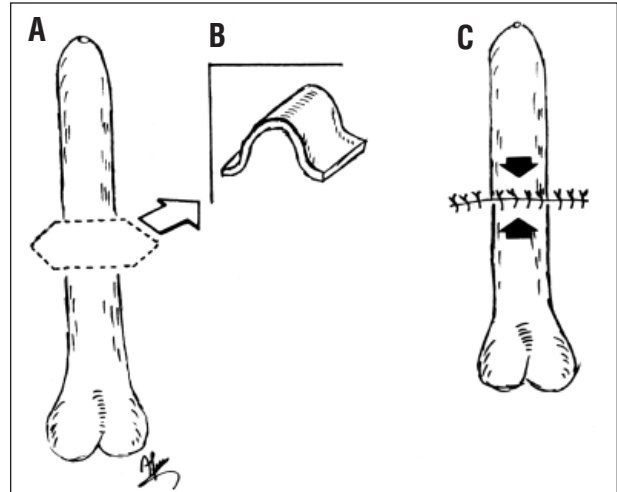


Figure 7—Preputial shortening. A portion of the prepuce is excised full-thickness (A and B). The skin and mucosa are reapposed in a simple interrupted suture pattern (C).

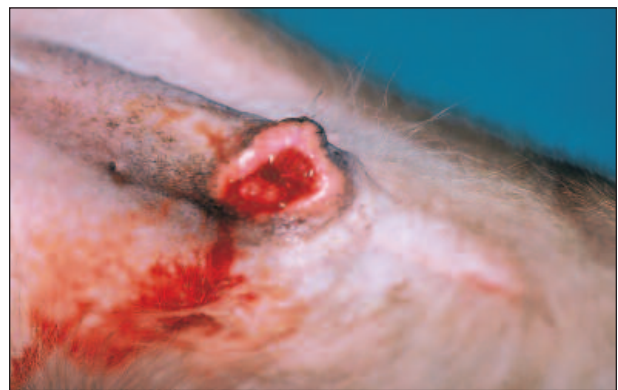

Figure 8—Squamous cell carcinoma of the penis and prepuce, resulting in secondary phimosis.

recommended for animals that are resistant to chemotherapy.²⁴ Prognosis is usually very good. Surgical excision is not recommended for TVTs because the recurrence rate is high.²⁶ Partial or complete penile amputation combined with scrotal urethrostomy is recommended for penile tumors, depending on the location and type of tumor. Perineal urethrostomy may also be used in cases in which the tumor extends too far proximal in the urethra (Figure 5). Ventral midline preputiotomy may be employed, especially for penile tumors that are large enough to allow penile extrusion through the preputial orifice.²⁷ Preputial closure is accomplished in two layers. The mucosa is closed in a simple continuous pattern with 4-0 or 5-0 synthetic monofilament absorbable suture, and the skin is closed in a routine fashion.²⁷ The effect of adjuvant therapies in prolonging survival has not been documented.²⁵

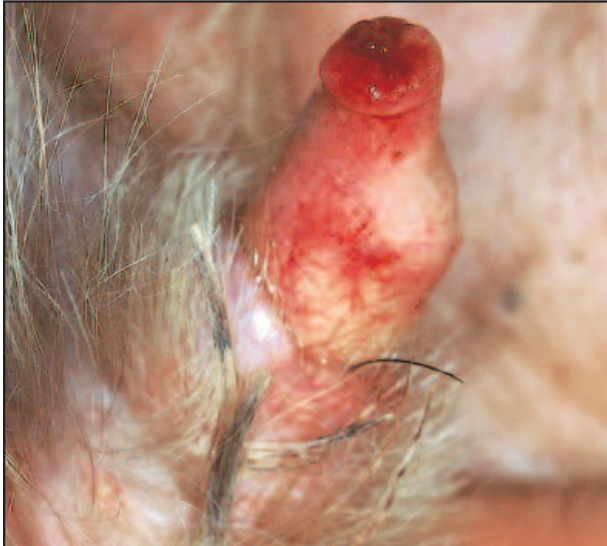

Figure 9—Urethral prolapse in a castrated 4-year-old Yorkshire terrier.

Urethral Prolapse

Prolapse of the distal urethra through the external urethral orifice is rarely reported in intact male dogs.⁷ Although this condition has been reported in two Boston terriers, a Yorkshire terrier, and other breeds, English bulldogs are mainly affected.²⁸⁻³¹ Most of the affected animals are young.³² The cause may be unknown, or the condition may occur after excessive sexual excitement or urogenital tract infection.^{7,23} Abnormal urethral anatomy in relation to increased intraabdominal pressure caused by upper airway obstructive syndrome, dysuria, and sexual excitement have also been proposed to explain the increased predilection in brachycephalic breeds.³² The prolapsed urethra, which appears as a pea-shaped mass at the distal end of the penis, becomes edematous and congested (Figure 9). Licking and intermittent hemorrhage, which becomes worse during erection, are the usual clinical signs.^{6,7,31}

Diagnosis is made by visual examination of the penis. The condition should be differentiated from fracture of the os penis, neoplasm, persistent penile frenulum, urethral stricture, and urethral calculi.³⁰ The use of castration and hormonal therapy to prevent erection has been unsuccessful.^{30,31} Surgical excision of the prolapse is the treatment of choice, especially for dogs with severe trauma and necrosis.^{10,30,33} The ventral aspect of the penis is incised down to the penile and urethral mucosa halfway around the circumference.³⁰ The urethral mucosa is sutured to the penile mucosa in a simple interrupted or continuous pattern¹⁷ using 4-0 synthetic monofilament absorbable suture. The

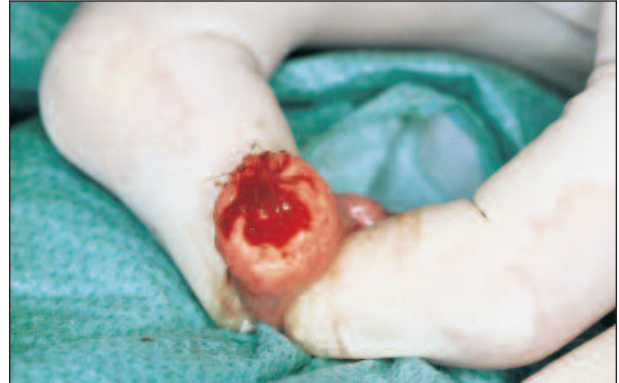

Figure 10—The prolapsed urethra has been resected, and the urethral mucosa is sutured to the penile mucosa in a simple interrupted suture pattern.

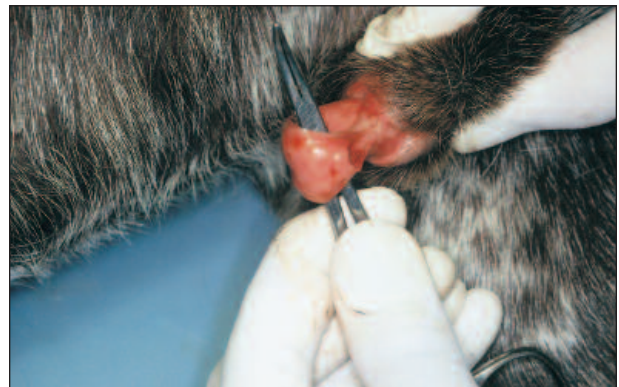

Figure 11—Persistent penile frenulum in a German short-haired pointer.

dorsal aspect of the urethral mucosa is then incised and sutured with the same pattern (Figure 10).³⁰ An Elizabethan collar should be placed after surgery to prevent licking of the anastomosis site. For 5 to 10 days, sedation and avoidance of contact with females in estrus are also recommended to control postoperative hemorrhage. If further trauma of the anastomosis site is prevented, prognosis following surgical removal is usually good.¹⁷ In rare cases in which urethral prolapse recurs, re-excision is recommended.³³

Persistent Penile Frenulum

Persistent penile frenulum is a thin band of connective tissue that unites the ventral midline aspect of the glans penis to the prepuce. Rupture of the frenulum in dogs occurs during puberty, and the process is controlled by testosterone levels.^{6,7} The condition has been reported in cocker spaniels, miniature poodles, Pekingese, and mixed-breed dogs.^{17,34-36} Dogs with a penile frenulum may be asymptomatic or may be presented with penile and preputial licking, urine scalding

of the hindlimbs caused by diversion of the urine stream, pain during penile engorgement, unsuccessful mating, and deviation of the penis during erection (i.e., phallocampsis).^{6,17,23}

Diagnosis of penile frenulum is made by visual examination (Figure 11). Treatment includes severing the abnormal band with electrosurgery or a surgical blade while the animal is under light anesthesia. Prognosis following surgery is good.⁷ Persistent penile frenulum is sometimes accompanied by other congenital defects of the prepuce and penis that may require reconstructive surgery.^{3,17}

Hypoplastic Penis

Hypoplastic penis, which is an uncommon disorder, usually occurs in association with other anomalies.^{17,23,37} This condition is often seen in intersex dogs.^{6,10,17} Dogs with penile hypoplasia are usually asymptomatic; the condition is often found incidentally during routine clinical examination.^{6,10} In most cases, no treatment is required.^{6,10} However, if the abnormality is accompanied by a hypoplastic preputial orifice, urine pooling, scalding inside the prepuce, or urine dribbling, then

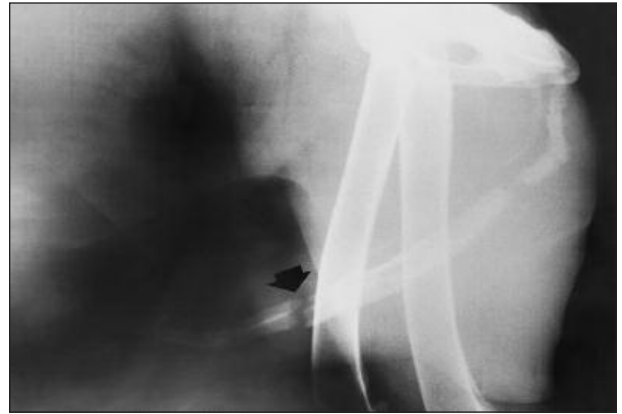


Figure 12—Transverse fracture of the os penis (*arrow*) in a dog. (Courtesy of M. N. Patsikas, DVM, Aristotle University of Thessaloniki, Greece.)

surgical intervention is necessary.³⁷ Surgical enlargement of the preputial orifice can be accomplished by making a triangular incision on the dorsal side of the orifice; preputial shortening should be performed for correction of the abnormality (Figure 7).^{12,37} However, severe penile hypoplasia may be more easily managed by amputation and scrotal urethrostomy.

Fracture of the Os Penis

Fracture of the canine os penis is a rarely reported surgical condition.^{38,39} This condition can occur in any size or breed of dog and often follows external penile trauma.^{2,6} Simple fractures with minimal displacement may go undetected, especially if accompanied by minimal soft tissue injury.¹⁷ In the reported studies,^{4,38,39} the most common presenting signs were associated with urinary outflow obstruction (e.g., strangury, dysuria, distended urinary bladder, uremia). Other signs include local pain, inflammation, and urethral bleeding.^{20,38} Palpation may reveal crepitus, but radiographic examination will determine os penis damage and the amount of callus formation, especially if the lesion is old (Figure 12).^{38–40} Urethral catheterization and retrograde urography will determine urethral involvement (e.g., tear, obstruction).^{4,6,38,39}

Treatment may not be necessary in dogs with minimally displaced simple fractures.^{6,7,17,20} Mobile fractures require immobilization (for 1 to 3 weeks) with the use of a urinary catheter that should extend beyond the os penis.^{4,17} More severe fractures may require plating, wiring, or partial or total amputation of the penis.^{2,7,38,39} Urethral tears rarely need to be sutured and usually heal around the catheter, except in cases in which complete severance has occurred.^{17,20} Retrograde urography is recommended for 6 to 8 months after the fracture to mon-

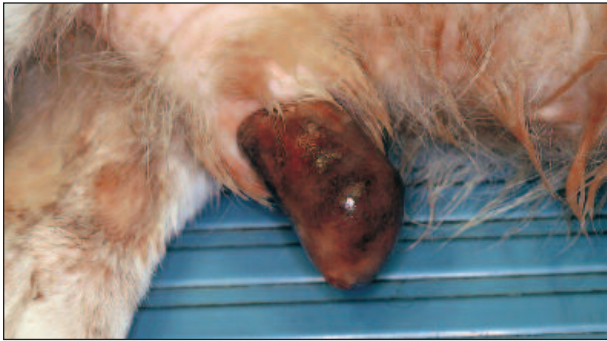

Figure 13—Priapism and self-induced traumatization of the penis in a dog following intervertebral disk disease.

itor whether callus formation impedes urine passage.⁶ In one study,³⁹ however, obstructive uropathy appeared 21 months after the fracture occurred. Urethral obstruction caused by callus formation can be managed with urethrostomy distal to the obstruction site.¹⁷

Deformity of the Os Penis

Phallocampsis may be caused by deformity of the os penis. Mild phallocampsis may result in the inability to achieve vaginal penetration because of misdirected copulatory efforts, leading to infertility.^{10,41} This abnormality may predispose some dogs to urethral obstruction.¹⁰ Penile exposure results in drying of the exposed portion of the penis, self-induced trauma, and eventually infection and necrosis.^{7,20}

Treatment depends on the condition of the exposed penis and is generally the same as for paraphimosis.^{7,20} Treatment may include fracturing the os penis with wedge osteotomy and straightening it with the aid of an indwelling urinary catheter and without fixation.^{7,20,41} Partial penile amputation may be performed in severe cases (e.g., infection, necrosis).⁷ However, if no other problems (e.g., paraphimosis, outflow urine obstruction) accompany the deformity, therapy may not be indicated.¹⁰

Priapism

Priapism, which is rarely reported in dogs, is a persistent penile erection not associated with sexual excitement.^{7,10} The condition is either idiopathic or associated with spinal cord lesions (Figure 13), trauma during mating, genitourinary infection, constipation, thromboembolism of the cavernous venous tissue at the base of the penis, or therapy for narcolepsy.^{2,7,42} Excessive parasympathetic stimulation or decreased venous outflow caused by an occlusive thrombosis or mass results in stagnation of blood with increased carbon dioxide and low oxygen concentrations in the corpus cavernosum penis. This leads to edema with enhanced

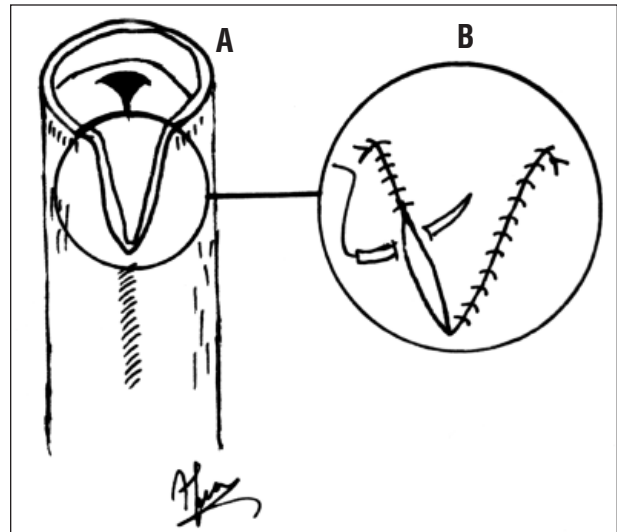


Figure 14—Surgical correction of phimosis. A full-thickness, V-shaped incision is made in the dorsal aspect of the prepuce (A). The skin and preputial mucosa are apposed using a simple interrupted or continuous pattern (B).

venous obstruction and eventually irreversible fibrosis in the main venous outflow tracts of the penis.⁴²

This condition must be differentiated from frequent erections seen in young small-breed dogs⁶ and, at least in early stages, from paraphimosis.⁷ Chronic exposure and excessive licking of the penis result in congestion, swelling, and finally drying and necrosis, rendering differentiation from paraphimosis difficult. Although spontaneous remission can occur,^{7,17} delay in providing supportive care may necessitate amputation. The penis must be kept clean, lubricated with antibiotic creams to prevent desiccation, and protected from self-induced trauma.^{7,10,17} The erection should subside once the spinal condition is resolved.⁷ Amputation of the penis and scrotal urethrostomy (Figure 4) may be necessary if the underlying cause cannot be identified and corrected.^{10,17} According to other reports, successful surgical treatment has consisted of incision of the bulbus and pars longa glandis and exsanguination of accumulated blood from the corpus cavernosum penis. The ability to maintain an erection after surgery, however, was not reported in the study.⁴³

SURGICAL CONDITIONS OF THE PREPUCE Phimosis

Phimosis is a condition in which the preputial orifice is absent or too small to allow extrusion of the penis.⁴⁴ In a study of 185 dogs with penile and preputial lesions,⁴ phimosis accounted for 0.5%. The condition may be congenital or acquired. Congenital preputial stenosis has been reported in Bouvier de Flandres, Ger-

man shepherds, Labrador and golden retrievers, and mixed-breed dogs.⁶ The most common causes of acquired phimosis are scarring from lacerations following trauma, sucking of the puppy's prepuce by littermates, and licking from the dam.^{7,17} Neoplasia in this area may also narrow the preputial orifice.^{7,17} When the preputial opening is large enough to allow urination, puppies may be asymptomatic. In severely affected dogs, either urine retention in the prepuce is noted or, depending on the size of the orifice, urine dribbling or an abnormal stream of urine is evident. Secondary infections may lead to balanoposthitis and septicemia if left untreated.^{2,6} Phimosis may interfere with erection in sexually mature dogs.^{10,44}

Diagnosis is made by inspecting an anatomically small preputial opening in relation to the penis. In less severe cases, it may be necessary to observe the erect penis and its inability to be extruded from the preputial orifice.^{10,44} Differentiation from persistent penile frenulum should be made since phimosis can also result in the inability of the penis to fully protrude from the prepuce.⁴⁴ In congenital phimosis, in which the preputial orifice is stenotic, it is possible to further evaluate the penis and prepuce by performing a radiographic examination with the use of a contrast media injected into the preputial cavity via the external opening.⁴⁵

Surgical correction of the primary condition or enlargement of the preputial orifice usually leads to a successful outcome. Removal of neoplasms is usually accompanied by aggressive removal of the prepuce and sometimes partial penile amputation.^{7,46} Postsurgical stenosis of the orifice should be avoided.^{7,46} Surgical enlargement of the orifice should be performed on the craniodorsal surface instead of the ventrocaudal aspect to avoid excessive protrusion of the penis.^{12,46} A midline full-thickness incision is made to the desired length to ensure an unrestricted opening.¹² It is sometimes necessary to excise a V-shaped amount of tissue in order for the penis to protrude normally (Figure 14).³⁷ The preputial mucosa and ipsilateral skin edges can be apposed in a simple interrupted⁷ or continuous pattern using 4-0 or 5-0 synthetic monofilament nonabsorbable suture material to avoid irritation from knots.⁴⁶ If necessary, the incision may extend cranially into the skin on the ventral abdominal wall.⁴⁶

Neoplasms

All neoplastic diseases that affect the skin can be found in the prepuce.^{7,8} Those most commonly encountered include mastocytomas, TVTs, squamous cell carcinomas, and perianal gland adenomas.^{7,8,25} As they grow, tumors may obstruct the preputial orifice, eventually causing phimosis. Ulcerations may favor

bacterial overgrowth; therefore, orifice involvement may lead to balanoposthitis.⁴⁴ Preputial neoplasms may sometimes extend to the penis.¹⁷

Diagnosis is made using cytology of fine-needle aspirate or impression smear, incisional or excisional biopsy, and histopathology.^{7,24} Clinical staging is required for mast cell tumors and squamous cell carcinomas because of their metastatic potential.²⁵ Appropriate therapy depends on tumor type, behavior, and metastases. Treatment of small neoplasms includes surgical removal of the mass with closure of the prepuce in two layers.⁷ Postoperative paraphimosis should be avoided.⁷ Wide surgical excision (partial or total preputial/penile amputation) should be included in the therapy plan for malignant tumors.^{7,44} Radiotherapy or chemotherapy may be required for mast cell tumors not amenable to surgical excision or as an adjuvant therapy.⁴⁷ Management of preputial TVTs is the same as for penile TVTs.²⁴ Orchidectomy is advised in cases of perianal gland tumors.

Trauma- and Foreign Body-Related Conditions

Preputial trauma may result from motor vehicle accidents, dog fights, attempts to mate, environmental injuries, gunshot injuries, or failing to clear fences when jumping.^{6,17} In some cases only the external lamina is involved; with full-thickness lacerations, both the external and internal laminae may be involved.⁸ Preputial wounds, which may also result from foreign bodies (e.g., grass awns, plant seeds, urinary calculi), usually cause irritation or ulceration of the mucosa, leading to mucopurulent or blood-tinged discharge, discomfort, and mild hindlimb stiffness. A draining tract is usually present ventral or lateral to the penis. Draining tract exploration, foreign-body removal, and tract drainage should be performed.⁷ Prognosis is usually good after foreign-body removal.^{7,10} For dogs with full-thickness lacerations or those in which loss of tissue has occurred, the prepuce should be closed in two layers.¹⁷ The mucosa is closed in a continuous pattern with 4-0 or 5-0 synthetic monofilament absorbable suture material, and the skin is closed routinely. Measures aimed at preventing self-induced trauma should be taken. Extensive traumatic loss of the prepuce may be managed with reconstructive staged surgery.¹⁴ Partial or complete preputial and penile amputation should also be considered with injuries resulting from extensive trauma.¹⁷

Preputial Hypoplasia and Abnormal Fusion

The prepuce may be underdeveloped or absent or may not fuse normally because of failure of the genital folds to close normally during fetal life.⁷ Abnormal preputial fusion can be seen in association with

hypospadias (Figure 3).^{6,15,48} Clinical signs are related to chronic paraphimosis, which may lead to inflammation, drying, self-mutilation, and penile trauma.^{7,46}

Paraphimosis may be managed successfully with cranial advancement of the prepuce.⁹ Severe preputial hypoplasia usually requires staged reconstruction of both preputial laminae using skin flaps and oral grafts^{13,14}; however, partial penile amputation remains an alternative to reconstructive surgery.⁹ Abnormal preputial fusion may be treated by complete excision of the exposed preputial mucosa, partial amputation of the penis, and scrotal or perineal urethrostomy.^{7,12,48}

REFERENCES

- Rawlings CA: Correction of congenital defects of the urogenital system. *Vet Clin North Am Small Anim Pract* 14:49–60, 1984.
- Johnston SD: Disorders of the canine penis and prepuce, in Morrow DA (ed): *Current Therapy in Theriogenology*, ed 2. Philadelphia, WB Saunders Co, 1986, pp 549–550.
- Olsen D, Salwei R: Surgical correction of a congenital preputial and penile deformity in a dog. *JAAHA* 37:187–192, 2001.
- Ndiritu CG: Lesions of the canine penis and prepuce. *Mod Vet Pract* 60:712–715, 1979.
- Chaffee VW, Knecht CD: Canine paraphimosis: Sequel to inefficient preputial muscles. *Vet Med Small Anim Clin* 70:1418–1420, 1975.
- Johnston DS: Disorders of the external genitalia of the male, in Ettinger SJ (ed): *Textbook of Veterinary Internal Medicine*, ed 3. Philadelphia, WB Saunders Co, 1989, pp 1881–1889.
- Boothe HW: Penis, prepuce, and scrotum, in Slatter D (ed): *Textbook of Small Animal Surgery*, ed 2. Philadelphia, WB Saunders Co, 1993, pp 1336–1348.
- Fowler DJ: Preputial reconstruction, in Bojrab MJ (ed): *Current Techniques in Small Animal Surgery*, ed 4. Baltimore, Williams & Wilkins, 1998, pp 534–537.
- Papazoglou LG: Idiopathic chronic penile protrusion in the dog: 6 cases. *J Small Anim Pract* 42:510–513, 2001.
- Feldman EC, Nelson RW: *Canine and Feline Endocrinology and Reproduction*, ed 2. Philadelphia, WB Saunders Co, 1996, pp 691–696.
- Leighton RL: A simple surgical correction for chronic penile protrusion. *JAAHA* 12:667, 1976.
- Hobson HP: Surgical procedures of the penis, in Bojrab MJ (ed): *Current Techniques in Small Animal Surgery*, ed 4. Baltimore, Williams & Wilkins, 1998, pp 527–534.
- Pope ER, Swaim SF: Surgical reconstruction of a hypoplastic prepuce. *JAAHA* 22:73–77, 1986.
- Smith MM, Gourley IM: Preputial reconstruction in a dog. *JAVMA* 196:1493–1496, 1990.
- Ader PL, Hobson HP: Hypospadias: A review of the veterinary literature and report of three cases in the dog. *JAAHA* 14:721–727, 1978.
- Hayes Jr HM, Wilson GP: Hospital incidence of hypospadias in dogs in North America. *Vet Rec* 118:605–606, 1986.
- Hobson HP: Surgical pathophysiology of the penis, in Bojrab MJ (ed): *Disease Mechanisms in Small Animal Surgery*, ed 2. Philadelphia, Lea & Febiger, 1993, pp 552–559.
- Meyers-Wallen VN, Patterson DF: Disorders of sexual development in dogs and cats, in Kirk RW (ed): *Kirk's Current Veterinary Therapy X: Small Animal Practice*. Philadelphia, WB Saunders Co, 1989, pp 1261–1269.
- Howard PE, Bjorling DE: The intersexual animal: Associated problems. *Probl Vet Med* 1:74–84, 1989.
- Johnston DE: Repairing lesions of the canine penis and prepuce. *Mod Vet Pract* 46:39–47, 1965.
- Lobetti RG, Griffin HE, Nothing JO: Suspected corpus cavernosum trauma in three dogs. *Vet Rec* 137:492, 1995.
- Schneider R: Epidemiological aspects of mammary and genital neoplasia, in Morrow DA (ed): *Current Therapy in Theriogenology*. Philadelphia, WB Saunders Co, 1980, pp 636–639.
- Root Kustritz MV: Disorders of the canine penis. *Vet Clin North Am Small Anim Pract* 31:247–257, 2001.
- Rogers KS, Walker MA, Dillon HB: Transmissible venereal tumor: A retrospective study of 29 cases. *JAAHA* 34:463–470, 1998.
- Cooley DM, Waters DJ: Tumors of the male reproductive system, in Withrow SJ, MacEwen EG (eds): *Small Animal Clinical Oncology*, ed 3. Philadelphia, WB Saunders Co, 2001, pp 478–489.
- Boscos C: Canine transmissible venereal tumor: Clinical observations and treatment. *Anim Fam* 3:10–15, 1988.
- Hayes AG, Pavletic MM, Schwartz A, Boudrieau RJ: A preputial splitting technique for surgery of the canine penis. *JAAHA* 30:291–295, 1994.
- Copland MD: Prolapse of the penile urethra in a dog. *N Z Vet J* 23:180–181, 1975.
- Hobson HP, Heller RA: Surgical correction of prolapse of the male urethra. *Vet Med Small Anim Clin* 66:1177–1179, 1971.
- Sinibaldi KR, Green RW: Surgical correction of prolapse of the male urethra in three English Bulldogs. *JAAHA* 9:450–453, 1973.
- McDonald RK: Urethral prolapse in a Yorkshire terrier. *Compend Contin Educ Pract Vet* 11(6):682–683, 1989.
- Osborne CA, Sanderson SL: Medical management of urethral prolapse in male dogs, in Bonagura JD (ed): *Kirk's Current Veterinary Therapy XII: Small Animal Practice*. Philadelphia, WB Saunders Co, 1995, pp 1027–1029.
- Birchard SJ: Surgical treatment of urethral prolapse in male dogs, in Bojrab MJ (ed): *Current Techniques in Small Animal Surgery*, ed 4. Baltimore, Williams & Wilkins, 1998, pp 475–477.
- Hutchison JA: Persistence of the penile frenulum in dogs. *Can Vet J* 14:71, 1973.
- Ryer KA: Persistent penile frenulum in a cocker spaniel. *Vet Med Small Anim Clin* 74:688, 1979.
- Balke J: Persistent penile frenulum in a cocker spaniel. *Vet Med Small Anim Clin* 76:988–990, 1981.
- Proescholdt TA, De Young DW, Evans LE: Preputial reconstruction for phimosis and infantile penis. *JAAHA* 13:725–727, 1977.
- Stead AC: Fracture of the os penis in the dog—Two case reports. *J Small Anim Pract* 13:19–22, 1972.
- Kelly SE, Clark WT: Surgical repair of fracture of the os penis in a dog. *J Small Anim Pract* 36:507–509, 1995.
- Denholm TC: Fracture of the os penis. *Vet Rec* 69:15, 1957.
- Bennet D, Baughan J, Murphy F: Wedge osteotomy of the os penis to correct penile deviation. *J Small Anim Pract* 27:379–382, 1986.
- Root Kustritz MV, Olson PN: Theriogenology question of the month. *JAVMA* 214:1483–1484, 1999.
- Orima H, Tsutsui T, Waki T, et al: Surgical treatment of priapism observed in a dog and a cat. *Jpn J Vet Sci* 51:1227–1229, 1989.
- Christie TR: Phimosis and paraphimosis, in Bojrab MJ (ed): *Pathophysiology in Small Animal Surgery*. Philadelphia, Lea & Febiger, 1981, pp 442–443.
- Sarierler M, Kara ME: Congenital stenosis of the preputial orifice in a dog. *Vet Rec* 143:201, 1998.

46. Pope ER: Surgery of the penis, prepuce and scrotum. *Proc ACVS Vet Symp*:492-494, 1997.
47. Thamm DH, Vail DM: Mast cell tumors, in Withrow SJ, MacEwen EG (eds): *Small Animal Clinical Oncology*, ed 3. Philadelphia, WB Saunders Co, 2001, pp 261-282.
48. Croshaw JE, Brodey RS: Failure of preputial closure in a dog. *JAVMA* 136:450-452, 1960.

ARTICLE #2 CE TEST

The article you have read qualifies for 1.5 contact hours of Continuing Education Credit from the Auburn University College of Veterinary Medicine. Choose the best answer to each of the following questions; then mark your answers on the postage-paid envelope inserted in *Compendium*.

1. Cranial advancement of the prepuce should not be performed in cases of
 - a. paraphimosis caused by preputial muscle ineffectiveness.
 - b. idiopathic paraphimosis.
 - c. preputial hypoplasia.
 - d. paraphimosis following trauma.
2. Vincristine chemotherapy may be used to treat penile TVTs at a dose of _____ mg/m².
 - a. 0.2
 - b. 0.1
 - c. 0.5 to 0.7
 - d. 1
3. Which of the following statements regarding the treatment of urethral prolapse is true?
 - a. Surgical excision of the prolapsed mass is necessary.
 - b. Spontaneous resolution of the prolapse is common.
 - c. Castration is effective in treating urethral prolapse.
 - d. Hormonal therapy should be included in the treatment protocol for urethral prolapse.
4. Priapism may result from
 - a. a spinal cord lesion.
 - b. constipation.
 - c. genitourinary infection.
 - d. all of the above
5. Which of the following conditions is not included in the diagnostic differentials of urethral prolapse?
 - a. stricture
 - b. tumor
 - c. calculus
 - d. phimosis
6. Which of the following tumors is commonly located in the prepuce?
 - a. melanoma
 - b. mastocytoma
 - c. lymphoma
 - d. osteosarcoma
7. Which of the following is not recommended for the treatment of preputial hypoplasia?
 - a. staged reconstructive surgery using skin flaps and oral grafts
 - b. mesh skin graft
 - c. partial penile amputation
 - d. cranial preputial advancement
8. Which of the following conditions does not predispose a dog to urethral obstruction?
 - a. persistent penile frenulum
 - b. os penis deformity
 - c. os penis fracture
 - d. paraphimosis
9. Which of the following statements regarding the management of hypospadias is false?
 - a. Dogs with hypospadias always require surgical correction.
 - b. Dogs with mild hypospadias may require no surgical treatment.
 - c. Dogs with severe hypospadias may need penile amputation and urethrostomy.
 - d. Surgical correction depends on the severity and location of hypospadias.
10. The prepuce in dogs with full-thickness lacerations should be closed
 - a. using one suture layer.
 - b. using two suture layers.
 - c. using healing by second intention.
 - d. by suturing the mucosa with nonabsorbable suture material.