

Physical Examination of the Wrist: Useful Provocative Maneuvers

William B. Kleinman, MD

Chronic wrist pain resulting from partial interosseous ligament injury remains a diagnostic dilemma for many hand and orthopedic surgeons. Overuse of costly diagnostic studies including magnetic resonance imaging, computed tomography scans, and bone scans can be further frustrating to the clinician because of their inconsistent specificity and reliability in these cases. Physical diagnosis is an effective (and underused) means of establishing a working diagnosis of partial ligament injury to the wrist. Carefully performed provocative maneuvers can be used by the clinician to reproduce the precise character of a patient's problem, reliably establish a working diagnosis, and initiate a plan of treatment. Using precise physical examination techniques, the examiner introduces energy into the wrist in a manner that puts load on specific support ligaments of the carpus, leading to an accurate diagnosis. This article provides a broad spectrum of physical diagnostic tools to help the surgeon develop a working diagnosis of partial wrist ligament injuries in the face of chronic wrist pain and normal x-rays. (*J Hand Surg Am.* 2015; ■(■): ■–■. Copyright © 2015 by the American Society for Surgery of the Hand. All rights reserved.)

Key words Carpus (wrist), physical examination, ligament injuries, provocative maneuvers, anatomy.

OVER THE PAST HALF-CENTURY, a plethora of clinical and laboratory research has been published on the kinesiology and biomechanics of the wrist joint. Gross and micro cadaver dissections have elucidated details of wrist anatomy; sophisticated imaging studies have clearly defined mechanisms of carpal motion; and mechanical studies under load-to-failure conditions have contributed to a deeper understanding of the carpus, including small aggregates of motion among carpals that allow the wrist to function like a ball-and-socket joint.

PATHOMECHANICS OF CARPAL LIGAMENT INJURY

The complex nature of carpal mechanics can be simplified by considering the distal carpal row (trapezium, trapezoid, capitate, and hamate) as securely attached to the medial 4 metacarpals through short, tight, intrinsic ligaments. The distal row moves with the hand as a single unit. The proximal carpal row (scaphoid, lunate, and triquetrum) can be considered a single free-body, intercalated between the hand (including the distal row) and the forearm, suspended by extrinsic radiocarpal and intrinsic intercarpal ligaments (Fig. 1). As the hand–forearm unit moves the wrist, the position of the intercalary proximal row shifts at the radiocarpal joint (relative to the forearm) and at the midcarpal joint (relative to the hand), similar to a ball-and-socket joint. The carpal mechanism depends on the health and integrity of the intrinsic and extrinsic ligaments to guide bony relationships among the 7 critical carpals (pisiform excluded).

Carpal alignment at rest is maintained with considerable stored potential energy and, by definition, a

From the Indiana Hand to Shoulder Center, Indianapolis, IN.

Received for publication December 15, 2014; accepted in revised form January 13, 2015.

No benefits in any form have been received or will be received related directly or indirectly to the subject of this article.

Corresponding author: William B. Kleinman, MD, The Indiana Hand to Shoulder Center, and the Department of Orthopaedic Surgery, Indiana University School of Medicine, 8501 Harcourt Road, Indianapolis, IN 46260; e-mail: wbk@hand.md.

0363-5023/15/ ■ ■ -0001\$36.00/0
<http://dx.doi.org/10.1016/j.jhssa.2015.01.016>

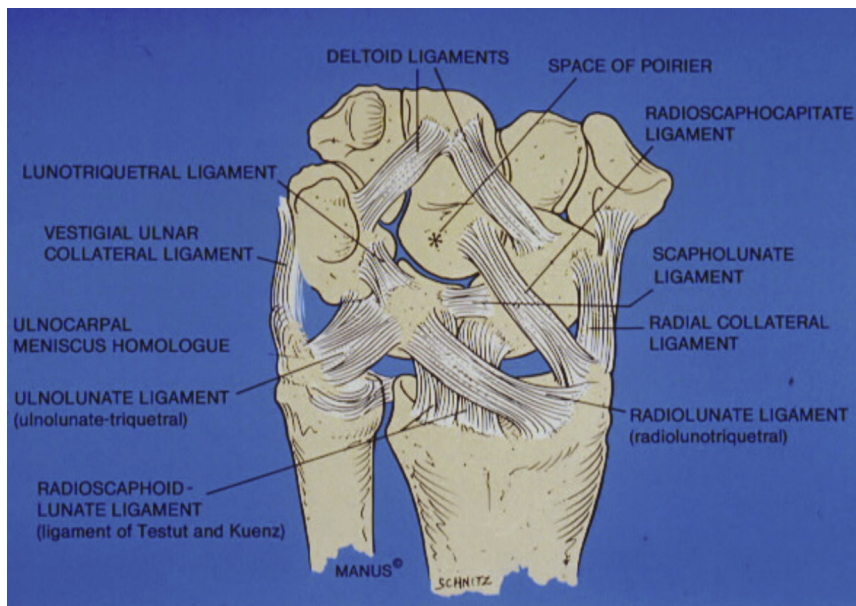


FIGURE 1: The proximal carpal row, consisting of scaphoid, lunate, and triquetrum, is suspended as an intercalated segment between the hand (distal carpal row) and forearm (radius and ulna). Major palmar ligaments serve as struts and guy-wires that allow the proximal row to move as a free body in space between the hand and forearm. By changing its position between the moving hand and forearm, the wrist behaves like a ball and socket, generating a full arc of circumduction by small aggregates of motion from each intercarpal joint.

predisposition of the carpus to collapse into a more stable but less physiologic attitude. Ligamentous struts and guy wire mechanisms maintain the longitudinal axis of the scaphoid at about 47° relative to the longitudinal axis of the hand–forearm unit (Fig. 2).¹ A neutral position of the lunate is maintained through its secure attachment to the proximal scaphoid pole by the scapholunate (SL) interosseous ligament. Separated from the palmar-flexing influence of the scaphoid, the lunate is predisposed to collapse into extension (Fig. 3). In physics terms, “carpal instability” is a misnomer. Whereas healthy ligaments maintain normal carpal alignment, their failure either by injury or disease will result in predictable patterns of carpal collapse into physically more stable but less physiologic relationships.

Anatomic carpal alignment (stored potential energy and predisposition to collapse) is a prerequisite for healthy wrist biomechanics. Loss of ligament support by injury or disease dissipates potential energy as kinetic energy and results in collapse of the carpus. Inherent in carpal collapse is either subtle or overt disintegration of healthy bony alignment of the components of the intercalated proximal row. Dissipation of kinetic energy, collapse of the carpus, and reorientation of articular surfaces result in surface cartilage shear. Hyaline cartilage loss from chronic shear forces leads to painful degenerative arthritis.

Normally, hyaline cartilage surfaces are apposed in compression along a principal axis of load bearing regardless of the position of the hand relative to the forearm. (The principal axis is an engineering term used to define an imaginary point at the center of an infinite number of cluster points between 2 loaded surfaces in contact with each other.) The principal axis of load bearing across the carpus constantly shifts as the hand circumducts. The intercalated proximal row translates and rotates to maintain surface cartilage contact in compression mode, guided by healthy ligaments. Alignment of surface cartilage in compression mode allows the wrist to function painlessly like a ball and socket. Ligament damage that allows carpal collapse (dissipation of stored potential energy) will result in a wrist that is physically more stable, but with joint surfaces aligned in shear rather than compression, and eventual pain from synovitis and cartilage loss.

An example is static SL dissociation (Fig. 4). A healthy SL interosseous ligament normally prevents separation and malrotation of the scaphoid and lunate relative to each other. Without structural integrity of the SL ligament, the scaphoid will collapse from its approximately 47° attitude into a position relatively more perpendicular to the longitudinal axis of the hand–forearm unit. Scapholunate separation results in lunate extension into dorsiflexion intercalated segment

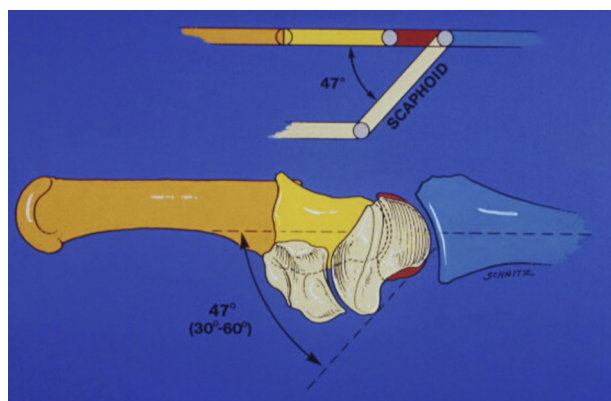


FIGURE 2: The scaphoid is suspended by extrinsic and intrinsic carpal ligaments at approximately 47° relative to the longitudinal axis of the radius. This position is maintained by intercarpal ligaments with stored potential energy and a predisposition to collapse if separated from its neighbors by ligamentous injury or disease.

instability¹ as the palmar-flexing influence of the scaphoid on the lunate is lost. The lunate slides palmarly on the radius, tilting into extension. Scapholunate dissociation, with its inherent scaphoid malalignment, leads to insidious degenerative changes as joint malalignment converts surface shear rather into surface compression, first between the radial styloid and scaphoid, then between the proximal scaphoid pole and scaphoid fossa of the radius, and finally between the radial surface of the lunate and the adjacent medial border of the translating capitate at the midcarpal joint.² These predictable and sequential degenerative cartilage changes are referred to as scapholunate advanced collapse wrist (Fig. 5).

If the restraining ligaments holding healthy anatomic relationships among carpals are only partially injured, the carpus will not collapse. Even partially damaged ligaments can become painful and chronically debilitating to the patient. It can be challenging for the surgeon to make a definitive diagnosis of a partial intercarpal ligament tear because multiple etiologies can result in pain and tenderness in the wrist. X-rays (including stress views) are not helpful because they are invariably normal. Even special studies such as computed tomography or magnetic resonance imaging are of little value in diagnosing partial ligament tears.

PHYSICAL DIAGNOSIS

Physical diagnosis can provide considerable information for identifying a partial wrist ligament injury. The provocative maneuvers described below emphasize the value of introducing energy into a damaged or diseased system in an effort to provoke a response of

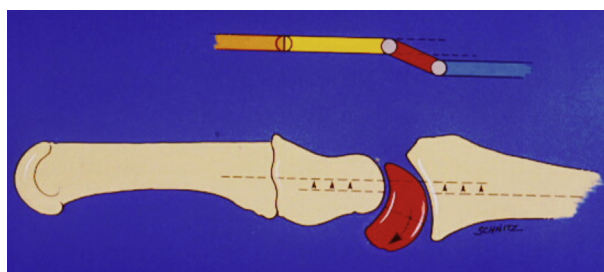


FIGURE 3: Separated from the palmar-flexing influence of the scaphoid, the lunate slides palmarly on the articular surface of the radius and rolls into extension. Non-axisymmetric axes of rotation between midcarpal and radiocarpal joints are principally responsible for lunate dorsiflexion intercalated segment instability¹ when the lunate is separated from the palmar-flexing influence of the scaphoid.

greater pain from the patient being examined. The reliability of each test described below is high, as is its specificity. The response of each maneuver must be compared with the opposite healthy wrist for validity.

SCAPHOLUNATE JOINT

Injuries to the SL interosseous ligament most commonly occur after a fall onto an outstretched hand while the wrist is in extension and ulnar deviation (Fig. 6). Impact is at the thenar eminence, forcing the hand into supination as the forearm pronates. In their classic article, Mayfield et al³ emphasized the importance of the magnitude of energy entering the wrist at the time of impact. In wrist extension, ulnar deviation, and supination torque relative to a pronating forearm, ligaments fail sequentially in tension: Minor trauma results in stage 1 injury to the SL ligament complex (Fig. 7) that will be only partially disrupted. Stage 1 injuries lead to chronic wrist pain and tenderness at the dorsal SL joint (Fig. 8) but no radiographically demonstrable collapse of the carpus. When the energy of impact is sufficient to tear the SL ligament completely (stage 2), collapse of the carpus can be readily seen on plain x-ray (Fig. 4).

Wrist pain with local tenderness of the dorsal SL joint (without swelling) is one of the more common patient symptoms seen by a hand surgeon. Except for rare conditions, only 4 diagnoses mimic chronic SL injury and normal wrist x-rays (including an axial-loading grip view and an ulnar deviation anteroposterior view through the SL ligament, compared with the healthy contralateral side) (Fig. 9): (1) occult dorsal carpal ganglion cyst; (2) scaphoid impaction; (3) dorsal carpal impingement syndrome, sometimes referred to as type II gymnast's wrist; and (4) dynamic or pre-dynamic SL instability, which should not to be

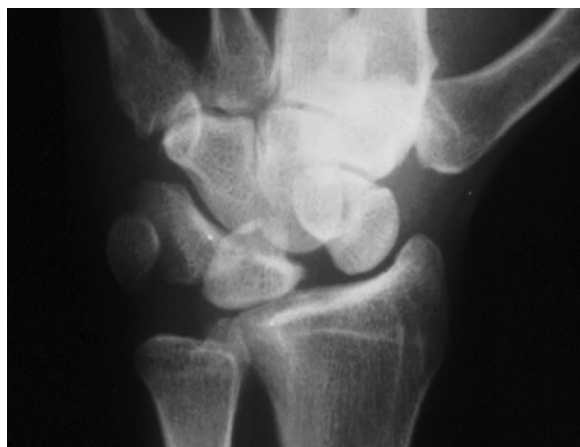

FIGURE 4: X-ray showing Mayfield and Johnson³ stage 2 progressive perilunar instability. With total failure of the interosseous SL, the scaphoid collapses into flexion, the scaphoid and lunate separate, and the lunate extends. The hand (distal row) migrates radially and proximally, fully engaging the triquetrum at the triquetrum-hamate joint and forcing the LT unit into extension.

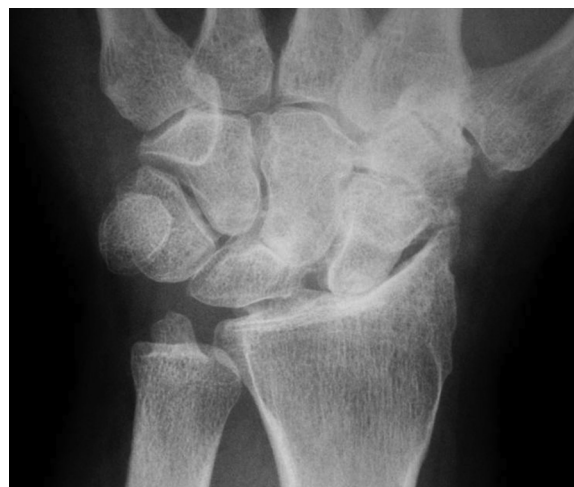

FIGURE 5: X-ray showing the end stage of static SL dissociation (ie, SL advanced collapse).² Predictable degenerative changes occur at the radial styloid–scaphoid interface first, followed by degeneration at the radius elliptical (scaphoid) fossa and then the capitolunate joint.

confused with type I gymnast's wrist, or premature physal closure of the palmar-medial growth plate of the distal radius as a result of-term, repetitive superphysiologic load.⁴

Occult dorsal carpal ganglion cysts are common but difficult to diagnose, even with adequate history and physical examination. They should always be considered in the differential diagnosis of dorsal wrist pain.⁴ In addition to pain at the end arc of motion under load, their only physical manifestation is point tenderness at the dorsal-distal margin of the SL ligament. Ultrasonography and/or magnetic resonance imaging can provide a definitive diagnosis (Fig. 9B).

Scaphoid impaction is often diagnosed by a careful history and physical examination. Onset of chronic pain follows a single hyperextension injury, usually a hard fall on an outstretched hand. A thin transchondral or osteochondral divot can be knocked off the dorsal scaphoid proximal pole immediately adjacent to the dorsal SL ligament, as the hyperextended hand drives the dorsal neck of the scaphoid against the dorsal margin of the distal radius. The resulting defect is usually small ($< 1 \text{ cm}^2$). Its proximity to the dorsal SL ligament and associated tenderness can easily be confused with an SL ligament injury. A suspicion of scaphoid impaction can be corroborated by a positive 3-phase bone scan. Wrist arthroscopy can also be helpful in making a definitive diagnosis (Fig. 9A).

Gymnast's wrist⁵ also can present with symptoms and signs suggestive of SL ligament pathology. Chronic, repetitious superphysiologic load bearing on a hyperextended wrist (eg, long gymnastic workouts

on a pommel horse) can result in hypertrophic dorsal carpal synovitis richly loaded with free nerve endings. Thickened synovial tissue overlying the dorsal SL ligament becomes a sensitive, space-occupying lesion tender to palpation (Fig. 9C).

Dynamic (and/or pre-dynamic) SL instability completes the differential diagnosis of wrist pain, SL tenderness, and normal plain x-ray. This condition results from partial injury to the SL ligament, insufficient to dissociate the 2 bones at rest but enough to partially destabilize the SL relationship, causing pain with load bearing.

Diagnosis of dynamic (or pre-dynamic) SL instability

Diagnosis is most readily made using provocative maneuvers. A thorough understanding of wrist biomechanics is necessary to fully appreciate how these physical diagnostic techniques can be used.

In neutral wrist position, the average normal scaphoid attitude relative to a longitudinally aligned hand-forearm is approximately 47° (range, 30° to 60°) (Fig. 2).¹ X-ray measurements form an angle between the lateral longitudinal axis of the hand-forearm unit (third metacarpal and radius) and a line drawn across the palmar tips of the distal and proximal poles of the scaphoid. Because of its shape and position in the carpus, an internal force couple exists between load delivered to the articular surface of the distal scaphoid pole and that absorbed by the proximal pole at the scaphoid fossa of the radius (Fig. 10).⁶ If separated from the lunate, under physiologic load the scaphoid will collapse into a more stable (but less

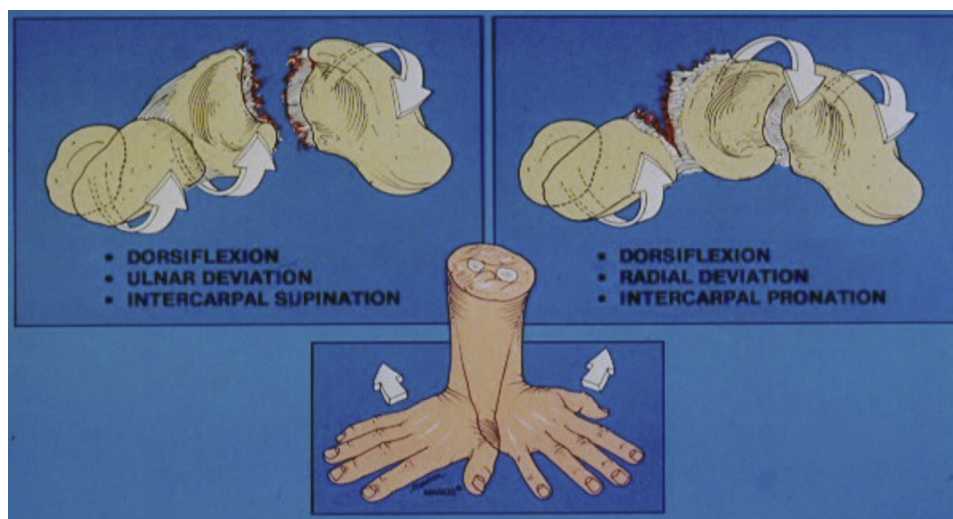


FIGURE 6: The position of the hand on the forearm at the time of impact load determines the location of tension forces. Ligament failure occurs in tension on either the lateral (ulnar deviation) or medial (radial deviation) side of the carpus.

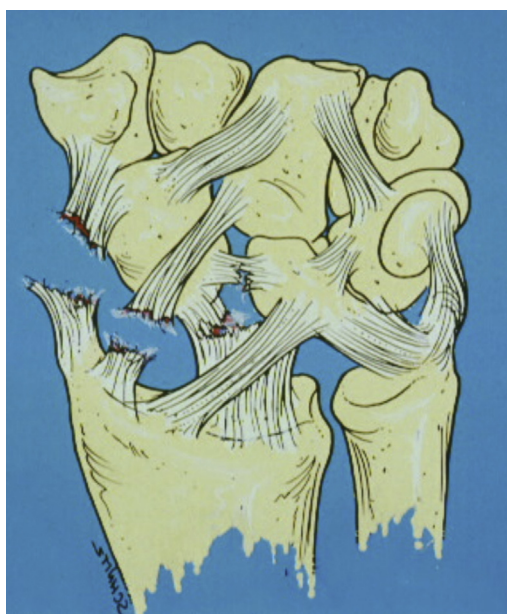

FIGURE 7: Ligament failure in extension, ulnar deviation, and intercarpal supination is progressive. In stage 1 progressive perilunar instability, energy expended is sufficient to cause failure of the radial collateral ligament and radioscapohcapitate ligament, and the radioscapohoid portion of the ligament of Testut and Kuenz, ending with incomplete injury to the SL interosseous ligament.

physiologic) position perpendicular to the plane of the palm. The lunate will slide palmar on the distal radius articular surface and extend (Fig. 3). Factors responsible for this are the taller palmar pole of the lunate relative to its dorsal pole, making it wedge-shaped in the lateral projection; a normal 10° to 12° palmar tilt of the distal radius; the relative paucity of supporting ligaments on the dorsum of the lunate; and

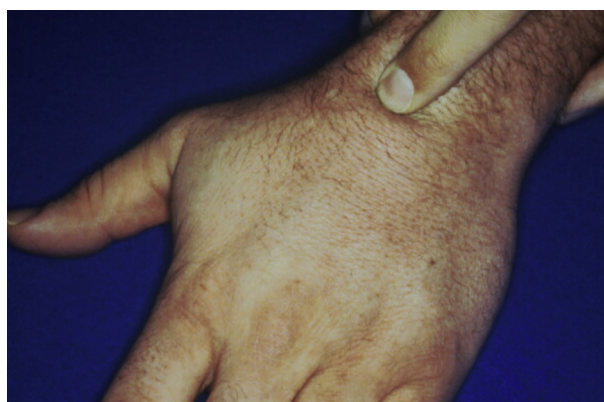

FIGURE 8: Partial injury to the SL ligament is manifested by point tenderness on the dorsal SL ligament.

non-axisymmetric axes of rotation of the radiocarpal and midcarpal joints, giving the lunate its own internal force couple and propensity to extend under load if left to its own volition (Fig. 11).^{7,8}

In the presence of a healthy SL ligament, different radii of curvature between scaphoid and lunate, and the microanatomy of the SL ligament allow the scaphoid to flex physiologically through twice the arc of motion as the flexing lunate; in extension, the arc of motion of both bones is essentially equal.^{7,8}

As the hand deviates ulnarly, the scaphoid is pulled by intrinsic scaphotrapezium-trapezoid ligaments into a more longitudinal attitude (extended) relative to the plane of the palm. Simultaneously, the lunate is pulled more squarely onto the spherical (lunate) fossa of the radius through the intact SL ligament (Fig. 12A, B). The effect of the scaphoid on the lunate in ulnar deviation is commonly referred to

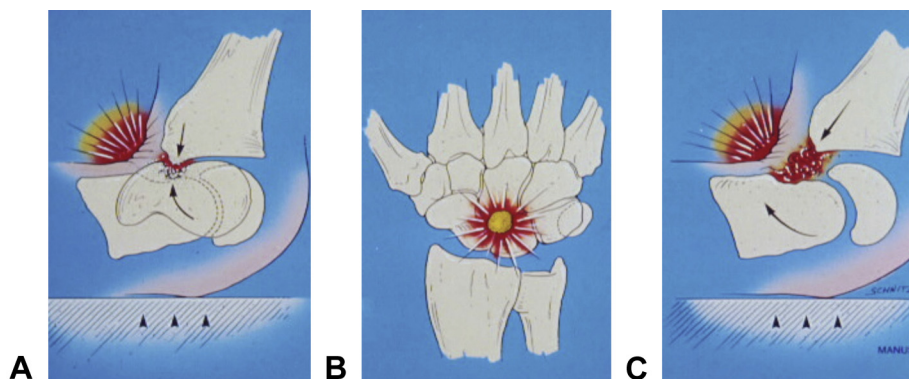


FIGURE 9: Three of 4 conditions can manifest themselves as focal SL point tenderness: **A** scaphoid impaction, **B** occult dorsal carpal ganglion, and **C** dorsal carpal impingement syndrome. Not pictured is dynamic SL instability, a fourth condition that can manifest as SL tenderness (see text).

as its carpal-shift influence.⁹ In ulnar deviation, both the scaphoid and the lunate are extended.

In radial deviation, the hand is brought closer to the forearm, narrowing the space available for the scaphoid between the trapezium–trapezoid unit and the radius (Fig. 13A, B). Lacking available space, the scaphoid is pushed into flexion, reducing the scaphoid angle. The flexing scaphoid drags the lunate into flexion (through the healthy SL ligament) and pushes the lunate ulnarly onto the triangular fibrocartilage complex (TFCC). This action of scaphoid and lunate together is the foundation for one of the most effective provocative maneuvers a surgeon can use in a complete wrist examination: the scaphoid shift test, or the Watson maneuver.¹⁰

Described by Watson et al¹⁰ for stress-testing the integrity of the SL ligament after injury, the scaphoid shift test should be used especially when plain x-rays are normal. Radiographic studies to rule out SL instability should include: (1) an anteroposterior (or posteroanterior) view straight through the SL ligament with hand–forearm alignment at 0°; (2) a true lateral projection to measure the scaphoid angle relative to the longitudinal axis of the hand–forearm unit; (3) an axial-loading grip view, stress-testing the SL ligament to determine whether increasing the joint reaction force across the wrist will result in the head of the capitate driving the wedge-shaped scaphoid and lunate apart; and (4) an ulnar deviation view to determine whether there has been loss of carpal shift influence⁹ of the scaphoid on the lunate, resulting in diastasis between the 2 bones. These x-rays must be compared with the contralateral wrist.

Scaphoid shift test (Watson maneuver)

The examiner and the patient are seated opposite each other at a hand examination table. The patient places

the elbow of the affected right wrist on the table, fingers toward the ceiling and forearm in neutral rotation. The examiner deviates the patient's hand ulnarly on his forearm, lifting the scaphoid into a more longitudinal (extended) attitude. He then places his right thumb tip securely under the distal pole of the scaphoid in an effort to keep it from flexing into a perpendicular attitude with passive wrist radial deviation. As the right thumb holds the distal pole of the scaphoid in extension, the left hand passively radially deviates the patient's hand, decreasing the distance between trapezium-trapezoid and the radius (Fig. 14A, B). The scaphoid is compressed by the decreasing distance between the patient's hand and forearm but it is kept from flexing by the examiner's right thumb. The maneuver is performed slowly and repeatedly, each time with the examiner's right thumb precluding scaphoid flexion (Fig. 15A, B).

In a patient with a partial SL ligament injury, load against the distal pole of the scaphoid will be transmitted along the scaphoid longitudinal axis to its proximal pole. To dissipate energy of the scaphoid being squeezed by passive wrist radial deviation (with nowhere for it to flex because of the examiner's right thumb), the proximal pole will tend to lift dorsally out of the elliptical (scaphoid) fossa of the radius. The result of the test will be pain (relative to the opposite side) and/or an audible or palpable sign of SL instability.¹⁰ The frequency of sound created (eg, a higher-frequency click or a lower-frequency clunk) will be based on how much partial damage has been incurred by the SL ligament and how much the proximal pole of the scaphoid will subluxate over the dorsal margin of the radius. The scaphoid shift test is used only if the patient's symptoms are chronic wrist pain with local tenderness in the dorsal SL ligament.

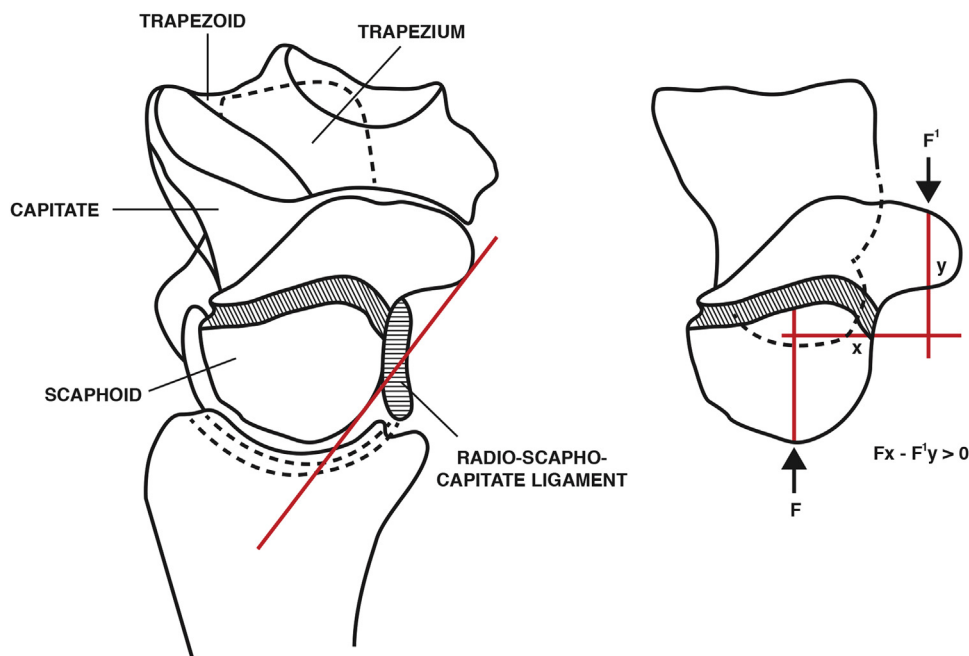


FIGURE 10: The approximately 47° attitude of the scaphoid relative to the longitudinal axis of the radius creates an internal force couple and predisposition of the scaphoid to collapse into flexion, around an axis of rotation provided by the radioscapohcapitate ligament.^{6–9}

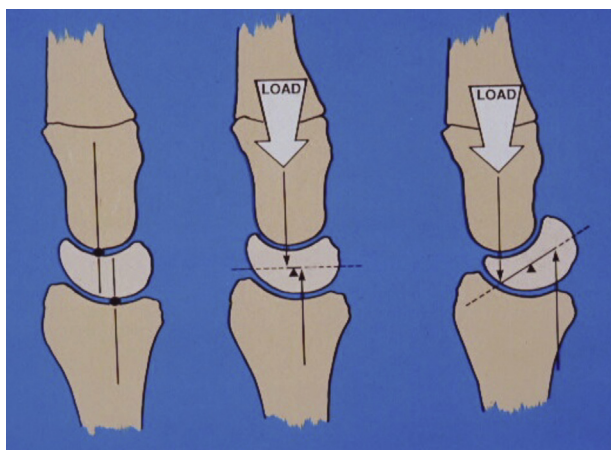


FIGURE 11: Because of offset non-axisymmetric axes of rotation at the radiocarpal and midcarpal joints, an internal force couple exists within the lunate, predisposing it to slide palmarly on the palmarly tilted distal radius joint surface and roll into extension.^{7,8}

If the SL ligament has minimal damage, neither palpable nor audible signs will be encountered with the scaphoid shift test. The patient will experience only pain. This test and all others described must be compared with the opposite, uninjured wrist.

Provocative maneuver for pre-dynamic SL instability

A specific test for minor injury to the SL ligament is simply to ask the patient to extend the fingers

maximally with the wrist flexed. This maneuver increases the joint reaction force between the capitate and the SL unit, driving the head of the capitate between the 2 bones and increasing tension on the SL ligament. Patients with minor SL instability and chronic wrist pain will experience increased pain with this provocative maneuver. The classic scaphoid shift test can be used in patients with minor injury to the SL ligament (pre-dynamic instability), as well.

In the absence of x-ray changes, these 2 provocative maneuvers can be useful in making a diagnosis of subtle injury to the SL ligament of the wrist.

LUNATOTRIQUETRAL JOINT

Injuries to the lunatotriquetral (LT) joint commonly occur with the hand–forearm unit positioned in extension and radial deviation at the time of impact load (Fig. 6). An example of this mechanism of injury is driving an automobile with hands holding the steering wheel at the 10- and 2-o'clock positions. The car is hit broadside from the right front with a high-energy impact while the hands grip the steering wheel tightly (both wrists in extension). On impact, the front wheels of the car are wrenched to the right, spinning the tightly gripped steering wheel and torquing the extended left wrist into pronation and radial deviation. This causes sprain of the LT ligament.

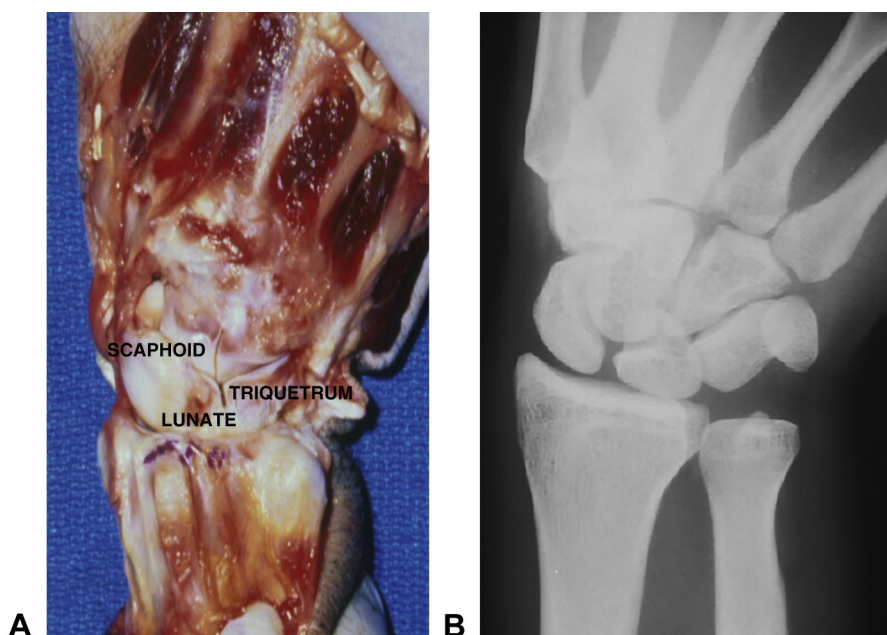


FIGURE 12: Cadaver specimen **A** and X-ray film **B** show how, in ulnar deviation, the scaphoid is pulled into an extended longitudinal attitude, shifting the lunate laterally and more squarely onto the spherical (lunate) fossa of the radius and fully engaging the triquetrum joint, forcing the triquetrum and lunate into extension.

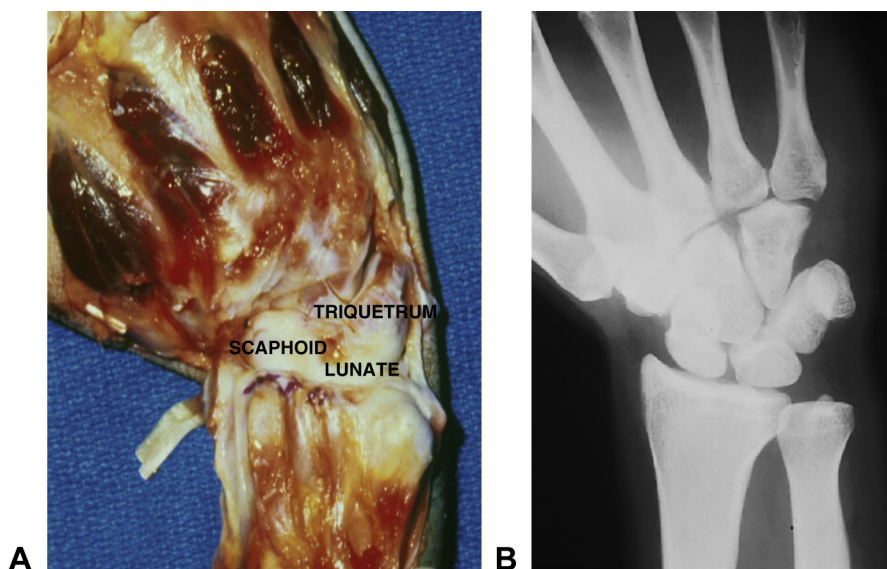


FIGURE 13: Cadaver specimen **A** and X-ray film **B** show how, in radial deviation, the space available between the hand (trapezium and trapezoid) and the forearm is decreased, forcing the scaphoid into flexion. The palmar-flexing scaphoid flexes the lunate through an intact interosseous SL ligament. Radial deviation also disengages the triquetrum from the influence of the hamate, allowing the entire proximal row to flex.

Severe LT instability is defined in this type of injury by complete separation of the SL unit from the triquetrum and collapse of the scaphoid and lunate together into flexion (Fig. 16). Separated from any influence of the triquetrum, the palmar-flexing scaphoid and lunate dissipates stored potential energy and collapses into the more stable (but less physiologic)

position defined by Linscheid and Dobyns as volar intercalated segment instability.¹ The interosseous LT ligament is completely torn, the palmar LT ligament is disrupted, and the dorsal radiotriquetral ligament is avulsed from the triquetrum.^{11–13} After a severe LT ligament complex blowout, the internal force couple within the scaphoid precipitates scaphoid flexion, and

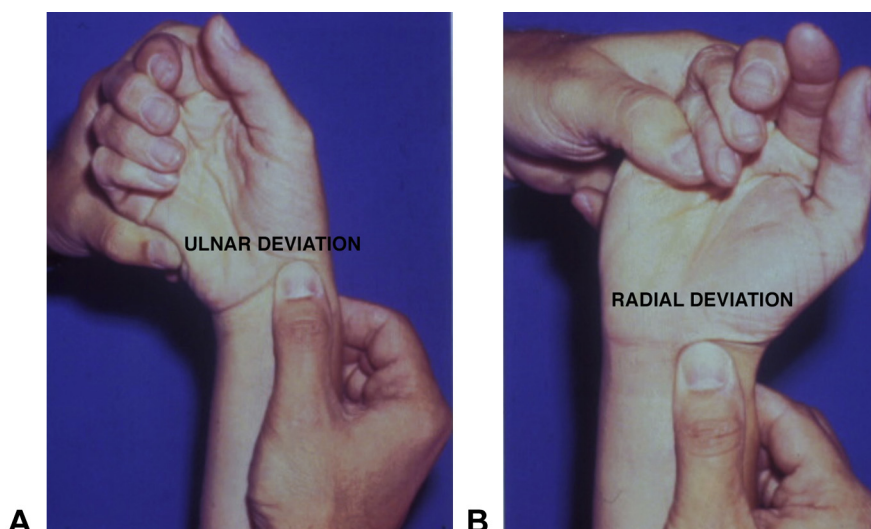


FIGURE 14: The scaphoid shift test (Watson maneuver) for dynamic SL instability.¹⁰ The examiner's thumb prevents scaphoid flexion as the patient's wrist is passively brought from **A** the extremes of ulnar deviation (scaphoid extended) to **B** the extremes of radial deviation.

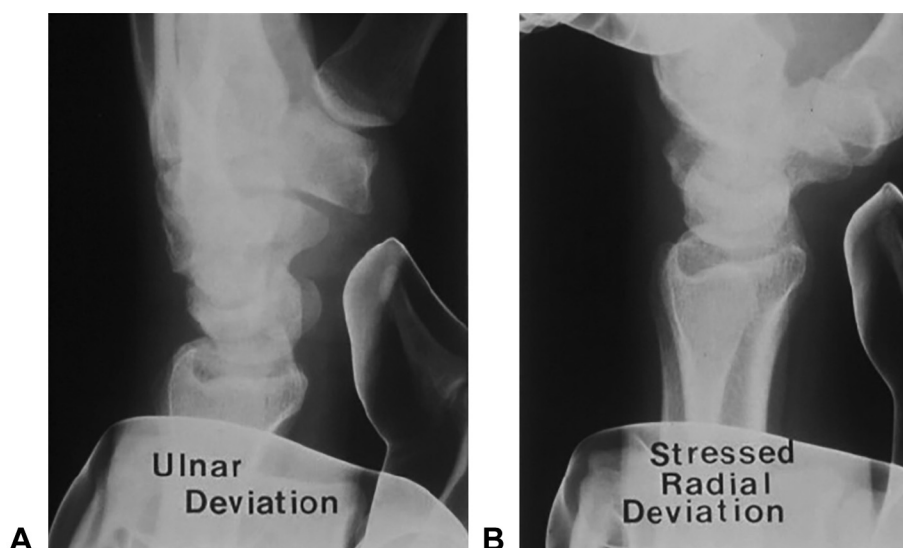


FIGURE 15: X-rays demonstrate the scaphoid shift test: The examiner's thumb prevents scaphoid flexion as the wrist is passively moved from **A** ulnar to **B** radial deviation. A positive test results in pain mechanical sounds, or both, as passive radial deviation in the face of a severely damaged SL ligament lifts the proximal pole of the scaphoid dorsally over the dorsal margin at the distal radius.

consequently lunate flexion through the uninjured SL ligament (Fig. 10).

X-rays readily confirm the diagnosis of stage III^{12,13} LT instability as severe SL flexion on true lateral projection (Fig. 16). The anteroposterior image shows no gap between scaphoid and lunate, a scaphoid cortical ring sign,¹⁴ a triangular rather than quadrangular lunate, and LT diastasis. This should not be misdiagnosed as SL dissociation. With standard posteroanterior x-rays, the hyperflexed SL unit may appear to have a diastasis between the 2 bones. The normal SL ligament has 2 distinct components according to Kauer,^{7,8} and 3

according to Berger.¹⁵ In either case, the palmar portion of the SL ligament is loose and areolar. In cases of severe LT instability, the palmar, areolar portion of the SL ligament is seen by the x-ray beam in profile, suggesting a widening, or diastasis, between the 2 bones. This normal condition may lead to misdiagnosis of a Stage 2 SL ligament injury³ because under the conditions of stage 3 LT instability the examiner sees only the normal palmar SL ligament in an unusual attitude. Perceived widening of the SL relationship can be seen in LT wrist instabilities that result in volar intercalated segment instability (Fig. 17).

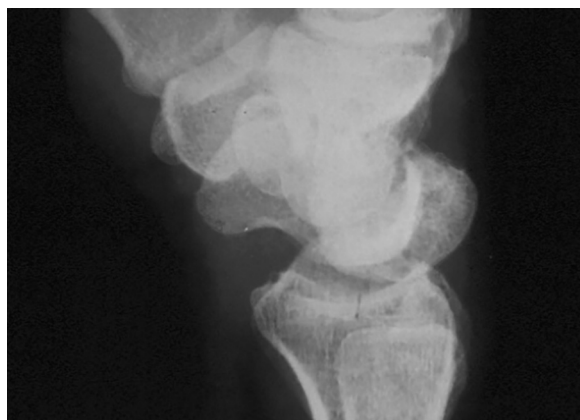

FIGURE 16: True lateral x-ray of the carpus demonstrating severe dramatic scaphoid and lunate flexion, seen in stage 3 LT instability.^{12,13} Separated palmarly and dorsally from the triquetrum, the lunate is dragged into flexion by the palmar-flexing influence of the scaphoid through an intact SL ligament.

After the automobile accident, in addition to ulnar-sided wrist pain, the injured wrist will manifest a subtle palmar sag of the hand on the forearm. The palmar-flexing scaphoid and lunate tend to spill the capitate head palmarly out of the midcarpal joint, resulting in this subtle sag.

A partial injury of the LT ligament will result if the energy of impact on the hypothetical area was less than required to completely tear palmar and dorsal ligaments surrounding the LT joint. X-rays would be normal; tenderness would be localized to the dorsal LT joint.

DIAGNOSING PARTIAL LT LIGAMENT INJURY

Partial sprains of the LT ligament complex are difficult to diagnose because x-rays are normal. Provocative maneuvers become essential in helping the surgeon establish a working diagnosis. There are 3 maneuvers that can be completed in seconds that help diagnose LT injury in the face of dorsal LT joint tenderness and normal x-rays. In each, the surgeon introduces energy into the system using the following techniques.

Ballotment test

Attributed to Linscheid (personal communication), the ballotment examination elicits LT pain by compressing the medial border of the triquetrum against the medial border of the lunate, increasing the joint reaction force at the LT joint (Figs. 18A, B, and 19). The examiner sits at a table opposite the patient. The patient's elbow is placed on the examination table with the fingers facing the ceiling.

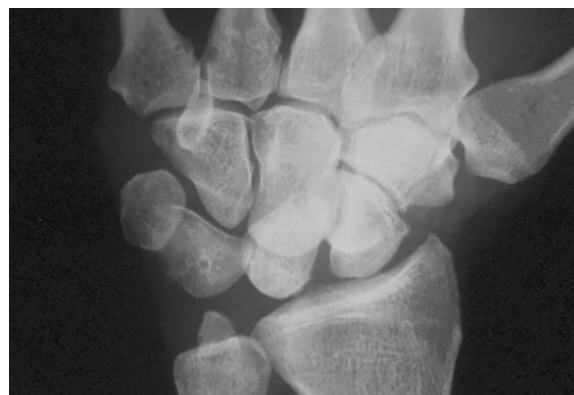


FIGURE 17: Anteroposterior x-ray of the carpus demonstrating widening of the SL interval in stage 3 LT instability. Palmar flexion of the scaphoid and lunate together puts the loose areolar portion of the SL ligament toward the x-ray beam, leading to the perception of widening of a normal SL ligament.

The forearm and wrist are held in neutral position. The examiner places his or her thumb directly on the medial body of the triquetrum and pushes it radially against the lunate in a rocking or balloting manner. The examiner's 2 hands are used to support the hand—forearm relationship. Patients with considerable damage or disease at the LT joint will report pain when this provocative maneuver is performed. Unfortunately, this technique is not specific. The force required to push the body of the triquetrum against the lunate must be of sufficient magnitude to push the triquetrum and the remaining portion of the proximal intercalated segment (lunate and scaphoid) up the normal angle of inclination of the radius. The examiner requires substantial effort to accomplish this. Simultaneous tensile forces are inadvertently placed on the ulnocarpal ligaments, the triangular fibrocartilage complex (TFCC), and even the extrinsic radiocarpal ligaments (Fig. 1). False positives results are common because of the gross effort that has to be made to perform the test adequately.

Shuck sign

Less crude than the ballotment examination is the shuck sign,¹¹ performed by grasping the dorsal body of the triquetrum and the palmar surface of the pisiform securely between the thumb and index finger (Fig. 20). The 2-bone relationship is then repeatedly shucked dorsally and palmarly to stress the LT ligament. Patients report pain if the LT ligament has been injured. Before using the shuck sign, the pisotriquetral (PT) joint must be examined and determined to be healthy. Symptoms of pain when compressing or shucking the pisiform against the triquetrum suggest PT pathology. If the PT joint is diseased or injured

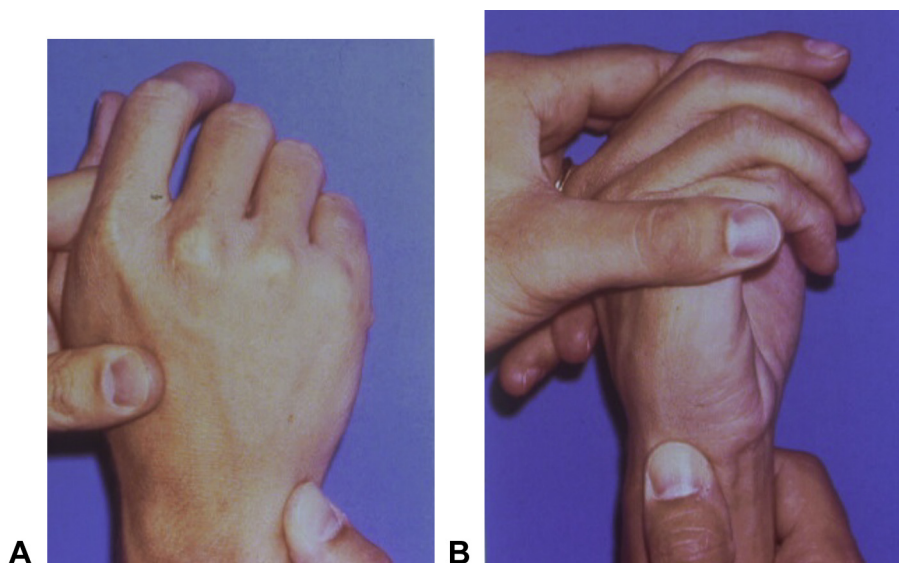


FIGURE 18: A, B The ballotment test of the LT joint relies on pressure applied to the medial border of the triquetrum to compress the LT joint, resulting in LT pain. **A** View of examination technique from the dorsum; **B** examination technique from the medial side of the wrist.

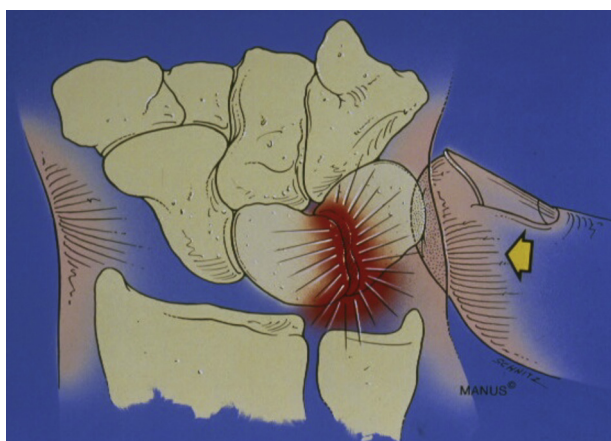


FIGURE 19: Tenderness at the LT joint caused by compression or ballotment of the triquetrum against the lunate. Yellow arrow demonstrates direction of load bearing administered using the provocative maneuver.

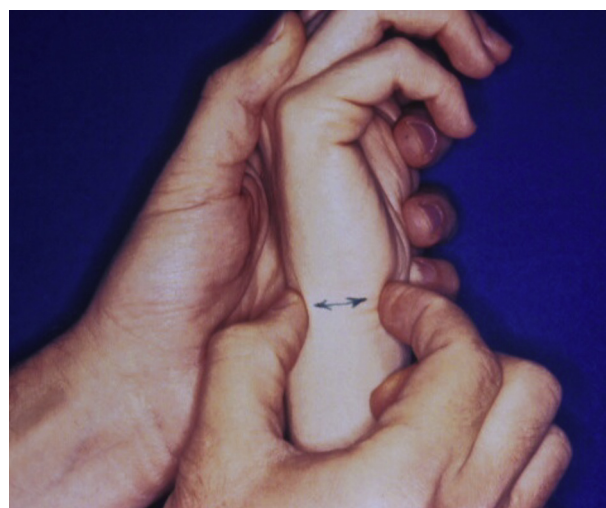

FIGURE 20: The shuck sign relies on the examiner grasping the pisiform and dorsal body of the triquetrum between his or her thumb and index finger and shucking this 2-bone relationship repeatedly dorsally and palmarly, resulting in LT pain.

(eg, osteoarthritis), false-positive findings can result from performing the LT shuck sign.

Shear test

The author designed this provocative maneuver 25 years ago because of the poor specificity of the ballotment examination and the shuck sign. The shear test affords the examiner an opportunity to titrate small aliquots of energy carefully into the system, which makes it a reliable test for subtle instability of the LT joint. As with ballotment and shuck, the patient's elbow rests on the table with the forearm in neutral rotation and fingers toward the ceiling. Both

of the examiner's hands support the hand–forearm unit (Fig. 21A). If the right LT joint is being examined, the examiner's right thumb is placed on the palmar pisiform. The tip of the left thumb is placed squarely on the dorsal body of the lunate (Fig. 21B). In neutral position, two-thirds of the lunate sits on the spherical lunate fossa of the radius; one-third sits on the TFCC articular disc. It is easy to find the dorsal body of the lunate by palpating the medial edge of the distal radius and then moving the thumb distally. If the left wrist is being examined, the examiner's hands are reversed. Before performing the shear test, the PT

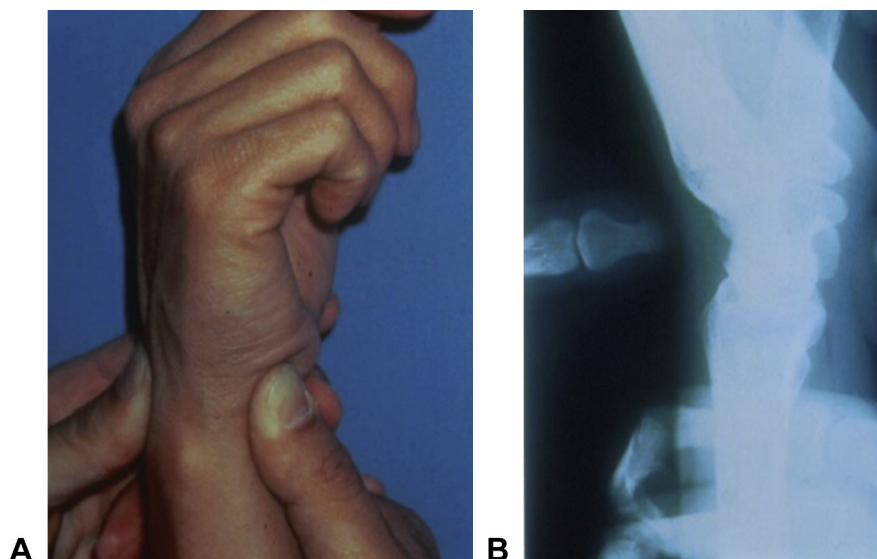


FIGURE 21: **A** The shear test allows the examiner to titrate small aliquots of energy into the patient's wrist, eliciting pain with subtle loads. The examiner's thumb supports the dorsal body of the lunate as a compression load is delivered at the pisotriquetral joint. This test converts compression of the pisotriquetral joint into shear at the LT joint. The test is specific and reliable. It is pathognomonic for LT disease or injury. **B** Lateral X-ray projection demonstrates the precise position of the examiner's thumbs relative to the patient's wrist anatomy.

joint must be examined to rule out its pathology. Otherwise the LT shear test could be ineffective.

To perform the shear test, the examiner's thumb firmly compresses the pisiform against the triquetrum. The opposite thumb steadies and supports the dorsal body of the lunate against the compressive load being provoked at the benign PT joint (Fig. 21A). This maneuver converts the energy of compression at the PT joint to shear at the LT joint, resulting in LT joint pain. The examiner has full control of how much energy is used to increase the joint reaction force at the PT joint. The compressive load delivered through the pisiform against the triquetrum can be great or small and subtle. The contralateral examining thumb supports the dorsal lunate against the increasing provocative load being delivered by the examiner's right thumb for right-sided LT dynamic instability (left thumb for left-sided instability). While using both thumbs for the test, the examiner's 2 hands stabilize the patient's hand–forearm unit.

Of the 3 maneuvers used to examine an injured or diseased wrist for dynamic LT instability, the shear test is the most specific, controllable, and subtle. To say that a well-performed, positive shear test is pathognomonic for dynamic LT instability might be overstated, but not by much.

MIDCARPAL JOINT

An accurate diagnosis of midcarpal instability requires a clear understanding of carpal mechanics. Intrinsic

ligament injury leading to midcarpal instability occurs either medially or laterally in the wrist, between the intercalated proximal row of the carpus and the distal row. Lichtman et al¹⁶ suggested that the causative mechanism of injury is to the medial limb of the deltoid (arcuate or “V”) ligament. Hankin et al¹⁷ suggested that the injury is between the distal scaphoid and the trapeziotrapezoid complex. Regardless, patients with midcarpal instability manifest a subtle flexion sag of the entire proximal row at rest. In severe cases, clinical inspection of the hand–forearm unit in neutral position reveals the longitudinal axis through the third metacarpal to be considerably more palmar than that of the radius, creating a subtle zigzag collapse deformity with the hand more palmar than the forearm.

Patients with painful midcarpal instability can themselves perform a provocative maneuver that begins with the wrist in neutral deviation and slightly flexed, with the fingers tightly clasped. Flexing the fingers increases the joint reaction force in the wrist. Under load, the patient actively brings the hand from neutral (slight wrist flexion) to extension-ulnar deviation. In the normal wrist, this movement is smooth, silent, and painless, coordinated by healthy, intact ligamentous struts and guy-wires that guide the transition of the scaphoid from an approximately 47° attitude (see above) to an extended posture in ulnar deviation. In a healthy wrist, this maneuver allows the triquetrum to engage the hamate smoothly at the helicoidal triquetrohamate joint. The proximal row is

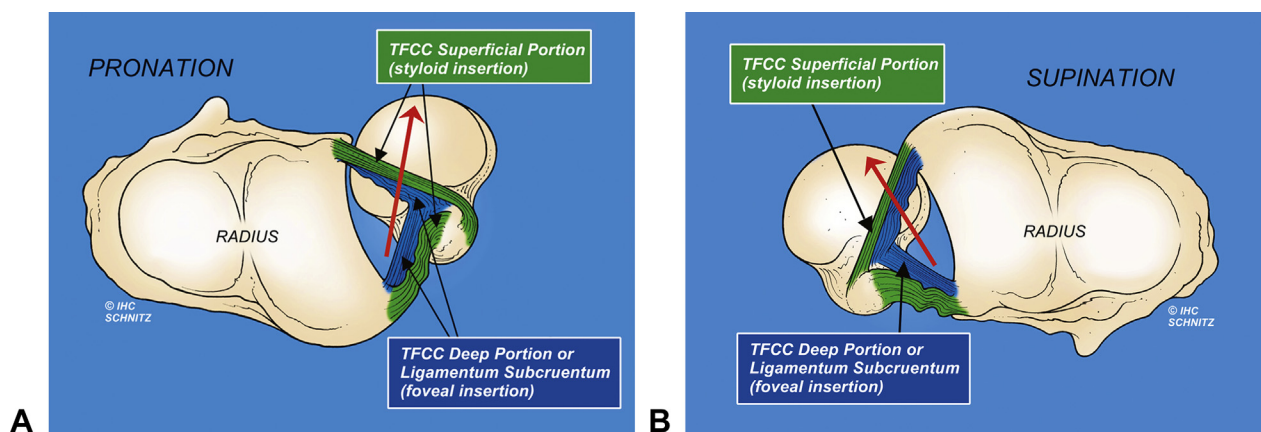


FIGURE 22: **A** Illustration of tightening of the palmar, deep fibers of the ligamentum subcruentum as the radius rotates into pronation and translates palmarly off the seat of the ulna in pronation. The head of the ulna translates along the sigmoid notch and herniates out from under cover of the tightening superficial dorsal TFCC fibers, rendering these (green) fibers ineffective in controlling DRUJ mechanics. **B** In supination, the reverse takes place as the radius, carpus, and hand rotate and translate dorsally off the head of the ulna, check reined by the tight dorsal ligamentum subcruentum. Superficial volar (green) TFCC fibers are ineffective in controlling DRUJ mechanics.

guided into progressive extension as the wrist is extended and ulnarly deviated.

Patients with midcarpal instability start this maneuver with the entire proximal row sagging slightly in flexion. As the wrist is actively driven into ulnar deviation and extension, the sagging proximal row does not move. The triquetrum does not engage the hamate at the triquetrohamate joint. The patient's extrinsic muscle-tendon units continue to pull the hand into ulnar deviation but the flexed triquetrum remains bound at the proximal aspect of the hamate. As the joint reaction force between triquetrum and hamate continues to build by this movement, the coefficient of friction between triquetrum and proximal hamate pole is finally overcome. Under load the entire proximal row jumps to a position where it should be physiologically, creating a low-pitch-frequency sound as the triquetrum suddenly and completely engages onto the articular surface of the hamate. The resultant audible clunk has been described as a catch-up clunk.^{18,19} This maneuver is extremely valuable in confirming the diagnosis of midcarpal instability, and should be considered a vital part of the hand surgeon's armamentarium.

TRIANGULAR FIBROCARILAGE COMPLEX AND ITS COMPONENTS

Much light has been shed on ulnocarpal pathology over the past 30 years, especially in the area of injuries and diseases of the TFCC. Despite the many advances in research made in more than a quarter-century, diagnosis of TFCC pathology remains a challenge; for many

clinicians, it is the black box at the end of the distal ulna. A review article published 7 years ago summarized what researchers have learned about TFCC mechanics pathology and diagnosis in the prior 25 years.²⁰ This article highlighted the fine details of TFCC anatomy and distinct differences between injuries to the superficial and/or deep components of the vascularized, fibrous portion (periphery) of the TFCC. Research studies^{21–24} have shown that the principal stabilizers of rotation and translation of the radius-carpus-hand unit around the fixed ulna through a physiologic arc of pronosupination are the deep fibers of the TFCC—the so-called ligamentum subcruentum—including their palmar and dorsal components.²⁰ In full pronation, the sigmoid fossa of the radius rotates and translates around the seat of the ulna to a point where less than 10% of the distal ulna articular surface is still in contact with the sigmoid fossa.²¹ In this extreme position, the part of the TFCC that prevents superphysiologic migration of the radius off the ulna head, whether distal radioulnar joint (DRUJ) subluxation or dislocation, is the palmar portion of the deep fibers (Fig. 22A). In full supination, superphysiologic migration of the sigmoid fossa of the radius off the seat of the ulna is prevented by the check-rein effect of the dorsal portion of the deep fibers (Fig. 22B).²⁰

Stress-testing integrity of ligamentum subcruentum

The specific anatomic parts of the TFCC responsible for maintaining DRUJ stability in the extremes of pronosupination have been studied; these findings are no longer as controversial as they were 30 years



FIGURE 23: Stress testing the dorsal, deep fibers of the ligament subcruentum for pain or mechanical instability. The examiner applies a superphysiologic load to push the distal ulna volarly while pulling the radius-carpus-hand dorsally.

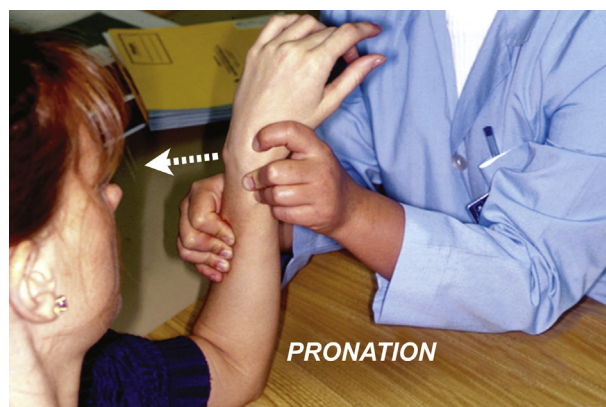

FIGURE 24: Stress testing the palmar, deep fibers of the ligamentum subcruentum for pain and possible mechanical instability. (Findings must be compared with the opposite, uninjured aide). The examiner applies a superphysiologic load to push the distal ulna dorsally while pulling the radius-carpus-hand volarly.

ago.^{21,23} Although there is tightening of the dorsal superficial fibers of the TFCC with forearm pronation, the palmar deep fibers of the ligamentum subcruentum serve as primary stabilizers as the radius rotates and translates at the DRUJ.²⁰ Orientation of superficial fibers between radius and ulna renders this portion of the TFCC relatively less important in providing DRUJ stability. The ulna head translates from under the influence of the superficial TFCC at the extremes of pronation and supination. In pronation, the dorsal superficial TFCC fibers are tight but inconsequential; in supination, the palmar superficial fibers are tight but also inconsequential. Throughout the physiologic arc of pronosupination, only the ligamentum subcruentum is essential for maintaining DRUJ stability (Fig. 22A, B).

Provocative maneuvers should be used to examine patients without gross DRUJ instability, those with full forearm range of motion, and those with weakness and ulnar-sided wrist pain after injury to the DRUJ—stabilizing portions of the TFCC.

Stress-testing of the guiding, check-rein portions of the ligamentum subcruentum is most effective when used in patients with chronic tenderness in the anatomic area of the TFCC and normal x-rays. Before stress-testing the deep fibers described below, the examiner should first palpate a point²⁵ described by Berger¹⁵ distal to the ulna styloid and proximal to the medial body of the triquetrum, between the flexor carpi ulnaris and extensor carpi ulnaris tendons. This ensures minimal tenderness and absence of general pathology in the area. Tenderness at this point is more specific for disease or injury of the superficial components of the TFCC. The examiner sits across from

the patient, with the patient's elbow on the table and fingers toward the ceiling. To stress-test the integrity or health of the dorsal deep fibers of the TFCC, the patient's forearm is passively rolled into full supination (Fig. 23). In this position, dorsal deep fibers are under maximum tension, keeping the sigmoid fossa of the radius from translating onto the seat of the ulna beyond physiologic limits. If the examiner is evaluating the patient's right wrist, he or she will supinate the patient's forearm, place the left 4 fingers on the palmar aspect of the patient's distal radius, and prepare to pull the radius toward himself or herself. Concurrently, the right thumb is placed on the dorsum of the patient's distal ulna (with the right fingers supporting the distal ulna by placing them on its palmar surface). Simultaneously, the examiner pushes the ulna away with the right thumb while pulling the radius toward himself or herself. This provocative maneuver introduces a superphysiologic load into the dorsal deep fibers of the ligamentum subcruentum, causing considerable pain relative to the uninjured, opposite distal forearm. The examiner's hands are reversed to stress-test the patient's left wrist.

To examine the palmar deep fibers of the ligamentum subcruentum, the examiner passively rolls the patient's injured right forearm into full pronation, tightening the deep, palmar fibers of the TFCC (Fig. 24). The ulna is then pushed away from the examiner with his or her right thumb while the radius is simultaneously pulled toward the examiner with his or her fingers. This provocative maneuver places a superphysiologic load on the palmar deep TFCC, causing pain if this tissue is injured or diseased. To examine the left wrist, the examiner's hands are reversed.

Stress-testing the integrity of the TFCC by provocative maneuvers can provide excellent diagnostic information to the surgeon without the need for sophisticated and expensive special imaging studies (eg, contrast magnetic resonance or computed tomography scanning).

REFERENCES

- Linscheid RL, Dobyns JH, Beabout JW, Bryan RS. Traumatic instability of the wrist: diagnosis, classification, and pathomechanics. *J Bone Joint Surg Am.* 1972;54(8):1612–1632.
- Watson HK, Ballet FL. The SLAC wrist: scapholunate advanced collapse pattern of degenerative arthritis. *J Hand Surg Am.* 1984;9(3):358–365.
- Mayfield JK, Johnson RP, Kilcoyne RK. Carpal dislocations: pathomechanics and progressive perilunar instability. *J Hand Surg Am.* 1980;5(3):226–241.
- Steinberg B, Kleinman WB. Occult scapholunate ganglion: a cause of dorsal radial wrist pain. *J Hand Surg Am.* 1999;24(2):225–231.
- Albanese SA, Palmer AK, Kerr DR, Carpenter CW, Lisi D, Levinsohn EM. Wrist pain and distal growth plate closure of the radius in gymnasts. *J Pediatr Orthop.* 1989;9(1):23–28.
- Smith DK, Cooney WP III, An KN, Linscheid RL, Chao EY. The effects of simulated unstable scaphoid fractures on carpal motion. *J Hand Surg Am.* 1989;14(2 pt 1):283–291.
- Kauer JM. The interdependence of carpal articulation chains. *Acta Anat (Basel).* 1974;88(4):481–501.
- Kauer JM. Functional anatomy of the wrist. *Clin Orthop Relat Res.* 1980;(149):9–20.
- Kleinman WB. Dynamics of carpal instability. In: Watson HK, Weinzwieg J, eds. *The Wrist.* Philadelphia, PA: Lippencott Williams & Wilkins; 2001:455–481.
- Watson HK, Ashmead D IV, Makhlof MV. Examination of the scaphoid. *J Hand Surg Am.* 1988;13(5):657–660.
- Reagan DS, Linscheid RL, Dobyns JH. Lunotriquetral sprains. *J Hand Surg Am.* 1984;9(4):502–514.
- Horii E, Garcia-Elias M, An KN, et al. A kinematic study of lunotriquetral dissociations. *J Hand Surg Am.* 1991;16(2):355–362.
- Viegas SF, Patterson RM, Peterson PD, et al. Ulnar-sided perilunate instability: an anatomic and biomechanic study. *J Hand Surg Am.* 1990;15(2):268–278.
- Crittenden JJ, Jones DM, Santarelli AG. Bilateral rotational dislocation of the carpal navicular: case report. *Radiology.* 1970;94(3):629–630.
- Berger RA. The gross and histologic anatomy of the scapholunate interosseous ligament. *J Hand Surg Am.* 1996;21(2):170–178.
- Lichtman DM, Schneider JR, Swafford AR, Mack GR. Ulnar midcarpal instability—clinical and laboratory analysis. *J Hand Surg Am.* 1981;6(5):515–523.
- Hankin FM, Amadio PC, Wojtys EM, Braunstein EM. Carpal instability with volar flexion of the proximal row associated with injury to the scapho-trapezial ligament: report of two cases. *J Hand Surg Br.* 1988;13(3):298–302.
- Lichtman DM, Wroten ES. Understanding midcarpal instability. *J Hand Surg Am.* 2006;31(3):491–498.
- Wright TW, Dobyns JH, Linscheid RL, Macksoud W, Siegert J. Carpal instability non-dissociative. *J Hand Surg Br.* 1994;19(6):763–773.
- Kleinman WB. Stability of the distal radioulna joint: biomechanics, pathophysiology, physical diagnosis, and restoration of function: what we have learned in 25 years. *J Hand Surg Am.* 2007;32(7):1086–1106.
- af Ekenstam F, Hagert CG. Anatomical studies on the geometry and stability of the distal radio ulnar joint. *Scand J Plast Reconstr Surg.* 1985;19(1):17–25.
- Af Ekenstam FW, Palmer AK, Glisson RR. The load on the radius and ulna in different positions of the wrist and forearm: a cadaver study. *Acta Orthop Scand.* 1984;55(3):363–365.
- Schuind F, An KN, Berglund L, et al. The distal radioulnar ligaments: a biomechanical study. *J Hand Surg Am.* 1991;16(6):1106–1114.
- Palmer AK, Werner FW. Biomechanics of the distal radio-ulnar joint. *Clin Orthop Relat Res.* 1984;(187):26–35.
- Tay SC, Tomita K, Berger RA. The “ulnar fovea sign” for defining ulnar wrist pain: an analysis of sensitivity and specificity. *J Hand Surg Am.* 2007;32(4):438–444.