

Management for intermediat level anorectal malformation in male in the newborn period

Incidence

- 2.0–2.5 per 10,000 live births

Table 8.1 Summary of incidences of anorectal malformations (ARM) from registries

ARM Registry	Region	Incidence (per) 10,000 live births
Texas Registry [3]	USA	5.0
Kansas [24]	USA	2.5
Louw [8]	South Africa	5.7
ECLAMC [10]	South America	4.1
EUROCAT [14]	Europe	4.1
Haeusler [25]	Europe	1.4
Finley [26]	Sweden	2.5
Stoll [27]	France	4.8

Frequency

- more frequently in boys than girls

Table 8.2 Gender ratio of anorectal anomalies

	Stephens [44]	Endo et al. [55]
Male	57%	57%
Female	43%	43%
Total No. of patients	3,645	1,992

Classification

Table 8.5 Ladd and Gross classification 1934 [64]

Type	Anomaly
I	Anal and anorectal stenosis
II	Imperforate anus
III	Imperforate anus with blind ending pouch with fistula
IV	Rectal Atresia

Male

Female

Anorectal deformities

A: Defect of the partition of the internal cloaca

1. Anorectal agenesis (no fistula)
2. Rectovesical fistula
3. Rectourethral fistula

1. Anorectal agenesis (no fistula)
2. Rectovesical fistula
3. Rectourethral fistula
4. Rectovaginal fistula
5. Rectovestibular fistula

B: Secondary defects after Partition

Rectal atresia

Rectal atresia

Rectal deformities

A: Defects of the perineum

1. Anterior perineal anus

1. Anterior perineal anus
Perineal
Vulvar
2. Anovestibular fistula
3. Perineal groove
4. Perineal canal

B: Defects of the genital fold

1. Covered anus complete
2. Anocutaneous fistula
3. Anobulbar fistula

1. Covered anus complete
2. Anocutaneous fistula
3. Anovulvar fistula

C: Defects of the proctodeal pit

1. Anorectal agenesis
2. Imperforate anal membrane
3. Anal stenosis
 - (i) Covered anal stenosis
 - (ii) Anal membrane stenosis
 - (iii) Anorectal stenosis

1. Anorectal agenesis
2. Imperforate anal membrane
3. Anal stenosis
 - (i) Covered anal stenosis
 - (ii) Anal membrane stenosis
 - (iii) Anorectal stenosis

Unclassified

1. Vesicointestinal fissure
2. Duplication of the rectum and anus
3. Combination of usual deformities

Table 8.6 Stephens and Smith 1963 classification based on embryological concepts

Type of anomaly	Female	Male
High	1. Anorectal agenesis A: Rectal atresia B: With fistula Rectocloacal fistula Rectovaginal/high 2. Rectal atresia	1. Anorectal agenesis A: Rectal atresia Rectovesical fistula Rectourethral fistula 2. Rectal atresia
Intermediate	1. Anal agenesis A. Without fistula B. With fistula Rectovaginal fistula low Rectovestibular fistula 2. Anorectal stenosis	1. Anal agenesis A. Without fistula B. With fistula Rectobulbar fistula 2. Anorectal stenosis
Low	1. At normal anal site Covered anus – complete Covered anal stenosis 2. At perineal site Anocutaneous fistula Anterior perineal anus 3. At vulvar site Vulvar anus Anovulvar fistula Anovestibular fistula	1. At normal anal site Covered anus – complete Covered anal stenosis 2. At perineal site Anocutaneous fistula Anterior perineal anus
Miscellaneous	Anal membrane stenosis Imperforated anal membrane Perineal groove Perineal canal	Anal membrane stenosis Imperforated anal membrane Perineal groove Perineal canal

Table 8.8 A simplified version of the 'International' classification

Table 8.9 Wingspread Conference classification

Level of anomaly	Male	Female
High	<ol style="list-style-type: none">1. Anorectal agenesis<ol style="list-style-type: none">A. Rectovesical fistulaB. Without fistula2. Rectal Atresia	<ol style="list-style-type: none">1. Anorectal agenesis<ol style="list-style-type: none">A. Rectovaginal fistulaB. Without fistula2. Rectal Atresia
Intermediate	<ol style="list-style-type: none">1. Rectourethral fistula2. Anal agenesis without fistula	<ol style="list-style-type: none">1. Rectovestibular Fistula,2. Rectovaginal fistula3. Anal agenesis without fistula
Low	<ol style="list-style-type: none">1. Anocutaneous (perineal) fistula2. Anal stenosis	<ol style="list-style-type: none">1. Anovestibular (perineal) fistula,2. Anocutaneous (perineal) fistula3. Anal stenosis
Miscellaneous	Rare malformations	Persistent cloacal anomaly Rare malformations




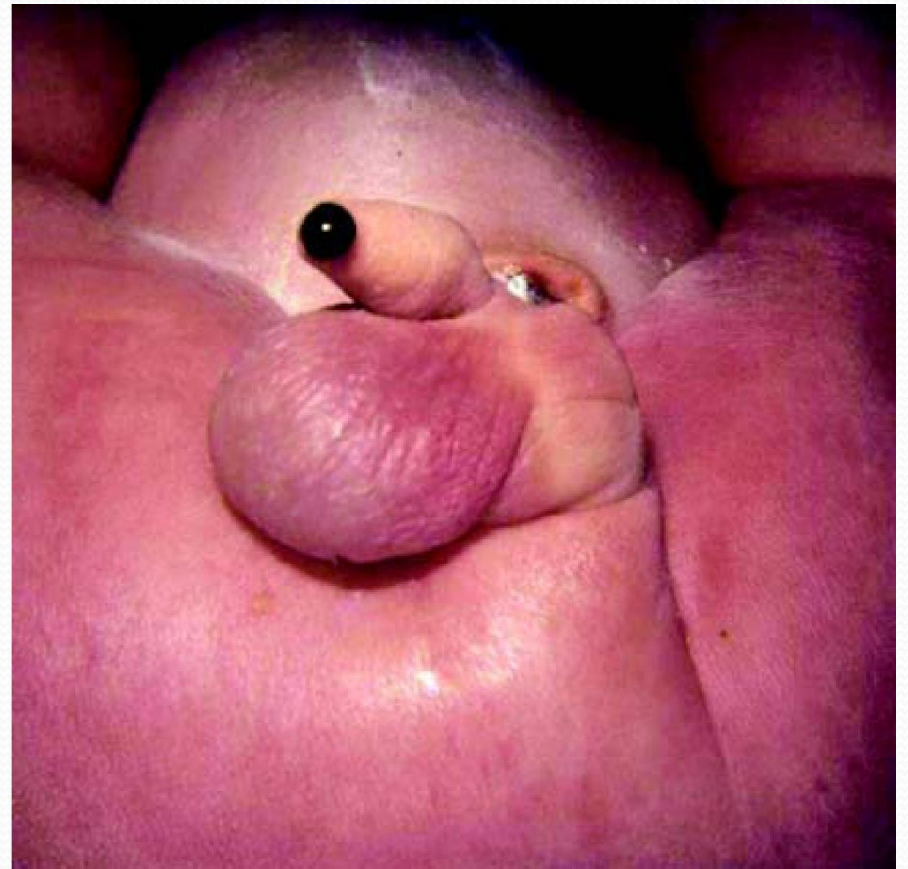
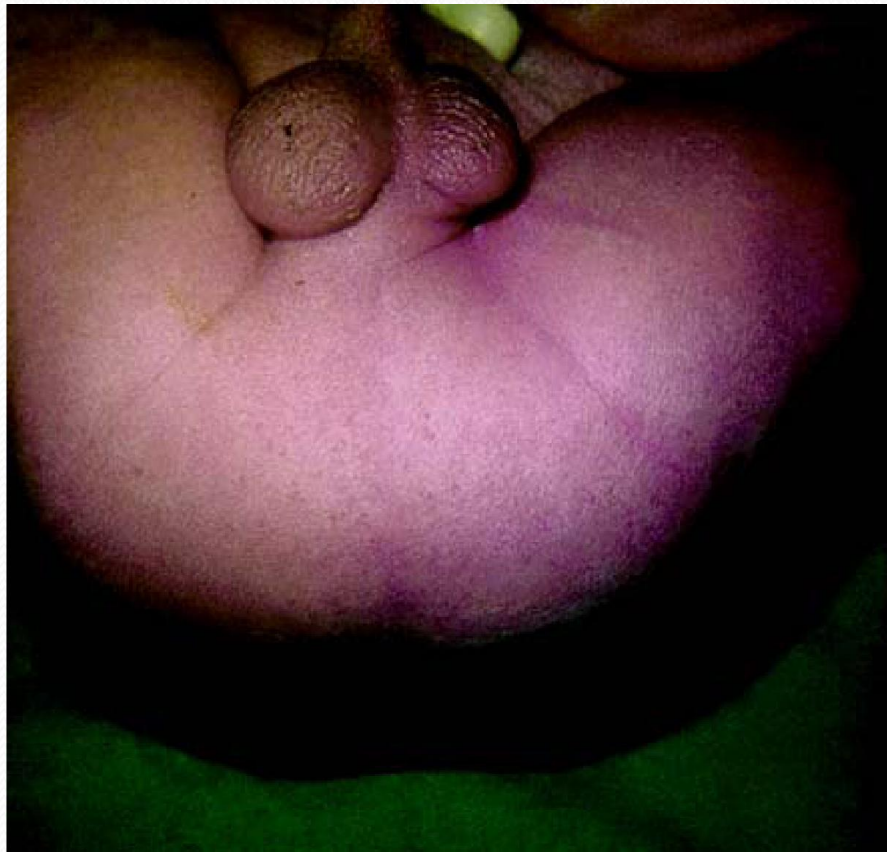
Table 8.10 Peña's classification

Males	Females
Perineal (cutaneous) fistula	Perineal (Cutaneous) fistula
Rectourethral fistula	Vestibular fistula
Bulbar	
Prostatic	
Rectovesical fistula	Persistent Cloaca
Imperforate anus without fistula	Imperforate anus without fistula
Rectal atresia	Rectal atresia

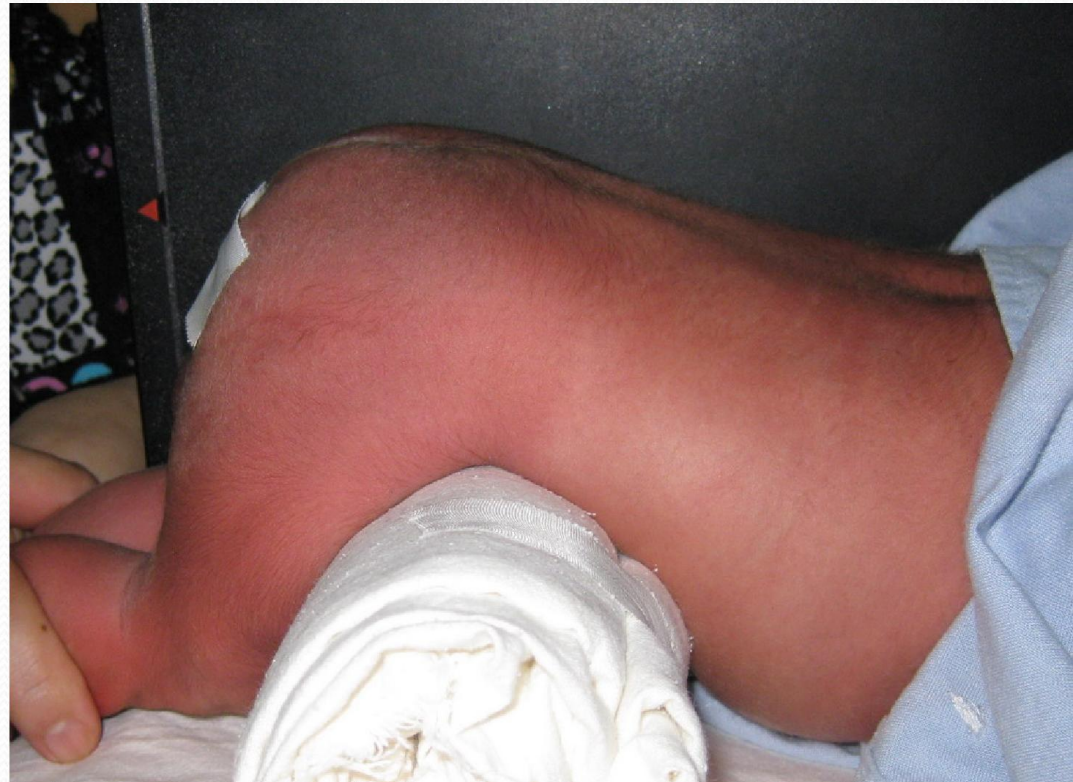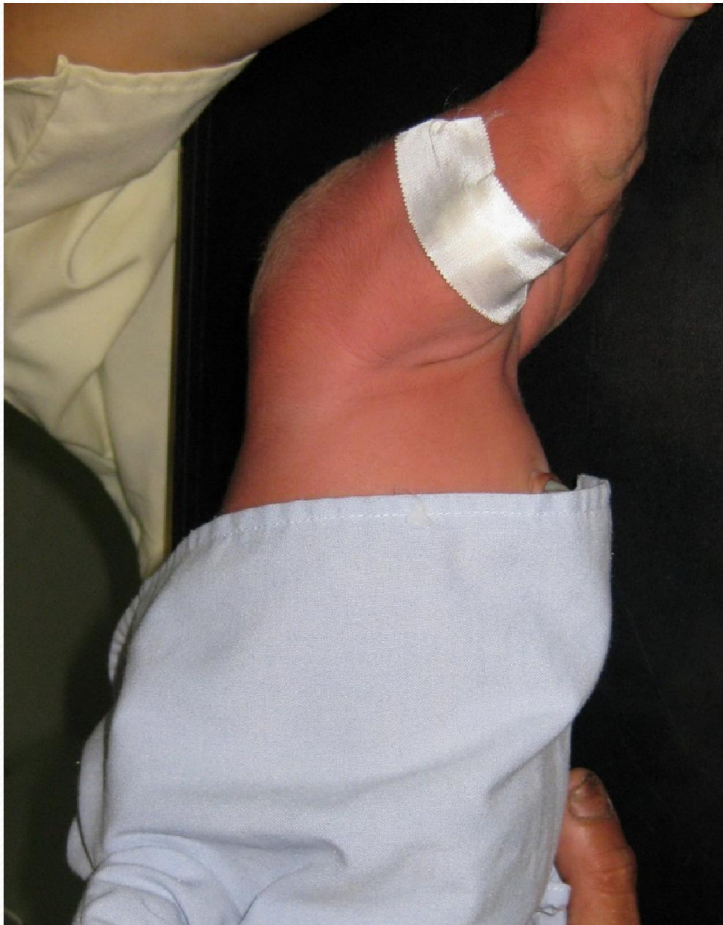Table 8.11 Standards for diagnostic procedures: International Classification (Krackenbeck) [69]

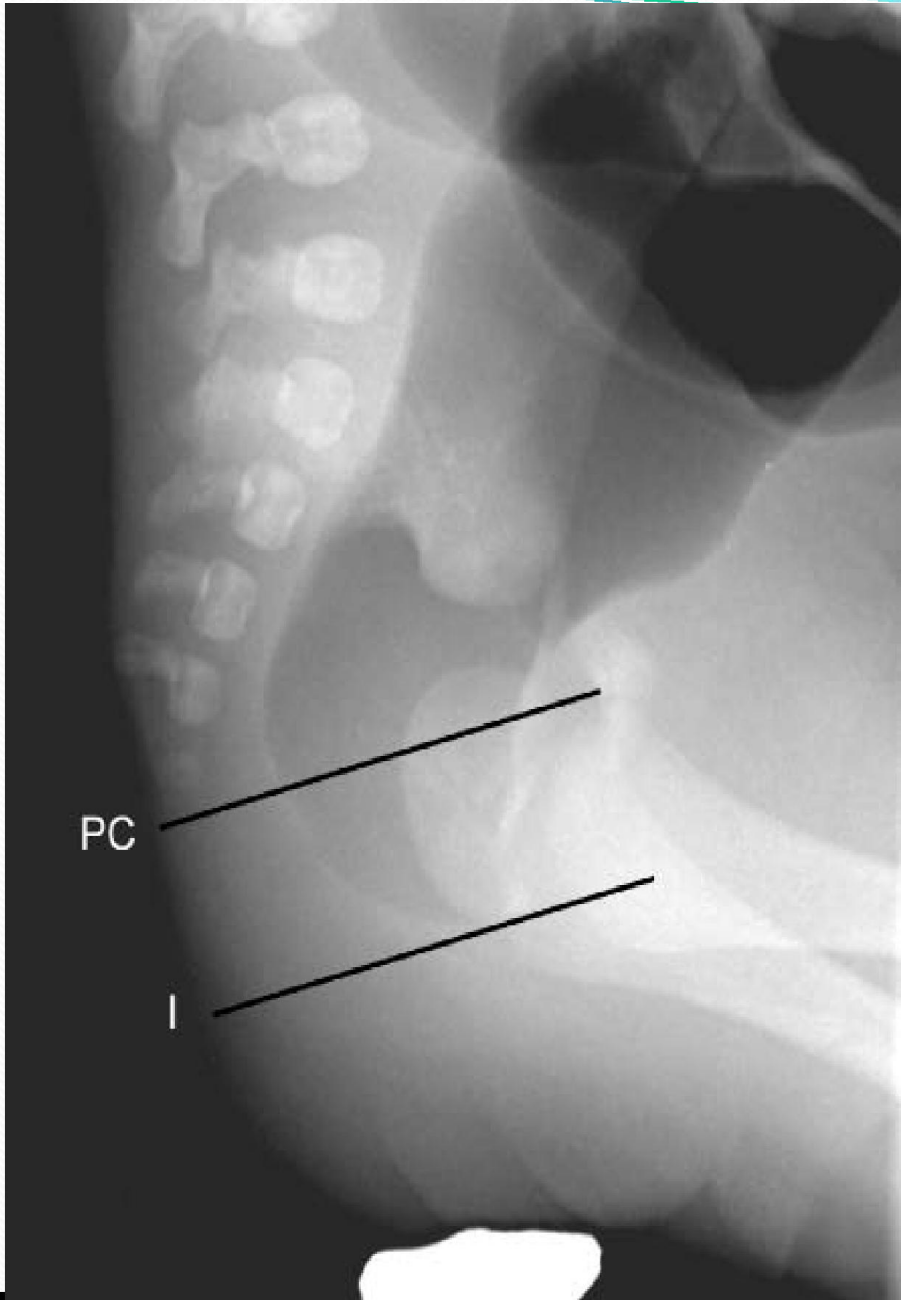
Major clinical groups	Perineal (cutaneous) fistula Rectourethral fistula Bulbar Prostatic Rectovesical fistula Vestibular fistula Cloaca No fistula Anal stenosis
Rare/regional variants	Pouch Colon Rectal atresia/stenosis Rectovaginal fistula H type fistula Others

Diagnosis




Radiography

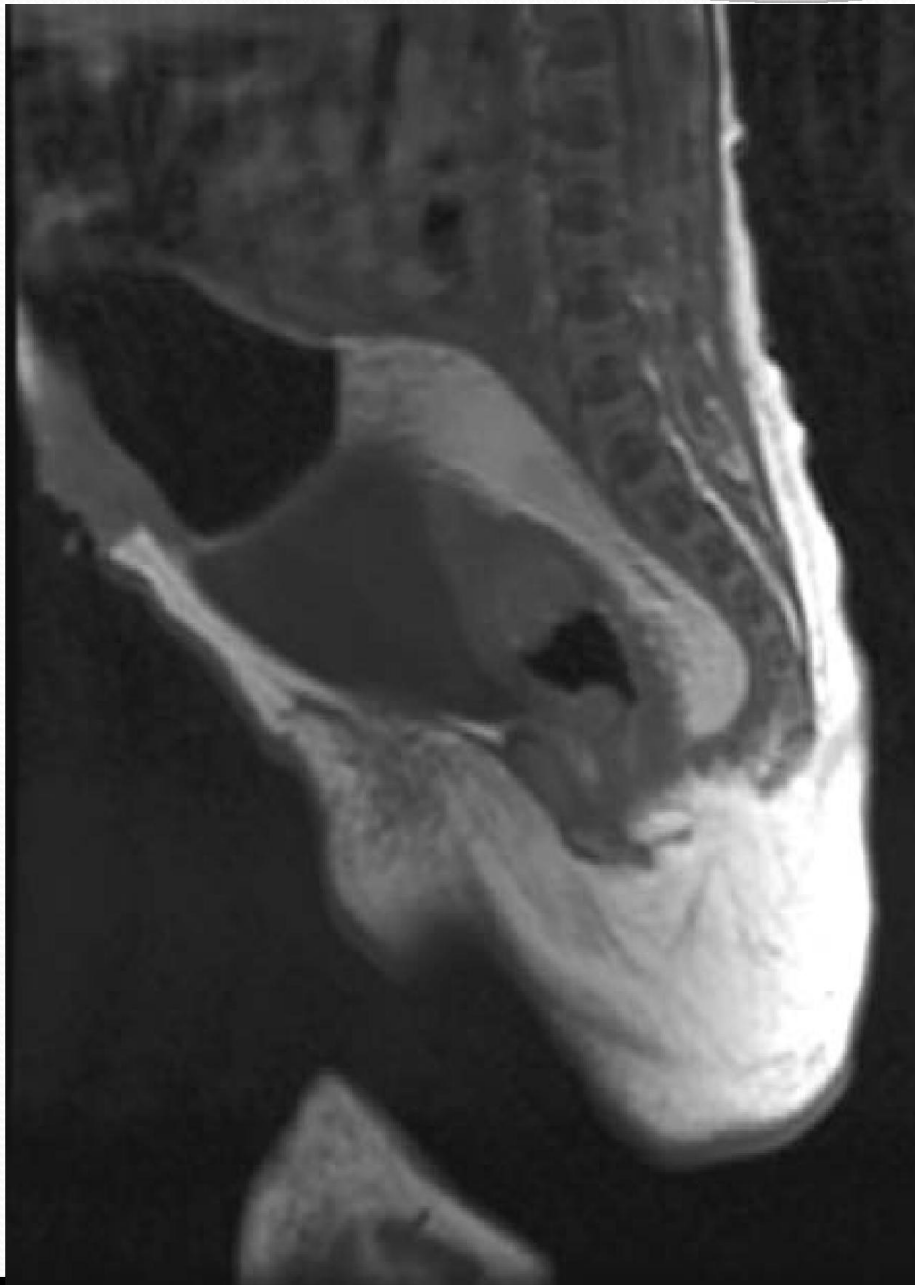




PC

I

- 
- Common causes for erroneous interpretation of prone, cross-table lateral x-ray
 - Insufficient time for gas to reach the terminal bowel
 - Meconium plug in the terminal gut may produce an erroneously high shadow
 - Active contraction of the levator ani/sphincter muscle complex
 - Erroneous estimation of level may occur if the pelvic floor muscles are relaxed, or if there is a sacral anomaly
 - gas in the vagina may be mistaken for gas in the distal bowel



Management



Colostomy

Colostomy in anorectal malformations: a procedure with serious but preventable complications

Alberto Pena^{a,*}, Melissa Migotto-Krieger^b, Marc A. Levitt^a

^a*Colorectal Center for Children Cincinnati Children's Hospital Medical Center, Surgery and Pediatrics University of Cincinnati, Cincinnati, OH 45229, USA*

^b*Pediatric Surgeon University Hospital Universidad Católica Rio Grande do Sul Porto Alegre, Brazil*

Abstract

Purpose: Colostomy for patients with anorectal malformations decompresses an obstructed colon, avoids fecal contamination of the urinary tract, and protects a future perineal operation. The procedure is associated with several significant complications.

Materials and Methods: The medical records of 1700 cases of anorectal malformations were retrospectively reviewed. A total of 230 patients underwent reconstruction without a colostomy. Of the remaining 1470 patients, 1420 had their colostomy performed at another institution (group A) and 50 did at our institution (group B) using a specific technique with separated stomas in the descending colon.

Results: There were 616 complications identified in 464 patients of group A and in 4 patients in group B, an incidence of 33% vs 8% ($P < .01$). Complications in group A were classified into several groups. The first group was mislocation (282 cases), including 116 with stomas too close to each other, 97 with stomas located too distally in the rectosigmoid (which interfered with the pull-through), 30 with inverted stomas, 21 with stomas too far apart from each other, and 18 with right upper sigmoidostomies. The second largest group was prolapse (119 cases), which occurred mainly in mobile portions of the colon. The third group was composed of general surgical complications after colostomy closure (82 cases), such as intestinal obstruction (47 cases), wound infection (13 cases), incisional hernia (11 cases), anastomotic dehiscence (7 cases), sepsis (3 cases), and bleeding (1 case). Two of the septic patients died. Another group included 62 patients who received a Hartmann's procedure, which we considered to be contraindicated in anorectal malformations. A total of 42 patients suffered from stenosis of the stoma; 29, from retraction.

Conclusions: Most colostomy complications are preventable using separated stomas in the descending colon. Mislocated stomas lead to problems with appliance application, interference with the pull-through, megasigmoid, distal fecal impaction, and urinary tract infections. Loop colostomies lead to urinary tract infections, distal fecal impaction, and prolapse. Prolapse is a potentially dangerous complication that mostly occurs when the stoma is placed in a mobile portion of the colon. Recognizing this makes the complication preventable by trying to create colostomies in fixed portions of the colon or by fixing the bowel to the abdominal wall when necessary. The trend to avoid colostomies is justified; however, colostomy is the best way to prevent complications in anorectal surgery and, when indicated, should be done with a meticulous technique following strict rules to avoid complications.

© 2006 Published by Elsevier Inc.

Colostomy for high anorectal malformation: an evaluation of morbidity and mortality in a developing country

Lohfa B. Chirdan · Francis A. Uba ·
Emmanuel A. Ameh · Philip M. Mshelbwala

Abstract Colostomy is a life-saving procedure in newborns with high anorectal malformations (ARM). However, the procedure may be attended by complications, particularly in resource limited settings. This is an evaluation of the morbidity and mortality following colostomy for ARM in newborns in two paediatric teaching centres in a developing country. A retrospective review of 61 neonates who had colostomy for high ARM in 4 years is conducted. The babies were categorised into Group A (weight at presentation < 2.5 kg) and Group B (weight at presentation > 2.5 kg). There were 47 boys and 14 girls aged 18 h to 28 days (median 6 days). There were 23 babies in Group A; 18 had colostomy under local anaesthetic (LA), 5 of whom died while 5 had the procedure done under general anaesthetic (GA), 3 of whom died (mortality 8/23, 34.78%). Group B consisted of 38 babies, 18 had colostomy under GA, 3 died, while in 20 the procedure was under LA, 1 of who died (mortality 4/38, 10.5%). The difference in mortality between groups A and B was statistically insignificant ($p < 0.056$). There were no significant differences in outcome between the two groups when the type of anaesthesia or types of colostomy were considered. Surgical site infection was the most common 12/61, 19.7%. Of the 12 babies that died, 7 were due to overwhelming infections, 4 respiratory insufficiencies and 1 cyanotic heart disease. The overall procedure related mortality was therefore 7 (11.5%). None of the centres had adequate

Anorectal malformations with good prognosis: Variables affecting the functional outcome

Rosella Arnodi et al. Volume 49, Issue 8, Pages 1232–1236

- **Background/Purpose**
 - The purpose of this study was to investigate the outcome of patients operated for anorectal malformations (ARMs) with good prognosis.
- **Methods**
 - Thirty patients underwent clinical evaluation by Rintala score and anorectal manometry recording anal resting pressure (ARP), rectoanal inhibitory reflex (RAIR), and rectal volume (RV). The results were analysed with regard to sex, type of ARM, surgical timing of posterior sagittal anorectoplasty (PSARP), neurospinal cord dysraphism (ND), neonatal colostomy, and institution where they underwent surgery.
- **Results**
 - 6/30 (20%) presented ND despite normal sacrum. 17/30 (57%) patients had a normal Rintala score. ND and neonatal colostomy were significantly associated with a pathologic score ($p = 0.0029$ and $p = 0.0016$). Patients with ND had significantly lower ARP compared to patients with normal spine (23.5 ± 7.2 mmHg vs 32 ± 7.9 mmHg, $p = 0.023$). ARP was significantly lower in patients with neonatal colostomy compared to patients with primary repair (25.22 ± 10.24 mmHg vs 32.57 ± 6.68 mmHg, $p = 0.026$). RAIR was present in only 2/6 (33%) patients with ND, while in 21/24 (87.5%) without ND ($p = 0.015$) and in 4/9 (44%) patients with neonatal colostomy, while in 19/21 (90.5%) patients submitted to primary repair ($p = 0.014$).
- **Conclusions**
 - Neurospinal cord dysraphism may be present despite normal sacral ratio. From a clinical point of view, patients with good prognosis ARMs are not completely comparable to healthy children. Neurospinal cord dysraphism and neonatal colostomy seem to worsen the clinical and manometric (ARP and RAIR) outcomes of these patients.

J. O. Adeniran · L. Abdur-Rahman

One-stage correction of intermediate imperforate anus in males

Abstract This prospective study was designed to assess the safety, cost-effectiveness, and advantages of performing posterior sagittal anorectoplasty (PSARP) without colostomy on males with intermediate imperforate anus in a developing country. Fifteen consecutive males with intermediate imperforate anus were entered into the study. Chest and abdominal x-rays, skeletal surveys, renal ultrasound scans, and invertograms were done. Patients were resuscitated and Peña's PSARP done in prone positions. A 2-ml syringe vent was inserted into the new anus for 10 days. Babies were nursed prone postoperatively. Cephalosporin and metronidazole were given as perioperative antibiotics. All patients had intermediate anomalies. There were no other major associated congenital anomalies. A urethral catheter could not be inserted in one patient, and one patient who presented with septicemia and jaundice was deemed too ill to withstand a major operation; these two patients therefore had diverting colostomies. There were no problems with PSARP in the other 13 patients. One patient's father discharged him against medical advice on the 5th postoperative day; the mother had had postpartum hemorrhage, so they opted for traditional treatment because they could not provide blood donors. The skin wounds of 10 patients healed completely with removal of stitches; two boys had superficial wound infection. Parents who lived far from the hospital were taught how to dilate the anus. Follow-up has ranged between 3 months and 2 years. This prospective study shows that it is feasible for males with intermediate imperforate anus to have safe PSARP without colostomy. The advantages of one instead of three major operations are many, especially in developing countries.

ARM 1

Primary PSARP for Intermediate and High Anorectal Malformations in Male Neonates.

Loksha K, Prema Menon, KLN Rao. *Advanced Pediatric Centre, PGIMER, Chandigarh, India.*

Background: Literature on Primary PSARP is scanty. This study was aimed to assess the morbidity, mortality and short term outcome of primary PSARP in male neonates with intermediate and high ARM. **Methods:** Prospective study conducted from July 2005 to June 2007. All male neonates with intermediate and high anomaly were included in the study. Cases with Pouch colon, rectal pouch above pre-sacral area on CTPL and cases with associated esophageal atresia or duodenal atresia were excluded. All underwent standard PSARP. Assessment was made for complications, mortality and continence according to Kiesewetter functional scoring with a minimum of 3 months follow up. **Results:** Among 54 cases, 30 underwent primary PSARP and 24 excluded from the study. Age at surgery ranged from 1 to 14 days. Two had intra-op injuries (6.6%), two required additional surgical procedure (6.6%), perianal excoriation in 10 (33.3%), wound infection in 2 (6.6%), superficial wound gaping in 10 (33.3%), transient neurogenic bladder in 2 (6.6%), neo-anus stenosis in 3 (9.9%), 4 had constipation (13.2%), fecal soiling in 10 (33.3%) and 1 had urinary incontinence (3.3%). Kiesewetter scoring for fecal continence was good in 19(79.17%), fair in 4 (16.67%), and poor in 1 (4.16%) and most of them used to pass stools 1 to 3 times a day. Three expired (10% mortality), which was comparable to neonatal colostomy mortality (11.32%) in similar patients. **Conclusions:** Primary PSARP in male neonate with intermediate and high ARM is safe, feasible with good short term results and less socioeconomic burden..

The Treatment of High and Intermediate Anorectal Malformations: One Stage or Three Procedures?

By Guochang Liu, Jiyan Yuan, Jinmei Geng, Chunhua Wang, and Tuanguang Li
Wuhan, China

Background/Purpose: The aim of this study was to examine the safety, feasibility, and the long-term outcome of complete 1-stage repair of high and intermediate anorectal malformation using posterior sagittal anorectoplasty (PSARP) in a neonate.

Methods: One hundred thirteen patients with high-type and intermediate-type anorectal malformations (ARM) underwent follow-up. Of 113 cases, 48 cases entailed a divided colostomy, definitive operation, and colostomy closure (group I); the other 65 patients underwent 1-stage PSARP (group II). Anorectal function was measured by the modified Wingspread scoring, including "excellent," "good," "fair," and "poor." In barium enema studies, anorectal angulation was judged as "clear," "unclear," and "not present," and leakage of barium was observed in the meantime. For anorectal manometric studies, anal resting pressure (ARP), anal squeezing pressure (ASP), and positive anorectal reflex (PAR) were measured.

Results: In group I, the rate of excellent and good scores was 58.3% (28 of 48). In the barium enema examination, 85.4% (41 of 48) was clear and 14.6% (7 of 48) unclear or not present. The rate of barium leakage was 10.4% (5 of 48). In group II,

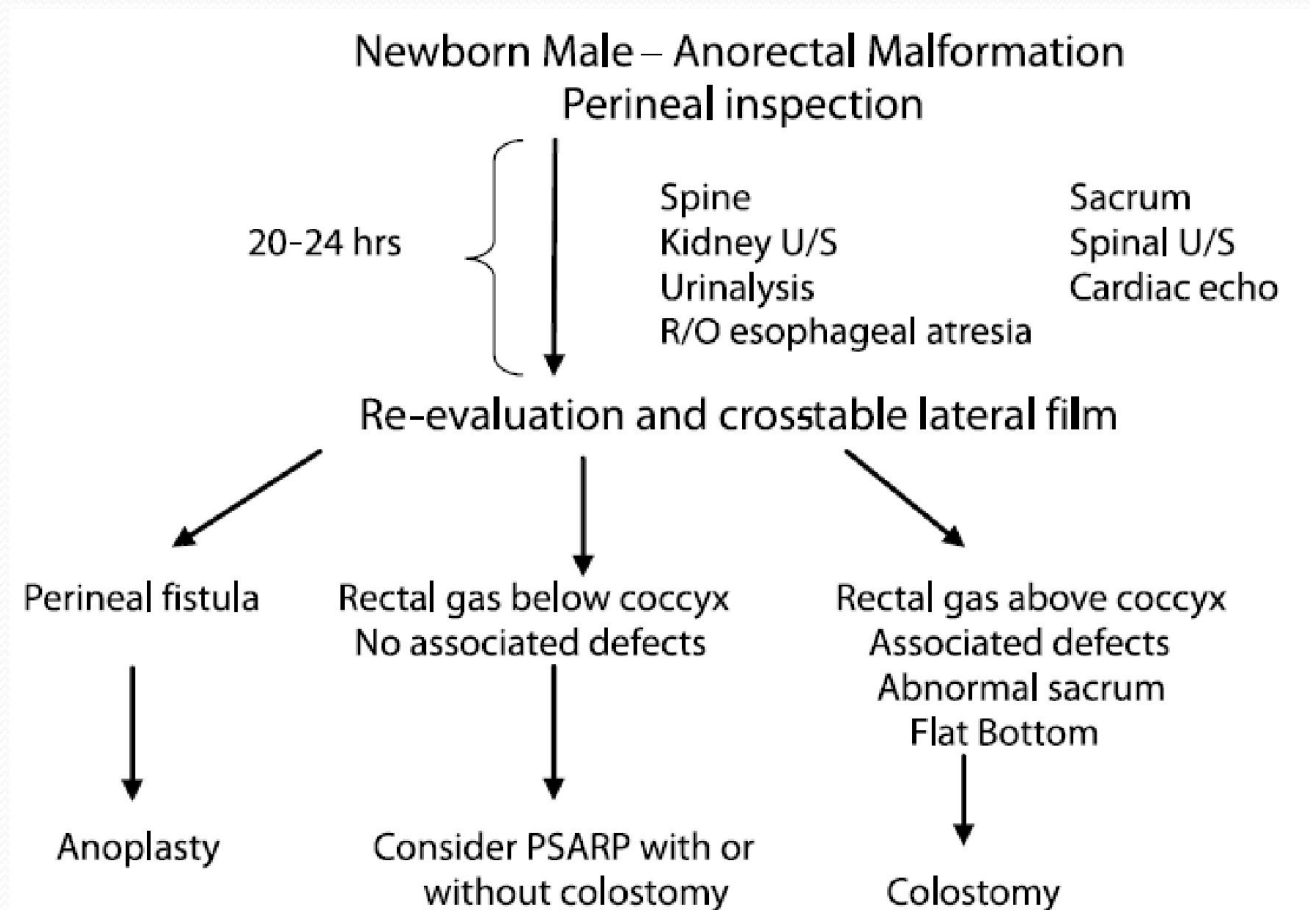
the rate of excellent and good was 53.8% (35 of 65). Anorectal angulations were clear in 83.1% of patients (54 of 65). Barium leakage happened in 7.69% of patients (5 of 65). Early operative complications occurred in 56.3% (27 of 48) of patients in group I and 29.2% (19 of 65) in group II. The incidence of colostomy complications in group I was 39.6% (19 of 48). Soiling and constipation were the major complications after the PSARP operation. The respective rates of constipation in the 2 groups were 47.9% (23 of 48) and 44.6% (29 of 65), and the respective rates of soiling were 47.9% (23 of 48) and 50.8% (33 of 65). There was no significant difference in the mean ARP between the 2 groups.

Conclusions: The 1-stage PSARP procedure in the neonate not only achieves the same long-term outcome as the conventional PSARP procedure but also involves fewer short-term complications. Complete 1-stage repair using the PSARP to treat high-type and intermediate-type anorectal malformations is safe and feasible.

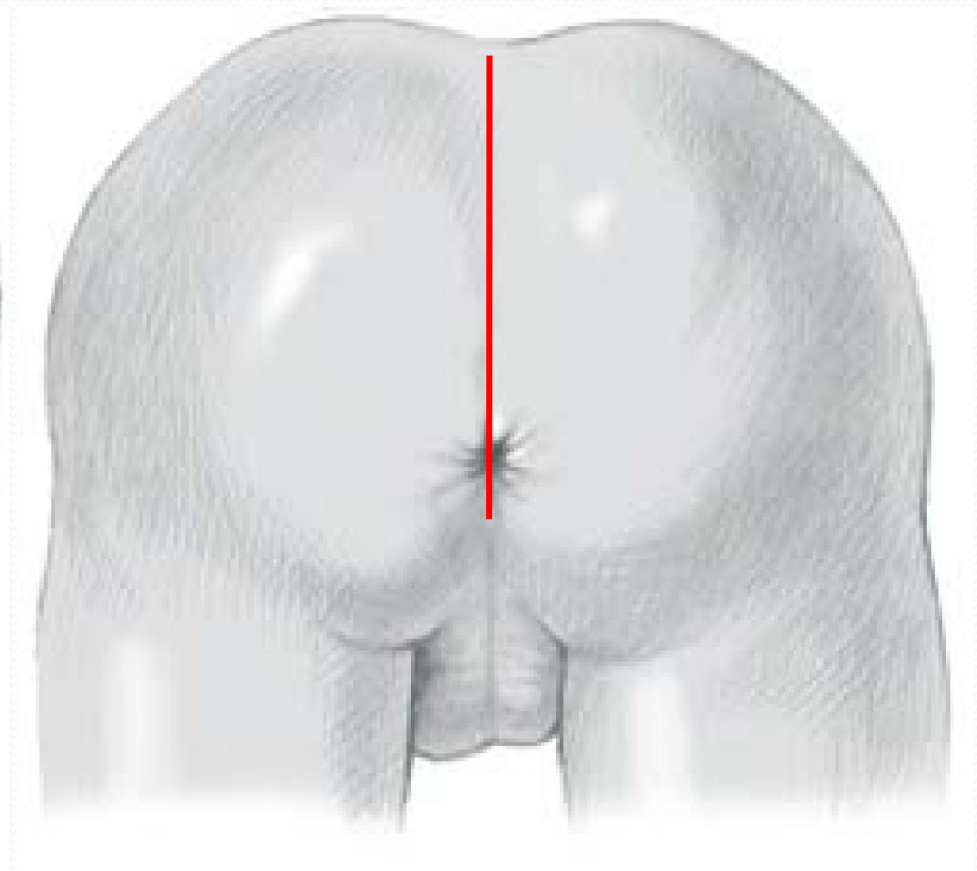
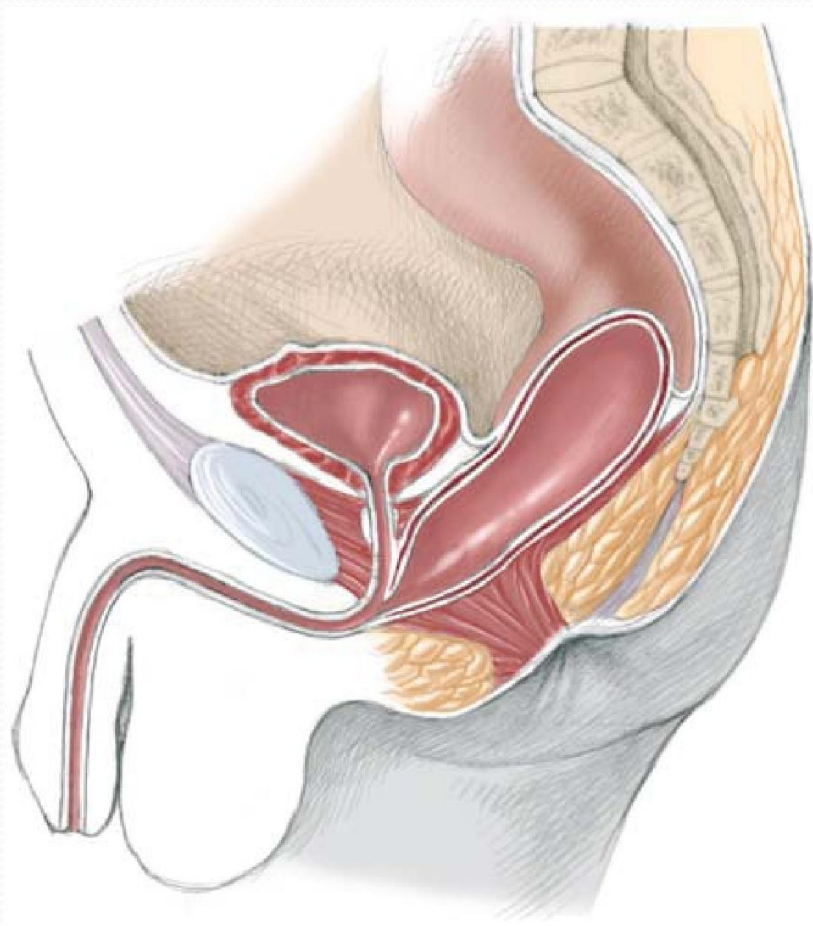
J Pediatr Surg 39:1466-1471. © 2004 Elsevier Inc. All rights reserved.

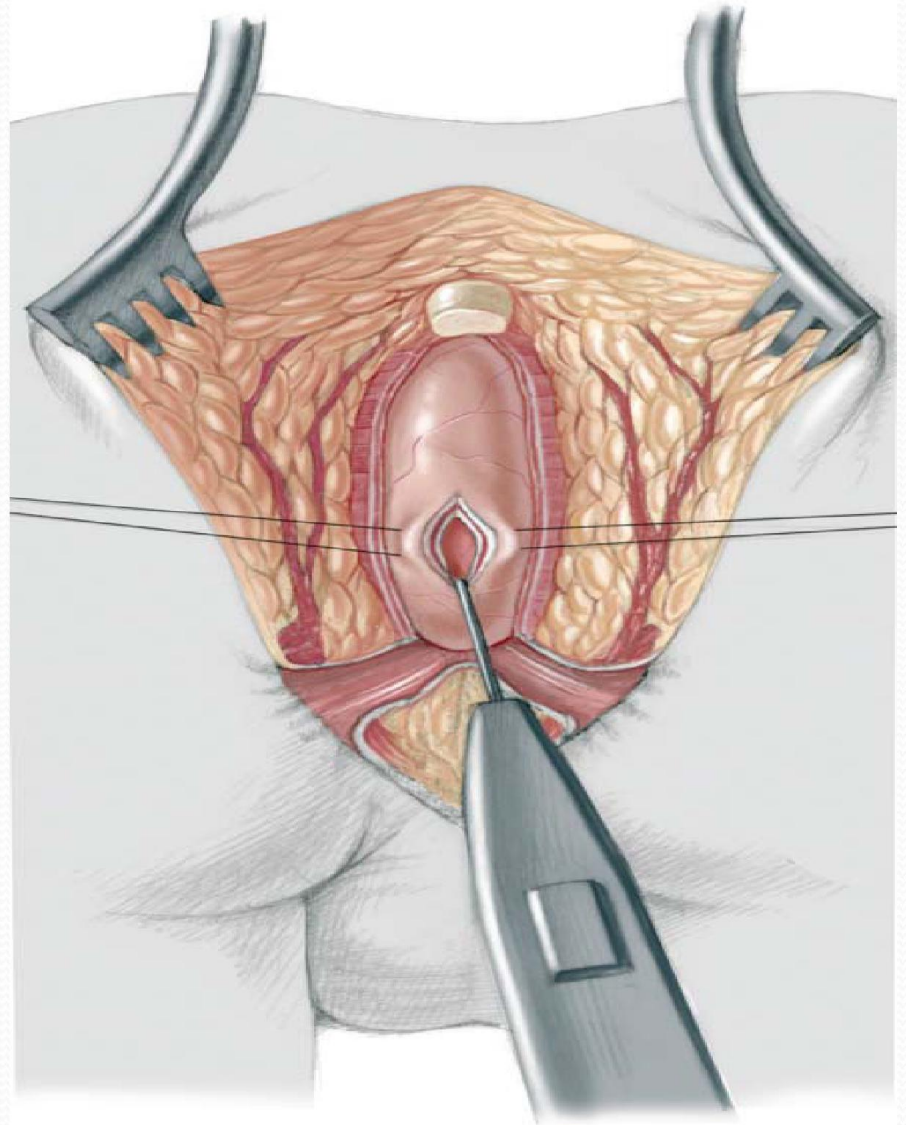
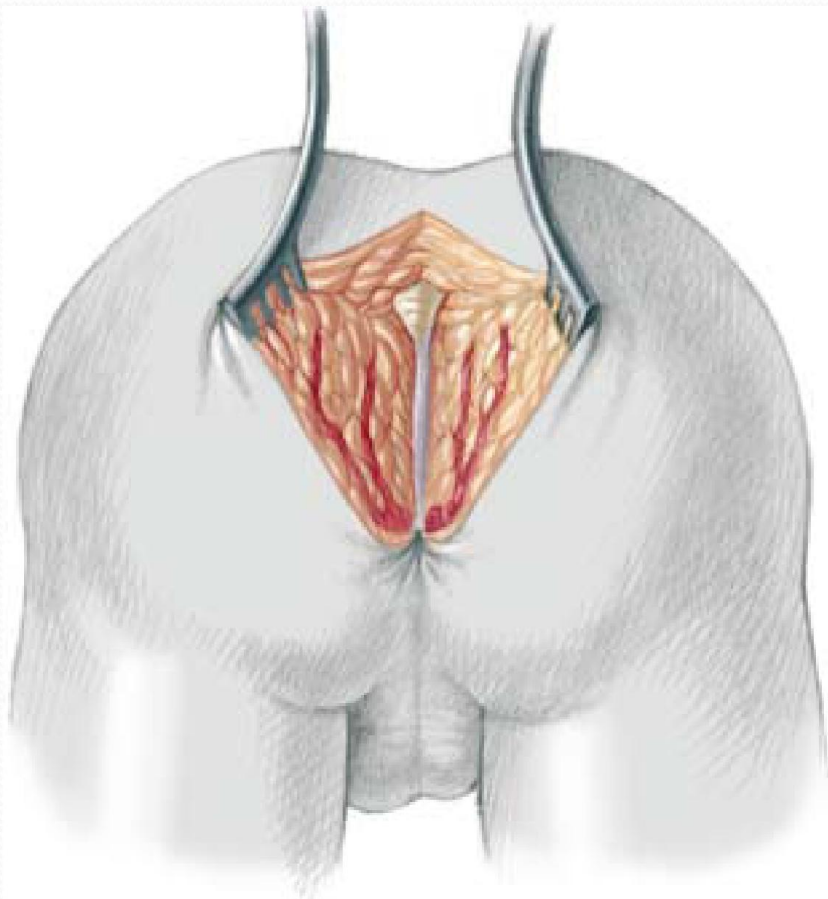
INDEX WORDS: Anorectal malformation, posterior sagittal anorectoplasty, neonate.

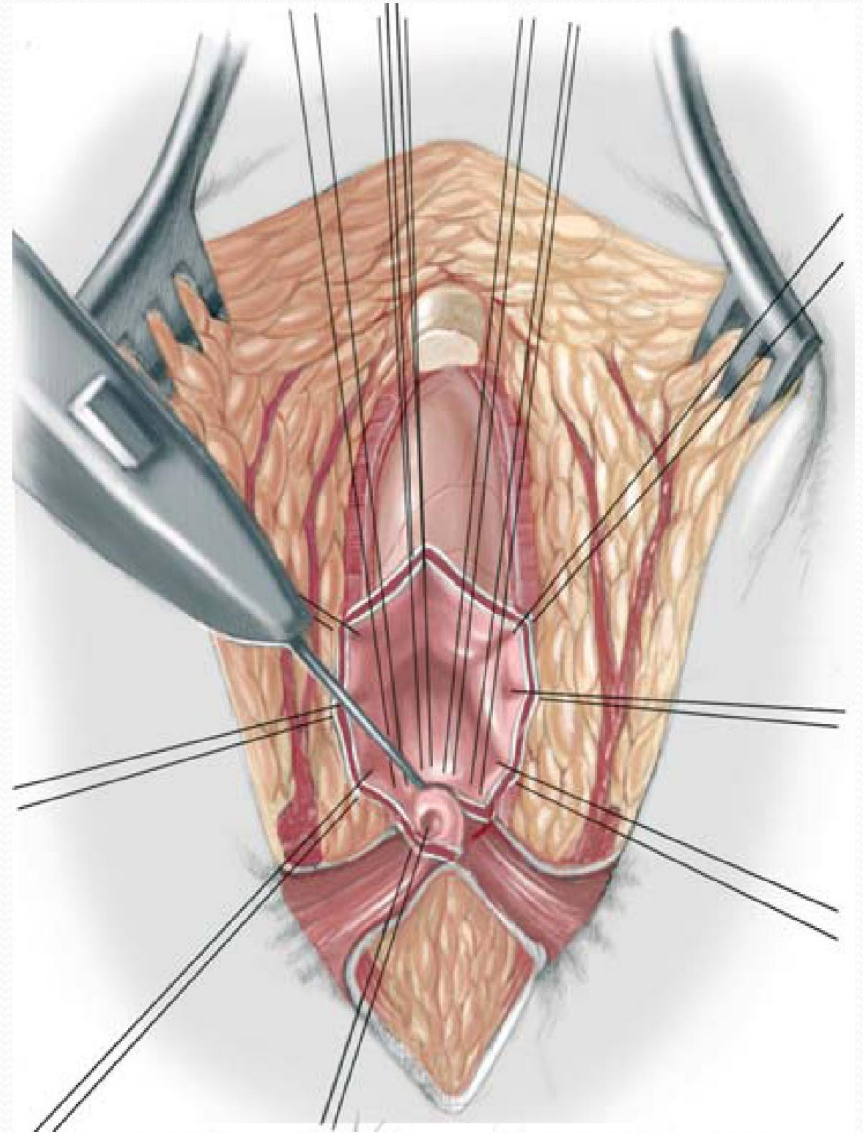
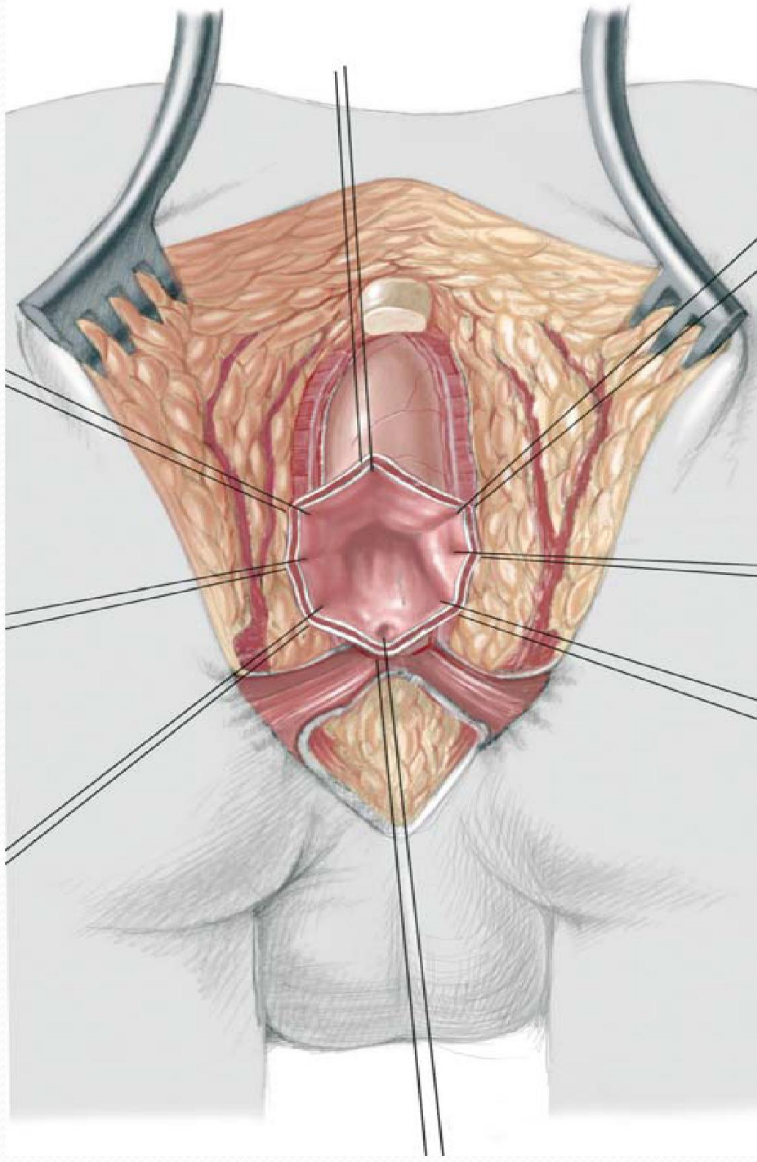
Management

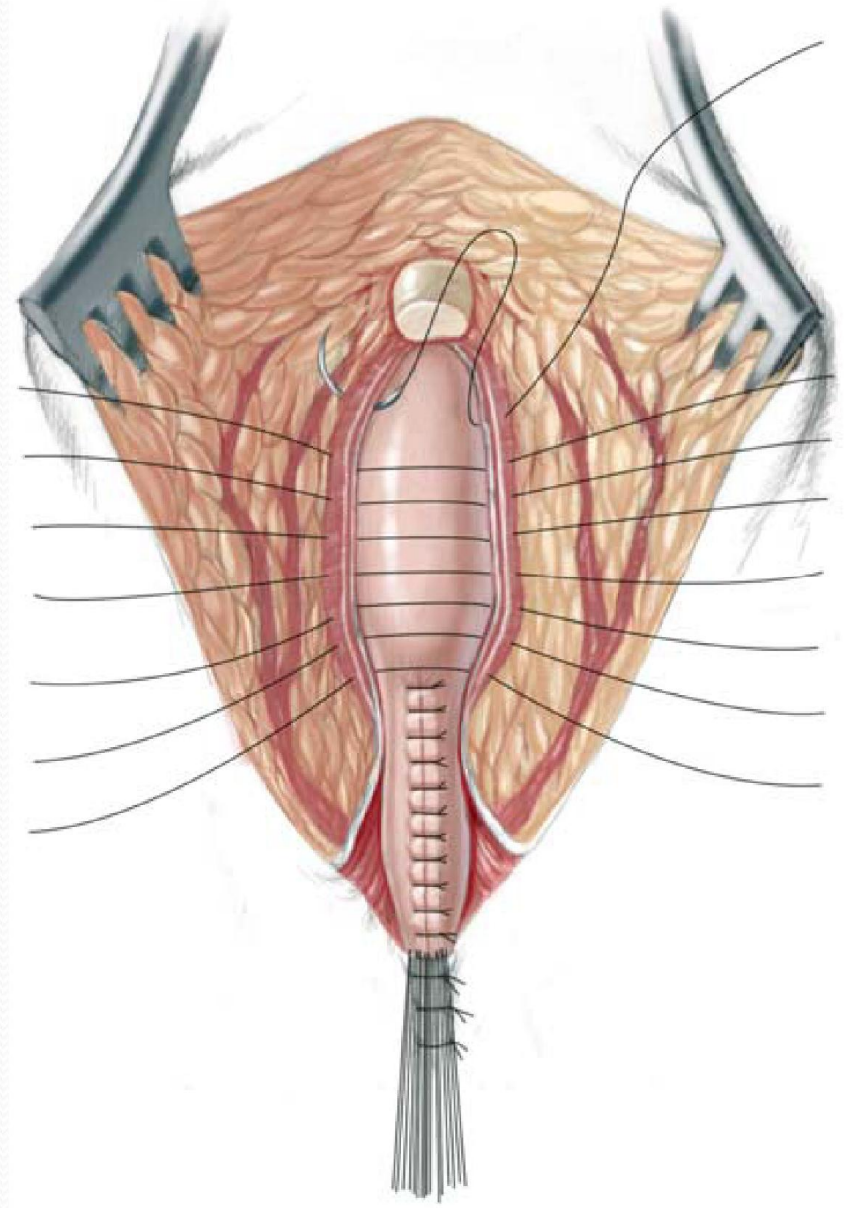
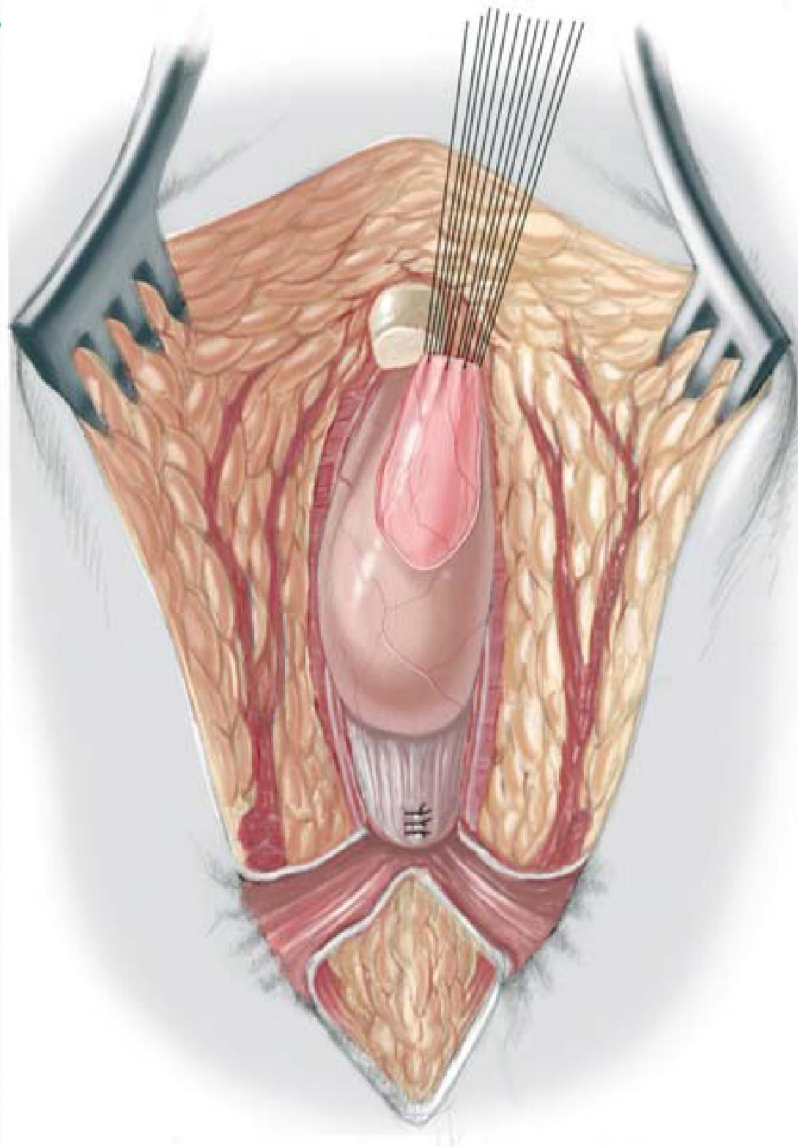


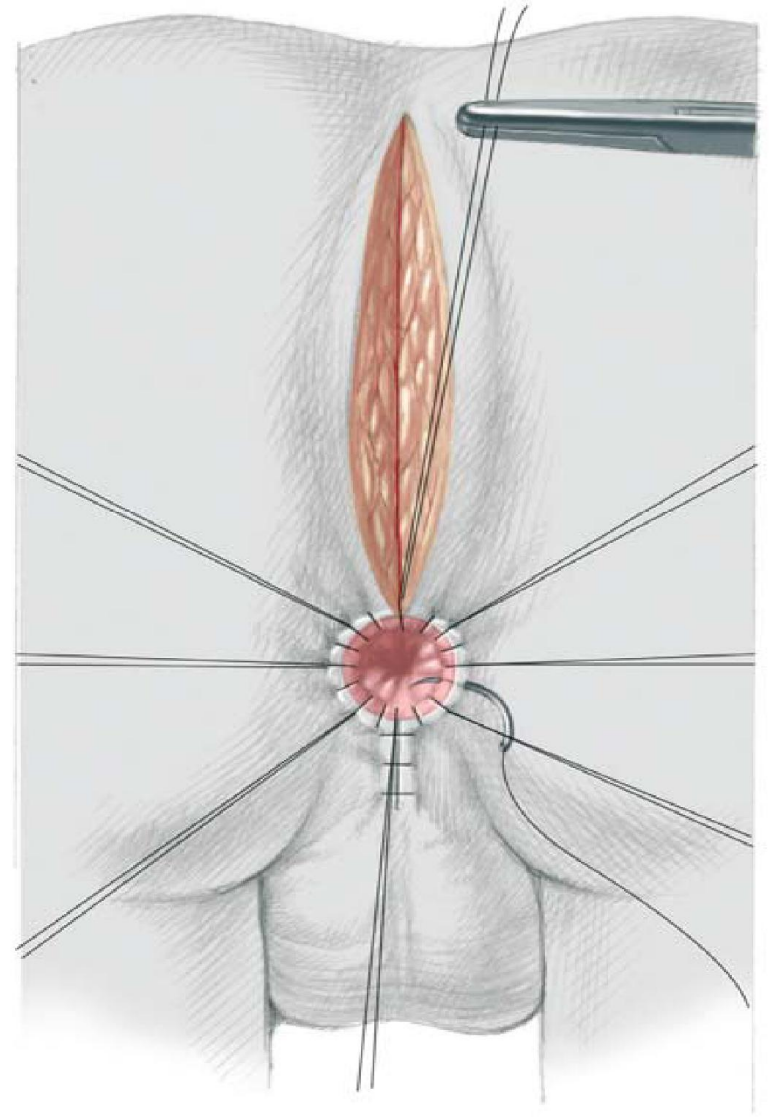
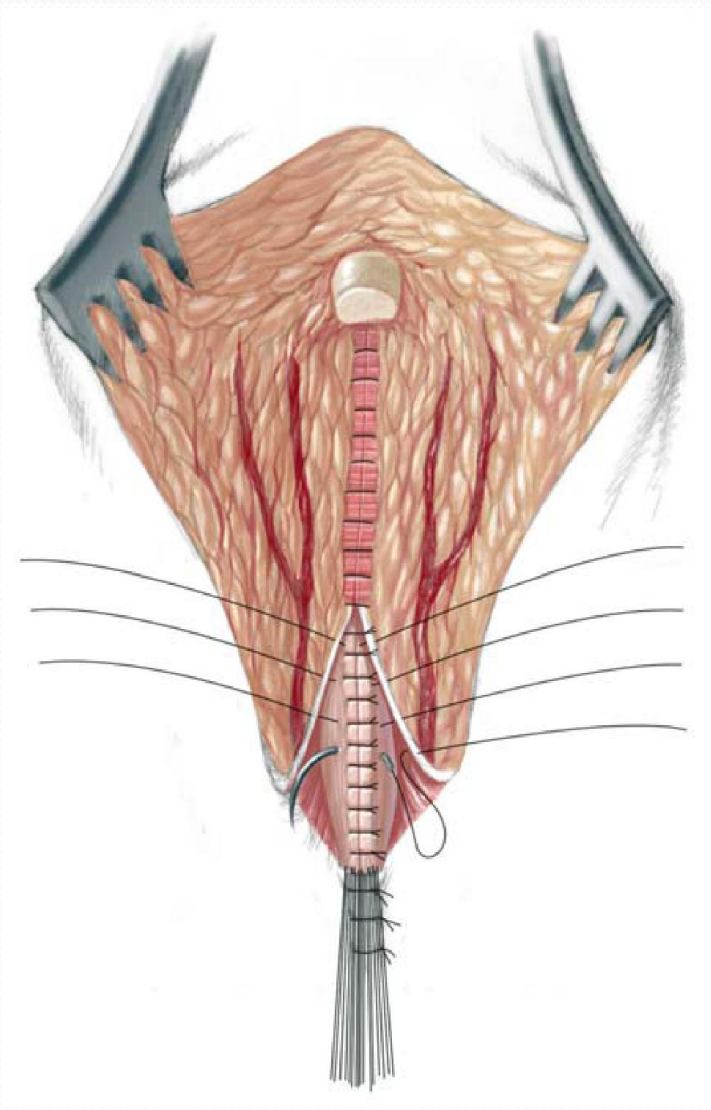
Operation













The end