

## 01. Title

# Neurootological Aspects of Presbydystaxia

## 02. Authors with affiliation

**Prof. Dr. Claus-Frenz Claussen \*)**

\*)Neurootologisches Forschungsinstitut der 4-G-F Forschung e.V. , Bad Kissingen, Germany

**Elemér Nagy MD. \*\*)**

\*\*)Leader of the Vestibular and Psychological Research Groups , Budapest, Hungary

**Dr. José Carlos Rosmaninho Seabra \*\*\*)**

\*\*\*)Hospital Privado de Boavista

**Dr. Beata Bencsik \*\*\*\*)**

\*\*\*\*)Semmelweis University of Medicine, Budapest, Hungary

**Dr. Gabor Bencze \*\*\*\*\*)**

\*\*\*\*\*)Controlling Department of State Health Center, Budapest, Hungary

**Dr. Lóránt Heid \*\*\*\*\*)**

\*\*\*\*\*)State Health Center, Budapest, Hungary

**Prof. Dr. Michael Kersebaum \*\*\*\*\*)**

\*\*\*\*\*)Neurootologisches Forschungsinstitut der 4-G-F Forschung e.V. , Bad Kissingen, Germany

## 03. Key words:

ataxia, abasia, astasia, presbydystaxia, equilibrimetry, vestibulometry, Cranio-Corpo-Graphy (CCG), human space trail (HUSPATRAC), 3-D head and body movements, , neuronal degeneration, sensorial degeneration, human aging process , old age

## 04. Summary:

Coordination deficits exhibiting failures in the human harmonious function of interrelated organs, which expresses the connection between the human sensors and the brain, can lead to dysfunctions in the bipedestal standing and walking reactions. Especially these failures in the regular organization of human standing and walking occur in the age above 50 but especially above 70. Besides they also occur in various neurodegenerative diseases.

We discriminate abasia, which is the inability to walk. For instance, abasia atacticta is characterized by uncertainty of movement due to a defect of coordination. The astasia abasia expresses a motor incoordination with inability to stand or walk despite normal ability to move the legs when sitting or lying down. Finally, the dystaxia ataxia expresses a motor incoordination with an inability to stand. It depends on a failure of muscular coordination or an irregularity of muscular action.

Special interest is drawn from clinical examples of Cranio-Corpo-Graphy patterns of stepping and standing reactions. The recordings of CCG are quick, objective and quantitative. This paper underlines the typical findings by CCG patterns expressing the various pathology in the head and movements deviations, which can be read off the CCG-chart instantaneously by the first glance from the configuration of the picture.

## 05. Introduction:

Ataxia means inability to coordinate voluntary muscular movements. Ataxia in old age is also called Presbytaxia.

In common usage, the term describes an unsteady gait. Ataxia may be characterized by involuntary trembling of parts of the body when performing voluntary movements, by difficulty in performing precise movements, or by disturbance in balancing the body. The condition is a symptom of a number of different disorders, such as Parkinson's disease, but ataxia is not a disease itself. It may be caused by an injury to, or a disease of, the central nervous system, particularly the cerebellum, basal ganglia, or cerebrum.

Most hereditary ataxias of neurological origin are caused by degenerations of the spinal cord and cerebellum. Frequently also other parts of the nervous system are involved. The most common of these is Friedreich's ataxia, named after the German neurologist Nikolaus Friedreich.

Aging begins as soon as adulthood is reached and is as much a part of human life as are infancy, childhood, and adolescence. During senescence, the gait may become progressively unsteady, frequently interpreted as clumsiness. The unsteadiness further progresses to a broad-based, lurching gait; sudden turns are extremely difficult without falling. Tremors develop in the upper extremities and in the head. Speech is slow, slurred, and monotonous. Skeletal degenerations and muscle weakness are common.

Human behaviour is highly dependent on the reception and integration of information derived from sensory organs, such as the eye and ear, as well as from nerve endings in skin, muscle, joints, and internal organs. There is, however, no direct relation between the sensitivity of receptors and the adequacy of behaviour, because the usual level of stimulation is considerably greater than the minimum required for stimulation of the sense organs. In addition, an individual adapts to gradual impairments in one sensory organ by using information available from other sense organs. Modern technology has also provided eye glasses and hearing aids to compensate for age reduced acuity in the sense organs.

In Neurotology we are regularly confronted with Patients suffering from vertigo, dizziness, giddiness, tinnitus, hearing deficiencies alone or in combinations. With respect to old age the subjective signs of rocking vertigo, instability and a tendency to falling increase steadily with growing age. Prominent signs are different forms of ataxias including "presbydystaxia". Nowadays we can further discriminate different forms of dystaxias by their images of CCG recorded individual movement patterns.

A simple objective and quantitative neurotometric test for measuring the degree of instability during standing and walking, i.e. stepping, is the Cranio-Corpo-Graphy - CCG (Claussen, 1968). It transfers the movement patterns of head and shoulders into charts looking like radar images.

Cranio-corpo-graphy serves several major functions - as a neurotological clinical diagnostic test for differentiating normals from patients with peripheral vestibular or central disequilibrium, further as a follow-up investigation testing the efficacy of a medication or a surgery. It also serves for proving malingering, for making occupational medical judgements upon ability. Finally it helps for monitoring the patient's neurotological status over time.

Computerised ultrasound cranio-corpo-graphy (US-COMP-CCG) now also enables us to distinguish between lesions at various levels in the psychomotor system. Further, the method can be used as monitor for drug trials. This method has been further developed into human space trail of Claussen (HUSPATRAC), which easily shapes and analysis 3-D head and body movements like virtual holograms.

## 06. Material & Methods

### Method of the ultrasound computer Cranio-corpo-graphy (US-COMP-CCG).

In different pathologies many different gait patterns have been described in relation with various and most different diseases. Typical expressional temporo-spatial movement patterns now can be established by means of precise functional measurements at typical spots of interest within a virtual mathematical framework. (fig.1 -3)

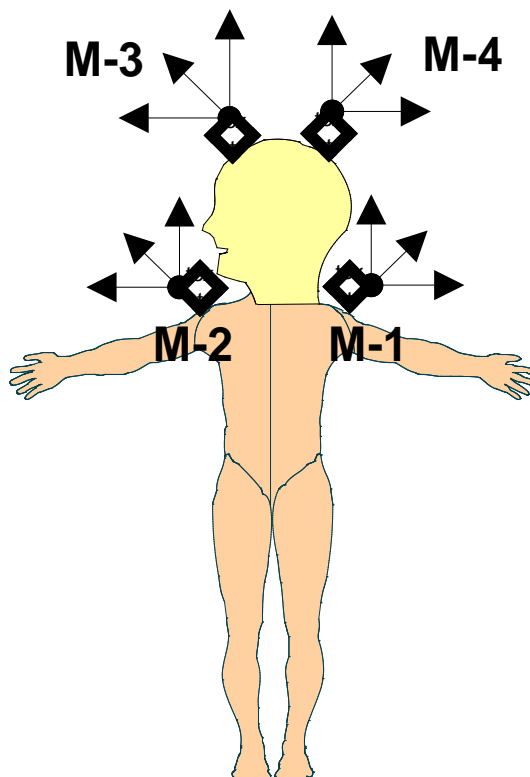


Fig.1. Marking the upright standing (and /or stepping) patient for the cranio-corpo-graphy (CCG) at 4 typical spots of interest (M1 – M4).

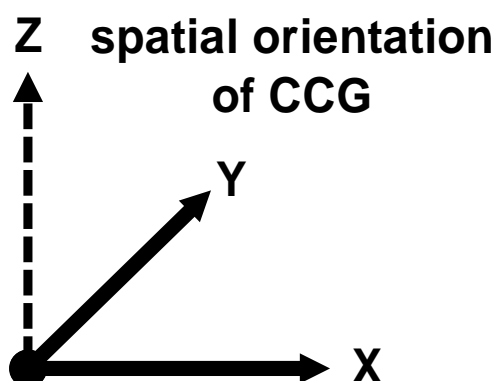


Fig.2. Coordinate system for measuring the upright standing (and /or stepping) patient during the cranio-corpo-graphy (CCG) within a virtual rectangular mathematical framework.

Cranio-corpo-graphy with the newly developed ultrasound computer cranio-corpo-graphy (US-COMP-CCG) is very easily to be handled. It is an important achievement in the toolbox of equilibrimetry for regular and special neurootological investigations. (fig.3)

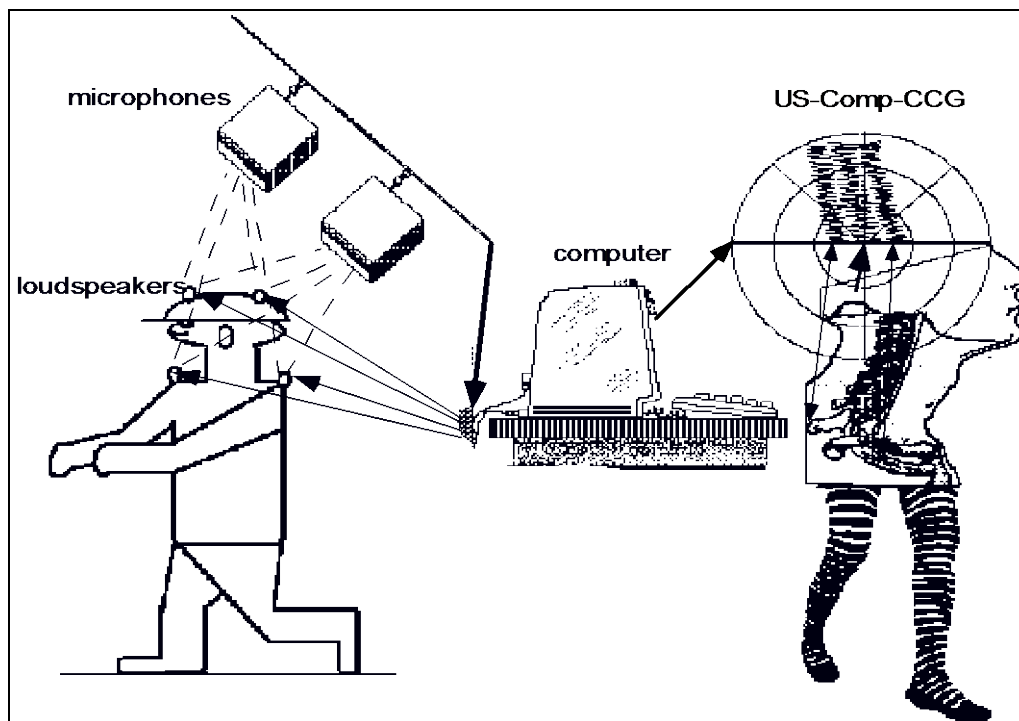


Figure 3.

Schematic graph of ultrasound computer cranio-corpo-graphy (US-COMP-CCG). The patient is carrying a helmet with 2 ultrasound markers and a shoulder supports with 2 other ultrasound markers. A computer unit in the center of the picture is triggering the ultrasound impulses. Backwardly and above the patient are several ultrasound receivers with microphones and data processors. The signals received are sent to the computer unit. The computer unit calculates the spatial positions of all the 4 ultrasound markers. It is displaying a radar image like graph with a centrally adjusted starting point and the traces of all the 4 head and shoulder movements on the screen (picture on the right, up). The computer program in the PC (center) is handling the protocol, the procedure and the movement analysis.

During the recording procedure, each of the markers is producing 20 short sound impulses per second. The trigger is operated by a central computer unit. The sound impulses are received by a fixed set of 3 microphones in each box, being installed on top of the test person. The sound impulses are received, processed and transmitted to the personal computer. Finally, the run time differences between each of the acoustic markers and each of the microphones are compared with each other by means of a specific computer program. A computer program then establishes a spatial image of each of the marker positions.

Storing the marker positions during a time series into a data bank allows to draw 2-dimensional (US-COMP-CCG) or 3-dimensional (HUSPATRAC) images, like trajectories, of each of the recorded marker points at the head or the shoulders together or separately.

For clinical purposes we mainly apply this method together with the well established polar network of cranio-corpo-graphy charts. The head and the shoulder movements

then appear like the radar images of 4 moving objects, progressing in the same direction, in a polar plane.

Clinically we regularly apply the ultrasound computer cranio-corpo-graphy (US-COMP-CCG) for 2 important vestibular spinal tests, i.e., Romberg's standing test, and Unterberger's and Fukuda's stepping test.

### **Standing test**

During the standing test, i.e. Romberg's standing test, the test person or patient is blindfoldedly standing in an upright position in front of the computer and receiver system. The microphone receiver unit is mounted approximately 2.2 m above the floor level with an inclination of about 15 degrees anteriorly. (fig.3) The sound markers are mounted above the front and the occiput of a workman's hard hat. The shoulder markers are mounted on a special shoulder harness above both the shoulders, pointing backwardly. By a cable the patient is permanently connected to the computer system. The whole investigation can take place in an illuminated environment.

At the beginning of the investigation cycle, the operator is writing the personal identification data of the patient and the kind of investigation into the computer. Then he is selecting the special investigation program for the Romberg's standing test. After pressing the start button, the computer monitor is displaying a polar coordinate network like a radar image. Then it receives the tracings of each of the marker points within this network. So the operator can follow the progress of the investigation during 60 seconds. At the end of the recording procedure, the computer is releasing a sound signal. Immediately after the end of the investigation, the computer is digitally evaluating the important data of the lateral and the sagittal sway of the marker points. These results are graphically displayed in the radar image like chart. They are also numerically written into a schedule right of the graphic display.

The parameters for evaluating the standing test cranio-corpo-grams are:

1. longitudinal sway in cm, (normal 1.75 to 10.53 cm),
2. lateral sway in cm, (normal 1.74 to 7.06 cm),
3. torticollis angle in degrees of the cranial torque with respect towards the connecting line between the shoulders (normal – 8.06 (right) to + 6.08 degrees (left)).
4. area of coverage of the frontal marker in sqarecm.

An interrelated movement pattern between the longitudinal axis of the skull, combining the frontal and the occipital light, with the transversal axis of the shoulders allows to continuously displaying the angular instability of the neck. (Rotations of the head towards the right and towards the left are displayed in a time extended strip chart. This measurement is especially of importance for posttraumatic neck sprains and neck hypermobilities.)

The protocol of the investigation and the test results are printed on a colour printer, graphically separating all the 4 traces of the 2 head markers and the 2 shoulder markers.

### **Stepping test**

Basically the performance of the Unterberger's and Fukuda's stepping test is similarly recorded like the above described Romberg's standing test.

The investigator is identifying the patient in the computer data bank. Then he selects the test program for the stepping test procedure. The patient is blindfolded. He is carrying the head and shoulder markers.

At the beginning of the recording procedure, he is requested to step on the spot with a speed of at least 1 step per second. The marker movements are recorded, calculated and displayed in the radar image like CCG-chart. During the stepping procedure, the patients regularly move about 1 m forward. After 60 seconds, the computer releases a sound signal, indicating that the patient shall stop.

Then the test results are analyzed graphically and numerically. The movement pattern is graphically adjusted to the center of a polar coordinate system, from where the test started. This means that the starting position of the test person is not bound to a concise starting point. The adjustment is performed by the program.

The 4 parameters for quantitatively evaluating the stepping test cranio-corporo-grams are:

1. longitudinal displacement from the starting to the end position in cm, (normal 30.03 to 113.35 cm),
2. lateral sway width during the stepping cycles measured in cm, (normal 5.17 to 16.15 cm),
3. angular deviation in angular degrees between the directions of the starting position and the end position, (normal – 55.13 (right) to + 48.37 degrees (left)),
4. body axis spin in angular degrees in the end position compared with the starting position (normal – 82.21 (right) to + 82.89 degrees (left)).

The patient is requested to step 80 to 100 times during one minute on the spot. After about 30 to 40 steps he is mainly dependent on his inborn vestibular orientation system when trying to maintain his position. Patients with peripheral vestibular lesions then deviate to the affected side (fig.4) and additionally mostly exhibit a body spin, i. e., they also rotate around their own axis towards the side of the lesion. Stepping is a dynamic locomotion test needing a high degree of central coordination.

Patients with central (brainstem) lesions enlarge their sway (fig.4).

The system is also supplied with a zoom function so that we easily can enlarge tiny head and shoulder movements or reduce overactive dystactic movements.

Higher brainstem lesions also show an increase in the width of sway in the Romberg test CCG. The more sensitive test, however, is the stepping test.

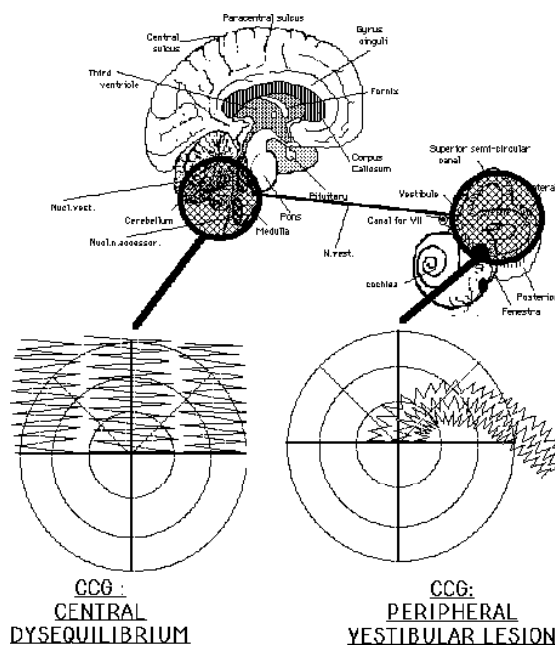


Fig.04- The topdiagnostically explained model graph of a central disequilibrium shown in the stepping test (left side) and a peripheral vestibular lesion exhibited on the right side.

Clinical interpretation: A systematic analysis of the CCGs helped by clinical statistics of big samples revealed certain typical patterns, which were associated with lesions at various levels in the vestibular system. An abnormally large angular deviation together with a normal width of the lateral sway indicates a peripheral lesion (fig.4). A desinhibited, i.e. supranormal, lateral sway in the stepping test proves to be a reliable indicator for central dysfunctions (mostly of the cerebello-ponto-medullary type) (fig.4). Abnormal standing sway values add to the lesion. Combined lesions, i. e., those occurring at multiple levels, are diagnosed when the CCG pattern shows both a large angular deviation as well as wide sway.

## 07. Results:

### **Statistical results:**

The histories of our vertigo patients have been taken by means of our preprinted questionnaire NODEC III. 4 major databanks NODEC I - IV have been established during more than 15 years from all our about 30.000 neurotological patients of both sexes and 10 decades of ages.

Table 1 contains the major vertigo symptoms of old-age persons in relation to one of our statistical data banks NODEC IV.

Tab. 1

Vertigo and nausea symptoms of old-age persons according to a statistical analysis of 10335 patients from both genders and 10 decades of the neurotological data bank NODEC IV with respect to the total sample as well as to 3 age classes (10335=100%):

Symptoms	NODEC IV 10335=100%	51-60 years 1965=100%	61-70 years 1033=100%	71-80 years 313=100%
Rocking sensation	39,1 %	44,9 %	49,6 %	54,2 %

Lift sensation	5,3 %	5,8 %	5,2 %	1,6 %
Rotating vertigo	35,9 %	43,0 %	35,2 %	34,3 %
Falling tendency	19,7 %	26,1 %	24,5 %	22,8 %
Blackout	19,7 %	24,1 %	19,6 %	14,7 %
Instability	35,5 %	45,0 %	45,0 %	51,0 %
Sweating	11,9 %	14,0 %	12,2 %	9,7 %
Nausea	30,1 %	34,7 %	32,1 %	27,1 %
Wretching	3,7 %	4,7 %	3,0 %	2,3 %
Vomiting	15,1 %	18,8 %	16,6 %	16,1 %
Collapse	5,8 %	9,0 %	7,5 %	5,2 %

From table 1 it can easily be found that not all the vertigo symptoms show an increase with a growing age. The most prominent signs which increase with increasing age are a rocking sensation, falling tendency and instability. The falling tendency and the instability objectively correlate with the body movements of the patients. During walking the patient is staggering, unstable and swaying more than in younger years.

### Casuistic results:

In the following section we want to demonstrate case wise by the results of the ultrasound computer cranio-corpo-graphy (US-COMP-CCG) for 2 important vestibular spinal tests, i.e., Romberg's standing test, and Unterberger's and Fukuda's stepping test how presbydistaxia individually may express itself through the different shapes and configurations of individually drawn images of CCG-charts..

Typical corporal scripts of standing test CCGs are depicted below, starting with a normal standing-CCG in fig.05.

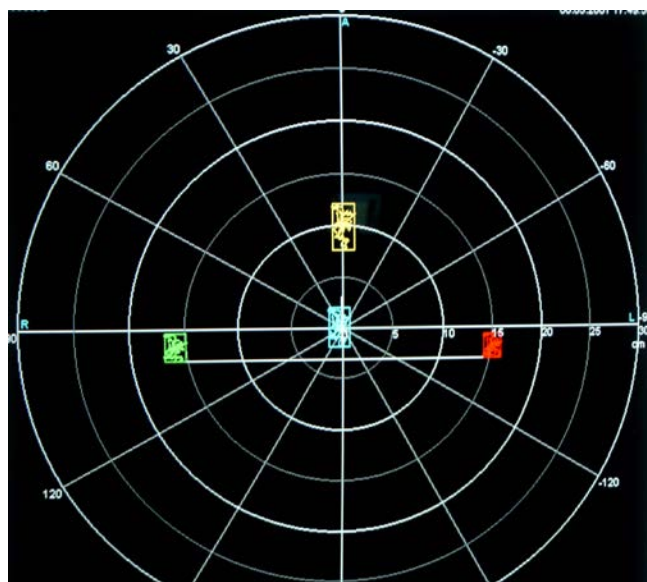


Fig.05- This ultrasound computer cranio-corpo-graphy (US-COMP-CCG) figure exhibits a standing test CCG of a 54-year-old male suffering from little vertigo. During 1 minute of standing, he exhibits a longitudinal sway of 4.46 cm, whereas the lateral sway only amounts to 2.32cm. The coverage of the frontal marker area only amounts to 10.32 cm<sup>2</sup>. There is a torticollis angle of only 1,12° to the left.



This cranio-corpo-gram shows a normal sway pattern at the right shoulder (green) and the left shoulder (red). Also, the forehead (orange) and the occiput (blue) are normal.

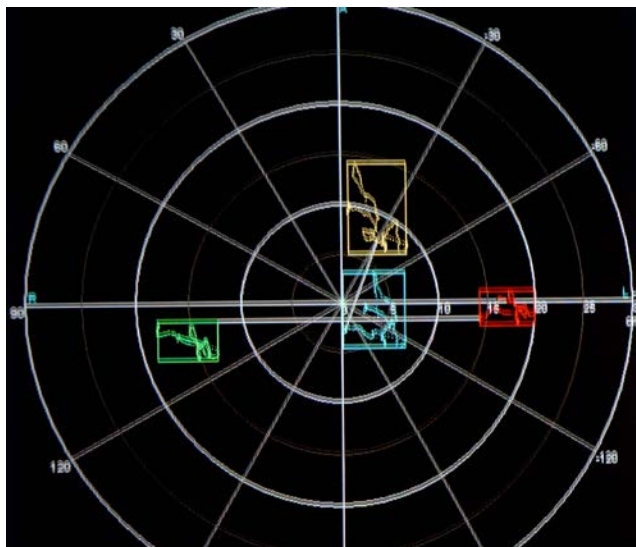


Fig.06- This ultrasound computer cranio-corpo-graphy (US-COMP-CCG) picture exhibits the results of a 1-minute standing test in a 66-year-old male. During the standing, he exhibits a longitudinal sway of 9.12 cm, a lateral sway of 6.17 cm, area coverage of the forehead marker of only 56.27 cm<sup>2</sup>. There is a torticollis angle of 20.24° to the left.

When looking into movements of the right shoulder (green), the left shoulder (red), the occiput (blue) and the forehead (orange), it is easy to be seen that the head moves more than the shoulders. The surfaces of the oscillations of the head are more than triple as big than those of the shoulders. However, the movements are very slow when relating them to a 1 minute standing time. This is a disrhythmia with reduced excursions during 1 minute standing. Intracorporally, the head enlarges the sway patterns of the two shoulders.

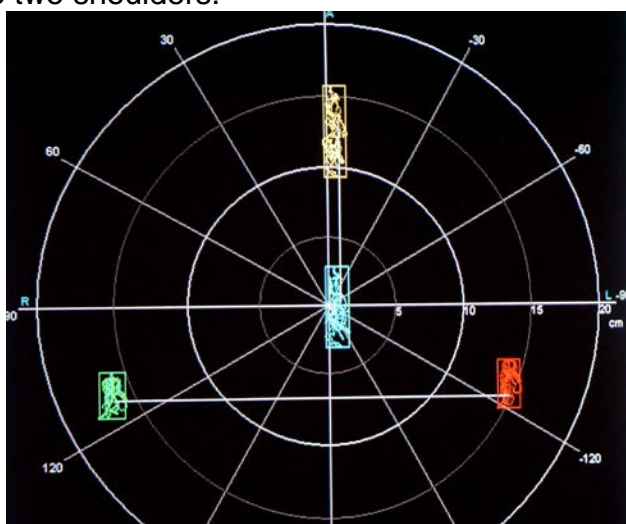


Fig.07- This computer cranio-corpo-graphy (US-COMP-CCG) picture exhibits a standing test CCG of a 60-years-old male suffering from a Parkinsonism. During 1 minute of standing, he exhibits a longitudinal sway of 6.46 cm, whereas the lateral sway only amounts to 1.81cm. The coverage of the frontal marker only amounts to 11.69 cm<sup>2</sup>. There is a torticollis angle of only 0.09°.

This cranio-corpo-gram shows a strictly longitudinal sway with a normal sway pattern at the right shoulder (green) and the left shoulder (red). However the head hangs forwardly in front of the shoulder line.

However, the forehead (orange) and the occiput (blue) are significantly longitudinally extended, as it mostly happens during the nodding movement of Parkinson's patients.

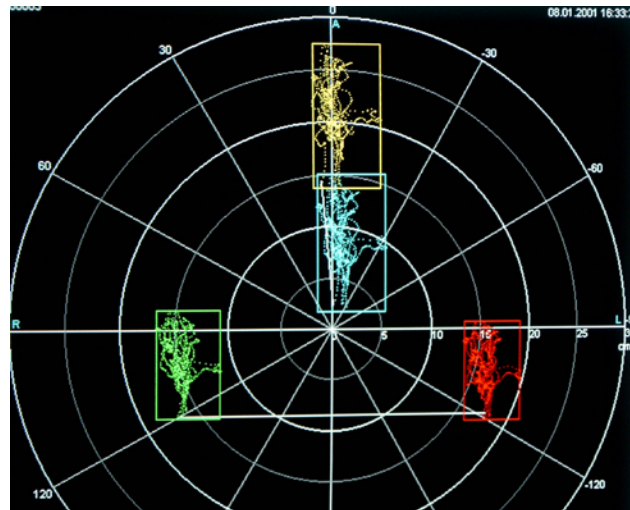


Fig.08- This computer cranio-corpo-graphy (US-COMP-CCG) picture exhibits a standing test CCG of a 66-years-old-male of a 1-minute standing test procedure. It shows a longitudinal sway of 13.77 cm, a lateral sway of 6.84 cm, an area coverage of the frontal marker of 94.19 cm<sup>2</sup>, and torticollis angle of 6.16°.

This configuration shows that all the four markers (right shoulder = green, left shoulder = red, occiput = blue, front = orange) attempt to sway in a dystaxic manner more in the longitudinal frontal axis than laterally. The head hangs remarkably in front of the shoulder line.

However, additionally, it is seen that the patient increases his sway patterns as well as in both the shoulders as in the head from the smaller excursion from the starting position to a V-shaped widening by the end of the 1-minute standing procedure. This pattern is typical of time stress dystaxias in a special combination with Parkinson's disease.

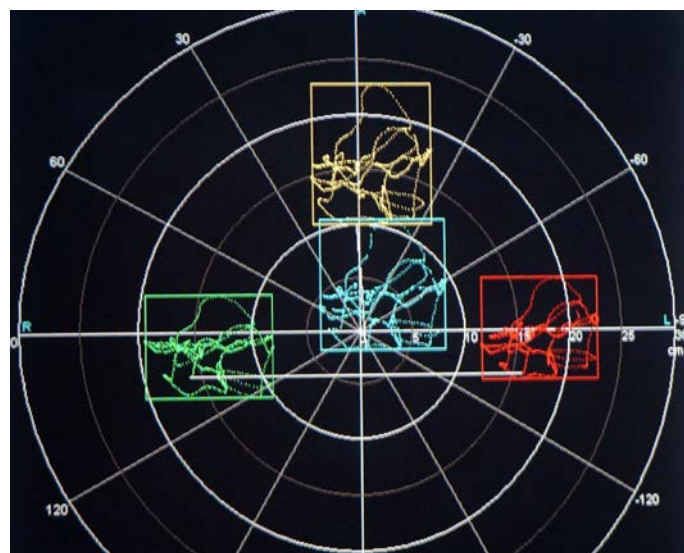

Fig.09- This computer cranio-corpo-graphy (US-COMP-CCG) picture exhibits a standing test CCG of a 66-year-old female. During 1 minute of standing, she exhibits a longitudinal sway of 12.78 cm, a lateral sway of 11.37 cm, a coverage area of the frontal marker of 145.31 cm<sup>2</sup> and a torticollis angle of 4.92°.

At all the four markers, i.e. right shoulder (green), left shoulder (red), occiput (blue) and front (orange), nearly equal patterns of overshooting movements and oscillations of a typical irregular dystactic manner are recorded.

So, this pattern exhibits a whole-body dystactic and overshooting sway with no intracorporal differentiations between head and shoulders.

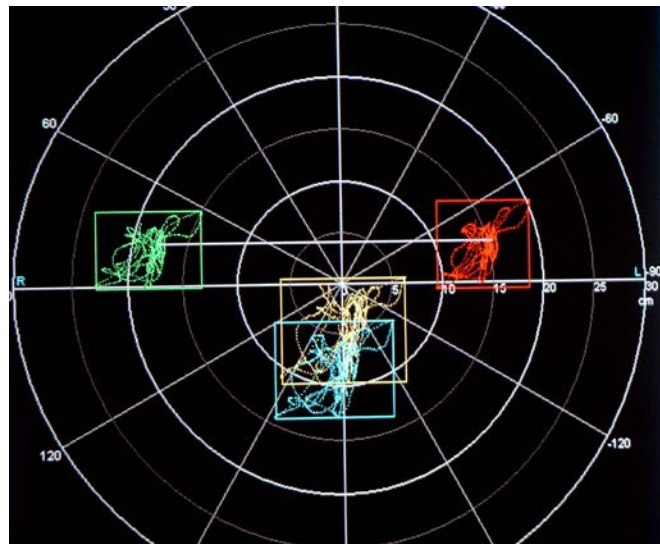


Fig.10- This computer cranio-corpo-graphy (US-COMP-CCG) picture exhibits a standing test CCG of a 60-year-old male of a 1 minute standing test.

Longitudinal sway 10.21 cm, lateral sway 12.25 cm, coverage area of the forehead 125.07 cm<sup>2</sup>, torticollis angle 11.42° to right.

The patient shows an inadequate position with the head hanging much more backwardly off the shoulder line than normal.

All the movement patterns of the right shoulder (green), of the left shoulder (red), of the forehead (orange) and of the occiput (blue) are dystactic.

However, the head seemingly is much too loose and sways double as much as the two shoulders in the laterally hanging or over-extended position.

This exhibits an intracorporal distortion combined with a general dystaxia.

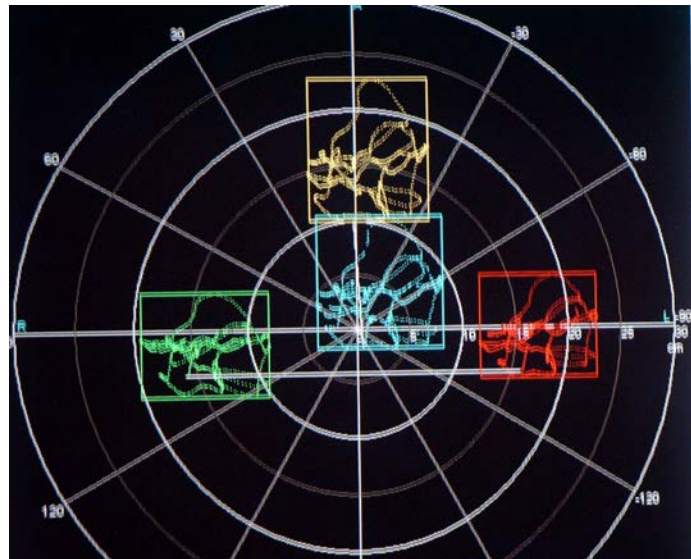

Fig.11- This computer cranio-corpo-graphy (US-COMP-CCG) picture exhibits a standing test CCG of a 66-year-old female. During 1 minute of standing, she exhibits a longitudinal sway of 12.78 cm, a lateral sway of 11.37 cm, an area coverage of the frontal marker of 145.31 cm<sup>2</sup> and a torticollis angle of 4.02°.

When looking at the performance of the standing test, there is a predominance towards a lateral sway in the right shoulder (green), in the left shoulder (red), in the occiput (blue) and in the front (orange).

These pronounced lateral sways are rather rare within our catalogue of dystaxic patterns.

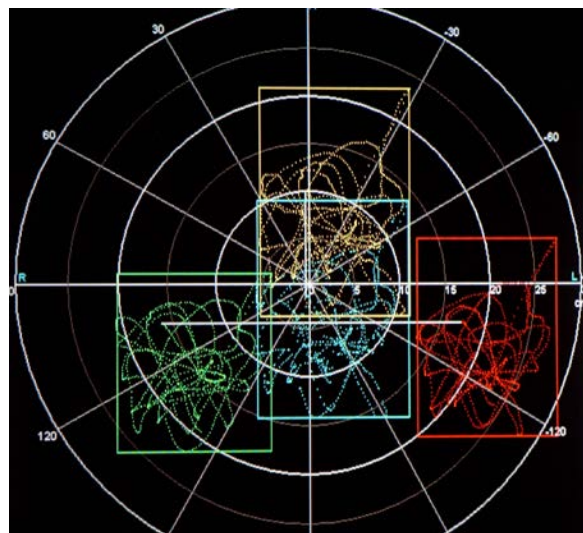


Fig.12- This computer cranio-corpo-graphy (US-COMP-CCG) picture exhibits a standing test CCG of a 62-year-old male.

During 1 minute of standing, he exhibits a longitudinal sway of 24.34 cm, a lateral sway of 16.48 cm, an area coverage of the frontal marker of 401.12 cm<sup>2</sup> and a torticollis angle of 0°.

It is a very rough dystaxic pattern occurring in the same manner on the right shoulder (green), on the left shoulder (red) as well as on the occiput (blue) and on the front (orange).

This is a typical major standing dystaxia of a large scale without any directional preference in the sense of a dystaxia ataxia, which expresses a motor incoordination with an inability to stand .

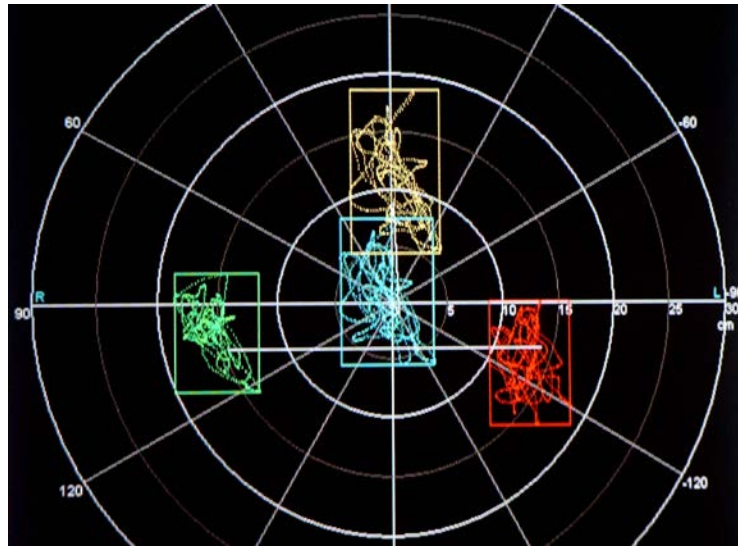


Fig.13- This computer cranio-corpo-graphy (US-COMP-CCG) picture exhibits a standing test CCG of a 67-year-old female.

The head and shoulder movements during 1 minute of standing procedure exhibit a longitudinal sway of 14.13 cm, a lateral sway of 8.13 cm, an area coverage of the frontal marker of 814.88 cm<sup>2</sup> and a torticollis angle of 2.37° towards the right.

The head (occiput: blue, forehead: orange) is rotated towards the right as well as the right shoulder (green), whereas the left shoulder (red) oscillates in the spot mainly in the longitudinal direction but with no oblique torsion.

This pattern shows a dystaxia with an intracorporal torsion mainly on one side (right).

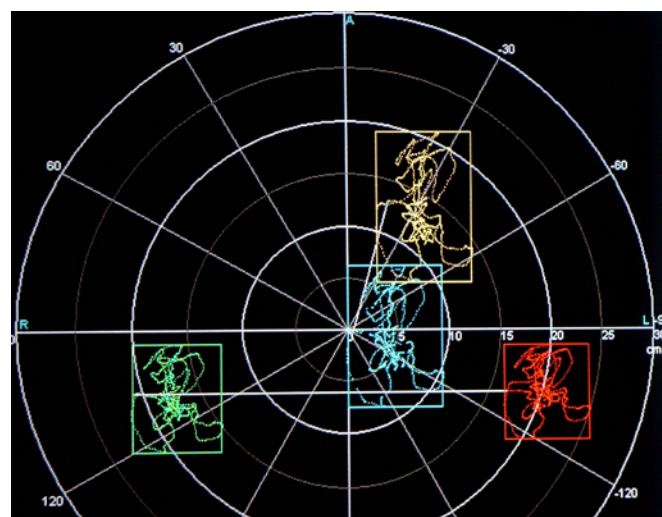


Fig.14- This computer cranio-corpo-graphy (US-COMP-CCG) picture exhibits a standing test CCG of a 52-year-old female.

During a 1 minute standing, she exhibits a longitudinal sway of 14.31 cm, a lateral sway of 9.44 cm, an area coverage of the frontal marker of 135.9 cm<sup>2</sup> and a torticollis angle of 15.25° towards the left.

Even the position of the head is more deflected to the left than to the midline.

The person exhibits much of dystaxic activity in the right shoulder (green), the left

shoulder (red) and even more in the head (occiput: blue; forehead orange). In this case, the dystaxia, which is demonstrated by irregular movements, is oscillating more in the longitudinal direction than in the lateral direction, those together with a head deflection towards the right shoulder demonstrates a supratentorially pronounced deregulation.

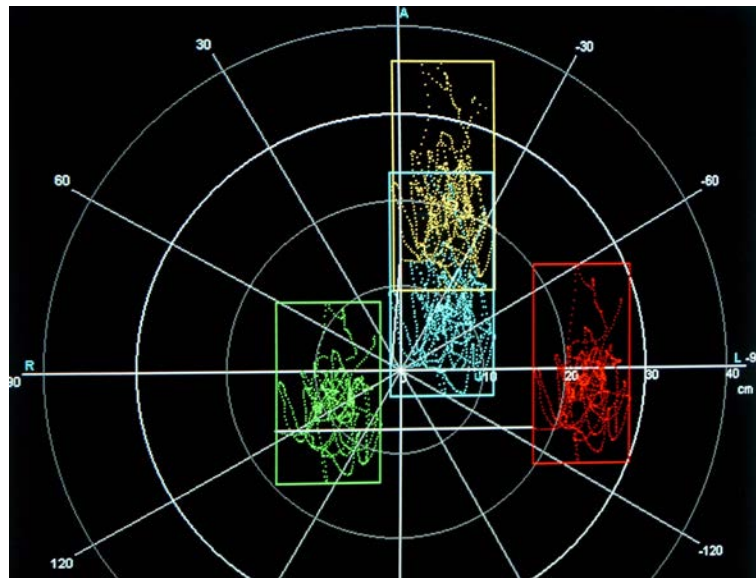


Fig.15- This computer cranio-corpo-graphy (US-COMP-CCG) picture exhibits a standing test CCG of a 57-year-old male.

Stepping test of 1 minute: Longitudinal sway 26.63 cm, lateral sway 12.35 cm, area coverage of the frontal marker 328.8 cm<sup>2</sup>, torticollis angle 5.32°.

The patient exhibits a dystaxia occurring as well in the right (green) as well as in the left (red) shoulder and especially in the frontal marker (orange) with a combined dystaxia in the occipital marker (blue).

Seemingly, the head swings more in the postero-anterial direction than the two shoulders. But the whole sway pattern is directed in the longitudinal axis. This gives a certain suspicion for Parkinsonism overlaying the dystaxia with an instable head.

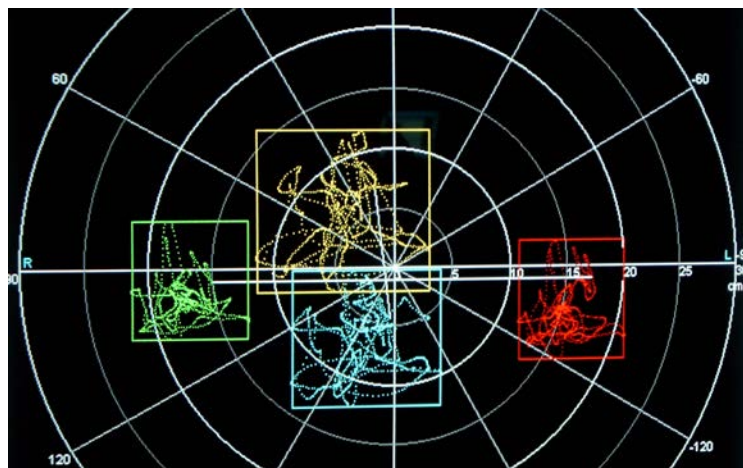


Fig.16- This computer cranio-corpo-graphy (US-COMP-CCG) picture exhibits a standing test CCG of a 67-year old female.

Standing test of 1 minute: Longitudinal sway 13.63 cm, lateral sway 14.60 cm, area coverage of the frontal marker 199 cm<sup>2</sup>, torticollis angle 6.33°.

The standing pattern of this female patient shows that there are much lesser excursions in the two shoulders than in the head as demonstrated by the occiput (blue) and the front (orange).

The right shoulder (green) and the left shoulder (red) show in comparison to the head movements that this is the picture of an ataxia with a typical loose head also in the sense of a dystaxia ataxia, which expresses a motor incoordination with an inability to stand.

The above samples in fig.06 till 16 represent typical results of ultrasound computer cranio-corpo-graphy (US-COMP-CCG) pictures recording head and shoulder movements from standing tests.

The following case reports in fig.17 till 27 are examples of ultrasound computer cranio-corpo-graphy (US-COMP-CCG) charts from objective and quantitative recordings of individual stepping tests.

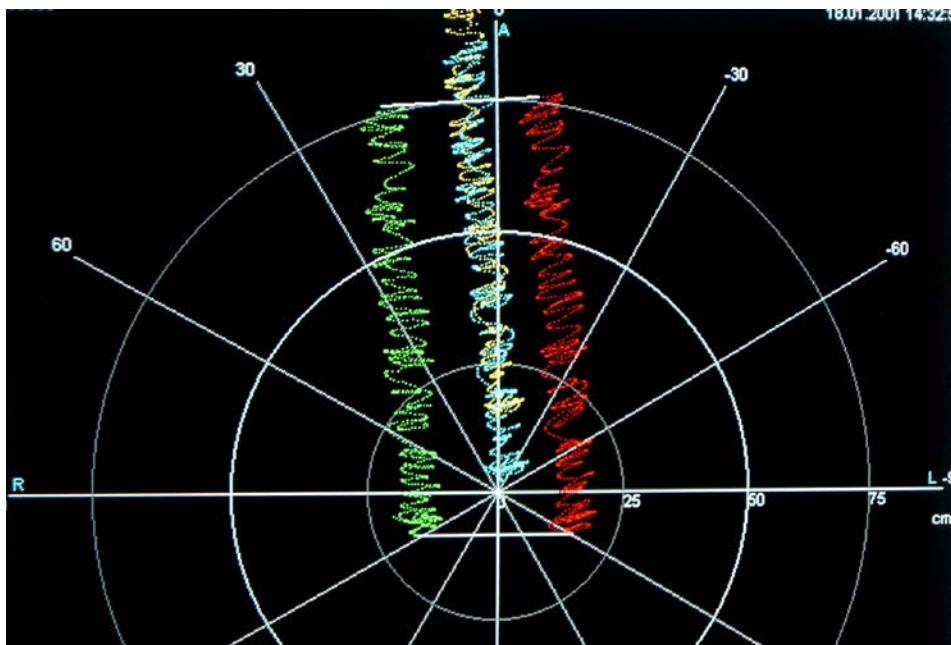


Fig.17- This computer cranio-corpo-graphy (US-COMP-CCG) picture exhibits a stepping test CCG of a 47-years male.

He shows a normal chart with a longitudinal deviation of 583.48 cm, a lateral sway of 9.40 cm, an angular deviation of  $4.75^\circ$  towards the right and a body spin of  $3.84^\circ$ . Number of steps during one minute: 84.

The traces of the right shoulder (green) and the left shoulder (red) are graphically well separated from those of the head (occiput: blue; forehead orange)..

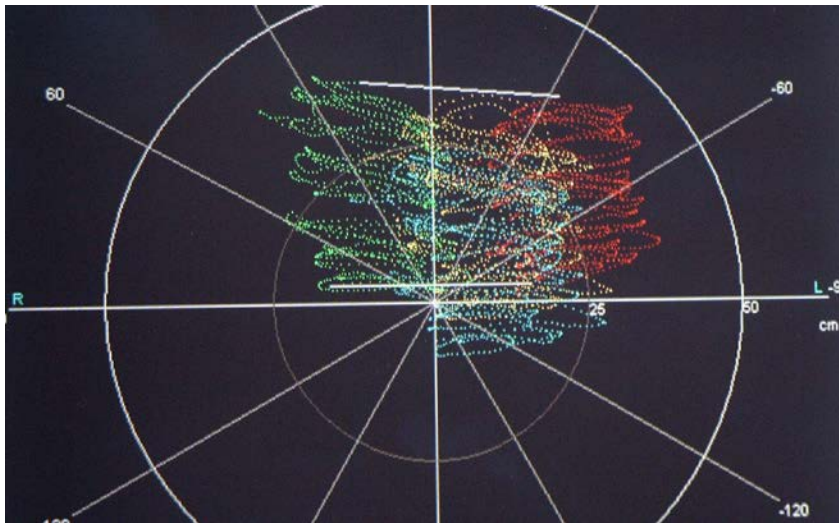


Fig.18- This computer cranio-corpo-graphy (US-COMP-CCG) picture exhibits a stepping test CCG of a 76-year-old female stepping with 44 step cycles during 1 minute. Longitudinal deviation: 33.98 cm, lateral sway 41.29 cm, angular deviation 10,98° towards the left, body spin 4.30° towards the left.

The patient exhibits a major lower brainstem instability with a dystaxia with a broadened, however regular and systematically broadened sway from right (green) to left (red) and left to right. The amount of sway is nearly equal in the head as well as in the shoulder movements, which refers to a whole body giddiness .

Dystactic brainstem pattern of a type which occurs in relation with a PICA-syndrome.

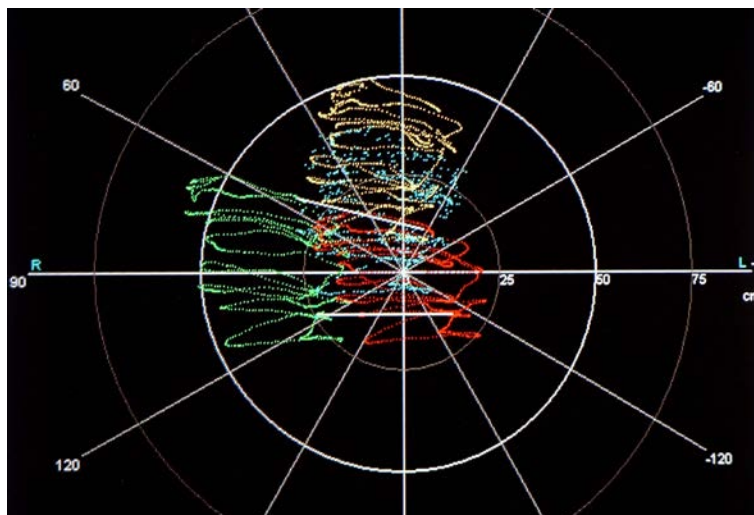


Fig.19- This computer cranio-corpo-graphy (US-COMP-CCG) picture exhibits a stepping test CCG of a 70-year-old male, who only performs 24 steps during 1 minute.

He deviates forwards by 25.83 cm, his lateral sway amounts to 27.23 cm and the angular deviation to 4.11° to the left. His body spin shows 13.9° to the left.

This is a regular destabilization of the lower brainstem type (PICA-syndrome).

The patient oscillates much but in a regular way towards both the sides. However, due to his instability and insecurity, he remains much on the spot and only performs a few steps. The number of step cycles per minute is much less than in a normal patient. Thus, he only advance a little into the regular anterior direction.



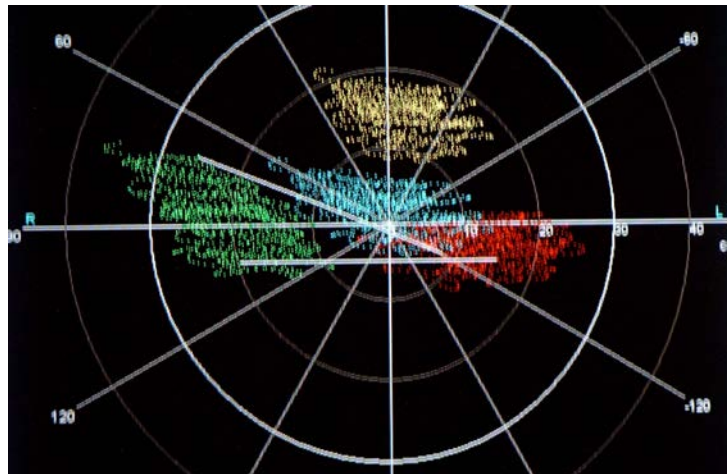


Fig.20- This computer cranio-corporography (US-COMP-CCG) picture exhibits a stepping test CCG of a 67-year-old female carefully performing 70 steps on the spot. Longitudinal deviation 6.92 cm, lateral sway 17.11 cm, angular deviation 11.71°, body spin 22.17°.

The patient exhibits a dystactic pattern, where she tries much to stay on the spot, even though the stepping frequency is rather high for her age.

More excursions occur on the right shoulder (green) than on the left shoulder (red), whereas the head shows at the occiput (blue) and the forehead (orange) minor oscillations than the shoulders. This means that the trunk buffers the dystaxia for the head.

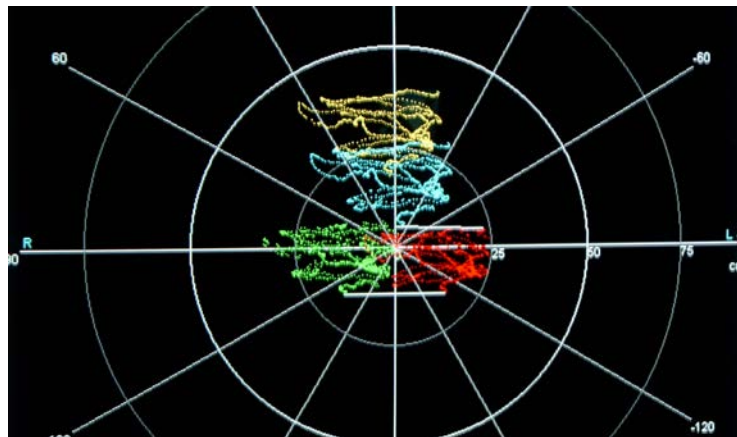


Fig.21- This computer cranio-corporography (US-COMP-CCG) picture exhibits a stepping test CCG of a 63-year-old female with 22 steps during a minute.

She performs a longitudinal deviation of 25.22 cm, a lateral sway of 23.25 cm, an angular deviation of 30.8° towards the left and a body spin of 123°.

The patient mainly steps carefully on the spot as she is afraid of falling. She is dystaxic with wide lateral and irregular oscillations.

The longitudinal deviation from the starting point during 1 minute of stepping is much too short. Also the number of steps within a minute is too small. This demonstrates much of dystactic instability and insecurity.

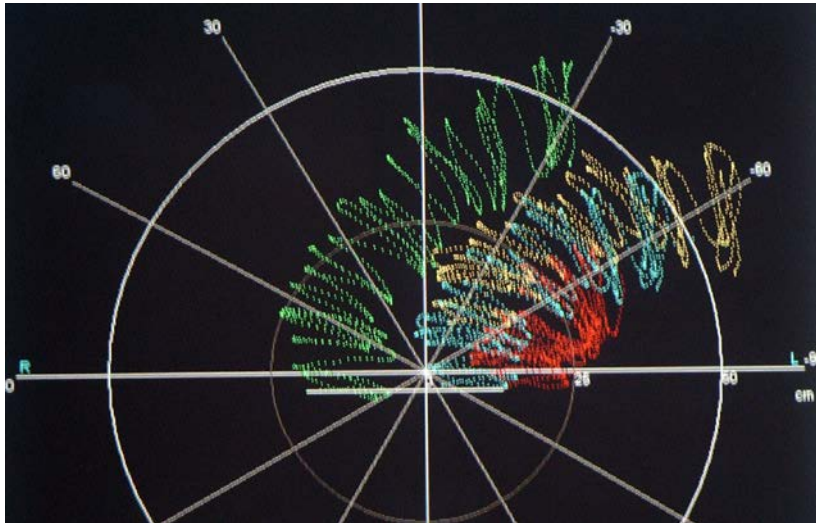


Fig.22- This computer cranio-corpo-graphy (US-COMP-CCG) picture exhibits a stepping test CCG of a 73-year-old female performing 62 steps during 1 minute . The measurements show a longitudinal deviation of 127.30 cm, a lateral sway of 33.53 cm , an angular deviation of 135.61° and a body spin of 33.13°. This patient exhibits an increased lateral sway with a large forward propulsion and a rotation towards the left. In the whole test, she walks forward and deviates to the left. The sway is broad and shows a typical overactivity pattern of a pontine cerebello angular brainstem lesion in the right brainstem (opposite to the side of deviation).

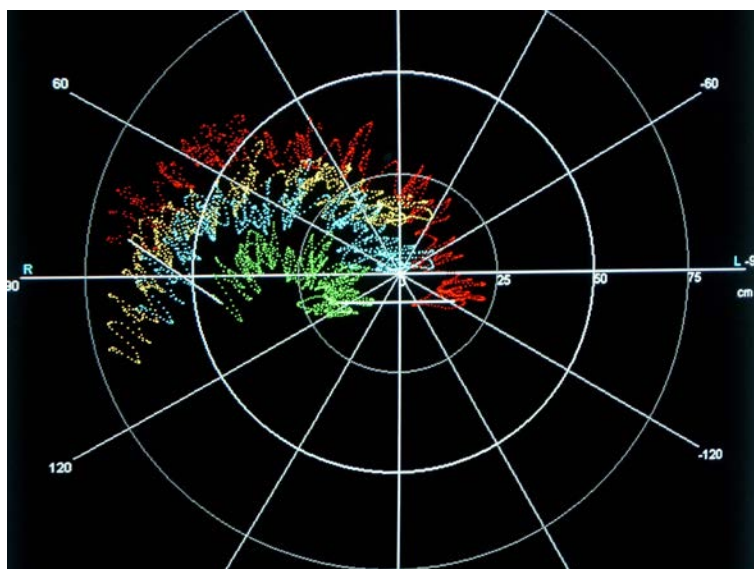


Fig.23- This computer cranio-corpo-graphy (US-COMP-CCG) picture exhibits a stepping test CCG of a 63-year-old male with 86 steps. The measurements show a longitudinal deviation of 74.92 cm, a lateral sway of 18.20 cm, an angular deviation of 115.1° to the right and a body spin of 143.4° to the right. Typical combined dystaxia with deviation towards the right (green), suspicion of a combined peripheral and central vestibular pathology in the brainstem at cerebellar pontine angle of the left side (red) (opposite to the side of deviation).

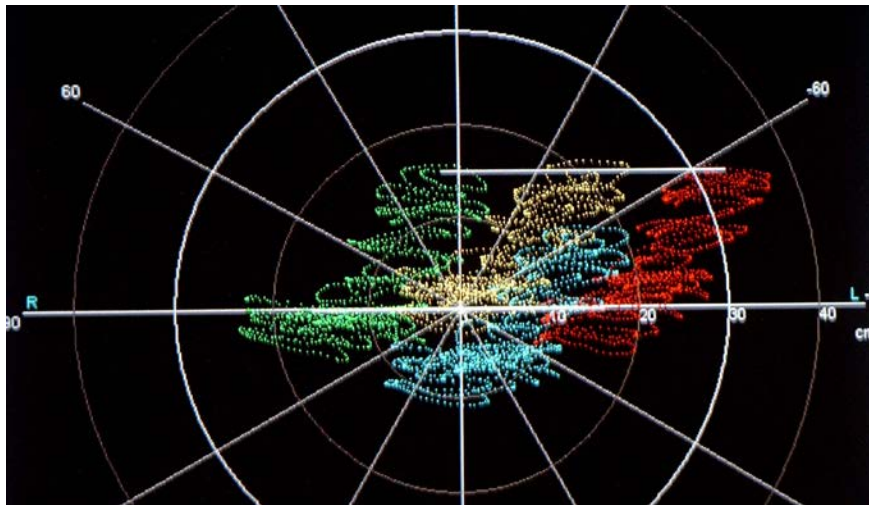


Fig.24- This computer cranio-corpo-graphy (US-COMP-CCG) picture exhibits a stepping test CCG of a 67-year old female performing 58 steps on the spot during the stepping test.

Her longitudinal deviation amounts to 17.97 cm, her lateral sway to 15.67 cm. The angular deviation goes with  $44.04^\circ$  to the left, and her body spin only shows  $0.09^\circ$ .

This patient exhibits a deregulated walking pattern, whereas she partly goes backward. While doing most of the test, she advances forwardly. She is dysrhythmical during her stepping. The patterns are congruent in the shoulder movements on the left side (red) and the right side (green). The posterior head is marked in blue and the forehead part in orange.

A typical psycho-dystaxic pattern, which, however, is affecting the whole body and rather organized.

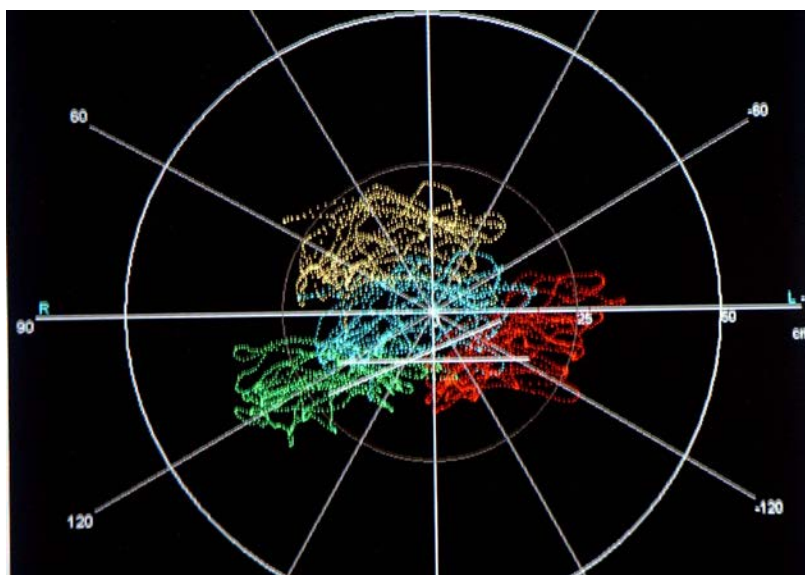


Fig.25- This computer cranio-corpo-graphy (US-COMP-CCG) picture exhibits a stepping test CCG of a 57-year-old male performing 22 steps during 1 minute.

He steps with a pathologically short longitudinal deviation of 13.65 cm but a very large lateral sway of 32.24 cm and angular backward deviation towards the left of  $102.15^\circ$  and a body spin of  $21,9^\circ$ .

This patient nearly performs a  $60^\circ$  rotation from the anterior position towards the left. The shoulders are swinging in a chaotic way, this occurs also with a counterrotation of the forehead (orange) and the occiput (blue).

Mainly, this dystaxic and disorientated patients somehow tries to stay on the spot.

This pattern expresses a psycho-dystaxia in the sense of an abasia attacticta.

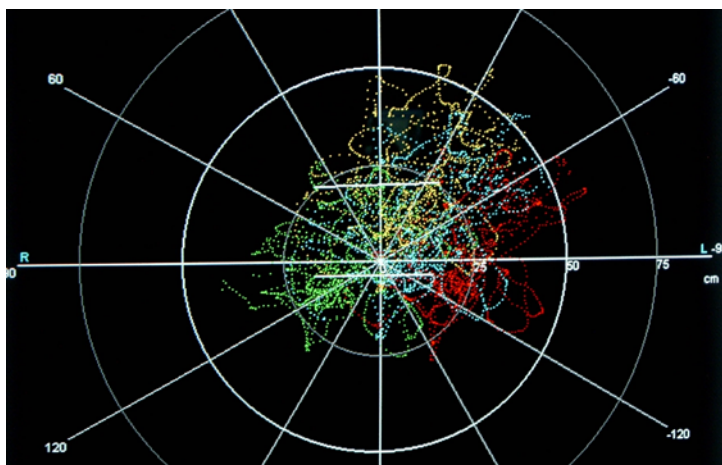


Fig.26- This computer cranio-corpo-graphy (US-COMP-CCG) picture exhibits a stepping test CCG of a 84-year-old female demonstrating severe dystaxia during 44 steps during 1 minute.

Her longitudinal deviation reaches to 29.26 cm, the lateral sway is extremely broad with 48.60 cm. The angular deviation is small with  $6.65^\circ$  towards the left (red), and her body spin  $1.63^\circ$ .

This patient exhibits a severe dystaxia with much subjective instability and insecurity. This shows a typical late presbyataxia with a decrease of physical and mental performance in the sense of an abasia attacticta.

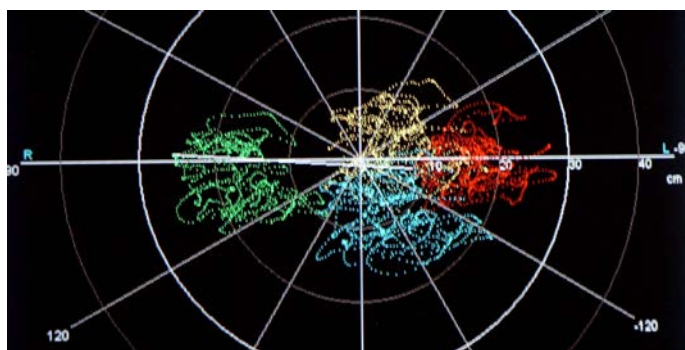


Fig.27- This computer cranio-corpo-graphy (US-COMP-CCG) picture exhibits a stepping test CCG of a 69-year-old female performing 83 steps during the stepping time of 60 seconds.

Longitudinal deviation 8.40 cm, lateral sway 19.86 cm, angular deviation  $115.15^\circ$ , body spin  $4.01^\circ$  towards the right.

When looking at the chart, most of the excursions occur in the neck. The movements are very chaotic. However, the patient tries to step on the spot. Most of the excursions occur at the occiput (blue), whereas the two shoulders (right: green; left: red) are exhibiting oscillations being larger than those of the forehead (orange).

This psycho-dystaxia occurs in intracorporal destabilization and mental desorientation in the sense of an abasia attacticta. It is frequently found in presbydystaxias.

## **08. Discussion & Conclusions**

It is now well accepted that the geriatric population is an important clinical group in its own right, faced with neurootological problems unique to the ageing person. These patients require a sympathetic attitude, a complete clinical history and examination,

and a specific differential therapy based on topodiagnosis, and on pre-existing clinical studies.

Neurootology is covering a pathophysiology, a clinical handling of patients, diagnostic and therapy in the fore fields of the human neurosensorium, namely:

Neurootology basically forms a clinical specialty related to the diseases and the systematic of the disorders of the cranial senses like vision, hearing, equilibrium, taste and smell.

Special interest has arisen in verifying and quantifying the most important subjective disorders, for instance, like instability and dystaxia.

It must be noted here that presbyvertigo is not only the result of a mismatch in data input from the age dependant receptors of the orientation mechanisms. It is also due to a degeneration of the neurotransmittive capabilities of the central balance pathways changing the capabilities of biological data processing. This leads to a general reduction in the sensitivity and the efficacy of the integrated vestibular system, leading to a high risk of falling hazards with all its accompanying disorders. The chronic nature of the condition also raises a number of socio-economic issues. Major aspects of geriatric care include long term nursing facilities and hospitalisation, and the obligations of society towards this "peer group" in general.

More than 40 years back cranio-corpo-graphy was designed as a non electronic, simple office recording procedure for head and body movements. The light tracings of the head and shoulder movements were transformed through an instant camera into photographs which look like a radar image of the head and shoulders floating in the space. This set of tests especially was developed for the West German Berufsgenossenschaften (labour security surveillance boards) as a field test for occupational medical purposes. In 1983 it was officially introduced into occupational medicine in West Germany through the decrete G 41 of the West German Berufsgenossenschaften (labour security surveillance boards).

When the caloric vestibular test investigates the vestibular ocular pathway, the Cranio-Corpo-Graphy especially together with Unterberger's and Fukuda's stepping test investigates the vestibular spinal pathway of the human equilibrium regulation. In the vestibular spinal pathway activities, also dystaxia of various degrees is reflected in the patient (tab.3). The Cranio-Corpo-Graphy is used for analyzing the vestibular spinal body axis. Here, we especially apply the most sensitive vestibular test, the stepping test of Unterberger and Fukuda.

The older Romberg standing test (1848), was meant to elicit "unsteadiness" or "standing ataxia", however it did not really permit quantification as such. Unterberger (1938) developed a gait test where the patient for instance was observed to rotate to the side of an inner ear lesion, when stepping on the spot. However, he did not quantify the test protocol until Fukuda (1959) added on a spider net on the floor for marking the starting and the end position of the feet. They did not yet look to the instability of the trunk and the head as it was performed by Claussen since 1968.

Coordination deficits exhibiting failures in the harmonious functioning of interrelated organs such as the process of the motor apparatus of the brain, which provides for the coordination of particular groups of muscles for the performance of definite adaptive and useful responses, are regularly described by the term "ataxia". Many different clinical forms of ataxia are known today. Typical movement patterns can be

derived by means of the ultrasound computer cranio-corpo-graphy (US-COMP-CCG).

Now it becomes more and more important to differentiate other types of dystaxias as being listed in table 2.

Abasia	Inability to walk, for instance : Abasia astasia; Abasia atactica, i.e. characterized by uncertainty of movement, due to a defect of coordination; Choreic Abasia, i.e. a form due to chorea of the legs; Paralytic Abasia, i.e. a form due to paralysis of the leg muscles; Paroxysmal tripodant Abasia, i.e. astasia – abasia caused by spastic stiffening of the legs on attempting to stand (also spastic Abasia); Trembling Abasia, i.e. abasia due to trembling of the legs (Abasia trepidans)
Astasia – abasia	Motor incoordination with inability to stand or walk despite normal ability to move the legs when sitting or lying down, a form of hysterical ataxia.
astasia	Motor incoordination with inability to stand
Ataxia	Failure of muscular coordination or irregularity of muscular action.

Table 2.: Various categories of motor regulation failures of the bipedestal human.

In fig. 6 – 27 we have tried to give the different categories of motor regulation failures of the dystaxic type of the bipedestal human a face especially in relation the the ageing process. While fig. 6 – 16 deal with afflictions in the standing reactions , fig. 17 – 27 go into the functional imaging of the stepping procedure, which also includes locomotion.

Clinically many of the pontomedullary syndromes may also be the cause of various dystaxias: Wallenberg syndrome, Cestan-Chenais-syndrome, Babinski-Nageotte-syndrome, Avellis-syndrome, Schmidt-syndrome, Tapia-syndrome, Vernet-syndrome, Jackson-syndrome, cerebellar hereditary ataxia of the type Nonne-Marie, Friedreich's ataxia etc.. Furthermore the cerebello pontine medullary desinhibitions are found together with cases suffering from uraemia, liver cirrhosis, Wilson's disease, myxedema, thyrotoxicosis, Hardnup-syndrome, Wernicke's encephalopathia , symptomatic cerebellar atrophia etc..

It must be noted here that presbyvertigo is not only the result of a mismatch in data input from the age dependant receptors of the orientation mechanisms. It is also due to a degeneration of the neurotransmittive capabilities of the central balance pathways changing the capabilities of biological data processing. This leads to a general reduction in the sensitivity and the efficacy of the integrated vestibular system, leading to a high risk of falling hazards with all its accompanying disorders. The chronic nature of the condition raises a number of socio-economic issues. Major aspects of geriatric care include long term nursing facilities and hospitalisation, and the obligations of society towards this "peer group" in general.

Especially space orientation and motor regulation of the human with his total body as well as with his head and his eye movements is subject to our further clinical neurootological investigations by the help of the newly developed ultrasound computer cranio-corpo-graphy (US-COMP-CCG) , which also can give a face and an image to various types of dystaxias including presbydystaxia.

## 09. Bibliography:

01. Abrahams V. C. (1977)  
The physiology of neck muscles  
Can. J. Physiol. Pharmacol. 55: 332-338.
02. Barany R., Witmaack K.: (1911)  
Funktionelle Prüfung des Vestibularisapparates.  
Fischer-Verlag, Jena,
03. Bartual Pastor, J., N.Perez Fernandez: (1998)  
El sistema vestibular y sus alteraciones. Tomo I : Fundamentos y semiologia.Masson S.A., Barcelona,
04. Bartual Pastor, J., N.Perez Fernandez: (1999)  
El sistema vestibular y sus alteraciones. Tomo II : Patologia.  
Masson S.A., Barcelona,
05. Bartual Pastor, J.: (1978)  
El sistema vestibulo-espinal.  
The vestibulospinal system.  
Proc.NES, (Vol.VI,1)pp. 111-148.
06. Bergmann J., Bertora G. (1981)  
Cranio-Corpo-Graphie-Muster beim Zustand nach Schädeltraumata  
Proc. NES vol. VIII, 161-175,
07. Claussen C-F, Haralanov S, Haralanova E(2002)  
Computerized Ultrasound Cranio-Corpo-Graphy (Comp-USCCG) for Equilibrimetric Measurements in Patients with Movement Disorders  
Published on the Archives for Sensology and Neurootology in Science and Practice – ASN [Internet], Buenos Aires
08. Claussen C.-F. (2004)  
Clinical differential charts of HUSPATRAC® of the stepping test.  
Published on the Archives for Sensology and Neurootology in Science and Practice – ASN [Internet], Buenos Aires
09. Claussen C.F, E. Claussen(1996)  
About the strength of the neck in linking the head to the trunk as measured by the US-CCG  
Proc. NES 23 , Excerpta Medica 1133, 9-20
10. Claussen C.F., (2003)  
“HUSPATRAC - A method of measuring and visualizing human space trails of movements and accelerations of head, neck and body.” .  
Published on the Archives for Sensology and Neurootology in Science and Practice – ASN [Internet], Buenos Aires
11. Claussen E., Volle E., Montazem A., Claussen C.-F. (1998),  
Interdisciplinary clinical vertigo studies in whiplash lesions to the ligamenta alaria by means of dynamic MRI-findings in combination with ultrasound cranio-corpo-graphy (USCCG)  
Proc. Barany Soc. 20 Excerpta Medica 1201,451, 2000
12. Claussen, C.-F., Claussen, E., Heindl, E.: (1995)  
Recent developments in the computer evaluation of cranio-corpo-graphy.  
Excerpta Medica, International Congress Series, 1087, Elsevier Publishers, Amsterdam, Lausanne, New York, Oxford, Shannon, Tokyo, , pg. 287-292.
13. Claussen, C.-F., Claussen, E.: (1996)  
About the strength of the neck in linking the head to the trunk as measured by the US-CCG.

- Excerpta Medica, International Congress Series, 1133, Elsevier Publishers, Amsterdam, Lausanne, New York, Oxford, Shannon, Tokyo, pg.9 – 20
14. Claussen, C.-F., Claussen, E.: (2000)  
Cranio-corpo-graphy (CCG) - 30 years of equilibrium measurements of spatial head, neck and trunk movements.  
Excerpta Medica, International Congress Series, 1201, Elsevier Publishers, Amsterdam, Lausanne, New York, Oxford, Shannon, Tokyo, pg. 245-260
  15. Claussen, C.F. Schneider.D., Marcondes L.G., Patil N: (1990)  
A Computer analysis of typical CCG patterns in 1021 neurootological patients.  
Acta-Otolaryng.(Stockh.)-Supplement 468, 235 – 238
  16. Claussen, C.F., Claussen, E. : (1986)  
Forschungsbericht - Cranio-Corpo-Graphie (CCG). Ein einfacher, objektiver und quantitativer Gleichgewichtstest für die Praxis.  
Schriftenreihe des Hauptverbandes der gewerblichen Berufsgenossenschaften e.V., D-5205 Sankt Augustin
  17. Claussen, C.F., Claussen, E., von Schlachta, I.: (1982)  
Das impulsmarkierte Cranio-Corpo-Gramm (IMCCG).  
Arch.Otorhinolaryngol., 235, 608-612
  18. Claussen, C.F., Claussen, E., von Schlachta, I.: (1984)  
Das impulsmarkierte Cranio-Corpo-Gramm, ein differenzierter vestibulo-spinaler Test mit besonderer Bedeutung für die Arbeitsmedizin.  
Aus: Neurootologie - Forschung und Praxis, Abt. Wissenschafts-publizistik der Wilhelm-Pieck-Universität, Rostock,  
S. 117-123
  19. Claussen, C.F., Estelrrich, P.R.: (1975)  
Desarrollo de la craneo-corpografia a partir de la pruebe de Unterberger.  
Acta Otorrinolaringol.Espan.,26, 139-146
  20. Claussen, C.F., Nagy, E. (2002)  
Head position above the trunk in USCCG  
Published on the Archives for Sensology and Neurootology in Science and Practice  
ASN (Internet), Buenos Aires
  21. Claussen, C.F., Schneider, D., Marcondes, L.G., Patil, N.: (1990)  
A Computer Analysis of Typical CCG Patterns in 1021 Neurootological Patients.  
Acta Otolaryngologica (Stockh.) - Suppl. 468, 235-238
  22. Claussen, C.F.; Claussen E.: (1987)  
Neurootological findings in tinnitus patients.  
Harsch Verlag, Karlsruhe,  
Proceedings III. International Tinnitus Seminar, Münster 1987, 196 – 204
  23. Claussen, C.F.;Schneider D; Helms, J.: (1991)  
Cranio-Corpo-Graphy Patterns in Patients with Acoustic Neurinoma.  
Acta-Otolaryng.(Stockh.)-Supplement 481, 490 – 493
  24. Claussen, C.F.: (1970)  
Die Cranio-Corpo-Graphie (CCG), eine einfache photooptische Registriermethode für vestibulo-spinale Reaktionen.  
Zeitschr. Laryngol.Rhinol., 49, 634-639
  25. Claussen, C.F.: (1970)  
Über eine Gleichgewichtsfunktionsprüfung mit Hilfe der Cranio-Corpo-Graphie (CCG) und Polarkoordinaten im Raume.  
Arch.klin.exp.Ohr.-,Nas.-u.Kehlk.Heilk., 196, 256-261
  26. Claussen, C.F.: (1974)  
Die Cranio-Corpo-Graphie.  
Arch.klin.exp.Ohr.-,Nas.-u.Kehlk.Heilk.,207
  27. Claussen, C.F.: (1979)  
Cranio Corpo Graphy (CCG), a simple and objective equilibrium screening test.  
Prepr.Aerospace med.ann.scient.meet., pp.53-54.
  28. Claussen, C.F.: (1981)  
Die objektive Aufzeichnung und quantitative Auswertung von Raumorientierungsaufgaben mittels eines



- fotooptischen Schnelltests, der Cranio-Corpo-Graphie.  
Verhdlg.d.GNA, Bd. VIII, 107-150
29. Claussen, C.F.: (1981)  
Cranio-Corpo-Graphy (CCG), a simple objective and quantitative whole-body as well as intracorporal posturography.  
Vle Symposium international de posturographie, Kyoto 17-19 Sept., Agressologie , 24, 2:97-98,1983
  30. Claussen, C.F.: (1981)  
Die objektive Darstellung des Torticolliswinkels mittels der Cranio-Corpo-Graphie (CCG).  
Arch.Otorhinolaryngol.,231, 625-628
  31. Claussen, C.F.: (1982)  
Beispiele einfacher und impulsmarkierter Cranio-Corpo-Gramme beim Zustand nach Schädel-Hirn-Trauma durch Arbeitsunfall.  
Verhdlg.d.Deutsch.Ges.f.Arbeitsmed., 22. Jahrestagung, S. 299-305
  32. Claussen, C.F.: (1985)  
Presbyvertigo, Presbyataxie, Presbytinnitus - Gleichgewichts- und Sinnesstörungen im Alter.  
Springer-Verlag, Berlin, Heidelberg, New York, Tokio
  33. Claussen, C.F.: (1987)  
La Cranio-Corpo-Graphie montre une reduction statistiquement signicative de la symptomatologie vertigineuse et ataxique chez des patients traités par l'extrait de Ginkgo biloba comparé a une serie temoin.  
in: M.Toupet, Colloque de la Fondation Ipsen, Interet de la Posturographie dans le diagnostic oto-neurologique et la therapeutique, Paris,pg. 39 – 40
  34. Claussen, C.F.: (1990)  
Cranio-corpo-Graphy, an objective and quantative representation of movement patterns during the stepping and standing test.  
Aus:A.Cesarani u. D.Alpini : Diagnosi e Trattamento dei Disturbi dell'Equilibrio. Mediamix Edizioni Scientifiche, Milano, pg. 79 – 84
  35. Claussen, C.F.(1975)  
Über die Objektivierung von normalem, simuliertem und gestörtem Gleichgewichtsverhalten mittels der Cranio-Corpo-Graphie (CCG).  
Verhdlg.Deut.Ges.Arbeitsmed. ,15, 155-164,
  36. Claussen, C.F.(1983)  
Cranio-Corpo-Graphy (CCG), a simple objective and quantitative whole-body as well as intracorporal posturography.  
Vle Symposium international de posturographie, Kyoto 17-19 Sept.1981, Agressologie , 24, 2:97-98
  37. Claussen,C.F., Claussen ,E.: (1986)  
CCG, eine einfache, vestibulo-spinale Taumeligkeitsmessung für Verlaufsbeobachtungen in der Praxis.  
Arch. Ohr.-, Nas.-,Kehlk.Heilk., Suppl., II, S.61 – 64
  38. Claussen,C.F./Bad Kissingen2002  
Human Space Trail (HUSPATRAC).  
Published on the Archives for Sensology and Neurootology in Science and Practice  
ASN (Internet), Buenos Aires
  39. Claussen,C.F.  
Human Space Trail (HUSPATRAC).  
Published on the Archives for Sensology and Neurootology in Science and Practice ASN (Internet),
  40. Claussen., C.-F., Helms, J., Patil, N., Schneider, D.: (1990)  
Vestibular Spinal Testing Using Cranio-Corpo-Graphy in Patients Suffering from Acoustic Neuroma.  
Acta Otolaryngologica (Stockh.) - Suppl. 468, 239-242
  41. Claussen C.-F: (1978)  
Cranio-Corpo-Graphie.  
Verhdlg. der GNA, Bd. 6, 151-189
  42. Claussen, C.-F.; Franz B. (2006):  
Contemporary & Practical Neurootology
  43. Claussen, C.-F.; Bergmann, J. M.; Bertora G. O. (2009):  
Equilibrimetría y Tinnitología práctica

44. Fukuda, T.: (1959).  
"The stepping test: two phases of the labyrinthine reflex".  
Acta Otolaryngol. (Stockh.), 50: 95-108
45. Gagey, P. M.; Bizzo, C.; Debruille, O. (1988)  
Are Fukuda's test parameters valid ?  
Proc.NES, (Vol.XI)pp. 99-110
46. Glück, W., Claussen, C.F., Kempf, H., Breyer, A.: (1981)  
Cranio-Corpo-Graphische Untersuchungen des Kopf-Körper-Gleichgewichts bei Hochleistungsmonteuren.  
Verhdg.GNA, Bd. VIII, 265-284
47. Haralanov S, Claussen C-F, Haralanova E( 2002)  
Computerized Ultrasound Cranio-Corpo-Graphy (Comp-USCCG) for Equilibrimetric Measurements in  
Psychiatric Patients  
Published on the Archives for Sensology and Neurootology in Science and Practice – ASN [Internet], Buenos  
Aires
48. Haralanov S, Claussen C-F, Milushev E, Haralanova E, Kmetska K (2002)  
Computerized Ultrasound Cranio-Corpo-Graphy (Comp-USCCG) for Objective and Quantitative Treatment  
Monitoring in Multiple Sclerosis Patients  
Published on the Archives for Sensology and Neurootology in Science and Practice – ASN [Internet], Buenos  
Aires
49. Haralanov S., Claussen C.-F., Svinarov D., Haralanova E., Shkodrova D. (2004)  
4D-CCG and antipsychotic drug management: pharmacokinetic/pharmacodynamic monitoring in  
schizophrenic patients.  
Published on the Archives for Sensology and Neurootology in Science and Practice – ASN [Internet], Buenos  
Aires
50. Haralanova E, Haralanov S, Claussen C-F (2002)  
Computerized Ultrasound Cranio-Corpo-Graphy (Comp.-USCCG) in Differential Psychophysiology.  
ASN (Internet), Buenos Aires
51. Haralanov, S., Claussen, C.-F., Shkodrova, D., Haralanov, L., Schneider, D., Carvalho, C.: (1995)  
Cranio-corpo-graphy in schizophrenic patients.  
Excerpta Medica, International Congress Series, 1087, Elsevier Publishers, Amsterdam, Lausanne, New  
York, Oxford, Shannon, Tokyo, , pg. 325-328.
52. Kirtane, M. V., Medikeri, S. B., Merchant, S. N., Kelkar, D.: (1988)  
Cranio-corpo-graphy - a modified technique.  
Proc. NES, (Vol. XII/XIII)pp. 149-158.
53. Lischke, H., Claussen, C.F.: (1978)  
Durchführung der Cranio-Corpo-Graphie unter arbeitsmedizinischen Bedingungen.  
Verhdg.d.GNA, Bd. VI, 263-278
54. Marcondes, L.G., Claussen, C.F., Schneider, D., Marcondes, V.: (1987)  
Computer cataloguing cranio-corpo-graphy pictures for a detailed data bank analysis of gait and standing  
patterns.  
Acta AWHO -Otologia-Otoneurologia-Fonaudiologia-ORL, 6, 182 – 185
55. Marcondes, L.G.: (1987).  
"Über eine Systematik der mittels der Cranio-Corpo-Graphie aufgezeichneten Kopf-Körper-  
Bewegungsmuster".  
Inaugural-Dissertation Würzburg
56. Nagy, E., Claussen, C.F. Heid, L., Bencze, G. (2002)  
About typical USCCG-patterns of peripheral vestibular disturbances  
ASN (Internet), Buenos Aires
57. Nagy, E., Claussen, C.F., Kersebaum, M., Heid, L., Bencze, G(2002)  
USCCG a quick, objective and quantitative tool for vestibular spinal equilibrium testing.  
Published on the Archives for Sensology and Neurootology in Science and Practice ASN (Internet), Buenos  
Aires
58. Patil N; Claussen, C.F.Schneider.D: (1991)  
Cranio-Corpo-Graphy: An Analysis of angular Deviation as a criterion for peripheral Vestibulopathies.  
Proc.14. World Congr. of ORL, Kugler & Ghedini Publ., Amsterdam, Milano, New York, pg. 855 – 857
59. Patil, N., Schneider, D., Claussen, C.-F.: (1988)

- Ginkgo Biloba Extract and the Vestibular System - A Cranio-Corpo-Graphic and Electronystagmographic Assessment.  
Verhdlg.d.GNA, Elsevier, Amsterdam
60. Rakel, Robert E., Bope Edward T. (2009):  
Conn's Current Therapy 2009
61. Romberg M.: (1848)  
Lehrbuch der Nervenkrankheiten.  
Springer-Verlag, Berlin
62. Schimrigk, K.: (1978)  
Die Ataxie aus klinischer Sicht.  
On clinical aspects of ataxia.  
Proc.NES, (Vol.VI,2)pp.709 – 722
60. Schneider, D., Claussen, C.F., Marcondes, L. G., Patil, N. P.: (1988)  
Typical CCG patterns in different dysequilibrium states.  
Proc.NES, (Vol. XVI)pp. 91-94
61. Schneider, D.; L.G. Marcondes; C.F. Claussen: (1988)  
Die Computeranalyse typischer Grafoelemente der Cranio-Corpo-Graphie bei 1021 Vertigo-Patienten.  
Verhdlg.d.Deutsch.Ges.f.Arbeitsmed., 28. Jahrestagung, Gentner Verlag, Stuttgart, 683 – 685
62. Schubert, J., Claussen, C.F., Prott, W.: (1978)  
CCG bei Zustand nach Neck dissection.  
CCG in neck dissected persons.  
Proc.NES, (Vol.VI,1)pp. 393-418.
63. Sekezdi, T., Claussen, C.F.: (1987)  
Graphoelements of the undulating head - body sway in cranio-corpo-graphy.  
Acta AWHO -Otologia-Otoneurologia-Fonaudiologia-ORL, 6, 178-185
64. Shkodrova D, Haralanov S, Claussen C-F, Haralanova E (2002)  
Objective and Quantitative Monitoring of Antipsychotic Treatment by Computerized Ultrasound Cranio-Corpo-Graphy (Comp-USCCG).  
Published on the Archives for Sensology and Neurotology in Science and Practice ASN (Internet), Buenos Aires
65. Unterberger S.: (1938)  
Neue registrierbare Vestibularis-Körperdreh-Reaktionen, erhalten durch Treten auf der Stelle. Der Tretversuch.  
Arch.Ohr.-,Nas.-u.Kehlk.Heilk., 140, 273-282

## **10. Authors address:**

**Prof. Dr. C.-F. Claussen**

**Kurhausstraße 12**

**97688 Bad Kissingen**

**Germany**

**E-Mail: [claussensolog@t-online.de](mailto:claussensolog@t-online.de)**