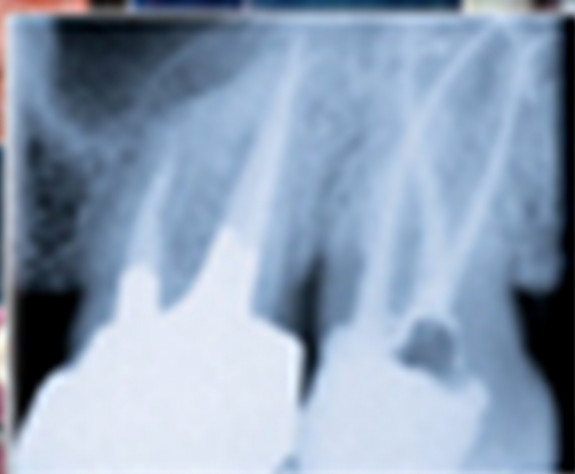
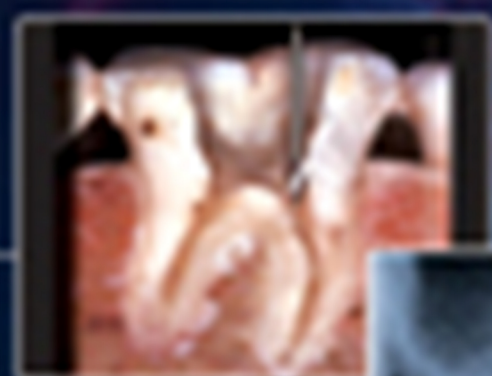

Nisha Garg  
Amit Garg



Textbook of  
**Preclinical  
Conservative Dentistry**

JAYPEE

# **Textbook of Preclinical Conservative Dentistry**



# Textbook of Preclinical Conservative Dentistry

## **Nisha Garg**

MDS (Conservative Dentistry and Endodontics)  
Ex-Resident, PGIMER, Chandigarh  
Ex-Resident, Government Dental College, Patiala  
Presently at, Manav Rachna Dental College  
Faridabad, Haryana, India

## **Amit Garg**

MDS (Oral and Maxillofacial Surgery)  
Ex-Resident, Government Dental College  
PGIMS, Rohtak  
Presently at, Manav Rachna Dental College  
Faridabad, Haryana, India

*Foreword*

**S Ramachandran**



**JAYPEE BROTHERS MEDICAL PUBLISHERS (P) LTD**

New Delhi • St Louis (USA) • Panama City (Panama) • London (UK) • Ahmedabad  
Bengaluru • Chennai • Hyderabad • Kochi • Kolkata • Lucknow • Mumbai • Nagpur

*Published by*

Jitendar P Vij

**Jaypee Brothers Medical Publishers (P) Ltd**

***Corporate Office***

4838/24, Ansari Road, Daryaganj, **New Delhi** 110 002, India

Phone: +91-11-43574357, Fax: +91-11-43574314

***Registered Office***

B-3, EMCA House, 23/23B Ansari Road, Daryaganj, **New Delhi** 110 002, India

Phones: +91-11-23272143, +91-11-23272703, +91-11-23282021, +91-11-23245672

Rel: +91-11-32558559, Fax: +91-11-23276490, +91-11-23245683

e-mail: jaypee@jaypeebrothers.com, Website: www.jaypeebrothers.com

***Offices in India***

- **Ahmedabad**, Phone: Rel: +91-79-32988717, e-mail: ahmedabad@jaypeebrothers.com
- **Bengaluru**, Phone: Rel: +91-80-32714073, e-mail: bangalore@jaypeebrothers.com
- **Chennai**, Phone: Rel: +91-44-32972089, e-mail: chennai@jaypeebrothers.com
- **Hyderabad**, Phone: Rel: +91-40-32940929, e-mail: hyderabad@jaypeebrothers.com
- **Kochi**, Phone: +91-484-2395740, e-mail: kochi@jaypeebrothers.com
- **Kolkata**, Phone: +91-33-22276415, e-mail: kolkata@jaypeebrothers.com
- **Lucknow**, Phone: +91-522-3040554, e-mail: lucknow@jaypeebrothers.com
- **Mumbai**, Phone: Rel: +91-22-32926896, e-mail: mumbai@jaypeebrothers.com
- **Nagpur**, Phone: Rel: +91-712-3245220, e-mail: nagpur@jaypeebrothers.com

***Overseas Offices***

- **North America Office, USA**, Ph: 001-636-6279734  
e-mail: jaypee@jaypeebrothers.com, anjulav@jaypeebrothers.com
- **Central America Office, Panama City, Panama**, Ph: 001-507-317-0160  
e-mail: cservice@jphmedical.com, Website: www.jphmedical.com
- **Europe Office, UK**, Ph: +44 (0) 2031708910  
e-mail: info@jpmedpub.com

***Textbook of Preclinical Conservative Dentistry***

© 2011, Jaypee Brothers Medical Publishers

All rights reserved. No part of this publication should be reproduced, stored in a retrieval system, or transmitted in any form or by any means: electronic, mechanical, photocopying, recording, or otherwise, without the prior written permission of the authors and the publisher.

This book has been published in good faith that the material provided by authors is original. Every effort is made to ensure accuracy of material, but the publisher, printer and authors will not be held responsible for any inadvertent error(s). In case of any dispute, all legal matters are to be settled under Delhi jurisdiction only.

*First Edition:* **2011**

ISBN 978-93-5025-077-8

*Typeset at* JPBMP typesetting unit

*Printed at*

*Dedicated to  
Our Parents  
and  
Beloved Daughter  
“Prisha”*



## FOREWORD

It gives me great pleasure to write a foreword to the *Textbook of Preclinical Conservative Dentistry*. Preclinical Conservative Dentistry has assumed a lot of significance with relevance to the rapid progress made in dental materials and instruments. Preclinical Conservative Dentistry has been introduced as a separate examination subject bearing in mind the importance it demands. This textbook forms the basis and backbone for a dental student for his future clinical training. It assumes greater importance in view of the fact that these fundamentals are to be properly imparted to the dental student.

This book on Preclinical Conservative Dentistry explicitly deals with these fundamentals in different Chapters dealing widely in introduction, description of teeth, instruments, nomenclature, tooth preparation, filling materials including endodontics. The significance of this book is that these fundamentals are explained in a simple understandable manner which will make the student grasp the same without any strain or confusion. I am sure, this will also be useful as a handbook or reference book to all the dentists as well.

I have no hesitation in recommending this book to all dental students as well as dental surgeons and I heartily congratulate Dr Nisha Garg on her excellent effort in bringing out this book in a presentable way.



A handwritten signature in black ink, appearing to read 'S Ramachandran'.

**S Ramachandran** MDS

Principal, Ragas Dental College & Hospital, Chennai  
Professor, Conservative Dentistry & Endodontics  
Member, Dental Council of India





## PREFACE

Operative dentistry is one of the oldest branches of dental sciences forming the central part of dentistry as practiced in primary care. It occupies the use of majority of dentist's working life and is a key component of restorative dentistry. The subject and clinical practice of conservative dentistry continues to evolve rapidly as a result of improved understanding of etiology, prevention and management of common dental diseases. The advances and developments within the last two decades have drastically changed the scope of this subject. But before taking professional training, gathering basic knowledge along with operating skill is mandatory.

The main objective of this book is to provide students with the knowledge required while they are developing necessary clinical skills and attitude in their undergraduate training in conservative dentistry and endodontics. We have tried to cover wide topics like morphology of teeth, cariology, different techniques, instruments and materials available for restorations of teeth along with the basics of endodontics.

So we can say that after going through this book, the student should be able to:

- Sit properly while operating and be able to organize their operating environment efficiently.
- Understand the morphology of teeth and differentiate one tooth from another.
- Chart teeth.
- Understand basics of cariology, its prevention and conservative management.
- Tell indications and contraindications of different dental materials.
- Apply modern pulp protective regimens.
- Select suitable restorative materials for restoration of teeth.
- Understand the basics of endodontic treatment like what are the indications of endodontic treatment, basic instruments, access preparation, biomechanical preparation and obturation of root canal system.

**Nisha Garg**  
**Amit Garg**



## ACKNOWLEDGMENTS

First and foremost, we bow in gratitude to Almighty God for endowing us strength, courage and confidence in accomplishing this venture to best of our abilities. Without his blessings, we could not have completed this project.

Since a textbook is product of never-ending efforts and contributions, words fall short to express our feelings for persons who helped us.

We offer our humble gratitude and sincere thanks to Dr OP Bhalla (Chairman), Dr Amit Bhalla and Mr Prashant Bhalla (Vice-Chairman) MRDC, Faridabad for providing healthy and encouraging environment for our work.

We shall express our sincere thanks to Dr AK Kapoor, Principal, MRDC, Faridabad who always appreciated our over-occupation and inspired us to learn more and more.

We would like to express our thanks to staff of Department of Operative Dentistry, MRDC, Faridabad, Dr Arundeeep Singh, Dr Manish Gupta and Dr Sarika for their “ready to help” attitude, constant guidance and positive criticism which helped in improvement of this book.

We are grateful to Dr Pankaj Dhawan (Dean Academics) and Dr SK Mangal (Medical Superintendent) for their support and constant encouragement.

We are thankful to Shri Jitendar P Vij (Chairman and Managing Director), Mr Tarun Duneja (Director-Publishing) and staff of Jaypee Brothers Medical Publishers, New Delhi, for all encouragement as well as for bringing out this book in an excellent form.

Last but not least, we are thankful to students of this country, who appreciated our previous books “Textbook of Endodontics”, “Review of Endodontics and Operative Dentistry” and “Textbook of Operative Dentistry” and encouraged us to venture out this project.

Please send us reviews and suggestions to incorporate in further edition of this book to make it more student friendly.

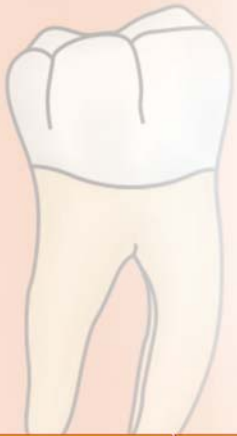e-mail: drnishagarg1@gmail.com

e-mail: dramitgarg1@gmail.com



# CONTENTS

<b>1. Morphology of Teeth .....</b>	<b>1</b>
<b>2. Tooth Nomenclature .....</b>	<b>25</b>
<b>3. Structure of Teeth .....</b>	<b>36</b>
<b>4. Dental Caries .....</b>	<b>51</b>
<b>5. Cutting Instruments .....</b>	<b>72</b>
<b>6. Matricing and Tooth Separation .....</b>	<b>103</b>
<b>7. Principles of Tooth Preparation .....</b>	<b>119</b>
<b>8. Dental Cements .....</b>	<b>144</b>
<b>9. Dental Amalgam .....</b>	<b>163</b>
<b>10. Tooth Preparation for Amalgam Restoration .....</b>	<b>185</b>
<b>11. Composite Restorations .....</b>	<b>201</b>
<b>12. Cast Metal Restorations .....</b>	<b>226</b>
<b>13. Pulp Protection .....</b>	<b>249</b>
<b>14. Basics of Endodontics .....</b>	<b>260</b>
<b>Glossary .....</b>	<b>301</b>
<i>Index</i> .....	<b>309</b>



# Morphology of Teeth

## Chapter 1

### INTRODUCTION

#### MAXILLARY CENTRAL INCISOR

- Labial Aspect
- Lingual Aspect
- Mesial Aspect
- Distal Aspect
- Incisal Aspect

#### MAXILLARY LATERAL INCISOR

- Labial Aspect
- Lingual/Palatal Aspect
- Mesial Aspect
- Distal Aspect
- Incisal Aspect

#### CANINE

- Labial Aspect
- Lingual/Palatal Aspect
- Mesial Aspect
- Distal Aspect
- Incisal Aspect

#### FIRST PREMOLAR

- Buccal Aspect
- Palatal Aspect
- Mesial Aspect
- Distal Aspect
- Occlusal Aspect

#### SECOND PREMOLAR

- Buccal Aspect
- Palatal Aspect
- Mesial Aspect
- Distal Aspect
- Occlusal Aspect

#### FIRST MOLAR

- Buccal Aspect
- Palatal Aspect
- Mesial Aspect
- Distal Aspect
- Occlusal Aspect

#### SECOND MOLAR

- Buccal Aspect
- Palatal Aspect
- Mesial Aspect
- Distal Aspect
- Occlusal Aspect

#### CENTRAL INCISOR

- Labial Aspect
- Lingual Aspect
- Mesial Aspect
- Distal Aspect
- Incisal Aspect

#### MANDIBULAR LATERAL INCISOR

- Labial Aspect
- Lingual Aspect
- Mesial Aspect
- Distal Aspect
- Incisal Aspect

#### CANINE

- Labial Aspect
- Lingual Aspect
- Mesial Aspect
- Distal Aspect
- Incisal Aspect

#### FIRST PREMOLAR

- Buccal Aspect
- Lingual Aspect
- Mesial Aspect
- Distal Aspect
- Occlusal Aspect

#### SECOND PREMOLAR

- Buccal Aspect
- Lingual Aspect
- Mesial Aspect
- Distal Aspect
- Occlusal Aspect

**MANIBULAR FIRST MOLAR**

- Buccal Aspect
- Lingual Aspect
- Mesial Aspect
- Distal Aspect
- Occlusal Aspect

**SECOND MOLAR**

- Buccal Aspect
- Lingual Aspect
- Mesial Aspect
- Distal Aspect
- Occlusal Aspect

**DIFFERENTIATION BETWEEN RIGHT AND LEFT MAXILLARY CENTRAL INCISOR**

**DIFFERENTIATION BETWEEN RIGHT AND LEFT MAXILLARY LATERAL INCISOR**

**DIFFERENTIATION BETWEEN RIGHT AND LEFT MAXILLARY CANINE**

**DIFFERENTIATION BETWEEN RIGHT AND LEFT FIRST MAXILLARY PREMOLAR**

**DIFFERENTIATION BETWEEN RIGHT AND LEFT SECOND PREMOLAR**

**DIFFERENTIATION BETWEEN RIGHT AND LEFT MAXILLARY FIRST MOLAR**

**DIFFERENTIATION BETWEEN RIGHT AND LEFT MAXILLARY SECOND MOLAR**

**DIFFERENTIATION BETWEEN RIGHT AND LEFT MANDIBULAR LATERAL INCISOR**

**DIFFERENTIATION BETWEEN RIGHT AND LEFT MANDIBULAR CANINE**

**DIFFERENTIATION BETWEEN RIGHT AND LEFT MANDIBULAR FIRST PREMOLAR**

**DIFFERENTIATION BETWEEN RIGHT AND LEFT SECOND PREMOLAR**

**DIFFERENTIATION BETWEEN RIGHT AND LEFT MANDIBULAR FIRST MOLAR**

**DIFFERENTIATION BETWEEN RIGHT AND LEFT MANDIBULAR SECOND MOLAR**

**INTRODUCTION**

As we know there are 32 teeth in permanent dentition and 20 teeth in deciduous dentition. A tooth has crown and a root portion. Crown part of the tooth is covered with enamel and root portion of tooth is covered by cementum. The crown and root join at cemento-enamel junction (CEJ).

Before discussing the individual tooth, one should be familiar with few terms. These are:

**Cervical line:** Each tooth has a crown and root portion. The crown is covered with enamel and the root portion is covered with cementum. The crown and root join at the cemento-enamel junction (CEJ). This junction is also called the cervical line.

**Cingulum:** It is lingual lobe of an anterior tooth and makes up the bulk of the cervical third of the lingual surface.

**Ridge:** It is linear elevation on the surface of a tooth.

**Marginal ridges:** These are rounded borders of enamel that form the mesial and distal margins of occlusal surfaces of posterior teeth (premolars and molars) and mesial and distal margins of the lingual surfaces of anterior teeth (incisors and canines).

**Triangular ridges:** These descend from the tips of the cusps of molars and premolars toward the central part of occlusal surfaces.

**Transverse ridge:** When both buccal and lingual triangular ridges join, they combine to form a transverse ridge.

**Oblique ridge:** It is a ridge obliquely crossing the occlusal surfaces of maxillary molars. It is usually formed by the union of triangular ridge of distobuccal cusp and distal cusp ridge of the mesiolingual cusp.

**Fossa:** It is an irregular depression or concavity.

**Lingual fossae:** Occur on lingual surface of incisors.

**Central fossae:** Occur on occlusal surface of molars.

**Sulcus:** It is a long depression on the surface of tooth ridges and cusps.

**Developmental groove:** It is shallow groove between the primary parts of the crown or root.

**Pits:** These are small pinpoint depressions located at the junction of developmental grooves or at ending of those grooves.

**Lobe:** It is one of the primary sections of formation in the development of the crown.

**Mamelons:** These are three rounded protuberances found on the incisal edges of newly erupted incisor teeth.

**Cusp:** It is elevation on the crown portion of a tooth making up a divisional part of the occlusal surface.

**Tubercle:** Smaller elevation on some portion of crown produced by an extra formation of enamel.



## DESCRIPTION OF PERMANENT TOOTH

### MAXILLARY CENTRAL INCISOR

#### Labial Aspect (Fig. 1.1)

1. Widest mesiodistally (10-11 mm) of any anterior teeth, with almost square or rectangle shape.
2. Medial outline is straight or slightly convex; whereas the distal outline is more convex.
3. Distoincisor angle is not as sharp as mesioincisor angle.
4. Incisal outline is almost straight, but newly erupted teeth may show mamelons.
5. Cervical outline follows a semicircular shape with convexity towards root surface.

#### Lingual Aspect (Fig. 1.2)

1. Mesial and distal outlines converge palatally.
2. Below cervical line, a smooth convexity is present called cingulum.
3. Below cingulum there is a shallow concavity which is bordered by mesial and distal marginal ridge, incisal ridge and cingulum.

#### Mesial Aspect (Fig. 1.3)

1. Wedge triangular shaped crown with base towards cervix and apex towards incisal ridge.
2. Incisal edge of crown is in line with center of the root.
3. Labial outline is convex from cervix till incisal edge.

4. Lingual outline is convex at the point where it joins crest of curvature at cingulum. After this, it becomes concave and then slightly convex again when it approaches linguoincisor ridge.
5. Cervical line curves incisally. This curve is more on the mesial surface than on distal surface.

#### Distal Aspect (Fig. 1.4)

Distal aspect is almost similar to that of mesial aspect except in following:

1. Crown appears thicker at mesial.
2. Curvature of cervical line is less than on the mesial surface.

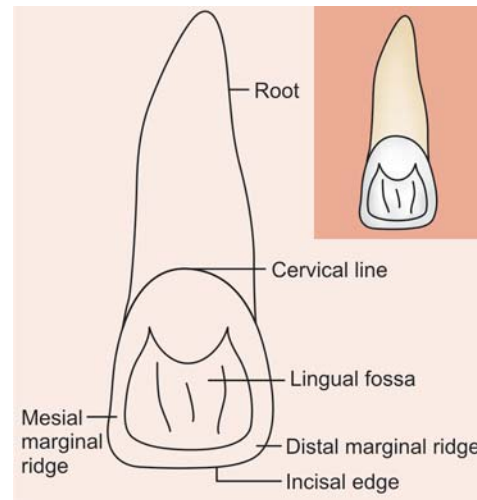


Fig. 1.2: Lingual aspect

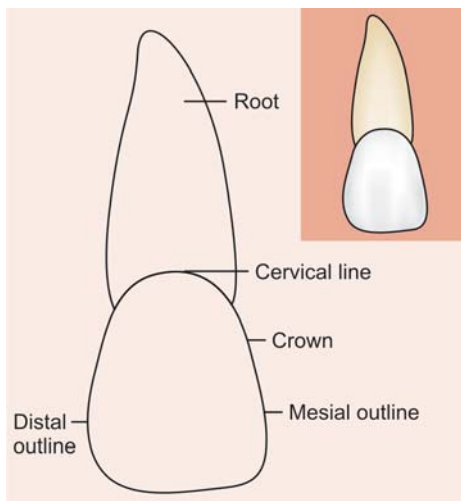


Fig. 1.1: Labial aspect

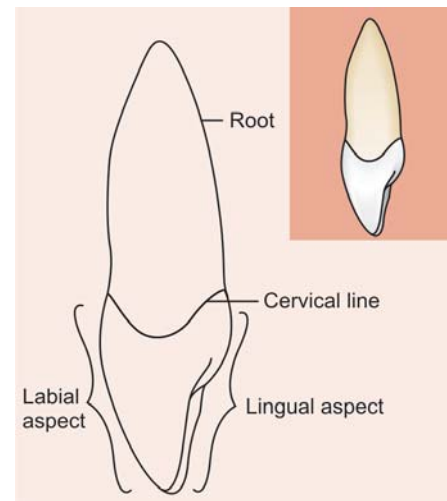
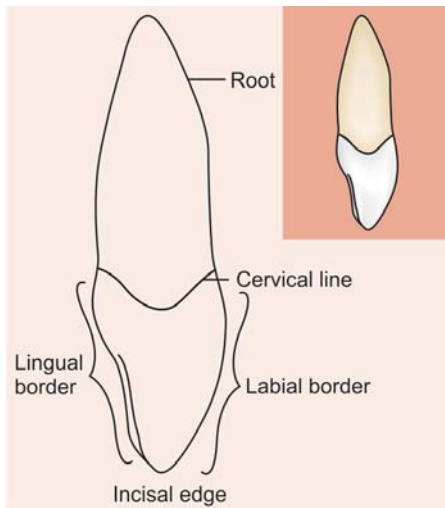
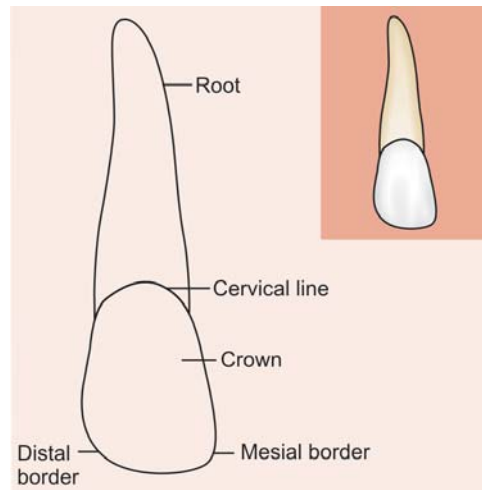


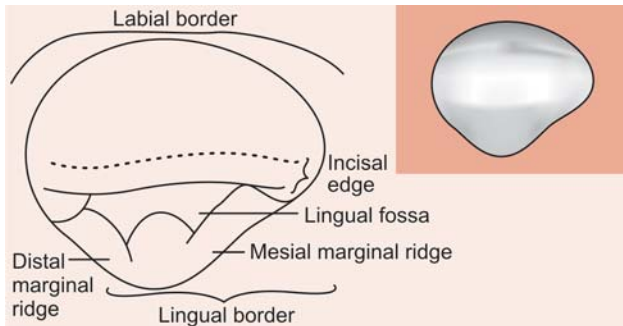
Fig. 1.3: Mesial aspect



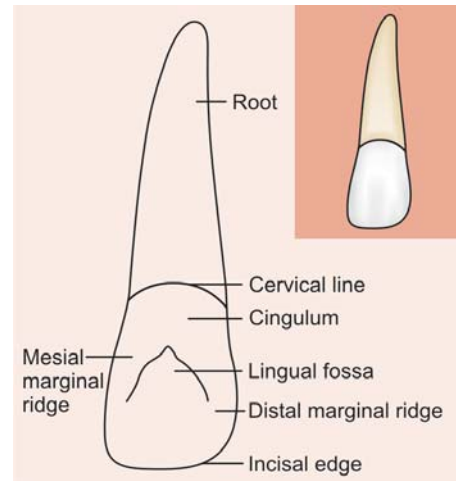
**Fig. 1.4:** Distal aspect



**Fig. 1.6:** Labial aspect



**Fig. 1.5:** Incisal aspect



**Fig. 1.7:** Lingual aspect

### Incisal Aspect (Fig. 1.5)

1. Incisal edge is centered over the root.
2. Labial surface appears broad and flat, whereas the lingual portion tapers lingually towards the cingulum.

### MAXILLARY LATERAL INCISOR

#### Special features

- Most commonly found missing tooth.
- Peg shaped lateral-common finding.
- Palatogingival groove.

### Labial Aspect (Fig. 1.6)

1. When compared to central incisor, it has more curvature, rounded incisal edge and rounded incisal angles mesially and distally.

2. Mesioincisal angle can be as sharp as that of central incisor.
3. Distal outline is more rounded than central incisor.
4. Crest of contour mesially is at point of junction of middle and incisal third and on distal side, it lies more towards cervical aspect.
5. Lateral incisor is narrower mesiodistally and shorter cervicoincisally than central incisor.

### Lingual/Palatal Aspect (Fig. 1.7)

1. Palatal aspect is narrower than labial.
2. Cingulum is prominent with affinity towards deep developmental grooves within lingual fossa.
3. Marginal ridges are more prominent than that of central incisor.

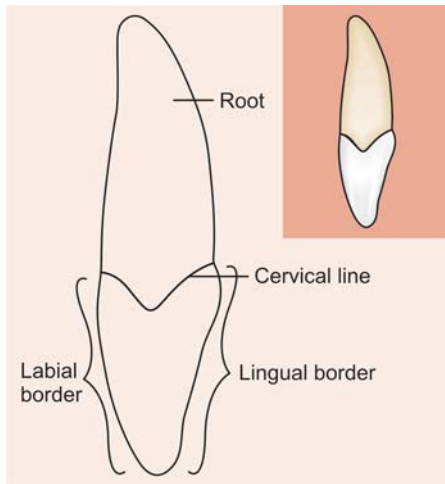
- When compared to central incisor, lingual fossa is more concave and circumscribed.

**Mesial Aspect (Fig. 1.8)**

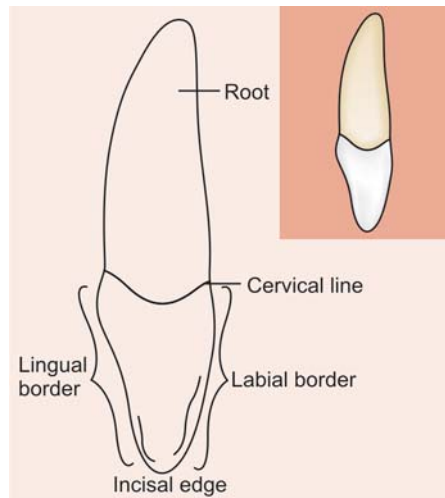
- Almost similar to that of central incisor.
- Curvature of cervical line more on mesial surface than on distal surface.

**Distal Aspect (Fig. 1.9)**

- Width of crown appears more than on mesial surface because of placement of crown on the root.
- Curvature of cervical line is usually less than that of mesial surface.



**Fig. 1.8:** Mesial aspect



**Fig. 1.9:** Distal aspect

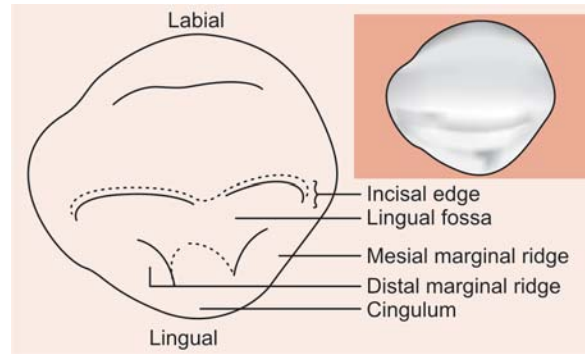
**Incisal Aspect (Fig. 1.10)**

- May resemble central incisor or canine.
- Labial surface is more convex with prominent cingulum.
- Labiolingual dimensions may be greater than mesiodistal dimensions.

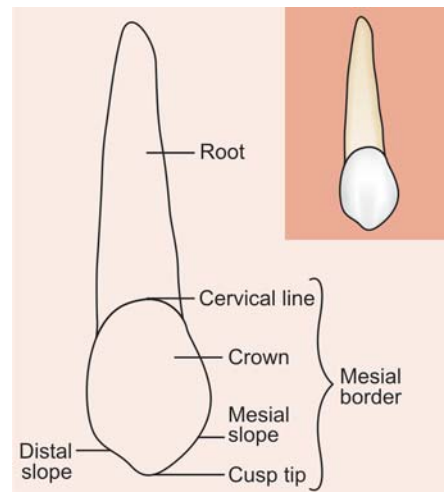
**CANINE**

**Labial Aspect (Fig. 1.11)**

- Mesiodistal dimensions are shorter than central incisor.
- Labial surface is smooth with slight shallow depressions.
- Due to more development of middle lobe, labial ridge is seen.
- Mesial outline is convex from cervix to mesial contact area.
- Distal outline is usually concave from cervical line to distal contact area.
- Incisal edge comes to a distinct point in form of cusp. It has mesial and distal slopes. The mesial slope is shorter than distal slope.



**Fig. 1.10:** Incisal aspect



**Fig. 1.11:** Labial aspect

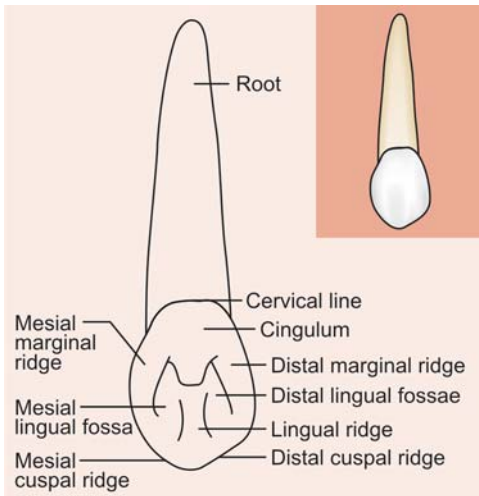
7. Root appears slender from the labial aspect. Canine has the longest root.

**Lingual/Palatal Aspect (Fig. 1.12)**

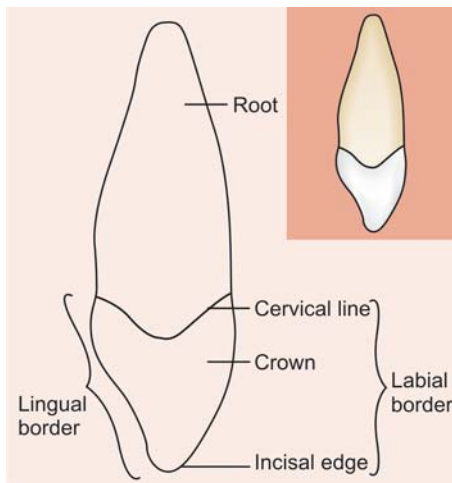
1. Crown is narrower on lingual side.
2. Cingulum is prominent sometimes pointed and may appear as a small cusp.
3. Marginal ridges are prominent. Lingual ridge is found below cingulum and between marginal ridges. It divides lingual fossa in mesial and distal lingual fossa.

**Mesial Aspect (Fig. 1.13)**

1. Outline is wedge shaped with greatest measurements towards cervical third.



**Fig. 1.12:** Lingual aspect



**Fig. 1.13:** Mesial aspect

2. Labial surface appears convex from cervical line towards cusp tip.
3. Lingual outline shows convexity at cervical area, straight at middle third and again convex at incisal third.
4. A line bisecting the cusp is labial to the line bisecting root.

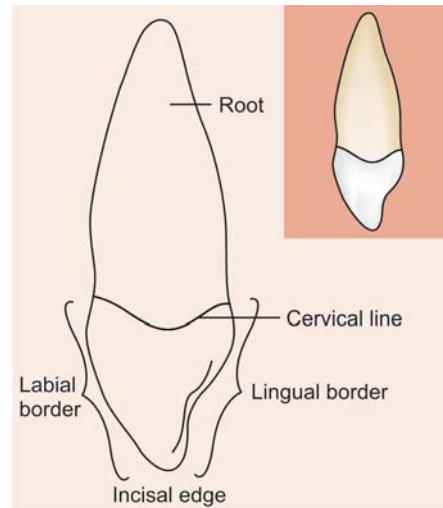
**Distal Aspect (Fig. 1.14)**

It is almost similar to that of mesial aspect except that:

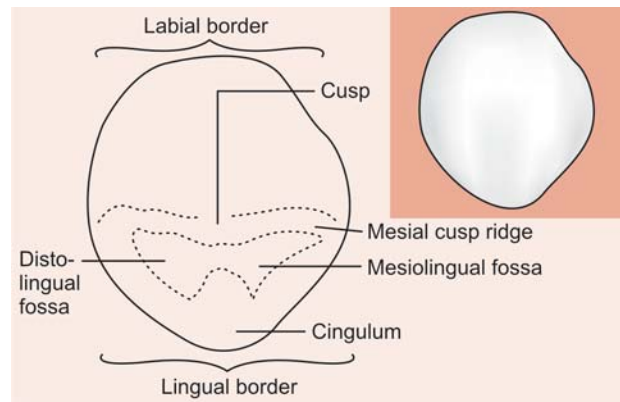
1. Cervical line shows less curvature.
2. Distal marginal ridge is heavier and more irregular in outline.

**Incisal Aspect (Fig. 1.15)**

1. Labiolingual dimensions are more than mesiodistal.
2. Labial ridge appears on labial surface.
3. On lingual surface, cingulum makes up the cervical third of the crown.



**Fig. 1.14:** Distal aspect



**Fig. 1.15:** Incisal aspect

- Cusp tip and cusp slopes lie labial to long axis of the root.
- Distal cusp ridge is longer than the mesial cusp ridge.

## FIRST PREMOLAR

### Buccal Aspect (Fig. 1.16)

- Crown is roughly trapezoidal with convex buccal surface and buccal ridge.
- Mesial outline is slightly concave from cervical line to the mesial contact area.
- Distal outline is straighter than mesial outline.
- Buccal cusp is long and sharp, and thus resembles canine.
- Mesial cusp slope is longer than distal cusp slope. This difference places buccal cusp tip distal to long axis of the tooth.

### Palatal Aspect (Fig. 1.17)

- Due to palatal convergence, crown is narrower on palatal side than on buccal side.
- Palatal cusp is smooth, short and blunt as compared to buccal cusp.
- Mesial and distal slopes of palatal cusp make rounded angle at cusp tip.
- Since palatal cusp is shorter than buccal cusp, the tips of both cusps with their mesial and distal slopes can be seen from palatal aspect.

### Mesial Aspect (Fig. 1.18)

- Roughly trapezoidal in shape with longest side towards cervical portion, and shortest towards occlusal portion.

- Buccal and palatal outlines are smoothly curved from the cervical line till the tips of buccal and palatal cusps.
- Mesial developmental depression is found cervical to mesial contact area bordered by mesiobuccal and mesiolingual line angles. This depression continues apically beyond cervical line and joins the deep developmental depressions of roots.
- Developmental groove is found in enamel of mesial marginal ridge. This groove is usually continuous with central groove of occlusal surface of crown.
- Two roots; one buccal and one palatal are clearly visible from mesial aspect.

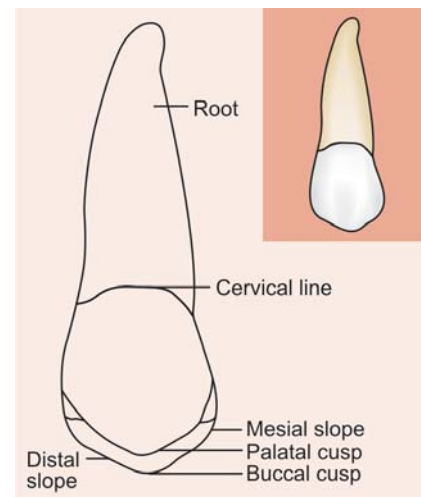


Fig. 1.17: Palatal aspect

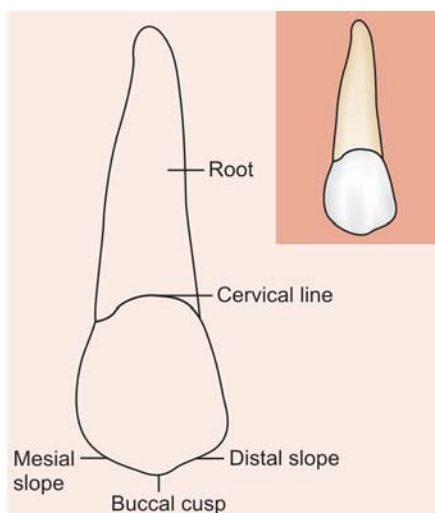


Fig. 1.16: Buccal aspect

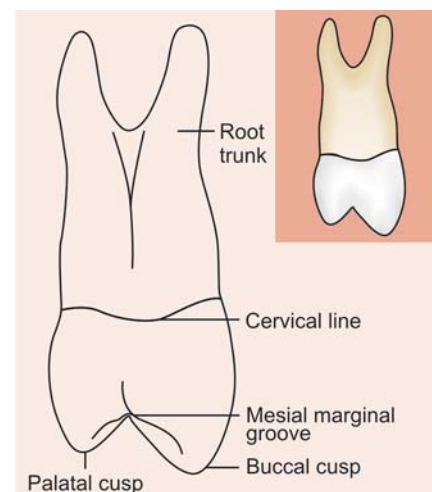


Fig. 1.18: Mesial aspect

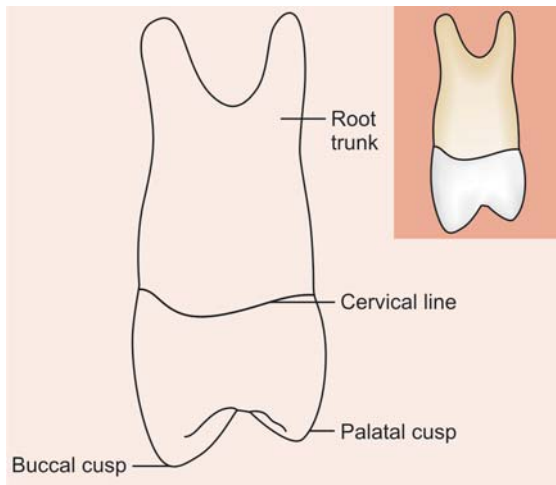
### Distal Aspect (Fig. 1.19)

It is almost similar to mesial aspect except that:

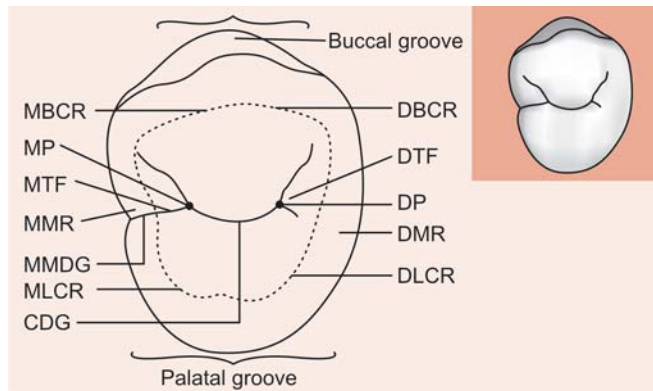
- Convex distal surface with no depression at cervical third.
- Absence of deep developmental groove.
- Curvature of cervical line is less than on mesial aspect.

### Occlusal Aspect (Fig. 1.20)

1. Resembles a six sided hexagon, and circumscribed by cusp ridges and marginal ridges.
2. Crown is wider on buccal aspect than on palatal aspect.
3. Angle formed by junction of mesiobuccal ridge is almost right angle. Whereas angle formed by junction of distobuccal cusp ridge and distal marginal is acute.
4. Central developmental groove divides the occlusal surface buccolingually. This groove extends from distal



**Fig. 1.19:** Distal aspect



**Fig. 1.20:** Occlusal aspect: MBCR: Mesiobuccal cusp ridge; MP: Mesial pit; MTF: Mesial triangular fossa; MMDG: Mesial marginal development groove; CDG: Central development groove; DBCR: Distobuccal cusp ridge; DTF: Distal triangular fossa; DMR: Distal marginal ridge; DLCR: Distolingual cusp ridge

marginal ridge to mesial marginal ridge where it joins mesial marginal developmental groove.

5. Mesiobuccal and distobuccal developmental groove join the central groove just inside the mesial and distal marginal ridges. The junction of grooves are deeply pointed and referred as mesial and distal developmental pits.
6. Distal to mesial marginal ridge is a triangular depression, called mesial triangular fossa.
7. Mesial to distal marginal ridge, a depression called distal triangular fossa is present.
8. Buccal and lingual triangular ridges are visible extending from center of central groove to their respective cusp tips.

## SECOND PREMOLAR

### Buccal Aspect (Fig. 1.21)

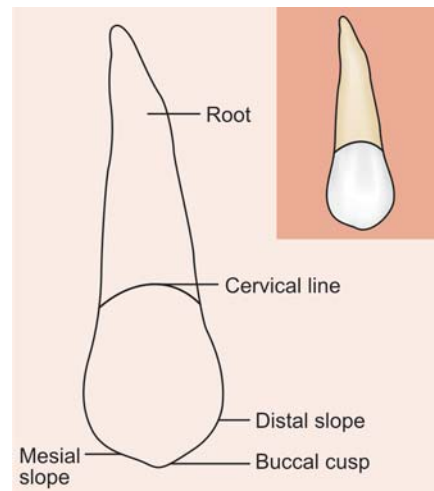
1. Crown is shorter (approximately 1 mm) than first premolar.
2. It is less pointed and more oblong in shape when compared to first premolar.
3. Mesial slope of buccal cusp is shorter than distal slope (reverse is true for first premolar).

### Palatal Aspect (Fig. 1.22)

1. Both palatal and buccal cusps are of same dimensions.
2. Palatal surface is narrower than buccal surface.

### Mesial Aspect (Fig. 1.23)

1. Buccal and palatal cusps are of almost same height.
2. No developmental groove or depression is found on mesial surface.
3. Greater distance between cusp tips increases the dimensions of occlusal surface buccolingually.



**Fig. 1.21:** Buccal aspect

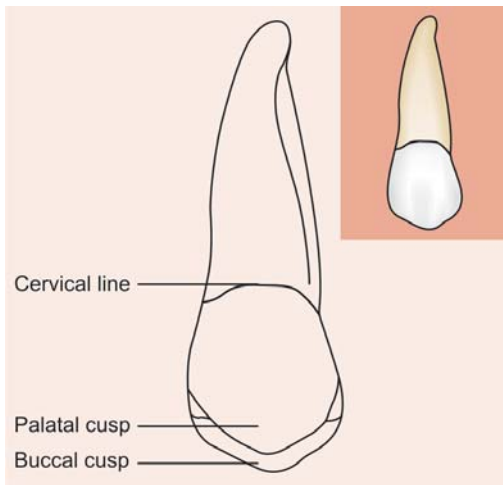


Fig. 1.22: Palatal aspect

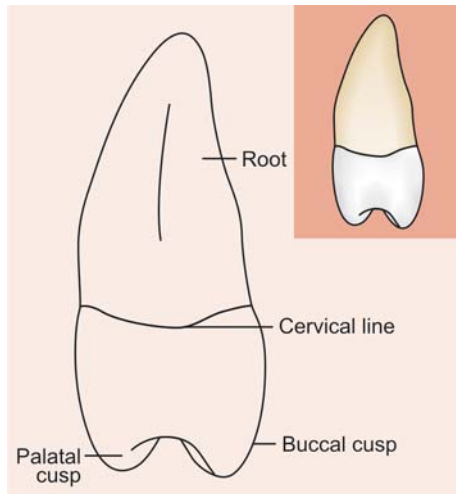


Fig. 1.23: Mesial aspect

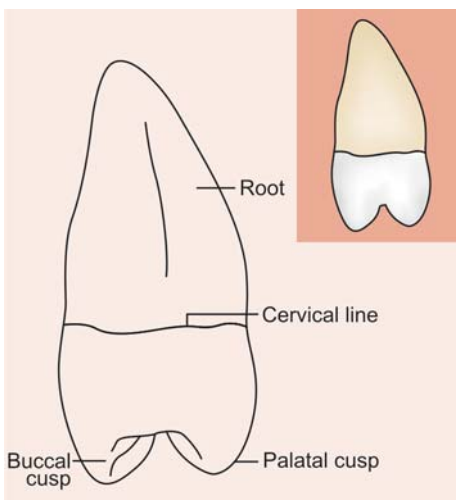


Fig. 1.24: Distal aspect

### Distal Aspect (Fig. 1.24)

It is almost similar to mesial aspect except that distal root depression is present, which is deeper than mesial depression.

### Occlusal Aspect (Fig. 1.25)

1. Outline is rounded or oval.
2. Central developmental groove is shorter and more irregular.
3. Multiple supplementary grooves radiate from central groove. These grooves end in shallow depressions in the enamel of occlusal surface giving it a wrinkled appearance.

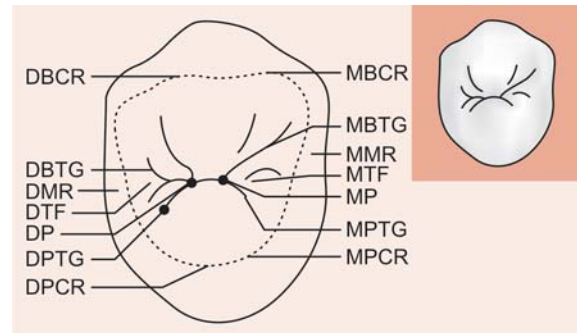


Fig. 1.25: Occlusal aspect: DBCR: Distobuccal cusp ridge; MBCR: Mesiobuccal cusp ridge; DBTG: Distobuccal triangular groove; DMR: Distal marginal ridge; DTF: Distal triangular fossa; DP: Distal pit; DPTG: Distopalatal triangular groove; MBTG: Mesiobuccal triangular groove; MMR: Mesial marginal ridge; MTF: Mesial triangular fossa; MP: Mesial pit; MPTG: Mesiopalatal triangular groove; MPCR: Mesiopalatal cusp ridge

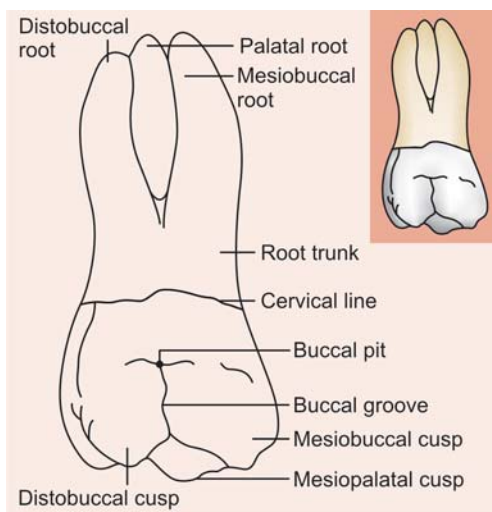
## FIRST MOLAR

### Important features

1. First permanent tooth to erupt.
2. Most caries prone.
3. Location is at center of fully developed jaw antero-posteriorly, so also considered as "corner stones" of dental arches.

### Buccal Aspect (Fig. 1.26)

1. Crown is trapezoidal in shape, the cervical line representing the shorter of uneven sides.
2. Two cusps; mesiobuccal and distobuccal are seen.
3. Mesiobuccal cusp is broader and its mesial and distal slopes meet at an obtuse angle.
4. Distobuccal cusp is less broad and its mesial and distal slopes meet at a right angle.
5. Buccal developmental groove divides two buccal cusps. It extends occlusoapically and terminates approximately



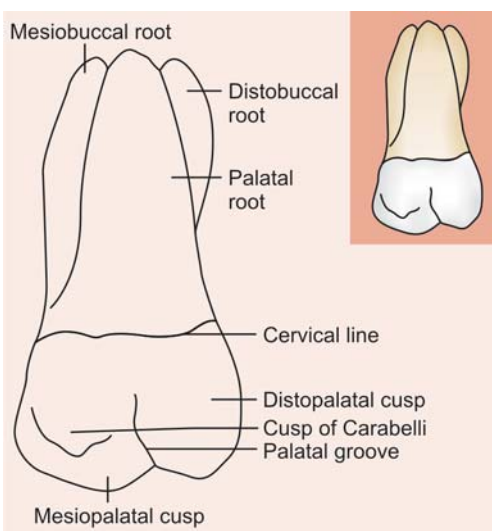
**Fig. 1.26:** Buccal aspect

half the distance from its origin occlusally to the cervical line. At this point, a pit is present called buccal pit.

6. Mesial outline of crown is almost straight whereas distal outline is convex.
7. Mesiopalatal and distopalatal cusps are also seen.
8. All three of roots, i.e. mesiobuccal, distobuccal and palatal are also seen from buccal aspect.

**Palatal Aspect (Fig. 1.27)**

1. It is almost reverse of buccal aspect.
2. Crown is broader mesiodistally.
3. Mesiopalatal and distopalatal cusps are seen.
4. A fifth cusp is also seen on the palatal surface of mesiopalatal cusp, it is termed as “cusp of Carabelli”.



**Fig. 1.27:** Palatal aspect

Cusp ridge of this cusp is 2 mm cervical to the cusp tip of mesiopalatal cusp. Cusp of Carabelli is found in 60 percent of cases.

5. Mesiopalatal cusp is the longest cusp whereas distopalatal cusp is round and spheroidal in shape.
6. All three roots are visible from this aspect.

**Mesial Aspect (Fig. 1.28)**

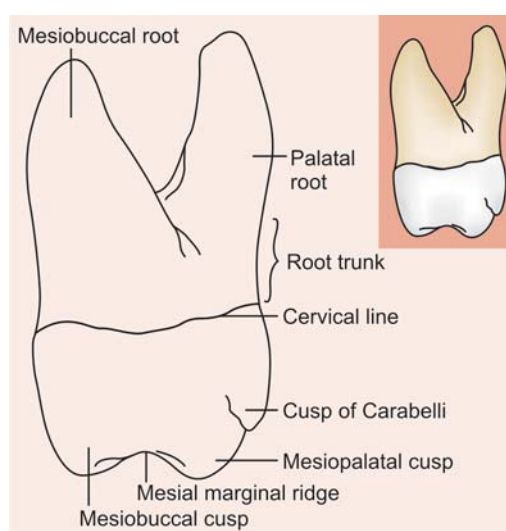
1. Crown appears as shorter and broader buccolingually.
2. Mesiobuccal, mesiopalatal and fifth cup, “the cusp of Carabelli” are seen from this aspect.
3. Mesial marginal ridge is confluent with mesiobuccal and mesiopalatal cusp ridges. It is irregular and curves cervically.

**Distal Aspect (Fig. 1.29)**

1. It is almost similar to that of mesial aspect.
2. Since crown is narrower on the distal surface than mesial surface, most of the palatal and buccal surfaces can be seen from distal aspect.
3. All cusps are visible.

**Occlusal Aspect (Fig. 1.30)**

1. Almost rhomboidal or parallelogram in outline with four major cusp ridges and marginal ridges.
2. Buccolingual measurement of crown on mesial side is greater than distal side, i.e. distal surface is narrower buccolingually, than mesial surface.
3. Mesiopalatal cusp is largest cusp, followed by mesiobuccal, distopalatal, distobuccal and fifth cusp in decreasing size.



**Fig. 1.28:** Mesial aspect



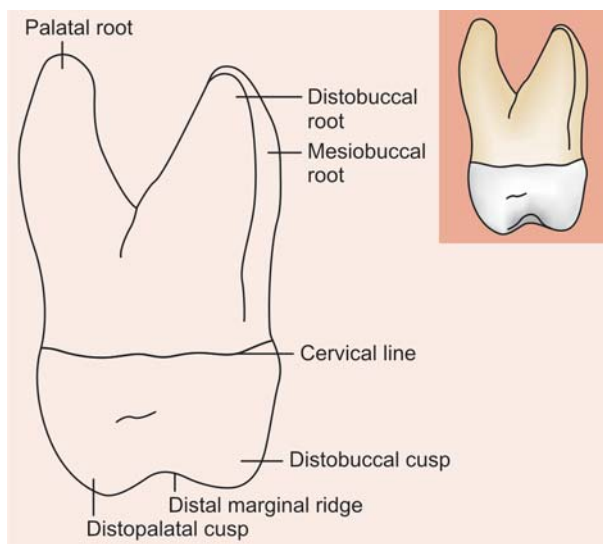


Fig. 1.29: Distal aspect

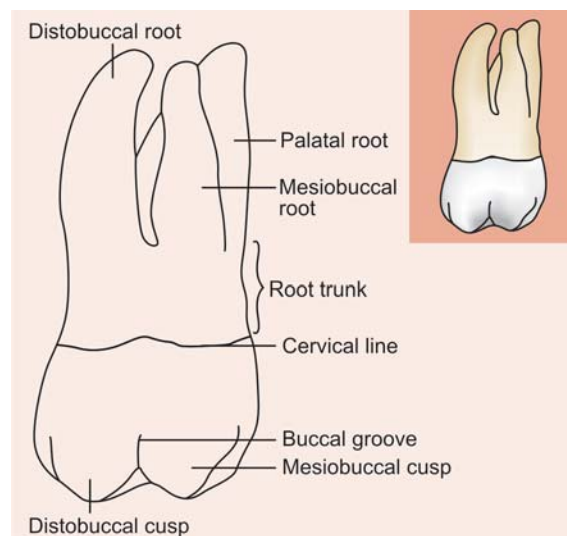
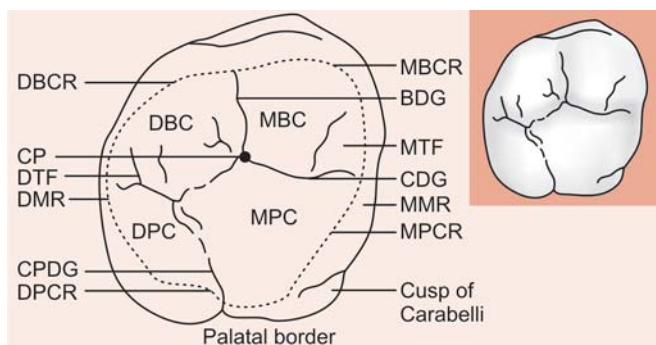


Fig. 1.31: Buccal aspect



**Fig. 1.30:** Occlusal aspect: DBCR: Distobuccal cusp ridge; CP: Central pit; DTF: Distal triangular fossa; DMR: Distal marginal ridge; DPCR: Distopalatal cusp ridge; DBC: Distobuccal cusp; DPC: Distopalatal cusp; MPC: Mesiopalatal cusp; MBCR: Mesiobuccal cusp ridge; BDG: Buccal development groove; MTF: Mesial triangular fossa; CDG: Central development groove; MMR: Mesial marginal ridge; MPCR: Mesiopalatal cusp ridge

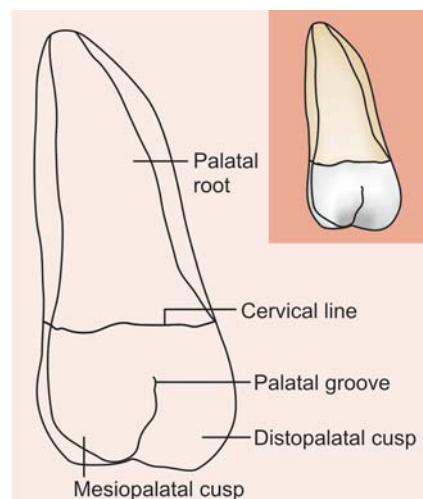


Fig. 1.32: Palatal aspect

- Rhomboidal shape has two acute angles—mesiobuccal and distopalatal and two obtuse angles, i.e. mesiopalatal and distobuccal.
- Each cusp has triangular ridge. The triangular ridges of mesiopalatal and distobuccal cusp meet to form oblique ridge.
- Second triangular ridge of mesiopalatal cusp and triangular ridge of mesiobuccal cusp meet to form transverse ridge.
- Two major fossae present are central fossa and distal fossa. Central fossa is present mesial to oblique ridge, whereas distal fossa is present distal to oblique ridge.
- Two minor fossae present are mesial and distal triangular fossae.
- Four grooves are present, i.e. central groove, buccal groove, transverse groove and distal oblique groove.

## SECOND MOLAR

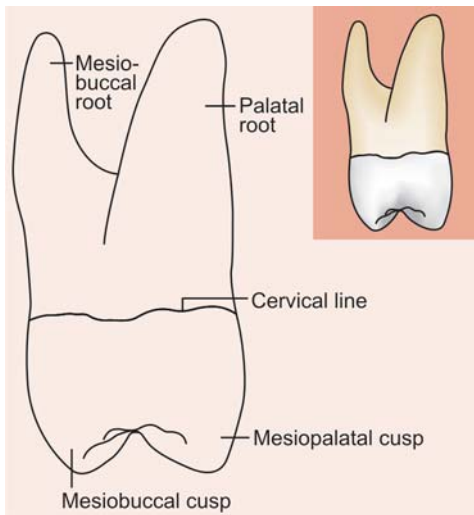
### Buccal Aspect (Fig. 1.31)

- The crown is slightly shorter and narrower than first molar.
- Mesiobuccal cusp is larger than distobuccal cusp.
- Buccal groove is present which separates two buccal cusps.

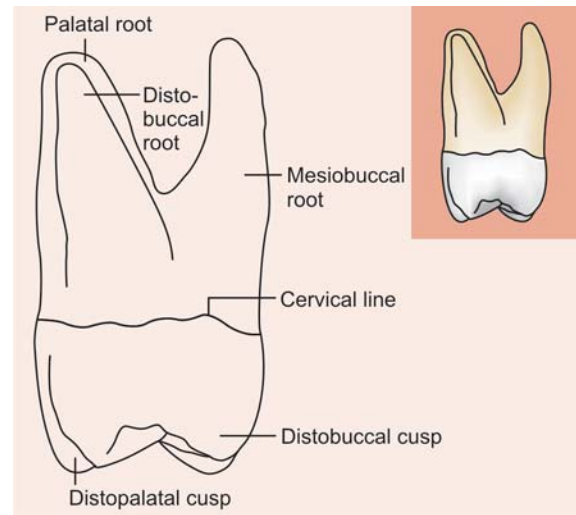
### Palatal Aspect (Fig. 1.32)

It is mainly different from first molar in following aspects:

- Shorter distopalatal cusp.
- Absence of fifth cusp.
- Distobuccal cusp can be seen through the sulcus between mesiopalatal and distopalatal cusp.



**Fig. 1.33:** Mesial aspect



**Fig. 1.34:** Distal aspect

### Mesial Aspect (Fig. 1.33)

Crown length is less when compared to first molar. Mesial marginal ridge is located more occlusally than distal marginal ridge.

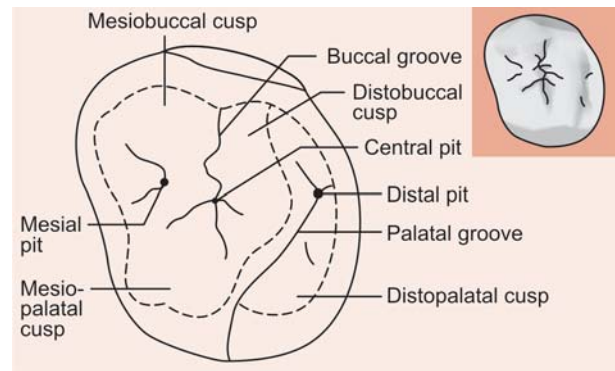
### Distal Aspect (Fig. 1.34)

1. Since distobuccal cusp is smaller, mesiobuccal cusp can be seen from this aspect.
2. Distal marginal ridge is placed more cervically than mesial marginal ridge.

### Occlusal Aspect (Fig. 1.35)

It is almost similar to maxillary first molar except that:

1. Mesiodistal dimensions are smaller than first molar.
2. Mesiobuccal and mesio-palatal cusps are same as that of first molar, but distobuccal and distopalatal cusps are smaller and less well developed.
3. Fifth cusp is missing.
4. More of supplementary grooves and pits are present than first molar.



**Fig. 1.35:** Occlusal aspect

### Labial Aspect (Fig. 1.36)

1. Crown is smooth, tapered from incisal ridge to cervical portion.
2. Sharp mesial and distal incisal angles with straight incisal edge perpendicular to long axis of the tooth.

### Lingual Aspect (Fig. 1.37)

1. Smooth surface with slight concavity.
2. Due to lingual convergence, crown is narrower on lingual side.
3. Small and convex cingulum.

### Mesial Aspect (Fig. 1.38)

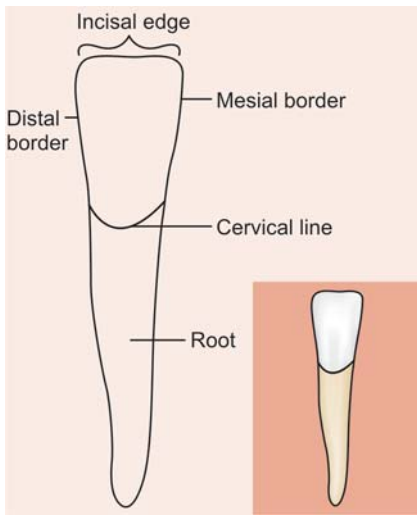
1. Wedge shaped with incisal edge being lingual to long axis of the root.

## MANDIBULAR TEETH

### CENTRAL INCISOR

#### Important points

- Smallest tooth in arch
- Bilaterally symmetrical



**Fig. 1.36:** Labial aspect

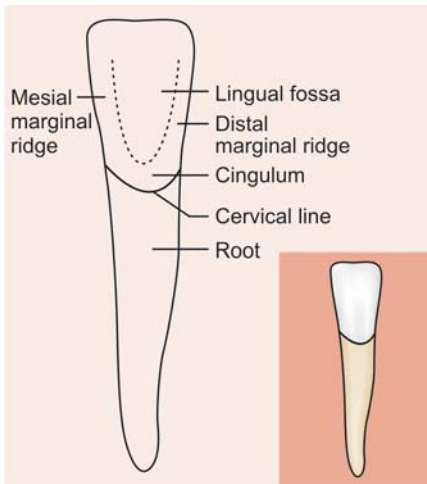
2. Mesial surface is straight above the cervical line till incisal ridge.
3. Cervical line is deeply curved.

**Distal Aspect (Fig. 1.39)**

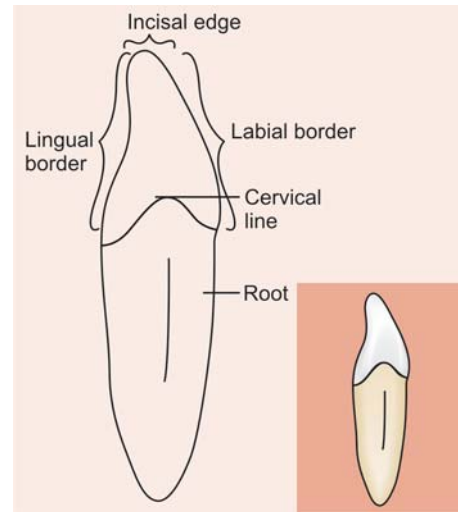
It is almost similar to mesial aspect, except that cervical line curves 1 mm less than on mesial surface.

**Incisal Aspect (Fig. 1.40)**

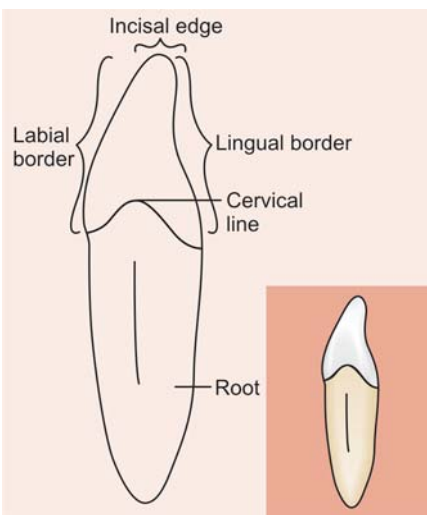
1. Bilateral symmetrical.
2. Incisal edge is perpendicular to the line bisecting labiolingually.
3. Labial surface of crown is wider mesiodistally than lingual surface.



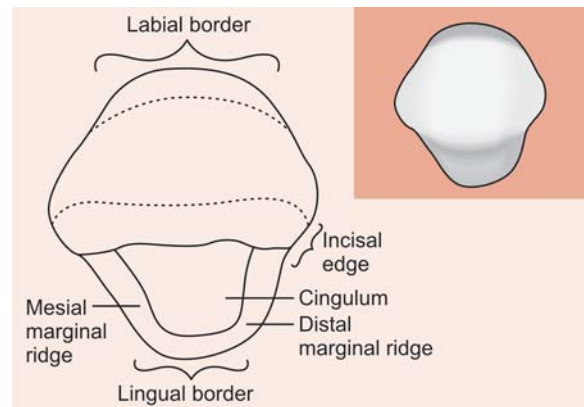
**Fig. 1.37:** Lingual aspect



**Fig. 1.39:** Distal aspect



**Fig. 1.38:** Mesial aspect



**Fig. 1.40:** Incisal aspect

## MANDIBULAR LATERAL INCISOR

### Labial Aspect (Fig. 1.41)

1. Crown is tilted distally on the root.
2. Mesioincisal angle is sharp, whereas distoincisal angle is slightly rounded.

### Lingual Aspect (Fig. 1.42)

1. Distal marginal ridge is shorter than mesial marginal ridge.
2. Cingulum lies slight distal to the long axis of the tooth.

### Mesial Aspect (Fig. 1.43)

1. Slightly longer than distal aspect.
2. Incisal edge slopes downwards in the distal direction due to longer mesial side.
3. Curvature of cervical line is deep.

### Distal Aspect (Fig. 1.44)

1. Incisal edge is twisted distolingually, i.e. distal portion is placed more lingually than mesial portion.
2. Curvature of cervical line is less deep than on mesial surface.

### Incisal Aspect (Fig. 1.45)

Incisal edge is twisted distolingually. This twist corresponds to the curvature of mandibular arch.

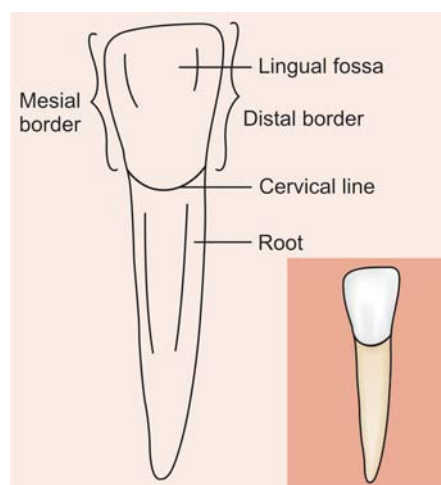


Fig. 1.42: Lingual aspect

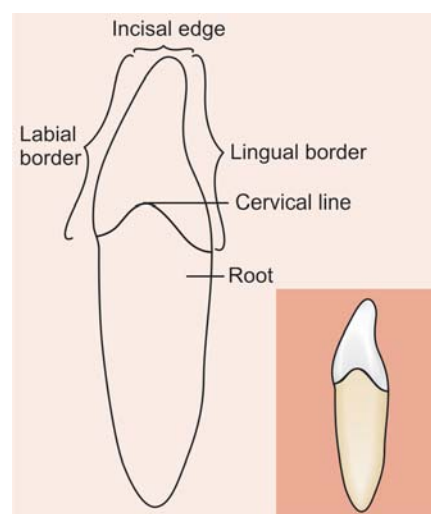


Fig. 1.43: Mesial aspect

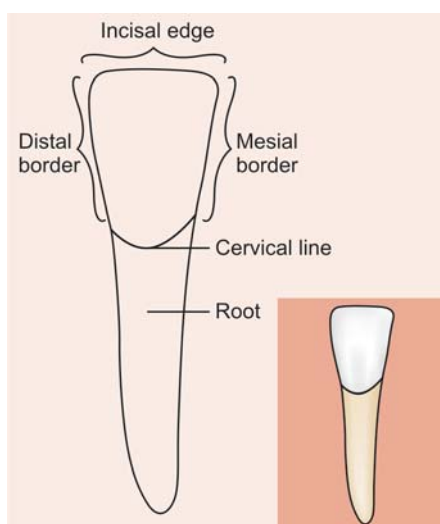


Fig. 1.41: Labial aspect

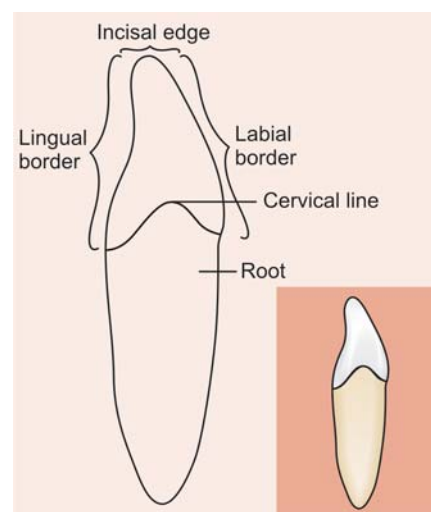
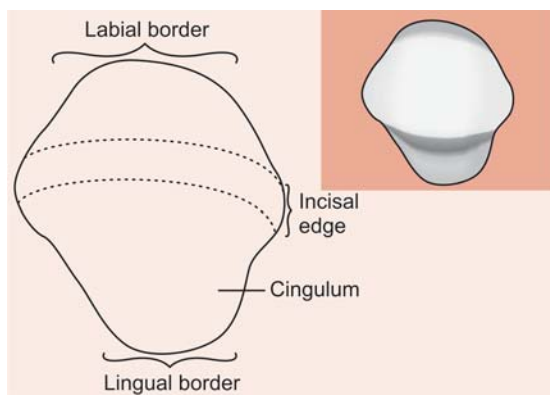
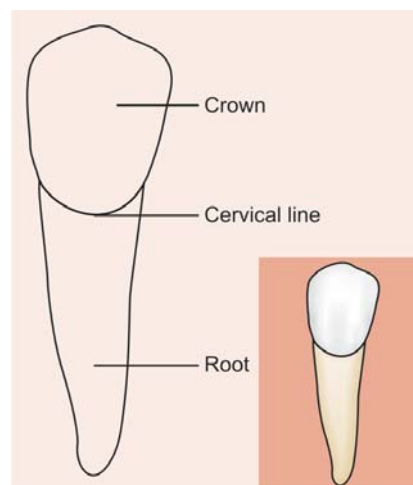


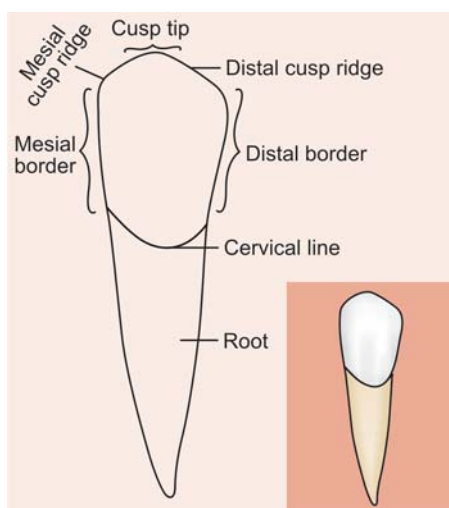
Fig. 1.44: Distal aspect



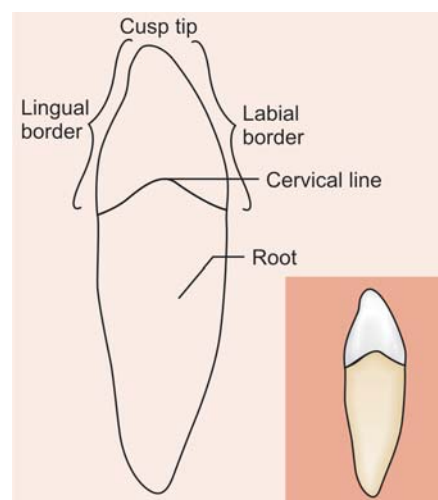
**Fig. 1.45:** Incisal aspect



**Fig. 1.47:** Lingual aspect



**Fig. 1.46:** Labial aspect



**Fig. 1.48:** Mesial aspect

## MANDIBULAR CANINE

### Labial Aspect (Fig. 1.46)

1. Crown is narrower than maxillary canine.
2. Crown appears longer because of its narrowness than maxillary crown.
3. Mesial outline is almost straight.
4. Mesial slope of cusp is shorter than distal slope.
5. Crown appears to be tilted distally because there is more of crown distal to long axis of root than mesial to it.

### Lingual Aspect (Fig. 1.47)

1. Lingual surface is flatter in comparison to maxillary canine.
2. Cingulum is not very much prominent.
3. Mesial marginal ridge is longer than the distal marginal ridge.

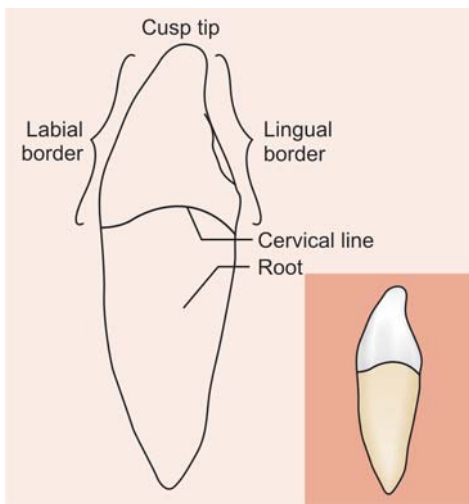
### Mesial Aspect (Fig. 1.48)

1. Wedge shaped with cusp tip almost centered over the root.
2. Curvature of cervical line is more than on maxillary canine.
3. Due to less prominence of cingulum and less labiolingual thickness of crown, cusp appears more pointed with slender cusp ridge.

### Distal Aspect (Fig. 1.49)

It is almost similar to mesial aspect except that:

1. Crown is twisted distolingually, so distolingual angle is positioned slightly lingual than cusp tip.
2. Curvature of cervical line is less than on mesial side.



**Fig. 1.49:** Distal aspect

### Incisal Aspect (Fig. 1.50)

1. Mesiodistal dimensions are lesser than labiolingual dimensions.
2. Cusp tip and mesial cusp ridge are lingually placed.
3. Tooth appears to have distolingual twist.

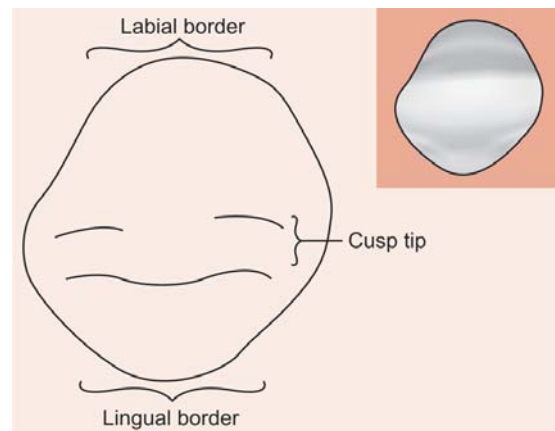
## FIRST PREMOLAR

### Buccal Aspect (Fig. 1.51)

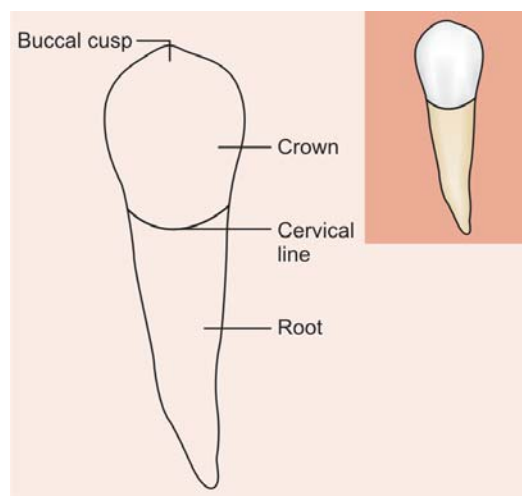
1. Appears bilateral symmetrical.
2. Buccal cusp tip is located near the long axis of tooth.
3. Crown appears trapezoidal in shape with cervical margin being the shortest of uneven sides.
4. Buccal cusp tip is pointed and the cusp slopes meet at an obtuse angle.
5. Mesial cusp slope is slightly shorter than distal cusp slope.
6. Buccal ridge is present from cervical margin to cusp tip.

### Lingual Aspect (Fig. 1.52)

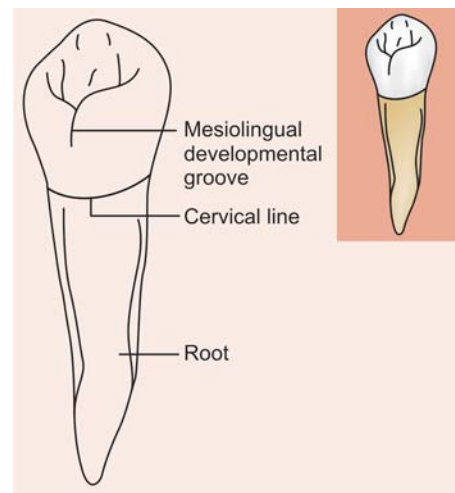
1. Because of lingual convergence, crown of first premolar tapers toward the lingual side.
2. Lingual cusp is small, with pointed tip.
3. Middle buccal lobe is well developed making its major portion. Due to this feature, it resembles canine.
4. Mesiolingual developmental groove is present which demarcates mesiobuccal and lingual lobe. It extends into the mesial fossa of occlusal surface.
5. A characteristic feature of this tooth is that mesial marginal ridge is located more cervically than distal marginal ridge.



**Fig. 1.50:** Incisal aspect



**Fig. 1.51:** Buccal aspect



**Fig. 1.52:** Lingual aspect

**Mesial Aspect (Fig. 1.53)**

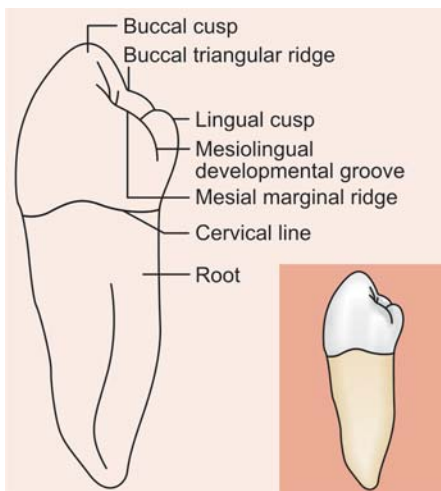
1. Crown is rhomboidal in shape with buccal tip centered over the root.
2. Crown is tilted lingually.
3. Buccal outline is convex from cervical line to the cusp tip.
4. Lingual outline shows prominent mesiobuccal lobe.
5. Mesial marginal ridge merges with mesiolingual fossa. This houses mesiolingual slopes.
6. Buccal triangular ridge slopes parallel to mesial marginal ridge. It slopes cervically at 45° from cusp tip towards center of occlusal surface.

**Distal Aspect (Fig. 1.54)**

1. Distal marginal ridge is higher above the cervix than mesial marginal ridge.
2. There is no developmental groove on distal marginal ridge.
3. Most of the distal surface of crown appears smooth and spheroidal.

**Occlusal Aspect (Fig. 1.55)**

1. Roughly diamond shaped.
2. Tip of buccal cusp is slightly buccal to center of root.
3. Mesiobuccal and distobuccal line angles are prominent.
4. Buccal ridge appears prominent.
5. Distal marginal ridge is at right angle to the buccal surface whereas mesial marginal ridge is at an acute angle to buccal surface.
6. Mesial fossa contains mesial developmental groove which extends buccolingually.

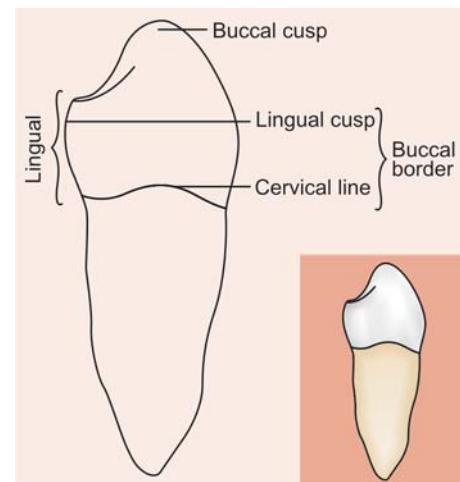
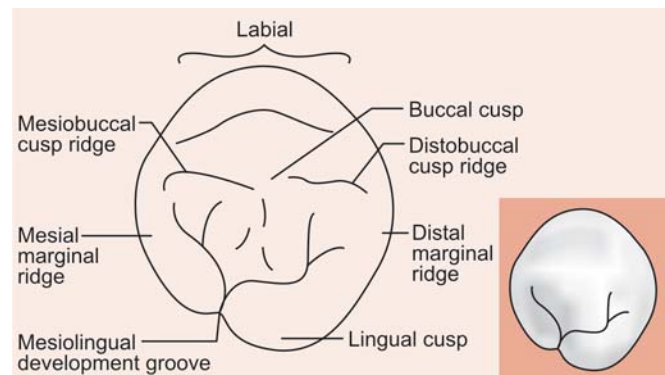
**Fig. 1.53:** Mesial aspect**SECOND PREMOLAR****Buccal Aspect (Fig. 1.56)**

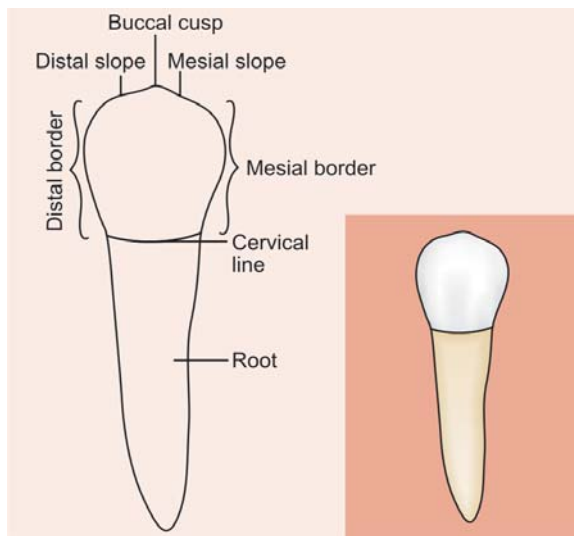
1. Shorter buccal cusps than first premolar.
2. Crown appears as a square in shape.
3. Two cusps; mesiobuccal and distobuccal are seen.
4. Contact areas appear broad and located occlusally because of short buccal cusp.

**Lingual Aspect (Fig. 1.57)**

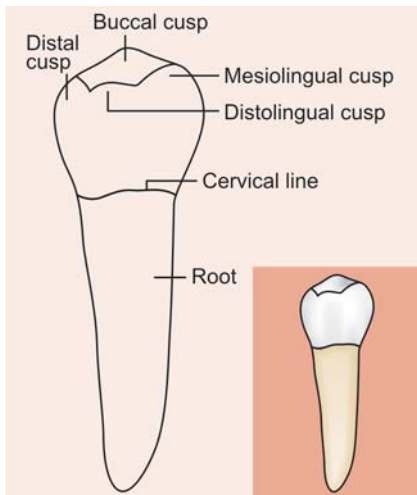
Two forms are seen from this aspect:

1. *One buccal and one lingual cusp.*
  - a. Lingual cusp is well developed.
  - b. Lingual cusp lies mesial to or along the long axis of the root.
  - c. Spheroidal and smooth surface with constricted cervical portion.

**Fig. 1.54:** Distal aspect**Fig. 1.55:** Occlusal aspect



**Fig. 1.56:** Labial aspect



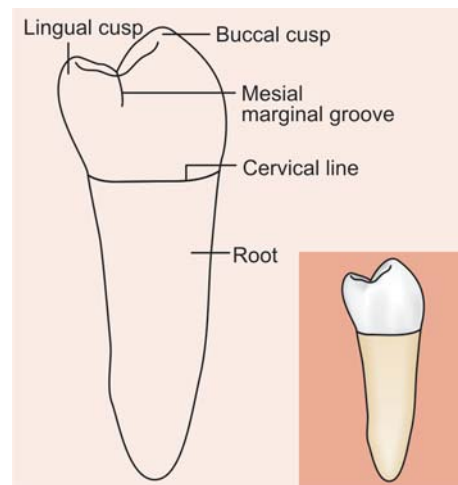
**Fig. 1.57:** Lingual aspect

2. *One buccal cusp and two lingual cusps.*
  - a. Mesiolingual and distolingual cusps are seen, mesiolingual being higher than distolingual cusp.
  - b. A groove is present between two lingual cusps.

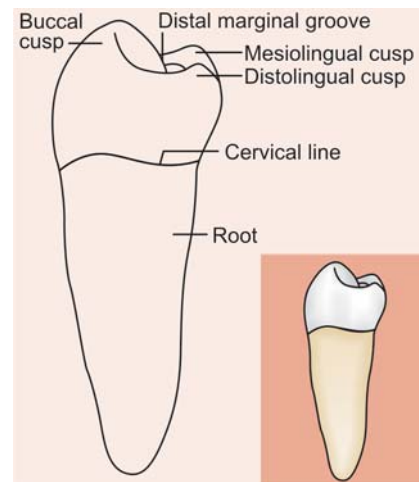
### Mesial Aspect (Fig. 1.58)

When compared with first premolar, second premolar shows following differences:

1. Crown is wider buccolingually.
2. Buccal cusp is not so nearly centered over the root.
3. Marginal ridge is perpendicular to long axis of tooth.
4. Lingual lobe is developed to greater extent.
5. Absence of mesiolingual groove on crown portion.



**Fig. 1.58:** Mesial aspect



**Fig. 1.59:** Distal aspect

### Distal Aspect (Fig. 1.59)

It is almost similar to mesial aspect except that:

1. Cervical line curvature is less than on mesial surface.
2. Distolingual cusp is smaller than mesiolingual cusp.

### Occlusal Aspect (Fig. 1.60)

#### *One Buccal Cusp and One Lingual Cusp*

1. Rounded occlusal outline.
2. Lingual convergence is seen.
3. Buccal cusp is bigger in size than lingual cusp.
4. Rounded mesiolingual and distolingual line angles.
5. Central developmental groove extends mesiodistally. It terminates in mesial and distal fossa.
6. There is no central fossa.
7. No lingual groove present.



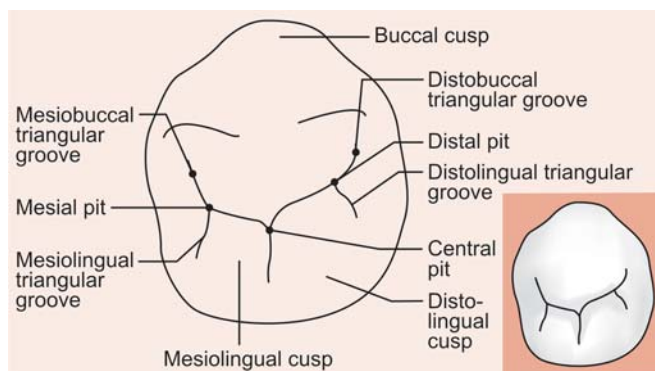


Fig. 1.60: Occlusal aspect

### One Buccal Cusp and Two Lingual Cusps

1. Square shape with buccal cusp being largest in size, followed by mesiolingual and distolingual cusps.
2. Each cusp has well developed triangular ridges, separated by grooves.
3. Grooves join to form a central pit and Y shape appearance.
4. Lingual development groove extends between two lingual cusps and ends on lingual surface of crown just below convergence of lingual cusp ridges.

## MANDIBULAR FIRST MOLAR

### Buccal Aspect (Fig. 1.61)

1. Trapezoidal in shape.
2. Two buccal cusps and three lingual cusp tips are seen because buccal cusps are usually flattened and lingual cusps are higher.
3. Two buccal grooves, i.e. mesiobuccal and distobuccal grooves are found which demarcate mesiobuccal and distobuccal cusp, distobuccal and distal cusp respectively.
4. Mesiobuccal cusp is widest mesiodistally and distal cusp is smallest of all.
5. Two roots, one mesial and one distal are seen from buccal aspect. Mesial root is more curved than the distal root.

### Lingual Aspect (Fig. 1.62)

1. Three cusps, i.e. mesiolingual, distolingual and lingual portion of distal cusp are seen.
2. Mesiolingual cusp is widest mesiodistally with its cusp tip placed higher than distolingual cusp.
3. Lingual developmental groove demarcates mesiolingual and distolingual and distolingual cusp.

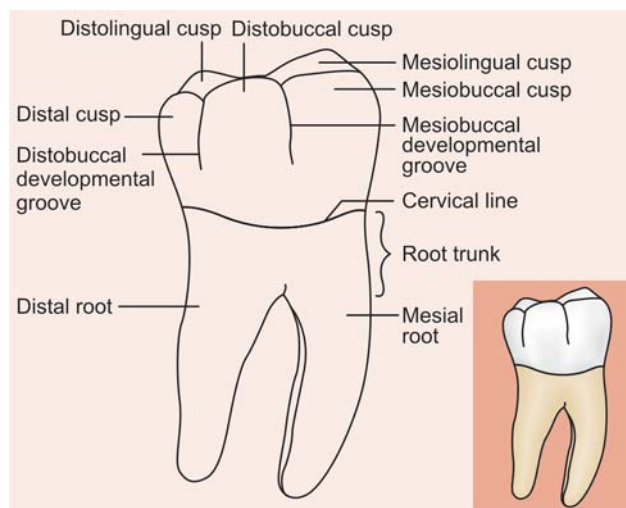


Fig. 1.61: Buccal aspect

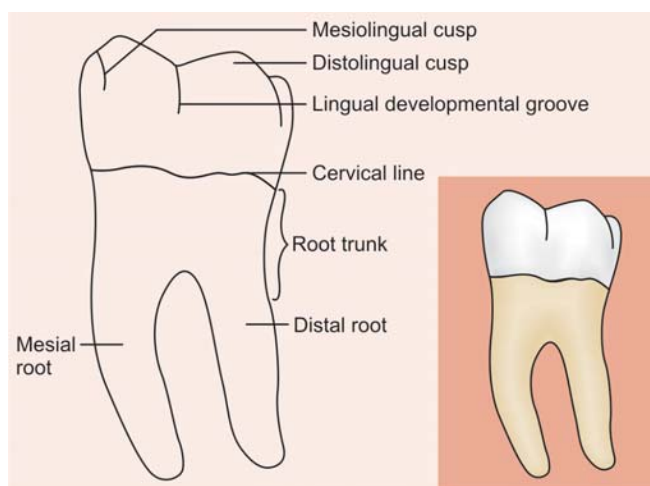
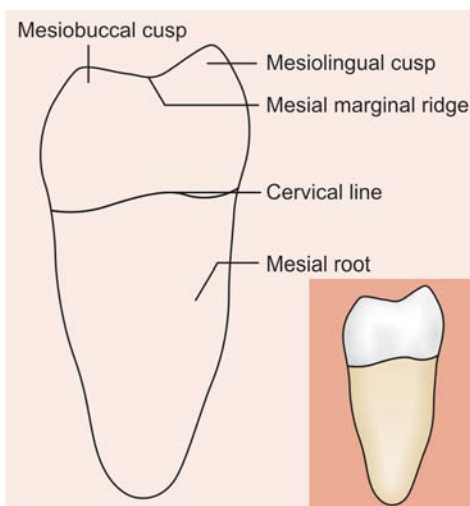


Fig. 1.62: Lingual aspect

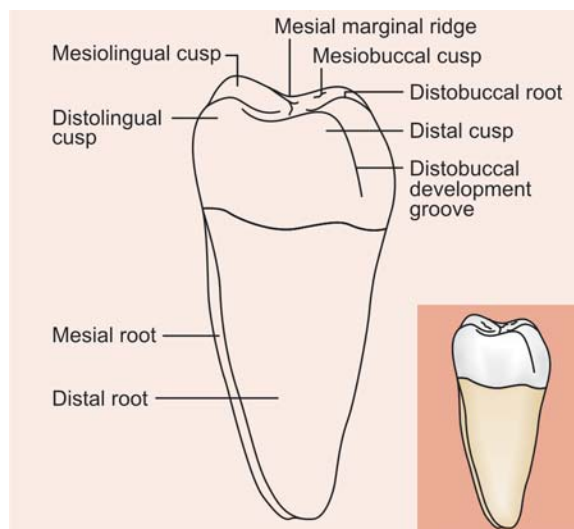
4. Surface of crown lingually is smooth and spheroidal on each cusp.
5. Mesial and distal roots are seen from lingual aspect.

### Mesial Aspect (Fig. 1.63)

1. Roughly rhomboidal in shape.
2. Two cusps, i.e. mesiobuccal and mesiolingual cusps are seen.
3. Since, mesial portion of tooth is broader the distal portion of tooth cannot be seen from mesial aspect.
4. Crown has lingual tilt with respect to long axis of root.
5. There is a curvature over the cervical third of the crown buccally termed as buccal cervical ridge.
6. Marginal ridge is confluent with mesial ridges of mesiobuccal and mesiolingual cusp.



**Fig. 1.63:** Mesial aspect



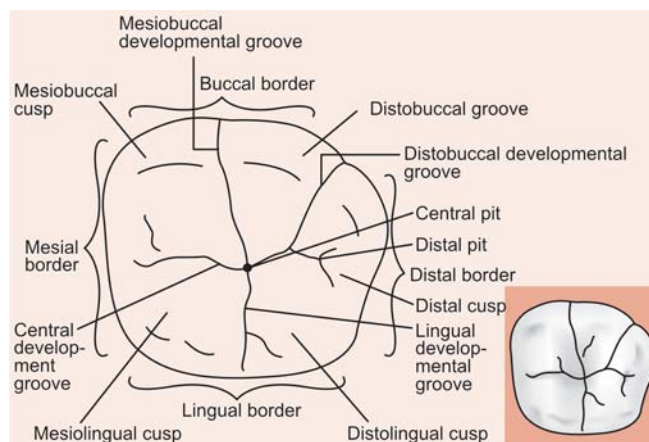
**Fig. 1.64:** Distal aspect

### Distal Aspect (Fig. 1.64)

1. Since crown is shorter on distal surface, most of the crown portion can be seen through distal aspect.
2. All cusps can be seen.
3. Distolingual cusp is higher than distobuccal cusp.
4. Distal cusp, located on distobuccal angle of crown is smallest of all cusps.
5. Distal marginal ridge is short and is made up of distal cusp ridge of distal cusp and distolingual cusp ridge of distolingual cusp.
6. Occlusal surface shows distal tipping (slopes cervically from mesial to distal).

### Occlusal Aspect (Fig. 1.65)

1. Hexagonal in outline.
2. Buccolingual dimensions are more on mesial side than on distal side.
3. Mesiodistal dimensions are more than buccolingual dimensions.
4. Five cusps are seen, i.e. mesiobuccal, distobuccal, mesiolingual, distolingual and distal.
5. There is one major fossa; central fossa which is present between buccal and lingual cusp ridges.
6. Two minor fossae present are mesial and distal triangular fossa. Mesial triangular fossa is present distal to mesial marginal ridge and distal triangular fossa is present mesial to distal marginal ridge.
7. Grooves present are central development groove, mesiobuccal, distobuccal and lingual development groove.



**Fig. 1.65:** Occlusal aspect

## SECOND MOLAR

### Buccal Aspect (Fig. 1.66)

1. Crown is shorter cervico-occlusally and narrower mesiodistally when compared to first molar.
2. Four cusps seen are mesiobuccal, distobuccal, mesiolingual and distolingual.
3. Buccal groove separates mesiobuccal and distobuccal cusp.
4. Two roots, one mesial and one distal are seen from buccal aspect.

### Lingual Aspect (Fig. 1.67)

1. Mesiolingual and distolingual cusps are seen.
2. Crown slightly converges on lingual side.

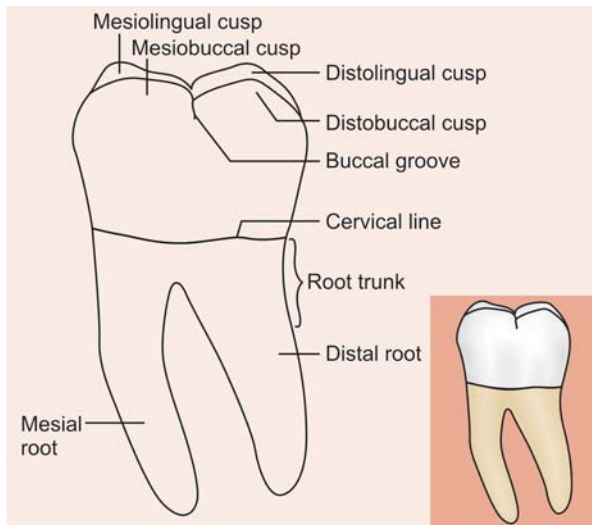


Fig. 1.66: Buccal aspect

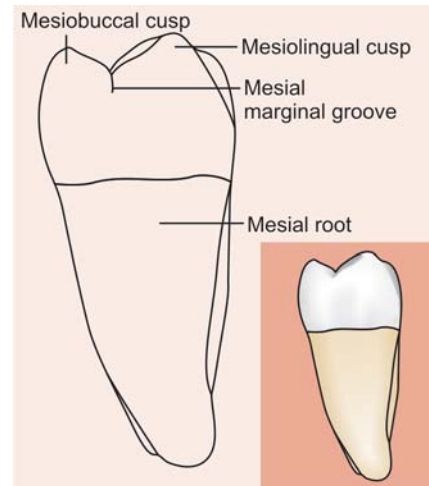


Fig. 1.68: Mesial aspect

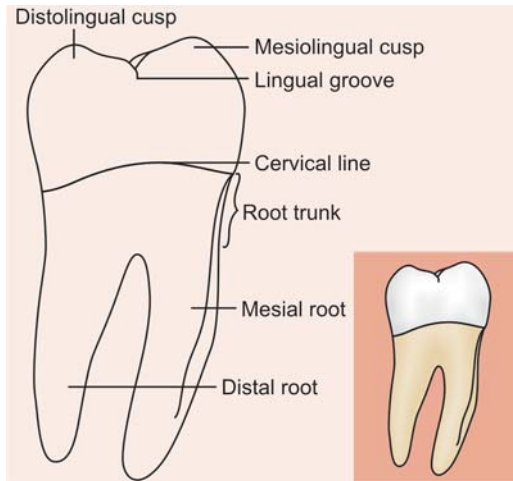


Fig. 1.67: Lingual aspect

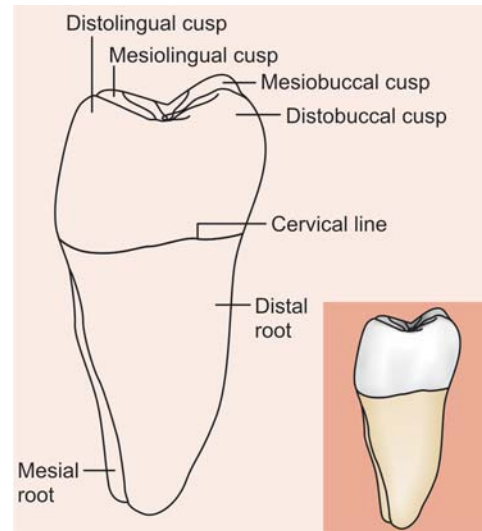


Fig. 1.69: Distal aspect

3. Mesiolingual cusp is larger than distolingual cusp.
4. Mesial and distal roots are seen from lingual aspect.

#### Mesial Aspect (Fig. 1.68)

1. Almost similar to first molar.
2. Mesiolingual cusp is the largest cusp.
3. Occlusal surface is constricted buccolingually.

#### Distal Aspect (Fig. 1.69)

1. Almost similar to first molar.
2. Mesiobuccal and mesiolingual cusp tips can be seen.
3. Distobuccal cusp is shortest of four cusps.
4. Crown shows distal tilt, i.e. distal marginal ridge is placed more cervically.

#### Occlusal Aspect (Fig. 1.70)

1. Almost rectangular in shape.
2. Crown tapers both lingually and distally.
3. Mesiodistal dimensions are more than buccolingual dimensions.
4. Buccal surface of mesiobuccal cusp shows a prominent bulge, i.e. mesial cervical bulge.
5. Since no distal cusp is present, distobuccal groove is not there.
6. Transverse ridge is formed by triangular ridges of mesiobuccal and mesiolingual cusps, triangular ridges of distobuccal and distolingual cusps.
7. Grooves mainly present are central groove, buccal groove and the lingual groove.

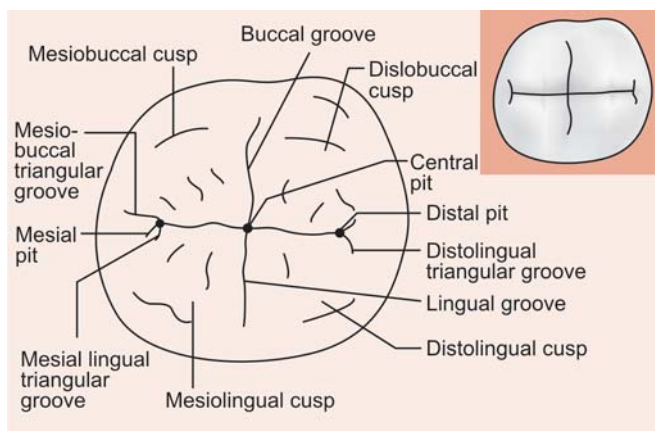


Fig. 1.70: Occlusal aspect

### DIFFERENTIATION BETWEEN RIGHT AND LEFT MAXILLARY CENTRAL INCISOR

1. Mesial outline is straight.
2. Distal outline is rounded.
3. Mesioincisal angle is sharp and distoincisal angle is rounded.
4. Curvature of cervical line towards incisal surface is more on mesial side than on distal side.

### DIFFERENTIATION BETWEEN RIGHT AND LEFT MAXILLARY LATERAL INCISOR

1. Distal outline is more rounded than mesial outline.
2. Distoincisal angle is more rounded than mesioincisal angle.

### DIFFERENTIATION BETWEEN RIGHT AND LEFT MAXILLARY CANINE

1. Mesial cusp ridge is shorter than distal cusp ridge.
2. Curvature of cervical line is more on mesial side than on distal side.

### DIFFERENTIATION BETWEEN RIGHT AND LEFT FIRST MAXILLARY PREMOLAR

1. Mesial cusp ridge is longer than distal cusp ridge.
2. Mesial development groove is present in enamel of mesial marginal ridge.
3. Mesial development depression is present.

### DIFFERENTIATION BETWEEN RIGHT AND LEFT SECOND PREMOLAR

1. Mesial cusp ridge is shorter than distal cusp ridge.

### DIFFERENTIATION BETWEEN RIGHT AND LEFT MAXILLARY FIRST MOLAR

1. Cusp of Carabelli is present on palatal surface of mesiopalatal cusp.
2. Mesiopalatal cusp is the largest cusp.
3. Oblique ridge extends from mesiopalatal to distobuccal cusp.

### DIFFERENTIATION BETWEEN RIGHT AND LEFT MAXILLARY SECOND MOLAR

1. Mesiopalatal cusp is largest of all.
2. Occlusal surface shows tilt from mesial to distal.

### DIFFERENTIATION BETWEEN RIGHT AND LEFT MANDIBULAR LATERAL INCISOR

1. Mesial side longer than distal.
2. Incisal edge twisted distolingually.
3. Incisal edge slopes downwards in distal direction.
4. A deep concavity is present on distal side above the cervical line.

### DIFFERENTIATION BETWEEN RIGHT AND LEFT MANDIBULAR CANINE

1. Mesial outline is almost straight and distal outline is convex.
2. Mesial cusp ridge is shorter than distal cusp ridge.

### DIFFERENTIATION BETWEEN RIGHT AND LEFT MANDIBULAR FIRST PREMOLAR

1. Occlusal surface slopes lingually.
2. Presence of mesiolingual groove which extends into mesial fossa of occlusal surface.

### DIFFERENTIATION BETWEEN RIGHT AND LEFT SECOND PREMOLAR

#### *One Buccal and One Lingual Cusp*

1. Curvature of cervical line is more on mesial side than on distal.
2. Distal marginal ridge is placed more cervically than mesial marginal ridge
3. Mesial fossa is smaller than distal fossa.

#### *One Buccal and Two Lingual Cusps*

1. Distolingual cusp is smaller than mesiolingual cusp.
2. Central fosse lies distal to the occlusal surface.
3. Distal groove is shorter than mesial groove.

**Table:** Difference between central and lateral incisor

<i>Central incisor</i>	<i>Lateral incisor</i>
1. Slightly more in dimensions (bigger size)	Smaller in dimensions (smaller size)
2. Mesiodistal dimensions more than labiolingual dimensions.	Mesiodistal and labiolingual dimensions are almost same.
3. Palatal fossae is large and shallow	Palatal fossae is small and deep
4. Palatal pit is not a common finding	Palatal pit is commonly seen
5. Mesioincisal angle is sharp	It is somewhat rounded
6. Distoincisal angle is slightly rounded	It is more rounded
7. Marginal ridges and cingulum are moderately prominent	Marginal ridge and cingulum are more prominent

**Table:** Difference between first and second molar

<i>First molar</i>	<i>Second molar</i>
1. Usually five cusps are present	Usually four cusps are present.
2. Cusp of Carabelli is present	It is absent
3. Buccal cusps are equal in height	Distobuccal cusp is smaller in size
4. Oblique ridge is prominent	It is not prominent
5. Distopalatal cusp is large	It is smaller in size

**Table:** Difference between maxillary and mandibular canine

<i>Maxillary canine</i>	<i>Mandibular canine</i>
1. Buccolingual dimensions are more	Buccolingual dimensions are smaller than maxillary canine.
2. Cingulum is more prominent	It is less prominent
3. Lingual fossa is quite deep	It is almost flat.
4. In mesial and distal aspect cusp tip lies labial to long axis of root	Cusp tip lies lingual to line passing through cusp tip and long axis of root.

**Table:** Difference between maxillary first and second premolar

<i>First premolar</i>	<i>Second premolar</i>
1. Buccal cusp is higher than palatal cusp	Both cusps are almost of similar height
2. Mesial and distal surfaces converge palatally	Mesial and distal sides are almost parallel
3. Mesial cusp slope is larger than distal cusp slope	Mesial cusp slope is shorter than distal cusp slope
4. Mesial marginal development groove is present	It is absent
5. Occlusal outline is almost hexagonal in shape	It is almost rounded or ovoid in shape

**Table:** Difference between mandibular central and lateral incisor

<i>Central incisor</i>	<i>Lateral incisor</i>
1. Bilateral symmetrical	Asymmetrical
2. Mesioincisal and distoincisal angles are sharp	Distoincisal angle is more rounded than mesioincisal angle
3. Mesiodistal dimensions are less than lateral	Mesiodistal dimensions are more
4. Incisal edge is at right angle to labiolingual bisecting line	Incisal edge is twisted distolingually

**Table:** Difference between first and second premolar

<i>First premolar</i>	<i>Second premolar</i>
1. Two cusps are present	Two or three cusps are present
2. Buccal cusp is prominent	Both buccal and lingual are equal in size
3. Occlusal outline is diamond shaped	It is square or triangular in shape
4. Occlusal surface slopes lingually	It is almost horizontal
5. Mesiolingual development groove is present	It is usually not present
6. Mesial and distal margins converge lingually	Mesial and distal margins are parallel
7. Central pit is not present	Central pit is seen in three cusp type

**Table:** Difference between mandibular first and second molar

<i>First molar</i>	<i>Second molar</i>
1. Usually five cusps are present	Four cusps are present
2. Mesiodistal dimensions are more	Mesiodistal dimensions are less
3. Occlusal outline is almost hexagonal in shape	It is almost rectangular in shape
4. Main groove form Y shaped pattern	Main groove forms + shaped pattern

### DIFFERENTIATION BETWEEN RIGHT AND LEFT MANDIBULAR FIRST MOLAR

1. Mesiobuccal cusp is widest of all and distal cusp is smallest of all.
2. Occlusal surface shows distal tipping.

### **DIFFERENTIATION BETWEEN RIGHT AND LEFT MANDIBULAR SECOND MOLAR**

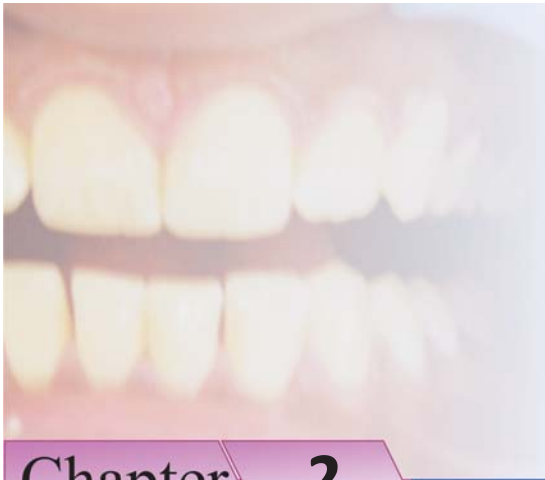---

1. Crown shows distal tilt making occlusal surface to slope cervically from mesial to distal.
2. Crown shows distal and lingual taper.

### **VIVA QUESTIONS**

---

- Q. Which is the largest tooth?
- Q. Which tooth has longest root?
- Q. Which tooth is widest mesiodistally?
- Q. Which cusp ridge is bigger in maxillary canine?
- Q. Which tooth is named as corner stone of mouth?
- Q. In which tooth cusp of carabelli is present?
- Q. In lower arch which tooth has five cusps?
- Q. Which is the smallest cusp in mandibular first molar?
- Q. Which is the largest cusp of maxillary first molar?
- Q. What are differences between maxillary first and second molar?
- Q. How can you differentiate maxillary right and left central incisor?
- Q. How can you differentiate maxillary first and second premolar?
- Q. How can you differentiate mandibular central and lateral incisor?
- Q. How can you differentiate maxillary and mandibular canine?
- Q. How can you differentiate mandibular first and second premolar?
- Q. How can you differentiate maxillary right and left central incisor?
- Q. Which tooth is bilateral symmetrical?
- Q. How can you differentiate right and left maxillary first premolar?
- Q. Enumerate special features of maxillary lateral incisor.
- Q. What are important features of maxillary first molar?
- Q. What are important features of mandibular central incisor?



# Tooth Nomenclature

## Chapter 2

### DEFINITION OF OPERATIVE DENTISTRY CLASSES OF HUMAN TEETH

- Incisors
- Canines
- Premolars
- Molars

### SETS OF TEETH

### TOOTH NUMBERING SYSTEMS

- Zsigmondy-Palmer System
- Universal System
- FDI—Fédération Dentaire Internationale
- Comparison of Tooth Numbering Systems

### NOMENCLATURE OF TOOTH SURFACES

- Buccal
- Labial
- Facial
- Mesial
- Distal
- Lingual
- Occlusal
- Incisal
- Gingival
- Cervical
- Anatomic Crown
- Clinical Crown

### NOMENCLATURE RELATED TO DENTAL CARIES

- Dental Caries
- Primary Caries
- Recurrent Caries
- Residual Caries
- Active Carious Lesion
- Inactive/Arrested Carious Lesion
- Pits and Fissure Caries
- Smooth Surface Caries
- Root Caries
- Acute Dental Caries
- Rampant Caries
- Chronic Dental Caries

### NOMENCLATURE RELATED TO NONCARIOUS DEFECTS OF TEETH

- Attrition
- Abrasion
- Erosion
- Abfraction
- Resorption
- Localized Non-hereditary Enamel Hypoplasia
- Localized Non-hereditary Enamel Hypocalcification

Operative dentistry plays an important role in enhancing dental health and now branched into dental specialties. Today operative dentistry continues to be the most active component of most dental practice. Epidemiologically, demand for operative dentistry will not decrease in the future.

### DEFINITION OF OPERATIVE DENTISTRY

According to *Mosby's dental dictionary*. "Operative dentistry deals with the functional and esthetic restoration of the hard tissues of individual teeth."

According to *Sturdevant*, “Operative dentistry is defined as science and art of dentistry which deals with diagnosis, treatment and prognosis of defects of the teeth which do not require full coverage restorations for correction.”

Such corrections and restorations result in the restoration of proper tooth form, function and esthetics while maintaining the physiological integrity of the teeth in harmonious relationship with the adjacent hard and soft tissues. Such restorations enhance the dental and general health of the patient.

According to *Gilmore*, “Operative dentistry is a subject which includes diagnosis, prevention and treatment of problems and conditions of natural teeth vital or nonvital so as to preserve natural dentition and restore it to the best state of health, function and esthetics.”

*Definition of dental anatomy* or anatomy of teeth is the branch of anatomy which deals with the study of human teeth structures. It includes development, appearance and classification of teeth. Dental anatomy is also a taxonomical science; it is concerned with the naming of teeth and the structures of which they are made.

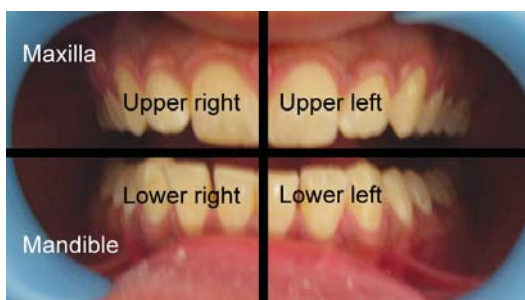For convenience human dentition is divided into four quadrants viz; upper (maxillary) right, upper (maxillary) left, lower (mandibular) right and lower (mandibular) left (**Fig. 2.1**). Right and left here relate to patient’s right and left side.

It is important to understand anatomy of teeth because of following reasons:

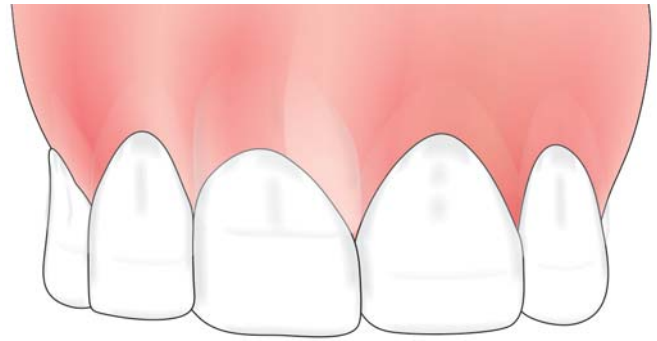- For maintenance of supporting tissues in the healthy state.
- For restoration of damaged tooth to its original form.
- For optimal functions of teeth.

## CLASSES OF HUMAN TEETH

Depending upon their form and function human teeth can be divided into following classes:



**Fig. 2.1:** Photograph showing division of whole dentition into four quadrants, i.e. upper right, upper left, lower right and lower left. Here right and left relate to patient’s right and left



**Fig. 2.2:** Maxillary central and lateral incisors

### Incisors

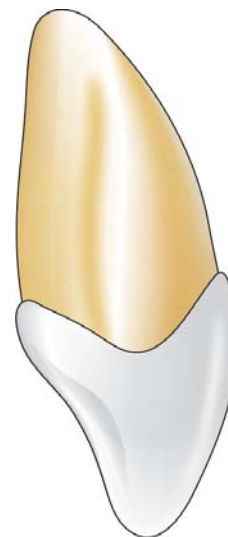
The square-shaped teeth located in front of the mouth, with four on the upper and four on the lower are called incisors. Incisors are important teeth for phonetics and esthetics. They help in cutting the food (**Fig. 2.2**).

### Canines

The sharp teeth located near the corner of the mouth. Because of their anatomy and long root, they are strong teeth. They help in tearing and cutting of food (**Fig. 2.3**).

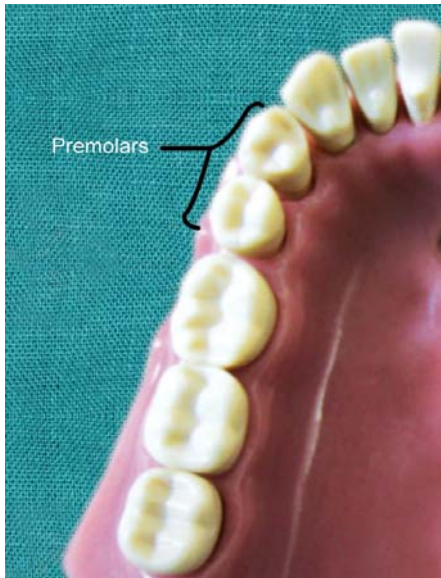
### Premolars

There are a total of eight premolars inside the mouth present after the canines. Four premolars are present in upper and lower arch, two on each side of the canine. Facially they resemble canines and lingually as molars (**Fig. 2.4**). They help in tearing and grinding of the food.



**Fig. 2.3:** Maxillary canine showing sharp tip and long root





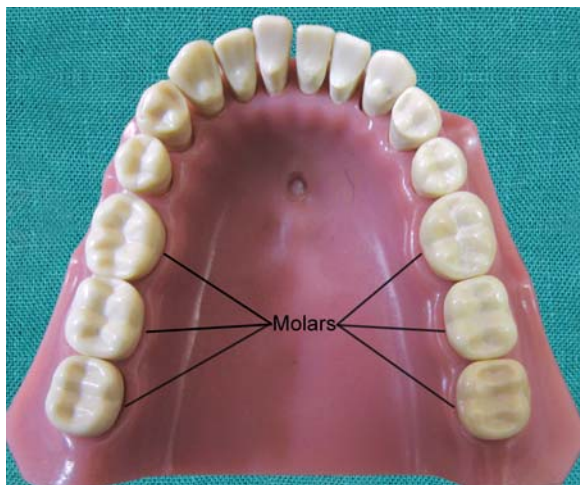
**Fig. 2.4:** Photograph showing premolars

### Molars (Fig. 2.5)

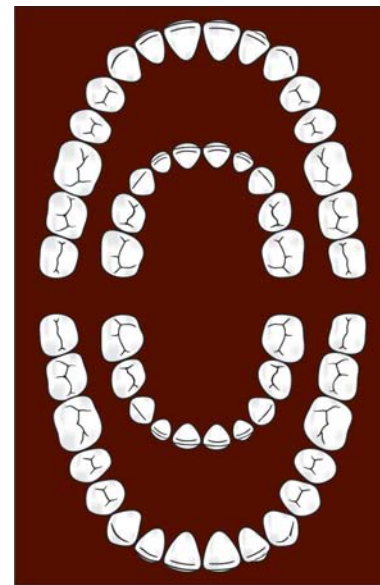
Distal to premolars are the molars. There are six molars on each arch (three on each side), therefore a total of 12 inside the mouth. They have multiple cusps which help in crushing and grinding the food. These teeth also help in maintenance of vertical height of the face.

### SETS OF TEETH

There are two sets of teeth that develop in a person's mouth (**Fig. 2.6**). The first set of teeth is called as "milk or baby" or "primary teeth". The total number of teeth in this set are twenty. Primary teeth erupt at the age between 6 months and 2 years. Most children develop all their primary teeth at the age of three.



**Fig. 2.5:** Photograph showing molars



**Fig. 2.6:** Figure showing two sets of teeth. The outer ring represents the permanent teeth. The inner ring represents the deciduous teeth

The second set of teeth, i.e. the permanent teeth erupt at the age of six. There are a total of 32 permanent teeth in an adult mouth. Total number of teeth are divided into two arches, i.e. an upper and a lower arch each found on the upper and lower jaws respectively. Normally, a total of 16 teeth may be found on each complete arch.

### TOOTH NUMBERING SYSTEMS

There are different tooth numbering systems for naming a specific tooth. The three most common systems are the FDI World Dental Federation notation, Universal numbering system and Zsigmondy-Palmer notation method. The FDI system is used worldwide and the universal is used widely in the USA.

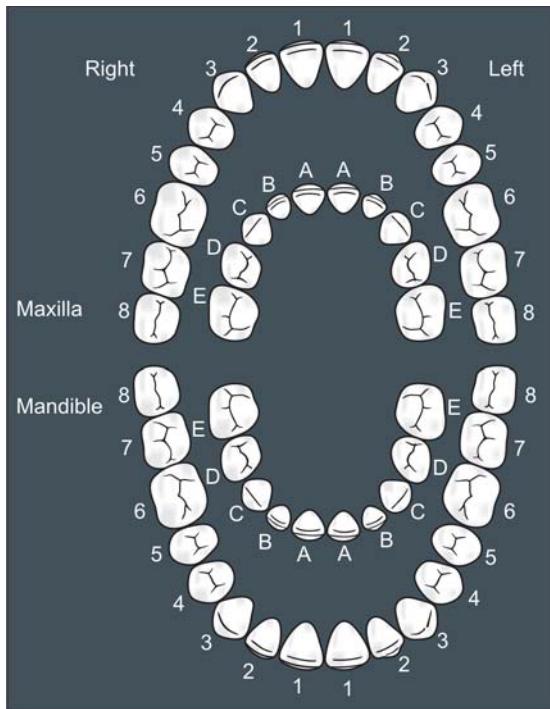
#### Most commonly used tooth numbering systems

1. Zsigmondy-Palmer system
2. Universal system (ADA system)
3. FDI system (Fédération Dentaire Internationale)

### Zsigmondy-Palmer System (Fig. 2.7)

It was originally termed as "Zsigmondy system" after the Austrian dentist Adolf Zsigmondy who developed the idea in 1861, using a Zsigmondy cross to record quadrants of tooth positions.

Adult teeth were numbered 1 to 8 and the primary dentition as Roman numerals I, II, III, IV, V from the midline. Palmer changed this to A, B, C, D, E. This makes it less confusing and less prone to errors in interpretation.



**Fig. 2.7:** Diagram showing presentation of Zsigmondy-Palmer notation of both deciduous and permanent dentitions

The Zsigmondy-Palmer notation consists of a symbol ( ) designating in which quadrant the tooth is found and a number indicating the position from the midline. Permanent teeth are numbered 1 to 8 and primary teeth are indicated by a letter A to E.

#### Advantages

- Simple and easy to use.
- Less chances of confusion between primary and permanent tooth as there is different notation, e.g. permanent teeth are described by numbers while primary teeth by alphabets.

#### Disadvantages

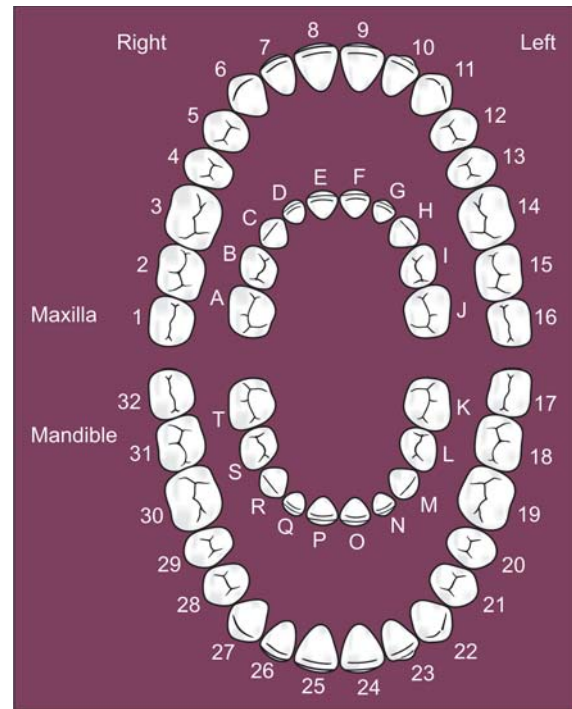
- Difficulty in communication.
- Confusion between upper and lower quadrants, while communication and transferring a data.

#### Features

- Introduced by "Zsigmondy" in 1861
- Each quadrant is designated by symbol
- Permanent teeth are numbered 1-8
- Primary teeth are indicated by A-E

#### Universal System

This system was given by American Dental Association in 1968. This system is most popular in the United States.



**Fig. 2.8:** Diagram showing presentation of universal system of tooth nomenclature for both deciduous and permanent teeth

The universal numbering system uses a unique letter or number for each tooth.

The universal/national system is represented as follows.

#### Permanent Teeth

For permanent teeth, 1 is the patient's upper right third molar and follows around the upper arch to the upper left third molar 16, descending to the lower left third molar 17 and follows around the lower arch to the lower right third molar (32) (**Fig. 2.8**).

In this system, the teeth that should be there are numbered. If wisdom tooth is missing the first number will be 2 instead of 1, acknowledging the missing tooth. If teeth have been extracted or teeth are missing, the missing teeth will be numbered as well.

In the original system, children's 20 primary teeth were numbered in the same order, except that a small letter "d" follows each number to indicate deciduous teeth. So, a child's first tooth on the upper right would be 1d and the last tooth on the lower right would be 20d.

#### Modified Version of Universal System Order for the Primary Dentition

It is denoted by English upper case letters A through T instead of number 1 to 20, with A being the patient's upper

right second primary molar and T being the lower right second primary molar, e.g.

B is maxillary right deciduous first molar

P is mandibular right deciduous central incisor

5 is maxillary right permanent first premolar

### Advantage

Unique letter or number for each tooth avoiding confusions.

### Disadvantage

Difficult to remember each letter or number of tooth.

#### Features

- Given by American Dental Association in 1968
- Use a unique number/letter for each tooth
- Permanent teeth are numbered 1-32 starting from upper right molar
- Deciduous teeth are designated as A-T, in this A is upper right second molar.

### FDI—Fédération Dentaire Internationale (Two-digit Notation)

This two-digit system was first introduced in 1971 which later on, was adopted by ADA (1996). This system is commonly practiced in European countries and Canada. Now it is gaining popularity in India also.

This system is known as two digit system because it uses a two-digit numbering system in which the first number represents a tooth's quadrant and the second number represents the number of the tooth from the midline of the face. Both digits should be pronounced separately while communication. For example, the lower left permanent second molar is 37; however, it is not said thirty-seven, but rather three seven.

#### Permanent Teeth (Fig. 2.9)

In the FDI (Fédération Dentaire Internationale) notation 1s are central incisors, 2s are laterals, 3s are canines, 4s are 1st premolars, 5s are 2nd premolars, 6s are the 1st molar, etc. up through 8s which are 3rd molars. The permanent teeth quadrants are designated 1 to 4 such that 1 is upper right, 2 is upper left, 3 is lower left and 4 is lower right, with the resulting tooth identification a two-digit combination of the quadrant and tooth (e.g. the upper right canine is 13 and the left is 23) (Figs 2.10 and 2.11).

#### Deciduous Teeth

In the deciduous dentition the numbering is correspondingly similar except that the quadrants are designated 5, 6, 7 and

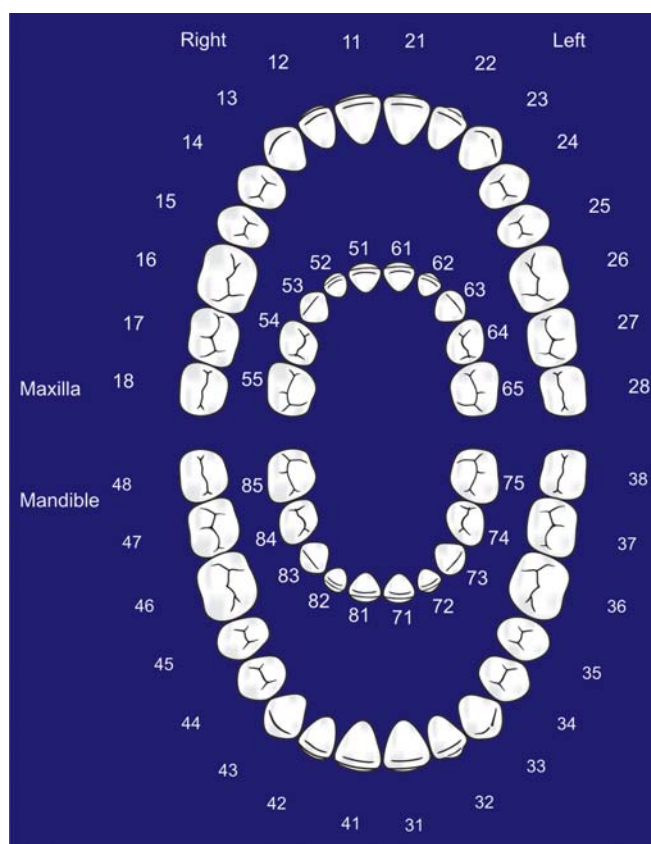


Fig. 2.9: Diagram showing presentation of FDI system of tooth nomenclature for permanent and primary teeth

8. Teeth are numbered from number 1 to 5, 1 being central incisor and 5 is second molar.

#### Advantages

- Simple to understand
- Simple to teach

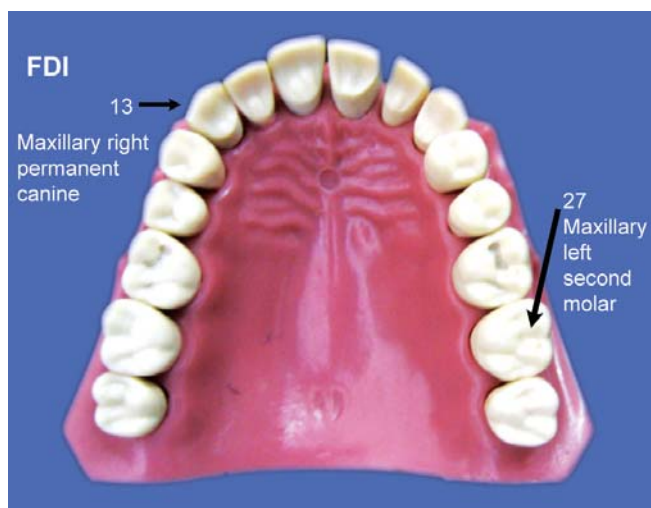
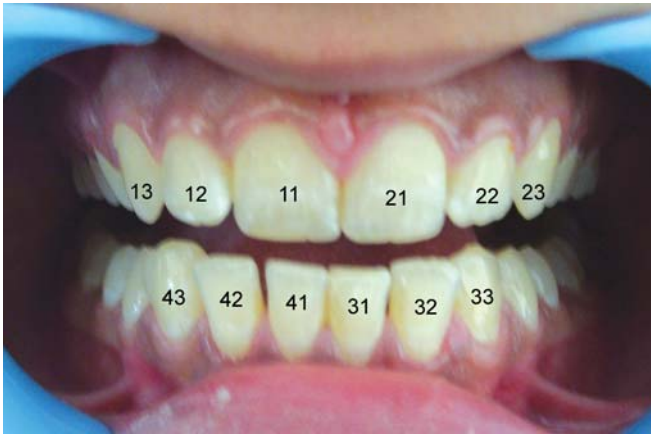

Fig. 2.10: Diagrammatic presentation of FDI notation of maxillary right canine and left second molar



**Fig. 2.11:** FDI system of permanent teeth

- Simple to pronounce
- No confusion
- Each tooth has specific number
- Easy to record on computers
- Easy for charting.

**Disadvantage**

May be confused with universal tooth numbering system.

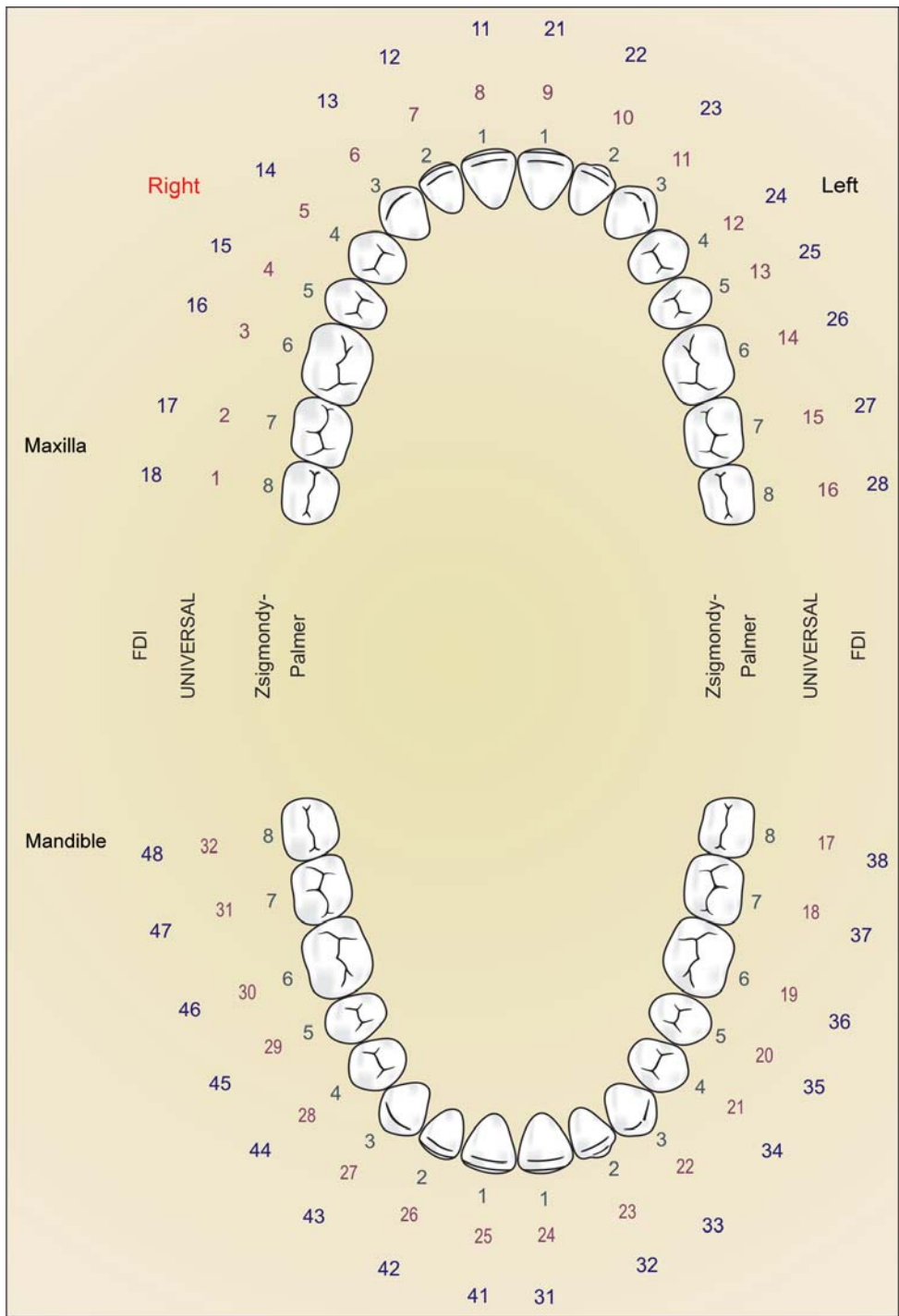
**Features**

- Introduced in 1971
- Also known as two-digit notation
- In two-digit system, first number represents tooth's quadrant while second number—number of tooth from midline
- Permanent right central incisor is designated as 11
- Deciduous right central incisor is designated as 51.

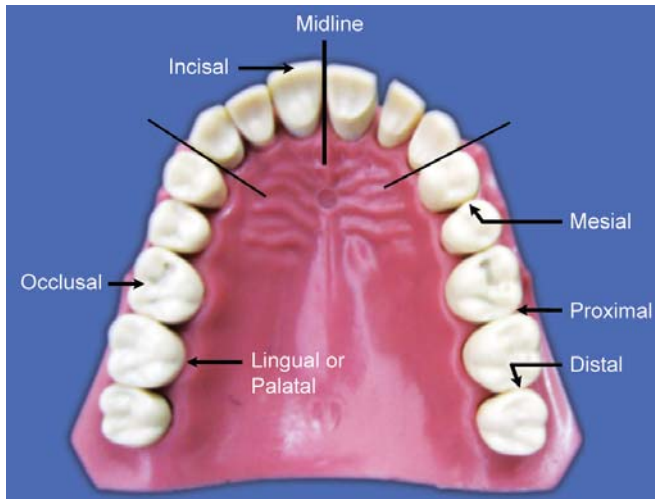
**Comparison of Tooth Numbering Systems**

As a result, any given tooth has three different ways to identify it, depending on which notation system is used (**Fig. 2.12**). The permanent left maxillary central incisor is identified by the number “9” in the universal system. In the FDI system, the same tooth is identified by the number “21”. The Palmer system uses the number and symbol, L1, to identify the tooth. Further confusion may result if a number is given on a tooth without assuming a common notation method. Since, the number, “21”, may signify the permanent left mandibular first premolar in the universal system or the permanent left maxillary central incisor in the FDI system, the notation being used must be clear to prevent confusion.

Permanent Teeth															
<b>Zsigmondy-Palmer Notation</b>															
8	7	6	5	4	3	2	1	1	2	3	4	5	6	7	8
8	7	6	5	4	3	2	1	1	2	3	4	5	6	7	8
<b>Universal Numbering System</b>															
				<b>Upper right</b>								<b>Upper left</b>			
1	2	3	4	5	6	7	8	9	10	11	12	13	14	15	16
32	31	30	29	28	27	26	25	24	23	22	21	20	19	18	17
				<b>Lower right</b>								<b>Lower left</b>			
<b>FDI Two-digit Notation</b>															
18	17	16	15	14	13	12	11	21	22	23	24	25	26	27	28
48	47	46	45	44	43	42	41	31	32	33	34	35	36	37	38
Deciduous Teeth															
<b>Palmer Notation</b>															
			E	D	C	B	A	A	B	C	D	E			
			E	D	C	B	A	A	B	C	D	E			
<b>Universal Numbering System</b>															
				<b>Upper right</b>								<b>Upper left</b>			
			A	B	C	D	E	F	G	H	I	J			
			T	S	R	Q	P	O	N	M	L	K			
				<b>Lower right</b>								<b>Lower left</b>			
<b>FDI Two-digit Notation</b>															
			55	54	53	52	51	61	62	63	64	65			
			85	84	83	82	81	71	72	73	74	75			



**Fig. 2.12:** Diagram showing all nomenclature (All systems)  
 First row describes—Zsigmondy-Palmer  
 Second row describes—Universal  
 Third row describes—FDI



**Fig. 2.13:** Diagrammatic representation of different surfaces of teeth

## NOMENCLATURE OF TOOTH SURFACES

Coronal portion of each tooth is divided into surfaces that are designated according to their related anatomic structures and landmarks (**Fig. 2.13**).

### Buccal

Tooth surface facing the cheek.

### Labial

Tooth surface facing the lip.

### Facial

Labial and buccal surface collectively form facial surface.

### Mesial

Tooth surface toward the anterior midline.

### Distal

Tooth surface away from the anterior midline.

### Lingual

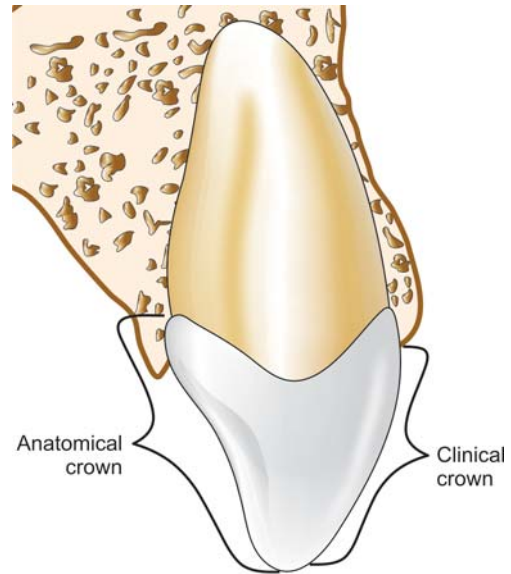
Tooth surface towards the tongue.

### Occlusal

Masticating surface of posterior teeth (in molar or premolar).

### Incisal

Functioning/cutting edge of anterior tooth (in incisors and cuspids).



**Fig. 2.14:** Anatomical crown and clinical crown

### Gingival

Tooth surface near to gingiva.

### Cervical

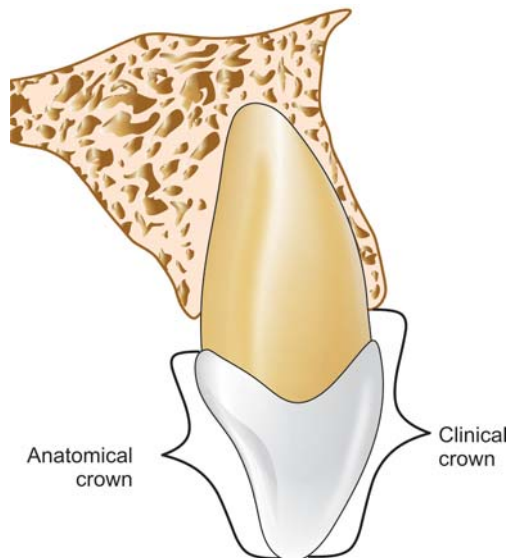
Tooth surface near the cervix or neck of tooth.

### Anatomic Crown

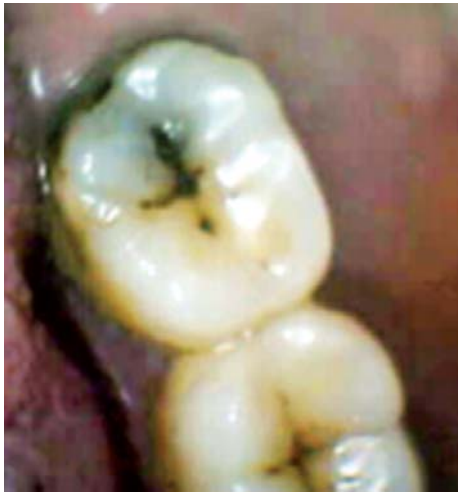It is part of tooth that is covered with enamel (**Fig. 2.14**).

### Clinical Crown

It is part of tooth that is visible in oral cavity (**Fig. 2.14**). In case of gingival recession, clinical crown is longer than anatomical crown (**Fig. 2.15**).



**Fig. 2.15:** When there is gingival recession, clinical crown is more than anatomical crown



**Fig. 2.16:** Photograph showing dental caries

## NOMENCLATURE RELATED TO DENTAL CARIES

### Dental Caries

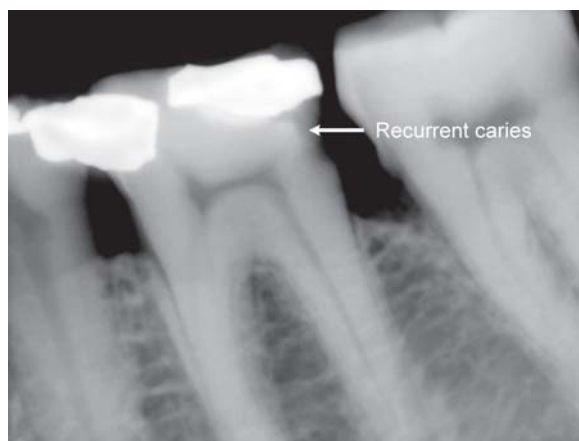
It is defined as a microbiological disease of the hard structure of teeth, which results in localized demineralization of the inorganic portion and destruction of the organic substances of the tooth (**Fig. 2.16**).

### Primary Caries

It denotes lesions on unrestored surfaces.

### Recurrent Caries

Lesions developing adjacent or beneath the restorations are referred to as either recurrent or secondary caries (**Fig. 2.17**).



**Fig. 2.17:** Radiograph showing recurrent caries

### Residual Caries

It is demineralized tissue left in place before a restoration is placed. It can occur by clinician's neglect or intentionally.

### Active Carious Lesion

A progressive lesion is described as an active carious lesion.

### Inactive/Arrested Carious Lesion

A lesion that may have formed earlier and then stopped is referred to as an arrested or inactive carious lesion. Arrested carious lesion is characterized by a large open preparation which no longer retains food and becomes self-cleansing.

### Pits and Fissure Caries

Pit and fissure caries are the caries which occur on occlusal surface of posterior teeth and buccal and lingual surfaces of molars and on lingual surface of maxillary incisors (**Fig. 2.18**).

### Smooth Surface Caries

Smooth surface caries occurs on gingival third of buccal and lingual surfaces and on proximal surfaces (**Fig. 2.19**).

### Root Caries

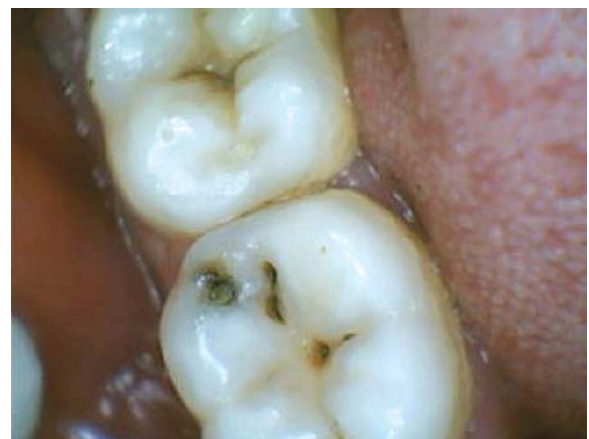Root caries occur on exposed root cementum and dentin usually following gingival recession.

### Acute Dental Caries

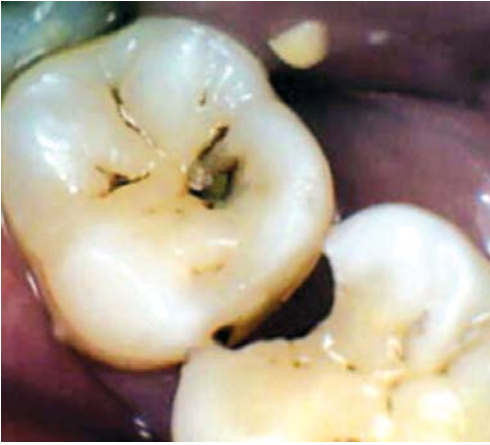Acute caries travels towards the pulp at a very fast speed.

### Rampant Caries

It is the name given to multiple active carious lesions occurring in the same patient, frequently involving surfaces



**Fig. 2.18:** Pit and fissure caries



**Fig. 2.19:** Smooth surface caries

of teeth that are usually caries-free. Rampant caries is of following three types:

- *Early childhood caries* is a term used to describe dental caries presenting in the primary dentition of young children.
- *Bottle caries or nursing caries* are seen in the primary dentition of infants and young children. The clinical pattern is characteristic, with the four maxillary deciduous incisors most severely affected.
- *Xerostomia induced rampant caries* are commonly seen after radiotherapy of malignant areas because of reduced salivary flow.

### Chronic Dental Caries

Chronic caries progresses very slowly towards the pulp. They appear dark in color and hard in consistency.

## NOMENCLATURE RELATED TO NONCARIOUS DEFECTS OF TEETH

### Attrition

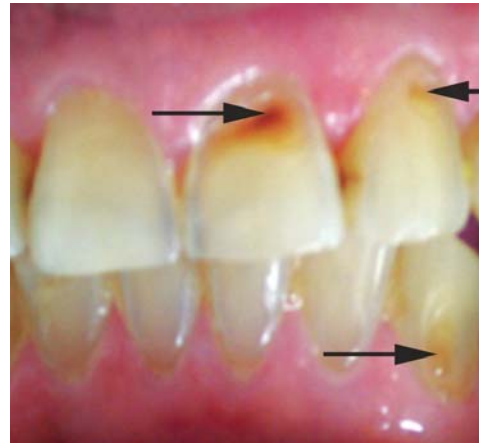It is defined as a physiological, continuous, process resulting in loss of tooth structure from direct frictional forces between contacting teeth. It occurs both on occlusal and proximal surfaces. Attrition is accelerated by parafunctional mandibular movements, especially bruxism.

### Abrasion

It refers to the loss of tooth substance induced by mechanical wear other than that of mastication. Abrasion results in saucer-shaped or wedge-shaped indentations with a smooth, shiny surface (**Fig. 2.20**).

### Erosion

It can be defined as a loss of tooth substance by a chemical process that does not involve known bacterial action. The eroded area appears smooth, hard and polished.



**Fig. 2.20:** Photograph showing abrasion cavities

### Abfraction

Abfractions are the microfractures which appear in the enamel as cervical area of tooth flexes under heavy loads. Abfraction lesion appears as a wedge shaped defect with sharp line angles.

### Resorption

Resorption is defined as “a condition associated with either a physiologic or a pathologic process resulting in the loss of dentin, cementum or bone.”

If resorption occurs, it is because of some pathologic reasons but deciduous teeth show physiologic resorption before they are shed off.

### Localized Non-hereditary Enamel Hypoplasia

It refers to the localized defects in the crown portion of tooth caused due to injury to ameloblasts during the enamel matrix formative stage. These lesions may appear as isolated pits or widespread linear defects, depressions or loss of a part of enamel. Injury to ameloblasts may be caused by the following:

- Traumatic intrusion of deciduous teeth.
- Fluorosis.
- Exanthematous diseases.
- Deficiency of vitamins A, C and D.
- Hypocalcemia.

### Localized Non-hereditary Enamel Hypocalcification

It refers to the localized defects in crown portion of tooth due to injury caused to the ameloblasts during mineralization stage. In these, the enamel is normal in structure but its mineralization is defective. The color of lesion changes fast from chalky to yellow, brown, dark brown or grayish.



## VIVA QUESTIONS

---

**Q. What do you mean by nomenclature?**

**Ans.** Nomenclature means the system of naming things. It is helpful for clarity of thought, communication and better understanding.

**Q. What are different tooth numbering systems?**

**Q. What is Zsigmondy-Palmer system?**

**Q. What are advantages and disadvantages of ZPS?**

**Q. What is ADA/Universal system of tooth numbering?**

**Q. What are advantages and disadvantages of ADA system?**

**Q. What is FDI system of tooth numbering?**

**Q. What are advantages and disadvantages of FDI system?**

**Q. What are different surfaces of teeth?**

**Q. Does nomenclature (like mesial or distal) change if tooth is rotated?**

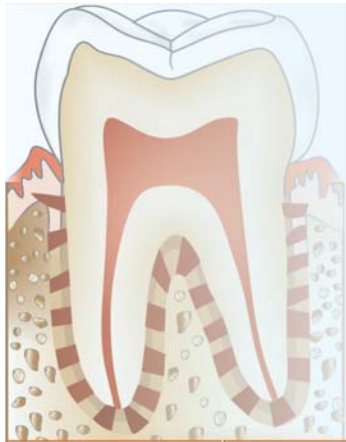**Ans.** No, nomenclature does not change even in rotated tooth.

**Q. Define clinical crown?**

**Q. What is anatomical crown?**

**Q. What are different noncarious defects of teeth?**

**Q. What is mesial and distal surface?**



## Structure of Teeth

### Chapter 3

#### ENAMEL

- Composition
- Structure
- Thickness
- Color
- Strength
- Structure Present in Enamel
- Functions of Enamel
- Clinical Significance of Enamel

#### DENTIN

- Composition
- Color
- Thickness
- Hardness
- Structure of Dentin

- Difference between Enamel and Dentin
- Difference between Primary, Secondary and Reparative/ Tertiary Dentin
- Clinical Considerations of Dentin

#### DENTAL PULP

- Histology of Dental Pulp
- Structural or Cellular Elements
- Extracellular Components
- Anatomy of Dental Pulp
- Functions of Pulp
- Age Changes in Pulp

#### PERIRADICULAR TISSUE

- Cementum
- Periodontal Ligament
- Alveolar Bone

Good knowledge of dental anatomy, histology, physiology and occlusion is the foundation stone of operative dentistry. In other words, thorough knowledge of morphology, dental anatomy, histology, is essential to get optimal results of operative dentistry. Though the dental tissues are passive, the occurrence of caries can only be understood when the structure of the teeth is understood.

The teeth consist of enamel, dentin, pulp and cementum (Fig. 3.1).

#### ENAMEL

Tooth enamel is the hardest and most highly mineralized substance of the body which covers the crown of the tooth. It is the normally visible dental tissue of a tooth which is mainly responsible for color, esthetics, texture and translucency of the tooth. One of the main goal in operative dentistry is preservation of enamel. So today's dentistry

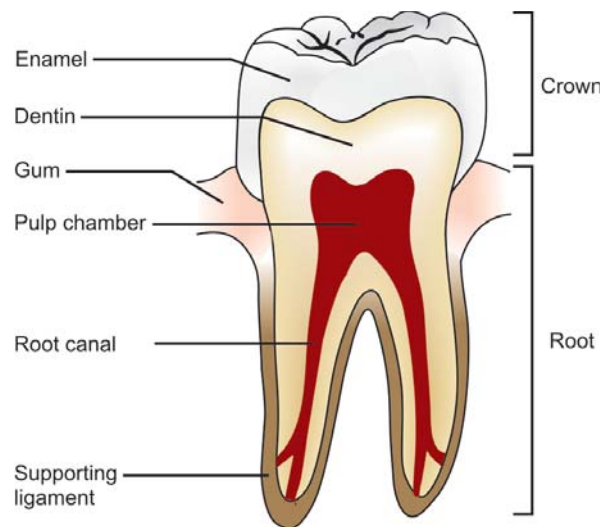


Fig. 3.1: Diagrammatic representation of enamel, dentin, pulp and supporting structures

mainly revolves around simulating natural enamel in its color, esthetics, contours and translucency by replacing with synthetic restorative materials.

Although enamel can serve lifelong, but it is more susceptible to caries, attrition (physical forces) and fracture due to its structural make up, i.e. mineralized crystalline structure and rigidity. One of the interesting features of enamel is that it cannot repair itself. So, loss in enamel surface can be compensated only by restorative treatment.

### Composition

It is highly mineralized structure which mainly contains inorganic contents in the form of crystalline structure. Main inorganic content in the enamel is hydroxyapatite. In addition to inorganic content, it also contains a small portion of organic matrix along with small amount of water which is present in intercrystalline spaces.

#### Composition

1. Inorganic content (by vol.)
  - a. Hydroxyapatite—90-92%
  - b. Other minerals and trace elements—3-5%

#### Organic content (by vol.)

1. Proteins and lipids—1-2%
2. Water—4%

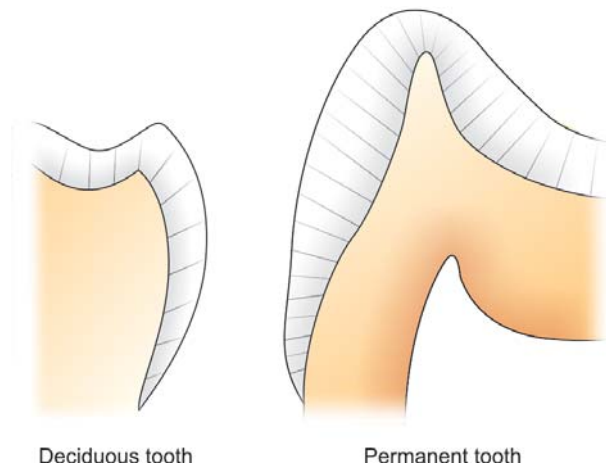
### Structure

Enamel is mainly composed of millions of enamel rods or prisms as well as sheaths and a cementing inter rod substance. Each rod has a head and tail. The head is directed occlusally and the tail is directed cervically. The rod is formed of number of hydroxyapatite crystals which vary in size, shape and number. Each rod formed of about 300 unit crystal length and 40 units wide and 20 unit thick in three-dimensional hexagon. In transverse sections, enamel rods appear as hexagonal and occasionally round or oval. Rods may also resemble fish scales.

The diameter of rods increases from dentinoenamel junction towards the outer surface of enamel in a ratio of 1:2.

The rods or the prisms run in an alternating course of clockwise and anticlockwise direction (twisting course). Initially there is wavy course in one-third of enamel thickness adjacent to DEJ, then the course becomes more straight in the remaining thickness.

Enamel rods are arranged in such planes so as to resist the maximum masticatory forces. Rods are oriented at perpendicular to the dentinoenamel junction. Towards the incisal edge these become increasingly oblique and are almost



**Fig. 3.2:** Diagram showing direction of enamel rods in deciduous and permanent teeth

vertical at the cusp tips. In the cervical region, there is difference in the direction of the enamel rods of deciduous and permanent teeth (**Fig. 3.2**). The cervical enamel rods of deciduous teeth are inclined incisally or occlusally, while in permanent teeth they are inclined apically. This change in direction of enamel rods should be kept in mind during tooth preparation so as to avoid unsupported enamel rods.

#### Structure

- Composed of millions of rods or prisms
- Diameter of enamel rod increases from dentinoenamel junction towards outer surface of enamel in 1:2
- Enamel rods lie perpendicular to dentinoenamel junction
- In cervical region, direction of enamel rod is incisally/occlusally in deciduous while in permanent, it is apically.

### Thickness

The thickness of enamel varies in different areas of the same tooth and from one type of tooth to another type of tooth. The average thickness of enamel at the incisal edges of incisors is 2 mm; at the cusp of premolar and molar from 2.3 to 3.0 mm. Thickness of enamel decreases gradually from cusps or incisal edges to cementsoenamel junction.

#### Thickness of enamel

Tooth type	Thickness
Anterior tooth-incisal edges	2.0 mm
Premolar tooth-cusp	2.3-2.5 mm
Molar tooth-cusp	2.5-3.0 mm

## Color

The color of enamel is usually gray and translucent in nature. Color of tooth mainly depends upon three factors: (a) color of underlying dentin, (b) thickness of enamel, (c) amount of stains in enamel. The translucency of enamel is directly related to degree of mineralization and homogeneity. Anomalies occurring during developmental and mineralization stage, antibiotic usage and excess fluoride intake affect the color of tooth.

### Color of enamel is affected by

- Color of underlying dentin
- Thickness of enamel
- Amount of stains in enamel
- Anomalies occurring during developmental and mineralization stage like antibiotic usage and excess fluoride intake affects the color.

## Strength

Enamel has a rigid structure. It is brittle, has a high modulus of elasticity and low tensile strength. The specific gravity of enamel is 2.8. Hardness of enamel is different in different areas of the external surface of a tooth. The hardness also decreases from outer surface of the enamel to its inner surface. Also the density of enamel increases from dentino-enamel junction to the outer surface. When compared, dentin has high compressive strength than the enamel, this acts as a cushion for enamel when masticatory forces are applied on it. For this reason during tooth preparation, for maximal strength of underlying remaining tooth structure all enamel rods should be supported by healthy dentin base.

### Structure present in enamel

1. Gnarled enamel
2. Bands of Hunter-Schreger
3. Enamel tufts
4. Enamel lamellae
5. Enamel spindles
6. Striae of Retzius
7. Prismless layer
8. Dentinoenamel junction
9. Occlusal pits and fissures.

## Structure Present in Enamel (Fig. 3.3)

### Gnarled Enamel

There are group of irregular enamel that is more resistant to cleavage called Gnarled enamel present mostly in cervical, incisal and occlusal portion. This consists of bundles of enamel rods which intertwine in an irregular manner with

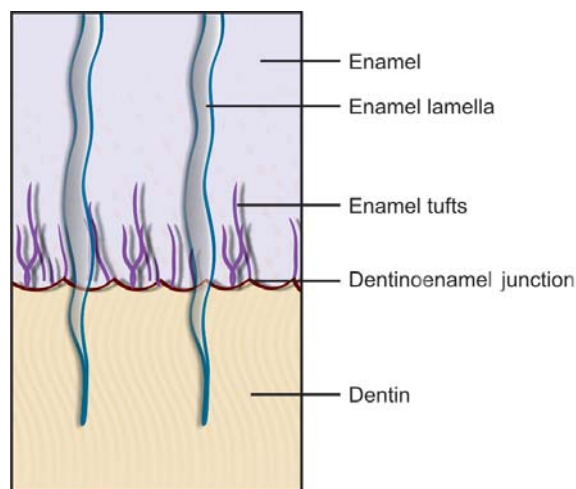


Fig. 3.3: Diagram showing different structures present in enamel

other group of rods, finally taking a twisted and irregular path towards the tooth surface.

**Significance:** This part of enamel is resistant to cutting while tooth preparation.

### Bands of Hunter-Schreger

Hunter-Schreger bands usually occur because of alteration of light reflection (optical phenomenon) due to changes in rod direction. This results in alternating light and dark zones under the microscope. It is best seen in longitudinal ground sections seen under reflected light. They are mainly found in the inner surface of tooth. H-S bands are composed of different contents of organic material and varied permeability.

**Significance:** They are considered to resist and disperse the strong forces.

### Enamel Tufts

Enamel tufts are ribbon-like structures which run from dentin to enamel. They are named so because they resemble tufts of grass. They contain greater concentration of enamel proteins.

**Significance:** Hypomineralized structure in the enamel, thus it plays role in spread of dental infection.

### Enamel Lamellae

These are leaf like defects present in enamel and may extend to DEJ. They contain organic substances. Lamellae are commonly found at the base of occlusal pits and fissures. Bodecker in 1906 was the first to describe these developmental defects of enamel which he named "lamellae".

These are caused by “imperfect calcification of enamel tissue”.

Pincus suggested that if developing cusps fail to coalesce when forming a fissure, a gap in the enamel occurs. Such a gap may vary in size from a crack or lamella.

Three types of lamellae are commonly seen:

- Type A composed of “poorly calcified rod segments”
- Type B composed of degenerated cells
- Type C arising after eruption where the crack is filled with mucoproteins from the oral preparation.

Type A lamellae is confined to enamel while types B and C may extend into dentin.

Various studies have shown that lamellae might be the site of entry of caries.

Ten Cate stated that tufts and lamellae are of no significance and do not appear to be sites of increased vulnerability to caries attack.

A lamella at the base of an occlusal fissure provides an appropriate pathway for bacteria and initiate caries.

### Enamel Spindles

Odontoblastic processes sometimes crosses DEJ and their end is thickened. Spindles serve as pain receptors, that is why, when we cut in the enamel patient complains of pain.

### Striae of Retzius

They appear as brownish bands in the ground sections and illustrate the incremental pattern of enamel. These represent the rest periods of ameloblast during enamel formation, therefore also called as growth circles. When these circles are incomplete at the enamel surface, it results in alternating grooves called imbrications lines of pickerills, the elevations in between called perikymata. Perikymata are shallow furrows where the striae of Retzius end. These are continuous around the tooth and parallel the CEJ.

Striae of Retzius are stripes that appear on enamel when viewed microscopically in cross-section. Formed from changes in diameter of “Tomes” processes, these stripes demonstrate the growth of enamel, similar to the annual rings on a tree.

### Prismless Layer

There is structureless layer of enamel near the cervical line and to a lesser extent on the cusp tip which is more mineralized.

### Dentinoenamel Junction

Dentinoenamel junction is pitted/scalloped in which crests are toward enamel and shallow depressions are in dentin.

This helps in better interlocking between enamel and dentin. This is a hypermineralized zone and is about 30 microns thick.

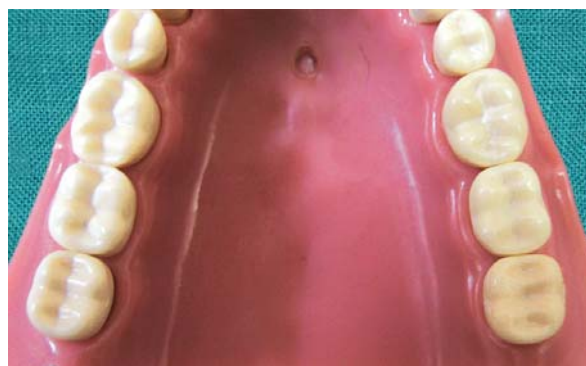**Significance:** Shape and nature of the dentinoenamel junction prevents tearing of enamel during functions.

### Occlusal Pits and Fissures

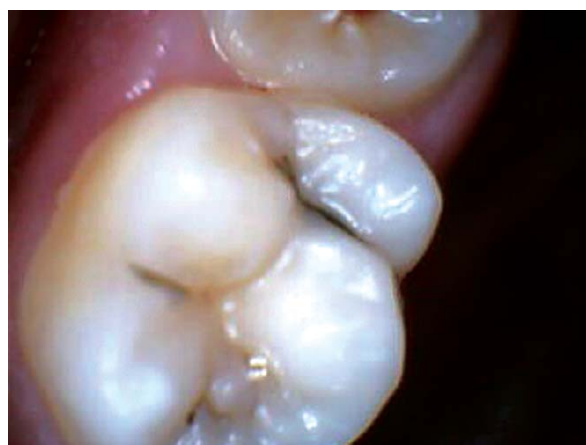Pits and fissures are formed by faulty coalescence of developmental lobes of premolars and molars (**Fig. 3.4**). These are commonly seen on occlusal surfaces of premolars and molars. These are formed at the junction of the developmental lobes of the enamel organs. Grooves are developed by smooth coalescence of developmental lobes.

### Significance:

- Thickness of enamel at the base of pit and fissure is less.
- Pits and fissures are the areas of food and bacteria impaction which make them caries prone (**Fig. 3.5**).
- V-shaped grooves provide escapement of food when cusps of teeth of opposite arch occlude during mastication.



**Fig. 3.4:** Showing pits and fissures of premolars and molars



**Fig. 3.5:** Deep pits and fissures making areas favorable for food impaction

## Functions of Enamel

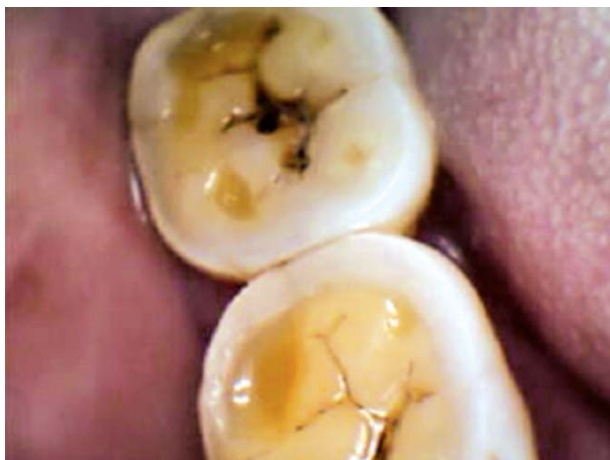1. It is hardest structure of tooth which supports masticatory forces.
2. It is mainly responsible for color, esthetics, surface texture and translucency of the tooth.
3. It also supports the underlying dentin and pulp.

### Functions of enamel

- Hardest structure of tooth supporting the masticatory forces
- Responsible for color and esthetics
- Responsible for surface texture and translucency of tooth
- Support underlying dentin and pulp

## Clinical Significance of Enamel

- **Color:** Color of the enamel varies because of following factors:
  - Age
  - Ingestion of tetracycline during the formative stages
  - Ingestion of fluoride
  - Extrinsic stains
  - Developmental defects of tooth.
- **Attrition:** The change usually seen in enamel with age due to wear of occlusal surfaces and proximal contact points during mastication. Sometimes bruxism or contacts with porcelain also lead to attrition (**Fig. 3.6**). So, in these patients, try to avoid placing the margins of restoration in occlusal contact area or place a restorative material that wears at a same rate as enamel.
- **Acid etching:** Acid etching is used in fissure sealants and bonding of restorative material to enamel. Acid etching has been considered as accepted procedure for improving the bonding between resin and enamel. Acid



**Fig. 3.6:** Attrition of teeth

etching causes preferential dissolution of enamel surface and helps in increasing the bonding between resin and enamel.

- **Permeability:** Enamel has been considered to be permeable to some ions and molecules. Hypomineralized areas present in the enamel are more permeable than mineralized area. So, these hypomineralized areas are more sensitive to dental caries.
- Defective surfaces like hypoplastic areas, pits and fissures are at more risk for dental caries.
- Cracks present on the enamel surface sometimes lead to pulpal death and fracture of tooth.
- To avoid fracture of tooth and restoration, enamel walls should be supported by underlying dentin. Also the preparation walls should be made parallel to direction of enamel rods since enamel rod boundaries are natural cleavage lines through which fracture can occur.
- **Remineralization:** Remineralization is only because of enamel's permeability to fluoride, calcium and phosphate (available from saliva or other sources).

## DENTIN

Dentin, the most voluminous mineralized connective tissue of the tooth, forms the hard tissue portion of the dentin-pulp complex, whereas the dental pulp is the living, soft connective tissue that retains the vitality of dentin. Enamel covers the dentin in crown portion while cementum covers the dentin in root portion. Dentin contains closely packed dentinal tubules in which the dentinal fluid and the cytoplasmic processes of the odontoblasts, are located. Hence, dentin and bone are considered as vital tissues because both contain living protoplasm. Dentin is type of specialized connective tissue which is mesodermal in origin, formed from dental papilla.

The unity of dentin-pulp is responsible for dentin formation and protection of the tooth.

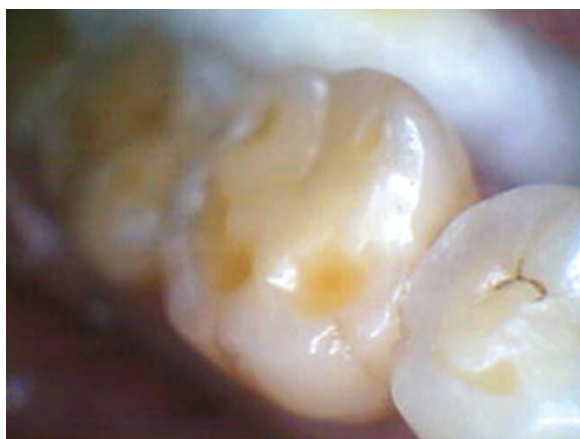## Composition

Dentin contains 70% inorganic hydroxyapatite crystals and the rest is organic substance and water making it more resilient than enamel.

The organic components consist primarily of collagen type 1.

### Composition (by wt.)

Inorganic material	70%
Organic material	20%
Water	10%



**Fig. 3.7:** Photograph showing dark colored dentin because of irritants

### Color

The color of dentin is slightly darker than enamel and is generally light yellowish in young individuals while it becomes darker with age. On constant exposure to oral fluids and other irritants, the color becomes light brown or black (**Fig. 3.7**).

### Thickness

Dentin thickness is usually more on the cuspal heights and incisal edges and less in the cervical areas of tooth. It is around 3-3.5 mm on the coronal surface. With advancing age and various irritants, the thickness of secondary and tertiary dentin increases.

### Hardness

The hardness of dentin is one-fifth that of enamel. Hardness is not the same in all its thickness. Its hardness at the DEJ is 3 times more than that near the pulp so it is important to keep the depth of preparation near the DEJ. Hardness of dentin also increases with advancing age due to mineralization. Compressive hardness is about 266 MPa. The modulus of elasticity is about  $1.67 \times 10^6$  Psi. As the modulus of elasticity of dentin is low, so it indicates dentin is flexible in nature. The flexibility of dentin provides support or cushion to the brittle enamel. The tensile strength of dentin is 40-60 MPa. It is approximately one-half of that of enamel.

#### Hardness of dentin

- One-fifth of enamel
- Compressive hardness is 266 MPa
- Tensile strength—40-60 MPa
- Hardness increases with age.

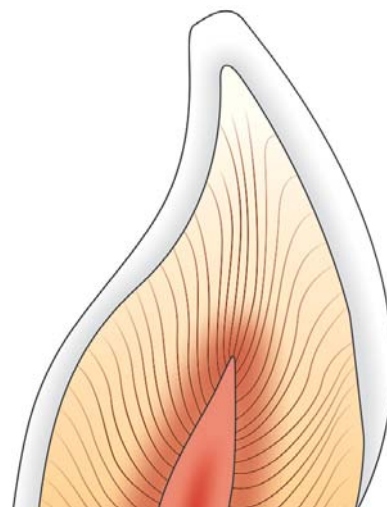
## Structure of Dentin

### Structure of dentin

1. Dentinal tubules
2. Predentin
3. Peritubular dentin
4. Intertubular dentin
5. Primary dentin
  - a. Mantle
  - b. Circumpulpal
6. Secondary dentin
7. Reparative dentin
8. Sclerotic dentin

### Dentinal Tubules (Table 3.1)

The dentinal tubules follow a gentle “S”-shaped curve in the tooth crown and are straighter in the incisal edges, cusps and root areas. The ends of the tubules are perpendicular to dentinoenamel and dentinocemental junctions (**Fig. 3.8**). The dentinal tubules have lateral branches throughout the dentin, which are termed as canaliculi or microtubules. Each dentinal tubule is lined with a layer of peritubular dentin, which is much more mineralized than the surrounding intertubular dentin. Number of dentinal tubules increase from 15,000-



**Fig. 3.8:** Diagram showing course of dentinal tubules

**Table 3.1:** Dentinal tubules

	Pulp	DEJ
Diameter	2-3 $\mu\text{m}$	0.5-0.9 $\mu\text{m}$
Numbers	45,000-65,000/mm <sup>2</sup>	15,000-20,000/mm <sup>2</sup>

20,000/mm<sup>2</sup> at DEJ to 45,000-65,000/mm<sup>2</sup> toward the pulp. Dentinal tubules may extend from the odontoblastic layer to the dentinoenamel junction and give high permeability to the dentin. In addition to an odontoblast process, the tubule contains dentinal fluid, a complex mixture of proteins such as albumin, transferrin, tenascin and proteoglycans.

### *Predentin*

The predentin is 10-30  $\mu$ m unmineralized zone between the mineralized dentin and odontoblasts.

This layer of dentin, lie very close to the pulp tissue which is just next to cell bodies of odontoblasts. It is first formed dentin and is not mineralized.

### *Peritubular Dentin*

This dentinal layer usually lines the dentinal tubules and is more mineralized than intertubular dentin and predentin.

### *Intertubular Dentin*

This dentin is present between the tubules which is less mineralized than peritubular dentin. Intertubular dentin determines the elasticity of the dental matrix.

### *Primary Dentin*

This type of dentin is formed before root completion, gives initial shape of the tooth. It continues to grow till 3 years after tooth eruption.

1. ***Mantle dentin:*** At the outermost layer of the primary dentin, just under the enamel, a narrow zone called mantle dentin exists. It is formed as a result of initial mineralization reaction by newly differentiated odontoblasts. In other words, it is first formed dentin in the crown underlying the dentinoenamel junction.
2. ***Circumpulpal dentin:*** It forms the remaining primary dentin and is more mineralized than mantle dentin. This dentin outlines the pulp chamber and therefore, it may be referred to as circumpulpal dentin. It is formed before root completion.

### *Secondary Dentin*

*Secondary dentin* is formed after completion of root formation. In this, the direction of tubules is more asymmetrical and complicated as compared to primary

dentin. Secondary dentin forms at a slower rate than primary dentin.

### *Reparative Dentin/Tertiary Dentin*

Tertiary dentin frequently formed as a response to external stimuli such as dental caries, attrition and trauma. If the injury is severe and causes odontoblast cell death, odontoblast like cells synthesize specific reparative dentin just beneath the site of injury to protect pulp tissue. The secondary odontoblasts which produce reparative dentin are developed from undifferentiating mesenchymal cells of pulp. Unlike physiological dentin, reparative dentin is irregular, with cellular inclusions. Also the tubular pattern of the reparative dentin ranges from a irregular to an atubular nature. Reparative dentin matrix has decreased permeability, therefore helping in prevention of diffusion of noxious agents from the tubules.

### *Sclerotic Dentin*

It occurs due to aging or chronic and mild irritation (such as slowly advancing caries) which causes a change in the composition of the primary dentin. In sclerotic dentin, peritubular dentin becomes wider due to deposition of calcified materials, which progress from enamel to pulp. This area becomes harder, denser, less sensitive and more protective of pulp against irritations.

***Physiologic sclerotic dentin:*** Sclerotic dentin occurs due to aging.

***Reactive sclerotic dentin:*** Reactive sclerotic dentin occurs due to irritants.

***Eburnated dentin:*** It is type of reactive sclerotic dentin which is formed due to destruction by slow caries process or mild chronic irritation and results in hard, darkened cleanable surface on outward portion of reactive dentin.

### *Dead Tracts*

This type of dentin usually results due to moderate type of stimuli such as moderate rate caries or attrition. In this case, both affected and associated odontoblasts die, resulting in empty dental tubules which appear black when ground sections of dentin are viewed under transmitted light. These are called dead tracts due to appearance of black under transmitted light.



## Difference between Enamel and Dentin

	<i>Enamel</i>	<i>Dentin</i>
Color	Whitish blue or white gray	Yellowish white or slightly darker than enamel
Sound	Sharp, high pitched sound on moving fine explorer tip	Dull or low pitched sound on moving fine explorer tip
Hardness	Hardest structure of the tooth	Softer than enamel
Reflectance	More shiny surface and reflective to light than dentin	Dull and reflects less light than enamel

## Difference between Primary, Secondary and Reparative/Tertiary Dentin

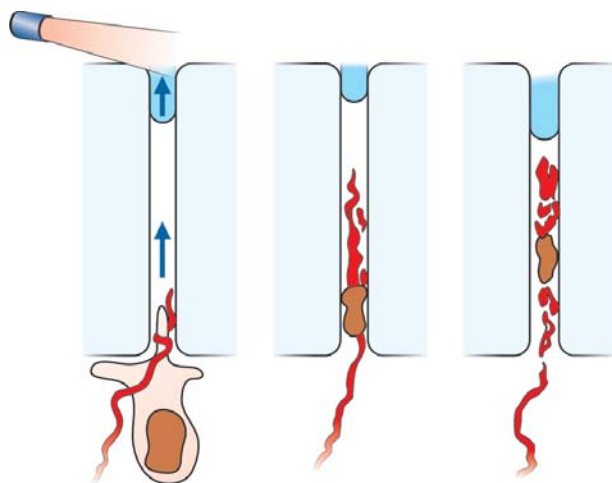
	<i>Primary</i>	<i>Secondary</i>	<i>Tertiary</i>
1. Definition	Dentin formed before root completion	Formed after root completion	Formed as a response to any external stimuli such as dental caries, attrition and trauma
2. Type of cells	Usually formed by primary odontoblasts	Formed by primary odontoblasts	Secondary odontoblasts or undifferentiated mesenchymal cells of pulps
3. Location	Found in all areas of dentin	It is not uniform, mainly present over roof and floor of pulp chamber	Localized to only area of external stimulus
4. Orientation of tubules	Regular	Irregular	Atubular
5. Rate of formation	Rapid	Slow	Rapid between 1.5 $\mu\text{m}$ to 3.5 $\mu\text{m}/\text{day}$ depending on the stimuli
6. Permeability	More	Less	Least

### Functions of dentin

1. Provide strength to the tooth
2. Offers protection of pulp
3. Provides flexibility to the tooth
4. Affects the color of enamel
5. Defensive in action (initiating pulpal defence mechanism).

### Clinical Considerations of Dentin

1. As dentin is known to provide strength and rigidity to the tooth, care should be taken during tooth preparation.
2. Tooth preparations should be done under constant air water spray to avoid build up of heat formation which, in further, damages dental pulp.
3. Dentinal tubules are composed of odontoblastic processes and dentinal fluid. The dehydration of dentin by air blasts causes outward fluid movement and stimulates the mechanoreceptor of the odontoblast, resulting in dentinal sensitivity (**Fig. 3.9**).
4. Dentin should always be protected by liners, bases or dentin bonding agents.
5. When tooth is cut, considerable quantities of cutting debris made up of small particles of mineralized collagen matrix are formed. This forms a layer on enamel of dentin called smear layer for bonding of restorative materials to tooth structure, this smear layer has to be



**Fig. 3.9:** Diagram showing fluid movement in dentinal tubules resulting in dentin hypersensitivity

- removed or modified. This can be done by etching or conditioning.
6. Etching of dentin causes removal of smear layer and etching of intertubular and peritubular dentin for micromechanical bonding.
7. Restoration should be well adapted to the preparation walls so as to prevent microleakage and thus damage to underlying dentin/pulp.

## DENTAL PULP

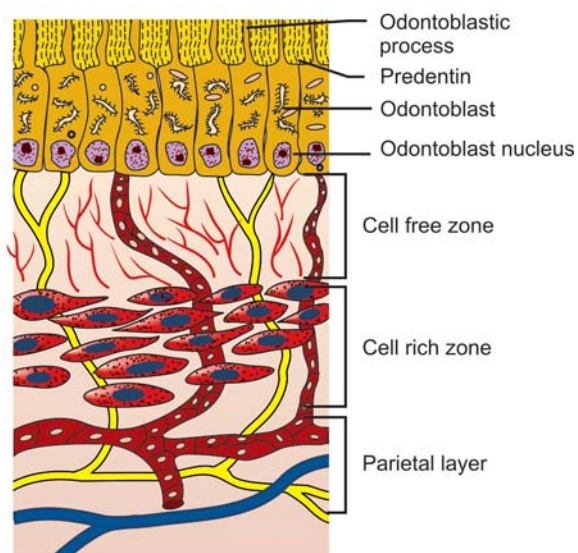
The dental pulp is soft tissue of mesenchymal origin located in the center of the tooth. It consists of specialized cells, odontoblasts arranged peripherally in direct contact with dentin matrix. This close relationship between odontoblasts and dentin is known as “Pulp – dentin complex”. The pulp is connective tissue system composed of cells, ground substances, fibers, interstitial fluid, odontoblasts, fibroblasts and other cellular components. Pulp is actually a microcirculatory system consists of arterioles and venules as the largest vascular component. Due to lack of true collateral circulation, pulp is dependent upon few arterioles entering through the foramen. Due to presence of the specialized cells, i.e. odontoblasts as well as other cells which can differentiate into hard tissue secreting cells. The pulp retains its ability to form dentin throughout the life. This enables the vital pulp to partially compensate for loss of enamel or dentin occurring with age.

### Histology of Dental Pulp

Basically the pulp is divided into the central and the peripheral region. The central region of both coronal and radicular pulp contains nerves and blood vessels.

The peripheral region contains the following zones (**Fig. 3.10**):

1. Odontoblastic layer
2. Cell free zone of Weil
3. Cell rich zone.



**Fig. 3.10:** Diagram showing different zones of dental pulp

### Odontoblastic Layer

Odontoblasts consist of cell bodies and their cytoplasmic processes. The odontoblastic cell bodies form the odontoblastic zone whereas the odontoblastic processes are located within predentin matrix. Capillaries, nerve fibers and dendritic cells may be found around the odontoblasts in this zone.

### Cell Free Zone of Weil

Central to odontoblasts is subodontoblastic layer, termed as cell free zone of Weil. It contains plexuses of capillaries and fibers ramification of small nerve.

### Cell Rich Zone

This zone lies next to subodontoblastic layer. It contains fibroblasts, undifferentiated cells which maintain number of odontoblasts by proliferation and differentiation.

### Contents of pulp

1. Cells
  - a. Odontoblasts
  - b. Fibroblasts
  - c. Undifferentiated mesenchymal cells
  - d. Defense cells
    - Macrophages
    - Plasma cells
    - Mast cells
2. Matrix
  - a. Collagen fibers
    - Types I and II
  - b. Ground substance
    - Glycosaminoglycans
    - Glycoproteins
    - Water
3. Blood vessels
  - Arterioles, venules, capillaries
4. Lymphatics
  - Draining to submandibular, submental and deep cervical nodes
5. Nerves
  - Subodontoblastic plexus of Raschkow
  - Sensory afferent from Vth nerve and superior cervical ganglion

### Structural or Cellular Elements

1. **Odontoblasts:** They are first type of cells encountered as pulp is approached from dentin. The number of odontoblasts has been found in the range of 59,000 to 76,000 per square millimeter in coronal dentin with a lesser number in root dentin. In the crown of the fully developed tooth, the cell bodies of odontoblasts are columnar and measure approximately 500  $\mu\text{m}$  in height,

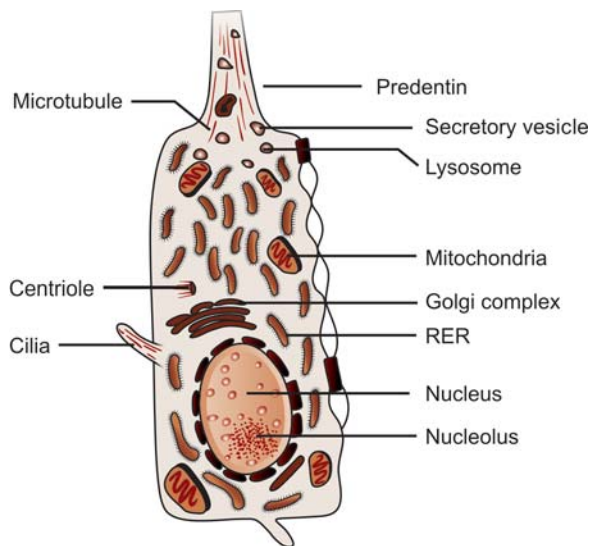


Fig. 3.11: Diagram showing odontoblasts

whereas in the midportion of the pulp, they are more cuboid and in apical part, more flattened.

Ultrastructure of the odontoblast shows (Fig. 3.11) large nucleus which may contain up to four nucleoli. Nucleus is situated at basal end. Golgibodies is located centrally. Mitochondria, rough endoplasmic reticulum (RER), ribosome are also distributed throughout the cell body.

Odontoblasts synthesize mainly type I collagen, proteoglycans. They also secrete sialoproteins, alkaline phosphatase, phosphophoryn (phosphoprotein involved in extracellular mineralizations).

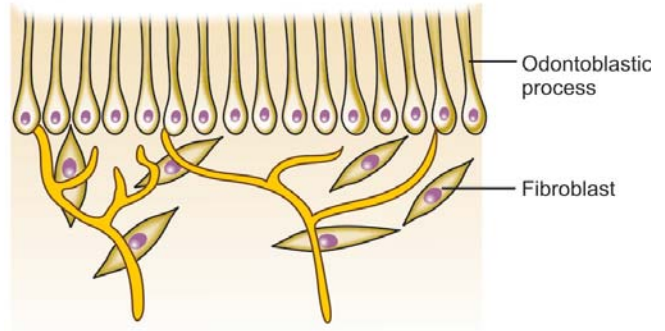


Fig. 3.12: Histology of pulp showing fibroblasts

Irritated odontoblast secretes collagen, amorphous material and large crystals into tubule lumen which result in dentin permeability to irritating substance.

2. **Fibroblasts:** The cells found in greatest numbers in the pulp are fibroblasts. These are particularly numerous in the coronal portion of the pulp, where they form the cell-rich zone. These are spindle shaped cells which secrete extracellular components like collagen and ground substance (Fig. 3.12). They also eliminate excess collagen by action of lysosomal enzymes.
3. **Undifferentiated mesenchymal cells:** Undifferentiated mesenchymal cells are descendants of undifferentiated cells of dental papilla which can dedifferentiate and then redifferentiate into many cells types.
4. **Defence cells (Fig. 3.13):**
  - a. **Histiocytes and macrophages:** They originate from undifferentiated mesenchymal cells or monocytes.

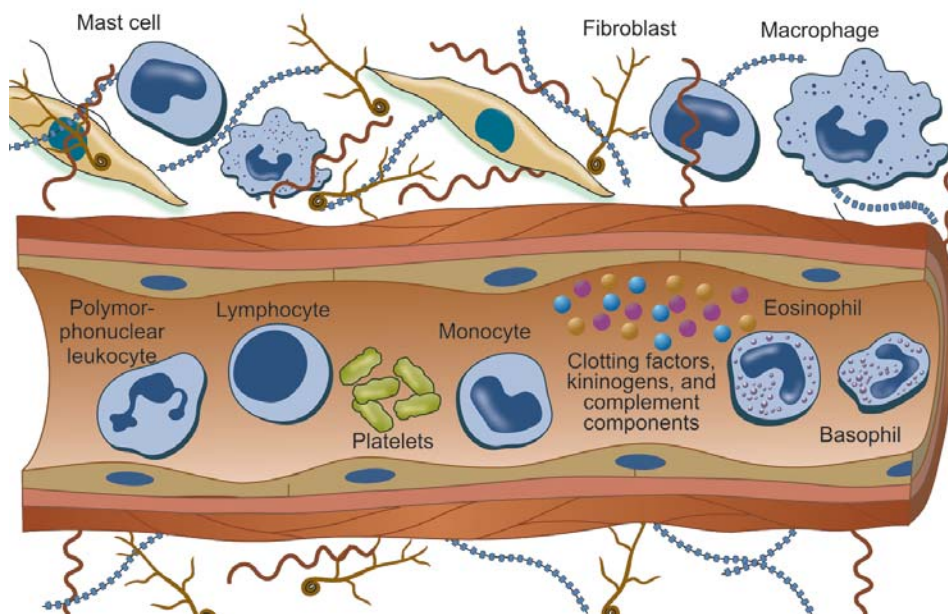


Fig. 3.13: Cells taking part in defence of pulp

They appear as large oval or spindle shaped cells which are involved in the elimination of dead cells, debris, bacteria and foreign bodies, etc.

- b. *Polymorphonuclear leukocytes*: Most common form of leukocyte is neutrophil, though it is not present in healthy pulp. They are major cell type in micro-abscesses formation and are effective at destroying and phagocytizing bacteria and dead cells.
- c. *Lymphocytes*: In normal pulps, mainly T-lymphocytes are found. They are associated with injury and resultant immune response.
- d. *Mast cells*: On stimulation, degranulation of mast cells release histamine which causes vasodilatation, increased vessel permeability and thus allowing fluids and leukocytes to escape.

### Extracellular Components

The extracellular components include fibers and the ground substance of pulp:

#### Fibers

The fibers are principally type I and type III collagen. Collagen is synthesized and secreted by odontoblasts and fibroblasts.

#### Ground Substance

It is a structureless mass with gel like consistency forming bulk of pulp.

Components of ground substance are:

1. Glycosaminoglycans
2. Glycoproteins
3. Water.

Functions of ground substance:

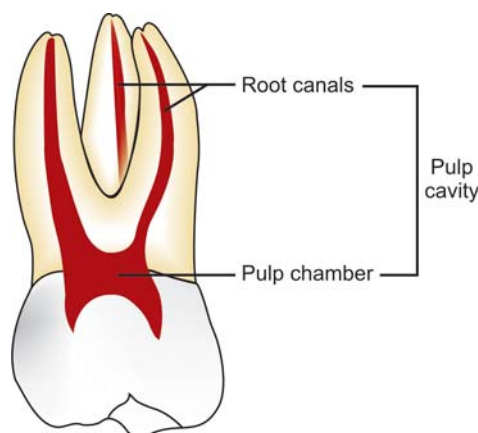
1. Forms the bulk of the pulp.
2. Supports the cells.
3. Acts as medium for transport of nutrients from the vasculature to the cells and of metabolites from the cells to the vasculature.

### Anatomy of Dental Pulp

Pulp lies in the center of tooth and shapes itself to miniature form of tooth. This space is called pulp cavity which is divided into pulp chamber and root canal (**Fig. 3.14**).

#### Pulp Chamber

It reflects the external form of enamel at the time of eruption, but anatomy is less sharply defined. The roof of pulp chamber consists of dentin covering the pulp chamber occlusally.



**Fig. 3.14:** Diagrammatic representation of pulp cavity

#### Root Canal

It is that portion of pulp preparation which extends from canal orifice to the apical foramen. The shape of root canal varies with size, shape, number of the roots in different teeth.

The apical foramen is an aperture at or near the apex of a root through which nerves and blood vessels of the pulp enter or leave the pulp cavity.

### Functions of Pulp

The pulp lives for dentin and the dentin lives by the grace of the pulp.

*Pulp performs four basic functions, i.e.:*

1. Formation of dentin
2. Nutrition of dentin
3. Innervation of tooth
4. Defense of tooth.

#### Formation of Dentin

It is primary function of pulp both in sequence and importance. Odontoblasts are differentiated from the dental papilla adjacent to the basement membrane of enamel organ which later deposits dentin. Pulp primarily helps in:

- Synthesis and secretion of organic matrix.
- Initial transport of inorganic components to newly formed matrix.
- Creates an environment favorable for matrix mineralization.

#### Nutrition of Dentin

Nutrients exchange across capillaries into the pulp interstitial fluid, which in turn travels into the dentin through the network of tubules created by the odontoblasts to contain their processes.

### Innervation of Tooth

Through the nervous system, pulp transmits sensations mediated through enamel or dentin to the higher nerve centers. Pulp transmits pain, also senses temperature and touch.

### Defense of Tooth

Odontoblasts form dentin in response to injury particularly when original dentin thickness has been compromised as in caries, attrition, trauma or restorative procedure.

### Age Changes in Pulp

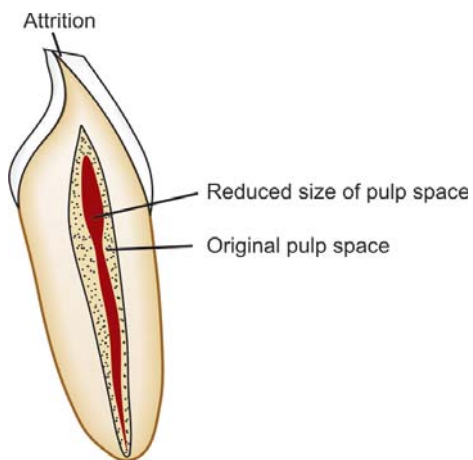
Pulp like other connective tissues, undergoes changes with time. Pulp can show changes in appearance (morphogenic) and in function (physiologic).

#### Morphologic Changes

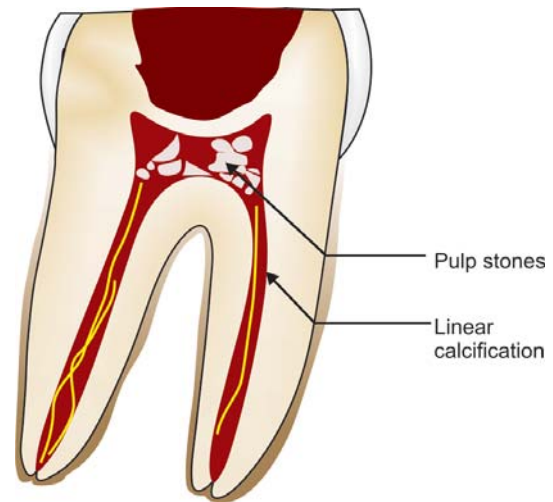
- Continued deposition of intratubular dentin- reduction in tubule diameter.
- Reduction in pulp volume due to increase in secondary dentin deposition (**Fig. 3.15**).
- Presence of dystrophic calcification and pulp stones (**Fig. 3.16**).
- Decrease in sensitivity.
- Reduction in number of blood vessels.

#### Physiologic Changes

- Decrease in dentin permeability provides protected environment for pulp-reduced effect of irritants.
- Possibility of reduced ability of pulp to react to irritants and repair itself.



**Fig. 3.15:** Reduced volume of pulp cavity because of secondary dentin deposition



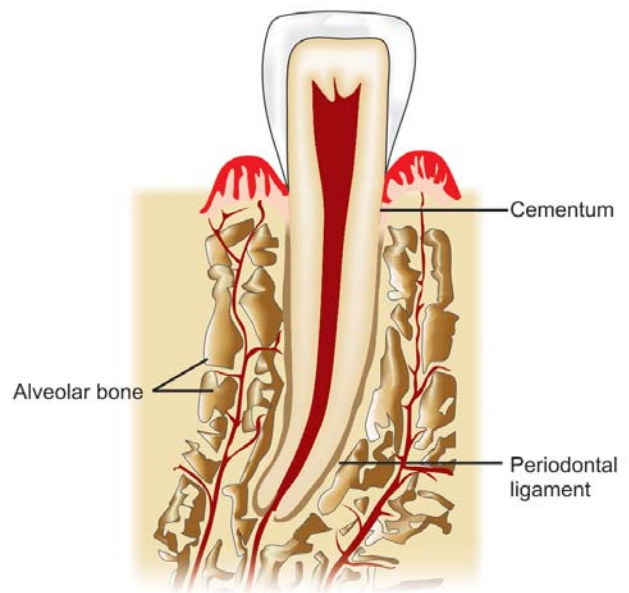
**Fig. 3.16:** Diagrammatic representation of pulp stones

### PERIRADICULAR TISSUE

Periradicular tissue consists of cementum, periodontal ligament and alveolar bone (**Fig. 3.17**).

#### Cementum

Cementum can be defined as hard, avascular connective tissue that covers the roots of the teeth. It is light yellow in color and can be differentiated from enamel by its lack of luster and darker hue. It is very permeable to dyes and chemical agents, from the pulp canal and the external root surface.



**Fig. 3.17:** Diagram showing cementum periodontal ligament and alveolar bone

Cementum consists of approximately 45 to 50% inorganic matter and 50 to 55% organic matter and water by weight. It is softer than dentin. Sharpey's fibers, which are embedded in cementum and bone, are the principal collagenous fibers of periodontal ligament.

#### Composition

- Inorganic content—45-50% (by wt.)
- Organic matter—50-55% (by wt.)
- Water

#### Types

There are two main types of root cementum:

1. **Acellular (Primary)**
2. **Cellular (Secondary)**

#### 1. Acellular cementum

- a. Covers the cervical third of the root.
- b. Formed before the tooth reaches the occlusal plane.
- c. As the name indicates, it does not contain cells.
- d. Thickness is in the range of 30-230  $\mu\text{m}$ .
- e. Abundance of Sharpey's fibers.
- f. Main function is anchorage.

#### 2. Cellular cementum

- a. Formed after the tooth reaches the occlusal plane.
- b. It contains cells.
- c. Less calcified than acellular cementum.
- d. Sharpey's fibers are present in lesser number as compared to acellular cementum.
- e. Mainly found in apical third and interradicular.
- f. Main function is adaptation.

### Periodontal Ligament

Periodontal ligament is a unique structure as it forms a link between the alveolar bone and the cementum. It is continuous with the connective tissue of the gingiva and communicates with the marrow spaces through vascular channels in the bone. Periodontal ligament houses the fibers, cells and other structural elements like blood vessels and nerves.

The periodontal ligament comprises of the following components:

- I. Periodontal fibers
- II. Cells
- III. Blood vessels
- IV. Nerves

#### Periodontal Fibers (Fig. 3.18)

The most important component of periodontal ligament is principal fibers. These fibers are composed mainly of

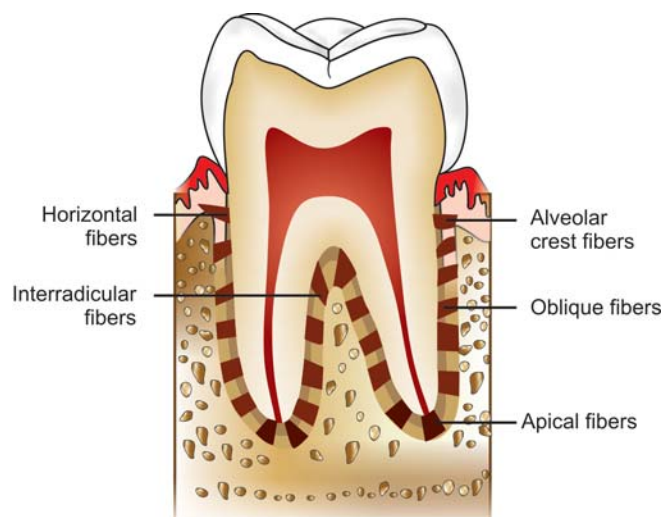


Fig. 3.18: Diagrammatic representation of periodontal ligament fibers

collagen type I while reticular fibers are collagen type III. The principal fibers are present in six arrangements.

**Horizontal group:** These fibers are arranged horizontally emerging from the alveolar bone and attached to the root cementum.

**Alveolar crest group:** These fibers arise from the alveolar crest in fan-like manner and attach to the root cementum. These fibers prevent the extrusion of the tooth.

**Oblique fibers:** These fibers make the largest group in the periodontal ligament. They extend from cementum to bone obliquely. They bear the occlusal forces and transmit them to alveolar bone.

**Transeptal fibers:** These fibers run from the cementum of one tooth to the cementum of another tooth crossing over the alveolar crest.

**Apical fibers:** These fibers are present around the root apex.

**Interradicular fibers:** Present in furcation areas of multirooted teeth.

Apart from the principal fibers, oxytalan and elastic fibers are also present.

#### Cells

The cells present in periodontal ligament are:

- a. Fibroblast
- b. Macrophages
- c. Mast cells
- d. Neutrophil
- e. Lymphocytes
- f. Plasma cells
- g. Epithelial cells rests of Mallassez.

### Nerve Fibers

The nerve fibers present in periodontal ligament, is either of myelinated or non-myelinated type.

### Blood Vessels

The periodontal ligament receives blood supply from the gingival, alveolar and apical vessels.

#### Functions:

- It supports the tooth and is suspended in alveolar socket.
- This tissue has very rich blood supply. So, it supplies nutrients to adjoining structures such as cementum, bone and gingiva by way of blood vessels.
- It also provides lymphatic drainage.
- These fibers perform the function of protection absorbing the occlusal forces and transmitting to the underlying alveolar bone.
- The cells of PDL help in formation of surrounding structures such as alveolar bone and cementum.
- The resorptive function is also accomplished with the cells like osteoclasts, cementoclasts and fibroblasts provided by periodontal ligament.

#### Functions of Periodontal Ligament

1. Supportive
2. Nutritive
3. Provides lymphatic drainage
4. Protective
5. Formative
6. Resorptive function is accomplished with cells like osteoclasts and cementoclasts.

### Alveolar Bone

Bone is specialized connective tissue which comprises of inorganic phases that is very well designed for its role as load bearing structure of the body.

#### Cells and Intercellular Matrix

1. Cells present in bone are:
  - a. Osteocytes
  - b. Osteoblasts
  - c. Osteoclasts
2. **Intercellular matrix:** Bone consists of two-third inorganic matter and one-third organic matter. Inorganic matter is composed mainly of minerals calcium and phosphate along with hydroxyapatite, carbonate, citrate, etc. while organic matrix is composed mainly of collagen type I (90%).

Bone consists of two plates of compact bone separated by spongy bone in between. In some area, there is no spongy bone. The spaces between trabeculae of spongy bone are filled with marrow which consists of hemopoietic tissue in early life and fatty tissue latter in life. Bone is a dynamic tissue continuously forming and resorbing in response to functional needs. Both local as well as hormonal factors play an important role in metabolism of bone. In healthy conditions, the crest of alveolar bone lies approximately 2-3 mm apical to the cemento-enamel junction but it comes to lie more apically in periodontal diseases. In periapical diseases, it gets resorbed easily.

#### VIVA QUESTIONS

**Q. What is thickness of enamel?**

**Q. Is enamel opaque?**

**Ans.** No, enamel is translucent. It transmits the yellowish color of the dentin so tooth appears yellowish in color.

**Q. What is chemical composition of enamel?**

**Q. What is enamel composed of?**

**Q. What is gnarled enamel? What is its significance?**

**Q. Is enamel a living tissue?**

**Ans.** No, enamel forming cells (that is ameloblast) degenerate after forming enamel, consequently it cannot regenerate after injury.

**Q. What are Hunter Schreger bands?**

**Q. What is dentin composed of?**

**Q. What is reason for dentin hypersensitivity?**

**Q. What is DEJ? What is its significance?**

**Q. What are different types of dentin?**

**Q. How can you differentiate enamel from dentin during tooth preparation?**

**Q. What is significance of dentin for bonding?**

**Q. What is pulp?**

**Q. What is composition of pulp?**

**Q. What are enamel lamellae? What is their significance?**

**Q. What are enamel tufts and their significance?**

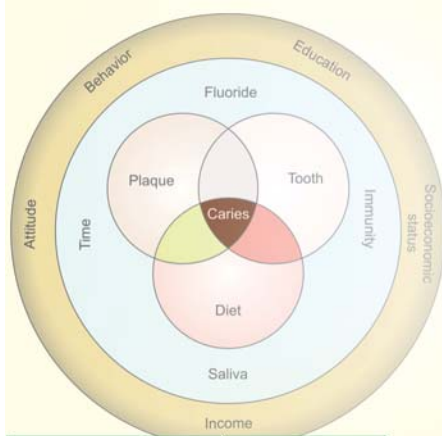
**Q. What is clinical significance of enamel?**

**Q. What is secondary dentin?**

**Q. What is sclerotic dentin?**

- Q. What are dead-tracts?
- Q. Differentiate between primary, secondary and tertiary dentin?
- Q. What is pulp chamber?
- Q. What are functions of pulp?
- Q. What are age changes in pulp?
- Q. What are components of periradicular tissue?
- Q. How many types of cementum are there?
- Q. What is periodontium?
- Q. What are types of periodontal fibers?
- Q. How does periodontal ligament fibers join tooth to bone?





# Dental Caries

## Chapter 4

### DEFINITION

#### SITES OF DENTAL CARIES

- Pathogenic Properties of Cariogenic Bacteria and Pathogenesis of Dental Caries
- Hypothesis Concerning Relation between Plaque and Caries

#### THEORIES OF DENTAL CARIES

- Acidogenic Theory
- Proteolytic Theory
- Proteolysis-chelation Theory
- “Caries Balance Concept” (Proposed by Featherstone)

#### LOCAL FACTORS AFFECTING THE INCIDENCE OF CARIES

- The Host
- Environment of the Tooth: Saliva and Diet
- The Bacteria
- Time Period

#### CLASSIFICATION OF DENTAL CARIES

- According to their Anatomical Site
- According to Whether it is a New Lesion or Recurrent Carious Lesion
- According to the Activity of Carious Lesion
- According to Speed of Caries Progression

- Based on Treatment and Restoration Design
- Based on Pathway of Caries Spread
- Based on Number of Tooth Surfaces Involved
- Classification According to the Severity
- Graham Mount’s Classification

#### HISTOPATHOLOGY OF DENTAL CARIES

- Caries of Enamel
- Caries of Dentin

#### DIAGNOSIS OF DENTAL CARIES

- Visual-Tactile Method of Diagnosis
- Radiographic Method of Diagnosis

#### CARIES RISK ASSESSMENT

#### PREVENTION OF DENTAL CARIES

- Methods to Reduce Demineralizing Factors
- Methods to Improve Oral Hygiene
- Chemical Measures
- Methods to Increase Protective Factors

#### CURRENT METHODS OF CARIES PREVENTION

- Genetic Modalities in Caries Prevention
- Caries Vaccine

#### MANAGEMENT OF DENTAL CARIES

### DEFINITION

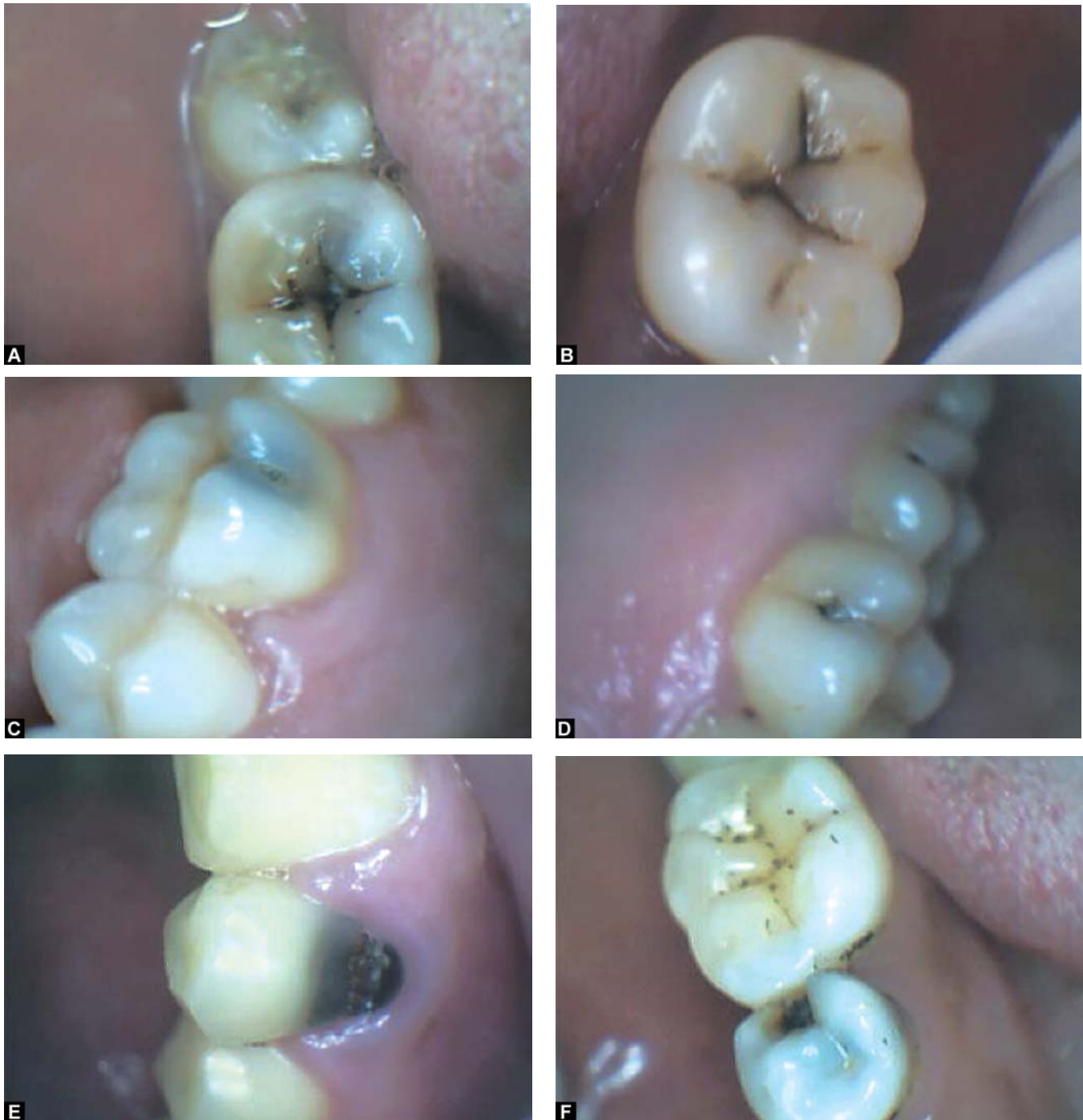
**Dental caries** is defined as a microbiological disease of the hard structure of teeth, which results in localized demineralization of the inorganic portion and destruction of the organic substances of the tooth.

**Cariology** is a science which deals with the study of etiology, histopathology, epidemiology, diagnosis, prevention and treatment of dental caries.

### SITES OF DENTAL CARIES (FIGS 4.1A TO F)

As we know that plaque is the essential forerunner of caries and therefore the sites on the tooth surface which encourage plaque retention and stagnation are particularly prone to progression of lesions. These sites are:

- Pits and fissures on occlusal surfaces of molars and premolars.
- Buccal pits of molars.



**Figs 4.1A to F:** Most common sites of caries development

- Palatal pits of maxillary incisors.
- Enamel of the cervical margin of the tooth just coronal to the gingival margin.
- Proximal enamel smooth surfaces apical to the contact point.
- In teeth with gingival recession occurring because of periodontal disease.

- The margins of restorations predominantly which are deficient or overhanging.
- Tooth surfaces adjacent to dentures and bridges.

#### **Pathogenic Properties of Cariogenic Bacteria and Pathogenesis of Dental Caries**

Cariogenic bacterias have some characteristics which make them special:

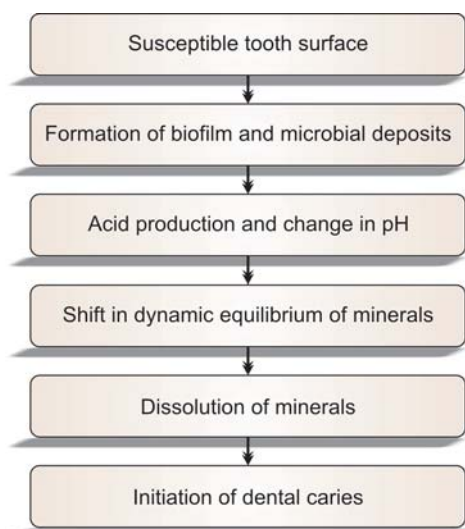


Fig. 4.2: Pathogenesis of dental caries

- **Acidogenic nature:** This means bacteria should be able to transport sugars and convert them to acid.
- **Aciduric nature:** Bacteria should be able to thrive at low pH.
  - Bacteria should be able to produce extracellular and intracellular polysaccharides which contribute to the plaque matrix. These intracellular polysaccharides can be used for energy production and converted to acid when sugars are not available (Fig. 4.2).

### Hypothesis Concerning Relation between Plaque and Caries

- The **specific plaque hypothesis** says that only a few organisms out of the diverse collection in the plaque flora are actively involved in the disease. Preventive measures against these bacteria can control occurrence of the disease.
- The **non-specific plaque hypothesis** believes that the carious process is caused by the overall activity of the total plaque microflora. Accordingly all plaque should be removed by mechanical plaque control.
- The **ecological plaque hypothesis** says that the organisms associated with disease may be present at sound sites. Demineralization results if there is a shift in the balance of these resident microflora by a change in the local environment. Frequent sugar intake encourages the growth of acidogenic and aciduric species, thus predisposing to caries. According to this hypothesis, both mechanical cleaning and restriction of sugar intake are important in controlling caries progression.

## THEORIES OF DENTAL CARIES

As we know, dental caries is a multifactorial disease of tooth which has been explained by many theories. Though there is no universally accepted theory of the etiology of dental caries, but following three theories are considered in the etiology of dental caries:

1. Acidogenic theory
2. Proteolytic theory
3. Proteolysis-chelation theory.

### Acidogenic Theory

- WD Miller was the first known investigator of dental caries. He published his results in 1882.
- This theory is most accepted.
- Miller said “Dental decay is a chemico-parasitic process consisting of two stages, the decalcification of enamel, which results in its total destruction, as a preliminary stage; followed by dissolution of the softened residue of the enamel and dentin.
- In the first stage there is destruction which is done by the acid attack where as the dissolution of the residue (2nd stage) is carried out by the proteolytic action of the bacteria.
- This whole process is supported by the presence of carbohydrates, microorganisms and dental plaque.
- All the preventive steps have been based on this theory.

### The Role of the Dental Plaque

Dental plaque also known as microbial plaque is important for the beginning of caries because it provides the environment for bacteria to form acid, which causes demineralization of hard tissue of teeth.

### Proteolytic Theory

- Heider, Bodecker (1878) and Abbott (1879) thrown considerable light to this theory.
- According to this theory, organic portion of the tooth plays an important role in the development of dental caries.
- It has been recognized that enamel contains 0.56% of organic matter out of which 0.18% is keratin and 0.17% is a soluble protein.
- Enamel structure which are made of the organic material such as enamel lamelle and enamel rods prove to be the pathways for the advancing microorganisms.
- Microorganisms invade the enamel lamelle and the acid produced by the bacteria causes damage to the organic pathways.

### Proteolysis-chelation Theory

This theory was put forward by Schatz and his co-workers.

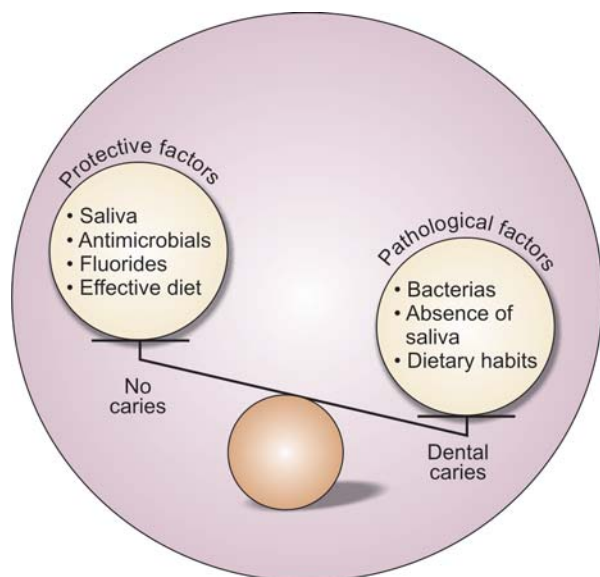
#### Chelation

- It is a process in which there is complexing of the metal ions to form complex substance through coordinate covalent bond which results in poorly dissociated/or weakly ionized compound. Example of chelation reaction is hemoglobin in which 4 pyrrole nuclei are linked to iron by a similar bond.
- Chelation is independent of the pH of the medium.
- Bacterial attack on the surface of the enamel is initiated by keratinolytic microorganisms. This causes the breakdown of the protein chiefly keratin. This results in the formation of soluble chelates which decalcify enamel even at neutral pH.
- Enamel contains mucopolysaccharides, lipids and citrate which are susceptible to bacterial attack and act as chelators.

Reduced incidence of caries because of fluoridation has been explained by this theory. According to this, due to formation of fluoroapatite, strength of linkage between organic and inorganic phases of enamel is increased which helps in reducing their destruction.

#### “Caries Balance Concept” (Proposed by Featherstone) (Fig. 4.3)

According to the caries balance theory, caries does not result from a single factor; rather, it is the outcome of the complex



**Fig. 4.3:** Caries balance concept. If pathological factors overweight then caries progress

interaction of pathologic and protective factors. Pathological factors involved in a carious lesion are bacteria, poor dietary habits, and xerostomia. Protective factors include saliva, antimicrobial agents (chlorhexidine, xylitol), fluoride, pit and fissure sealants and an effective diet.

A balance between pathologic and protective factors dynamically changes throughout the day, even in healthy individuals. Any change in balance of these factors can result in carious lesion. So these risk factors must be evaluated from time-to-time because the effect of each factor can change over time. For example, if a person is healthy today and develops xerostomia, he can develop severe decay months later.

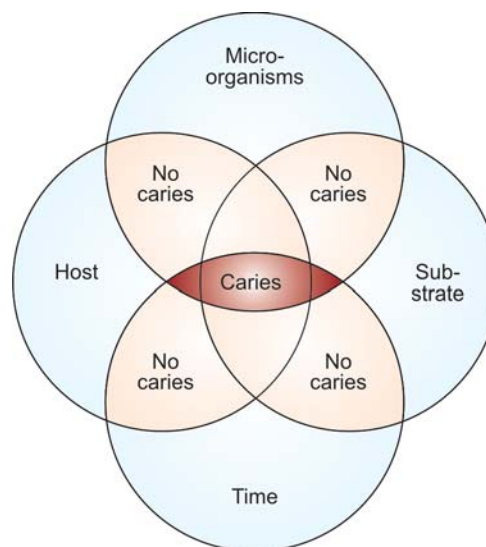
#### LOCAL FACTORS AFFECTING THE INCIDENCE OF CARIES (FIG. 4.4)

**Dental caries** is an ecological disease in which the diet, the host and the microbial flora interact in a way which increases demineralization of the tooth structure with resultant caries formation.

Some races have higher incidence of dental caries, e.g. white American and English people. Some races (e.g. Indians and black Americans) due to hereditary patterns have lower incidence of dental caries. There are some local factors which can easily alter the manifestation of caries activity based on heredity pattern.

The difference in occurrence of dental caries in different individuals of same age, sex, race and geographic area, diet, and similar living conditions is because of various factors that manipulate the etiology of caries.

1. Tooth (Host)
  - a. Variation in morphology



**Fig. 4.4:** Factors affecting incidence of dental caries

- b. Composition
- c. Position
2. Substrate (Environmental factors)
  - a. Saliva
    - i. Composition
    - ii. Quantity
    - iii. pH
    - iv. Viscosity
    - v. Antibacterial factors
  - b. Diet
    - i. Physical factors
    - ii. Local factors
      - Carbohydrate content—presence of refined cariogenic carbohydrate particles on the tooth surface
      - Vitamin content
      - Fluoride content
      - Fat content
3. Microorganisms—most commonly seen microorganisms associated with caries are *Streptococcus mutans* and *Lactobacillus*.
4. Time period

### The Host

- Lack of enamel maturation or the presence of developmental defects in enamel may result in increase the caries risk. These defects increase plaque retention, increase bacterial colonization, and in some cases, the loss of enamel make it more susceptible to tooth demineralization.
- The physical characteristics of teeth like deep and narrow occlusal fissures, deep buccal or lingual pits and enamel hypoplasia, etc. affect the initiation of dental caries.
- Fluoride content is lesser in carious enamel and dentin as compared to a sound tooth. In carious enamel and dentin it is 139 ppm and 223 ppm, whereas in sound enamel and dentin it is 410 ppm and 873 ppm, respectively.
- If a tooth is out of position, rotated or in any abnormal position, it becomes difficult to clean, and hence retains more food and debris.

### Environment of the Tooth: Saliva and Diet

#### Saliva

- Saliva contains salivary proteins which get deposited onto the tooth surface which help the enamel against acid dissolution. This protective layer is referred to as the pellicle.

- Since saliva is rich in calcium, phosphate and fluoride, these materials help in remineralization of the enamel.
- Saliva acts as cleaner of teeth as it quickly washes away food debris from the mouth and to buffer the organic acids that are produced by the bacteria.
- Any salivary dysfunction, effect of medication or radiotherapy can result in decreased quantity and quality of saliva which further promotes caries.
- When salivary flow is reduced or absent, there occurs the increased food retention. Since salivary buffering capacity is lost, an acid environment is encouraged which further promotes the growth of aciduric bacteria. These aciduric bacteria savor the acid conditions and metabolize carbohydrates in the low-pH environment. This results in initiation of the caries.

Functions of saliva	Components of saliva
Antimicrobial action	Lysozyme, lactoperoxides, mucins, cystins, immunoglobulins, IgA
Maintaining mucosa integrity	Water, mucins, electrolytes
Lubrication	Mucin, glycoproteins, water
Cleansing	Water
Buffer capacity and remineralization	Bicarbonate, phosphate, calcium, fluorides

#### Diet (Fig. 4.5)

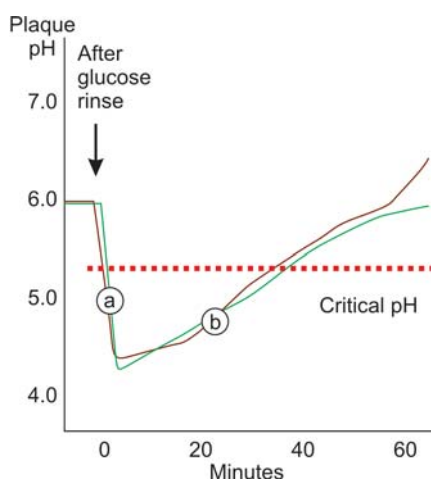
- **Physical nature of diet:** In the earlier times, the primitive man used to eat rough and raw unrefined foods which had self-cleansing capacity. But in present times, soft

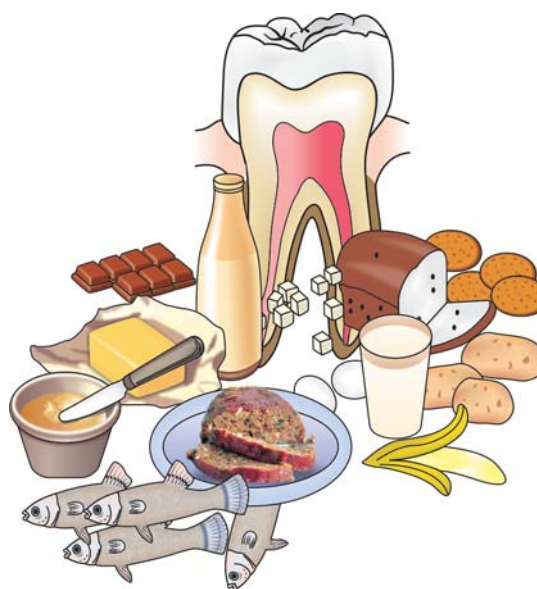

Fig. 4.5: Physical nature of diet affects the incidence of dental caries

refined foods are eaten which stick stubbornly to the teeth and are not removed easily due to lack of roughage. This is the reason for higher incidence of dental caries nowadays than the past.

- **Nature of carbohydrate content of the diet:** To cause demineralization of dental enamel, it is essential for fermentable carbohydrates and plaque to be present on the tooth surface for a minimum length of time. These need to be retained in the mouth long enough to be metabolized by oral bacteria to produce acid.
- It is seen that acids produced by fermentable carbohydrates cause a rapid drop in plaque pH to a level which results in demineralization of the tooth structure. But since acids produced in plaque diffuse out of the plaque combined with buffering capacity of saliva exerting a neutralizing effect, this acidic nature of plaque remains for sometime only, and with in 30-60 minutes, plaque returns to its normal pH. However, repeated and frequent consumption of sugar will keep plaque pH depressed which results in demineralization of the teeth. Stephan has shown the relationship between change in plaque pH over a period of time following a glucose rinse in form of a graph. This graph is called a "Stephan curve" (Stephan and Miller, 1943) (Fig. 4.6). The drop in pH is the result of fermentation of carbohydrates by plaque bacteria. The gradual return of the pH occurs because of buffers present in plaque and saliva. This drop in pH can demineralize tooth structure depending on the absolute pH decrease, as well as the length of time that the pH is below the "critical pH" level. The critical pH value for demineralization usually ranges between 5.2 to 5.5. Caries occurs when the process of remineralization is slower than the process of demineralization



**Fig. 4.6:** Stephan curve graph showing plaque pH before and after glucose rinse. (a) pH decreases because of acids produced by bacteria, (b) pH increases, due to buffering of plaque and saliva

and there is a net loss of mineral into the environment. It can be prevented by restricting the intake of dietary sugars, and removing plaque.

Tooth remineralization can take place if the pH of the environment adjacent to the tooth is high due to:

- Lesser number of cariogenic bacteria
  - Availability of fluoride
  - Lack of substrate for bacterial metabolism
  - Elevated secretion rate of saliva
  - Strong buffering capacity of saliva
  - Presence of inorganic ions in saliva
  - Quick washing of retained food.
- **Frequency of carbohydrate intake:** In a person with normal salivary function, after intake of fermentable carbohydrate foods or drinks, the acidic pH lasts 30-60 minutes. Greater time between acid attacks allows greater time for the repair process (remineralization) to occur.
  - **Vitamin content of the diet:** As we know vitamin are essential components of daily diet. Deficiency of some vitamins increases the incidence of dental caries.

**Vitamin A:** Deficiency or excess are not related to dental caries.

**Vitamin D:** Vitamin D helps in normal development of teeth. Enamel hypoplasia can result due to vitamin D deficiency. It can result in early attack of caries. It has been seen that supplement of vitamin D in children helps in the formation of healthy teeth and thus helps in reduction in the dental caries.

**Vitamin K:** Deficiency does not affect the dental caries incidence.

**Vitamin B complex:** Its deficiency may exert a caries protective influence on the tooth. Several types of vitamin B are important growth factors for the oral acidogenic flora which serve as component of the co-enzymes involved in glycolysis. Vitamin B<sub>6</sub> acts as an anticaries agent because it promotes the growth of non-cariogenic organisms.

**Vitamin C:** Directly vitamin C does not help in protection of tooth against dental caries, but it is required for the normal health of the gingiva.

## The Bacteria

- **Dental caries** do not occur if the oral cavity is free of bacteria.
- Most commonly seen bacteria associated with caries are *Streptococcus mutans*, *Lactobacillus spp.*, *Veillonella spp.* and *Actinomyces spp.*

- Streptococci mutans are considered main causative factors for caries because of their ability to adhere to tooth surfaces, produce abundant amounts of acid, and survive and continue metabolism at low pH conditions. Colonization with *Streptococcus mutans* at an early age is an important factor for early caries initiation.

### Time Period

The time period during which all above three direct factors, i.e. tooth, microorganisms and substrate are acting jointly should be adequate to produce acidic pH which is critical for dissolution of enamel to produce a carious lesion. Time required for acid production from the fermentation of the carbohydrates by bacteria and for demineralization of tooth, is allowed by poor oral hygiene and not cleaning teeth immediately after eating.

## CLASSIFICATION OF DENTAL CARIES

Cariou lesions can be classified in different ways.

### According to their Anatomical Site

- Pit and fissure caries (Fig. 4.7):** Pit and fissure caries occur on occlusal surface of posterior teeth and buccal and lingual surfaces of molars and on lingual surface of maxillary incisors.
- Smooth surface caries (Fig. 4.8):** Smooth surface caries occurs on gingival third of buccal and lingual surfaces and on proximal surfaces.
- Root caries (Fig. 4.9):** When the lesion starts at the exposed root cementum and dentin, it is termed as root caries.

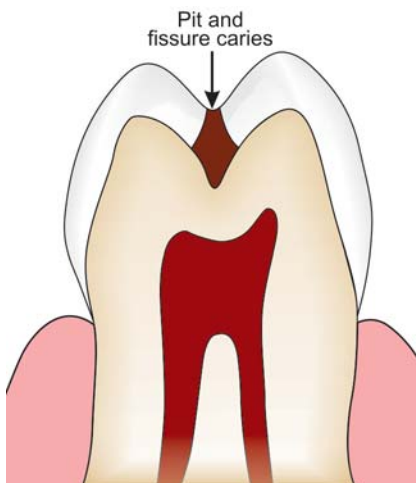


Fig. 4.7: Pit and fissure caries

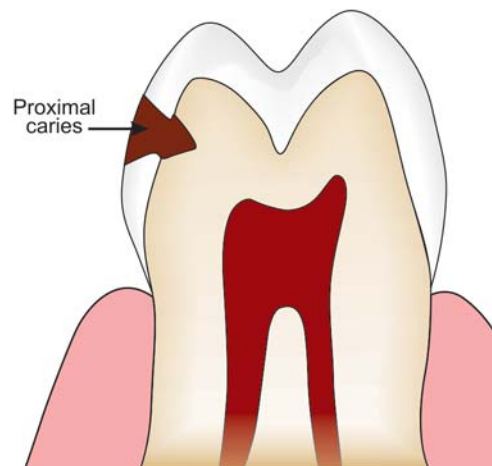


Fig. 4.8: Smooth surface caries

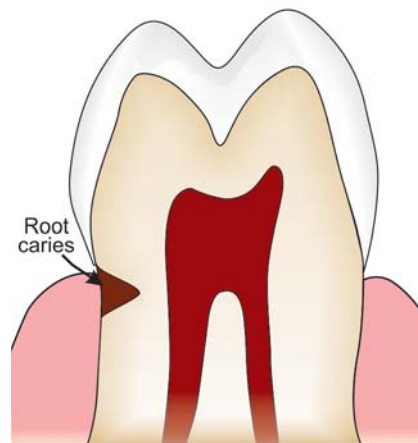


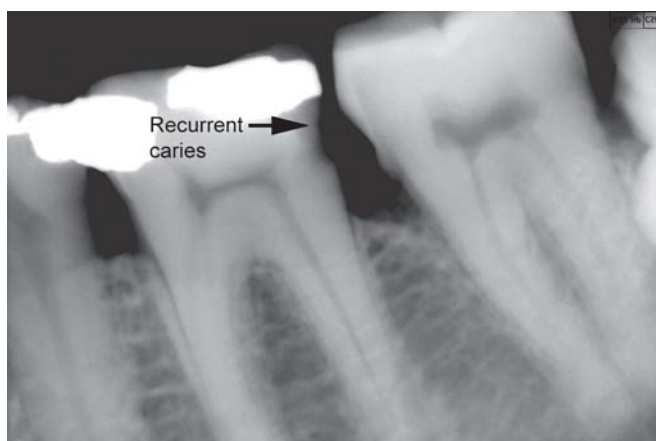
Fig. 4.9: Root caries

### According to Whether it is a New Lesion or Recurrent Carious Lesion

- Primary caries** denotes lesions on unrestored surfaces (Fig. 4.10).
- Recurrent caries (Fig. 4.11):** Lesions developing adjacent to fillings are referred to as either recurrent or secondary caries.

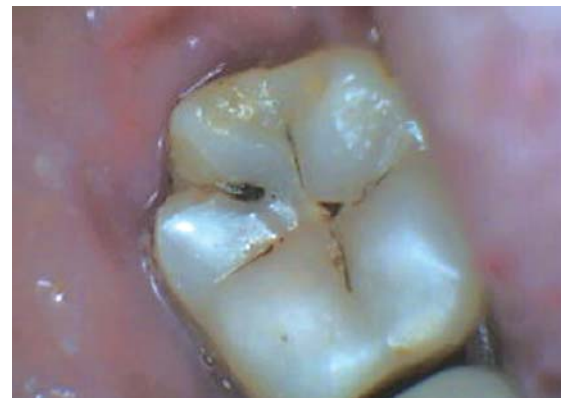

Fig. 4.10: Primary caries



**Fig. 4.11:** Radiograph showing recurrent caries adjacent to proximal restoration

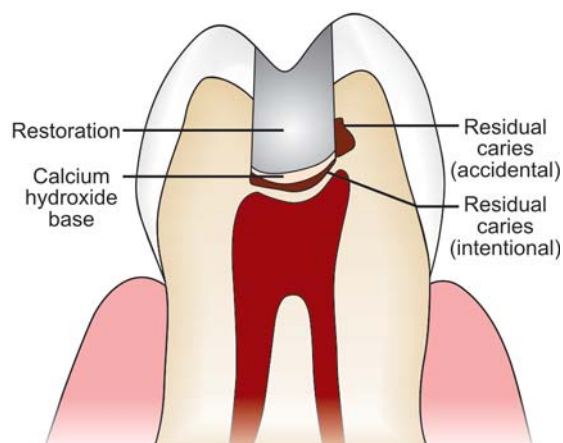
- **Residual caries** is demineralized tissue left in place before a filling is placed (**Fig. 4.12**).

#### According to the Activity of Carious Lesion

- **Active carious lesion:** A progressive lesion is described as an active carious lesion.
- **Inactive/arrested carious lesion:** A lesion that may have formed earlier and then stopped is referred to as an arrested or inactive carious lesion. Arrested carious lesion is characterized by a large open cavity which no longer retains food and becomes self-cleansing.

#### According to Speed of Caries Progression

- **Acute dental caries:** Acute caries travels towards the pulp at a very fast speed.
- **Rampant caries:** It is the name given to multiple active carious lesions occurring in the same patient, frequently involving surfaces of teeth that are usually caries free.



**Fig. 4.12:** Residual caries

It occurs usually due to poor oral hygiene and taking frequent cariogenic snacks and sweet drinks between meals. It is also seen in mouths where there is hypo-salivation.

Rampant caries is of following three types:

- **Early childhood caries** is a term used to describe dental caries present in the primary dentition of young children.
- **Bottle caries or nursing caries** are names used to describe a particular form of rampant caries in the primary dentition of infants and young children. The clinical pattern is characteristic, with the four maxillary deciduous incisors most severely affected.
- **Xerostomia induced rampant caries (radiation rampant caries)** are commonly observed that after radiotherapy of malignant areas of or near the salivary glands. Because of radiotherapy salivary flow is very much reduced. This results in rampant caries even in those teeth which were free from caries before radiotherapy.
- **Chronic dental caries:** Chronic caries travel very slowly towards the pulp. They appear dark in color and hard in consistency.

#### Based on Treatment and Restoration Design

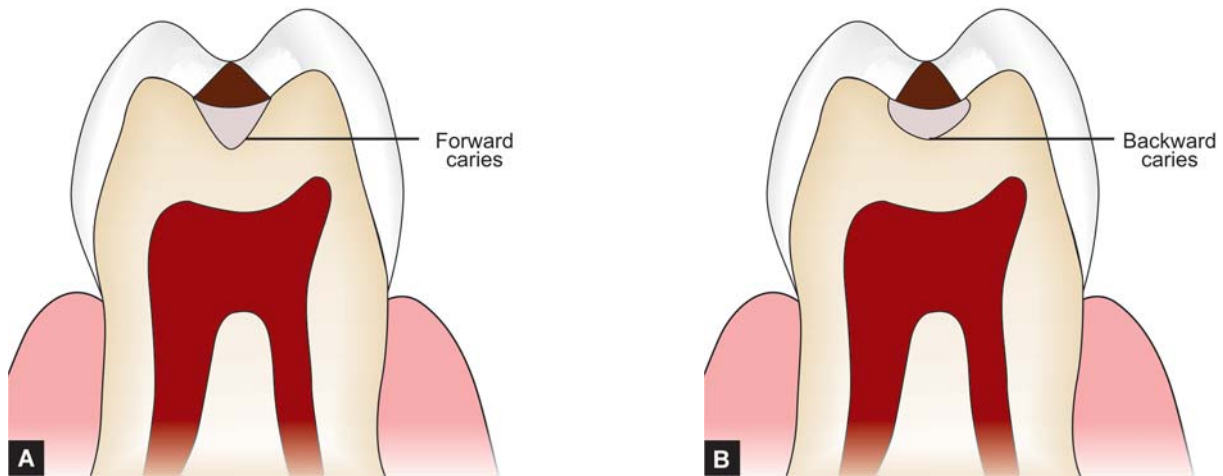
- **Class I:** Pit and fissure caries occur in the occlusal surfaces of premolars and molars, the occlusal two-third of buccal and lingual surface of molars, lingual surface of incisors.
- **Class II:** Caries in the proximal surface of premolars and molars.
- **Class III:** Caries in the proximal surface of anterior (incisors and canine) teeth and not involving the incisal angles.
- **Class IV:** Caries in the proximal surface of anterior teeth also involving the incisal angle.
- **Class V:** Caries on gingival third of facial and lingual or palatal surfaces of all teeth.
- **Class VI:** Caries on incisal edges of anterior and cusp tips of posterior teeth without involving any other surface.

#### Based on Pathway of Caries Spread (Figs 4.13A and B)

##### Forward Caries

When the caries cone in enamel is larger or of same size as present in dentin, it is called as forward caries.





**Figs 4.13A and B:** A. Forward caries, B. Backward caries

### Backward Caries

When spread of caries along dentinoenamel junction exceeds the adjacent caries in enamel, it is called backward caries (here caries extend from DEJ to enamel).

### Based on Number of Tooth Surfaces Involved

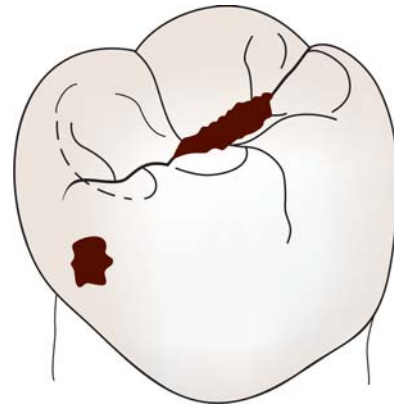
**Simple caries:** Caries involving only one tooth surface is termed as simple caries (Fig. 4.14).

**Compound caries (Fig. 4.15):** If two surfaces are involved it is termed as compound caries.

**Complex caries (Fig. 4.16):** If more than two surfaces are involved it is called as complex caries.

### Classification According to the Severity

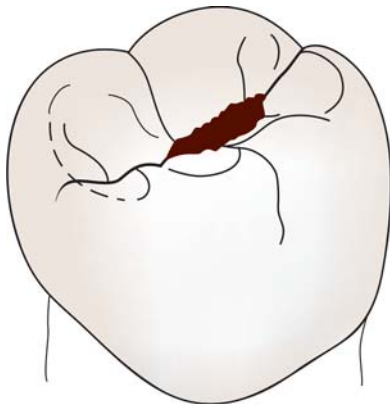
**Incipient caries (Fig. 4.17):** Involves less than half the thickness of enamel.



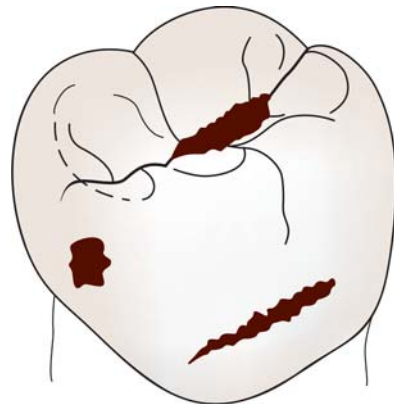
**Fig. 4.15:** Compound caries

**Moderate caries (Fig. 4.18):** Involves more than half the thickness of enamel, but does not involve dentinoenamel junction.

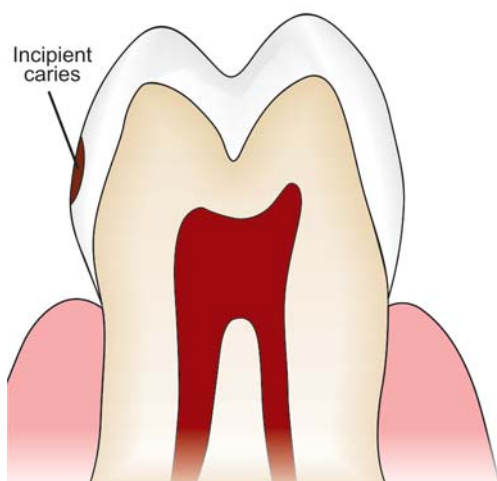
**Advanced caries (Fig. 4.19):** Involves the dentinoenamel junction and less than half distance to pulp cavity.



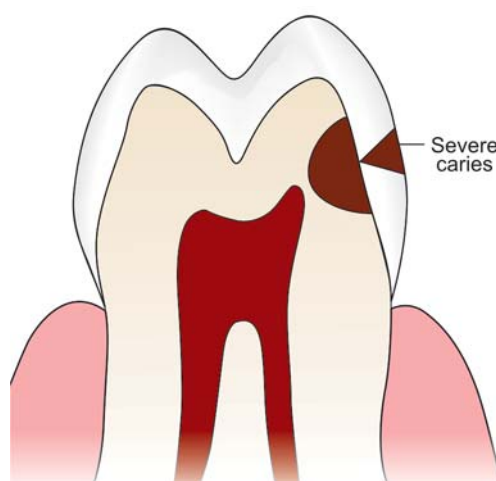
**Fig. 4.14:** Simple caries



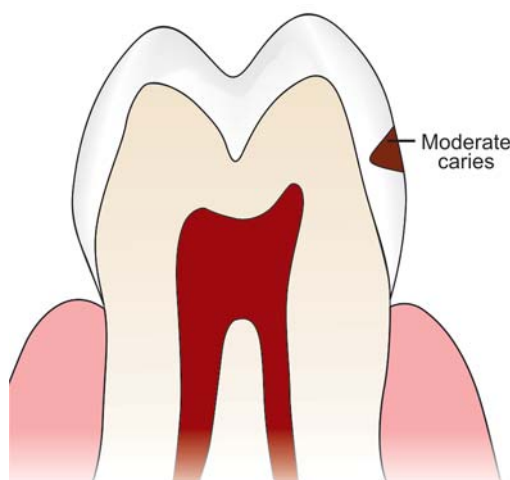
**Fig. 4.16:** Complex caries



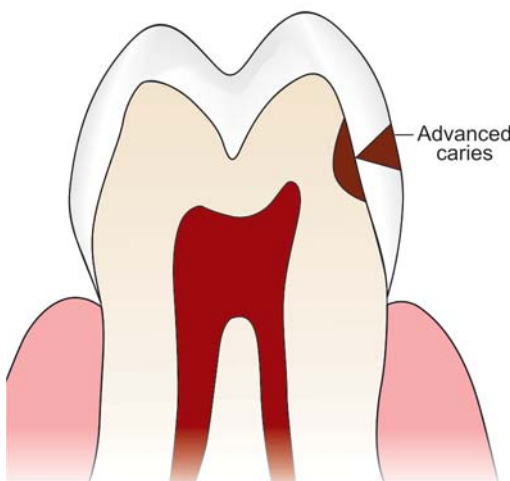
**Fig. 4.17:** Incipient caries



**Fig. 4.20:** Severe caries



**Fig. 4.18:** Moderate caries



**Fig. 4.19:** Advanced caries

**Severe caries (Fig. 4.20):** Involves more than half distance to pulp cavity.

### Graham Mount's Classification

This classification system is based on two simple parameters:

- a. Location of carious lesion
- b. Size of carious lesion

Here, the system is designed to recognize carious lesions beginning at the earliest stage, in which remineralization is the indicated.

Cavity site	Size 1 (Minimal)	Size 2 (Moderate)	Size 3 (Enlarged)	Size 4 (Extensive)
Site 1 Pit and fissure	1.1	1.2	1.3	1.4
Site 2 Contact area	2.1	2.2	2.3	2.4
Site 3 Cervical region	3.1	3.2	3.3	3.4

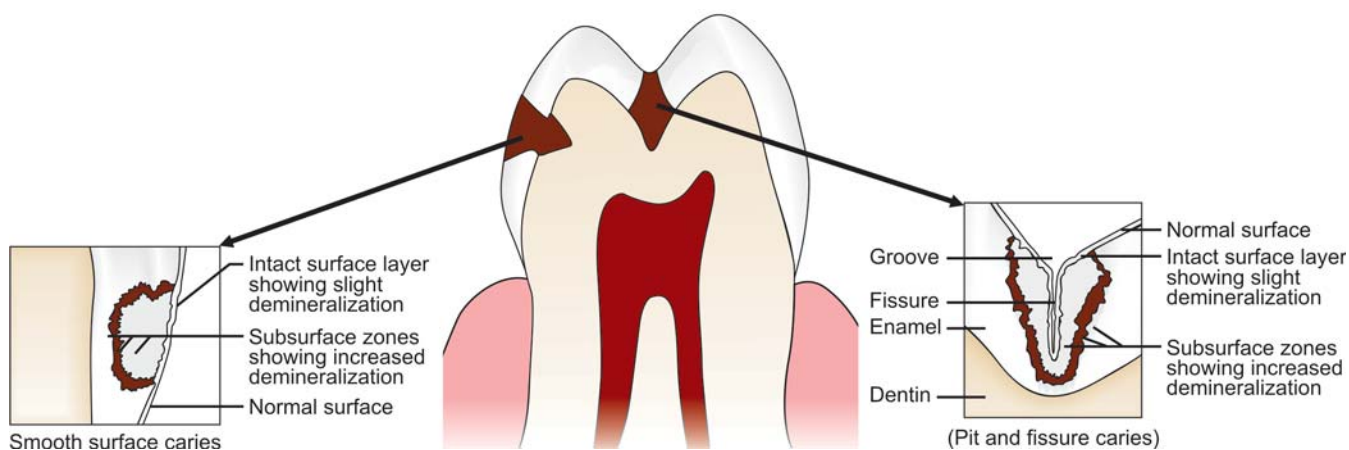
### HISTOPATHOLOGY OF DENTAL CARIES

#### Caries of Enamel (Fig. 4.21)

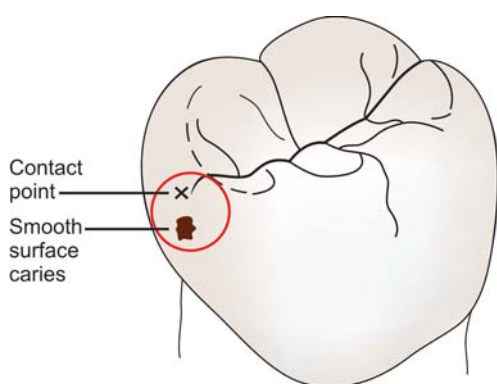
Caries of enamel initiates by deposition of dental plaque on tooth surface. We will discuss the carious process of the enamel according to its location on tooth surface, i.e. smooth surface caries, and pit and fissure caries.

#### Smooth Surface Caries

- Smooth surface caries occurs on gingival third of buccal and lingual surfaces and on proximal surfaces below the contact point (**Fig. 4.22**).



**Fig. 4.21:** Magnified schematic presentation of smooth surface caries (Pit and fissure caries)



**Fig. 4.22:** The most common site of occurrence of smooth surface caries below the contact print

- The earliest manifestation of incipient caries (early caries) of enamel is usually seen beneath dental plaque as areas of decalcification (white spots). As caries progresses it appears bluish-white in color.
- The first change seen histologically is the loss of inter-prismatic/interrod substance of enamel with increased prominence of the rods.
- There is also accentuation of the incremental lines of Retzius.
- This is followed by the loss of mucopolysaccharides in the organic substance.
- As it goes deeper, the caries forms a triangular pattern or cone shaped lesion with the apex towards DEJ and base towards the tooth surface.
- Finally, there is loss of enamel structure, which gets roughened due to demineralization, and disintegration of enamel prisms.

#### *Pit and Fissure Caries*

- The shape of pits and fissures contributes to their high susceptibility to caries because of entrapment of bacteria and food debris in them.

- Initially caries of pits and fissures appears brown or black in color and with a fine explorer, a “catch” is felt. Enamel at the margins of these the pits and fissures appears opaque bluish-white.
- Caries begin beneath plaque resulting in decalcification of enamel.
- Enamel in the bottom of pit or fissure is very thin, so early dentin involvement frequently occurs.
- Here the caries follows the direction of the enamel rods.
- It is triangular in shape with the apex facing the surface of tooth and the base towards the DEJ.
- When reaches DEJ, greater number of dentinal tubules are involved.
- It produces greater cavitation than the smooth surface caries and there is more undermining of enamel.
- When undermined enamel fractures, it causes exposure of cavitation and caries.

#### *Zones in Caries of Enamel*

Different zones are seen before complete disintegration of enamel. Early enamel lesion seen under polarized light reveals four distinct zones of mineralization (**Fig. 4.23**). These zones begin from the dentinal side of the lesion.

##### **Zone 1: Translucent zone**

- Represent the advancing front of the lesion.
- Ten times more porous than sound enamel.
- Not always present.

##### **Zone 2: Dark zone**

- It lies adjacent and superficial to the translucent zone.
- Usually present and thus referred as positive zone.
- Called dark zone because it does not transmit polarized light.
- Formed due to demineralization.

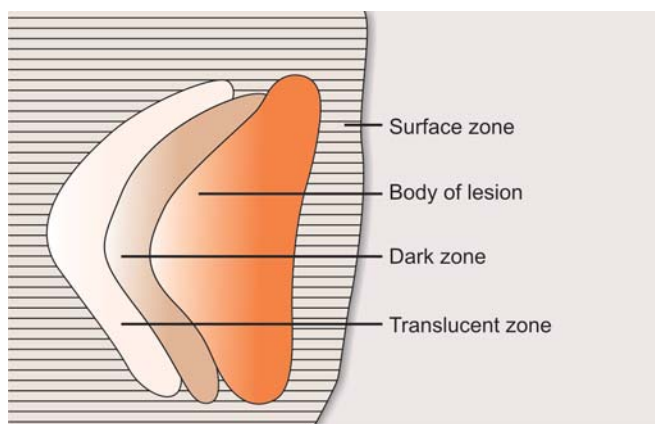


Fig. 4.23: Zones in caries of enamel

### Zone 3: Body of the lesion

- Largest portion of the incipient caries.
- Found between the surface and the dark zone.
- It is the area of greatest demineralization making it more porous.

### Zone 4: Surface zone

- This zone is not or least affected by caries.
- Greater resistance probably due to greater degree of mineralization and greater fluoride concentration.
- It is less than 5 percent porous.
- Its radiopacity is comparable to adjacent enamel.

## Caries of Dentin

Although caries of enamel is clearly a dynamic process, it is not a vital process because it does not defend itself from trauma. But since pulp and dentin are vital tissues, they are capable of defending. Relationship between pulp and dentin is termed as pulp-dentin complex, it acts as a structural and functional biological unit.

When enamel caries reaches the dentinoenamel junction it spreads rapidly laterally because it is least resistant to caries.

### Dentinal caries appear brown because of color produced by

1. Pigment producing microorganisms
2. Chemical reaction which occurs when proteins breakdown in presence of sugar
3. Exogenous stains.

The caries process in dentin involves the demineralization of the inorganic component and breakdown of the organic component of collagen fibers. The caries process in dentin is twice as fast in enamel because dentin provides

much less resistance to acid attack. When caries attacks the dentin, the following changes occur in dentin.

### Early Dentinal Changes

- Initial penetration of the dentin by caries causes an alteration in dentin, known as dentinal sclerosis.
- In this reaction there occurs the calcification of dentinal tubules which seals off from further penetration by microorganisms.
- More prominent in slow chronic caries.
- When dentinal tubules are completely occluded by the mineral precipitate, section of the tooth gives a transparent appearance in transmitted light, this dentin is termed as transparent dentin.
- In transparent dentin, intertubular dentin is demineralized and lumen is filled by calcified materials, which provides softness and transparency to the dentin compared to sound dentin.
- In the earliest stages, when only few tubules are involved, microorganisms may be found penetrating the tubules, called Pioneer Bacteria.
- In early caries, fatty degeneration of Tomes' fiber and deposition of fat globules in these processes act as predisposing factor for sclerosis of the tubules.
- This initial decalcification involves the walls allowing them to distend as the tubules are packed with microorganisms. Each tubule is seen to be packed with pure forms of bacteria, e.g. one tubule packed with coccid forms the other tubule with bacilli.
- As the microorganisms proceed further they are distanced from the carbohydrates substrate that was needed for the initiation of the caries. Thus, the high protein content of dentin must favor the growth of the microorganisms. Therefore, proteolytic organisms might appear to predominate in the deeper caries of dentin while acidophilic forms are more prominent in early caries.

### Advanced Dentinal Changes

- In advanced lesion, decalcification of the wall of the individual tubules takes place, resulting in confluence of the dentinal tubules.
- Sometimes the sheath of Neumann shows swelling and thickening at irregular intervals in the course of dentinal tubules.
- The diameter of dentinal tubules increases because of packing of microorganisms.
- There occurs the formation of tiny "liquefaction foci", described by Miller. They are formed by the focal

coalescing and breakdown of dentinal tubules. These are ovoid areas of destruction parallel to the course of the tubules which are filled with necrotic debris and increase in size by expanding. This expansion produces compression and distortion of adjacent dentinal tubules, leading to course of dentinal tubules being bent around the “liquefaction focus”.

- The destruction of dentin by decalcification and then proteolysis occurs in numerous focal areas. It results in a necrotic mass of dentin with a leathery consistency.
- Clefs occur in the carious dentin that extends at right angles to the dentinal tubules. These account for the peeling off of dentin in layers while excavating.
- Shape of the lesion is triangular with the apex towards the pulp and the base towards the enamel.

### Zones of Dentinal Caries (Fig. 4.24)

Five zones have been described in dentinal caries. These zones are clearly distinguished in chronic caries than in acute caries. These zones begin from the pulpal side (Fig. 4.24).

#### Zone 1: Normal dentin

- Zone of fatty degeneration of Tome’s fibers.
- Formed by degeneration of the odontoblastic process.
- Otherwise dentin is normal and produces sharp pain on stimulation.

#### Zone 2: Zone of dentinal sclerosis

- Intertubular dentin is demineralized.
- Dentinal sclerosis, i.e. deposition of calcium salts in dentinal tubules takes place.
- Damage to the odontoblastic zone process is apparent.
- There are no bacteria in this zone. Hence, this zone is capable of remineralization.

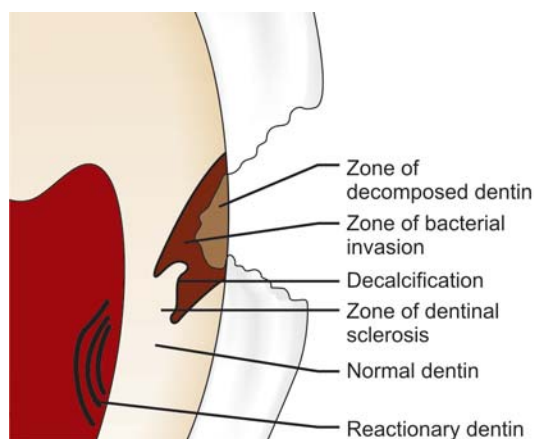


Fig. 4.24: Zones of dentinal caries

#### Zone 3: Zone of decalcification of dentin

Further demineralization of intertubular dentin lead to softer dentin.

#### Zone 4: Zone of bacterial invasion

- Widening and distortion of the dentinal tubules which are filled with bacteria.
- Dentin is not self-repairable, because of less mineral content and irreversibly denatured collagen.
- This zone should be removed during tooth preparation.

#### Zone 5: Zone of decomposed dentin due to acids and enzymes

- Outermost zone
- Consists of decomposed dentin filled with bacteria
- It must be removed during tooth preparation.

## DIAGNOSIS OF DENTAL CARIES

Accurate diagnosis of the non-cavitated lesion is extremely valuable because an increased prevalence of difficult to diagnose caries can be an indication of high caries activity, a circumstance that must be treated with a more aggressive preventive program.

The accuracy of any diagnostic test or evaluation is typically measured according to its sensitivity and specificity.

**Sensitivity and specificity** refer to the capability of a test to diagnose disease correctly when disease is actually present and to rule out the disease when it is absent.

### Various methods for diagnosis of dental caries

- I. Visual-tactile method
  1. Conventional methods
    - a. Tactile examination
    - b. Visual examination
  2. Advances in visual method
    - a. Illumination
      - i. Ultrasonic illumination
      - ii. Ultrasonic imaging
      - iii. Fiberoptic transillumination (FOTI)
      - iv. Wavelength dependent FOTI
      - v. Digital imaging FOTI (DIFOTI)
    - b. Dyes
    - c. Endoscopy filtered fluorescence (EFF) method
- II. Radiographic methods
  1. Conventional methods
    - a. Intraoral periapical X-rays (IOPA)
    - b. Bitewing radiographs
    - c. Panorex radiography
    - d. Xeroradiography
  2. Recent advances in radiographic techniques
    - a. Digital imaging
    - b. Computerized image analysis

Contd...

Contd...

- c. Substraction radiography
  - d. Tuned aperture computerized tomography (TACT)
  - e. Magnetic resonance microimaging (MRMI)
- III. Electrical conductance measurement
- IV. Lasers
1. Argon laser
  2. Diode lasers
  3. Qualitative laser fluorescence
  4. Diagnodent (Quantitative laser fluorescence)
  5. Optical coherence tomography
  6. Polarization sensitive optical coherence tomography (PSOCT)
  7. Dye enhanced laser fluorescence

### Visual-Tactile Method of Diagnosis

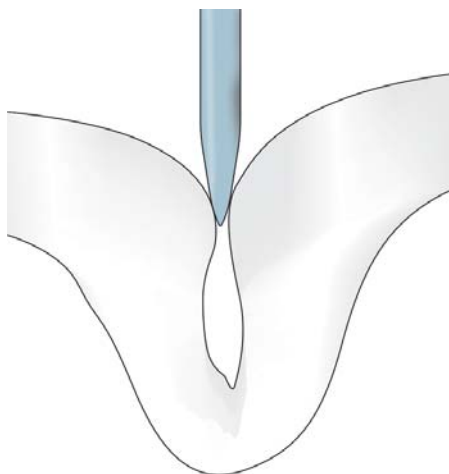
This method is most commonly used method for tooth examination. This method involves the use of mirror, explorer and light for detecting caries.

#### Conventional Methods

**Tactile examination:** In this method, explorer is used to detect softened tooth structure. When an explorer sticks, it's usually a good indication that there is decay beneath; however, when it does not stick, it does not necessarily mean that decay is not present.

#### Disadvantages

- Sturdevant said cavitation at the base of a pit or fissure can be detected tactilely as softness, but mechanical binding of an explorer in the pits or fissures may be due to noncarious causes, like shape of the fissure, sharpness of the explorer, or the force of application (**Fig. 4.25**).



**Fig. 4.25:** An explorer can stick to a healthy deep fissure giving false positive result

- Sharp edge of explorer may fracture the demineralized enamel, if left alone, such lesion could have remineralized and reverted back to normal.
- Use of a sharp explorer tip within a pit and fissure can cavitate the enamel and actually create an opening through which cariogenic bacteria can penetrate.
- Use of an explorer has a low sensitivity and low specificity. This means an explorer used for diagnosis of caries may give false positives.

**Visual examination:** It is based on the criteria such as cavitation, surface roughness, opacification and discoloration of clean and dried teeth under adequate light source.

#### Advantage

Preferred over probing because of harmful effects of probing.

#### Disadvantages

- Very small lesion is difficult to detect.
- Discoloration of the pits and fissures which is found in normal healthy teeth, can be mistaken for the presence of caries.

#### Advances in Visual Method

##### Illumination

1. **Ultraviolet illumination:** The natural fluorescence of enamel as seen under UV light is decreased in areas of less mineral content such as carious lesion, artificial demineralization and developmental defects. The carious lesion appears as a dark spot against a fluorescent background.

##### Advantages:

- More sensitive method as compared to the visual tactile methods
- More reliable results.

##### Disadvantages:

- Difficult to differentiate developmental defects and caries.
- It is not a quantitative method.

2. **Ultrasonic imaging:** The demineralization of enamel is assessed by ultrasound pulse echo-technique.

**Advantage:** More sensitive than visual tactile method.

**Disadvantage:** It is not a quantitative method.

3. **Fiberoptic transillumination (FOTI):** Transillumination takes advantage of the opacity of a demineralized tooth structure over more translucent healthy structures. The decalcified area will not let light pass through as much

as it does in a healthy area, generating a shadow corresponding to decay.

*Advantages:*

- Noninvasive method
- Useful in patients with posterior crowding
- No radiation hazards
- Comfortable to patients

*Disadvantages:*

- Not possible in all anatomic locations
- Considerable intra- and inter-observer variation

4. *Digital imaging fiberoptic transillumination (DIFOTI):*

The light from the DIFOTI probe is positioned on the tooth to be assessed, then the tooth is illuminated and the resultant images are captured by a digital electronic charged coupled device camera (CCD) and sent to a computer where these are analyzed using proprietary algorithms. The illumination and imaging conditions are controlled and repeatable.

*Advantages:*

- Noninvasive
- DIFOTI provides clear signal of different types of frank caries
- Instant image projection
- Shows surface changes associated with early demineralization as early as two weeks

*Disadvantages:*

- Not able to measure the depth of the carious lesions
- Cannot differentiate dental caries and stained deep fissures.

## Radiographic Method of Diagnosis

Radiographs play an important role in diagnosis of the dental diseases.

The interpretation of radiographs should be done in a systematic manner. The clinician should be familiar with normal radiographic landmarks.

### Normal radiographic landmarks (Fig. 4.26)

- **Enamel:** It is the most radiopaque structure.
- **Dentin:** Slightly darker than enamel.
- **Cementum:** Similar to dentin in appearance.
- **Periodontal ligament:** Appears as a narrow radiolucent line around the root surface.
- **Lamina dura:** It is a radiopaque line representing the tooth socket.
- **Pulp cavity:** Pulp chamber and canals are seen as radiolucent lines within the tooth.

It is important to understand the radiographic appearance of carious lesions at various areas of the tooth

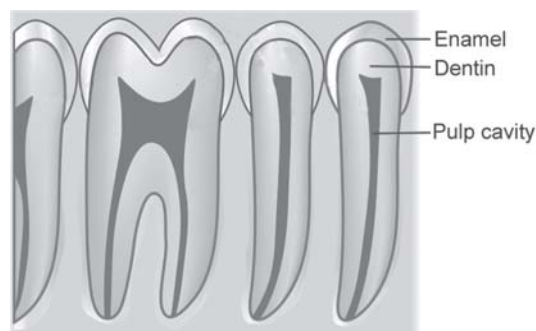


Fig. 4.26: Normal radiographic landmarks

surface before talking about the various radiographic techniques.

### Caries of Various Surfaces

**Caries of occlusal surfaces: Radiographic interpretation of occlusal caries** is possible only when the decay is more advanced in the dentin and where it has created a greater damage to the tooth integrity (Fig. 4.27).

Once in dentin, the classical radiographic appearance of a broad based thin radiolucent zone in the dentin with little or no change apparent in the enamel is seen.

**Caries of proximal surfaces:** Lesions confined to enamel may not be evident radiographically until approximately 30-40% demineralization has occurred (Fig. 4.28).

The shape of early radiolucent lesion in the enamel is a triangle with its broad base at the tooth surface. Once the lesion crosses the DEJ and invades into the dentin, it appears as another triangle with base at DEJ and apex towards the pulp chamber. Collectively, these may appear as two triangles with their bases facing towards the external surface.

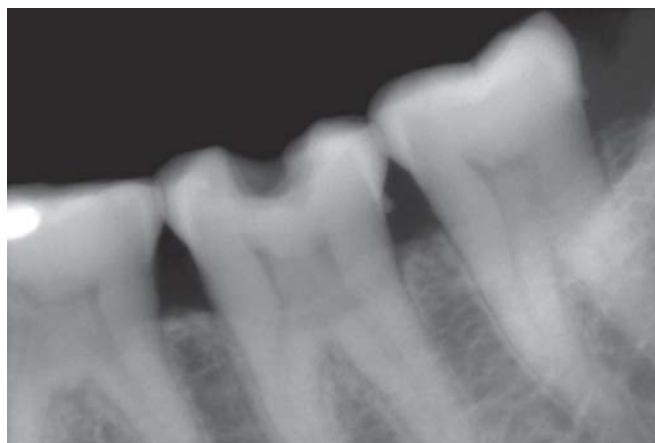
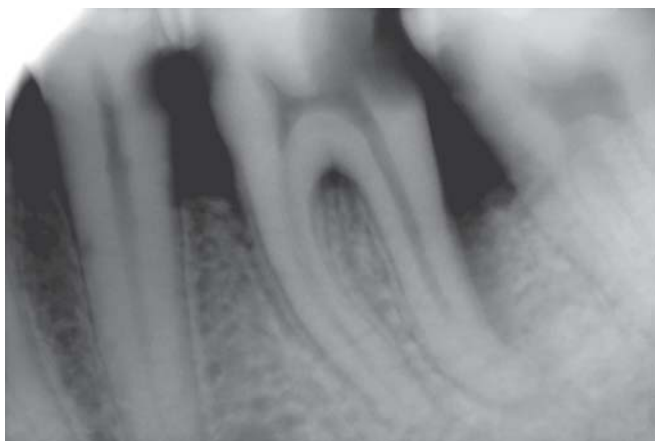
Fig. 4.27: Radiograph showing occlusal caries



**Fig. 4.28:** Radiograph showing proximal caries of molar

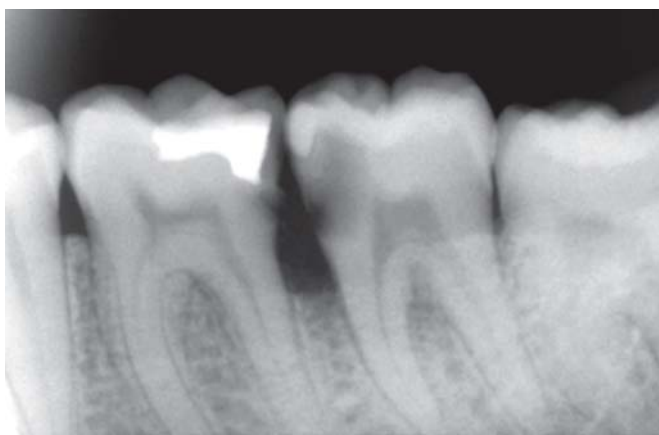Bitewing radiographs are preferably utilized to detect interproximal caries. Recurrent caries at cervical margins is best observed in bitewing films, since the central ray is directed along the plane of the cervical areas.

**Caries of buccal and lingual surfaces:** More than one radiographs are needed to diagnose because the buccal or lingual lesion may be superimposed on the DEJ and suggest occlusal caries.

**Root surface caries:** Should be detected clinically as radiographs are not needed for diagnosis.

#### Secondary Caries (Fig. 4.29)

- Radiographs may not be helpful until the lesion is at an advanced stage.
- Lesion next to a restoration may be obscured by the radiopaque image of the restoration.



**Fig. 4.29:** Radiograph showing secondary caries

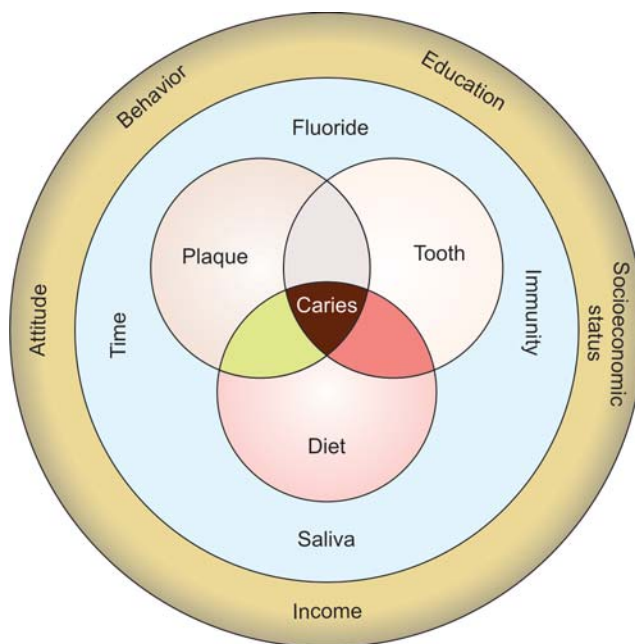
## CARIES RISK ASSESSMENT

The main objective of caries risk assessment in dentistry is to deliver preventive and restorative care specific to an individual patient. Various caries risk indicators are sociodemographic factors, such as education and income of parents, systemic and topical fluoride exposure, toothbrushing behavior, bottle use and dietary habits (**Fig. 4.30**).

In 1960s, Keyes has showed that there are three prerequisite factors for the development of dental caries, known as **Keyes's triad (Fig. 4.30)**. These factors are plaque, tooth and the diet. Later on many studies were conducted which extended Keyes model with many other factors affecting the interplay between these primary factors.

#### A patient is said to be at high caries risk if there is:

- One new lesion on smooth surface during past one year
- New carious lesion on root surface
- Patient on medication which causes hyposalivation
- Systemic disorder
- Past dental history with multiple restorations
- Exposure to sugary snacks for more than three times a day
- Senility.



**Fig. 4.30:** Factors affecting caries. Here plaque, tooth and diet are shown as three main prerequisites for caries development (Keyes's triad). Other factors modify the interplay between these factors



Following factors are commonly seen in patients with high-risk caries:

1. Status of oral hygiene
  - Poor oral hygiene
  - Non-fluoridated toothpaste
  - Low frequency of tooth cleaning
  - Orthodontic treatment
  - Partial dentures
2. Dental history
  - History of multiple restorations
  - Frequent replacement of restorations
3. Medical factors
  - Medications causing xerostomia
  - Gastric reflux
  - Sugar containing medications
  - Sjögren's syndrome
4. Behavioral factors
  - Bottle feeding at night
  - Eating disorders
  - Frequent intake of snacks
  - More sugary foods
  - Non-fluoridated toothpaste
5. Socioeconomic factors
  - Low education status
  - Poverty
  - No fluoride supplement.

## PREVENTION OF DENTAL CARIES

Method of dental caries control can be classified into two main types (Fig. 4.31):

### Methods to reduce demineralizing factors:

1. Dietary measures
2. Methods to improve oral hygiene
3. Chemical measures

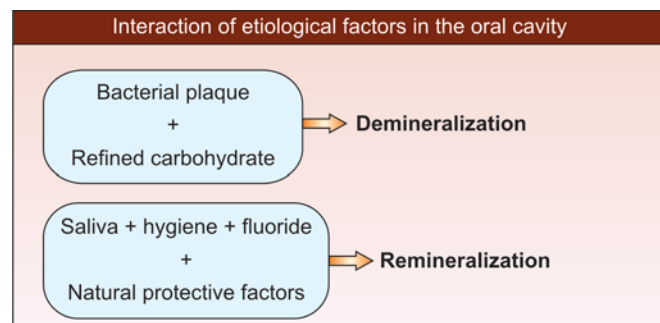


Fig. 4.31: Factors promoting demineralization and remineralization of the tooth surface

### Methods to increase protective factors:

1. Methods to improve flow, quantity and quality of saliva
2. Chemicals altering the tooth surface or tooth structure:
  - a. Fluorides
  - b. Iodides
  - c. Zinc chloride
  - d. Silver nitrate
  - e. Bisbiguanides
3. Application of remineralizing agents
4. Use of pit and fissure sealants.

## Methods to Reduce Demineralizing Factors

### Dietary Measures

Diet has been considered one of the main step in influencing the dental caries. Different nutritional substitutes are:

1. **Sugar substitutes:** (a) Xylitol (b) Sorbitol
 

**Xylitol** is non-fermen-table, noncariogenic sugar and has anticaries effects. Anticariogenic effects of xylitol:

  - Xylitol reduces plaque formation
  - It reduces bacterial adherence
  - It inhibits enamel demineralization
  - It has a direct inhibitory effect on *S. mutans*
  - Increases salivary flow
  - It is nonfermentable
  - It increases concentration of amino acids which neutralize the plaque acidity.

**Xylitol chewing gums** or lozenges used four times are effective anticaries therapeutic measures.
2. **Fibrous food:** It has been seen that intake of raw vegetables, fruits and grains increases caries protective mechanism as they contain natural phosphates, phytates and non- digestable fibers, moreover they do not stick to teeth.
3. **Low caloric sweeteners:** In this, several sweetener such as aspartame, saccharin and cyclamate considered to have some role.
4. **Fats:** Fats used to form a protective barrier on enamel or on carbohydrate surface so that it is less available for bacteria.
5. **Cheese:** Cheese is considered responsible for:
  - Increasing the salivary flow
  - Increasing the pH
  - Promoting the clearance of sugar.

All these factors help in reducing the incidence of caries.
6. **Trace elements**

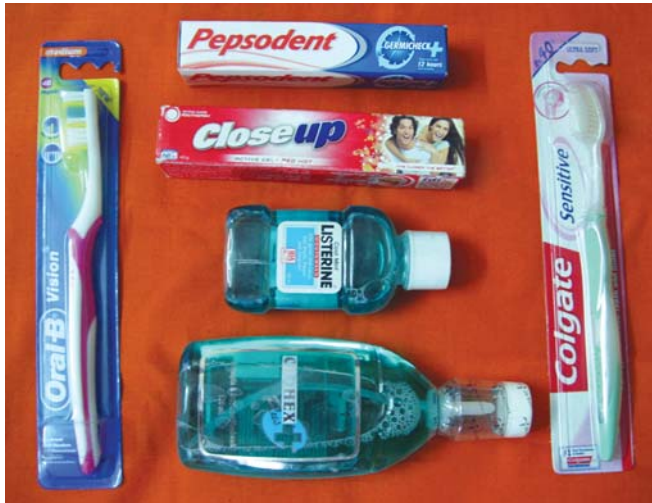

Fig. 4.32: Materials used for maintaining oral hygiene

Effect	Mineral
Cariostatic	Fluoride (F), phosphate (PO <sub>4</sub> )
Mild cariostatic	Fe, Li, Cu, B, Mo, V, Sr, Au
Doubtful	Co, Zn, Br, I
Caries inert	Al, Ni, Ba, Pd
Caries promoting	Mg, Cd, Pb, Si

**Methods to Improve Oral Hygiene (Fig. 4.32)**

Measures for preventing dental caries include the following:

- Dental prophylaxis
- Toothbrushing
- Interdental cleaning.

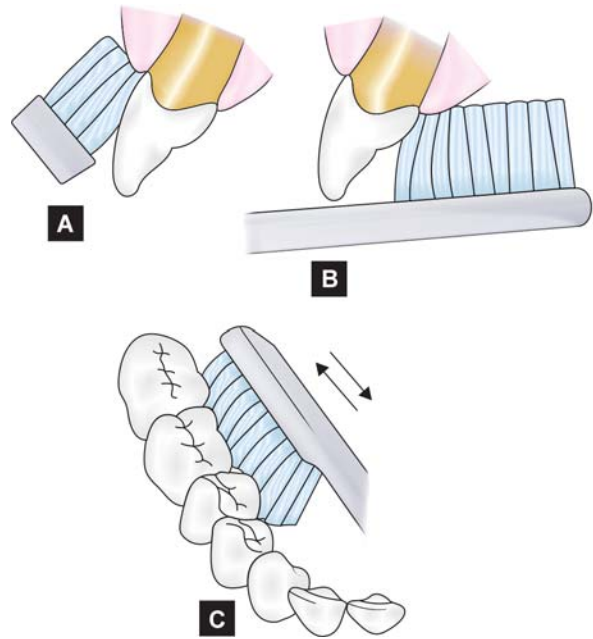
**Dental prophylaxis:** In dental prophylaxis, polishing of roughened tooth surfaces and replacement of faulty restorations is done so as to decrease the formation of dental plaque, therefore, resulting in less incidence of caries.

**Toothbrushing:** Toothbrushing is considered to be the most reliable means of controlling plaque and provide clean tooth surface.

Many toothbrushing techniques have been described and being promoted as being effective. Bass technique is most recommended as it emphasizes sulcular placement of bristles while in periodontal cases, sulcular technique with vibratory motion is preferred (Figs 4.33A to C).

**Interdental cleaning aids (Fig. 4.34):** Interdental cleaning devices can be (Figs 4.35A to C):

- **Dental floss and tape:** Used in persons with normal proximal contact between their teeth.

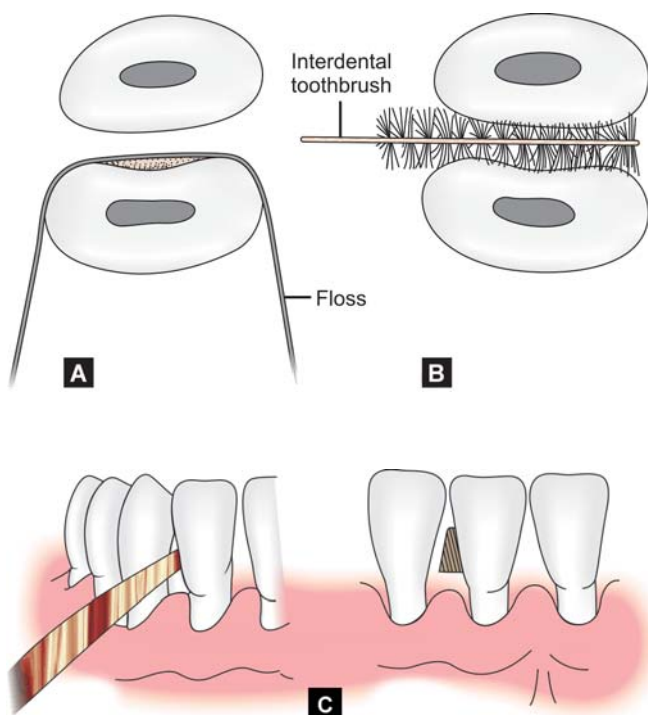


Figs 4.33A to C: Sulcular brushing (A) Keep the bristles in gingival sulcus at 45° to long axis of tooth, (B) Brushing on palatal surface, (C) Brushing on posterior teeth

- **Woodsticks and interdental brushes:** They are indicated in patients with wide interdental spaces because of gingival recession and/or loss of periodontal attachment.
- Other mechanical devices.

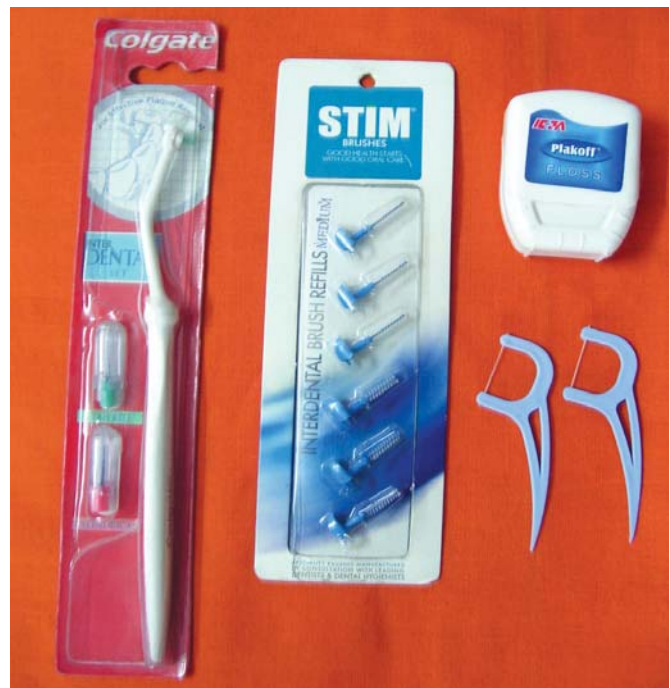

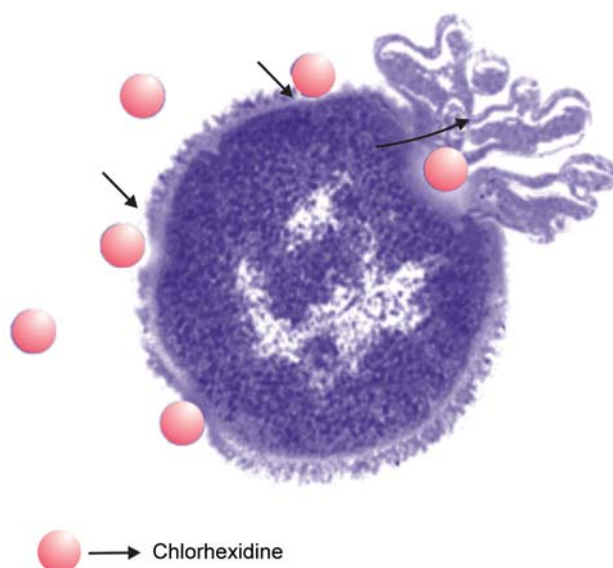
Fig. 4.34: Interdental cleaning aids



**Figs 4.35A to C:** Various interdental cleaning devices: (A) Dental floss, (B) Interdental brush, (C) Wooden stick

## Chemical Measures

1. **Substances interfering with carbohydrate degradation through enzymatic alterations**
  - a. **Vitamin K:** Vitamin K, synthetically made, has been found to prevent acid formation, when added in incubated mixtures of glucose and saliva.
  - b. **Sarcocide:** It has also been found to have some role in caries prevention.
2. **Substances interfering with bacterial growth and metabolism**
  - a. **Chlorhexidine:** Chlorhexidine has highly positive charge, which is responsible for reducing the number of *Streptococcus mutans* (**Fig. 4.36**).
  - b. **Urea and ammonium compounds:** Urea is usually degraded by urea which releases ammonia, neutralizes the acids and also interferes with bacterial growth.
  - c. **Glutaraldehyde:** It has been shown that a two minutes daily application of glutaraldehyde reduces mineral loss in dentin caries.



**Fig. 4.36:** Mechanism of action of chlorhexidine

## Methods to Increase Protective Factors

### Methods to Improve Flow, Quantity and Quality of Saliva

In patients with hyposalivation, the mouth rinse prepared by mixing two teaspoons of baking soda in eight oz of water is used.

### Chemicals Altering the Tooth Surface or Structure

1. **Fluorides:** Fluoride, inorganic component, is important part of natural diet for humans.

Fluoride ions increase the resistance of the hydroxyapatite in enamel and dentin to dissolution by plaque acids. The dentin requires higher levels of fluorides for remineralization (100 ppm) than enamel (5 ppm).

#### Fluoride reacts with enamel and dentin and produce different effects

1. Formation of fluoroapatite (less soluble than hydroxyapatite) (**Fig. 4.37**)
2. Inhibits demineralization
3. Induces remineralization
4. Inhibition of bacterial metabolism
5. Inhibition of plaque formation

**Clinical fluoride products:** These include:

- i. Professional topical fluorides
- ii. Fluoride varnishes
- iii. Mouthrinses

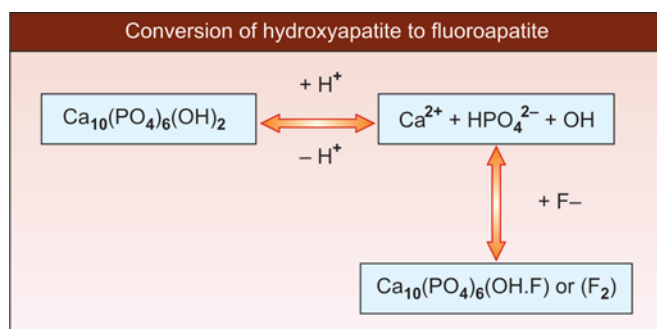


Fig. 4.37: Mechanism of action of fluorides

- iv. Dentifrices
  - v. Supplements in form of fluoride tablets and drops
  - vi. Fluoridated salt.
    - i. *Professional topical fluorides:*
      - 2.72% acidulated phosphate fluoride (APF) gel: It has 3.5 pH and contains 12,300 ppm fluoride.
      - 2% sodium fluoride gel: It contains 9200 ppm fluoride.

*Methods of use:*

      - a. Before using first determine total fluoride exposure of the patient.
      - b. Administer 0, 1, 2, 3, 4 times a year as indicated by caries risk level.
      - c. Isolate the teeth and apply gel for 4 minutes.
      - d. Advise patient to avoid rinsing, drinking or eating for 30 min after application.
    - ii. *Fluoride varnishes:* Duraflor (contains 5% NaF) and Florprotector (contains 0.7% silane fluoride)
    - iii. *Mouthrinses:* Daily rinsing with 0.05% NaF (226 ppm F) and once a week or use of 0.2% NaF (900 ppm F) once every two weeks has shown to effective.
    - iv. *Dentifrices:* Different sources of fluoride used in dentifrices are stannous fluoride ( $\text{SnF}_2$ ), sodium monofluorophosphate ( $\text{Na}_2\text{PO}_3\text{F}$ ), and sodium fluoride (NaF). All dentifrices are formulated to contain either 1000 or 1100 ppm fluoride by and large in the form of NaF and MFP.
    - v. *Fluoride supplements:* While prescribing the fluoride supplements (Fluoride tablets), the dosage must take into account and it should be scheduled according to patient need.
    - vi. *Fluoridated salt:* Concentration of fluoride in salt should depend on salt intake and the availability of fluoride from other sources.
2. **Silver nitrate:** Silver combines with soluble inorganic portion of enamel to form a less soluble combination.

**Remineralizing approaches:** Remineralizing agents are available in various forms like dentifrices, mouthwashes, chewing gums, lozenges, and foods and beverages. Various approaches have been employed to enhance the remineralization of teeth. These are:

1. Combining remineralizing agents with fluoride (to increase anticariogenicity of fluorides).
2. Combining remineralizing agents with a lower dosage of fluoride to decrease the possibility of dental fluorosis without losing effectiveness.
3. The use of remineralizing materials as independent agents as we know that even a small amount of fluoride can reverse early carious lesions by remineralization because of precipitation of calcium phosphates, and the formation of fluorohydroxyapatite in the tooth tissues.

Commonly used agents are calcium glycerophosphate and calcium lactate, dicalcium phosphate dihydrate (DCPD), and calcium carbonate. Recently, casein phosphopeptide (CPP), amorphous calcium phosphate (ACP) complexes have also been considered as agents for remineralization.

#### Mechanism of Action CPP-ACP

- CPP stabilize calcium phosphate in solution and increases the level of calcium phosphate. Thus, CPP-ACP nanocomplexes act as a reservoir of calcium and phosphate ions so as to have supersaturation state with respect to tooth enamel and buffer plaque pH.
- Provide ions for tooth remineralization.
- CPP-ACP inhibit caries by concentrating ACP in dental plaque, preventing demineralization and increasing remineralization.

#### Pit and Fissure Sealant

“A pit and fissure sealant is a material that is placed in the pits and fissures of teeth in order to prevent or arrest the development of dental caries.”

For better effects, sealants should be placed as soon as possible because of more susceptibility of caries during the posteruption period.

## CURRENT METHODS OF CARIES PREVENTION

### Genetic Modalities in Caries Prevention

In an attempt to produce the strains of *S. mutans* which can- not cause caries, various researches were conducted at genetic level to control caries. The genes for enzyme

glycosyl transferase were decoded, resulting new strains of *S. mutans* which lacked the capability to produce lactic acid responsible for caries.

### Genetically Modified Foods

The research have been carried out so to produce genetically modified foods in an attempt to prevent tooth decay. They can be given to patients with “high caries risk” as “probiotics”.

### Genetically Modified Organisms

A new strain of *S. mutans* has been created which lacks lactodehydrogenase gene, thus unable to produce lactic acid.

**Lactobacillus zae:** These are genetically modified bacteria which produce antibodies so as to attach to surface of *S. mutans* resulting in their death.

## Caries Vaccine

### Rationale of Caries Vaccine

1. Rationale for caries vaccine is that immunization with *S. mutans* should induce an immune response so as to prevent organisms from colonizing the tooth surface and thus prevent carious decay.
2. General public should be well exposed to vaccine.
3. Vaccine should be given before eruption of deciduous teeth so as to achieve maximum benefits.

## MANAGEMENT OF DENTAL CARIES

The restoration of a decayed tooth involves the use of a drill, low or high speed for preparation cutting. But nowadays other procedures have also been used for removal of caries like air abrasion, chemomechanical caries removal, atraumatic restorative therapy (ART) and latest with lasers.

## VIVA QUESTIONS

**Q. Define dental caries.**

**Q. Which bacteria cause dental caries?**

**Ans.** Dental caries is a multibacterial diseases in which single bacteria cannot be said as the causative factor, though

the most commonly associated bacterias with dental caries are *S. mutans* and *L. acidophilus*.

The causative microorganisms are aciduric (capable of living in acid environment) and acidogenic (capable of producing acid).

**Q. What is role of plaque in developing dental caries?**

**Ans.** Plaque is a tenacious membrane formed around the teeth, mainly consisting of microorganisms. These microorganisms produce acids which reduce pH of plaque, and dissolve mineral content of enamel and thus initiate caries.

**Q. If bacteria are present in mouth, will they initiate caries?**

**Ans.** For caries to occur, fermentable carbohydrates need to be present around the teeth so that bacteria can utilize food particles for energy by breakdown of carbohydrate molecules. This produces acids byproducts which initiate the dental caries.

**Q. What are most commonly affected parts of teeth?**

**Ans.** – Deep pits and fissures  
– Gingival recession cases  
– Below contact area.

**Q. Classify dental caries.**

**Q. What are pit and fissure caries?**

**Q. What are acute and chronic caries?**

**Q. What are rampant caries?**

**Q. What are arrested caries?**

**Q. What are smooth surface caries?**

**Q. What is difference between affected and infected dentin?**

**Q. What are residual caries?**

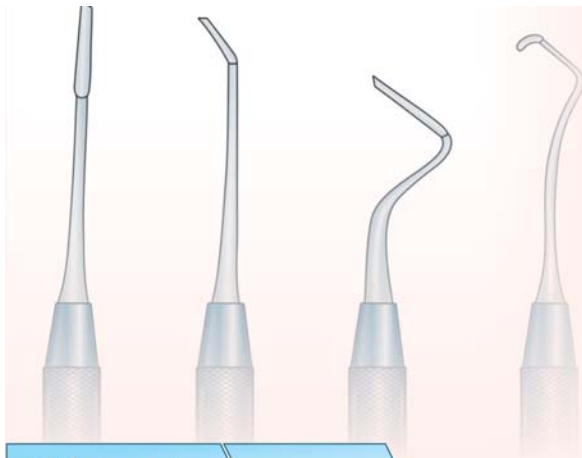
**Q. What are different ways of preventing caries?**

**Q. What are forward and backward caries?**

**Q. What is Graham Mount’s Classification of caries?**

**Q. What are different ways of preventing caries?**

**Q. What is role of fluorides in caries prevention?**



# Cutting Instruments

## Chapter 5

### INTRODUCTION

- Metals Used for Manufacturing Cutting Instruments
- Heat Treatment of Materials

### CLASSIFICATION OF HAND CUTTING INSTRUMENTS

- Classification Given by GV Black
- Classification Given by Marzouck
- Nomenclature for the Instruments

### PARTS OF HAND CUTTING INSTRUMENTS

- Handle or Shaft
- Shank
- Blade or Nib
- Instrument Formula
- Bevels in Cutting Instruments
- Instrument Motions

### EXPLORING INSTRUMENTS

- Mouth Mirrors
- Explorer
- Tweezers
- Periodontal Probes

### HAND CUTTING INSTRUMENTS

- Instrument Families
- Chisels
- Angle Former
- Cleiod-discoid
- Hatchet
- Spoon Excavator
- Gingival Margin Trimmer (GMT)

### RESTORATION INSTRUMENTS

- Cement Spatulas
- Plastic Filling Instrument

- Condensers
- Amalgam Carriers
- Carvers
- Burnisher
- Composite Resin Instruments

### INSTRUMENT GRASPS

- Modified Pen Grasp
- Inverted Pen Grasp
- Palm and Thumb Grasp
- Modified Palm and Thumb Grasp

### FINGER RESTS

### SHARPENING OF HAND INSTRUMENTS

- Goals of Sharpening
- Advantages of Sharp Instruments
- Principles of Sharpening
- Devices Used for Sharpening
- Guidelines for Sharpening Operative Instruments

### ROTARY CUTTING INSTRUMENTS

- Types of Rotary Cutting
- Handpieces
- Dental Burs
- Factors Affecting Cutting Efficiency of Bur

### RECENT ADVANCES IN ROTARY INSTRUMENTS

- Fiberoptic Handpiece
- Smart Prep Burs
- Chemical Vapor Deposition (CVD) Diamond Burs
- Fissurotomy Burs

### ABRASIVE INSTRUMENTS

- Diamond Abrasive Instruments
- Other Abrasive Instruments

- Finishing and Polishing Instruments
- Advantages of Bur Cutting
- Disadvantages

## ULTRASONIC INSTRUMENTS

### HAZARDS AND PRECAUTIONS WITH ULTRASPEED CUTTING INSTRUMENTS

- Pulpal Damage
- Damage to Soft Tissue
- Damage to Ear
- Inhalation Problems
- Eye Injuries

## INTRODUCTION

For preparation of tooth, cutting the tooth tissue and for other operative procedures wide range of specific instruments is required which can be hand or/and rotary. Rotary instruments help in gross cutting and final refining of the preparation whereas hand instruments are used for examination, producing minor details of the tooth preparation and for insertion, compaction and finishing of the restoration. One must be able to use both hand and rotary instruments judiciously so as to perform the operative procedures accurately. In this chapter we will discuss different types of instruments and instrumentation techniques used in operative dentistry.

In Lilian Lindsay's English translation of 1946, it has been shown that most preparation was carried out by hand instruments. Fauchard advocated the use of the manually operated bow drill, an unwieldy device widely used in the early 18th century and adapted by dentists from the workshops of jewellers, silversmiths and ivory turners. George Greenwood, modified spinning wheel for use as footoperated dental engine in 1790. The first commercially manufactured footpowered engine was patented by Morrison in 1871.

Black described hand instruments as chisels, hatchets, hoes, excavators and margin trimmers—terms which might have been taken from wood working and gardening.

## Metals Used for Manufacturing Cutting Instruments

Carbon steel or stainless steel are most commonly used for manufacturing of cutting instruments.

### The Carbon Steel

Carbon steel alloy contains 0.5 to 1.5% carbon in iron. Instruments made from carbon steel are known for their hardness and sharpness. But disadvantages with these instruments are their susceptibility to corrosion and the fracture of instrument if dropped. They are of two types:

1. **Soft steel:** It contains < 0.5% carbon
2. **Hard steel:** It contains 0.5-1.5% carbon

### Stainless Steel

Stainless steel alloy contains 72 to 85% iron, 15 to 25% chromium and 1 to 2% carbon. Instruments made from stainless steel remain shiny bright because of deposition of chromium oxide layer on the surface of the metal and chromium reduces the tendency to tarnish and corrosion. Problem with stainless steel instruments is that they tend to lose their sharpness with repeated use, so they need to sharpened again and again.

## Heat Treatment of Materials

For gaining maximum benefits from instruments made from carbon or stainless steel, they are subjected to two heat treatments—hardening and tempering heat treatment.

- **Hardening heat treatment:** In this, instrument is heated to 815°C in oxygen free environment and then quenched in a solution of oil. By hardening treatment, the alloy becomes brittle.
- **Tempering heat treatment:** In this, instrument is heated at 176°C and then quenched in solutions of oil, acid or mercury. Tempering heat treatment is done to relieve the strains and increase the toughness of alloy.

## CLASSIFICATION OF HAND CUTTING INSTRUMENTS

### Classification Given by GV Black

This classification is based according to use of the instrument.

#### 1. *Cutting instruments*

- |              |           |
|--------------|-----------|
| a. Hand      | b. Rotary |
| • Hatchets   | • Burs    |
| • Chisels    | • Stones  |
| • Hoes       | • Others  |
| • Excavators |           |
| • Others     |           |

#### 2. *Condensing instruments*

##### *Pluggers*

- Hand
- Mechanical

3. **Plastic instruments**
  - Plastic filling instrument
  - Cement carriers
  - Carvers
  - Burnishers
  - Spatulas
4. **Finishing and polishing instruments**
  - a. Hand
    - Orangewood sticks
    - Polishing points
    - Finishing strips
  - b. Rotary
    - Finishing brushes
    - Mounted brushes
    - Mounted stones
    - Rubber cups
5. **Isolation instruments**
  - Rubber dam frame clamps, forceps and punch
  - Saliva ejector
  - Cotton roll holder
  - Evacuating tips and equipment
6. **Miscellaneous instruments**
  - Mouth mirrors
  - Explorers
  - Probes
  - Scissors
  - Pliers
  - Others

### Classification Given by Marzouk

This classification is based upon different procedures performed by different instruments.

1. **Exploring instruments**
  - Tweezers/cotton pliers
  - *Retractors*: Mouth mirror, blunt bladed restoring instruments, plastic instruments, tongue depressors
  - *Probes/Explorers*: Straight, right angled, arch explorer, interproximal explorer.
  - Separators
2. **Instruments for tooth structure removal**
  - a. **Hand cutting instruments**
    - *Excavators*: Hatchet, hoes, spoon, discoid, cleoid, angle formers.
    - *Chisels*: Straight, monoangle, biangle and triple angle.
    - *Special forms of chisel*: Enamel hatchets, gingival marginal trimmers, Wedelstaedt chisel, offset hatchets, triangular chisel and hoe chisel.
  - b. **Rotary cutting and abrasive instruments**
    - Handpieces
    - Burs
    - Ultrasonic instruments
3. **Restoring instruments**
  - *Mixing instruments*: Stainless steel or plastic spatulas
  - Plastic instruments

- *Condensing instruments*: Rounded, triangular, diamond, or parallelogram condensers.
  - *Burnishing instruments*: Ball/egg/conical-shaped burnishers
  - *Carvers*: Hollenback's discoid and cleoid, diamond shaped carvers
  - *Files*: Hatchet/parallelogram-shaped
  - *Knives*: Bard parker knife and Stein's knife.
4. **Finishing and polishing instruments**: Burs, stones, brushes, rubber (wheel, cups or cones), cloth or felt.

### Nomenclature for the Instruments

Dr GV Black has given a way to describe instruments for their easier identification similar to biological classification.

1. **Order**: Function or purpose of the instrument, e.g. excavator, condenser.
2. **Suborder**: Position, mode or manner of use, e.g. push, pull.
3. **Class**: Design or form of the working end, e.g. hatchet, spoon excavator.
4. **Subclass**: Shape of the shank, e.g. binangle, contra-angle.

These names are combined to give a complete description of the instrument. Naming of an instrument generally moves from 4 to 1. Sometimes, the suborder is omitted due to variable and nonspecific use of the instrument. For example, the instrument will be named according to the classification as biangle enamel hatchet or biangle spoon excavator.

### PARTS OF HAND CUTTING INSTRUMENTS

Though there is great variation among hand cutting instruments, they have certain design features in common.

**Each hand instrument is composed of three parts (Figs 5.1A and B)**

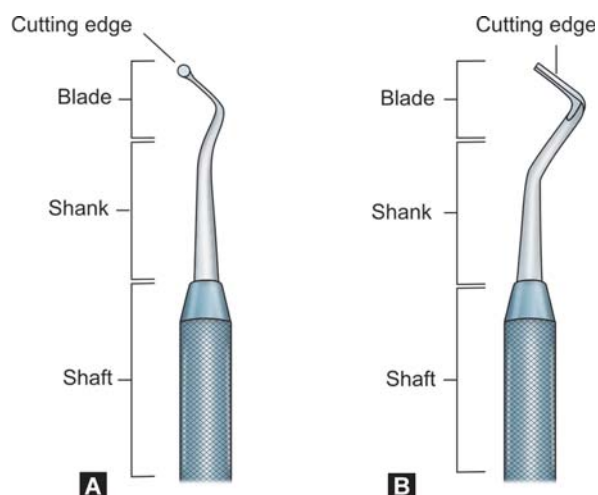
1. Handle or shaft
2. Shank
3. Blade or nib

### Handle or Shaft

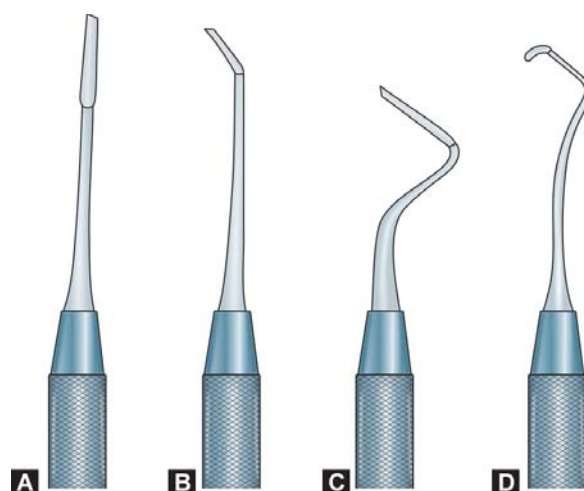
The handle is used to hold the instrument. The handle can be small, medium or large, smooth or serrated for better grasping and developing pressure (**Figs 5.2A to C**). Earlier, instruments had handles of quite large diameter and were to be grasped in the palm of the hand.

Nowadays, instrument handles are smaller in diameter for ease of their use. On the handle, there are two numbers; one is the instrument formula, which describes the dimensions and angulation of the instrument, the other number is the manufacturer's number which is used for ordering purposes.

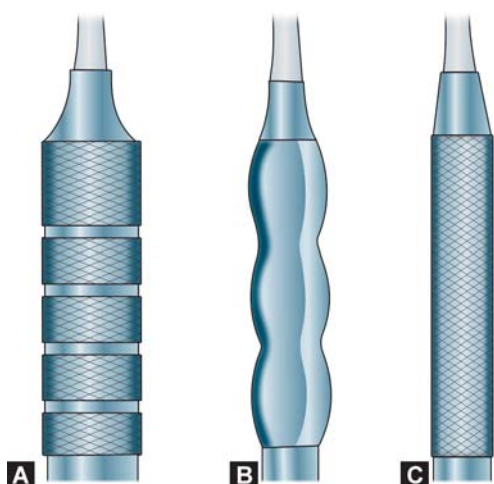




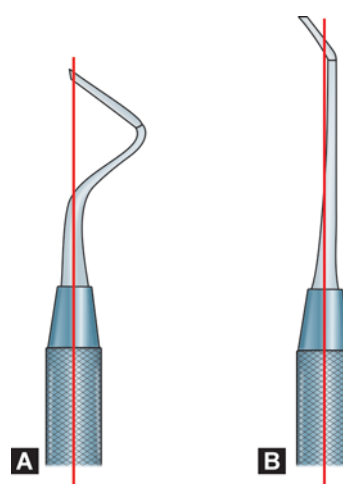
**Figs 5.1A and B:** Parts of a hand instrument



**Figs 5.3A to D:** Instruments with different shank angles



**Figs 5.2A to C:** Different designs of instrument handle for better grasping



**Figs 5.4A and B:** Balancing of instrument (A) Working end of instrument lies within 2-3 mm to long axis of handle, this provides balancing, (B) Working end is away from long axis of handle, this is not balanced

## Shank

Shank connects the handle to the blade. It tapers from the handle down to the blade and is normally smooth, round or tapered. The shank may be straight or angled.

Based on number of shank angles (**Figs 5.3A to D**), instruments can be classified as:

1. **Straight:** Shank having no angle.
2. **Monoangle:** Shank having one angle.
3. **Biangle:** Shank having two angles.
4. **Triple angle:** Shank having three angles.

The angulation of instrument is provided for access and stability. Closer the working point to the long axis of the handle, better will be the control on it. For better control, the working point should be preferably within 3 mm of the center of the long axis of the handle (**Figs 5.4A and B**).

## Blade or Nib

The blade is the last section. It is the working part of the instrument. It is connected to the handle by the shank. For non-cutting instruments, the working part is termed the nib and is used to place, adapt and condense the materials in the prepared tooth. Depending on the materials being used, the surface of the nib may be plain or serrated. To cleave and smoothen the enamel and dentin, the working point of the instrument is beveled to create the cutting edge. If instrument has blade on both the ends of the handle, it is known as “double-ended” instrument. In such cases, one end is for the left side and other for the right.

In some instruments, there are three bevels. Two are on the side and one is at the end. The edge on the end is called the primary cutting edge and the edges on the sides are called the secondary cutting edges.

### Instrument Formula

GV Black established an instrument formula for describing dimensions of blade, nib or head of instrument and angles present in shank of the instrument (**Fig. 5.5**). The formula is usually printed on the handle consisting of a code of three or four numbers separated by spaces.

The first number of the formula indicates width of the blade or primary cutting edge in tenths of a millimeter (**Fig. 5.6**).

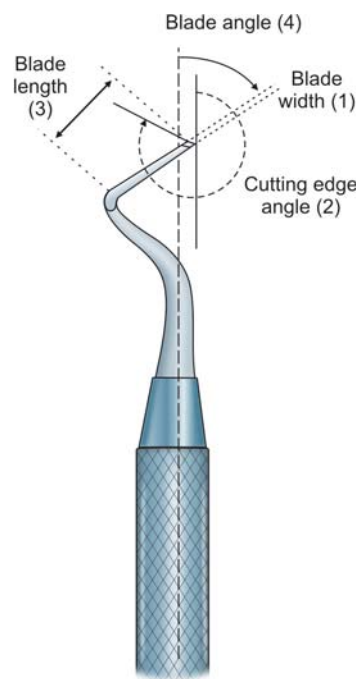
The second number represents the angle formed by the primary cutting edge and long axis of the instrument handle in clockwise centigrade. The instrument is positioned in such a way that the number always exceeds 50 and is measured in clockwise centigrades. If the cutting edge is at right angle to the length of the blade, then this number is omitted.

The third number (second number in three number code) represents the length of the blade in millimeters, that is, from the shank to the cutting edge (**Fig. 5.7**).

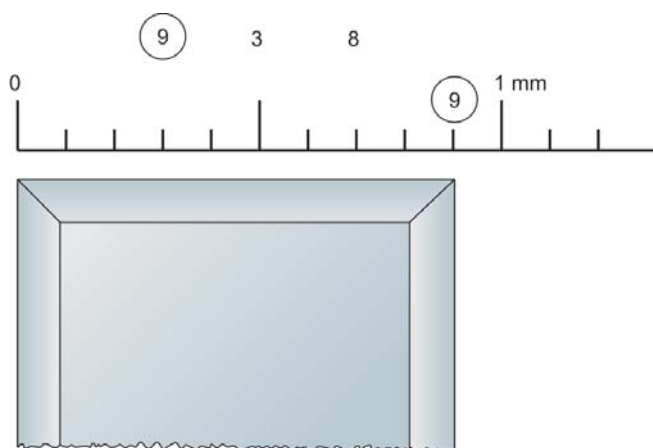
The fourth number (third number in three number code) represents the angle which the blade forms with the long axis of the handle or the plane of the instrument in clockwise centigrade. To calculate the measurement of the angle, place the instrument on the center of the circle and move it until the blade lines up with one line on the ruler. This measurement represents the angulation of the blade from the long axis of the handle. To keep balance during working, tip of blade is brought in the line of the long axis of the handle.

#### Example:

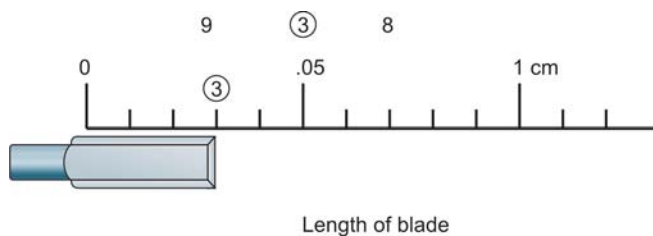
1. An instrument having instrument formula of 15-8-14 indicates following:
  - 15 represents the width of the blade in tenths of a millimeter, i.e. 1.5 mm.
  - 8 represents the length of the blade in millimeters, i.e. 8 mm.
  - 14 represents the blade angle in centigrades.
2. Instrument with formula 15-95-8-12 represents the following:
  - 15 represents width of the blade in tenths of a millimeter, i.e. 1.5 mm.
  - 95 represents the cutting edge angle in centigrades.
  - 8 represents length of the blade, i.e. 8 mm.
  - 12 represents blade angle in centigrades.



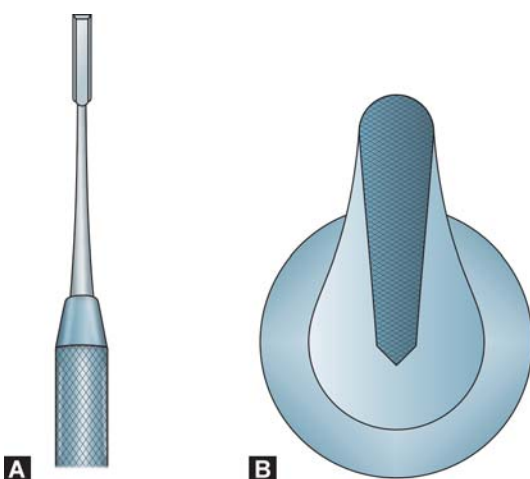
**Fig. 5.5:** Instrument formula



**Fig. 5.6:** First digit of formula indicates width of blade in 1/10th of a millimeter



**Fig. 5.7:** Third number indicates length of blade in millimeters



**Figs 5.8A and B:** Different bevels of an instrument  
(A) Straight chisel with single bevel, (B) Bibeveled instrument

## Bevels in Cutting Instruments

### Single Bevel Instruments

Most of the instruments have single bevel that forms the primary cutting edge. These are called single beveled instruments. These can be right or left bevel and mesial or distal bevel instruments (**Figs 5.8A and B**).

**Right and left bevel instruments:** Single-beveled direct cutting instruments such as enamel hatchets are made in pairs having bevels on opposite sides of the blade. These are named as right and left bevel instruments. During use, move the instrument from right to left in right beveled instrument and from left to right in left bevel instrument.

**Identification of bevel:** Hold the instrument in such a way that the primary cutting edge faces downwards and pointing away from operator. If bevel is on the right side of the blade, the instrument is right sided and if bevel is on the left side of the blade the instrument is left sided.

**Mesial and distal bevel instrument:** If we observe the inside of the blade curvature and the primary bevel is not visible then the instrument has a distal bevel and if the primary bevel can be seen from the similar viewpoint the instrument has a mesial or reverse bevel.

### Bibeveled Instrument

If two additional cutting edges extend from the primary cutting edges, then the instrument with secondary cutting edges is called bibeveled instrument.

### Triple-beveled Instrument

If three additional cutting edges extend from the primary cutting edge, then the instrument is called triple-beveled instrument.

## Instrument Motions

**Pulling:** Here, instrument is moved towards operator's hand.

**Scraping:** Here, instrument is move side-to-side or back and forth on the tooth surface.

**Pushing:** Here, instruments is moved away from operator's hand.

**Cutting:** Here, instrument is used parallel to the long axis of handle.

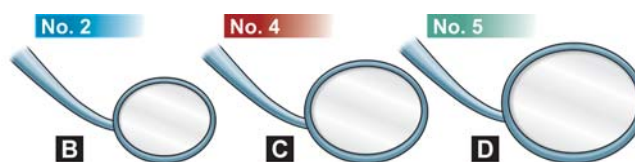
## EXPLORING INSTRUMENTS

### Mouth Mirrors

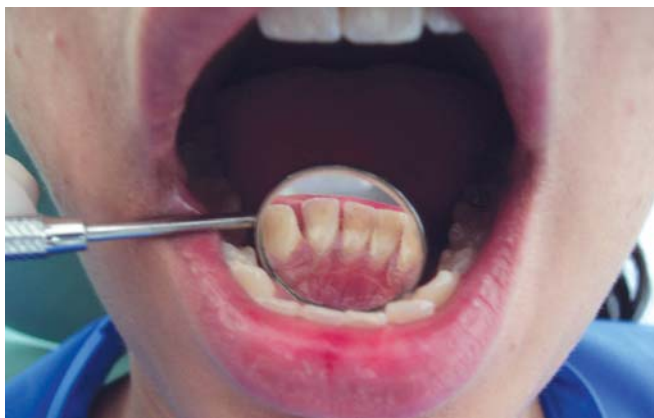Mouth mirrors are used as supplement to improve access to instrumentation (**Figs 5.9A to D**).

#### Types of Mirror Faces

1. a. Front surface reflecting mirror  
b. Rear surface reflecting mirror
2. a. Plane or flat surface  
b. *Concave surface:* Reflecting surface on the front of lens and produce a clear image. It is mirror of choice
3. a. One sided—image on one side  
b. Two sided—image on either side (Advantage—retraction with indirect vision simultaneously).



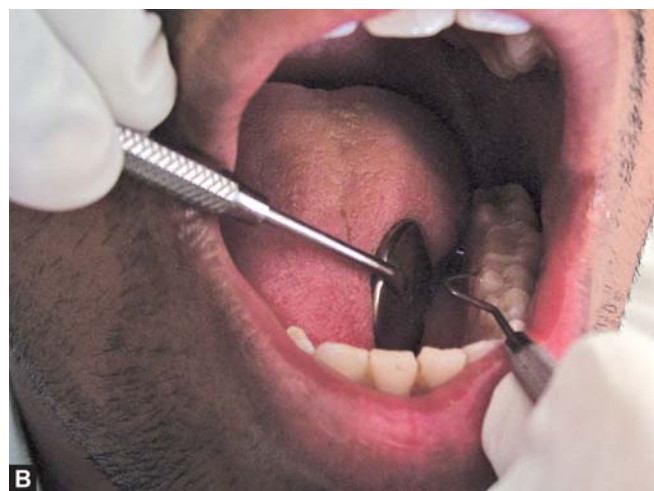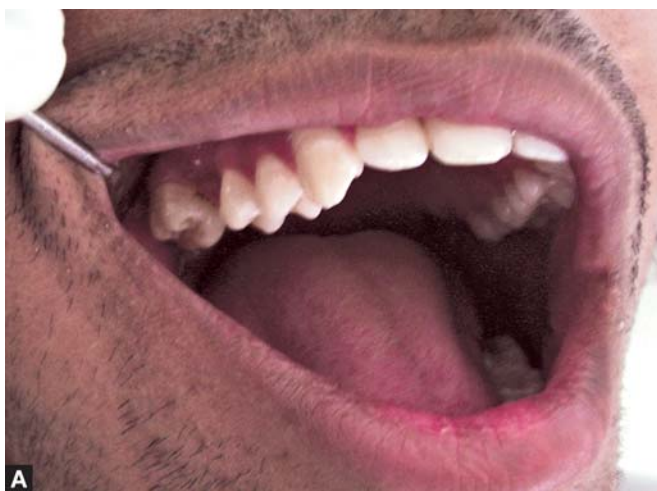**Figs 5.9A to D:** (A) Photograph showing mouth mirror (B to D) Different sizes of mouth mirrors



**Fig. 5.10:** Mirror used for indirect vision of lingual surfaces of mandibular anterior teeth

#### Uses of Mouth Mirror

- **Direct vision:** Retraction is done with mirror to enhance visibility in specific area. Illumination allows the dentist to use mirror a spotlight to reflect light from dental light on to a specific area of oral cavity. For example, use in maxillary left palatal aspect.
- **Indirect illumination:** In this, mirror is placed in oral cavity that cannot be seen directly without compromising dentist's position. For example, use in maxillary right palatal area and for palatal surfaces of anterior teeth (**Fig. 5.10**).
- **Transillumination:** Mirror is placed behind the teeth and direction of light perpendicular to long axis of teeth.
- **Retraction:** Retraction of soft tissue such as tongue and cheeks to aid in better visualization of the operating field (**Figs 5.11A and B**).



**Figs 5.11A and B:** (A) Mirror helps in retraction of cheek, (B) Tongue can be retracted using mirror

#### Uses of mouth mirror

- Direct vision
- Indirect illumination
- Retraction
- Transillumination

#### Explorer

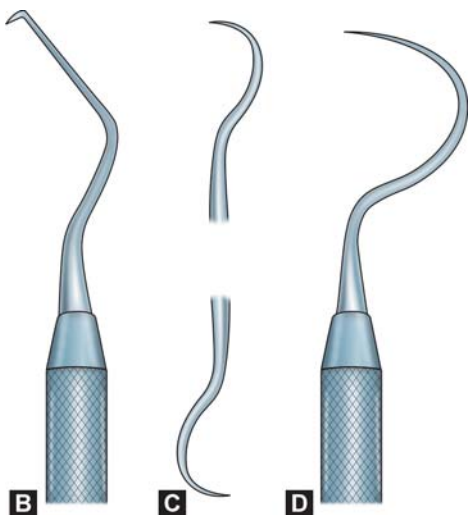
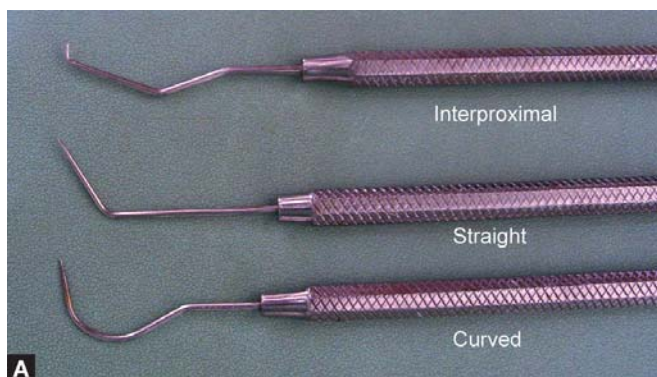
Explorer is commonly used as a diagnostic aid in evaluating condition of teeth especially pits and fissures (**Figs 5.12A to D**).

#### Parts

- Handle of explorer is straight which could be plain or serrated.
- Shank of explorer is curved with one/more angle.
- Working tip of explorer is pointed.

#### Types of Explorer

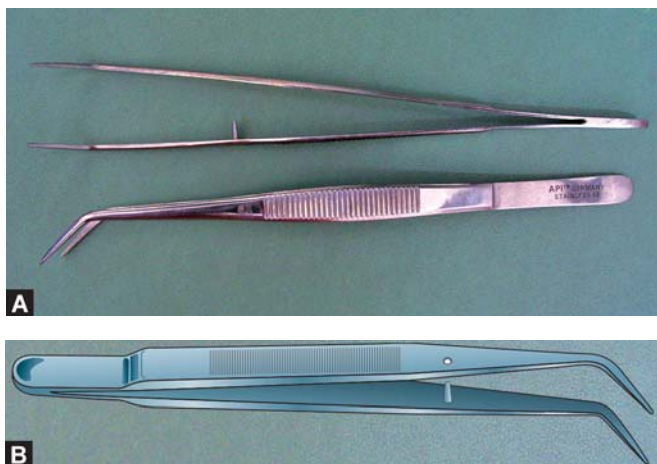- **Straight explorer:** It is bent perpendicular to the handle. This is used for examining occlusal surfaces of teeth.
- **Shepherd's Crook or curved explorer:** It has semilunar-shaped working tip perpendicular to the handle. This is used for examining occlusal surfaces.
- **Interproximal explorer/Briault explorer/Back action probe:** Commonly used for examination of interproximal surfaces of teeth, this explorer has two more angles in the shank with working tip-pointed towards the handle.



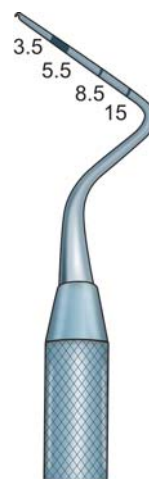**Figs 5.12A to D:** Different types of explorers

### Tweezers

These have angled tip and are available in different sizes (**Figs 5.13A and B**). They are used to place and remove cotton rolls and other small materials.



**Figs 5.13A and B:** (A) Tweezers, (B) Diagrammatic representation of tweezers



**Fig. 5.14:** Periodontal probe

### Periodontal Probes

Though they almost look like explorers but they have blunt end which is marked with graduations (**Fig. 5.14**). They are used for measuring pocket depth and tooth preparations.

## HAND CUTTING INSTRUMENTS

### Instrument Families

Many dental procedures require the use of hand instruments with sharp cutting edges. They are used in the tooth preparation procedures for amalgam, composite and other restorations. All instruments can be basically divided into two families:

- **The chisel family** consisting of chisel, hoe, angle former and cleoid-discoid.
- **The hatchet family** consisting of hatchet, gingival margin trimmer and spoon excavator.

### Chisels

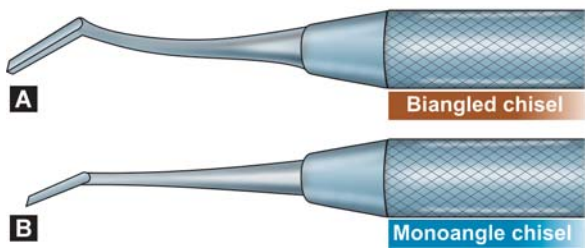
Chisels are used for cleaving, planing and lateral scraping. In other words, they are used to split tooth enamel, to smooth preparation walls and to sharpen the preparations. Chisels are used with a push motion.

#### Straight Chisel

In straight chisel, the cutting edge of the chisel makes a 90° angle to the plane of the instrument. It is used for gingival restoration of the anterior teeth (**Fig. 5.15**).



**Fig. 5.15:** Chisel



**Figs 5.16A and B:** Angled chisels; (A) Biangled, (B) Monoangle chisel

### Angled Chisel

In angled chisels, the primary cutting edge is in a plane perpendicular to the long axis of the shaft and may have either a mesial or distal bevel. They are used with a push or pull motion for anterior proximal restorations, smoothing proximal walls and gingival walls for full coverage restorations (**Figs 5.16A and B**).

The two most common types used in operative dentistry are the Wedelstaedt and biangle chisels (**Fig. 5.17**). The Wedelstaedts have slightly curved shanks. They are mainly used on anterior teeth. The biangle chisels have two different angles—one at the working end and other at the shank. This design permits access to tooth structures which are not possible with straight chisels.

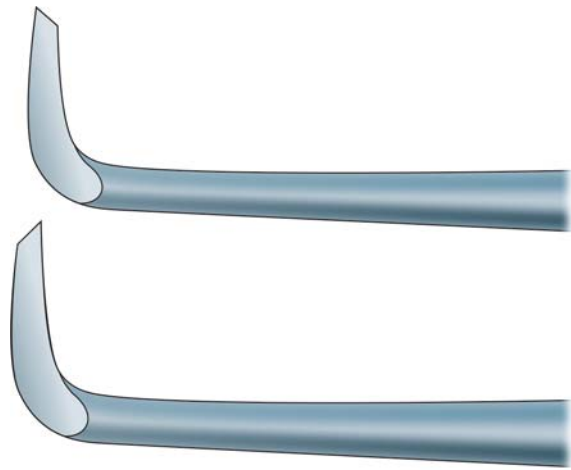
**Hoes:** Dental hoes resemble a miniature garden hoe. By definition, the hoe is any instrument where the blade makes more than a 12.5° angle with the plane of the instrument (**Fig. 5.18**). Commonly hoe blades make 45 to 90° angle to the long axis of handle. Its shank can have one or more angles (**Figs 5.19A and B**). Hoe is used with a pulling motion. Hoe is used to smooth and shape the floor and form line angles in class III and V restorations.

#### Chisel vs Hoe

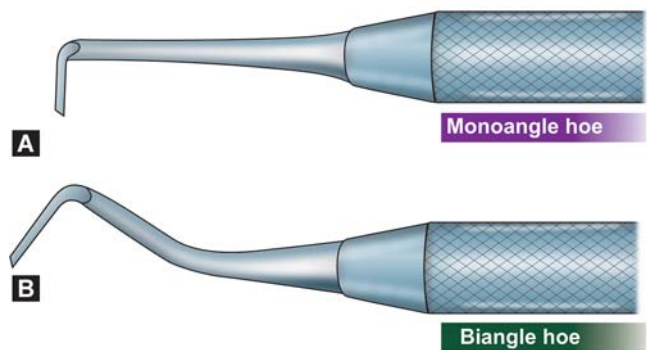
By definition chisel is an instrument where the blade makes up to 12.5° angle with the plane of the instrument, whereas in hoe, the blade is angled more than a 12.5° with the plane of the instrument.



**Fig. 5.17:** Wedelstaedt chisel



**Fig. 5.18:** Hoe



**Figs 5.19A and B:** Monoangle and biangle hoe

### Angle Former

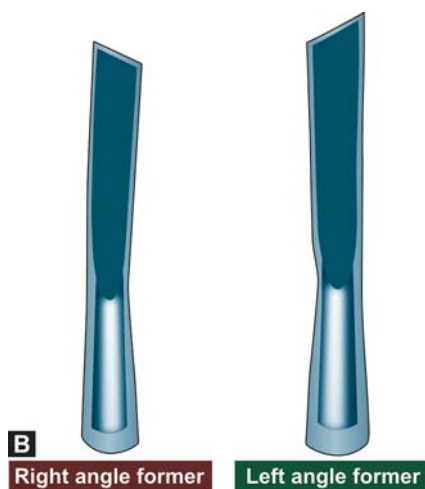
Angle former is a type of excavator which is monoangled with the cutting edge sharpened at an angle to the long axis of the blade. Angle of cutting edge to blade axis lies between 80 to 85 centigrades (**Figs 5.20A and B**). Blade of angle former is beveled on sides as well as the end, this forms three cutting edges. It is used with a push or pull motion for accentuating line and point angles, to establish retention form in direct filling gold restoration.

There are two sets of angle formers, mesial and the distal angle former. Each instrument in the set is a double-ended instrument.

The mesial angle former is used to plane the gingival cavosurface margin in the mesial proximal box. The distal angle former is used to plane the gingival cavosurface margin in the distal proximal box.

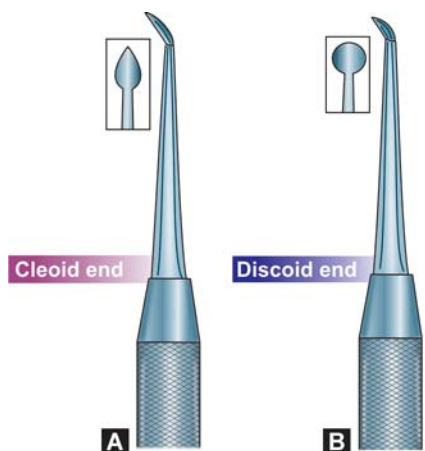
### Cleiod-discoid

It is modified chisel with different shape of cutting edges (**Figs 5.21A and B**). In cleoid, it is claw-like and in discoid

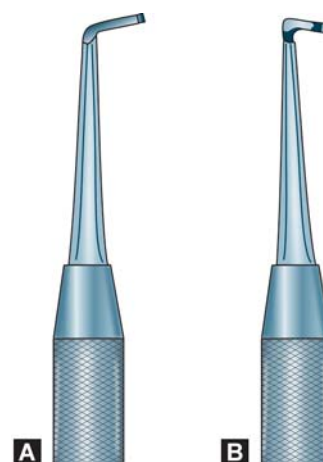


**Figs 5.20A and B:** Angle formers

it is disk-like, instead of a sharp edge, the edge is rounded. These instruments have sharp cutting edges as spoon excavators but blade to shaft relationship is similar to chisels. They are used for removing caries and carving amalgam or wax patterns.



**Figs 5.21A and B:** Cleoid-discoid



**Figs 5.22A and B:** Hatchet

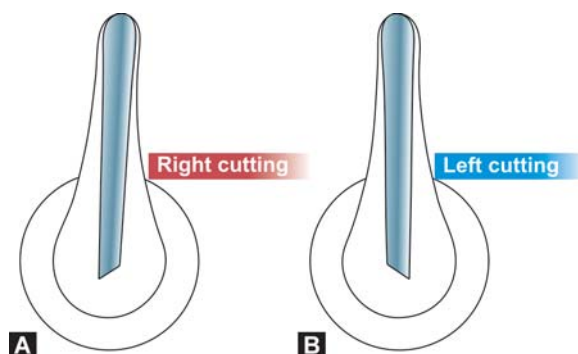
### Hatchet

Any instrument where the cutting edge is parallel or close to parallel to the plane of the instrument is called a hatchet. Basically, a hatchet is similar to an axe except that it is much smaller (**Figs 5.22A and B**).

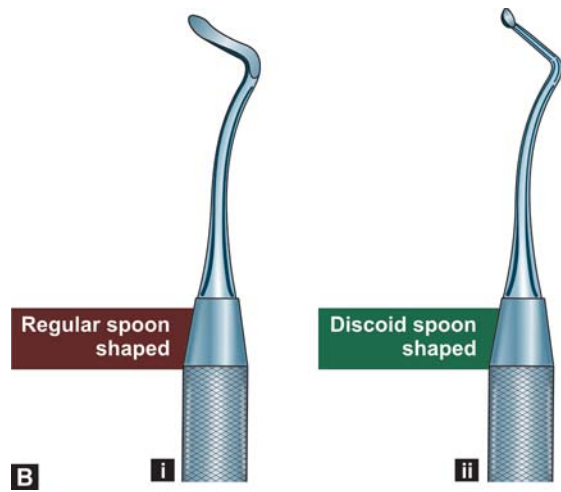
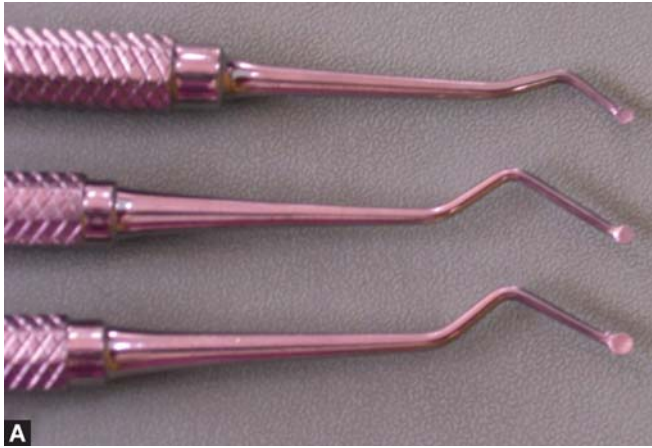Hatchet is a paired instrument in which blades make 45 to 90° angle to the shank. In paired right and left hatchets blades are beveled on opposite sides to form their cutting edges (**Figs 5.23A and B**).

Some hatchets have single cutting ends and some have cutting edges on both ends of the handle. Hatchets are used for cleaving enamel and planning the dentinal walls so as to have sharp outline of the preparation.

Some hatchets are bibeveled, i.e. blade has two bevels with cutting edge in the center. These bibeveled biangle hatchets are used in a chopping motion to refine line and point angles.



**Figs 5.23A and B:** Right and left cutting hatchets



**Figs 5.24A and B:** Spoon excavators; (i) Regular spoon shaped, (ii) Discoid spoon shaped

### Spoon Excavator

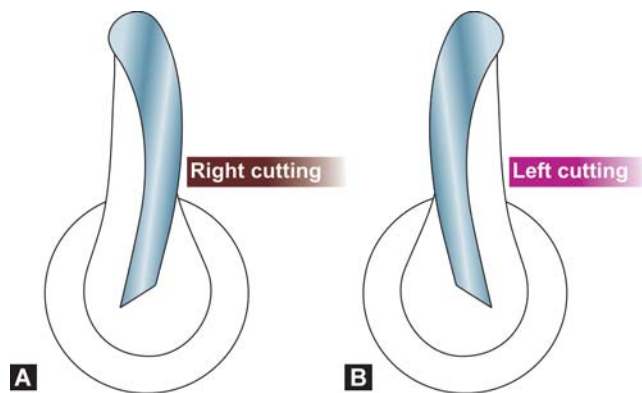
The spoon excavator is a modified hatchet. It is a double-ended instrument with a spoon, claw, or disk-shaped blade (**Figs 5.24A and B**). Spoon excavator is used to remove caries and debris in the scooping motion from the carious teeth.

#### Two main differences between the spoon excavator and hatchet

1. The blade of a spoon excavator is curved to emphasize the lateral scraping motion.
2. The cutting edge of the spoon excavator is rounded.

### Gingival Margin Trimmer (GMT)

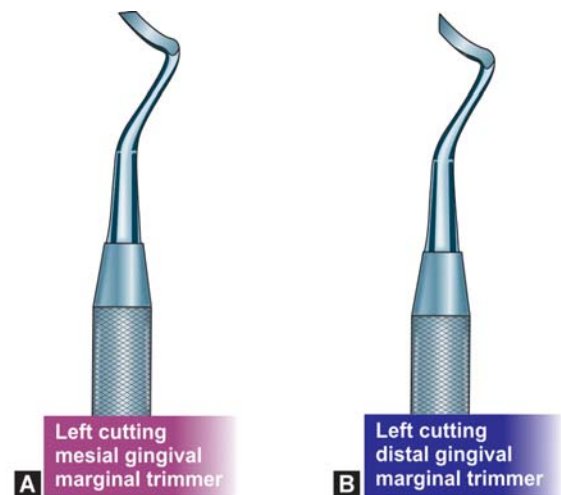The gingival margin trimmer (GMT) is a modified hatchet which has working ends with opposite curvatures and bevels (**Figs 5.25A and B**).



**Figs 5.25A and B:** (A) Right cutting, (B) Left cutting end of a paired GMT

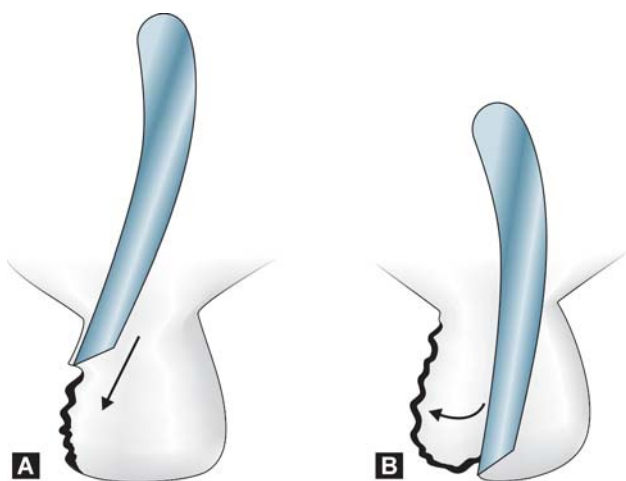
The gingival marginal trimmer is available in a set of two double ended styles and is used in pairs, constituting a set of four instruments (**Figs 5.26A and B**). Distal gingival margin trimmer is used for the distal surface and the mesial GMT is used for the mesial surface. If the second number in instrument formula is 75-85, it is mesial GMT and if second number is 95 to 100, it is distal GMT.

GMT is used for planing of the gingival cavosurface margin that is removal of unsupported enamel and to bevel axiopulpal line angle in the class II tooth preparation (**Figs 5.27A and B**).



**Figs 5.26A and B:** Paired gingival marginal trimmer





**Figs 5.27A and B:** Use of GMT in proximal box; (A) GMT in vertical motion to plane facial/lingual wall of proximal box, (B) GMT in horizontal stroke to plane the gingival wall

#### Main difference between gingival marginal trimmer and hatchet

1. Gingival marginal trimmer has a curved blade, hatchet has straight blade. The curved blade helps in the lateral scraping skill of the gingival marginal trimmer.
2. The cutting edge of the gingival marginal trimmer makes an angle with the plane of the blade whereas cutting edge of the hatchet makes a 90° angle to the plane of the blade.

## RESTORATION INSTRUMENTS


Following are the commonly used instruments when temporary or permanent restoration is being done.

### Cement Spatulas

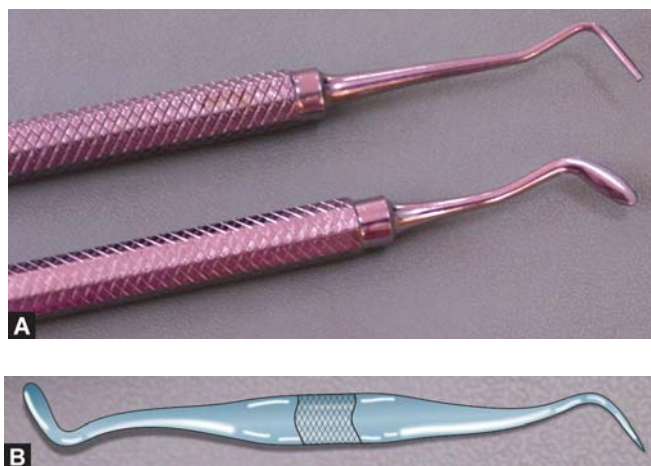Several types of spatulas are available in the market differing in shape and size (**Fig. 5.28A**). On the basis of size, cement spatula can be classified into two types (**Fig. 5.28B**):



**Fig. 5.28A:** Different types of cement spatulas



**Fig. 5.28B:** Large and small cement spatula



**Figs 5.29A and B:** (A) Plastic filling instrument, (B) Diagrammatic representation of plastic carrier

1. **Large cement spatula:** Mixing of luting cements
2. **Small cement spatula:** Mixing of liner

Cement spatula also can be classified on the basis of thickness such as rigid and flexible. Their use depends on viscosity of cement and personal preference.

### Plastic Filling Instrument

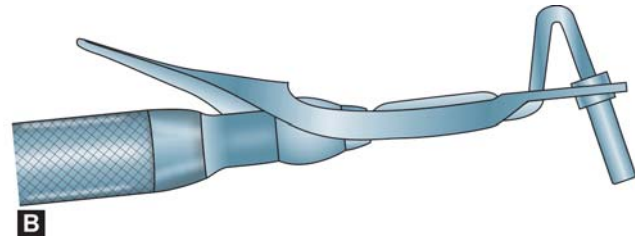
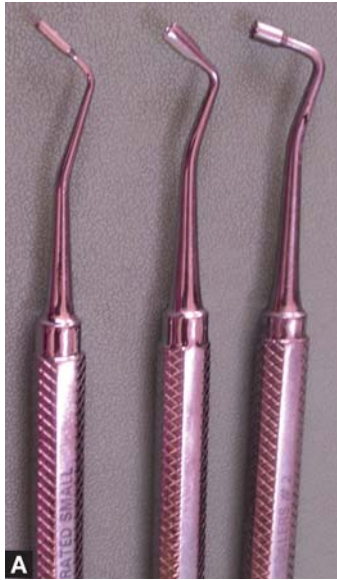These instruments have a small metal ball at the working end. They are used to mix, carry and place cements (**Figs 5.29A and B**).

### Condensers

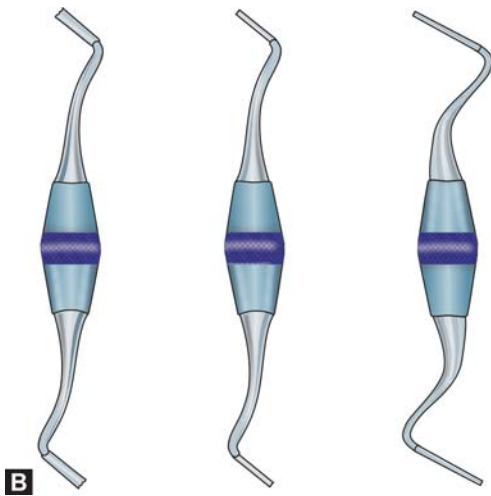
To deliver the restoration to the tooth preparation and properly condense it, condensers are used. The hammer-like working end of condenser should be large enough to pack the restoration without sinking into it. Condensers come in single and double-ended designs. They are available in differently shaped and sized working ends like round, triangular or parallelogram, which may be smooth or serrated. Condensers can be hand or mechanical in nature (**Figs 5.30A and B**).

### Amalgam Carriers

To pack amalgam material into the tooth preparation, amalgam carriers are needed. They carry the freshly prepared amalgam restorative material to the prepared tooth. These carriers have hollow working ends, called barrels, into which the amalgam is packed for transportation (**Figs 5.31A and B**). Carriers can be both single and double ended. Barrel of amalgam carriers comes in a variety of sizes viz; small, large and jumbo. Lever of amalgam carrier is located on the top of the carrier. When lever is depressed, the amalgam is



**Figs 5.31A and B:** (A) Amalgam carriers, (B) Diagrammatic representation of amalgam carrier

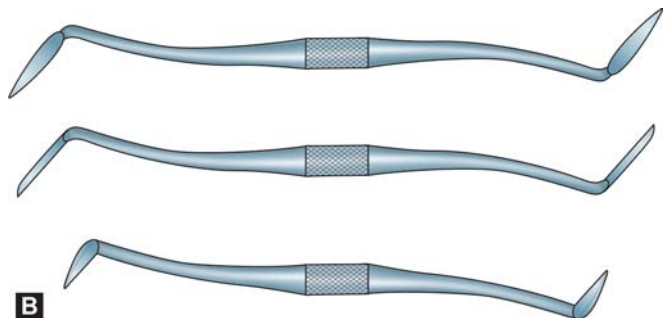
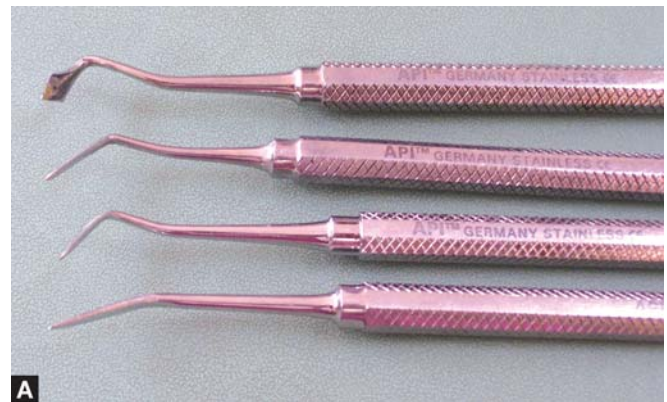

**Figs 5.30A and B:** (A) Condensers, (B) Diagrammatic representation of different condensers

expelled into the preparation. A poorly packed amalgam carrier may result amalgam fall out before it is ejected into the prepared tooth. After restoration is completed, expel out any remaining amalgam alloy from the carrier into the amalgam well otherwise carrier will no longer be serviceable when the amalgam is allowed to harden in the carrier.

### Carvers

Carvers are used to contour the restoration approximately same to original tooth structure. Sharp cutting edges present in carvers are used to shapen and form tooth anatomy from a restorations. Carvers come in different shapes and sizes in double ended designs (**Figs 5.32A and B**). Many carvers are designed for carving specific tooth surfaces. For



**Figs 5.32A and B:** (A) Carvers, (B) Diagrammatic representation of carvers

example, interproximal and hollenback carvers are used for carving proximal surfaces and discoid cleoid and diamond-shaped carvers are used for carving occlusal surfaces.

## Burnisher

Burnishers are the kind of instruments which make the surface shiny by rubbing. They are used to smoothen and polish the restoration and to remove scratches present on the amalgam surface after its carving. Burnishers have smooth rounded working ends and come in single and double-ended types (Figs 5.33A and B).

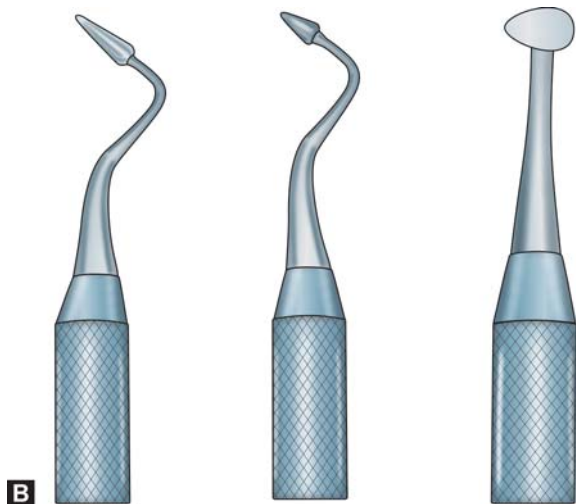
Different types of burnishers are available but most commonly used are:

1. PKT3—designed by Peter K Thomas
  - Rounded cone-shaped burnisher.
2. Beavetail condenser—narrow type of burnisher.
3. Ovoid burnisher—comes in various sizes such as 28, 29, 31.


### Uses of Burnishers

Burnishers are used for:

- Final condensation of amalgam.
- Initial shaping of occlusal anatomy of amalgam.



**Figs 5.33A and B:** (A) Burnishers, (B) Diagrammatic representation of burnishers



**Fig. 5.34:** Composite resin instruments

- Shaping of metal matrix bands.
- Shaping of occlusal anatomy in posterior resin composite before polymerization of resin.
- Burnishing margins of cast gold restoration.

## Composite Resin Instruments

For composite resin restorations, a wide range of double-ended instruments are used to transport and place resins. The working ends on these instruments range from varying small cylinders to angled, paddle like shapes (Fig. 5.34). Composite resin instruments are made of plastic or titanium coating. Advantages of using plastic instruments are that they do not discolor or contaminate the composite restoration, also the composite resin material does not stick to the instrument.

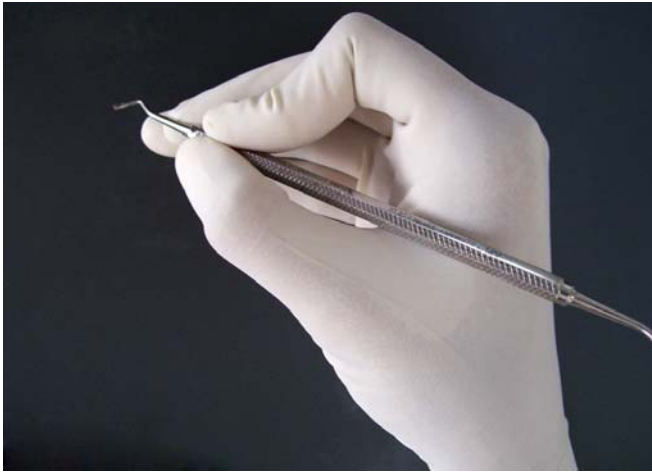## INSTRUMENT GRASPS

For accurate and precise control over the instrument certain instrument grasps are suggested which help in increasing efficiency of the operator, offer more flexibility of movements and decrease strain on the operator. In other words, correct instrument grasps are important for achieving success in operative procedures.

The correct grasp is selected according to the instruments being used, position of instrument being used, the operator, the area which is being operated and the specific procedure to be done.

### Commonly used instrument grasps in operative dentistry

1. Modified pen grasp
2. Inverted pen grasp
3. Palm and thumb grasp
4. Modified palm and thumb grasp.



**Fig. 5.35:** Modified pen grasp

### Modified Pen Grasp

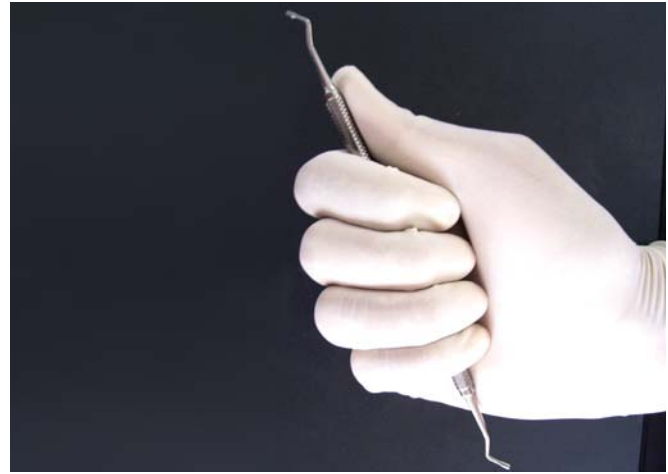This is the most commonly used grasp. The greatest delicacy of touch is provided by this grasp. Normally, a pen is held with the thumb and index finger, with the middle finger placed under the pen. The modified pen grasp is similar to the pen grasp except the operator uses the pad of the middle finger on the handle of the instrument rather than going under the instrument (**Fig. 5.35**). The positioning of the fingers in this manner creates a triangle of forces or tripod effect, which enhances the instrument control. It is most commonly used in mandibular teeth. Here palm of the operator faces away from the operator. This position stabilizes the instrument and allows the middle finger to help push the instrument down.

### Inverted Pen Grasp

In inverted pen grasp finger positions are the same as for the modified pen grasp except that hand is rotated so that palm faces towards the operator (**Fig. 5.36**). This grasp is



**Fig. 5.36:** Inverted pen grasp



**Fig. 5.37:** Palm and thumb grasp

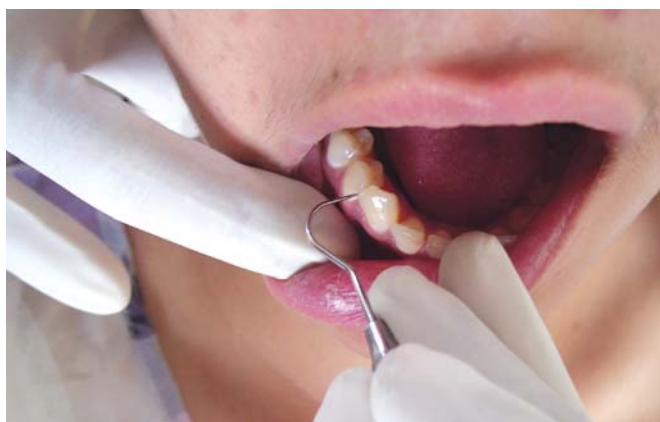most commonly used for preparing a tooth in the lingual aspect of maxillary anterior and occlusal surface of maxillary posterior teeth.

### Palm and Thumb Grasp

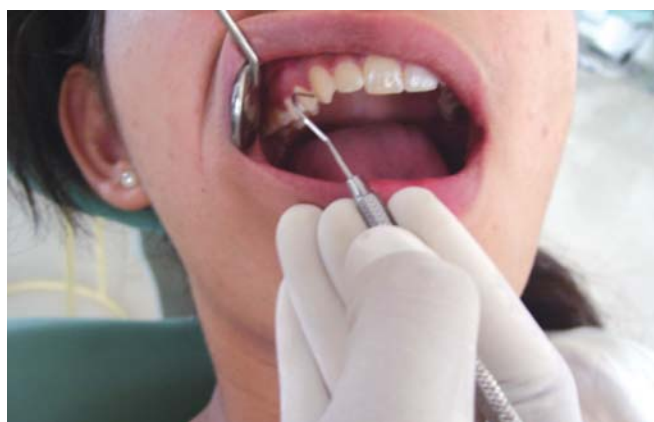This grasp is same as for holding the knife for peeling the skin of an apple. The palm and thumb grasp is commonly used for bulky instruments. In this, instrument is grasped very near to its working end so that thumb can be braced against the teeth so as to provide control during instrument movements. The shaft of the instrument is placed on the palm of the hand and grasped by the four fingers to provide firm control, while the thumb is free to control movements and provide rest on a adjacent tooth of the same arch (**Fig. 5.37**). To achieve the thrust action with the fingers and palm, instrument is forced away from the tip of the thumb which is at the rest position. This grasp has limited use only while operating on maxillary anterior teeth. Since, it offers application of heavy force with greater control, it is used for holding a handpiece while cutting incisal retention for a class III preparation in maxillary incisor.

### Modified Palm and Thumb Grasp

The instrument is held like the palm grasp but the pads of all the four fingers press the handle against the palm and pad and first joint of the thumb. Here tip of the thumb rests on the tooth being prepared or the adjacent tooth. Modified palm and thumb grasp provides more control to avoid slipping of instrument. This grasp is commonly used in maxillary anterior teeth.



**Fig. 5.38:** Conventional finger rest



**Fig. 5.40:** Palm up finger rest

## FINGER RESTS

The finger rest helps to stabilize the hand and the instrument by providing a firm rest to the hand during operative procedures. Finger rests may be intraoral or extraoral.

### 1. Intraoral finger rests:

- a. *Conventional:* In this, the finger rest is just near or adjacent to the working tooth (**Fig. 5.38**).
- b. *Crossarch:* In this, the finger rest is achieved from tooth of the opposite side but of the same arch (**Fig. 5.39**).
- c. *Opposite arch:* In this, the finger rest is achieved from tooth of the opposite arch.
- d. *Finger on finger:* In this, rest is achieved from index finger or thumb of nonoperating hand.

### 2. Extraoral finger rest:

It is used mostly for maxillary posterior teeth.

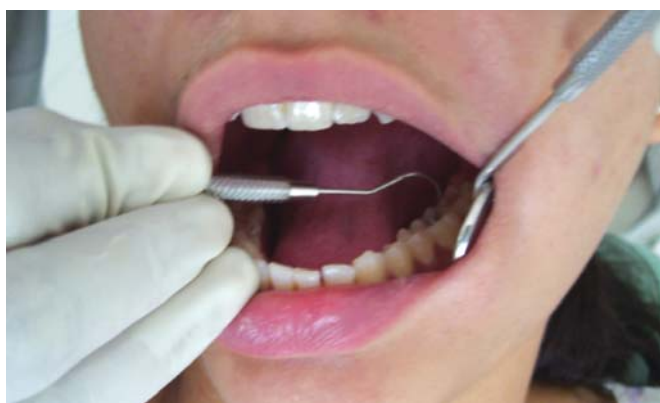- a. *Palm up:* Here rest is obtained by resting the back of the middle and fourth finger on the lateral aspect

of the mandible on the right side of the face (**Fig. 5.40**).

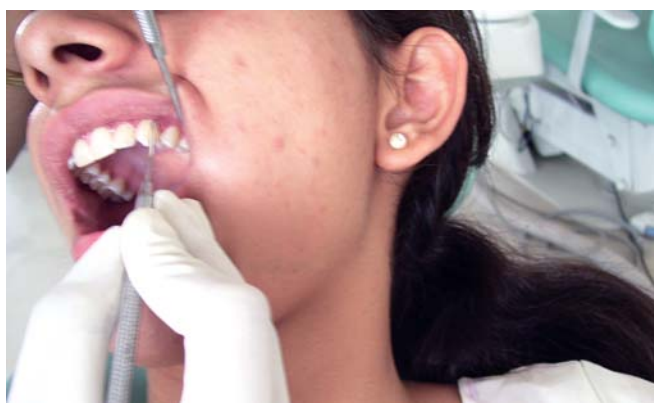- b. *Palm down:* Here rest is obtained by resting the front surface of the middle and fourth fingers on the lateral aspect of the mandible on the left side of the face (**Fig. 5.41**).

### Methods of use of instruments

- The instruments are effectively used when they are used from the bevel side to the non-bevel side.
- Instrument should be held in such a way that allows the cutting edge to remove any unsupported enamel from the preparation walls.
- Instrument should always be held parallel to the wall being working upon. Holding an instrument at this angle may increase its cutting but it may also cause damage or fracture of the tooth.
- For the buccal wall, one side of the instrument is used and on the lingual wall, the other side of the instrument should be used.



**Fig. 5.39:** Crossarch finger rest



**Fig. 5.41:** Palm down finger rest

## SHARPENING OF HAND INSTRUMENTS

Instrument sharpening is a critical component of operative dentistry. It is impossible to carry-out procedures with dull instruments. A sharp instrument cuts more precisely and quickly than dull instruments. Therefore to avoid wasting time on using dull instruments, dentists must be thoroughly familiar with principles of sharpening.

### Goals of Sharpening

- To produce a functionally sharp edge.
- Maintain the contour (shape) of instrument.
- Maintain the life of instrument.

### Advantages of Sharp Instruments

Use of well sharpened instruments results in:

- Improved efficiency.
- Improved tactile sensations.
- Less pressure and force.
- Improved instrument control.
- Minimized patient discomfort.
- Less treatment time.

### Principles of Sharpening

Some basic principles used during sharpening are:

- Select the appropriate type of stone for type of instrument to be used.
- Instrument should be clean and sterile before sharpening.
- Establish proper angle between stone and surface of instrument on the basis of design.
- Lubricate the stone during sharpening as it reduces the clogging of sharpening stone and heat generated during sharpening.
- Stable and firm grip of both instrument and stone is required during sharpening. Maintain the proper angulation throughout sharpening strokes.
- Sharpening should be done with light stroke or pressure. Avoid excessive pressure.
- When sharpening is completed observe the cutting edge for wire edges. Wire edges should be removed. (**Wire edges** are unsupported metal fragments that extend beyond the cutting from the lateral side or face of blade).
- Resterilize the sharpened instruments.

### Devices Used for Sharpening

- Mechanical
- Mounted
- Handhold stones (Unmounted).

### Mechanical

It is bench type piece of equipment in which honing disks are mounted. On top disk rotates up to 7,000 rpm. It saves time, e.g. honing machine.

### Mounted Stones

In this, stones are mounted on metal mandrel and used with slow speed handpiece. Most common mounted stones are Arkansas and ruby. Various shapes such as cylindrical, conical or disk shaped are available. Mounted stones are not preferred in routine because they:

1. Tend to wear down quickly.
2. Result in generation in frictional heat.
3. Difficult to control during sharpening.

### Unmounted/Handhold Stones

These are commonly used for instrument sharpening. These come in variety of sizes and shapes. Stone can be rectangular with flat, rectangular with grooved surfaces or cylindrical in shape.

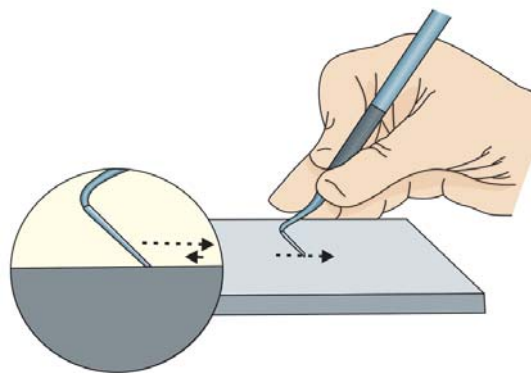
- Flat stone is ideal for moving technique.
- Cylindrical stone for removing wire edges.

**Stone type can come in natural or synthetic form:**

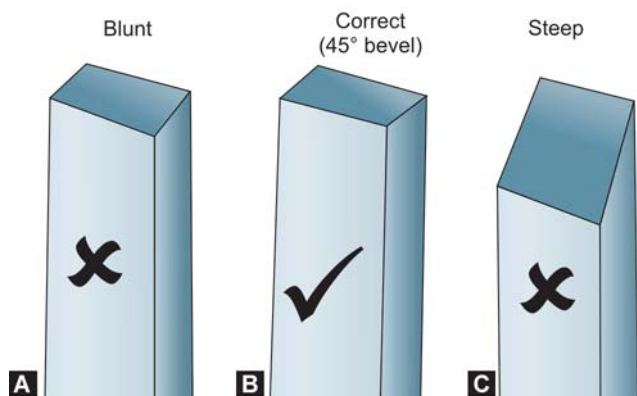
1. Natural–Arkansas (preferred)
2. Synthetic
  - India stone
  - Ceramic stone
  - Composition stone

### Guidelines for Sharpening Operative Instruments

1. When sharpening GMT, chisels, hatchets and hoes, place the cutting edge bond flat against the flat stone and push or pull the instrument so that acute cutting angle moved forward (**Fig. 5.42**).



**Fig. 5.42:** Sharpening the bevel end of hoe

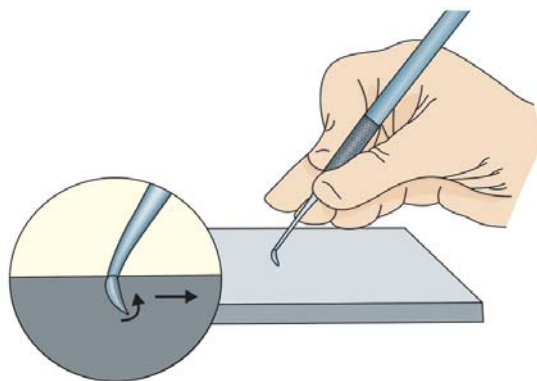


**Figs 5.43A to C:** Different bevels of sharpened instrument; (A) Blunt bevel—incorrect, (B) Correct bevel with 45°, (C) Steep bevel—incorrect

2. Bevel of instrument should make 45° angle with face of blade. So, while sharpening blade should make a 45° angle with the sharpening surface (**Figs 5.43A to C**).
3. While sharpening spoon excavators, cleoid and discoid carvers, rotate the instrument as the blade is moved on the sharpening stone.
4. Move the instrument with bevel against the stone surface and cutting edge placed perpendicular to the path of movement (**Fig. 5.44**).
5. For curved or round cutting edge instrument, handle of edge instrument should be moved in an arc to keep the cutting edge perpendicular to direction of cutting stroke.

#### Advantages of hand cutting instruments

- Self-limited in cutting enamel.
- They can remove large pieces of undermined enamel quickly.
- No vibration or heat accompanies the cutting.
- Efficient means of precise cutting.
- Create smooth surface on cutting.
- Long lifespan and can be resharpened.



**Fig. 5.44:** Sharpening of cleoid carver is done in such a way that handle is moved in an arc to rotate the blade as bevel end is pulled on sharpening stone surface

## ROTARY CUTTING INSTRUMENTS

Rotary cutting instruments are those instruments which rotate on an axis to do the work of abrading and cutting on tooth structure.

### Types of Rotary Cutting

1. **Handpiece:** It is a power device.
2. **Bur:** It is a cutting tool.

### Handpieces

The first rotary instruments were drill or bur heads that were twisted with the fingers for crude cutting of the tooth tissue. Drilling came as the modification (1728) where seat for the drill was provided by a socket fitting against the palm and the ring was adapted to the index or middle finger. In the mid 19th century, there occurred the invention and development of both mechanical and pedal powered handpieces. In 1864, British dentist George Fellows invented the “clockwork” drill. The bur was attached to it by a shaft with a rotating spindle inside. The drill was wound up like a clock, with a key inserted into the back. Drill used to spin for 2 minutes before needing to be rewound.

In 1868, American dentist GF Green developed a pneumatic handpiece powered by pedal operated bellows.

First “dental engine” to provide enough power to spin the bur with sufficient speed for tooth cutting was developed in 1871 by Dr James B Morrison. It was adapted from sewing machine concept.

In the 1950s and 1960s, maximum developments occurred for improvements in design, mechanical operation and speed of the handpieces.

In 1957, the Borden, Airtor was developed as the prototype for today’s modern air-turbine handpiece. It had speeds up to 250,000 rpm.

Air-turbine systems depend mainly on momentum to produce their power. Since, they are powered by the speed of airflow, there is no physical or mechanically connected power source. Thus, under load, they tend to slow down. Therefore, “touch-and-go” rule should be followed with these air-driven turbines. This means touch the bur to tooth and start cutting by applying pressure, when as the bur slows, release pressure until the bur resumes its speed. Because of their ease of use, simple design and patient acceptance air turbine handpieces are still very popular.

Electrically driven handpieces were introduced in the 1970s. They offer many advantages over their air driven predecessors. Though these handpieces are heavier and bigger than air-driven handpieces, but they have the advantage of maintaining a constant speed during cutting,

which does not decrease under load. Also these handpieces have ability to control the rpm rate.

In general for better efficiency, the diameter and bend of the handpiece should be designed such that it fits optimally between thumb and forefinger and also has balanced center of gravity to make the handpiece feel lighter than its actual weight. Head diameter of handpiece should be smaller in size so as to allow greater visibility and maneuverability.

Development of rotary cutting instruments in dentistry		
Year and instrument		Maximum speed (in rpm)
1. Ultra low speed		
1728	Finger rotated instruments	300
1871	Foot engine	700
1874	Electric engine motor driven	1000
2. Low speed		
1914	Dental unit (Electric motor as a power source)	5000
1942	Diamond cutting instruments	5000
3. Medium speed		
1947	High speed electric engines with tungsten carbide burs	12,000
1953	Ball bearings handpieces	25,000
4. High speed		
1955	High speed engine with water cooling turbine angle handpiece	50,000
1955	Belt driven water cooling angle handpiece	150,000
5. Ultra high speed		
1957	Air-turbine angle handpiece with coolant	2,00,000
6. Super ultra high speed		
1960	Air-turbine angle handpiece with coolant	3,00,000
1961	Air-turbine straight handpiece with coolant (Air motor)	25,000
1994	Contemporary air-turbine handpiece with coolant	3,00,000 to 4,00,000

### Classification of Handpiece

Dental handpiece are classified according to their driving mechanisms.

- Gear driven handpiece:** Rotary power is transferred by a belt which runs from an electric engine. Power is transferred from the straight handpiece by a shaft and gears inside the angle section. These handpieces are capable of working with wide speed range, though they work best at low speed because of so many moving parts with metal to metal contact.
- Water driven handpiece:** They were discovered in 1953. These handpieces operate at speeds up to 100,000 rpm. In these handpieces, a small inner piece transport water under high pressure to rotate the turbine in the handpiece

and the larger outer tube returns the water to the reservoir. Advantage of this handpiece is its quiet nature and highest torque.

- Belt driven handpiece:** Belt driven angle handpiece were made available in 1955. They run at speed of > 100,000 rpm. These handpieces have excellent performance and great versatility.
- Air-driven handpieces:** These became available in the later part of 1956. They run at speed of approximately 300,000 rpm.

### Types of Handpiece

- Contra-angle handpiece:** In this, head of handpiece is first angled away from and then back towards the long axis of the handle. Because of this design, bur head lies close to long axis of the handle of handpiece which improve accessibility, visibility and stability of handpiece while working.
  - Air-rotor contra-angle handpiece:** It gets power from the compressed air supplied by the compressor. This handpiece has high speed and low torque (Fig. 5.45).
  - Micromotor handpiece:** It gets power from electric micromotor or airmotor. This handpiece has high torque and low speed (Fig. 5.46).
- Straight handpiece:** In straight handpiece long axis of bur lies in same plane as long axis of handpiece. This handpiece is commonly used in oral surgical and laboratory procedures (Fig. 5.47).



Fig. 5.45: Air-rotor contra-angle handpiece



Fig. 5.46: Micromotor contra-angle handpiece



Fig. 5.47: Straight handpiece



## Dental Burs

“Bur is a rotary cutting instrument which has bladed cutting head.”

Burs are used to remove tooth structure either by chipping it away or by grinding. The earliest burs were handmade. Before 1890s, silicon carbide disks and stones were used to cut enamel since carbon steel burs were not effective in cutting enamel.

William and Schroeder first made diamond dental bur in 1897, modern diamond bur was introduced in 1932 by WH Drendel by bonding diamond points to stainless steel shanks. Diamond burs grind away the tooth. Diamond particles of  $< 25 \mu\text{m}$  size are recommended for polishing procedures and  $> 100 \mu\text{m}$  are used for cavity preparation.

Diamond particles are attached to bur shank either by sintering or by galvanic metal bond. Degree of bonding and clearance of shavings determine the quantity and effectiveness of bur.

### Materials Used for Bur

1. **Stainless steel burs:** These were first developed burs. Stainless steel burs are designed for slow speed  $< 5000$  rpm. Usually a bur has eight blades with positive rake angle for active cutting of dentin. But this makes steel burs fragile, so they do not have a long life.

They are used for cutting soft carious dentin and finishing procedures.

2. **Tungsten carbide burs:** With the development of high speed handpieces, tungsten carbide burs were designed to withstand heavy stresses and increase shelf life.

These burs work best beyond 3,00,000. These burs have six blades and negative rake angle to provide better support for cutting edge. Tungsten carbide burs have head of cemented tungsten carbide in the matrix of cobalt or nickel. These burs can cut metal and dentin very well but can produce microcracks in the enamel so weaken the cavosurface margins.

Diamonds have good cutting efficiency in removing enamel (brittle) while carbide burs cut dentin (elastic material) with maximum efficiency.

### Classifications of Burs

There are various systems for the classification of burs:

1. **According to their mode of attachment to the handpiece:**

- Latch type
- Friction grip type

2. **According to their composition:**

- Stainless steel burs

- Tungsten carbide burs
- A combination of both

3. **According to their motion:**

- **Right bur:** A right bur is one which cuts when it revolves clockwise.
- **Left bur:** A left bur is one which cuts when revolving anticlockwise.

4. **According to the length of their head:**

- Long
- Short
- Regular

5. **According to their use:**

- Cutting burs
- Finishing burs
- Polishing burs

6. **According to their shapes:**

- Round bur
- Inverted cone
- Pear-shaped
- Wheel shaped
- Tapering fissure
- Straight fissure
- End cutting bur

### Part of a Bur (Fig. 5.48)

Parts of dental bur are:

1. Shank
2. Neck
3. Head

1. **Shank:** The shank is that part of the bur that fits into the handpiece, accepts the rotary movement from the handpiece and controls the alignment and concentricity of the instrument. The three commonly seen instrument shanks are:

- Straight handpiece shank
- Latch type handpiece shank
- Friction grip handpiece shank.

2. **Neck:** The neck connects the shank to the hand. Main function of neck is to transmit rotational and translational forces to the head.

3. **Head:** It is working part of the instrument. Based upon their head characteristics, the instruments can be bladed

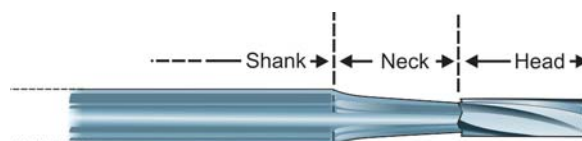
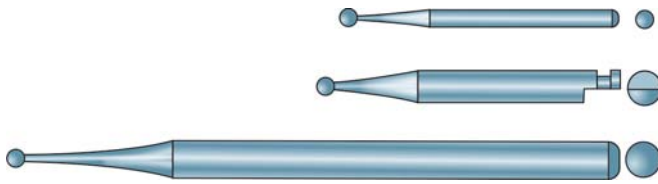


Fig. 5.48: Parts of a dental bur



**Fig. 5.49:** Shank design of burs

or abrasive. These are available different sizes and shapes.

1. **Shank design (Fig. 5.49):** Depending upon mode of attachment to handpiece, shanks of burs can be of following types:

- a. Straight handpiece shank
- b. Latch type angle handpiece shank
- c. Friction grip angle handpiece shank.

a. *Straight handpiece shank:* Shank part of straight handpiece is like a cylinder into which bur is held with a metal chuck which has different sizes of shank diameter.

b. *Latch type angle handpiece shank:* In this handpiece posterior portion of shank is made flat on one side so that end of bur fits into D-shaped socket at bottom of bur tube. In this, instrument is not retained in handpiece with chuck but with a latch which fits into the grooves made in shank of bur. These instruments are commonly used in contra-angle handpiece for finishing and polishing procedures.

c. *Friction grip angle handpiece shank:* This was introduced for high speed handpiece. Here the shank is simple cylinder which is held in the handpiece by friction between shank and metal chuck. This design of shank is much smaller than latch type instruments.

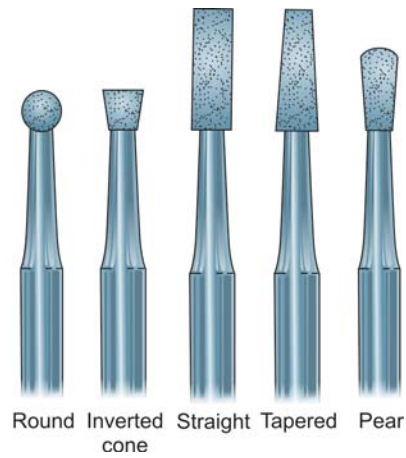
2. **Design of neck:** Neck connects head and shank. It is tapered from shank to the head. For optical visibility and efficiency of bur, dimensions of neck should be small but at the same time it should not compromise the strength.

3. **Design of bur head (Fig. 5.50):** The term “bur shape” refers to the contour or silhouette of the bur head.

a. *Round bur:* Spherical in shape, used for removal of caries, extension of the preparation and for the placement of retentive grooves.

b. *Inverted cone bur:* It has flat base and sides tapered towards shank. It is used for establishing wall angulations and providing undercuts in tooth preparations.

c. *Pear shaped bur:* Here head is shaped like tapered cone with small end of cone directed towards shank. It is used in class I tooth preparation for gold foil. A long length pear bur is used for tooth preparation for amalgam.



**Fig. 5.50:** Different design of bur heads

d. *Straight fissure bur:* It is parallel sided cylindrical bur of different lengths and is used for amalgam tooth preparations.

e. *Tapering fissure bur:* It is tapered sided cylindrical but sides tapering towards tip and is used for inlay and crown preparations.

f. *End cutting bur:* It is used for carrying the preparation apically without axial reduction.

#### Modifications in Bur Design

Because of introduction of handpieces with high speed ranges, many modifications have been made in design of bur. Since, cutting efficiency of carbide burs increase with increase in speed. Larger diameter carbide burs have been replaced by small diameter burs.

**Others modifications in bur design are as following:**

a. *Reduced number of crosscuts:* Since at high speed, crosscuts tends to produce rough surface, newer burs have reduced number of crosscuts.

b. *Extended head lengths:* Burs with extended head length have been introduced so as to produce effective cutting with very light pressure.

c. *Rounding of sharp tip corners:* Since, sharp tip corners of burs produce sharp internal angles, resulting in stress concentration. Burs with round tip corners produce rounded internal line angles and thus lower stress in restored tooth.

4. **Sizes of bur:** Bur size represents the diameter of bur head. Different numbers have been assigned to burs which denote bur size and head design. Earlier burs had a numbering system in which burs were grouped by 9 shapes and 11 sizes.

But later because of modifications in bur design this numbering system was modified. For example, after introduction of crosscut burs, 500 numbers was added to the bur equivalent to noncrosscut size and 900 was added

for end cutting burs. Thus, we can say that no. 58, 558 and no. 958 burs all have same dimensions of the head irrespective of their head design.

**Head shapes and dimensions of burs**

Shape of head	Head diameter (mm)	Number
Round	0.5	¼
	0.6	½
	0.8	1
	1.0	2
	1.2	3
	1.4	4
Straight fissure	0.6	55½
	0.8	56
	1.0	57
	1.2	58
	1.4	59
	1.0	700
Tapered fissure	1.2	701
	1.0	33½
Inverted cone	0.8	34
	1.0	35
	1.2	36
	1.3	37
	0.8	556
Straight fissure	1.0	557
	1.2	558
	1.3	559
Crosscut	1.0	957
	1.2	958
End cutting Bur	1.0	959
	1.4	959

### Bur Design

Bur head consists of uniformly spaced blades with concave areas in between them. These concave depressed areas are called chip or flute spaces. Normally, a bur has 6, 8, or 10 numbers of blades (**Fig. 5.51**).

- Bur blade (Fig. 5.52):** Blade is a projection on the bur head which forms a cutting edge. Blade has two surfaces:
  - Blade face/Rake face:** It is the surface of bur blade on the leading edge.
  - Clearance face:** It is the surface of bur blade on the trailing edge.
- Rake angle:** This is angle between the rake face and the radial line (**Fig. 5.53**).
  - Positive rake angle:** When rake face trails the radial line.
  - Negative rake angle:** When rake face is ahead of radial line.
  - Zero rake angle:** When rake face and radial line coincide each other.
- Radial line:** It is the line connecting center of the bur and the blade.
- Land:** It is the plane surface immediately following the cutting edge (**Fig. 5.54**).
- Clearance angle:** This is the angle between the clearance face and the work (**Fig. 5.55**).

**Significance:** Clearance angle provides a stop to prevent the bur edge from digging into the tooth and provides adequate chip space for clearing debris.

Speed	Range (rpm)	Commonly used bur (with this speed)	Uses	Advantages	Disadvantages
Low speed	500 to 25,000	Steel burs with or without lubricant	<ul style="list-style-type: none"> <li>Polishing, finishing</li> <li>Drilling holes</li> <li>For implants</li> <li>Excavation of caries</li> </ul>	Good tactile sense	<ul style="list-style-type: none"> <li>Ineffective cutting</li> <li>Time consuming</li> <li>Operator fatigue</li> <li>Produce patient discomfort</li> </ul>
High speed	20,000 to 1,20,000	Diamond burs with lubricant	<ul style="list-style-type: none"> <li>Tooth preparations</li> <li>Making small tooth preparations</li> <li>Refining tooth preparations</li> <li>Refining occlusions</li> </ul>	<ul style="list-style-type: none"> <li>Fine tactile sense</li> <li>Minimum overcutting</li> </ul>	<ul style="list-style-type: none"> <li>More heat production</li> <li>Not fit for larger preparations</li> <li>Preparations can cause operator fatigue</li> </ul>
Ultra high speed	2,50,000 to 4,00,000	Tungsten carbide burs with lubricant	<ul style="list-style-type: none"> <li>Tooth preparations</li> <li>Removal of old restorative materials</li> <li>Crown preparations For fixed prosthesis</li> </ul>	<ul style="list-style-type: none"> <li>Faster preparation takes less time</li> <li>Less fatigue for patient and operator</li> <li>Quadrant dentistry is possible</li> <li>Ease for operator</li> </ul>	<ul style="list-style-type: none"> <li>Overcutting is possible</li> <li>Less tactile sense</li> <li>Iatrogenic errors are more common</li> </ul>

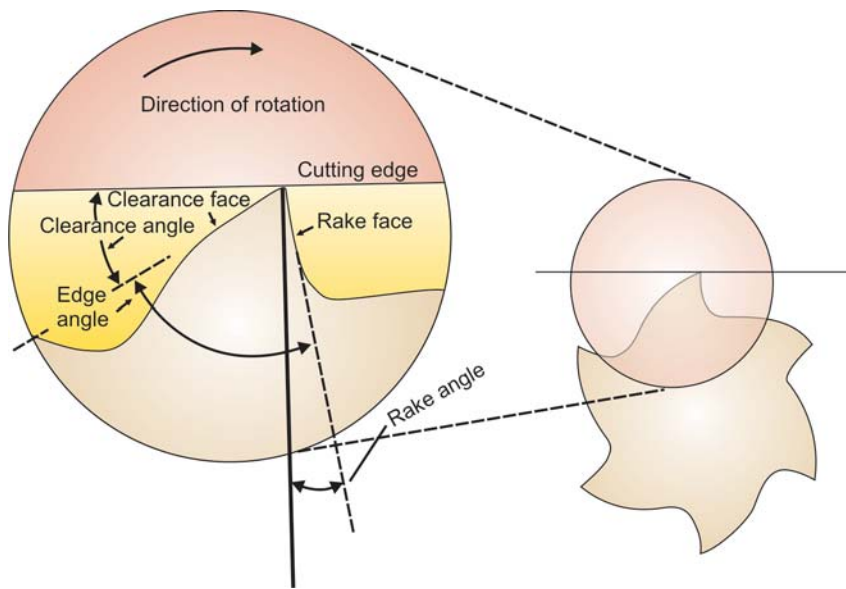


Fig. 5.51: Design of bur head

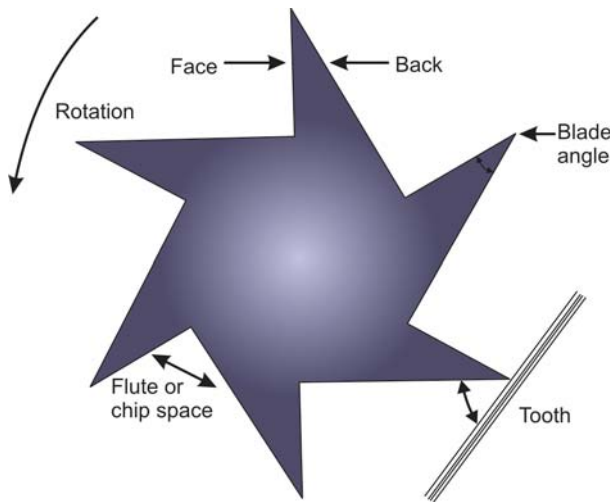


Fig. 5.52: Bur blade




Fig. 5.54: Land of bur

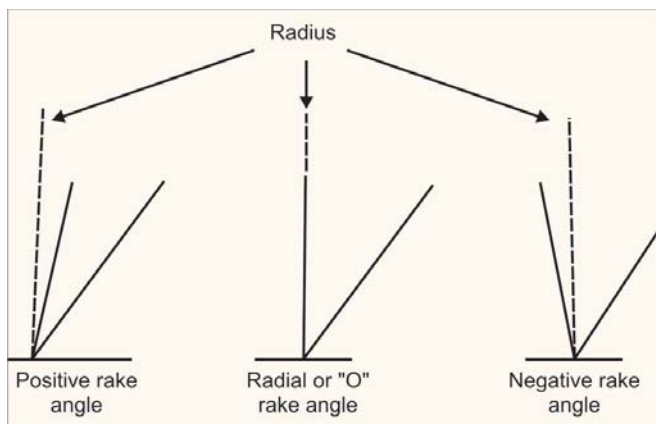


Fig. 5.53: Three types of rake angles

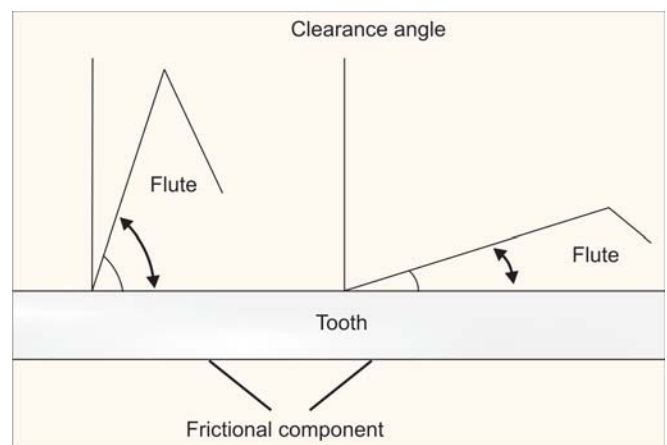
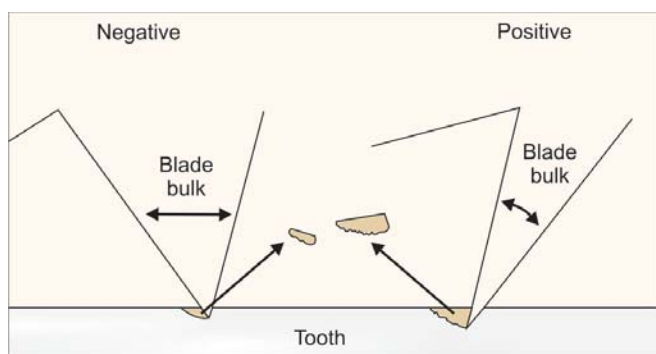


Fig. 5.55: Clearance angle provides a stop to prevent bur edge from digging into the tooth



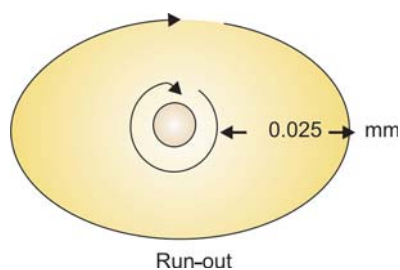
**Fig. 5.56:** Relationship between cutting efficiency and clogging of bur space with change in rake angle

6. **Blade angle:** It is the angle between the rake face and the clearance face.

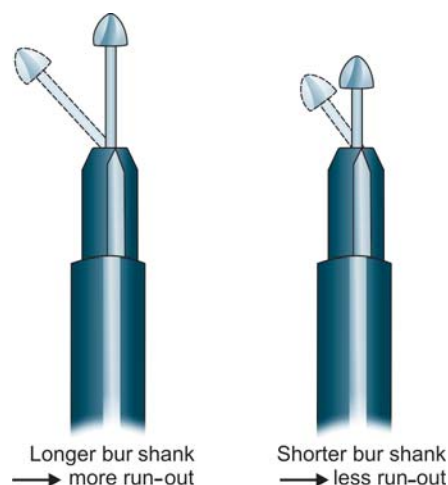
**Significance:** Among these rake angle is one of the most important feature of bur blade design. Negative rake angle increases the life of bur by reducing fracture of cutting edges. Positive rake angle increases the cutting efficiency but since it reduces the bulk of bur blade, it becomes prone to fracture. Positive rake angle also causes clogging of debris in the chip space (**Fig. 5.56**).

If blade angle is increased, it reinforces the cutting edge and thus reduces their fracture. But clearance angle, blade angle and rake angle cannot be varied independent of each other. For example, increase in blade angle, decreases the clearance angle. Usually, the carbide burs have negative rake angles and  $90^\circ$  of blade angle so as to reduce their chances of fracture. For better clearance of debris, the clearance faces of carbide burs are made curved to provide adequate flute space.

7. **Concentricity:** It is a direct measurement of symmetry of the bur head. In other words, concentricity measures whether blades are of equal length or not. It is done when the bur is static.
8. **Run-out:** It measures the accuracy with which all the tip of blades pass through a single point when bur is moving (**Fig. 5.57**). It measures the maximum displacement of bur head from its center of rotation. In



**Fig. 5.57:** Run-out



**Fig. 5.58:** Relationship between length of bur shank and run-out

case, there is trembling of bur during rotation, this effect of run-out is directly proportional to length of bur shank (**Fig. 5.58**). Run-out occurs if:

- Bur head is off center on axis of the bur.
- If bur neck is bent.
- If bur is not held straight in handpiece chuck.

**Run-out causes:**

- Increase in vibration during cutting.
- Causes excessive removal of tooth structure.

### Factors Affecting Cutting Efficiency of Bur

Burs remove the tooth tissue at different rates depending upon various factors. It is always desirable to cut a large quantity of tooth in short-time. Following affect the cutting efficiency of a bur:

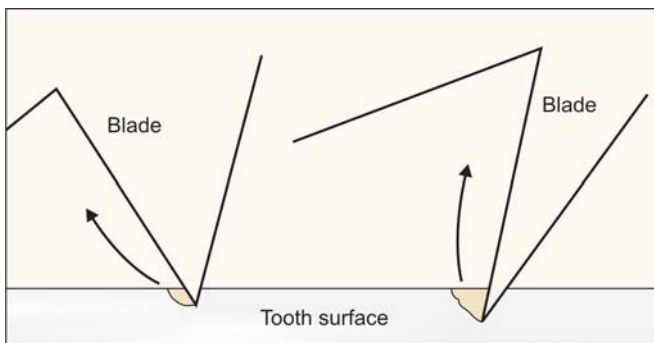
- Clearance angle, rake angle and blade angle:** Clearance angle reduces the friction between cutting edge and the work. It also prevents the bur from digging excessively into the tooth structure. But an increase in rake angle decreases the blade angle which inturn decreases the bulk of bur blade (see **Fig. 5.56**).

Positive rake angle increases cutting efficiency of bur, but increase in rake angle causes decrease in bulk of bur blade and clogging of flute space because of production of larger chips.

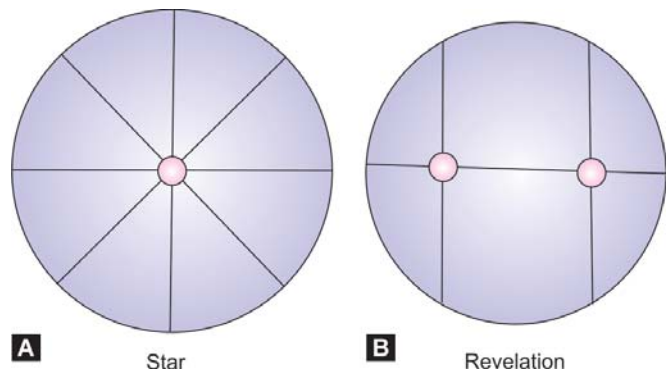
- End cutting or side cutting bur:** According to particular task, choice of bur can be end cutting, side cutting or combination of both. For example, it is preferred to make entry to enamel by end cutting bur, while for making preparation outline, use side cutting bur.
- Neck diameter of bur:** If neck diameter of bur is large, it may interfere with accessibility and visibility. But if

diameter is too short, it will make bur unable to resist the lateral forces.

4. **Spiral angle:** Burs with smaller spiral angle have shown better efficiency at high speeds.
5. **Linear surface speed:** Within the limit, faster the speed of cutting instrument, faster is the abrasive action and more efficient is the tooth cutting instrument. Bur speed should be increased in limits because with ultrahigh speed, centrifugal force comes into the play.
6. **Application of load:** Load is force exerted by an operator on tool head. Normally for high speed instruments, load should range between 60 and 120 gm and for low rotational speeds, it should range between 1000 and 1500 gm. Cutting efficiency decreases when load is applied, there is increase in temperature at work face which results in greater wear and tear of handpiece bearings.
7. **Concentricity and run-out:** The average clinically acceptable run-out is 0.023 mm. Increase in run-out causes increase in vibrations of the bur and excessive removal of tooth structure.
8. **Lubrication:** Lubricant/coolant applied to tooth and bur during cutting increases the cutting efficiency and decreases the rise in temperature during cutting. Absence of coolant can result in increase in surface temperature which may produce deleterious effects on pulp.
9. **Heat treatment of bur:** Heat treatment of bur preserve the cutting edges and increases shelf life of the bur.
10. **Number of blades:** Usually a bur has 6-8 number of blades. Decrease in number of blades reduces the cutting efficiency but causes faster clearance of debris because of larger chip space (Fig. 5.59).
11. **Visual contact with bur head:** For efficient tooth cutting, it is mandatory to maintain visual contact with bur head while working.
12. **Design of flute ends:** There are two types of flute ends (Figs 5.60A and B):



**Fig. 5.59:** As the number of blades reduce, it results in increase in chip size and faster clearance because of larger chip space



**Figs 5.60A and B:** Flute end designs; (A) Star, (B) Revelation

- **Star cut design:** Here the flutes come together in a common point at the axis of bur.
- **Revelation design:** Here the flutes come together at two junctions near diametrical cutting edge. It has better efficiency in direct cutting.

### RECENT ADVANCES IN ROTARY INSTRUMENTS

1. Fiberoptic handpiece.
2. Smart prep burs.
3. Chemical vapors deposition (CVD) diamond burs.
4. Fissurotomy burs.

#### Fiberoptic Handpiece

Nowadays to avoid shadow or visibility problem associated with external lightening, handpiece with a built in optics have been made available. This fiberoptic delivers a high beam of light to the handpiece head directly on working site.

#### Smart Prep Burs

Smart prep instrument is also known as polymer bur or smart bur.

This type of instrument is made from polymer that safely and effectively remove decayed dentin without affecting the healthy dentin.

Smart prep bur has property of self-limiting, this means it will not cut the healthy dentin. It cuts dentin only when large amount of force is applied.

#### Availability

- Sizes 2, 4, 6.
- Used with slow speed handpiece (500-800 rpm).
- Single patient use.

### Advantages

- Used for deep caries removal in lieu of indirect capping procedure.
- Chances of iatrogenic pulp exposure are less.
- Minimum removal of tooth structure.

### Disadvantages

- Technique sensitive.
- This instrument leaves large amount of decayed portion unexcavated.
- Costly.
- Chances of damage of bur are more if, touches the enamel or sound dentin during and after the procedure.

## Chemical Vapor Deposition (CVD) Diamond Burs

In 1996, CVD diamond burs attached to an ultrasonic handpiece were introduced to eliminate problems faced with diamond burs.

These diamond burs are obtained by chemical vapor deposition of diamond film over a molybdenum substrate.

These tips are made in a reactor in which mixture of methane and hydrogen gas results in the formation of artificial diamond layer over the molybdenum substrate.

These tips require only slight touch to promote tooth grinding.

If too much pressure and force is applied during cutting, the effects would be:

1. Excessive heat generation.
2. Decrease in cutting efficiency.
3. Excessive noise production.
4. Pain.
5. Fracture of the molybdenum substrate.

### Advantages

1. Less noise
2. Greater durability
3. Better access and visibility
4. Better cooling
5. Effective tooth preparation
6. Improved proximal access
7. Reduced risk of metal contamination
8. Preservation of tooth structure and also minimal damage to gingival tissues.

### Disadvantages

1. Technique sensitive
2. Very costly.

## Fissurotomy Burs

1. New instrument for ultraconservative dental treatment.
2. As the name indicates, these are specially designed for pit and fissure lesions.
3. Available in three different shapes and sizes:
  - a. Original fissurotomy.
  - b. Original fissurotomy micro STF.
  - c. Original fissurotomy micro NTF.
4. Original fissurotomy and fissurotomy micro NTF has head length of 2.5 mm while fissurotomy micro STF has head length of 1.5 mm.
5. Fissurotomy micro STF is suitable for deciduous teeth, adult premolars, enameloplasty, etc.
6. Fissurotomy bur is mainly indicated for small caries and enlarging the fissure.

### Advantages

1. Minimum heat build up and vibration
2. Conservation of tooth structure
3. Increased patient comfort.

### Disadvantages

1. Should be used with suitable restorative materials
2. Costly.

## ABRASIVE INSTRUMENTS

The head of these instruments consists of small angular particles of a hard substance held in a matrix of softer material called as the binder. Different materials used for a binder are ceramic, metal, rubber, shellac, etc.

Abrasive instruments can be divided into: (i) Diamond abrasives, (ii) Other abrasives.

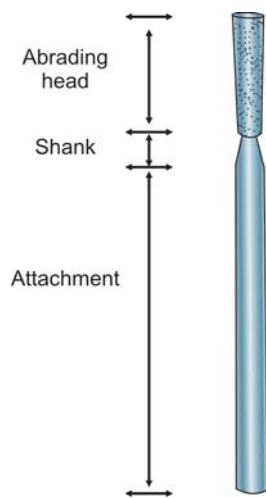
### Diamond Abrasive Instruments

They were introduced in 1942. They have greater resistance to abrasion, lower heat generation and longer life to be preferred over tungsten carbide burs. Diamond instruments consist of three parts:

1. A metal blank.
2. **Powdered diamond abrasive:** Abrasive diamond can be natural or synthetic which is crushed to a powder of desired particles.
3. **The bonding agent:** It serves the purpose of holding the abrasive particles together and binding the particles to the metal blank. Most commonly used binding agents for diamond instruments are ceramic and metal.

### Classifications

- Coarse grit diamonds burs (125-150  $\mu$  particle size)
- Medium grit diamond burs (88-125  $\mu$  particle size)



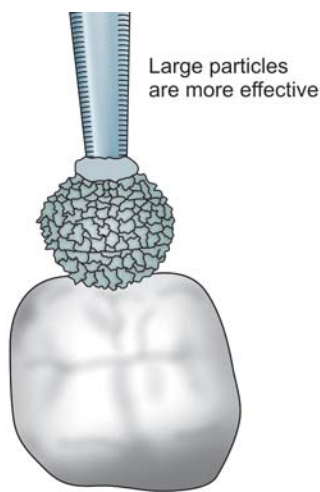
**Fig. 5.61:** Parts of diamond abrasive instrument

- Fine grit diamond burs (60-74  $\mu$  particle size)
- Very fine grit diamond burs (38-44  $\mu$  particle size).

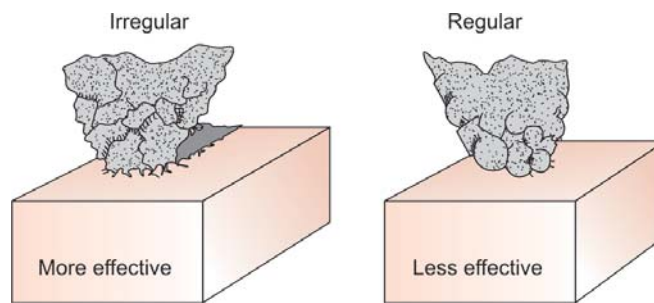
Abrasive stones are available as mounted and unmounted. The mounted stones have abrading head which is joined to the shank and the attachment part (**Fig. 5.61**). In unmounted stones, the abrading head is supplied separately which can be attached to the mandrel when required.

#### Factors Influencing the Abrasive Efficiency and Effectiveness

1. **Size of the abrasive particles:** Abrasive nature is directly proportional to size of abrasive particle. Rapid removal of material occurs with coarse grit burs compared to medium or fine grit burs (**Fig. 5.62**).



**Fig. 5.62:** Larger particles cause deeper cutting



**Fig. 5.63:** Irregular shaped particles have better abrasive efficiency

2. **Shape of the abrasive particles:** The abrasive particles with irregular shape show more efficiency because they present a sharp edge (**Fig. 5.63**).
3. **Density of the abrasive particles:** Coarse grit burs have a low density compared to fine grit burs.
4. **Hardness of the abrasive particle:** The hardness of the abrasive particles should be more than the hardness of the surface on which it is to be used.
5. **Clogging of the abrasive surface:** Clogging of the spaces between the particles by grinding debris decreases efficiency.
6. **Pressure:** Excessive pressure causes the loss of diamonds, thus, decrease their cutting efficiency.
7. **Miscellaneous like** individual dental techniques, difference in pressure, differences in handpieces, etc. also affect abrasive efficiency of instrument.

#### Other Abrasive Instruments

They are used for shaping, finishing and polishing restorations in the clinic and in the laboratory. They are of two types:

1. **Moulded abrasive instruments:** These have heads made by moulding mixture of abrasive and matrix around the roughened end to the shank. They are of two types:
  - Soft moulded instruments use flexible materials like rubber as matrix while rigid moulded instruments use ceramic as matrix. Soft moulded instruments are used for finishing and polishing procedures while the rigid ones are used for grinding and sharpening procedures.
2. **Coated abrasive instruments:** These are mostly disks which have a thin layer of abrasive cemented to a flexible backing. They are used in the finishing of enamel walls of tooth preparations and restorations. The abrasives used here can be silicon carbide, aluminium oxide, garnet, quartz, pumice, cuttle bone, etc.



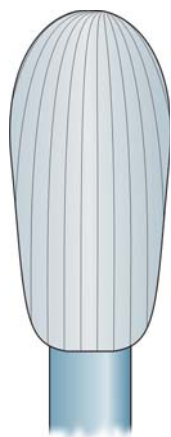


Fig. 5.64A: Finishing burs

## Finishing and Polishing Instruments (Fig. 5.64)

### Finishing Burs

Finishing burs are usually made of stainless steel or tungsten carbide. Bur should be at least 12 fluted (Fig. 5.64A). The main function of finishing bur is to remove excess of restorative material rather than cutting the surface. These burs also make the surface smoother. Burs are available in different shapes and sizes, i.e. tapered, inverted cone, rounded and pear-shaped, etc.

### Brushes

Several types of shapes, i.e wheels, cylinders or cones are available, which may be screwed in handpiece either attached to mandrel or having their own attachment (Fig. 5.64B). These brushes can be used for finishing alone or with abrasive pastes. They are used in polishing cast restorations.

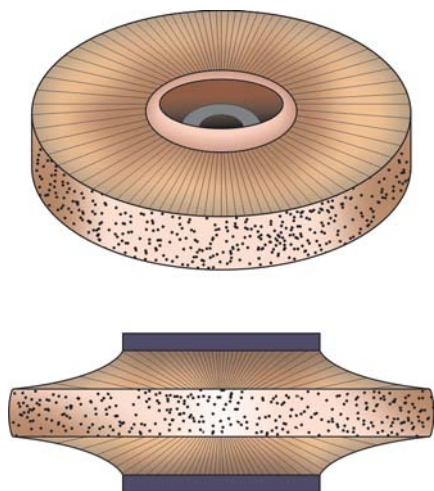


Fig. 5.64B: Brushes

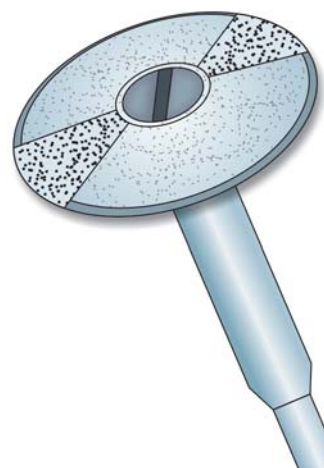

Fig. 5.64C: Paper disk

### Diamond Instruments and Pastes

They are available in the form of abrasive rotary instruments, metal backed abrasive strips and polishing pastes. These instruments should always be used with light force and copious water spray. These are mainly used on ceramic and composite materials.

### Paper-carried Abrasives

These are usually abrasives, i.e. sand, garnet or boron carbide attached to paper disks or strips (Fig. 5.64C). These are preferably used in back and forth motion polishing (similar to shoe polishing).

### Rubber Ended Rotary Tools

These type of instruments are available in variety of shapes, i.e. cups, wheels, etc. (Fig. 5.64D). These can be attached to handpiece with the help of mandrel or with their own extension. These are used with other abrasive or polishing pastes.

### Cloth

Cloth, carried on metal wheel can be used in final stages of polishing with or without polishing medium.

### Felt

Felt is used for obtaining luster for metallic restorations with polishing agent. It is available in the different shapes such as wheel, cones and cylinders (Fig. 5.64 E).



Fig. 5.64D: Rubber ended rotary tool

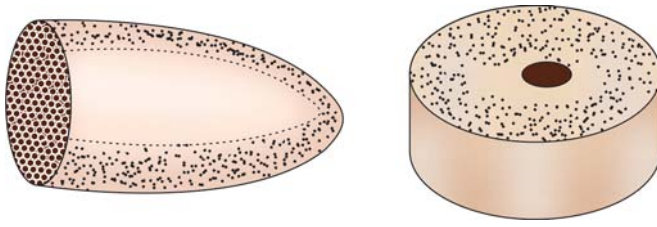


Fig. 5.64E: Felt

### Advantages of Bur Cutting

- Well known procedure of tooth cutting.
- Precision is obtained.
- Easy to control the cutting.
- Tactile perception during cutting.
- Debris can be removed by water and use of suction.

### Disadvantages

- Pain occurs during cutting.
- Vibration caused by cutting may crack or fracture tooth structure.
- Noise production.
- Constant use and sterilization can cause their breakage.
- Dull burs produce excessive heat and causes pulpal damage.
- If operator loses control or the patient moves inadvertently, chances of overcutting.

## ULTRASONIC INSTRUMENTS

Ultrasound emerged for caries removal in 1950s. The ultrasonic dental unit consists of an ultrasonic generator and transducer located within the handpiece. The generator transports the energy to the transducer which causes vibrations for removal of tooth. A water cooling system is incorporated into the equipment. But the conventional technology for diamond powder aggregation with nickel metallic binders cannot withstand ultrasonic power. Recently an alternative approach using chemical vapor deposition (CVD) resulted in synthetic diamond technology. CVD diamond burs are obtained with high adherence of the diamond on the metal surface with outstanding abrading ability. This technology allows diamond deposition with coalescent granulation in different formats of substrates. When connected to an ultrasonic handpiece, CVD diamond burs show following advantages while tooth preparation:

- Maximizing preservation of tooth structure.
- Decreased noise.
- Minimal damage to the gingival tissue.
- More bur life better proximal access.
- Decreased risk of touching the adjacent tooth.
- Minimal patient's risk of metal contamination.

## HAZARDS AND PRECAUTIONS WITH ULTRASPEED CUTTING INSTRUMENTS

High speed rotary cutting instruments can result in many hazards, can be avoided or reduced by taking the certain precautions. These are as following:

### Pulpal Damage

Pulp can be injured during tooth preparation because of mechanical vibration, improper tooth preparation and heat generation during cutting. Dull burs and diamond instruments have poor efficiency and also produce more heat, further resulting in pulpal trauma.

### Precautions to Avoid Pulpal Trauma

- Tooth tissue should be done only with adequate finger rests and good visibility of the operating field.
- Debris clogging the burs should be cleaned before tooth preparation. Coolant should be used while using rotary instrument to control the heat rise.
- For this, air-water spray should be used as it acts as a coolant, moistens the tissues, lubricates and clean the rotary cutting instruments and also cleans the operating site.

### Damage to Soft Tissue

Lacerations may occur in the lips, tongue, cheeks and floor of the mouth, if proper precautions are not taken. During cutting procedures, sudden movement by the patient due to gagging, swallowing or coughing can also result in soft tissue injury.

### Precautions

- Use good visibility and accessibility to the operative field.
- Isolate the operating site preferably by the rubber dam.
- Patient should be instructed not to make sudden movement while working.
- All the burs and rotary instruments should be perfectly centric. Even a slightly eccentric bur can destructively damage the surrounding dental tissues.

### Damage to Ear

When compared to conventional rotary instruments, air-turbine handpieces produce high noise level and frequency of vibration (ranges from 75 to 100 decibels with the frequency more than 2000 cycles per second). But when noise level reaches 85 decibels with frequency ranging more than 5000 cycles per second, it is always preferred to practice protective measures. These are:

- Sound proofing of the room with sound absorbing materials.

- Use of ear plugs.
- Lubrication of ball bearings so as not to further increase the noise level.

### Inhalation Problems

As we know, aerosols and vapors are produced during cutting of tooth structure and restorative materials by rotary instruments. Aerosols are fine dispersions in air consisting of water, cutting debris, microorganisms and restorative materials. While removal of amalgam restoration, mercury vapors are released and while polishing, composite restoration monomers are released. These aerosols can be inadvertently inhaled by the patient or dentist resulting in alveolar (lung) irritation, tissue reactions or may transfer infectious diseases. Their inhalation can be prevented by the use of rubber dam, use of disposable masks and eye wear, etc.

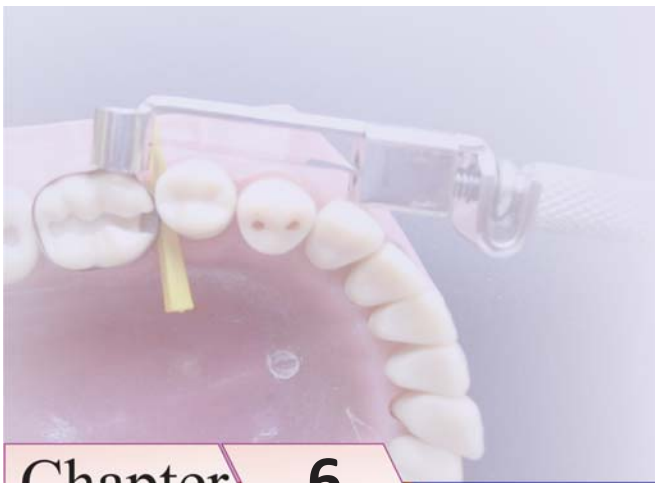### Eye Injuries

When tooth tissue, calculus or any old restorations are removed at high speeds, injury to eyes can occur because of flying particles, microorganisms and other debris. These can be avoided by using protective glasses worn by the patient and the dental personnel. Also plastic shields or protective eyeglasses should be used while using laser equipment or light curing machine.

### VIVA QUESTIONS

- 
- Q. Classify hand instruments?
  - Q. What is Black's system of nomenclature for instruments?
  - Q. What are different parts of hand instruments?
  - Q. What is an instrument formula?
  - Q. What are different bevels of instruments?
  - Q. What are uses of mouth mirror?
  - Q. What are uses of explorer?
  - Q. What is dental tweezer? What are the uses of tweezers?
  - Q. What do you mean by right and left of the instrument?
  - Q. What is spoon excavator?
  - Q. What are uses of spoon excavator?
  - Q. What is straight chisel ?
  - Q. What is angled chisel?
  - Q. What are different bevels of instrument?
  - Q. What are different motions of instrument?
  - Q. What is a hoe?
  - Q. What is difference between hoe and a chisel?
  - Q. What is a GMT?
  - Q. What are types of GMT?
  - Q. What is difference between GMT and a hatchet?
  - Q. How do you differentiate right and left GMT?
  - Q. How do you differentiate mesial and distal GMT?
  - Q. What is angle former?
  - Q. What is amalgam carrier?
  - Q. What is burnisher and its use?
  - Q. What is a cement spatula?
  - Q. What are different types of cement spatulas?
  - Q. What is a plastic instrument?
  - Q. What is condenser? What are types of condensers?
  - Q. How many types of carvers are there?
  - Q. What are different types of instrument grasps used in operative dentistry?
  - Q. What do you mean by rotary instruments?
  - Q. What are types of rotary instruments?
  - Q. Classify rotary instruments according to speed?
  - Q. What are different parts of a dental bur?
  - Q. What are different types of burs?
  - Q. What are different types of bur shanks?
  - Q. What are the uses of round bur?
  - Q. What is use of inverted cone bur?
  - Q. What is use of straight fissure bur?
  - Q. What are different types of bur heads?
  - Q. What is rake angle?
  - Q. What is clearance angle?
  - Q. What is chip/flute space?
  - Q. What is significance of blade angle of a bur?
  - Q. What is significance of clearance angle?

- Q. Define concentricity.
- Q. What do you mean by run-out?
- Q. What are different factors affecting cutting efficiency of a bur?
- Q. What are different finishing and polishing instruments?
- Q. What are advantages and disadvantages of bur cutting?
- Q. What is a pen grasp?
- Q. What is inverted pen grasp?
- Q. What is palm and thumb grasp?
- Q. What is a rest?
- Q. What are different types of rests?
- Q. What is a guard?
- Q. What are abrasive instruments?
- Q. What are factors affecting abrasive efficiency of an instrument?



# Matricing and Tooth Separation

## Chapter 6

### INTRODUCTION

#### MATRICING

- Parts of Matrix
- Functions of a Matrix
- Requirements of a Matrix Band
- Classification of Matrices
- Ivory Matrix Holder (Retainer) No. 1
- Ivory Matrix Band (Retainer) No. 8
- Tofflemire Universal Matrix Band Retainer
- Steele's Siqveland Self-adjusting Matrix Holder for Tapering Teeth
- Anatomical Matrix Band/Compound Supported Matrix

- Retainerless Automatrix System
- T-shaped Matrix Band
- S-shaped Matrix Band
- Full Circle or Ring Bands
- Plastic Matrix Strips
- Precontoured Matrix/Palodont Bitine System
- Aluminium or Copper Collars
- Transparent Crown Forms Matrices
- Anatomic Custom Made Matrix

#### TOOTH SEPARATION

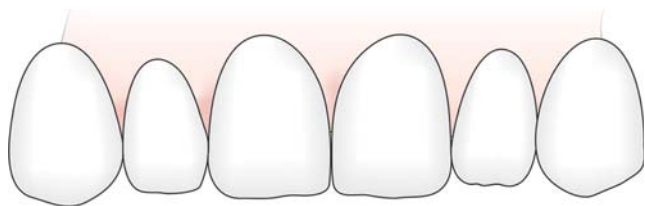
- Reason for Tooth Separation
- Methods of Tooth Separation

### INTRODUCTION

Teeth and periodontium are designed in such a manner that mutually they significantly contribute to their own health and support. They are complimentary to each other. Proper form and alignment of teeth protect periodontium. During mastication, the contours of teeth as a unit protect the periodontium. A breach in the continuity of contacts of teeth give rise to diseases of periodontium resulting in loss of teeth.

#### *Ideal tooth form of interproximal area is as follows:*

1. Interproximal embrasures extend on all the four sides of a tooth with definite shape around each contact area. These four embrasures are gingival, occlusal, lingual and facial.
2. Anterior teeth have less pronounced embrasures than posterior teeth (**Fig. 6.1**).



**Fig. 6.1:** Interproximal spaces of anterior teeth

3. Interproximal space between the adjacent teeth is proper triangular in shape with apex at the contact area and base towards the outer surface (**Fig. 6.2**). This triangle increasingly widens out in from the contact area of all the four directions—occlusal, lingual, gingival and facial.

#### *Consequences of not restoring proximal areas*

- Food impaction leading to recurrent caries (**Fig. 6.3**).
- Change in occlusion and intercuspal relations
- Rotation and drifting of teeth
- Trauma to the periodontium.

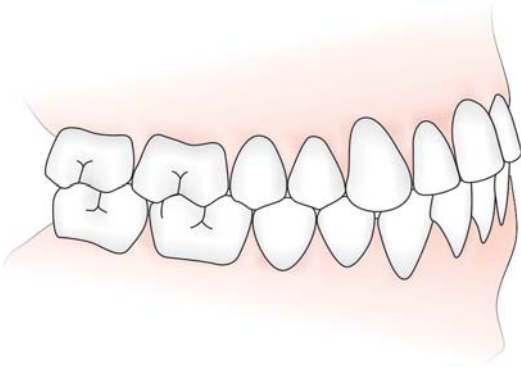


Fig. 6.2: Interproximal spaces of posterior teeth

## MATRICING

Restoration of a tooth requires great clinical acumen so as to reproduce the original contours and contacts of the tooth. In case of large missing wall of the tooth, support has to be provided while placing and condensing the restorative material. Usually a metallic strip serves this function and is known as the matrix band. Matrix band which forms the temporary walls is held in its place by means of a matrix band retainer which may be a mechanical device, floss, wire, thread or impression materials, etc.

**MATRICING:** It is the procedure by which a temporary wall is built opposite to the axial wall, surrounding the tooth structure which has been lost during the tooth preparation.

**MATRIX:** It is an instrument which is used to hold the restoration within the tooth while it is setting.

### Parts of Matrix

#### Retainer

It holds a band in desired position and shape.

#### Band

It is a piece of metal or polymeric material, intended to give support and form to the restoration during its insertion and setting. Commonly used materials for bands are:

1. Stainless steel
2. Polyacetate
3. Cellulose acetate
4. Cellulose nitrate.

Matrix band should extend 2 mm above the marginal ridge height and 1 mm below gingival margin of the preparation. Matrices range in width from 6.35 mm (1/4") to 9.525 mm (3/8") for permanent teeth and 3.175 mm

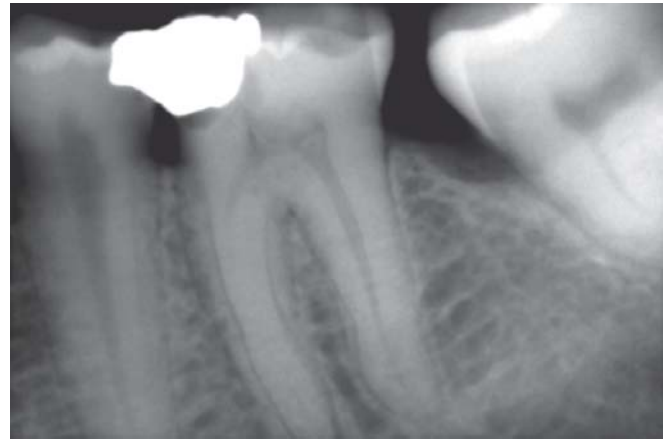

Fig. 6.3: Radiograph showing incorrectly done proximal restoration

(1/8") to 7.9375 mm (5/16") for deciduous teeth. Their thickness may range between 0.0381 mm (0.0015") to 0.0508 mm (0.002").

### Functions of a Matrix

1. To confine the restoration during setting
2. To provide proper proximal contact and contour
3. To provide optimal surface texture for restoration
4. To prevent gingival overhangs.

### Requirements of a Matrix Band

To achieve an optimal restoration, matrix band should have following requirements:

1. **Rigidity:** The matrix band should be rigid enough so as to withstand the pressure of condensation applied during restoration, placement and maintains its shape during hardening.
2. **Adaptability:** The matrix band should be able to match to almost any size and shape of tooth.
3. **Easy to use:** The band should be simple in design so that it does not cause any difficulty to the patient, or hindrance to the operator during restoration of the tooth.
4. It should be able to displace the gingiva and rubber dam for ease in working.
5. **Nonreactive:** It should be inert to tissues and the restorative material.
6. **Height and contour:** The matrix band should not extend more than 2 mm beyond the occlusogingival height of the crown of tooth. This facilitates vision and speeds up working. The matrix band helps in formation of a physiologic proximal contact relationship.
7. **Application:** The matrix band should be such that it can be applied and removed easily.

8. **Sterilization:** It should be easy to sterilize.
9. **Inexpensive:** It should be inexpensive.

### Classification of Matrices

#### Depending upon their Method of Retention

1. Mechanically retained, e.g. Ivory matrix retainers no. 1 and 8, Tofflemire universal dental matrix band retainer.
2. Self-retained, e.g. copper or stainless steel bands.

#### Depending upon its Preparation

- Mechanical matrix, e.g. Ivory matrix retainers no. 1 and 8
- Anatomic/custom made matrix, e.g. compound supported.

#### On the Basis of Transparency

1. Transparent matrices, e.g. cellophane, celluloid
2. Nontransparent matrices, e.g. stainless steel.

#### Depending upon the Tooth

#### Preparation for which they are Used

Type of preparation	Matrices and retainers
<ul style="list-style-type: none"> <li>• Class II tooth preparation</li> <li>• Class II mesio-occluso-distal, (MOD) tooth preparation</li> </ul>	<ul style="list-style-type: none"> <li>• Ivory matrix no. 1</li> <li>• Ivory matrix no. 8</li> <li>• Tofflemire matrix</li> <li>• Steele's Siqveland self-adjusting matrix</li> <li>• Anatomical matrix band</li> <li>• T-shaped matrix band</li> <li>• Retainerless automatrix</li> </ul>
<ul style="list-style-type: none"> <li>• Class III tooth preparation</li> </ul>	<ul style="list-style-type: none"> <li>• S-shaped matrix band</li> <li>• Cellophane matrix strips</li> <li>• Mylar strips</li> </ul>
<ul style="list-style-type: none"> <li>• Class IV tooth preparation</li> </ul>	<ul style="list-style-type: none"> <li>• Plastic strips</li> <li>• Aluminium foil</li> <li>• Transparent crown form</li> <li>• Anatomic matrix</li> </ul>
<ul style="list-style-type: none"> <li>• Class V tooth preparation</li> </ul>	<ul style="list-style-type: none"> <li>• Custom made plastic matrix</li> </ul>
<ul style="list-style-type: none"> <li>• Direct tooth colored and all other complex, preparations</li> </ul>	<ul style="list-style-type: none"> <li>• Cellophane matrices</li> <li>• Anatomic matrices</li> <li>• Aluminium or copper collars</li> <li>• Transparent plastic crown forms</li> </ul>

### Ivory Matrix Holder (Retainer) No. 1

Ivory matrix holder no. 1 is most commonly used matrix band holder for unilateral class II tooth preparations. The

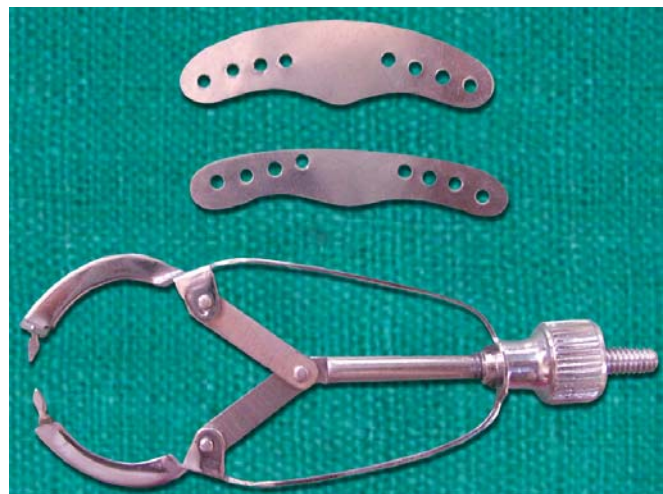


Fig. 6.4: Ivory no. 1 matrix retainer and band

matrix holder has a claw at one end with two flat semicircle arms having a pointed projection at the end (Fig. 6.4). On the other end of the matrix band holder, there is a screw which when tightened, brings the ends of both the claws closer to each other. Band used with this matrix has one margin slightly projected in its middle part. This projected margin is kept towards the gingiva on the side of tooth preparation. The band of suitable size is selected and encircled around the tooth. Keeping the matrix band around the tooth, the screw of the retainer is tightened so that the band perfectly fits around the tooth. After this, wedge is placed which also helps in further adaptation of the matrix band to the tooth (Fig. 6.5).

#### Indication

For unilateral class II tooth preparations.

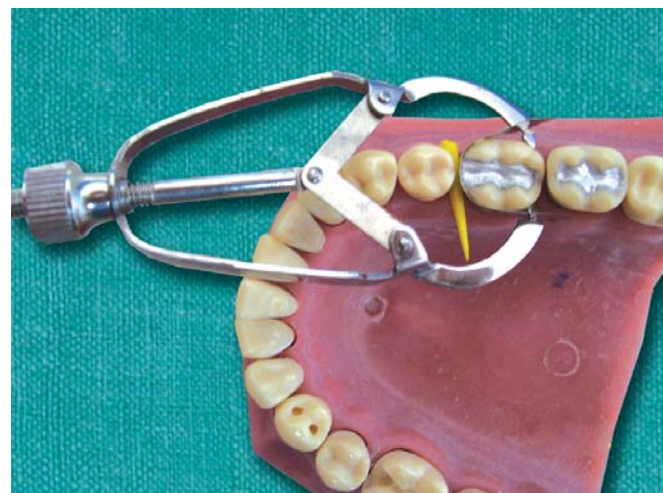

Fig. 6.5: Matrix and band used in class II restoration




Fig. 6.6: Ivory no. 8 matrix and bands

#### Advantages

- Economical
- Used for restoring class II tooth preparations
- Can be sterilized.

#### Disadvantage

Cumbersome to apply and remove.

### Ivory Matrix Band (Retainer) No. 8

Ivory matrix band retainer holds the matrix band that encircles the tooth to provide missing walls on both proximal sides. The matrix band is made up of thin sheet of metal so that it can pass through the contact area of the unprepared proximal side of the tooth (Fig. 6.6). The circumference of the band can be adjusted using the screw present in the matrix band retainer.

#### Indications

- Unilateral or bilateral class II preparations (MOD).
- Class II compound tooth preparations having more than two missing walls.

#### Advantages

- Economical
- Can be sterilized.

#### Disadvantage

Cumbersome to apply and remove.

### Tofflemire Universal Matrix Band Retainer

It was designed by Dr BF Tofflemire. It is also well known as 'universal' matrix because it can be used in all types of tooth preparations of posterior teeth. In this, the matrix band is fitted onto the retainer and then fitted loosely over the tooth, which then can be tightened in position by means of the screw (Fig. 6.7).




Fig. 6.7: Tofflemire retainer

#### Tofflemire matrix

- Also known as universal matrix
- Design given by Dr Tofflemire (Name based on inventor)
- Preferred for class II and compound amalgam restorations

#### Indications

- Class I tooth preparations with buccal or lingual extensions.
- Unilateral or bilateral class II (MOD) tooth preparations.
- Class II compound tooth preparations having more than two missing walls.

#### Advantages

- Can be used from both facial and lingual sides
- Economical
- Sturdy and stable in nature
- Provides good contact and contours
- Can be easily removed
- Can be sterilized.

#### Disadvantages

- Cannot be used in badly broken teeth
- Does not offer optimal results with resin restorations.

#### Types of Tofflemire Matrix

1. Based on type of head
  - a. Straight (Fig. 6.7):
    - i. Head of matrix system is straight
    - ii. Placed only from buccal side
  - b. Contra-angle (Fig. 6.8):
    - i. Head is angulated
    - ii. Placed either from buccal or lingual side.
2. Based on type of dentition
  - a. Standard—used in permanent dentition
  - b. Small—used in primary dentition.

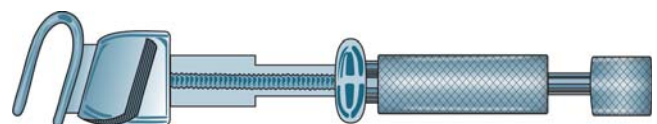
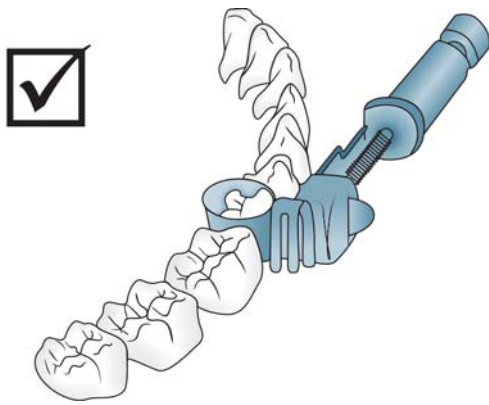
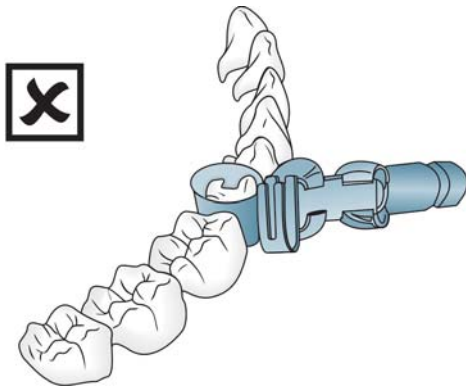


Fig. 6.8: Angulated Tofflemire retainer

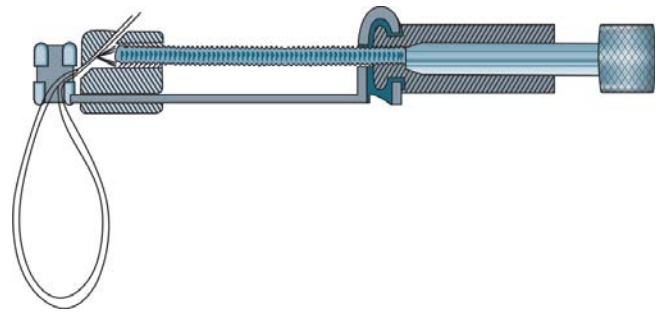




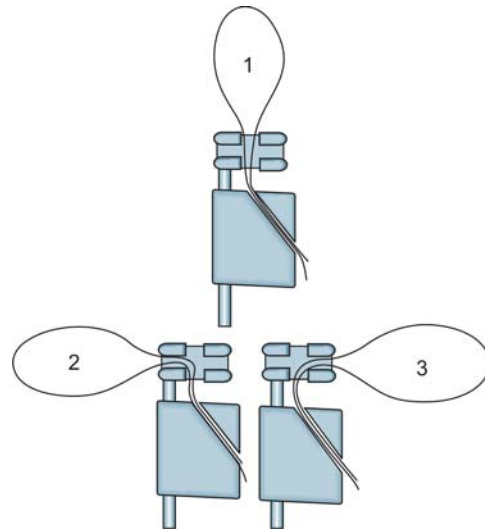
**Fig. 6.9:** Slots of head should always be directed gingivally



**Fig. 6.10:** Slots should not be directed occlusally



**Fig. 6.11:** Assembled Tofflemire matrix band with retainer



**Fig. 6.12:** Loop from band can extend in straight, right or left direction

### Parts of Tofflemire Retainer

#### Head

- Uses slots for positioning of matrix
- U-shaped head with two slots in open side
- Open side of the head should be facing gingivally when the band is placed around the tooth (**Figs 6.9 and 6.10**).

#### Slide (Diagonal slot)

1. Amount of band extending beyond the slot depends upon type of tooth to be treated.
2. This portion is located near the head for installation of band in the retainer, helps in placement of band around the tooth.

#### Knurled nuts

1. Two knurled knots in retainer
  - a. Large knurled nut—near the matrix band
  - b. Small knurled nut.
    - a. *Large knurled nut (Also known as rotating spindle)*
      - Helps in adapting the loop of matrix band against the tooth.

- Helps in adjusting the size of loop of matrix band against the tooth.
- b. *Small knurled nut*—helps in tightening the band to retainer.

**Assembly of retainer:** When band and retainer are assembled, two ends of band must be of same length protruding from the diagonal slot (**Fig. 6.11**).

Loop extending from retainer can project in following ways (**Fig. 6.12**):

1. Straight—used near anterior teeth
2. Left/right—used mostly in posterior areas of oral cavity.

While adapting the matrix band to retainer loop of the matrix, band appears as funnel-shaped, i.e. one side of the opening has greater diameter than other (**Fig. 6.13**). Opening



**Fig. 6.13:** Tofflemire with band in place

with greater diameter should be placed occlusally while with lesser diameter should be placed gingivally.

### Types of bands

Two types of bands are usually used:

1. Flat bands
2. Precontoured bands.

#### 1. Flat bands

- a. Available in two thicknesses
  - i. 0.0020 inches
  - ii. 0.0015 inches
 Any of these thicknesses can be used, it depends upon operators preference.

- b. According to shapes, three shapes of flat bands are available (**Fig. 6.14**)

- i. No. 1 or universal band
- ii. No. 2 or (MOD band): It has two extensions projecting at gingival edge. It is commonly used in molars.
- iii. No. 3: Similar to No. 2 band in design but narrower than No. 2.

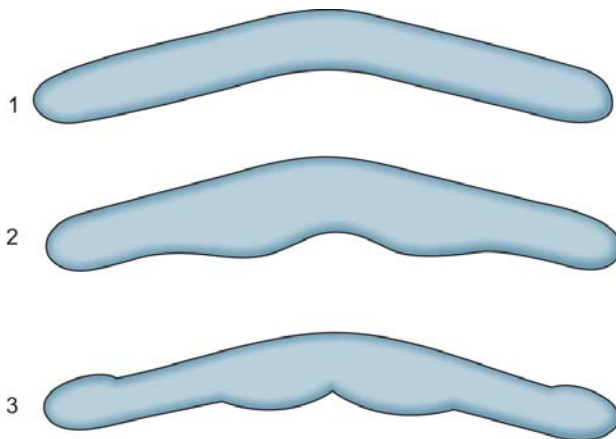
- Flat band needs to be contoured before placing it in retainer. Contouring of band can be done with the help of:

- i. Ovoid burnisher
- ii. Spoon excavator (using its convex side).

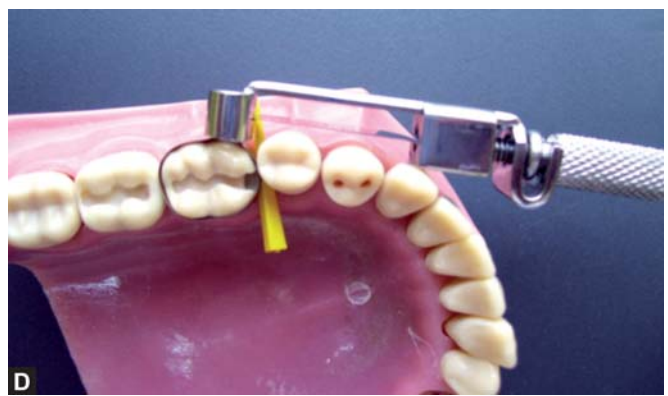
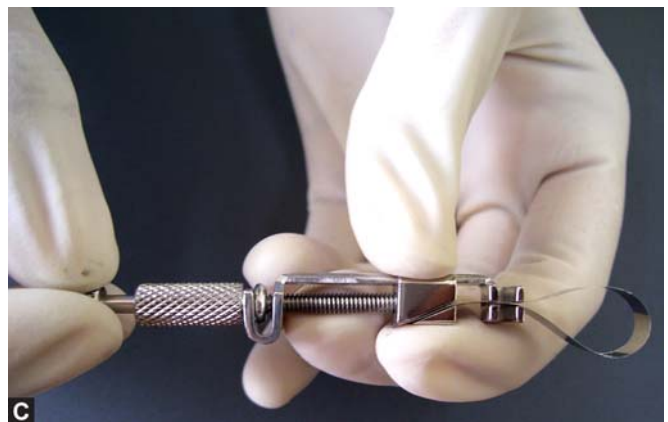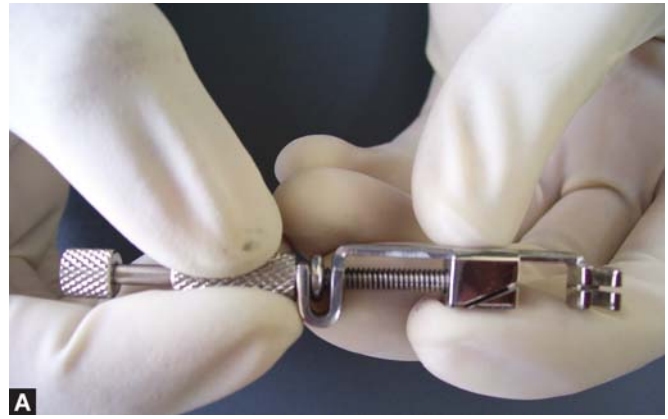2. *Precontoured bands*: They are also available but less commonly used. While removing these bands, one must take care of contour of band. Band should be rotated in such a way that its trailing end should not fracture the restoration.

### Operative instruction for placement (Figs 6.15A to D)

1. First open the large knurled nut so that slide is at least  $\frac{1}{4}$  inch from the head (**Fig. 6.15A**).



**Fig. 6.14:** Three types of Tofflemire bands



**Figs 6.15A to D:** Placement of Tofflemire retainer

2. Hold the knurled nut (large) with one hand, open the small knurled nut in opposite direction (counter clockwise) for clearance of diagonal slot for reception of matrix band (**Fig. 6.15B**).
3. Two ends of matrix band are secured together to form loop or either use preformed loop (**Fig. 6.15C**).
4. Place the ends of band in diagonal slot.
5. Then, small knurled nut is tightened to secure the band to the retainer.
6. After securing the band tightly to the retainer, it is placed around the tooth to be restored.
7. For final adaptation of matrix band to the tooth, tighten the large knurled nut (**Fig. 6.15D**).
8. *Wedge placement:* Wedge should be placed after the retainer and band are snugly fitted to the tooth. Always insert the wedge from widest embrasure area. Wedge helps in developing the adequate contact and contour despite the thickness of material.

#### **Procedure for removal**

This is usually accomplished in two steps:

1. Removal of retainer
2. Removal of band.

#### **Removal of retainer**

Small knurled knot is moved counter clockwise to free the band from the retainer. While rotating the smaller knurled knot, hold the larger knot. Keep the index finger on occlusal surface of tooth to stabilise the band.

#### **Removal of band**

1. Carefully remove the band from each contact point
2. Support the occlusal surface of the restoration. While removing the band, a condenser can be held against the marginal ridge of the restoration
3. Do not pull band in occlusal direction rather move the band in facial or lingual direction
4. Band can be cut near to the teeth on the lingual side and then try to pull it from the buccal side.

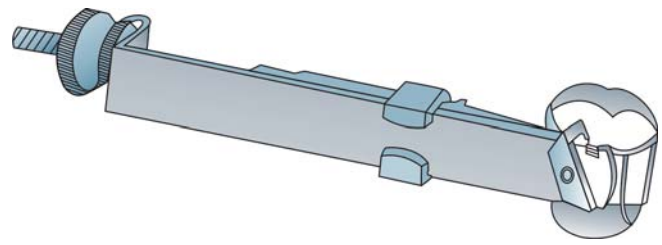
#### **Modification in Tofflemire retainer**

##### **Omni matrix**

1. Preassembled Tofflemire retainer
2. One time use (disposable)
3. Available with band thickness
  - 0.0010 inch thick
  - 0.0015 inch thick

*Advantage:* Takes less time to use.

*Disadvantage:* Expensive.



**Fig. 6.16:** Siqueland matrix retainer

#### **Steele's Siqueland Self-adjusting Matrix Holder for Tapering Teeth**

It is especially used when there is a significant difference between the diameters of the cervical and occlusal one-third of the tooth (**Fig. 6.16**). This matrix retainer can give two different diameters at the two ends of the matrix band. It is based on the principle of a movable slide which holds and tightens the band in the required position.

#### **Indication**

All types of compound and complex tooth preparations in posterior teeth.

#### **Advantages**

- Can adapt to tooth contour properly
- Due to Steele's siqueland self-adjusting matrix holder anatomic adaptation of the band is possible without the help of wedges.

#### **Anatomical Matrix Band/Compound Supported Matrix**

It was described by Sweeney. These are adapted over the tooth with one healthy tooth on either side. To contour the band according to tooth, pliers are used, though precontoured anatomic matrix bands are also available. For further adaptation of the band to surface of the tooth, wedges are placed. Buccal and lingual embrasures are sealed with the help of self cure acrylic or impression compound cones.

#### **Advantages**

- Provides better contact and contour in restoring class II tooth preparation.
- Adequate rigid and stable than other matrix system
- Easy to remove
- Little proximal carrying is required
- Recontouring can be easily done after compound placement.

**Disadvantage**

Time consuming.

**Indications**

- Restoration of class II proximal tooth preparation involving one surface or both
- Large restoration, not supported by adjacent teeth.

**Materials Used**

- Matrix band of width 5/16 inch (8 mm) and 0.002 inch (0.05 mm) thick stainless steel matrix band
- Impression compound or low fusing compounds.

**Procedure**

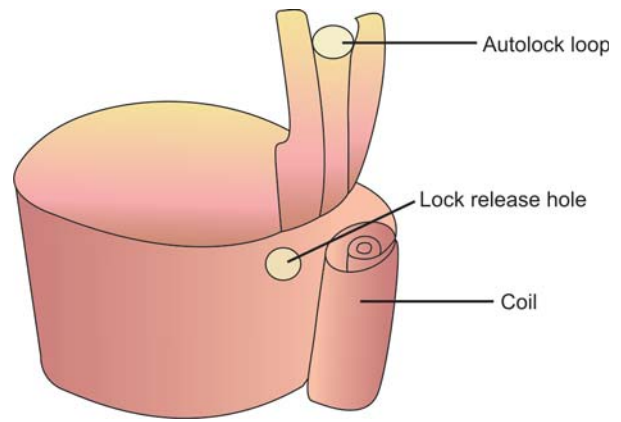
1. Cut a sufficient length of matrix band so that it covers 1/3rd of facial and lingual surface along with prepared proximal tooth preparation.
2. Contour the band with egg-shaped burnisher in a back and forth motion to achieve desired proximal as well as facial and lingual contour of the tooth.
3. Check the contour of band occlusogingivally as well as facially and lingually.
4. Wedging should be done after securing the band in right position.
5. Heat one end of impression compound over flame for 5-10 seconds.
6. When compound starts drooping, carry it with dampened glove fingers into the oral cavity.
7. After the compound is pressed into desired place, cool and harden it with air.
8. Recontouring of band can easily be done by pressing the warmed instrument to inside of matrix to soften the compound.
9. For extraretention and stability:
  - a. Compound can be carried over cusps of adjacent teeth
  - b. Staple-shaped piece of metal can be inserted after warming for holding the facial and lingual compound together.

**Removal**

1. Easy to remove
2. Can be easily removed with sharp instrument such as enamel hatchet or Hollenback carver.

**Retainerless Automatrix System**

This matrix system can be adjusted according to tooth shape and size. The bands are available in different sizes, and come in preformed and disposable form (**Fig. 6.17**). Height of



**Fig. 6.17:** Automatrix band

bands vary from 3/16 to 5/16 inch. Thickness of bands can be 0.038 mm or 0.05 mm. The matrix is adapted over the tooth with the clip on the buccal aspect. To tighten the band, an automate mechanical device is used. Once the restoration is complete, the band is cut with the help of cutting pliers.

**Indications**

- In tilted and partially erupted teeth
- In patients who cannot tolerate retainers
- For complex amalgam restorations.

**Advantages**

- Simple to use
- Convenient
- Takes less time to apply
- No interference from retainer, so increased visibility.

**Disadvantages**

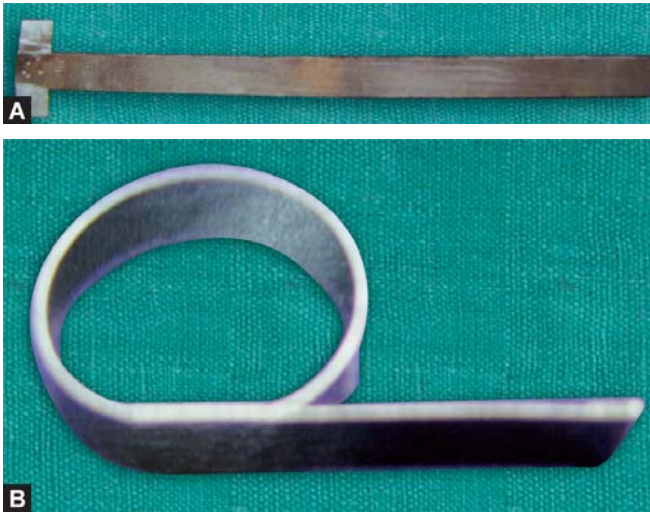
- Unable to develop proper contours
- Costly
- Difficult to burnish because bands are flat.

**T-shaped Matrix Band**

This is preformed brass, copper or stainless steel matrix bands without a retainer. In this band, the long arm of the T surrounds the tooth and overlaps the short arm of the T (**Figs 6.18A and B**). The band is adapted according to the tooth shape and size. Wedges and impression compound may be used to provide further stability to the band.

**Indication**

Unilateral or bilateral class II (MOD) tooth preparations.



**Figs 6.18A and B:** (A) T-shaped band, and (B) T-band matrix

#### Advantages

- Simple to use
- Economical.

#### Disadvantage

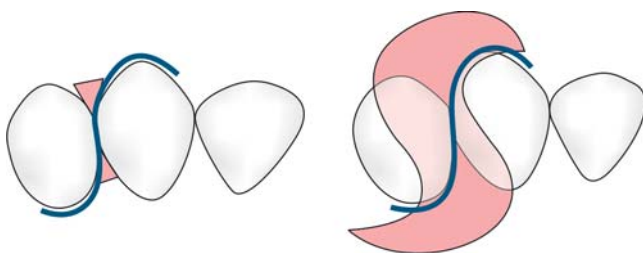
Not stable in nature.

#### S-shaped Matrix Band

S-shaped matrix band is used for restoring distal part of canine and premolar. In this, stainless steel matrix band is taken and twisted like “S” with the help of a mouth mirror handle. The contoured strip is placed interproximally over the facial surface of tooth and lingual surface of bicuspid (Fig. 6.19). To increase its stability, wedge and impression compound can be used.

#### Indications

- For restoring distal part of canine and premolar
- Class II slot restorations.



**Fig. 6.19:** S-shaped matrix band

#### Advantage

Offers the optimal contour for distal part of canine and premolar.

#### Disadvantage

Cumbersome to apply and remove.

#### Full Circle or Ring Bands

Copper or stainless steel full circle or ring bands are generally indicated for mesio-occlusodistal compound preparations and complex preparations. Band is selected according to required size, softened by heating to a red hot state and quenching in water. After all these it is contoured using pliers, trimmed by cutting pliers and finished by finishing stones. Occlusal height of the band is also adjusted accordingly. Proximal contact of the band may be thinned using a small round fine, grinding stone. Wedges and impression compound can also be used to further stabilize the band.

After condensation of restoration is done, the band can be cut by means of a bur at the same appointment or the next day.

#### Indications

- For restoring badly broken and mutilated teeth
- Mesio-occlusodistal compound tooth preparations and complex tooth preparations.

#### Advantage

Offers the optimal contour for damaged teeth.

#### Disadvantage

Time consuming to apply and remove.

#### Plastic Matrix Strips

These are transparent matrix strips used for tooth colored restorations. They can be of different types:

- Celluloid (Cellulose nitrate) strips are used for silicate cements
- Cellophane (Cellulose acetate) strips are used for resins.
- Mylar strips used for composite and silicate restorations (Fig. 6.20).

For class IV tooth preparations, the strip is folded in “L Shape”. The matrix is measured and cut so that one side is as wide as the length of the tooth and the other side is as wide as the width of the tooth. The matrix strip is burnished



Fig. 6.20: Mylar strips

over the end of a steel instrument (e.g. a tweezer handle) to produce a convexity in the strip. This convex contoured surface is positioned facing the proximal surface of the tooth to be restored. A wedge is used for further stabilization and adaptation of the strip.

The preparation is filled to slight excess and one end of the strip is brought across the proximal surface of the filled tooth. The other end of the strip is folded over the incisal edge. The matrix is held with the thumb of the left hand till the initial setting or curing takes place.

#### Indication

For restoring class III and IV tooth preparations.

#### Advantages

- Simple and easy to use
- Economical.

#### Disadvantage

Lack of stability.

### Precontoured Matrix/Palodent Bitine System

This system consists of precontoured matrices made up of soft metal. In this, the wedge is used to separate the teeth and hold the sectional matrix in position.

The “BITINE” springy ring wedge along with matrix is shaped to provide the proximal contours of a posterior tooth.

#### Steps of Application and Removal

- Approximately 3 mm blob of impression compound is applied to each of its tips.
- The ring is held with rubber dam forcep.
- Impression compound is warmed quickly over the flame and carried into the oral cavity.
- Beaks are placed into the embrasures of the preparation side and ring is allowed to shrink. Ring tightly seals the sectional matrix band around the tooth due to spring action.
- The matrix band is properly contoured with a ball burnisher so as to adapt it to the tooth.
- After this, gingival wedge is inserted under the contact area.
- After checking the fit of the matrix band, restoration is completed.
- Then the ring is widened apart and removed.
- The wedge is removed after this.

#### Indication

For restoring class II compound or complex tooth preparations.

#### Advantages

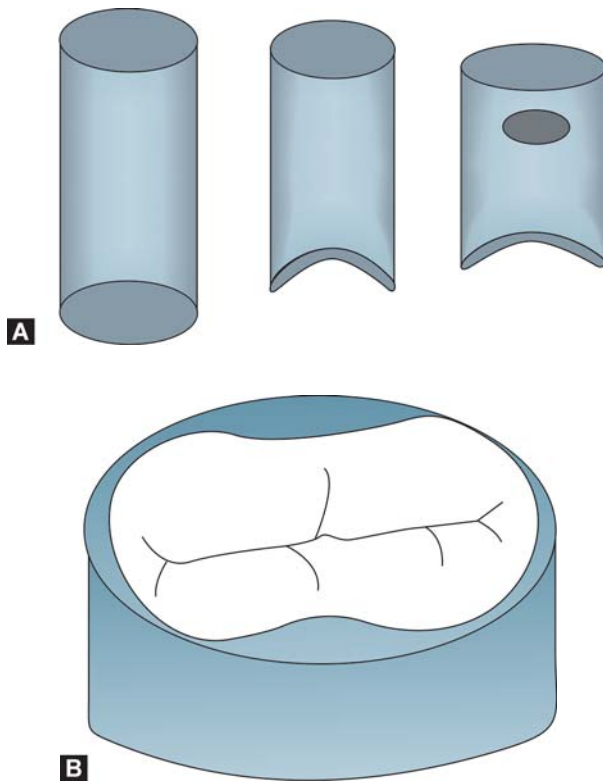
- Simple and easy to use
- Provides tooth separation
- Offers better contours with composite restorations.

#### Disadvantages

- Tight contacts may prevent insertion of the band
- Expensive.

### Aluminium or Copper Collars

These are preshaped for class V restorations according to the gingival third of the buccal and lingual surfaces. They can be adjusted so as to cover 1 to 2 mm of the tooth surface circumferentially beyond the preparation margins (Figs 6.21A and B). After selecting appropriate size, they are mounted on the tip of a softened stick of compound which is being used as a handle. After the restoration is placed in preparation, apply the selected matrix onto the tooth till the initial setting is over.



**Figs 6.21A and B:** (A) Copper band matrix, and (B) Copper band matrix in place

#### Indication

For restoring class V preparations.

#### Advantages

- Simple and easy to use
- Offers better contours.

#### Disadvantage

Cannot be used with resin restorations.

#### Transparent Crown Forms Matrices

These are “Stock” plastic crowns which can be contoured according to tooth shape and size. These are specially used for bilateral class IV preparation. After selecting the appropriate crown form, it is trimmed to fit 1mm beyond the preparation margins. When composite restoration is loaded in this crown form, it is positioned over the prepared tooth and cured. After the restoration is completed, this crown form can be cut with the help of burs for its removal. For unilateral class IV, the plastic crown is cut incisogingivally to use one-half of the crown according to the side of restoration.

#### Indication

For restoring class IV tooth preparations and fractured teeth.

#### Advantages

- Simple and easy to use
- Offers better contours.

#### Disadvantages

- Time consuming
- Costly.

#### Anatomic Custom Made Matrix

This matrix offers best contours and contact for restoration of compound or complex class II tooth preparations. In this, the defective area is restored on study model to tooth anatomy with the help of heat-resistant material like plasticine, acrylic resin or impression compound.

By using combination of heat to soften the template material, followed by suction to draw the moldable material onto the study model, a plastic template is made for the restored tooth. After this, for fitting tooth this template is trimmed gingivally. Template should hold at least one sound tooth on each side. The restorative material is loaded into the preparation, then the matrix filled with the material is inserted and properly seated over the tooth and cured.

#### Indication

For restoring class IV preparations and fractured teeth.

#### Advantages

- Simple and easy to use
- Offers better contours.

#### Disadvantages

- Time consuming
- Costly.

#### TOOTH SEPARATION

Separation of teeth is defined as the process of separating the involved teeth slightly away from each other or bringing them closer to each other and/or changing their spatial position in one or more dimensions.

#### Reason for Tooth Separation

Following are reasons for tooth separation:

1. **Examination:** For examination of initial proximal caries which is usually not seen on the radiograph.

2. **Preparation of teeth:** For providing accessibility to proximal area during preparation of class II and class III tooth preparations.
3. **Polishing of restorations:** Tooth separation helps in providing accessibility to the proximal area of class II and class III tooth preparations.
4. **Matrix placement:** Matrix can be placed easily during restoration of class II restoration.
5. **Removal of foreign bodies:** Foreign bodies and objects, forced interproximally, can be removed using tooth separation.
6. **Repositioning shifted teeth:** It also helps to some extent in repositioning of shifted teeth.

### Methods of Tooth Separation

There are two methods which are usually used for tooth separation. These are:

1. Slow or delayed separation
2. Rapid or immediate separation.

#### Slow or Delayed Separation

In this separation, teeth are slowly and gradually shifted apart by inserting some materials between the teeth. This separation usually takes long time, i.e from several days to weeks.

**Indications:** Tilted, drifted and rotated teeth in which rapid separation is not useful.

**Advantages:** One of the main advantages of slow tooth separation is that tooth repositioning occurs without damage to periodontal ligament fibers.

#### Disadvantages

1. Time consuming
2. May require many visits.

#### Methods for achieving slow separation

1. Separating rubber ring/bands
2. Rubber dam sheet
3. Ligature wire/copper wire
4. Gutta-percha stick
5. Oversized temporary crowns
6. Fixed orthodontic appliances.

#### Separating rubber ring/band (Fig. 6.22)

- Separating rubber band is usually used in orthodontic cases.
- It is stretched and placed interproximally between the two teeth to achieve separation.
- It may take 2-3 days to 1 week.




Fig. 6.22: Separating rings

#### Rubber dam sheet (Fig. 6.23)

- It is stretched and placed interproximally between the teeth.
- Usually heavy or extra-heavy type is preferred due to thickness of sheet.
- Time for tooth separation may vary from 1 hour to 24 hours or more.
- In case of pain and swelling, a floss may be used to remove the sheet.




Fig. 6.23: Rubber dam sheet






Fig. 6.24: Ligature wire

#### Ligature wire/copper wire (Fig. 6.24)

- Wire is passed beneath the contact area to form a loop.
- Tightening of wire loop is done by twisting two ends together. This causes increase in the separation.
- Separation is usually achieved in 2-3 days.

#### Gutta-percha stick

- It is softened with heat and packed into proximal area.
- Usually indicated for adjoining tooth preparation of posterior teeth.
- Tooth separation usually takes 1 week to 2 weeks.

**Oversized temporary crowns:** Oversized temporary crowns is also one of methods for slow separation.

In this, acrylic resin is periodically added in the mesial and distal contact area to increase the separation.

#### Fixed orthodontic appliances

- Indicated only in cases where extensive repositioning of teeth is required.
- Most predictable and effective method.

#### Rapid or Immediate Tooth Separation

Rapid separation is most frequently used method in which tooth separation can be achieved in very short span of time.

#### Advantages

1. More useful and advantageous than slow separators
2. Quicker than slow separators
3. More predictable.

#### Principles used in rapid separator

1. Traction principle
  2. Wedge principle.
1. **Traction principle used for separation:** This type of principle always uses mechanical devices which engage the proximal area of the tooth with holding arms. These

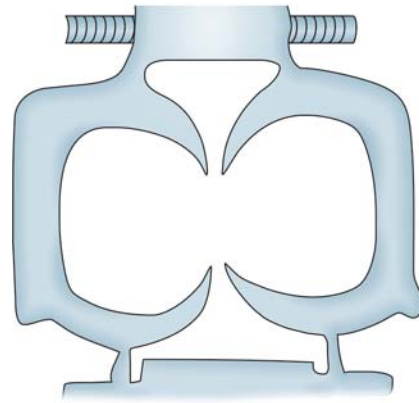


Fig. 6.25: Ferrier double bow separator

holding arms are moved apart to create the separation between the contacting teeth. Few devices are based on this principle which are:

- a. Ferrier double bow separator
- b. Non-interfering true separator.

#### a. Ferrier double bow separator (Fig. 6.25)

- As the name indicates, it has 2 bows.
- Each bow engages the proximal contact area of tooth just gingival to contact area of tooth.
- A “Wrench” system is used for turning the threaded bars, this helps in causing separation.

#### Advantages

- Stabilization of the separation throughout operation.
- Separation is achieved at expense of both contacting teeth rather than one tooth.

**Uses:** Tooth preparation and during finishing and polishing of class III direct gold restoration.

#### b. Non-interfering true separator:

As the name indicates, it is non-interfering type rapid separator.

It is used where continuous stabilized separation is required.

#### Advantages

- Separation can be increased or decreased after stabilization.
- Non-interfering in nature.

#### 2. Wedge principle used for rapid separation:

A pointed, wedge-shaped mechanical device is inserted beneath the contact area of teeth, which in turn, produce the separation.

This is usually accomplished by 2 means:

- a. Elliot separator
- b. Wedges

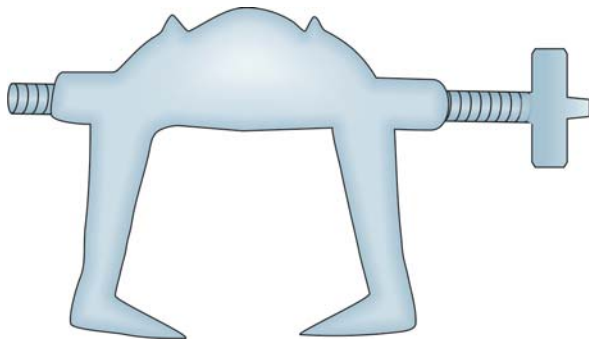


Fig. 6.26: Elliot separator

a. **Elliot separator (Fig. 6.26)**

- Also known as “Crab claw” separator because of its design.
- Mechanical device consisting of:
  - Bow
  - Two holding jaws
  - Tightening screw.
- Two holding jaws are positioned gingival to contact area without damaging the interproximal area.
- Clockwise rotation of tightening screw moves the contacting teeth apart.
- The separation should not be more than thickness of periodontal ligament, i.e. 0.2-0.5 mm.

*Uses:* Used for examination and final polishing of proximal restoration.

- b. **Wedges (Fig. 6.27):** Wedges are devices which are usually preferred for rapid tooth separation. These are used in tooth preparation and restoration.



Fig. 6.27: Wedges

*Functions of wedges*

- Help in rapid separation of teeth
- Prevent gingival overhang of restoration
- Provide space to compensate for thickness of matrix band
- Help in stabilization of retainer and matrix during restorative procedures
- Provide close adaptability in cervical portions of the proximal restorations, thereby help in achieving correct contour and shape at cervical area
- Help in retracting and depressing the interproximal gingival area, thus help in minimizing trauma to soft tissue
- Help in depressing rubber dam in interproximal area.

**Types of wedges**

1. Wooden wedges
2. Plastic wedges

1. **Wooden wedges**

- These are most commonly used and preferred as they can be easily trimmed and can be fitted in gingival embrasure
- Adapt well in the gingival embrasure
- Easy to use
- Wooden wedges absorb water, thus increase the interproximal retention
- Provide stabilization to matrix band
- Available in 2 shapes:
  - a. Triangular
    - Most commonly used
    - It has two positions—apex and the base
    - Apex of the wedge usually lies in gingival portion of the contact area
    - Base lies in contact with gingiva. This helps in stabilization and retraction of gingiva
    - Used in tooth preparations with deep gingival margins.
  - b. Round wedge
    - Not so commonly used
    - Made from wooden tooth picks by trimming the apical portion
    - It has uniform shape
    - Used in class II tooth preparation.

2. **Plastic wedges:** Though commercially available, they are not much preferred because:

- Trimming is difficult
- Adaptability is difficult in some cases.

**Light-transmitting wedge**

- As the name indicates this type of wedge transmits 90-95% of incident light
- It is a type of plastic wedge
- Transparent in nature
- Designed for use in cervical area of class II composite resin restoration.

**Advantages of light-transmitting wedges over other wedges in composite restorations**

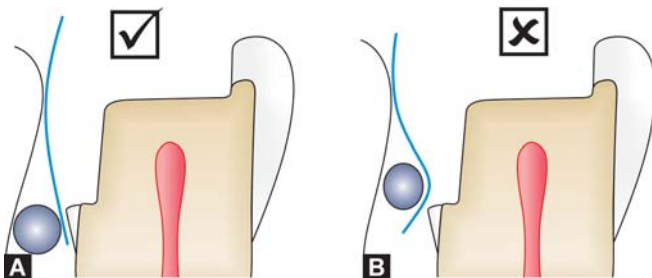
- Help in reducing the polymerization shrinkage as these transmit light
- Better adaptability.

**Important points regarding wedges**

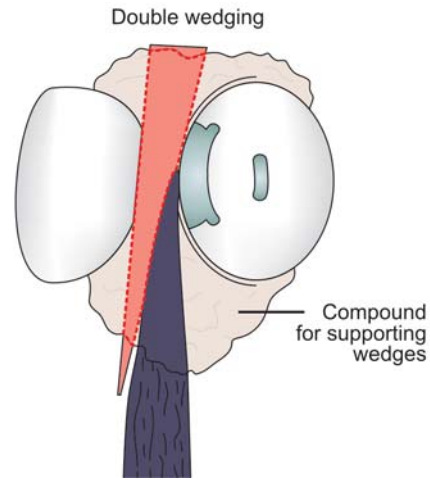
- Select the type and shape according to requirement. These are:

Type of wedge	Indications
Round wooden	Conservative class II preparations
Triangular wooden	Preparation with deep gingival margin
Plastic wooden	Preparation with deep gingival margin
Light transmitting	Cervical portion of class II composite wedge

- Length of the wedge should be in the range of 1-1.2 cm.
- It should not irritate tongue, cheek and gingival tissue.
- Wedge should be inserted beneath the contact area in the gingival embrasure (**Figs 6.28A and B**).
- Usually inserted from lingual embrasure area as it is wider than buccal area. Sometimes when it irritates tongue; it can be inserted from buccal area also.
- Wedge should be firm and stable during restorative procedure.
- Should not be forcibly inserted in the contact area leading to pain and swelling.



**Figs 6.28A and B:** Wedge in place (A) Correct position, and (B) Incorrect position



**Fig. 6.29:** Double wedging technique

**Modified wedging techniques**

1. Double wedging
2. Wedge wedging
3. Piggyback wedging

**1. Double wedging (Fig. 6.29)**

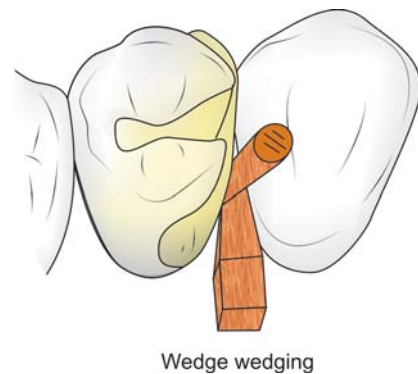
Two wedges are used: One is inserted from buccal embrasure and the other is inserted from lingual embrasure.

This technique is indicated in following cases:

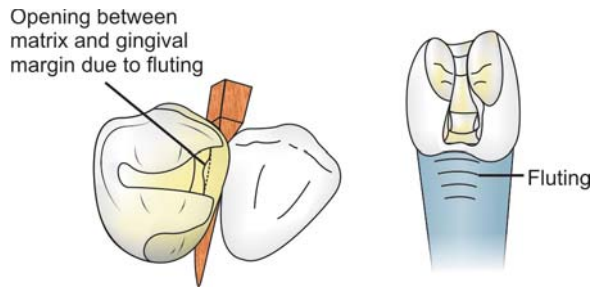
- Spacing between adjacent teeth where single wedge is not sufficient
- Widening of proximal box in buccolingual dimension.

**2. Wedge wedging (Fig. 6.30):**

- In this technique, two wedges are used
- One wedge is inserted from lingual embrasure area while the other is inserted between the wedge and matrix band at right angle to first wedge
- Primarily indicated while treating mesial aspect of maxillary first premolar.



**Fig. 6.30:** Wedge wedging technique



**Fig. 6.31:** Fluting in the roots near gingival area

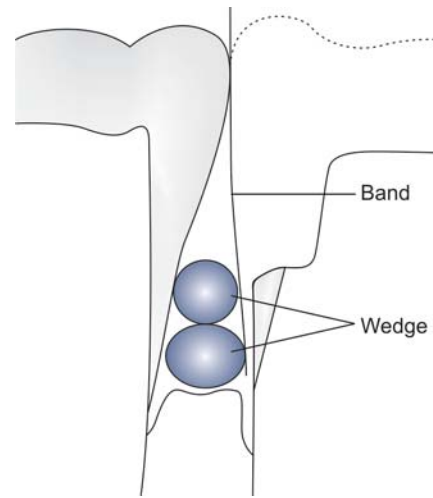
These are primarily indicated in upper first premolar because of presence of flutes in root near the gingival area (**Fig. 6.31**)

**Piggyback wedging (Fig. 6.32):** In this technique two wedges are used.

- One (larger) wedge is inserted as used normally, while the other smaller wedge (piggyback) is inserted above the larger one.
- It is indicated in cases of shallow proximal box with gingival recession.
- This technique provides closer adaptation and contour of the matrix band.

### VIVA QUESTIONS

- Q. What is tooth separation?
- Q. What is purpose of tooth separation?
- Q. How can you achieve tooth separation?
- Q. What are different ways of slow separation?
- Q. What are different ways of rapid separation?
- Q. What is Elliot separator?
- Q. What is Ferrier separator?
- Q. What are wedges?
- Q. What is principle of wedging?
- Q. What are different types of wedges?
- Q. Why are advantages of wooden wedges?
- Q. What are functions of wedges?
- Q. What are different techniques of wedging?
- Q. What are matrices?
- Q. What are objectives of matricing?
- Q. What are requirements of a matrix band?
- Q. What are different materials used for matricing?
- Q. What are matrix retainers?

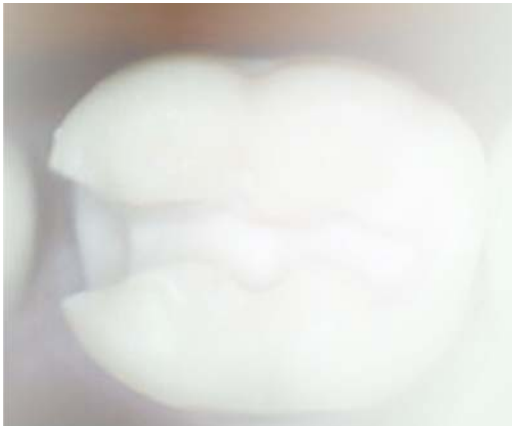

**Fig. 6.32:** Piggyback wedging

- Q. Classify matrix retainers?
- Q. What is Ivory No. 1 retainer? What are its advantages and disadvantages?
- Q. Describe Ivory No. 8 retainer?
- Q. What are advantages and disadvantages of Tofflemire retainer?
- Q. How is tofflemire retainer applied?
- Q. What are different types of Tofflemire bands?
- Q. Classify Tofflemire retainers.
- Q. What is T band matrix?
- Q. What is window matrix?
- Q. What is 'S' Shaped matrix?
- Q. What are the consequences of not restoring proximal area?
- Q. What is mylar strip?
- Q. What is double wedging technique?
- Q. What is wedge wedging technique?
- Q. What is double matricing technique? (Balter's technique)

**Ans.** In case of buccal or lingual preparations, it is difficult to form cervico-occlusal contour of buccal and lingual surface because of the convexity of occlusal two-third.

In these cases, second band is inserted to cover the occlusal part of buccal or lingual surface between the tooth and the band which is already applied. Both bands can be stabilized using a softened compound between the bands.



# Principles of Tooth Preparation

## Chapter 7

### INTRODUCTION

#### PURPOSE OF TOOTH PREPARATION

- Preventing and Treating Caries
- Replacing Restorations
- Treatment of Malformed, Fractured and Traumatized Teeth
- Esthetic Improvement
- For Restoration of Loss of Tooth Material
- Types of Restoration

#### TERMINOLOGY OF TOOTH PREPARATION

- Tooth Preparation
- Simple, Compound and Complex Tooth Preparation
- Tooth Preparation Walls
- Cavosurface Angle Margin/Tooth Preparation Margin
- Angle

#### NUMBER OF LINE ANGLES AND POINT ANGLES IN DIFFERENT TOOTH PREPARATION DESIGNS

- Class I Tooth Preparation
- Class II Tooth Preparation
- Class III Tooth Preparation
- Class IV Tooth Preparation
- Class V Tooth Preparation

#### TOOTH PREPARATION

- Classification of Tooth Preparations

#### STEPS IN TOOTH PREPARATION

- Initial Tooth Preparation
- Final Stages of Tooth Preparation
- Air Abrasion/Kinetic Tooth Preparation
- Technique
- Advantages of Air Abrasion
- Disadvantages
- Uses of Air Abrasion Technology

### INTRODUCTION

Operative dentistry requires essential knowledge of basic tooth preparation, which is important to the dental practitioner. The most important fundamental procedure of operative dentistry is tooth preparation to receive a restoration so that it can fulfill all its requirements. Therefore, it is a must for every operative clinician to be well aware of all the fundamentals of the tooth preparation. A cavity is a defect in the mineralized dental tissues which results from pathological processes like caries, attrition, abrasion and erosion.

The tooth preparation includes all mechanical procedures performed to remove all infected and affected tissues and to give proper design to the remaining hard dental tissues, so that a mechanically and biologically sound restoration

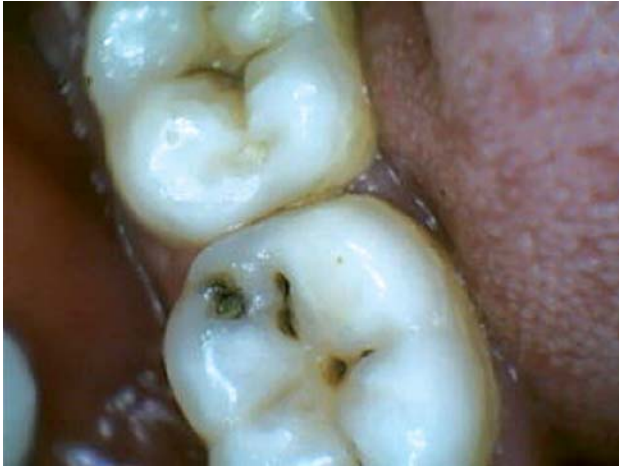can stay in the prepared tooth. Tooth preparation is a surgical procedure that removes the caries till the sound tooth tissue of proper shape is reached which will retain a restorative material that resists masticatory forces, maintains form function and esthetics.

#### PURPOSE OF TOOTH PREPARATION

Restoration is usually required to repair a diseased, injured or defective tooth structure. The restoration helps in maintaining proper form, function and esthetics.

#### Preventing and Treating Caries

Dental caries is one of the most common diseases with approximately 80% of the population in developed countries (Fig. 7.1).



**Fig. 7.1:** Photograph showing carious tooth which needs restoration

The aim of prevention and treatment is to maintain a functioning set of teeth. Interventions can halt and even reverse the development of caries.

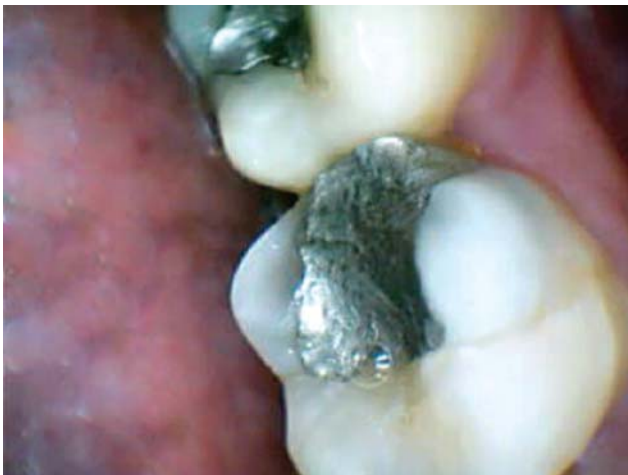### Replacing Restorations

Restorations may fail due to a number of “objective” factors which further depend upon characteristics of the restorative material, operator skill and technique, patients’ dental characteristics, and the environment around the tooth.

The decision to replace a restoration is affected by factors such as condition of restoration, health of the tooth, and the criteria used to define failure and patient demand (**Fig. 7.2**).

### Treatment of Malformed, Fractured and Traumatized Teeth

Restorations are needed to treat malformed, fractured or traumatized teeth so as to retain them to normal form and function.



**Fig. 7.2:** Photograph showing an old restoration needing replacement

### Esthetic Improvement

Teeth which are unesthetic and discolored can be treated by esthetic restorations.

### For Restoration of Loss of Tooth Material

Attrition, abrasion or erosion of teeth can be treated by different restorative materials depending upon the extend and location of the lesion.

### Types of Restoration (Figs 7.3A and B)

Tooth restoration may be classified as intracoronal, when it is placed within a preparation made in the crown of a tooth or extracoronal, when it is placed outside the tooth as in the case of a crown. Intracoronal restoration is placed directly into the tooth preparation while extracoronal restoration uses an indirect technique.

The materials used to restore teeth are: dental amalgam, composite resins, glass ionomer cements, resin-modified glass ionomer cements, compomers and cermets, cast gold and other alloys, and porcelain.

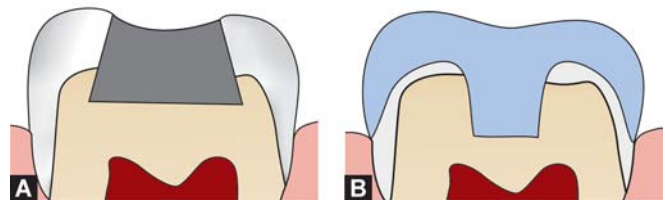
#### Factors affecting the decision to restore a tooth

##### Tooth factors

- Primary or permanent
- Occlusal stresses
- Quality of tooth (hypoplasia)
- Location of tooth
- Type of tooth
- Type of tooth preparation.

##### General patient factors

- Patient’s exposure to fluoride
- Age
- Xerostomia
- Socioeconomic status
- Diet
- Caries status
- General health
- Presence of any parafunctional habit.



**Figs 7.3A and B:** (A) Intracoronal amalgam restoration, (B) Extracoronal restoration

**Factors related to clinician and the restoration to be used**

- Type of restoration
- Physical properties of the restoration
- Whether moisture control can be achieved or not
- Technical expertise

**TERMINOLOGY OF TOOTH PREPARATION**

**Tooth Preparation**

It is a mechanical alteration of a defective, injured or diseased tooth in order to best receive a restorative material which will re-establish the healthy state of the tooth including esthetics correction when indicated along with normal form and function (Fig. 7.4).

**Simple, Compound and Complex Tooth Preparation**

*Simple Tooth Preparation*

A tooth preparation involving only one tooth surface is termed simple preparation (Fig. 7.5). For example, mesial, distal, occlusal, buccal, lingual tooth preparation.

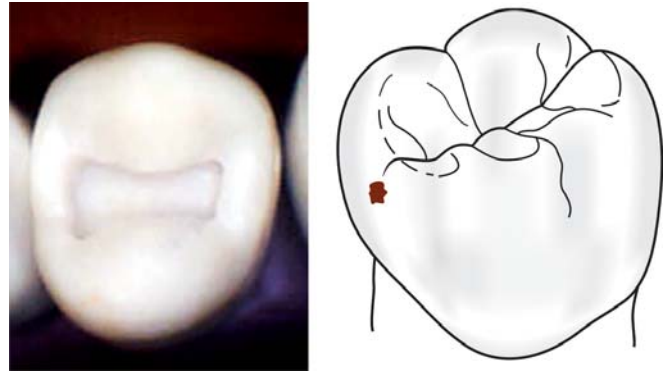
*Compound Tooth Preparation*

A tooth preparation involving two surfaces is termed compound tooth preparation (Fig. 7.6). For example, mesio-occlusal (MO), disto-occlusal (DO), mesiolingual (ML), or distobuccal (DB) tooth preparation.

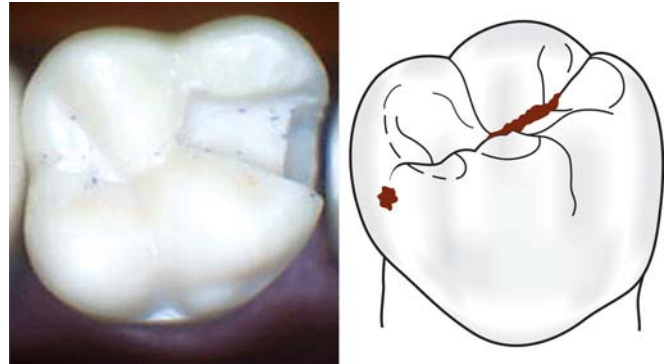
*Complex Tooth Preparation*

A tooth preparation involving more than two surfaces is called as complex tooth preparation (Fig. 7.7). For example,

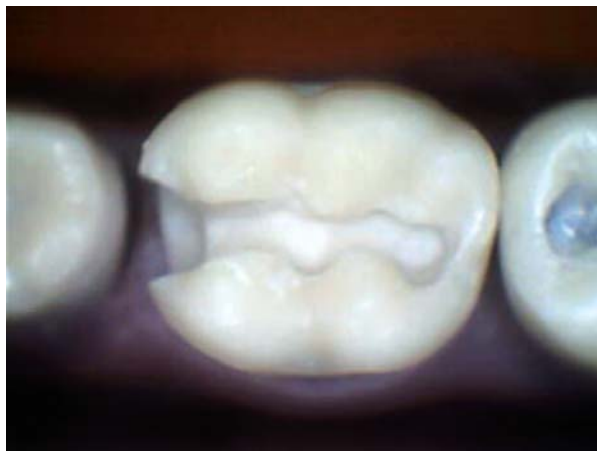mesio-occlusodistal (MOD), facio-occlusolingual (FOL) or mesioincisodistal (MID) tooth preparation.



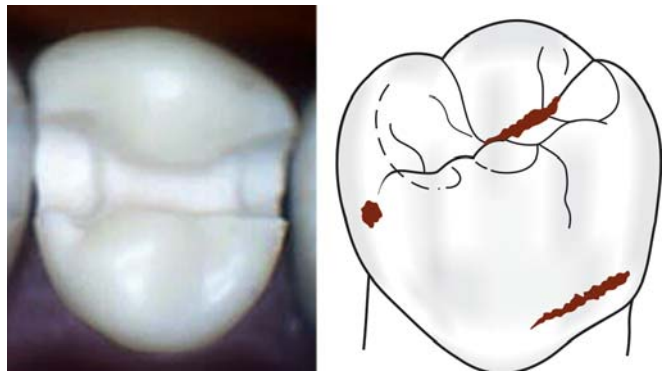
**Fig. 7.5:** Simple tooth preparation involving one tooth surface only



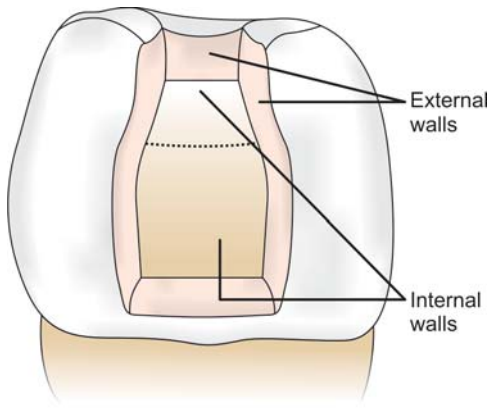
**Fig. 7.6:** Compound tooth preparation involving two surfaces



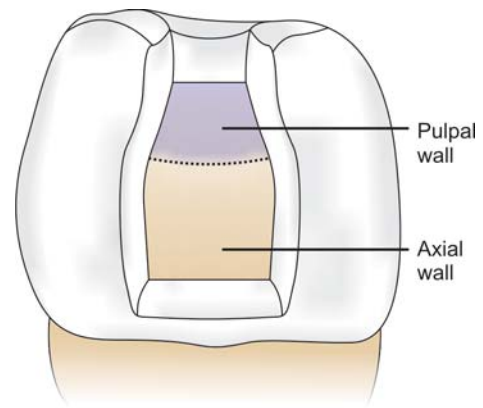
**Fig. 7.4:** Photograph showing tooth preparation on molar



**Fig. 7.7:** Complex tooth preparation involving more than two surfaces



**Fig. 7.8:** Internal wall of tooth preparation



**Fig. 7.10:** Pulpal wall

## Tooth Preparation Walls

### Wall

Any surface of the tooth preparation is referred to as a wall.

### Internal Wall

It is a wall in the preparation, which is not extended to the external tooth surface (**Fig. 7.8**).

### External Wall

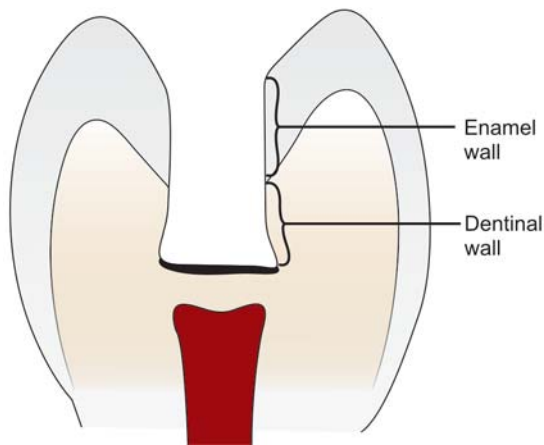
An external wall is a wall in the prepared tooth surface that extends to the external tooth surface (**Fig. 7.9**). External wall takes the name of the tooth surface towards which it is situated.

### Enamel Wall

An enamel wall that portion of tooth preparation which is composed of enamel.

### Dentin Wall

A dentin wall that portion of tooth preparation which is composed of dentin.



**Fig. 7.9:** External wall of tooth preparation

### Dentinoenamel Junction

Dentinoenamel junction is the line representing the junction of enamel and dentin.

### Cementoenamel Junction

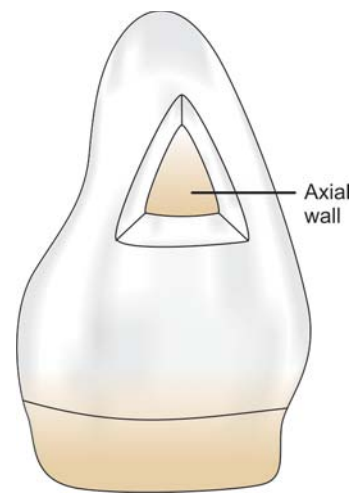
Cementoenamel junction is the line representing the junction of enamel and dentin.

### Pulpal Wall

A pulpal wall is an internal wall that is towards the pulp and covering the pulp (**Fig. 7.10**). It may be both vertical and perpendicular to the long axis of tooth.

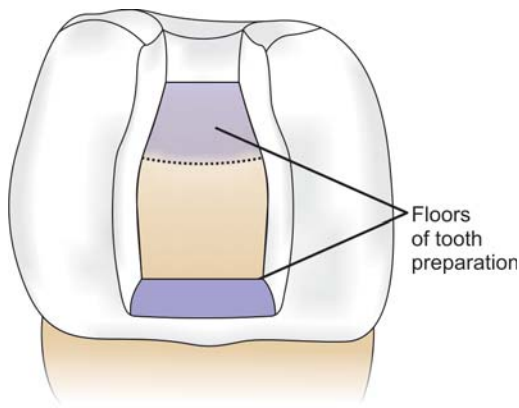
### Axial Wall

It is an internal wall which is parallel to the long axis of the tooth (**Fig. 7.11**).



**Fig. 7.11:** Axial wall





**Fig. 7.12:** Pulpal and gingival floors of a class V tooth preparation

### Step

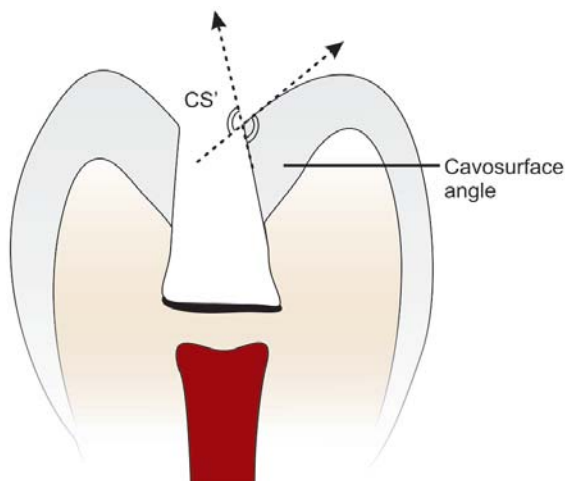
It is an auxiliary extension of the main tooth preparation on to an adjoining surface. For example in class III tooth preparation with lingual dovetail is called as lingual step.

### Floor

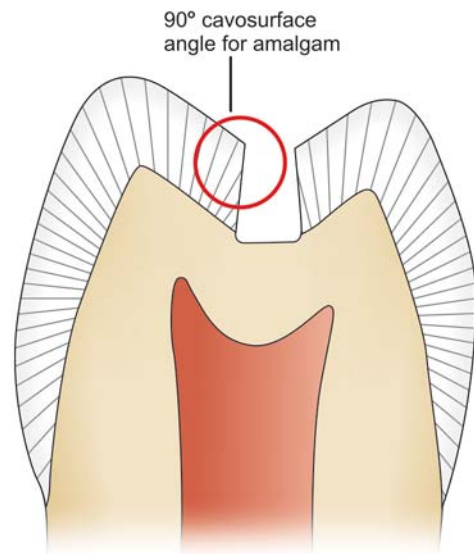
Floor is a prepared wall which is usually flat and perpendicular to the occlusal forces directed occlusogingivally, for example, pulpal and gingival walls (**Fig. 7.12**).

### Cavosurface Angle Margin/Tooth Preparation Margin

Cavosurface angle is formed by the junction of a prepared tooth surface wall and external surface of the tooth (**Fig. 7.13**). The acute junction is referred to as preparation margin or cavosurface margin. The cavosurface angle may differ with the location of tooth and enamel rod direction of the prepared walls and also differ according to the type of restorative material to be used (**Figs 7.14 and 7.15**).



**Fig. 7.13:** Cavosurface margin



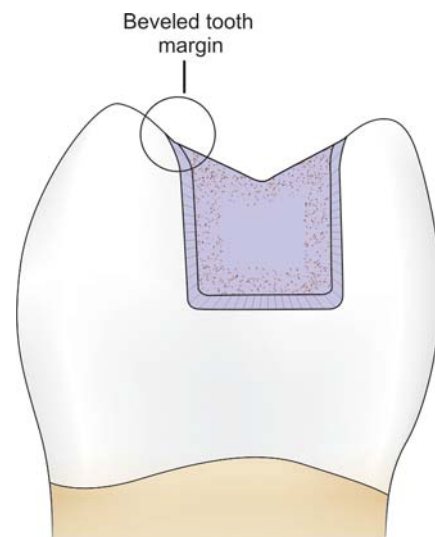
**Fig. 7.14:** Butt joint cavosurface margin for amalgam

### Angle

A junction of two or more surfaces of tooth preparation is termed as an angle.

### Line Angle

It is a junction of two surfaces of different orientations along the line and its name is derived from the involved surfaces.



**Fig. 7.15:** Beveled cavosurface margin for cast gold restoration

### Point Angle

It is a junction of three plane surfaces or three line angles of different orientation and its name is derived from its involved surfaces or line angles.

### Pulpal Line Angle

Any angle perpendicular to long axis of tooth is called pulpal line angle.

### Axial Line Angle

Any angle parallel to long axis of tooth is called axial line angle.

### How to Combine Different terms?

When one word is to be formed by combination of two or more walls or surfaces, the “al” word of prefix word is replaced with “O”. For example, if distal and occlusal words are to be combined, the combined term will be distocclusal. The combined word of mesial, distal and occlusal surface is mesio-occlusodistal.

## NUMBER OF LINE ANGLES AND POINT ANGLES IN DIFFERENT TOOTH PREPARATION DESIGNS

The line angles and point angles of different tooth preparation designs are as follows:

Number of line angles and point angles in different tooth preparation designs		
Type of tooth preparation	Line angles	Point angles
Class I	8	4
Class II	11	6
Class III	6	3
Class IV	11	6
Class V	8	4

### Class I Tooth Preparation

For simple class I tooth preparation involving only occlusal surface of molars eight line angles and four-point angles are named as follows (Fig. 7.16):

#### Line Angles

- Mesio Buccal line angle
- Mesiolingual line angle
- Distobuccal line angle
- Distolingual line angle
- Faciopulpal line angle

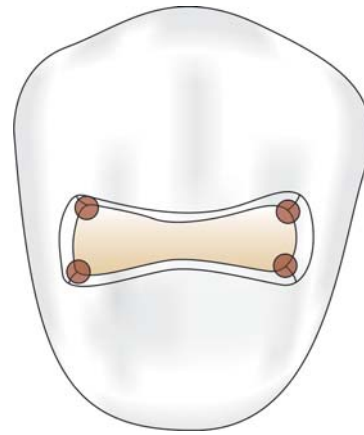


Fig. 7.16: Class I tooth preparation showing line angle and point angles

- Linguopulpal line angle
- Mesiopulpal line angle
- Distopulpal line angle.

#### Point Angles

- Mesio-buccopulpal point angle
- Mesio-linguopulpal point angle
- Disto-buccopulpal point angle
- Distolinguo-pulpal point angle.

### Class II Tooth Preparation

For class II preparation (mesio-occlusal or disto-occlusal) 11 line angles and 6-point angles are as follows (Fig. 7.17). The following is the nomenclature for mesio-occlusal tooth preparation.

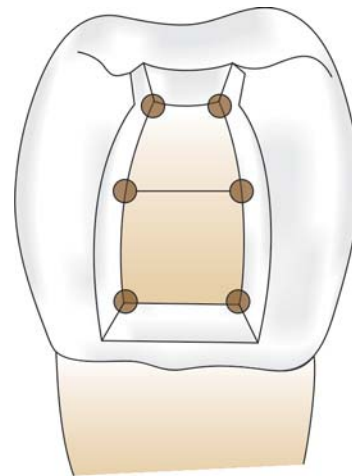


Fig. 7.17: Class II tooth preparation showing line and point angles

### Line Angles

- Distofacial
- Faciopulpal
- Axiofacial
- Faciogingival
- Axioingival
- Linguogingival
- Axio lingual
- Axio pulp al
- Distolingual
- Distopulpal
- Linguopulpal

### Point Angles

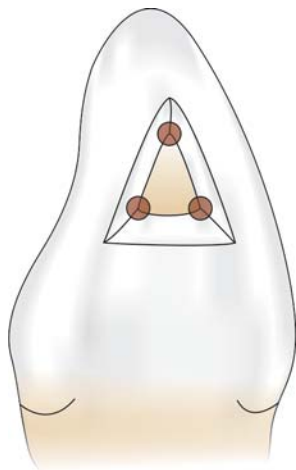
- Distofaciopulpal point angle
- Axiofaciopulpal point angle
- Axiofaciogingival point angle
- Axioinguogingival point angle
- Axioinguopulpal point angle
- Distinguopulpal point angle.

### Class III Tooth Preparation

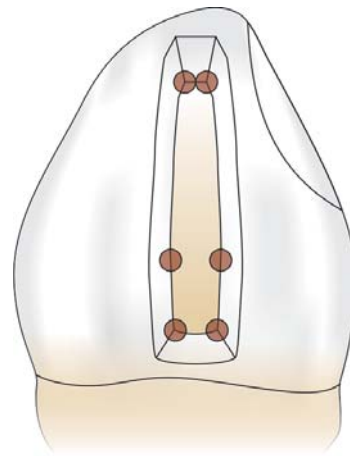
For class III preparation on anterior teeth 6 line angles and 3-point angles are as follows (**Fig. 7.18**).

#### Line Angles

- Faciogingival
- Linguogingival
- Axioingival
- Axio lingual
- Axio incisal
- Axio facial



**Fig. 7.18:** Class III preparation showing line and point angles



**Fig. 7.19:** Class IV preparation showing line and point angles

#### Point Angles

- Axiofaciogingival point angle
- Axioinguogingival point angle
- Axio incisal point angle.

### Class IV Tooth Preparation

For class IV tooth preparation on anterior teeth, 11 line angles and 6-point angles are as follows (**Fig. 7.19**).

#### Line Angles

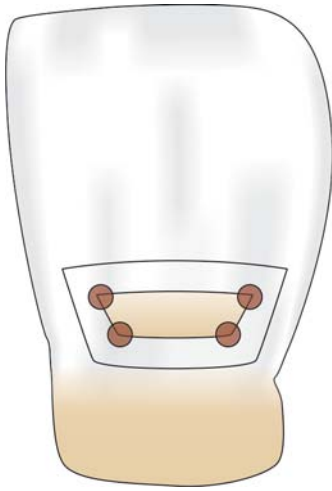
- Faciogingival
- Linguogingival
- Mesiofacial
- Mesiolingual
- Mesio pulp al
- Facio pulp al
- Linguo pulp al
- Axioingival
- Axio lingual
- Axio facial
- Axio pulp al.

#### Point Angles

- Axiofaciopulpal point angle
- Axioinguopulpal point angle
- Axiofaciogingival point angle
- Axioinguogingival point angle
- Distofaciopulpal point angle
- Distinguopulpal point angle.

### Class V Tooth Preparation

For class V preparation, 8 line angles and 4-point angles are as follows (**Fig. 7.20**).



**Fig. 7.20:** Class V preparation showing line and point angles

### Line Angles

- Axioingival
- Axioincisal
- Axio mesial
- Axiodistal
- Mesioincisal
- Mesioingival
- Distoincisal
- Distoringival.

### Point Angles

- Axiodistoringival point angle
- Axiodistoincisal point angle
- Axio mesioingival point angle
- Axio mesioincisal point angle.

## TOOTH PREPARATION

Black gave following guidelines for tooth preparation:

- Providing definite mechanical retention in the preparation.
- Extension of preparation in adjacent pits and fissures for prevention of recurrent caries.
- Removal of infected and affected dentin from all surfaces.
- Removal of even healthy tooth structure to gain access and good visibility.

When Black gave classification, following conditions and considerations were prevalent at that time:

- Poor oral hygiene habits.
- Poor properties of the existing restorative materials.
- The expected longer life of the restoration.
- Hard and fibrous food.

- Low consumption of refined carbohydrates.
- More liking towards gold and silver fillings in teeth.
- Prevailing common diagnostic aids such as PMT.

Nowadays because of change in following conditions, design of the tooth preparation has become most conservative:

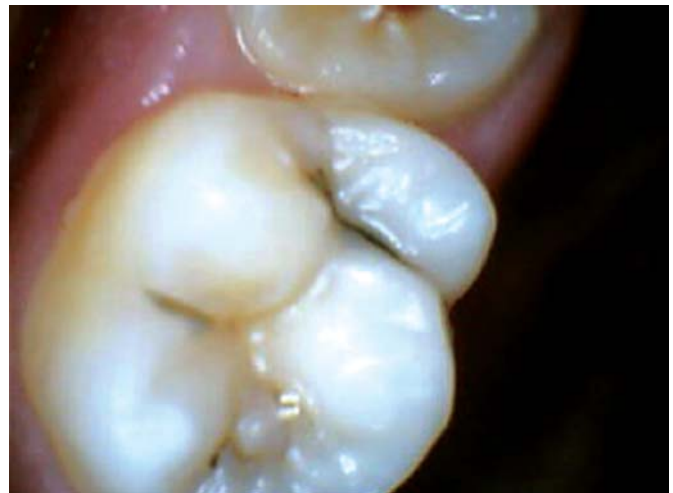- Use of preventive measures like fluoridation of water supply, fluoride toothpaste, topical fluoride applications, proper brushing and flossing, etc.
- Understanding of the fact that the remineralization of enamel and affected dentin can take place.
- Advances in tooth colored, adhesive, fluoride releasing restorative materials.
- Newer advancements in restorative materials.
- Improvements in diagnostic aids.
- Better oral hygiene maintenance.
- Mechanical retention forms further improve the retention.

## Classification of Tooth Preparations

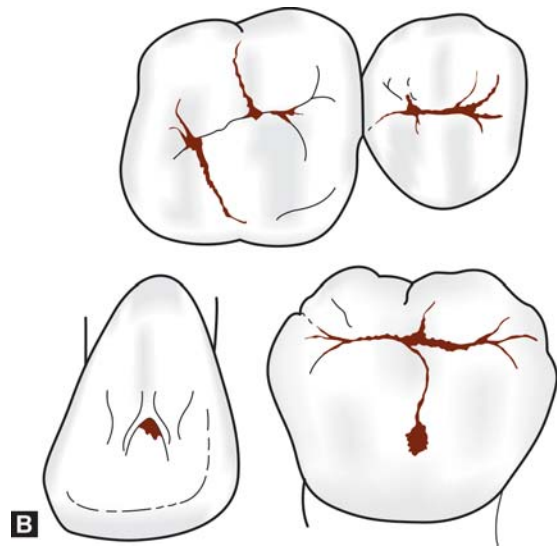
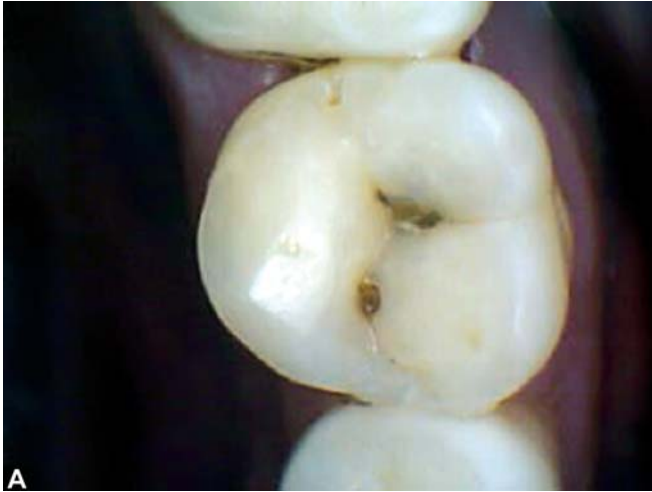Tooth preparations may be classified according to the location where the carious lesion initiates. Caries oftenly initiate in the developmental pits and fissures of the teeth. These areas are morphologically deeper than the surrounding tooth substance and are thus sites for food impaction and nearly impossible to clean thoroughly, forming ideal conditions for bacterial plaque formation (**Fig. 7.21**).

Commonly seen locations of pit and fissure in teeth are:

- Palatal pits of maxillary incisors.
- Palatal grooves and pits of maxillary molars.
- Occlusal surfaces of posterior teeth.
- Facial grooves and pits of mandibular molars.
- Pits occurring in teeth because of irregularities in the enamel formation.



**Fig. 7.21:** Deep pits and fissures are primary areas for food impaction and caries formation



**Figs 7.22A and B:** (A) Clinical presentation of class I lesion, (B) Diagrammatic presentation of class I lesion

Smooth surface lesions can be found in all teeth on the proximal surfaces, and gingival one-third of the facial and lingual surfaces. GV Black gave a simple classification based on clinical location of the defects, listed as class I, class II, class III, class IV and class V. An additional class VI was later on added by Simon as modification to Black's classification.

Class I is the only pit and fissure preparation whereas rest are smooth surface preparations.

*Class I:* Pit and fissure preparations occur on the occlusal surfaces of premolars and molars, the occlusal two-third of buccal and lingual surface of molars, lingual surface of

incisors and any other abnormal position (**Figs 7.22A and B**).

*Class II:* Preparations on the proximal surface of premolars and molars are class II (**Figs 7.23A and B**).

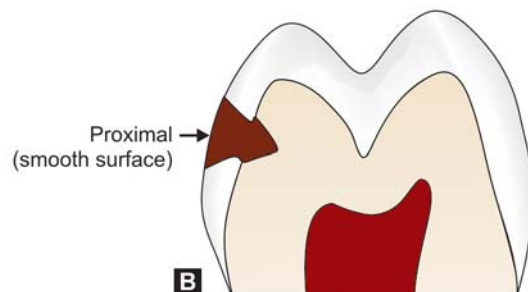
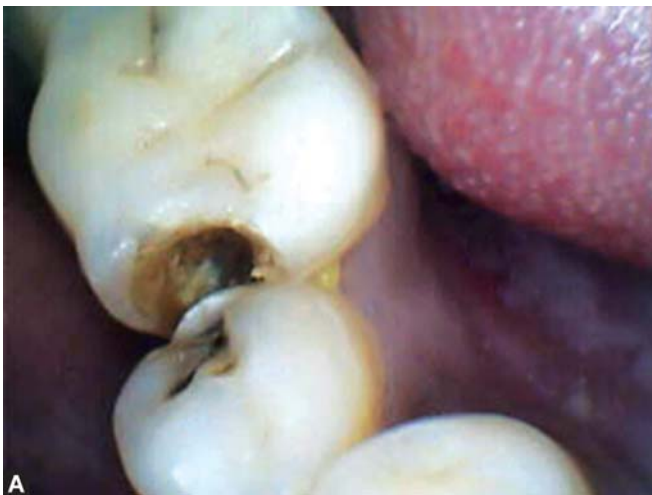*Class III:* Preparations on the proximal surface of anterior teeth and not involving the incisal angles are class III (**Figs 7.24A and B**).

*Class IV:* Preparations on the proximal surface of anterior teeth also involving the incisal angle come under class IV (**Figs 7.25A and B**).

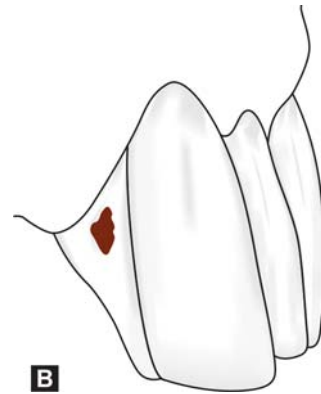
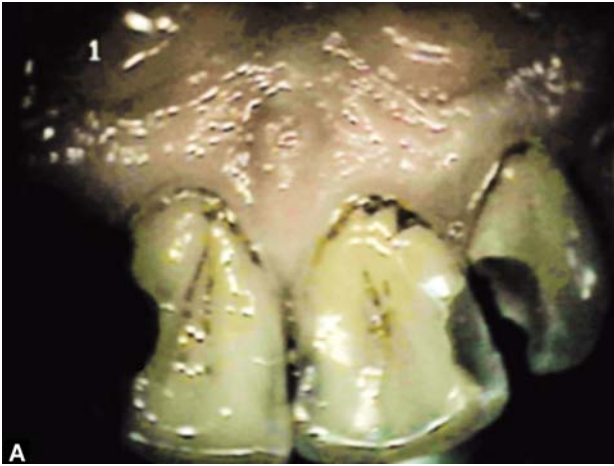
*Class V:* Preparations on gingival third of facial and lingual or palatal surfaces of all teeth came under class V (**Figs 7.26A and B**).

Modification of Black's classification was made to provide more specific localization of preparations.

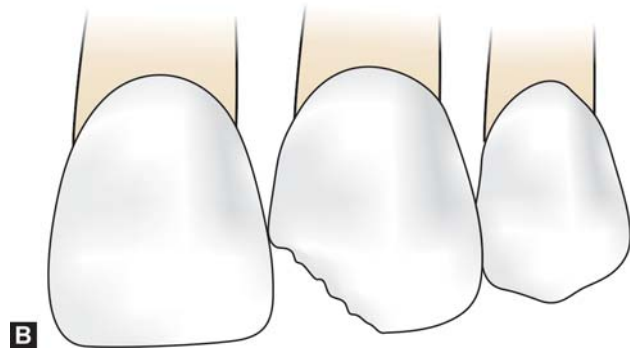
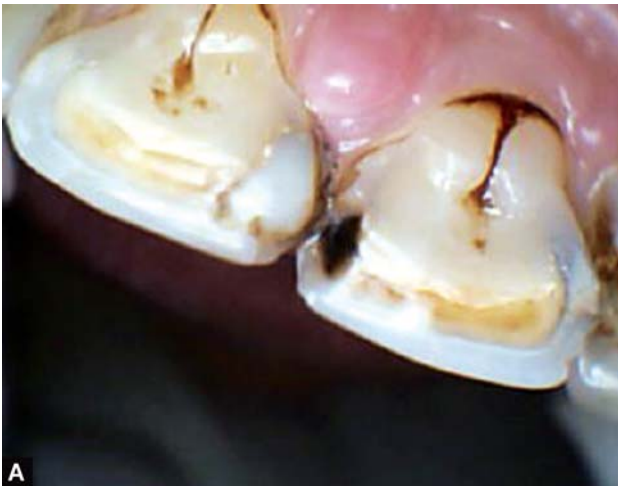*Class II:* Preparations on the single or both proximal surface of premolar and molar teeth. When there is involvement of



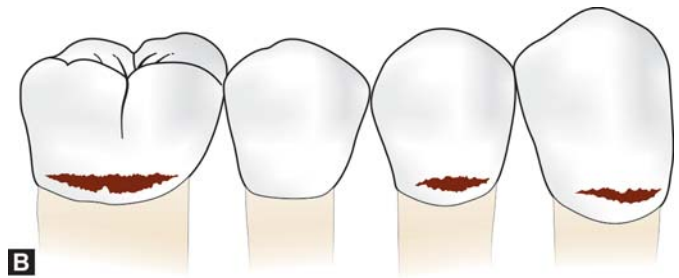
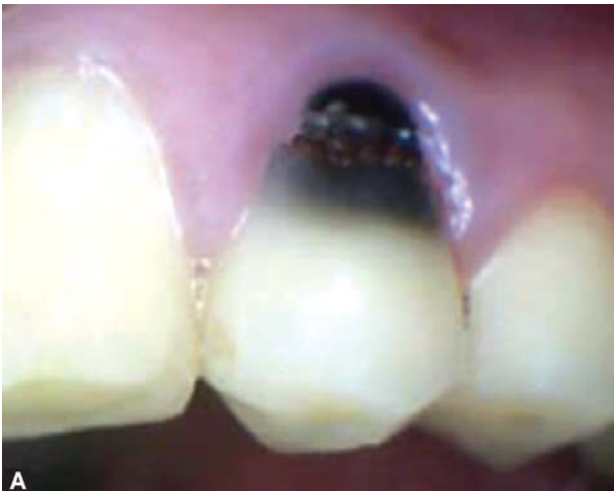**Figs 7.23A and B:** (A) Class II lesion, (B) Diagrammatic presentation of class II lesion



**Figs 7.24A and B:** (A) Class III lesion, (B) Diagrammatic representation of class III lesion



**Figs 7.25A and B:** (A) Class IV lesion, (B) Diagrammatic representation of class IV defect



**Figs 7.26A and B:** (A) Class V lesion, (B) Diagrammatic representation of class V lesion

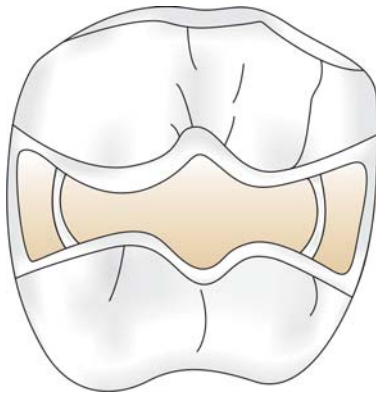


Fig. 7.27: MOD preparation

both proximal surfaces, it is called mesio-occlusodistal (MOD) preparation (Fig. 7.27).

*Class VI:* Preparations on incisal edges of anterior and cusp tips of posterior teeth without involving any other surface (Fig. 7.28) come under class VI.

### STEPS IN TOOTH PREPARATION

Before initiating tooth preparation one should identify presence of caries. There should be an opacity surrounding the pit and fissure indicating demineralization of the enamel. Softened enamel can be detected and removed away with the sharp tip of explorer.

After the clinician decides which tooth to restore, the anesthesia is given.

Tooth preparation involves a systemic approach based on the mechanical and physical principles which should be followed in an orderly sequence. The design of the tooth preparation for either a tooth with initial caries or replacement restoration depends upon location of the caries, the amount and extent of the caries, the amount of lost tooth structure, and the restorative material to be used. But there are some basic principles which should be followed while doing tooth preparation.

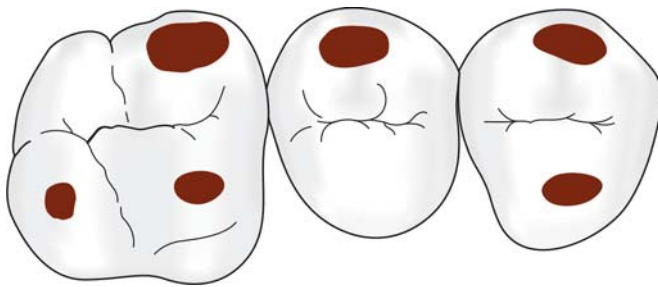


Fig. 7.28: Class VI lesion are present on cuspal tips

Earlier when the affected tooth was prepared because of caries, cutting of tooth was referred to as cavity preparation. But nowadays many indications other than caries lead to preparation of the tooth. Hence, the term cavity preparation has been replaced by tooth preparation.

Tooth preparation is divided into two stages, each consisting of many steps. Though each step should be done to perfection, but sometimes modifications can be made in steps.

#### A. Stage I

Initial tooth preparation steps:

1. Outline form and initial depth.
2. Primary resistance form.
3. Primary retention form.
4. Convenience form.

#### B. Stage II

Final tooth preparation steps:

5. Removal of any remaining enamel pit or fissure, infected dentin and/or old restorative material, if indicated.
6. Pulp protection, if indicated.
7. Secondary resistance and retention form.
8. Procedures for finishing the external walls of the tooth preparation.
9. *Final procedures:* Cleaning, inspecting and sealing. Under special conditions these sequences are changed.

### Initial Tooth Preparation

#### Outline Form and Initial Depth

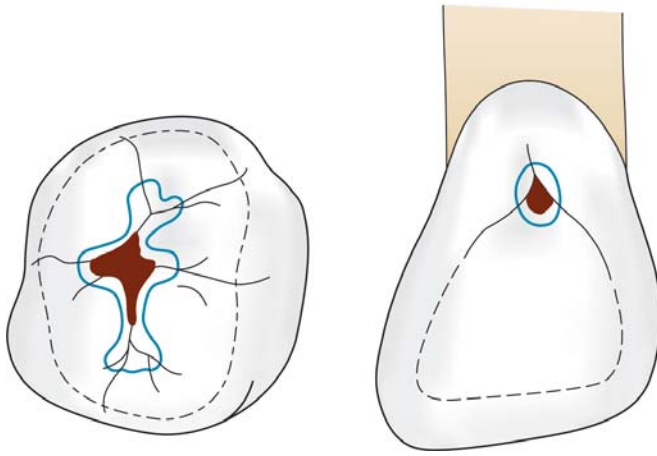
*The outline form means:*

- Placing the preparation margins to the place they will occupy in the final tooth preparation except for finishing enamel walls and margins.
- Maintaining the initial depth of 0.2 to 0.8 mm into the dentin.

Outline form defines the external boundaries of the preparations.

*The following factors affect the outline form and initial depth form of tooth preparation:*

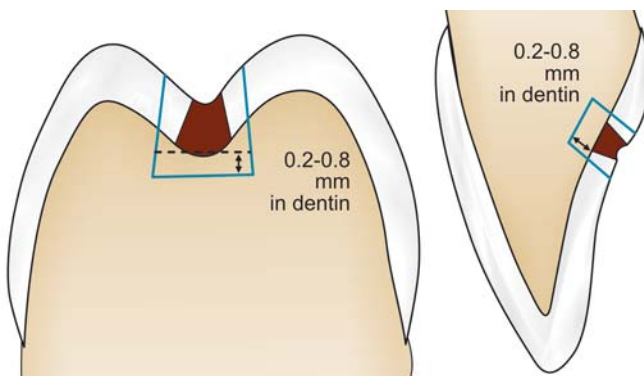
- Extension of carious lesion.
- Proximity of the lesion to other deep structural surface defects.
- Relationship with adjacent and opposing teeth.
- Caries index of the patient.
- Need for esthetics.
- Restorative material to be used.



**Fig. 7.29:** Outline form should include all defective pits and fissures

Before initiating the tooth preparation, outline must be visualized to access the proposed shape of the preparation (**Fig. 7.29**). The outline form includes the external outline form and internal outline form.

The external outline form is established first to extend all margins into sound tooth tissue while maintaining the initial depth of 0.2 to 0.8 mm into the dentin towards the pulp (**Fig. 7.30**). In small or localized carious lesion, preparation design should be conservative in dimensions whereas in moderate to large lesion, the outline form may be more extensive. During tooth preparation, the margins of preparation not only extend into sound tooth tissue but also involve adjacent deep pits and fissures in preparation. This was referred to it as “extension for prevention” by GV Black.



**Fig. 7.30:** Initial depth of preparation should be 0.2 to 0.8 mm into dentin

“Extension for prevention means the placing the margins of preparations at areas that would be cleaned by the excursions of food during chewing. It is done with the objective of preventing the recurrence of caries at the margins of fillings where the recurrence of decay is most commonly seen. His concept also included extending preparations through enamel fissures to allow cavosurface margins to be placed on nonfissured enamel”.

#### For This

- Margins of the restoration are placed on line angles of the tooth.
- Occlusal surface is extended through pits and fissures.
- Proximal line angles extended buccally and lingually through embrasures and cervically below the gingival margin.

#### Advantages

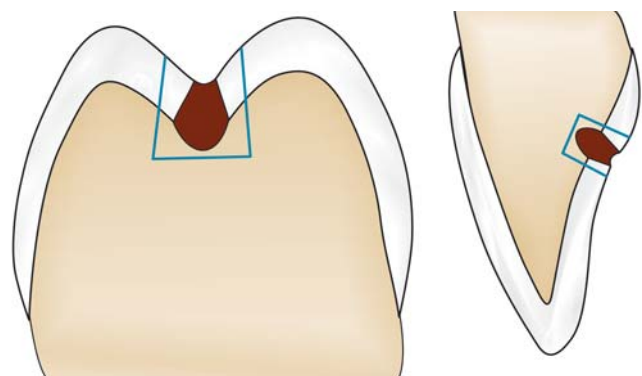
- Prevents recurrence of decay in the tooth surface adjoining restoration.
- Results in self-cleaning embrasure areas.

#### Contraindications

- Natural remineralization (via calcium and phosphate from saliva).
- Fluoride-induced remineralization (through water, dentifrices, restorative materials).
- Advancements in instrumentation.
- Advancements in restorative materials.
- Modifications in tooth preparation designs.

#### Following principles are kept in mind while preparing an outline form:

- Removal of all weakened and friable tooth structure.
- Removal of all undermined enamel (**Fig. 7.31**).
- Incorporate all faults in preparation.
- Place all margins of preparation in a position to afford good finishing of the restoration.



**Fig. 7.31:** Removal of all undermined enamel



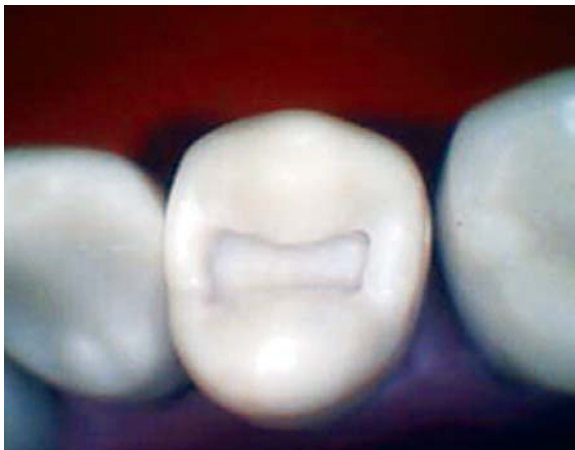**Features for establishing a proper outline form are:**

- Preserving cuspal strength.
- Preserving strength of marginal ridge.
- Minimizing the buccolingual extensions.
- If distance between two faults is less than 0.5 mm, connect them.
- Limiting the depth of preparation 0.2-0.8 mm into dentin.
- Using enameloplasty wherever indicated.

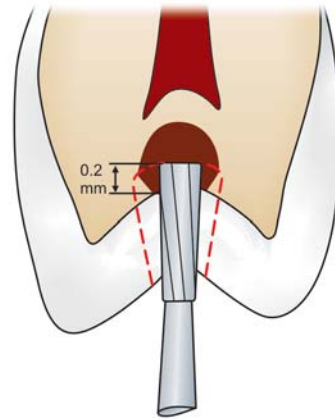
**Outline form for pit and fissure lesions:**

- Remove all defective portion and extend the preparation margins to healthy tooth structure.
- Remove all unsupported enamel rods or weakened enamel margins.
- If the thickness of enamel between two preparation sites is less than 0.5 mm, connect them to make one preparation, otherwise prepared as separate tooth preparations.
- Avoid ending the preparation margins in high stress areas like cusp eminences.
- Extend the preparation margins to include all pits and fissures which cannot be managed by enameloplasty.
- Limit the depth of preparation to 0.2 mm into the dentin, though the actual depth of preparation may vary from 1.5 mm depending on steepness of cuspal slopes and thickness of the enamel.
- Extend the outline form to facilitate the convenience for preparation and restoration.
- If indicated because of esthetic reasons, make the preparation as conservative as possible.

**External outline form:** It should consist of smooth curves, straight lines and rounded line and point angles (Fig. 7.32). Sharp and irregular projection of tooth tissue should be removed because they are not only fragile but also make



**Fig. 7.32:** Outline form should consist of smooth curves, straight lines and rounded line and pointed angles



**Fig. 7.33:** Preparation depth should be at least 1.5-2 mm from the cavosurface margin and atleast 0.2-0.5 mm into dentin

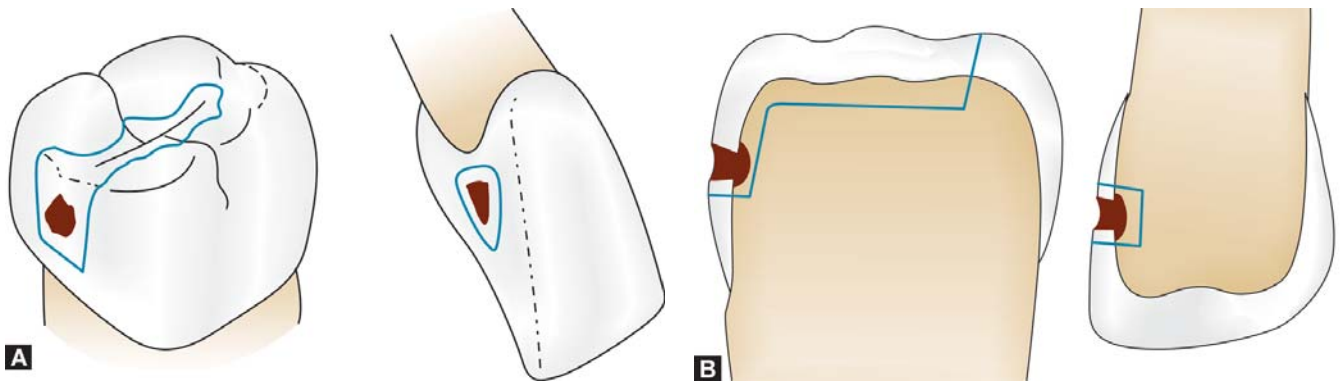
good adaptation of restorative material to tooth preparation walls and margins difficult. The enamel which is unsupported by dentin as well as the demineralized enamel should be removed, since it is liable to fracture.

**Internal outline form:** It includes the relationship of occlusal walls from cavosurface angle to the pulpal floor. Unnecessary loss of tooth structure should be avoided from the inner dimensions of the preparation. Since, enamel is brittle and dentin is elastic, one should avoid placing pulpal floor in enamel. The preparation depth should be at least 1.5 to 2.0 mm vertical from the cavosurface margin to the pulpal floor and at least 0.2 to 0.5 mm in dentin so as to provide adequate strength to resist fracture due to masticatory forces (Fig. 7.33).

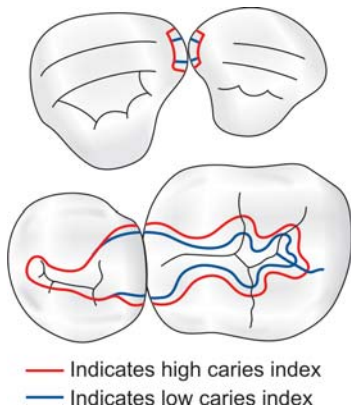
**Outline form for smooth surface lesions: Outline form of proximal caries (Class II, III and IV lesions):** Class II are generally diagnosed using bitewing radiographs. It should be noted that a proximal lesion which appears to be 2/3 or more toward the dentin has actually penetrated the dentinoenamel junction.

**Following factors affect the outline form of proximal preparations:**

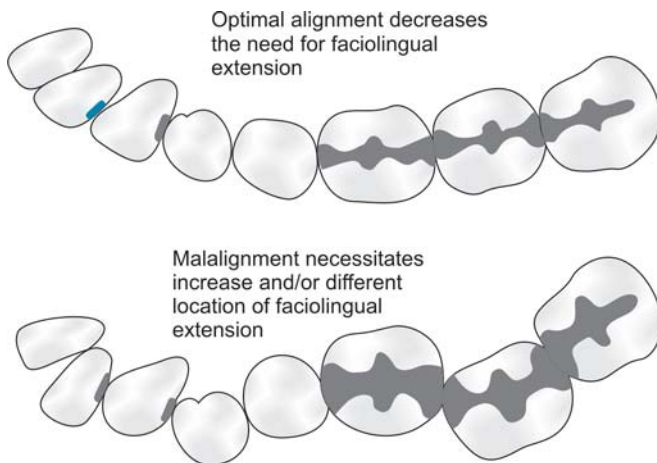
- Extent of the caries on the proximal side (Figs 7.34A and B).
- Dimensions of the contact area in the affected tooth.
- Contact relationship with adjacent tooth.
- Caries index of the patient (Fig. 7.35).
- Age of the patient.
- Position of gingiva.
- Alignment of teeth and masticatory forces likely to fall on restorative material (Fig. 7.36).
- Esthetic requirement of the patient.



**Figs 7.34A and B:** Outline form should include all the carious lesion and undermined enamel



**Fig. 7.35:** In a patient with high caries risk it is always preferred to place gingival margin further into the embrasure



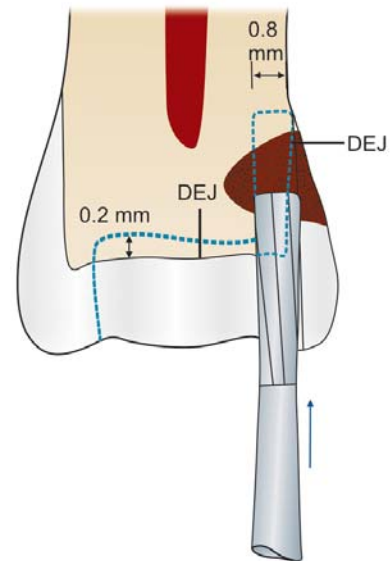
**Fig. 7.36:** Proper alignment of teeth requires less faciolingual extensions as compared to malaligned teeth. It also offer better cleanliness of embrasure area

As we saw that class II tooth preparations varies according to the morphology, anatomy and extent of carious involvement of the individual tooth being restored. However, some features are common to all class II tooth preparations. A class II tooth preparation consists of:

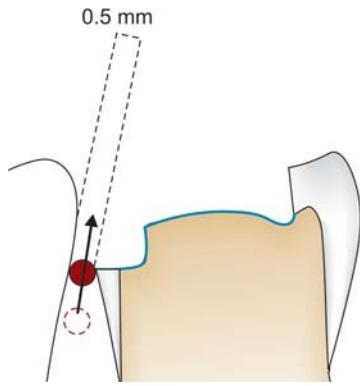
- Occlusal segment
- Proximal segment.

**Rules for making outline form for proximal preparation:**

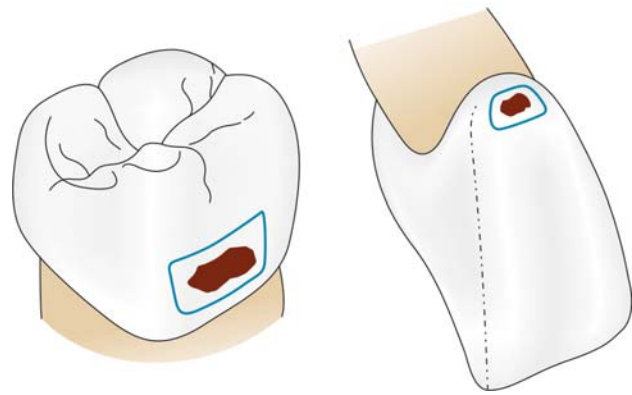
- Extend the preparation until sound tooth structure is reached (**Figs 7.34A and B**).
- Remove all unsupported enamel rods, extending the margins to allow sufficient access for restoration.
- Restrict the depth of axial wall 0.2 to 0.8 mm into dentin (**Fig. 7.37**).



**Fig. 7.37:** Restrict the depth of axial wall 0.2-0.8 mm into dentin



**Fig. 7.38:** In proximal tooth preparation, gingival margin should clear adjacent tooth by 0.5 mm



**Fig. 7.39:** Outline form of class V cavity depends upon extent of caries

- In class II tooth preparation, place gingival seat apical to the contact but occlusal to gingival margin and have the clearance of 0.5 mm from the adjacent tooth (**Fig. 7.38**).
- In class III preparation, position of incisal margins is in the area of contact, especially if esthetic restorative material is used or when incisal embrasure is not large to allow incisal extension out of contact area.

**Axial wall should**

- Be placed into dentin 0.5-0.8 mm from DEJ.
- Follow curvature of dentinoenamel junction buccolingually.
- Follow curvature of dentinoenamel junction occluso-lingually.

**Outline form for class V lesions:** Outline form for cervical/ root/gingival lesions for buccal and lingual surfaces of class V preparations, is as follows:

- In class V lesions the outline form is governed by the extent of caries. Therefore, extend the cavity mesially, gingivally, distally and occlusally till when sound tooth structure may be reached (**Fig. 7.39**).
- The minimum axial wall depth is 0.2 to 0.5 mm extension into dentin.

**Enameloplasty**

Enameloplasty is the careful removal of sharp and irregular enamel margins of the enamel surface by “rounding” or “saucering” it and converting it into a smooth groove making it self-cleansable, finishable and allowing conservative placement of margins (**Figs 7.40A and B**). Enameloplasty is done when caries are present only in the superficial part of the enamel or a fissure is present in less than one-third

thickness of the enamel. The enameloplasty does not extend the outline form, also the use of enameloplasty often confines the preparation to one surface and restoration is not done in the recontoured area.

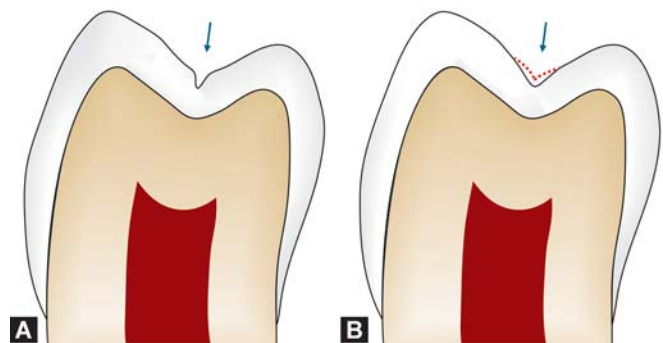
**Primary Resistance Form**

**Definition:** Primary resistance form is that shape and placement of preparation walls to best enables both the tooth and restoration to withstand, without fracture the stresses of masticatory forces delivered principally along long axis of the tooth (**Figs 7.41A and B**).

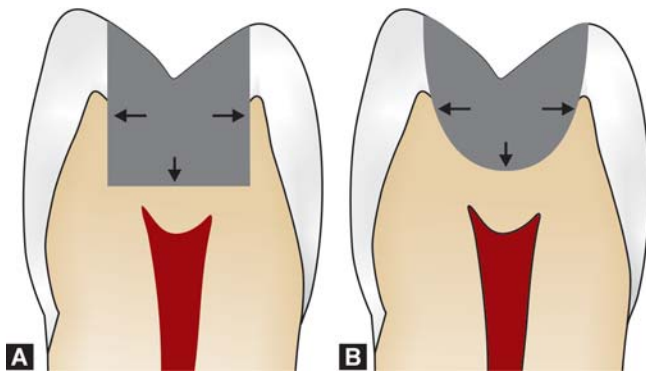
As we know that masticatory stress pattern is different for each tooth. Accordingly, for success of the tooth preparation and restoration, this stress pattern must be recognized.

**Factors affecting resistance form:**

- Amount of occlusal stresses.
- Type of restoration used.
- Amount of remaining tooth structure.



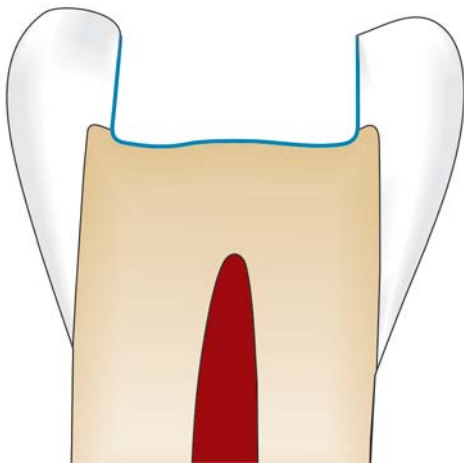
**Figs 7.40A and B:** Enameloplasty; (A) Tooth with deep pit and fissure, (B) Removal of superficial enamel resulting in rounding of deep pit and fissure caries making it self-cleansable



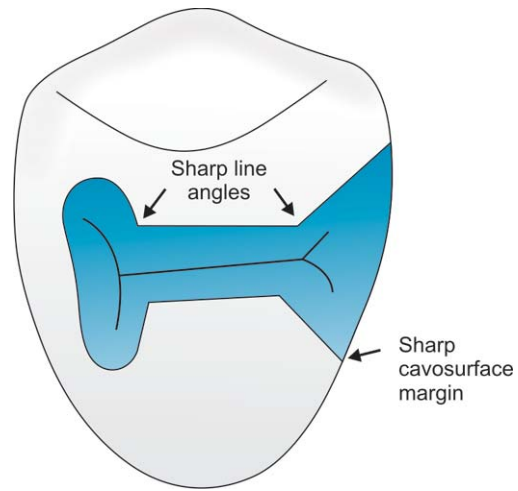
**Figs 7.41A and B:** (A) Resistance form of tooth provided by flat pulpal and gingival floor, (B) In case of rounded pulpal floor, the rocking motion of restoration results in wedging force which may result in failure of restoration

#### Features of resistance form:

- A box-shaped preparation.
- A flat pulpal and gingival floor, which helps the tooth to resist occlusal masticatory forces without any displacement (**Fig. 7.41A**).
- Adequate thickness of restorative material depending on its respective compressive and tensile strengths to prevent the fracture of both the remaining tooth structure and restoration. In case of class IV preparations, we check the width of faciolingual narrowness of anterior teeth, to establish the resistance form.
- Restrict the extension of external walls to allow strong marginal ridge areas with sufficient dentin support (**Fig. 7.42**).
- Inclusion of weakened tooth structure to avoid fracture under masticatory forces.



**Fig. 7.42:** Restrict the extensions of external wall so as to have strong marginal ridge area



**Fig. 7.43:** Sharp line angle and cavosurface margins can lead to poor resistance form because of concentration of stresses at that point

- Rounding of internal line angle to reduce the stress concentration points in tooth preparation (**Fig. 7.43**).
- Consideration to cusp capping depending upon the amount of remaining tooth structure.

Resistance form also depends upon type of restorative material being used. For example, high copper amalgam requires minimal thickness of 1.5 mm, cast metal requires thickness of 1.0 mm and the porcelain requires a minimum thickness of 2.0 mm to resist fracture. The composite restorations and glass ionomer restorations are more dependent on occlusal wear potential of restorative area and usually require thickness of more than 2.5 mm.

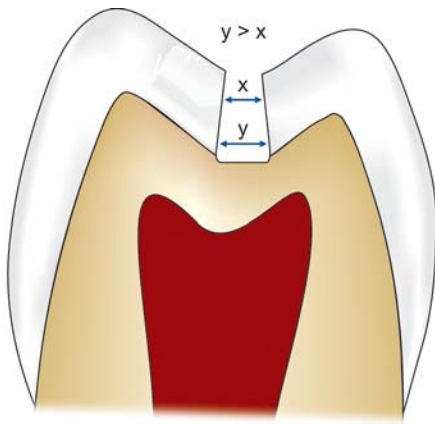
#### Primary Retention Form

**Definition:** Primary retention form is that form, shape and configuration of the tooth preparation that resists the displacement or removal of restoration from the preparation under lifting and tipping masticatory forces.

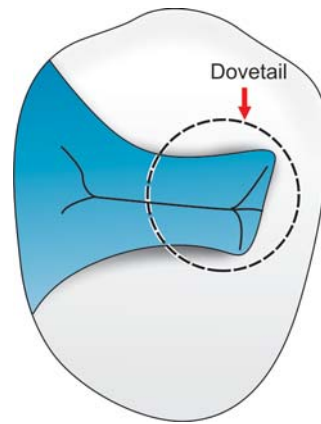
Usually, resistance and retention forms are obtained by providing same features, hence they are sometimes described together.

The retention form is affected by the type of the restorative material used. The common factors affecting retention form are as follows:

- Amount of the masticatory stresses falling on the restoration.
- Thickness of the restoration.
- Total surface area of the restoration exposed to the masticatory forces.
- The amount of remaining tooth structure.



**Fig. 7.44:** Preparation walls should have 2°-5° occlusal convergence for amalgam retention

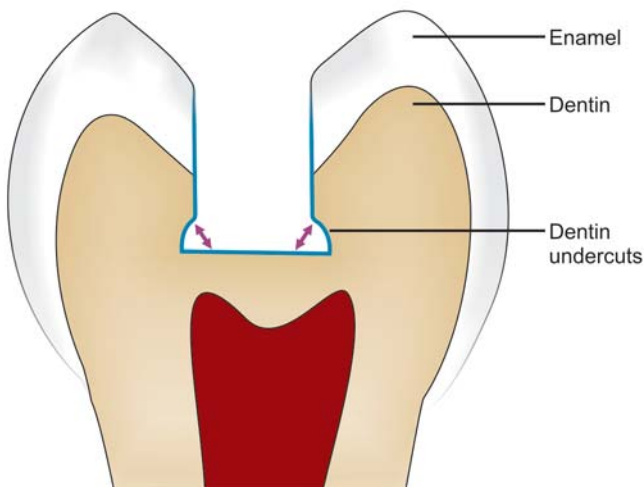


**Fig. 7.46:** Dovetail helps in providing retention

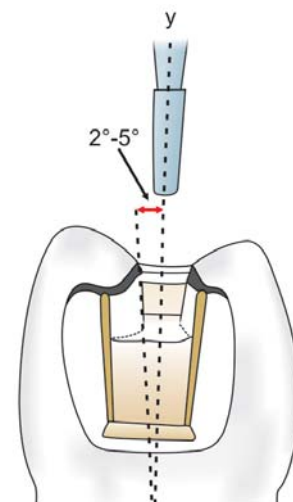
1. **Amalgam:** Retention is increased in amalgam restoration by the following:
  - Providing occlusal convergence (about 2 to 5%) the dentinal walls towards the tooth surface (**Fig. 7.44**).
  - Giving slight undercut in dentin near the pulpal wall (**Fig. 7.45**).
  - Conserving the marginal ridges.
  - Providing occlusal dovetail (**Fig. 7.46**).
2. **Cast metals:** Retention is increased in cast restorations by the following:
  - a. Close parallelism of the opposing walls with slight occlusal divergence of two to five degrees (**Fig. 7.47**).
  - b. Making occlusal dovetail to prevent tilting of restoration in class II preparations.
  - c. Use of secondary retention in the form of coves, skirts and dentin slot.
- d. Give reverse bevel in class I compound, class II, and MOD preparations to prevent tipping movements.
3. **Composites:** In composites, retention is increased by:
  - Micromechanical bonding between the etched and primed prepared tooth structure and the composite resin.
  - Providing enamel bevels.
4. **Direct filling gold:** Elastic compression of dentin and starting point in dentin provide retention in direct gold fillings by proper condensation.

#### Convenience Form

**Definition:** The convenience form is that form which facilitates and provides adequate visibility, accessibility and ease of operation during preparation and restoration of the tooth.



**Fig. 7.45:** Undercut in dentin near the pulpal wall helps in retention of amalgam



**Fig. 7.47:** Parallelism of opposing walls and slight occlusal divergence provides retention of inlay

**Features of convenience form:**

- Sufficient extension of distal, mesial, facial or lingual walls should be given to gain adequate access to the deeper portion of the preparation.
- The cavosurface margin of the preparation should be related to the selected restorative material for the purpose of convenience to marginal adaptation.
- In class II preparations access is made through occlusal surface for convenience form.
- Provide proximal clearance from the adjoining tooth during class II tooth preparation.
- For class II tunnel preparation, for convenience, the proximal caries in posterior teeth is approached through a tunnel initiating from the occlusal surface and ending on caries lesion on the proximal surface without cutting the marginal ridge.
- In tooth preparation for cast gold restorations occlusal divergence is one of the feature of convenience form.

**Final Stages of Tooth Preparation**

After initial stages of the preparation, the prepared tooth should be carefully examined. For most of the conservative restorations, after initial stages of tooth preparation the tooth is ready for restoration except for some final procedures like varnishing, etching and bonding, etc. For extensive restorations, some of additional steps may be required.

The remaining carious portion should be removed only after the initial tooth preparation has been completed. It provides two advantages:

- It allows optimal visibility and convenience form for removal of remaining carious lesion.
- Completion of the initial preparation permits immediate placement of a base and the restoration.

**Removal of any Remaining Enamel Pit or Fissure, Infected Dentin and/or Old Restorative Material, if Indicated**

After the establishment of external and internal outline form, if any of the remaining carious tooth structure or defective restorative material is left in tooth, it is to be removed in this stage.

Infected dentin must be removed even, if it leads to exposure of pulp which is treated accordingly.

A small isolated carious lesion should be eliminated by a conservative preparation. After the establishment of pulpal and axial wall, if a small amount of carious lesion remains, only this lesion should be removed, leaving concave, rounded area in the wall.

**Difference between infected and affected dentin****Infected dentin:**

- It is a superficial layer of demineralized dentin.
- Cannot be remineralized.
- Lacks sensation.
- In this intertubular layer is demineralized with irregularly scattered crystals.
- Collagen fibers are broken down, appear as only indistinct cross bands.
- It can be stained with:
  - 0.2% Propylene glycol
  - 10% Acid red solution
  - 0.5% basic fuschin

**Affected dentin:**

- It is a deeper layer.
- Intermediate demineralized dentin.
- Can be remineralized.
- It is sensitive.
- In this, intertubular layer is only partly demineralized.
- Distinct cross bands are present.
- It cannot be stained with any solution.

In the extensive preparations with soft caries, the removal of carious dentin is done early in initial tooth preparation. It is better to remove the extensive caries early in tooth preparation to provide better opportunity to specific needs of retention and resistance form.

Removal of old restorative material is indicated if:

- It affects esthetics of new restoration
- Has secondary caries beneath (seen on radiograph)
- Tooth is symptomatic
- It compromises new restoration
- Marginal deterioration of old restoration.

**Points to remember while removing the remaining carious lesion**

1. Isolate the remaining carious lesion and remove, it using the following instruments:
  - Low speed handpiece with the round bur that will fit in the carious lesion used with light force and a wiping motion.
  - Spoon excavator that will fit in the carious lesion. Use of a large spoon excavator decreases the chance of a pulpal exposure.
2. Forces for removal of infective dentin should be directed laterally and not towards the center of the carious lesion.
3. Start removal of caries from the lateral borders of the lesion.
4. After removal, confirm it with the explorer applying it laterally. Avoid using excessive force with the explorer it may cause a pulpal exposure.

### Pulp Protection

Pulp protection is a very important step in adapting the preparation for final restoration although actually it is not a step of tooth preparation. When remaining dentin thickness is less, pulpal injury can occur because of heat production, high speed burs with less effective coolants, irritating restorative materials, galvanic currents due to fillings of dissimilar metals, excessive masticatory forces transmitted through restorative materials to the dentin and ingress of microorganisms and their noxious products through microleakage.

Pulp protection is achieved using liners, varnishes and bases depending upon:

- The amount of remaining dentin thickness
- Type of the restorative material used.

Liners and varnishes are used where preparation depth is shallow and remaining dentin thickness is more than 2 mm. They provide:

- Barrier to protect remaining dentin and pulp
- Galvanic and thermal insulation.

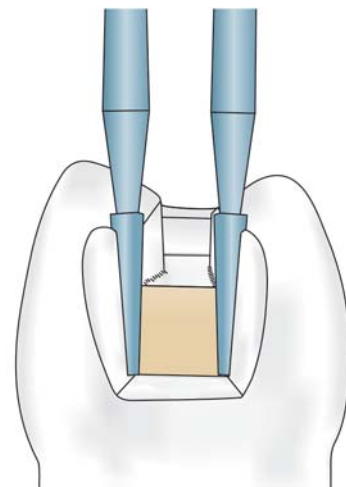
Bases are the cements used on pulpal and axial walls in thickness of about 0.5 to 2 mm beneath the permanent restorations. They provide thermal, galvanic, chemical and mechanical protection to the pulp. Commonly used restorative materials as base are zinc phosphate cements, glass ionomers, polycarboxylate cements, zinc oxide eugenol, and calcium hydroxide cement.

### Secondary Resistance and Retention Forms

This step is needed in complex and compound tooth preparations where added preparation features are used to improve the resistance and retention form of the prepared tooth. These are as following:

**Grooves and coves:** Wherever bulk of dentin is present, grooves are prepared without undermining the adjacent enamel (**Fig. 7.48**). Coves are small conical depressions prepared in healthy dentin to provide additional retention. These are normally prepared in the proximal walls of class II preparations at the axiofacial and axiolingual line angles, thus reducing proximal displacement of the restoration. More than one groove per wall should be avoided as they may weaken the wall. Grooves are especially useful for cast restorations. They are kept parallel to the line of withdrawal of the wax pattern.

**Slots or internal boxes:** These are mainly used in amalgam restorations. They are 1.0 to 1.5 mm deep box like grooves prepared in dentin to increase the surface area. These are prepared in occlusal box, buccoaxial, linguoaxial and gingival



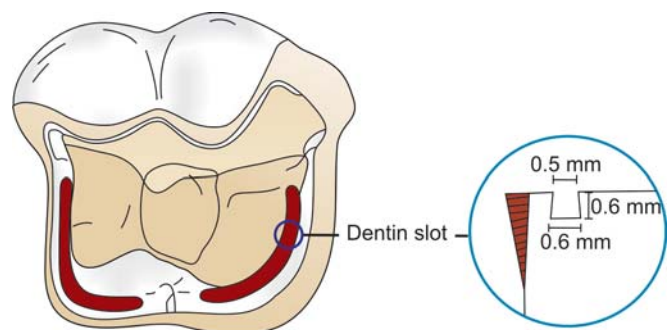
**Fig. 7.48:** Grooves are placed in axiofacial and axiolingual line angles so as to increase retention of the restoration

walls (**Fig. 7.49**). For cast restorations these are prepared by tapered fissure bur to avoid undercuts and for plastic restorative materials like amalgam, these are prepared by inverted cone bur to create slight undercuts in dentin.

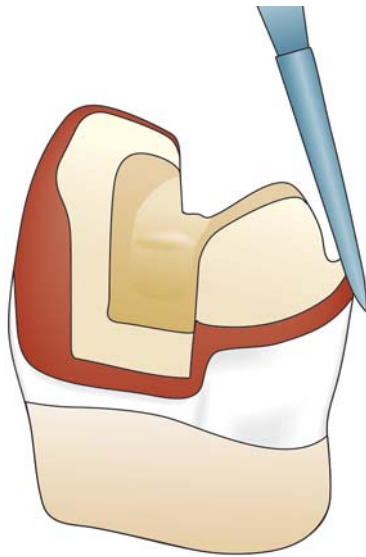
**Locks:** Locks are usually prepared for amalgam class II restoration in the proximal or occlusal box of class II prepared. These are made smaller in size measuring 0.25 to 0.5 mm wide and 0.5 to 1.0 mm deep in dentin.

**Pins:** Different types of pins of various shapes and sizes are used to provide additional retention. They can be used in all types of restorations like amalgam, composite and cast restorations.

**Skirts:** Skirts are prepared for providing additional retention in cast restorations. They increase the total surface area of the preparation. Skirts can be prepared on one to all four sides of the preparation depending upon the required retention (**Fig. 7.50**). Skirts have shown to improve both resistance and retention form.



**Fig. 7.49:** Slot

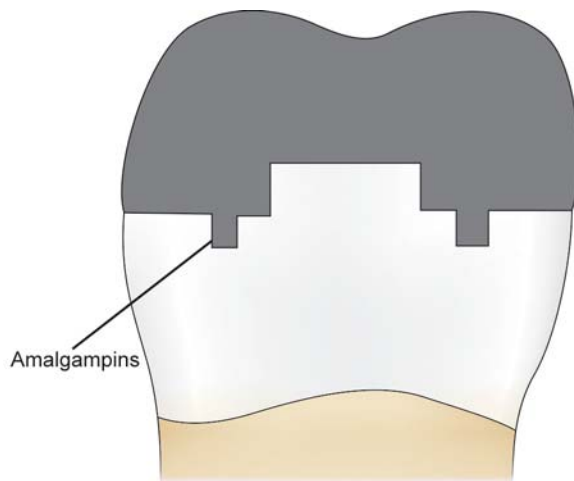


**Fig. 7.50:** Skirt in cast restoration helps in increasing retention

**Amalgampins:** Amalgampins are vertical posts of amalgam anchored in dentin. Dentin chamber is prepared by using inverted cone bur on gingival floor 0.5 mm in dentin with 1 to 2 mm depth and 0.5 to 1 mm width (**Fig. 7.51**). Amalgampins increase the retention and resistance of complete restoration.

**Beveled enamel margins:** Beveling of the preparation margins increases the surface area and thus, the retention in composite restorations.

**Enamel wall etching:** Etching results in microscopic roughness, which increases the surface area and thus helps in enhancing the micromechanical retention.



**Fig. 7.51:** Amalgampins increase retention of the restoration

**Dentin conditioning (etching and priming):** Etching and priming of the dentin surface done in some restorative materials increases the retention.

**Adhesive luting cements:** Adhesive luting cements increase the retention of indirect restorations.

#### *Procedures for Finishing the External Walls of the Tooth Preparation*

Finishing of the enamel margins should be done irrespective of restorative material used. During finishing there occurs the further enhancement of the cavosurface design and smoothness that produces the maximum adaptation of restoration to the walls and the margins and maximum effectiveness of restoration.

The finishing of the preparation walls results in:

- Better marginal seal between restoration and tooth structure.
- Increased strength of both tooth structure and restoration at and near the margins.
- Strong location of the margins.
- Increase in degree of smoothness of the margins.

**Degree of smoothness of walls:** It depends upon type of restoration used. For example, for cast metal restorations, a very smooth surface is required whereas for direct gold, amalgam and composite restorations, slight roughness is needed in the preparation walls.

**Location of the margins:** During finishing of the preparation walls and margins, one should follow the principles of paralleling the direction of enamel wall. The knowledge of enamel rods is necessary for proper finishing of the preparation margins. At the margins, all the enamel walls should have full length rods supported by dentin. To remove unsupported enamel rods near gingival margins it should be slightly beveled. In case of cast gold restorations a short bevel is given and an ultrashort bevel is given in case of gold foil.

**Features of finished preparation:** The design of cavosurface angle depends on type of restorative material being used. For example, for amalgam restoration, cavo-surface angle of 90 degrees affords maximum strength to tooth restoration.

In case of cast metal restoration beveling of external wall is done to produce stronger enamel margin, as the marginal metal is more easily burnished and adapted.

#### *Final Procedures; Cleaning, Inspecting and Sealing*

The final step in tooth preparation is cleansing of the preparation. This includes the removal of debris, drying of the preparation, and final inspection before placing restorative materials.



The debridement of the preparation serves the following objectives:

- **Cleaning of preparation walls, floors and margins from enamel and dentin chips resulting during tooth preparation:** Remove all the debris from the preparation, especially on the margins, otherwise deposits left on them consequently dissolve, resulting in a microleakage which further can result in secondary caries. Cleaning of preparation can be done by using warm water. Immovable particles of debris can be removed with the help of a small cotton pellet dampened with water or hydrogen peroxide.
- **Drying the tooth preparation before insertion of the restorative materials:** It can be done using air, dry cotton pellets and commercial cleaners. It is important that teeth are not dehydrated by overuse of air or hot air.
- **Sterilization of preparation walls using very mild alcohol free disinfectant:** Use of mild disinfectant in tooth preparation serves the purpose of disinfection.

### Air Abrasion/Kinetic Tooth Preparation

Air abrasion technique involves high energy sandblasting of tooth surface.

It is also called as advanced particle beam technology or microabrasion. This technique was given by Dr Robert Black in 1943. This system is used as an adjunct not as replacement for handpiece. The first air abrasion system was Airdent abrasion unit (SS white company).

It was heavy weight (more than 100 pounds) but had small tip to deliver a beam of aluminium oxide particles.

Later on many improvements occurred in air abrasion devices like the never air abrasion devices come in precised designed and have control on flow of abrasion particles with narrow beam.

### Technique

Basically in an air abrasion technique, the abrasion particles are emitted in a well defined sharply focused beam to the target.

There are many factors which come into play while evaluating efficiency of air abrasive technology.

- Distance between tip and the tooth.
- Particle energy this is guarded by air pressure.
- **Intensity of beam:** This depends on multiple factors like type of particles, size of nozzle size of particles, design of nozzle.
- Angle of beam.
- Commonly used particle size is 25-30  $\mu$  with 60-120 pounds per square inch pressure.

### Advantages of Air Abrasion

1. Precise and rapid enamel cutting.
2. Produce less heat and pressure.
3. Generate less vibrations.
4. Patient requiring air abrasion do not need local anesthesia.
5. Less discomfort to patient.
6. No sound production while tooth preparation.

### Disadvantages

- Large and heavy air abrasive units.
- Over preparation of tooth can occur.
- High cost of the equipment.
- Loss of tactile sense.
- Can result in soft tissue injury like gingival hemorrhage.
- If handled improperly can damage sound tooth structure.
- Inhalation of particles can cause systemic problems.

### Uses of Air Abrasion Technology

1. **Treatment of pits and fissures:** Using air abrasion technology, deep pits and fissures can be widened and deepened.
2. **Diagnosis of pits and fissure caries:** By targeting the particle beam, the discolored portion of tooth can be removed, if surface underneath it is carious, it can be restored and if it is sound tooth is restored with a sealant.
3. It can be used as an adjunct to acid etching.
4. Cementation of crown is facilitated by air abrasion technology as sandblasting of internal surface of crown can result in increased abrasion.
5. Air abrasion can also be used for removal of debris and repair of defective composite restorations.

So we have seen the basic steps in a tooth preparation, though specific tooth preparation techniques have been discussed in other chapters. One of the most important things before carrying tooth preparation is assessment of factors like extent of caries, esthetics, occlusion, age of patient, operator skill, anatomy of tooth, pulp protection, so as to have a successful long-term restoration which is functionally acceptable with optimal esthetics and in harmony with occlusion.

### VIVA QUESTIONS

#### Q. What is preclinical operative dentistry?

**Ans.** Preclinical operative dentistry is a branch of operative dentistry where practical training is given for tooth preparation and restoration of teeth with various materials on dummy models in simulated oral environment.

**Q. Define Operative dentistry?**

**Ans.** According to Sturdevant, "Operative dentistry is defined as science and art of dentistry which deals with diagnosis, treatment and prognosis of defects of the teeth which do not require full coverage restorations for correction." Such corrections and restorations result in the restoration of proper tooth form, function and aesthetics while maintaining the physiological integrity of the teeth in harmonious relationship with the adjacent hard and soft tissues.

**Q. Why is subject preclinical operative dentistry important?**

**Ans.** As we know oral cavity is a small area which consist of lips, cheeks, palate, and a mobile tongue. To do tooth preparation in this area, a great skill is required. Repeated tooth preparation in extracted natural teeth increases the skill and efficiency of the person.

By doing tooth preparation in dummy models, a person is able to juxtapose his acquired skill in clinical patient easily. Moreover this training increases the confidence and psychomotor skills for handling tissues.

**Q. What are different causes of loss of tooth structure?**

**Ans.** Most common cause is dental caries. Other causes can be trauma resulting in tooth fracture, attrition, abrasion, erosion, tooth malformation, hypoplasia, tooth resorption, etc.

**Q. What is simple, compound and complex tooth preparations?****Q. What are different walls and floors of a tooth preparation**

- Ans.**
1. Buccal
  2. Lingual/Palatal
  3. Mesial
  4. Distal
  5. Axial wall
  6. Occlusal/Incisal
  7. Pupal floor
  8. Gingival seat

**Q. What are different walls of preparation on class I tooth preparation?****Q. What are different walls, line and point angles of class II tooth preparation?****Q. What are preparation walls, line and point angles of class III tooth preparation?****Q. Name the preparation walls, line and point angles of class II tooth preparation?****Q. Name the preparation walls, line and point angles of class V tooth preparation.****Q. Define a line angle.****Q. What is a point angle?****Q. Do we have line angle at cavosurface margin?**

**Ans.** No, because line angle is the junction between two prepared parts of tooth preparation. Cavosurface margin is the junction of prepared tooth with unprepared tooth surface.

**Q. Classify tooth preparation?****Q. If class II tooth preparation involves only proximal surface, why do we make occlusal preparation also?**

**Ans.** Occlusal preparation is done for convenience form. Since directly reaching the affected area with bur is difficult because of close proximity of the adjacent tooth therefore an occlusal preparation is made through which proximal surface is reached.

**Q. Why is class VI added to Black is classification?**

**Ans.** Black classified the cavities according to some order and pattern of caries in affected teeth. But he did not include the areas which he assumed might not be attacked by caries, though in reality they might be affected. Simon latter modified Black's classification and added class VI.

The class VI are the tooth preparations which occur in the areas not covered by any of the other five classes like cusp tips, incisal two-third of anterior teeth, etc.

**Q. What will be the treatment if caries involve proximal surface of anterior tooth without involving incisal edge and caries at palatal pit?**

**Ans.** If lesions are not interconnected they are treated as separate preparations.

But if they are connected, the preparation is class III with lingual extension.

**Q. What is treatment for caries present on buccal surface and proximal surface of a molar?**

**Ans.** If lesions are not interconnected and small, they are treated as separate class II and class I preparations.

But if decay is more and lesions are interconnected, it is treated as class VI preparation (proximo-occluso-buccal preparation).

**Q. What is similarity between class II, III, IV and V preparation?**

**Ans.** All occur on smooth surfaces.

**Q. What is common between class II, III, IV preparation?**

**Ans.** All these occur on proximal surfaces.

**Q. How is tooth preparation done?**

**Ans.** It is done by use of hand and rotary instruments.

**Q. What are different steps of tooth preparation?**

**Q. Define outline form. List the factors influencing the outline form?**

**Q. What is extension for prevention?**

**Ans.** This concept was given by GV Black which advocated involvement of all pits and fissures even if they are unaffected by caries.

**Q. What do you mean by breaking the contact?**

**Ans.** In case of class II, and III and IV caries, there is always a contact with the adjacent tooth. In these cases, whether caries are below or above the contact, the contact has to be broken so as to bring preparation margins into the embrasures for easy cleansability.

If preparation margins end in non-cleansable areas, food stagnation in those areas may result in secondary caries.

**Q. What should be ideal depth of the preparation?**

**Ans.** Ideal depth should be 0.5 mm below DEJ, especially for non-adhesive materials. Since enamel is inelastic, it cannot be used for providing retentive and resistance form. So depth of preparation should be increased till elastic dentin is reached. Preparation should not end at dentinoenamel junction. This area is sensitive because of lateral branching of dentinal tubules and cytoplasmic extensions of odontoblasts.

**Q. How does convenience form affects outline form?**

**Ans.** This is specially seen in case of class II, III and IV preparations where adjacent tooth is present. In these cases it is impossible to reach the proximal area without cutting occlusal surface, otherwise adjacent tooth is cut.

But if adjacent tooth as missing, one can gain entry to proximal box without cutting the occlusal surface.

**Q. What is meant by cuspal contour?**

**Ans.** Cuspal contour means making preparation at uniform depth providing equal dentin thickness between pulp and the preparation. Since cusps are conical in shape, if pulpal floor is made straight it may result in uneven

dentin thickness. The areas where less of dentin is present, preparation will be closer to pulp, resulting in its damage.

**Q. Why should not preparation have sharp angles?**

**Ans.** If preparation has sharp angles, it leads to concentration of stresses at those areas which may fracture the restoration. So to avoid stress concentration, preparation should have gentle curves and smooth walls.

**Q. What is significance of stress bearing areas?**

**Ans.** When opposing teeth come in contact, they contact only some areas of occlusal surfaces. These areas where they contact are stress bearing areas.

*Significance:* Preparation margins should not end at stress bearing areas otherwise stresses are met partially by the tooth and partially by restoration resulting in separation between the two. This can fracture the restoration or may result in marginal leakage. So preparation margin should be avoided at stress bearing areas. They should be kept entirely either on tooth surface or on restorative material.

**Q. How does outline form is affected by direction of enamel rods?**

**Ans.** Enamel rods extend perpendicular from DEJ to enamel in a slightly wavy course. In vertical direction, they appear to converge towards a pit from DEJ, whereas they diverge as they move towards cusp tip from the DEJ.

In horizontal section, enamel rods flare out from DEJ towards outer surface.

Because of the direction of enamel rods, following walls are flared externally:

- Buccal and lingual walls of proximal box.
- Mesial and distal walls of buccal and lingual boxes of class I extensions.
- All walls of class V preparation.

If these walls are made to converge towards each other, this will result in unsupported enamel rods which may fracture latter on.

**Q. How does aesthetic affect outline form?**

- Ans.**
- For class III preparation, labial enamel is kept intact.
  - Preparation margins should be kept into embrasures for better aesthetics.
  - Reverse curve is given in maxillary premolars.

**Q. How does age affect outline form?**

**Ans.** Because of presence of deep pits and fissures, young teeth are more caries prone, therefore for a young patient, a conventional preparation is indicated.

For older patients, a conservative preparation is indicated. In these patients teeth become less susceptible to caries because of following reasons:

- Attrition of teeth.
- Cumulative effect of fluoride from food, water supply, dentifrices, etc.
- Older patient may follow oral instructions better.

**Q. Define resistance form.**

**Q. What are factors affecting resistance form?**

**Q. What is extension for resistance?**

**Ans.** When outline is extended for reinforcing the weakened tooth structure, it is referred as extension for resistance. For example, when preparation involves more than one-half of the cusp, outline is extended in which cusp is reduced and cuspal coverage is done.

**Q. Why is floor of preparation made perpendicular to occlusal forces?**

**Ans.** When masticatory forces are applied perpendicular to floor, there is equal and opposite force offered by preparation floor to resist the masticatory forces.

If pulpal floor is made at an angle, it will split occlusal forces into two components:

- Perpendicular component which is resisted by occlusal forces, this helps in seating of the restoration.
- Lateral component of force along the surface of floor.

**Q. Is pulpal floor always horizontal?**

**Ans.** No the mandibular premolar has a lingual tilt, so the pulpal floor is also made with lingual tilt.

**Q. Why should a restorative material have bulk?**

**Ans.** To have resistance form a restorative material should have sufficient bulk, for example for amalgam, at least 1.5-2 mm of depth is required.

**Q. Why should be unsupported enamel removed from the preparation?**

**Ans.** If enamel is not supported by dentin, it can fracture by masticatory forces because of its brittle nature.

**Q. What is isthmus and its significance?**

**Ans.** Isthmus is the narrow connection between two portions of a preparation (occlusal and proximal). Most of the restoration failures occur at isthmus area. If it is very narrow, restoration will be very weak at that area. If isthmus is very wide, the remaining tooth structure will become very weak.

**Q. When should two adjacent preparation be connected??**

**Ans.** If healthy tooth structure between two preparations is less than 0.5 mm, the two adjacent preparations are joined to form one large preparation. For example, mesial and distal pits of maxillary first molar.

**Q. What is retention form?**

**Ans.** Classify retention form

- Intracoronal
- Extracoronal

**Q. What are factors affecting retention form?**

**Ans.** a. Proximity between tooth and restoration  
b. Parallelism of opposing walls  
c. Total surface area of contact

**Q. What are different modes of retention?**

**Q. How does dentin help in retention?**

**Ans.** Due to elastic nature of dentin, there is microscopic movement of dentinal walls (away from each other) when a restorative material is being condensed in the preparation. Once the restorative material sets, dentin comes back to its original position resulting in better retention and more gripping action.

**Q. What is significance of dovetail?**

**Ans.** It helps in retention in proximal direction. In other words dovetail holds the proximal restoration from dislodging proximally.

**Q. What is undercut?**

**Ans.** Undercut is a mode of retention which is prepared with an inverted cone bur in line angles of the preparation. While preparing undercut, one should take care to make the cut in the wall not into the floor.

While restoration, one should take care that only the restorative material should be filled in the undercut area, and not the base.

**Q. What are secondary means of retention?**

**Q. What is convenience form?**

**Q. What is meant by convenience for access?**

**Ans.** In case of class II and III preparations, due to presence of adjacent tooth, one has to cut the occlusal or labial surface. This outline for gaining access to carious lesion is called as convenience for access.

**Q. What do you mean by removal of remaining caries?**

**Ans.** In some teeth, if any caries remain on the deeper part of preparation after gaining resistance and retention

form, these are removed carefully without causing any harm to pulp.

If attempts are made for complete caries removal at the initial stages only, one might end up for over cutting so it is always advised to incorporate retentive and resistance features before complete caries removal is done.

**Q. Which instrument is used for removal of remaining caries?**

**Q. Difference between affected and infected dentin?**

**Q. What precautions should be taken while removing deep carious lesion?**

**Q. What do you mean by unsupported enamel?**

**Q. Which instrument is used for removal of unsupported enamel rods ?**

**Ans.** Chisel, hoe or hatchet is used for removal of unsupported rods.

**Q. For smoothening the gingival seat which instruments is used?**

**Ans.** GMT is used for making gingival seat.

**Q. How do you check convenience form?**

**Ans.** After tooth preparation, insert the small amalgam condenser into all parts of preparation. If even the small instrument does not enter some parts of tooth preparation, tooth preparation is widened.

**Q. Is breaking of contact also required for insertion of matrix band?**

**Ans.** No, the main reason for breaking a contact is to bring the preparation margins in self cleansable area.

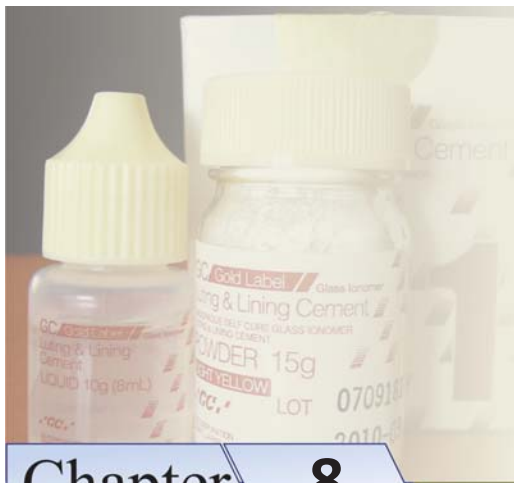For matrix band insertion, teeth can be separated using separators rather than cutting natural teeth structure.

**Q. For preparations near gingival margins, where should be gingival seat located?**

**Ans.** As we know gingival area is a delicate area, any irritant present at tooth – gingival interface can cause inflammation of soft tissue and epithelial attachment.

One should always try to keep the gingival margins supragingivally for easy cleansability. Subgingival margins are given only when:

- a. Decay extends subgingivally.
- b. Old restoration is present subgingivally.
- c. A biocompatible restorative material is used for aesthetic concerns.



# Dental Cements

## Chapter 8

### INTRODUCTION

Uses of Dental Cements

Classification of Dental Cements

### ZINC OXIDE EUGENOL CEMENT

Composition

Setting Reaction of Zinc Oxide Eugenol Cement

Manipulation of Zinc Oxide Eugenol (ZOE) Cement

Biocompatibility of Zinc Oxide Eugenol Cement

Types of ZOE

Clinical Uses

### ZINC PHOSPHATE CEMENT

Composition

Setting Reaction

Manipulation of Cement

Mechanical Properties

Biocompatibility

Clinical Uses

### ZINC SILICOPHOSPHATE CEMENTS (ZSPC)

### ZINC POLYCARBOXYLATE CEMENT

Composition

Manipulation of Zinc Polycarboxylate Cement

Setting Reaction

Bonding of Polyacrylate Cement to Tooth Structure

Mechanical Properties

Solubility

Biological Considerations

Uses of Zinc Polycarboxylate Cement

### GLASS IONOMER CEMENT

Classification of Glass Ionomer Cements

Composition of Glass Ionomer Cement

Water Settable Glass Ionomer

Metal Reinforced Glass Ionomer Cement

Resin Modified Glass Ionomer

Manipulation of Glass Ionomer Cement

Manipulation of Glass ionomer cement – Capsule Form

### SETTING REACTION

Setting Reaction of Autocure Glass Ionomer Cement

Setting Reaction of Resin Modified Glass Ionomers

Setting Time

### INDICATIONS OF GLASS IONOMER CEMENT

### CONTRAINDICATIONS OF GLASS IONOMER CEMENTS

### PROPERTIES OF GLASS IONOMER CEMENT

Physical Properties

Biocompatibility

Water Sensitivity

Adhesion

Fluoride Release

Esthetics

Margin Adaptation and Leakage

Radiopacity

### RESIN CEMENTS

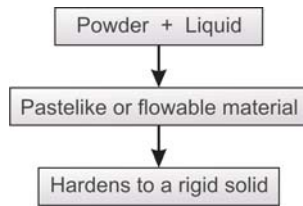
Uses

Types of Resin Cements

Technique for Using Resin Cements

## INTRODUCTION

*Dental cements:* Dental cements are the materials made from two components, powder and liquid when mixed together form a pastelike or flowable material which hardens to a solid structure.



## Uses of Dental Cements

Dental cement can be used as:

- Temporary restoration
- Permanent restoration
- Temporary luting
- Permanent luting
- Root canal sealing
- Pulp protection
  - bases
  - liners/pulp capping agents
  - varnishes

### Different uses of cements are determined by:

- Composition
- Compressive strength
- Modulus of elasticity
- Film thickness
- Solubility
- Biocompatibility

## Classification of Dental Cements

### Based on Composition

- i. Conventional cement
  - Zinc phosphate cement
  - Zinc oxide eugenol cement
  - Polycarboxylate cement
  - Glass ionomer cement
- ii. Resin-base cement
  - Resin cement
  - Resin modified glass ionomer cement

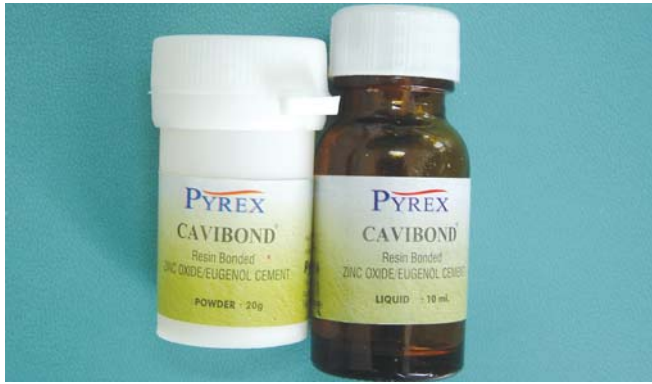### Classification Based on Uses

1. Permanent luting cements:
  - Zinc phosphate
  - Zinc silicophosphate
  - Zinc polycarboxylate cement

- Modified ZOE type-II
  - Glass ionomer cement
2. Temporary luting cements:
    - ZOE type I
  3. Permanent restoratives:
    - Silicates
    - GIC type II
  4. Temporary restorative materials:
    - ZOE (reinforced) type III
    - GIC type II
  5. Bases:
    - A. Under amalgam:
      - Zinc phosphate
      - Zinc silicophosphate
      - Zinc polycarboxylate
      - Reinforced ZOE (type III)
      - GIC (type III)
      - $\text{Ca}(\text{OH})_2$
    - B. Bases under composites:
      - Zinc polycarboxylate
      - GIC type III
      - $\text{Ca}(\text{OH})_2$
    - C. Bases under gold:
      - Zinc phosphate
      - Zinc polycarboxylate
      - GIC (type III)
  6. Pulp capping agents:
    - i. Indirect pulp capping agents
      - $\text{Ca}(\text{OH})_2$
      - ZOE
    - ii. Direct pulp capping agents
      - $\text{Ca}(\text{OH})_2$
  7. Cavity liners
    - i. Under amalgam
      - $\text{Ca}(\text{OH})_2$
    - ii. Under composite
      - $\text{Ca}(\text{OH})_2$
      - GIC type III
      - Varnishes

## ZINC OXIDE EUGENOL CEMENT (FIG. 8.1)

Zinc oxide eugenol cement is one of the oldest used cement. Since, it has soothing action on pulpal tissues and eugenol has topical anesthetic properties. Hence, it is termed an obtundent material. Though other cements are also used for temporization, but zinc oxide eugenol cement is used most commonly because zinc oxide eugenol cements are much less irritant to the pulp, less soluble in oral fluids and produce better marginal seal than zinc phosphate. A thick mix of zinc oxide eugenol cement is used for small tooth



**Fig. 8.1:** Zinc oxide eugenol cement

preparations, but before placing the cement, the prepared surface must be isolated and cleansed. Zinc oxide eugenol is not used as base material especially when unfilled and filled resins are used as restorative materials because eugenol interferes with polymerization process of resins. In these cases calcium hydroxide is used as base material under resin restoration.

### Composition

- a. Powder
  - Powder Zinc oxide (ZnO)—69.0%—Reactive ingredient
  - White rosin—29.3%—Reduces brittleness
  - Zinc stearate—1.0%—Catalyst
  - Zinc acetate (acts as accelerator)—0.7%—Accelerator
- b. Liquid
  - Eugenol—85.0%—Reactor
  - Olive oil—15.0%—Plasticizer.

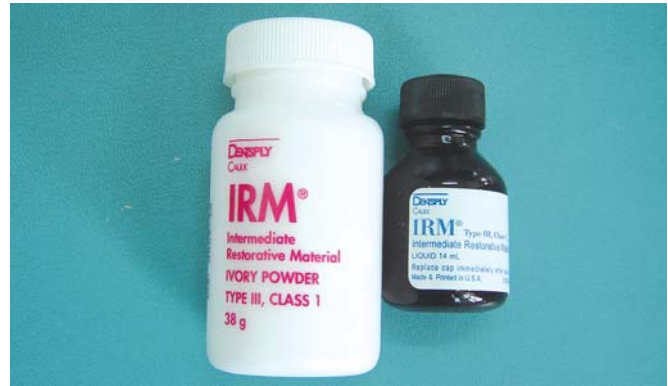### Setting Reaction of Zinc Oxide Eugenol Cement

On mixing powder and liquid, the zinc oxide hydrolysis and subsequent reaction takes place between zinc hydroxide and eugenol to form a chelate, zinc eugenolate. Within this matrix unreacted zinc oxide powder particles are embedded.

- First reaction  

$$\text{ZnO} + \text{H}_2\text{O} \rightarrow \text{Zn}(\text{OH})_2$$
- Second reaction  

$$\text{Zn}(\text{OH})_2 + 2\text{HE} \rightarrow \text{ZnE}_2 + 2\text{H}_2\text{O}$$
- Water is needed for the reaction and it is also a byproduct of the reaction so reaction progresses more rapidly in humid conditions.
- Because zinc eugenolate rapidly hydrolyzes to form free eugenol and zinc hydroxide, it is one of the most soluble cements. To increase the strength of the set material,



**Fig. 8.2:** Intermediate restorative material; modified zinc oxide eugenol cement

changes in composition can be made to the powder and liquid. For example, ortho-ethoxybenzoic acid can be added to the liquid or alumina or polymethyl methacrylate powder can be added to the powder. These modified zinc oxide-eugenol cements (**Fig. 8.2**) have the following compositions:

### Alumina and Ortho-ethoxybenzoic Acid Reinforced Composition

- a. Powder
 

• Zinc oxide	70%
• Alumina	30%
• Fused quartz and calcium	30%
- b. Liquid
 

• Ortho-ethoxybenzoic acid	62.5%
• Eugenol	37.5%

*EBA (Ortho-ethoxybenzoic acid) cement:* In this cement, EBA chelates with zinc forming zinc benzoate. Addition of fused quartz, alumina and dicalcium phosphate has also shown to improve mechanical properties of cement.

### Effect of EBA on Eugenol Cement

1. Increase in compressive and tensile strength.
2. More powder can be incorporated to achieve standard consistency.
3. Decrease in setting time (if concentration is < 70%).
4. EBA does not show adverse effects on pulp.

### Polymer Reinforced Zinc Oxide

- a. Powder
 

• Zinc oxide	80%—Reactive ingredient
• Polymethyl methacrylate	20%—Increases strength
• Traces of zinc stearate, zinc acetate	
- b. Liquid
 

• Eugenol	85%—Reactor
• Acetic acid	15%—Accelerator



*Polymer reinforced zinc oxide eugenol cement:* In this mixture, resin helps in improving strength, smoothness of the mix and decreasing flow, solubility and brittleness of the cement.

### Manipulation of Zinc Oxide Eugenol (ZOE) Cement

- ZOE are available as: (i) powder and liquid system, (ii) paste-paste system.

#### Manipulation of Powder and Liquid System

Powder is measured and dispensed with a scoop where as liquid is dispensed as drops on glass slab.

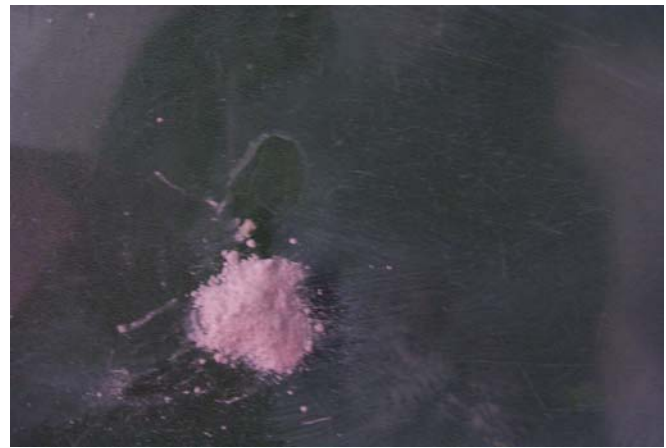- Powder is dispensed at one end of glass slab, using cement spatula. The powder is divided in main bulk increment, followed by smaller increments (**Figs 8.3 and 8.4**). While dispensing liquid, bottle should be held 90° to the mixing pad. It lets the fluid fall under its own weight.
- Start the mixing by incorporating half of the powder into the liquid with a heavy folding motion and pressure.
- When powder particles are wet with the liquid, add the remaining powder to the mix and continue to use a heavy folding motion to attain a putty consistency.
- For base, when mixing is done, bring the mix together and role it. One should be able to pick up the mix without deformation (**Fig. 8.5**).
- Pick-up a piece of mixed cement and place it into the preparation using a condenser.
- If the mix sticks to the condenser, powder the condenser head with cement powder to prevent the instrument from sticking during condensation.
- Use the condenser head and merge the restoration to the margin of the preparation.
- For smoothing, clean up and hardening of the restoration, use a wet cotton pellet.
- For luting consistency, “1 inch” string should be formed when flat surface of spatula is pulled from the mixed cement.

#### Paste-paste System

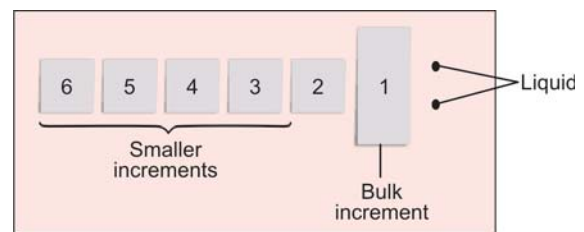
In this two pastes are dispensed in equal lengths on paper pad. Two pastes have different colors, mixing is done till a homogeneous color is obtained.

#### Working Time and Setting Time

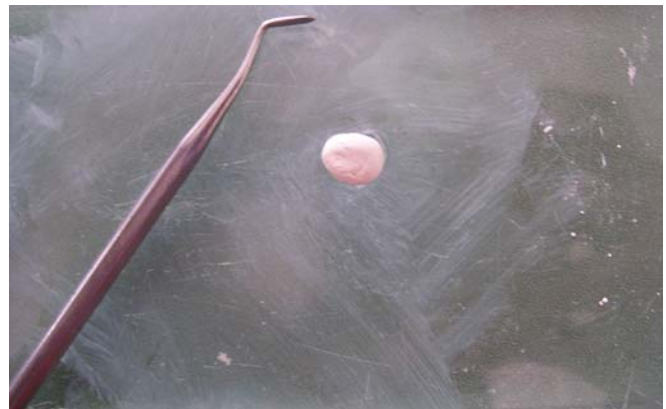These are usually not specified. In general, higher is the P:L, faster the materials sets. Cooling of glass slab slows



**Fig. 8.3:** Dispensing of zinc oxide eugenol powder and liquid



**Fig. 8.4:** Diagrammatic representation of increments of zinc oxide powder



**Fig. 8.5:** Right consistency of ZOE mix

down the setting reaction (unless the temperature is below the dew point).

Setting time of this cement is long but since water accelerates the setting reaction, it sets faster in mouth than outside.

### Biocompatibility of Zinc Oxide Eugenol Cement

ZOE is the best known obtundent. pH of cement is 7. This makes it least irritating cement. Because of this it is considered most palliative agent to the pulp.

## Types of ZOE

Type I – Temporary luting

Type II – Long-term luting

Type III – Temporary restoration

Type IV – Intermediate restoration

### Type I

Main features:

- Strength of the cement is low so it can be easily removed.
- It is used for short-term restorations.
- Free eugenol interferes with the setting of resin bonded composites so carboxylic acids can be used to replace eugenol making it non eugenol cement.

### Type II

Main features:

- This cement has improved strength and abrasion resistance.
- In this cement the part of eugenol liquid substituted by ortho-ethoxybenzoic acid (EBA) and alumina is added to powder.

or

- Powder is made up of 20 wt percent to 40 wt percent of fine polymer particles and zinc oxide particles that have been surface treated with carboxylic acid, in this the liquid remains eugenol.

### Type III

It is used for temporary restorations which last for a few days to few weeks.

### Type IV

It lasts for atleast up to 1 year. In this more powder has to be added for achieving better strength.

## Clinical Uses

- Base
- Temporary cementation
- Temporary restoration
- Root canal sealer
- Liner
- Pulp capping agent
- Permanent cementation

## Advantages

- Soothing effect on the pulp
- Good short-term sealing.

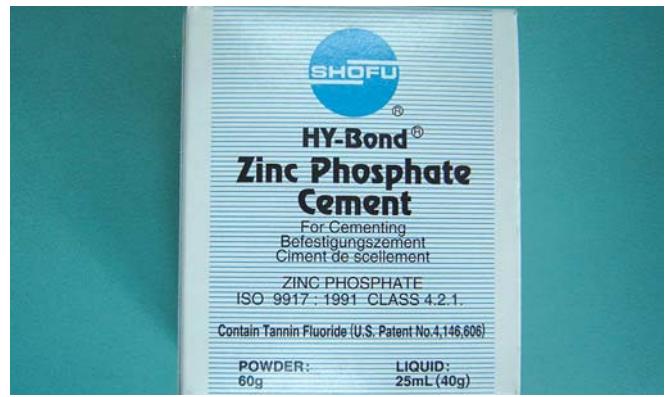


Fig. 8.6: Zinc phosphate cement

## Disadvantages

- Highly soluble
- Low strength
- Long setting time
- Low compressive strength.

## ZINC PHOSPHATE CEMENT (FIG. 8.6)

One of the oldest and most widely used cements, zinc phosphate cement is the standard against which new cements are compared. It was first introduced in 1878 and still used today because of excellent clinical track record.

## Two Types

**Type I:** Used for cementation. Specification requires the film thickness of less than 25 microns.

**Type II:** Used as a base and for luting. Specification requires a film thickness between 25 and 40 microns.

## Composition

**Powder:** The primary ingredients of zinc phosphate cement powder are zinc oxide and magnesium oxide.

- ZnO—90.2%.
- MgO—8.2%—condenses the ZnO during the sintering process
- $S_iO_2$ —1.4%—acts as an insert filler
- $Bi_2O_3$ —0.1%—imparts smoothness to the mixed cement
- Miscellaneous—(BaO,  $Ba_2SO_4$ , CaO)—0.1%.

All the ingredients are sintered at temperatures between 1000°C and 1400°C into a cake that is subsequently ground into fine powder.

**Liquid:** The liquid is phosphoric acid and water in the ratio of two parts acid to one part water. It may also contain

aluminium phosphate and zinc phosphate. The water content of the liquid is critical and should be controlled to provide a adequate setting time. When the liquid is exposed in open bottle, it absorbs moisture from the air in case of high humidity but in low humidity times it will lose moisture. In case of very old liquids, the last 25% portion remaining in the bottle should be discarded because it is usually discolored or contaminated.

- Phosphoric acid 38.2%
- Water 36.0%
- Aluminium or zinc phosphate 16.2%
- Zinc 7.1%
- Aluminium 2.5%

Both aluminium and zinc act as buffers to reduce the reactivity of the powder and liquid.

### Setting Reaction

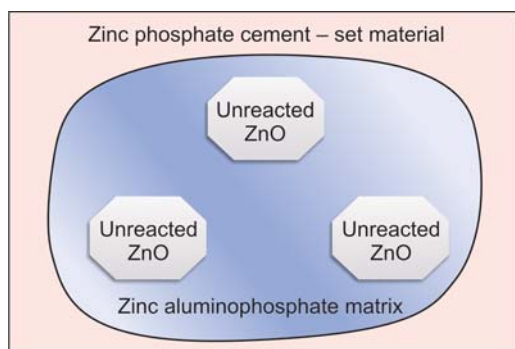
Phosphoric acid attacks surface of the particles and releases Zn ions into the liquid. Aluminium which already forms a complex with the phosphoric acid reacts with zinc and yields a zincaluminophosphate gel

The set cement consists of a zinc phosphate matrix in which unreacted zinc oxide powder particles are embedded. Crystals of tertiary zinc phosphate/ hopeite, are found on the surface of the cement (**Fig. 8.7**).

### Manipulation of Cement

#### Manipulation of Zinc Phosphate Cement

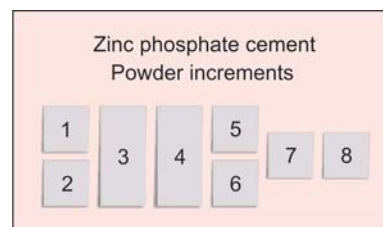
- Working time ~ 5 minutes
- Setting time ~ 2.5 to 8 minutes
- Powder is measured and dispensed with scoop a liquid is dispensed as drops. Cement mixing should be done on cool glass slab with a narrow bladed stainless steel spatula. Lower the temperature of the slab during mixing, the longer will be the working time. This is advantageous




**Fig. 8.7:** Structure of set zinc phosphate cement

because it allows incorporation of more powder into the liquid which results in greater compressive strength and lower solubility of the final cement.

- Some clinicians prefer to mix the cement using the “frozen slab” technique which greatly extends the working time and allows incorporation of more powder into the liquid. But this method has disadvantage of incorporating water into the mix.
- Since setting reaction is an exothermic type the heat liberated while setting further accelerates the setting rate. So it is very important to dissipate this heat which can be done by
  - a. Using chilled glass slab.
  - b. Using smaller increment for initial mixing of cement.
  - c. Mixing an large area of glass slab
- Powder is divided into 5-8 increments (**Figs 8.8A and B**) in which initial two increments are smaller, third and fourth increments are bigger one and after that increments are again smaller in size.
- Initial increments are smaller in size so as:
  - To achieve the slow neutralization of the liquid.
  - To control the reaction.
- Middle increments are larger in size so as to further saturate the liquid to form zinc phosphate. Because of



**Fig. 8.8A:** Diagrammatic representation of increments of zinc phosphate powder



**Fig. 8.8B:** Photograph showing increments of zinc phosphate powder

presence of less amount of unreacted acid, this step is not affected by heat released from the reaction.

- In the end the smaller increments of powder are added so as to achieve optimum consistency
- After dividing powder, dispense liquid on the glass slab. While dispensing, the liquid bottle should be held vertical and close to the powder (**Fig. 8.9**). Repeated opening of the liquid bottle or early dispensing of the liquid prior to mixing should be avoided because evaporation of liquid can result in changes in water/acid ratio which can further result in decrease in pH and an increase in viscosity of the mixed cement.
- For luting, mixing is continued until a “1 inch string” is formed when spatula is pulled away from the glass slab (**Fig. 8.10**). For base, consistency should be such that it can be rolled into a ball without sticking (**Fig. 8.11**).
- While setting of cement is taking place, water contamination should be avoided because on moisture contamination, the phosphoric acid leaches out of the cement and solubility greatly increases.

### Mechanical Properties

Strength of the cement is almost linearly depends on its powder-to-liquid ratio; zinc phosphate cement achieves 75% of its ultimate strength within 1 hour.

- Compressive strength of cement is 104 Mpa
- Tensile strength - 5.5 Mpa
- Modulus of Elasticity is 13.7 gigapascals. This high MOE makes the cement quite stiff and resistant to elastic deformation.
- Retention of cement is by mechanical interlocking not chemical interaction.


### Biocompatibility

Because of presence of phosphoric acid, acidity of cement is quite high making it irritable. pH of cement liquid is 2.0. two minutes after mixing the pH is almost 2 and after 48 hours it is 5.5.


### Clinical Uses

It is used both as an intermediate base and as a cementing medium.

1. *Intermediate base*: A thick mix of zinc phosphate cement is used as an intermediate base beneath a permanent metallic restoration.
2. *Cementing medium*: It is used to cement crowns, inlays, orthodontic appliances and fixed partial dentures. A creamy mix of cement is applied to place the restoration.



**Fig. 8.9:** While dispensing liquid, the bottle should be held vertical and close to the powder



**Fig. 8.10:** For luting, “1 inch string” should be formed when spatula is pulled away from the glass slab



**Fig. 8.11:** For base, consistency should be such that mix can be rolled into a ball without sticking

It holds tooth and restoration together by mechanical interlocking, filling the space between the irregularities between the two.

#### Uses of zinc phosphate cement

- Luting agent for crowns, inlays
- Intermediate base
- Temporary restoration
- Luting orthodontics band

### Advantages

- Long record of clinical acceptability
- High compressive strength
- Thin film thickness.

### Disadvantages

- Low initial pH
- Lack of an adhesion to tooth structure
- Lack of anticariogenic effect
- Soluble in water.

## ZINC SILICOPHOSPHATE CEMENTS (ZSPC)

Zinc silicophosphate cements consist of a mixture of silicate glass and zinc phosphate cement.

### Composition

Powder contains an acid soluble silicate, zinc and magnesium oxides. Liquid is phosphoric acid.

### Properties of Zinc Silicophosphate Cements

- Translucent and more esthetic than zinc phosphate cement.
- Anticariogenic because of fluoride release from this cement.
- Has sufficient strength.

## ZINC POLYCARBOXYLATE CEMENT

Zinc polycarboxylate cement is also known as zinc polyacrylate cement. It was one of the first chemically adhesive dental materials introduced in the 1960s. It sets by an acid-base reaction between a powder and a liquid. It bonds to the tooth structure because of chelation reaction between the carboxyl groups of the cement and calcium present in the tooth structure. This implies that more mineralized the tooth structure, the stronger the bond.

### Composition

**Powder:** It is similar to that of zinc phosphate cement powder. Four percent (4%) stannous fluoride acts primarily as a strengthening agent. Fluoride does not exert an anticariogenic effect because zinc polycarboxylate cement leaches only 10 to 15% of the fluoride when compared to glass ionomer cement.

**Liquid:** Liquid is an aqueous solution of 32 to 43% high molecular weight polyacrylic acid.

The liquid has tendency to become viscous because it is a partially polymerized polyacrylic acid.

Even though it is quite viscous after mixing, but it can attain a satisfactory film thickness because of pseudoplasticity and decrease in viscosity when sheared.

### Manipulation of Zinc Polycarboxylate Cement

- Usually we take 1.5:1 powder to liquid ratio.
- Cement should be mixed on surface that will not absorb liquid like glass slab or paper pads.
- Liquid is dispensed just before mixing of the cement as the loss of water from liquid can result in increase in its viscosity.
- Mix first half of powder to liquid to obtain the maximum length of working time.
- Mixed cement should be adapted to tooth till it is glossy in appearance. Loss of gloss makes it nonadhesive.
- Before application of cement on to the tooth, conditioning of prepared tooth surface is recommended. Conditioning is done with an organic acid (polyacrylic acid 10-20%) for 10-20 sec, after this tooth is rinsed for 20-30 sec and dried.

### Setting Reaction

- When powder and liquid are mixed, hydrated protons formed from ionization of the acid, attack the zinc and magnesium powder particles. This results in release of zinc and magnesium ions which form polycarboxylates that crosslink the polymer chains. The final set consists of zinc polycarboxylate crosslinked polymer matrix in which unreacted zinc oxide particles are implanted.

### Working Time and Setting Time

Working time ~ 2.5 minutes

Setting time ~ 6-9 minutes

Lowering the temperature increases working time. Since, cooling glass slab causes thickening of polyacrylic acid, this further increases viscosity so only powder should be refrigerated for increasing working time.

While setting, the cement passes through the rubbery stage which makes it difficult to remove the cement. If excess cement is removed at this stage, it can cause pulling of some cement leaving a void. So the excess cement should be removed once it is set.

### Bonding of Polyacrylate Cement to Tooth Structure

- The polyacrylic acid is believed to react with calcium ion via the carboxyl group.
- The adhesion depends on the unreacted carboxyl group.

## Mechanical Properties

Compressive strength ~ 55-67 MPa

Tensile strength ~ 2.4-4.4 MPa

## Solubility

- It is low in water. But in acidic environment with pH of less than 4.5, solubility increases. Reduction in P:L ratio also increases solubility.

## Biological Considerations

pH of the liquid is 1.7 but increases rapidly after mixing. Zinc polycarboxylate cement shows excellent biocompatibility with the pulp because of following reasons:

- The size of polyacrylic acid molecule is bigger, this makes it less favorable to disperse into the dentinal tubules.
- The pH of the cement rises more rapidly when compared to that of zinc phosphate.

## Uses of Zinc Polycarboxylate Cement

- Cement inlays or crowns
- Used as base
- Temporary restorations
- Lute the stainless steel crown.

## Advantages

- Adhesion to tooth structure
- Rapid rise in pH upon cementation
- Lack of penetration of the large molecules into the dentinal tubules make it a biocompatible cement.

## Disadvantages

- Short working time (2-3 minutes)
- Does not resist plastic deformation under high masticatory stresses.

## GLASS IONOMER CEMENT

Glass Ionomer Cement were introduced to the dentistry 35 years ago (in 1972) by Wilson and Kent.

The invention of the glass ionomer cement resulted from previous fundamental studies on silicate cements and studies where the phosphoric acid in dental silicate cements was replaced by organic chelating acids. It was supported by work on the zinc polycarboxylate cement in which Smith showed that dental cements exhibiting the property of adhesion could be prepared from polyacrylic acid. Glass ionomer cement for that reason has been described as a hybrid of dental silicate cements and zinc polycarboxylates

(Fig. 8.12). Extensive use of this cement to replace dentin, has given it different names: Dentin substitute, man-made dentin and artificial dentin.

## Classification of Glass Ionomer Cements

### A. Traditional classification (Based on application)

- Type I—Luting cements (Fig. 8.13)
- Type II—Restorative cements (Fig. 8.14)
  - Type II.1—Restorative esthetic
  - Type II.2—Restorative reinforced
- Type III – Liner or base

### B. Newer classification

- Type I—Luting cements
- Type II—Restorative esthetic or reinforced cements
- Type III—Liner or base

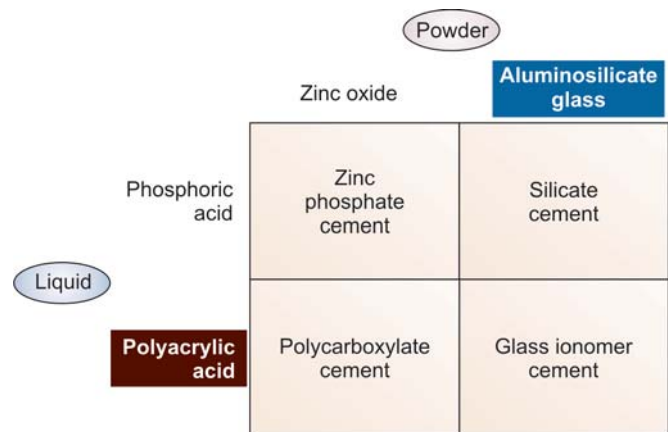


Fig. 8.12: GIC, hybrid of silicate and zinc polycarboxylate cements

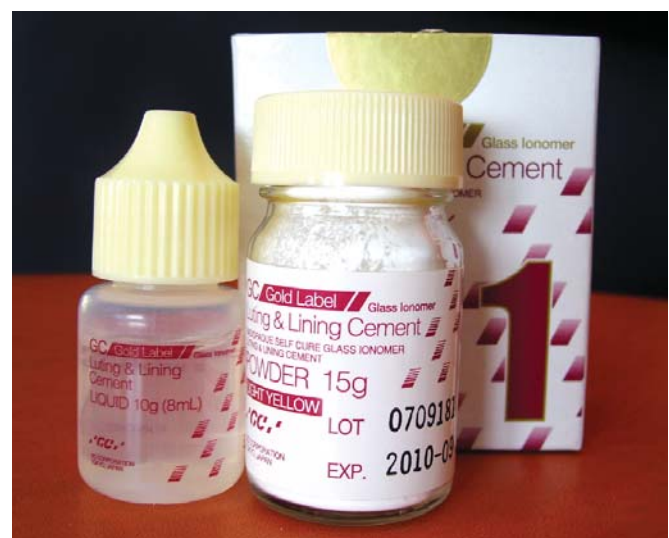

Fig. 8.13: Type I luting GIC

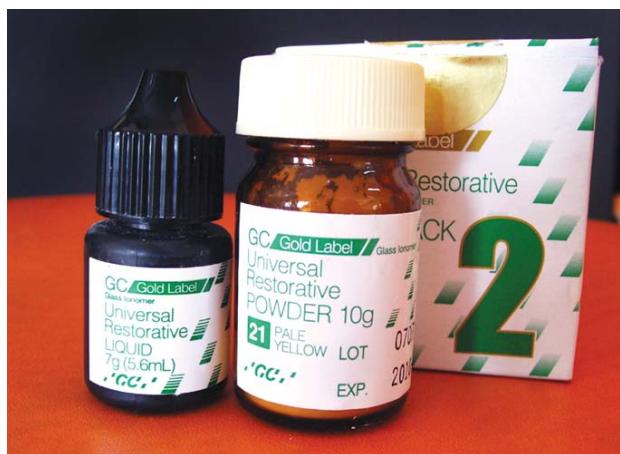

Fig. 8.14: Type II restorative GIC

### C. Classification of GICs according to their use

- Type I—For luting cements
- Type II—For restorations
- Type III—Linings and bases
- Type IV—Fissure sealants
- Type V—Orthodontic cements
- Type VI—Core build up

### Composition of Glass Ionomer Cement

Glass ionomer cement usually comes in mixtures of a powder and a liquid.

#### GIC Powder

The powder is an acid-soluble calcium fluoroaluminosilicate glass similar to that of silicate but with a higher alumina-silicate ratio that increases its reactivity with liquid. The fluoride portion acts as a “ceramic flux”. Lanthanum, strontium, barium or zinc oxide additives provide radiopacity. These powders are combined and fused (at temperatures 1100 to 1500°C) with a fluoride flux that serves to reduce their fusion temperature. The molten glass is then poured onto a steel tray. To fragment it, the mass is plunged into water and the resulting fragments are crushed, milled, and powdered. The particles are then sieved to separate them according to size. Particle size varies according to manufacturer, however sizes usually range from 20 microns for luting forms to 50 microns for restorative products.

The percentages of the raw materials in powder are:

- Silica – 41.9%
- Alumina – 28.6%
- Aluminium fluoride – 1.6%
- Calcium fluoride – 15.7%
- Sodium fluoride – 9.3%
- Aluminium phosphate – 3.8%

#### GIC Liquid

The liquid is an aqueous solution of polymers and copolymers of acrylic acid.

Originally, the liquids for GIC were aqueous solutions of polyacrylic acid in a concentration of about 40 to 50%. The liquid was quite viscous and had tendency to gel overtime.

#### Composition of Liquid

- |  |        |
|--|--------|
| • Polyacrylic acid<br>(Itaconic acid, Maleic acid) | 40-55% |
| • Tartaric acid                                    | 6-15%  |
| • Water  | 30%    |

To decrease the viscosity of liquid, itaconic, and tricarboxylic acids were added to the liquid. These acids tend to:

- Decrease the viscosity.
- Promote reactivity between the glass and the liquid.
- Prevent gelation of the liquid which can result from hydrogen bonding between two polyacrylic acid chains.

Polymaleic acid is often present in the liquid. It is a stronger acid than polyacrylic acid and causes the cement to harden and lose its moisture sensitivity faster. This occurs because polymaleic acid has more carboxyl (COOH) groups which lead to more rapid polycarboxylate crosslinking. This also allows more conventional, less reactive glasses to be used which results in a more esthetic final set cement.

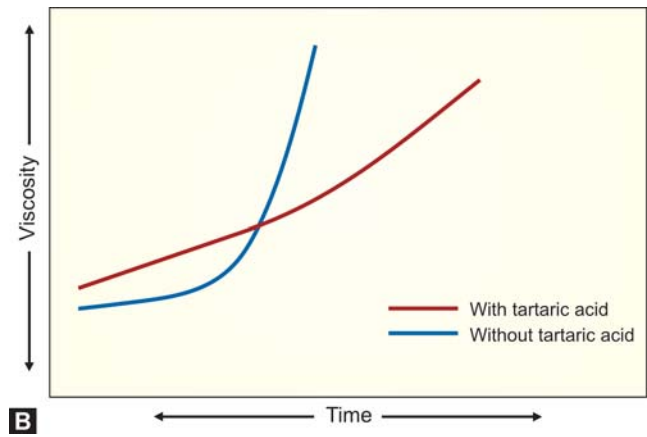
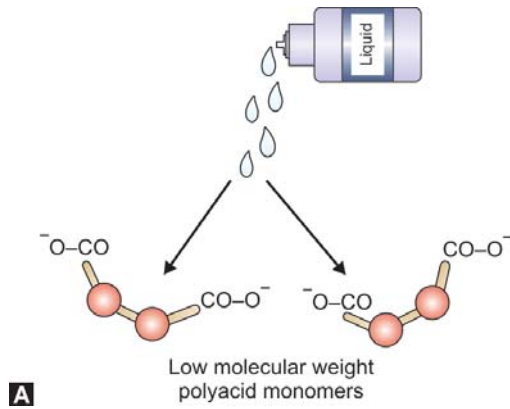
Tartaric acid is also present in the liquid. It improves handling characteristics and increases the working time, but it shortens the setting time. The viscosity of tartaric acid-containing cement does not generally change over shelf life of the cement (**Figs 8.15A and B**). However, a viscosity change can occur if the cement is out of date.

#### Water Settable Glass Ionomer

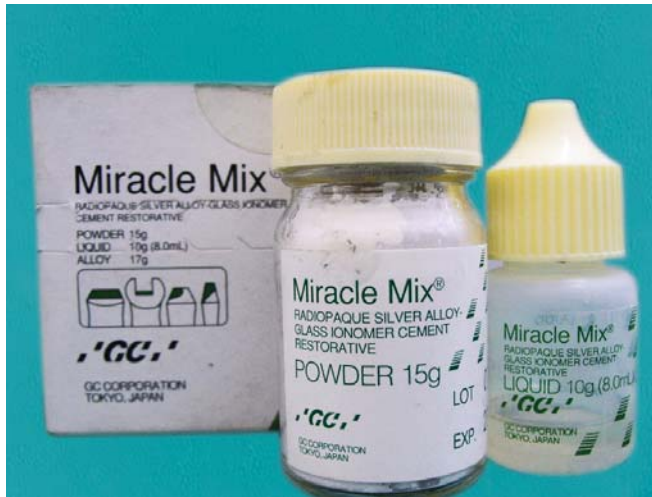As a means of extending the working time of the GIC, freeze-dried polyacid powder and glass powder are placed in the same bottle as the powder. The liquid consists of water or water with tartaric acid. When the powders are mixed with water, the acid powder dissolves to reconstitute the liquid acid and this process is followed by the acid-base reaction. This type of cement is referred to occasionally as water settable glass ionomer or anhydrous glass ionomer.

#### Metal Reinforced Glass Ionomer Cement

In order to reinforce the physical properties of glassionomer, metal particles in powder or fiber form are added to glass powder. This cement is of two types.



**Figs 8.15A and B:** (A) Only two carboxyl group are present in tartaric acid to react with powder, (B) Effect of tartaric acid on viscosity of GIC liquid



**Fig. 8.16:** Miracle mix

### *Miracle Mix (Silver alloy admix glass ionomer cement) (Fig. 8.16)*

It was introduced by Simmons in 1983. In this, silver alloy powder is blended with glass ionomer powder in ratio of 1:6 and mixed with glass ionomer liquid. This increases the compressive strength, tensile strength and abrasion resistance to some extent.

#### *Disadvantages*

- Difficult to achieve homogeneous mix of silver alloy and glass.
- Poor esthetics.
- Poor burnishing.
- Sensitive to moisture contamination during setting.

### *Cermet Cement*

It is introduced by Mclean and Gasser in 1987. This cement is fusion of glass ionomer to metal powders like silver or gold through sintering. Here the cement ionomers are manufactured by sintering compressed pellets made from fine metal powder and glass ionomer powder at temperature of 800°C. The sintered metal and glass fit is then ground into fine form which results in ceramicometal particles of fused metal and ground glass. Most accepted metal for sintering with glass ionomer is silver or gold. Titanium dioxide (5%) is added to improve the color.

#### *Advantages*

- Better abrasion resistance.
- Higher flexure strength.

#### *Disadvantage*

Poor esthetics.

### **Resin Modified Glass Ionomer**

It was first introduced as vitrebond (3M) in powder—liquid system to incorporate the best properties of both glass ionomer cement and composite resin. In this system, powder is fluorosilicate glass with photoinitiator or chemical initiator. The liquid contains 15 to 25% resin component in the form of HEMA, a polyacrylic acid copolymer along with photoinitiator and water.

#### *Advantages of Resin Modified Glass Ionomer Cements*

RMGIs show combined advantages of both composites and glass ionomers. These are:

- Extended working time
- Control on setting



- Good adaptation
- Chemical adhesion to enamel and dentin
- Fluoride release
- Improved aesthetics.
- Low interfacial shrinkage stress
- Superior strength characteristics.

#### Disadvantages of Resin Modified Composites

- Shrinkage on setting.
- Limited depth of cure especially with more opaque lining cements.

### Manipulation of Glass Ionomer Cement

#### Powder and Liquid

Mixing should be done

- At room temperature 21 to 25°C
  - With humidity of 40 to 60%
  - For 45 to 60 seconds
  - On a cool (not below the dew point) and dry glass slab or paper pad
  - With the help of a flat and firm plastic spatula.
- Mixing should be done using the powder: liquid ratio as recommended by the manufacturer. The powder to liquid ratio is important and varies from manufacturer to manufacturer. A reduction in powder to liquid ratio can result in poor physical properties.
  - Mixing of GIC is done on a special mixing paper pad which consists of sheets of plastic coated paper. This plastic coating prevents the absorption of liquid by paper.

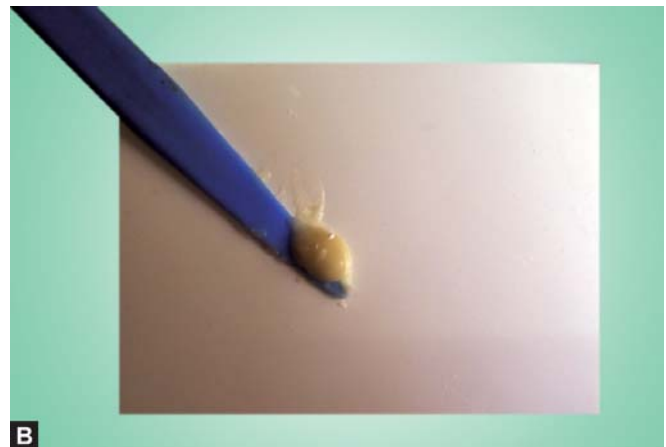- Glass slab is better than paper pad for mixing as it can be cooled to prolong the working time if required. It should be noted that an excessively chilled slab can cause a reduction in the cement compressive strength and modulus of elasticity.
- It is not necessary to mix the cement over a large area on the glass slab because the setting reaction is only mildly exothermic.
- For mixing, divide the dispensed cement powder into two equal portions. Mix the first portion into the liquid in 20 seconds and then add the remaining powder and mix for another 20 seconds. Mixing should be completed within 40-60 seconds (**Figs 8.17A and B**). Working time for glass ionomer cement is 60-90 sec.
- Loss of gloss on the surface of the mixed cement shows end of working time and start of setting reaction. The cement should be used before it loses its glossiness. If the glossiness is lost, the cement won't wet the tooth surface and becomes a non adhesive cement.

#### Manipulation of Glass Ionomer Cement – Capsule Form

- Capsules have preproportioned P:L ratio.
- For mixing break the seal separating powder and liquid.
- Mixing is done in an amalgamator.
- Capsule contains nozzle so that mix can be injected directly.

#### Advantages of Capsule System

- Convenient to use
- Reliable control of P:L ratio.



**Figs 8.17A and B:** Mixing of GIC; (A) Dispensing of powder and liquid of GIC for mixing; (B) Freshly mixed GIC ready to be used for restoration

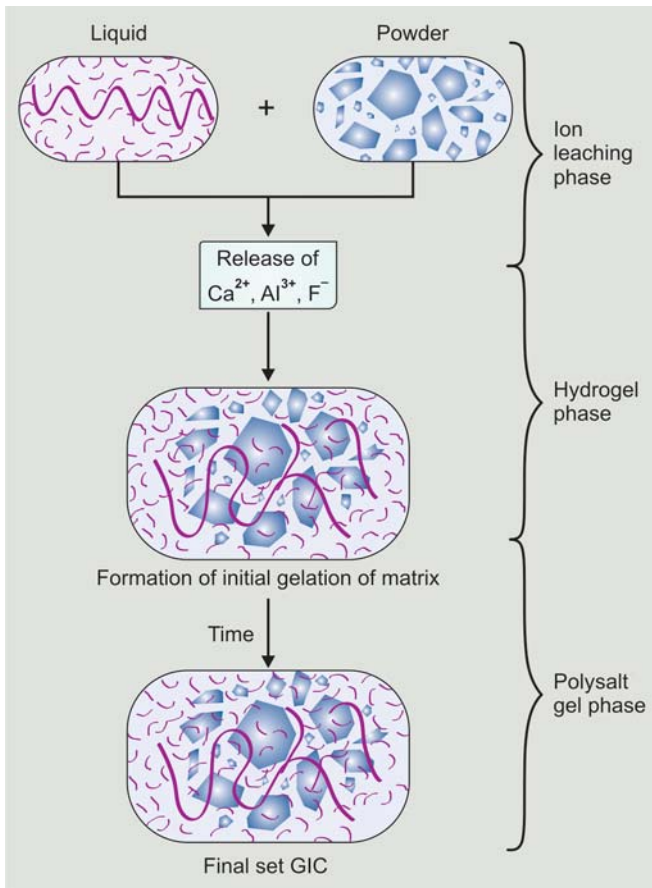


Fig. 8.18: Setting reaction of glass ionomer cement

## SETTING REACTION

### Setting Reaction of Autocure Glass Ionomer Cement

Basically in autocure glass ionomer cement, setting reaction is an acid-base reaction between the acidic polyelectrolyte and the aluminosilicate glass. It occurs in three different but overlapping stages (Fig. 8.18).

#### Three Stages of GIC Setting Reaction

1. Ion leaching phase
2. Hydrogel phase
3. Polysalt gel phase.

#### Ion Leaching Phase

- This phase occurs when powder and liquid are mixed. When the powder and aqueous acidic solution are mixed, the polyacid attacks the glass particles (called leaching) to release cations like  $\text{Ca}^{2+}$  and  $\text{Al}^{3+}$ .
- These ions react with the fluoride ions to form  $\text{CaF}_2$  and  $\text{AlF}_3$ . Soon because of continued increase in acidity,

$\text{CaF}_2$  dissociates and reacts with acrylic copolymer to form a stable matrix.

- At this stage, the mix appears glossy in nature and it can adhere to the tooth structure.

#### Hydrogel Phase

- In this phase, calcium ions are released rapidly. These liberated ions react with the acid and cross-link with the polyacrylic acid, i.e. calcium bridges to form a calcium polycarboxylate gel in which the non-reacted glass is embedded.
- The initial setting of the cement is because of this reaction. At this stage, the cement appears rigid and opaque.
- Water plays a critical role in the setting of GIC. It serves as the reaction medium initially and then slowly hydrates the crosslinked agents thereby yielding stable gel structure which is stronger and less susceptible to moisture contamination.
- If freshly mixed cement is exposed to ambient air without any protective covering the surface will craze and crack as a result of desiccation. Any contamination by water that occurs at this stage can cause dissolution of the matrix forming cations and anions to the surrounding areas. Both desiccation and contamination are water changes in the structure during placement and for a few weeks after placement is possible.

#### Polysalt Gel Phase

- This phase occurs when the mix reaches its final set. This stage is continued for many months.
- In this stage continued attack of hydrogen ions cause a delayed release of Al ions from silicate glass in the form of  $\text{AlF}$  ions which are deposited in the already preformed matrix to form a water-insoluble Ca-Al-Carboxylate gel. It is the Al ions which provide strength to the cement.
- The structure of the fully set cement is a composite of glass particles surrounded by silica gel in a matrix of polyanions crosslinked by ionic bridges (Fig. 8.19).

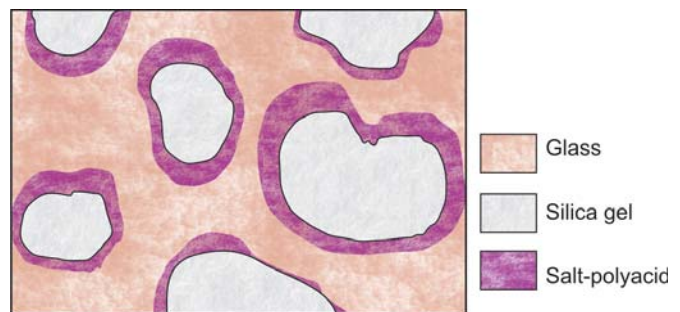


Fig. 8.19: Diagrammatic representation of finally set GIC

Within the matrix are small particles of silica gel containing fluorite crystallites.

### Setting Reaction of Resin Modified Glass Ionomers

Basically, in these cements two types of setting reactions occur:

1. Acid base neutralization reaction
2. Free radical methacrylate cure.

Because of these two reactions, following can be accounted:

- a. Formation of two different matrices – an ionomer salt hydrogel and a poly HEMA matrix. This whole system can inhibit the acid base reaction.
- b. Also there occurs multiple crosslinking chain formation which can occur by acid base reaction, light cure mechanism and resin autocure mechanism.

When powder and liquid are mixed and light is activated, a photoinitiated setting reaction starts. Now the methacrylate group of polymer grafts into polyacrylic acid chain and methacrylate groups of HEMA. This crosslinking of HEMA and of methacrylate group of polymer causes hardening of the cement (**Fig. 8.20**). But acid base reaction continues for some days.

### Setting Time

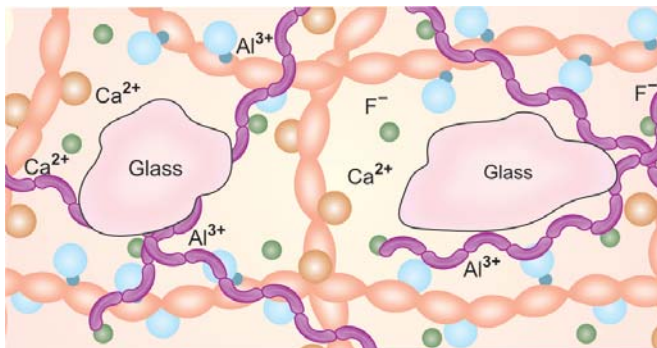
GIC sets within 6-8 minutes from the start of mixing. Setting time is less for type I materials than type II materials. The setting can be slowed when the cement is mixed on a cool glass slab.

Setting time for type I GIC—5-7 minutes

Setting time for type II GIC—10 minutes.

### INDICATIONS OF GLASS IONOMER CEMENT

1. Restoration of permanent teeth
  - a. Class V, Class III, small class I tooth preparations
  - b. Abrasion/Erosion
  - c. Root caries



**Fig. 8.20:** Setting reaction of resin modified glass ionomers

2. Restoration of deciduous teeth
  - a. Class I – Class VI tooth preparations
  - b. Rampant and nursing bottle caries
3. Luting or cementing
  - a. Metal restorations (Inlay, onlay, crowns)
  - b. Nonmetal restorations (composite inlays and onlays)
  - c. Veneers
  - d. Pins and posts
  - e. Orthodontic bonds and brackets
4. Preventive restorations
  - a. Tunnel preparation
  - b. Pit and fissure sealants
5. Protective liner under composite and amalgam
6. Bonding agent
7. Dentin substitute
8. Core build up
9. Splinting
10. Glazing
11. Endodontics
  - a. Repair of external root resorption
  - b. Repair of perforation
12. Other restorative technique
  - Sandwich technique
  - Atraumatic restorative treatment
  - Bonded restorations.

### CONTRAINDICATIONS OF GLASS IONOMER CEMENTS

1. In stress bearing areas like class I, class II and class IV preparations.
2. In cuspal replacement cases.
3. In patients with xerostomia.
4. In mouth breathers because restoration may become opaque, brittle and fracture over a time.
5. In areas requiring aesthetics like veneering of anterior teeth.

### Advantages of GIC

- Inherent adhesion to tooth structure because of chemical bonding to enamel and dentin through ion exchange.
- Biocompatible because large sized polyacrylic acid molecules prevent the acid from producing pulpal response.
- Little shrinkage and good marginal seal.
- Anticariogenic because of fluoride release. This fluoride can also be recharged from topical fluoride applications.
- Good color matching and translucency makes it esthetic.

- Minimal tooth preparation required hence easy to use on children.
- Less soluble than other cements.
- Less technique sensitive than composite resins.

#### Disadvantages of GIC

- Brittle and low fracture resistance
- Low wear resistance
- Water sensitivity during setting phase affects physical properties and esthetics.
- Some newer products release less fluoride than conventional GIC.
- Opaque which makes glass ionomer cement less esthetic than composites.
- Not inherently radiopaque.
- Require moisture control during manipulation and placement.

### PROPERTIES OF GLASS IONOMER CEMENT

#### Physical Properties

- Glass ionomer cements have high compressive strength, but low fracture toughness, flexure strength, high modulus of elasticity and wear resistance, thus we can mark them as hard but brittle material. Because of this nature, glass ionomer cements should not be used in high stress bearing areas.
- Modified GICs like cermet cements have more strength but their fracture resistance remains low.
- The resin modified glass ionomers have more flexural and tensile strength and lower modulus of elasticity when compared to conventional glass ionomer cements. This makes them more resistant to fracture but their wear resistance is still not improved much.

#### Biocompatibility

Glass ionomer cements are considered as biocompatible dental materials because of following reasons:

- Polyacrylic acid present in the liquid is a weak acid
- Dissociated hydrogen ions present in GIC are further bound to the polymer chains electrostatically.
- The long polymer chains tangle on one another, this prevents their penetration into the dentin tubules.

#### Water Sensitivity

Conventional glass ionomer cement is very sensitive to moisture contamination during the initial stage of setting reaction and to desiccation when the cement begins to harden (Fig. 8.21).

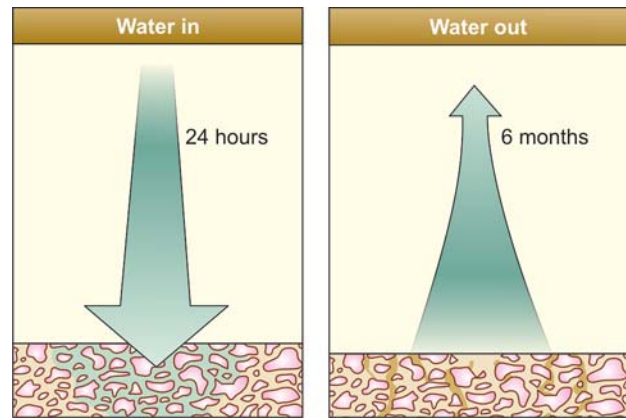


Fig. 8.21: GIC shows sensitivity to water uptake and loss during initial setting stage. This may affect its physical properties

- If moisture contamination occurs in first 24 hours of setting, calcium and aluminum ions leach out of the cement, thus they are prevented from forming polycarboxylates. This results in formation of chalky and eroded rough surface of restoration with low surface hardness.
- If early desiccation occurs during initial setting of the cement, it retards the setting reaction since water plays an important role in setting reaction.
- If desiccation occurs in later stages, it prevents increase in strength of the cement because hydration of the silica based hydrogel and the polycarboxylates cannot occur. It can also result in crazing, decreased esthetics and early deterioration of the cement.

Therefore, one should always apply a low viscosity bonding resin, varnish or vaseline as a protective agent as soon as possible following cement placement to prevent both moisture contamination and desiccation across the surface of the GIC.

#### Adhesion

- Glass ionomer cements are known chemical adhesives to tooth structure. The exact mechanism by which glass ionomer cements bond to tooth structure is not known, though it is said that chelation between the carboxyl groups of the cement and calcium of the tooth structure is responsible for their bonding.
- According to Wilson, adhesion of the glass ionomer cement is due to displacement of calcium and phosphate ions of the tooth structure because of the action of the carboxylate ions of cement. This results in formation of an intermediate aluminum and calcium phosphate layer which forms bond at the tooth/cement interface (Figs 8.22 and 8.23).

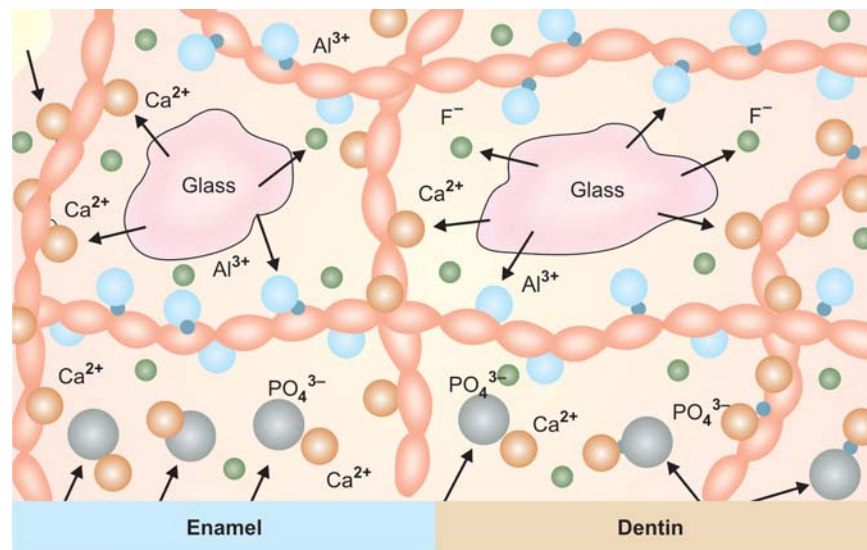


Fig. 8.22: Chemical adhesion of GIC to tooth structure

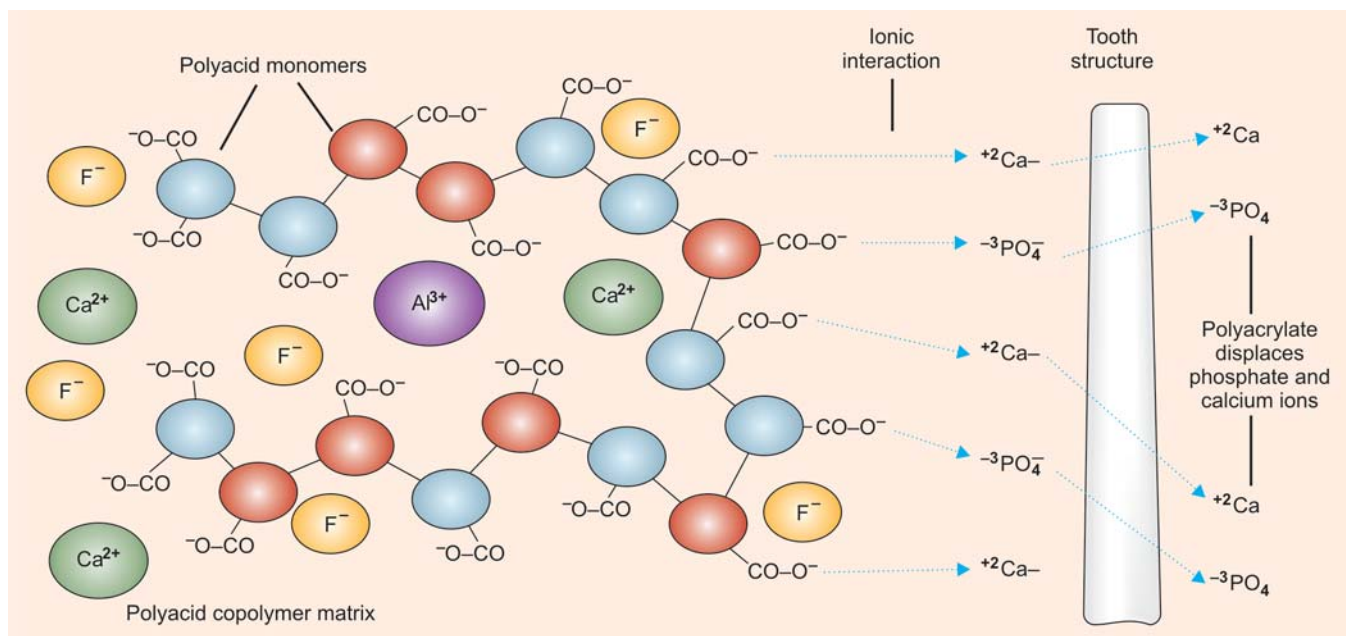
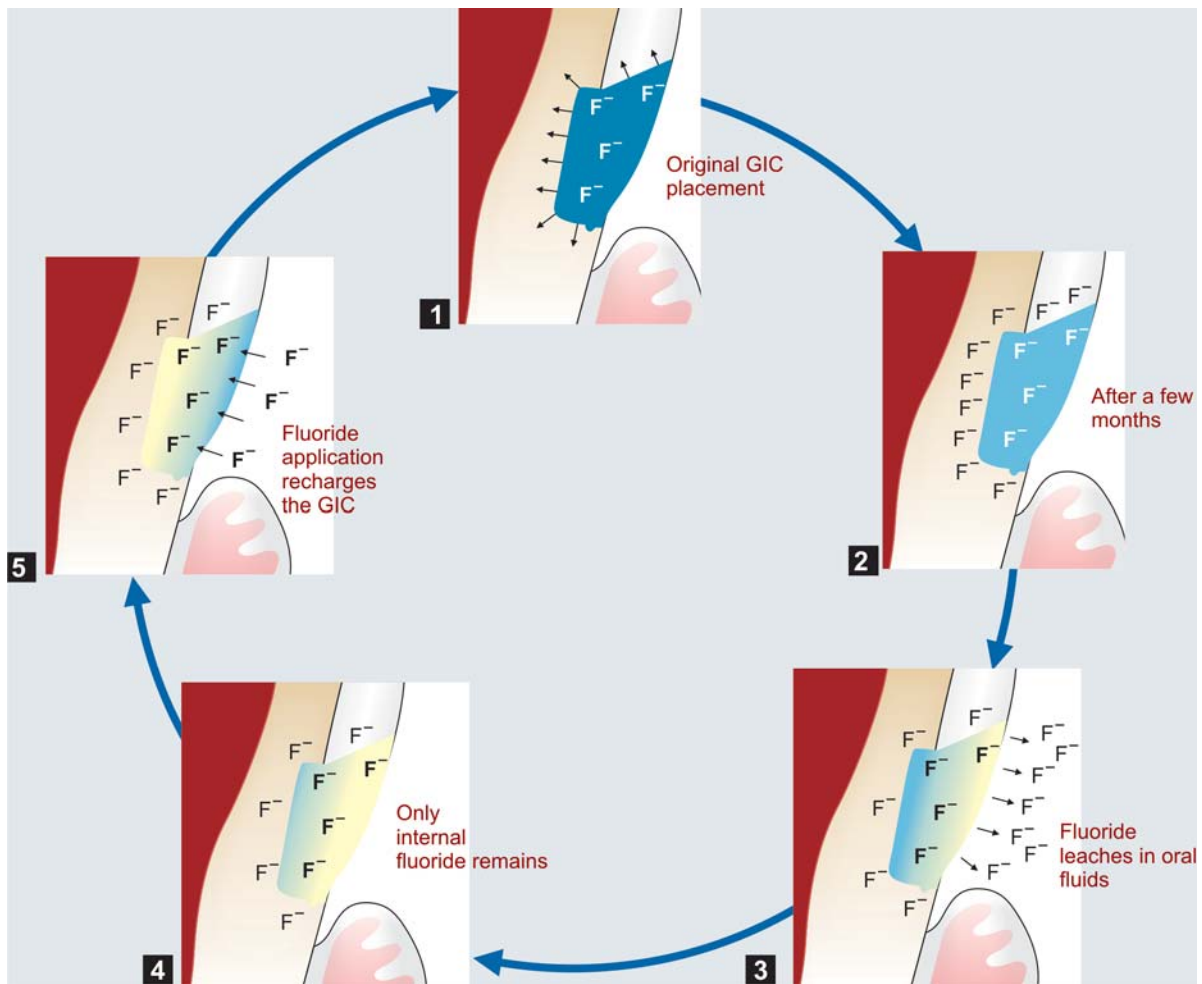


Fig. 8.23: Diagrammatic representation of adhesion between GIC and tooth structure

- Since enamel has higher percentage of inorganic content, bonding of GIC to enamel is stronger than to dentin.
- Though glass ionomer cement can bond directly to enamel and dentin even in the presence of a smear layer, but it has been shown that removal of smear layer results in better bonding. It is always preferred to condition the tooth surface before bonding for improving bonding of GIC. Conditioning of tooth causes improved bonding because of following reasons:
  - It removes the smear layer, thus GIC can wet the dentin surface better.
  - There is direct bond between the tooth and the cement, not with the smear layer.
  - Conditioning also helps in ion exchange and increases surface energy which further increases the bonding. Commonly used conditioner for glass ionomer cement is polyacrylic acid (10 to 25%) applied for 10 to 15 seconds.

### Fluoride Release

- It has been shown in many studies that GICs contain fluoride in 10 to 23% concentration. This fluoride lies free in the matrix and it is released from the glass powder at the time of mixing.



**Fig. 8.24:** Diagram showing reservoir effect of glass ionomers; (1) Fluoride ions leach out from GIC into tooth, (2) Balance of fluoride between tooth and restoration, (3) Fluoride enters in saliva, (4) Both tooth and restoration are short of fluoride, (5) Topical application of fluoride replenish the cement

- When the powder and liquid of GIC are mixed, the setting reaction is initiated, in which the fluoride ions are released from the powder along with calcium, aluminium and sodium ions to build up the cement matrix as ions, salt compounds etc. which later on deliver the fluoride from the set cement.
- The pattern of fluoride release by GIC is that it tends to peak in first 24 hours after the mixing, after this rate of release of fluoride decreases over many weeks and finally it stabilizes at a constant level in 3-4 months.
- In fresh GIC, the fluoride content is much more than that of tooth. This causes diffusion of fluoride from GIC to the tooth forming fluoroapatite crystals. This helps the tooth to resist development of caries.

Studies have shown that GICs can act as rechargeable, fluoride releasing systems. It has been seen that application of topical fluorides help in recharging the glass ionomers with fluorides. This capacity of glass ionomers to recharge

with fluoride is called **reservoir effect**. These recharged glass ionomers release fluorides from the reservoir and when this is depleted, it can be recharged again with topical application of fluorides (**Fig. 8.24**).

### Esthetics

In glass ionomer cements, the translucency gets better over the first 24 hours. These cements have shown good color stability.

Though glass ionomer cements are reasonably tooth-colored and available in different shades (formed by addition of pigments like metal oxides, ferric oxide), they are still considered inferior to composites.

### Margin Adaptation and Leakage

Coefficient of thermal expansion of glass ionomer cement is almost similar to that of tooth, this is responsible for good marginal adaptation of glass ionomer restorations.

## Radiopacity

Conventional glass ionomer cements are radiolucent, but metal modified and RMGIs are radiopaque because of presence of silver and heavy metal salts respectively.

The tooth surface well and bond strength will be reduced.

## RESIN CEMENTS (FIG. 8.25)

These cements have been available since 1952 for cementation of inlays, crowns and other appliances. To achieve high bond strength, these cements depend on acid etch technique with dentin conditioning, similar to composite restorations. Resin cements are marketed under different commercial names by manufacturers: Panavia Ex, Rely X, ARC–Resin cements, Scotch bond resin cement, Porcelite dual cure, etc.

## Uses

1. For cementation of inlays/onlays
  - a. Metal
  - b. Porcelain
  - c. Precured composite.
2. For cementation of crown and bridge.
3. For bonding amalgam restorations.
4. For cementation of orthodontic brackets.
5. For cementation of endodontic posts.

## Types of Resin Cements

1. Unfilled resin cements.
2. Filled resin cements.



Fig. 8.25: Resin cement

Available in the form of:

1. Powder and liquid system.
2. Dual cure—two paste system.
3. Supplied as single paste with accelerator in bonding agent.

## Composition

1. **Unfilled resin cements:** It is not used nowadays. It is based on methyl methacrylate and co-monomers. Accelerator and initiator are tertiary amine and peroxide setting reaction is accomplished by liberation of heat and shrinkage of polymer.
2. **Filled resin cements:** These are almost identical to resin based composite restorative materials.

## Powder

1. **Resin matrix:**
  - a. BISGMA
  - b. TEGDMA
2. **Inorganic filler:**
  - a. Colloidal silica
  - b. Zirconia filler
3. **Coupling agent**—Organosilane
4. **Chemical/photoinitiators and activators:** For improving the rheology of material and handling.

## Liquid

1. Adhesive monomer
  - a. HEMA
  - b. 4-META
  - c. MDP (10-metha)
2. Initiator—Benzoyl peroxide
3. Inorganic fillers
  - a. Zirconia
  - b. Silica

Polymerization can be achieved by any means: Polymerization can be achieved by any means:

1. Conventional chemical cure system
2. Light activation
3. Dual cure system.

## Technique for Using Resin Cements

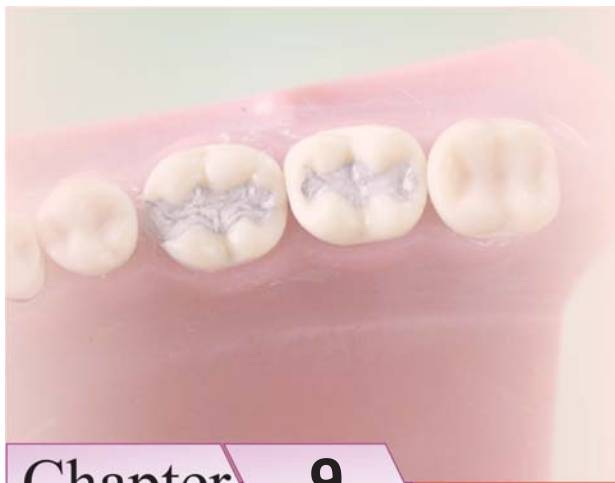1. Isolate the area, preferably with rubber dam.
2. Apply etchant, wait for 15 seconds, rinse for 10 seconds with distilled water. Remove excess water, leaving tooth surface moist.
3. Apply adhesive to enamel and dentin, dry for 5 seconds and light cure for 10 seconds.

4. Roughen the bonding surface of restoration using air abrasion/diamond. In case of ceramic, apply ceramic primer such as organosilanes to etched porcelain and roughened metal surfaces. Dry for 5 seconds.
5. Dispense appropriate amount of cement on mixing pad and mix for 10 seconds.
6. Apply thin layer of cement on bonding surface of restoration.
7. Seat the restoration, remove excess of cement and light cure for 40 seconds.

### VIVA QUESTIONS

- Q. Define cement.
- Q. How can you classify cements?
- Q. What is composition of zinc phosphate cement?
- Q. What are uses of dental cements?
- Q. What are uses of zinc phosphate cement?
- Q. Discuss biocompatibility of zinc phosphate cement.
- Q. What is composition of zinc polycarboxylate cement?
- Q. What is pseudoplasticity? What is its significance?
- Q. What are uses of zinc polycarboxylate cement?
- Q. Discuss biocompatibility of zinc polycarboxylate cement.
- Q. When should we remove excess zinc polycarboxylate cement while luting?
- Q. What is GIC?
- Q. Classify zinc phosphate cement.
- Q. Classify glass ionomer cement.
- Q. What is composition of glass ionomer cement?
- Q. What are advantages of GIC?
- Q. Discuss anticariogenicity of GIC.
- Q. How does GIC bond to tooth structure?
- Q. What is setting reaction of GIC?
- Q. What is resin modified glass ionomer cement?
- Q. What are advantages of RMGI?
- Q. What is composition of zinc oxide eugenol cement?
- Q. Classify ZOE cement.
- Q. What are uses of ZOE?
- Q. What is EBA?
- Q. What is modified ZOE?
- Q. How does setting of ZOE take place?
- Q. What are effects of EBA on eugenol cement?
- Q. How do you manipulate ZOE cement?
- Q. How do you manipulate zinc phosphate cement?
- Q. What is composition of zinc oxide eugenol cement?
- Q. How do you manipulate zinc oxide eugenol cement?
- Q. What are uses of zinc oxide eugenol cement?
- Q. What is setting reaction of zinc oxide eugenol cement?
- Q. What is reinforced zinc oxide eugenol cement?
- Q. What is EBA?
- Q. What is setting reaction of zinc phosphate cement?
- Q. Classify zinc phosphate cement.
- Q. Why do you use cool glass slab for cement mixing?
- Q. What are synonyms of GIC?
- Q. What is composition of resin modified glass ionomer?
- Q. What is cermet?
- Q. What is miracle mix?
- Q. GIC is mixture of which two cements?
- Q. What is composition of zinc polycarboxylate cement?
- Q. What are advantages of RMGI?
- Q. Why do we divide zinc phosphate cement in 5-8 increments?
- Q. Why liquid bottle is kept vertical while dispensing?





# Dental Amalgam

## Chapter 9

### INTRODUCTION

#### COMPOSITION OF AMALGAM POWDER

#### COMPOSITION OF AMALGAM ALLOYS

- Effects of Constituent Metals on the Properties of Amalgam
- Proportioning

#### CLASSIFICATION OF AMALGAM

- Generations of Dental Amalgam
- Difference between High Copper and Low Copper Alloys

#### SETTING REACTION OF AMALGAM

#### ADVANTAGES OF SILVER AMALGAM

#### DISADVANTAGES OF SILVER AMALGAM

#### INDICATIONS OF AMALGAM RESTORATION

#### CONTRAINDICATIONS OF AMALGAM RESTORATION

#### TYPES OF AMALGAM POWDER

#### PHYSICAL PROPERTIES OF AMALGAM

- Dimensional Change
- Strength
- Plastic Deformation (Creep)
- Corrosion
- Biocompatibility
- Thermal Conductivity
- Coefficient of Thermal Expansion
- Microleakage in Amalgam

### RECENT ADVANCES IN AMALGAM

- Mercury-free Direct Filling Alloy
- Low Mercury Alloy
- Bonded Amalgam System
- Gallium in Place of Mercury in Amalgam
- Consolidated Silver Alloy

### STEPS OF AMALGAM RESTORATION

- Selection of Amalgam Alloy
- Mercury Alloy Ratio
- Trituration
- Mulling
- Application of Matrix Band
- Insertion of Amalgam
- Condensation
- Burnishing
- Carving
- Finishing and Polishing

### FAILURES OF AMALGAM RESTORATIONS

- Reasons for Failure of Amalgam Restorations

### MERCURY HYGIENE

- History of Conflicts regarding Amalgam Use
- Forms of Mercury
- Mercury Exposure in Dental Office
- Mercury Toxicity

### INTRODUCTION

The first form of silver mercury mixture was given by M Taveau in 1826 at Paris. Crawcour brothers in US introduced dental amalgam to the dentistry in 1833. Since 1850, dental amalgam has been used more than any other restorative material. The dental amalgam alloys consist of silver and other alloys like tin, copper and smaller amounts of zinc which are mixed with mercury.

#### Historical development of amalgam

1650	Stocker	Copper amalgam
1818	Dr Louis Regnard	Father of amalgam
1959	Dr Wilmer Eames	1:1 ratio of mercury: alloy
1963	Innes and Youdelis	High copper alloy (Admixed type)
1974	Asgar	Single composition high copper alloy
1980	Showell	Amalgapin

**Alloy:** Alloy is a union of two or more metals

**Amalgam:** Amalgam is an alloy in which mercury occurs as a main constituent.

**Dental amalgam:** The dental amalgam is an alloy of mercury with silver, tin, and varying amounts of copper, zinc and other minor constituents.

### COMPOSITION OF AMALGAM POWDER

Amalgam consists of amalgam alloy and mercury. Amalgam alloy is composed of silver-tin alloy with varying amounts of copper, zinc, indium and palladium (**Fig. 9.1**). Dental amalgam alloys are mainly of two types—low copper and high copper alloys.

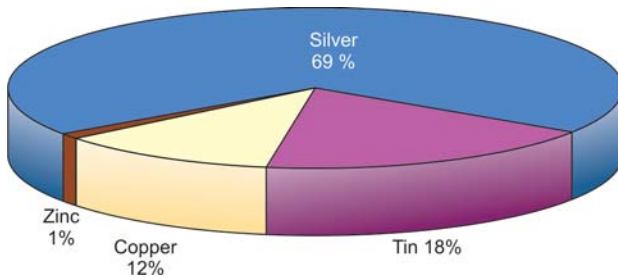
Low copper alloys contain up to 6% by weight of copper. In high copper alloys, copper content lies between 6-30%.

In general, amalgam alloy consists of silver 40% minimum, tin 32% maximum, copper 30% maximum, zinc 2% maximum, and sometimes traces of indium or palladium. In preamalgamated alloys, mercury 3% is used which react more rapidly when mixed with mercury. Mercury used for dental amalgam is purified by distillation.

#### Effects of Constituent Metals on the Properties of Amalgam

**Silver:** It has the following effects on the properties of amalgam.

- Increases strength



**Fig. 9.1:** Composition of amalgam powder

- Increases setting expansion
- Reduces setting time
- Resists tarnish and corrosion
- Decreases flow.

**Tin:** Tin helps in formation of a silver/tin compound (Ag<sub>2</sub>Sn). This is the gamma phase which readily undergoes an amalgamation reaction with mercury. Tin causes following effects:

- Increases setting time
- Reduces strength, hardness, and setting expansion.

**Copper:** It has the following effects on the properties of amalgam:

- Reduces tarnish and corrosion
- Reduces creep
- Strengthening effect on the set amalgam
- Helps in uniform comminution of the alloy.

**Zinc:** Its presence is not essential. It may vary from 0 to 2% by weight. It has the following effects on the properties of amalgam:

- Scavenges the available oxygen to impede oxidization of Ag, Sn or Cu during alloy ingot manufacture.
- If zinc-containing alloys are contaminated with moisture, Zn gives rise to delayed or secondary expansion.

**Palladium (0 to 1% by weight)**

- Improves the corrosion resistance and the mechanical properties.

**Indium (0 to 4% by weight)**

- It decreases the evaporation of mercury and the amount of mercury required to wet the alloy particles.

#### Proportioning

Usually Alloy/mercury ratios range between 5 : 8 and 10 : 8. But to achieve optimum properties of the amalgam, mercury should be less than 50%. For lathe cut alloys, it is 45%. For spherical alloys, it is 40% Hg.

### COMPOSITION OF AMALGAM ALLOYS (TABLE 9.1)

**Table 9.1:** Percentage of elements by weight

Alloy	Particle	Silver	Tin	Copper	Zinc	Palladium	Indium
1. Low copper	Lathe cut or Spherical	65 to 77	26 to 28	2 to 5	0 to 2	0	0
2. High copper							
a. Admixed	Lathe cut	40 to 70	26 to 30	13 to 30	0 to 1	0	0
	Spherical	40 to 70	0 to 30	20 to 30	0	0	0
b. Unicompositional	Spherical	40 to 60	22 to 30	15 to 30	0 to 1	0 to 4	0

## CLASSIFICATION OF AMALGAM

There are different ways of classifying amalgam alloys. These are:

1. **Based on shape of particles**
  - a. *Irregular*: In this, shape of particles is irregular, may be in the shape of spindles or shavings.
  - b. *Spherical*: In this, shape of particle is spherical with smooth surface.
  - c. *Spheroidal*: In this, shape of particle is spheroidal with irregular surface.
2. **Based on copper content**
  - a. *Low copper alloy*: Copper is in range of 2-6%
  - b. *High copper alloy*: Copper is in range of 6-30%
3. **Based on zinc content**
  - a. *Zinc-containing alloys*: Zinc is in range of 0.01-1%
  - b. *Zinc-free alloys*: Zinc is in range of < 0.01%
4. **Based on the presence of noble metals**
  - a. *Binary alloys*: Contain 2 metals, i.e. silver and tin.
  - b. *Ternary alloys*: Contain 3 metals, i.e. silver, tin and copper.
  - c. *Quaternary alloys*: Contain 4 metals, i.e. silver, tin, copper and zinc.

Out of these, quaternary alloys are most acceptable.

### Generations of Dental Amalgam

Class-I	Silver and tin in ratio (8:1)
Class-II	Silver, tin, copper (4%), zinc
Class-III	Silver eutectic alloy added to original alloy
Class-IV	Copper content increased to 29%
Class-V	Indium added to mixture of silver, tin and copper
Class-VI	Noble metals added such as palladium

### Difference between High Copper and Low Copper Alloys

	High copper alloys	Low copper alloys
1. Copper content	6-30%	<6%
2. Mercury required for amalgamation	Less	More
3. Setting reaction	Fast setting	Slow setting
4. Amalgamation speed and energy	Require high-speed and energy for amalgamation since copper has low solubility in mercury	Require less speed and low energy for amalgamation
5. Dormant phase	It is $\text{Cu}_6\text{Sn}_5$ , i.e. $\eta$ phase	It is $\text{Ag}_2\text{Hg}_3$ , i.e. $\gamma_1$ phase

Contd...

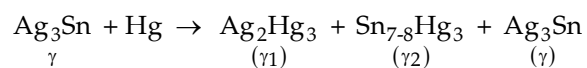
Contd...

	High copper alloys	Low copper alloys
6. Tarnish and corrosion	It is due to copper rich phase, i.e. $\text{Cu}_6\text{Sn}_5$ .	It is due to gamma 2 phase, i.e. $\text{Sn}_{7-8}\text{Hg}_3$
7. Creep	Less creep (<1%)	More creep (1-8%)
8. Compressive strength	High (250-500 Mpa)	Low (150-350 Mpa)
9. Dimensional change	Less (1-9 $\mu\text{m}/\text{cm}$ )	More (10-20 $\mu\text{m}/\text{cm}$ )

### SETTING REACTION OF AMALGAM

#### For Lathe Cut Low Copper Alloys

On mixing amalgam alloy with mercury, the alloy particles get dissolved in the mercury. In the initial reaction, mercury reacts with tin and silver without involving copper and zinc. Mercury reacts with alloy particles to form two products, i.e. the silver mercury phase and tin mercury phase. After this reaction, the unreacted particles are embedded in the matrix of reaction products with mercury. The reaction is as follows:



In lathe-cut low copper amalgams both  $\gamma_1$  and  $\gamma_2$  form a continuous network. Since  $\gamma_2$  phase is least corrosion-resistant phase, its distribution in reaction product is important.

#### For Admixed High Copper Alloys

For high copper alloys, the reaction is different. It occurs in two phases. The initial reaction is similar to that of low copper alloys, i.e.

The second phase of reaction involves the silver copper phase (Ag-Cu).

It reacts with  $\gamma$  ( $\text{Ag}_3\text{Sn}$ ) and mercury to form  $\text{Ag}_2\text{Hg}_3$ ,  $\text{Sn}_{7-8}\text{Hg}$  and  $\text{Cu}_6\text{Sn}_5$  phase. The mercury released from  $\text{Sn}_{7-8}\text{Hg}$  ( $\gamma_2$  phase) reacts with silver to form  $\text{Ag}_2\text{Hg}_5$  ( $\gamma_1$ ) phase.

This reaction goes on. After one week, the  $\gamma_2$  phase reacts completely with eutectic and replace all the  $\gamma_2$  phase by  $\gamma$  and  $\gamma_1$  phase.

#### For Unicompositional Silver Alloy

The difference in admix type and the unicompositional alloys is that in latter the eutectic phase, i.e. Ag-Cu phase is absent. In these only silver reacts with mercury and the tin remains bound to copper.

The final phase formed is  $\text{Cu}_6\text{Sn}_5$  ( $\gamma$ ) phase and there is no  $\text{Ag}_2\text{Hg}_3$  ( $\gamma_2$ ) phase.

### ADVANTAGES OF SILVER AMALGAM

- Ease of manipulation
- Satisfactory marginal adaptation
- Wider range of application
- Physical characteristics of amalgam are comparable to enamel and dentin
- Less technique sensitive
- Self-sealing
- Biocompatible
- Good wear resistance
- Low cost
- Can be completed in one dental visit
- Bonded amalgam restorations can also bond to tooth structure.

### DISADVANTAGES OF SILVER AMALGAM

- Less aesthetic
- Extensive preparation to hold an amalgam filling.
- Amalgam fillings can corrode or tarnish over time, causing discoloration.
- Does not bond to tooth.
- Being metallic restoration it is noninsulating
- Marginal degradation is seen in low copper alloys.
- Amalgam is not strong enough to reinforce the weakened tooth structure
- Poor tensile strength making it a brittle material
- Results in galvanic current in association with gold restoration or even in same restoration with nonuniform condensation.
- Oral lichen planus is also seen with amalgam restoration.

### INDICATIONS OF AMALGAM RESTORATION

1. Moderate to large class I preparation.
2. Class II preparations in which there is:
  - Heavy occlusion
  - Extension on the root surface
  - Problem of isolation.

It is indicated in heavy occlusion because amalgam has greater wear resistance than composites. Minor contamination during the amalgam placement has less adverse effects as compared to composite restorations.

3. Class V preparations in which:
  - Aesthetic is not a problem
  - Preparation entirely on root surface
  - Isolation is difficult.

4. Class VI preparations.
5. Class III preparations (sometimes) where isolation is difficult.
6. Used as a foundation in cases of grossly decayed teeth while planning for cast restoration.
7. Used as a postendodontic restoration.
8. Teeth having nondefinitive pulpal prognosis—used as type of interim restoration before assessment of pulpal status of the tooth.
9. Tooth having fractured cusp can be restored with the help of amalgam using pin and slot.

### CONTRAINDICATIONS OF AMALGAM RESTORATION

1. **Esthetics:** Use of amalgam is avoided in aesthetic areas of oral cavity. So, preparations class III, IV, V usually are not indicated except in certain cases.
2. Small to moderate class I and class II preparations should be restored with composite rather than amalgam as former results in more conservative tooth preparation.

#### Indications

- Moderate to large class I and II preparations
- Class V preparations (some cases)
- Class VI preparation
- Class III preparation (some cases)
- Used as foundation
- Used as postendodontic filling
- Tooth having nondefinitive pulpal prognosis
- Tooth having fractured cusp

#### Contraindications

- When esthetics is the prime concern
- Small to moderate class I and class II preparations

#### Phases of silver amalgam

Code	Component
( $\gamma$ ) gamma	$\text{Ag}_3\text{Sn}$
( $\gamma_1$ ) gamma 1	$\text{Ag}_2\text{Hg}_3$
( $\gamma_2$ ) gamma 2	$\text{Sn}_{7-8}\text{Hg}_3$
( $\epsilon$ ) epsilon	$\text{Cu}_3\text{Sn}$
( $\eta$ ) eta	$\text{Cu}_6\text{Sn}_5$

### TYPES OF AMALGAM POWDER

**Lathe cut** is made by cutting fillings of alloy from a prehomogenized ingot which was heat treated at  $420^\circ\text{C}$  for many hours. The fillings are then reheated at  $100^\circ\text{C}$  for 1 hour for aging of the alloy.

**Spherical (spheroidal) alloy** is formed when molten alloy is sprayed into a column filled with inert gas, this molten metal solidifies as fine droplets of alloy.

**Admixed alloy** is that when different size or shape of amalgam powder is mixed together to increase filling efficiency.

**Single composition** is that alloy in which every particle of alloy is having same shape, size and composition.

**Dispersion modified, high copper alloy** is that in which high copper alloy is mixed with conventional alloy.

## PHYSICAL PROPERTIES OF AMALGAM

### Dimensional Change

Small amount of contraction occurs in the first half an hour after trituration because mercury diffuses into the silver and tin and the mix dissolves in the mercury. After this, expansion occurs because of crystallization of the new phases. According to ADA specification no. 1 dimensional change should be limited to 20 microns/cm measured between 5 minutes and 24 hours after trituration.

#### *Factors affecting Dimensional Changes of Amalgam*

- Type of alloy being used, for example, single composition spherical alloys contract more than single composition lathe-cut or admixed alloys.
- Condensation technique, i.e. more mercury removed from the alloy, the more it will contract.
- Trituration time, overtrituration causes contraction.
- Presence of zinc can result in delayed expansion after 3-5 days of restoration, if during condensation or trituration, zinc-containing amalgam comes in contact with moisture or saliva. This occurs due to formation of zinc oxide and hydrogen gas when zinc react with water. This expansion can result in extrusion of restoration beyond preparation margins and pulpal pain.

### Strength

- Strength of amalgam develops slowly. It takes 24 hours to reach maximum. In first hour, only 40 to 60% of its maximum compressive strength is achieved.
- According to ADA specification no. 1, amalgam should have minimum 1 hour compressive strength of 11,600 psi (80 MPa).
- Amalgam has much higher compressive strength than tensile or shear strength making it brittle material.
- Compressive strength of amalgam is seven times more than that of its tensile strength. Being a brittle material,

it is weak in thin sections, thus unsupported edges of restoration fracture frequently. To avoid this, a 90° butt joint angle of amalgam is required at the margins.

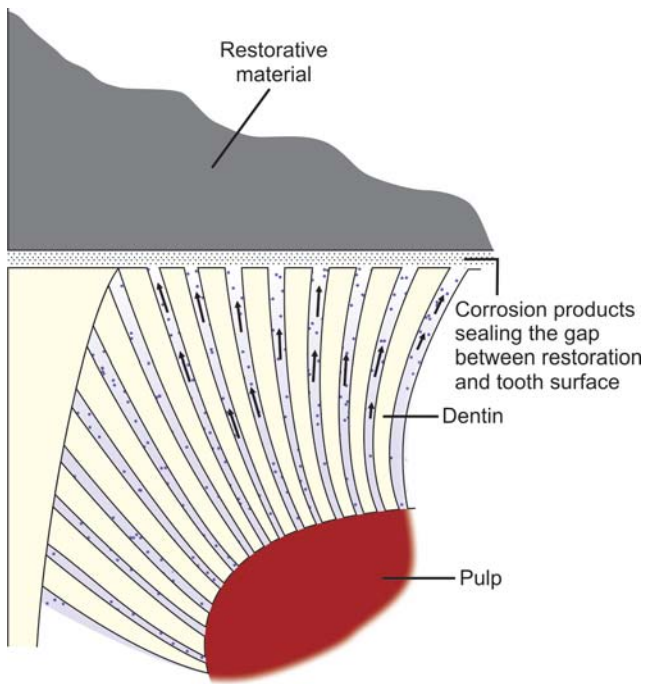
- Spherical alloys are harder and stronger when compared to lathe-cut alloys because they require less mercury during trituration, thus less of the weak matrix portion forms.

### Plastic Deformation (Creep)

- Creep is the time-dependent response of an already set material to stress. This response is in form of plastic deformation. It can be of two types depending on the stresses involved, viz. static and dynamic.
- By ADA specification no. 1, creep is limited to 3% in a set amalgam.
- Creep/flow usually occurs near the melting temperature of the material. In amalgam, creep happens because gamma 1 is a fine grained structure, also these particles “slide” across each other resulting in slipping of grain boundaries.
- Creep is unfavorable to amalgam because it causes amalgam to flow out over margins where the thin amalgam fractures. This results in marginal deterioration.
- **Factors affecting creep:**
  - Low copper alloys have higher creep than high copper alloys because in latter copper binds tin and forms eta phase, and this prevents formation of gamma 2 phase. Crystals of eta phase interlock and check slippage at gamma 1 grain boundaries, resulting in less creep.
  - Higher the residual mercury levels, more is the creep.
  - Increased condensation pressure reduces creep because it reduces residual mercury level.
  - Marginal areas show more creep because they have higher levels of residual mercury.
  - A delay between trituration and condensation increases creep.

### Corrosion

- Amalgam restoration shows corrosion and tarnish over a period of time. Though corrosion causes decrease in strength of a restoration by 50% in five years, the advantageous fact of corrosion is that the byproducts that form, act to seal the preparation margin, responsible for self-sealing feature of amalgam (**Fig. 9.2**).
- In low copper amalgams, the most corrosion-prone phase is gamma 2 ( $\text{Sn}_{7.8}\text{Hg}_3$ ) phase. In these alloys, corrosion products are tin oxides and tin chlorides. Here the corrosion proceeds from outer surface to interior of restoration making it porous and spongy.



**Fig. 9.2:** Sealing of restorative margins because of corrosion products of amalgam

- In high copper amalgams, corrosion products are similar to that of low copper alloys, in addition there is formation of copper chloride which corrode slower than low copper amalgams. High copper alloys corrode slower because they contain little or none of gamma 2 phase. Also the corrosion is not of penetrating type as in low copper alloys. In high copper alloys, the most corrosion-prone phase is the eta phase.

### Biocompatibility

Though there has been great debate related to mercury toxicity, yet if careful handling of mercury is taken, amalgam proves to be a biocompatible material.

### Thermal Conductivity

Because of good thermal conductivity, amalgam can transmit temperature changes readily to the pulp. Hence, its closeness to pulp should be avoided without adequate pulp protection.

### Coefficient of Thermal Expansion

It is three times more in amalgam than that of dentin. This large difference is responsible for microleakage.

### Microleakage in Amalgam

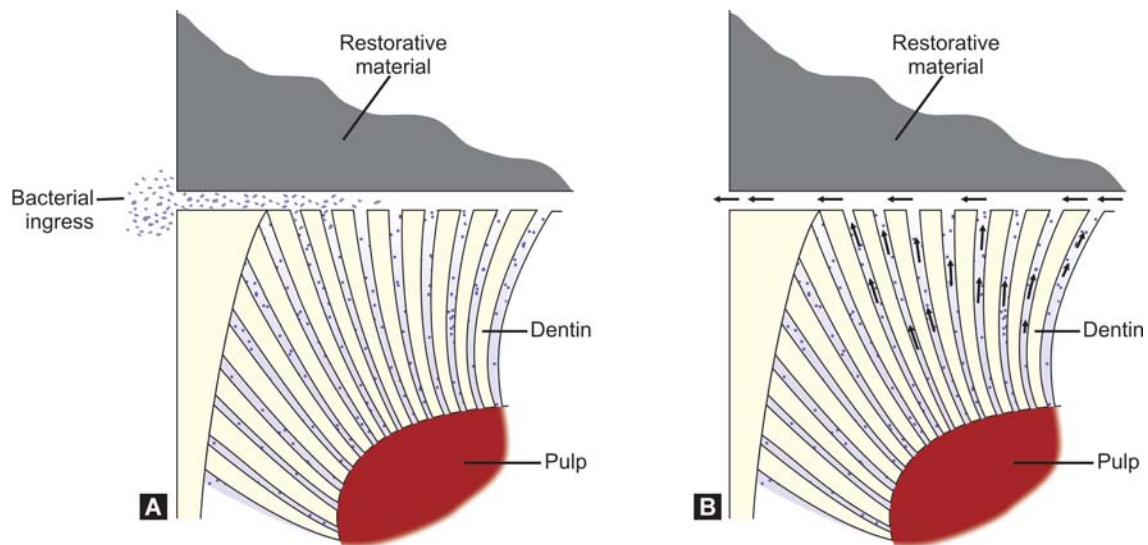
Microleakage occurs when there is 2 to 20 micron wide gap between the amalgam and tooth structure.

Following factors are responsible for microleakage in amalgam:

- Poor condensation techniques that cause marginal voids.
- Lack of corrosion byproducts which are necessary for sealing of margins.
- High coefficient of thermal expansion of amalgam.
- Use of single composition spherical alloys which show more leakage than lathe-cut or admixed alloys.

### Microleakage can lead to (Figs 9.3A and B):

- Pulpal inflammation
- Tooth discoloration
- Postoperative sensitivity
- Restoration failure



**Figs 9.3A and B:** (A) Bacteria can pass into the marginal gap causing pulpal inflammation, (B) The dentinal fluid can come out of the marginal gap causing pain and sensitivity

## RECENT ADVANCES IN AMALGAM

### Mercury-free Direct Filling Alloy

The American Dental Association, in combination with National Institute on Standard and Technology (ADA-NIST) has patented a mercury-free direct filling alloy which is based on Ag-coated Ag-Sn particles that can be self-welded by compaction to create a restoration. To keep the surface of alloy particles clean, a fluoroboric acid solution is used. These alloys can be condensed in the same manner as direct filling gold restoration.

### Low Mercury Alloy

In this approach, alloy particles are carefully selected so that they can pack together well. Then it is possible to reduce the mercury content for mixing to the 15-25% range. However, the clinical properties of these alloys are not yet known.

### Bonded Amalgam System

One of the major disadvantages of the amalgam is that it does not adhere to the preparation walls. To conquer this problem, bonding systems to bond the amalgam to tooth structure have been developed. In the bonded amalgam technique, a dentin bonding system is used along with a viscous resin liner which physically mixes with the amalgam and forms a micromechanical union to increase amalgam's retention to tooth structure.

Since amalgam is hydrophobic, and tooth is hydrophilic, therefore, to achieve optimal wetting, bonding systems must have dual properties. For this monomer molecule having hydrophilic and hydrophobic ends of 4-methoxy ethyl trimellitic anhydride (4-META) based systems are used.

### Indications of Bonding

- When remaining tooth structure, after tooth preparation is weak.
- In extensively carious posterior teeth where it acts as cost effective alternate for cast metal and metal ceramic restorations.
- In cases with deep bite where short clinical crown is present, here pin-retained restorations are not possible. In these cases, bonding provides auxiliary retention.
- As core for foundation of cast crown restoration.

### Advantages of Using Bonded Amalgam System

- Adequate dentin sealing
- Increased resistance form

- Increased retention
- Conservative tooth preparation
- Improved marginal seal
- Elimination of use of retention pins and other modes of retention.
- Reduction in microleakage, secondary caries and postoperative sensitivity.
- Cost effective for extensively carious tooth
- Can be done in single appointment.

### Limitations of Amalgam Bonding

- Reduction in bond strength over years because of repeated thermocycling in the oral cavity.
- Technique sensitive system, amalgam must be condensed over wet adhesive resin.
- Expensive than nonbonded amalgam restoration.

### Technique of Bonded Amalgam

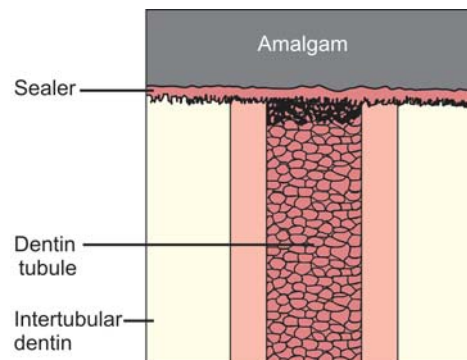
#### **Bonding agents used in amalgam bonding system:**

Although many products are available for adhesion to enamel and dentin, most of these are meant for use with resin composites. Some of them have metal bonding capabilities thus can be used for amalgam bonding. These are Amalgambond Plus with HPA (High Performance Additive) powder (Parkell), Optibond 2 (Kerr), All Bond 2 (Bisco), Panavia EX and Panavia 21 (Kuraray).

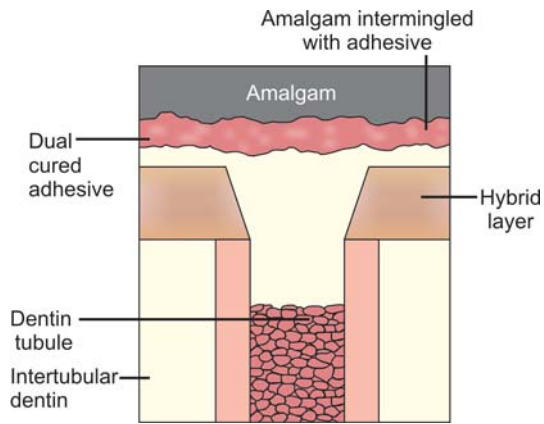
**Bonding interface (Figs 9.4 and 9.5):** The bonding interface constitutes tooth, amalgam and adhesive resin present in between them.

The bonding interface may consist of the following:

1. Tag formation
2. Precipitates on pretreated dentin surfaces to which adhesive resin binds mechanically or chemically.
3. Formation of hybrid layer of reinforced dentin.



**Fig. 9.4:** Bonding interface of amalgam and tooth: Conventional amalgam restoration



**Fig. 9.5:** Bonding interface of amalgam and tooth in bonded amalgam restoration

4. Chemical binding to the inorganic and organic components of dentin and enamel.

#### **Technique of placing bonded amalgam**

- Isolate the tooth with rubber dam.
- Do the conservative preparation, i.e. conventional retention and resistance forms are not strictly followed. Remove all the carious portion and unsupported enamel rods.
- In deep preparation, protect the pulp with suitable liner and base.
- Place matrix and wedges properly.
- Etch the enamel and dentin walls of the preparation with 10% citric or phosphoric acid gel for 15-20 seconds. Wash and dry the preparation.
- Apply adhesive primer to the conditioned dentin and then evenly apply dentin bonding agent.
- Before the bonding agent is dried, condense freshly triturated high copper amalgam into the preparation.
- Carve, finish and polish the final restoration as usual.

#### **Future of Bonded Amalgam Restoration**

Bonded amalgam restoration has advantages of conservative tooth preparation, good qualities of amalgam, better marginal seal along with improved retention and resistance.

But since, there are very few comparative studies done on bonded amalgam restorations, exact conclusion cannot be made about their prognosis and future use. However, most of the workers have good hope about their future and expect that very soon bonded amalgam fillings may be routinely used in place of conventional unbonded amalgam fillings.

#### **Gallium in Place of Mercury in Amalgam**

To conquer the harmful effects of mercury, gallium metal which has second lowest melting point (next to mercury)

has been tried in mercury-free amalgam restoration. Use of alternative containing gallium, instead of mercury, was first suggested in 1928 in Germany.

#### **Advantages of Gallium Amalgam**

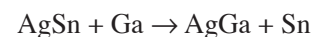
- Gallium amalgam can be manipulated with same instruments used for silver amalgam.
- Its strength is almost equal to silver mercury amalgam, and like latter its strength also increases with time.
- The creep resistance complies with ISO requirements.
- Since gallium amalgam expands after trituration, it provides better marginal seal than silver amalgam.
- Setting time is less than silver mercury amalgam, therefore, can be finished and polished after one hour.
- Most of the physical and mechanical properties of gallium alloy are similar to high copper mercury amalgam.

#### **Disadvantages**

- Corrosion resistance of gallium amalgam is very low.
- Handling of gallium alloys is difficult because they have tendency to stick to the instruments. This sticking problem can be reduced by adding a drop of absolute alcohol to the mix before trituration. Alcohol slowly evaporates and thus does not adversely affect the properties of the amalgam.
- Extremely technique sensitive, any moisture contamination during placement results in alloy expansion.
- Shows expansion after setting. Excessive expansion can produce stresses sufficient to crack the tooth.

Composition		
<b>Powder</b>		
• Silver (Ag)	-	55 to 65%
• Tin (Sn)	-	20 to 30%
• Copper (Cu)	-	10 to 16%
• Palladium (Pd)	-	10 to 15%
<b>Liquid</b>		
• Gallium (Ga)	-	57 to 67%
• Indium (In)	-	15 to 25%
• Tin (Sn)	-	15 to 25%

**Setting reaction:** The reaction between powder AgSn particles and liquid gallium results into the formation of AgGa phase and a pure tin phase.



#### **Properties of Gallium Amalgam Restorations**

- **Compressive strength:** Gallium alloys have sufficient strength for small restoration.



- **Setting expansion:** In initial stages, controlled expansion occurs but if contaminated, uncontrolled expansion can result. This excessive expansion can cause cuspal fracture, and postoperative sensitivity.
- **Creep value:** In gallium alloys, creep value is less.
- Gallium amalgam has very high wetting ability, hence the final restoration is highly resistant to microleakage.
- **Time consuming:** Since their handling is difficult because of being sticky, it takes more time for condensation and matrix band has to be removed very carefully to avoid fracture of restoration.
- **Costly:** Gallium amalgam is about 16 times costlier than the silver mercury amalgam.

### Conclusion

Gallium amalgam restorations have been developed in an attempt to provide a mercury-free amalgam restoration. If meticulous attention is paid to moisture control, these restorations can function well for short-time. But since they are prone to tarnish and corrosion, long-term effects are unknown. To prevent excessive expansion, restoration should be sealed with a hydrophobic resin sealant. Since there is demand for less technique sensitive alternative to silver amalgam than resin composite, for difficult and larger posterior situations, gallium alloys do not provide the answer.

### Consolidated Silver Alloy

It is a recently introduced amalgam developed at National Institute of Standards and Technology. It uses fluoroboric acid solution for keeping the surface of silver alloy particles clean. The alloy is condensed in the preparation similar to direct filling gold. The main limitation of using this material is that alloy hardens due to repeated burnishing. This makes it difficult to compact in preparation. For good adaptation of material and to avoid voids in the final restoration, an excessive force is required for compaction.

#### Steps of amalgam restoration

1. Selection of amalgam alloy
2. Mercury alloy ratio
3. Trituration
4. Mulling
5. Application of matrix bond
6. Insertion of amalgam
7. Condensation
8. Burnishing
9. Carving
10. Finishing and polishing

## STEPS OF AMALGAM RESTORATION

### Selection of Amalgam Alloy

Following factors are considered while selecting an alloy for restoration:

- a. **Type of alloy:**
  - High copper or low copper alloys
  - Zinc-free or zinc-containing alloys
  - Size and shape of the particles.
- b. If restoration undergoes high occlusal stresses, choose amalgam with high resistance to marginal fracture.
- c. Patients with psychological problems or other diseases, requiring early disposal, indicate the use of fast setting alloy.
- d. In wider and broader preparations, alloy with low creep values is preferred.
- e. If it is difficult to control moisture, it is preferred to use zinc-free alloy to avoid delayed expansion.

### Mercury Alloy Ratio

For success of the restoration, mercury ratio should be specific and accurate according to type of alloy used. Mercury is basically required to wet the alloy particles before they can react. Eames has preferred 1:1 ratio of alloy/mercury for best results. Generally, it is 5 : 8 or 5 : 7, if mercury content is more than required amount, resultant mix will be weaker, but if it is less, it might not sufficiently wet the alloy particles. Lathe-cut amalgam alloys require more (45%) of mercury to wet than the spherical alloys (40%).

### Trituration

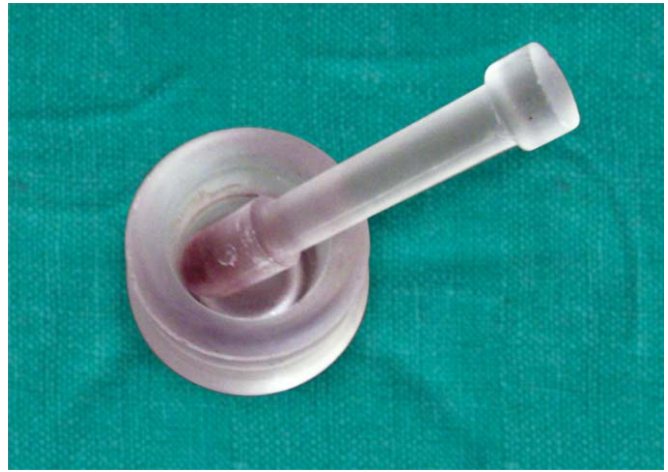The purpose of trituration is to remove oxide layers from the alloy particles so as to coat each alloy particle with mercury, resulting in a homogeneous mass for condensation. Trituration can be done by hand or mechanical means. Mechanical method is done with the help of automatic amalgamator (**Fig. 9.6**) and hand method of trituration is done with the help of mortar and pestle (**Fig. 9.7**).

#### Objectives of trituration

1. Achieve a workable mass of amalgam within minimum time
2. Increase direct contact between the particle and mercury by removing oxides from powder
3. Reduce particle size of powder so that fast and more complete amalgamation can be done
4. Help in dissolving the particles of powder in mercury
5. Reduce the amount of gamma-1 and gamma-2.



**Fig. 9.6:** Amalgamator used for mechanical trituration



**Fig. 9.7:** Mortar pestle used for hand trituration

Time for which the trituration is carried out, speed and force applied for trituration, affect the quality of trituration.

Sign of a good mix amalgam is shiny, homogeneous mass that adheres together (**Fig. 9.8**). Undertrituration results in a crumbly mix that is very weak (**Fig. 9.9**). It causes decrease in the tensile and compressive strength values and increase in creep.

Overtrituration results in a mix that is warm and has a shiny surface. This overtrituated mix sticks to the capsule which is difficult to remove (**Fig. 9.10**). There occurs fast setting because the amalgam mass becomes heated.



**Fig. 9.9:** Undertrituated amalgam mix appears dry and crumbled



**Fig. 9.8:** Properly mixed amalgam should be shiny, cohesive homogeneous mass



**Fig. 9.10:** Overtrituated mix sticks to be capsule which is difficult to remove

Overtrituration causes increase in contraction, creep, tensile and compressive strength values for lathe-cut alloys, decrease in tensile and compressive strengths for spherical alloys.

#### Test for trituration

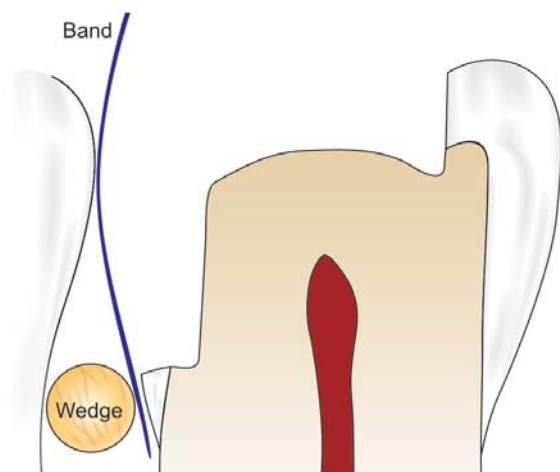
1. Normal trituration
  - Good shiny mix
  - Homogeneous mass, adheres together
2. Overtrituration
  - Mix is 'warm'
  - Difficult to remove from capsule
  - Shiny wet and soft
3. Undertrituration
  - Dry mix
  - Crumbled mix that is very weak

### Mulling

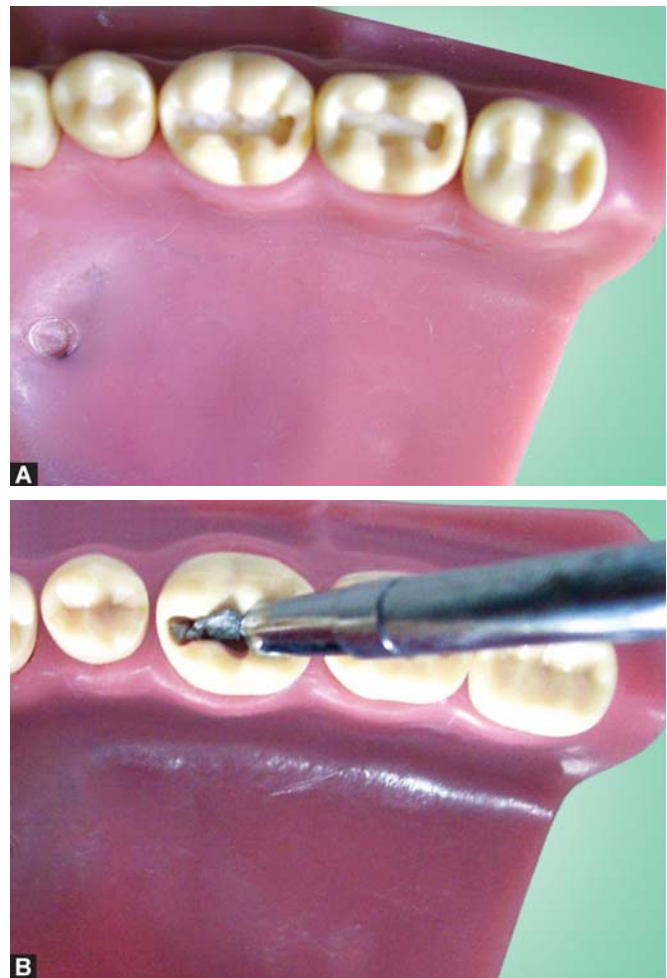
Mulling is done so that all alloy particles are properly coated with mercury, in other words it is continuation of the trituration. Mulling of the amalgam can be done manually or mechanically. By hand, it can be done by squeezing the freshly mixed amalgam collected in the chamois skin. Mulling should not be done by bare hands as it can be contaminated by moisture. Mechanical mulling is done in the amalgamator by trituration for one to two seconds.

### Application of Matrix Band

Placing a matrix for an amalgam restoration allows the dentist to insert restoration without exceeding the limits of the normal tooth structure. Place the matrix band in the matrix retainer. Pass the matrix band between the contact points so that its lower edge comes just over the cervical margin of the preparation. Tighten the band and stabilize it using wedges (**Fig. 9.11**). It is very important not to overtighten



**Fig. 9.11:** Placement of band and wedge



**Figs 9.12A and B:** (A) Class I preparation in 46, 47  
(B) Insertion of amalgam into the preparation

the band because this will flex the cusps, resulting in postrestoration sensitivity, and failure of the restoration. Finally, burnish the contact area of the band against the adjacent tooth.

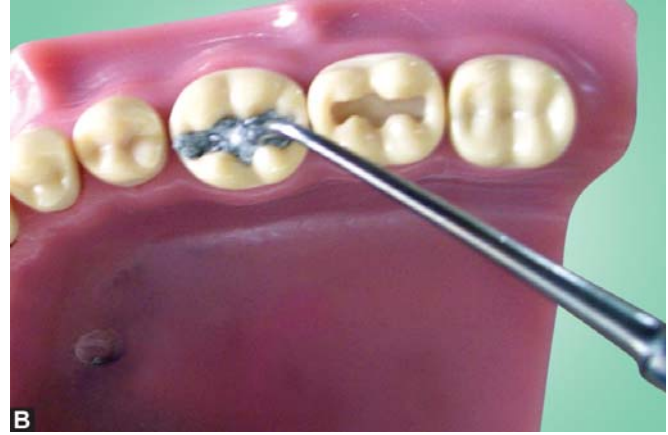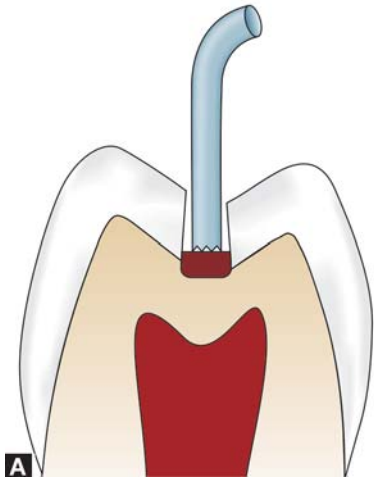
### Insertion of Amalgam (Figs 9.12A and B)

Pick a small amount of amalgam alloy with the help of amalgam carrier and transfer it to the preparation. Proximal box should be filled before the occlusal part of the preparation.

Place the first increment of amalgam in the deepest proximal part of the preparation and condense it with flat surface of condenser.

Apply firm pressure on the amalgam mass for adequate condensation. After it, add next increment and again condense it.

When the level of amalgam reaches the preparation margins, continue the packing of preparation to allow an excess to build up for better finishing.



**Figs 9.13A and B:** Condense amalgam with the help of flat surface of condenser

### Condensation

Various shapes (triangular, round, elliptical, trapezoidal and rectangular) and sizes of condensers are used for amalgam condensation. Working end of a condenser is usually serrated (**Figs 9.13A and B**) since the force delivered to the amalgam depends upon the area of condensing tips and selection of condenser depends on the outline form of tooth preparation.

#### Rules of Condensation

- Start condensation within three minutes of trituration.
- Condense continuously.
- Condense laterally as well as apically.
- Apply adequate force for condensation.
- Have a constant supply of amalgam.

#### Objectives of condensation

- Brings excess mercury on the surface of restoration
- Reduces the number and size of voids in the restoration
- Prepares the surface of restoration for carving
- Adapts amalgam to the preparation walls and floors.

#### Condensation Depends upon Following Factors

- Plasticity of the mass.
- **Size of the amalgam increment:** A larger mass results in incomplete condensation.
- **Condenser size:** The smaller the condenser working end, the greater the force.
- Direction of force.
- Amount of force.

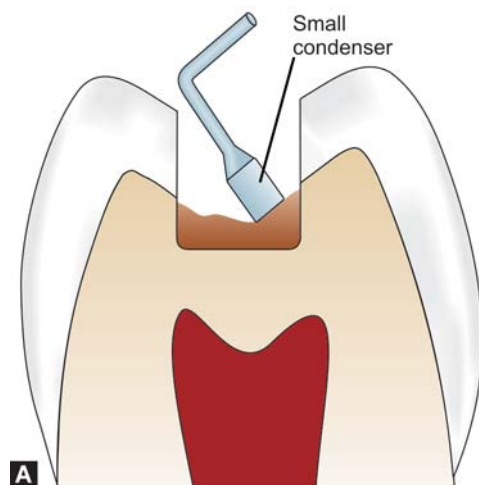
- **Type of alloy:** Use larger condensers when condensing spherical alloys because smaller condenser will displace the spherical particles rather than condensing them.

#### Choice of condenser depending upon type of amalgam alloy (Figs 9.14A and B)

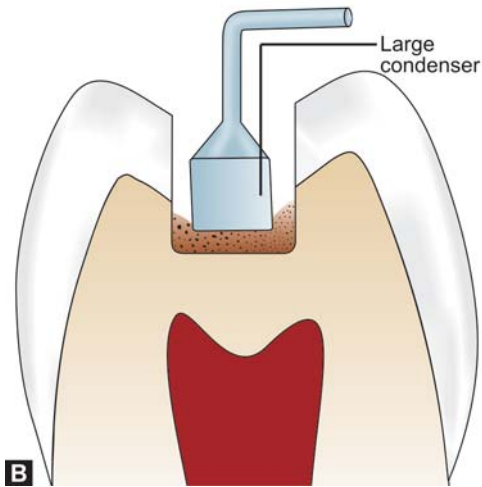
Type of alloy	Type of condenser
• Lathe-cut alloy	Small condenser
• Blended alloy	Small condenser
• Spherical alloy	Large condenser

### Burnishing

Precurve burnishing is done after condensation. It is the process of rubbing, generally done to make the surface



**Fig. 9.14A:** (A) Condensation of nonspherical alloy using small condenser



**Fig. 9.14B:** (B) Condensation of spherical alloy with large condenser

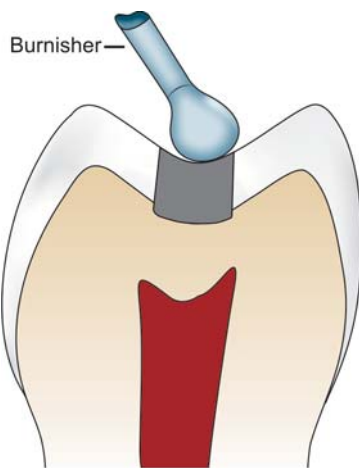
shiny. Amalgam is overfilled and burnished immediately with heavy strokes so as to improve marginal adaptability of the restoration and remove excess mercury from overpacked amalgam (**Fig. 9.15**).

#### Advantages of Precarve Burnishing

1. Improves the marginal integrity of restoration.
2. Shapes the restoration according to contours and curvatures of the tooth.
3. Helps in reducing the mercuric content of amalgam.

#### Postcarve Burnishing

It is done after completion of carving with the help of small-sized burnishers using light strokes.



**Fig. 9.15:** Precarve burnishing improves marginal adaptation of amalgam and removes excess mercury from amalgam

#### Advantages of Postcarve Burnishing

- Reduces number of voids on surface of restoration.
- Produces denser amalgam at margins.
- Improves marginal seal.
- Increases surface hardness.
- Decreases rate of corrosion.

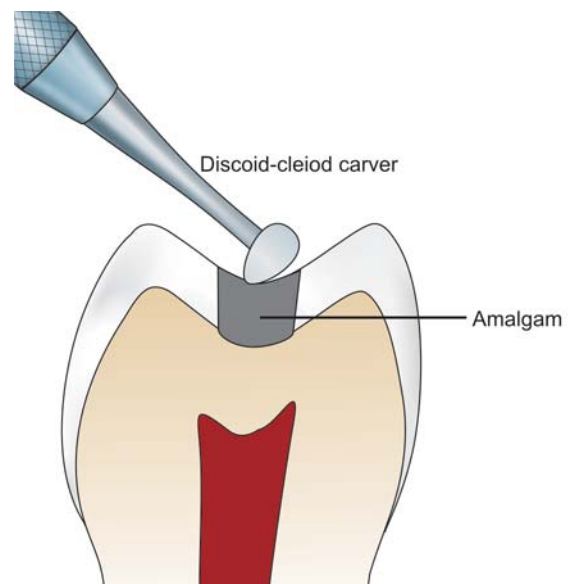
#### Carving

Objectives of carving are to achieve restoration with:

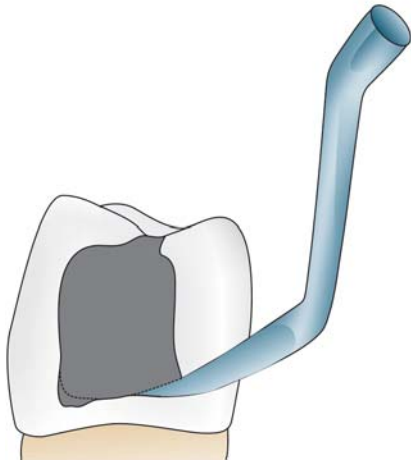
1. No over-and under-hangs
2. Proper size, location and good interproximal contact
3. Adequate marginal ridges
4. Proper contours
5. Optimal occlusal anatomy
6. Adequate embrasures
7. Enhancing the health of periodontium

Amalgam should not be carved until it is sufficiently firm. For adequate carving, it is preferable to overpack the preparation and then carve it to the margins. Carving causes removal of mercury-rich surface layer. For proper carving, occlusal anatomy should be kept low to preserve bulk of the alloy at the margins. The carving instruments should have discoid and cleoid blade design (**Fig. 9.16**). Larger instrument is used first, followed by smaller instruments.

In proximal tooth preparation, carving of the cervical margins should begin following the removal of matrix band. Loosen the band and then wedge before carving because axial and cervical margins become accessible after removal of band.



**Fig. 9.16:** Use of discoid-cleoid carver for carving occlusal surface

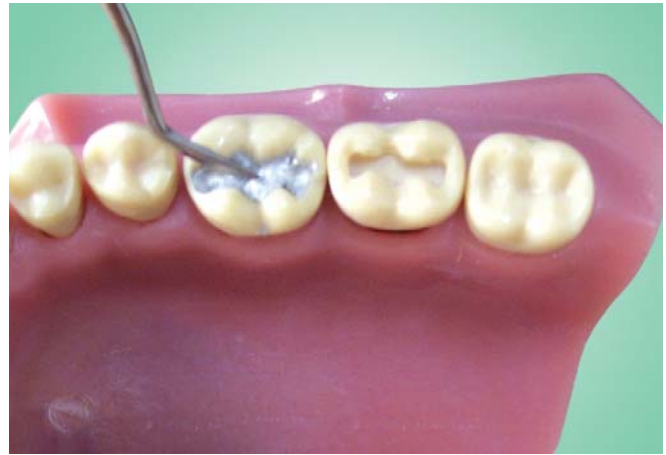

**Fig. 9.17:** Trim the axial margins towards gingiva with sharp carvers

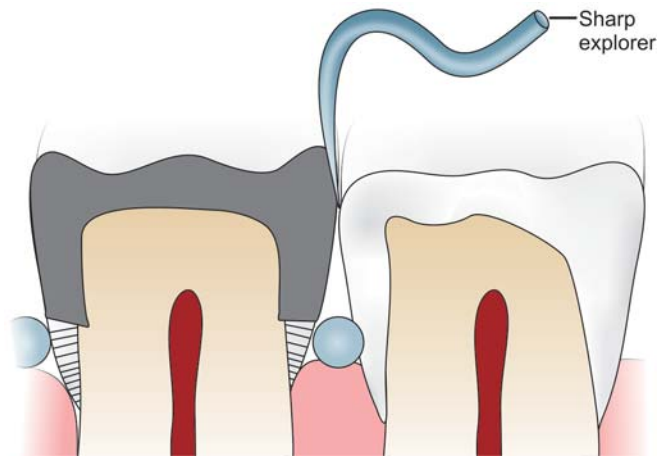
Trim the axial margins towards the gingiva in downward direction with a sharp carver (**Fig. 9.17**). Do not overcarve amalgam as it can lead to acute angles and stress concentration within the amalgam which can fracture the restoration (**Fig. 9.18**).

Carve the occlusal surface with a sharp carver like hollenback. Hold it in a way so that its blade lies across the margin of the restoration, half on tooth and half on restoration (**Fig. 9.19**). Define marginal ridge and occlusal embrasure using a sharp explorer (**Fig. 9.20**). Remove any overhanging margins in the interdental region, if present.

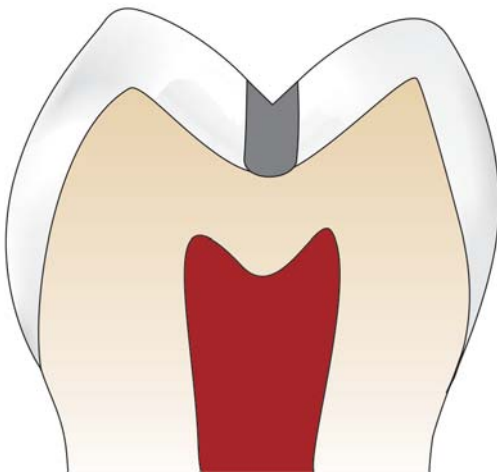During carving, movement of instrument should be parallel to the margin and edge of blade should be perpendicular to the margins, to avoid ditching of the metal and to minimize the overlay (**Figs 9.21A and B**).



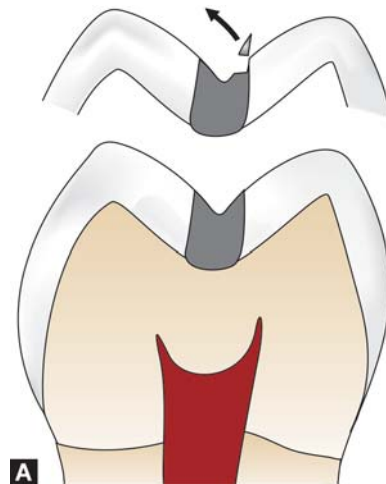**Fig. 9.19:** Carving amalgam restoration



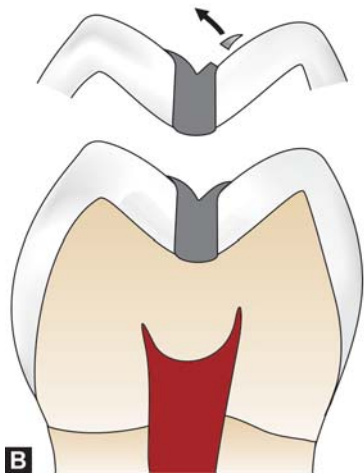
**Fig. 9.20:** Sharp explorer is used to define marginal ridge



**Fig. 9.18:** Overcarving of amalgam can cause fracture of restoration



**Fig. 9.21A:** Improper carving can result in: Ditching of restoration



**Fig. 9.21B:** Improper carving can result in restoration overlay and fracture

### Checking the Contact Points

Check the integrity of contact points using dental floss by passing it buccally, palatally and gingivally (**Figs 9.22A to C**).

### Checking the Occlusion

It is done after carving so as to remove any areas left high in the final restoration. Ask the patient to close the mouth so that the teeth meet lightly.

Use articulating paper to localize any high spots, if the restoration is high, it indicates the premature contacts which are carefully removed. Then carving is carefully done. The process of light closure is repeated and carving is finally done until the teeth are in their prerestoration occlusion.

Burnish the finished restoration. Finally smoothen the restoration with a cotton pledget.

**Postcarve burnishing** is done after carving with suitable size of burnisher to improve the smoothness with shiny

appearance. It helps in reducing the surface roughness produced by carving. In high copper amalgam restoration postcarve burnishing has no significant effect on the clinical performance but in low copper amalgam, postcarve burnishing produces denser amalgam at the margins.

### Finishing and Polishing

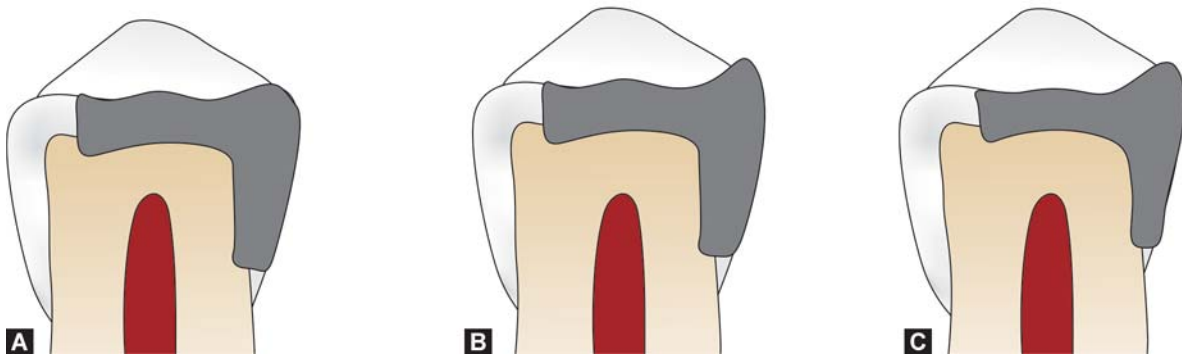
Finishing amalgam restorations involves removal of marginal irregularities, defining anatomical contours, and smoothening the surface roughness of the restoration. Polishing is done to achieve a smooth, shiny luster on the surface of the amalgam. Finishing is done before polishing by use of abrasive agents that are coarse enough to remove the bulk from the surface. Polishing requires mildly abrasive materials for producing smooth and shiny surface of amalgam restoration.

Finishing and polishing of the restorations should be done at least 24 hours after the placement of the amalgam. Premature finishing and polishing will interfere with the crystalline structure of the hardening amalgam. The result will be a weakened restoration. Polishing may not be essential for restorations with high-copper alloys because they have a tendency of self-polishing.

The clinician should check the margins and proximal contacts of the restoration initially using metal filing strip to remove any roughness or overhand of the restoration in the proximal area.

### Advantages of Finishing and Polishing

- Improves marginal adaptation of restoration by removing flash.
- Reduces tarnish and corrosion.
- Polished surface is plaque-resistant.
- Polished surface is smoother and easier to clean.
- Prevention of recurrent decay.
- Prevention of amalgam deterioration.



**Figs 9.22A to C:** (A) Optimal proximal contour (B) High marginal ridge and improper occlusal embrasure form (C) Too high contact and improper occlusal embrasure form

- Maintenance of periodontal health.
- Prevention of occlusal problems.

One of the most important precautions to be taken while doing finishing and polishing is the minimization of heat production. Heat generated during the polishing procedure is potentially dangerous because:

- It can cause thermal damage to the pulp.
- Heat brings the mercury to the surface of the restoration resulting in a dull, cloudy surface, and makes it more susceptible to corrosion.

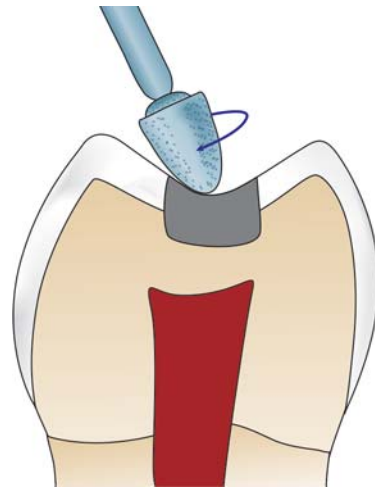
#### To Minimize Heat Production

1. Use light, intermittent pressure with rotary instruments.
2. Use slow speed with rotary instruments.
3. Use abrasive agents that are wet rather than dry.

The most commonly rotary instruments used are abrasive stones, disks and finishing burs available in different shapes, sizes, degrees of abrasiveness, and in either high-speed or slow speed. Pumice and tin oxide are two commonly used polishing agents. Pumice is usually mixed with water to decrease the heat produced by the friction of the abrasive particles during polishing. Tin oxide or amalgloss is used as the finest abrasive agent. It can be used in a slurry, dry, or both forms.

#### Steps for Finishing and Polishing of Amalgam

- Using an explorer, evaluate the cavosurface margins for marginal integrity.
- Determine the presence of any marginal discrepancies and evaluate the contour of the restoration.
- Identify the occlusal pattern. Mark the occlusal contacts in centric occlusion and excursive movements. Areas that need to be reduced are identified by darker markings on the restoration. Establish proper occlusion by grinding.
- Smoothen the margins by using a round bur moving it along all cavosurface margins. This procedure is done to blend the tooth structure to amalgam.
- Use a large round finishing bur to eliminate scratches and graininess from the amalgam.
- Using the side of the finishing bur, smoothen the occlusal surface and marginal ridges. Move the bur mesiodistally, overlapping each stroke, then do the same in a bucco-lingual direction.
- Use a finishing strip for smoothening and polishing of the gingival cavosurface margins and interproximal space.
- Smoothen the facial and lingual surfaces with finishing disks.
- Finally polish the surface by using progressively finer abrasive agents (**Fig. 9.23**).



**Fig. 9.23:** Final polishing of amalgam restoration using abrasive stones

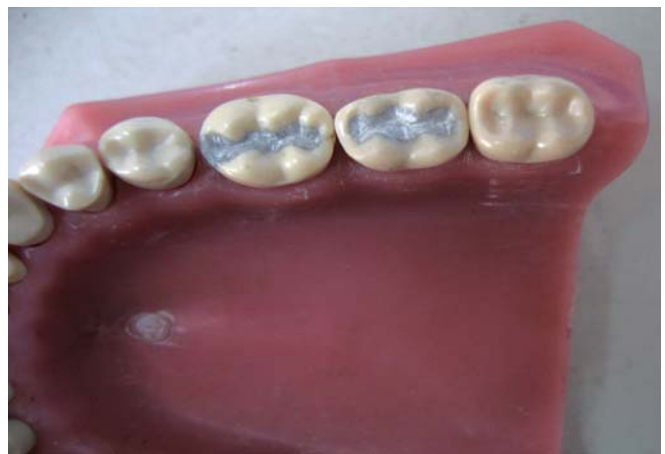- Rinse and clean out all debris completely.
- Evaluate all margins and surfaces of the restoration (**Fig. 9.24**).

A polished amalgam restoration should have following features:

- Surface is smooth with no scratches or graininess.
- Surface is lustrous, with a mirror-like shine.
- There is no break between margins and the tooth surface.
- Restoration has proper contact and contour.
- There is no damage to the restoration or adjacent tooth structure.

#### FAILURES OF AMALGAM RESTORATIONS

Since 1860, amalgam has been the most widely used restorative material in posterior teeth. But after 1970 because of development of newer restorative materials and mercury toxicity, its use has been limited.



**Fig. 9.24:** Completed amalgam restoration



Studies have shown that the life of a properly manipulated and restored silver amalgam restoration is about 10-12 years. With time, the restoration may show some changes like tarnish, corrosion, recurrent marginal caries, discoloration of teeth, fracture of restoration or tooth and ultimately loss of restoration.

#### Most common failures associated with dental amalgam restoration

##### At microscopic level

- Pain after amalgam restoration
- Periodontal tissue injury due to proximal overhangs
- Pulpal involvement
- Tarnish and corrosion
- Internal stresses due to excessive masticatory forces

##### At macroscopic level

- Bulk fracture of restoration
- Tooth fracture
- Marginal fracture of amalgam
- Secondary or recurrent caries commonly takes place due to marginal leakage.
- Dimensional changes, especially in zinc-containing amalgam
- Discoloration of restoration
- Discoloration of tooth

### Reasons for Failure of Amalgam Restorations

#### The reasons for failure of amalgam restorations can be divided under following headings:

1. Poor case selection
2. Defective tooth preparation
3. Defective amalgam manipulation
4. Defective matrix adaptation
5. Postrestorative failures

#### Poor Case Selection

For long-term success of the amalgam restorations, a careful selection of case is very important. Since amalgam requires sufficient sound tooth structure to provide sufficient resistance and retention form for the amalgam, selecting teeth with extensive caries, abnormal habits like bruxism and heavy masticatory forces can result in restoration failure. Amalgam should be placed in small to moderate sized carious lesions.

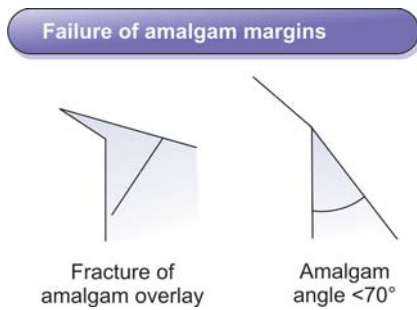
#### Defective Tooth Preparation

This is one of the major causes of failure of amalgam restorations. The following defects usually occur during tooth preparation.

- **Inadequate occlusal extension:** Insufficient extension to include adjacent deep pits and fissures increases

chances for secondary/recurrent caries. This is specially seen in patients with high caries index. One should involve all susceptible pits and fissures in the preparation margins.

- **Underextension of the proximal box:** To prevent occurrence of secondary caries, walls of the proximal box of class II preparation must be extended to self-cleansing areas. If the proximal margins of the filling are not adequately extended into the embrasures, they are not open to cleaning by mastication and brushing resulting in secondary caries. On the other hand, overextension into the embrasure areas makes the preparation walls weak, especially in lower bicuspids and on distal sides of maxillary and mandibular first molars. Therefore, one should avoid overextension of the margins of the restoration into the embrasures.
- **Overextended tooth preparation:** Ideally the faciolingual width of the preparation at isthmus for amalgam restoration should be less than one-fourth of the intercuspal distance. If the faciolingual width of the preparation is more than half of the intercuspal distance, cusp capping should be considered. Cusp capping becomes necessary if the tooth preparation involves more than two-thirds of the intercuspal distance. Though for cusp capping, only cast restoration is preferred. If amalgam is to be used for capping, it should be at least 2 mm thick over the functional cusp and 1.5 mm over nonfunctional cusp to prevent its fracture over the cusps under masticatory load.
- **Depth of preparation:** Minimum depth of preparation should be 1.5 to 2 mm so as to provide bulk which can prevent its fracture under masticatory load.
- There should be flat pulpal floor of the preparation to avoid fracture of amalgam and the tooth. Curved floor for restoration acts as a wedge, which can result in tooth fracture.
- The tooth and amalgam joint, i.e. cavosurface angle should be a butt joint, especially where the masticatory stresses are present. If cavosurface angle is acute, enamel margins may fracture under load. But if cavosurface angle is obtuse, marginal amalgam may fracture under masticatory stresses (**Fig. 9.25**).
- Presence of unsupported enamel rods can result in fracture and thus secondary caries because of gap formation. They should be removed properly.
- In proximal preparations, fracture of amalgam can occur because of inadequate width and depth of isthmus or insufficient proximal retention form.
- Fracture of amalgam restoration may occur because of sharp axiopulpal line angle because of concentration of stresses in that area. So these angles should be rounded.



**Fig. 9.25:** Cavosurface margins should be  $90^\circ$  for amalgam fracture of restoration can occur if angle is acute or obtuse

- Wherever additional retentive forms and devices are used for additional retention, they should be prepared entirely in dentin.
- Incomplete removal of the defective enamel before restoration can also result in fracture of the restoration under masticatory load.
- Postoperative pain may occur due to pulpal hyperemia. To avoid this, one should make use of effective cooling, sharp burs and intermittent cutting.

#### Defective Amalgam Manipulation

Defective amalgam manipulation may occur in the following forms:

- Inappropriate condensation:** The purpose of condensation is to adapt amalgam to the preparation walls and floors and to express excess mercury from the amalgam. An ideal amalgam mix should have mercury content below 55%, this can be achieved during condensation. Following points should be kept in mind while condensing amalgam.
- a. Small increments of amalgam should be used to make sure proper condensation.
  - b. Use of adequate condensation pressure.
  - c. Avoid delay between trituration and condensation.
  - d. Amalgam mix should be used within three minutes of its trituration.

**Incorrect mercury alloy ratio:** Ideally in amalgam, the mercury content should be less than 55%. If it is more than 55%, there is decrease in strength of the amalgam. If large amount of mercury is used in trituration, the excess removal of mercury becomes difficult by mulling and condensation. Hence, before trituration, proper proportion of alloy and mercury should be used.

**Contamination during manipulation:** During manipulation of amalgam if the amalgam gets contaminated with moisture, there occurs reduction in strength of amalgam. In zinc-containing alloys, contamination with moisture causes

delayed expansion resulting in pain, weakness at the margins, tarnish, and corrosion.

**Faulty finishing and polishing:** Excessive heat production during polishing may result in pulpal trauma. Heavy pressure applied during polishing results in spur-like overhangs, which fracture under mastication causing leaky margins and prone to secondary caries.

Overcarving of deep pits and fissures results in reduced thickness of amalgam, this can cause fracture of the restoration. Improper polishing results in rough surface which is prone to tarnish, corrosion, pitting, plaque accumulation and gingival irritation.

To reduce these while polishing, temperature at the surface should be maintained below  $65^\circ\text{C}$ . Excessive heat production can be minimized by use of adequate coolant and polishing should be done with very light pressure.

#### Defective Matrix Adaptation

- As we know a variety of matrices are available, proper matrix and retainer should be selected according to requirement. Matrix should be properly contoured according to the tooth type and stabilized using a wedge.
- If wedge is not used, excess material can go into gingiva and thus irritate the periodontium.
- Before condensation of amalgam, matrix should be properly made stable to avoid distortion of the restoration.
- If matrix band is removed prematurely before the restoration is set, it may fracture the restoration.

#### Postrestorative Failures

**Postrestorative pains:** It can occur because of following reasons:

- High points in amalgam restoration can result in apical periodontitis or, fracture of the filling or tooth and pain.
- In zinc-containing alloys, delayed expansion can cause fracture of filling or tooth and pain.
- If the patient has restoration placed adjacent or opposite to gold restoration, in presence of saliva, there is production of galvanic currents. This can also result in pain after amalgam restoration.
- Extreme changes in temperature in oral cavity may cause pulpal hyperemia resulting in pain. Because of good thermal conductivity, insufficient pulp protection may give rise to pain. Thus it is advisable to use pulp protective materials beneath amalgam restoration.

**Premature fracture of restoration:** If patient bites the restoration soon after its placement and before final setting of amalgam takes place, restoration may fracture. Therefore, postoperative instructions must be clearly explained to the patient.

## MERCURY HYGIENE

Mercury has been used in dentistry from a very long time. It is considered as major component in amalgam restorations and also used in medicines such as skin, antibacterial ointment and laxatives.

Mercury has been considered to be hazardous if not managed properly. Mercury vapors present in the dental office are toxic if they cross the threshold limit. So, management of free mercury is very important.

### History of Conflicts regarding Amalgam Use

- 1920 (First Amalgam war)—War between the dentists using gold foil and dental amalgam.
- 1980 Dr Hal Huggins—Amalgam responsible for cardiovascular and nervous problem.
- 1991 NIH–NIDR and FDA—National Institute of Health–National Institute for Dental Research. Several experts concluded that amalgam is not considered as a significant health hazard.

Mercury is present in the environment which is taken into the body through water, air and food, daily in one or another form.

The mercury usually enters into the body every day no matter what type of restorative filling is present in oral cavity. Very low amount of mercury is usually released from set amalgam as compared to daily intake.

It has been found that health hazards from the amalgam use are mainly to dental and its associated staff in dental office than patient because of the long-term contact with mercury usage.

### Forms of Mercury

Exists in three chemical forms:

1. **Elemental mercury**
  - Most volatile
  - Exist in liquid/vapor form
  - Inhaled and absorbed into lungs (80%) and GIT (0.01%)
  - Most common form of entry in human body during amalgam restoration
  - Exposure to this form can occur due to accidental spillage of mercury in dental office.
2. **Inorganic mercury**
  - Normally mined as inorganic sulfide ore
  - Mainly in liquid form
  - Can also exist in other forms than sulfides
  - Potentially toxic
  - Irritating in nature
  - Main route of entry is through lungs (80%).

### 3. Organic mercury

- Mainly in the form of methyl mercury
- Main route of entry is absorption through GIT (95-98%) through food
- Used in fungicide and pesticide
- Found in vegetables, fruits and grains
- Toxic in nature

### Mercury Exposure in Dental Office

In the dental office, mercury exposure can occur from the following sources (Fig. 9.26):

1. Storage of amalgam raw materials for use.
2. Mixed but unset amalgam during trituration, insertion and intraoral hardening.
3. Amalgam scrap containing insufficient alloy for consuming mercury completely.
4. Finishing and polishing of restoration.
5. Removal of old restoration.

### Steps to Reduce Mercury Exposure in the Dental Clinic

1. **Storage of mercury:** Storage of mercury is considered difficult because it:
  - Is very mobile
  - Has high diffusion rate
  - Can penetrate extremely fine spaces
 Therefore, one should take care while storage of mercury is concerned.
  - a. Precapsulated alloys should be preferred for avoiding mercury spill
  - b. If bulk mercury is purchased, store it in tight container with tight lid in closed cabinets.
  - c. Location of storage should be near the window/exhaust vent.
2. **Trituration of amalgam**
  - a. Use precapsulated alloy in amalgamator
  - b. Avoid manual mixing

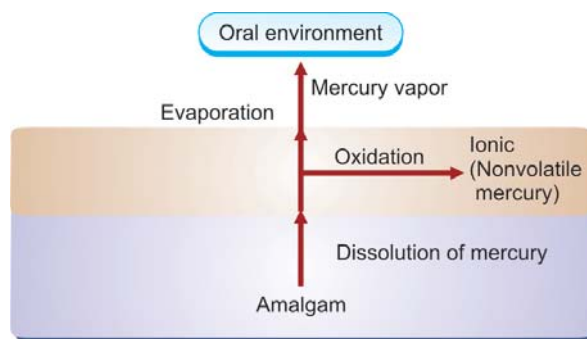


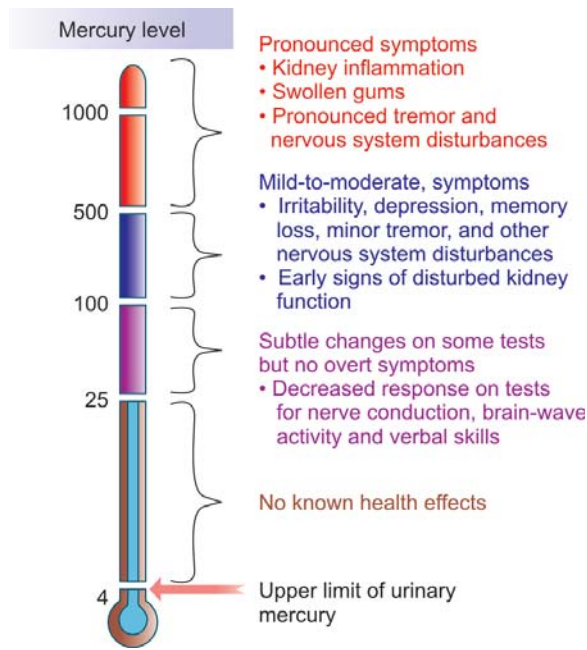
Fig. 9.26: Sources of mercury in oral environment

- c. High vibrations during mixing can create aerosols of liquid droplets and these vapors may extend up to 6-12 ft from the amalgamator. So, to minimize the risk, small covers are used over the amalgamator to contain the aerosol in that area.
  - d. Air flow should be reasonably high in dental office to minimize air contamination.
  - e. Avoid direct exposure of the mercury with skin as it may cause hypersensitivity reactions.
3. **Designing of office:** Office should be designed so as to reduce mercury contamination. Following points are to be kept in mind while designing:
    - a. Proper ventilation of the dental office
    - b. Avoid carpeting/floor coverings in dental office as there is no way of removing mercury from the carpet.
  4. **Insertion and condensation of amalgam**
    - After mixing, the unhardened mixture releases mercury vapors in air and causes air pollution. Proper ventilation of the area should be done.
    - Proper aseptic techniques such as use of mouth masks, gloves and protective eyeglasses should be done.
    - Avoid direct exposure of mercury with skin.
    - Use rubberdam to isolate the tooth.
    - Use high volume evacuation system to control the mercury level in air.
  5. **Polishing of amalgam:** The mercury is tightly bound when amalgam is set. Polishing should be done with coolant to decrease heat and vapors present in atmosphere.
  6. **Disposal of scrap amalgam:** Scrap amalgam during insertion and condensation should be carefully collected and stored under water, glycerin or spent X-ray fixer solution in tightly capped jar.
 

Spent X-ray fixer is preferred for storage of amalgam scrap because it is source of both silver and sulfide ions which react with mercury present in scrap amalgam to form solid product and decrease the mercury vapor pressure.
  7. **Disposal of mercury contaminated waste:** Disposal of spent capsules, mercury contaminated cotton rolls and paper napkins should be done properly. These items should be disposed in tightly closed plastic container/plastic bag which can be placed into sanitary landfill for disposal.
  8. **Removal of old amalgam restorations:** Certain points should be kept in mind while removing amalgam restoration.
    - Rubberdam and high volume evacuator should be used to decrease mercury vapor.
    - Watercooling should also be used as high rotary instruments used without water increase the temperature of filling and increase the mercury vapors in that area.
  9. **Cleaning of mercury contaminated instruments**
    - Clean the mercury-contaminated instrument used during insertion, finishing and polishing and during removal of restoration as amalgam material left on the instrument surface, heated during sterilization can release mercury vapor in atmosphere.
    - Isolation of the area along with proper ventilation of sterilization area is preferred.
  10. **Monitoring of mercury vapors:** The accepted threshold limit for exposure to mercury vapor for a 40-hour work per week is  $50\text{-}\mu\text{g}/\text{m}^3$  (given by OSHA). Periodical monitoring of mercury vapor in dental office should be done and carefully recorded.
 

Dental Mercury Hygiene Recommendations in Dental Office.

    1. Follow aseptic technique, i.e wear protective clothing, protective masks, gloves and glasses to prevent exposure to mercury vapors.
    2. Dental personnel's involved in handling of mercury and dental amalgam products should follow proper mercury hygiene practice.
    3. Dentists and dental assistants should have proper knowledge of amalgam disposal and their handling.
    4. Proper ventilation of the working space should be there, to reduce mercury levels in the atmosphere.
    5. Periodically check the working area to analyze the mercury vapor pressure using dosimeter badges.
    6. Avoid carpet/floor coverings in dental office; floor coverings should be easy to clean, nonabsorbent and seamless.
    7. Mercury should be stored in unbreakable closed container in isolated area.
    8. Use precapsulated alloy for mixing.
    9. Instead of manual/hand mixing, use amalgamator with completely closed arm.
    10. Polish amalgam restoration under coolant to decrease the mercury vapor pressure.
    11. Avoid direct contact of mercury with skin.
    12. Use high volume evacuation and rubberdam during insertion, condensation and polishing of restoration.
    13. Store scrap amalgam in water, glycerine or spent fixer solution in closed container.
    14. Precapsulated alloys, mercury contaminated cotton rolls should be disposed in closed plastic container.
    15. Clean the spilled mercury using trap bottles or freshly mixed amalgam.



**Fig. 9.27:** Mercury thermometer depicting different levels of mercury toxicity

- Remove professional clothing, gloves, masks before leaving operating area.

### Mercury Toxicity (Fig. 9.27)

Mercury toxicity is mainly seen because of chronic exposure of mercury which can be in form of food, restorations or other sources. Since too many factors are involved, it takes time for symptoms to appear. Usually mercury gradually accumulates in the body over a period of time, contributes to chronic mercury poisoning.

#### Toxic effects of mercury depend upon following factors

- Amount of exposure
- Length of exposure
- Location of mercury accumulation in body
- Amount of accumulated mercury
- Overall health of the patient (for detoxification)

#### Acute Mercury Poisoning

It occurs when there is sudden exposure of high levels of mercury, especially from elemental mercury or organic mercury. It results in immediate and severe symptoms requiring urgent medical attention.

Toxic levels of mercury are measured in micrograms. The following table compares the effects of different levels of mercury present in urine.

#### Levels of Hg toxicity

- At level of 4  $\mu\text{g}$ :** This level is attributed as the upper limit in urine when extensive restoration of amalgam is present in patient's mouth
- At level 0-25  $\mu\text{g}$ :** No known health hazards are detected
- At level 25-100  $\mu\text{g}$ :** Decreased response on tests done for brain conduction. Decreased response related to verbal skills
- 100-500  $\mu\text{g}$ :** Mild-to-moderate effects can be seen:
  - Irritability
  - Memory loss
  - Depression
  - Tremors
  - Nervous system disturbances
- 500-1,000  $\mu\text{g}$ :** Pronounced symptoms
  - Inflammation of kidney
  - Tremors and pronounced nervous system disturbances
  - Swollen gums

### QUESTIONS

- Define alloy.
- What is dental amalgam?
- What is composition of amalgam alloys?
- What is significance of silver in silver alloy?
- What is significance of zinc in amalgam alloys?
- Classify silver amalgam.
- What are differences between high and low copper alloys?
- What are advantages of silver amalgam?
- What are disadvantages of silver amalgam?
- Where do we use silver amalgam restoration?
- What are factors affecting dimensional changes of silver amalgam?
- Which strength is more for amalgam-Compressive or tensile strength?
- Define creep. What is significance of creep?
- Discuss corrosion in high and low copper amalgams.
- What is mercury free direct filling alloy?
- What are advantages of bonded amalgam?
- What are indications of bonded amalgam?
- What is gallium amalgam?
- What is trituration? How is it done?

- Q. What are signs of an ideal mix?
- Q. What are signs of poorly triturated mix?
- Q. What are signs of over triturated mix?
- Q. What is mulling?
- Q. What is normal condensation pressure for amalgam?

Ans. 4-6 pounds

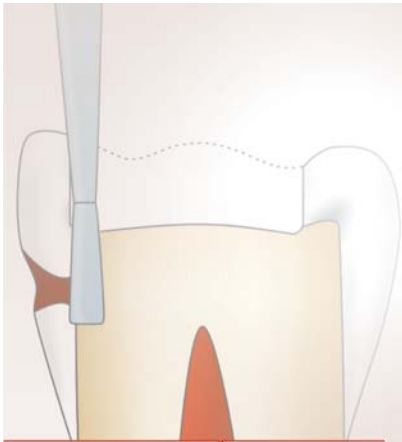
- Q. How does size of condenser affect condensation?

Ans. If condenser is too small it will not effectively condense amalgam, and it will form holes in it. If condenser is too large, it will not be able to condense amalgam properly. Because of its large surface area, it will transmit lesser pressure per unit area.

- Q. Why should we overfill the preparation before caving?

Ans. Since, the topmost layer of filled amalgam is rich in mercury, this mercury rich layer could be removed during carving.

- Q. What are objectives of condensation?
  - Q. What are different condenser types?
  - Q. What is burnishing?
  - Q. Why is pre carve burnishing done?
  - Q. Why is post carve burnishing done?
  - Q. What are different types of burnishers which are used for burnishing?
  - Q. How do you check occlusion after restoration?
- Ans. Patient is asked to bite in centric and eccentric position with an articulating paper kept between upper and lower teeth. Any premature contact may show as mark on restoration. It should be removed.
- Q. What do you mean by mercury hygiene?
  - Q. Where should be excess mercury stored?
  - Q. What precautions should be taken while handling amalgam/mercury?



# Tooth Preparation for Amalgam Restoration

## Chapter 10

### TOOTH PREPARATION FOR CLASS I AMALGAM RESTORATION

- Initial Tooth Preparation
- Final Tooth Preparation
- Tooth Preparation on Occlusal Surface of Different Teeth
- Tooth Preparation on Occlusal Surface with Buccal or Lingual Extension

### TOOTH PREPARATION FOR CLASS I AMALGAM RESTORATION

*Class I:* Pit and fissure preparations occur on the occlusal surfaces of premolars and molars, the occlusal two-third of buccal and lingual surface of molars, lingual surface of incisors and any other abnormal position.

The basic principles of tooth preparation are as follows:

1. *Initial tooth preparation:*
  - Outline form
  - Primary resistance form
  - Primary retention form
  - Convenience form
2. *Final tooth preparation:*
  - Management of remaining caries
  - Secondary resistance and retention form
  - Pulp protection, if required
  - Finishing of enamel margins
  - Final inspection of the preparation

### CLASS II TOOTH PREPARATION FOR AMALGAM RESTORATION

- Modifications in Class II Preparation Design

### CLASS III TOOTH PREPARATION FOR AMALGAM RESTORATION

### CLASS V TOOTH PREPARATION FOR AMALGAM RESTORATION

### CLASS VI TOOTH PREPARATION FOR AMALGAM RESTORATION

### STEPS OF AMALGAM RESTORATION

#### 1. Initial Tooth Preparation

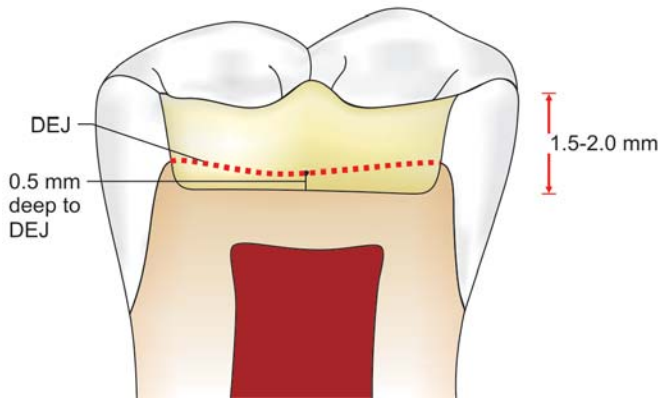
##### *Outline Form*

The outline form means extending the preparation margins to the place they will occupy in the final preparation. Following facts, must be kept in mind while making outline form:

- Removal of all carious and defective pits and fissures to healthy tooth structure.
- Removal of all unsupported enamel rods
- To avoid ending preparation margins in high stress areas like cusp tip and crest of the ridges.
- Placing margins on sound tooth structure.

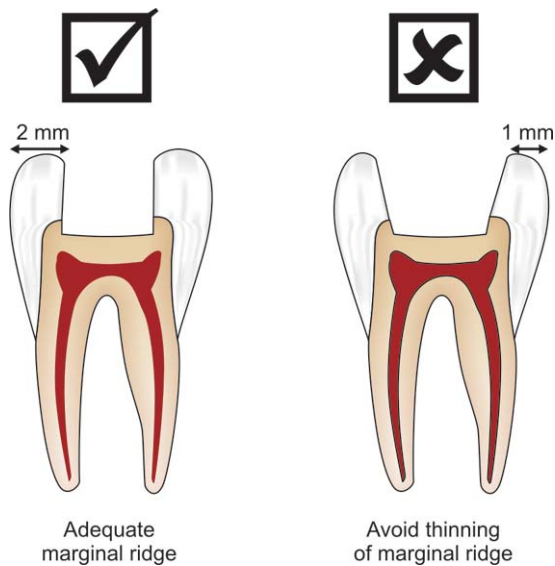
##### *Steps*

- With the help of no. 245 bur, establish the external outline form to extend all margins into sound tooth tissue.
- Bur should be kept parallel to long axis of the tooth to make a ditch in the carious portion of the tooth and it should be rotating when applied to the tooth and should not stop rotating until removed.

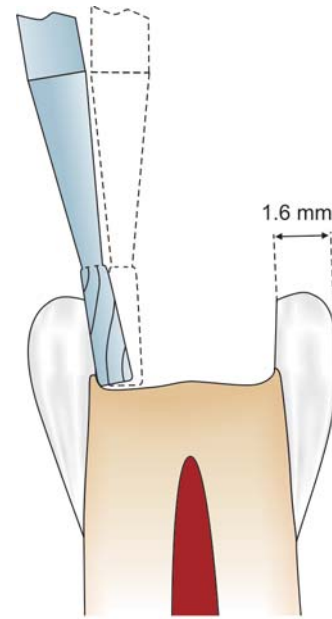


**Fig. 10.1:** Initial depth of 1.5 mm should be maintained while preparing outline form

- Maintain the initial depth of 1.5 mm, this is approximately one-half the length of the cutting bur. This should be, at least 0.2 to 0.5 mm in dentin to provide adequate strength to resist fracture due to occlusal forces (**Fig. 10.1**). While maintaining the same depth and bur orientation, move the bur to extend the outline to include the central fissure. The margins of preparation not only extend into sound tooth tissue but also involve adjacent deep pits and fissures in the preparation.
- Extend the margin mesially and distally but do not involve marginal ridges. These walls should have dovetail shape to provide retention to the restoration (**Figs 10.2A and B**).



**Figs 10.2A and B:** (A) Sufficient marginal ridge, (B) Overcutting of marginal ridge causes thinning



**Fig. 10.3:** Sometimes slight divergence of mesial and distal wall is done so as to have dentinal support of marginal ridges

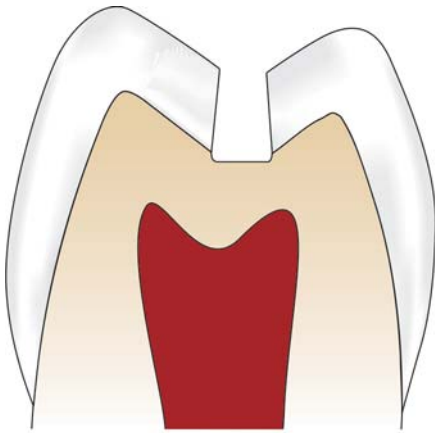
- While working towards mesial and distal surface, orient the bur towards respective marginal ridge. This will result in slight divergence of mesial and distal walls which helps to provide dentinal support for marginal ridges (**Fig. 10.3**).
- The isthmus width should be as narrow as possible, it should not be wider than the intercusp distance.
- The deep pit and fissure defects less than 0.5 mm apart should be included within the outline form.
- The external outline form should have smooth curves, straight lines and rounded angles. All unsupported and demineralized enamel should be removed.
- Enameloplasty is the careful removal of sharp and irregular enamel margins by “rounding” or “saucering” it and forming a easily cleansable area. The enameloplasty should not extend the outline form. The use of enameloplasty should be done in ends of fissures whenever needed.

#### Primary Resistance Form

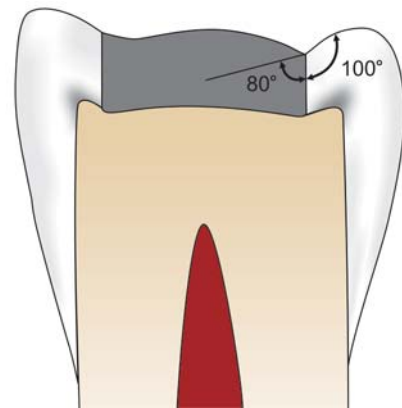
Resistance form is that shape given to a preparation planned to afford such a seat for the restoration so as to best enable it to withstand the occlusal stresses. Primary resistance form should have following features:

- Shape of the preparation should be like a box with flat floor (**Fig. 10.4**). This helps the tooth to resist occlusal masticatory forces without any displacement. Though it should be flat, at the same time it should follow the contour of occlusal surface (**Fig. 10.5**).





**Fig. 10.4:** Box shaped preparation to provide resistance form



**Fig. 10.6:** Amalgam-tooth interface should have butt joint

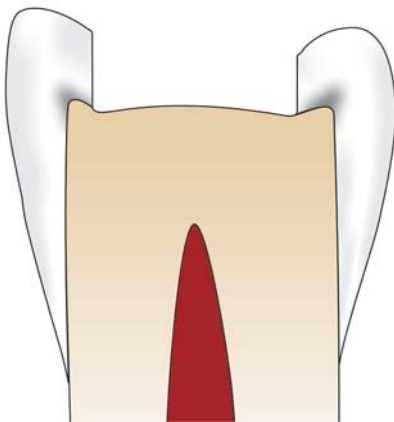
- To provide adequate thickness of amalgam keep the minimum occlusal depth of 1.5 mm.
- Provide the cavosurface angle of  $90^\circ$  (**Fig. 10.6**).
- Restrict the extension of external walls so as to have strong marginal ridge areas with sufficient dentin support.
- Include all the weakened tooth structure.
- Round off all the internal line and point angles (**Figs 10.7A and B**).
- Consider capping of cusp for preserving cuspal strength.

#### Primary Retention Form

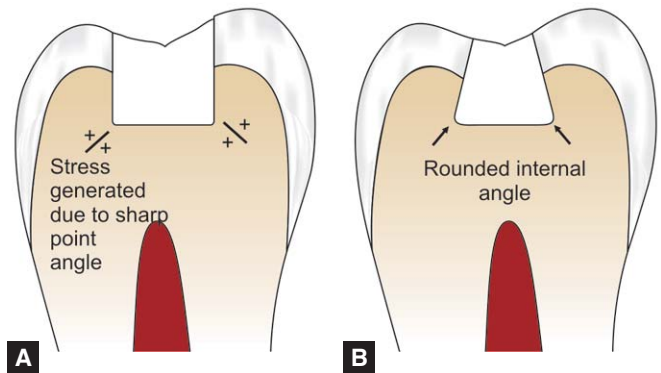
Primary retention form prevents the restoration from being displaced.

Retention can be increased by the following:

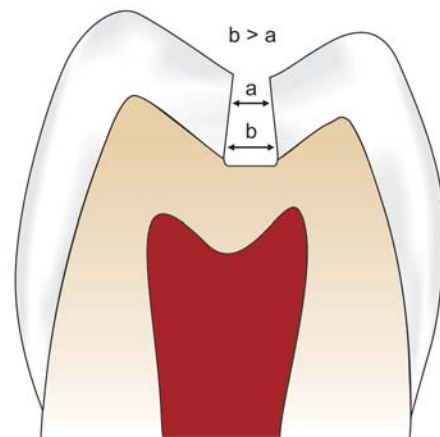
- Occlusal convergence (about 2 to 5%) of buccal and lingual walls (**Fig. 10.8**).
- Giving slight undercut in dentin near the pulpal wall (**Figs 10.9A and B**).



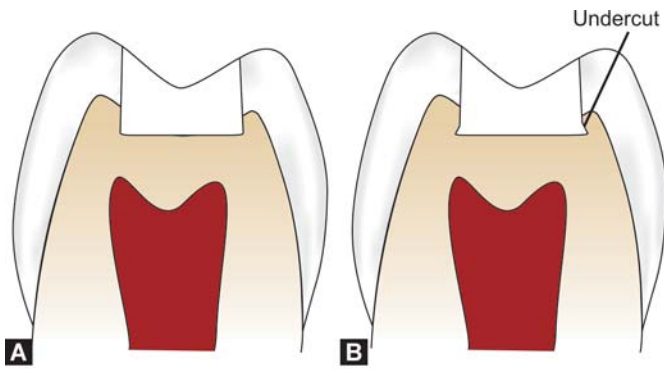
**Fig. 10.5:** Though pulpal floor is flat but it should follow the contour of occlusal surface



**Figs 10.7A and B:** Internal angles of preparation should be round; (A) Sharp angles lead to stress concentration, (B) Rounded internal angle



**Fig. 10.8:** Convergence of walls to provide retention to amalgam restoration



**Figs 10.9A and B:** Undercuts in dentin wall to provide retention of restoration

- Conserving the marginal ridges.
- Occlusal dovetail.

### Convenience Form

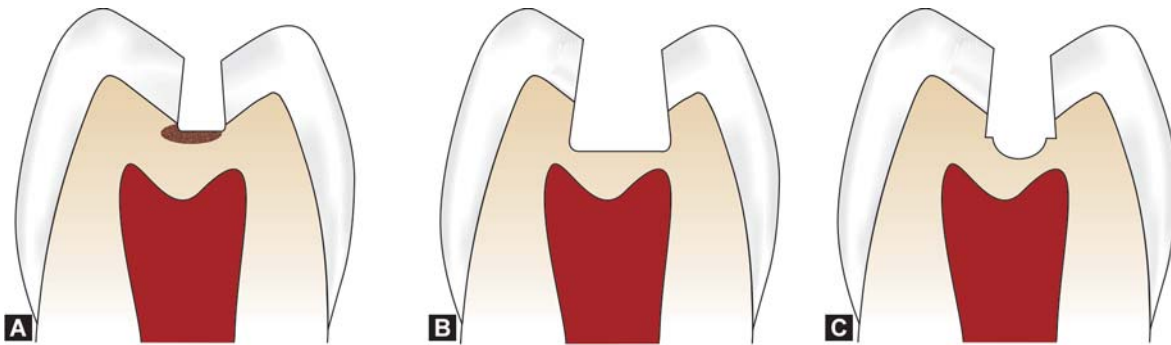
The convenience form of the preparation facilitates and provides sufficient visibility, accessibility and ease of operation in preparation and restoration of the tooth. For amalgam restoration, it is the form or shape that also permits access of condensing and carving instruments.

## 2. Final Tooth Preparation

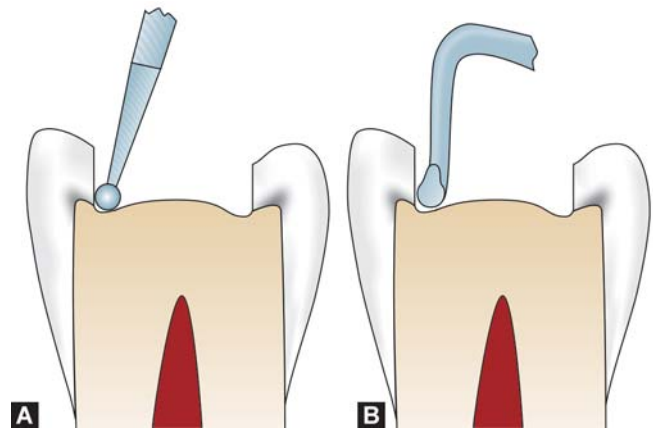
### Removal of Remaining Carious Dentin

In this, remaining caries, old restorative material and adjacent deep pits and fissures are also removed and involved in the preparation.

In the large preparations with soft caries, the removal of carious dentin is done with spoon excavator or slow speed round bur (**Figs 10.10A and B**). In this, two-step pulpal floor is made, i.e. only portion of tooth which is affected by caries is removed, leaving the remaining, floor untouched (**Figs 10.11A to C**).



**Figs 10.11A to C:** (A) Caries present beyond tooth preparation, (B) Overpreparation of tooth in an attempt to involve caries, (C) Stepped pulpal floor to involve carious lesion



**Figs 10.10A and B:** (A) Removal of remaining caries using round bur, (B) Removal of caries using spoon excavator

### Protection of Pulp if Needed

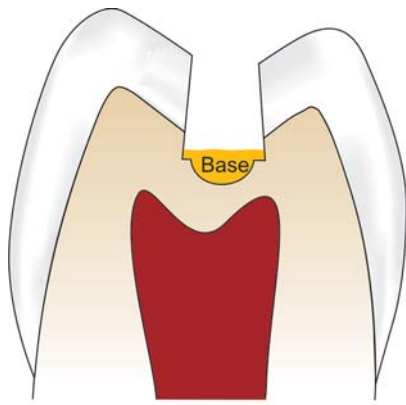
Use of pulp protective materials depends upon following factors:

- A base is not needed in shallow preparations, as it compromises thickness and thus compressive strength of amalgam.
- In a deep preparation, a base is placed on the deepest part in the thickness of 0.5 to 0.75 mm, so as to protect pulp (**Fig. 10.12**).

Be sure that no trace of the base material remains on enamel walls of preparation (**Fig. 10.13**), as this would eventually dissolve in the oral fluids leaving a gap between the restoration and the tooth resulting in microleakage and recurrent caries.

The selection of bases for amalgam restorations are based on two factors:

- It should have sufficient strength to support the forces of amalgam condensation
- It should be able to strengthen the restoration under masticatory stresses.



**Fig. 10.12:** In deep preparations, base is applied on pulpal floor so as to protect pulp

The strength of the bases depends upon the size, thickness and mechanical properties of base along with preparation design, position and amount of occlusal load.

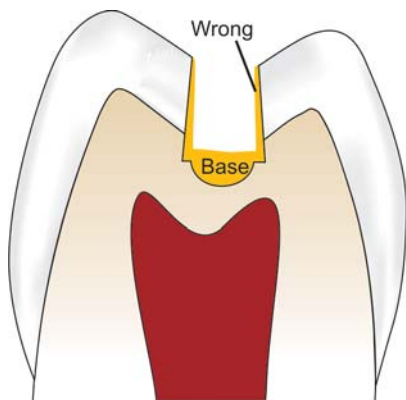
#### *Finishing of the Enamel Walls and Margins*

Finishing of walls and margins is guided by the knowledge of dental histology. At this stage all unsupported enamel is removed. Cavosurface angle, i.e. angle between enamel wall and amalgam interface should be made 90° butt joint type. This provides bulk to restoration, which in turn provides maximum strength.

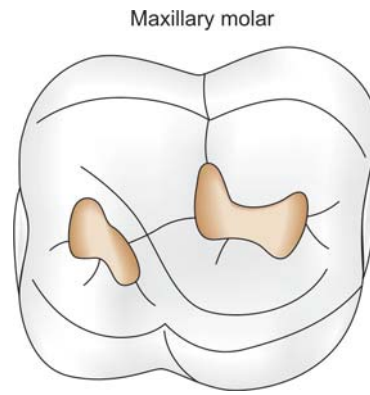
#### *Final Cleaning and Inspection of the Preparation*

The final stage of tooth preparation is to clean the preparation thoroughly with water and air spray. Then dry it with moist air and inspect it for final approval.

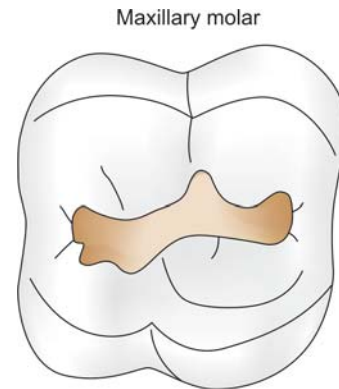
### **Tooth Preparation on Occlusal Surface of Different Teeth (Figs 10.14 to 10.16)**



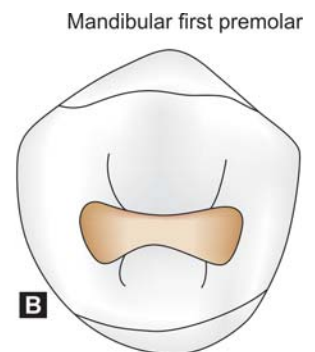
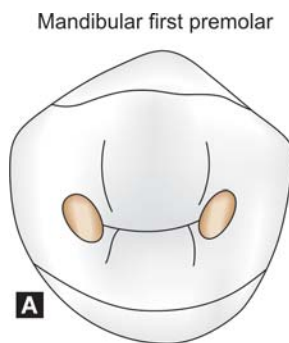
**Fig. 10.13:** Do not place base on walls as it would ultimately dissolve in oral fluids, leaving a gap between tooth and restoration



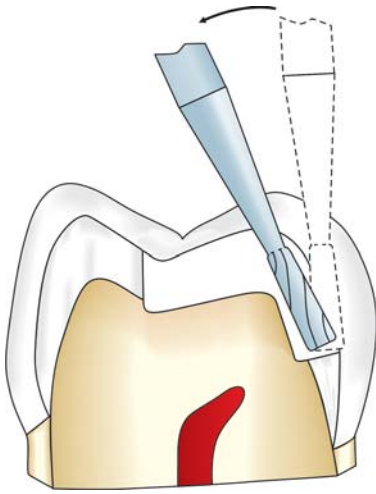
**Fig. 10.14:** Conservative tooth preparation on occlusal surface of maxillary first molar showing preservation of oblique ridge



**Fig. 10.15:** Conventional tooth preparation of maxillary first molar involving oblique ridge



**Figs 10.16A and B:** (A) Conservative class I preparation of mandibular first premolar, (B) Conventional class I preparation of mandibular first premolar



**Fig. 10.17:** Tooth preparation on occlusal surface with buccal or lingual extension

### Tooth Preparation on Occlusal Surface with Buccal or Lingual Extension (Fig. 10.17)

- For removal of caries from buccal or lingual pits and fissures, slight modification in preparation is needed.
- In this, extend the pulpal floor in the same plane to include the caries.
- Make a box type preparation with mesial and distal walls parallel.
- Place retention grooves in the mesial and distal walls.
- Remove all the unsupported enamel by using slow speed bur.
- Finally inspect the preparation to evaluate the need of additional cleaning and additional finishing.

### CLASS II TOOTH PREPARATION FOR AMALGAM RESTORATION

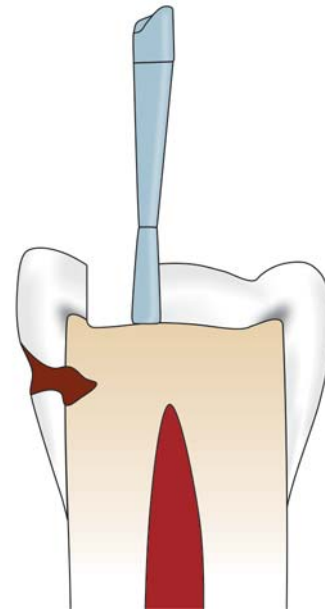
Class II restoration involves the proximal (mesial or distal) surfaces of premolars and molars.

Class II preparation is initiated same as Class I preparation, i.e. entrance through occlusal surface.

Outline of proximal preparations is controlled by the following factors:

- Caries susceptibility of the patient.
- Age of the patient.
- Position of gingiva
- Extent of the caries on the proximal side.
- Dimensions of the contact area
- Masticatory forces.
- Esthetic requirement of the patient.

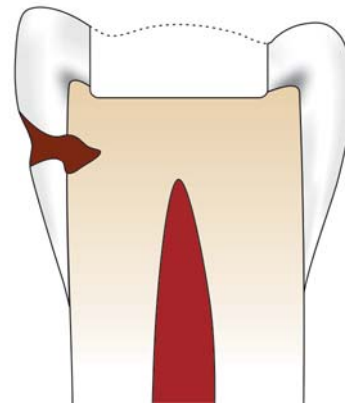
**Outline form:** The outline form for occlusal portion follows the same principles as given for pit and fissure lesions except



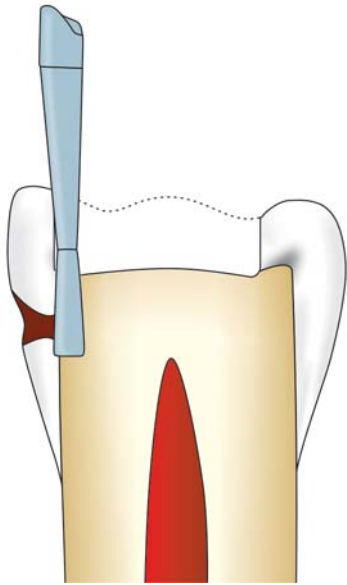
**Fig. 10.18:** Extend the bur keeping it parallel to the long axis of tooth

that the external outline is extended proximally toward defective proximal surface.

- Using high-speed bur with air water spray, enter the pit on occlusal surface which is nearest to the involved proximal surface. Keep long axis of the bur parallel to the long axis of the tooth and maintain the initial depth of 1.5 to 2.0 mm (**Fig. 10.18**).
- Extend the outline to include the central fissure while maintaining uniformity in depth of pulpal floor (**Fig. 10.19**).
- Make isthmus width as narrow as possible, but not wider than one-fourth the intercusp tip distance.
- Give slight occlusal convergence to facial, lingual and proximal walls (in caries free side), this provides favorable retention for amalgam.

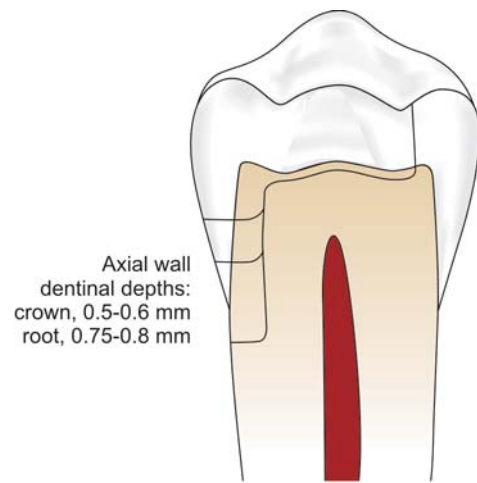

**Fig. 10.19:** Make the occlusal box with the uniform depth of pulpal floor



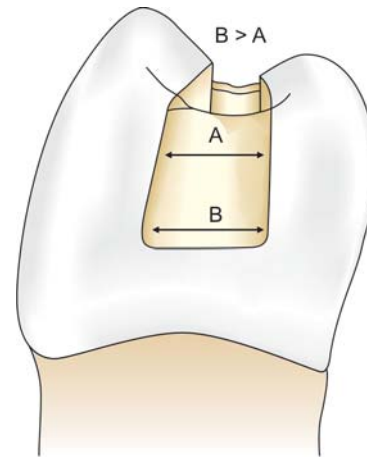
**Fig. 10.20:** Extend the preparation ending short by 0.8 mm of cutting through marginal ridge

- Consider enameloplasty wherever required to conserve tooth structure.
- Visualize the proximal box relative to contact area before extending into proximal marginal ridge, this will prevent the over extension of the occlusal outline form.
- Outline form in the proximal area is primarily determined by the faciolingual position of the contact area and the extent of carious lesion. External outline form on the occlusal portion is extended to just break contact with the adjacent tooth.
- While maintaining the established pulpal depth and with the bur held parallel to the long axis of the tooth, extend the preparation towards the contact area of the tooth, ending short by 0.8 mm of cutting through the marginal ridge (**Fig. 10.20**). The proximal cutting is sufficiently deep into the dentin (0.5-0.6 mm) so that retentive locks are prepared into axiolingual and axiofacial line angles (**Fig. 10.21**).
- Widen the preparation faciolingually to just clear the contact areas. The proximal cut is diverged gingivally. In other words, faciolingual dimension at the gingival surface is greater than the occlusal surface, this provides good retention and conservation of marginal ridge (**Fig.10.22**).
- Keep a small slice of enamel at the contact area to prevent accidental damage to the adjacent tooth (**Fig. 10.23**). If there is any doubt that accidental damage to the adjacent tooth can occur, use a metal matrix band interdentally. This will offer some protection to the adjacent tooth.

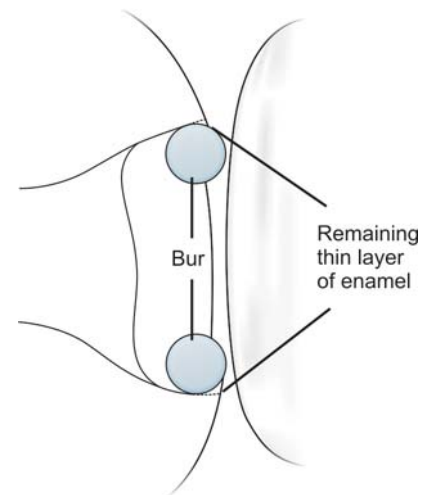


Axial wall  
dentinal depths:  
crown, 0.5-0.6 mm  
root, 0.75-0.8 mm

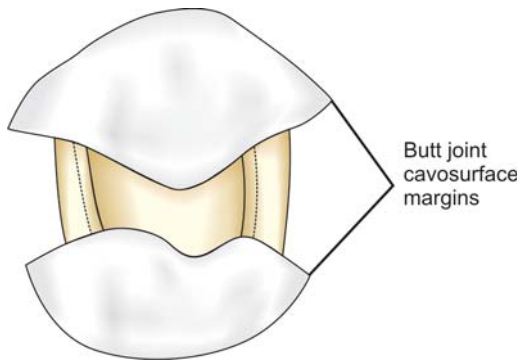
**Fig. 10.21:** Proximal cutting should be sufficiently deep into dentin



**Fig. 10.22:** Faciolingual dimension of proximal box are more at gingival surface than at occlusal



**Fig. 10.23:** A small slice of enamel is kept at contact area so as to prevent accident damage to adjacent tooth



**Fig. 10.24:** The cavosurface margins should be 90° with occlusal convergence

- Fracture the slice of enamel in the region of the contact area with a small chisel or enamel hatchet.
- Proximal margins should have a cavosurface angle of 90° and when completed, the walls of the proximal box should converge occlusally (**Fig. 10.24**).
- It is important to conserve the tooth tissue so that the tooth remains as strong as possible and occlusal forces placed on the amalgam are as small as possible.
- Ideal clearance of facial and lingual margins of the proximal box should be 0.2 to 0.5 mm from the adjacent tooth (**Fig. 10.25**).

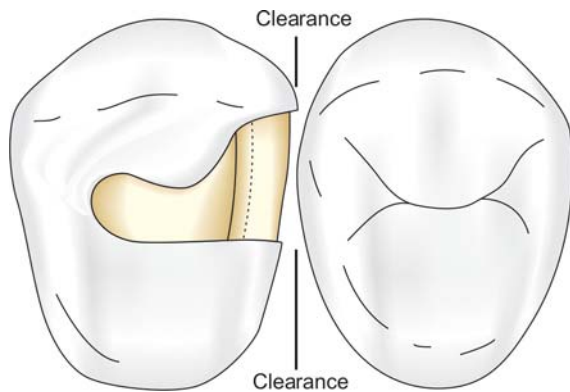
The directions of the buccal and lingual proximal walls are affected by morphology of tooth, anatomy and relationship with the adjacent tooth.

In this buccal and lingual proximal margins are extended:

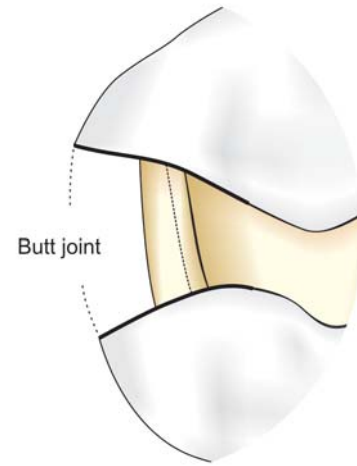
1. To include all the defects
2. To break contact with the adjacent tooth so to provide convenience form and accessibility.

### Reverse Curve

In the preparation of a class II amalgam restoration, extension of the preparation in the proximal area is important



**Fig. 10.25:** The ideal clearance of facial and lingual margins of proximal box should be 0.2 to 0.5 mm from adjacent tooth



**Fig. 10.26:** Reverse curve is given to the proximal walls by curving them towards the contact area

for elimination of caries and breaking proximal contacts. But in teeth with broader contacts, reverse-S shape curve is given to both widen the box yet remove less tooth structure. Reverse curve is given to the proximal walls by curving them inwards towards the contact area (**Fig. 10.26**). If excessive flare is given in these teeth, proximal walls will end past the axial angle of tooth through the cusps resulting in weakening of tooth structure and fracture of restoration. Reverse curve has following advantages:

- Conserves the sound tooth structure.
- Preserves the triangular ridge of the affected cusp.
- Flare of the proximal wall leaves the tangent to that outer tooth surface at 90° angle, this causes further increase in resistance for both tooth and restoration.

### Primary Resistance Form

This can be obtained by incorporating following features in the preparation:

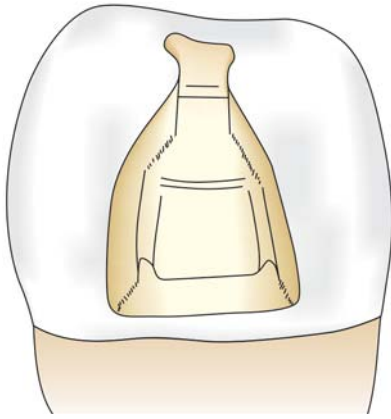
- Shape of the preparation like a box with flat pulpal and gingival floor.
- Cavosurface angle of 90°.
- Include all the weakened tooth structure.
- Maintain minimal width of the preparation so as to preserve tooth structure.
- Round off all the internal line and point angles.
- Consider capping of cusp for preserving cuspal strength.

### Primary Retention Form

Primary retention form prevents the restoration from being displaced.

Retention can be increased by the following:

- Occlusal convergence (about 2 to 5%) of buccal and lingual walls (**Fig. 10.27**).
- Occlusal dovetail.



**Fig. 10.27:** Occlusal convergence of buccal and lingual walls provide retention to amalgam restoration

### Final Tooth Preparation

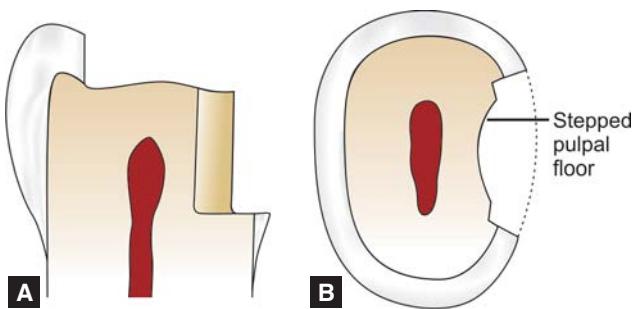
- During final preparation of tooth, clean it with air/water spray or with cotton pellet and inspect it for detection and removal of debris and examine for correction of all cavosurface angles and margins.
- Remove remaining caries, old restorative material and adjacent deep pit and fissure involved in the preparation as done in class I preparation.
- In the large preparations with soft caries, the removal of carious dentin is done with spoon excavator or slow speed round bur. In this, two step pulpal floor is made, i.e. only portion of tooth which is affected by caries is removed, leaving the remaining preparation floor untouched (**Figs 10.28A and B**).

### Secondary retention and resistance form

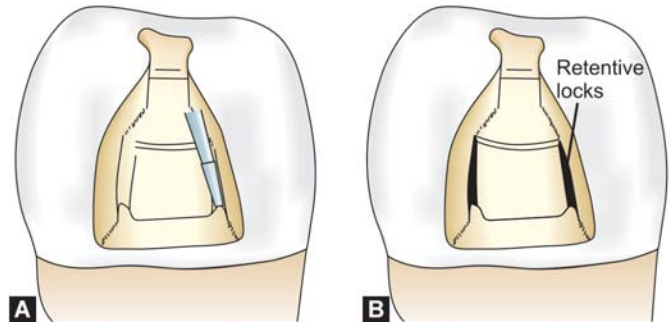
- Placing retention grooves and locks in the proximal box (**Figs 10.29A and B**).
- “Slots” and “Pot holes” in the gingival floor may be given to provide additional retention.

### Pulp protection

- Use pulp protective materials whenever needed as in class I restoration (**Fig. 10.30**).



**Figs 10.28A and B:** (A) Caries in axial wall extending towards pulp, (B) Removal of carious dentin only, resulting in stepped pulpal floor



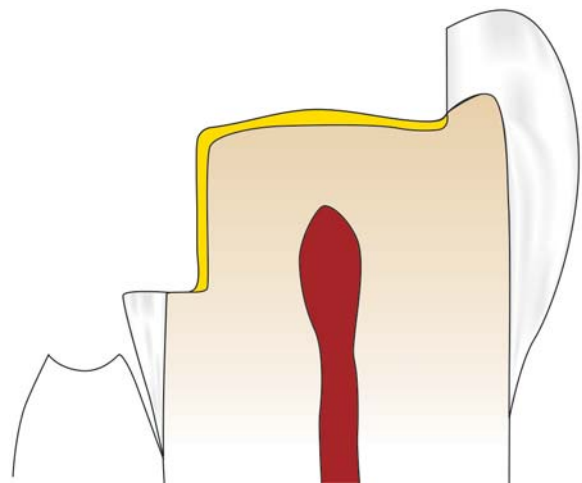
**Figs 10.29A and B:** Retention locks in the proximal box; (A) Preparation of locks using fissure bur, (B) Completed locks in proximal box

- **Finally finishing** of walls and margins is done by removing all unsupported enamel. Beveling of enamel portion of gingival wall is done with the help of gingival marginal trimmer. This helps to have full length enamel rods at the gingival margin (**Fig. 10.31**).
- Make cavosurface angle  $90^\circ$  butt joint type to provide bulk to restoration, which in turn provides maximum strength (**Fig. 10.32**).
- The final stage of **tooth preparation** is to clean the preparation thoroughly with water and air spray. Then dry it with moist air.

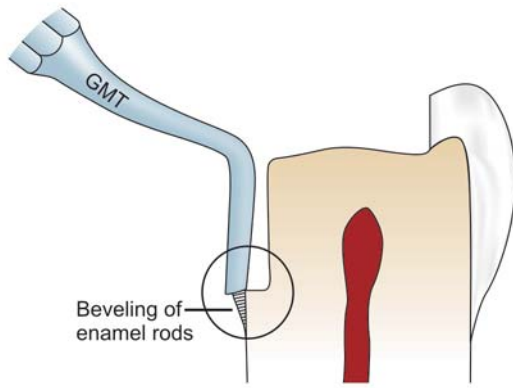
### Modifications in Class II Preparation Design

Sometimes depending upon following factors, various modifications are made in class II tooth preparation:

1. **Extent of caries:** In extensive caries, there can be need for complex amalgam restorations as full coverage restorations. In case of small proximal caries, instead of making ideal class II preparation, only proximal box can do.



**Fig. 10.30:** Base is applied on pulpal and axial wall in class II preparation

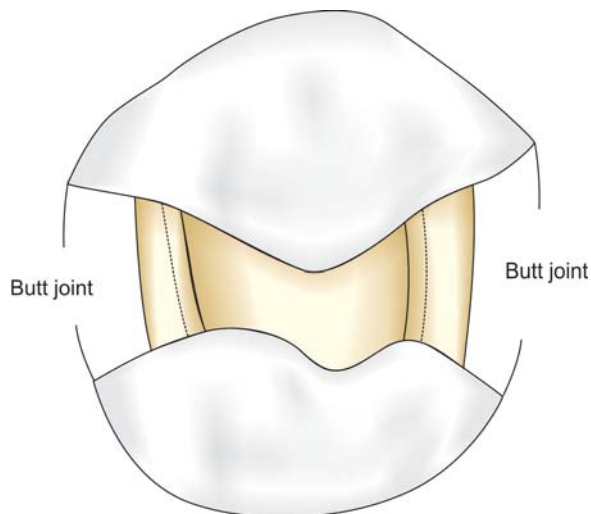


**Fig. 10.31:** Beveling of enamel portion of the gingival wall is done with the help of GMT

2. **Esthetic requirement:** In maxillary premolars, for aesthetics reasons, minimal facial extension is suggested so as to display less of amalgam.
3. **Relationship with adjacent tooth:** If adjacent tooth is missing, slot preparations are made for treating proximal caries.
4. **Requirements for abutment teeth for partial dentures:** Here modifications are done for providing retention to the prosthesis without compromising class II amalgam restoration.
5. **Rotated teeth:** Here preparation is modified according to contact with adjacent tooth.

#### Factors affecting class II preparation design

1. Extent of caries
2. Esthetic requirement
3. Relationship with adjacent tooth
4. Requirement for abutment tooth
5. Rotated teeth



**Fig. 10.32:** 90° cavosurface margin for amalgam restoration

#### Modifications in class II design

1. Slot preparation
2. Simple box preparation
3. Esthetic considerations
4. Rotated teeth
5. Unusual outline form
6. Conservative preparation for mandibular first premolar and maxillary molar
7. Adjoining restoration
8. Modification for abutment teeth

#### Slot Preparation

##### Indications

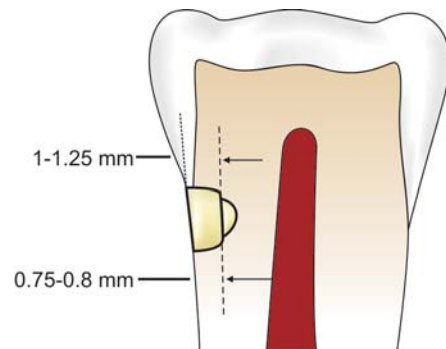
1. Proximal root caries in geriatric patients with gingival recession.
2. When adjacent tooth is missing.
3. When isolation is difficult in treating cervical one-third root caries.

**Design features:** It is similar to class V tooth preparation. Preparation is normally approached from the facial aspect. It is done with round bur no. 2 or no. 4 to a limited depth axially, i.e. 0.75-1.25 mm (**Fig. 10.33**). When occlusal margins are in enamel, extend the preparation 0.5 mm inside the dentin. Prepare 90° cavosurface margins, give retention grooves at axio-occlusal and axiogingival line angles. 0.2 mm inside the DEJ (**Fig. 10.34**).

#### Simple Box Preparation

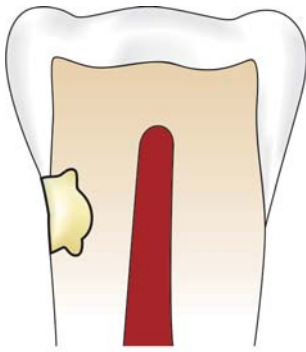
##### Indications

1. Small proximal caries, not involving the occlusal surface.
2. Proximal surface caries with narrow proximal contact.
3. Proximal caries in attrited teeth.



**Fig. 10.33:** The preparation is done with round bur keeping the axial wall depth 0.75 to 1.25 mm





**Fig. 10.34:** 90° cavosurface margins and retention grooves at axio-occlusal and axiokingival line angle of slot preparation

**Design features (Fig.10.35):** Prepare proximal box only with minimum facial and lingual extensions. For retention, converge facial and lingual extensions. Proximal retention locks are made for added retention in proximal box. These have 0.5 mm depth gingivally and 0.3 mm occlusally.

#### *Esthetic Considerations*

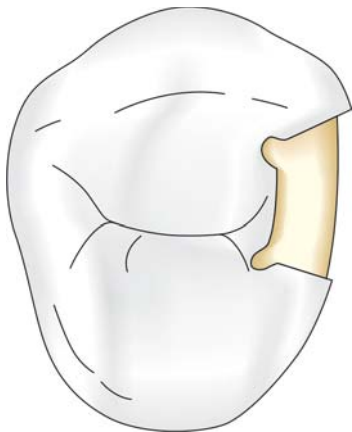
Sometimes modification is indicated for maxillary first premolar restoration to avoid unesthetic display of amalgam. Design feature for mesio-occlusal preparation, is that facial wall of proximal box is prepared straight parallel to long axis of the tooth.

#### *For Rotated Teeth*

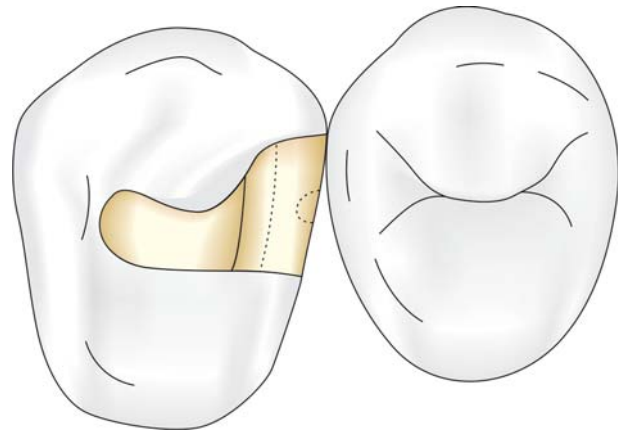
**Design features:** They are same as that of normally aligned teeth except that preparation depends on area of tooth which is in contact with adjacent tooth (**Fig. 10.36**).

#### *Unusual Outline Form*

If fissures are separated by 0.5 mm or more, restore the tooth with individual amalgam restorations. Until or unless



**Fig. 10.35:** Box preparation



**Fig. 10.36:** Class II tooth preparation for rotated teeth

fissure is emanating from occlusal surface, dovetail is not required.

#### *Conservative Preparation for Mandibular First Premolar and Maxillary Molar*

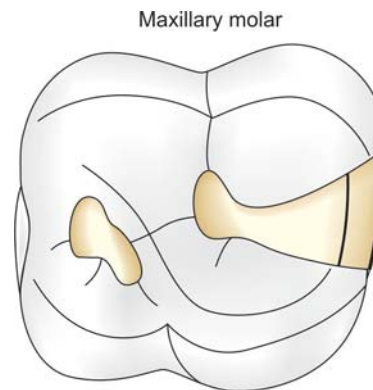
Conservative design in these teeth helps in the preservation of oblique ridge or the transverse ridge which protects the cuspal strength.

**Design features (Fig.10.37):** For maxillary first molar, mesio-occlusal and disto-occlusal preparations are made independently without oblique ridge. For mandibular first premolar, transverse ridge is not involved in proximal preparation (**Fig. 10.38**).

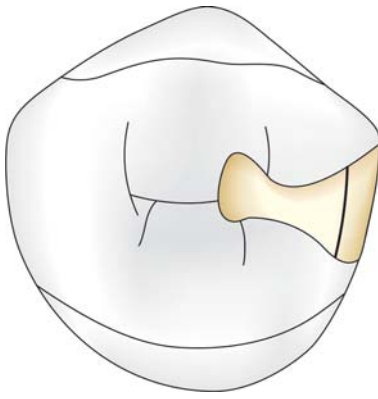
Also because of high facial pulp horn, pulpal floor should have facial inclination (**Fig. 10.39**).

#### *Adjoining Restoration*

If proximo-occlusal restoration is already present and a new restoration is required adjoining it, then care should be taken



**Fig. 10.37:** Conservative class II preparation in maxillary first molar. Here mesio-occlusal and distobuccal preparations are made independently without involving oblique ridge



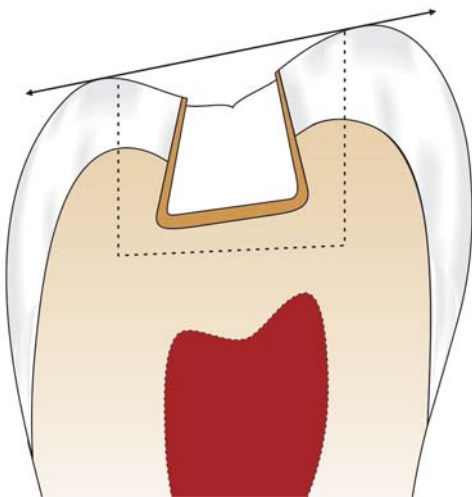
**Fig. 10.38:** Conservative class II preparation in mandibular first premolar not involving transverse ridge

while preparing the tooth for second restoration without weakening the margins of previous restoration. The intersecting margins of two restoration should be perpendicular to each other (**Fig. 10.40**).

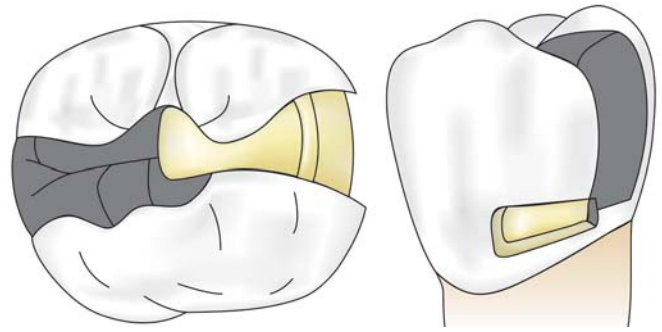
If a tooth has continuous class II and class V preparation, then prepare and restore class II lesion before class V.

#### *Modification for Abutment Teeth*

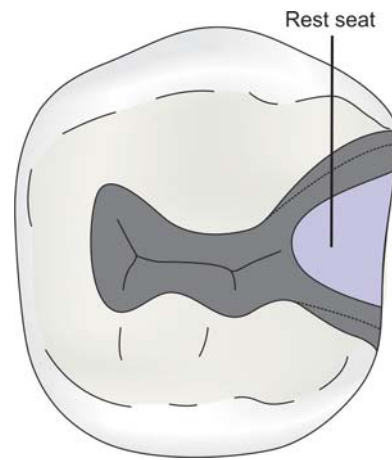
For abutment tooth, additional extension is required, if rest seat is planned for partial denture. For abutment teeth, facial and lingual walls are extended more for providing space rest seat (**Fig. 10.41**). Also pulpal floor is deepened 0.5 mm more in the area of rest seat so as to provide sufficient thickness for the amalgam (**Fig. 10.42**).



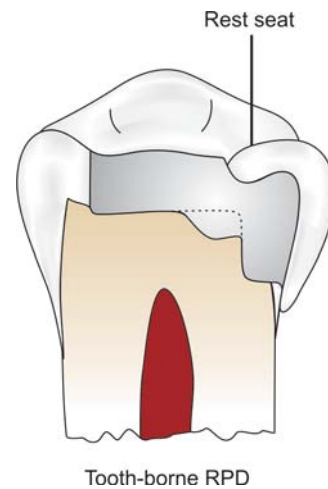
**Fig. 10.39:** Because of high facial pulp horn, pulpal floor should have facial inclination so as to avoid exposure



**Fig. 10.40:** New amalgam restoration should be placed adjacent to old restoration such that the intersecting margins of two restorations are perpendicular to each other



**Fig. 10.41:** For abutment teeth, facial and lingual walls are extended for providing rest seat



**Fig. 10.42:** Class II restoration showing rest seat and deepening of pulpal wall in the area of rest seat so as to provide sufficient amalgam bulk

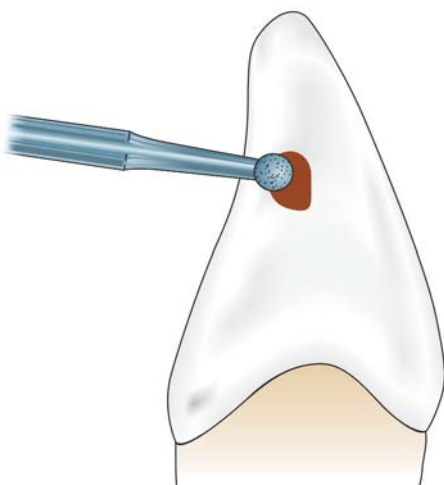
## CLASS III TOOTH PREPARATION FOR AMALGAM RESTORATION

Since amalgam is not esthetic restoration, it is not indicated for proximal surface of incisors and mesial surface of canines. Amalgam for class III restoration is indicated in the distal surface of maxillary and mandibular canines especially, if:

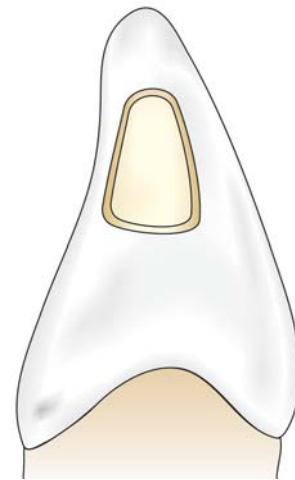
- Caries do not undermine distal slopes of canines.
- Labial axial angle is intact.
- Even after removal of caries, sufficient tooth structure is present.
- Restoration will not be directly loaded with occlusal forces.

### Initial Tooth Preparation

- Outline form includes only the proximal surface. Shape of preparation is like a triangle with round corners. Labial side of triangle conforms more to the anatomy than with lingual side.
- A no. 2 round bur is penetrated through enamel on distolingual marginal ridge (**Fig. 10.43**). Preliminary shaping of preparation is completed with inverted cone bur with long axis of bur keeping perpendicular to the lingual surface of the tooth.
- Outline form is completed when facial, gingival and lingual walls are formed (**Fig. 10.44**).
- Lingual wall should meet the axial wall at obtuse angle.
- Depth of bur should be 0.5 mm into the dentin.
- Cavosurface angle should be about 90° at all margins.
- Lingual margins should be in confines of lingual embrasure except for incisal and gingival turn extension,



**Fig. 10.43:** Entry of lesion is made through lingual side with the help of round bur

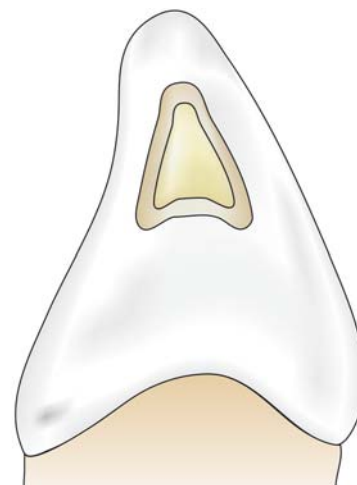


**Fig. 10.44:** Outline of class III preparation

later is indicated when lingual embrasure is not sufficiently wide to aid instrumentation.

### Final Tooth Preparation

- **Removal of any remaining infected dentin** is done using a slow speed round bur or/and spoon excavator.
- **Pulp protection** is by using base or liner.
- **Secondary resistance and retention form** is achieved by butt joint, rounded internal angles and sufficient bulk of amalgam. Retention is obtained by placing retention groove with a small round bur in the axiofaciogingival point angle and lingual dovetail (**Fig. 10.45**). Lingual dovetail is not required for small sized class III preparation. It is needed for large preparations. Lingual dovetail is prepared only when the preparation of



**Fig. 10.45:** Class III preparation with retention grooves

proximal portion is complete because otherwise tooth structure needed for isthmus between proximal portion and dovetail might be removed when the proximal outline form is prepared.

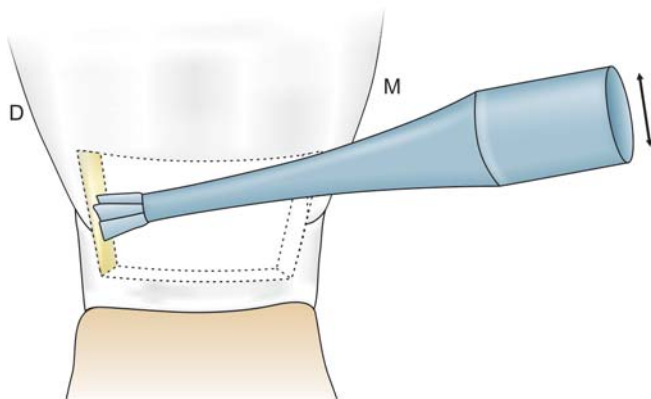
- **Finishing the external walls** is done to remove all unsupported enamel and to make cavosurface angle  $90^\circ$ . For rounding of junctions between different retentive grooves, angle former or GMT can be used.
- **Final cleaning and inspection of the preparation** is done by cleaning the preparation thoroughly with water and air spray and then drying it with moist air.

### CLASS V TOOTH PREPARATION FOR AMALGAM RESTORATION

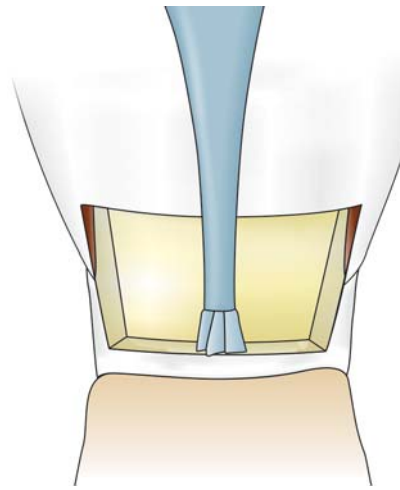
Class V lesion is present on the gingival third of facial and lingual surfaces of all teeth. Amalgam is not indicated for anterior teeth except when esthetics is of no concern, for example in very aged patients.

#### Initial Tooth Preparation

- The outline form of class V lesions is dictated by the extension of caries process. Like in others, prepare the tooth in normal manner, i.e. breaking down the undermined enamel and extending the preparation to the sound tooth structure. This is accomplished by using inverted cone bur held perpendicular to the long axis of tooth (**Fig. 10.46**).
- Initial axial wall depth should be 0.5 mm into the dentin. Axial wall depth at the occlusal wall should be more than at the gingival wall (**Fig. 10.47**). This will result in a curved axial wall which conforms to the contour of the tooth.



**Fig. 10.46:** Entry into lesion with the help of inverted cone bur

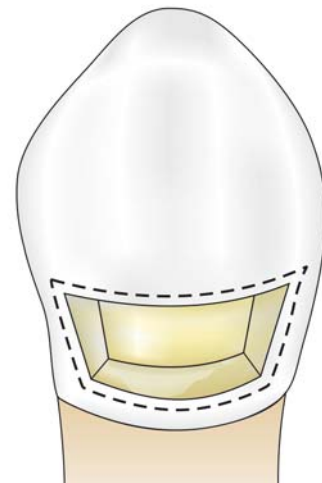


**Fig. 10.47:** Preparation of gingival wall

- Prepare the mesial and distal wall surfaces perpendicular to the outer tooth surface, paralleling the direction of enamel rods.

#### Final Tooth Preparation

- Remove any remaining caries using a round bur.
- Since preparation walls diverge towards the facial aspect, retention is mandatory in these preparations. Retention is made by giving grooves incisally and gingivally along axioincisal and axiokingival line angles using an inverted cone bur.
- To prevent secondary caries, extend the preparation close to but not to axial angles of the tooth. In young patients, it is extended under free margins of gingiva and in older patients, it is determined by extent of the lesion.
- Finally, hoes and chisels are used to finish the mesial, distal and gingival walls (**Fig. 10.48**).



**Fig. 10.48:** Completed class V preparation

- In the last, inspect the preparation using clean air and water spray followed by drying.

## CLASS VI TOOTH PREPARATION FOR AMALGAM RESTORATION

Class VI tooth preparation involves restoration of incisal edge of anterior teeth or the cusp tip of posterior teeth. For class VI preparations in anterior teeth, amalgam is usually not filled because of poor esthetics. For posterior teeth it is indicated because of its satisfactory wear resistance.

Indications of restoration of class VI lesions with amalgam:

- In teeth where because of too much wear, enamel is gone and the underlying dentin has become carious, commonly seen in geriatric patients.
- In the hypoplastic cusp tip as these are more prone to caries.

### Steps of Tooth Preparation (Fig. 10.49)

- Penetrate the enamel with a small tapered fissure bur extending to the depth of 1.5 mm.
- Prepare a 90° cavosurface margin on enamel.
- Make small undercuts along the internal line angles to provide retention.

## STEPS OF AMALGAM RESTORATION

### Steps of amalgam restoration

1. Selection of amalgam alloy
2. Mercury–alloy ratio
3. Trituration
4. Mulling
5. Application of matrix band
6. Insertion of amalgam
7. Condensation
8. Burnishing
9. Carving
10. Finishing and polishing

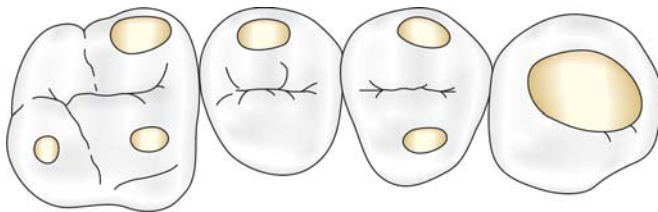


Fig. 10.49: Class VI preparation for amalgam restoration

## Selection of Amalgam Alloy

- If restoration undergoes high occlusal stresses, choose amalgam with high resistance to marginal fracture.
- Patients with psychological problems or other diseases, requiring early disposal, indicate the use of fast setting alloy.
- In wider and broader preparations, alloy with low creep values is preferred.

## Mercury-Alloy Ratio

Mercury is basically required to wet the alloy particles before they can react. Eames has preferred 1:1 ratio of alloy/mercury for best results. Lathecut amalgam alloys require more (45%) of mercury to wet than the spherical alloys (40%).

## Trituration

The purpose of trituration is to remove oxide layers from the alloy particles so as to coat each alloy particle with mercury, resulting in a homogeneous mass for condensation. Trituration can be done by hand or mechanical means. Signs of a good mix amalgam is shiny, homogeneous mass that adheres together.

## Mulling

Mulling is done so that all alloy particles are properly coated with mercury. It can be done by squeezing the freshly mixed amalgam collected in the chamois skin. Mechanical mulling is done in the amalgamator by trituring it for one to two seconds.

## Application of Matrix Band

Place the matrix band in the matrix retainer. Pass the matrix band between the contact points so that its lower edge comes just over the cervical margin of the preparation. Tighten the band and stabilize it using wedges.

## Insertion of Amalgam

Pick a small amount of amalgam alloy with the help of amalgam carrier and transfer it to the preparation. Proximal box should be filled before the occlusal part of the preparation. Apply firm pressure on the amalgam mass for adequate condensation. After it, add next increment and again condense it.

## Condensation

Different sizes of condensers are used for amalgam condensation. Working end of a condenser is usually serrated.

One should shrinkage start condensation within three minutes of trituration and apply adequate force for condensation.

### Burnishing

Precurve burnishing is done after condensation. Amalgam is overfilled and burnished immediately with heavy strokes so as to improve marginal adaptability of the restoration and remove excess mercury from overpacked amalgam.

#### *Postcarve Burnishing*

Postcarve burnishing is done after completion of carving with the help of small sized burnishers using light strokes. *It is done to* reduce number of voids on surface of restoration and to produce denser amalgam at margins.

### Carving

For adequate carving, it is preferable to overpack the preparation and then carve it to the margins. The carving instruments should have discoid and cleoid blade design. Larger instrument is used first, followed by smaller instruments. In proximal tooth preparation, carving of the cervical margins should begin following the removal of matrix band. Loosen the band and then wedge before carving because axial and cervical margins become accessible after removal of band.

Trim the axial margins towards the gingiva in downward direction with a sharp carver. Carve the occlusal surface with a sharp carver like hollenback. Hold it in the way so that its blade lies across the margin of the restoration, half on tooth and half on restoration. Define marginal ridge and occlusal embrasure using a sharp explorer. Remove any overhanging margins in the interdental region, if present.

### Finishing and Polishing

Finishing amalgam restorations involves removal of marginal irregularities, defining anatomical contours, and smoothening the surface roughness of the restoration. Polishing is done to achieve a smooth, shiny luster on the surface of the amalgam. Finishing is done before polishing by use of abrasive agents that are coarse enough to remove the bulk from the surface. Polishing requires mildly abrasive materials for producing smooth and shiny surface of amalgam restoration.

Finishing and polishing of the restorations should be done at least 24 hours after the placement of the amalgam. Premature finishing and polishing will interfere with the crystalline structure of the hardening amalgam. The result will be a weakened restoration.

### VIVA QUESTIONS

- Q. What is class I tooth preparation?
- Q. What is ideal depth of pulpal floor for class I amalgam restoration?
- Q. How do you achieve primary resistance form in class I amalgam restorations?
- Q. How do you achieve primary retention form in class I amalgam restorations?
- Q. What are different factors which affect outline form of class II amalgam restoration?
- Q. What is depth of axial wall in class II preparation for amalgam?
- Q. What should be the ideal clearance of facial and lingual margins of proximal box from the adjacent tooth?
- Q. What is reverse curve?
- Q. What are advantages of reverse curve?
- Q. What is slot preparation?
- Q. What are indications of class III tooth preparation for amalgam restoration?
- Q. How do you achieve secondary retention form in class III preparation?
- Q. What is shape of class V tooth preparation for amalgam?
- Q. What are indications of class VI tooth preparation for amalgam restoration?
- Q. How do you modify class II tooth preparation for amalgam in case of maxillary premolars and first molar for aesthetic reasons?

# Composite Restorations

## Chapter 11

### INTRODUCTION

#### COMPOSITION OF COMPOSITES

- Organic Matrix
- Fillers
- Coupling Agent
- Coloring Agents
- UV Absorbers
- Initiator Agents
- Inhibitors

#### CLASSIFICATION OF COMPOSITES

##### TYPES OF COMPOSITE RESINS

- Macrofilled Composite Resins
- Microfilled Composite Resins
- Hybrid Composite Resins

##### RECENT ADVANCES IN COMPOSITES

- Flowable Composite Resins
- Condensable (Packable) Composites
- Giomers
- Compomers (Polyacid Modified Composite Resins)
- ORMOCER (Organically Modified Ceramic)
- Antibacterial Composites/Ion Releasing Composites
- “Smart” Composites

#### PROPERTIES OF COMPOSITE RESTORATIVE MATERIALS

- Coefficient of Thermal Expansion
- Water Absorption
- Wear Resistance
- Surface Texture
- Radiopacity
- Modulus of Elasticity
- Solubility
- Creep
- Polymerization Shrinkage
- Configuration or “C-factor”
- Esthetics of Composites
- Microleakage and Nanoleakage

- Biocompatibility
- Working and Setting Times

#### POLYMERIZATION OF COMPOSITES

- Curing Time
- Shade of Composite
- Distance and Angle between Light Source and Resin
- Temperature
- Resin Thickness
- Inhibition of Air
- Intensity of Curing Light
- Type of Filler

#### INDICATIONS OF COMPOSITE RESTORATIONS

#### CONTRAINDICATIONS OF COMPOSITES

#### ADVANTAGES OF COMPOSITES

#### DISADVANTAGES OF COMPOSITES

#### TOOTH PREPARATION FOR COMPOSITE RESTORATIONS

##### CLASS III TOOTH PREPARATION

- Conventional Class III Tooth Preparation
- Beveled Conventional Class III Tooth Preparation
- Modified (Conservative) Class III Tooth Preparation

##### CLASS V TOOTH PREPARATION

- Conventional Class V Preparation
- Beveled Conventional Class V Tooth Preparation
- Modified (Conservative) Class V Tooth Preparation

#### RESTORATIVE TECHNIQUE FOR COMPOSITES

- Pulp Protection
- Etching of the Tooth Preparation
- Application of Adhesive System
- Matrix Application
- Composite Placement
- Final Contouring, Finishing and Polishing of Composite Restoration
- Checking the Occlusion
- Glazing

#### FAILURES IN COMPOSITE RESTORATIONS

## INTRODUCTION

The modern history of tooth colored restorative materials was started with silicate cement which was introduced by Fletcher in the year 1878 in England, which was further encouraged by Steenback and Ashor in 1903. Silicate cements were discouraged later on because of their poor strength, irritation to pulp tissue and brittleness. Moreover tooth preparations for silicate cement need to be of the conventional type.

Self-curing acrylic resins were developed in 1930 in Germany, but they became popular in dentistry in late 1940s. They were used as veneers on the facial surface of metal restorations and as facings in crowns and bridges. But they too showed poor physical properties like high polymerization, shrinkage and coefficient of thermal expansion (CTE), lack of wear resistance, poor marginal seal, irritation to pulp and dimensional instability.

In an attempt to improve their properties, R Bowen, in 1962, developed a polymeric dental restorative material reinforced with silica particles used as fillers. These materials were called 'composites'. Thus we can say that composite resins have been introduced in operative dentistry to overcome the drawbacks of the acrylic resins that replaced silicate cements in the 1940s. Over the past two decades, there has been a substantial progress in the development and application of resin-based composites. Earlier composites were recommended only as a restorative material for anterior restorations, but now they have become one of the most commonly used direct restorative materials for both anterior and posterior teeth. This is because of better understanding of their application methods, including composite placement and curing and improvement of their physical and mechanical properties. The principal reasons for the shifting from dental amalgam to composites are the reduced need for preparation and the strengthening effect on the remaining tooth. Roeters et al have said once that the introduction of resin composites is not just a change in materials and techniques but also a change in treatment philosophy. Nowadays, composite resins are considered as an economical and aesthetic alternative to other direct and indirect restorative materials. They can be used in different clinical conditions like diastema closures, veneers for anterior teeth and restorations for Class I, II, III, IV and V conservative restorations. If properly manipulated, they can prove the success rate and longevity equal to those of other materials. Since composite do not have self-adhering property, an adhesive is required before their placement. Placement of a composite resin is very technique-sensitive than the placement of other restorations.

By definition, a composite is a compound composed of at least two different materials with properties which are superior or intermediate to those of an individual component.

Dental composite resins have two primary components which are matrix phase and the filler phase and many secondary components like polymerization initiators, pigments for providing different shades and silane coupling agents. Though secondary components are required for every composite material, most of the properties of material are dependent upon filler and matrix phases.

Although different composite materials have specific composition and distribution of the matrix and filler particles, they are often composed of bisphenol-A-diglycidyl-methacrylate (Bis-GMA) or urethane di-methacrylate (UDMA) matrix polymers and glass filler particles. Both the amount and the size of the filler particles determine mechanical properties of different composites.

### History of composite resins (From 1901 to 2007)

1901	Synthesis and polymerization of methyl methacrylate
1930	Use of PMMA as denture base resin
1944	First acrylic filling material
1951	Addition of inorganic fillers to direct filling materials
1955	Acidetch technique introduced by Buonocore
1956	Bowen investigated dimethacrylates (Bis-GMA) and silanized inorganic filler
1962	Introduction of silane coupling agents
1964	Marketing of Bis-GMA composites
1968	Development of polymeric coatings on fillers
1973	UV-cured dimethacrylate composite resins
1976	Introduction of microfilled composites
1977	Visible light cured dimethacrylate composite resins
1996	Development of flowable composites
1997	Development of packable composites
1998	Development of fiber reinforced, ion releasing composites and ormocers.

## COMPOSITION OF COMPOSITES

Composites are basically modified methacrylates or acrylates with other ingredients to produce different structures and properties. The methacrylates are used because of their refractive index of 1.3 which is close to tooth. This allows metamorphism (chameleon effect) giving the effect of similarity since methacrylates shrinks, inorganic inert filler particles of similar refractive index are added.

In general, dental composites are composed of following materials (**Fig. 11.1**):

- Organic matrix or organic phase
- Inorganic matrix
- Filler or disperse phase
- An organosilane or coupling agent



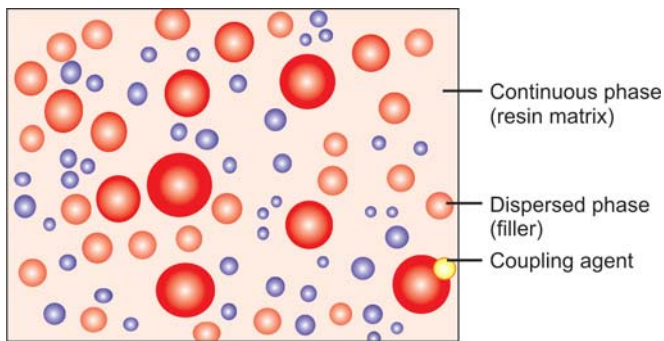


Fig. 11.1: Composition of composite resin

- Activator–initiator system
- Inhibitors
- Coloring agents.

#### Composition of composites

##### Organic resins

- Bis-GMA (Bowen's resin)
- Dipentaerythritol pentaacrylate monophosphate
- Urethane dimethacrylate
- Urethane tetramethacrylate
- Hexamethylenediisocyanate

##### Fillers

- Fused or crystalline quartz
- Silicon dioxide
- Borosilicate/Lithium aluminosilicate glass
- Ceramics
- Ytterbium trifluoride
- Radiopaque silicates
- Organically modified ceramics (ORMOCERS)

##### Others

- Triethyleneglycol dimethacrylate (TEGDMA)
- HEMA
- Camphorquinone (CQ)
- META; phosphorated esters
- Silane coupling agents
- Antibacterial monomers
- Benzoyl peroxide and amine activator

### Organic Matrix

The matrix base consists of polymeric mono-, di- or tri-functional monomers like Bis-GMA or UDMA. The monomer system represents as the backbone of the composite resin system. Most preferred monomer is Bis-GMA either alone or in conjunction with urethane dimethacrylate UDMA. Since this resin is very viscous, in order to improve clinical handling, it is diluted with low viscosity monomers to control the viscosity. These can be bisphenol A dimethacrylate (Bis-DMA), ethylene glycol dimethacrylate (EGDMA), triethylene glycol dimethacrylate (TEGDMA), methyl methacrylate (MMA). Bis-GMA and

TEGDMA have been tried in the ratio of 1:1 and 3:1, latter is preferred because an increase in TEGDMA increases the chances of polymerization shrinkage.

### Fillers

The dispersed phase of composite resins is made up of an inorganic filler material. Since filler particles are added to improve the physical and mechanical properties of the organic matrix, the basic aim is always to incorporate high percentage of filler. Commonly used fillers are silicon dioxide, boron silicates and lithium aluminium silicates. The filler particles are silanated so that the hydrophilic filler can bond to the hydrophobic resin matrix. The wear of composite restorations depends on filler particle size, interparticle spacing and filler loading. Composites with smaller particles show decreased wear due to fewer voids and smaller interparticle spacing.

#### Addition of filler causes following effects

- Reduces the thermal expansion coefficient
- Reduces polymerization shrinkage
- Increases abrasion resistance
- Decreases water sorption
- Increases tensile and compressive strengths
- Increases fracture toughness
- Increases flexure modulus
- Provides radiopacity
- Improves handling properties
- Increases translucency

In some composites, the quartz is partly replaced with heavy metal particles like zinc, aluminium, barium, strontium or zirconium. Nowadays calcium metaphosphate has also been tried. Since these are less hard than glass, they cause less wear on the opposing tooth.

Recently nanoparticles having the size of 25 nm and nanoaggregates of 75 nm, made up of zirconium/silica or nanosilica particles have also been introduced. The smaller size of filler particles results in better finish to the restoration.

### Coupling Agent

Interfacial bonding between the matrix phase and the filler phase is provided by coating the filler particles with silane coupling agents. In other words a coupling agent is used to bond the filler to the organic resin. This agent is a molecule with silane groups at one end (ion bond to  $\text{SiO}_2$ ) and methacrylate groups at the other.

#### Functions of Coupling Agents

- Bonding of filler and resin matrix.
- Transfer forces from flexible resin matrix to stiffer filler particles.

- Prevent penetration of water along filler resin interface, thus provide hydrolytic stability.  
*Examples:* Organic silane

### Coloring Agents

Coloring agents are used in very small percentage to produce different shades of composites. Mostly metal oxides such as titanium oxide and aluminium oxides are added to improve the opacity of composite resins.

### UV Absorbers

They are added to prevent discoloration, in other words they act like a “sunscreen” to composites. Commonly used UV absorber is Benzophenone.

### Initiator Agents

These agents activate the polymerization of composites. Most common photoinitiator used is camphoroquinone. Currently most recent composites are polymerized by exposure to visible light in the range of 410-500 nm.

Initiator varies with type of composites whether it is light cured or chemically cured.

### Inhibitors

These agents inhibit the free radical generated by spontaneous polymerization of the monomers. For example, Butylated hydroxyl toluene (0.01%).

#### Difference between chemically cured and light cured composites

<i>Chemically cured</i>	<i>Light cured</i>
<ul style="list-style-type: none"> <li>• Polymerization initiated</li> <li>• Less color stability</li> <li>• Curing is done in single step, i.e. at one time</li> <li>• Very less working time</li> <li>• Setting time is long</li> <li>• Less aesthetics</li> <li>• Economical</li> <li>• More polymerization shrinkage</li> <li>• Less abrasion resistance</li> </ul>	<ul style="list-style-type: none"> <li>• Polymerization is towards the source of light in the center</li> <li>• More than chemically cured</li> <li>• Placement of material is done in increments</li> <li>• Adequate working time for insertion and contouring</li> <li>• Sets after activation by light</li> <li>• Aesthetically good</li> <li>• Expensive</li> <li>• Less polymerization shrinkage</li> <li>• More abrasion resistance</li> </ul>

#### Initiator-activator system used in various types of composites

<i>Type of composite</i>	<i>Initiator-activator system</i>
<ul style="list-style-type: none"> <li>• Chemically cured composite</li> <li>• Ultraviolet light activated</li> </ul>	<ul style="list-style-type: none"> <li>• Benzoyl peroxide and 2% aromatic tertiary amine</li> <li>• 0.1% Benzoin methyl ether composite</li> </ul>
<ul style="list-style-type: none"> <li>• Visible light cured composite</li> </ul>	<ul style="list-style-type: none"> <li>• 0.06% camphoroquinone and tertiary amine</li> </ul>

#### Difference between visible light and ultraviolet light curing

<i>Visible light curing</i>	<i>UV light curing</i>
<ul style="list-style-type: none"> <li>• Wavelength required for activation is 400-500 nm</li> <li>• Greater depth of curing is possible (up to 3 mm)</li> <li>• Intensity remains constant</li> <li>• Less side effect to operator and patient's eye</li> <li>• Better color stability</li> <li>• No warm up time required</li> </ul>	<ul style="list-style-type: none"> <li>• Wavelength required for activation is 360-400 nm</li> <li>• Limited penetration (up to 1-2 mm)</li> <li>• Intensity decreases with usage</li> <li>• Harmful to operator and patient's eyes, can cause corneal burns</li> <li>• Less than visible light</li> <li>• Units need warm up time of 5 minutes</li> </ul>

### CLASSIFICATION OF COMPOSITES

Composite resins can be classified by filler size and % filler loading and by the viscosity of the composite. With the expanded categories of composite resins, they can also be classified by their uses.

Composite resins have been classified in different ways:

#### 1. *According to Skinner:*

- Traditional or conventional composite—8-12  $\mu\text{m}$
- Small particle filled composites—1-5  $\mu\text{m}$
- Microfilled composites—0.4-0.9  $\mu\text{m}$
- Hybrid composites—0.6-1  $\mu\text{m}$

#### 2. *Philips and Lutz classification according to filler particle size:*

- Macrofiller composites (particles from 0.1-100  $\mu$ )
- Microfiller composites (0.04  $\mu$  particles)
- Hybrid composites (fillers of different sizes).

#### 3. *According to the mean particles size of the major fillers:*

- Traditional composite resins
- Hybrid composite resins
- Homogeneous microfilled composites—if the composite simply consists of fillers and uncured matrix material, it is classified as homogeneous

- d. Heterogeneous microfilled composites—if it includes procured composites and other unusual filler, it is called heterogeneous.

4. **Classification according to Bayne and Heyman:**

Category	Particle size
a. Megafill	1-2 mm
b. Macrofill	10-100 $\mu\text{m}$
c. Midifill	1-10 $\mu\text{m}$
d. Minifill	0.1-1 $\mu\text{m}$
e. Microfill	0.01-0.1 $\mu\text{m}$
f. Nanofill	0.005-0.01 $\mu\text{m}$

5. **Classification according to matrix compositions:**

- Bis-GMA
- UDMA

6. **Classification according to polymerization method**

- Self-curing
- Ultraviolet light curing
- Visible light curing
- Dual curing
- Staged curing.

## TYPES OF COMPOSITE RESINS

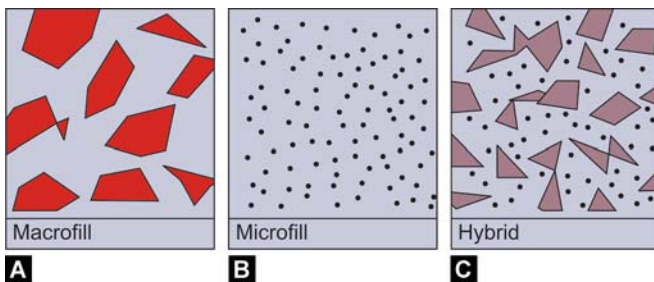
Though composites have been classified according to different characteristics, the most commonly followed classification is based on the type, distribution and filler phase of composites (**Table 11.1**).

Composite resin can be divided into three types based on the size, amount and composition of the inorganic filler (**Figs 11.2A to C**):

- Macrofilled composite resins
- Microfilled resins
- Hybrid composite resins.

### Macrofilled Composite Resins

Average particle size of macrofill composite resins is from 5-25 micron. Filler content is approximately 75-80% by weight.



**Figs 11.2A to C:** Diagrammatic representation of different composites

It exhibits a rough surface texture because of the relatively large size and extreme hardness of the filler particles. The surface becomes more rough as the resin matrix being less hard, wears at faster rate.

Due to roughness, discoloration and wearing of occlusal contact areas and plaque accumulation take place quickly than other types of composites.

### Advantage of Conventional Composite

- Physical and mechanical performance is better than unfilled acrylic resins.

### Disadvantages

- Rough surface finish
- Poor polishability
- More wear
- More prone to staining.

### Microfilled Composite Resins

Microfilled composites were introduced in the early 1980s. Average particle size of microfilled resins ranges from 0.04-0.1 micrometer. Filler content of microfilled resins is 35-50% by weight. The small particle size results in smooth polished surface which is resistant to plaque, debris and stains.

But because of less filler content, some of their physical properties are inferior. They have low modulus of elasticity and high polishability, excellent translucency. However, they exhibit low fracture toughness and increased marginal breakdown.

They are indicated for the restoration of anterior teeth and cervical abfraction lesions (**Table 17.2**).

### Advantages

- Highly polishable
- Good esthetic.

### Disadvantages

- Poor mechanical properties due to more matrix content
- Poor color stability
- Low wear resistance.
- Less modulus of elasticity and tensile strength
- More water absorption
- High coefficient of thermal expansion

### Hybrid Composite Resins

In order to combine the advantages of conventional and microfilled composites, hybrid composites were developed.

**Table 11.1:** Resin-based composite classification

Composite type	Average particle size (micrometers)	Filler percentage (volume %)
Nanofill	0.04-0.01	35-50
Nanohybrid	1-3	70-77
Microhybrid	0.4-0.8	56-66

**Table 11.2:** Clinical indications of resin-based composites

Composite type	Clinical indications
Microfill	<ul style="list-style-type: none"> <li>• For class III, IV and V restorations</li> <li>• Minimal correction of tooth form and localized discoloration</li> </ul>
Hybrid	<ul style="list-style-type: none"> <li>• Posterior restoration</li> <li>• Class V restoration</li> <li>• Class III and IV restoration</li> </ul>
Microhybrid	<ul style="list-style-type: none"> <li>• Posterior and anterior direct composite restoration veneer</li> <li>• Correction of tooth form and discoloration</li> </ul>

Hybrid composites are named so because they are made up of polymer groups (organic phase) reinforced by an inorganic phase. Hybrid composites are composed of glasses of different compositions and sizes, with particle size diameter of less than 2  $\mu\text{m}$  and containing 0.04  $\mu\text{m}$  sized fumed silica. Filler content in these composites is 75-80% by volume. This mixture of fillers is responsible for their physical properties similar to those of conventional composites with the advantage of smooth surface texture.

#### Advantages of Hybrid Composites

- Availability in various colors
- Different degrees of opaqueness and translucency in different tones and fluorescence
- Excellent polishing and texturing properties
- Good abrasion and wear resistance
- Similar coefficient of thermal expansion
- Ability to imitate the tooth structure
- Decreased polymerization shrinkage
- Less water absorption.

#### Disadvantages of Hybrid Composites

- Not appropriate for heavy stress-bearing areas.
- Not highly polishable as microfilled because of presence of larger filler particles in between smaller ones.
- Loss of gloss occurs when exposed to toothbrushing with abrasive toothpaste.

#### Two new generations of hybrid composite resins are:

1. Nanofill and nanohybrids
  2. Microhybrids.
1. **Nanofill and nanohybrid composites:** Nanofill and nanohybrid composites have average particle size less than that of microfilled composites.

The introduction of these extremely small fillers and their proper arrangement within the matrix results in physical properties equivalent to the original hybrid composite resins.

#### Advantages

- Highly polishable
- Tooth-like translucency with excellent aesthetic
- Optimal mechanical properties
- Good handling characteristics.
- Good color stability
- Stain resistance
- High wear resistance
- Can be used for both anterior and posterior restorations and for splinting teeth with fiber ribbons.

2. **Microhybrid composites:** Microhybrid composites have evolved from traditional hybrid composites.

Filler content in microhybrids are 56 to 66% by volume. The average particle size in these composites range from 0.4-0.8  $\mu\text{m}$ .

Incorporation of smaller particles makes them better to polish and handle than their hybrid counterparts. Because of presence of large filler content, microhybrid composites have improved physical properties and wear resistance than microfilled composites.

#### Advantages

- Better polish and surface finish
- Easy handling
- Improved physical properties
- Good wear resistance.

### RECENT ADVANCES IN COMPOSITES

- Flowable composite resins
- Condensable (packable) composites
- Giomers
- Compomers
- Ormocers
- Antibacterial/ion releasing composites
- "Smart" composites

#### Flowable Composite Resins

They were introduced in the dentistry in late 1996. These resins have lower filler content ranging from 41-53% by

volume. Low filler loading is responsible for decreased viscosity of composites, which allows them to be injected into both preparation, this makes them a good choice as a pit and fissure restorative.

They have an average particle size ranging from 0.04-1  $\mu\text{m}$ . Their decreased viscosity is achieved by reducing the filler volume.

### Type

Filler content in flowable resins is 60% by weight. It is usually silica which are 0.02 to 0.05  $\mu\text{m}$  in size. Lower filler content is responsible for poor mechanical properties of these composites than conventional composites.

### Advantages

- Low viscosity
- Improve marginal adaptation of posterior composites by acting as an elastic, stress absorbing layer over which composite is placed
- High wettability of the tooth surface
- High depth of cure
- Penetration into every irregularity of preparation
- Ability to form layers of minimum thickness, thus eliminate air entrapment
- High flexibility, so less likely to be displaced in stress concentration areas
- Radiopaque
- Availability in different colors
- Require minimally invasive tooth preparations
- For the pediatric patient to be used in narrow and deep pits and fissures.

### Disadvantages

- More susceptible to wear in stress-bearing areas
- Weaker mechanical properties
- More polymerization shrinkage and wear
- Sticks to the instrument, so difficult to smoothen the surface.

### Indications

- Preventive resin restorations
- Small pit and fissure sealants
- Small, angular class V lesions
- For repairing ditched amalgam margins
- Repair of small porcelain fractures
- Inner layer for class II posterior composite resin placement for sealing the gingival margin
- Resurfacing of worn composite or glass ionomer cement restorations

- For repair of enamel defects
- For repair of crown margins
- Repair of composite resin margins
- For luting porcelain and composite resin veneers
- Class I restorations
- Small class III restorations
- As base or liner
- Tunnel restorations.

### Condensable (Packable) Composites

Condensable composites have been developed in an attempt to improve the compressive, tensile and edge strength and handling of the composite. The principle of the high viscosity of packable composites is that they can be pushed into the posterior tooth preparation and have greater control over the proximal contour of class II preparations. Their basis is polymer rigid inorganic matrix material (PRIMM). In this components are resin and ceramic inorganic fillers which are incorporated in silanated network of ceramic fibers. These fibers are composed of alumina and silicon dioxide which are fused with each other at specific sites to form a continuous network of small compartments. Filler content in packable composites ranges from 48-65% by volume. Average particle size ranges from 0.7-20  $\mu\text{m}$ .

Packable composites possess improved mechanical properties because of presence of ceramic fibers. They have improved handling properties because of presence of higher percentage of irregular or porous filler, fibrous filler and resin matrix. The consistency of the condensable composites is like freshly triturated amalgam. Each increment can be condensed similar to amalgam restoration and can be cured to a depth of over 4 mm.

### Indications

- Indicated for stress-bearing areas
- In class II restorations as they allow easier establishment of physiological contact points.

### Advantages

- Increased wear resistance because of presence of ceramic fibers
- Condensability like silver amalgam restoration
- Greater ease in achieving a good contact point
- Produce better reproduction of occlusal anatomy
- Deeper depth of cure because of light conducting properties of individual ceramic fibers
- High flexural modulus
- Decreased polymerization shrinkage because of presence of ceramic fibers

- Reduced stickiness
- Physical and mechanical performance is similar to that of silver amalgam.

#### Disadvantages

- Difficulties in adaptation between one composite layer and another
- Difficult handling
- Poor aesthetics in anterior teeth.

#### Giomers

Giomers are hybrid of words “glass ionomers” and “composite”. These are relatively new type of restorative materials. They are also known as PRG composites (Prereacted glass ionomer composites). Giomers have properties of both glass ionomers (fluoride release, fluoride recharge) and resin composite (excellent aesthetics, easy polishability, biocompatibility).

#### Chemistry

Giomers are hybrid aesthetic restorative materials which employ the use of PRG technology, in other words, they are resin-based materials which contain prereacted glass ionomer (PRG) particles. The particles are made of fluoroaluminosilicate glass that has been reacted with polyalkenoic acid before incorporating into the resin matrix. The prereaction may involve either the surface or full particle. Giomers are very much similar to compomers and composite materials in that they are light activated and require the use of bonding agent for adhesion to tooth structure.

#### Properties of Giomers

1. Easier to polish than glass ionomers
2. Optimum fluoride release
3. Excellent aesthetics
4. Better surface finish
5. Chemical bonding to tooth structure
6. Biocompatibility
7. Sensitive to moisture and desiccation.

#### Indications

1. Noncarious cervical lesions
2. Root caries
3. Deciduous tooth caries.

#### Compomers (Polyacid Modified Composite Resins)

Compomers are class of dental materials that provide combined advantages of composites (term ‘Comp’ in their

name) and glass ionomer (‘Omers’ in their name). These materials consist of 2 components, viz. dimethacrylate monomers with two carboxylic acid groups present. They are available in single paste, light enable material in syringe or compules.

#### History

The first compomer was introduced in 1993 under the name ‘Dyract’. Initially the compomers were introduced as a type of glass-ionomers which offered fluoride release along with improved physical properties. But in terms of clinical use and performance, these are considered as a type of composite resin.

Later on ‘Compoglass’ followed by Hytac was introduced.

#### Composition

- Resin matrix: Dimethacrylate monomers with two carboxylic groups present in their structure
- Filler: Reactive silicate glass containing filler
- Photoinitiators and stabilizers
- There is no water in the composition and ionleachable glass is partially silanized to ensure bonding to matrix.

#### Setting Reaction

These materials set by free radical polymerization reaction. There are two stages in the polymerization reaction.

1. **Stage 1:** Typical light activated composite resin polymerization reaction occurs which helps in forming resin networks enclosing the filler particles. This reaction causes hardening of products.
2. **Stage 2:** It occurs after the initial setting of material. The restoration absorbs water and carboxyl groups present in the polyacid and metal ions in the glass ionomers show slow acid-base reaction. This results in formation of hydrogel. It is like glass ionomer cement within the set resin structure. There occurs slow release of fluoride also.

#### Properties

Their characteristics are very similar to composite resins.

- **Adhesion:** Adhesion to tooth structure is by micro-mechanical means and requires acid etching and use primer/adhesive.
- **Physical properties:** Physical properties such as strength, fracture toughness are very much similar to composites.
- **Bond strength:** It is similar to composite.
- **Adaptation** at cervical margin is similar to composite resins.

- **Fluoride release:** It is greater than composite resins but less than glass ionomer systems. They initially release high levels of fluorides but after some time the level falls rapidly to low level.
- **Color matching** and optical properties are superior to glass ionomer cements.

#### Advantages

- Optimal aesthetics
- Easy to handle
- Easy to polishing
- Easy to place
- Require no mixing
- Bond strength is higher than glass ionomers.

#### Disadvantages

- Require use of bonding agent
- Technique sensitive
- Limited fluoride release
- Microleakage more than resin modified glass ionomers
- Expansion of matrix due to water sorption
- Physical properties decrease with time.

#### Clinical Usage

They are preferred in anterior proximal and cervical restorations as an alternative to composite and glass ionomer cements.

#### Difference between compomers and giomers

In compomers, variable amount of polyalkenoic acid is incorporated into the resin matrix and acid does not react with glass until the water uptake occurs into restoration, while in giomers, fluoroaluminosilicate glass particles are reacted with polyalkenoic acid in water prior to their incorporation into the resin matrix.

### ORMOCER (Organically Modified Ceramic)

ORMOCER is an organically modified non metallic inorganic composite material. It is three dimensionally cross-linked copolymer. First time, it was introduced as dental restorative material in 1998.

#### Composition

ORMOCERS have both organic and inorganic networks. They are characterized by presence of three main units:

- Organic molecules segment having methacrylate groups which form a highly cross-linked matrix.

- Inorganic condensing molecules to make three dimensional network which is formed by inorganic polycondensation. This forms the backbone of ORMOCER molecules.
- Fillers are further added to this complex.

#### Properties

1. More biocompatible than conventional composites.
2. Higher bond strength.
3. Polymerization shrinkage is least among resin-based filling material.
4. Highly esthetic, comparable to natural tooth.
5. High compressive (410 MPa) and transverse strength (143 MPa).

#### Indications

1. Restoration for all types of preparations.
2. For esthetic veneers.
3. As orthodontic bonding adhesive.

### Antibacterial Composites/Ion Releasing Composites

Since composites show more tendency for plaque and bacteria accumulation in comparison to enamel, attempts have been made to develop caries-resistant antibacterial composites. For this, following have been tried to incorporate in the composites:

#### Chlorhexidine

Though chlorhexidine has shown antibacterial properties, its addition to composites has been unsuccessful because of the following reasons:

- Weakening of the physical properties of composites.
- Release chemicals which show toxic effects.
- Temporary antibacterial activity.
- Shift in microorganisms and plaque to adjacent areas of the tooth.

#### Methacryloxydecyl Pyridinium Bromide (MDPB)

Use of MDPB was recommended by Imazato in 1994. It has following features:

- Its antibacterial property remains constant and permanent.
- It has shown to be effective against streptococci.
- It does not have adverse effect on the physical properties of Bis-GMA based composites.
- On polymerization, it forms chemical bond to the resin matrix, therefore, no release of any antibacterial component takes place.

## Silver

Addition of silver ions in the composites has also been suggested so as to make antibacterial composites. Silver ions cause structural damage to the bacteria. In these composites, the antibacterial property is due to direct contact with bacteria and not because of release of silver ions. Addition of silver into composite without silica gel does not affect its physical properties like depth of cure, compressive strength, tensile strength, color stability and polymerization.

Silver ions can be added in any of the following methods:

- Incorporated into inorganic oxide like silicone dioxides.
- Incorporated into silica gel and the thin films are coated over the surface of composites.
- Hydrothermally supported into the space between the crystal lattice network of filler particles.

## “Smart” Composites

In smart composites the micron size sensor particles are embedded during manufacturing process into composite. These sensors interact with resin matrix and generate quantifiable anions. This type of composites was introduced in 1998 under the name Ariston pHc (Vivadent).

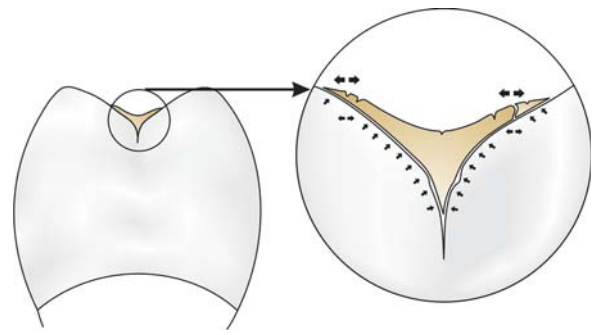
It releases fluoride, hydroxyl and calcium ions if the pH falls in the vicinity of the restoration. The fall in pH value is attributed to the deposition of plaque in that area. Smart composites work based on the recently introduced alkaline glass fillers which inhibit the bacterial growth and thereby reduce formation of secondary caries. The paste of smart composites contain barium, aluminium fluoride and silicate glass fillers with silicon dioxide, ytterbium trifluoride and calcium silicate glass in dimethacrylate monomers. Filler content in these composites is 80% by weight.

The fluoride release from smart composites is higher than that of compomers but lower than conventional glass ionomers.

## PROPERTIES OF COMPOSITE RESTORATIVE MATERIALS

### Coefficient of Thermal Expansion

Coefficient of thermal expansion of composites is approximately three times higher than normal tooth structure. This results in more contraction and expansion than enamel and dentin when there are temperature changes, it can result in loosening of the restoration (**Fig. 11.3**). This can be reduced by adding more filler content.



**Fig. 11.3:** Coefficient of thermal expansion can result in dimensional change in restoration which can cause gap between tooth and the restoration

### Water Absorption

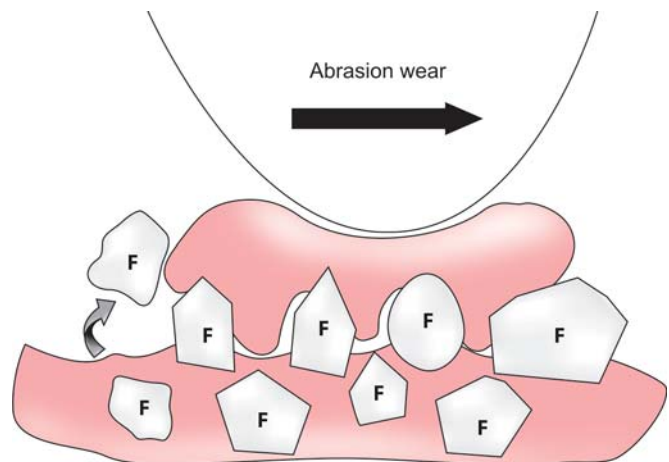
Composites have tendency to absorb water which can lead to the swelling of resin matrix, filler debonding and thus restoration failure.

#### Factors affecting Water Absorption of Composites

- More is the filler content, less is the water sorption.
- Lesser degree of polymerization causes more sorption.
- Type and amount of monomer and diluent also affect water sorption. For example, UDMA-based composites show less sorption and solubility.

### Wear Resistance

Composites are prone to wear under masticatory forces or use of tooth brushing and abrasive food (**Fig. 11.4**). Wear



**Fig. 11.4:** Abrasive wear in composite restoration causes exposure of filler-particles which get removed from the surface of composite restoration



resistance is a property of filler particles depending on their size and quantity. The site of restorations in dental arch and occlusal contact relationship, size, shape and content of filler particles affect the wear resistance of the composites.

#### Factors affecting Degradation/Wear of Composites

- Lesser is the polymerization, more is the degradation.
- Microfilled composites show less of degradation.
- Hydrolytic degradation of strontium or barium glass fillers can result in pressure built up at resin filler junction. This may cause cracks and fracture of composite restoration.
- Sudden temperature change can result in disruption is silane coating and thus bond failure between matrix and filler.

#### Surface Texture

The size and composition of filler particles determine the smoothness of the surface of a restoration. Microfilled composites offer the smoothest restorative surface.

#### Radiopacity

Resins are inherently radiolucent. Presence of radiopaque fillers like barium glass, strontium and zirconium makes the composite restoration radiopaque.

#### Modulus of Elasticity

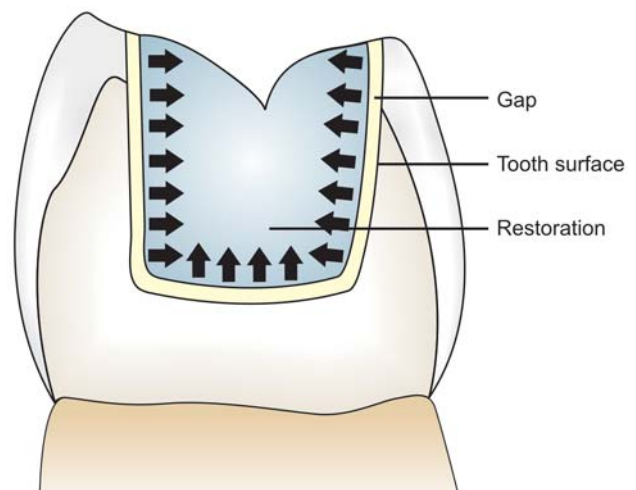
Modulus of elasticity of a material determines its rigidity or stiffness. Microfill composites have greater flexibility than hybrid composite since they have lower modulus of elasticity.

#### Solubility

Composite materials do not show any clinically significant solubility in oral fluids. Water solubility of composites ranges from 0.5-1.1 mg/cm<sup>2</sup>.

#### Creep

Creep is progressive permanent deformation of material under occlusal loading. More is the content of resin matrix, more is the creep. For example, microfilled composites show more creep since they contain more of resin matrix.



**Fig. 11.5:** Polymerization shrinkage can result in gap between restoration and the tooth surface

#### Polymerization Shrinkage

Composite materials shrink while curing which can result in formation of a gap between resin-based composite and the preparation wall (**Fig. 11.5**). It accounts for 1.67-5.68% of the total volume.

##### Polymerization shrinkage

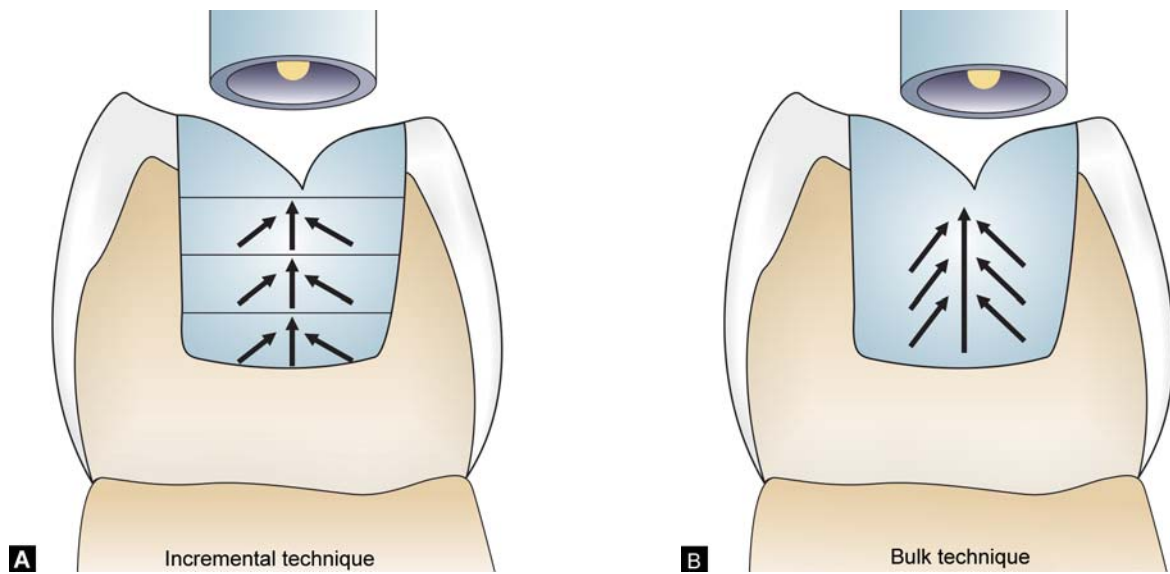
- In light-cured composites, about 60% polymerization occurs within 60 seconds, further 10% in next 48 hours; remaining resin does not polymerize. Since the material nearest to the light sets first. Shrinkage in light cured composites occurs in the direction of light (**Figs 11.6A and B**).
- For chemical-cured composites shrinkage occurs slowly and uniformly towards the center of restoration (**Fig. 11.7**).

##### *Polymerization shrinkage can result in:*

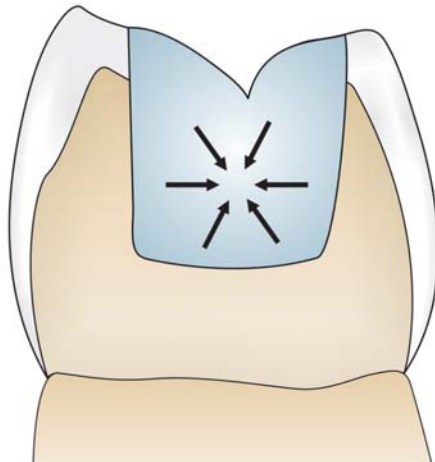
- Postoperative sensitivity
- Recurrent caries
- Failure of interfacial bonding
- Fracture of restoration and tooth (**Fig. 11.8**).

##### *Polymerization shrinkage can be reduced by:*

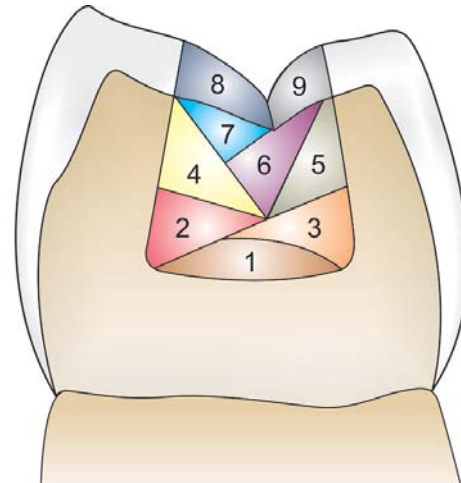
- Decreasing monomer level
- Increasing monomer molecular weight



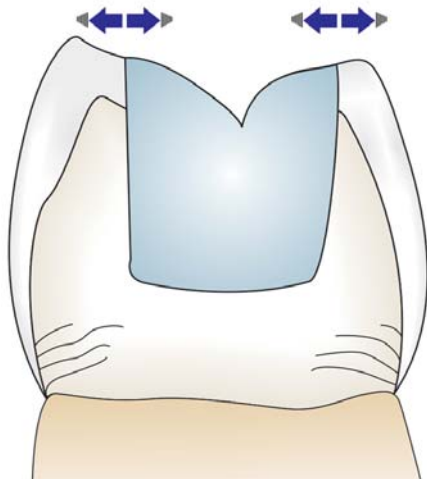
**Figs 11.6A and B:** In light cured composites, shrinkage occurs towards source of light



**Fig. 11.7:** In chemical cured composites, shrinkage occurs towards center of restoration



**Fig. 11.9:** Incremental build-up of restoration results in decreased polymerization shrinkage



**Fig. 11.8:** Polymerization shrinkage can pull cusps together and can result in fracture

- Improving composite placement technique: Placing successive layers of wedge-shaped composite (1-1.5 mm) decreases polymerization shrinkage (**Fig. 11.9**).
- *Polymerization rate*: “Soft-start” polymerization reduces polymerization shrinkage.

### Configuration or “C-Factor”

The cavity configuration or C-factor was introduced by Prof Carol Davidson and his colleagues in 1980s. The configuration factor (C-factor) is the ratio of bonded surface of the restoration to the unbonded surfaces. The higher the value of C-factor, the greater is the polymerization shrinkage (**Fig. 11.10**).

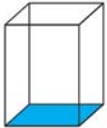
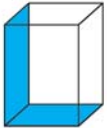
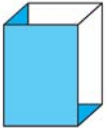
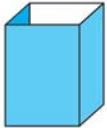
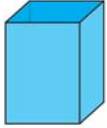
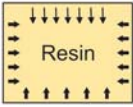
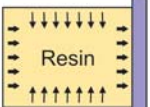
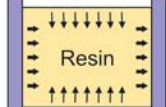
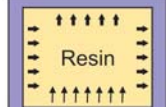
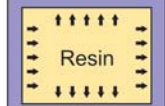
Restoration surfaces	1 sides	2 sides	3 sides	4 sides	5 sides
					
	1s	2s	3s	4s	5s
Cross-sectional view					
C-factor	$1/5 = 0.2$	$2/4 = 0.5$	$3/3 = 1$	$4/2 = 2$	$5/1 = 5$

Fig. 11.10: Configuration factor of different tooth preparations

#### Evaluation of C-factor in different tooth preparations

S.No.	Type of preparation	Value
1.	Class I and V (five-walled preparation)	5
2.	Class II (four-walled preparation)	2
3.	Class III (three-walled preparation)	1
4.	Class IV (two-walled preparation)	0.5
5.	Smooth surface restoration (one-walled preparation)	0.2

Therefore, three-dimensional tooth preparations (Class I) have the highest (most unfavorable) C-factor and thus are at more risk to the effects of polymerization shrinkage. C-factor plays a significant role when tooth preparation extends up to the root surface causing a V-shaped gap formation between the composite and root surface due to polymerization shrinkage.

#### Esthetics of Composites

Composites have shown good aesthetics because of their property of translucency. Composites are available in different opacities and shades so they can be used in different places according to aesthetic requirements. But due to oxidation, moisture and exposure to ultraviolet light, etc. some chemical changes can occur in the resin matrix which results in discoloration of composite with time.

#### Microleakage and Nanoleakage

- **Microleakage:** It is passage of fluid and bacteria in micro-gaps ( $10^{-6}$  m) between restoration and tooth. It can result

in damage to the pulp. Microleakage can occur due to:

- Polymerization shrinkage of composites
- Poor adhesion and wetting
- Thermal stresses
- Mechanical loading

Microleakage can result in bacterial leakage which can further cause discoloration, recurrent caries and pulpal infection.

- **Nanoleakage:** It is passage of fluid/dissolved species in nanosized ( $10^{-9}$  m) gaps. These nanosized porosities occur within hybrid layer. These can occur because of:
  - Inadequate polymerization of primer before application of bonding agent.
  - Incomplete resin infiltration.
  - Polymerization shrinkage of maturing primer resin.
 Nanoleakage can result in sensitivity during occlusal and thermal stresses.

#### Biocompatibility

Since composites are made from petrochemical products, studies have shown that the major components are cytotoxic if used in pure state. These products have shown to cause contact allergy in those who regularly handle uncured composite. These have shown to cause:

- Inflammation
- Toxicity
- Mutagenicity
- Leaching of TEGDMA, HEMA, etc.
- Deposition of plaque on restoration
- Allergic response
- Genotoxicity
- Mutagenicity
- Carcinogenicity

### Biocompatibility of composites

- Unpolymerized monomers are responsible for toxic effects of composites
- HEMA is known to cause allergy

### Working and Setting Times

#### Light Cure Composites

In case of light cure composites, application of light source to the composite material starts the polymerization. Usually, 70% of polymerization takes place during the first 10 minutes, though the polymerization reaction continues for period of 24 hours.

#### Mixing for Self-cure Composites

Self-cure composites come in two syringes. One syringe contains the peroxide initiator or catalyst while other syringe contains the amine accelerator. They are dispensed in equal amounts and then thoroughly mixed for 20-30 seconds. For mixing, plastic or wooden spatulas are preferred. Use of metal spatula is avoided because inorganic filler particles are abrasive, they can abrade small amount of metal and thus discolor the composite. The working time for self-cure composite resins is 1-1½ minutes. Once the mix starts hardening, it should not be disturbed for 4-5 minutes (setting time).

## POLYMERIZATION OF COMPOSITES

Complete polymerization of the composite is determined by degree of conversion of monomers into polymers. **Degree of conversion** of the composite is dependent on following factors:

### Curing Time

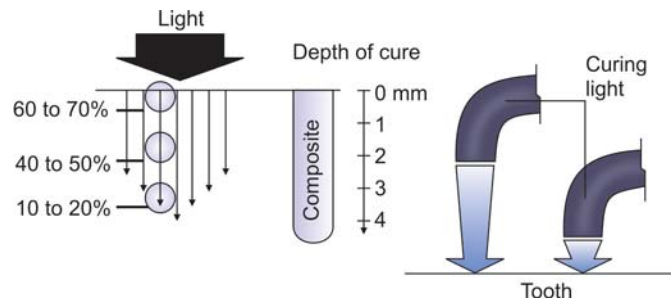
Curing time depends on different factors like shade of the composite, intensity of the light used, temperature, depth of the preparation, thickness of the resin, curing through tooth structure, composite filling.

### Shade of Composite

It has been seen that darker composite shades polymerize slower when compared to lighter shades.

### Distance and Angle between Light Source and Resin

The recommended distance is 1 mm and should be at 90° to the resin material. Intensity of light decreases as the



**Fig. 11.11:** As the distance between light source and tooth increases, polymerization decreases

distance is increased. If the cavity is deep, use highpower density lamp (about 600 mW/cm<sup>2</sup>) so that deeper layer is also cured (**Fig. 11.11**). Polymerization can also be achieved in tooth preparation with deep proximal box by curing from proximal surface (**Fig. 11.12**).

The angle of source should be 90° to the resin. If angle diverges from 90°, intensity of light decreases.

### Temperature

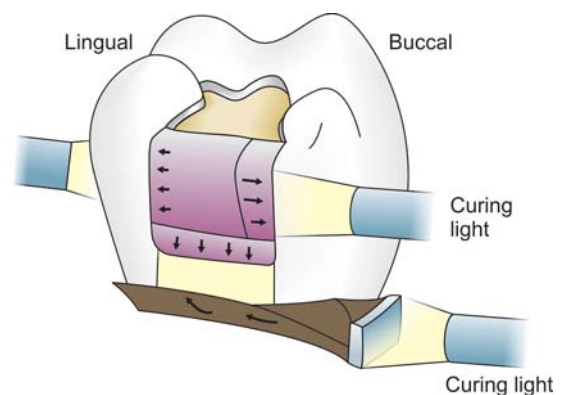
Composite curing would be less if they are taken out immediately from refrigerator. These materials should be at least held at room temperature 1 hour before use.

### Resin Thickness

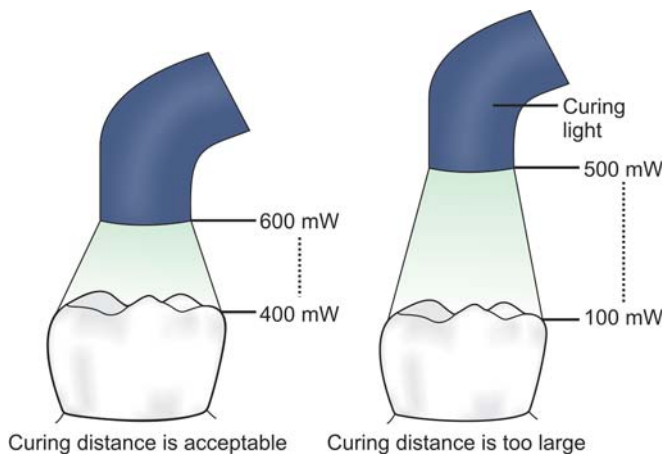
Resin thickness is also one of the main factors during curing of resin. It should be ideally 0.5-1.0 mm for optimum polymerization of resin.

### Inhibition of Air

Oxygen in the air also affects the polymerization of the resin.



**Fig. 11.12:** Polymerized light should be directed from all sides of proximal box so as to have complete polymerization



**Fig. 11.13:** As the distance between light source and the restoration increases, the intensity of light decreases

### Intensity of Curing Light

Intensity of curing light usually decreases as the lamp ages. Decrease in intensity of light affects the properties of composites significantly.

For optimal results, wavelength of light should range between 400-500 nm. To make it sure that 400 mW/cm reaches the first increment of the restoration, a power density of 600 mW/cm is needed (**Fig. 11.13**).

### Type of Filler

Microfine composites are more difficult to cure than heavily loaded composites.

### INDICATIONS OF COMPOSITE RESTORATIONS

- For restoration of mild to moderate class I and class II tooth preparations of all teeth.
- Restoration of class III, IV and V preparations of all teeth, especially when aesthetics is important.
- Restoration of class VI preparations of teeth where high occlusal stress is not present.
- Esthetic improvement procedures:
  - a. Laminates
  - b. Partial veneers
  - c. Full veneers
  - d. Treatment of tooth discolorations
  - e. Diastema closures
- To restore erosion or abrasion defects in cervical areas of all the surfaces of premolars, canines and incisors where aesthetics is the main concern.
- For restoration of hypoplastic or other defects on the facial or lingual areas of teeth.

- As core build up for grossly damaged teeth and endodontically treated teeth.
- For cementation of indirect restorations like inlays, onlays and crowns.
- As a pit and fissure sealants.
- For periodontal splinting of weakened teeth or mobile teeth.
- For repair of fractured ceramic crowns.
- For bonding orthodontic appliances.

### CONTRAINDICATIONS OF COMPOSITES

- When isolation of operating field is difficult.
- Where very high occlusal forces are present.
- Class V lesions where aesthetics is not the prime concern.
- When clinician does not possess the necessary technical skill for the restoration.
- When lesion extends up to the root surface.
- Small lesions on distal surface of canines where metallic restoration is treatment of choice.
- Patients with high caries susceptibility.
- When preparation extends subgingivally.
- Patients with poor oral hygiene.

### Advantages of Composites

- Since composite restoration requires minimal tooth preparation, maximum conservation of tooth structure is possible.
- Esthetically acceptable.
- Less complex tooth preparation is required.
- Composite resin can be used in combination with other materials, such as glass ionomer, to provide the benefits of both materials.
- Composites have low thermal conductivity, thus no insulation base is required to protect underlying pulp.
- Restorations are bonded with enamel and dentin, hence show good retention.
- Restoration with composite resins can be finished immediately after curing.
- It can be repaired rather than replaced.
- Composite restoration shows low microleakage than unfilled resins.
- Can be used almost universally.
- They have extended working time, this makes their manipulation easier.
- Restoration can be completed in one dental visit.
- Composite restorations can bond directly to the tooth, making the tooth stronger than it would be with an amalgam filling.

- Indirect composite fillings and inlays are heat-cured, increasing their strength.
- No galvanism because composite resins do not contain any metals.
- Composite resins have adequate radiopacity to enable their detection in radiographs.

### DISADVANTAGES OF COMPOSITES

- Because of polymerization shrinkage, gap formation on margins may occur, usually on root surfaces. This can result in secondary caries and staining.
- More difficult, time consuming.
- Expensive than amalgam.
- More technique sensitive.
- Low wear resistance.
- Postoperative sensitivity due to polymerization shrinkage.
- High LCTE may result in marginal percolation around composite restorations.
- In large preparation, composites may not last as long as amalgam fillings.

### TOOTH PREPARATION FOR COMPOSITE RESTORATIONS

#### Prerequisites for tooth preparation to receive composite restoration

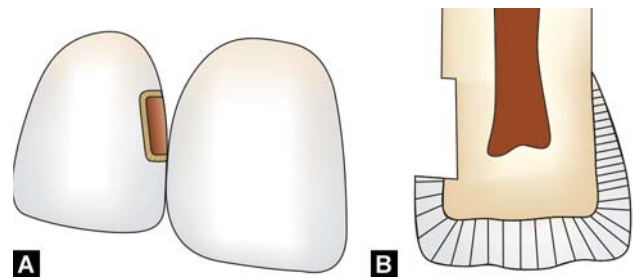
- Use rubber dam for optimal isolation of the working area.
- Use yellow filter for the operating light or to keep it on low intensity so as to avoid the premature polymerization of the composite.
- Take proper precautions to protect eyes from glare, so use safety specs or for this a hand-held shield can be used.
- Use teflon coated composite filling instruments so as to prevent the composite resin from sticking and 'pulling back'.

### CLASS III TOOTH PREPARATION

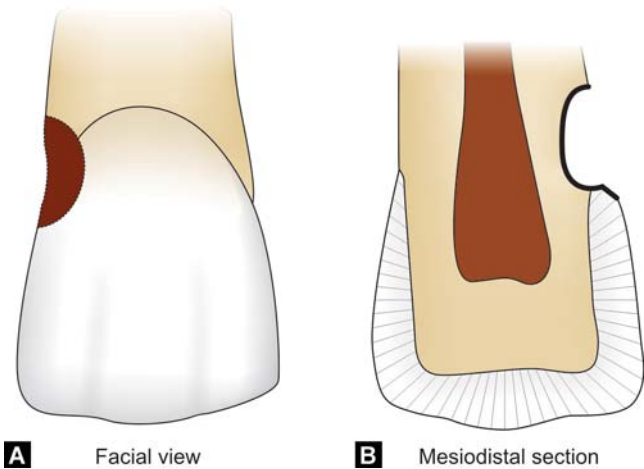
Depending upon the type of dental tissues involved, the tooth preparation for the composites can be done in three designs: conventional, beveled conventional and modified.

#### Conventional Class III Tooth Preparation (Figs 11.14A and B)

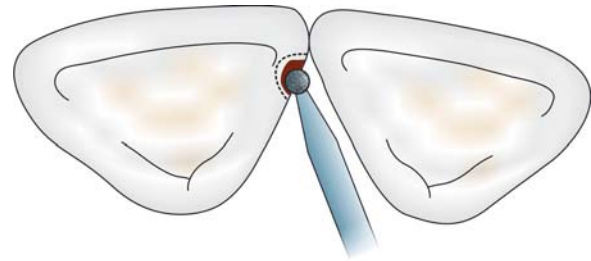
- Indication for conventional tooth preparation is the lesion present on the root surfaces.
- Usually most of the lesions occur partly on the root and partly on crown. The tooth preparation on the root is done in conventional method whereas on the crown it is prepared in beveled conventional or modified type (Figs 11.15A and B).



**Figs 11.14A and B:** Conventional class III tooth preparation for composites



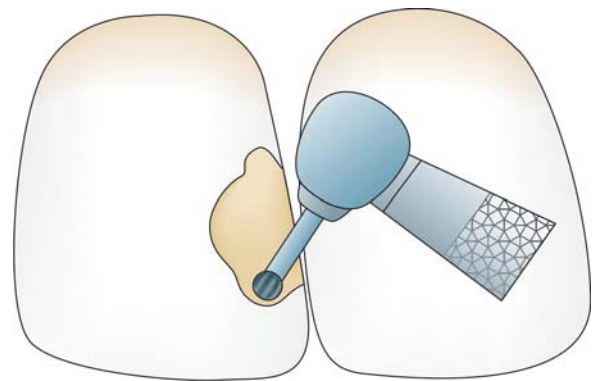
**Figs 11.15A and B:** When caries extend to root surface, (A) Conventional tooth preparation is made on root and (B) Beveling is done in coronal portion



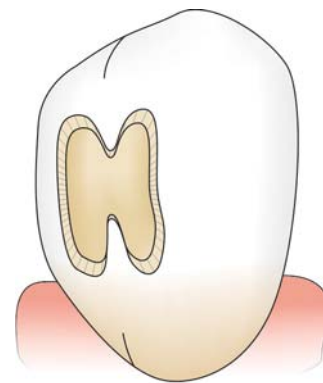
**Fig. 11.16:** For initial penetration, entry into tooth should be made from the palatal side so as to preserve esthetics

- The extent of lesion determines the outline of tooth preparation. For penetration into lesion, usually the direction for entry of bur is from lingual side except for a few cases (**Fig. 11.16**). This lingual approach helps in preservation of aesthetics. Following are the indications for labial approach:
  1. Involvement of labial enamel.
  2. In cases of rotated teeth where lingual approach is difficult.
  3. In cases of malaligned teeth.

- When the damage is present only on the root surface, the conventional preparation is made only on the root with 90° cavosurface margins. In the crown portion of the preparation, the retention is mostly achieved by adhesive bonding to enamel and dentin.
- The external walls are made perpendicular to the root surface.
- While preparing, there should be adequate removal of caries, old restoration or defective tooth structure. The external walls of the preparation should be located on sound tooth structure with a cavosurface angle of 90° for butt joint relation.
- If the carious lesion is not deep, the depth of the preparation is kept 0.75 mm. After this, it is deepened wherever caries is present.
- Retention in conventional tooth preparation is attained by:
  - Roughening of the preparation surface
  - Parallelism or convergence of opposing external walls
  - Giving retention grooves and coves (**Fig. 11.17**).
- Grooves can be placed continuous or isolated. Continuous groove is placed in external walls, parallel to tooth surface. It should be located at least 1 mm from the tooth surface and at least 0.5 mm deep into dentin.



**Fig. 11.17:** Making grooves in class III preparation for retention



**Fig. 11.18:** Completed class III tooth preparation for composites

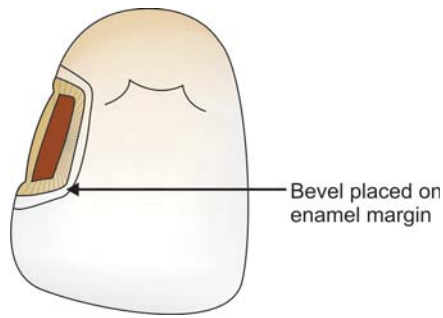
### Beveled Conventional Class III Tooth Preparation

Indications of beveled class III preparation are following:

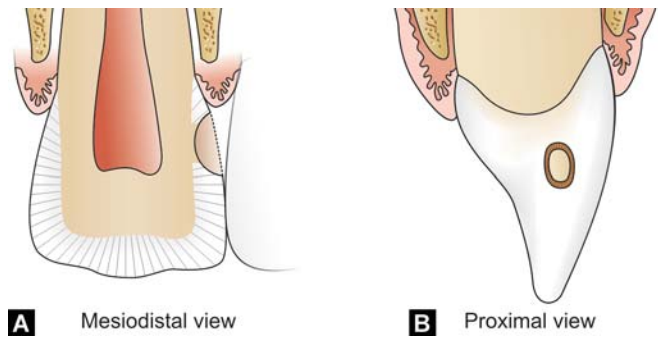
- For replacing an existing defective restoration on crown portion of an anterior tooth if a large carious lesion is present.

#### Steps

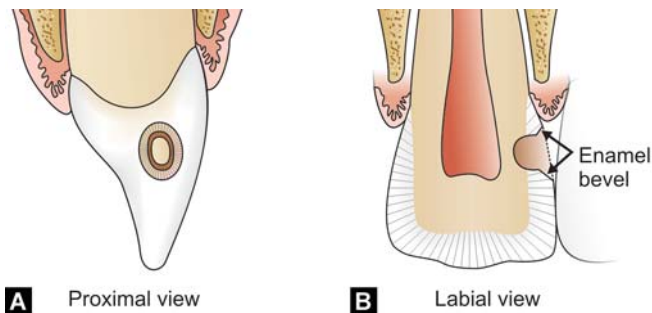
- Approach the area lingually with a no. 1/2, 1 or 2 round bur. Penetrate the lesion and move the bur in incisogingival direction.
- Entry angle of the bur should be such that it places the neck portion of the bur far into the embrasure.
- Shape of the tooth preparation should be identical to the shape of existing carious lesion or the restoration.
- One should take care to include any secondary caries, friable tooth structure and defects while placing the external walls on sound tooth structure.
- Initial depth of the axial wall should be 0.75 mm deep gingivally and 1.25 mm deep incisally. This results in the axial wall depth of 0.2 mm into the dentin (**Fig. 11.18**).
- Shape of the axial wall should be convex outwardly, that is, it should follow the contour of the tooth.
- In final tooth preparation, remove all the remaining infected dentin or defective restoration using spoon excavator or slow speed round bur.
- For pulp protection, place a calcium hydroxide liner if indicated.
- Keep external walls of the tooth preparation perpendicular to the enamel surface with all enamel margins beveled (**Fig. 11.19**). Prepare the bevels using flat end tapering fissure diamond bur at cavosurface margins in the areas of centric contacts. The bevel should be about 0.2 to 0.5 mm wide at an angle of 45° to the external tooth surface (**Figs 11.20A and B**).
- Bevels are not given in areas bearing heavy occlusal forces or on cemental cavosurface margins.
- If required, prepare retentive grooves and coves along gingivoaxial line angle and incisioaxial line angle, respectively, with the help of no. 1/4 or 1/2 round burs. Depth of these grooves should be 0.2 mm into the dentin.



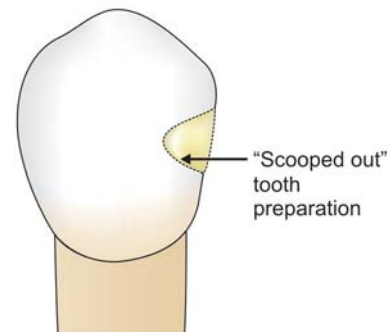
**Fig. 11.19:** Beveled class III tooth preparation for composites



**Figs 11.21A and B:** Saucer shaped class III tooth preparation (A) Mesiodistal view (B) Proximal view



**Figs 11.20A and B:** Proximal and labial view of beveled class III tooth preparation for composites



**Fig. 11.22:** Extent of preparation is determined by extent of caries

### Modified (Conservative) Class III Tooth Preparation

- It is the most conservative type of tooth preparation used for composites. Indication for modified preparation is small to moderate class III lesion. In this tooth preparation, basically infected carious area is removed as conservatively as possible by “scooping” out. This results in “scooped-out” or “concave” appearance of the preparation (**Figs 11.21A and B**).

#### Steps

- Make initial entry through the palatal surface with a small round bur in the air rotor handpiece. It is always preferred to use the lingual approach since it conserves labial tooth structure which is more esthetic.
- The bur should be kept rotating when being entered into the tooth and should not stop rotating until being removed.
- The design and extent of the preparation is determined by the extent of the carious lesion (**Fig. 11.22**).
- Keep all the internal line angles rounded to decrease internal stresses. It can be done using a half round bur head.

- This type of preparation may not have any definite axial wall depth and the walls may diverge externally from axial depth in a scoop shape.
- In the final stage, remove the remaining infected dentin using slow speed round bur or spoon excavator.
- Then finally check the preparation after cleaning with water and air spray and provide pulp protection.

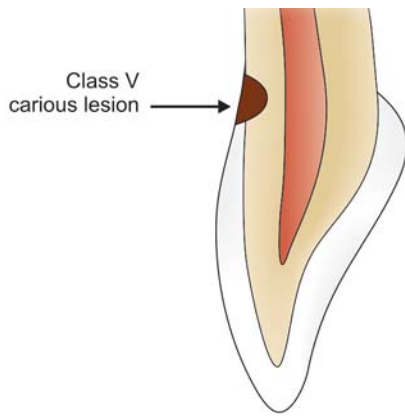
### CLASS V TOOTH PREPARATION

Composites are material of choice for restoration of class V lesions which are aesthetically prominent. Among composites, microfill composites are material of choice because they provide better and more smooth surface and have sufficient flexibility to resist stresses caused by cervical flexure, when tooth flexes under heavy occlusal forces.

#### Conventional Class V Preparation

Conventional class V preparation is indicated if it is present completely or mainly on root surface (**Fig. 11.23**). If the lesion is partly on crown and partly on root, the crown portion is prepared using beveled conventional or modified





**Fig. 11.23:** Conventional tooth preparation is indicated if caries are present mainly on root surface

preparation design and the root surface lesion is prepared in conventional method.

In conventional class V tooth preparation, shape of the preparation is a “box” type. Isolate the area well and use a tapered fissure (no. 700, or 701) bur to make entry at 45° angle to tooth surface initially. After this keep long axis of bur perpendicular to the external surface in order to get a cavosurface angle of 90°.

During initial tooth preparation, keep the axial depth of 0.75 mm into the dentin.

After achieving the desired distal extension, move the bur mesially, incisally (occlusally) and gingivally for placing the preparation margins onto the sound tooth surface while maintaining a cavosurface margin of 90°.

The axial wall should follow the contour of facial surface incisogingivally and mesiodistally.

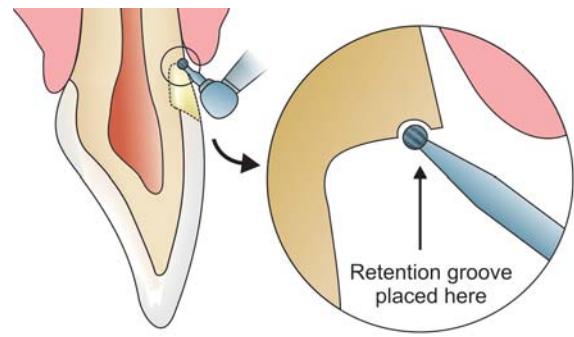
During the final tooth preparation, remove any remaining infected dentin, restoration material using spoon excavator or slow speed round bur.

For pulp protection, use calcium hydroxide liner, if necessary.

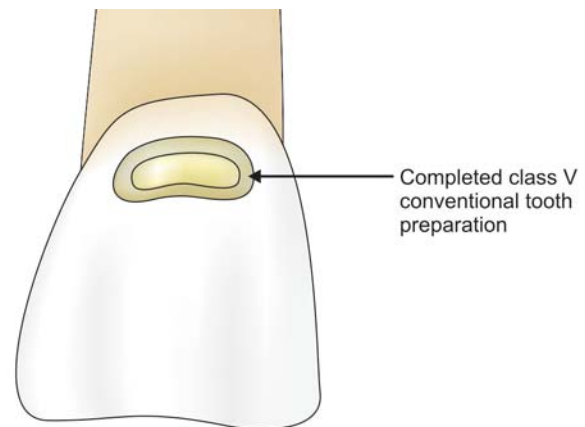
If additional retention is required, place retention grooves all along the whole length of incisoaxial and gingivoaxial line angles using a no. 1/4 or 1/2 round bur 0.25 mm deep into the dentin (**Fig. 11.24**). At this stage, all the external walls appear outwardly divergent. Finally clean tooth preparation with water and air dry it (**Fig. 11.25**).

### Beveled Conventional Class V Tooth Preparation

Beveled conventional class V preparation is indicated for replacing defective existing restoration or for restoring a large, carious lesion.



**Fig. 11.24:** Placing retention grooves in class V preparation



**Fig. 11.25:** Conventional class V tooth preparation

The initial axial wall depth should be limited to only 0.25 mm into the dentin, when retention grooves are not placed and 0.5 mm when a retention groove is placed. Place a mechanical retention groove inside the gingival cavosurface margin.

After this, bevel the enamel margins at an angle of 45° to the external surface and to a width of 0.25 to 0.5 mm (**Fig. 11.26**). When the class V carious lesion is large enough to extend onto the root surface, the gingival part is prepared in the conventional class V tooth preparation design with the initial axial depth of 0.75 mm. Beveling is done only on enamel cavosurface margins (**Fig. 11.27**).

Roughen the dentin with a medium-sized diamond bur to provide mechanical retention and thus increasing the bond strength.

### Modified (Conservative) Class V Tooth Preparation

Modified class V design is indicated for:

- Restoration of small and moderate carious lesions and defects.

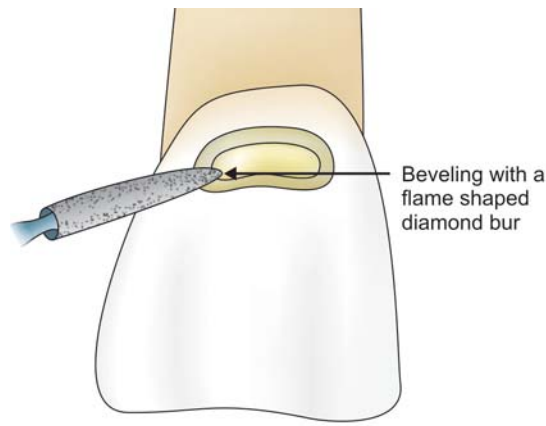


Fig. 11.26: Beveling of preparation using a flame shaped bur

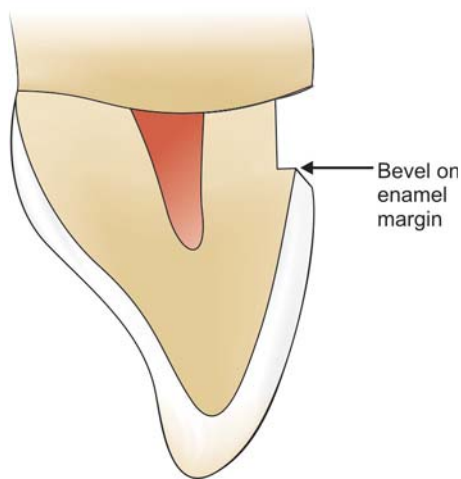
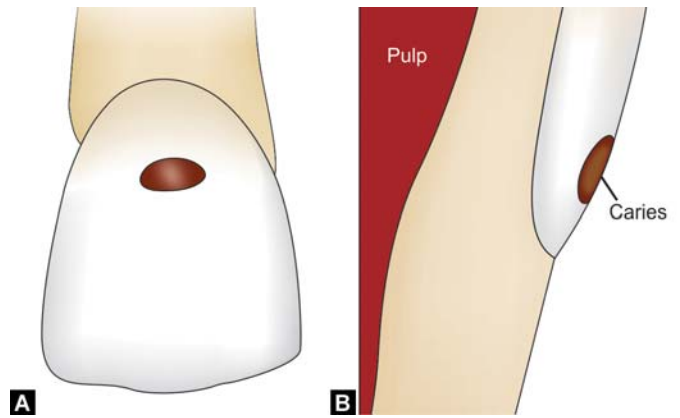


Fig. 11.27: Beveling is done on enamel surface



Figs 11.28A and B: Modified class V tooth preparation is indicated only in cases when small lesion is present in cervical third of the teeth

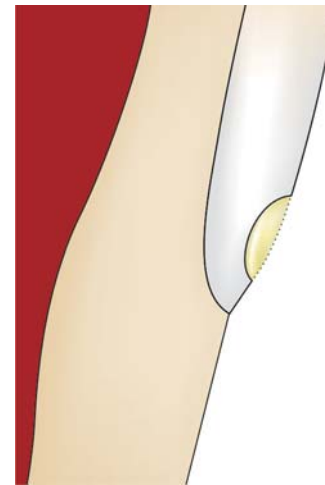


Fig. 11.29: Scooped out appearance of tooth preparation

- Small enamel defects like decalcified and hypoplastic areas present in cervical third of the teeth (Figs 11.28A and B).

Modified class V tooth is prepared as discussed in previous modified preparation.

The final tooth preparation should have 'scooped out' appearance with divergent walls and axial wall either in enamel or in dentin (Fig. 11.29).

### RESTORATIVE TECHNIQUE FOR COMPOSITES (FIGS 11.30A TO F)

#### Pulp Protection

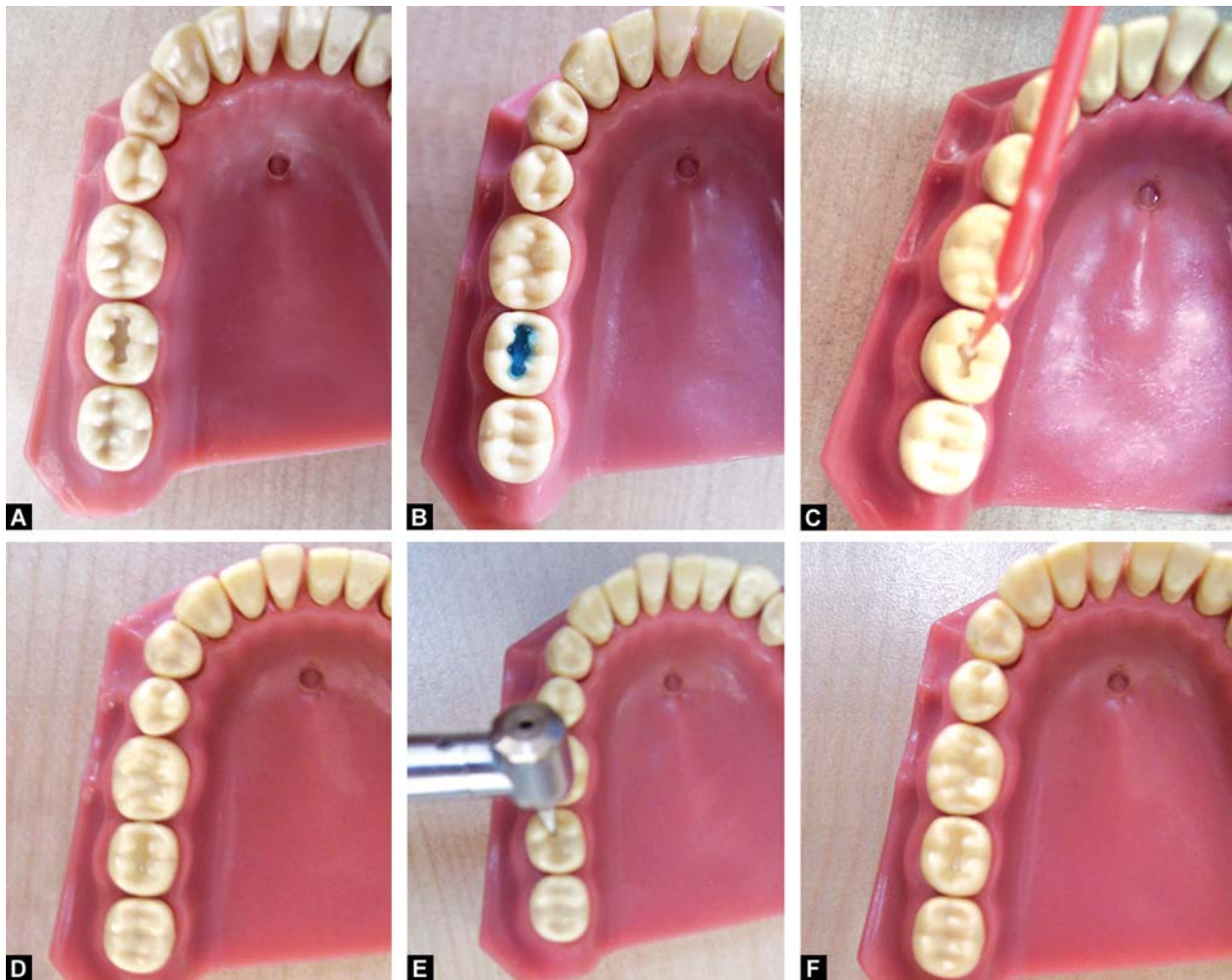
Zinc oxide eugenol should not be used as a sub-base because it inhibits the polymerization of resins.

If the intermediary basing has been applied, all dentinal walls and floors should be covered with powdered calcium hydroxide, before etching is carried out. This calcium

hydroxide should be removed after etching. If the tooth preparation is deep, that is, it has less than 1 mm distance from the pulp, it is preferable to use a glass ionomer base before acid etching because of following reasons:

- There is compromised resin bond strength in the areas of partially demineralized or deep dentin areas which results in a gap formation between restoration and the tooth. Since glass ionomer cements undergo minimum polymerization shrinkage during the setting reaction, this tends to preserve the bonded interface.
- For rerestitution in future, the presence of the white opaque surface of glass ionomers makes them easily distinguishable from the tooth surface.
- Anticariogenicity property because of fluoride release from glass ionomer cement.
- Use of glass ionomer cement decreases postoperative sensitivity.

Apply glass ionomer liner, etch the preparation, wash and gently air dry it. Then apply bonding agent and cure it.



**Figs 11.30A to F:** Restorative technique for composites; (A) Class I tooth preparation (37), (B) Application of etchant, (C) After washing and rinsing, application of adhesive resin, (D) Placement of composite, (E) Finishing of composite restorations, (F) Completed composite restoration

### Etching of the Tooth Preparation

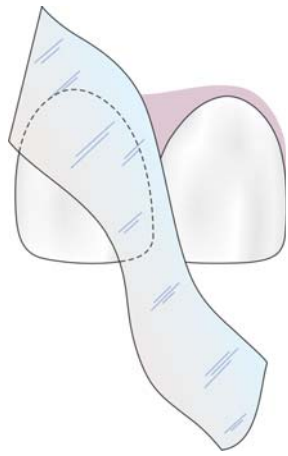
First of all, proximal surface of adjacent unprepared tooth should be protected from involuntary etching by covering it with a polyester strip. Then apply a gel etchant with a syringe or brush to the prepared surfaces, approximately 0.5 mm beyond the cavosurface margins onto the unprepared tooth surface. Usually 37% buffered phosphoric acid is used to provide the optimal etch pattern having ground glass or frosted appearance. Etching is done for generally 15-20 seconds. After this, rinse the etched area for at least 15 seconds with copious amounts of water. Dry the area if only enamel has been etched but leave it moist if only dentin is involved in the tooth preparation. If by chance dentin has been dried, rewet it with water-saturated applicator tip.

### Application of Adhesive System

After etching, a primer and an adhesive are applied according to the instructions provided. Though bonding systems are available in different forms, current bonding systems combine the primer and adhesive into a single bottle, thus making the application easier. Use disposable brushes or applicator tips for applying the adhesive agents (**Fig. 11.31**). One should avoid collection of these resins in corners and line angles. If the system does not contain both primer and adhesive, bonding adhesive is applied after the primer and polymerized with curing light.

### Matrix Application

A matrix helps in confining the excess restorative material and in development of appropriate axial tooth contours. It



**Fig. 11.31:** For class III restoration, a properly contoured mylar strip is used

also helps in isolation of the prepared tooth. The matrix should be applied and stabilized by a wedge before applying etchant, primer and adhesive to protect the adjacent teeth from being etched and bonded. The matrix should extend 1 mm beyond the incisal and gingival cavosurface margins.

#### Matrix used for composite resin

1. Mylar strip matrix
2. Compound supported metal matrix.

For class III restoration, a properly contoured wedge supported, clear polyester mylar strip matrix is used (**Fig. 11.31**).

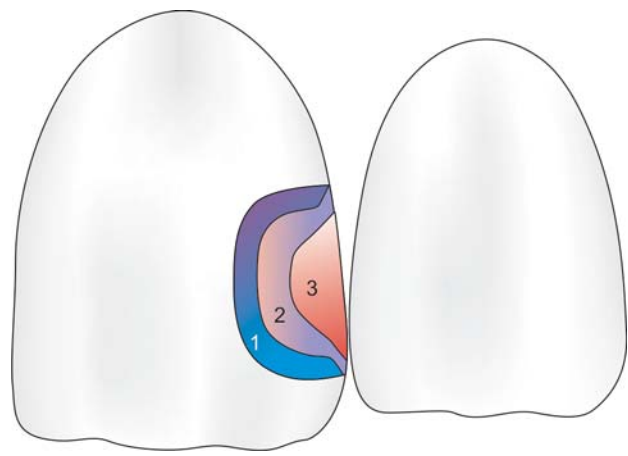
#### *Mylar strip serves the following purposes:*

- Contains the material
- Restores the proximal contact
- Reduces flash
- Reduces oxygen contact with the surface of the composite so ensures more complete polymerization.

### Composite Placement

#### *Placing Self-Cured Composite*

Mix the base and accelerator paste for bonding adhesive on a pad and immediately apply to etched enamel and primed dentin with a microbrush. Simultaneously, mix the base and catalyst paste of selected composite on mixing pad for 30 seconds and place it into the preparation. Use hand instrument to spread the composite material uniformly and plugger to condense it. If two or three increments are needed for packing the preparation, they should be placed in less



**Fig. 11.32:** Composite should be placed in small increments so as to reduce polymerization shrinkage

than one minute for insertion. Slightly overfill the preparation so that condensing pressure can be applied with matrix strip. Remove gross excess using sharp spoon excavator. Close the lingual end of strip over the composite followed by the facial and tighten the matrix using pressure from fingers holding the strip. Hold the matrix for approximately three minutes, until polymerization is complete and the composite hardens. After the composite has hardened, remove the wedge and matrix strip.

#### *Placing Light-Cured Composites*

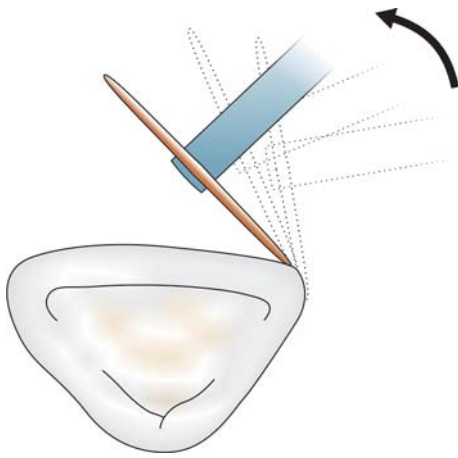
As we know that greater the bulk of material, the greater is the shrinkage and, thus more is the resultant stress on bonded interfaces. Therefore, composite restoration should be placed in small increments to reduce polymerization shrinkage (4-7% shrinkage) (**Fig. 11.32**). Place the first increment of composite using a plastic instrument and pack.

After its insertion, cure it for 20 to 30 seconds by holding the light source close to but not in contact with the restorative material. Longer exposure to light is required for darker and opaque shades. Each increment is added and cured till the complete preparation is filled.

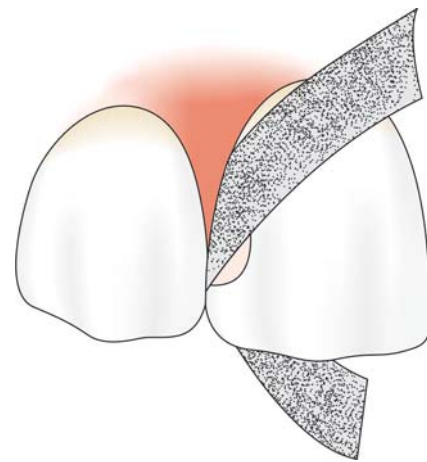
### Final Contouring, Finishing and Polishing of Composite Restoration

The main objectives of contouring, finishing and polishing of final restoration are to:

- Attain optimal contour
- Remove excess composite material
- Polish the surface and margins of the composite restoration.



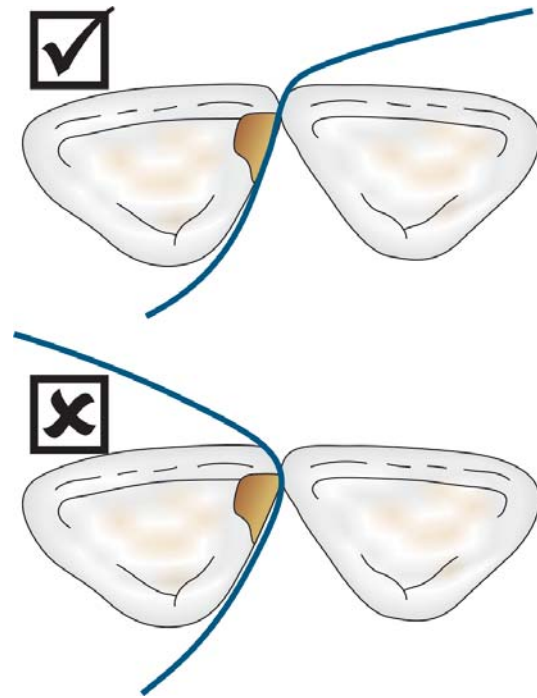
**Fig. 11.33:** Gross proximal contouring of restoration can be done using small thin disc rotating from 90° towards the facial surface



**Fig. 11.34:** Contact area is polished with the help of abrasive finishing strips

1. For composite restorations, the amount of contouring required after final polymerization of the composite can be reduced by careful placement technique. Minimizing contouring retains the sealed margins of the restoration. It also helps minimizing microcracks which can be formed by using abrasives on the surface of restoration.
2. Remove flash with a sharp hand instrument. Any excess material can be trimmed with sharp scalpel blade no. 11, composite finishing diamond bur and/or multibladed tungsten carbide finishing bur. Use a coolant/lubricant in gross reduction to reduce production of heat and friction.
3. Gross contouring of proximal restoration can be done using a small and thin disc rotating from 90° towards the facial surface (**Fig. 11.33**).
4. Contact areas may be finished by using a series of abrasive finishing strips threaded below the contact point so as not to destroy the contact point (**Fig. 11.34**). In class III restoration, to avoid any damage to contact point, the finishing strip should be used in S-shaped pattern. If strip is pulled on same side it can lead to open contact points (**Fig. 11.35**).
5. Final contouring, finishing and polishing of a composite restoration is done with finishing diamond points (**Figs 11.36A and B**). Polishing is done using rubber-polishing points, abrasive disks or pumice-impregnated points.

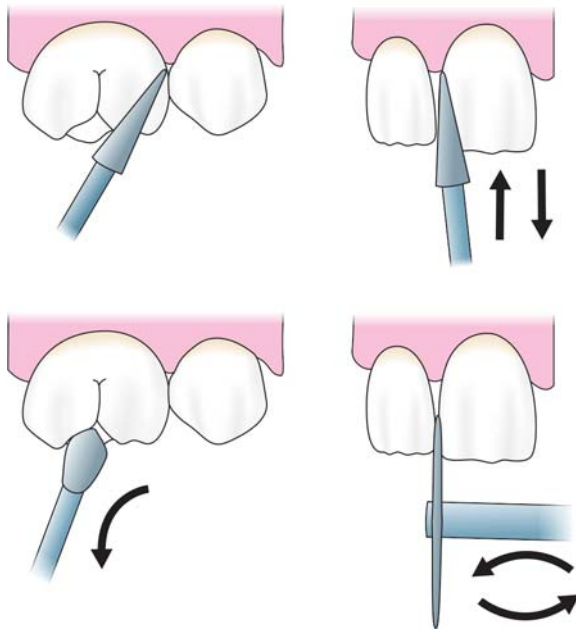
Check the contours and margins on proximal area with explorer and dental floss. A sharp no. 12 surgical blade in BP handle or gold finishing knife contouring, is used for contouring and finishing of composite filling at gingival margin. It is specially important to avoid creating a ledge cervically as it is difficult to remove excess from this area.



**Fig. 11.35:** In class III restoration, to avoid damage to contact point, finishing strip should be used in S-shaped pattern. Pulling of strip on same side can lead to open contact points

### Checking the Occlusion

After contouring of restoration, occlusion is evaluated in centric position and during various mandibular movements for proper contacts. If occlusion is not proper, further adjustments are made and restorations are finished with fine rubber abrasive points or disks.



**Figs 11.36A and B:** Final contouring, finishing and polishing of restoration is done with the help of finishing diamond points

### Glazing

The surface smoothness and shine of a composite restoration can be increased by a “glazing”. Glazing is the process of placing of a thin layer of unfilled resin over the finished composite resin. This is then light cured. The resultant surface is very smooth and shiny initially but it lasts only for a few weeks. Since it lacks the abrasive resistance and adhesion, with time the surface is abraded away during function. To improve the adhesion of glaze, before glazing the restoration, surface should be etched with low concentration of hydrofluoric acid.

*Glazing serves the following purposes:*

- Improves aesthetics.
- Creates a smooth glossy surface, resistant to plaque retention.
- Fills surface porosity.

### FAILURES IN COMPOSITE RESTORATIONS

Composite restorations may show failure because of:

- Incomplete removal of carious lesion
- Incomplete etching or incomplete removal of residual acid from tooth surface
- Excess or deficient application of bonding agent

- Lack of moisture control
- Contamination of composite with finger/saliva
- Following bulk placement technique during polymerization of composite
- Improper polymerization method
- Incomplete finishing and polishing of composites
- Inadequate occlusion of restored tooth

*Following Failures are Commonly seen in Composite Restorations with Time*

- Discoloration, especially at the margins
- Fracture of margins
- Secondary caries
- Postoperative sensitivity
- Gross fracture of restoration
- Loss of contact after a period of time
- Accumulation of plaque around the restorations.

**Certain Guidelines should be followed which can Minimize the Chances of Composite Failure:**

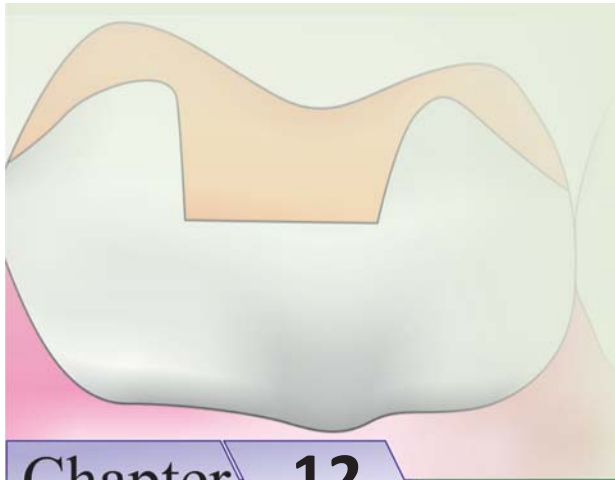1. The tooth preparation should be kept as small as possible since composite in bulk lead to failure
2. Avoid sharp internal line angles in tooth preparation, which increases stress concentration
3. Deeper preparations should be given base of calcium hydroxide or glass ionomer cement
4. Strict isolation regime is to be followed
5. Avoid inadequate curing, since it leads to hydrolytic breakdown of composites
6. Use small increments, holding each increment with teflons coated instruments.
7. Fill proximal box separately and create proper contact areas
8. Composite, especially at the beveled areas, should be finished and polished properly.

### REPAIR OF COMPOSITE RESTORATIONS

When the area to a defective restoration is accessible, for repair, the old restoration is roughened with a diamond stone and the enamel margins are etched. After this, primer and adhesive are applied and finally composite is placed, finished and polished. In case, when the defective restoration is in area which is difficult to access, the defective restoration should be exposed by tooth preparation. After this, place a matrix and wedge and etch the enamel margins. Apply primer and bonding agent and finally place composite. Cure it and do the final finishing and polishing.

**VIVA QUESTIONS**

- 
- Q. Define composites.
- Q. What is composition of composites?
- Q. What are advantages of fillers?
- Q. What are disadvantages of fillers?
- Q. What are hybrid composite resins?
- Q. What are advantages and disadvantages of hybrid composites?
- Q. What are nanofill and nanohybrid composites?
- Q. What are microhybrid composites?
- Q. What are advantages of microhybrids?
- Q. Why do flowable composites have less viscosity?
- Q. What are advantages of flowable composites?
- Q. What are disadvantages of flowable composites?
- Q. What makes the condensable composite highly viscous?
- Q. What are advantages and disadvantages of composite resins?
- Q. Where are packable composites used?
- Q. What are GIOMERS?
- Q. What are PRG composites?
- Q. What are advantages of GIOMERS?
- Q. What are compomers?
- Q. What is composition of compomers?
- Q. What are advantages of compomers?
- Q. What is difference between COMPOMERS and GIOMERS?
- Q. What are ORMOCERS?
- Q. What are advantages of ORMOCERS?
- Q. Which chemicals are used in antibacterial composites?
- Q. How can coefficient of thermal expansion of composites be reduced?
- Q. Mention different factors affecting wear of composites?
- Q. What is polymerization shrinkage?
- Q. How can we reduce polymerization shrinkage?
- Q. What are ill-effects of polymerization shrinkage?
- Q. Define C-factor?
- Q. What is value of C-factor for class I and class II preparation?
- Q. Define Nano-leakage? How does it occur?
- Q. What is microleakage? How is it caused?
- Q. Are composites biocompatible?
- Q. How does distance between light source and composite resin affect polymerization?
- Q. Where do we use composite material?
- Q. Where are composites contraindicated?
- Q. What are advantages of composites?
- Q. What are indications of conventional tooth design for composite restoration in class III preparations?
- Q. What are indications of beveled tooth preparation for composite restoration in class III cases?
- Q. What is modified tooth preparation for class III lesions?
- Q. What is shape of class V conventional preparation for composites?
- Q. What are the indications of modified class V tooth preparation for composites?
- Q. What are different steps of composite placement?



# Cast Metal Restorations

## Chapter 12

### INTRODUCTION

#### INDICATIONS OF METAL INLAY AND ONLAY CONTRAINDICATIONS OF METAL INLAY AND ONLAY

#### ADVANTAGES OF CAST METAL RESTORATIONS

#### DISADVANTAGES OF CAST METAL RESTORATIONS

#### PRINCIPLES OF TOOTH PREPARATION FOR CAST METAL INLAY

- Preparation Path
- Inlay Taper
- Circumferential Tie

#### STEPS OF TOOTH PREPARATION FOR INLAY

- Occlusal Outline Form
- Proximal Box Preparation
- Resistance and Retention Form
- Placement of Grooves, Bevels and Flares

#### MODIFICATIONS IN CLASS II TOOTH PREPARATION FOR INLAY

- In Mandibular First Premolar
- For Esthetic Reasons
- In Maxillary Molars with Unaffected and Strong Oblique Ridge
- Capping of Cusp

#### ADDITIONAL RETENTION AND RESISTANCE FORM FEATURES FOR CAST RESTORATION

### TECHNIQUE FOR MAKING CAST METAL RESTORATION

- Impression Taking for Cast Metal Restoration
- Record of Interocclusal Relationship
- Temporary (Interim) Restoration
- Working Cast
- Working Die
- Wax Pattern Fabrication
- Spruing
- Washing of Wax Pattern
- Investing
- Casting Procedure
- Cleaning of Casting
- Trying in the Casting
- Cementation of the Casting

### CASTING DEFECTS

- Surface Roughness and Irregularities
- Distortion
- Incomplete Casting and Rounded Margins
- Discoloration
- Porosity

### PIN RETAINED CAST RESTORATIONS

- Indications for Pin Retained Cast Restorations

### INTRODUCTION

Though various defects of teeth can be restored using different restorative materials like amalgam, composite resins, direct filling gold and cast metal restorative materials. Each material has its own indications, contraindications, advantages and disadvantages. When sufficient tooth

structure is not present for the support of restoration, then cast metal restorations are indicated. Cast metal restorations were introduced in dentistry about 100 years ago and soon they became a subject of great interest to both dentists and patients. Most advantageous properties of gold alloy is its malleability, and when properly manipulated, it has wear



similarly to that of tooth structure. Cast gold restorations became most popular from the 1930s to the 1970s because of their acceptable functions and restorative longevity. Most of the cast metal restorations are made from alloys formed by combination of gold with other metals such as silver, copper, zinc, platinum and palladium. Casting procedures have been used for replacement of teeth by means of fixed and removable partial denture prosthesis, and full mouth restorations.

In operative dentistry, cast metal restorations are mainly used in three forms:

1. Inlay
2. Onlay
3. Partial crown.

After 1970s, restorative materials providing esthetics came into light. And after that there was increase in awareness of tooth colored restorations in comparison to cast gold restorations.

History of casting of objects in gold by the wax elimination process dates back to four or five thousand years ago by Chinese. Italian artisan Benvenuto Cellini described the use of this technique to make statues and artistic pieces. Dr Taggart developed a technique of casting gold inlays by the invested wax pattern method, introduced this to the profession in 1907.

In 1897, Dr Philbrook read a paper "Cast Fillings".

In 1908, Dr JG Lane developed casting into a hot mold using an investment with a high silica content.

In 1909, Dr CS Van Horn evaluated wax expansion, this was an attempt to overcome the effects of shrinkage of the gold alloy.

In 1930, Dr Carl Scheu discovered the phenomenon of hygroscopic setting expansion.

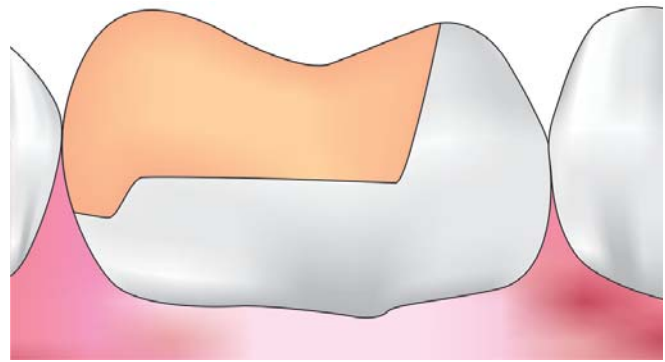
Dr GV Black's principles of cavity preparation were vital to success of cast metal restorations then as they are today.

**Inlay:** An inlay is an indirect intracoronal restoration which is fabricated extraorally and cemented in the prepared tooth. Inlay may cover none, or all but one cusp of a tooth.

**Onlay:** An onlay is a combination of intracoronal and extracoronal cast restoration which covers one or more cusps.

**Class II inlay:** Class II inlay essentially involves proximal surface or surfaces of a posterior tooth, usually may involve occlusal surface and also may involve facial and/or lingual surface(s) and covers none or may cover all but one cusp of a tooth (**Fig. 12.1**).

**Class II onlay:** Class II onlay is a modification of the inlay and involves the proximal surface or surfaces, and may

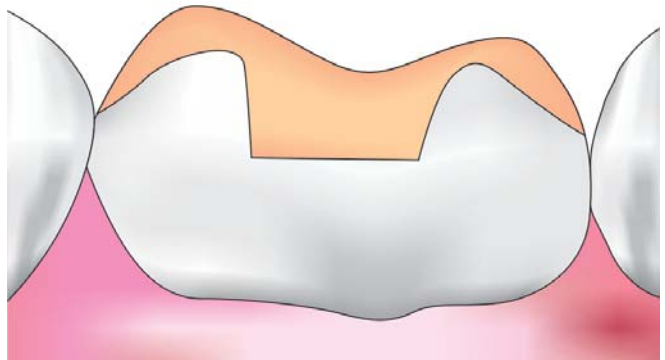


**Fig. 12.1:** Class II inlay

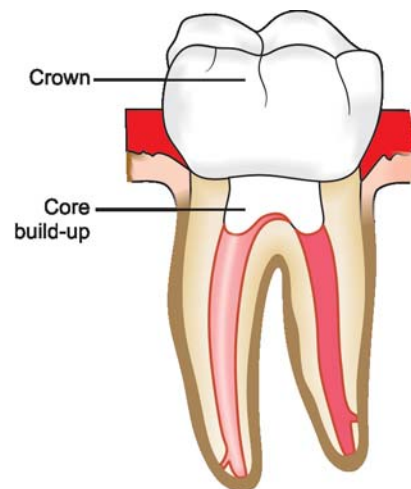
involve facial and/or lingual surface/s of a posterior tooth and covers all the cusps (**Fig. 12.2**).

**Partial crown:** In partial crown, a part of the crown remains uncovered and rest of the crown is covered like three quarter crown and seven-eighth crown.

**Crown:** A crown completely covers the crown of the tooth (**Fig. 12.3**).



**Fig. 12.2:** Onlay



**Fig. 12.3:** Crown given on root canal treated tooth

## INDICATIONS OF METAL INLAY AND ONLAY

- In extensive proximal surface caries in posterior teeth involving buccal and lingual line angles.
- In patients with good oral hygiene and low caries index.
- Postendodontic restoration are preferably restored by onlay to strengthen the remaining tooth structure and to distribute occlusal forces.
- In teeth with extensive restoration, sometimes fracture line is present in enamel and dentin. Inlay/onlay can brace the tooth and prevent fragmentation of the tooth.
- To maintain and restore proper interproximal contact and contour and for occlusal plane correction.
- When there are other teeth present already restored with cast metal restorations.
- Abutment teeth of removable partial denture are indicated for onlay because they provide superior physical properties to withstand the forces imparted by the partial denture. Moreover, the contours of the rest seats, guiding planes, and other aspects of contour are better controlled when the indirect technique is used.
- In posterior teeth with heavy occlusal forces and attrition.

## CONTRAINDICATIONS OF METAL INLAY AND ONLAY

- Where esthetics is prime consideration because metal inlay and onlay display metal color.
- Patient having high caries index.
- When patient cannot come for second visit.
- In young patients, usually direct restorations are preferred since they require longer and more number of appointments. Also the chances of iatrogenic pulp exposure are more in these patients because of high pulp horns.
- Where expected life of a tooth is short, i.e. periodontally involved teeth in aged persons.
- In cases where extensive caries are present in facial, lingual and multiple surfaces. In such cases, full crown is indicated.
- For patient of low economic status, inlay and onlay are not given because of higher costs.
- In patients having restorations with different metals since dissimilar metals cause galvanic currents when they come in contact with each other.
- When there are extensive occlusal wear facets involving the remaining marginal ridge of the tooth.

## ADVANTAGES OF CAST METAL RESTORATIONS

- Since they are fabricated by indirect technique, there is better reproduction of contacts and contours.

- Cast metal restorations are much more wear resistant than direct composite restorations, especially when restoring the occlusal surface.
- More biocompatible with better tissue response.
- Strengthens remaining tooth structure. In grossly carious lesion the remaining tooth structure is weakened and can be strengthened by the adhesive bonding of indirect inlays/onlays.
- Less chairside time is required.
- Since cast metal restorations are build in bulk and not in increments, there are less chances of voids and internal stresses.
- Extraoral polishing is easy.

## DISADVANTAGES OF CAST METAL RESTORATIONS

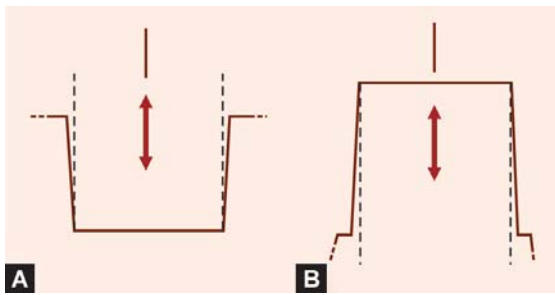
- It requires patient's subsequent appointment, with need for temporary restoration.
- More expensive than direct restorations.
- They are more technique sensitive.
- Repair is difficult with these restoration.
- Bonding of these restoration to tooth is weak at tooth cement casting junction. It can lead to microleakage of the restoration with time.
- Cast metal restorations are not acceptable esthetically.

## PRINCIPLES OF TOOTH PREPARATION FOR CAST METAL INLAY

Preparation of inlay requires some fundamental steps. Each step has equal importance and although some steps are easier to accomplish, each step should be given the same careful attention for successful results.

1. Tooth preparation
2. Impression
3. Die
4. Wax pattern
5. Mold for casting
6. Gold casting.

Any flaw in any of above mentioned steps or lack of attention could result in a failure or unsatisfactory restoration. Among these the single step which can contribute to a large number of failures and which requires a special efforts from the clinician is the tooth preparation. An optimally prepared tooth should meet the standard criteria of a outline form, resistance and retention form, and the other requirements given by GV Black, and also it should be smooth and accurate in both its internal and external form. Ultimately, this accurate, smooth, optimally tapered preparation with sharp margins and internal angles makes it possible to carry-out each of the other steps with accuracy.



**Figs 12.4A and B:** Inlay preparation should have single path of insertion parallel to long axis of tooth

The purpose of proper diagnosis and treatment plan is gone if care is not taken during tooth preparation. The preparation to receive a gold inlay should not only be designed to gain perfection of margins and restore occlusion, but should be made to enhance the strength of the tooth as well.

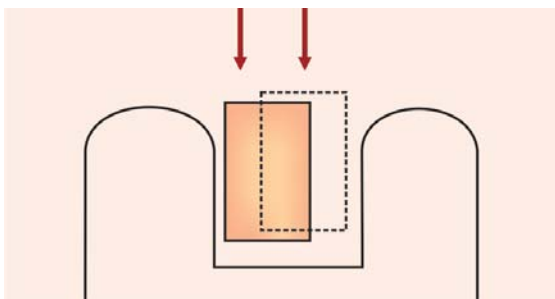
Since cast metal restorations involves making a wax pattern which should be removed from cast or die without any distortion. For this purpose, some fundamental basic designs are incorporated during preparation of class II inlay. These are:

### Preparation Path

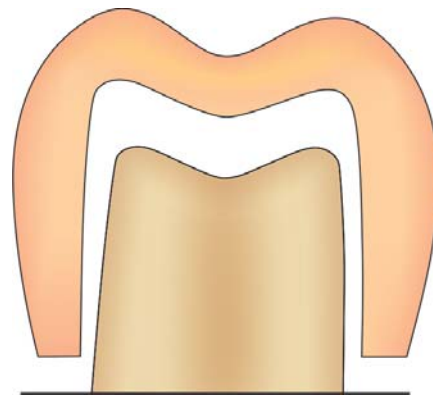
Preparation should have single insertion path opposite to the occlusal load and parallel to the long axis of tooth (**Figs 12.4A and B**). This helps in retention of the restoration (**Fig. 12.5**).

### Inlay Taper

To have unhindered removal and placement of the wax pattern and seating of the final casting, intracoronal and extracoronal tooth preparation should have some taper. Ideally, a tooth preparation should have slight diverging walls from gingival to occlusal surface. This is the concept of taper (**Fig. 12.6**).



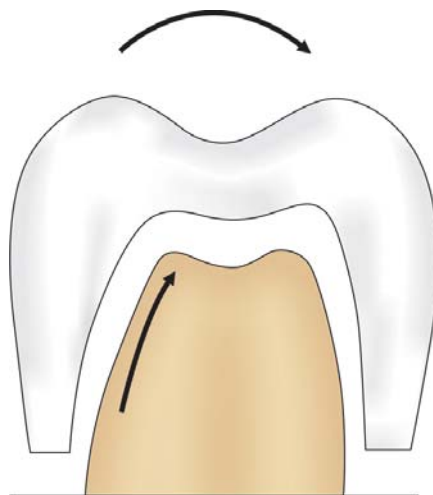
**Fig. 12.5:** With multiple paths of insertion, there is no retention for inlay even if walls are parallel to each other



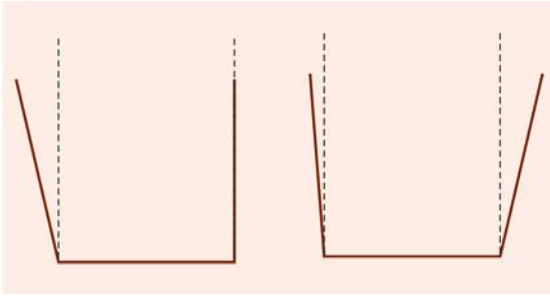
**Fig. 12.6:** A 2°-5° of taper provides optimal retention for inlay

If possible, throughout the tooth preparation, the cutting instrument should be kept parallel to the long axis of the tooth and thus the preparation develops a line of withdrawal. This line of withdrawal also describes the path of insertion and removal of the casting and is the axis of taper. The optimal taper should lie in the range of 2° to 5° per wall. But if longitudinal walls of preparation are short, a maximum of 2° taper is given, and if longitudinal height of preparation is more, then taper should also be increased, although it should never exceed 10° (**Fig. 12.7**). Also the preparation should never have one side with more taper than the other since it can result in more than one path of insertion (**Fig. 12.8**).

For shallow preparations, the axis of taper is usually parallel to the long axis of the tooth and for class V preparations, the axis of taper is perpendicular to the long axis of the tooth. The angle formed by the convergence of the tapered preparation walls to a point of their intersection



**Fig. 12.7:** Giving more than required taper in preparation walls results in reduced retention of inlay



**Fig. 12.8:** Uneven taper of preparation walls result in failure of inlay

is bisected by line of withdrawal. The amount of taper upon opposing preparation walls is described by this convergent angle.

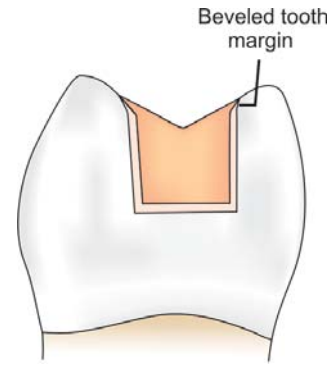
### Circumferential Tie

Circumferential tie refers to the design of cavosurface margin of an inlay tooth preparation. This junction between tooth cement inlay is the weakest part of the cast metal restoration. For the success of restoration, the margins of restoration should be designed so as to achieve its maximum adaptation to tooth structure. Cavosurface margins of an inlay preparation can be of two types:

1. Bevels
2. Flares.

### Bevels

Bevel is defined as the inclination that one surface makes with another when not at right angles. An accurate wax pattern and casting may not have precise adaptation to the margins of tooth preparation if bevel is not given.



**Fig. 12.9:** Bevel helps in better adaptation of restoration to the tooth surface

Objective of bevel is to form a metal wedge of  $30^\circ$  to  $35^\circ$ , thus enhancing the chance to achieve closure at the interface of cast gold and tooth (**Fig. 12.9**). By beveling, a strong enamel margin with an angle of  $140^\circ$  to  $150^\circ$  can be produced.

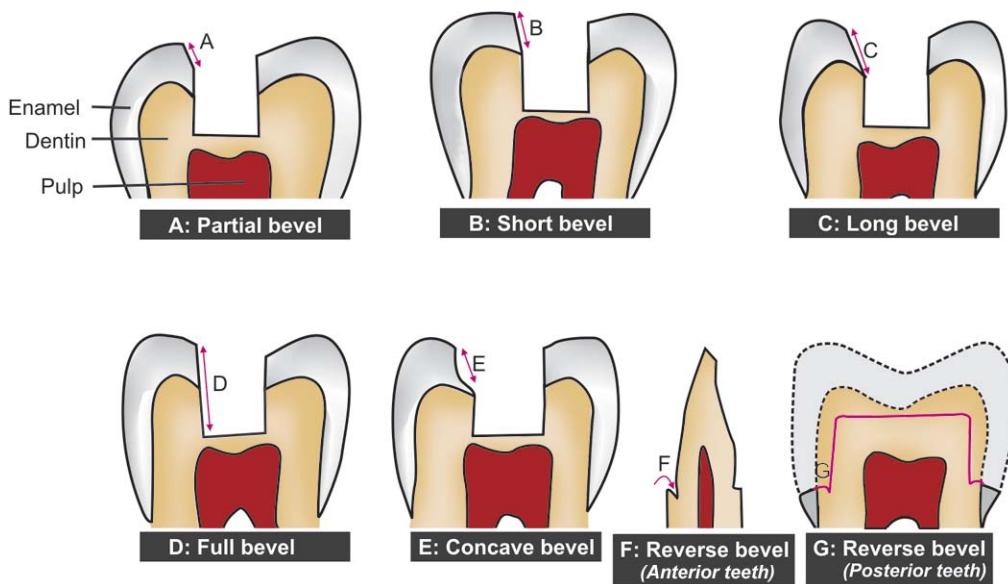
**Types of bevel (Figs 12.10A to G):** According to shape and type of tissue involved, bevels can be:

#### a. Ultrashort or partial bevel

- Beveling of less than two-third of the total enamel thickness.
- Used to trim the enamel rods from preparation margins.
- Used in type I casting alloys.

#### b. Short bevel

- Beveling of full thickness of enamel wall but not dentin.
- Used mostly for restorations with types I and II casting alloys.



**Figs 12.10A to G:** Diagrammatic representation of different bevels

- c. *Long bevel*
- Includes full thickness of enamel and half or less than half thickness of dentin.
  - Preserves the internal “boxed up” resistance and retention features of the preparations.
  - Used in types I, II and III of cast gold alloys.
- d. *Full bevel*
- Includes full enamel and dentinal wall.
  - It deprives the preparation of its internal resistance
  - Full bevel should be avoided except in cases where it is a must.
- e. *Hollow ground (concave) bevel*
- Hollow ground is concave in shape and not a bevel in true sense.
  - It is rarely used.
- f. *Counter bevel*
- Used when capping of the cusps is done to protect and support them.
  - It is opposite to an axial wall of the preparation on the facial or lingual surface of the tooth.
  - It has a gingival inclination facially or lingually.
- g. *Reverse or inverted bevel in anterior teeth:* It is beveling in the reverse or inverted shape given on the gingival seat in the axial wall toward the root in anterior teeth.
- h. *Reverse or inverted bevel in posterior teeth:* In posterior teeth (in MOD preparations for full cast metal restorations), it is used to prevent tipping of cast restoration and to increase the resistance and retention form.

#### Functions of bevels:

- By beveling, weak enamel is removed.
- Beveling produce obtuse angled tooth margins. Resultant cavosurface angle of  $135^\circ$  to  $140^\circ$  forms the strongest and the bulkiest configuration.
- Acute angled metal margins ( $35^\circ$ - $45^\circ$ ) allow the metal margins to be burnished against tooth surface (Fig. 12.11).

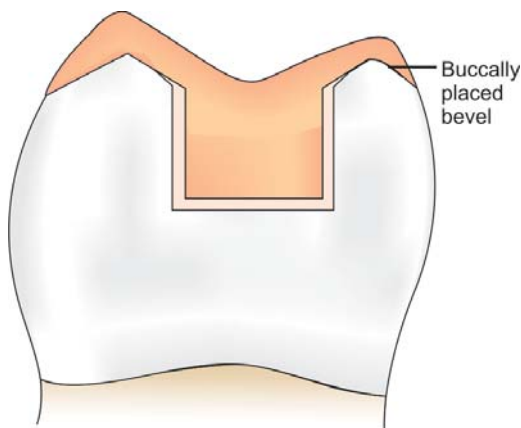


Fig. 12.11: Bevels allow better finishing and burnishing of metal margins against tooth

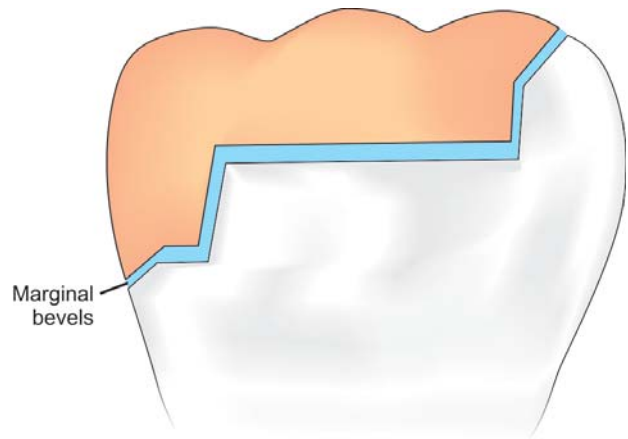


Fig. 12.12: Marginal bevels reduce the space between tooth structure and the restoration, thus help in better retention

- Beveling increases retention, resistance, aesthetics and color matching.
- It improves junctional relationship between the restorative material and tooth (Fig. 12.12).
- The types of margin of tooth preparation depends mainly on the compressive strength, edge strength and tensile strength of the restorative material.
- Bevels are the flexible extensions, i.e. they allow inclusion of faults, wear facets, etc. without overextending the preparation margins.
- Gingival margins become finishable and cleansable because of gingival bevels.
- Counter bevel increases the resistance form to remaining tooth structure.
- Because of beveling, the gingival margin has a lap sliding fit which provides better fit at this region (Fig. 12.13).

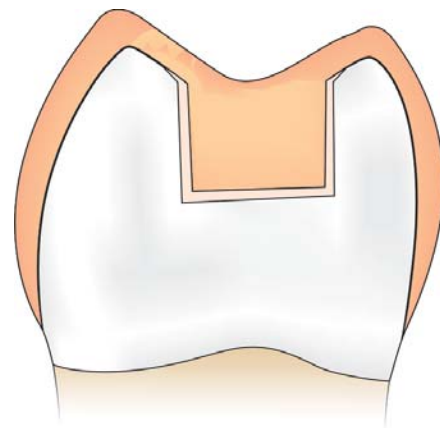
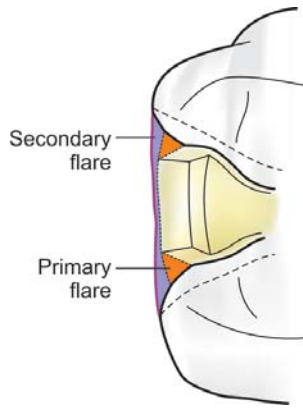


Fig. 12.13: Lap sliding fit of restoration because of bevel



**Fig. 12.14:** Primary flare and secondary flare

### Flares

Flares are concave or flat peripheral portions of the facial or lingual proximal walls. These are of two types:

**Primary flare:** It is basic part of circumferential tie. It is like a long bevel and is always directed  $45^\circ$  to the inner dentinal wall proper (**Fig. 12.14**).

#### Indications:

- Primary flare is indicated when normal contacts are present.
- When there is minimal extension of caries in buccolingual direction.

#### Functions:

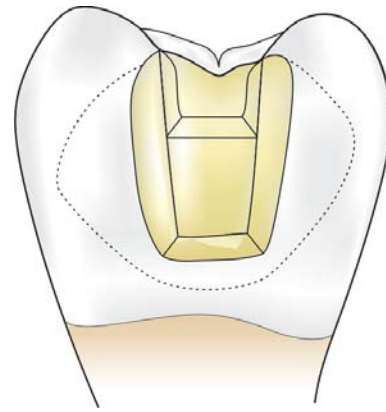
- Weak enamel is removed.
- Improves junctional relationship between the restorative material and tooth.
- Maintains the marginal seal.
- Brings the facial and lingual margins to cleansable and finishable areas.

#### Secondary flare:

- It is a flat plane superimposed peripherally to the primary flare (**Fig. 12.14**).
- It may have different angulations, involvement and extent depending upon requirement.
- Secondary flare is not given in the areas where esthetics is more important.

#### Indications of secondary flares:

- When broad contact area is present.
- To include the faults present on facial and lingual walls beyond primary flare (**Fig. 12.15**).
- When caries are widely extended in buccolingual direction.
- To include the undercuts present at cervical aspect of facial and lingual walls.



**Fig. 12.15:** Secondary flare is extended beyond primary flare to involve all faults and defects

#### Advantages of secondary flare:

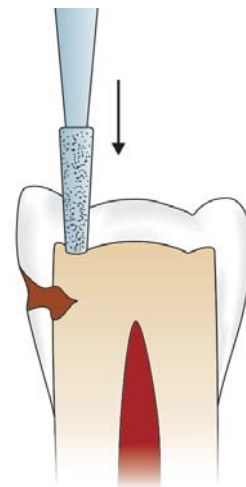
- Secondary flare encourages self-cleansing margins because it is extended into the embrasures.
- Permits easy finishing of the restoration.
- Allows better burnishing of the metal.
- Produces more blunted and stronger margins.

### STEPS OF TOOTH PREPARATION FOR INLAY

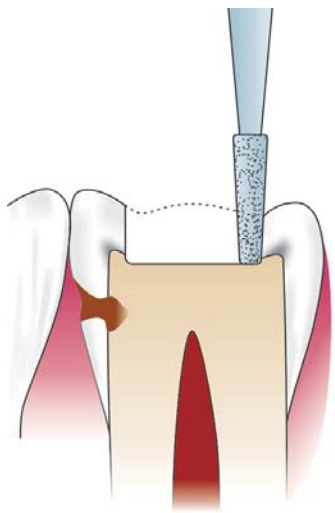
The following steps are involved in the tooth preparation for class II inlay:

#### Occlusal Outline Form

Anesthetize the tooth and apply a rubber dam to give better visibility, tissue retraction, and ease of operation. Penetrate the tooth with no. 271 bur held parallel to long axis of the tooth. The entry point should be closest to the involved marginal ridge (for example, mesial) (**Fig. 12.16**). First

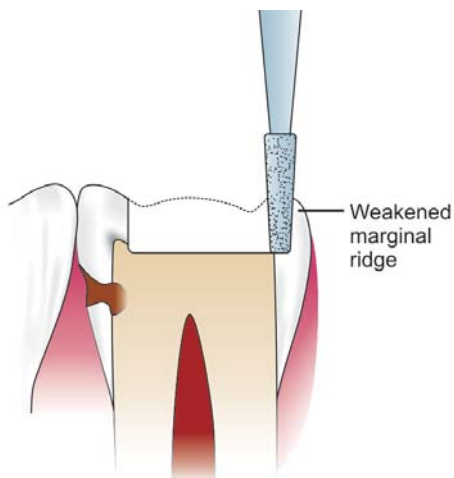


**Fig. 12.16:** Penetrate the bur closest to the involved marginal ridge

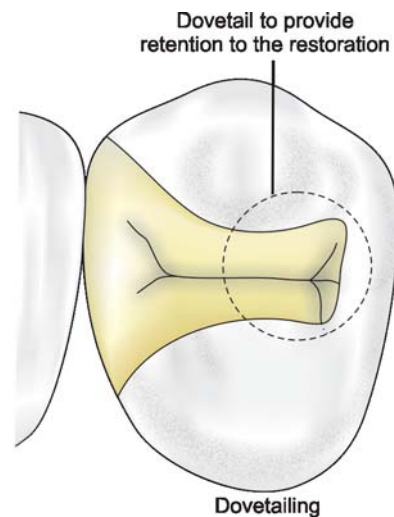


**Fig. 12.17:** Keeping the same depth (1.5 mm), establish the occlusal outline

establish the occlusal outline. Keeping the bur parallel, extend the tooth preparation while maintaining the initial pulpal depth of 1.5 mm. At the same time as the occlusal outline is being established, a flat pulpal floor of proper depth and the occlusal walls of a uniform taper are being prepared with the same bur (**Fig. 12.17**). Care is used to avoid overcutting (**Fig. 12.18**). While maintaining the established pulpal depth and with the bur held parallel to the long axis of the tooth, extend the preparation towards the contact area of the tooth, ending short by 0.8 mm of cutting through the marginal ridge. Now extend the bur to the opposite side of marginal ridge (distal side) and move the bur facially and lingually to make occlusal dovetail which provides retention to the restoration (**Fig. 12.19**). Conserve the marginal ridge on the sound side of the tooth and if any faulty shallow fissure is present, it should be managed during preparation either by enameloplasty or including it using cavosurface bevel.



**Fig. 12.18:** Overcutting can result in weakening of marginal ridge



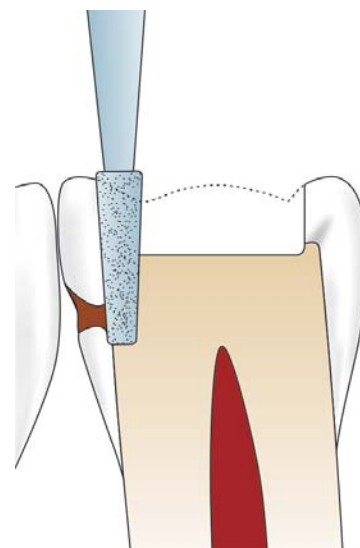
**Fig. 12.19:** Extension of preparation and dovetail

The width of the isthmus of the preparation on the occlusal surface should be maintained to a minimal extension for conservation of tooth structure.

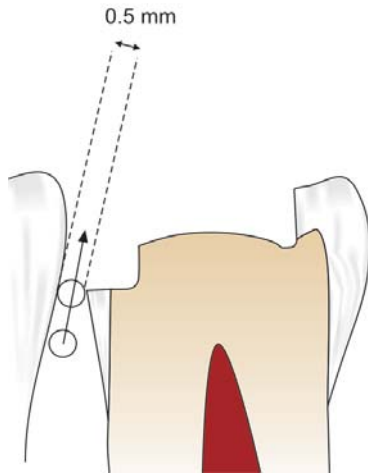
Outline form should be carried onto smooth areas of the buccal and lingual slopes of the cusps of the tooth. This extension will place the margins of the casting in areas where they may be easily finished.

### Proximal Box Preparation

Using the same bur, isolate the distal enamel by proximal ditch cut. Width of this cut should be 0.8 mm with 0.5 mm in dentin and 0.3 mm in enamel. Extend this ditch facially and lingually to the sound tooth structure and proceed gingivally (**Fig. 12.20**).



**Fig. 12.20:** The proximal ditch is given after occlusal preparation



**Fig. 12.21:** The gingival floor should provide at least 0.5 mm clearance from the adjacent tooth

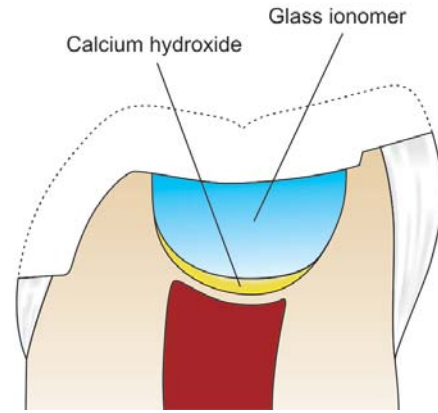
Gingival extension should remove any caries present on the gingival floor and it should provide at least 0.5 mm clearance from the adjacent tooth (**Fig. 12.21**). To break the contact from the adjacent tooth, make two cuts with no. 271 bur; one on facial limit and other at lingual limit of the proximal box. Extend these cuts gingivally till the bur is through the marginal ridge. Keep a small slice of enamel at the contact area to prevent accidental damage to the adjacent tooth. If there is any doubt that accidental damage to the adjacent tooth can occur, use a metal matrix band interdentally. This will offer some protection to the adjacent tooth.

The remaining thin slice of unsupported enamel wall can be removed using hand instruments. In that way the flat gingival floor of proper depth is formed at the same time as the proximal and axial walls are being formed.

The gingival wall is usually established at approximately a right angle to the long axis of the tooth. Gingival bevel is generally placed about one millimeter below the free margin of the gingiva when the tissue is in normal relationship to the coronal portion of the tooth.

### Resistance and Retention Form

- A nicely designed inlay preparation should have proximal box form for retention and flat pulpal and gingival walls for resistance to dislodging forces.
- The extrathickness of gold provided by the box form and the occlusal step of the preparation helps in increasing its retention and resistance.
- The occlusal dovetail of the preparation also provides added retention to the restoration.
- The resistance and retention form of the occlusal step of the preparation will often require variations in design



**Fig. 12.22:** Pulp protection in deep preparation is provided by placing calcium hydroxide as liner and glass ionomer as base

depending upon a careful study of the size and position of the pulp horns.

During final preparation, clean the prepared tooth with air/water spray or with cotton pellet and inspect it for detection and removal of debris and examine for correction of all cavosurface angles and margins.

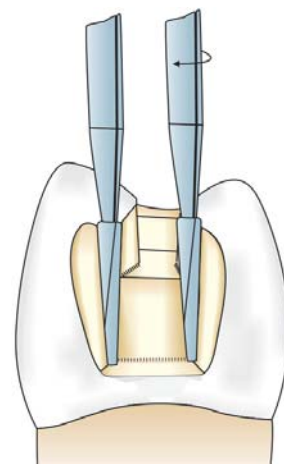
Remove remaining caries, old restorative material and adjacent deep pit and fissure involved in the preparation.

In the large preparations with soft caries, the removal of carious dentin is done with spoon excavator or slow speed round bur. In this, two step pulpal floor is made, i.e. only portion of tooth which is affected by caries is removed, leaving the remaining preparation floor untouched.

Use pulp protective materials whenever indicated (**Fig. 12.22**).

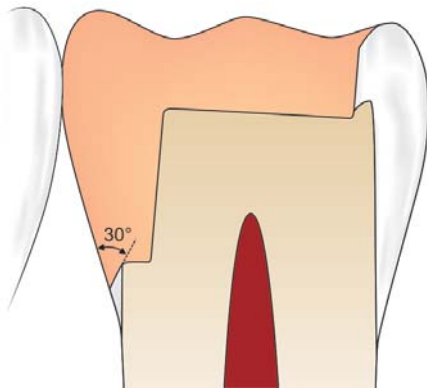
### Placement of Grooves, Bevels and Flares

Retention grooves if needed are placed in the facioaxial and linguoaxial line angles using number 169 L carbide bur (**Fig. 12.23**).



**Fig. 12.23:** Retention grooves are placed in linguo- and facioaxial line angles





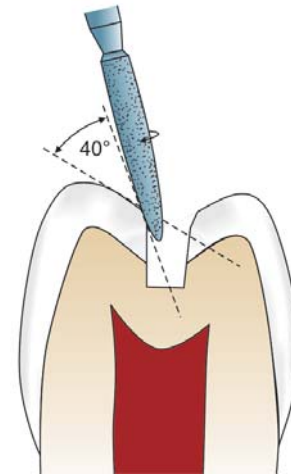
**Fig. 12.24:** Bevel in gingival margin of proximal box

### The Gingival Bevel

It is advantageous to place a gingival bevel of approximately  $45^\circ$  to inlay preparations (**Fig. 12.24**). It should be made smooth and uniformly placed with the help of double ended gingival marginal trimmers. The gingival bevel should include one-half the width of the gingival wall. A properly placed gingival bevel eliminates the possibility of leaving weak or unsupported enamel on gingival wall. It provides a stronger obtuse angle of tooth structure which aids in finishing of the casting and a design which lends itself to a more efficient sealing of the margins of the restoration. Failure to bevel the gingival margin can result in formation of weak margins because of presence of undermined rods (**Fig. 12.25**). Gingival bevels more than  $45^\circ$  results in over extension of the gingival and proximal margins which causes difficulty in impression making, fabricating the wax pattern and finishing of the restoration.

### Occlusal Bevels

It is suggested that the occlusal bevel should be about  $40^\circ$  beginning at the occlusal one-third of the adjacent occlusal



**Fig. 12.26:** Occlusal bevel

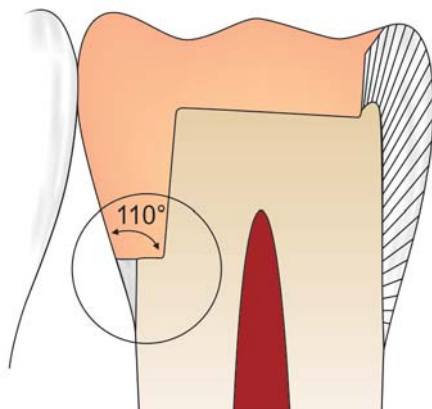
walls (**Fig. 12.26**). The purpose of the bevel is to remove any irregularities in the preparation or unsupported enamel rods at the cavosurface margin (**Fig. 12.27**). This gives the cavosurface margin a smooth, flowing outline. When the cusps are steep, little or no bevel is placed (**Fig. 12.28**), but when shallow cusps are present, a more distinct bevel is placed.

When it is required to cover a cusp with cast metal, prepare a hollow ground bevel using a #7404 twelve-fluted, round ended bur. This allows bulk of the restoration at the cavosurface margin.

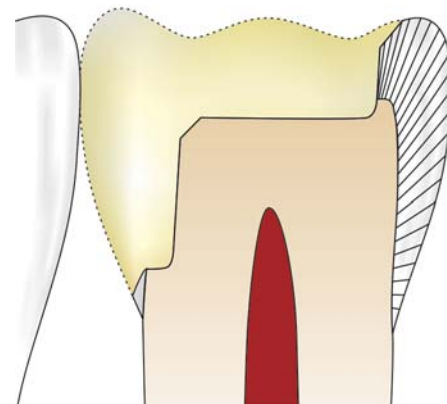
Finally finishing of walls and margins is done by removing all unsupported enamel.

The final stage of inlay preparation is to clean the preparation thoroughly with water and air spray. Then dry it with moist air (**Fig. 12.29**).

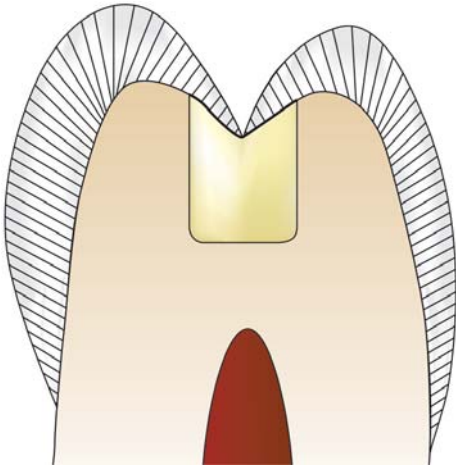
The surrounding margins of a preparation designed to accept a cast metal restoration should form an obtuse angle with the surface of the tooth. This gives the advantage of



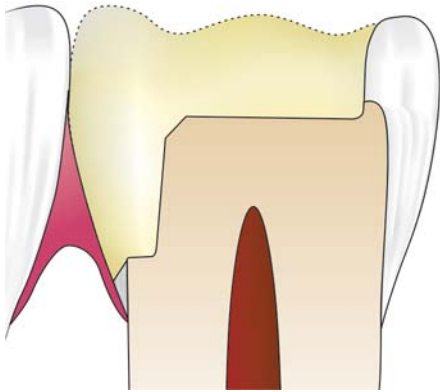
**Fig. 12.25:** If no bevel is given, unsupported enamel rods can cause restoration failure



**Fig. 12.27:** Bevel helps in removing unsupported enamel rods at cavosurface margins



**Fig. 12.28:** When cusps are steep, no occlusal bevel is placed especially in case of narrow preparation because here while occlusal preparation enamel rods of inner one-third of inclined plane get beveled automatically



**Fig. 12.29:** Completed inlay tooth preparation

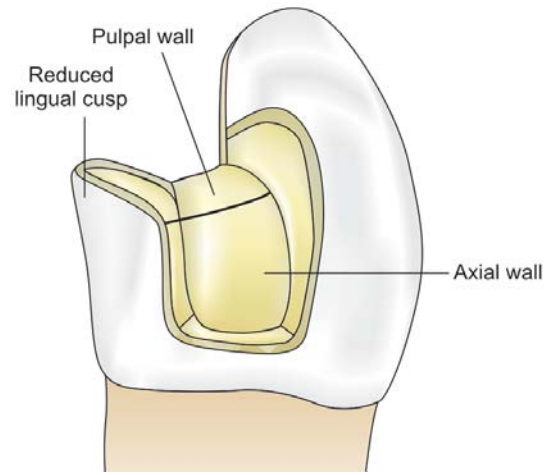
being able to finish an acute angle of tough malleable gold alloy against an obtuse angle of tooth structure.

## MODIFICATIONS IN CLASS II TOOTH PREPARATION FOR INLAY

### In Mandibular First Premolar

As we know, anatomy of the mandibular first premolar is different which requires special attention during tooth preparation. For example:

- Small lingual cusp may require cusp capping whenever indicated (**Fig. 12.30**).
- Occlusal depth should not be more than 2 mm.
- Occlusal transverse ridge is involved when it is defective or when tooth is too small.
- If transverse ridge is strong, smooth and without a faulty central groove, then it should be conserved while preparing a proximal preparation.



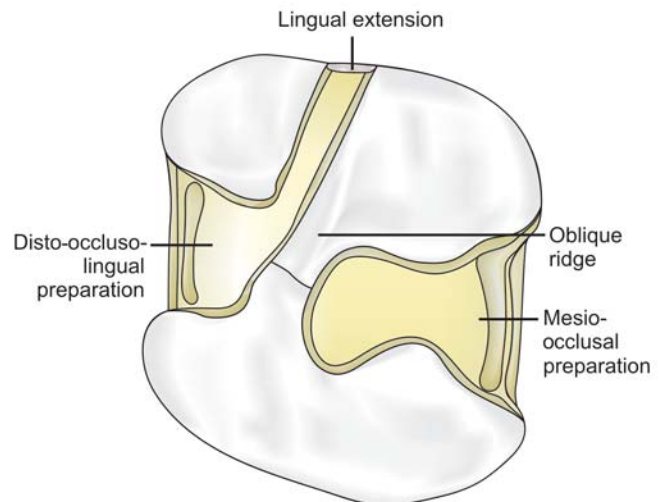
**Fig. 12.30:** Reduction of lingual cusp of mandibular premolar without involving the pulp

### For Esthetic Reasons

In teeth which are esthetically important, for example, maxillary premolars and first molars, the class II preparation involving mesioproximal side indicates less mesiofacial flare for the minimal or no metal exposure.

### In Maxillary Molars with Unaffected and Strong Oblique Ridge

In maxillary molars, oblique ridge provides strength to the tooth. If the oblique ridge is sound and unaffected by caries, then it is always preferred to preserve it while doing tooth preparation. This helps in maintaining the strength of the tooth. In this way, if tooth preparation is to be done on both mesial and distal sides, two separate preparations are made instead of one MOD (**Fig. 12.31**).



**Fig. 12.31:** If oblique ridge is unaffected by caries, two separate preparations can be made on both sides of ridge instead of one MOD

Mesio-occlusal preparation is same as described above. But some points are kept in mind while doing preparation on the distal side, especially when the palatal developmental groove is carious or prone to caries. To obtain adequate retention and resistance form, following can be done:

- Wall of the preparation should be almost parallel or have maximum of 2° occlusal divergence.
- Involve distopalatal cusp in the casting, if indicated.
- Palatal groove extension should not be very close to the distal proximal side, as this will result in weakening of the distopalatal cusp.
- Prepare mesioaxial and distoaxial grooves in the palatal groove extension and palatal and facial retention grooves in the mesial or distal box.

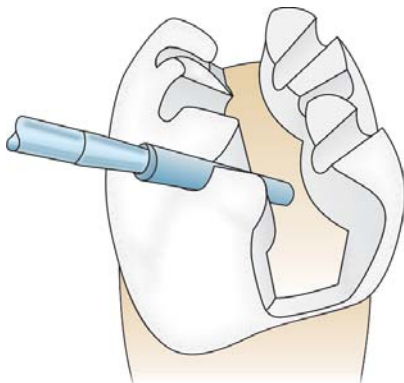
### Capping of Cusp

Cusp capping is indicated when occlusal caries is extensive involving most of the cusp, resulting in weakened cusps and/undermined enamel. When removal of carious structures results in loss of the occlusal surface more than half the distance from primary groove to the cusp tip, the capping of the cusps is desirable and capping is mandatory if two-thirds or more of this distance, is involved.

Cusp capping prevents fracture of the underlying tooth structure since occlusal margins of the preparation are placed away from strong occlusal forces.

### Steps

- Cusp reduction should be started after making a groove (**Fig. 12.32**). Groove helps in accurate and uniform cutting. Different cusps require reduction according to the situation of a particular cusp, in other words all cusps do not require equal reduction.
- While reducing the adjacent cusp, lingual or buccal developmental groove should be involved in cutting.



**Fig. 12.32:** Cusp capping should be done after making grooves so as to have accurate and uniform cutting

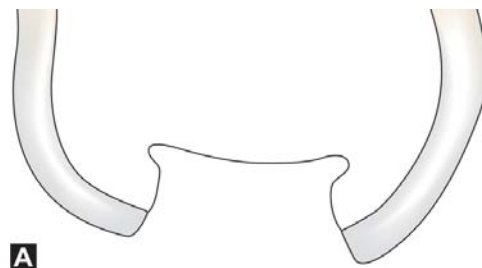
- For increasing retention and resistance, grooves are made at the proximal walls of the box.
- Prepare a reverse bevel or counter bevel on the facial or lingual side of the reduced facial or lingual cusp respectively. This bevel is not given in the areas where esthetics is a prime concern like facial margins on maxillary premolars and the first molar.

### ADDITIONAL RETENTION AND RESISTANCE FORM FEATURES FOR CAST RESTORATION

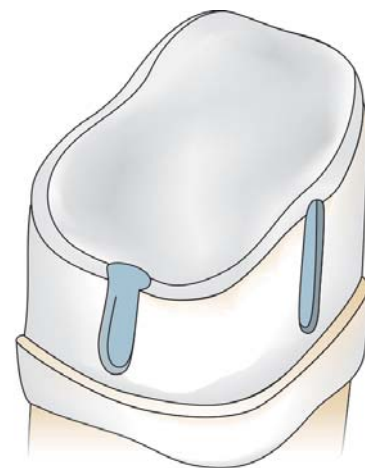
In addition to primary retention forms like parallelism of walls, circumferential tie, masticatory forces directed to seat the restoration and dovetail, etc. following auxiliary means of retention can be used to provide additional retention to the cast restorations.

1. **Grooves (Figs 12.33A and B):** Grooves are placed to provide additional retention and resistance to lateral displacement of mesial, distal, facial or lingual part of the restoration.

Internal grooves are given when preparation is shallow and small. They are contraindicated when preparation is deep with the danger of pulp involvement.



**A**



**B**

**Figs 12.33A and B:** Grooves placed in cast restoration

External grooves are indicated in extracoronal preparations which lack retention because of short preparation with severe taper or excessive width. They are placed at the periphery of preparation so as to prevent its dislocation. Sometimes, external grooves are prepared in stepped form so as to increase the retention form.

2. **Reverse bevel (Fig. 12.34):** It is indicated for class I, II and III restorations. It is used when sufficient dimensions of gingival floor are present so as to accommodate it. It is placed at gingival floor forming an inclined plane directed gingivally and axially.
3. **Internal box (Fig. 12.35):** It is prepared in dentin which forms vertical walls with definite line and point angles. It is indicated when sufficient dentin bulk is present to accommodate. It increases the retention 8-10 times and thus placed at the periphery of preparation close to marginal ridge. It should be at least 2 mm in dimension. Internal box is contraindicated in class IV and V preparations.

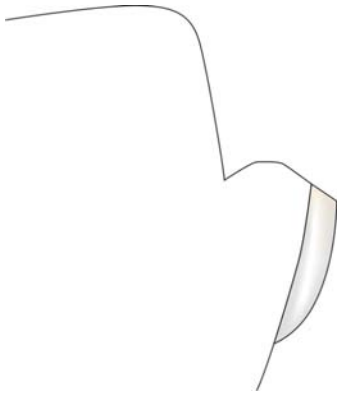


Fig. 12.34: Reverse bevel

4. **External box (Fig. 12.36):** It is box like preparation opening to the axial surface of the tooth. It may have three, four or five walls with a floor. The peripheral portion of their walls can be flared or beveled.
5. **Pins:** Various pins can be used to increase the retention of cast restorations. These can be cemented, threaded, parallel, cast and wrought.
6. **Slot (Fig. 12.37):** Slot is an internal cavity prepared with in the floor of preparation. It is indicated in tooth preparation with shallow depth, and when dovetail cannot be prepared because of restricted occlusal anatomy. They have depth of 2-3 mm and are prepared using round and tapered fissure bur.
7. **Skirt:** It is a specific extension which involves a part of axial wall of the tooth preparation.

It is indicated when restoration has short/missing facial or lingual wall and when defect is more extensive. Skirt is also indicated in cases where contact and contour of the tooth is to be changed.

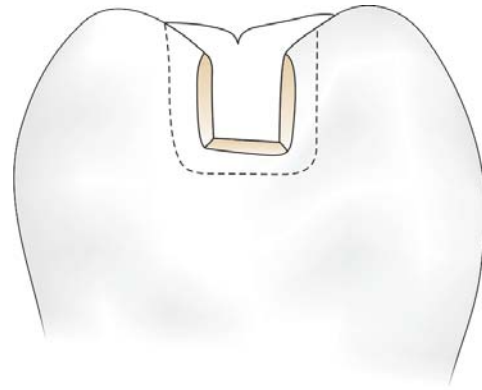


Fig. 12.36: External box

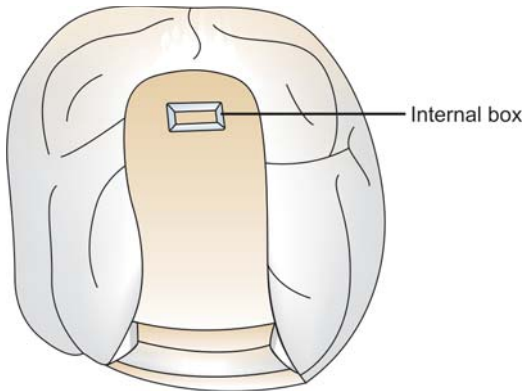


Fig. 12.35: Internal box

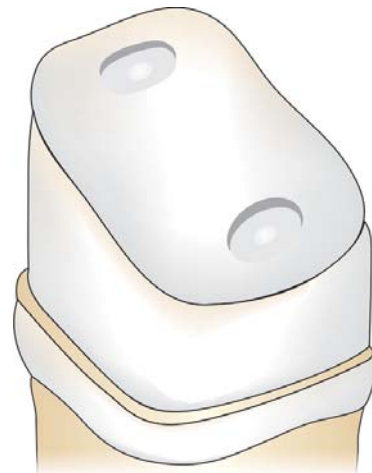


Fig. 12.37: Slot

8. **Collar:** It is surface extension which involves facial or lingual surfaces of one or more cusps. It helps in increasing retention and resistance in case of grossly decayed teeth, in short teeth and in the teeth where pins are contraindicated, collar is prepared 1.5-2 mm deep.
9. **Cusp capping:** Cusp capping also helps in increasing resistance and retention form, provided sufficient height of cusp is present to offer locking mechanism.
10. **Reciprocal retention:** In case of cemented preparations, if restoration is not locked from the opposite end of locked side, movements of the free end create stresses in the locked end. To reduce this, reciprocal retention is provided by placing retention mode at every end of the preparation in form of grooves, dovetail or internal box.

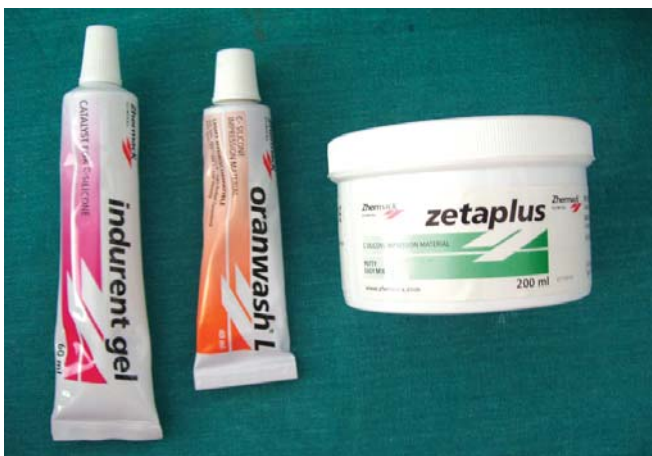## TECHNIQUE FOR MAKING CAST METAL RESTORATION

### Impression Taking for Cast Metal Restoration

For achieving better results, the occlusal contacts in maximum intercuspal position and in all lateral and protrusive movements should be evaluated before and after tooth preparation. After the tooth preparation, the impression of the prepared and adjacent teeth is taken using an elastomeric impression material (**Fig. 12.38**). Before taking impression, gingival retraction cord should be applied first for better recording of gingival margins of the preparation.

Requirements of a material to be used for final impression are that it should:

- Be able to become elastic after placement
- Have adequate strength
- Have dimensional accuracy, stability and reproduction of details.



**Fig. 12.38:** Rubber base impression material

Commonly used impression materials for final impression are:

- Polysulfide.
- Silicone (polyvinyl siloxane impression).
- Polyether impression materials.
- Agar.

Alginate hydrocolloid are mostly used for the impression of opposing arch and rubber impression material are used for the impression of prepared arch.

### Record of Interocclusal Relationship

For single tooth inlay procedure, simple hinge type articulators are sufficient. But for restoring multiple teeth with cast metal restorations, the semi-adjustable articulators are used. Final adjustments in centric occlusion and various mandibular movements are made in the mouth before cementation to assure complete functionally harmonious restoration.

### Temporary (Interim) Restoration

Interim restoration is given to the prepared tooth for the time period between tooth preparation and cementing the restoration so as to protect and stabilize it and to provide comfort to the patient.

An interim restoration should have the following features:

- Nonirritating
- Esthetically satisfactory
- Easy to clean and maintain
- Protect and maintain the health of periodontium
- Adequate strength and retention to withstand the masticatory forces.

Normally, the interim restorations are made up of acrylic resin. They can be prepared by direct and indirect methods.

#### Direct Techniques

- Take preoperative impression of the patient.
- Prepare the tooth.
- Pour the tooth colored self-cure acrylic resin in the preoperative alginate impression in the prepared tooth area.
- Seat the impression onto the prepared tooth and remove it after resin is cured.
- Do final finishing and polishing of temporary.

**Advantage:** Takes less time.

**Disadvantage:** Pulp and periodontal tissue may get trauma from heat produced by direct polymerization of the acrylic and its monomer.

### Indirect Techniques

- Take preoperative alginate impression (called impression no. 1). Preserve this impression in humid conditions by covering with wet cotton.
- Take an impression of the prepared tooth with alginate (called impression no. 2).
- Pour the impression no. 2 with fast setting plaster. Remove any defect if present in the cast and apply coldmold seal separating media over the prepared tooth and about 5 mm around it.
- Mix tooth colored acrylic resin and pour it over impression no. 1 only in the prepared tooth area.
- Now carefully seat the cast prepared by impression no. 2 in the impression no. 1 so as to give shape to the resin for making temporary restoration.
- Remove excessive resin from the embrasure areas.
- Wait for resin to cure completely and remove the cast after it is cured.
- Take out resin crown from impression no. 1 and do the final finishing and polishing.

### Advantages

- Better marginal accuracy.
- Since polymerization takes place outside the mouth, pulp and periodontal tissues are not traumatized by heat of polymerization and monomer.
- Resin cannot be locked on preparation surface of tooth in small undercuts and in the cervical areas.
- Less chair side time.

### Working Cast

Working cast is an accurate replica of the prepared and adjacent unprepared teeth over which cast metal restoration can be fabricated.

For making working cast, commonly type IV or V stones are used since they have superior properties. For making a working cast with removable dies, twice pouring of cast is required from an elastic impression. The first cast prepares the removable die and the second cast establishes the intraarch relationship called “master cast”. These casts are known as split casts.

### Working Die

#### Die Materials

Die is the positive replica of a prepared tooth.

Dies should replicate the tooth preparation in the most minute details along with all accessible unprepared area of the tooth. Though various die materials are available with different properties, the ideal die material should:

- Be compatible with the impression materials.
- Have a smooth nonabradable surface.
- Produce accurate details of impression.
- Have adequate strength.
- Be easy and quick to fabricate.
- Have contrasting color to that of inlay wax.

Commonly used materials for making die are:

- Dental stones
- Electroformed dies
- Epoxy resins
- Divestment

### Dental Stones

The material used to fabricate the die and working casts are usually gypsum products. Most commonly used are type IV dental stone (high strength) and type V dental stone (high strength and high expansion). Higher setting expansion of type V stone compensates for larger solidification shrinkage of base metal alloys.

### Electroformed Dies

Electrodeposition of copper or silver on the impression gives a high strength, adequate hardness and good abrasion resistance to the cast.

**Electroforming (Electroplating/Electrodeposition):** This is a process by which a thin coating of metal is deposited on the impression after which a gypsum cast is poured into the impression. The cast obtained will have hard metallic surface.

*Metals used for electroforming are:*

- Copper
- Silver

### Indications

- Individual tooth impression
- Full (upper/lower) arch impression.

**Epoxy resins:** They are supplied in two—paste and liquid systems which are mixed before insertion into the impression. They are mixed just before using the material. On mixing, they form a viscous paste and poured into impression. The abrasive resistance, strength, and reproduction of details are much better than that of gypsum products.

**Divestment:** Divestment is combination of die material and investing material. Divestment is mixed with a colloidal silica liquid, then a die is prepared from the mix and a wax pattern is made on it. After this the wax pattern with die is invested in divestment. This is highly accurate technique for extracoronary cast gold restorations.

## Wax Pattern Fabrication

There are two methods for wax pattern fabrication:

- **Direct wax pattern method:** In this wax pattern is prepared in the oral cavity.
- **Indirect wax pattern method:** In this wax pattern is prepared outside the oral cavity.

### Direct Wax Pattern Method

Direct wax pattern produces better fitting than indirect method. This method is possible only in inlays and onlays and not in crowns and bridges, etc.

#### Direct wax pattern using matrix band:

- Isolate the tooth using cotton rolls.
- Apply matrix band and retainer. Coat the internal surface of band using separating media like vaseline.
- For making direct wax pattern, type I inlay wax is used.
- Soften the inlay wax by heating and moving it over a alcohol flame.
- Compress the softened inlay wax into the prepared tooth for few minutes with finger pressure. This technique is called “compression technique”.
- Since cooling of wax to the mouth temperature results in shrinkage, it can be compensated by holding the wax in the preparation under finger pressure until it reaches mouth temperature.
- Remove excess of wax and do the carving. With a hot egg burnisher, contour the occlusal portion of the wax pattern.
- Now remove the matrix band and retainer carefully without disturbing the wax pattern.
- Ask the patient to bite in centric occlusion for a few seconds after placing a thin layer of cotton soaked in warm water.
- Examine the occlusal surface for high points and remove them. Do the occlusal carving.
- Pass a floss through the contact area while holding the pattern in place.
- Smoothen the proximal surface of the pattern with fine soft silk.
- Evaluate and correct all the margins of the pattern. Burnish and remove any excess wax over the axial margins with a warm hollenback waxing instrument.
- Finally, examine the pattern. There should be a slight excess of wax over the gingival margin. Add positive contact by applying soft wax.
- Once the satisfactory wax pattern is formed, attach the sprue former and reservoir to the thickest point of the wax pattern.
- Remove the wax pattern from the preparation and examine it for marginal integrity.

### Direct Wax Pattern without Use of Matrix Band

Here the technique is same except that matrix band is not used during fabrication of wax pattern. In this, after the carving of occlusal portion is done, use dental floss to remove extra wax from the proximal portion and to produce proper contact and contour.

#### Advantages

- Less chances of discrepancies.
- Less laboratory time.

#### Disadvantages

- Requires more chair side time.
- Requires more skill.
- Finishing and polishing done on prepared tooth.

### Indirect Wax Pattern Method

#### Indications

- Large preparations like onlays, full coverage crowns and MOD restoration.
- Insufficient access and visibility.
- When minute details like skirts and collars are present.

#### Steps for fabricating:

- Use type II inlay wax for indirect wax pattern.
- Lubricate the die using any lubricating fluid. The lubricator should produce a very thin separator film.
- Adapt the inlay wax to the die by flowing or by the compression technique.
- Do the carving using a warm instrument.
- Attach a sprue former to the wax pattern to the thickest portion as in direct method.

#### Advantages

- Less chair side time.
- Finishing and polishing can be done on die.

#### Disadvantages

- More laboratory work.
- Errors in cast can result in inadequate casting.

## Spruing (Fig. 12.39)

### Principles of Optimal Sprue Design

- Sprue former provides a channel so that molten metal flows into mold space after the wax pattern has been eliminated.
- **A sprue former can be made up of:**
  1. Wax
  2. Plastic
  3. Metal
- **Functions of sprue former:** A sprue former:
  1. Forms a channel through which molten metal can enter during casting.

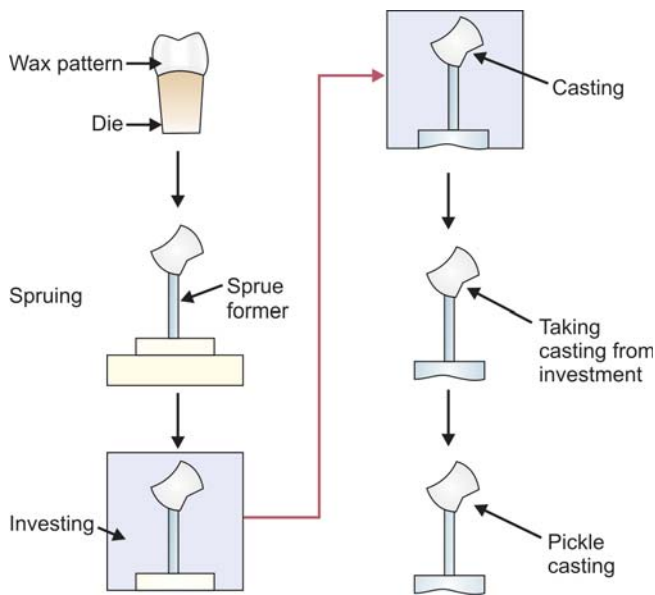


Fig. 12.39: Steps of casting process

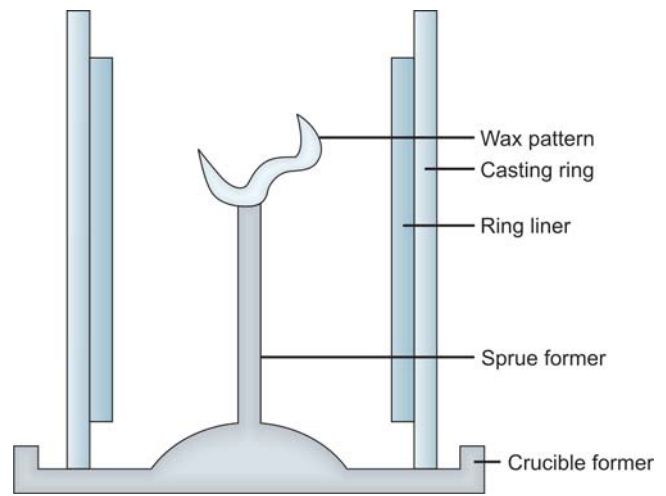


Fig. 12.40: Arrangement in casting ring ready for investing

- Provides a reservoir of molten metal to compensate for metal shrinkage during solidification.
  - Forms a channel for elimination of wax.
- **Sprue diameter:** Sprue diameter usually depends upon the size of wax pattern. It should be either equal or greater than the thickest part of wax pattern.
  - **Attachment of sprue former:** Sprue former should be attached to thickest portions of wax pattern. This helps in minimizing the turbulence of molten alloy. It also reduces residual stresses in wax while attachment of sprue former. It also ensures that molten metal has filled thinner section of the mold.
  - **Sprue length:** Length of sprue former should be long enough so that end of wax pattern is 1/8th to 1/4th of an inch away from the open end of casting ring. This permits the investment to withstand the impact of molten alloy and it also allows gases to escape.
  - **Direction of sprue:** The sprue former should not be attached to thin or delicate parts of wax pattern as molten alloy may fracture investment in that area and may cause failure of casting. It should always be attached at an angle of 45° to bulkiest portion of the wax pattern.  
The sprue former attachment to wax pattern should be flared for high density gold alloys but constricted for base metal alloys (low density alloys).
  - **Reservoir:** Should always be added to sprue former for constant supply of molten metal. This helps in reducing localized shrinkage porosity.

### Washing of Wax Pattern

Before investment, wash the wax pattern with soap and water using soft hair-brush carefully without pooling around internal line angles. It helps in removing the oil, lubricant and saliva. This also reduces surface tension and the air bubbles on the surface of wax pattern, and thus decreases bubbles on the casting.

### Investing (Fig. 12.40)

Once the wax pattern is cleaned, it is surrounded by an investment that hardens and forms the mold in which the casting is made.

Two main methods of investing the wax pattern are:

1. Hand investing.
2. Vacuum investing.

### Casting Procedure

It includes the burnout for wax elimination, expansion of the investment to compensate for casting shrinkage and placement of the gold alloy into the mold. Different types of casting machines are used for casting of gold alloys.

**Basically two types of casting machines are:**

- Centrifugal casting machine
- Air pressure casting machine.

### Centrifugal Casting Machine

It is very popular and cheapest in cost, giving good results for small castings. Here the centrifugal force is used to accelerate the flow of molten metal into the mold space.



Sequence of steps to be followed in gold alloy casting is as follows:

- Heat the ring in which wax pattern has been invested to 1200°F and keep it at this temperature for 15 minutes in the furnace.
- Move the arm of the casting machine by 2 to 3 turns in clockwise direction and lock it so that the arm does not rotate back.
- Heat the gold alloy in the crucible of the casting machine until it becomes bright orange in color and has a shiny appearance.
- Place the casting ring in the cradle of the casting machine. The end of the ring with the sprue way should be towards the crucible. Move up the crucible as close as possible to the casting ring.
- When the gold alloy is fully melt, release the lock of the casting arm so as to force the molten gold into the mold by centrifugal force.
- Remove the ring from the casting machine and keep it in the water keeping sprue end upward and above the water level, and dry, till the ring is cooled.
- Recover the casting and clean it with a bristle toothbrush and water, to remove investment from the casting.

### Air Pressure Casting Machine

In this, compressed air or gases like carbon dioxide or nitrogen is used to force the molten alloy into the mold. This type of machine is preferred for small castings.

### Cleaning of Casting

After completion of casting, the casting ring is removed from the casting machine and quenched.

Quenching involves rapid cooling at room temperature water bath or ice water bath. It does not allow sufficient time for atomic movements to form an ordered structure. This disordered structure is retained at room temperature, making it soft and ductile. This helps in final adjustments easier.

### Advantages of Quenching

- Easy removal of casting from casting ring due to cracking of investment material.
- Keeps the gold alloy in annealed state for easy burnishing and polishing.

**Pickling:** The surface of casting usually appears dark due to presence of oxides and other contaminants. This type of film can be removed by method known as “pickling”. Pickling is process in which discolored casting is heated with an acid in test tube or beaker.

*Solution preferred for pickling are:*

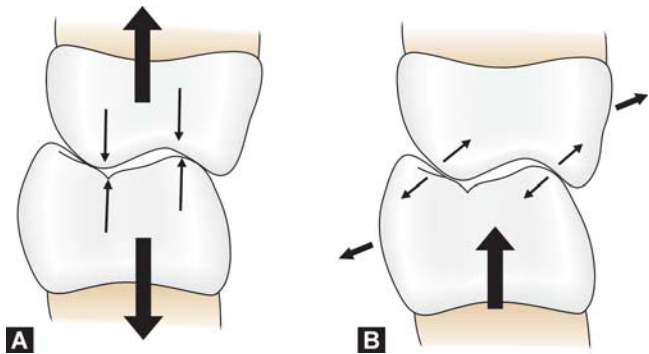
- Fifty percent hydrochloric acid solution (best suited for gypsum bonded investment).
- Fifty percent sulfuric acid.

*Precautions to be taken during pickling:*

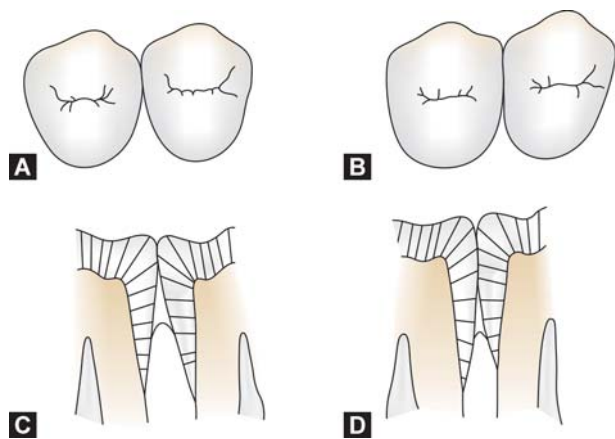
- Casting should not be heated and then dropped into the pickling solution as margins of casting may be distorted during heating.
- Casting should not be held with steel instruments as this may contaminate the pickling solution and casting.
- Acid solution should not be boiled rather it should be heated.
- Use fresh solution every time.

### Trying in the Casting

- Before the “trying in” procedure, remove the temporary restoration and cement completely and carefully.
- Place a four layered gauze piece as a throat screen during trying in and removal of small indirect restoration till the cementation of the casting.
- Place the casting on the tooth using light pressure. If it does not seat properly, do not force it in the preparation. Overcontoured proximal surfaces may also prevent seating of the casting.
- Check the occlusion by asking patient to bite on bite paper. High points in restoration results in perforation of articulating paper. Improper occluding contacts make the tooth unstable and tend to deflect it (**Figs 12.41A and B**).
- Evaluate the embrasures and judge the points where proximal recontouring is required. Contacts can be present too occlusally, broad faciolingually or occlusocervically (**Figs 12.42A to D**).
- Pass the dental floss through the contact to find out the tightness of the contact and its locations.



**Figs 12.41A and B:** (A) Proper occlusion tends to stabilize the cast (B) Improper occlusion tends to deflect the tooth



**Figs 12.42A to D:** (A) Proper contact (B) Contact too broad faciolingually (C) Contact too occlusally (D) Contact too broad occlusocervically

- Adjust the contact area so that casting seats passively. Fine carborundum particles, impregnated rubber disks or wheels can be used for adjusting the proximal contact and contours.
- If there is deficiency in the contact, it should be prepared by soldering the “solder” at a proper place. It can be done by cleaning the contact area using a mild acid. Cut a small piece about 2.0 to 3.0 mm of solder out of strip of solder. Apply borax type flux on the contact area of the casting and on both the surfaces of the piece of solder. Place the solder at proper place on the contact area requiring build-up and direct the pinpoint flame of Bunsen burner to the solder with the help of blowpipe so that the solder melts and flows.

### Cementation of the Casting

- Clean the casting thoroughly before cementation.
- Isolate the prepared tooth, clean it and apply a thin layer of varnish in the preparation.
- Apply warm air to the gingival sulcus of the prepared tooth to dry it.
- Apply a thin layer of cement on the surfaces of the casting which will be in contact with the tooth surface and on the tooth preparation surface.
- Seat the casting with the help of hand pressure using a suitable instrument.
- Ask the patient to bite on a small cotton pellet which is placed on the occlusal surface of the casting.
- Clean the area with dry cotton for removing the remnants of set cement.
- Recheck the occlusion for harmony of centric occlusion.
- Finally, check the gingival sulcus for any remnants of cement to avoid irritation to the supporting tissues.

### To prevent postcementation pain:

- Do not desiccate the tooth.
- Use the proper powder-to-liquid ratio.
- Do not remove the smear layer.
- Use a base material on deep areas of the preparation.
- Apply a resin dentin-desensitizer.
- Avoid overfilling the casting with cement.
- Seat the casting gently.
- Protect the cement from moisture contamination.
- Clean up excess cement only after it has fully set; this prevents the cement from being pulled out from underneath margins.

### CASTING DEFECTS

The various steps in making of casting should be followed systematically, otherwise chances of casting defects are increased.

Casting defects are of many types and may be classified as:

#### Surface Roughness and Irregularities

Surface roughness is generalized roughness of the surface of the casting while surface irregularities are isolated imperfections such as nodules, ridges, fins and spines.

#### Causes

- Inadequate water/powder ratio.
- Too rapid heating of investment.
- Prolonged heating of investment.
- Underheating causes incomplete elimination of wax.
- Air bubbles on the pattern during investment.
- Direction of sprue former.
- Placement of several patterns in a ring together.
- High temperature of molten alloy.
- High casting pressure.
- Presence of foreign bodies.

#### Preventions

- Powder and water ratio should be adequate.
- Heating should be done gradually as too rapid heating would cause flaking of the investment material.
- Gypsum bonded investment should not be heated above 700°C as it would cause disintegration of the investment material.
- Ring should be heated for adequate period of time for complete elimination of wax.
- Air bubbles can be avoided by vibrating mixture before and after mixing. Vacuum investing technique should be used to avoid air bubbles.

- The direction of sprue former should be adjusted to 45°.
- Several patterns should not be placed closely together in a single ring as expansion of wax can cause breakdown of investment material.
- High temperature of molten alloy causes surface roughness.
- Casting pressure should be according to manufacture's recommendation given for various types of casting machines.
- Foreign bodies should be avoided during investment of material.

### Distortion

Distortion of casting usually occurs due to distortion of inlay wax pattern. The coefficient of thermal expansion of inlay wax is high. Distortion of wax pattern increases, if it is improperly handled. Time lag between making of pattern and investing is also crucial during casting.

#### Causes

- Distortion of wax pattern.
- Mishandling of pattern.
- Due to unequal movement of walls of wax pattern while the investment is setting.

#### Preventions

- Proper manipulation of wax pattern.
- Wax pattern should be immediately invested after fabrication.

### Incomplete Casting and Rounded Margins (Fig. 12.43)

#### Causes

- Inadequate heating of the alloy.
- Inadequate casting pressure.
- Improper length and diameter of sprue.
- Improper burnout of wax pattern.
- Insufficient molten alloy.

#### Preventions

- Alloy should be heated above fusion temperature, i.e. 570°C.
- Casting pressure should be adequate to force the molten alloy.
- Proper length and diameter of sprue former.
- Proper burnout of wax pattern should be done so that no carbon residues left in the mold.
- Adequate amount of molten alloy should be available for casting.

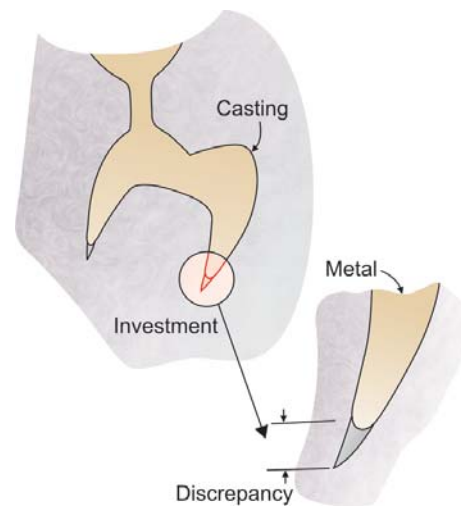


Fig. 12.43: Incomplete casting

### Discoloration

The casting usually appears dark after removing from the investment due to presence of oxides. This can be usually removed by process known as "Pickling".

#### Causes

- **Prolonged heating:** Heating the investment above 700°C usually causes breakdown of investment as well as formation of sulfur compounds, which causes blackening of the cast.
- Sulfur content of torch flame also affects the casting.
- Underheating of the investment also leaves the wax residues in the casting, affects the color of the casting.
- Contamination with copper during the process of pickling causes discoloration.

#### Preventions

- Avoid prolonged heating of the investment.
- Change the source of flame.
- Proper heating should be done.
- Tips of tongues must be covered with rubber to avoid contamination with copper during pickling.

### Porosity

Porosity is considered as a major defect in the casting which can occur on the internal as well as on the external surface of the casting. It usually weakens the casting.

Various types of porosities can be:

- Solidification shrinkage porosity
  - a. Localized shrinkage porosity
  - b. Microporosity

- Gaseous defects
  - a. Gas inclusion porosity
  - b. Pinhole porosity
- Backpressure porosity
- Subsurface porosity.

### Solidification Shrinkage Defects

**Localized shrinkage porosity (Figs 12.44A and B):** This type of porosity occurs due to shrinkage of molten alloy when alloy solidifies from molten state. This can be avoided by providing adequate molten alloy to compensate casting shrinkage.

#### Causes

- If direction of sprue former is at  $90^\circ$ , then it will cause “hot spot” in the casting, i.e. alloy will remain in molten state at that spot whilst solidifies everywhere else.
- Diameter of sprue is too narrow.
- Length of sprue former is long, i.e. molten alloy prematurely solidifies in the sprue before reaching to mold.
- Absence of reservoir.

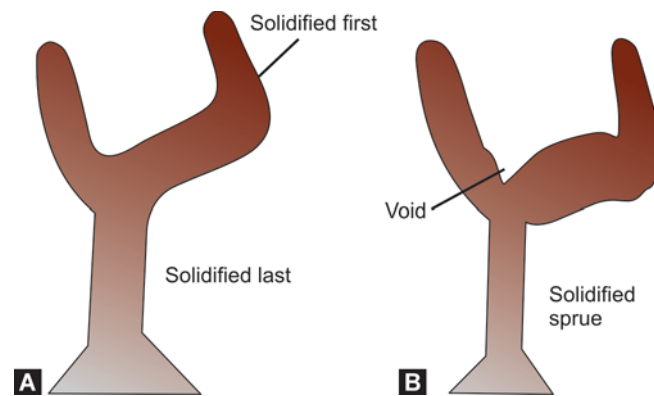
#### Preventions

- Direction of sprue former should be at  $45^\circ$ .
- Avoid using excessively long and narrow sprue former.
- Use reservoir.

**Microporosity:** It is usually seen in fine grain molten metal alloy castings. This usually happens due to solidification shrinkage of molten alloy.

#### Causes

- Too low casting temperature.
- Rapid solidification of molten alloy.



**Figs 12.44A and B:** Localized shrinkage porosity; (A) Proper sequence of hardening, (B) Improper sequence of hardening resulting in suckback porosity

#### Preventions

- Increase the casting temperature.
- Increase the melting temperature of alloy.

#### Gaseous Defects

Two types of defects are seen:

1. **Gas inclusion porosity:** Gas inclusion porosity is spherical voids larger in size than pinhole porosity.
2. **Pinhole porosity:** Spherical voids, smaller in size than gas inclusion porosity.

#### Causes

These are usually caused by entrapment of gas in alloy various causes are:

- Not using the reducing zone of flame.
- Poor adjustment of torch flame.

#### Preventions

- Use reducing zone of the flame.
- Position of torch flame should be correctly adjusted.

#### Backpressure Porosity

It usually occurs on the inner surface of the casting due to entrapment of gases.

#### Causes

- Use of dense investment material.
- Low casting temperature.
- Low casting pressure.
- Improper wax burnout.

#### Preventions

Use of porous investment material:

- Adequate casting temperature.
- Adequate casting pressure.
- Proper wax burnout.

#### Subsurface Porosity

**Causes:** Simultaneous nucleation of solid grains and gas bubbles when the metal freezes at mold walls.

**Prevention:** Can be prevented by controlling the flow at which molten alloy enters the mold space.

## PIN RETAINED CAST RESTORATIONS

Pins are generally used for providing additional retention. Cast pin channels are wider and have slightly divergent walls

in comparison to the pin holes prepared for pin retained amalgam restorations. The cast pin channels are prepared with the help of tapering fissure bur having a diameter of 1 mm with the depth of about 2 to 3 mm.

### Indications for Pin Retained Cast Restorations

Pin retained cast restorations are indicated in following cases:

- When occlusogingival height is very short.
- In cases of excessively tapered tooth preparation.
- Cuspal fractures where large occlusal inlays and onlays are to be prepared.
- When the proximal box is very long. The pin channel is prepared at the other end of occlusal lock.
- In full crown preparation when one wall is very short and another wall is very long. In these cases, pin channel is prepared towards the shorter wall.
- For shallow and wide preparations, when it is not possible to place surface extensions for retention.
- In very thin and fragile teeth where extensive tooth preparation can be detrimental.
- In absence of gingival floor, resistance and retention can be achieved by use of pins.

### VIVA QUESTIONS

- Q. What are different forms in which cast metal restoration used?
- Q. Define an inlay.
- Q. What is an onlay?
- Q. What is class II inlay?
- Q. What is a class II onlay?
- Q. Where are inlay and onlay used?
- Q. What are contraindications of cast metal restorations?
- Q. What are advantages of cast metal restorations?
- Q. What are disadvantages of cast metal restorations?
- Q. What are different steps for preparation of an inlay?
- Q. How many paths should an inlay have for better retention?
- Q. What do you mean by inlay taper?
- Q. Define circumferential tie.
- Q. Define bevel.
- Q. What are different types of bevel?
- Q. What are advantages of bevel?
- Q. Define primary flare.
- Q. What are functions of primary flare?
- Q. Where is primary flare indicated?
- Q. Where is secondary flare indicated?
- Q. What are advantages of secondary flare?
- Q. How does on inlay achieve retention and resistance form?
- Q. What should be the angle of gingival bevel for inlay?
- Q. What are commonly used impression materials for taking inlay impression?
- Q. Why do we give temporary restoration?
- Q. What is working cast?
- Q. Define "Die".
- Q. Which materials are used for making dies?
- Q. What is direct wax pattern method of fabrication?
- Q. What is indirect method for wax pattern fabrication?
- Q. Define sprue former.
- Q. What are functions of sprue former?
- Q. What should be the diameter of sprue former?
- Q. Where should be the sprue former attached?
- Q. What should be the length of sprue former?
- Q. Why do we add reservoir to the sprue former?
- Q. What is casting procedure?
- Q. What are different types of casting machines used for casting?
- Q. What is quenching?
- Q. What are advantages of quenching?
- Q. What is pickling?
- Q. How is pickling carried out?
- Q. How is casting cemented?

- Q. What are causes of surface roughness of casting?
- Q. How can we present surface roughness of casting?
- Q. What are the causes of distortion of wax pattern? How can it be prevented?
- Q. What are the causes of discoloration of casting? How can we prevent discoloration of casting?
- Q. What is localized shrinkage porosity?
- Q. What is "hot spot"?
- Q. What are causes of microporosity?
- Q. What is gas inclusion porosity?
- Q. What is pinhole porosity? How can it be prevented?
- Q. What is etiology of back pressure porosity?
- Q. What is subsurface porosity? How can it be prevented?
- Q. Which materials do we use for cast metal restoration?
- Ans. Noble metal alloys, base metal alloys, castable ceramics.
- Q. What is lost wax technique?
- Ans. It is the procedure in which restoration is made in wax and mould is created around it. After burning, wax is eliminated, and a space is created within mould. Into this space the final restorative material is packed.
- Q. Which wax is used for making max patterns?
- Ans. Inlay type I wax is used for taking direct wax pattern. Type II wax is used for taking indirect wax pattern.
- Q. What are advantages of direct pattern technique?
- Q. What are disadvantages of direct technique?
- Q. What are advantages and disadvantages of indirect technique?



# Pulp Protection

## Chapter 13

### INTRODUCTION

#### PULPAL IRRITANTS

#### EFFECT OF DENTAL CARIES ON PULP

#### EFFECT OF TOOTH PREPARATION ON PULP

- Pressure
- Heat Production
- Vibrations
- Remaining Dentin Thickness
- Speed of Rotation
- Nature of Cutting Instrument

#### EFFECT OF CHEMICAL IRRITANTS ON PULP

- Factors Influencing the Effect of Restorative Materials on Pulp

### PULP PROTECTION PROCEDURES

- Pulp Protection in Shallow and Moderate Carious Lesions
- Pulp Protection in Deep Carious Lesions

### MATERIALS USED FOR PULP PROTECTION

- Varnish
- Adhesive Sealer
- Liners
- Bases

### METHODS OF PULP PROTECTION UNDER DIFFERENT RESTORATIONS

- Amalgam
- Restorative Resins
- Glass Ionomer Cements
- Cast Gold Restorations

### INTRODUCTION

By definition, pulp is a soft tissue of mesenchymal origin residing within the pulp chamber and root canals of teeth.

Some important features of pulp are as follows (Fig. 13.1):

- Pulp is located deep within the tooth, so defies visualization.
- It gives radiographic appearance as radiolucent line.
- Pulp is a connective tissue with several factors making it unique and altering its ability to respond to irritation.
- Normal pulp is a coherent soft tissue, dependent on its normal hard dentin shell for protection and hence, once exposed, extremely sensitive to contact and temperature but this pain does not last for more than 1-2 seconds after the stimulus removed.

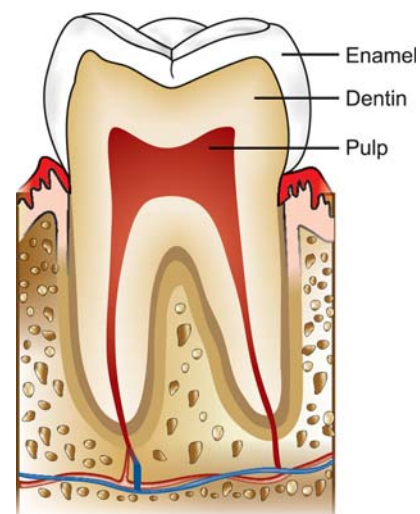


Fig. 13.1: Diagrammatic representation of dental pulp

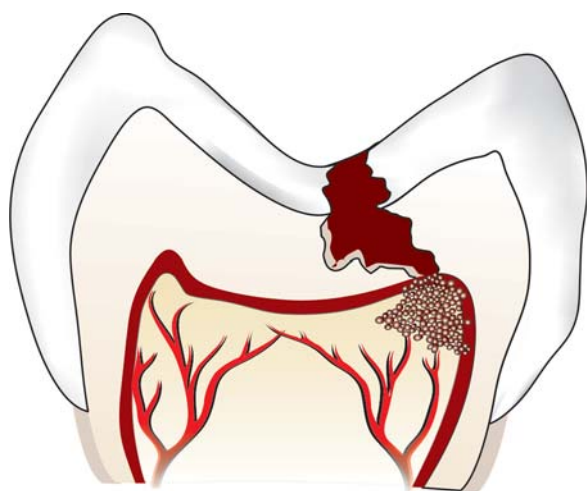

Fig. 13.2: Bacteria from caries resulting in pulpal irritation

- Since pulp is totally surrounded by a hard tissue, dentin which limits the area for expansion and restricts the pulp's ability to tolerate edema.
- The pulp has almost a total lack of collateral circulation, which severely limits its ability to cope with bacteria, necrotic tissue and inflammation.
- The pulp possess unique cells the odontoblasts, as well as cells that can differentiate into hard-tissue secreting cells that form more dentin and/or irritation dentin in an attempt to protect itself from injury.

### PULPAL IRRITANTS

Various pulpal irritants can be :

- **Bacterial irritants:** Most common cause for pulpal irritation are bacteria or their products which may enter pulp through a break in dentin either from:
  - Caries (Fig. 13.2)
  - Accidental exposure
  - Fracture
  - Percolation around a restoration
  - Extension of infection from gingival sulcus
  - Periodontal pocket and abscess (Fig. 13.3)
  - Anachoresis (Process by which microorganisms get carried by the bloodstream from another source localize on inflamed tissue).
- **Traumatic**
  - Acute trauma like fracture, luxation or avulsion of tooth
  - Chronic trauma including parafunctional habits like bruxism.
- **Iatrogenic:** Various iatrogenic causes of pulpal damage can be:

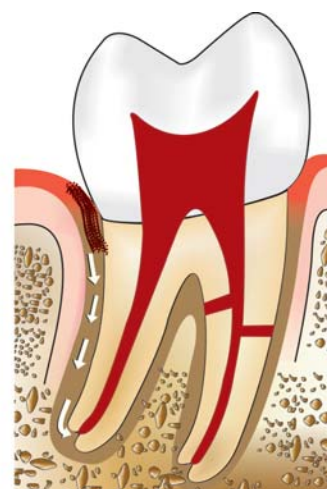

Fig. 13.3: Involvement of pulp via periodontal pocket

- Thermal changes generated by cutting procedures, during restorative procedures, bleaching of enamel, microleakage occurring along the restorations, electrosurgical procedures, laser beam, etc. can cause severe damage to the pulp, if not controlled.
- Orthodontic movement
- Periodontal curettage
- Periapical curettage
- Use of chemicals like temporary and permanent fillings, liners and bases and use of desiccants such as alcohol.
- **Idiopathic**
  - Aging
  - Resorption—internal or external.

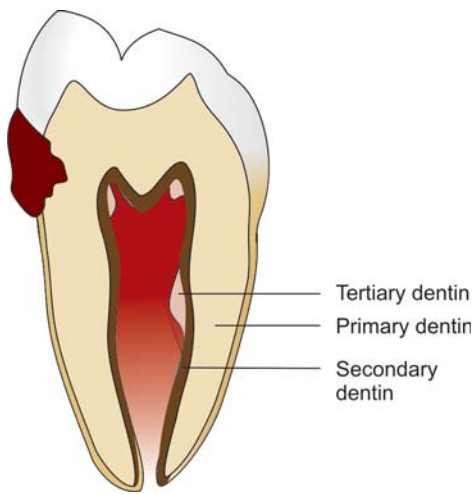
### EFFECT OF DENTAL CARIES ON PULP

Dental caries is the most common route for causing irritation to the pulp. Dental caries is localized, progressive, decay of the teeth characterized by demineralization of the tooth surface by organic acids, produced by microorganisms. From the carious lesion, acids and other toxic substances penetrate through the dentinal tubules to reach the pulp. The following defense reactions take place in a carious tooth to protect the pulp:

1. Formation of reparative dentin.
2. Dentinal sclerosis, i.e. reduction in permeability of dentin by narrowing of dentinal tubules.
3. Inflammatory and immunological reactions.

The rate of reparative dentin formation is related to rate of carious attack. More reparative dentin is formed in response to slow chronic caries than acute caries. For dentin sclerosis to take place, vital odontoblasts must be present





**Fig. 13.4:** Formation of irritation dentin in response to caries

within the tubules. In dentin sclerosis, the dentinal tubules are partially or fully filled with mineral deposits, thus reduce the permeability of dentin. Therefore, dentinal sclerosis act as a barrier for the ingress of bacteria and their product (Fig. 13.4).

## EFFECT OF TOOTH PREPARATION ON PULP

### Factors affecting response of pulp to tooth preparation

1. Pressure
2. Heat production
3. Vibrations
4. Remaining dentin thickness
5. Speed of rotation
6. Nature of cutting instruments.

### Pressure

The pressure of instrumentation on exposed dentin characteristically causes the aspiration of the nuclei of the odontoblasts or the entire odontoblasts themselves or nerve endings from pulp tissues into the dentinal tubules. This will obviously stimulate odontoblasts, disturb their metabolism and may lead to their complete degeneration and disintegration. This can occur by excessive pressure of hand or rotary instruments, especially in decreased effective depths.

### Heat Production

Heat production is the second most damaging factor. If the pulp temperature is elevated by 11°F, destructive reaction will occur even in a normal, vital periodontal organ. That “heat” is a function of;

1. **Revolutions per minute (RPM)**, i.e. more the RPM more is the heat production. In deep penetrations of dentin without using coolants, e.g. pin holes, the cutting speed must not exceed 3,000 rpm.
2. **Pressure:** It is directly proportional to heat generation. Whenever, the RPM’s are increased, pressure must be correspondingly reduced.
3. **Surface area of contact:** It is related to the size and shape of the revolving tool. The more the contact between the tooth structure and revolving tool, the more is the heat generation.
4. **Desiccation:** If occurring in vital dentin, can cause aspiration of the odontoblasts into the tubules. The subsequent disturbances in their metabolism may lead to the complete degeneration of odontoblasts. Coolant sprays should be used even in nonvital or devitalized tooth structures, since the heat will burn the tooth structures.

### Vibrations

Vibrations are measured by their amplitude or their capacity and frequency (the number/unit time). Vibrations are an indication of eccentricity in rotary instruments. The higher the amplitude, the more destructive may be the response of the pulp.

In addition to affecting the pulp tissues, vibration can create microcracks in enamel and dentin.

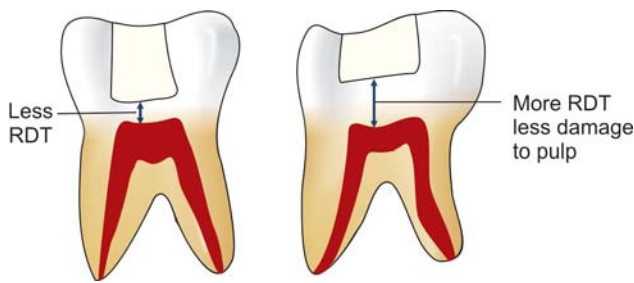
### Remaining Dentin Thickness

Remaining dentin thickness (RDT) between the floor of the tooth preparation and the pulp chamber is one of the most important factor in determining the pulpal response. This measurement differs from the depth of tooth preparation since the pulpal floor in deeper preparation on larger teeth may be far from the pulp than that in shallow preparations on smaller teeth.

#### Remaining dentin thickness (RDT)

- In human teeth, dentin is approximately 3 mm thick
- Dentin permeability increases with decreasing RDT
- RDT of 2 mm or more effectively precludes restorative damage to the pulp
- At RDT of 0.75 mm, effects of bacterial invasion are seen
- When RDT is 0.25 mm, odontoblastic cell death is seen.

The amount of remaining dentin underneath the tooth preparation plays the most important role in the incidence of a pulp response. Generally, 2 mm of dentin thickness



**Fig. 13.5:** As dentin thickness decreases, the pulp response increases

between the floor of the tooth preparation and the pulp will provide an adequate insulating barrier against irritants (**Fig. 13.5**). As the dentin thickness decreases, the pulp response increases. It is seen that response of cutting occurs only in areas beneath freshly cut dentinal tubules not lined with reparative or irregular dentin. In presence of reparative dentin only minimal response will occur.

### Speed of Rotation

Ultra high-speed should be used for removal of enamel and superficial dentin. A speed of 3,000 to 30,000 rpm without coolant can cause pulpal damage. It should be kept in mind that without the use of coolant there is no safe speed. High speed without coolant can produce burning of dentin, which in turn affect the integrity of the pulp.

### Nature of Cutting Instrument

Use of worn off and dull instruments should be avoided. Damaged cutting edges cause vibration and reduced cutting efficiency.

Use of dull instruments encourages the dentist to use excessive operating pressure, which results in increased temperature. This can result in thermal injury to pulp.

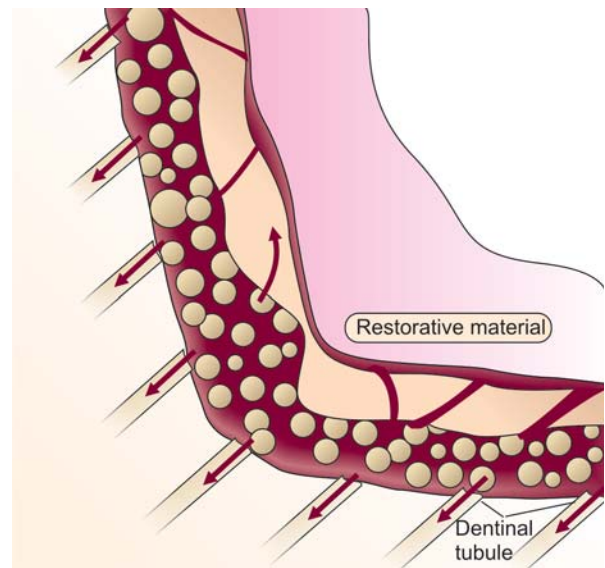
### EFFECT OF CHEMICAL IRRITANTS ON PULP

The pulp is subjected frequently to chemical irritation from materials generally used in dentistry. Various filling materials produce some irritation ranging from mild-to-severe, as do various medicaments used for desensitization or dehydration of the dentin.

Properties of a material that could cause pulpal injury are its cytotoxic nature, acidity, heat evolved during setting and marginal leakage (**Fig. 13.6**).

### Factors Influencing the Effect of Restorative Materials on Pulp

- Acidity
- Absorption of water from dentin during setting



**Fig. 13.6:** Pathways of marginal leakage

- Heat generated during setting
- Poor marginal adaptation leads to bacterial penetration
- Cytotoxicity of material.

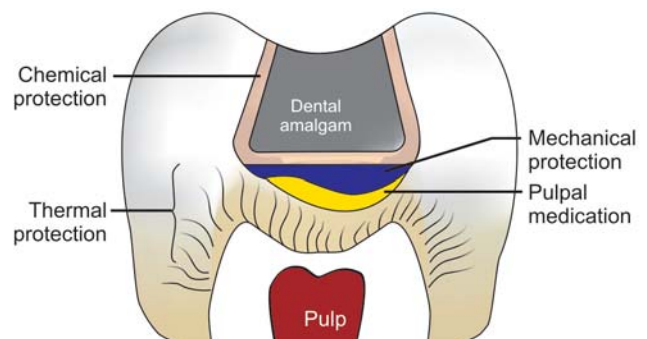
### PULP PROTECTION PROCEDURES

Pulp needs protection against various irritants as following (**Fig. 13.7**):

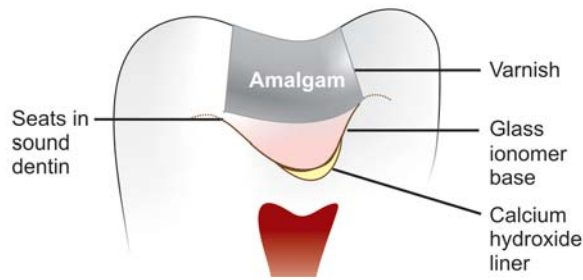
- Thermal protection against temperature changes
- Electrical protection against galvanic currents
- Mechanical protection during various restorative procedures
- Chemical protection from toxic components
- Protection from microleakage interface between tooth and the restoration.

### Pulp Protection in Shallow and Moderate Carious Lesions

In a moderate carious lesion, caries penetrates the enamel and may involve one-half of the dentin, but not to the extent



**Fig. 13.7:** Need of pulp protection from various irritants



**Fig. 13.8:** Pulp protection in moderate carious lesion using liner, base and varnish

of endangering the pulp. In these cases, to protect the pulp, after tooth preparation, liner is applied to cover the axial and/or pulpal wall. Then, base material (zinc phosphate, zinc oxide eugenol, glass ionomer or polycarboxylate) is placed over the liner. After the base material hardens, permanent restoration is done (**Fig. 13.8**).

### Pulp Protection in Deep Carious Lesions

In deep carious lesion, caries can reach very near or up to the pulp, so treatment of deep carious lesion requires precautions because of postoperative pulpal response. Depending upon the condition, following methods for pulpal protection are employed.

#### *In Moderately Deep Carious Lesions*

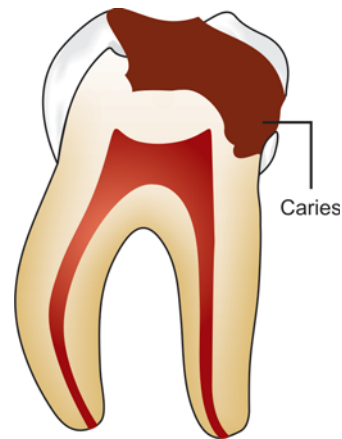
If hard dentin is present between carious lesion and the pulp and there is no threat to pulpal health after caries removal, give protective cement base and complete the permanent restoration as though it was a moderate lesion.

#### *Indirect Pulp Capping*

Indirect pulp capping is a procedure performed in a tooth with deep carious lesion adjacent to the pulp (**Fig. 13.9**). In this procedure, all the carious tissue is removed except the soft undischored carious dentin which is adjacent to the pulp. Caries near the pulp is left in place to avoid pulp exposure and preparation is covered with a biocompatible material.

#### *Indications*

- Deep carious lesion near the pulp tissue but not involving it.
- No mobility of tooth.
- No history of spontaneous toothache.
- No tenderness to percussion.
- No radiographic evidence of pulp pathology.
- No root resorption or radicular disease should be present radiographically.



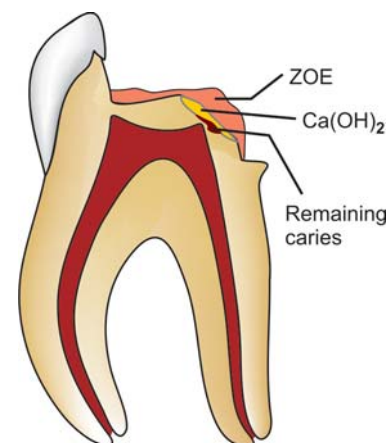
**Fig. 13.9:** Tooth showing deep carious lesion adjacent to pulp

#### *Contraindications*

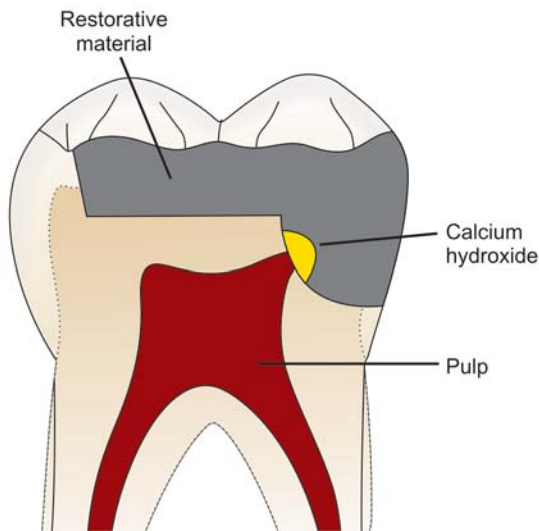
- Presence of pulp exposure.
- Radiographic evidence of pulp pathology.
- History of spontaneous toothache.
- Tooth sensitive to percussion.
- Mobility present.
- Root resorption or radicular disease is present radiographically.

#### *Clinical techniques*

- Band the tooth if tooth is grossly decayed.
- Anesthetize the tooth.
- Apply rubber dam to isolate the tooth.
- Remove soft caries either with spoon excavator or round bur.
- A thin layer of dentin and some amount of caries is left to avoid exposure.
- Place calcium hydroxide paste on the exposed dentin.
- Cover the calcium hydroxide with zinc oxide eugenol base (**Fig. 13.10**).



**Fig. 13.10:** Placement of calcium hydroxide and zinc oxide eugenol dressing after excavation of soft caries



**Fig. 13.11:** Direct pulp capping

- If restoration is to be given for a longer time, then amalgam restoration should be given.
- Tooth should be evaluated after 6-8 weeks.
- After 2 to 3 months, remove the cement and evaluate the tooth preparation. If due to remineralization and/or formation of secondary dentin, the soft dentin has become hard, then remove any residual soft debris and then finally give protective cement base and place the permanent restorative material.

The success of indirect pulp capping depends on the age of the patient, size of the exposure, restorative procedure and evidence of pulp vitality. In young patients, the potential for success is more due to large volume of pulp tissue and abundant vascularity.

### Direct Pulp Capping

Direct pulp capping procedure involves the placement of biocompatible material over the site of pulp exposure to maintain vitality and promote healing.

When a small mechanical exposure of pulp occurs during tooth preparation or following a trauma, an appropriate protective base should be placed in contact with the exposed pulp tissue so as to maintain the vitality of the remaining pulp tissue (**Fig. 13.11**).

### Indications

- Small mechanical exposure of pulp during
  - Tooth preparation.
  - Traumatic injury.
- No or minimal bleeding at the exposure site.

### Contraindications

- Wide pulp exposure
- Radiographic evidence of pulp pathology
- History of spontaneous pain
- Presence of bleeding at exposure site.

### Clinical procedures

- Administer local anesthesia.
- Isolate the tooth with rubber dam.
- When vital and healthy pulp is exposed, check the fresh bleeding at exposure site.
- Clean the area with distilled water or saline solution and then dry it with a cotton pellet.
- Apply calcium hydroxide (preferably Dycal) over the exposed area.
- Give interim restoration such as zinc oxide eugenol for 6-8 weeks.
- After 2 to 3 months, remove the cement very gently to inspect the exposure site. If secondary dentin formation takes place over the exposed site, restore the tooth permanently with protective cement base and restorative material. If favorable prognosis is not there, pulpotomy or pulpectomy is done.

### The factors on which the success of direct pulp capping depends are as follows:

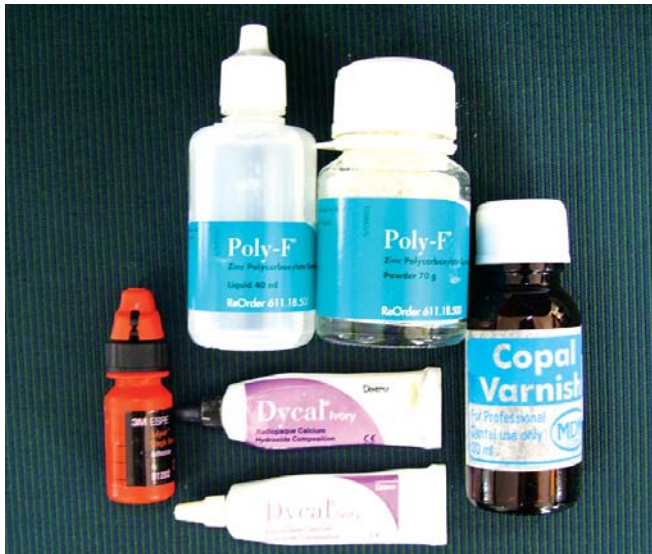1. *Age of the patient:* Due to vascularity of the pulp, young patients have greater potential for success than older ones.
2. *Type of exposure:* Mechanically done pulpal exposure has better prognosis than exposure caused by caries, due to less pulpal inflammation and deleterious effect of bacterial toxins on the pulp.
3. *Size of the exposure:* In large exposures, it is difficult to control the hemorrhage and tissue seepage. Small pinpoint exposures are easy to manage and have a greater potential for success.
4. *History of pain:* If previously pain has not occurred in the tooth, the potential for success is more.

### MATERIALS USED FOR PULP PROTECTION (FIG. 13.12)

Various materials are used to:

- Insulate the pulp
- Protect the pulp in case of deep carious lesion
- Act as barriers to microleakage
- Prevent bacteria and toxins from affecting the pulp.

The term varnish, sealer, liner and base is applied for these materials. Terminology of pulp protective materials according to thickness of material:



**Fig. 13.12:** Different materials used for pulp protection



**Fig. 13.13:** Dentin bonding agent to seal dentinal tubules

1. **Solution liner (include varnish and adhesive sealer):** Thin film of 2-5  $\mu\text{m}$  thickness.
  2. **Suspension liner:** Relatively thin film of 20-30  $\mu\text{m}$  thickness.
  3. **Cement liner:** Medium thickness of 100-500  $\mu\text{m}$  thickness.
  4. **Cement base:** Thick film of 500-1000  $\mu\text{m}$  thickness.
- McCoy (1995) gave following definitions for these terms:

1. **Sealer:** These materials provide a protecting covering the walls of tooth preparation and act as barrier to leakage occurring at restoration tooth interface.

These can be :

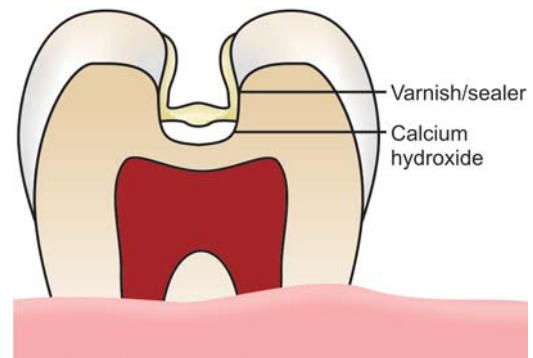
- **Varnish:** A varnish is an organic gum or rosin suspended in organic solutions like ether or chloroform.
  - **Adhesive sealer:** These help in sealing and adhesion at the tooth restoration interface. For example, dentin bonding agent and resin luting cements (**Fig. 13.13**).
2. **Linings:** They are applied in thin layer of less than 0.5 mm so as to attain a physical barrier to pulp and to provide therapeutic effect.
  3. **Bases:** They are applied in an attempt to replace the lost dentin and to provide thermal, physical and therapeutic advantages to the pulp.

### Varnish

A varnish is an organic copal or resin gum suspended in solutions of ether or chloroform (**Fig. 13.14**). When applied on the tooth surface the organic solvent evaporates leaving behind a protective film (**Fig. 13.15**).



**Fig. 13.14:** Varnish



**Fig. 13.15:** Varnish is applied on prepared tooth surface

Varnish liner is used for pulp protection and reduction of leakage. On drying, varnish acts as an inert plug between the tooth and restoration.

In case of amalgam restoration, varnish improves the sealing ability of the amalgam, reduces postoperative sensitivity and prevents discoloration of tooth by checking ion migration into the dentin. If base is to be given or casting is to be cemented by zinc phosphate cement, varnish application is advantageous as it will block the seepage due to the available acid. Use of varnish is contraindicated under glass ionomers as they interfere the bonding of tooth to these cements. With restorative resins varnish is not used because the varnish liners dissolve in the monomer of the resin and also they interfere in their polymerization process.

#### Indications for use of varnish

- To seal the dentinal tubules
- To act as barrier to protect the tooth from chemical irritants from cements
- To reduce microleakage around restorations.

#### Contraindication

- Contraindicated under composite resin and glass ionomer restorations.

### Adhesive Sealer

#### Indications for use of sealer

- To seal dentinal tubules
- To treat dentin hypersensitivity.

An adhesive sealer is commonly used under indirect restorations. For application, cotton tip applicator is used to apply sealer on all areas of exposed dentin.

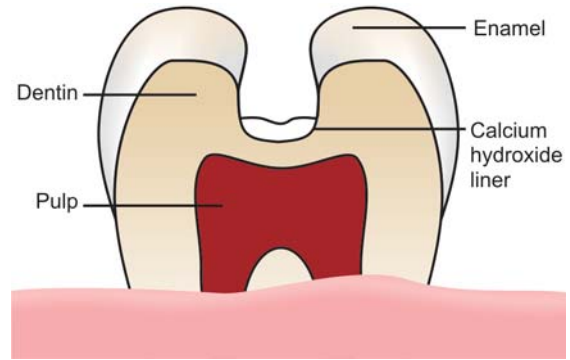
### Liners (Fig. 13.16)

Liners are typically fluid materials that, because of their rheology, can adapt more readily to all aspects of a tooth preparation. They can be used to create a uniform, even surface that aids in adaptation of more viscous filling materials such as amalgams or composites.

Liners usually do not have sufficient thickness, hardness and strength to be used alone in the deep preparation.

#### Indications of Use of Liners

- To protect pulp from chemical irritants by sealing ability
- To stimulate formation of reparative dentin.



**Fig. 13.16:** Calcium hydroxide liner is applied in an attempt to stimulate reparative dentin formation

### Types of Liners

Following three materials are most commonly used as liners:

- Zinc oxide eugenol liners
- Calcium hydroxide
- Flowable composites
- Glass ionomers.

### Zinc Oxide Eugenol Liners

Many dental materials containing eugenol and zinc oxide are used as liners. Eugenol is used to alleviate pain from mild to moderate inflammation of pulp. Though in low concentration, it acts as obtundant but in high concentration it acts as chemical irritant. When used as liner, there is release of eugenol for first few days of setting, therefore, this liner is not preferred especially in moderately deep tooth preparations.

Zinc oxide eugenol liners should not be used under composite restorations since they inhibit polymerization of bonding agent and composite.

**Calcium hydroxide:** Calcium hydroxide has been used as liner in deep preparations cavities because of its following features:

1. It causes dentin mineralization by activating the enzyme ATPase.
2. It stimulates reparative dentin formation.
3. It forms a mechanical barrier, when applied to dentin.
4. Because of high pH, it neutralizes acidity of silicate and zinc phosphate cements.
5. Calcium hydroxide dissociates into  $\text{Ca}^{2+}$  and  $\text{OH}^-$  ions, the  $\text{OH}^-$  ions neutralize the ( $\text{H}^+$ ) hydrogen ions from acids of cement.
6. Biocompatible in nature
7. Bactericidal in nature.

**Limitations:** It has low strength, high solubility thus when it is exposed to the oral environment (e.g. due to leakage) it will dissolve. This limits its use over only small areas requiring pulp protection. Sometimes glass ionomer or zinc phosphate base is applied over it to prevent its dissolution.

**Flowable composites:** Flowable composites are the composites with a lower amount of filler. This reduced filler content allows more fluid consistency, less strength and lower modulus than fully filled composites.

They are primarily used under composite restorations and in crown and bridge preparations to block out undercuts prior to impression taking.

*Advantages of using flowable composites as liners:*

- Adaptation to preparation walls because of their flow
- Placement ease since the materials are injected directly into the preparation
- Esthetic
- Consistency.

*Disadvantages of flowable composites:*

- Technique sensitive
- Requires maintenance of contamination free field
- Polymerization shrinkage can result in gap formation at resin-tooth interface.

**Glass ionomer cements (GICs):** Glass ionomer (GI) or resin modified glass ionomer (RMGI) liners have been used as a renewable source of fluoride under restorations which has been shown to reduce the incidence of caries.

*Advantages*

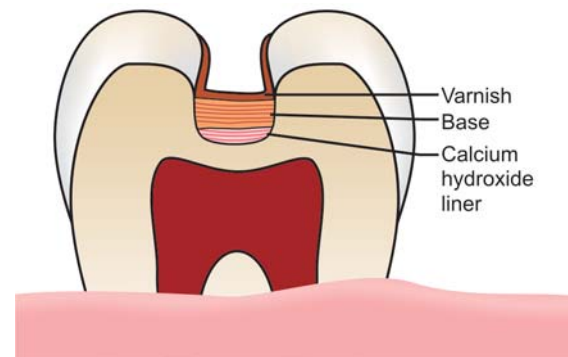
- Bond to tooth structure
- Act as a thermal barrier
- Can bond in a moist environment
- Easy to use.
- Anticariogenic

**Light-cured resin-modified glass ionomers (RMGIs):** They provide good adhesion to both tooth structure and restorative materials along with strength, flexibility (because of low modulus of elasticity).

RMGI materials have a dual-setting reaction—a light-activated, methacrylate crosslinking reaction and a slower, delayed, acid-base reaction that gives RMGIs an additional period of maximum flexibility to absorb stress from the adjacent shrinking composite.

### Bases (Fig. 13.17)

Bases are used as pulp protective materials since they provide thermal insulation, encourage recovery of injured pulp from thermal, mechanical or chemical trauma, galvanic shock and microleakage.



**Fig. 13.17:** Base is applied over liner as pulp protective material in deep preparations

Bases should have sufficient strength so as to withstand forces of mastication and condensation of permanent restorations. Bases can be classified as following:

1. **Protective bases:** They protect the pulp before restoration is placed.
2. **Sedative bases:** They help in soothing the pulp which has been irritated by mechanical, chemical or other means.
3. **Insulating bases:** They protect the tooth from thermal shock.

Commonly used materials as base are zinc oxide eugenol, zinc phosphate cement, glass ionomer cement and calcium hydroxide.

#### Zinc Oxide Eugenol

It provides excellent sealing qualities and is bacteriostatic in nature. Zinc oxide eugenol is used as intermediary base. Zinc oxide eugenol cement has anodyne effect, in other words it is helpful for relieving toothaches in case of deep preparations because of its sedative action. Zinc oxide eugenol cement should not be used with composite resins as it inhibits the polymerization of the resin.

#### Zinc Phosphate Cement

A thick creamy mix of zinc phosphate cement is used as base to reduce the thermal conductivity of metallic restorations and to block the undercuts in the preparation wall in case of cast restorations. Thick mixes should be used to minimize pulp irritation and marginal leakage. The thickness of the cement to provide effective thermal insulation should be at least between 0.50 and 1.0 mm. The cement should not cover on enamel wall or contact the cavosurface margin. If required, shape the cement with slow speed fissure bur or sharp explorer.



Fig. 13.18: Zinc carboxylate cement

### Polycarboxylate Cement (Fig. 13.18)

Zinc polycarboxylate cement contains modified zinc oxide powder and an aqueous solution of polyacrylic acid. It chemically bonds to enamel and dentin and has antibacterial properties. Polycarboxylate cement is well tolerated by the pulp. Varnish should not be used with polycarboxylate cement because it would neutralize the adhesion potential of the cement.

### Glass Ionomer Cement

Glass ionomer cements possess anticariogenic properties because of continuous release of fluoride throughout the life of restoration. Also these cements can bind to both enamel and dentin of the tooth via chemical bonding. They are also well tolerated by the pulp.

## METHODS OF PULP PROTECTION UNDER DIFFERENT RESTORATIONS

### Amalgam

Amalgam has been used in dentistry since ages. It is considered one of the safest filling materials with least irritating properties. It has been shown to produce discomfort due to its high thermal conductivity. So liners or bases are necessary to provide thermal insulation.

#### Effects of Amalgam on Pulp

- Mild-to-moderate inflammation in deep caries
- Harmful effects due to corrosion products
- Inhibition of reparative dentin formation due to damage to odontoblasts

- Copper in high copper alloy is toxic
- High mercury content exerts cytotoxic effects on pulp
- Postoperative thermal sensitivity due to high thermal conductivity.

#### Precautions to be Taken While Using Amalgam as a Restorative Material

- Use of varnish or dentin bonding agent at the margins of restoration if more than 2 mm of remaining dentin thickness is present.
- Use of liner or base under the silver amalgam restoration when remaining dentin thickness is 0.5 to 2 mm.
- Use of calcium hydroxide as sub-base (0.5-1 mm) covered with a base material in preparations with less than 0.5 mm remaining dentin thickness.

### Restorative Resins

Restorative resins have been used in dentistry for past many years. Despite of having several advantages, they are not considered best materials because of their high coefficient of thermal expansion and polymerization shrinkage, which results in marginal leakage, subsequently the recurrent caries and ultimately the pulp damage. Monomer present in composite resins also acts as an irritant to the pulp.

#### Precautions to be Taken While Using Composite Resin as a Restorative Material

Use of liner is advocated under composite restorations in deep preparations. Liners containing calcium hydroxide have shown to provide good protection against bacteria. Zinc oxide eugenol liners should not be used with composite resins since they interfere with polymerization of composites.

### Glass Ionomer Cements

Since it is compatible with pulp so nothing special is required except in very deep preparations (less than 0.5 mm remaining dentin thickness). In these cases, calcium hydroxide liner may be used for pulp protection.

### Cast Gold Restorations

- If remaining dentin thickness is more than 2 mm, nothing is required.
- If remaining dentin thickness is 0.5 to 2 mm, base is given below restoration.
- If remaining dentin thickness is less than 0.5 mm, to protect pulp calcium hydroxide liner is placed over which base is applied.



**VIVA QUESTIONS**

---

- Q. What do you mean by pulp protection?
- Q. What are different pulpal irritants?
- Q. What is significance of remaining dentin thickness?
- Q. What are factors affecting pulp while tooth preparation?
- Q. Define varnish, what are its uses?
- Q. Where should we apply varnish?
- Q. What are advantages of varnish?
- Q. Which materials are used for varnish?
- Q. What are cavity liners?
- Q. What is thickness of cavity liners?
- Q. What are functions of cavity liners?
- Q. Which materials are used as cavity liners?
- Q. What are bases?
- Q. What should be the thickness of base?
- Q. Which materials are used as bases?
- Q. Classify bases.
- Q. What materials are used as liners?
- Q. How will you provide pulp protection for amalgam if RDT is  $< 0.5$  mm.
- Q. What are advantages of GIC as liner?
- Q. Where is use of varnish contraindicated?
- Q. What is direct pulp capping?
- Q. What are indications of direct pulp capping?
- Q. What is indirect pulp capping?
- Q. What are indications of indirect pulp capping?



# Basics of Endodontics

## Chapter 14

### INTRODUCTION

### PROGRESSION OF PULPAL PATHOLOGIES

### ENDODONTIC INSTRUMENTS

- Classification of Endodontic Instruments
- Grossman's Classification
- Manufacturing of Hand Instruments
- Standardization of Instruments given by Ingle and Levine
- Modifications from Ingle's Standardization
- Broaches
- Uses of Broach
- Reamers
- Files
- Commonly Used Files
- K-files
- K-flex Files
- Hedstrom Files (H-files)
- Safety Hedstrom File
- Gates-Glidden Burs
- Peeso Reamers
- Nickle Titanium (NiTi) Endodontic Instruments
- Instruments Used for Obturation of Root Canals

### ACCESS CAVITY PREPARATION

- Pulp Cavity
- Pulp Horns
- Pulp Chamber
- Canal Orifice
- Definition of Access Cavity Preparation
- Guidelines for Access Cavity Preparation

### ACCESS CAVITY OF ANTERIOR TEETH

- Maxillary Central Incisor
- Maxillary Lateral Incisor
- Maxillary Canine
- Mandibular Incisors
- Mandibular Canine

### ACCESS CAVITY PREPARATION FOR PREMOLARS

- Maxillary First Premolar
- Maxillary Second Premolar

- Mandibular First Premolar
- Mandibular Second Premolar

### ACCESS CAVITY PREPARATION FOR MAXILLARY MOLARS

- Maxillary First Molar
- Maxillary Second Molar

### ACCESS CAVITY PREPARATION FOR MANDIBULAR MOLARS

- Mandibular First Molar
- Mandibular Second Molar

### WORKING LENGTH DETERMINATION

- Significance of Working Length
- Different Methods of Working Length Determination
- Radiographic Method of Working Length Determination

### IRRIGATION OF ROOT CANAL SYSTEM

- Functions of Irrigants
- Commonly Used Irrigating Solutions
- Normal Saline
- Sodium Hypochlorite
- Chelating Agents

### BIOMECHANICAL PREPARATION

- Cleaning
- Shaping
- Objectives of Biomechanical Preparation
- Basic Principles of Canal Instrumentation

### TECHNIQUES OF ROOT CANAL PREPARATION

- Step Back Technique
- Crown Down Technique

### OBTURATION OF ROOT CANAL SYSTEM

- Purpose of Obturation
- Material Used for Obturation
- Gutta-percha
- Root Canal Sealers
- Obturation Techniques
- Armamentarium for Obturation
- Lateral Compaction Technique
- Vertical Compaction Technique

### POST OBTURATION RESTORATION

## INTRODUCTION

Endo is a Greek word for “Inside” and Odont is Greek word for “Tooth”. Endodontic treatment treats inside of the tooth.

Endodontics is the branch of clinical dentistry associated with the prevention, diagnosis and treatment of the pathosis of the dental pulp and their sequelae.

*Main aim of the endodontic therapy involves to:*

- i. Maintain vitality of the pulp.
- ii. Preserve and store the tooth with damaged and necrotic pulp.
- iii. Preserve and restore the teeth which have failed to the previous endodontic therapy, to allow the tooth to remain functional in the dental arch.

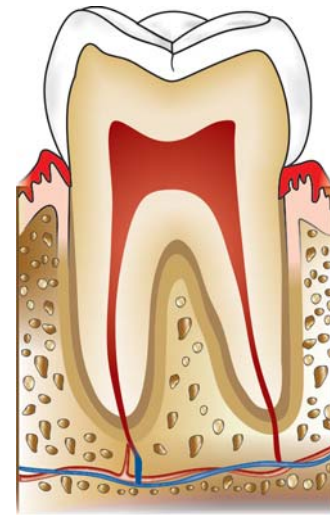### Features of pulp which distinguish it from tissue found elsewhere in the body

- a. Pulp is surrounded by rigid walls and so is unable to expand in response to injury as a part of the inflammatory process (Fig.14.1). Therefore, pulpal tissue is susceptible to a change in pressure affecting the pain threshold.
- b. There is minimal collateral blood supply to pulp tissue which reduces its capacity for repair following injury.
- c. The pulp is composed almost entirely of simple connective tissue, yet at its periphery there is a layer of highly specialized cells, the odontoblasts. Secondary dentin is gradually deposited as a physiological process which reduces the blood supply and therefore, the resistance to infection or trauma.
- d. The innervation of pulp tissue is both simple and complex. Simple in that there are only free nerve endings and consequently the pulp lacks proprioception. Complex because of innervation of the odontoblast processes which produces a high level of sensitivity to thermal and chemical change.

## PROGRESSION OF PULPAL PATHOLOGIES

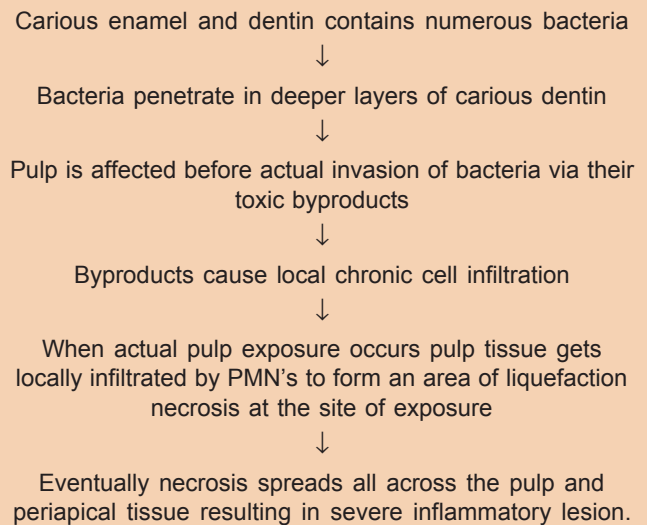
Pulp reacts to irritants as do other connective tissues. Degree of inflammation is proportional to intensity and severity of tissue damage. For example, slight irritation like incipient caries or shallow tooth preparation cause little or no pulpal inflammation, whereas extensive operative procedures may lead to severe pulpal inflammation.

Depending on condition of pulp, severity and duration of irritant, host response, pulp may respond from mild inflammation to pulp necrosis (Fig. 14.2).



**Fig. 14.1:** Normal anatomy of a tooth showing enamel, dentin, cementum and pulp

### Pulpal reaction to microbial irritation (Fig. 14.3)



## ENDODONTIC INSTRUMENTS

Although variety of instruments used in general dentistry, are applicable in endodontics, yet some special instruments are unique to endodontic purpose.

### Classification of Endodontic Instruments

ISO - FDI (Federation Dentaire International) grouped root canal instruments according to their method of use:

Group I : *Hand use only* for example K and H-files, reamers, broaches, etc.

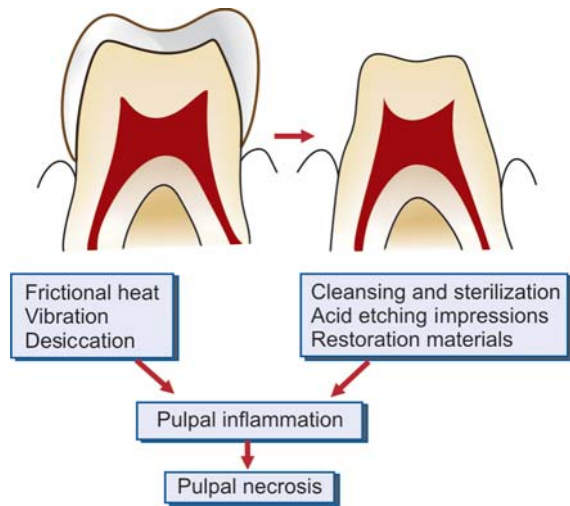


Fig. 14.2: Response of pulp to various irritants

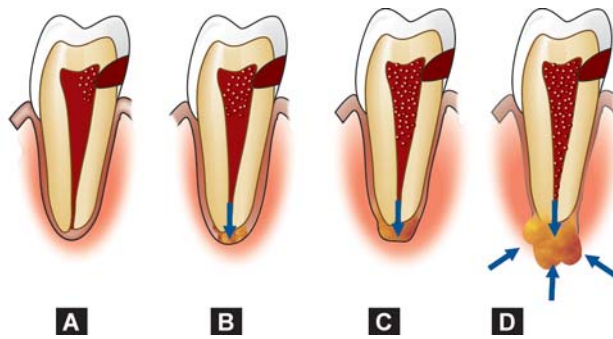


Fig. 14.3: Gradual response of pulp to microbial invasion

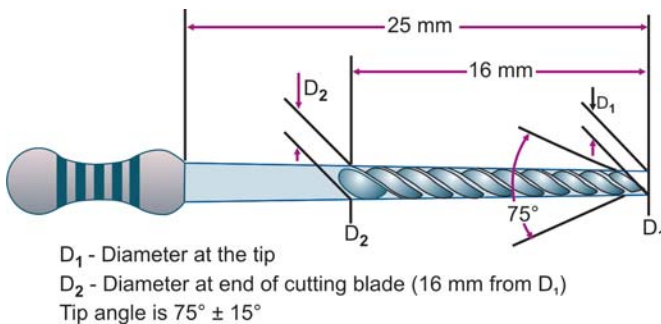


Fig. 14.4: Diagrammatic representation of an endodontic instrument in accordance with ANSI specification No. 57

- Group II : *Latch type Engine driven*: Same design as group I but can be attached to handpiece.
- Group III : *Drills or reamers latch type engine driven* for example Gates-Glidden, Peeso reamers.
- Group IV : *Root Canal points* like gutta-percha, silver point, paper point.

## Grossman's Classification

Function	Instruments
Exploring	Smooth broaches and endodontic explorers. (to locate canal orifices and determine patency of root canal)
Dibriding or extirpating	Barbed broaches (to extirpate the pulp and other foreign materials from the root canal)
Cleaning and shaping	Reamers and files (used to shape the canal space)
Obturing	Pluggers, spreaders and lentulo-spirals (to pack gutta-percha points into the root canal space).

## Manufacturing of Hand Instruments

A hand operated instrument reamer or file begins as a round wire which is modified to form a tapered instrument with cutting edges. Several shapes and forms of such instruments are available. These are manufactured by two techniques:

- By machining the instrument directly on the lathe for example H-file and NiTi instruments are machined.
- By first grinding and then twisting. Here the raw wire is ground into tapered geometric blanks, i.e. square, triangular or rhomboid. These blanks are then twisted counterclockwise to produce cutting edges.

## Standardization of Instruments given by Ingle and Levine

Ingle and Levine using an electronic microcomparator found variation in the diameter and taper for same size of instrument. They suggested few guidelines for instruments for having uniformity in instrument diameter and taper (Fig. 14.4). The guidelines were:

- Instruments are numbered from 10-100. There is increase in 5 units up to size 60 and in 10 units till they are size 100.
- Each number should represent diameter of instrument in 100th of millimeter at the tip.
- Working blade shall begin at tip ( $D_1$ ) and extend 16 mm up the shaft ( $D_2$ ).  $D_2$  should be 0.32 mm greater than  $D_1$ , ensuring that there is constant increase in taper, i.e. 0.02 mm per mm of instrument.
- Instruments handles should be color coded for their easier recognition (Pink, gray, purple, white, yellow, red, blue, green, black.....)
- Instruments are available in following length : 21 mm, 25 mm, 28 mm, 30 mm and 40 mm. 21 mm length is commonly used for molars, 25 mm for interiors, 28 and 30 mm for canines and 40 mm for endodontic implants.

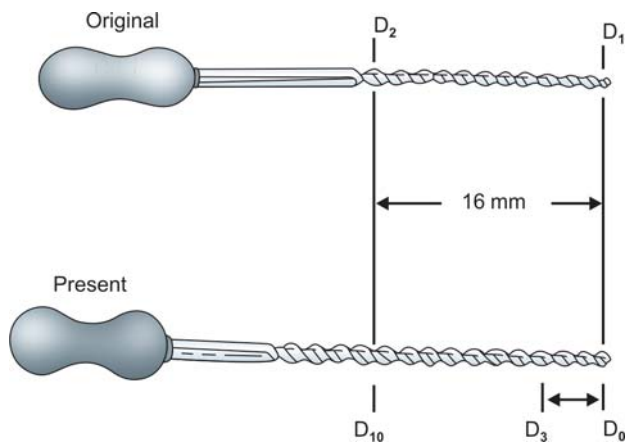


Fig. 14.5: Modification from Ingle's standardization

### Modifications from Ingle's Standardization (Fig. 14.5)

- An additional diameter measurement point at  $D_3$  is 3 mm from the tip of the cutting end of the instrument at  $D_0$  (Earlier it was  $D_1$ ).
- Tip angle of an instrument should be  $75^\circ \pm 15^\circ$ .
- Greater taper instruments (0.04, 0.06, 0.08 —) have also been made available.

Color coding of endodontic instruments (Fig. 14.6)

Color code	Instrument number
Pink	06
Gray	08
Purple	10
White	15
Yellow	20
Red	25
Blue	30
Green	35
Black	40
White	45
Yellow	50
Red	55
Blue	60
Green	70
Black	80

- Instruments available in length 21, 25, 28 and 30 mm are used for root canal therapy, and those of 40 mm size are used in preparing root canals for the endodontic implants.

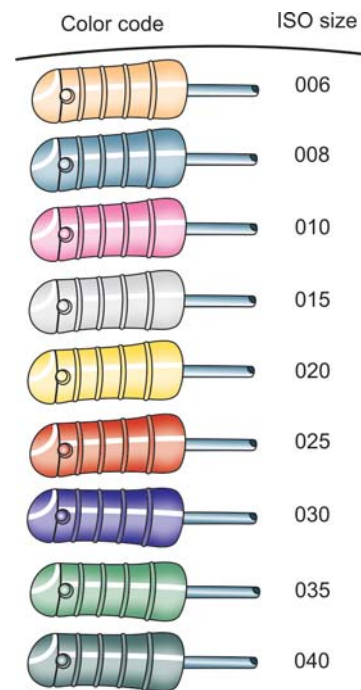


Fig. 14.6: Color coding of endodontic instruments



Fig. 14.7: Barbed broach

### Broaches

Broaches are of two types:

- Smooth broaches:** These are free of barbs. Previously they were used as pathfinder, but at present flexible files are used for this.
- Barbed broach (Fig. 14.7)**
  - Broaches are short handled instruments meant for single use only.
  - They are made from round steel wires. The smooth surface of wire is notched to form barbs bent at an angle from the long axis.
  - Broach does not cut the dentin but can effectively be used to remove cotton or paper points which might have lodged in the canal.

- Broach should not be forced apically into the canal, as its barbs get compressed by the canal wall. While removing this embedded instrument, barbs get embedded into dentin and broach may break on applying pressure.

### Uses of Broach

<i>Difference between files and reamers</i>		
	<i>Files</i>	<i>Reamers</i>
1. Cross-section	Square	Triangular
2. Area of cross-section	More	Less
3. Flutes	more (1 ½ -2/mm)	Less (1/2 -1/mm)
4. Flexibility	Less	More (because of less work hardening)
5. Cutting motion	Rasping penetration (Push and pull)	Rotation and retraction
6. Preparation shape	Usually avoid	Round
7. Transport of debris	Poor because of tighter flutes	Better because of space present in flutes

- Extirpation of pulp tissues (Fig. 14.8).
- Removal of cotton or paper points lodged in the canal.
- Loosen the necrotic debris from canal.

### Reamers (Figs 14.9A and B)

1. Reamers are K-type instruments (manufactured by Kerr company), which are used to ream the canals. They cut by inserting into the canal, twisting clockwise one quarter to half turn and then withdrawing, i.e. penetration, rotation and retraction.
2. Reamers have triangular blank and lesser number of flutes than files (Fig. 14.10). Numbers of flutes in reamer are ½-1/mm, while in files the flutes are 1½-2½/mm.
3. Though reamer has fewer numbers of flutes than file, cutting efficiency is same as that of files because more space between flutes causes better removal of debris (Fig. 14.11).

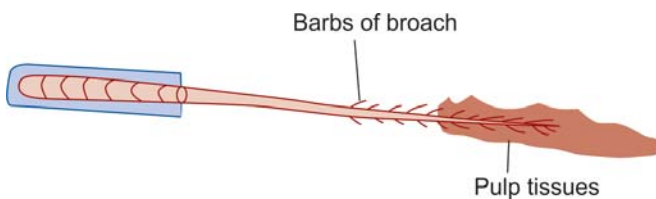


Fig. 14.8: Pulp extirpation using broach



A



B

Figs 14.9A and B: Reamers

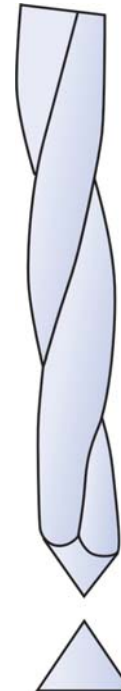


Fig. 14.10: Triangular blank and lesser number of flutes in reamer

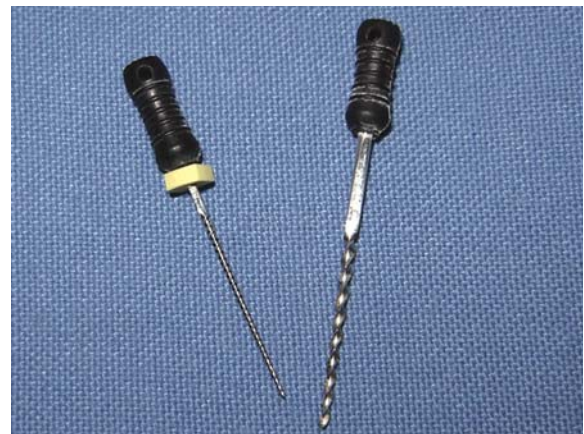

Fig. 14.11: Reamer has lesser number of flutes than file

- Reamer tends to remain self centered in the canal resulting in less chances of canal transportation.

### Files

Files are the instruments used during cleaning and shaping of the root canals for machining of the dentin. Since, Kerr manufacturing company was first to produce them, the files were also called K-files.

Files are predominantly used with filing or rasping action in which there is little or no rotation in the root canals. It is placed in root canal and pressure is exerted against the canal wall and instrument is withdrawn while maintaining the pressure (Fig. 14.12).

### Commonly Used Files

- K-files
- K-flex files
- Hedstrom files
- Safety H-files

### K-files (Fig. 14.13)

- They are triangular, square or rhomboidal in cross-section, manufactured from stainless steel wire, which is grounded into desired shape (Fig. 14.14).

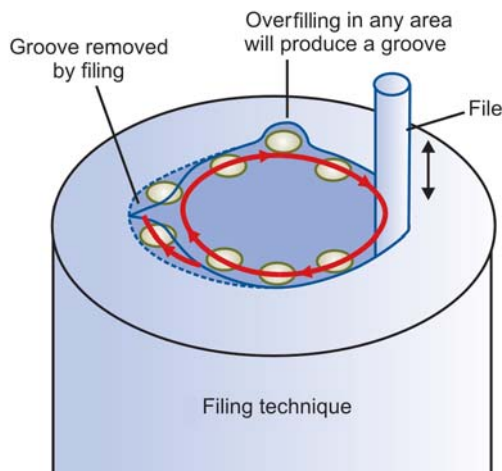


Fig. 14.12: Filing/Rasping action



Fig. 14.13: K-file

- K-files have 1½ to 2½ cutting blades per mm of their working end.
- Tighter twisting of the file spirals increases the number of flutes in files (more than reamer).
- Triangular cross-sectioned files show superior cutting and increased flexibility than the file or reamers with square blank (Fig. 14.15).

### Disadvantage of K-files

1. Less cutting efficiency.
2. Extrusion of debris periapically.

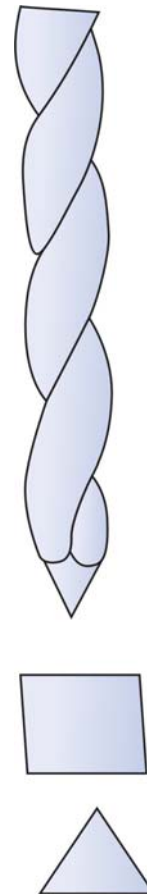


Fig. 14.14: Square or triangular cross-section of a K-file

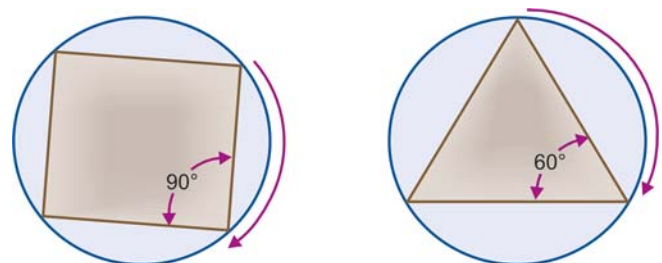


Fig. 14.15: Triangular cross-sectioned file shows better flexibility and cutting efficiency than square cross-sectioned file are reamer

### K-flex Files (Fig. 14.16)

- They were introduced by Kerr manufacturing company in 1982. It was realized that square blank of file results in total decrease in the instrument flexibility. To maintain shape and flexibility of these files, K-flex files were introduced.
- K-flex files are rhombus in cross-section having two acute angles and two obtuse angles (Fig. 14.17).
- Two acute angles increase sharpness and cutting efficiency of the instrument.
- Two obtuse angles provide more space for debris removal. Also the decrease in contact of instrument with canal walls provide more space for irrigation.
- They are used in filing and rasping motion.

### Hedstrom Files (H-files) (Fig. 14.18)

- Hedstrom files have flutes which resemble successively triangles set one on another (Fig. 14.19).
- Hedstrom files cut only when instrument is withdrawn because its edges face the handle of the instrument.
- When used in torquing motion, their edges can engage in the dentin of root canal wall and causing H-files to fracture.
- Hedstrom files should be used to machine straight canals because they are strong and aggressive cutters. Since they lack the flexibility and are fragile in nature, the H-files tend to fracture when used in torquing action.



Fig. 14.16: K-flex file

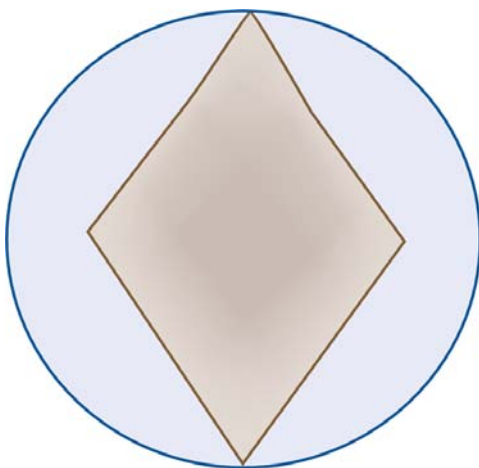


Fig. 14.17: Rhombus cross-section of K-flex file

### Advantages of H-files

1. Better cutting efficiency
2. Push debris coronally

### Disadvantages of H-files

1. Lack flexibility
2. Tend to fracture
3. Aggressive cutter

### Safety Hedstrom File

This file has noncutting safety side along the length of the blade which reduces the chances of perforations. The noncutting side is directed to the side of canal where cutting is not required. The noncutting side of safety file prevents lodging of the canals (Fig. 14.20).

### Gates-Glidden Burs (Fig. 14.21)

- Traditional engine driven instruments include Gates-Glidden drills which have flame shaped cutting point mounted on long thin shaft attached to a latch type shank (Fig. 14.22).
- Gates-Gliddens are available in a set from 1 to 6 with the diameters from 0.5 to 1.5 mm.
- Due to their design Gates-Glidden drills are side cutting instruments with safety tips (Fig. 14.23).



Fig. 14.18: Flexo-file

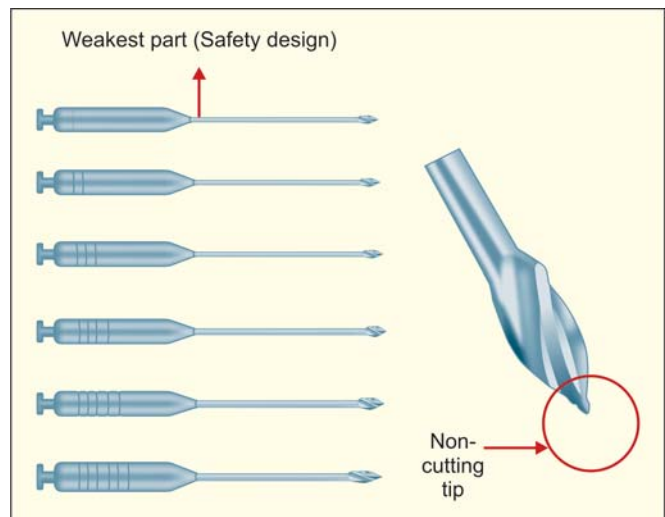


Fig. 14.19: Diagrammatic view of Hedstrom file





**Fig. 14.20:** Safety Hedstrom file



**Fig. 14.23:** Due to safety design, if cutting tip of instrument jams against canal wall, the fracture occurs at junction of shaft and shank and not at tip

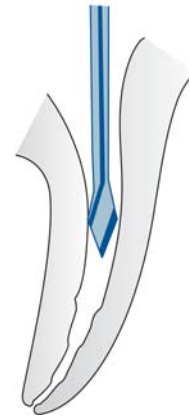


**Fig. 14.21:** Gates-Glidden drills



**Fig. 14.22:** Flame shaped head mounted on long thin shaft in Gates-Glidden drills

- They should be used at the speed of 750-1500 rpm. In brushing strokes.
- Safety design of Gates-Gliddens is that its weakest part lies at the junction of shank and shaft of the instrument. If its cutting tip jams against the canal wall, fracture



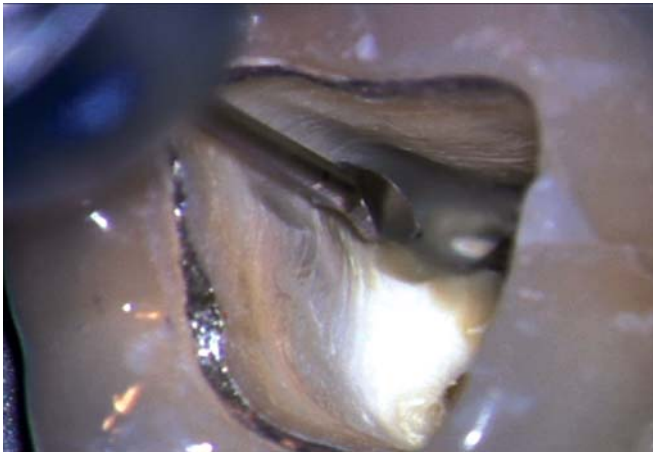
**Fig. 14.24:** Use of Gates-Glidden drill in canal

occurs at the junction of shank and the shaft but not at the tip of the instrument. This makes the easy removal of fractured drill from the canal.

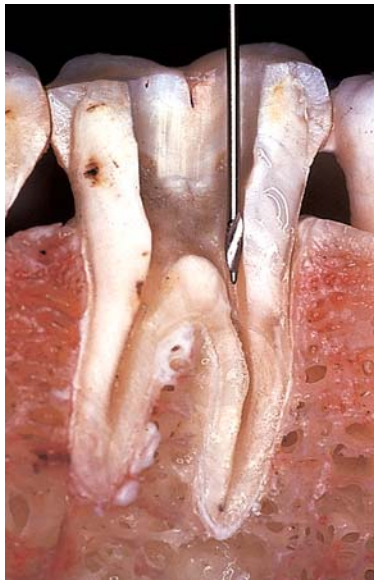
Number	Diameter at cutting tip
1.	0.50 mm
2.	0.70 mm
3.	0.90 mm
4.	1.1 mm
5.	1.3 mm
6.	1.5 mm

#### Uses of Gates-Glidden Drills

1. For coronal flaring during root canal preparation (Figs 14.24 to 14.26).
2. During retreatment cases or post space preparation for removal of gutta-percha.



**Fig. 14.25:** Use of Gates-Glidden drill for coronal flaring

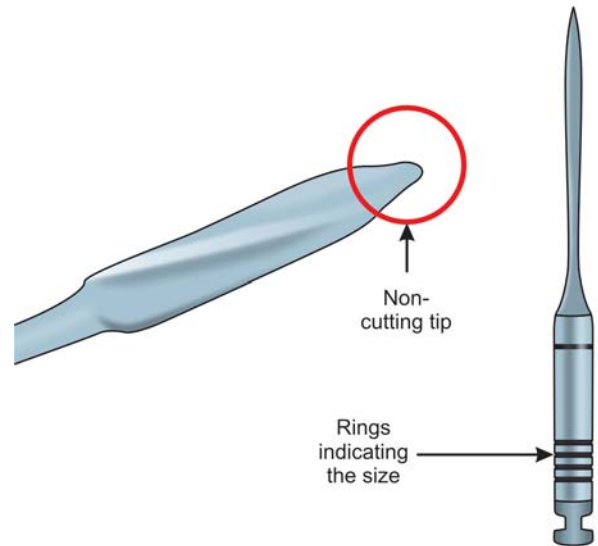


**Fig. 14.26:** Use of Gates-Glidden drill for coronal flaring

3. During instrument removal, if used incorrectly for example using at high rpm, incorrect angle of insertion, forceful drilling, the use of Gates-Glidden can result in procedural accidents like perforations, instrument separation, etc.

### **Peeso Reamers (Fig. 14.27)**

- They are rotary instruments used mainly for post space preparations.
- They have safe ended noncutting tip.
- Their tip diameter varies from 0.7 to 1.7 mm.
- They should be used in brushing motion.



**Fig. 14.27:** Peeso reamers

Number	Diameter at cutting tip
1.	0.70 mm
2.	0.90 mm
3.	1.1 mm
4.	1.3 mm
5.	1.5 mm
6.	1.7 mm

### **Nickle Titanium (NiTi) Endodontic Instruments**

NiTi was developed by Buchler 40 years ago. NiTi is also known as the NiTinol (NiTi Navol Ordinance Laboratory in US). In endodontics commonly used NiTi alloys are called 55 NiTinol (55% weight Ni and 45% Ti) and 60 NiTinol (60% weight of Ni, 40% Ti).

First use of NiTi in endodontics was reported in 1988, by Walia et al when a 15 No. NiTi file was made from orthodontic wire and it showed superior flexibility and resistance to torsional fracture. This suggested the use of NiTi files in curved canals.

#### *Advantages of NiTi Alloys*

1. Shape memory
2. Superelasticity
3. Low modulus of elasticity
4. Good resiliency
5. Corrosion resistance
6. Softer than stainless steel

### Disadvantages of NiTi Files

1. Poor cutting efficiency.
2. NiTi files do not show signs of fatigue before they fracture.
3. Poor resistance to fracture as compared to stainless steel.

### Instruments Used for Obturation of Root Canals

*Spreaders and pluggers* are the instruments used to compact the gutta-percha into root canal during obturation (Fig. 14.28). The use of instrument depends on the technique employed for obturation.

#### Hand Spreaders

- They are made from stainless steel and are designed to facilitate the placement of accessory gutta-percha points around the master cone during lateral compaction technique (Fig. 14.29).
- These spreaders do not have standardized size and shape.
- They are not used routinely because excessive pressure on the root may cause fracture of root.

#### Finger Spreaders (Fig. 14.30)

- They are shorter in length which allows them to afford a great degree of tactile sense and allow them to rotate freely around their axis.

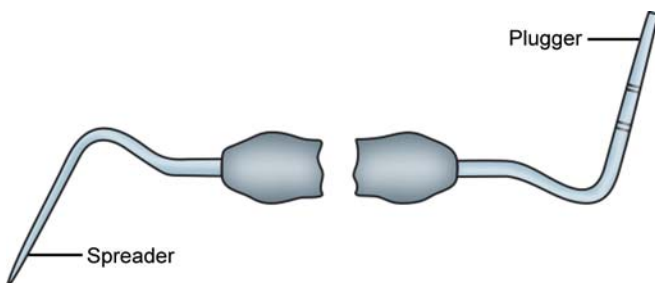


Fig. 14.28: Spreader and plugger tips



Fig. 14.29: Hand spreader



Fig. 14.30: Finger spreader

- They are standardized and color coded to match the size of gutta-percha points.
- They can be manufactured from stainless steel or nickel titanium.
- Stainless steel spreaders may pose difficulty in penetration in curved canals, may cause wedging and root fracture if forced during compaction. They also produce great stresses while compaction.
- NiTi spreaders are recently introduced spreaders which can penetrate the curved canals and produce less stresses during compaction (Fig. 14.31). But they may bend under pressure during compaction. So, we can say that combination of both types of spreaders, i.e. stainless steel and NiTi is recommended for compaction of gutta-percha, NiTi spreaders in apical area and stainless steel in coronal part of the root canal.

#### Hand Pluggers

- They consist of diameter larger than spreader and have blunt end (Figs 14.32A and B).
- They are used to compact the warm gutta-percha vertically and laterally into the root canal.
- They may also be used to carry small segments of gutta-percha into the canal during sectional filling technique (Fig. 14.33).

#### Finger Pluggers (Fig. 14.34)

- They are used for vertical compaction of gutta-percha. They apply controlled pressure while compaction, and have more tactile sensitivity than hand plugger.

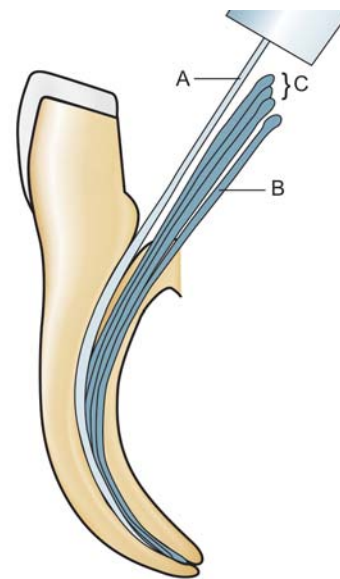

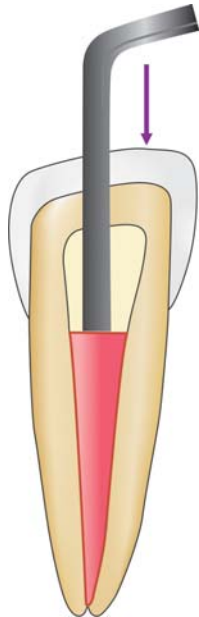


Fig. 14.31: Use of spreader during lateral compaction technique



**Figs 14.32A and B:** Hand pluggers



**Fig. 14.33:** Vertical compaction of gutta-percha using plunger

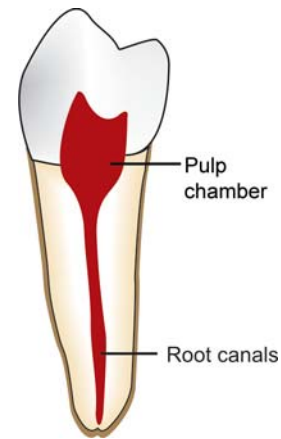


**Fig. 14.34:** Finger plunger

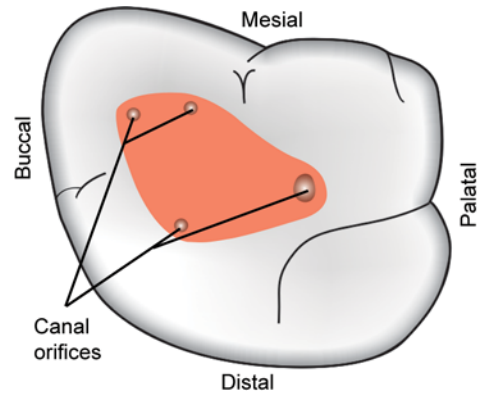
## ACCESS CAVITY PREPARATION

### Pulp Cavity

The pulp cavity lies within the tooth and is enclosed by dentin all around except at the apical foramen. It is divided into two—a coronal and a radicular portion. The coronal



**Fig. 14.35:** Pulp cavity showing pulp chamber and root canals



**Fig. 14.36:** Canal orifices

portion, i.e. pulp chamber (Fig. 14.35) reflects the external form of crown. The roof of pulp chamber consists of dentin covering the pulp chamber occlusally or incisally. The floor of pulp chamber merges into the root canal at the orifices. Thus, canal orifices are the openings in the floor of pulp chamber leading into the root canals (Fig. 14.36).

### Pulp Horns

Pulp horns are landmarks present occlusal to pulp chamber. Pulp horn tends to be single horn associated with each cusp of posterior teeth and mesial and distal in anterior teeth.

### Pulp Chamber

It occupies the coronal portion of pulp cavity. It acquires shape according to shape and size of crown of the tooth, age of person, and irritation, if any.

## Canal Orifice

Canal orifices are openings in the floor of pulp chamber leading into root canals.

### Root Canal

The root canal extends from canal orifice to the apical foramen. In anterior teeth, the pulp chamber merges into the root canal (Fig. 14.37) but in multirooted posterior teeth this division becomes quite obvious (Fig. 14.38).

**Apical root anatomy:** It is based on following anatomic and histological landmarks in the apical part of the root canal:

- i. **Apical constriction (Minor diameter):** It is apical part of root canal having the narrowest diameter short of the apical foramina or radiographic apex. It may or may not coincide with CDJ.
- ii. **Apical foramen (Major diameter):** It is main apical opening on the surface of root canal through which blood vessels enter the canal. Its diameter is almost double the apical constriction giving it a funnel shape appearance, which has been described as morning glory or hyperbolic. Average distance between minor and major diameter in young person is 0.5 mm and in older person, it is 0.7 mm.
- iii. **Cementodentinal junction:** Cementodentinal junction is the point in the canal, where cementum meets dentin. The position of CDJ varies but usually it lies 0.1 mm from the apical foramen (Fig. 14.39).

## Definition of Access Cavity Preparation

Access cavity preparation is defined as endodontic coronal preparation which enables unobstructed access to the canal orifices, a straight line access to apical foramen, complete control over instrumentation and to accommodate obturation technique.

The main objective of the access cavity preparation is to create a smooth, straight line access to the canal system and the apex. The optimal access cavity results in the straight entry into the canal orifices with line angles forming a funnel which drops smoothly into the canals (Fig. 14.40).

An ideal access preparation should have following qualities:

1. An unobstructed view into the canal.
2. A file should pass into the canal without touching any part of the access cavity.
3. No remaining caries should be present in access cavity.
4. Obturating instruments should pass into the canal without touching any portion of the access cavity.

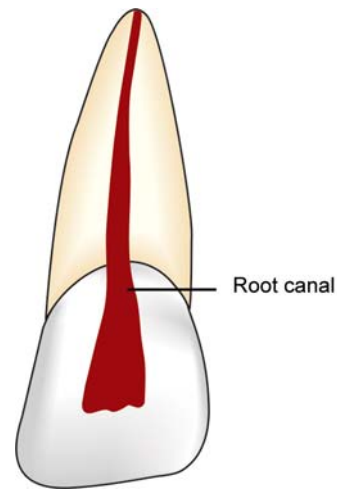


Fig. 14.37: Root canal anatomy of anterior tooth

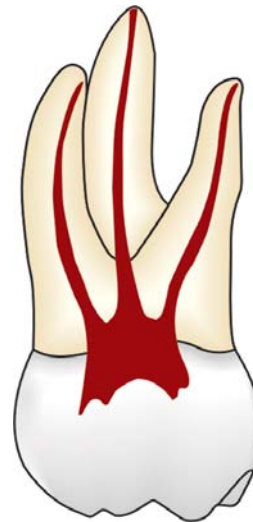


Fig. 14.38: Root canal anatomy of posterior tooth

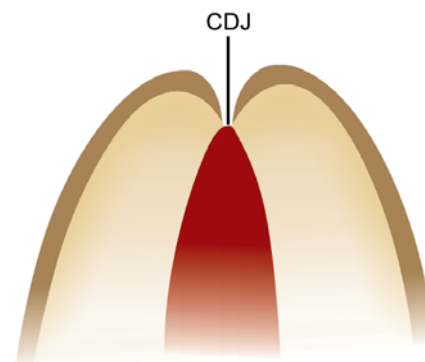
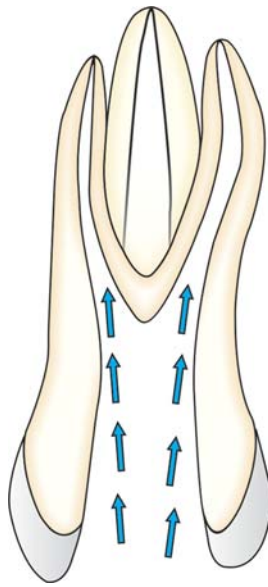
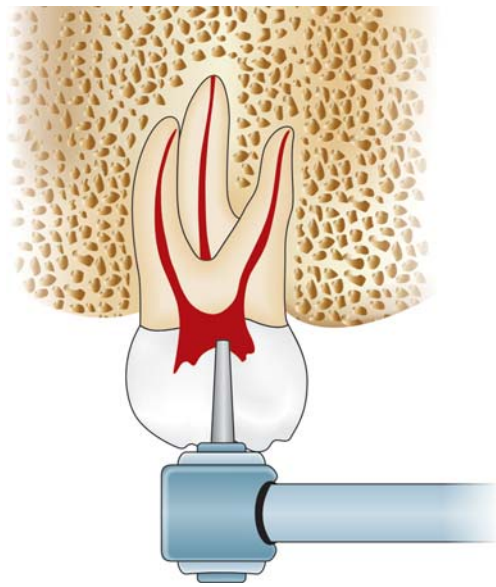


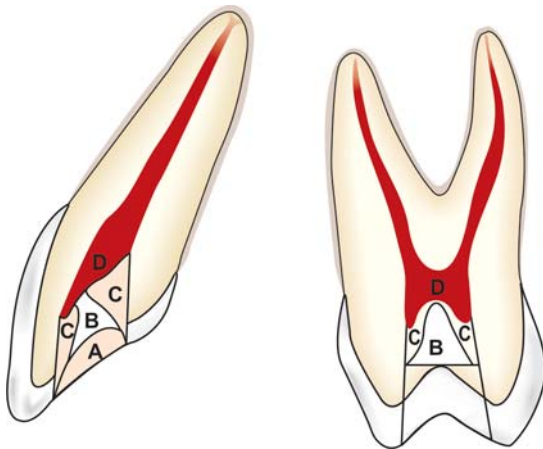
Fig. 14.39: Cementodentinal junction



**Fig. 14.40:** Smooth, straight line access to root canal system



**Fig. 14.42:** Preoperative radiograph can help to note the position and depth of pulp chamber

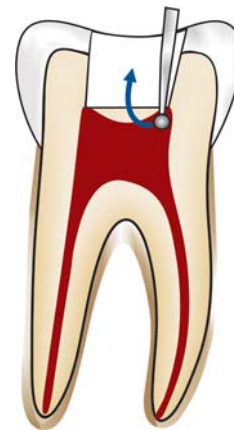


**Fig. 14.41:** Guidelines for access cavity preparation

- A. Penetration into enamel with No. 2 or No. 4 high speed round bur;
- B. Exposure of pulp chamber with tapered fissure bur;
- C. Refinement of the pulp chamber and removal of pulp chamber roof using round bur from inside to outside;
- D. Complete debridement of pulp chamber space

### Guidelines for Access Cavity Preparation (Fig. 14.41)

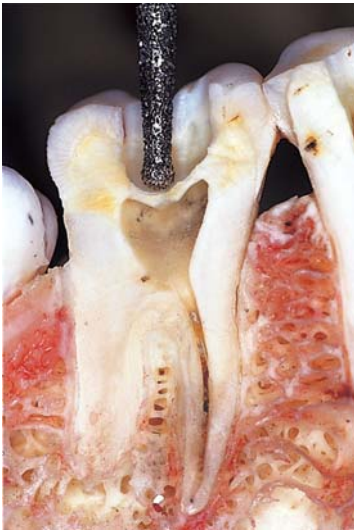
1. Before starting the access cavity preparation one should check the depth of preparation by aligning the bur and handpiece against the radiograph. This is done so as to note the position and depth of the pulp chamber (Fig. 14.42).
2. Place a safe-ended bur in handpiece complete the outline form. The bur is penetrated into the crown until the roof of pulp chamber is penetrated (Fig. 14.43).



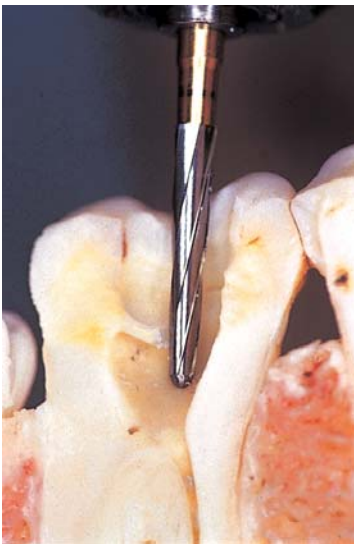**Fig. 14.43:** Once "drop in" into pulp chamber is obtained bur is moved inside to outside

Commonly recommended access opening bur is round bur, that is to penetrate the pulp chamber. It prevents the overpreparation. Once the "drop in" into the pulp chamber is obtained, round bur is replaced by tapered fissured bur.

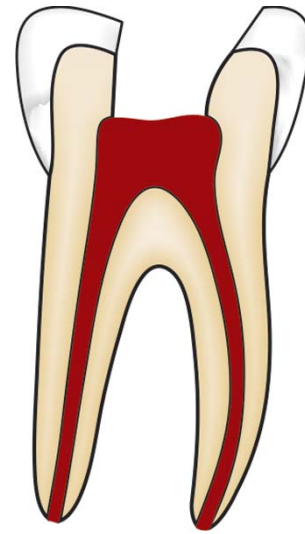
3. When locating the canal orifices is difficult, one should not apply rubber dam until correct location has been confirmed.
4. Remove all the unsupported tooth structure to prevent tooth fracture during treatment.



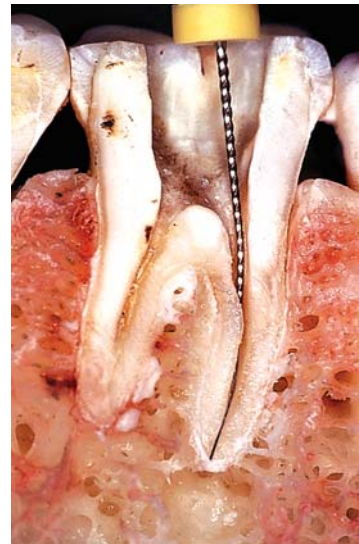**Fig. 14.44:** Access preparation



**Fig. 14.45:** Access refining

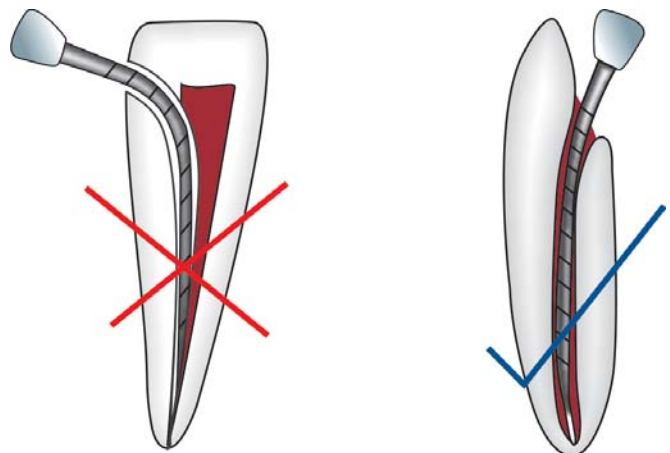


**Fig. 14.46:** Complete access cavity preparation



**Fig. 14.47:** Straight line access to root canal system

5. Remove the chamber roof completely as this will allow the removal of all the pulp tissue, calcifications, caries or any residuals of previous fillings (Fig. 14.45). If pulp chamber is not completely deroofed, it can result in:
  - a. Contamination of the pulp space.
  - b. Discoloration of endodontically treated tooth.
6. The walls of pulp chamber are flared and tapered to form a gentle funnel shape with larger diameter towards occlusal surface (Fig. 14.46).
7. Endodontic access cavity is prepared through the occlusal or lingual surface never through proximal or gingival surface. If access cavity as made through wrong entry, it will cause inadequate canal instrumentation resulting iatrogenic errors (Figs 14.47 and 14.48).



**Fig. 14.48:** Correct position for entering into the pulp cavity

8. Inspect the pulp chamber for determining the location of canals, curvatures, calcifications using well magnification and illumination.

#### Laws of access cavity preparation for locating canal orifices

**Law of centrality:** Floor of pulp chamber is always located in the center of tooth at the level of cemento-enamel junction.

**Law of cemento-enamel junction:** Distance from external surface of clinical crown to the wall of pulp chamber is same through out the tooth circumference at the level of CEJ.

**Law of concentricity:** Walls of pulp chamber are always concentric to external surface of tooth at the level of CEJ. This indicates anatomy of external tooth surface reflects the anatomy of pulp chamber.

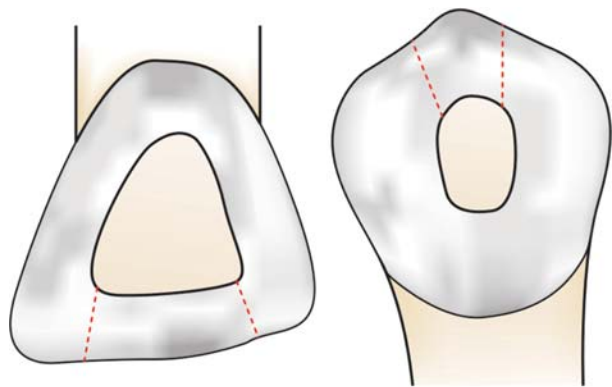
**Law of color change:** Color of pulp chamber floor is darker than the cavity walls.

**Law of symmetry:** Usually canal orifices are equidistant from a line drawn in mesial and distal direction through of floor of pulp chamber.

**Law of orifice location:** Canal orifices are located at the junction of floor and walls, and at the terminus of root development fusion lines.

#### ACCESS CAVITY OF ANTERIOR TEETH

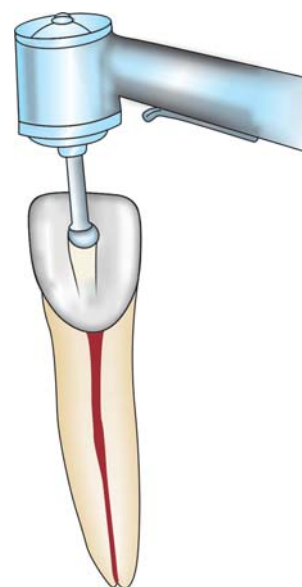
- The access cavity shape varies with size and shape accordingly the internal anatomy of the pulp chamber, so internal anatomy of tooth must be determined before starting the treatment.
- Remove all the caries and any defective restorations so as to prevent contamination of pulp space as well as to have a straight line access into the canals.
- Access opening is started at center of the lingual surface (Fig. 14.49). If it is made too small and too close to the cingulum the instrument tends to bind the canal walls and thus may not work optimally.



**Fig. 14.49:** Access opening is initiated at center of lingual surface

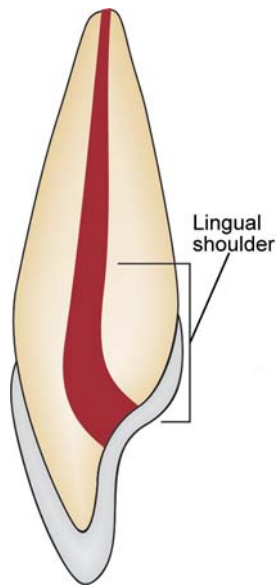
- Direct a round bur perpendicular to the lingual surface at its center to penetrate the enamel. Once enamel is penetrated, bur is directed parallel to the long axis of the tooth, until “a drop” in effect is felt (Fig. 14.50).
- Now when pulp chamber has been penetrated, the remainder of chamber roof is removed by working a round bur from inside to outside. This is done to remove all the obstructions of enamel and dentin overhangs that would entrap debris, tissues and other materials.
- Now locate the canal orifices using endodontic explorer. Sharp explorer tip is used to locate the canal orifices, to penetrate the calcific deposits if present, and also to evaluate the straight line access.
- Once the canal orifices are located, the lingual shoulder is removed using Gates-Glidden drills or safe tipped diamond or carbide burs. Lingual shoulder is basically a prominence of dentin formed by removal of lingual roof which extends from the cingulum to approximately 2 mm apical to the orifice (Fig. 14.51).

During the removal of lingual shoulder, the orifice should also be flared so that it becomes confluent with all the walls of access cavity preparation. By this a straight line access to the apical foramen is attained, i.e. an endodontic file can reach up to apical foramen without bending or binding to the root canal wall. Any deflection of file occurs should be corrected because it can lead to instrumental errors (Fig. 14.52). The deflected instruments work under more stress, more chance of instrument separation is there. Deflected instruments also result in procedural accidents like canal transportations, perforations, ledging and zipping.

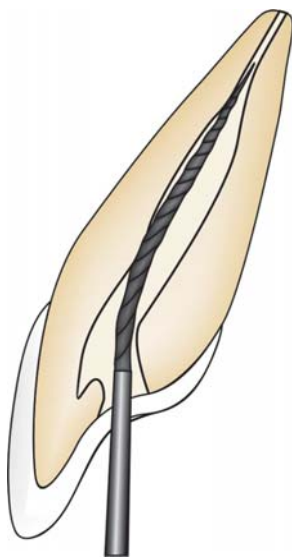


**Fig. 14.50:** Once enamel is penetrated, bur is directed parallel to long axis of tooth





**Fig. 14.51:** Lingual shoulder is prominence of dentin formed by lingual roof. It extends from cingulum to 2 mm apical to the canal orifice



**Fig. 14.52:** Improper access cavity preparation causing deflection of instrument

- After the straight line access of the canal is confirmed by passing a file passively into the canal, one should evaluate the access cavity using magnification and illumination.
- Finally smoothing of the cavosurface margins of access cavity is done because rough or irregular cavity margins can cause coronal leakage through restorations. Also smooth cavity margins allow better and precise placement of final composite restoration with minimal coronal leakage.

Since, the outline form of access cavity reflects the internal anatomy of the pulp space, though technique of the access opening of anterior teeth is the same, the shape may vary according to internal anatomy of each tooth.

### Maxillary Central Incisor

The outline form of access cavity of maxillary central incisor is a rounded triangular shape with base facing the incisal aspect (Fig. 14.53). The width of base depends upon the distance between mesial and distal pulp horns. Shape may change from triangular to slightly oval in mature tooth because of less prominence of mesial and distal pulp horns.

### Maxillary Lateral Incisor

The shape of access cavity is almost similar to that of maxillary central incisor except that:

- It is smaller in size.
- When pulp horns are present, shape of access cavity is rounded triangle.
- Generally the pulp horns are missing so shape of access cavity which results is oval.

### Maxillary Canine

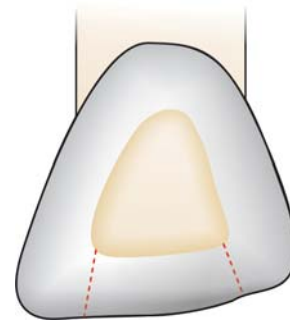
Shape of access cavity of canine though is quite similar to incisors with following differences:

- Canine does not have pulp horns.
- Access cavity is oval in shape with greater diameter labiopalatally (Fig. 14.54).

### Mandibular Incisors

Mandibular central and lateral incisors are similar in shape of access cavity and the root canal system. Shape of access cavity of mandibular incisors is different from maxillary incisors in following aspects (Fig. 14.55):

- It is smaller in shape.
- Shape is long oval with greatest dimensions directed incisogingivally.



**Fig. 14.53:** Outline of access cavity of maxillary incisor

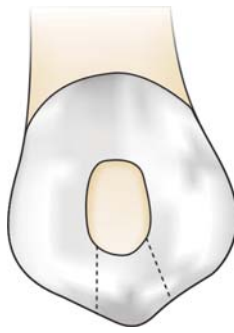


Fig. 14.54: Outline of access cavity of maxillary canine

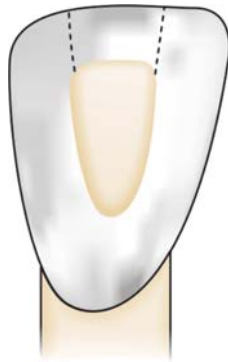


Fig. 14.55: Outline of access cavity of mandibular incisor

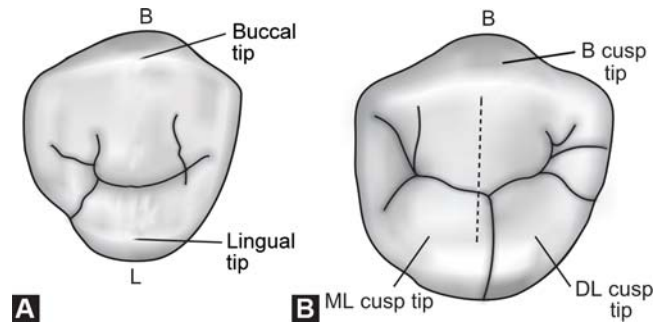


Fig. 14.56: Outline of access cavity of premolars

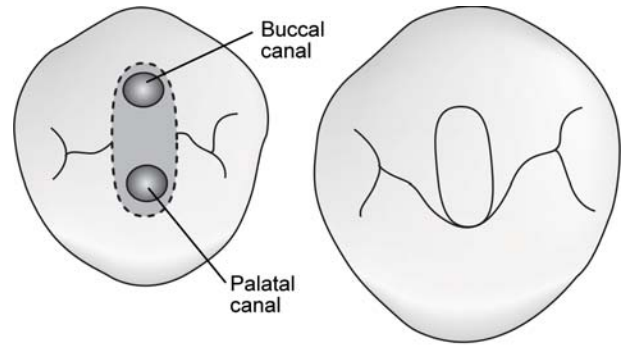


Fig. 14.57: Oval-shaped access cavity of premolars

### Mandibular Canine

The shape of access opening of mandibular canine is similar to that maxillary of canine except that:

- i. It is smaller in size.
- ii. Root canal outline is narrower in mesiodistal dimension
- iii. Generally two canals are present in mandibular canine.

### ACCESS CAVITY PREPARATION FOR PREMOLARS

- The basic step of access cavity preparation is removal of the caries and any other permanent restoration material if present.
- Determine the site of access opening on the tooth.
  - In premolars, it is in the center of occlusal surface between buccal and the lingual cusp tips (Fig. 14.56).
- Slight variations exist between mandibular and maxillary premolars because of the lingual tilt of mandibular premolars.
- Penetrate the enamel with No. 4 round bur in high speed contra-angle handpiece. The bur should be directed parallel to the long axis of tooth and perpendicular to the

occlusal table. Generally the external outline form for premolars is oval in shape with greater dimensions of buccolingual side (Fig. 14.57).

- Once the clinician feels “drop” into the pulp chamber, penetrate deep enough to remove the roof of pulp chamber without cutting the floor of pulp chamber. To remove the roof of pulp chamber and pulp horns, place the bur alongside the walls of pulp chamber and work from inside to outside.

For removal of pulp chamber roof, round bur, a tapered fissure or a safety tip bur can be used.

- After removal of roof of pulp chamber, locate the canal orifices with the help of sharp endodontic explorer.
- Remove any remaining cervical bulges or obstructions using safety tip burs or Gates-Glidden drills and obtain a straight line access to the canals.

It can be confirmed by passing a file passively into the canal which should reach the apex or the first point of curvature without any deflection.

- The walls of access cavity are then smoothed and sloped slightly towards the occlusal surface. The

divergence of access cavity walls creates a positive seat for temporary restorations.

Access cavity preparation for all premolars is same except for some differences.

### Maxillary First Premolar

Shape of access cavity is ovoid in first premolar in which boundaries should not exceed beyond half the lingual incline of buccal cusp and half the buccal incline of lingual cusp.

### Maxillary Second Premolar

It is similar to that of maxillary first premolar and varies only by anatomic structure of the pulp chamber.

### Mandibular First Premolar

Following differences are seen in case of mandibular first premolar from the maxillary premolars:

- i. There is presence of 30° lingual inclination of the crown to the root, hence the starting point of bur penetration should be halfway up the lingual incline of the buccal cusp on a line connecting the cusp tips.
- ii. Shape of access cavity is oval which is wider mesiodistally when compared with its maxillary counterpart.

### Mandibular Second Premolar

The access cavity preparation is similar to mandibular first premolar except that in mandibular second premolar:

- i. Enamel penetration is initiated in the central groove because its crown has smaller lingual tilt.
- ii. Because of better developed lingual half, the lingual boundary of access opening extends halfway up to the lingual cusp incline, i.e. pulp chamber is wider buccolingually.
- iii. Root canals are more often oval than round.
- iv. Ovoid access opening is wider mesiodistally.

## ACCESS CAVITY PREPARATION FOR MAXILLARY MOLARS

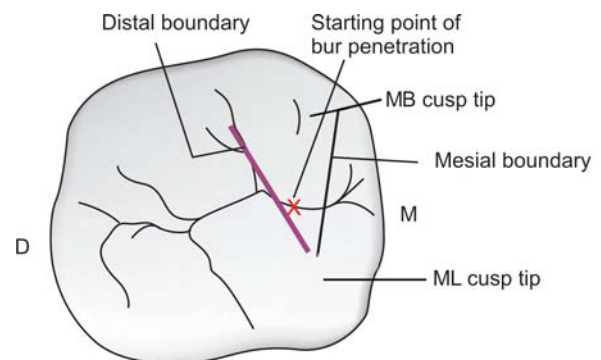
Though the technique of access cavity preparation of molar is similar to that of anterior teeth and premolar but because of anatomic differences, they are discussed separately.

- Remove all the carious portion or any restoration if present.
- Determine the shape and size of access opening by measuring the boundaries of pulp chamber mesially and distally and coronally on the radiograph.

- Determine the starting point of bur into the enamel. It is determined by mesial and distal boundary. Mesial boundary is a line joining the mesial cusps and the distal boundary is the oblique ridge. The starting point of bur penetration is on the central groove midway between mesial and distal boundaries (Fig. 14.58).
- Now penetrate the enamel with No. 4 round bur in the central groove directed palatally and prepare an external outline form.
- Penetrate the bur deep into the dentin until the clinician feels “drop” into the pulp chamber. Now remove the complete roof of pulp chamber using tapered fissure, round bur or safety tip diamond or the carbide bur working from inside to outside. The shape and size of the internal anatomy of pulp chamber guides the cutting.
- Explore the canal orifices with sharp endodontic explorer. All the canal orifices should be positioned entirely on the pulp floor and should not extend to the axial walls.
- After the canal orifices has been located, remove any cervical bulges, ledges or obstruction if present.
- Smoothen and finish the access cavity walls so as to make them confluent within the wall of pulp chamber and slightly divergent towards the occlusal surface.

### Maxillary First Molar

- The shape of pulp chamber is rhomboid with acute mesiobuccal angle, obtuse distobuccal angle and palatal right angles (Fig. 14.59).
- Palatal canal orifice is located palatally. Mesiobuccal canal orifice is located under the mesiobuccal cusp. Distobuccal canal orifice is located slightly distal and palatal to the mesiobuccal orifice.



**Fig. 14.58:** Outline of access cavity of maxillary molars is determined by mesial and distal boundary. Mesial boundary is a line joining the mesial cusps and the distal boundary is the oblique ridge. The starting point of bur penetration is on the central groove midway between mesial and distal boundaries

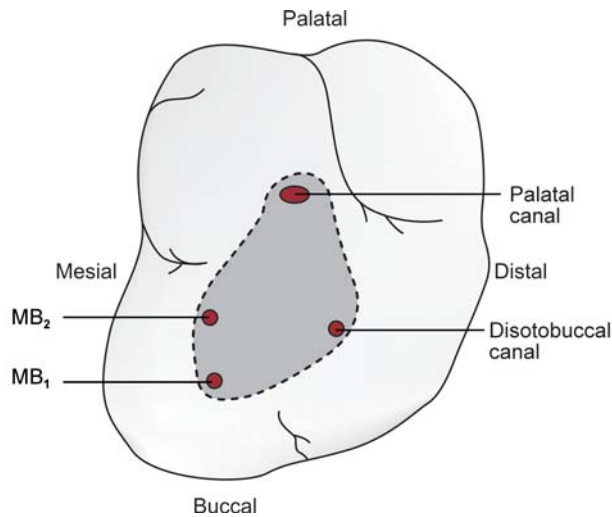


Fig. 14.59: Position of root canal orifices of maxillary first molar

A line drawn to connect all three orifices (i.e. MB, DB and palatal) forms a triangle, termed as **molar triangle**.

- Almost always a second mesiobuccal canal, i.e. MB<sub>2</sub> is present in first maxillary molars, which is located palatal and mesial to the MB<sub>1</sub>. Though its position can vary sometimes it can lie a line between MB<sub>1</sub> and palatal orifices.
- Because of presence of MB<sub>2</sub>, the access cavity acquires a rhomboid shape with corners corresponding to all the canal orifices, i.e. MB<sub>1</sub>, MB<sub>2</sub>, DB and palatal.

**Luebke** has shown that an entire wall is not extended to search and facilitate cleaning, shaping and obturation of extracanal. He recommended extension of only that portion of the wall where extracanal is present, and this may result in “**cloverleaf appearance**” in the outline form. Luebke referred this to as a **Shamrock preparation**.

### Maxillary Second Molar

**Basic technique is similar to that of first molar but with following differences:**

- Three roots are found closer which may even fuse to form a single root.
- MB<sub>2</sub> is less likely to be present in second molar.
- The three canals form a rounded triangle with base to buccal.
- Mesiobuccal orifice is located more towards mesial and buccal than in first molar.

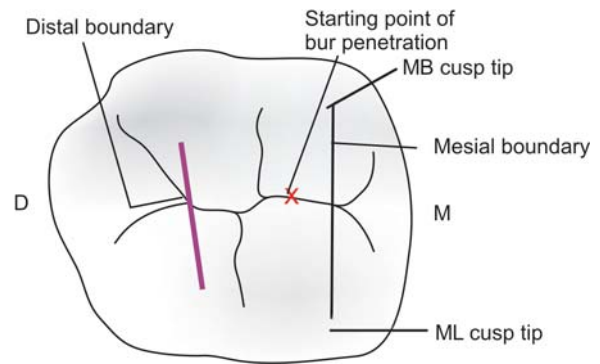
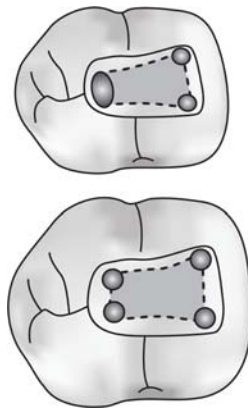


Fig. 14.60: Outline of access preparation of mandibular molars. The enamel is penetrated with No. 4 round bur on the central fossa midway between the mesial and distal boundaries. The mesial boundary is a line joining the mesial cusp tips and the distal boundary is the line joining buccal and the lingual grooves

### ACCESS CAVITY PREPARATION FOR MANDIBULAR MOLARS

- It is similar to that of any other access cavity preparation in removal of caries and any restorative material if present.
- The enamel is penetrated with No. 4 round bur on the central fossa midway between the mesial and distal boundaries. The mesial boundary is a line joining the mesial cusp tips and the distal boundary is the line joining buccal and the lingual grooves (Fig. 14.60).
- Bur is penetrated in the central fossa directed towards the distal root. Once the “drop” into pulp chamber is felt, remove whole of the roof of pulp chamber working from inside to outside with the help of round bur, tapered fissure bur or the safety tip diamond or the carbide bur as it was done in maxillary molars.
- Explore the canal orifices with sharp endodontic explorer and finally finish and smoothen the cavity with slight divergence towards the occlusal surface.
- Second molars with fused roots usually have two canals, buccal and palatal though the number, type, shape and form of canals may vary.
- When four canals are present, the shape of access cavity is rhomboid but when two canals are present, access cavity is oval in shape with wider dimensions buccolingually.
- Shape and size of the access cavity may vary according to the size, shape and location of the canal orifices.



**Fig. 14.61:** Outline of access cavity of mandibular molars

### Mandibular First Molar

Mesiobuccal orifice is under the mesiobuccal cusp. Mesiolingual orifice is located in a depression formed by mesial and the lingual walls. The distal orifice is oval in shape with largest diameter buccolingually, located distal to the buccal groove.

Orifices of all the canals are usually located in the mesial two third of the crown (Fig. 14.61).

Cases have also been reported with an extramesial canal, i.e. middle mesial canal (1-15%) lying in the developmental groove between mesiobuccal and mesiolingual canals. Distal root has also shown to have more than one orifices, i.e. distobuccal, distolingual and middle distal. These orifices are usually joined by the developmental grooves.

- The shape of access cavity is usually trapezoidal or rhomboid irrespective of number of canals present.

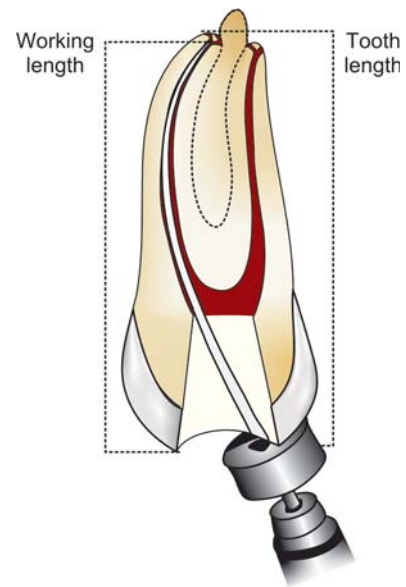
The mesial wall is straight, the distal wall is round.

The buccal and lingual walls converge to meet the mesial and distal walls.

### Mandibular Second Molar

Access opening of mandibular second molar is similar to that of first molar except for few differences. In mandibular second molar:

- Pulp chamber is smaller in size.
- One, two or more canals may be present.
- Mesiobuccal and mesiolingual canal orifices are usually located closer together.
- When three canals are present, shape of access cavity is almost similar to mandibular first molar, but it is more triangular and less of rhomboid shape.



**Fig. 14.62:** Working length distance is defined as the distance from coronal referencer point to a point where canal preparation and obturation should terminate

- When two canal orifices are present, access cavity is rectangular, wide mesiodistally and narrow buccolingually.
- Because of buccoaxial inclination, sometimes it is necessary to reduce a large portion of the mesiobuccal cusp to gain convenience form for mesio-buccal canal.

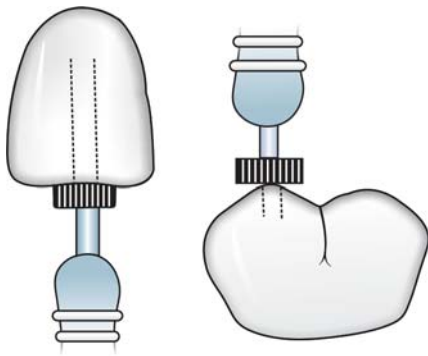
### WORKING LENGTH DETERMINATION

According to endodontic glossary *working length* is defined as “the distance from a coronal reference point to a point at which canal preparation and obturation should terminate” (Fig. 14.62).

**Reference point:** Reference point is that site on occlusal or the incisal surface from which measurements are made. A reference point is chosen which is stable and easily visualized during preparation. Usually this is the highest point on incisal edge of anterior teeth and buccal cusp of posterior teeth (Fig. 14.63).

### Significance of Working Length

- Working length determines how far into canal, instruments can be placed and worked.



**Fig. 14.63:** Usually the reference point is highest point on incisal edge of anterior teeth and cusp tip of posterior teeth

- If placed in correct limits, it plays an important role in determining the success of treatment.
- Once apical stop is calculated, monitor the working length periodically because working length may change as curved canal is straightened.
- Failure to accurately determine and maintaining working length may result in length being over or short of apical constriction.

#### Consequences of overextended working length

- Perforation through apical construction
- Over instrumentation
- Overfilling of root canal
- Increased incidence of postoperative pain
- Prolonged healing period
- Lower success rate due to incomplete regeneration of cementum, periodontal ligament and alveolar bone.

#### Consequences of working short of actual working length

- Incomplete cleaning and instrumentation of the canal
- Persistent discomfort due to presence of pulpal remnants
- Underfilling of the root canal
- Incomplete apical seal
- Apical leakage which supports existence of viable bacteria, this further leads to poor healing and periradicular lesion.

#### Causes of loss of working length

- Presence of debris in apical 2-3 of canal
- Failure to maintain apical patency
- Skipping instrument sizes
- Ledge formation
- Inadequate irrigation
- Instrument separation
- Canal blockage.

## Different Methods of Working Length Determination

### Methods of determining working length

#### Radiographic methods

- Grossman formula
- Ingle's method
- Weine's method
- Kuttler's method
- Radiographic grid
- Endometric probe
- Direct digital radiography
- Xeroradiography
- Subtraction radiography

#### Non-radiographic methods

- Digital tactile sense
- Apical periodontal sensitivity
- Paper point method
- Electronic apex locators

## Radiographic Method of Working Length Determination

This technique was first introduced by John Ingle. When radiographs are used in determining working length the quality of the image is important for accurate interpretations.

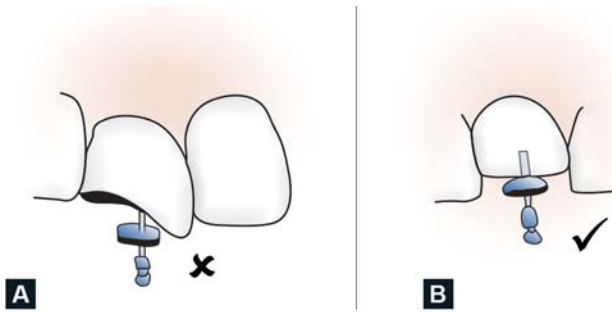
Among the two commonly used techniques, paralleling techniques have been demonstrated as superior to bisecting angle technique in determination and reproduction of apical anatomy.

Before studying the X-rays for endodontics, understanding of buccal object rule is essential. The basic concept of the rule is that as the vertical or horizontal angulation of X-ray tube changes, the object buccal or closest to tube head moves to opposite side of radiograph compared to the lingual object. To separate buccal and lingual roots (for example in maxillary first premolar) to visualize the working length, tube head should be moved from a 20° mesial angulation. This captures the buccal root to the opposite or distal side of radiograph and lingual root on mesial side of the radiograph. It is also known as SLOB rule that is same lingual opposite buccal.

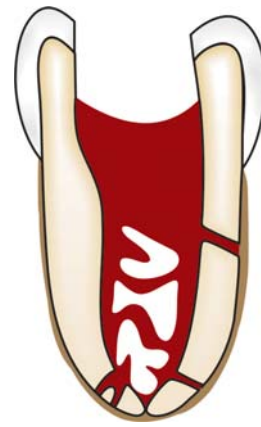
Before access opening, fractured cusps, cusps weakened by caries or restorations are reduced to avoid fracture of weakened enamel during the treatment. This will avoid the loss of initial reference point and thus the working length (Figs 14.64A and B).

### Radiographic Method of Length Determination (Figs 14.65A to D)

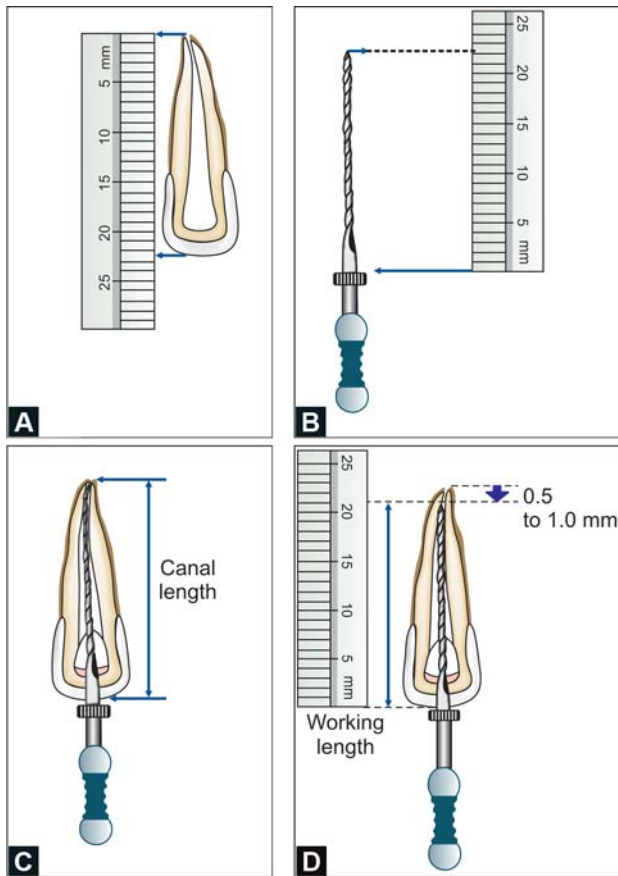
1. Measure the estimated working length from preoperative periapical radiograph.
2. Adjust stopper of instrument to this estimated working length and place it in the canal up to the adjusted stopper.
3. Take the radiograph.



**Figs 14.64A and B:** Reference point should not be made of fractured tooth surface or carious tooth structure. These should be first removed for avoiding loss in working length

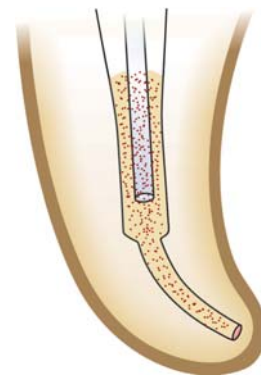


**Fig. 14.66:** Complicated root canal anatomy



**Figs 14.65A to D:** Radiographic method of working length determination

4. On the radiograph measure the difference between the tip of the instrument and root apex. Add or subtract this length to the estimated working length to get the new working length.
5. Correct working length is finally calculated by subtracting 1 mm from this new length.



**Fig. 14.67:** Irrigation helps in loosening of debris

### IRRIGATION OF ROOT CANAL SYSTEM

It's truly said, "Instruments shape, irrigants clean". Every root canal system has spaces that cannot be cleaned mechanically. The only way we can clean webs, fins and anastomoses is through the effective use of an irrigation solution (Fig. 14.66).

#### Functions of Irrigants

1. Irrigants perform physical and biologic functions. Dentin shavings get removed from canals by irrigation (Fig. 14.67).
2. Instruments are less likely to break when canal walls are lubricated with irrigation.
3. Irrigants act as solvent of necrotic tissue, so they loosen debris, pulp tissue and microorganisms from irregular dentinal walls (Fig. 14.68).
4. Irrigants help in removing the debris from accessory and lateral canals where instruments cannot reach.
5. Most irrigants are germicidal but they also have antibacterial action.

- Irrigants also have bleaching action to lighten teeth discolored by trauma or extensive silver restorations.

### Commonly Used Irrigating Solutions

#### Chemically Non-active Solution

- Water
- Saline
- Local anesthetic

#### Chemically Active Materials

- Alkalis:** Sodium hypochlorite 0.5-5.25%
- Chelating agents:** Ethylene diamine tetra-acetic acid (EDTA)
- Oxidizing agents:** Hydrogen peroxide, carbamide peroxide
- Antibacterial agents:** Chlorhexidine, Bisdequalinium acetate
- Acids:** 30% hydrochloric acid
- Enzymes:** Streptokinase, papain, trypsin
- Detergents:** Sodium lauryl sulphate.

#### Normal Saline (Fig. 14.68)

Normal saline causes gross debridement and lubrication of root canals. Since it is very mild in action, it can be used as an adjunct to chemical irrigant.

#### Advantage

It is biocompatible in nature. No adverse reaction even if extruded periapically because osmotic pressure of normal saline is same as that of the blood.

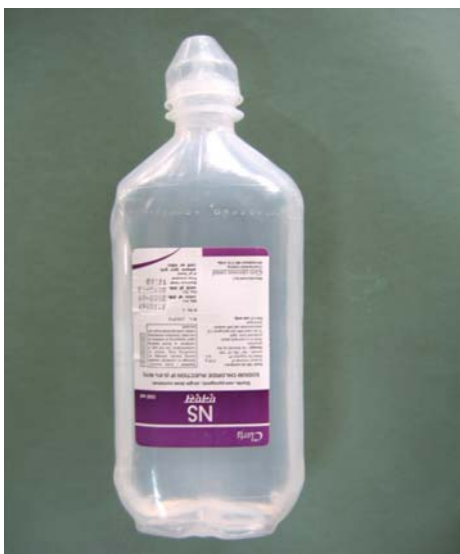

Fig. 14.68: Normal saline

#### Disadvantages

- Does not possess dissolution and disinfecting properties.
- Too mild to thoroughly clean the canals.
- Cannot clear microbial flora from inaccessible areas like accessory canal.
- Does not possess antimicrobial activity.
- Does not remove smear layer.

#### Sodium Hypochlorite

Sodium hypochlorite is a clear, pale, green-yellow liquid with strong odor of chlorine (Fig. 14.69). It is easily miscible with water and gets decomposed by light.

- Introduced in World War I by Dakin.
- Walker-1936—First suggested its use in root canal therapy.
- Grossman-1941—Used it as an intracanal medication.
- Spangberg-1973-0.5%—NaOCl has good germicidal activity.
- Madden-1977—Compared the different concentrations of Sodium hypochlorite.
- Foley et al-1983—Compared effectiveness of 0.5% NaOCl and Glyoxide.

#### Mechanism of Action of Sodium Hypochlorite

- At body temperature, reactive chlorine in aqueous solution exists in two forms—hypochlorite ( $OCl^-$ ) and hypochlorous acid ( $HOCl$ ). State of available chlorine depends on pH of solution, i.e. above pH of 7.6, it is mainly hypochlorite form and below this pH, it is hypochlorous acid.

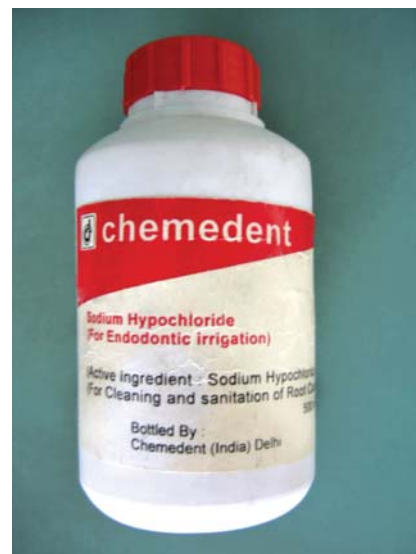


Fig. 14.69: Sodium hypochlorite



- Presence of 5% of free chlorine in sodium hypochlorite is responsible for breakdown of proteins into amino groups.
- The pH of commonly used sodium hypochlorite is 12, at which the OCl form exists. Hypochlorite dissolves necrotic tissue because of its high alkaline nature (pH 12).

#### Advantages of Sodium Hypochlorite

1. It causes tissue dissolution.
2. It has antibacterial and bleaching action.
3. It causes lubrication of canals.
4. Economical.
5. Easily available.

#### Disadvantages

1. Because of high surface tension, its ability to wet dentin is less.
2. Irritant to tissues, if extruded periapically, it can result in severe cellular damage.
3. If comes in contact, it cause inflammation of gingiva because of its caustic nature.
4. It can bleach the clothes if spilt.
5. It has bad odor and taste.
6. Vapors of sodium hypochlorite can irritate the eyes.
7. It can be corrosive to instruments.

#### Chelating Agents (Fig. 14.70)

**Chelating agent** is defined as a chemical which combines with a metal to form chelate. EDTA is most commonly used chelating agent. It was introduced in dentistry by Nygaard Ostby for cleaning and shaping of the canals. It contains four acetic acid groups attached to ethylenediamine. EDTA is relatively nontoxic and slightly irritating in weak solutions. The effect of EDTA on dentin depends on the concentration of EDTA solution and length of time it is in contact with dentin.



Fig. 14.70: Chelating agent

#### Functions of EDTA

- Lubrication
- Emulsification
- Holding debris in suspension
- Smear layer removal.

#### Mechanism of Action

- It inhibits growth of bacteria and ultimately destroys them by starvation because EDTA chelates with the metallic ions in medium which are needed for growth of microorganisms.
- EDTA has self limiting action. It forms a stable bond with calcium and dissolve dentin, but when all chelating ions have reacted, an equilibrium reached which prevents further dissolution.

#### Uses of EDTA

- It has dentin dissolving properties
- It helps in enlarging narrow canals
- Makes easier manipulation of instruments
- Reduces time needed for debridement.

#### BIOMECHANICAL PREPARATION

Cleaning and shaping is one of the most important step in the root canal therapy for obtaining success in the root canal treatment.

#### Cleaning

It comprises the removal of all potentially pathogenic contents from the root canal system.

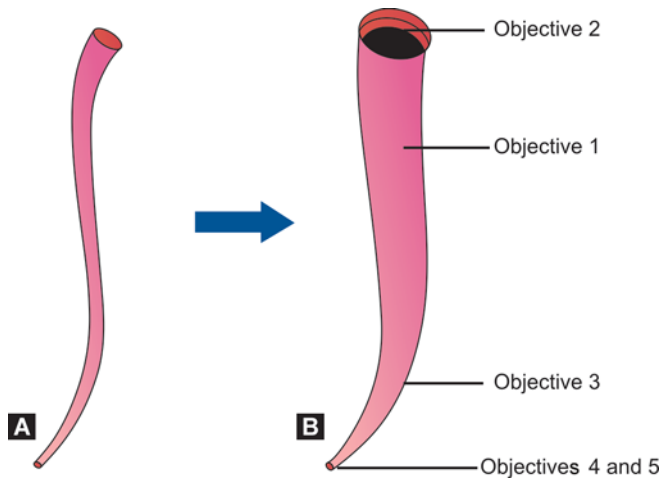
#### Shaping

The establishment of a specifically shaped cavity which performs the dual role of three-dimensional progressive access into the canal and creating an apical preparation which will permit the final obturation instruments and materials to fit easily.

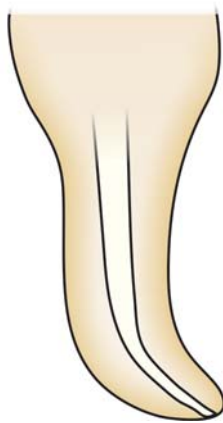
The mechanics of cleaning and shaping may be viewed as an extension of the principles of coronal cavity preparation to the full length of the root canal system. **Schilder** gave five mechanical objectives for successful cleaning and shaping 30 years ago. The objectives taught the clinicians to think and operate in three dimensions.

The objectives given by **Schilder** are (Fig. 14.71):

1. **The root canal preparation should develop a continuously tapering cone (Fig. 14.72):** This shape mimics the natural canal shape. Funnel shaped preparation of canal should merge with the access cavity so



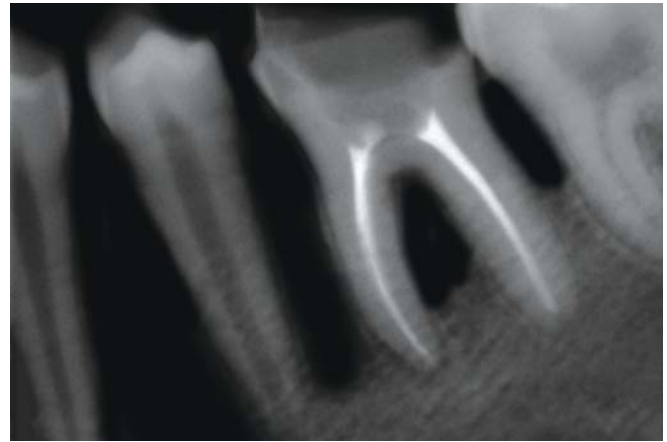
**Fig. 14.71:** Diagrammatic representation of objectives of canal preparation



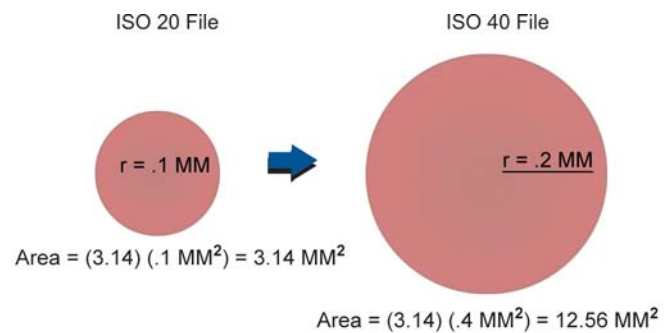
**Fig. 14.72:** Prepared root canal shape should be continuous tapered

that instruments will slide into the canal. Thus, access cavity and root canal preparation should form a continuous channel.

2. **Making the preparation in multiple planes which introduces the concept of “flow”:** This objective preserves the natural curve of the canal.
3. **Making the canal narrower apically and widest coronally:** To create a continuous tapers up to apical third which creates the resistance form to hold gutta-percha in the canal (Fig. 14.73).
4. **Avoid transportation of the foramen:** There should be gentle and minute enlargement of the foramen while maintaining its position.
5. **Keep the apical opening as small as possible:** The foramen size should be kept as small as possible as



**Fig. 14.73:** Radiograph showing obturated first molar



**Fig. 14.74:** Doubling the file size apically, increases the surface area of foramen four times

overlapping of foramen contributes to number of iatrogenic problems. Doubling the file size apically increases the surface area of foramen four folds ( $\pi r^2$ ) (Fig. 14.74). This overlapping of apical foramen should be avoided.

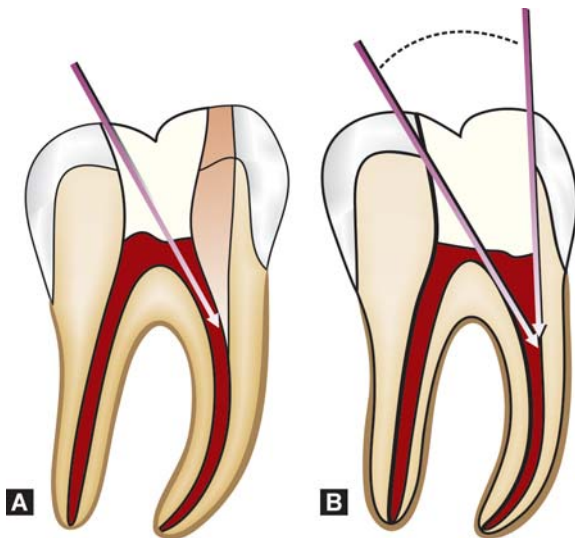
## Objectives of Biomechanical Preparation

### Biologic Objectives of Root Canal Preparation

Biologic objectives of biomechanical preparation are to remove the pulp tissue, bacteria and their byproducts from the root canal space.

### Clinical Objectives of Biomechanical Preparation

Before performing cleaning and shaping, the straight line access to canal orifice should be obtained. All the overlying dentin should be removed and there should be flared and smooth internal walls to provide straight line access to root canals (Fig. 14.75). Since shaping facilitates cleaning, in properly shaped canals, instruments and irrigants can go

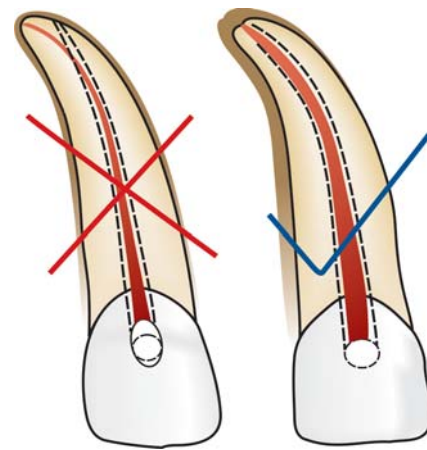


**Fig. 14.75:** Removal of overlying dentin causes smooth internal walls and provide straight line access to root canals

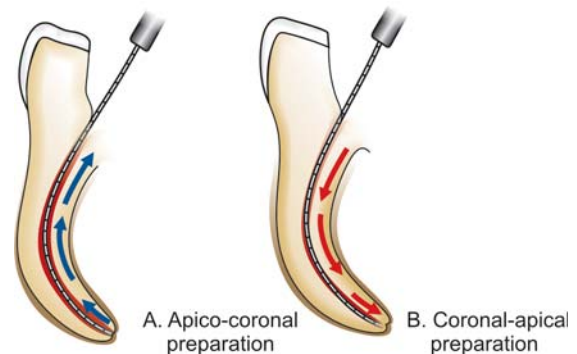
deeper into the canals to remove all the debris and contents of root canal. This creates a smooth tapered opening to the apical terminus for obtaining three-dimension obturation of the root canal system.

### Basic Principles of Canal Instrumentation

- There should be a straight line access to the canal orifices. Creation of a straight line access by removing overhang dentin influences the forces exerted by a file in apical third of the canal.
- Files are always worked with in a canal filled with irrigant. Therefore, copious irrigation is done in between the instrumentation, i.e. canal must always be prepared in wet environment.
- Preparation of canal should be completed while retaining its original form and the shape (Fig. 14.76).
- Canal enlargement should be done by using instruments in the sequential order without skipping sizes.
- All the working instruments should be kept in confines of the root canal to avoid any procedural accidents.
- Recapitulation is regularly done to loosen debris by returning to working length. The canal walls should not be enlarged during recapitulation.
- Over preparation and too aggressive over enlargement of the curved canals should be avoided.
- Never force the instrument in the canal. Forcing or continuing to rotate an instrument may break the instrument.



**Fig. 14.76:** Prepared canal should retain its original form and shape



**Fig. 14.77:** Techniques of biomechanical preparation

### TECHNIQUES OF ROOT CANAL PREPARATION

Basically, there are *two approaches* used for **biomechanical preparation**, either starting at the apex with fine instruments and working up to the orifice with progressively larger instruments, this is **Step back technique** or starting at the orifice with larger instrument and working up to apex with larger instruments, this is **Crown down technique** (Fig. 14.77).

#### Step Back Technique

Step back technique is also known as **Telescopic canal preparation** or **serial root canal preparation**. Step back technique emphasizes keeping the apical preparation small, in its original position and producing a gradual taper coronally (Fig. 14.78). This technique was first described in 1960 by Mullaney.

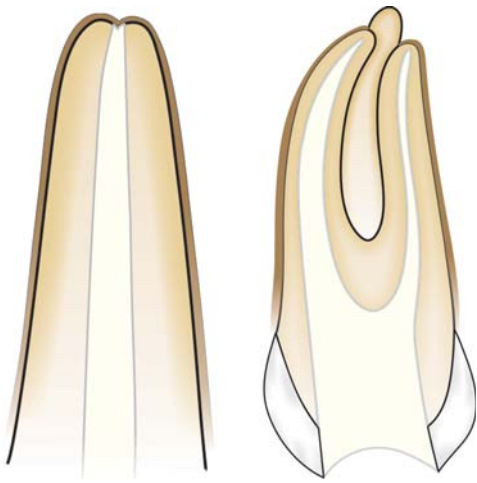


Fig. 14.78: Tapered canal preparation

Basically this technique involves the canal preparation into *two phases*; *phase I* involves the preparation of apical constriction and *phase II* involves the preparation of the remaining canal.

#### Phase I

1. Evaluate the carious tooth before initiating endodontic treatment (Fig. 14.79).
2. Initially prepare the access cavity, and locate the canal orifices (Fig. 14.80).
3. Establish the working length of the tooth using pathfinder.
4. Now insert the first instrument into the canal with watch winding motion. In watch winding motion, a gentle clockwise and anticlockwise rotation of file with minimal apical pressure is given (Fig. 14.81).
5. Remove the instrument and irrigate the canal.
6. Don't forget to lubricate the instrument for use in apical area because it is shown that lubricant emulsifies the fibrous pulp tissue allowing the instrument to remove it whereas irrigants may not reach the apical area to dissolve the tissues.
7. Place the next larger size files to the working length in similar manner and again irrigate the canal (Fig. 14.82).
8. Don't forget to recapitulate the canal with previous smaller number instrument. This breaks up apical debris which are washed away with the irrigant.
9. Repeat the process until a size 25 K-file reaches the working length (Fig. 14.83). Recapitulate between the files by placing a small file to the working length (Fig. 14.84).

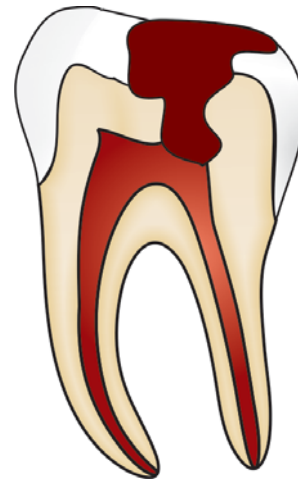


Fig. 14.79: Tooth decay causing pulp exposure

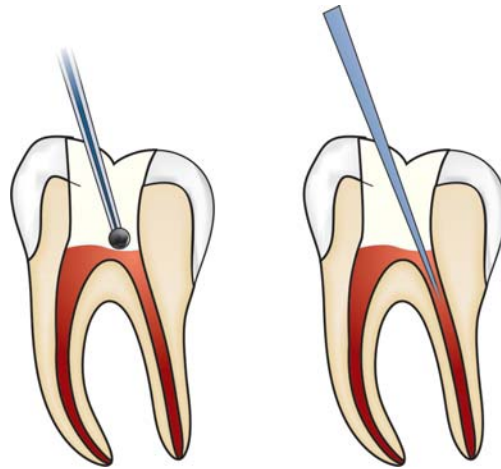


Fig. 14.80: Prepare the access cavity and locate the canal orifices

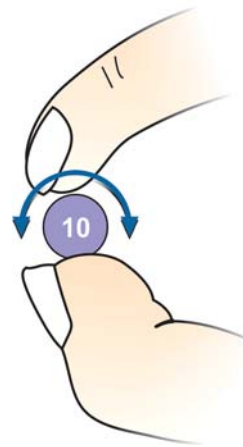
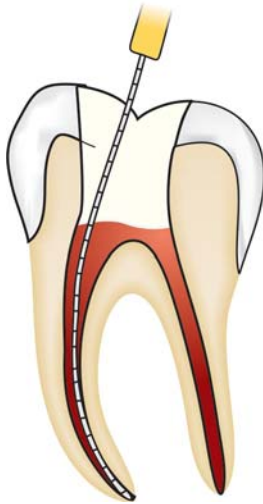
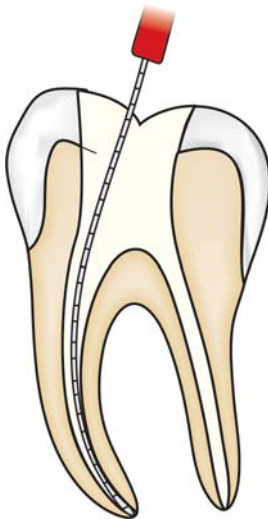


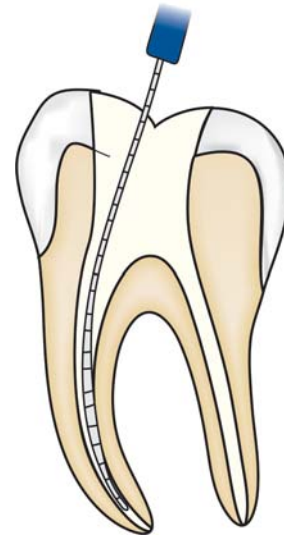
Fig. 14.81: Watch winding motion with gentle clockwise and anticlockwise motion of the file



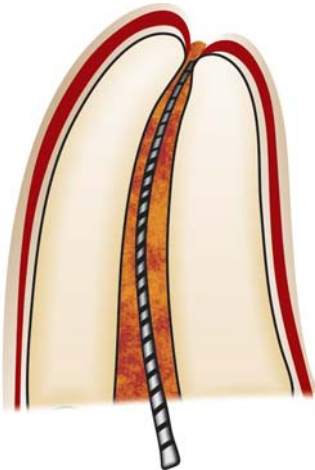**Fig. 14.82:** Place file to working length



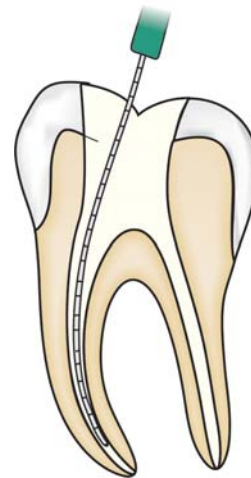
**Fig. 14.83:** 25 No. file at working length



**Fig. 14.85:** 30 No. file 1 mm short of working length



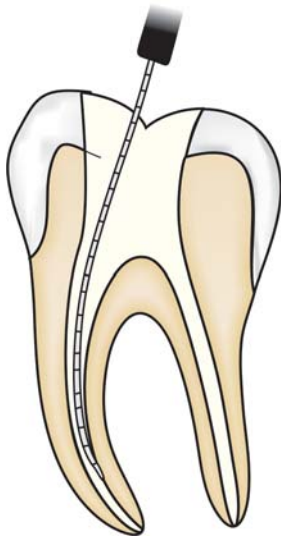
**Fig. 14.84:** Recapitulation using smaller file



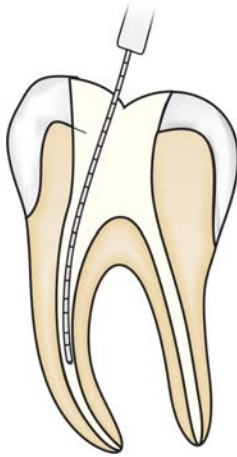
**Fig. 14.86:** 35 No. file 2 mm short of working length

### Phase II

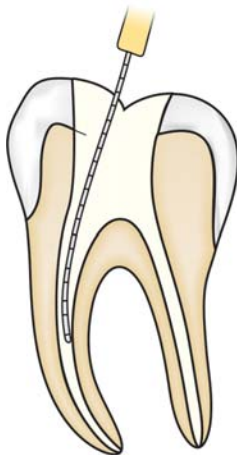
1. Place next file in the series to a length 1 mm short of working length. Insert the instrument into the canal with watch winding motion, remove it after circumferential filing, irrigate and recapitulate (Fig. 14.85).
2. Repeat the same procedure with successively larger files at 1 mm increments from the previously used file (Fig. 14.86).
3. Similarly mid canal area and coronal part of the canal is prepared and shaped with larger number files (Figs 14.87 and 14.88).
4. Finally, refining of the root canal is done by master apical file with push-pull strokes to achieve a smooth taper form of the root canal (Fig. 14.89).



**Fig. 14.87:** 40 No. file 3 mm short of working length



**Fig. 14.88:** 45 No. file 4 mm short of working length



**Fig. 14.89:** 50 No. file for canal preparation

### *Advantage of Step Back Technique*

More flare at coronal part of root canal with proper apical stop.

### *Disadvantages of Step Back Technique*

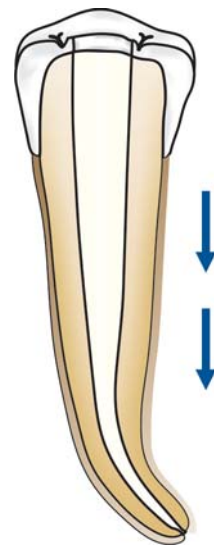
1. Difficult to irrigate apical region.
2. More chances of pushing debris periapically.
3. Time consuming.
4. Increased chances of iatrogenic errors for example ledge formation in curved canals.
5. Difficult to penetrate instruments in canal.
6. More chances of instrument fracture.

### **Crown Down Technique**

In the crown down technique, the dentist prepares the canal from crown of the tooth, does shaping of the canal while moving towards apical portion of the canal (Fig. 14.90).

### *Techniques of Crown Down Preparation*

1. First step in the crown down technique is the access cavity preparation with no pulp chamber obstructions. Locate the canal orifices with sharp explorer which shows binding in the pulp chamber.
2. Now fill the access cavity with an irrigant and start preflaring of the canal orifices. Preflaring of the coronal third of the canal can be done by using hand instruments, Gates-Glidden drills or the Nickle titanium rotary instruments.



**Fig. 14.90:** Crown down technique

- Gates-Glidden drills can be used after scouting the canal orifices with number 10 or 15 files. The crown down approach begins with larger Gates-Glidden first (Fig. 14.91). After using this subsequent, smaller diameter Gates-Glidden are worked into the canal with additional mm to complete coronal flaring.
- Frequent irrigation with sodium hypochlorite and recapitulation with a smaller file (usually No. 10 file) to prevent canal blockage.
- After establishing coronal and mid root enlargement explore the canal and establish the working length with small instruments (Fig. 14.92).
- Introduce larger files to coronal part of the canal and prepare it (Fig. 14.93). Subsequently introduce

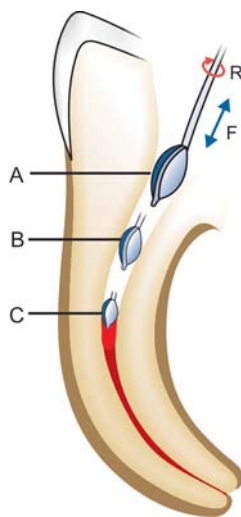
progressively smaller number files deeper into the canal in sequential order and prepare the apical part of the canal (Figs 14.94 and 14.95).

- Final apical preparation is prepared and finished along with frequent irrigation of the canal system.

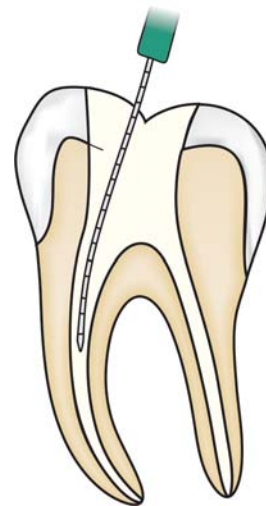
The classical apical third preparation should have a tapered shape which has been enlarged to at least size 20 at apex and each successive instrument should move away from the foramen by 1/2 mm increments.

#### *Biological Benefits of Crown Down Technique*

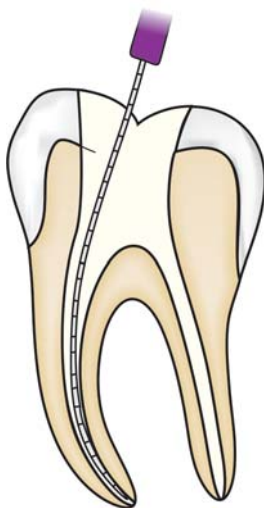
- Removal of tissue debris coronally, thus minimizing the extrusion of debris periapically.



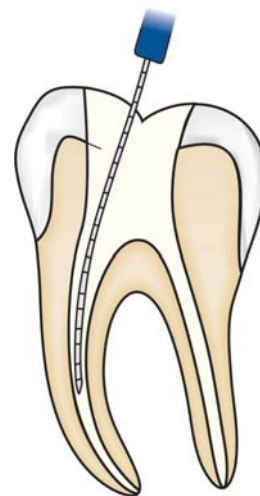
**Fig. 14.91:** Use of Gates-Glidden for preflaring



**Fig. 14.93:** Use of larger files to prepare coronal third



**Fig. 14.92:** Establishing working length using a small instrument



**Fig. 14.94:** Preparation of canal at middle third

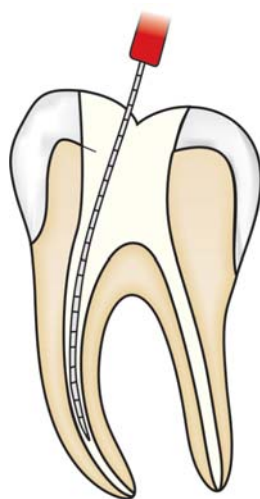


Fig. 14.95: Apical preparation of canal

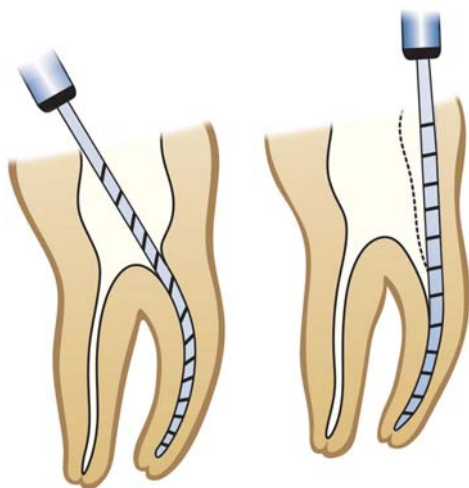


Fig. 14.96: Preflaring of canal causes removal of coronal interferences

2. Reduction of postoperative sensitivity which could result from periapical extrusion of debris.
3. Greater volumes of irrigants can reach in canal irregularities in early stages of canal preparation because of coronal flaring.
4. Better dissolution of tissue with increased penetration of the irrigants.
5. Rapid removal of contaminated and infected tissues from the root canal system.

#### Clinical Advantages of the Crown Down Technique

1. Enhanced tactile sensation with instruments because of removal of coronal interferences (Fig. 14.96).

2. Flexible (smaller) files are used in apical portion of the canal; whereas larger (stiffer) files need not be forced but kept short of the apex.
3. In curved canals, after doing coronal flaring, files can go up to apex more effectively due to decrease deviation of instruments in the canal curvature.
4. Provides more space of irrigants.
5. Straight line access to root curves and canal junctions.
6. Enhanced movement of debris coronally.
7. Desired shape of canal can be obtained that is narrow at apex, wider at coronal.
8. Predictable quality of canal cleaning and shaping.
9. Decreased frequency of canal blockages.

#### Step back vs crown down technique

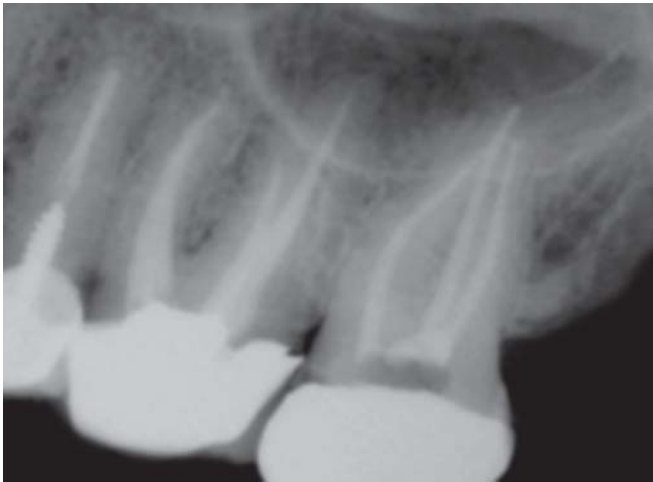Step back technique	Crown down technique
1. Apico-coronal technique	1. Coronoapical technique
2. Has been used for past many year	2. Introduced recently an gaining popularity
3. Starts with smallest instruments	3. Starts with largest instruments
4. Shapes apical 1/3rd initially	4. Shapes coronal 1/3rd initially
5. Commonly uses hand files	5. Commonly uses rotary files

## OBTURATION OF ROOT CANAL SYSTEM

### Purpose of Obturation

1. To achieve total obliteration of the root canal space so as to prevent ingress of bacterias and body fluids into root canal space as well as egress of bacterias which are left in canal.
  2. To attain fluid tight seal so as to prevent bacterial microleakage.
  3. To replace the empty root canal space with an inert filling material so as to prevent recurrent infection.
  4. To seal the root canal space as well as to have coronal seal for long-term success of root canal therapy.
- A three-dimensional well fitted root canal with fluid tight seal is the **main objective of the root canal obturation (Fig. 14.97)**. This helps in:
- a. Preventing percolation and microleakage of periapical exudate into the root canal space.
  - b. Preventing infection by completely obliterating the apical foramen and other portals of communication.
  - c. Creating a favorable environment for process of healing to take place.





**Fig. 14.97:** Radiograph showing three-dimensional obturation



**Fig. 14.98:** Sterilization of gutta-percha by immersing them in 5.25% sodium hypochlorite for one minute

### Materials Used for Obturation

- *Plastics:* Gutta-percha, resilon
- *Solids or metal cores:* Silver points, Gold, stainless steel, titanium and irridio-platinum.
- *Cements and pastes*
  - MTA
  - Calcium phosphate
  - Gutta flow

### Gutta-percha

***Gutta-percha is derived from two words.***

“GETAH” - meaning gum

“PERTJA” - name of the tree

Gutta-percha is a dried coagulated extract which is derived from Brazillian trees (Palaquium). Its molecular structure is close to natural rubber, which is also a cis-isomer of polyisoprene.

*Composition of Commercially Available Gutta-percha (Given by Friedman et al)*

- Organic content – Gutta-percha + Waxes = 23%
- Inorganic content – ZnO + Metal sulfates = 77%

*Different forms of Gutta-percha*

*Alpha Form*

- Pliable and tacky at 56°-64° available in form of bars or pellets.
- Available in form of bars or pellets.
- Used in thermoplasticized obturation technique.

*Beta Form*

- Rigid and solid 42°-44°.
- Used for manufacturing gutta-percha points and sticks.

*Amorphous Form*

- Exists in molten stage.
- Gutta-percha cannot be heat sterilized. For disinfection of gutta-percha points, they should be immersed in 5.25% NaOCl for one minute (Fig. 14.98). Then, gutta-percha should be rinsed in hydrogen peroxide or ethyl alcohol. The aim of rinsing is to remove crystallized NaOCl before obturation, as these crystallized particles impair the obturation.
- Gutta-percha should always be used with sealer and cement to seal root canal space as gutta-percha lacks adhering qualities.
- Gutta-percha is soluble in certain solvents like chloroform, eucalyptus oil, etc. This property can be used to plasticize gutta-percha by treating it with the solvent for better filling in the canal. But it has shown that gutta-percha shrinks (1-2%) when solidifies.
- Gutta-percha also shows some tissue irritation which is due to high content of zinc oxide.

*Current Available Forms of Gutta-percha*

1. *Gutta-percha points (Fig. 14.99):* Standard cones are of same size and shape as that of ISO endodontic instruments.
2. *Auxiliary points:* Non-standardized cones; perceive form of root canal (Fig. 14.100).
3. *Greater taper gutta-percha points:* Available in 4%, 6%, 80% and 10% taper (Fig. 14.101).



Fig. 14.99: Gutta-percha cones

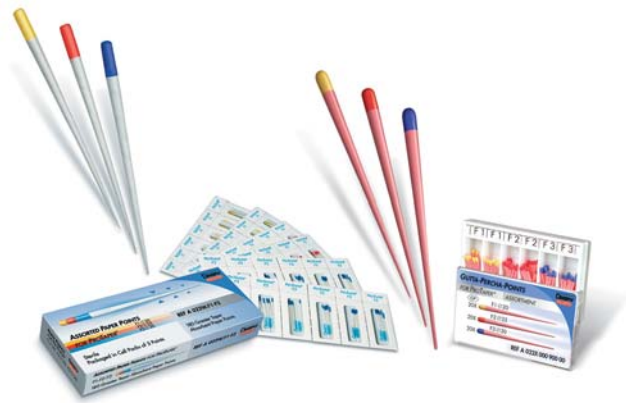

Fig. 14.101: Greater taper points



Fig. 14.100: Auxiliary points



Fig. 14.102: Thermafil gutta-percha

4. *Gutta-percha pellets/bars*: They are used in thermo-plasticized gutta-percha obturation, e.g. obtura system.
5. *Precoated core carrier gutta-percha*: In these stainless steel, titanium or plastic carriers are precoated with alpha phase gutta-percha for use in canal, e.g. thermafil (Fig. 14.102).
6. *Syringe systems*: They use low viscosity gutta-percha, e.g. successful and alpha seal.

#### Advantages of Gutta-percha

- **Compactibility**: adaptation to canal walls
- **Inertness**: makes it non-reactive material
- **Dimensionally stable**
- **Tissue tolerance**
- **Radiopacity**: easily recognizable on radiograph
- **Plasticity**: becomes plastic when heated
- **Dissolve in some solvents** like chloroform, eucalyptus oil, etc. This property makes it *more versatile as canal filling material*.

#### Disadvantages

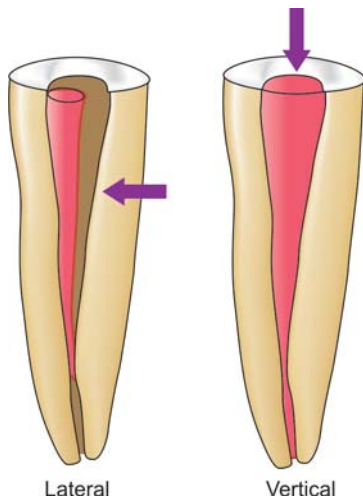
- **Lack of rigidity**: Bending of gutta-percha is seen when lateral pressure is applied. So, difficult to use in smaller canals.
- Easily displaced by pressure.
- Lacks adhesive quality.

#### Root Canal Sealers

The sealer performs several functions during the obturation of a root canal system with gutta-percha; it lubricates and aids the seating of the master gutta-percha cone, acts as a binding agent between the gutta-percha and the canal wall and fills anatomical spaces where the primary filling material fails to reach. Root canal sealers, although used only as adjunctive materials in the obturation of root canal systems, have been shown to influence the outcome of root canal treatment.

#### Obturation Techniques (Fig. 14.103)

Various root canal obturation techniques have been portrayed in the literature, each technique having its indications, contraindications, advantages and disadvantages. Generally speaking the root canal obturation with gutta-percha as filling material, can be mainly divided in to following groups:



**Fig. 14.103:** Lateral and vertical compaction of gutta-percha

1. Use of cold gutta-percha
  - Lateral compaction technique
2. Use of chemically softened gutta-percha
  - Chloroform
  - Halothane
  - Eucalyptol
3. Use of heat softened gutta-percha
  - Vertical compaction technique
  - System B continuous wave condensation technique
  - Lateral/vertical compaction
  - Sectional compaction technique
  - McSpadden compaction of gutta-percha
  - Thermoplasticized gutta-percha technique including
    - Obtura II
    - Ultrasonic plasticizing
    - Ultrafil system
  - Solid core obturation technique including
    - Thermafil system
    - Silver point obturation

### Armamentarium for Obturation (Fig. 14.104)

- Primary and accessory gutta-percha points.
- Spreaders and pluggers for compaction of gutta-percha.
- Absorbent paper points for drying the prepared root canal before applying sealer.
- Lentulospirals for placing sealer.
- Scissors for cutting gutta-percha.
- Endo gauge for measuring size of gutta-percha.

- Endo block for measuring gutta-percha points.
- Endo organizer for arranging gutta-percha and accessory points of various sizes.
- Heating device like spirit lamp or butane gas torch.
- Heating instrument like ball burnisher, spoon excavator, etc.

### Lateral Compaction Technique

It is one of the most common methods used for root canal obturation. It involves placement of tapered gutta-percha cones in the canal and then compacting them under pressure against the canal walls using a spreader. A canal should have continuous tapered shape with a definite apical stop, before it is ready to be filled by this method.

### Technique

1. Following the canal preparation, select the master gutta-percha cone whose diameter is consistent with largest file used in the canal up to the working length. One should feel the tugback with master gutta-percha point (Fig. 14.105). Master gutta-percha point is notched at the working distance analogous to the level of incisal or occlusal edge reference point (Fig. 14.106).
2. Check the fit of cone radiographically.
  - If found satisfactory, remove the cone from the canal and place it in sodium hypochlorite.
  - If cone fits short of the working length, check for dentin chip debris, any ledge or curve in the canal and treat them accordingly.
  - If cone selected is going beyond the foramen, either select the larger number cone or cut that cone to the working length (Fig. 14.107).
3. Select the size of spreader to be used for lateral compaction of that tooth. It should reach 1-2 mm of true working length (Fig. 14.108).
4. Dry the canal with paper points.
5. Apply sealer in the prepared root canal (Fig. 14.109).
6. Now premeasured cone is coated with sealer and placed into the canal. After master cone placement, spreader is placed into the canal alongside the cone (Fig. 14.110). Spreader helps in compaction of gutta-percha. It act as a wedge to squeeze the gutta-percha laterally under vertical pressure not by pushing it sideways (Fig. 14.111). It should reach 1-2 mm of the prepared root length.
7. After placement, spreader is removed from the canal by rotating it back and forth. This compacts the gutta-percha and a space gets created lateral to the master cone (Fig. 14.112).



Fig. 14.104: Armamentarium for obturation

8. An accessory cone is placed in this space and the above procedure is repeated until the spreader can no longer penetrate beyond the cervical line (Fig. 14.113).
9. Now sever the protruding gutta-percha points at canal orifice with hot instrument (Fig. 14.114).

#### Advantages of Lateral Compaction Technique

1. Can be used in most clinical situations.
2. During compaction of gutta-percha, it provides length control, thus decreases the chances of overfilling.

#### Disadvantages

1. May not fill the canal irregularities efficiently.
2. Does not produce homogeneous mass.
3. Space may exist between accessory and master cones.

#### Vertical Compaction Technique

Vertical compaction of warm gutta-percha method of filling the root canal was introduced by Schilder with an objective of filling all the portals of exit with maximum amount of gutta-percha and minimum amount of sealer. This is also

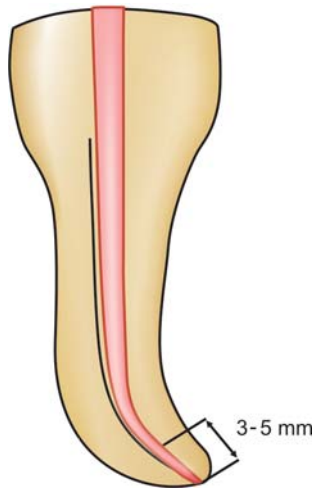


Fig. 14.105: Tugback with master gutta-percha cone

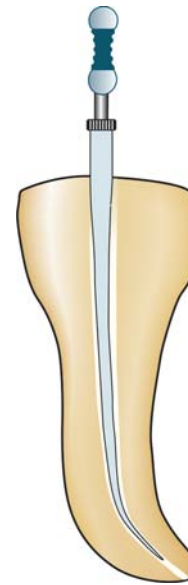

Fig. 14.108: Spreader should match the taper of canal

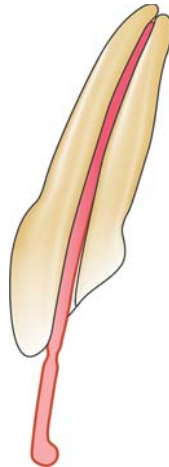


Fig. 14.106: Notching of gutta-percha at the level of reference point

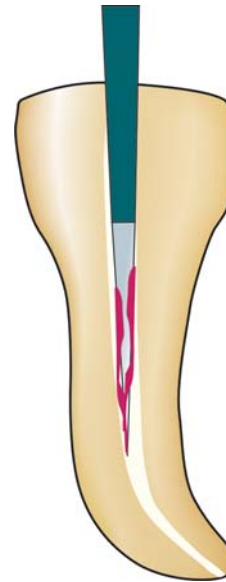


Fig. 14.109: Apply sealer in the prepared canal

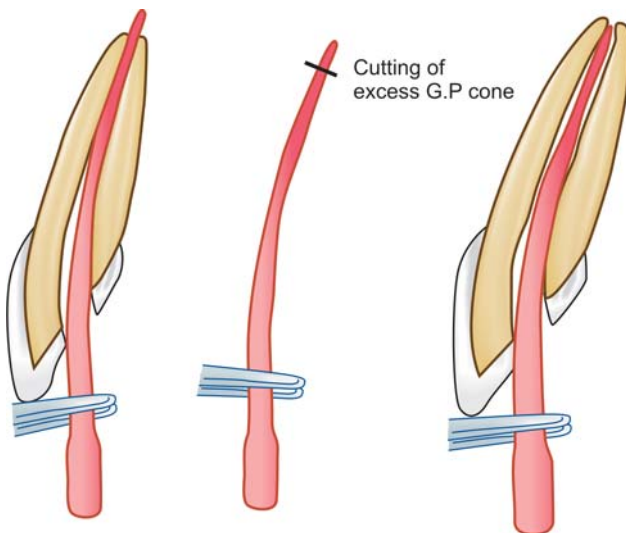
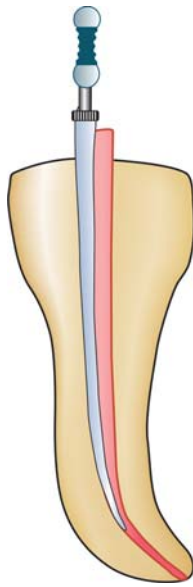


Fig. 14.107: If cone is going beyond apical foramen, cut the cone to working length or use larger number cone

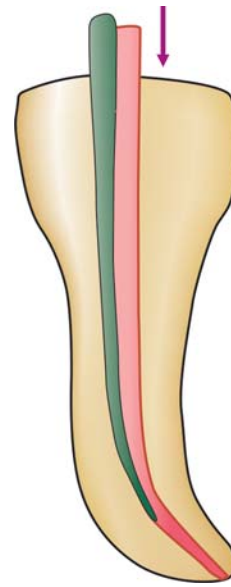
known as **Schilder's technique of obturation**. In this technique using heated pluggers, pressure is applied in vertical direction to heat softened gutta-percha which causes it to flow and fill the canal space (Fig. 14.115).

**Basic requirements of a prepared canal to be filled by this technique are:**

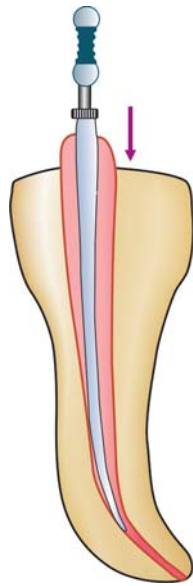
- a. Continuous tapering funnel shape from orifice to apex.
- b. Apical opening kept as small as possible.



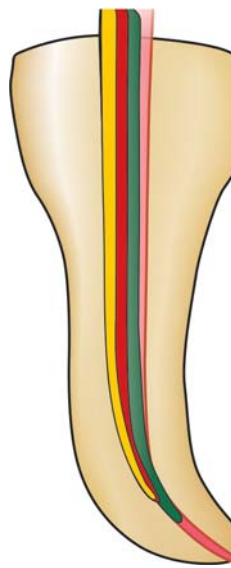
**Fig. 14.110:** Placing spreader along gutta-percha cone



**Fig. 14.112:** Placing accessory cone along master cone



**Fig. 14.111:** Compaction of gutta-percha using spreader

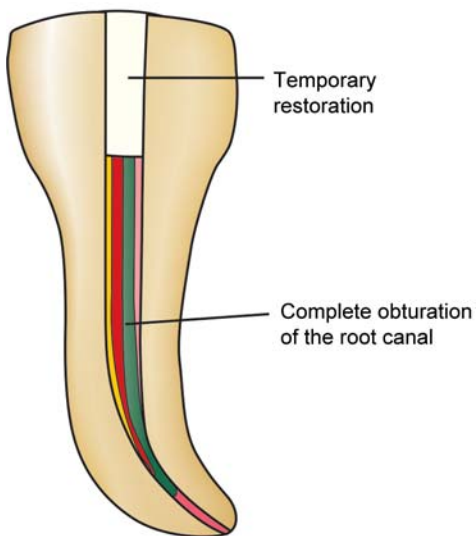


**Fig. 14.113:** Use of more accessory cones to complete obturation of the canal

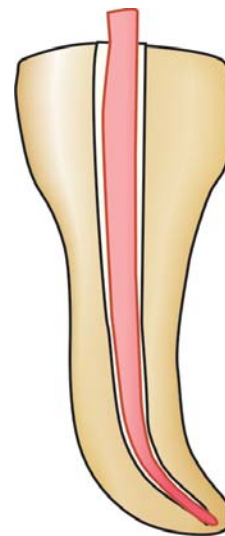
- c. Decreasing the cross-sectional diameter at every point apically and increasing at each point as canal is approached coronally.

#### Technique

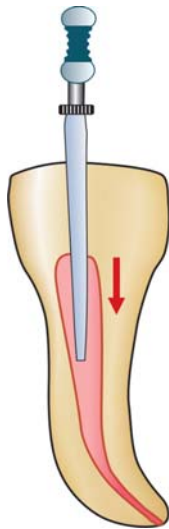
- Select a master cone according to shape and size of the prepared canal. Cone should fit in 1-2 mm of apical stop because when softened material moves apically into prepared canal, it adapts more intimately to the canal walls (Fig. 14.116).
- Confirm the fit of cone radiographically, if found satisfactory, remove it from the canal and place in sodium hypochlorite.
- Irrigate the canal and then dry by rinsing it with alcohol and latter using the paper points.
- Select the heat transferring instrument and pluggers according to canal shape and size.



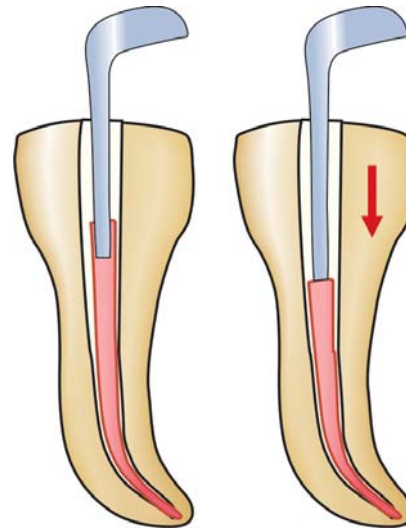
**Fig. 14.114:** Cut the protruding gutta-percha points at orifice with hot instrument and place temporary restoration over it



**Fig. 14.116:** Select the master gutta-percha cone

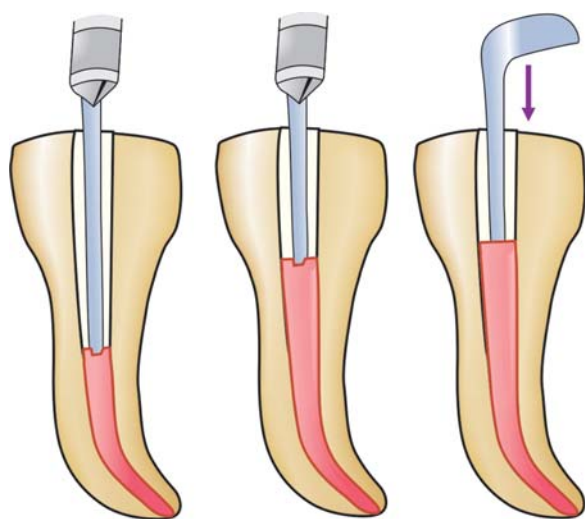


**Fig. 14.115:** Vertical compaction of gutta-percha using plugger



**Fig. 14.117:** Heated plugger used to compact gutta-percha

- Lightly coat the canal with sealer.
- Cut the coronal end of selected gutta-percha at incisal or occlusal reference point.
- Now use the heated plugger to force the gutta-percha into the canal. The blunted end of plugger creates a deep depression in the center of master cone (Fig. 14.117). The outer walls of softened gutta-percha are then folded inward to fill the central void, at the same time mass of softened gutta-percha is moved apically and laterally. This procedure also removes 2-3 mm of coronal part of gutta-percha.
- Once apical filling is done, complete obturation by doing backfilling. Obturate the remaining canal by heating small segments of gutta-percha, carrying them into the canal and then compacting them using heated pluggers as described above (Fig. 14.118).
- Take care not to overheat the gutta-percha because it will become too soft to handle.
- Do not apply sealer on the softened segments of gutta-percha because sealer will prevent their adherence to the body of gutta-percha present in the canal.



**Fig. 14.118:** Back filling of the canal

#### Advantages of vertical compaction technique

- Excellent sealing of canal apically, laterally and obturation of lateral as well as accessory canals.

#### Disadvantages of this technique

- Increased risk of vertical root fracture.
- Overfilling of canals with gutta-percha or sealer from apex.
- Time consuming.
- After completion of obturation, clean the pulp chamber with alcohol to remove remnants of sealer or gutta-percha.

### POST OBTURATION RESTORATION (FIG. 14.119)

#### Importance of Coronal Restoration

Post endodontic coronal restoration is important to prevent ingress of microorganisms into coronal pulp.

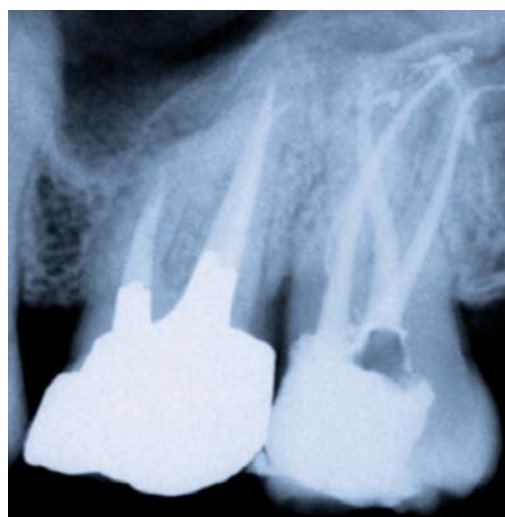
To prevent coronal leakage the clinician should:

1. Temporarily seal the tooth during or after the treatment.
2. Provide adequate coronal restoration after treatment.
3. Do long-term follow-up so as to evaluate the integrity of restoration.

Even a well done endodontic treatment can get infected due to following reasons:

- Poor quality of temporary restoration
- Delay in permanent restoration after completion of endodontic treatment
- Poor marginal integrity of final restoration
- Fractured tooth

So, it is very important to seal the root canal system after or during the endodontic treatment. Commonly used



**Fig. 14.119:** Complete endodontic treatment with root canal obturation and crown placement

materials for temporary restoration of endodontically treated tooth during or after treatment are IRM and Cavit. Studies have shown that most of temporary materials leak to some extent. Though zinc oxide eugenol cements show more leakage, but due to presence of antimicrobial properties, they are more resistant to microbial penetration.

Final restoration of endodontically treated tooth should be done at the earliest so as to long-term success clinician should evaluate the tooth at regular follow-ups because normal leakage can create an impact on success of treatment. One should evaluate signs, symptoms, radiographic changes, defect in coronal restoration like secondary caries, marginal integrity, etc. for better prognosis of treatment.

#### QUESTIONS

- Q. What is endodontics?
- Q. What are objectives of endodontics?
- Q. What is dental pulp?
- Q. What are features of pulp which distinguish it from other tissues?
- Q. How does caries affect pulp?
- Q. Classify endodontic instruments?
- Q. What are guidelines given by Ingle and Levine for standardization of instruments?
- Q. What will be the tip diameter of 40 No. instruments?

**Ans:** 0.40 mm



- Q. What is color coding of endodontic instruments?
- Q. What are types of broaches?
- Q. What are uses of barbed broach?
- Q. What are features of reamers?
- Q. How is reamer worked in the canal?
- Q. What is cross-section of K-file?
- Q. How can you differentiate reamer and file?
- Q. What is K-flex file?
- Q. How is file worked in the canal?
- Q. What is H-file? How does it look like?
- Q. What are advantages and disadvantage of H-file?
- Q. Describe Gates-Glidden drills.
- Q. What are uses of Gates-Gliddens?
- Q. What are advantages and disadvantages of NiTi instruments?
- Q. What is pulp cavity?
- Q. Define minor and major diameters.
- Q. What is significance of apical third of the canal?
- Q. What are guidelines for access cavity preparation?
- Q. How do proceed for access preparation of anterior teeth?
- Q. What is shape of access preparation in premolar?
- Q. What is shape of access preparation for maxillary first molar?
- Q. What is shape of access preparation for mandibular molar?
- Q. How many canals are these in maxillary and mandibular molar? Name them.
- Q. What is working length?
- Q. Define reference point.
- Q. What is significance of working length?
- Q. What are consequences of overextended working length?
- Q. What is radiographic method of working length determination?
- Q. What is irrigation? What are functions of irrigants?
- Q. What are advantages of normal saline?
- Q. What are uses of sodium hypochlorite?
- Q. What is EDTA?
- Q. Define biomechanical preparation?
- Q. What are Schilder's concepts of biomechanical preparation?
- Q. What are different methods of biomechanical preparation?
- Q. What is step back technique?
- Q. What are advantages and disadvantages of step back technique?
- Q. What is crown down technique?
- Q. What is purpose of obturation?
- Q. What are advantages of gutta-percha?
- Q. What are advantages of vertical compaction technique?
- Q. What is lateral compaction technique?
- Q. What is significance of post obturation restoration?

# Glossary

**Abfraction:** Abfractions are the microfractures which appear in the enamel as cervical area of tooth flexes under heavy loads. Abfraction lesion appears as a wedge shaped defect with sharp line angles.

**Abrasion:** It refers to the loss of tooth substance induced by mechanical wear other than that of mastication. Abrasion results in saucer-shaped or wedge-shaped indentations with a smooth, shiny surface.

**Abutment:** A term used to denote the teeth on either side of a missing tooth.

**Access cavity preparation:** It is defined as endodontic coronal preparation which enables unobstructed access to the canal orifices, a straight line access to apical foramen, complete control over instrumentation and to accommodate obturation technique.

**Acid etch technique:** It is the process of increasing the surface reactivity by demineralizing the superficial calcium layer and thus creating the enamel tags. These tags are responsible for micromechanical bonding between tooth and restorative resin.

**Active carious lesion:** A progressive lesion is described as an active carious lesion.

**Active eruption:** The emergence of the tooth from its position in the jaw.

**Acute dental caries:** Acute caries travels towards the pulp at a very fast speed.

**Adhesion:** The sticking together of unlike substances.

**Advanced caries:** Involves the dentinoenamel junction and less than half distance to pulp cavity.

**Aerobic bacteria:** Bacteria which grow in oxygen-rich environments in the oral cavity.

**Agar:** A gelatin-like substance obtained from seaweed used in impression materials.

**Air abrasion/kinetic tooth preparation:** Air abrasion technique involves high energy sandblasting of tooth surface. Basically in an air abrasion technique, the abrasion particles are emitted in a well-defined sharply focused beam to the target.

**Air-rotor contra-angle handpiece:** It gets power from the compressed air supplied by the compressor. This handpiece has high speed and low torque.

**Alginate:** An impression material used by dentists for making stone models.

**Alloy:** Alloy is a union of two or more metals.

**Alveolar bone:** The bony structure of the jaw that supports and anchors the roots of the teeth.

**Alveolar crest:** The alveolar crest refers to the highest point of the alveolar ridge, which extends beyond the tooth socket. The position of the crest moves slightly upwards as the tooth erupts.

**Alveolar eminence:** The alveolar eminence is the outline of the root on the facet section of the alveolar bone.

**Alveolus:** The bony socket in which the root of the tooth sits.

**Amalgam:** Amalgam is an alloy in which mercury occurs as a main constituent.

**Amalgam blues:** It is the discoloration of tooth which is caused by leakage of corrosion products of amalgam restoration.

**Amalgampins:** Amalgampins are vertical posts of amalgam anchored in dentin. They increase the retention and resistance of complete restoration.

**Anaerobic bacteria:** Bacteria that do not need oxygen to grow. They are generally associated with periodontal disease.

**Anatomic crown:** It is part of tooth that is covered with enamel.

**Anatomic tooth root:** It is part of tooth that is covered with cementum.

**Angle:** It is the junction of two or more surfaces of prepared tooth.

**Anodontia:** The developmental absence of teeth.

**Anomaly:** A deviation from the normal or expected outcome.

**Antagonist:** A structure that opposes or counteracts another structure.

**Anterior teeth:** The front teeth; these are made up of the incisors and canines (cuspid teeth).

**Apex:** The apex often refers to the tip or most superior point of a structure; the tip of the root of the tooth is also known as the apex.

**Apical constriction (Minor diameter):** It is apical part of root canal having the narrowest diameter short of the apical foramina or radiographic apex. It may or may not coincide with CDJ.

**Apical delta:** It is a triangular area of root surrounded by main canal, accessory canals and periradicular tissue.

**Apical foramen:** The opening at the end of the root of a tooth through which the tooth receives its nerve and blood supply.

**Apical foramen (Major diameter):** It is main apical opening on the surface of root canal through which blood vessels enter the canal. Its diameter is almost double the apical constriction giving it a funnel shape appearance, which has been described as morning glory or hyperbolic.

**Attrition:** It is defined as a physiological, continuous, process resulting in loss of tooth structure from direct frictional forces between contacting teeth. It occurs both on occlusal and proximal surfaces. Attrition is

accelerated by parafunctional mandibular movements, especially bruxism.

**Axial wall:** It is an internal wall which is parallel to the long axis of the tooth.

**Backpressure porosity:** It usually occurs on the inner surface of the casting due to entrapment of gases. It is caused by use of dense investment material, low casting temperature or improper wax burnout.

**Backward caries:** When spread of caries along dentinoenamel junction exceeds the adjacent caries in enamel, it is called backward caries (here caries extend from DEJ to enamel).

**Bases:** They are applied in an attempt to replace the lost dentin and to provide thermal, physical and therapeutic advantages to the pulp.

**Bevels:** Bevel is defined as the inclination that one surface makes with another when not at right angles.

*Types of bevel:* According to shape and type of tissue involved, bevels can be:

- a. Ultrashort or partial bevel
  - Beveling of less than two-third of the total enamel thickness.
  - Used in type I casting alloys.
- b. Short bevel
  - Beveling of full thickness of enamel wall but not dentin.
- c. Long bevel
  - Includes full thickness of enamel and half or less than half thickness of dentin.
- d. Full bevel
  - Includes full enamel and dentinal wall.
  - Full bevel should be avoided except in cases where it is a must.
- e. Hollow ground (concave) bevel
  - Hollow ground is concave in shape and not a bevel in true sense.
- f. Counter bevel
  - Used when capping of the cusps is done to protect and support them.
- g. **Reverse or inverted bevel in anterior teeth:** It is beveling in the reverse or inverted shape given on the gingival seat in the axial wall toward the root in anterior teeth.

**Bicuspid:** Bicuspid or having two cusps. The first and second bicuspid are the fourth and fifth teeth from the center of the mouth, respectively. These are the back teeth that are used for chewing.

**Blade angle:** It is the angle between the rake face and the clearance face.

**Bonding:** Bonding is the process in which tooth colored materials (composite resin) are adhered (bonded) to the tooth. This is a procedure that can be used to repair or improve the appearance of a tooth that has been badly stained, broken or chipped.

**Bruxism:** Bruxism or the grinding of teeth, usually occurs during sleep and can cause problems such as tooth wear, headaches and jaw joint or TMJ pain.

**Buccal:** Tooth surface facing the cheek.

**Bur blade:** Blade is a projection on the bur head which forms a cutting edge. Blade has two surfaces:

- a. *Blade face/Rake face:* It is the surface of bur blade on the leading edge.
- b. *Clearance face:* It is the surface of bur blade on the trailing edge.

**Burnishing:** It is the process of rubbing amalgam surface with hard and smooth rigid instrument to make the surface shiny.

**Canal orifice:** Canal orifices are openings in the floor of pulp chamber leading into root canals.

**Canines:** Canines, also known as the cuspid teeth, are the small, pointed teeth located between the incisors and the premolars. Traditionally, canine teeth are associated with ripping and tearing food. Adults usually have four canines; two on the top and two on the bottom; they are located either side of the incisors. Canine teeth have a single root.

**Caries:** Dental caries is an infectious microbiological disease of the teeth which results in localized dissolution and destruction of the calcified tissue, caused by the action of microorganisms and fermentable carbohydrates.

Based on anatomy of the surface involved dental caries can be of following types:

- Pit and fissures carious lesions
- Smooth surface carious lesions
- Root caries.

**Carving:** It is done to produce functional anatomy of the restoration. A properly carved restoration should have adequate marginal ridges, proper contours, optimal occlusal anatomy, adequate embrasures and no over and under hangs.

**Cavosurface angle margin/tooth preparation margin:** Cavosurface angle is formed by the junction of a prepared tooth surface wall and external surface of the tooth.

**Cementodentinal junction:** Cementodentinal junction is the point in the canal, where cementum meets dentin.

**Central fossae:** Occur on occlusal surface of molars.

**Cervical:** Tooth surface near the cervix or neck of tooth.

**Cervix:** The tooth cervix refers to the point where the crown connects to the root, or roots, in the tooth; it is also known as the cemento enamel junction. This junction is where the enamel meets the cementum that covers the root of the tooth.

**Chelating agent:** It is defined as a chemical which combines with a metal to form chelate. EDTA is most commonly used chelating agent.

**Chronic dental caries:** Chronic caries travel very slowly towards the pulp. They appear dark in color and hard in consistency.

**Cingulum:** Cingulum is the raised area of the front teeth (the incisors or canine teeth), which is located near to the lingual lobe (the surface of the tongue).

**Circumferential tie:** Circumferential tie refers to the design of cavosurface margin of an inlay tooth preparation. This junction between tooth cement inlay is the weakest part of the cast metal restoration.

**Class II inlay:** Class II inlay essentially involves proximal surface or surfaces of a posterior tooth, usually may involve occlusal surface and also may involve facial and/or lingual surface(s) and covers none or may cover all but one cusp of a tooth.

**Class II onlay:** Class II onlay is a modification of the inlay and involves the proximal surface or surfaces, and may involve facial and/or lingual surface/s of a posterior tooth and covers all the cusps.

**Clearance angle:** This is the angle between the clearance face and the work.

**Clinical crown:** It is part of tooth that is visible in oral cavity. In case of gingival recession, clinical crown is longer than anatomical crown.

**Complex caries:** If more than two surfaces are involved, it is called as complex caries.

**Complex tooth preparation:** A tooth preparation involving more than two surfaces is called as complex tooth preparation.

**Compomers (Polyacid modified composite resins):** Compomers are class of dental materials that provide combined advantages of composites (term “Comp” in their name) and glass ionomer (“Omers” in their name).

**Composite:** A composite is a compound composed of at least two different materials with properties which are superior or intermediate to those of an individual component.

Dental composite resins have two primary components which are matrix phase and the filler phase and many secondary components like polymerization initiators, pigments for providing different shades and silane coupling agents.

**Compound caries:** If two surfaces are involved it is termed as compound caries.

**Compound tooth preparation:** A tooth preparation involving two surfaces is termed compound tooth preparation.

**Concentricity:** It is a direct measurement of symmetry of the bur head. In other words, concentricity measures whether blades are of equal length or not. It is done when the bur is static.

**Condensable (Packable) composites:** The principle of the high viscosity of packable composites is that they can be pushed into the posterior tooth preparation and has greater control over the proximal contour of class II preparations. Their basis is polymer rigid inorganic matrix material (PRIMM). In this components are resin and ceramic inorganic fillers which are incorporated in silanated network of ceramic fibers.

**Condensation:** It is process of compacting amalgam mix into the prepared tooth surface. Various shapes (triangular, round, elliptical, trapezoidal and rectangular) and sizes of condensers are used for amalgam condensation.

**Conditioning:** It is the process of cleaning the surface and activating the calcium ions, so as to make them more reactive.

**Configuration or “C-factor”:** The cavity configuration or C-factor was introduced by Prof Carol Davidson and his colleagues in 1980s. The configuration factor (C-factor) is the ratio of bonded surface of the restoration to the unbonded surfaces. The higher the value of “C”-factor, the greater is the polymerization shrinkage.

**Contact angle:** Contact angle refers to the angle formed between the surface of a liquid drop and its adherent surface. The stronger the attraction of the adhesive for the adherent, the smaller will be the contact angle. The zero contact angle is the best to obtain wetting.

**Contour:** A prominent contour present on the crowns of teeth (on mesial, distal, buccal and lingual surfaces) is of essential importance as it protects the gingival tissue against bruising and trauma from food.

**Contra-angle handpiece:** In this, head of handpiece is first angled away from and then back towards the long axis of the handle. Because of this design, bur head lies close to long axis of the handle of handpiece which improve accessibility, visibility and stability of handpiece while working.

**Convenience form:** The convenience form is that form which facilitates and provides adequate visibility, accessibility and ease of operation during preparation and restoration of the tooth.

**Coupling agent:** A coupling agent is used to bond the filler to the organic resin. This agent is a molecule with silane groups at one end (ion bond to SiO<sub>2</sub>) and methacrylate groups at the other.

**Creep:** Creep is the time dependent response of an already set material to stress. This response is in form of plastic deformation.

**Cusp:** It is the elevation on the crown portion of a tooth making up a divisional part of the occlusal surface.

**Dead tracts:** This type of dentin usually results due to moderate type of stimuli such as moderate rate caries or attrition. In this case, both affected and associated odontoblasts die, resulting in empty dental tubules which appear black when ground sections of dentin are viewed under transmitted light. These are called dead tracts due to appearance of black under transmitted light.

**Dental amalgam:** The dental amalgam is an alloy of mercury with silver, tin, and varying amounts of copper, zinc and other minor constituents.

**Dental bur:** “Bur is a rotary cutting instrument which has bladed cutting head.”

**Dental cements:** These are the materials made from two components, powder and liquid, mixed together.

**Dentin:** The hard, yellowish tissue underlying the enamel and cementum it makes up the major bulk of the tooth.

**Dentinal tubules:** The dentinal tubules follow a gentle “S”-shaped curve in the tooth crown and are straighter in the incisal edges, cusps and root areas. The ends of the tubules are perpendicular to dentinoenamel and dentinocemental junctions.

**Dentinoenamel junction:** Dentinoenamel junction is pitted/scalloped in which crests are toward enamel and shallow depressions are in dentin. This helps in better interlocking between enamel and dentin.

**Developmental depression:** This is a hollow or depressed area. In the mouth, a developmental depression is a pitted area on the surface of a tooth: this is often visible on more defined regions of the tooth.

**Developmental groove:** It is shallow groove between the primary parts of the crown or root.

**Diagnosis:** A diagnosis is an evaluation of a condition or disorder often achieved by medical analysis such as examinations or laboratory tests.

**Diastema:** A diastema simply refers to the space or gap in between two teeth. With today’s technology in orthodontics and cosmetic dentistry, a diastema can be easily corrected.

**Diphyodont:** Diphyodont refers to the anatomical property of having two successive sets of teeth; this is a feature common to most mammals. Humans have two sets of teeth; these are known as the primary or deciduous teeth and the permanent teeth.

**Direct pulp capping:** Direct pulp capping procedure involves the placement of biocompatible material over the site of pulp exposure to maintain vitality and promote healing.

When a small mechanical exposure of pulp occurs during tooth preparation or following a trauma, an appropriate protective base should be placed in contact with the exposed pulp tissue so as to maintain the vitality of the remaining pulp tissue.

**Distal:** Tooth surface away from the anterior midline.

**Double wedging:** Here two wedges are used: One is inserted from buccal embrasure and another is inserted from lingual embrasure.

**Dynamic occlusion:** It is defined as tooth contact during mandibular movements.

**Embrasures:** These are V-shaped spaces that originate at proximal contact areas between adjacent teeth and are named for the direction towards which they radiate.

**Enamel lamellae:** These are leaf like defects present in enamel and may extend to DEJ. They contain organic substances. Lamellae are commonly found at the base of occlusal pits and fissures.

**Enamel spindles:** Odontoblastic processes sometimes cross DEJ and their end is thickened. Spindles serve as pain receptors, that is why, when we cut in the enamel patient complains of pain.

**Enamel tufts:** Enamel tufts are ribbon-like structures which run from dentin to enamel. They are named so because they resemble tufts of grass. They contain greater concentration of enamel proteins.

**Enameloplasty:** It is the careful removal of sharp and irregular enamel margins of the enamel surface by “rounding” or “saucerizing” it and converting it into a smooth groove making it self-cleansable, finishable and allowing conservative placement of margins.

**Erosion:** It can be defined as a loss of tooth substance by a chemical process that does not involve known bacterial action. The eroded area appears smooth, hard and polished.

**External:** External describes the outer surface or layer of a structure; this may also refer to something that is connected to an outer or outside part or structure.

**External wall:** An external wall is a wall in the prepared tooth surface that extends to the external tooth surface. External wall takes the name of the tooth surface towards which it is situated.

**Extraoral:** This term refers to any structure, object or event that occurs which is situated outside of the mouth. It is the opposite of intraoral.

**Facial:** Labial and buccal surface collectively form facial surface.

**Flares:** Flares are concave or flat peripheral portions of the facial or lingual proximal walls. These are of two types:

**Primary flare:** It is basic part of circumferential tie. It is like a long bevel and is always directed 45° to the inner dentinal wall proper.

**Secondary flare:**

- It is a flat plane superimposed peripherally to the primary flare.
- Secondary flare is not given in the areas where esthetics is more important.

**Floor of tooth preparation:** Floor is a prepared wall which is usually flat and perpendicular to the occlusal forces directed occlusogingivally, for example, pulpal and gingival walls.

**Flowable composite resin:** These resins have lower filler content ranging between 41 and 53% by volume. Low filler loading is responsible for decreased viscosity of composites, which allows them to be injected into both preparation, this makes them a good choice as a pit and fissure restorative.

**Forward caries:** When the caries cone in enamel is larger or of same size as present in dentin, it is called as forward caries.

**Fossa:** It is an irregular depression or concavity.

**Fritting:** It is the process followed by sintering. Here the fused components are quenched rapidly in water causing fractures through out the fused mass, called frit. This frit is then grounded into the fine powder form.

**Gingiva:** Gingiva covers the cervical portion of the crown. Anatomically gingiva is divided into three parts:

- Marginal or unattached gingival
- Attached gingival
- Gingival sulcus or crevice.

**Giomers:** Giomer is hybrid of words “glass ionomers” and “composite”. They are also known as PRG composites (Prereacted glass ionomer composites).

**Gnarled enamel:** There are group of irregular enamel that is more resistant to cleavage called Gnarled enamel present mostly in cervical, incisal and occlusal portion. This consists of bundles of enamel rods which intertwine in an irregular manner with other group of rods, finally taking a twisted and irregular path towards the tooth surface.

**Gutta-percha:** Material used in the filling of root canals.

**Handpiece:** The instrument used to hold and revolve burs in dental operations.

**Heterodont:** Different types of teeth within the same dentition (i.e. incisors, canines, molars).

**Histodifferentiation:** Development into a specialized tissue.

**Histology:** The study of tissues.

**Homodont:** A homodont has teeth that are all the same size and shape. Most vertebrates and all invertebrates are homodont; mammals are the exception as they have different shaped teeth and are therefore heterodont.

**Hyperemia:** A period of increased blood flow caused by an alteration in conditions; often occurs in the pulp of a tooth.

**Hyperplasia:** Over-growth of a part of an organ by an increase in the number of cells.

**Ideal occlusion:** A complete harmonious relationship of the teeth and masticatory system.

**Inactive/arrested carious lesion:** A lesion that may have formed earlier and then stopped is referred to as an arrested or inactive carious lesion. Arrested carious lesion is characterized by a large open cavity which no longer retains food and becomes self-cleansing.

**Incipient caries:** Involves less than half the thickness of enamel.

**Incisal edge:** The incisal edge of a tooth is the surface used to cut or tear. This surface is commonly found on the anterior teeth, which include the incisors and canine teeth. This area is also known as the incisal ridge.

**Incisors:** The square-shaped teeth located in front of the mouth, with four on the upper and four on the lower are called incisors. Incisors are important teeth for phonetics and esthetics. They help in cutting the food.

**Indirect pulp capping:** Indirect pulp capping is a procedure performed in a tooth with deep carious lesion adjacent to the pulp. In this procedure, all the carious tissue is removed except the soft undischolorated carious dentin which is adjacent to the pulp. Caries near the pulp is left in place to avoid pulp exposure and preparation is covered with a biocompatible material.

**Inlay:** An inlay is an indirect intracoronal restoration which is fabricated extraorally and cemented in the prepared tooth. Inlay may cover none, or all but one cusp of a tooth.

**Internal wall of preparation:** It is a wall in the preparation, which is not extended to the external tooth surface.

**Intertubular dentin:** This dentin is present between the tubules which is less mineralized than peritubular dentin. Intertubular dentin determines the elasticity of the dental matrix.

**Intraoral:** Inside your mouth.

**Inverted cone bur:** It has flat base and sides tapered towards shank. It is used for establishing wall angulations and providing undercuts in tooth preparations.

**Labial:** The term labial refers to the lips, which are also known as the labia.

**Land:** It is the plane surface immediately following the cutting edge.

**Line angle:** It is a junction of two surfaces of different orientations along the line and its name is derived from the involved surfaces.

**Liner:** It is applied in thin layer of less than 0.5 mm so as to attain a physical barrier to pulp and to provide therapeutic effect.

**Lingual fossae:** Occur on lingual surface of incisors.

**Lingual:** The term lingual refers to the tongue; structures that are close to the tongue are also often described as being lingual for example, lingual surface of the tooth.

**Lobe:** It is one of the primary sections of formation in the development of the crown.

**Malocclusion:** Any deviation from a physiologically acceptable contact of opposing dentition is called "malocclusion".

**Mamelon:** A mamelon is a small lump or protrusion, which appears on the surface of a tooth which has recently erupted; these are found on the incisors and there are usually three.

**Marginal ridges:** Marginal ridges are defined as rounded borders of enamel which form the mesial and distal margins of occlusal surfaces of premolars and molars and mesial and distal margins of lingual surfaces of the incisors and canines.

**Masticatory system:** The teeth and surrounding structures: jaws, temporomandibular joint, muscles, lips and tongue.

**Matricing:** It is the procedure by which a temporary wall is built opposite to the axial wall, surrounding the tooth structure which has been lost during the tooth preparation.

**Matrix:** It is an instrument which is used to hold the restoration within the tooth while it is setting.

**Mesial:** Tooth surface toward the anterior midline.

**Micromotor handpiece:** It gets power from electric micromotor or airmotor. This handpiece has high torque and low speed.

**Microporosity:** It is usually seen in fine grain molten metal alloy castings. This usually happens due to solidification shrinkage of molten alloy.

**Midline:** The midline refers to an invisible line which divides a structure or object into two equally-sized parts. In dentistry, the midline refers to the point of contact between the mesial surfaces of the incisors at the front of the mouth.

**Mixed dentition:** This refers to the mixture of primary and permanent teeth in the dental arch; this is common in children between the ages of 6 and 12 when some, but not all, of the deciduous teeth have fallen out and been replaced by permanent teeth.

**Moderate caries:** Involves more than half the thickness of enamel, but does not involve dentinoenamel junction.

**Molars:** Distal to premolars are the molars. There are six molars on each arch (three on each side), therefore a total of 12 inside the mouth. They have multiple cusps which help in crushing and grinding the food. These teeth also help in maintenance of vertical height of the face.

**Mulling:** Mulling is done so that all alloy particles are properly coated with mercury, in other words it is continuation of the trituration. Mulling of the amalgam can be done manually or mechanically. By hand, it can be done by squeezing the freshly mixed amalgam collected in the chamois skin. Mechanical mulling is done in the amalgamator by trituration it for one to two seconds.

**Oblique ridge:** It is a ridge obliquely crossing the occlusal surfaces of maxillary molars. It is usually formed by the union of triangular ridge of distobuccal cusp and distal cusp ridge of the mesiolingual cusp.

**Occlusal contact:** Any contacting or touching of tooth surfaces is called occlusal contact. Unmodified, contact should involve a normal, non-pathologic touching of tooth surfaces. Harmful occlusal contacts can occur in following forms:

**Occlusal surface:** Masticating surface of posterior teeth (in molar or premolar).

**Occlusion:** Any contact between the incising or masticating surfaces of the upper and lower teeth.

**Onlay:** An onlay is a combination of intracoronal and extracoronal cast restoration which covers one or more cusps.

**Operative dentistry:** “Operative dentistry is defined as science and art of dentistry which deals with diagnosis, treatment and prognosis of defects of the teeth which do not require full coverage restorations for correction.”

**Outline form and initial depth:** The outline form means:

- Placing the preparation margins to the place they will occupy in the final tooth preparation except for finishing enamel walls and margins.
- Maintaining the initial depth of 0.2 to 0.8 mm into the dentin.

**Palatal surface:** The surface of the maxillary teeth nearest the palate.

**Parafunctional (non-functional) contacts:** Normal tooth contacts that have been subjected to excessive use through bruxism, clenching, etc.

**Partial crown:** In partial crown, a part of the crown remains uncovered and rest of the crown is covered like three quarter crown and seven-eighth crown.

**Passive eruption:** Describes the process by which teeth continue to erupt into the mouth as tooth structure is lost to attrition and wear.

**Pear shaped bur:** Here head is shaped like tapered cone with small end of cone directed towards shank. It is used in class I tooth preparation for gold foil. A long length pear bur is used for tooth preparation for amalgam.

**Peritubular dentin:** This dentinal layer usually lines the dentinal tubules and is more mineralized than intertubular dentin and predentin.

**Permanent teeth:** The teeth that replace the deciduous or primary teeth.

**Piggyback wedging:** In this technique one (larger) wedge is inserted as used normally, while the other smaller wedge (Piggyback) is inserted above the larger one. It is indicated in cases of shallow proximal box with gingival recession.

**Pit and fissure caries:** Pit and fissure caries occur on occlusal surface of posterior teeth and buccal and lingual surfaces of molars and on lingual surface of maxillary incisors.

**Pit and fissure sealant:** “A pit and fissure sealant is a material that is placed in the pits and fissures of teeth in order to prevent or arrest the development of dental caries.”

**Pit:** A pinpoint depression in the occlusal surface of a tooth.

**Pits:** These are small pinpoint depressions located at the junction of developmental grooves or at ending of those grooves.

**Placebo:** A chemical often used to reduce anxiety; also used as a means of comparison for drug performance by health professionals.

**Point angle:** It is a junction of three plane surfaces or three line angles of different orientation and its name is derived from its involved surfaces or line angles.

**Polyphyodont:** Possessing several sets of teeth during a lifespan.

**Porosity:** Porosity is considered as a major defect in the casting which can occur on the internal as well as on the external surface of the casting. It usually weakens the casting.

Various types of porosities can be:

- Solidification shrinkage porosity
  - a. Localized shrinkage porosity
  - b. Microporosity
- Gaseous defects
  - a. Gas inclusion porosity
  - b. Pinhole porosity
- Backpressure porosity
- Subsurface porosity.

**Premolars/ bicuspid:** The two smaller teeth in front of the molars that are used for chewing. Instead of having four cusps (pointed areas) like a molar, bicuspid only have two cusps. Adults have a total of eight bicuspid - two on the lower right, two on the lower left, two on the upper right and two on the upper left.

**Primary caries:** Denotes lesions on unrestored surfaces.

**Primary dentin:** This type of dentin is formed before root completion, gives initial shape of the tooth. It continues to grow till 3 years after tooth eruption.

**Primary resistance form:** Primary resistance form is that shape and placement of preparation walls to best enables both the tooth and restoration to withstand, without fracture the stresses of masticatory forces delivered principally along long axis of the tooth.

**Primary retention form:** Primary retention form is that form, shape and configuration of the tooth preparation that resists the displacement or removal of restoration from the preparation under lifting and tipping masticatory forces.

**Primary teeth:** The baby teeth, also known as the primary dentition.

**Primate spacing:** The normal spacing between primary anterior teeth.

**Proximal surface:** The surface of the tooth adjacent to the next tooth refers to the mesial and distal surfaces.

**Pulp cavity:** The pulp cavity lies within the tooth and is enclosed by dentin all around except at the apical foramen. It is divided into two— a coronal and a radicular portion.

**Pulp chamber:** It occupies the coronal portion of pulp cavity. It acquires shape according to shape and size of crown of the tooth, age of person, and irritation, if any.

**Pulp horns:** Pulp horns are landmarks present occlusal to pulp chamber.

**Pulpal wall of tooth preparation:** A pulpal wall is an internal wall that is towards the pulp and covering the pulp. It may be both vertical and perpendicular to the long axis of tooth.

**Quadrant:** In dentistry the term quadrant refers to one of four equally sized sections; these are known as the upper left, lower left, upper right and lower right quadrants. Quadrants are sometimes also referred to as the corners of the mouth.

**Radial line:** It is the line connecting center of the bur and the blade.

**Radiographic:** Referring to X-rays.

**Rake angle:** This is angle between the rake face and the radial line.

- *Positive rake angle:* When rake face trails the radial line.
- *Negative rake angle:* When rake face is ahead of radial line.
- *Zero rake angle:* When rake face and radial line coincide each other.

**Rampant caries:** It is the name given to multiple active carious lesions occurring in the same patient, frequently involving surfaces of teeth that are usually caries free. It occurs usually due to poor oral hygiene and taking frequent cariogenic snacks and sweet drinks between meals. It is also seen in mouths where there is hyposalivation.

Rampant caries is of following three types:

- **Early childhood caries** is a term used to describe dental caries present in the primary dentition of young children.
- **Bottle caries or nursing caries** are names used to describe a particular form of rampant caries in the primary dentition of infants and young children. The clinical pattern is characteristic, with the four maxillary deciduous incisors most severely affected.
- **Xerostomia induced rampant caries (radiation rampant caries)** are commonly observed that after radiotherapy of malignant areas of or near the salivary glands. Because of radiotherapy salivary flow is very much reduced. This results in rampant caries even in those teeth which were free from caries before radiotherapy.

**Rapid or immediate tooth separation:** Rapid separation is most frequently used method in which tooth separation can be achieved in very short span of time.

**Recurrent caries:** Lesions developing adjacent to fillings are referred to as either recurrent or secondary caries.

**Reference point:** Reference point is that site on occlusal or the incisal surface from which measurements are made.

**Reparative dentin/tertiary dentin:** Tertiary dentin frequently formed as a response to external stimuli such as dental caries, attrition and trauma. If the injury is severe and causes odontoblast cell death, odontoblast like cells synthesize specific reparative dentin just beneath the site of injury to protect pulp tissue.

**Residual caries:** It is demineralized tissue left in place before a filling is placed.

**Resorption:** Resorption is defined as “a condition associated with either a physiologic or a pathologic process resulting in the loss of dentin, cementum or bone.”

**Root canal:** The root canal extends from canal orifice to the apical foramen. In anterior teeth, the pulp chamber merges into the root canal but in multirooted posterior teeth this division becomes quite obvious.

**Root caries:** When the lesion starts at the exposed root cementum and dentin, it is termed as root caries.

**Round bur:** Spherical in shape, used for removal of caries, extension of the preparation and for the placement of retentive grooves.

**Run-out:** It measures the accuracy with which all the tip of blades pass through a single point when bur is moving. It measures the maximum displacement of bur head from its center of rotation. In case, there is trembling of bur during rotation, this effect of run-out is directly proportional to length of bur shank.

**Sclerotic dentin:** It occurs due to aging or chronic and mild irritation (such as slowly advancing caries) which causes a change in the composition of the primary dentin. In sclerotic dentin, peritubular dentin becomes wider due to deposition of calcified materials, which progress from enamel to pulp. This area becomes harder, denser, less sensitive and more protective of pulp against irritations.

**Secondary dentin:** Secondary dentin is formed after completion of root formation. In this, the direction of tubules is more asymmetrical and complicated as compared to primary dentin.

**Simple caries:** Caries involving only one tooth surface is termed as simple caries.

**Simple tooth preparation:** A tooth preparation involving only one tooth surface is termed simple preparation.

**Slow or delayed separation:** In this separation, teeth are slowly and gradually shifted apart by inserting some materials between the teeth. This separation usually takes long-time, i.e. from several days to weeks.

**Smear layer:** When tooth surface is altered using hand or rotary instruments, cutting debris are smeared on enamel and dentin surface, this layer is called smear layer.

**Smooth surface caries:** Smooth surface caries occurs on gingival third of buccal and lingual surfaces and on proximal surfaces.

**Static occlusion:** It is defined as contact of teeth when jaws are closed.

**Straight fissure bur:** It is parallel sided cylindrical bur of different lengths and is used for amalgam tooth preparations.

**Straight handpiece:** In straight handpiece long axis of bur lies in same plane as long axis of handpiece. This handpiece is commonly used in oral surgical and laboratory procedures.

**Striae of Retzius:** They appear as brownish bands in the ground sections and illustrate the incremental pattern of enamel. These represent the rest periods of ameloblast during enamel formation, therefore also called as growth circles.

**Sulcus:** It is a long depression on the surface of tooth ridges and cusps.

**Tapering fissure bur:** It is tapered sided cylindrical but sides tapering towards tip and is used for inlay and crown preparations.

**Tooth preparation:** It is a mechanical alteration of a defective, injured or diseased tooth in order to best receive a restorative material which will re-establish the healthy state of the tooth including esthetics correction when indicated along with normal form and function.

**Tooth separation:** Separation of teeth is defined as the process of separating the involved teeth slightly away from each other or bringing them closer to each other and/or changing their spatial position in one or more dimensions.

**Transverse ridge:** The transverse ridge is a ridge which is formed by the junction of two inclines on the occlusal exterior of a tooth. These are usually found on the premolars and molars.

**Triangular ridges:** These descend from the tips of the cusps of molars and premolars toward the central part of occlusal surfaces.

**Trituration:** The purpose of trituration is to remove oxide layers from the alloy particles so as to coat each alloy particle with mercury, resulting in a homogeneous mass for condensation. Trituration can be done by hand or mechanical means.



**Tubercle:** Smaller elevation on some portion of crown produced by an extra formation of enamel.

**Varnish:** A varnish is an organic copal or resin gum suspended in solutions of ether or chloroform. When applied on the tooth surface the organic solvent evaporates leaving behind a protective film.

**Wedge:** Wedge is a device which is usually preferred for rapid tooth separation. It helps in stabilization of retainer and matrix during restorative procedures and prevents gingival overhang of restoration.

**Wedge wedging:** In this technique, two wedges are used, one wedge is inserted from lingual embrasure area while another is inserted between the wedge and matrix band at right angle to first wedge.

**Working die:** Die is the positive replica of a prepared tooth.

**Working length:** It is defined as “the distance from a coronal reference point to a point at which canal preparation and obturation should terminate”.

**Zinc containing alloys:** Amalgam alloys with zinc in range of 0.01-1%.

**Zinc free alloys:** Amalgam alloys with zinc in range of < 0.01 %.

# Index

## A

Abfraction 34  
Abrasion 34  
Abrasive instruments 97  
Access cavity of anterior teeth 274  
Access cavity preparation for  
  mandibular molars 278  
  maxillary molars 277  
  premolars 276  
Acellular cementum 48  
Acid etching 40  
Acidogenic  
  nature 53  
  theory 53  
Aciduric nature 53  
Active carious lesion 33, 58  
Activity of carious lesion 58  
Acute dental caries 33, 58  
Adhesive sealer 256  
Admixed alloy 167  
Advanced  
  caries 59  
  dentinal changes 62  
Advantages of  
  air abrasion 139  
  bur cutting 100  
  cast metal restorations 228  
  composites 215  
  hand cutting instruments 89  
  sharp instruments 88  
  silver amalgam 166  
  vertical compaction technique 298  
Aesthetics 160  
Age changes in pulp 47  
Air-driven handpieces 90  
Alloy 164  
Aluminium collars 112  
Alveolar  
  bone 49  
  crest group 48  
Amalgam 164, 258  
  carriers 83  
Anatomic  
  crown 32  
  custom made matrix 113  
Anatomical matrix band 109  
Anatomy of dental pulp 46  
Angle former 80  
Angled chisel 80  
Antibacterial composites 209

Apical  
  constriction 271  
  fibers 48  
  root anatomy 271  
Application of  
  adhesive system 221  
  load 96  
  matrix band 173, 199  
Argon laser 64  
Armamentarium for obturation 293  
Attrition 34  
Axial wall 122, 133

## B

Backward caries 59  
Bacteria 56  
Bacterial irritants 250  
Bands of Hunter-Schreger 38  
Barbed broach 263  
Basic principles of canal instrumentation 285  
Basics of endodontics 260  
Belt driven handpiece 90  
Bevels in cutting instruments 77  
Biocompatibility of  
  composites 214  
  zinc oxide eugenol cement 147  
Bisbiguanides 67  
Blade angle 95  
Blood vessels 49  
Body of lesion 62  
Bonded amalgam system 169  
Bonding  
  agent 97  
  interface 169  
Bonding of polyacrylate cement to tooth  
  structure 151  
Bottle caries 58  
Briault explorer 78  
Broaches 263  
Buccal 32  
Bur blade 93  
Burnisher 85  
Burnishing 174, 200  
  instruments 74

## C

Calcium hydroxide 256  
Canal orifice 271  
Canine 5, 26

Capping of cusp 237  
Carbon steel 73  
Caries  
  balance concept 54  
  vaccine 71  
Caries of  
  buccal and lingual surfaces 66  
  dentin 62  
  enamel 60  
  occlusal surfaces 65  
  proximal surfaces 65  
  various surfaces 65  
Cariology 51  
Carvers 74, 84  
Casein phosphopeptide 70  
Cast  
  gold restorations 258  
  metal restorations 226  
Casting  
  defects 244  
  procedure 242  
Causes of loss of working length 280  
Cavosurface angle margin 123  
Cell 48  
  free zone of Weil 44  
  rich zone 44  
Cellular  
  cementum 48  
  elements 44  
Cement spatulas 83  
Cementation of casting 244  
Cementodentinal junction 271  
Cementoenamel junction 2, 122  
Cementum 47, 65  
Central fossae 2  
Cervical line 2  
Checking occlusion 223  
Cheese 67  
Chelating agent 283  
Chisels 74, 79  
Chronic dental caries 34, 58  
Cingulum 2  
Circumferential tie 230  
Circumpulpal dentin 42  
Classes of human teeth 26  
Classification given by  
  GV black 73  
  Marzouk 74  
Classification of  
  amalgam 165

- composites 204
  - dental
    - caries 57
    - cements 145
  - endodontic instruments 261
  - glass ionomer cements 152
  - hand cutting instruments 73
  - matrices 105
  - tooth preparations 126
  - Cleaning of casting 243
  - Clearance angle 93,95
  - Cleiod-discoid 80
  - Clinical
    - considerations of dentin 43
    - crown 32
    - fluoride products 69
    - significance of enamel 40
  - Clogging of abrasive surface 98
  - Coated abrasive instruments 98
  - Coefficient of thermal expansion 168, 202, 210
  - Color 38
  - Coloring agents 204
  - Commonly used
    - files 265
    - instrument 85
    - irrigating solutions 282
  - Comparison of tooth numbering systems 30
  - Complex caries 59
  - Compomers 208
  - Components of saliva 55
  - Composite
    - placement 222
    - resin instruments 85
    - restorations 201
  - Composition of
    - amalgam powder 164
    - composites 202, 203
    - glass ionomer cement 153
  - Compound
    - caries 59
    - supported matrix 109
    - tooth preparation 121
  - Compressive strength 170
  - Condensable composites 207
  - Condensers 83
  - Condensing instruments 73,74
  - Consequences of overextended working length 280
  - Consolidated silver alloy 171
  - Contents of pulp 44
  - Contra-angle handpiece 90
  - Contraindications of
    - amalgam restoration 166
    - composites 215
    - glass ionomer cements 157
    - metal inlay and onlay 228
  - Conventional class
    - III tooth preparation 216
    - V preparation 218
  - Copper 164
    - collars 112
  - Corner stones 9
  - Corrosion 167
  - Coupling agent 203
  - Creep 211
    - value 171
  - Crown 227
    - down technique 288, 290
  - Curing time 214
  - Current methods of caries prevention 70
  - Cusp 2
  - Cutting instruments 72, 73
- D**
- 
- Damage to
    - ear 100
    - soft tissue 100
  - Dark zone 61
  - Dead tracts 42
  - Deciduous teeth 29
  - Defence cells 45
  - Defense of tooth 46, 47
  - Definition of
    - access cavity preparation 271
    - dental anatomy 26
    - operative dentistry 25
  - Density of abrasive particles 98
  - Dental
    - amalgam 163, 164
    - burs 91
    - caries 33, 51, 54, 56
    - cements 144, 145
    - floss and tape 68
    - prophylaxis 68
    - pulp 44
  - Dentin 40, 65
    - wall 122
  - Dentinal tubules 41
  - Dentinoenamel junction 38, 39, 122
  - Depth of preparation 179
  - Description of permanent tooth 3
  - Design of
    - bur head 92
    - flute ends 96
    - neck 92
  - Developmental groove 2
  - Devices used for sharpening 88
  - Diagnodent 64
  - Diagnosis of
    - dental caries 63
    - pits and fissure caries 139
  - Diamond
    - abrasive instruments 97
    - instruments and pastes 99
  - Diet 55
  - Difference between
    - chemically cured and light cured 204
    - compomers and giomers 209
    - high copper and low copper alloy 165
    - infected and affected dentin 136
    - visible light and ultraviolet light 204
  - Different
    - methods of working length determination 280
    - uses of cements 145
  - Digital imaging fiberoptic transillumination 65
  - Diode lasers 64
  - Direct
    - digital radiography 280
    - wax pattern without use of matrix band 241
  - Disadvantages of
    - cast metal restorations 228
    - composites 216
    - silver amalgam 166
  - Discoloration 245
  - Distal 32
    - Distal aspect 3, 5
    - bevel instrument 77
  - Distortion 245
  - Double wedging 117
  - Dye enhanced laser fluorescence 64
- E**
- 
- Early
    - childhood caries 58
    - dental changes 62
  - Eburnated dentin 42
  - Ecological plaque hypothesis 53
  - Effect of
    - chemical irritants on pulp 252
    - dental caries on pulp 250
    - tooth preparation on pulp 251
  - Elliot separator 116
  - Enamel 36, 65
    - lamellae 38
    - spindles 38, 39
    - tufts 38
    - wall 122
  - End cutting or side cutting bur 95
  - Endodontic
    - instruments 261
    - probe 280
  - Endoscopy filtered fluorescence method 63
  - Environment of tooth 55
  - Epithelial cells rests of Mallassez 48
  - Erosion 34
  - Esthetic
    - improvement 120
    - requirement 194
  - Esthetics of composites 213
  - Etching of tooth preparation 221
  - Excavators 74
  - Explorer 78
  - Exploring instruments 74, 77
  - Extent of caries 193
  - External wall 122

Extracellular components 46  
Eye injuries 101

## F

Facial 32  
Factors affecting  
  cutting efficiency of bur 95  
  decision to restore tooth 120  
Factors influencing effect of restorative  
  mate 252  
Failures  
  in composite restorations 224  
  of amalgam restorations 178  
Fats 67  
Fédération Dentaire Internationale 29  
Ferrier double bow separator 115  
Fiberoptic  
  handpiece 96  
  transillumination 63, 64  
Fibers 46  
Fibroblast 45, 48  
Fibrous food 67  
Files 74, 265  
Fillers 203  
Final  
  cleaning and inspection of preparation  
    198  
  stages of tooth preparation 136  
  tooth preparation 188  
Finger rests 87  
Finishing 74, 99, 177, 200  
  external walls 198  
First  
  molar 9  
  premolar 7, 16  
Fissurotomy burs 97  
Flowable composite resins 206  
Fluoridated salt 70  
Fluoride 67, 69  
  release 159  
  supplements 70  
Formation of dentin 46  
Forms of mercury 181  
Forward caries 58  
Fossa 2  
Frequency of carbohydrate intake 56  
Functions of  
  bevels 231  
  dentin 43  
  enamel 40  
  irrigants 281  
  matrix 104  
  periodontal ligament 49  
  pulp 46  
  saliva 55

## G

Gallium in place of mercury in amalgam 170

Gates-Glidden burs 266  
Gear driven handpiece 90  
Generations of dental amalgam 165  
Genetic modalities in caries prevention 70  
Genetically modified  
  foods 71  
  organisms 71  
Gingival margin trimmer 82  
Giomers 208  
Glass ionomer cement 152, 257, 258  
Glazing 224  
Gnarled enamel 38  
Graham Mount's classification 60  
Grossman formula 280  
Grossman's classification 262  
Guidelines for  
  access cavity preparation 272  
  sharpening operative instruments 88  
Gutta-percha 291

## H

Hand cutting instruments 74, 79  
Hard steel 73  
Hardening heat treatment 73  
Hardness of  
  abrasive particle 98  
  dentin 41  
Hatchet 81  
Heat  
  production 251  
  treatment of  
    bur 96  
    materials 73  
Hedstrom files 266  
Histology of dental pulp 44  
Histopathology of dental caries 60  
Historical development of amalgam 163  
History of composite resins 202  
Hoes 80  
Horizontal group 48  
Host 55  
Hybrid composite resins 205

## I

Identification of bevel 77  
Impression taking for cast metal restoration  
  239  
Inadequate occlusal extension 179  
Incipient caries 59  
Incisal aspect 4, 5  
Incisors 26  
Indications for  
  pin retained cast restorations 247  
  use of sealer 256  
  use of varnish 256  
Indications of  
  amalgam restoration 166  
  composite restorations 215

  glass ionomer cement 157  
  metal inlay and onlay 228  
Indium 164  
Ingle's method 280  
Inhibition of air 214  
Initial tooth preparation 129, 185  
Inlay 227  
  taper 229  
Innervation of tooth 46, 47  
Insertion of amalgam 173, 199  
Instrument  
  families 79  
  formula 76  
  grasps 85  
  motions 77  
Instruments for tooth structure removal 74  
Instruments used for obturation of root  
  canals 269  
Intensity of curing light 215  
Intercellular matrix 49  
Interdental cleaning aids 68  
Internal wall 122  
Interproximal explorer 78  
Interradicular fibers 48  
Intertubular dentin 41, 42  
Inverted pen grasp 86  
Iodides 67  
Ion releasing composites 209  
Irrigation of root canal system 281  
Isolation instruments 74  
Ivory matrix  
  band 106  
  holder 105

## K

K-flex files 266  
Kinetic tooth preparation 139  
Knives 74  
Knurled nuts 107  
Kuttler's method 280

## L

Lactobacillus zeae 71  
Lamina dura 65  
Large cement spatula 83  
Lateral compaction technique 293  
Law of  
  cementoenamel junction 274  
  centrality 274  
  color change 274  
  concentricity 274  
  orifice location 274  
  symmetry 274  
Linear 256  
  surface speed 96  
Lingual fossae 2  
Lobe 2  
Local factors affecting incidence of caries 54

Localized non-hereditary enamel hypocalcification 34  
hypoplasia 34

Low  
caloric sweeteners 67  
mercury alloy 169

Lymphocytes 46, 48

## M

Macrofilled composite resins 205

Macrophages 48

Magnetic resonance microimaging 64

Mamelons 2

Management of dental caries 71

Mandibular

canine 15, 276  
first  
molar 19, 279  
premolar 277  
incisors 275  
lateral incisor 14  
second  
molar 279  
premolar 277  
teeth 12

Manipulation of

cement 149  
glass ionomer cement 155  
zinc  
oxide eugenol cement 147  
polycarboxylate cement 151

Mantle dentin 42

Manufacturing of hand instruments 262

Marginal ridges 2

Mast cells 46, 48

Materials used for

obturation 291  
pulp protection 254

Matricing 103, 104

Matrix

application 221  
used for composite resin 222

Maxillary

canine 275  
central incisor 3, 275  
first  
molar 277  
premolar 277  
lateral incisor 4, 275  
second  
molar 278  
premolar 277

Mercury

alloy ratio 171  
exposure in dental office 181  
hygiene 181  
toxicity 183

Metal reinforced glass ionomer cement 153

Metals used for manufacturing cutting instruments 73

Methods of

determining working length 280  
tooth separation 114  
use of instruments 87

Methods to

improve oral hygiene 68  
increase protective factors 67, 69  
reduce demineralizing factors 67

Microfilled composite resins 205

Microleakage in amalgam 168

Miscellaneous instruments 74

Moderate caries 59

Modification in Tofflemire retainer 109

Modifications from Ingle's standardization 263

Modified

palm and thumb grasp 86  
pen grasp 86

Modulus of elasticity 211

Molars 27

Morphology of teeth 1

Moulded abrasive instruments 98

Mouth mirrors 77

Mulling 173, 199

## N

Nature of

carbohydrate content of diet 56  
cutting instrument 252

Neck diameter of bur 95

Nerve fibers 49

Neutrophil 48

Nickle titanium endodontic instruments 268

Nomenclature for instruments 74

Nomenclature of tooth surfaces 32

Nomenclature related to dental caries 33

Non-interfering true separator 115

Non-specific plaque hypothesis 53

Normal

dentin 63  
radiographic landmarks 65  
saline 282

Number of

blades 96  
tooth surfaces involved 59

Nursing caries 58

Nutrition of dentin 46

## O

Obturation of root canal system 290

Obturation techniques 292

Occlusal 32

outline form 232  
pits and fissures 38, 39

Odontoblastic layer 44

Odontoblasts 44

Onlay 227

Operative instruction for placement 108

Optical coherence tomography 64

Organic

content 37  
matrix 203  
resins 203

Organically modified ceramic 209

Ormocer 209

Osteoblasts 49

Osteoclasts 49

Osteocytes 49

Overextended tooth preparation 179

## P

Palladium 164

Palm and thumb grasp 86

Palodent bitine system 112

Paper-carried abrasives 99

Parts of

bur 91  
hand cutting instruments 74  
matrix 104

Pathway of caries spread 58

Peeso reamers 268

Periodontal

fibers 48  
ligament 48, 65  
probes 79

Periradicular tissue 47

Peritubular dentin 41, 42

Permanent teeth 28, 29

Phases of silver amalgam 166

Physical

nature of diet 55  
properties of amalgam 167

Physiologic sclerotic dentin 42

Piggyback wedging 118

Pin retained cast restorations 246

Pits 2, 33

Plasma cells 48

Plastic

deformation 167  
filling instrument 83  
instruments 74  
matrix strips 111  
wedges 116

Polishing 177, 200

Polyacid modified composite resins 208

Polycarboxylate cement 258

Polymerization of composites 214

Polymerization shrinkage 211

Polymorphonuclear leukocytes 46

Porosity 245

Post obturation restoration 298

Powdered diamond abrasive 97

Precontoured matrix 112

Predentin 41

Premolars 26

Preventing and treating caries 119

- Prevention of dental caries 67
- Primary  
 caries 33, 57  
 dentin 41, 42
- Principles of  
 sharpening 88  
 tooth preparation 119
- Prismless layer 38, 39
- Progression of pulpal pathologies 261
- Properties of  
 composite restorative materials 210  
 glass ionomer cement 158
- Proteolysis-chelation theory 53, 54
- Proteolytic theory 53
- Proximal box preparation 233
- Pulp  
 cavity 65, 270  
 chamber 46, 270  
 horns 270  
 performs four basic functions 46  
 protection 193, 197, 220, 249  
 in deep carious lesions 253  
 procedures 252
- Pulpal  
 damage 100  
 irritants 250  
 reaction to microbial irritation 261  
 wall 122
- Purpose of  
 obturation 290  
 tooth preparation 119
- Q**
- 
- Qualitative laser fluorescence 64
- Quantitative laser fluorescence 64
- R**
- 
- Radial line 93
- Radiation rampant caries 58
- Radiographic grid 280
- Radiographic method of  
 diagnosis 65  
 working length determination 280
- Radiopacity 211
- Rake angle 93, 95
- Rampant caries 33, 58
- Rationale of caries vaccine 71
- Reactive sclerotic dentin 42
- Reamers 264
- Reason for  
 failure of amalgam restorations 179  
 tooth separation 113
- Recent advances in  
 amalgam 169  
 rotary instruments 96
- Record of interocclusal relationship 239
- Recurrent caries 33, 57
- Remaining dentin thickness 251
- Repair of composite restorations 224
- Reparative dentin 41, 42
- Replacing restorations 120
- Requirements of matrix band 104
- Residual caries 33, 58
- Resin  
 cements 161  
 modified glass ionomer 154  
 thickness 214
- Resorption 34
- Restoration  
 instruments 83  
 of loss of tooth material 120
- Restorative  
 resins 258  
 technique for composites 220
- Restoring instruments 74
- Retainerless automatrix system 110
- Ridge 2
- Role of dental plaque 53
- Root  
 canal 46  
 sealers 292  
 caries 33, 57  
 surface caries 66
- Rotary cutting  
 and abrasive instruments 74  
 instruments 89
- Rotated teeth 194
- Rubber ended rotary tools 99
- S**
- 
- Saliva 55
- Sclerotic dentin 41, 42
- Second  
 molar 11, 20  
 premolar 8, 17
- Secondary  
 dentin 41, 42  
 resistance and retention form 197
- Selection of amalgam alloy 171, 199
- Serial root canal preparation 285
- Sets of teeth 27
- Setting expansion 171
- Setting reaction of  
 amalgam 165  
 autocure glass ionomer cement 156  
 resin modified glass ionomers 157  
 zinc oxide eugenol cement 146
- Severe caries 60
- Shade of composite 214
- Shank 75  
 design 92
- Shape of abrasive particles 98
- Shaping 283
- Sharpening of hand instruments 88
- Significance of working length 279
- Silver 164  
 nitrate 67, 70
- Simple  
 caries 59  
 tooth preparation 121
- Sites of dental caries 51
- Size of abrasive particles 98
- Small cement spatula 83
- Smart  
 composites 210  
 prep burs 96
- Smooth  
 broaches 263  
 surface caries 33, 57, 60
- Sodium hypochlorite 282
- Soft steel 73
- Solubility 211
- Special forms of chisel 74
- Specific plaque hypothesis 53
- Speed of  
 caries progression 58  
 rotation 252
- Spherical alloy 167
- Spiral angle 96
- Spoon excavator 82
- Spruing 241
- S-shaped matrix band 111
- Stainless steel 73  
 burs 91
- Step back technique 285, 290
- Steps in tooth preparation 129
- Steps of  
 amalgam restoration 171, 199  
 tooth preparation for inlay 232
- Straight  
 chisel 79  
 explorer 78  
 handpiece 90  
 handpiece shank 92
- Strength 38
- Streptococcus mutans* 56
- Structure of  
 dentin 41  
 teeth 36
- Structure present in enamel 38
- Subtraction radiography 280
- Sugar substitutes 67
- Sulcus 2
- Surface  
 texture 211  
 zone 62
- T**
- 
- Technique for  
 making cast metal restoration 239  
 using resin cements 161
- Technique of  
 placing bonded amalgam 170  
 root canal preparation 285
- Telescopic canal preparation 285
- Tempering heat treatment 73

Temporary restoration 239  
 Terminology of tooth preparation 121  
 Tertiary dentin 42  
 Test for trituration 173  
 Theories of dental caries 53  
 Thermal conductivity 168  
 Thickness of enamel 37  
 Tin 164  
 Tofflemire  
   matrix 106  
   universal matrix band retainer 106  
 Tooth  
   numbering systems 27  
   preparation for  
     amalgam restoration 185  
     class I amalgam restoration 185  
     composite restorations 216  
   preparation 126, 193  
     margin 123  
     walls 122  
     separation 103, 113  
 Toothbrushing 68  
 Trace elements 67  
 Transeptal fibers 48  
 Translucent zone 61  
 Transparent crown forms matrices 113  
 Transverse ridge 2  
 Treatment of pits and fissures 139  
 Triangular ridges 2  
 Trituration 199  
 Trying in casting 243  
 T-shaped matrix band 110  
 Tubercle 2  
 Tuned aperture computerized tomography 64  
 Tungsten carbide burs 91  
 Tweezers 79  
 Types of  
   amalgam powder 166  
   bands 108  
   bevel 230  
   composite resins 205

explorer 78  
 filler 215  
 handpiece 90  
 resin cements 161  
 restoration 120  
 rotary cutting 89  
 wedges 116  
 ZOE 148

## U

Ultrasonic  
   imaging 64  
   instruments 100  
 Ultraviolet illumination 64  
 Undifferentiated mesenchymal cells 45  
 Universal system 28  
 Uses of  
   air abrasion technology 139  
   broach 264  
   burnishers 85  
   dental cements 145  
   mouth mirror 78  
   zinc  
     phosphate cement 150  
     polycarboxylate cement 152  
 UV absorbers 204

## V

Varnish 255  
 Vertical compaction technique 294  
 Visual  
   contact with bur head 96  
   examination 64  
 Vitamin  
   A 56  
   B 56  
   C 56  
   content of diet 56  
   D 56  
   K 56

## W

Washing of wax pattern 242  
 Water  
   absorption 210  
   driven handpiece 90  
   sensitivity 158  
   settable glass ionomer 153  
 Wax pattern fabrication 241  
 Wear resistance 210  
 Wedge wedging 117  
 Weine's method 280  
 Wooden wedges 116  
 Woodsticks and interdental brushes 68  
 Working length determination 279

## X

Xeroradiography 63, 280  
 Xerostomia induced rampant caries 58  
 Xylitol 67  
   chewing gums 67

## Z

Zinc 164  
   chloride 67  
   oxide eugenol 257  
   cement 145  
   phosphate cement 148, 257  
   polycarboxylate cement 151  
   silicophosphate cements 151  
 Zones in caries of enamel 61  
 Zones of  
   bacterial invasion 63  
   decalcification of dentin 63  
   decomposed dentin due to acids and enzymes 63  
   dental  
     caries 63  
     sclerosis 63  
 Zsigmondy-Palmer system 27