

Lower Limb

OVERVIEW OF LOWER LIMB / 510

DEVELOPMENT OF LOWER LIMB / 510

BONES OF LOWER LIMB / 512

Arrangement of Lower Limb Bones / 512

Hip Bone / 514

Femur / 516

Tibia and Fibula / 520

Bones of Foot / 522

Surface Anatomy of Bones of Foot / 524

- **BLUE BOX: Bones of Lower Limb.** Lower Limb Injuries; Injuries of Hip Bone; Coxa Vara and Coxa Valga; Dislocated Epiphysis of Femoral Head; Femoral Fractures; Tibial Fractures; Fractures Involving Epiphysal Plates; Fibular Fractures; Bone Grafts; Calcaneal Fractures; Fractures of Talar Neck; Fractures of Metatarsals; Os Trigonum; Fracture of Sesamoid Bones / 525

FASCIA, VEINS, LYMPHATICS, EFFERENT VESSELS, AND CUTANEOUS NERVES OF LOWER LIMB / 532

Subcutaneous Tissue and Fascia / 532

Venous Drainage of Lower Limb / 532

Lymphatic Drainage of Lower Limb / 535

Cutaneous Innervation of Lower Limb / 536

- **TABLE 5.1.** Cutaneous Nerves of Lower Limb / 537

Motor Innervation of Lower Limb / 538

- **BLUE BOX: Fascia, Veins, Lymphatics, and Cutaneous Nerves of Lower Limb.** Compartment Syndromes and Fasciotomy; Varicose Veins, Thrombosis, and Thrombophlebitis; Saphenous Vein Grafts; Saphenous Cutdown and Saphenous Nerve Injury; Enlarged Inguinal Lymph Nodes; Regional Nerve

Blocks of Lower Limbs; Abnormalities of Sensory Function / 540

POSTURE AND GAIT / 542

Standing at Ease / 542

Walking: The Gait Cycle / 542

- **TABLE 5.2.** Muscle Action During Gait Cycle / 543

ANTERIOR AND MEDIAL REGIONS OF THIGH / 545

Organization of Proximal Lower Limb / 545

Anterior Thigh Muscles / 545

- **TABLE 5.3.I.** Muscles of Anterior Thigh: Flexors of Hip Joint / 546

- **TABLE 5.3.II.** Muscles of Anterior Thigh: Extensors of Knee / 547

Medial Thigh Muscles / 548

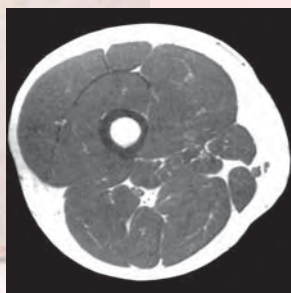
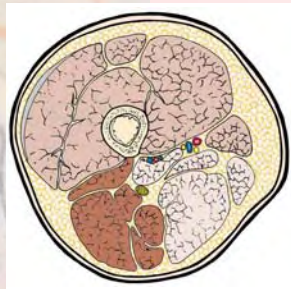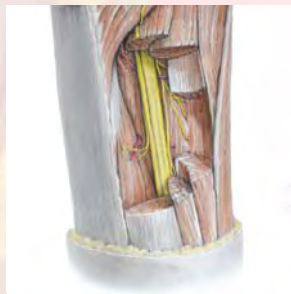- **TABLE 5.4.** Muscles of Medial Thigh: Adductors of Thigh / 549

Neurovascular Structures and Relationships in Anteromedial Thigh / 551

- **TABLE 5.5.** Arteries of Anterior and Medial Thigh / 555

Surface Anatomy of Anterior and Medial Regions of Thigh / 557

- **BLUE BOX: Anterior and Medial Regions of Thigh.** Hip and Thigh Contusions; Psoas Abscess; Paralysis of Quadriceps; Chondromalacia Patellae; Patellar Fractures; Abnormal Ossification of Patella; Patellar Tendon Reflex; Transplantation of Gracilis; Groin Pull; Injury to Adductor Longus; Palpation, Compression, and Cannulation of Femoral Artery; Laceration of Femoral Artery; Potentially Lethal Misnomer; Saphenous Varix; Location of Femoral Vein; Cannulation of Femoral Vein; Femoral Hernias; Replaced or Accessory Obturator Artery / 558



GLUTEAL AND POSTERIOR THIGH REGIONS / 562

Gluteal Region: Buttocks and Hip Region / 562

Muscles of the Gluteal Region / 563

- **TABLE 5.6.** Muscles of Gluteal Region: Abductors and Rotators of Thigh / 564

Posterior Thigh Region / 569

- **TABLE 5.7.** Muscles of Posterior Thigh: Extensors of Hip and Flexors of Knee / 570

Neurovascular Structures of Gluteal and Posterior Thigh Regions / 572

- **TABLE 5.8.** Nerves of Gluteal and Posterior Thigh Regions / 573

- **TABLE 5.9.** Arteries of Gluteal and Posterior Thigh Regions / 576

Surface Anatomy of Gluteal and Posterior Thigh Regions / 578

- **BLUE BOX: Gluteal and Posterior Thigh Regions.** Trochanteric Bursitis; Ischial Bursitis; Hamstring Injuries; Injury to Superior Gluteal Nerve; Anesthetic Block of Sciatic Nerve; Injury to Sciatic Nerve; Intragluteal Injections / 581

POPLITEAL FOSSA AND LEG / 584

Popliteal Region / 584

Anterior Compartment of Leg / 587

- **TABLE 5.10.** Muscles of Anterior and Lateral Compartments of Leg / 591

- **TABLE 5.11.** Nerves of Leg / 593

- **TABLE 5.12.** Arteries of Leg / 594

Lateral Compartment of Leg / 595

Posterior Compartment of Leg / 596

- **TABLE 5.13.I.** Superficial Muscles of Posterior Compartment of Leg / 597

- **TABLE 5.13.II.** Deep Muscles of Posterior Compartment of Leg / 598

Surface Anatomy of Leg / 603

- **BLUE BOX: Popliteal Fossa and Leg.** Popliteal Abscess and Tumor; Popliteal Pulse; Popliteal Aneurysm and Hemorrhage; Injury to Tibial Nerve; Containment and Spread of Compartmental Infections in the Leg; Tibialis Anterior Strain (Shin Splints); Fibularis Muscles and Evolution of the Human Foot; Injury to Common Fibular Nerve and Foot-drop; Deep Fibular Nerve Entrapment; Superficial Fibular Nerve Entrapment; Fabella in Gastrocnemius; Calcaneal Tendinitis; Ruptured Calcaneal Tendon; Calcaneal Tendon Reflex; Absence of Plantarflexion; Gastrocnemius Strain;

Calcaneal Bursitis; Venous Return From Leg; Accessory Soleus; Posterior Tibial Pulse / 604

FOOT / 609

Skin and Fascia of Foot / 610

Muscles of Foot / 610

- **TABLE 5.14.I.** Muscles of Foot: 1st and 2nd Layers of Sole / 612

- **TABLE 5.14.II.** Muscles of Foot: 3rd and 4th Layers of Sole / 613

- **TABLE 5.14.III.** Muscles of Foot: Dorsum of Foot / 614

Neurovascular Structures and Relationships in Foot / 614

- **TABLE 5.15.** Nerves of Foot / 618

Surface Anatomy of Ankle Region and Foot / 622

- **BLUE BOX: Foot.** Plantar Fasciitis; Infections of Foot; Contusion of Extensor Digitorum Brevis; Sural Nerve Grafts; Anesthetic Block of Superficial Fibular Nerve; Plantar Reflex; Medial Plantar Nerve Entrapment; Palpation of Dorsalis Pedis Pulse; Hemorrhaging Wounds of Sole of Foot; Lymphadenopathy / 624

JOINTS OF LOWER LIMB / 626

Hip Joint / 626

Knee Joint / 634

- **TABLE 5.16.** Movements of Knee Joint and Muscles Producing Them / 643

Tibiofibular Joints / 645

- **TABLE 5.17.** Bursae Around Knee Region / 646

Ankle Joint / 647

Foot Joints / 650

- **TABLE 5.18.** Joints of Foot / 652

- **TABLE 5.19.** Movements of Joints of Forefoot and Muscles Producing Them / 653

Surface Anatomy of Joints of Knee, Ankle, and Foot / 656

- **BLUE BOX: Joints of Lower Limb.** Bipedalism and Congruity of Articular Surfaces of Hip Joint; Fractures of Femoral Neck; Surgical Hip Replacement; Necrosis of Femoral Head in Children; Dislocation of Hip Joint; Genu Valgum and Genu Varum; Patellar Dislocation; Patellofemoral Syndrome; Knee Joint Injuries; Arthroscopy of Knee Joint; Aspiration of Knee Joint; Bursitis in Knee Region; Popliteal Cysts; Knee Replacement; Ankle Injuries; Tibial Nerve Entrapment; Hallux Valgus; Hammer Toe; Claw Toes; Pes Planus (Flatfeet); Clubfoot (Talipes equinovarus) / 659

OVERVIEW OF LOWER LIMB

The **lower limbs** (extremities) are extensions from the trunk specialized to support body weight, for *locomotion* (the ability to move from one place to another), and to maintain balance.

The lower limbs have six major regions (Fig. 5.1):

1. The **gluteal region** (*G. glutos*, buttocks) is the transitional region between the trunk and free lower limbs. It

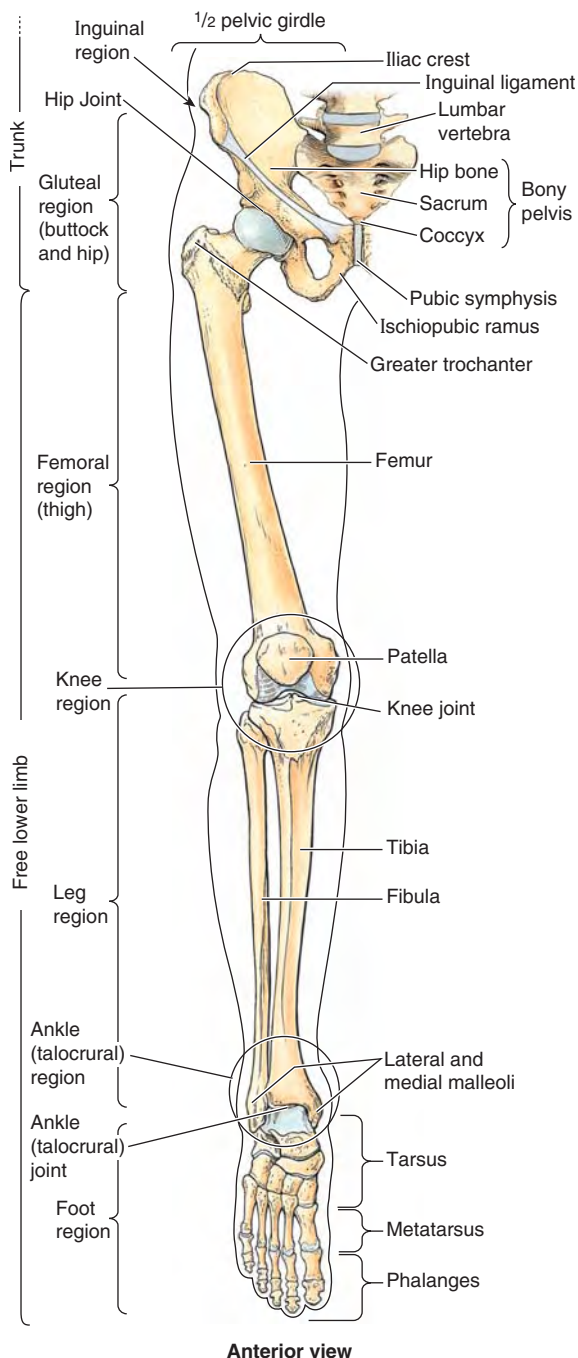


FIGURE 5.1. Regions and bones of lower limb.

includes two parts of the lower limb: the rounded, prominent posterior region, the **buttocks** (*L. nates, chunes*), and the lateral, usually less prominent **hip region** (*L. regio coxae*), which overlies the hip joint and greater trochanter of the femur. The “width of the hips” in common terminology is a reference to one’s transverse dimensions at the level of the greater trochanters. The gluteal region is bounded superiorly by the iliac crest, medially by the **intergluteal cleft**, and inferiorly by the skin fold (groove) underlying the buttock, the **gluteal fold** (*L. sulcus glutealis*). The gluteal muscles, overlying the pelvic girdle, constitute the bulk of this region.

2. The **femoral region** (thigh) is the region of the free lower limb that lies between the gluteal, abdominal, and perineal regions proximally and the knee region distally. It includes most of the *femur* (thigh bone). The transition from trunk to free lower limb occurs abruptly in the *inguinal region* or *groin*. Here the boundary between the abdominal and perineal regions and the femoral region is demarcated by the *inguinal ligament* anteriorly and the ischiopubic ramus of the *hip bone* (part of the *pelvic girdle* or skeleton of the pelvis) medially. Posteriorly, the gluteal fold separates the gluteal and femoral regions (see Fig. 5.46A).
3. The **knee region** (*L. regio genus*) includes the prominences (condyles) of the distal femur and proximal tibia, the head of the fibula, and the *patella* (knee cap, which lies anterior to the distal end of the femur), as well as the joints between these bony structures. The **posterior region of the knee** (*L. poples*) includes a well-defined, fat-filled hollow, transmitting neurovascular structures, called the *popliteal fossa*.
4. The **leg region** (*L. regio cruris*) is the part that lies between the knee and the narrow, distal part of the leg. It includes most of the *tibia* (shin bone) and *fibula* (calf bone). The **leg** (*L., crus*) connects the knee and foot. Often laypersons refer incorrectly to the entire lower limb as “the leg.”
5. The **ankle** (*L. tarsus*) or **talocrural region** (*L. regio talocruralis*) includes the medial and lateral prominences (*malleoli*) that flank the ankle (talocrural) joint.
6. The **foot** (*L. pes*) or **foot region** (*L. regio pedis*) is the distal part of the lower limb containing the *tarsus*, *metatarsus*, and *phalanges* (toe bones). The **toes** are the **digits of the foot**. The **great toe** (*L. hallux*), like the thumb, has only two *phalanges* (digital bones); the other digits have three.

DEVELOPMENT OF LOWER LIMB

Development of the lower limb is illustrated, explained, and contrasted with that of the upper limb in Figure 5.2. Initially, the development of the lower limb is similar to that of the upper limb, although occurring about a week later. During the 5th week, **lower limb buds** bulge from the lateral aspect of the L2–S2 segments of the trunk (a broader base than for the upper limbs) (Fig. 5.2A). Both limbs initially extend from

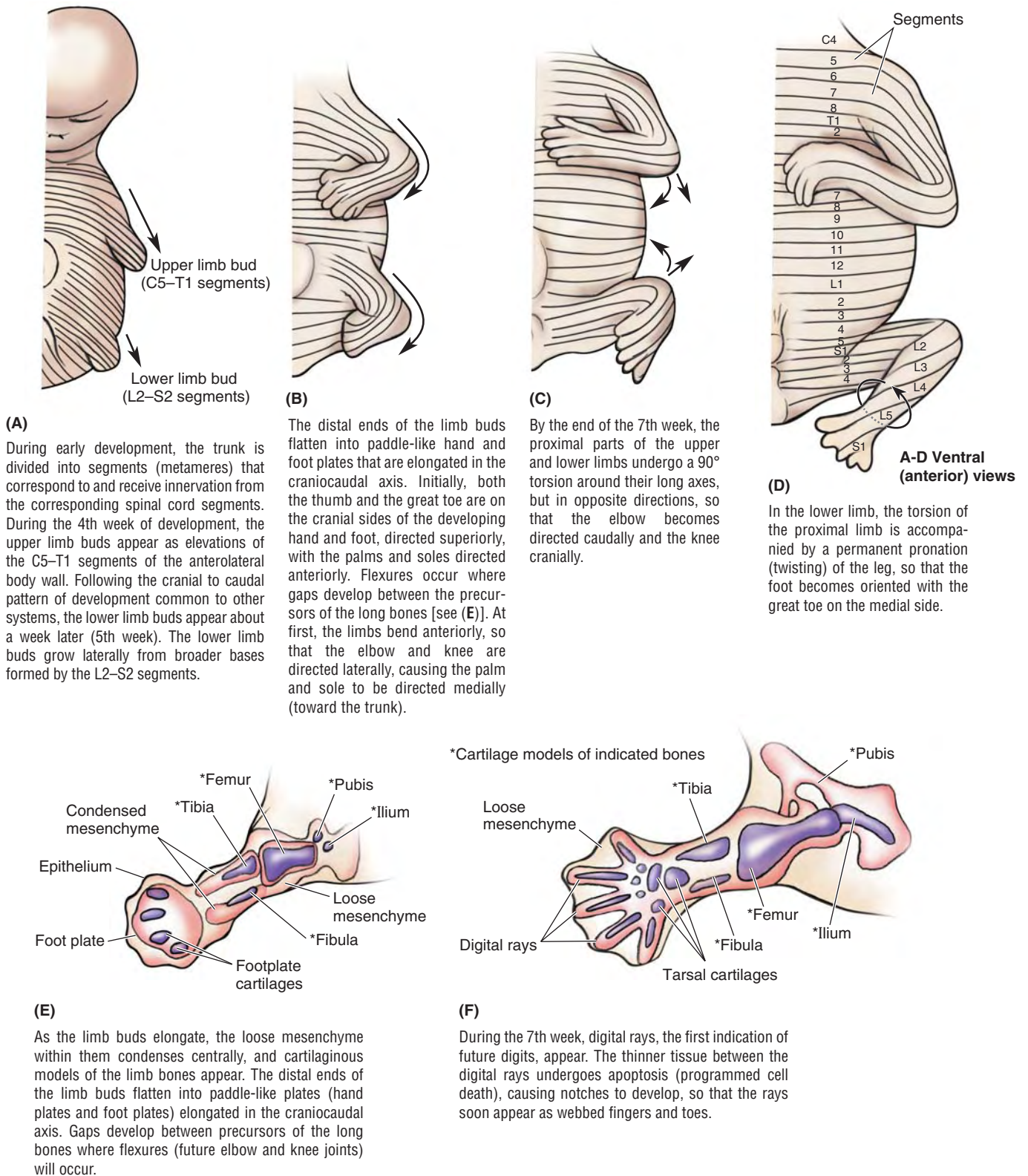


FIGURE 5.2. Development of lower limbs. A–D. The upper and lower limbs develop from limb buds that arise from the lateral body wall during the 4th and 5th weeks, respectively. They then elongate, develop flexures, and rotate in opposite directions. Segmental innervation is maintained, the dermatomal pattern reflecting the elongation and spiraling of the limb. **E and F.** Future bones develop from cartilage models, demonstrated at the end of the 6th week (E) and beginning of the 7th week (F).

the trunk with their developing thumbs and great toes directed superiorly and the palms and soles directed anteriorly. Both limbs then undergo torsion around their long axes, but in opposite directions (Fig. 5.2B–D).

The medial rotation and permanent pronation of the lower limb explain how:

- the knee, unlike the joints superior to it, extends anteriorly and flexes posteriorly, as do the joints inferior to the knee (e.g., interphalangeal joints of the toes);
- the foot becomes oriented with the great toe on the medial side (Fig. 5.2D), whereas the hand (in the anatomical position) becomes oriented with the thumb on the lateral side; and
- the “barber-pole” pattern of the segmental innervation of the skin (dermatomes) of the lower limb develops (see “Cutaneous Innervation of Lower Limb,” p. 536).

The torsion and twisting of the lower limb is still in progress at birth (note the way babies’ feet tend to meet sole to sole when they are brought together, like clapping). Completion of the process coincides with the mastering of walking skills.

BONES OF LOWER LIMB

The skeleton of the lower limb (inferior appendicular skeleton) may be divided into two functional components: the pelvic girdle and the bones of the free lower limb (Fig. 5.1). The **pelvic girdle** (bony pelvis) is a bony ring composed of the sacrum and right and left hip bones joined anteriorly at the pubic symphysis.

The pelvic girdle attaches the free lower limb to the axial skeleton, the sacrum being common to the axial skeleton and the pelvic girdle. The pelvic girdle also makes up the skeleton of the lower part of the trunk. Its protective and supportive functions serve the abdomen, pelvis, and perineum as well as the lower limbs. The bones of the free lower limb are contained within and specifically serve that part of the limb.

Arrangement of Lower Limb Bones

Body weight is transferred from the vertebral column through the *sacroiliac joints* to the pelvic girdle and from the pelvic girdle through the hip joints to the femurs (*L. femora*) (Fig. 5.3A).

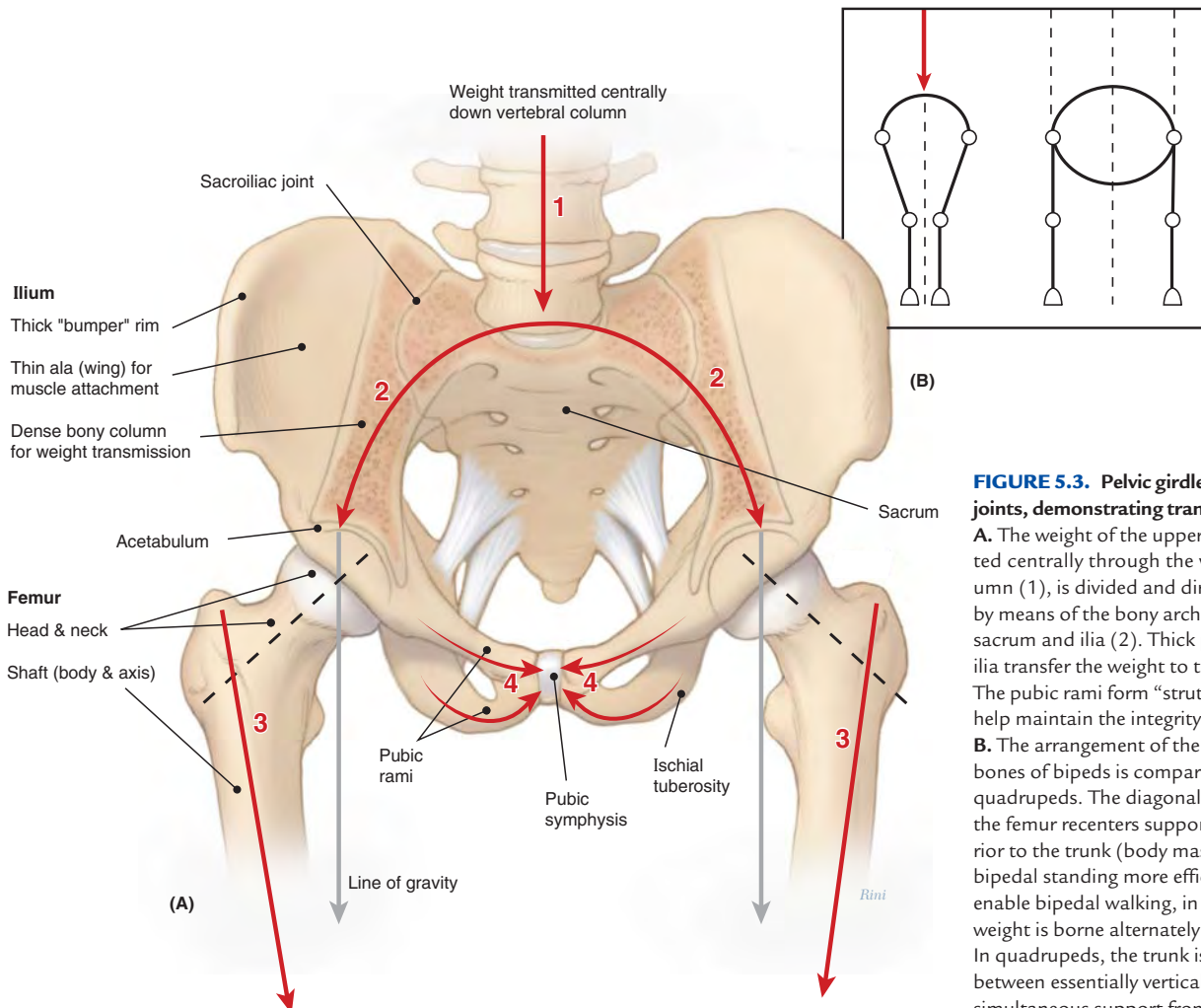


FIGURE 5.3. Pelvic girdle and related joints, demonstrating transfer of weight.

A. The weight of the upper body, transmitted centrally through the vertebral column (1), is divided and directed laterally by means of the bony arch formed by the sacrum and ilia (2). Thick portions of the ilia transfer the weight to the femurs (3). The pubic rami form “struts” or braces that help maintain the integrity of the arch (4). **B.** The arrangement of the lower limb bones of bipeds is compared to that of quadrupeds. The diagonal disposition of the femur recenters support directly inferior to the trunk (body mass) to make bipedal standing more efficient and to enable bipedal walking, in which the full weight is borne alternately by each limb. In quadrupeds, the trunk is suspended between essentially vertical limbs, requiring simultaneous support from each side.

To support the erect bipedal posture better, the femurs are oblique (directed inferomedially) within the thighs so that when standing the knees are adjacent and placed directly inferior to the trunk, returning the center of gravity to the vertical lines of the supporting legs and feet (Figs. 5.1, 5.3, and 5.4). Compare

this oblique position of the femurs with that of quadrupeds, in whom the femurs are vertical and the knees are apart, with the trunk mass suspended between the limbs (Fig. 5.3B).

The femurs of human females are slightly more oblique than those of males, reflecting the greater width of their pelvises.

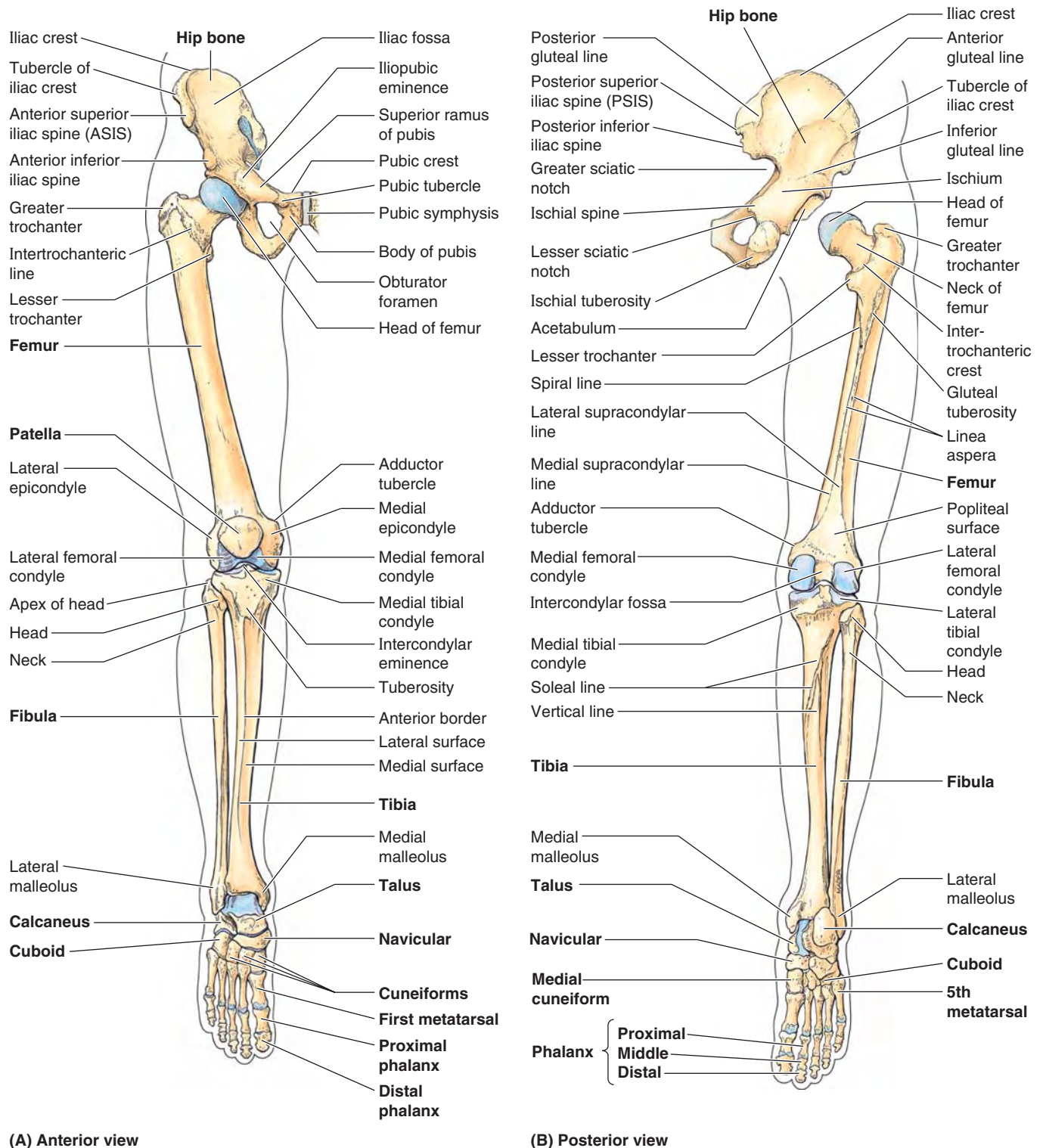


FIGURE 5.4. Bones of lower limb. **A and B.** Individual bones and bony formations are identified. The foot is in full plantarflexion. The hip joint is disarticulated (**B**) to demonstrate the acetabulum of the hip bone, which receives the head of the femur.

At the knees, the distal end of each femur articulates with the patella and tibia of the corresponding leg. Weight is transferred from the knee joint to the ankle joint by the tibia. The fibula does not articulate with the femur and does not bear or transfer weight, but it provides for muscle attachment and contributes to the formation of the ankle joint.

At the ankle, the weight borne by the tibia is transferred to the *talus* (Fig. 5.4). The talus is the keystone of a longitudinal arch formed by the tarsal and metatarsal bones of each foot that distributes the weight evenly between the heel and the forefoot when standing, creating a flexible but stable platform to support the body.

Hip Bone

The mature **hip bone** (*L. os coxae*) is the large, flat pelvic bone formed by the fusion of three primary bones—*ilium*, *ischium*, and *pubis*—at the end of the teenage years. Each of the three bones is formed from its own primary center of ossification; five secondary centers of ossification appear later.

At birth, the three primary bones are joined by hyaline cartilage; in children, they are incompletely ossified (Fig. 5.5). At puberty, the three bones are still separated by a Y-shaped **triradiate cartilage** centered in the acetabulum, although the two parts of the ischiopubic rami fuse by the 9th year (Fig. 5.5B). The bones begin to fuse between 15 and 17 years of age; fusion is complete between 20 and 25 years of age. Little or no trace of the lines of fusion of the primary bones is visible in older adults (Fig. 5.6). Although the bony components are rigidly fused, their names are still used in adults to describe the three parts of the hip bone.

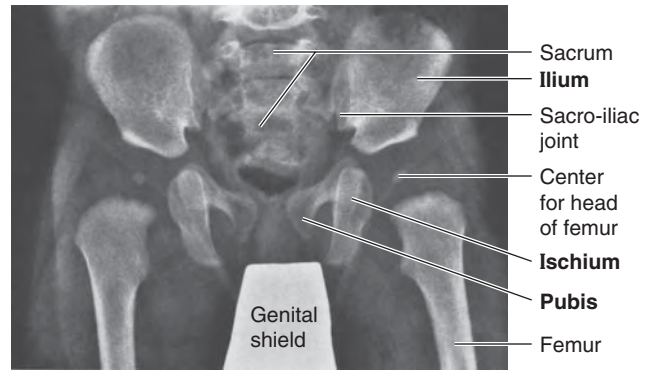
Because much of the medial aspect of the hip bones/bony pelvis is primarily concerned with pelvic and perineal structures and functions (Chapter 3) or their union with the vertebral column (Chapter 4), it is described more thoroughly in those chapters. Aspects of the hip bones concerned with lower limb structures and functions, mainly involving their lateral aspects, are described in this chapter.

ILIUM

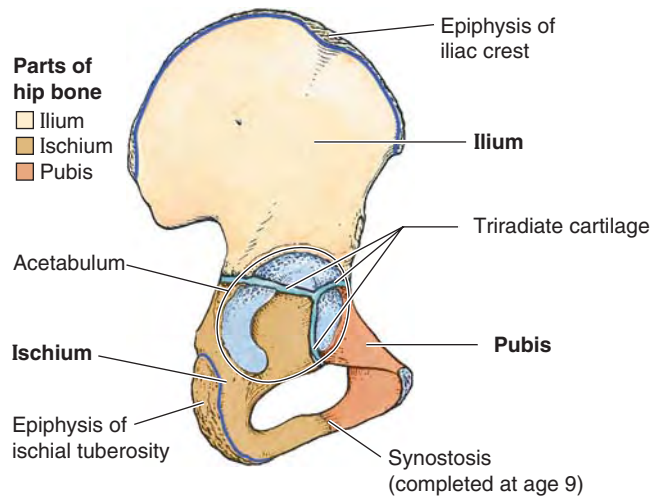
The **ilium** forms the largest part of the hip bone and contributes the superior part of the acetabulum (Fig. 5.5B). The ilium has thick medial portions (columns) for weight bearing and thin, wing-like, posterolateral portions, the **alae** (*L.* wings), that provide broad surfaces for the fleshy attachment of muscles (Fig. 5.3).

The **body of the ilium** joins the pubis and ischium to form the acetabulum. Anteriorly, the ilium has stout **anterior superior** and **anterior inferior iliac spines** that provide attachment for ligaments and tendons of lower limb muscles (Fig. 5.6).

Beginning at the anterior superior iliac spine (ASIS), the long curved and thickened superior border of the ala of the ilium, the **iliac crest**, extends posteriorly, terminating at the **posterior superior iliac spine** (PSIS). The crest serves



(A) Anterior view



(B) Lateral view

FIGURE 5.5. Parts of hip bones. **A.** An anteroposterior radiograph of an infant's hips shows the three parts of the incompletely ossified hip bones (ilium, ischium, and pubis). **B.** The right hip bone of a 13-year-old demonstrating the Y-shaped triradiate cartilage.

as a protective “bumper” and is an important site of aponeurotic attachment for thin, sheet-like muscles and deep fascia. A prominence on the external lip of the crest, the **tubercle of the iliac crest** (iliac tubercle), lies 5–6 cm posterior to the ASIS. The **posterior inferior iliac spine** marks the superior end of the *greater sciatic notch*.

The lateral surface of the ala of the ilium has three rough curved lines—the posterior, anterior, and inferior **gluteal lines**—that demarcate the proximal attachments of the three large gluteal muscles (glutei). Medially, each ala has a large, smooth depression, the **iliac fossa** (Fig. 5.6B), that provides proximal attachment for the iliacus muscle. The bone forming the superior part of this fossa may become thin and translucent, especially in older women with osteoporosis.

Posteriorly, the medial aspect of the ilium has a rough, ear-shaped articular area called the **auricular surface** (*L. auricula*, a little ear) and an even rougher **iliac tuberosity** superior to it for synovial and syndesmotomic articulation with the reciprocal surfaces of the sacrum at the sacroiliac joint.

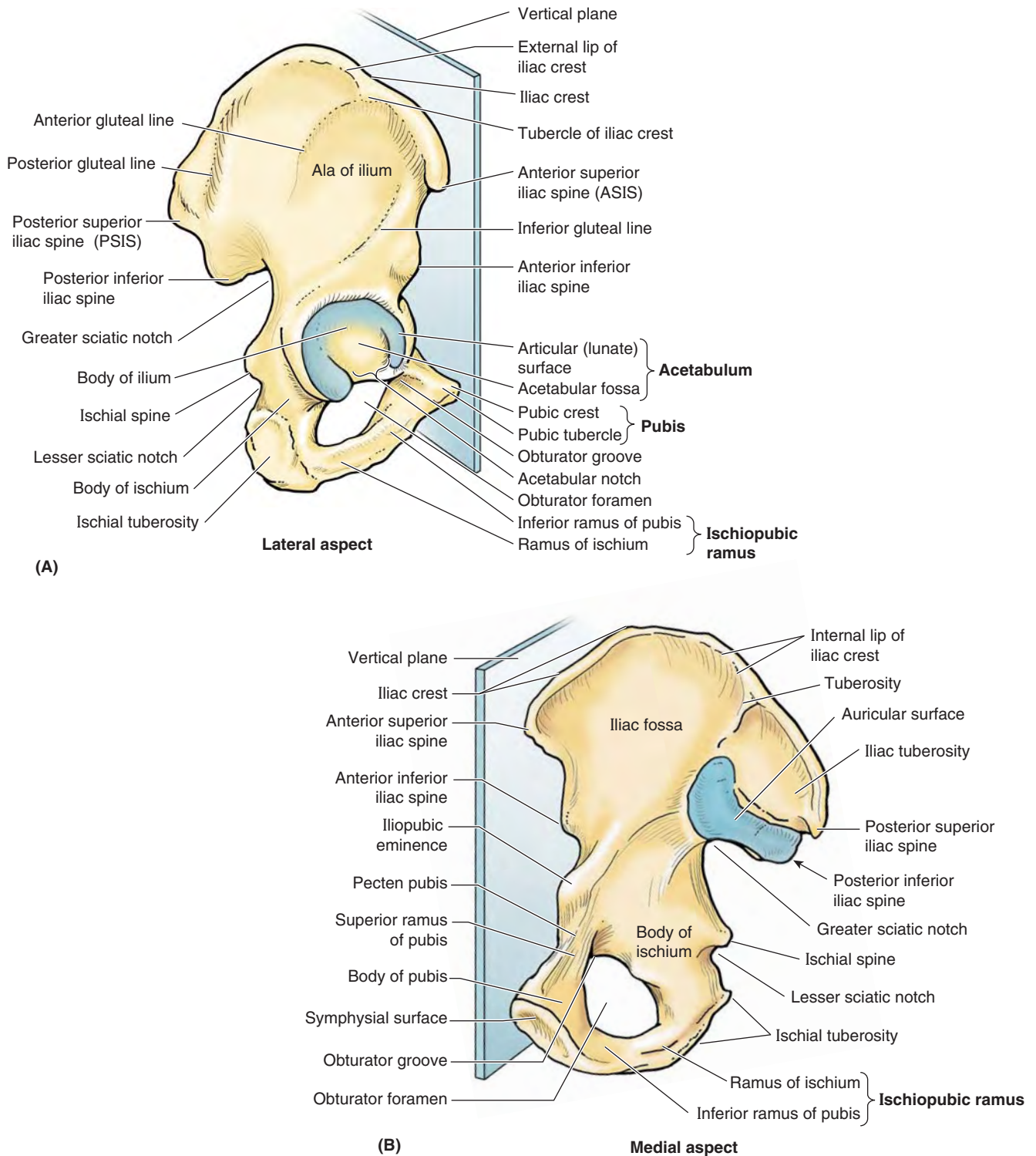


FIGURE 5.6. Right hip bone of adult in anatomical position. In this position, the anterior superior iliac spine (ASIS) and the anterior aspect of the pubis lie in the same coronal plane (blue). **A.** The large hip bone is constricted in the middle and expanded at its superior and inferior ends. **B.** The symphyseal surface of the pubis articulates with the corresponding surface of the contralateral hip bone. The auricular surface of the ilium articulates with a corresponding surface of the sacrum to form the sacroiliac joint.

ISCHIUM

The **ischium** forms the posteroinferior part of the hip bone. The superior part of the **body of the ischium** fuses with the pubis and ilium, forming the posteroinferior aspect of the acetabulum. The **ramus of the ischium** joins the *inferior ramus of the pubis* to form a bar of bone, the **ischiopubic ramus** (Fig. 5.6A), which constitutes the inferomedial boundary of the *obturator foramen*. The posterior border of the ischium forms the inferior margin of a deep indentation called the **greater sciatic notch**. The large, triangular **ischial spine** at the inferior margin of this notch provides ligamentous attachment. This sharp demarcation separates the greater sciatic notch from a more inferior, smaller, rounded, and smooth-surfaced indentation, the **lesser sciatic notch**. The lesser sciatic notch serves as a trochlea or pulley for a muscle that emerges from the bony pelvis. The rough bony projection at the junction of the inferior end of the body of the ischium and its ramus is the large **ischial tuberosity**. The body's weight rests on this tuberosity when sitting, and it provides the proximal, tendinous attachment of posterior thigh muscles.

PUBIS

The **pubis** forms the anteromedial part of the hip bone, contributing the anterior part of the acetabulum, and provides proximal attachment for muscles of the medial thigh. The pubis is divided into a flattened medially placed **body** and **superior** and **inferior rami** that project laterally from the body (Fig. 5.6).

Medially, the **symphyseal surface** of the body of the pubis articulates with the corresponding surface of the body of the contralateral pubis by means of the pubic symphysis. The anterosuperior border of the united bodies and symphysis forms the **pubic crest**, which provides attachment for abdominal muscles.

Small projections at the lateral ends of this crest, the **pubic tubercles**, are important landmarks of the inguinal regions. The tubercles provide attachment for the main part of the inguinal ligament and thereby indirect muscle attachment. The posterior margin of the superior ramus of the pubis has a sharp raised edge, the **pecten pubis**, which forms part of the pelvic brim (see Chapter 3).

OBTURATOR FORAMEN

The **obturator foramen** is a large oval or irregularly triangular opening in the hip bone. It is bounded by the pubis and ischium and their rami. Except for a small passageway for the obturator nerve and vessels (the *obturator canal*), the obturator foramen is closed by the thin, strong *obturator membrane*. The presence of the foramen minimizes bony mass (weight) while its closure by the obturator membrane still provides extensive surface area on both sides for fleshy muscle attachment.

ACETABULUM

The **acetabulum** (L., shallow vinegar cup) is the large cup-shaped cavity or socket on the lateral aspect of the hip bone that articulates with the head of the femur to form the hip joint (Fig. 5.6A). All three primary bones forming the hip bone contribute to the formation of the acetabulum.

The margin of the acetabulum is incomplete inferiorly at the **acetabular notch**, which makes the fossa resemble a cup with a piece of its lip missing. The rough depression in the floor of the acetabulum extending superiorly from the acetabular notch is the **acetabular fossa**. The acetabular notch and fossa also create a deficit in the smooth **lunate surface of the acetabulum**, the articular surface receiving the head of the femur.

ANATOMICAL POSITION OF HIP BONE

Surfaces, borders, and relationships of the hip bone are described assuming that the body is in the *anatomical position*. To place an isolated hip bone or bony pelvis in this position, situate it so that the:

- ASIS and the anterosuperior aspect of the pubis lie in the same coronal plane.
- Symphyseal surface of the pubis is vertical, parallel to the median plane (Fig. 5.6).

In the anatomical position, the:

- Acetabulum faces inferolaterally, with the acetabular notch directed inferiorly.
- Obturator foramen lies inferomedial to the acetabulum.
- Internal aspect of the body of the pubis faces almost directly superiorly. (It essentially forms a floor on which the urinary bladder rests.)
- Superior pelvic aperture (pelvic inlet) is more vertical than horizontal; in the anteroposterior (AP) view, the tip of the coccyx appears near its center (Fig. 5.3).

Femur

The **femur** is the longest and heaviest bone in the body. It transmits body weight from the hip bone to the tibia when a person is standing (Fig. 5.4). Its length is approximately a quarter of the person's height. The femur consists of a **shaft** (body) and two ends, superior or proximal and inferior or distal (Fig. 5.7).

The superior (proximal) end of the femur consists of a head, neck, and two trochanters (greater and lesser). The round **head of the femur** makes up two thirds of a sphere that is covered with articular cartilage, except for a medially placed depression or pit, the **fovea for the ligament of the head**. In early life, the ligament gives passage to an artery supplying the epiphysis of the head. The **neck of the femur** is trapezoidal, with its narrow end supporting the head and its broader base being continuous with the shaft. Its average diameter is three quarters that of the femoral head.

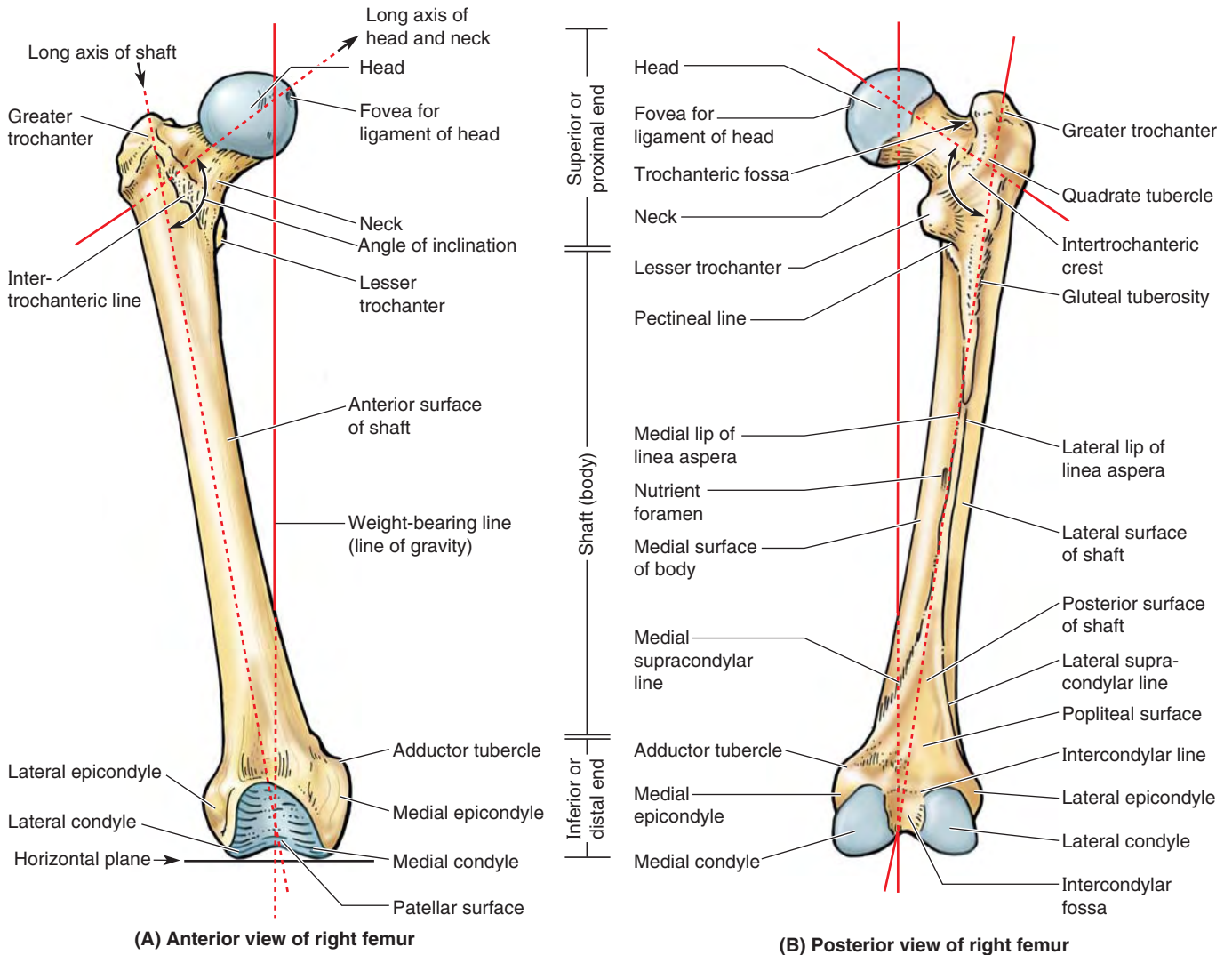


FIGURE 5.7. Right femur. A and B. The bony features of an adult femur are shown. Functionally and morphologically, the bone consists of highly modified superior and inferior ends and an intervening cylindrical shaft. A–E. The femur is “bent” so that the long axis of the head and neck lies at an angle (angle of inclination) to that of the shaft. When the massive femoral condyles rest on a horizontal surface, the femur assumes its oblique anatomical position in which the center of the round femoral head lies directly superior to the intercondylar fossa. C–E. The angle of inclination decreases (becomes more acute) with age, resulting in greater stress at a time when bone mass is reduced. When the femur is viewed along the long axis of the femoral shaft, so that the proximal end is superimposed over the distal end (F), it can be seen that the axis of the head and neck of the femur forms a 12° angle with the transverse axis of the femoral condyles (angle of torsion).

The proximal femur is “bent” (L-shaped) so that the long axis of the head and neck projects superomedially at an angle to that of the obliquely oriented shaft (Fig. 5.7A & B). This obtuse **angle of inclination** is greatest (most nearly straight) at birth and gradually diminishes (becomes more acute) until the adult angle is reached (115–140°, averaging 126°) (Fig. 5.7C–E).

The angle of inclination is less in females because of the increased width between the acetabula (a consequence of a wider lesser pelvis) and the greater obliquity of the femoral shaft. The angle of inclination allows greater mobility of the femur at the hip joint because it places the head and neck more perpendicular to the acetabulum in the neutral position. The abductors and rotators of the thigh attach mainly to the apex of the angle (the *greater trochanter*) so they are pulling on a lever (the short limb of the L) that is directed more laterally than vertically. This provides increased leverage for the abductors and rotators of the thigh and allows the considerable mass of the abductors of the thigh to be placed superior to the femur (in the gluteal region) instead of lateral to it, freeing the lateral aspect of the femoral shaft to provide increased area for the fleshy attachment of the extensors of the knee.

The angle of inclination also allows the obliquity of the femur within the thigh, which permits the knees to be adjacent and inferior to the trunk, as explained previously. All of this is advantageous for bipedal walking; however, it imposes considerable strain on the neck of the femur. Consequently, fractures of the femoral neck can occur in older people as a result of a slight stumble if the neck has been weakened by osteoporosis.

The torsion of the proximal lower limb (femur) that occurred during development does not conclude with the long axis of the superior end of the femur (head and neck) parallel to the transverse axis of the inferior end (femoral condyles). When the femur is viewed superiorly (so that one is looking along the long axis of the shaft), it is apparent that the two axes lie at an angle (the **torsion angle**, or **angle of declination**), the mean of which is 7° in males and 12° in females. The torsion angle, combined with the angle of inclination, allows rotatory movements of the femoral head within the obliquely placed acetabulum to convert into flexion and extension, abduction and adduction, and rotational movements of the thigh.

Where the neck joins the femoral shaft are two large, blunt elevations called trochanters (Fig. 5.7A, B, & F). The abrupt, conical and rounded **lesser trochanter** (G., a runner) extends medially from the posteromedial part of the junction of the neck and shaft to give tendinous attachment to the primary flexor of the thigh (the iliopsoas).

The **greater trochanter** is a large, laterally placed bony mass that projects superiorly and posteriorly where the neck joins the femoral shaft, providing attachment and leverage for abductors and rotators of the thigh. The site where the neck and shaft join is indicated by the **intertrochanteric line**, a roughened ridge formed by the attachment of a power-

ful ligament (iliofemoral ligament). The intertrochanteric line runs from the greater trochanter and winds around the lesser trochanter to continue posteriorly and inferiorly as a less distinct ridge, the **spiral line**.

A similar but smoother and more prominent ridge, the **intertrochanteric crest**, joins the trochanters posteriorly. The rounded elevation on the crest is the **quadrate tubercle**. In anterior and posterior views (Fig. 5.7A & B), the greater trochanter is in line with the femoral shaft. In posterior and superior views (Fig. 5.7B & F), it overhangs a deep depression medially, the **trochanteric fossa**.

The **shaft of the femur** is slightly bowed (convex) anteriorly. This convexity may increase markedly, proceeding laterally as well as anteriorly, if the shaft is weakened by a loss of calcium, as occurs in *rickets* (a disease attributable to vitamin D deficiency). Most of the shaft is smoothly rounded, providing fleshy origin to extensors of the knee, except posteriorly where a broad, rough line, the **linea aspera**, provides aponeurotic attachment for adductors of the thigh. This vertical ridge is especially prominent in the middle third of the femoral shaft, where it has **medial** and **lateral lips** (margins). Superiorly, the lateral lip blends with the broad, rough **gluteal tuberosity**, and the medial lip continues as a narrow, rough spiral line.

The **spiral line** extends toward the lesser trochanter but then passes to the anterior surface of the femur, where it is continuous with the intertrochanteric line. A prominent intermediate ridge, the **pectineal line**, extends from the central part of the linea aspera to the base of the lesser trochanter. Inferiorly, the linea aspera divides into medial and lateral **supracondylar lines**, which lead to the medial and lateral femoral condyles (Fig. 5.7B).

The **medial** and **lateral femoral condyles** make up nearly the entire inferior (distal) end of the femur. The two condyles are on the same horizontal level when the bone is in its anatomical position, so that if an isolated femur is placed upright with both condyles contacting the floor or tabletop, the femoral shaft will assume the same oblique position it occupies in the living body (about 9° from vertical in males and slightly greater in females).

The femoral condyles articulate with menisci (crescentic plates of cartilage) and tibial condyles to form the knee joint (Fig. 5.4). The menisci and tibial condyles glide as a unit across the inferior and posterior aspects of the femoral condyles during flexion and extension. The convexity of the articular surface of the condyles increases as it descends the anterior surface, covering the inferior end, and then ascends posteriorly. The condyles are separated posteriorly and inferiorly by an **intercondylar fossa** but merge anteriorly, forming a shallow longitudinal depression, the **patellar surface** (Fig. 5.7), which articulates with the patella. The lateral surface of the lateral condyle has a central projection called the *lateral epicondyle*. The medial surface of the medial condyle has a larger and more prominent *medial epicondyle*, superior to which another elevation, the **adductor tubercle**, forms in relation to a tendon attachment. The epicondyles provide

proximal attachment for the medial and lateral collateral ligaments of the knee joint.

SURFACE ANATOMY OF PELVIC GIRDLE AND FEMUR

Bony landmarks are helpful during physical examinations and surgery because they can be used to evaluate normal development, detect and assess fractures and dislocations, and locate the sites of structures such as nerves and blood vessels.

When your hands are on your hips, they rest on your *iliac crests* (Fig. 5.8A). The anterior third of the crests is easily palpated because the crests are subcutaneous (Fig. 5.8C & D). The posterior two thirds of the crests are more difficult to palpate because they are usually covered with fat. The iliac crest ends anteriorly at the rounded *ASIS* (anterior superior iliac spine), which is easy to palpate by tracing the iliac crest anteroinferiorly. The ASIS is often visible in thin individuals. In obese people these spines are covered with fat and may be

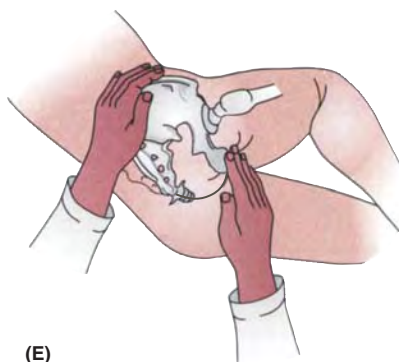
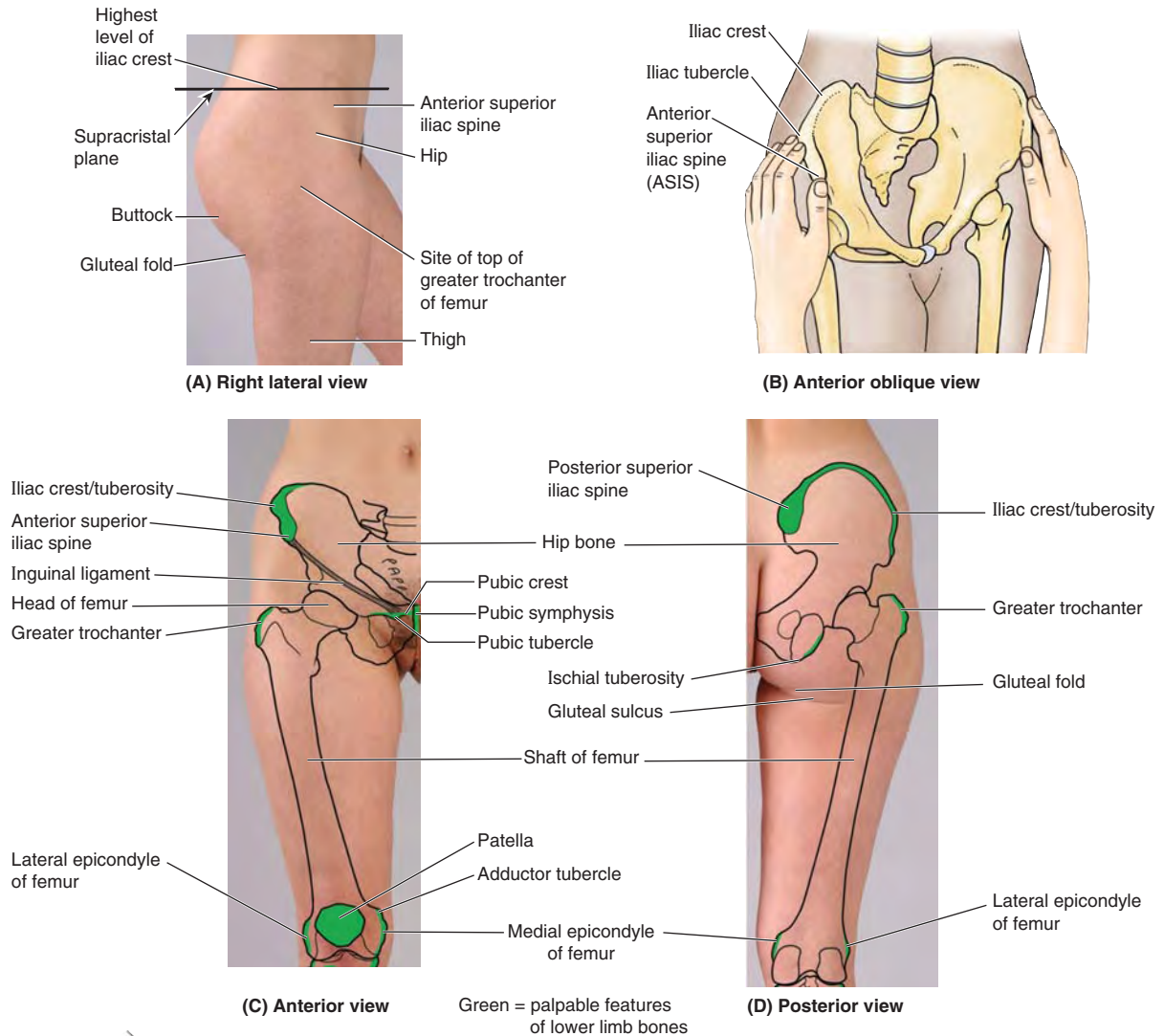


FIGURE 5.8. Surface anatomy of hip bone and femur. **A.** Surface landmarks. **B.** Bimanual palpation of anterior superior iliac spine, used to determine position of pelvis (pelvic tilt). **C and D.** Surface projection and palpable features of hip bone and femur. **E.** Palpation of ischial tuberosity.

difficult to locate; however, they are easier to palpate when the person is sitting and the muscles attached to them are relaxed.

The *iliac tubercle*, 5–6 cm posterior to the ASIS, marks the widest point of the iliac crest. To palpate this tubercle, place your thumb on the ASIS and move your fingers posteriorly along the external lip of the iliac crest (Fig. 5.8B). The iliac tubercle lies at the level of the spinous process of the L5 vertebra.

Approximately a hand's width inferior to the umbilicus, the *bodies* and *superior rami of the pubic bones* may be palpated (Fig. 5.8C). The *pubic tubercle* can be palpated about 2 cm from the pubic symphysis at the anterior extremity of the *pubic crest*. The iliac crest ends posteriorly at the sharp *PSIS* (posterior superior iliac spine) (Fig. 5.8D), which may be difficult to palpate; however, its position is easy to locate because it lies at the bottom of a skin dimple, approximately 4 cm lateral to the midline. The dimple exists because the skin and underlying fascia attach to the PSIS. The skin dimples are useful landmarks when palpating the area of the sacroiliac joints in search of edema (swelling) or local tenderness. These dimples also indicate the termination of the iliac crests from which bone marrow and pieces of bone for grafts can be obtained (e.g., to repair a fractured tibia).

The *ischial tuberosity* is easily palpated in the inferior part of the buttock when the thigh is flexed (Fig. 5.8E). The buttock covers and obscures the tuberosity when the thigh is extended (Fig. 5.8D). The *gluteal fold* coincides with the inferior border of the *gluteus maximus* and indicates the separation of the buttock from the thigh.

The center of the *femoral head* can be palpated deep to a point approximately a thumb's breadth inferior to the midpoint of the inguinal ligament (Fig. 5.8C). The *shaft of the femur* is covered with muscles and is not usually palpable. Only the superior and inferior ends of the femur are palpable. The laterally placed *greater trochanter* projects superior to the junction of the shaft with the femoral neck and can be palpated on the lateral side of the thigh approximately 10 cm inferior to the iliac crest (Fig. 5.8B).

The *greater trochanter* forms a prominence anterior to the hollow on the lateral side of the buttock. The prominences of the greater trochanters are normally responsible for the width of the adult pelvis. The posterior edge of the greater trochanter is relatively uncovered and most easily palpated when the limb is not weight-bearing. The anterior and lateral parts of the trochanter are not easy to palpate because they are covered by fascia and muscle. Because it lies close to the skin, the greater trochanter causes discomfort when you lie on your side on a hard surface. In the anatomical position, a line joining the tips of the greater trochanters normally passes through the pubic tubercles and the center of the femoral heads. The *lesser trochanter* is indistinctly palpable superior to the lateral end of the gluteal fold.

The *femoral condyles* are subcutaneous and easily palpated when the knee is flexed or extended (Fig. 5.8C & D). At the center of the lateral aspect of each condyle is a promi-

nent *epicondyle* that is easily palpable. The patellar surface of the femur is where the *patella* slides during flexion and extension of the leg at the knee joint. The lateral and medial margins of the patellar surface can be palpated when the leg is flexed. The *adductor tubercle*, a small prominence of bone, may be felt at the superior part of the medial femoral condyle by pushing your thumb inferiorly along the medial side of the thigh until it encounters the tubercle.

Tibia and Fibula

The tibia and fibula are the bones of the leg (Figs. 5.4 and 5.9). The *tibia* articulates with the condyles of the femur superiorly and the talus inferiorly and in so doing transmits the body's weight. The *fibula* mainly functions as an attachment for muscles, but it is also important for the stability of the ankle joint. The shafts of the tibia and fibula are connected by a dense **interosseous membrane** composed of strong oblique fibers descending from the tibia to the fibula.

TIBIA

Located on the anteromedial side of the leg, nearly parallel to the fibula, the **tibia** (shin bone) is the second largest bone in the body. It flares outward at both ends to provide an increased area for articulation and weight transfer. The superior (proximal) end widens to form **medial** and **lateral condyles** that overhang the shaft medially, laterally, and posteriorly, forming a relatively flat **superior articular surface**, or *tibial plateau*. This plateau consists of two smooth articular surfaces (the medial one slightly concave and the lateral one slightly convex) that articulate with the large condyles of the femur. The articular surfaces are separated by an **intercondylar eminence** formed by two **intercondylar tubercles** (medial and lateral) flanked by relatively rough **anterior** and **posterior intercondylar areas**.

The tubercles fit into the **intercondylar fossa** between the femoral condyles (Fig. 5.7B). The intercondylar tubercles and areas provide attachment for the menisci and principal ligaments of the knee, which hold the femur and tibia together, maintaining contact between their articular surfaces.

The anterolateral aspect of the lateral tibial condyle bears an **anterolateral tibial tubercle** (Gerdy tubercle) inferior to the articular surface (Fig. 5.9), which provides the distal attachment for a dense thickening of the fascia covering the lateral thigh, adding stability to the knee joint. The lateral condyle also bears a **fibular articular facet** posterolaterally on its inferior aspect for the head of the fibula.

Unlike that of the femur, the **shaft of the tibia** is truly vertical within the leg and somewhat triangular in cross-section, having three surfaces and borders: medial, lateral/interosseous, and posterior.

The **anterior border of the tibia** is the most prominent border. It and the adjacent **medial surface** are subcutaneous throughout their lengths and are commonly known as the "shin"; their periosteal covering and overlying skin are

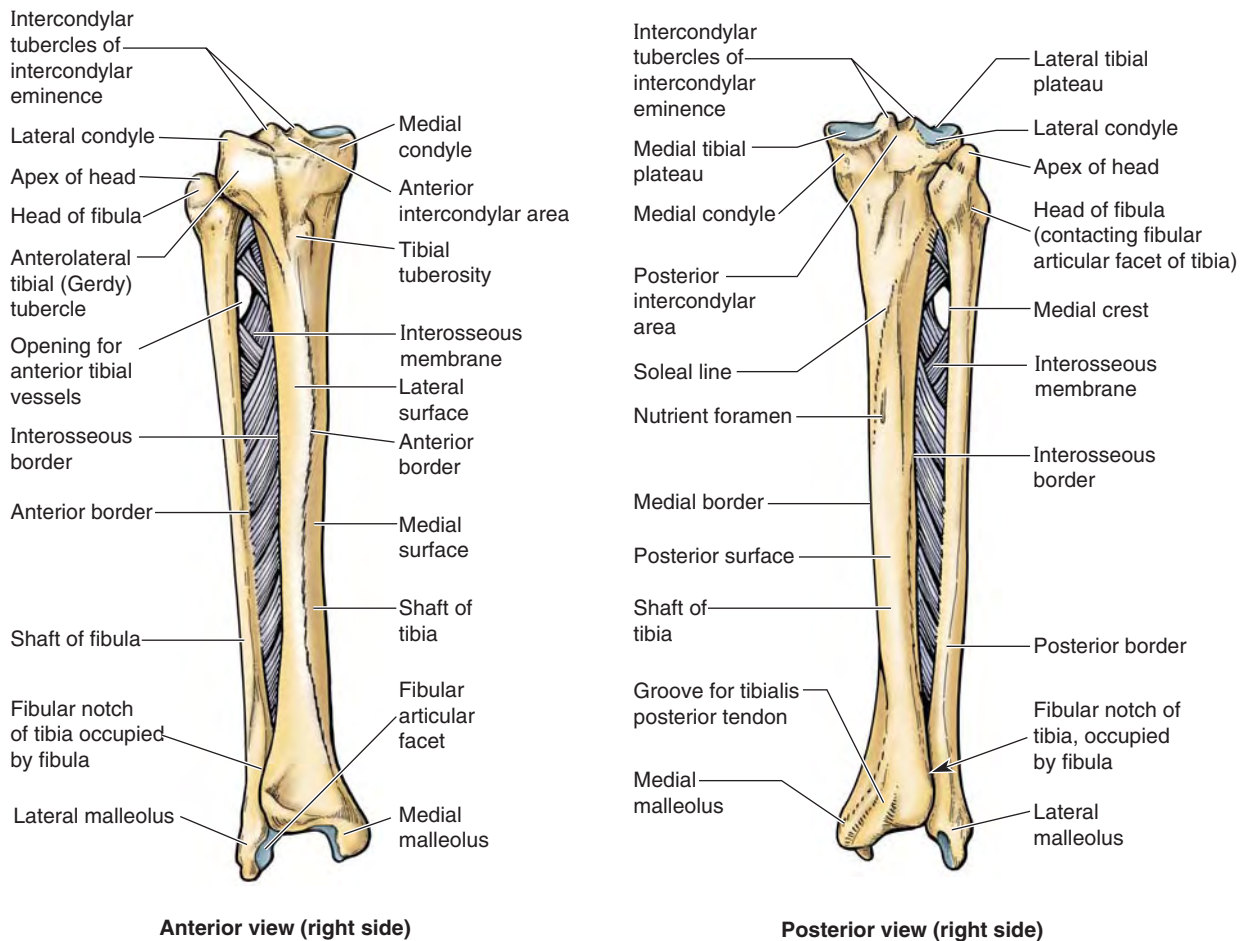


FIGURE 5.9. Right tibia and fibula. Tibiofibular syndesmoses, including the dense interosseous membrane, tightly connect the tibia and fibula. The interosseous membrane also provides additional surface area for muscular attachment. The anterior tibial vessels traverse the opening in the membrane to enter the anterior compartment of the leg.

vulnerable to bruising. At the superior end of the anterior border, a broad, oblong **tibial tuberosity** provides distal attachment for the *patellar ligament*, which stretches between the inferior margin of the patella and the tibial tuberosity.

The tibial shaft is thinnest at the junction of its middle and distal thirds. The distal end of the tibia is smaller than the proximal end, flaring only medially; the medial expansion extends inferior to the rest of the shaft as the **medial malleolus**. The inferior surface of the shaft and the lateral surface of the medial malleolus articulate with the talus and are covered with articular cartilage (Fig. 5.4).

The **interosseous border** of the tibia is sharp where it gives attachment to the *interosseous membrane* that unites the two leg bones. Inferiorly, the sharp border is replaced by a groove, the **fibular notch**, that accommodates and provides fibrous attachment to the distal end of the fibula.

On the posterior surface of the proximal part of the tibial shaft is a rough diagonal ridge, called the **soleal line**, which runs inferomedially to the medial border. This line is formed in relationship to the aponeurotic origin of the soleus muscle approximately one third of the way down the shaft. Immediately distal to the soleal line is an obliquely directed vascular

groove, which leads to a large **nutrient foramen** for passage of the main artery supplying the proximal end of the bone and its marrow. From it, the nutrient canal runs inferiorly in the tibia before it opens into the medullary (marrow) cavity.

FIBULA

The slender **fibula** lies posterolateral to the tibia and is firmly attached to it by the *tibiofibular syndesmosis*, which includes the *interosseous membrane* (Fig. 5.9). The fibula has no function in weight-bearing. It serves mainly for muscle attachment, providing distal attachment (insertion) for one muscle and proximal attachment (origin) for eight muscles. The fibers of the tibiofibular syndesmosis are arranged to resist the resulting net downward pull on the fibula.

The distal end enlarges and is prolonged laterally and inferiorly as the **lateral malleolus**. The malleoli form the outer walls of a rectangular socket (*mortise*), which is the superior component of the ankle joint (Fig. 5.4A), and provide attachment for the ligaments that stabilize the joint. The lateral malleolus is more prominent and posterior than the medial malleolus and extends approximately 1 cm more distally.

The proximal end of the fibula consists of an enlarged **head** superior to a small **neck**. The head has a pointed **apex**. The head of the fibula articulates with the fibular facet on the posterolateral, inferior aspect of the lateral tibial condyle. The **shaft of the fibula** is twisted and marked by the sites of muscular attachments. Like the shaft of the tibia, it is triangular in cross-section, having three borders (anterior, interosseous, and posterior) and three surfaces (medial, posterior, and lateral).

SURFACE ANATOMY OF TIBIA AND FIBULA

The *tibial tuberosity*, an oval elevation on the anterior surface of the tibia, is easily palpated approximately 5 cm distal to the apex of the patella (Fig. 5.10A). The subcutaneous, flat *anteromedial surface of the tibia* is also easy to palpate. The skin covering this surface is freely movable. The *tibial condyles* can be palpated anteriorly at the sides of the patellar ligament, especially when the knee is flexed.

The *head of the fibula* is prominent at the level of the superior part of the tibial tuberosity because the knob-like head is subcutaneous at the posterolateral aspect of the knee. The *neck of the fibula* can be palpated just distal to the lateral side of the fibular head. Doing so may evoke a mildly unpleasant sensation because of the presence of a nerve passing there.

The *medial malleolus*, the prominence on the medial side of the ankle, is also subcutaneous and prominent. Note that its inferior end is blunt and does not extend as far distally as the lateral malleolus. The medial malleolus lies approximately 1.25 cm proximal to the level of the tip of the lateral malleolus.

Only the distal quarter of the shaft of the fibula is palpable. Palpate your *lateral malleolus*, noting that it is subcutaneous and that its inferior end is sharp. Note that the tip of the lateral malleolus extends farther distally and more posteriorly than does the tip of the medial malleolus.

Bones of Foot

The bones of the foot include the *tarsus*, *metatarsus*, and *phalanges*. There are 7 tarsal bones, 5 metatarsal bones, and 14 phalanges (Figs. 5.1, 5.4, and 5.11). Although knowledge of the characteristics of individual bones is necessary for an understanding of the structure of the foot, it is important to study the skeleton of the foot as a whole and to identify its principal bony landmarks in the living foot (see “Surface Anatomy of Bones of Foot,” p. 524, and Surface Anatomy of Ankle Region and Foot,” p. 622).

TARSUS

The **tarsus** (posterior or proximal foot; hindfoot—Fig 5.11C) consists of seven bones (Fig. 5.11A & B): talus, calcaneus, cuboid, navicular, and three cuneiforms. Only one bone, the talus, articulates with the leg bones.

The **talus** (L., ankle bone) has a body, neck, and head (Fig. 5.11D). The superior surface, or **trochlea of the talus**, is gripped by the two malleoli (Fig. 5.4) and receives the weight of the body from the tibia. The talus transmits that weight in turn, dividing it between the calcaneus, on which the **body of talus** rests, and the forefoot, via an osseoligamentous “hammock” that receives the rounded and anteromedially directed

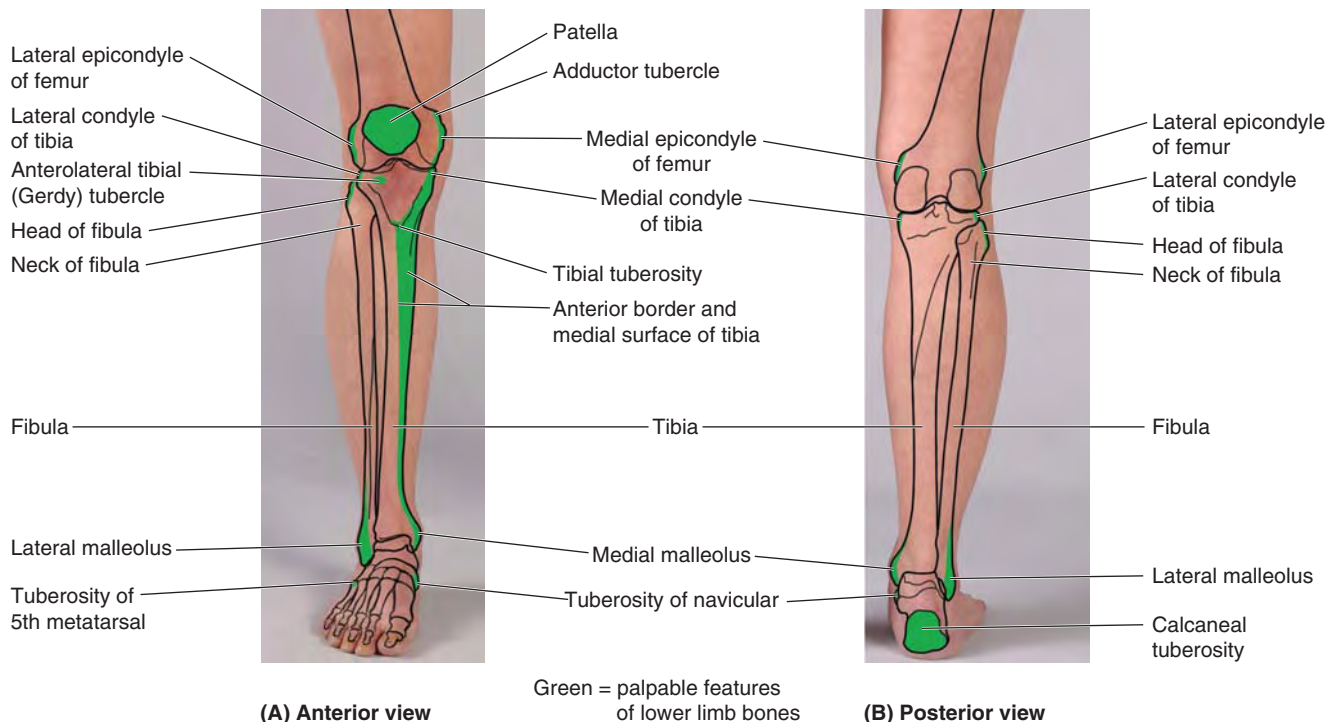
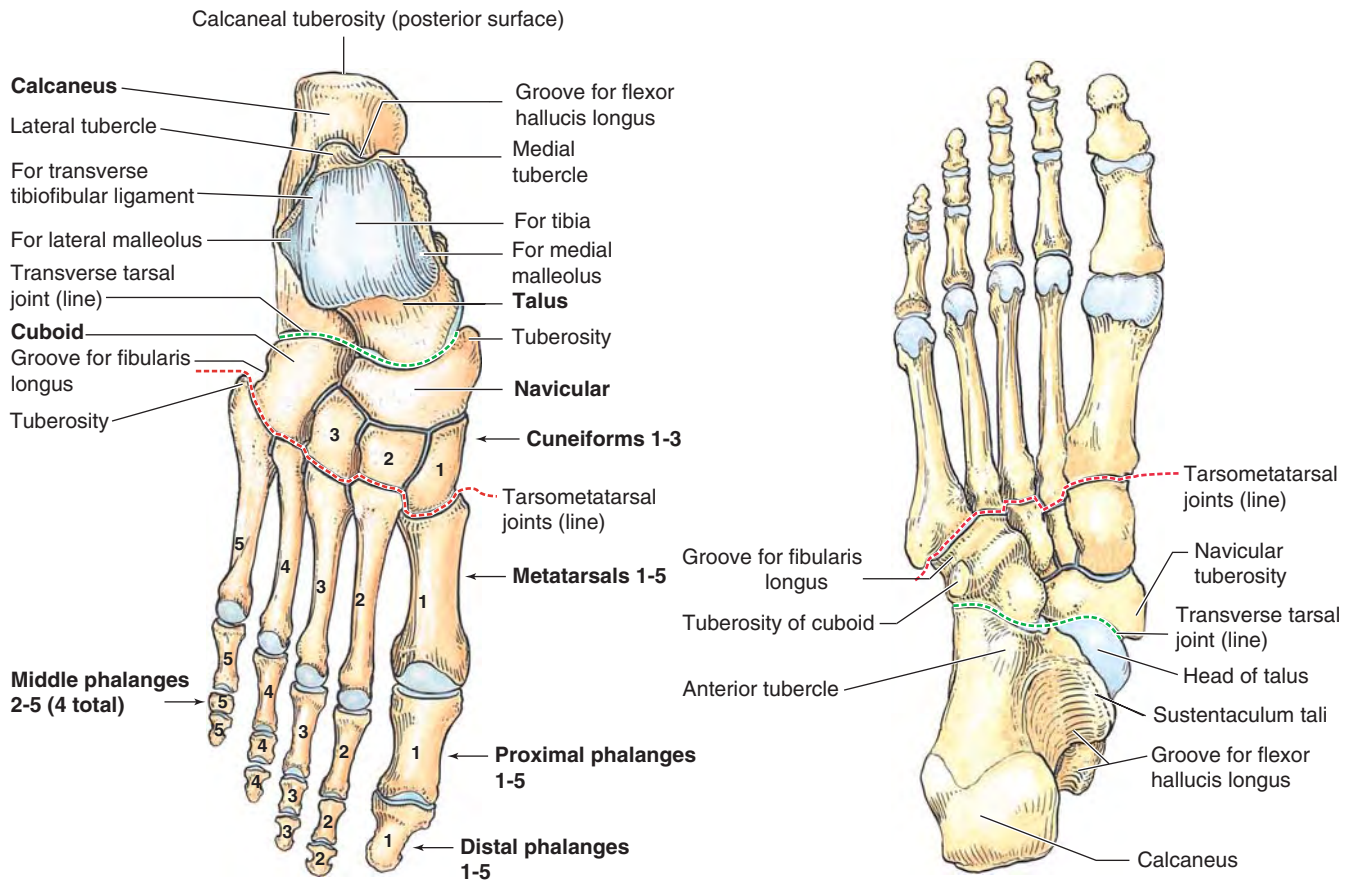
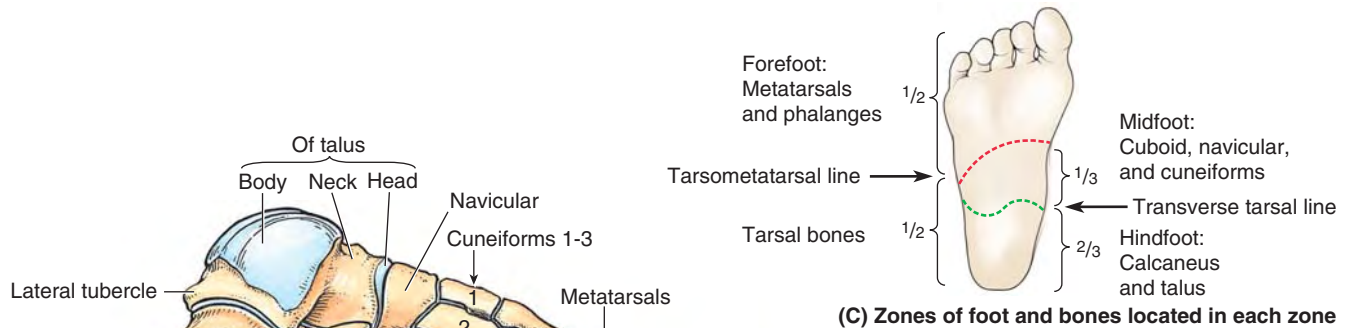


FIGURE 5.10. Surface projection and palpable features of bones of leg, ankle, and heel.



(A) Superior view of dorsum of foot

(B) Inferior view of plantar aspect



(D) Lateral view

(E) Medial view

FIGURE 5.11. Bones of right foot. A, B, D, and E. Bones of foot in four views, demonstrating articular surfaces and major prominences and grooves. **C.** The seven bones of the tarsus make up the posterior half of the foot (hindfoot). The talus and calcaneus occupy the posterior two thirds of the hindfoot, and the cuboid, navicular, and medial, lateral, and intermediate cuneiforms occupy the anterior third. The metatarsus connects the tarsus posteriorly with the phalanges anteriorly. Together, the metatarsus and phalanges make up the anterior half of the foot (forefoot).

head of talus. The hammock (spring ligament) is suspended across a gap between a shelf-like medial projection of the calcaneus (*sustentaculum tali*) and the navicular bone, which lies anteriorly (Fig. 5.11B & E).

The talus is the only tarsal bone that has no muscular or tendinous attachments. Most of its surface is covered with articular cartilage. The talar body bears the trochlea superiorly and narrows into a **posterior process** that features a **groove for the tendon of the flexor hallucis longus** (Fig. 5.11E), flanked by a prominent **lateral tubercle** and a less prominent **medial tubercle** (Fig. 5.11A & D).

The **calcaneus** (L., heel bone) is the largest and strongest bone in the foot (Fig. 5.11). When standing, the calcaneus transmits the majority of the body's weight from the talus to the ground. The anterior two thirds of the calcaneus's superior surface articulates with the talus and its anterior surface articulates with the cuboid.

The lateral surface of the calcaneus has an oblique ridge (Fig. 5.11D), the **fibular trochlea**, that lies between the tendons of the fibularis longus and brevis. This trochlea anchors a tendon pulley for the evertors of the foot (muscles that move the sole of the foot away from the median plane). The **sustentaculum tali** (L., talar shelf), the shelf-like support of the head of the talus, projects from the superior border of the medial surface of the calcaneus (Fig. 5.11B & E). The posterior part of the calcaneus has a massive, weight-bearing prominence, the **calcaneal tuberosity** (L. *tuber calcanei*), which has **medial, lateral, and anterior tubercles**. Only the medial tubercle contacts the ground during standing.

The **navicular** (L., little ship) is a flattened, boat-shaped bone located between the head of the talus posteriorly and the three cuneiforms anteriorly (Fig. 5.11). The medial surface of the navicular projects inferiorly to form the **navicular tuberosity**, an important site for tendon attachment because the medial border of the foot does not rest on the ground, as does the lateral border. Instead, it forms a *longitudinal arch of the foot*, which must be supported centrally. If this tuberosity is too prominent, it may press against the medial part of the shoe and cause foot pain.

The **cuboid**, approximately cubical in shape, is the most lateral bone in the distal row of the tarsus (Fig. 5.11A & D). Anterior to the **tuberosity of the cuboid** on the lateral and inferior surfaces of the bone is a **groove for the tendon of the fibularis** (peroneus) **longus** muscle.

The three cuneiform bones (Fig. 5.11A, D, & E) are the medial (1st), intermediate (2nd), and lateral (3rd). The **medial cuneiform** is the largest bone, and the **intermediate cuneiform** is the smallest. Each cuneiform (L. *cuneus*, wedge shaped) articulates with the navicular posteriorly and the base of its appropriate metatarsal anteriorly. The **lateral cuneiform** also articulates with the cuboid.

METATARSUS

The **metatarsus** (anterior or distal foot, forefoot—Fig. 5.11C) consists of five metatarsals that are numbered from the medial side of the foot (Fig. 5.11A). In the articulated skeleton of the

foot (Figs. 5.1, 5.4, and 5.11), the tarsometatarsal joints form an oblique **tarsometatarsal line** joining the midpoints of the medial and shorter lateral borders of the foot; thus the metatarsals and phalanges are located in the anterior half (forefoot) and the tarsals are in the posterior half (hindfoot) (Fig. 5.11A & C).

The **1st metatarsal** is shorter and stouter than the others. The **2nd metatarsal** is the longest. Each metatarsal has a base proximally, a shaft, and a head distally (Fig. 5.11C). The base of each metatarsal is the larger, proximal end. The bases of the metatarsals articulate with the cuneiform and cuboid bones, and the heads articulate with the proximal phalanges. The bases of the 1st and 5th metatarsals have large tuberosities that provide for tendon attachment; the **tuberosity of the 5th metatarsal** projects laterally over the cuboid. On the plantar surface of the head of the 1st metatarsal are prominent **medial and lateral sesamoid bones** (not shown); they are embedded in the tendons passing along the plantar surface (see the following section on surface anatomy).

PHALANGES

The 14 **phalanges** are as follows: the 1st digit (great toe) has 2 phalanges (proximal and distal); the other four digits have 3 phalanges each: proximal, middle, and distal (Fig. 5.11A & D). Each **phalanx** has a **base** (proximally), a **shaft**, and a **head** (distally). The phalanges of the 1st digit are short, broad, and strong. The middle and distal phalanges of the 5th digit may be fused in elderly people.

Surface Anatomy of Bones of Foot

The *head of the talus* is palpable anteromedial to the proximal part of the lateral malleolus when the foot is inverted, and anterior to the medial malleolus when the foot is everted (Fig. 5.12A). Eversion of the foot makes the talar head more prominent as it moves away from the navicular. The head of the talus occupies the space between the sustentaculum tali and the navicular tuberosity. If the talar head is difficult to palpate, draw a line from the tip of the medial malleolus to the navicular tuberosity; the head of the talus lies deep to the center of this line. When the foot is plantarflexed, the superior surface of the body of the talus can be palpated on the anterior aspect of the ankle, anterior to the inferior end of the tibia.

The weight-bearing *medial tubercle of the calcaneus* on the plantar surface of the foot is broad and large (Fig. 5.12D), but often it is not palpable because of the overlying skin and subcutaneous tissue. The *sustentaculum tali* is the only part of the medial aspect of the calcaneus that may be palpated as a small prominence approximately a finger's breadth distal to the tip of the medial malleolus. The entire lateral surface of the calcaneus is subcutaneous. The *fibular trochlea*, a small lateral extension of the calcaneus, may be detectable as a small tubercle on the lateral aspect of the calcaneus, anteroinferior to the tip of the lateral malleolus (Fig. 5.12).

Usually, palpation of bony prominences on the plantar surface of the foot is difficult because of the thick skin, fascia,

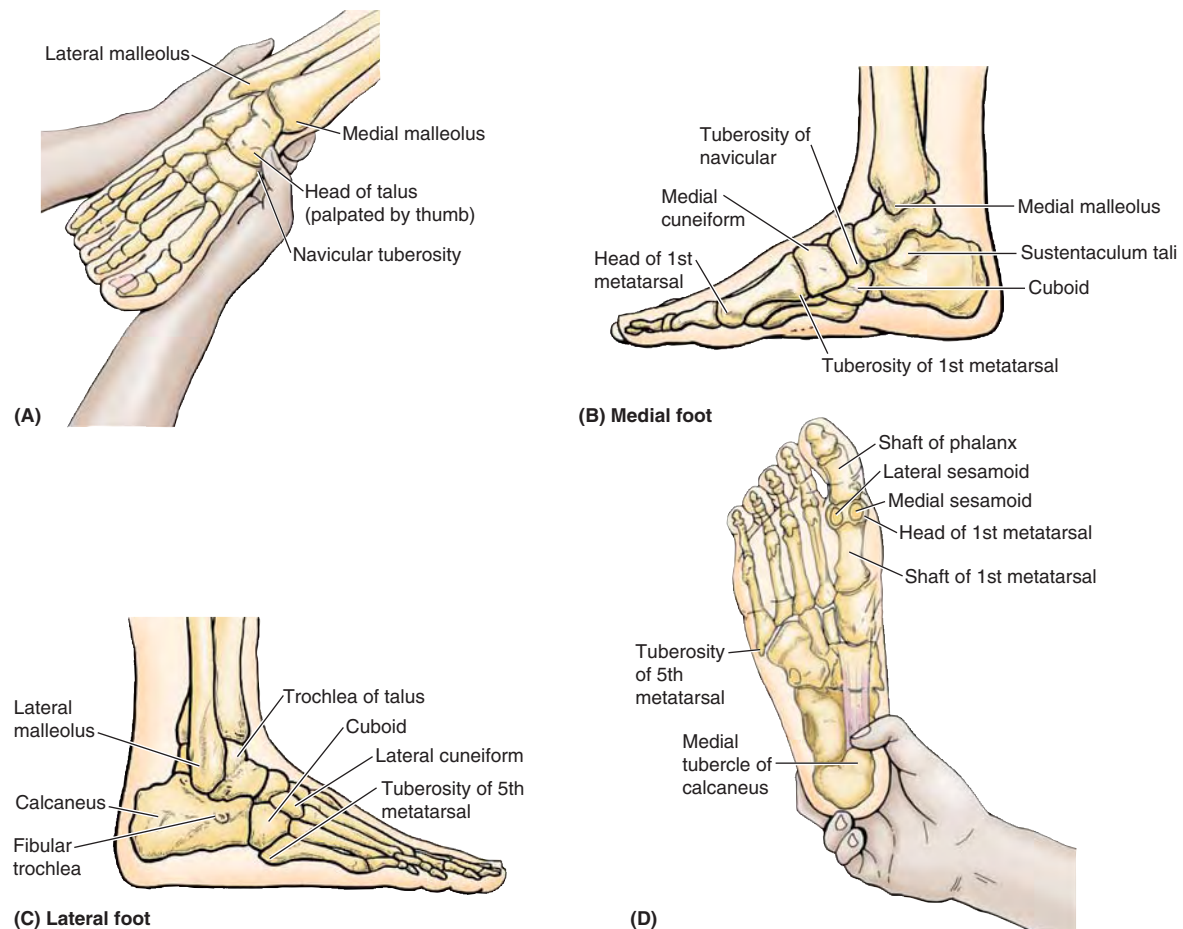


FIGURE 5.12. Surface projection and palpation of bony prominences of foot.

and pads of fat. The medial and lateral *sesamoid bones* inferior to the head of the 1st metatarsal can be felt to slide when the great toe is moved passively. The *heads of the metatarsals* can be palpated by placing the thumb on their plantar surfaces and the index finger on their dorsal surfaces. If *callosities* (calluses), thickenings of the keratin layer of the epidermis, are present, the metatarsal heads are difficult to palpate.

The *tuberosity of the 5th metatarsal* forms a prominent landmark on the lateral aspect of the foot (Fig. 5.12C & D), that can easily be palpated at the midpoint of the lateral border of the foot. The *shafts of the metatarsals and phalanges*

can be felt on the dorsum of the foot between the extensor tendons.

The *cuboid* can be felt on the lateral aspect of the foot, posterior to the base of the 5th metatarsal. The *medial cuneiform* can be palpated between the tuberosity of the navicular and the base of the 1st metatarsal (Fig. 5.12B). The *head of the 1st metatarsal* forms a prominence on the medial aspect of the foot. The *tuberosity of the navicular* is easily seen and palpated on the medial aspect of the foot (Fig. 5.12B), inferoanterior to the tip of the medial malleolus. The cuboid and cuneiforms are difficult to identify individually by palpation.

BONES OF LOWER LIMB

Lower Limb Injuries



Knee, leg, and foot injuries are the most common lower limb injuries. Injuries to the hips make up less than 3% of lower limb injuries. In general, most injuries result from acute trauma during contact sports such as hockey and football and from overuse during endurance sports such as marathon races.

Adolescents are most vulnerable to these injuries because of the demands of sports on their maturing musculoskeletal systems. The cartilaginous models of the bones in the developing lower limbs are transformed into bone by endochondral ossification (Fig. 5.2E & F). Because the process is not completed until early adulthood, cartilaginous epiphysal plates still exist during the teenage years when physical activity often peaks and involvement in competitive sports is most common.

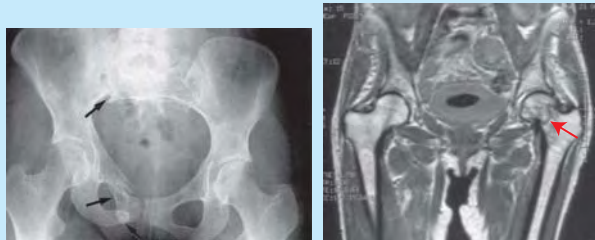The **epiphysal plates** are discs of hyaline cartilage between the metaphysis and epiphysis of a mature long bone that permits the bone to grow longer. During growth spurts, bones actually grow faster than the attached muscle. The combined stress on the epiphysal plates resulting from physical activity and rapid growth may result in irritation and injury of the plates and developing bone (*osteochondrosis*).

Injuries of Hip Bone

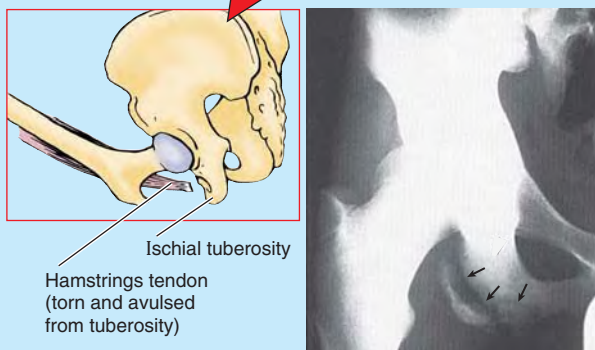
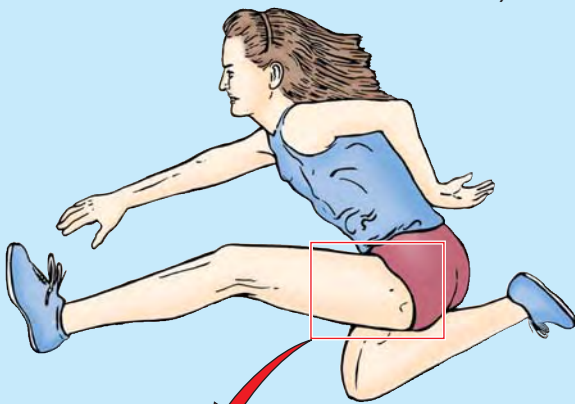


Fractures of the hip bone are referred to as *pelvic fractures* (see the blue box “Pelvic Fractures” in Chapter 3, p. 335). The term *hip fracture* is most commonly applied (unfortunately) to fractures of the femoral head, neck, or trochanters.

Avulsion fractures of the hip bone may occur during sports that require sudden acceleration or deceleration forces, such as sprinting or kicking in football, soccer, hurdle jumping, basketball, and martial arts (Fig. B5.1). A small part



(A) Pelvic fracture (radiograph) (B) Hip fracture (fracture of neck of left femur) -- MRI



(C) Tendon avulsion (Hamstrings tendon (torn and avulsed from tuberosity)) (D) Avulsion fracture of pelvis in an adolescent competitive athlete

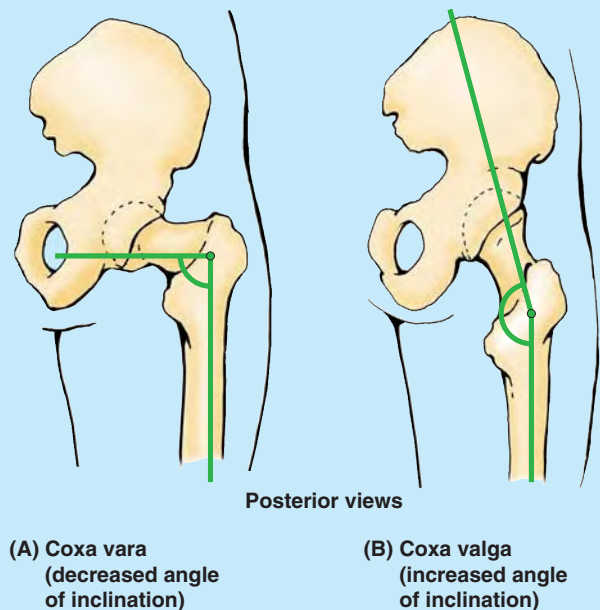
FIGURE B5.1.

of bone with a piece of a tendon or ligament attached is “avulsed” (torn away). These fractures occur at **apophyses** (bony projections that lack secondary ossification centers). Avulsion fractures occur where muscles are attached: anterior superior and inferior iliac spines, ischial tuberosities, and ischiopubic rami.

Coxa Vara and Coxa Valga



The angle of inclination between the long axis of the femoral neck and the femoral shaft (Fig. 5.7C–E) varies with age, sex, and development of the femur (e.g., a congenital defect in the ossification of the femoral neck). It may also change with any pathological process that weakens the neck of the femur (e.g., rickets). When the angle of inclination is decreased, the condition is **coxa vara** (Fig. B5.2A); when it is increased, it is **coxa valga** (Fig. B5.2B). The term “vara” or “varus” is a Latin adjective describing any bone or joint in a limb that is deformed so that the distal element (the shaft of the femur relative to the femoral neck in this case) deviates toward the midline. Conversely, the term “valga” or “valgus” describes a bone or joint in a limb that is deformed so that the distal element deviates away from the midline. Coxa vara causes a mild shortening of the lower limb and limits passive abduction of the hip.



Posterior views

(A) Coxa vara (decreased angle of inclination)

(B) Coxa valga (increased angle of inclination)

FIGURE B5.2.

Dislocated Epiphysis of Femoral Head



In older children and adolescents (10–17 years of age), the epiphysis of the femoral head may slip away from the femoral neck because of a weakened epiphysal plate. This injury may be caused by acute trauma or repetitive microtraumas that place increased shearing stress on the epiphysis, especially with abduction and lateral rotation of the thigh. The epiphysis often dis-

locates (slips) slowly and results in a progressive *coxa vara*. The common initial symptom of the injury is hip discomfort that may be referred to the knee. Radiographic examination of the superior end of the femur is usually required to confirm a diagnosis of a dislocated epiphysis of the head of the femur.

Femoral Fractures



Despite its large size and strength, the femur is commonly fractured. The type of fracture sustained is frequently age- and even sex-related. The neck of the femur is most frequently fractured because it is the narrowest and weakest part of the bone and it lies at a marked angle to the line of weight-bearing (pull of gravity). It becomes increasingly vulnerable with age, especially in females, secondary to *osteoporosis*.

Fractures of the proximal femur occur at several locations; two examples are transcervical (middle of neck) and intertrochanteric (Fig. B5.3). These fractures usually occur as a result of indirect trauma (stumbling or stepping down hard, as off a curb or step). Because of the angle of inclination, these fractures are inherently unstable and *impaction* (overriding of fragments resulting in foreshortening of the limb) occurs. Muscle spasm also contributes to the shortening of the limb.

Intracapsular fractures (occurring within the hip joint capsule), are complicated by degeneration of the femoral head owing to vascular trauma (see the blue boxes “Fractures of the Femoral Neck” on p. 659 and “Surgical Hip Replacement” on p. 660).

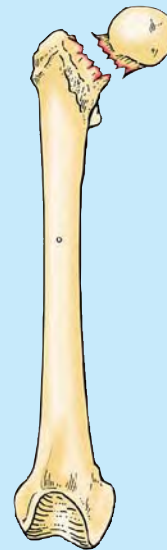
Fractures of the greater trochanter and femoral shaft usually result from direct trauma (direct blows sustained by the bone resulting from falls or being hit) and are most common during the more active years. They frequently occur during motor vehicle accidents and sports such as skiing and climbing. In some cases, a *spiral fracture* of the femoral shaft occurs, resulting in foreshortening as the fragments override, or the fracture may be *comminuted* (broken into several pieces), with the fragments displaced in various directions as a result of muscle pull and depending on the level of the fracture. Union of this serious type of fracture may take up to a year.

Fractures of the distal femur may be complicated by separation of the condyles, resulting in misalignment of the articular surfaces of the knee joint, or by hemorrhage from the large popliteal artery that runs directly on the posterior surface of the bone. This fracture compromises the blood supply to the leg (an occurrence that should always be considered in knee fractures or dislocations).

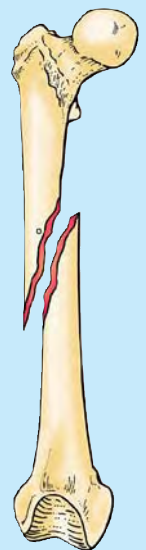
Tibial Fractures



The tibial shaft is narrowest at the junction of its middle and inferior thirds, which is the most frequent site of fracture. Unfortunately, this area of the bone also has the poorest blood supply. Because its anterior

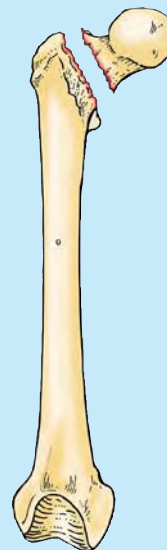


(A) Transcervical fracture of femoral neck

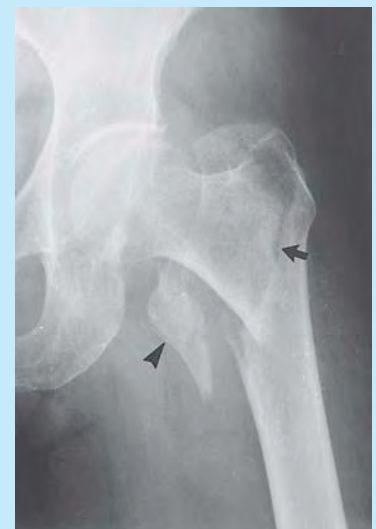


(B) Spiral fracture

A - C Anterior views



(C) Intertrochanteric fracture

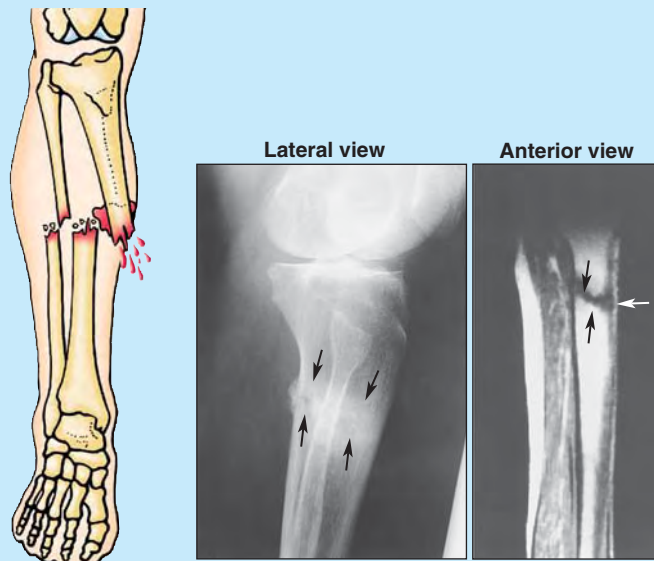


(D) Comminuted intertrochanteric fracture of left proximal femur

FIGURE B5.3.

surface is subcutaneous, the tibial shaft is the most common site for a *compound fracture* (Fig. B5.4A). Compound tibial fractures may also result from direct trauma (e.g., a “bumper fracture” caused when a car bumper strikes the leg). Fracture of the tibia through the nutrient canal predisposes the patient to non-union of the bone fragments resulting from damage to the nutrient artery.

Transverse stress (march) fractures of the inferior third of the tibia (Fig. B5.4B) are common in people who take long hikes before they are conditioned for this activity. The strain may fracture the anterior cortex of the tibia. Indirect violence applied to the tibial shaft when the bone turns with the foot fixed during a fall may produce a fracture (e.g., when a person is tackled in football).



(A) Compound (open) fracture with external bleeding
 (B) March (stress) fracture of tibia (arrows), most apparent in the MRI study at the right

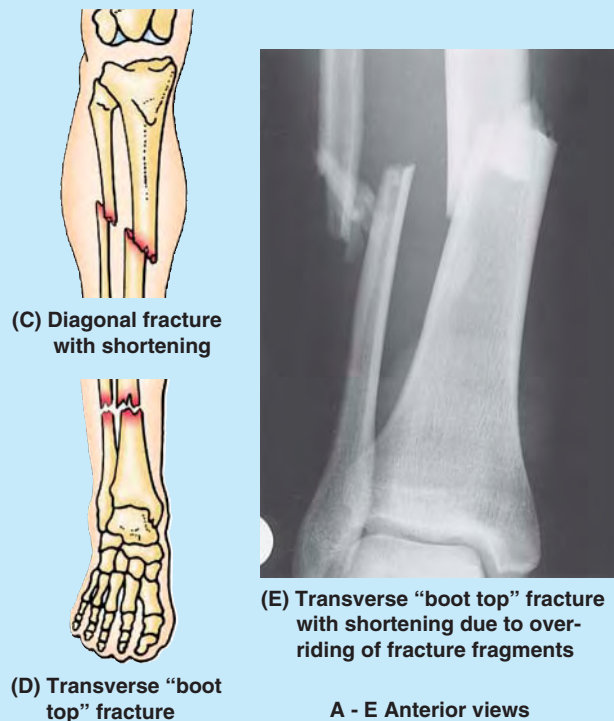


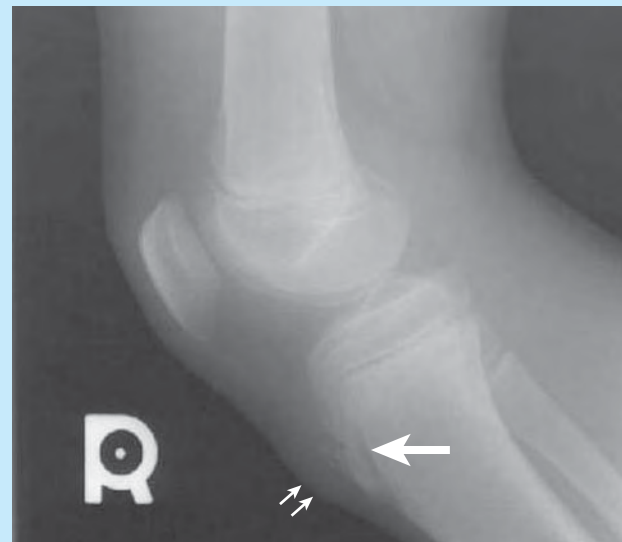FIGURE B5.4.

In addition, severe torsion during skiing may produce a *diagonal fracture* (Fig. B5.4C) of the tibial shaft at the junction of the middle and inferior thirds, as well as a *fracture of the fibula*. Diagonal fractures are often associated with limb shortening caused by overriding of the fractured ends. Frequently during skiing, a fracture results from a high-speed forward fall, which angles the leg over the rigid ski boot, producing a “boot-top fracture” (Fig. B5.4D & E).

Fractures Involving Epiphysal Plates



The primary ossification center for the superior end of the tibia appears shortly after birth and joins the shaft of the tibia during adolescence (usually 16–18 years of age). Tibial fractures in children are more serious if they involve the epiphysal plates because continued normal growth of the bone may be jeopardized. The tibial tuberosity usually forms by inferior bone growth from the superior epiphysal center at approximately 10 years of age, but a separate center for the tibial tuberosity may appear at approximately 12 years of age. Disruption of the epiphysal plate at the tibial tuberosity may cause inflammation of the tuberosity and chronic recurring pain during adolescence (*Osgood-Schlatter disease*), especially in young athletes (Fig. B5.5).



Osgood-Schlatter Disease

Tibial tuberosity (double arrow) elongated and fragmented (single arrow), with overlying soft tissue swelling

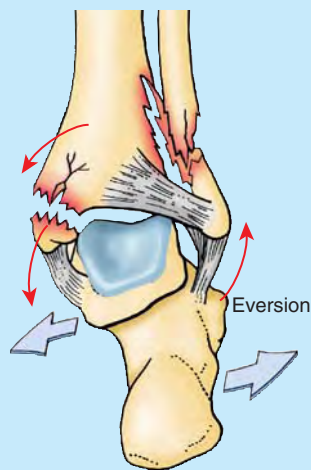
FIGURE B5.5.

Fibular Fractures

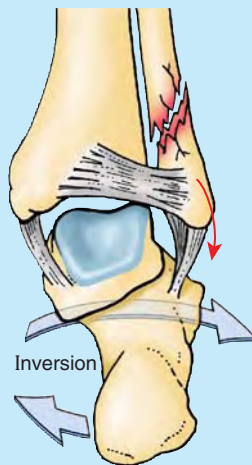


Fibular fractures commonly occur 2–6 cm proximal to the distal end of the lateral malleolus and are often associated with *fracture-dislocations of the ankle joint*, which are combined with tibial fractures (Fig. B5.6B). When a person slips and the foot is forced into an excessively inverted position, the ankle ligaments tear, forcibly tilting the talus against the lateral malleolus and shearing it off (Fig. B5.6C).

Fractures of the lateral and medial malleoli are relatively common in soccer and basketball players. Fibular fractures can be painful owing to disrupted muscle attachments. Walking is compromised because of the bone’s role in ankle stability.



(A) Tibial and fibular fractures



(B) Fibular fracture with excessive inversion of foot

Posterior views

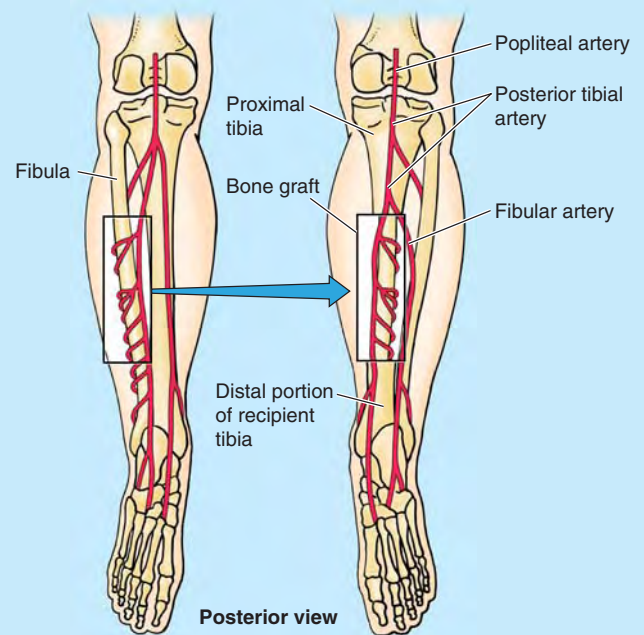
FIGURE B5.6.

Bone Grafts



If a part of a major bone is destroyed by injury or disease, the limb becomes useless. Replacement of the affected segment by a bone transplant may avoid amputation. The fibula is a common source of bone for grafting. Even after a segment of the shaft has been removed, walking, running, and jumping can be normal.

Free vascularized fibulas have been used to restore skeletal integrity to upper and lower limbs in which congenital bone defects exist and to replace segments of bone after trauma or excision of a malignant tumor (Fig. B5.7). The remaining parts of the fibula usually do not regenerate because the periosteum and nutrient artery are generally removed with the piece of bone so that the graft will remain alive and grow when transplanted to another site. Secured in its new site, the fibular segment restores the blood supply of the bone to which it is



Section of left fibula grafted into right tibia

FIGURE B5.7.

now attached. Healing proceeds as if a fracture had occurred at each of its ends.

Awareness of the location of the nutrient foramen in the fibula is important when performing free vascularized fibular transfers. Because the nutrient foramen is located in the middle third of the fibula in most cases, this segment of the bone is used for transplanting when the graft must include a blood supply to the medullary cavity as well as to the compact bone of the surface (via the periosteum).

Because of its extensive subcutaneous location, the anterior tibia is accessible for obtaining pieces of bone for grafting in children; it is also used as a site for *intramedullary infusion* in dehydrated or shocked children.

Calcaneal Fractures



A hard fall onto the heel, from a ladder for example, may fracture the calcaneus into several pieces, producing a *comminuted fracture* (Fig. B5.8A). A calcaneal fracture is usually disabling because it disrupts the subtalar (talocalcaneal) joint, where the talus articulates with the calcaneus.

Fractures of Talar Neck



Fractures of the talar neck (Fig. B5.8B) may occur during severe dorsiflexion of the ankle (e.g., when a person is pressing extremely hard on the brake pedal of a vehicle during a head-on collision). In some cases, the body of the talus dislocates posteriorly.

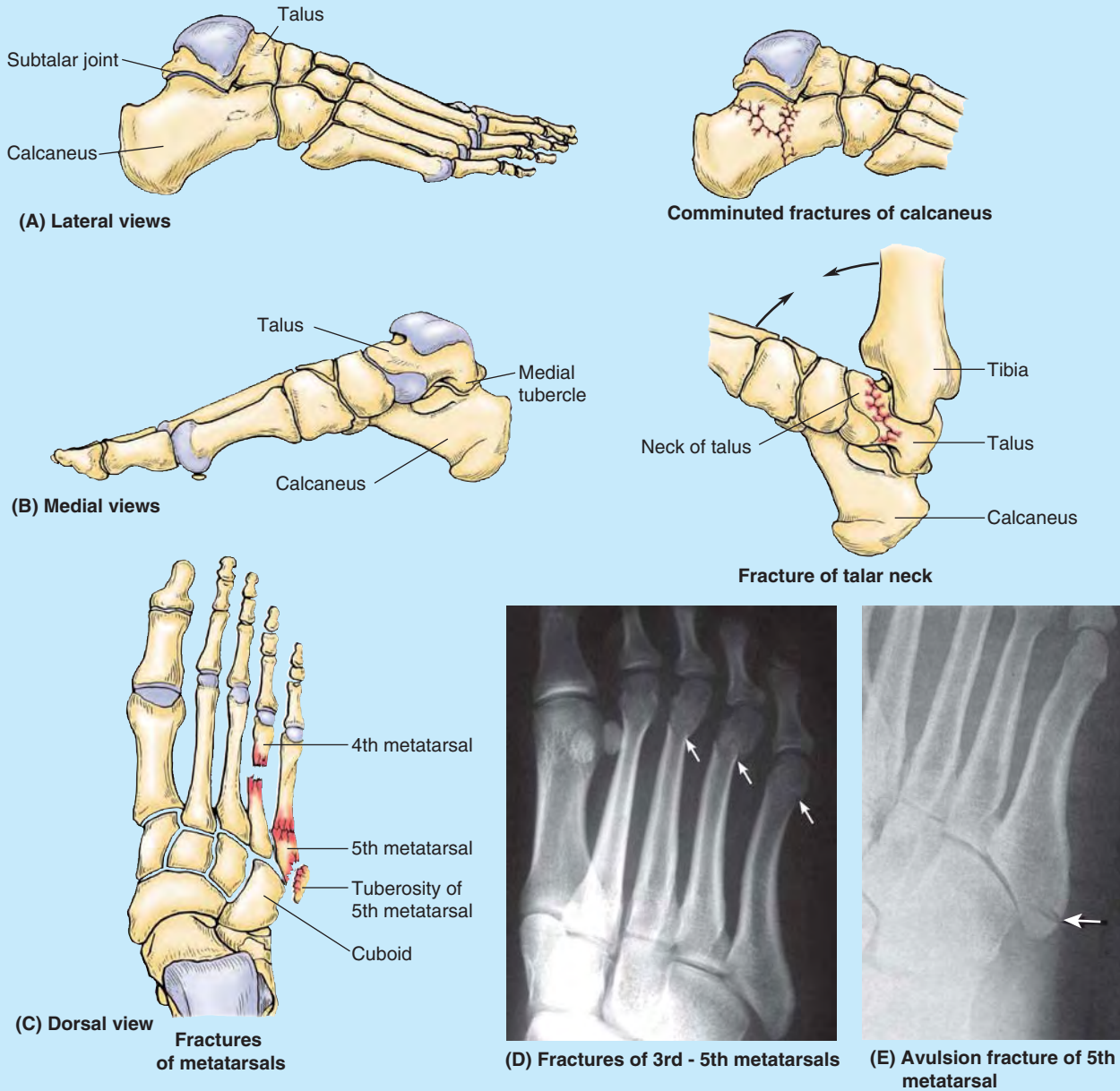



FIGURE B5.8.

Fractures of Metatarsals

 Metatarsal fractures occur when a heavy object falls on the foot, for example, or when it is run over by a heavy object such as a metal wheel (Fig. B5.8C & D). Metatarsal fractures are also common in dancers, especially female ballet dancers who use the demi-pointe technique. The *dancer's fracture* usually occurs when the dancer loses balance, putting the full body weight on the metatarsal and fracturing the bone. *Fatigue fractures of the metatarsals* may result from prolonged walking. These fractures, usually transverse, result from repeated stress on the metatarsals.

When the foot is suddenly and violently inverted, the tuberosity of the 5th metatarsal may be avulsed (torn away) by the tendon of the fibularis brevis muscle. An *avulsion fracture of the 5th metatarsal tuberosity* (Fig. B5.8C & E) is common in basketball and tennis players. This injury is associated with a severely sprained ankle that produces pain and edema at the base of the 5th metatarsal.

Os Trigonum



During ossification of the talus, the secondary ossification center, which becomes the lateral tubercle of the talus, occasionally fails to unite with the

body of the talus. This failure may be caused by applied stress (forceful plantarflexion) during the early teens. Occasionally, a partly or even fully ossified center may fracture and progress to non-union. Either event may result in a bone (accessory ossicle) known as an **os trigonum**, which occurs in 14–25% of adults, more commonly bilaterally (Fig. B5.9). It has an increased prevalence among soccer players and ballet dancers.

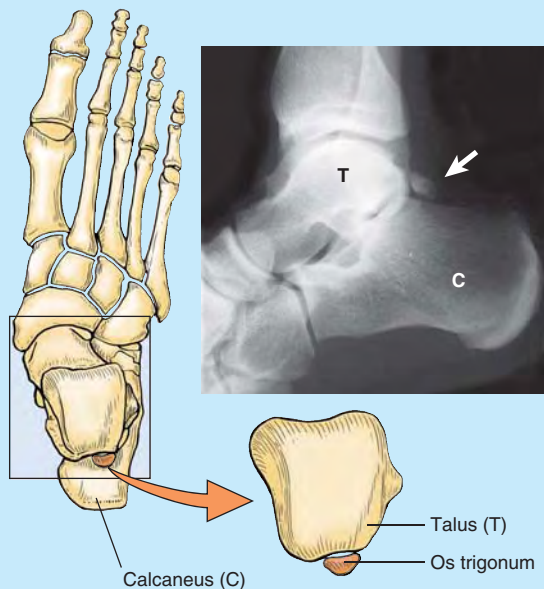
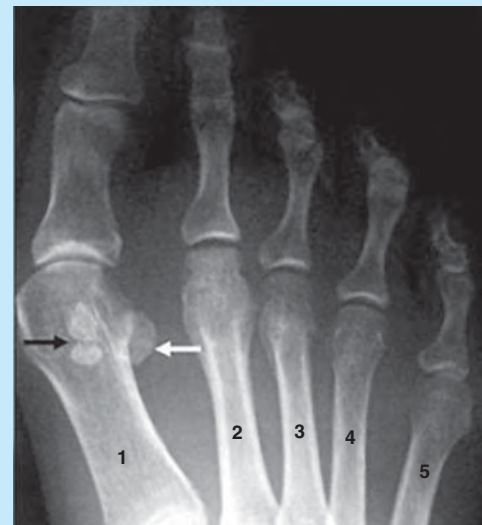

FIGURE B5.9.

Fracture of Sesamoid Bones



The sesamoid bones of the great toe (Fig. 5.8D) in the tendon of the flexor hallucis longus bear the weight of the body, especially during the latter part of the stance phase of walking. The sesamoids develop before birth and begin to ossify during late childhood. *Fracture of the sesamoid bones* may result from a crushing injury (Fig B5.10).



Black arrow: Fractured sesamoid bone
White arrow: Normal sesamoid bone
Metatarsals 1-5

FIGURE B5.10.

The Bottom Line

BONES OF LOWER LIMB

Hip bone: Formed by the union of three primary bones (ilium, ischium, and pubis), the hip bones are joined to the sacrum posteriorly and to each other anteriorly (at the pubic symphysis) to form the pelvic girdle. ♦ Each hip bone is specialized to receive half the weight of the upper body when standing and all of it periodically during walking. ♦ Thick parts of the bone transfer weight to the femur. ♦ Thin parts of the bone provide a broad surface for attachment of powerful muscles that move the femur. ♦ The pelvic girdle encircles and protects the pelvic viscera, particularly the reproductive organs.

Femur: Through development, our largest bone, the femur, has developed a bend (angle of inclination) and has twisted (medial rotation and torsion so that the knee and all joints inferior to it flex posteriorly) to accommodate our erect posture and to enable bipedal walking and running. ♦ The angle of inclination and attachment of the abductors and rotators to the greater trochanter allow increased leverage, superior placement of the abductors, and oblique orientation of the

femur in the thigh. ♦ Combined with the torsion angle, oblique rotatory movements at the hip joint are converted into movements of flexion–extension and abduction–adduction (in the sagittal and coronal planes, respectively) as well as of rotation.

Tibia and fibula: Our second largest bone, the tibia, is a vertical column bearing the weight of all superior to it. ♦ The slender fibula does not bear weight but, along with the interosseous membrane that binds it to the tibia, is accessory to the tibia in providing an additional surface area for fleshy muscle attachment and in forming the socket of the ankle joint. ♦ Through development, the two bones have become permanently pronated to provide for a stable stance and facilitate locomotion.

Bones of foot: The many bones of the foot form a functional unit that allows weight to be distributed to a wide platform to maintain balance when standing, enable conformation and adjustment to terrain variations, and perform shock absorption. ♦ They also transfer weight from the heel to the forefoot as required in walking and running.

FASCIA, VEINS, LYMPHATICS, EFFERENT VESSELS, AND CUTANEOUS NERVES OF LOWER LIMB

Subcutaneous Tissue and Fascia

The **subcutaneous tissue** (superficial fascia) lies deep to the skin (Fig. 5.13) and consists of loose connective tissue that contains a variable amount of fat, cutaneous nerves, superficial veins (great and small saphenous veins and their tributaries), lymphatic vessels, and lymph nodes.

The subcutaneous tissue of the hip and thigh is continuous with that of the inferior part of the anterolateral abdominal wall and buttock. At the knee, the subcutaneous tissue loses its fat and blends with the deep fascia, but fat is again present distal to the knee in the subcutaneous tissue of the leg.

The **deep fascia of the lower limb** is especially strong, investing the limb like an elastic stocking (Fig. 5.13A & B). This fascia limits outward expansion of contracting muscles, making muscular contraction more efficient in compressing veins to push blood toward the heart.

FASCIA LATA

The deep fascia of the thigh is called **fascia lata** (L. *lata*, broad). Superiorly, the fascia lata attaches to and is continuous with:

- The inguinal ligament, pubic arch, body of pubis, and pubic tubercle anteriorly.
- The membranous layer of subcutaneous tissue (Scarpa fascia) of the inferior abdominal wall also attaches to the fascia lata approximately a finger's breadth inferior to the inguinal ligament.
- The iliac crest laterally and posteriorly.
- The sacrum, coccyx, sacrotuberous ligament, and ischial tuberosity/ischiopubic ramus posteriorly and medially.

Inferiorly, the fascia lata attaches to and is continuous with:

- Exposed parts of bones around the knee.
- The deep fascia of the leg inferior to the knee.

The fascia lata is substantial because it encloses the large thigh muscles, especially laterally, where it is thickened and strengthened by additional reinforcing longitudinal fibers to form the **iliotibial tract** (Fig. 5.13B). This broad band of fibers is the shared aponeurosis of the tensor fasciae latae and gluteus maximus muscles. The iliotibial tract extends from the iliac tubercle to the **anterolateral tubercle of the tibia** (*Gerdy tubercle*).

The thigh muscles are separated into three compartments— anterior, medial, and posterior. The walls of these compartments are formed by the fascia lata and three fascial intermuscular septa that arise from its deep aspect and attach to the linea aspera of the femur (Fig. 5.13D). The **lateral intermuscular septum** is especially strong; the other two septa are relatively weak. The lateral intermuscular septum

extends deeply from the iliotibial tract to the lateral lip of the linea aspera and lateral supracondylar line of the femur. This septum offers an internervous plane (plane between nerves) to surgeons needing wide exposure of the femur.

The **saphenous opening** in the fascia lata (Fig. 5.13A) is a gap or hiatus in the fascia lata inferior to the medial part of the inguinal ligament, approximately 4 cm inferolateral to the pubic tubercle. The saphenous opening is usually approximately 3.75 cm in length and 2.5 cm in breadth, and its long axis is vertical. Its medial margin is smooth but its superior, lateral, and inferior margins form a sharp crescentic edge, the **falciform margin**. The falciform margin is joined at its medial margin by fibrofatty tissue, the **cribriform fascia** (L. *cribrum*, a sieve). This sieve-like fascia is a localized membranous layer of subcutaneous tissue that spreads over the saphenous opening, closing it. The connective tissue is pierced by numerous openings (thus its name) for the passage of efferent lymphatic vessels from the superficial inguinal lymph nodes, and by the great saphenous vein and its tributaries. After passing through the saphenous opening and cribriform fascia, the *great saphenous vein* enters the femoral vein (Fig. 5.13A). The lymphatic vessels enter the deep inguinal lymph nodes.

DEEP FASCIA OF LEG

The **deep fascia of the leg**, or *crural fascia* (L. *crus*, leg), attaches to the anterior and medial borders of the tibia, where it is continuous with its periosteum. The deep fascia of the leg is thick in the proximal part of the anterior aspect of the leg, where it forms part of the proximal attachments of the underlying muscles. Although thinner distally, the deep fascia of the leg forms thickened bands both superior and anterior to the ankle joint, the **extensor retinacula** (Fig. 5.13A).

Anterior and **posterior intermuscular septa** pass from the deep surface of the lateral deep fascia of the leg and attach to the corresponding margins of the fibula. The *interosseous membrane* and intermuscular septa divide the leg into three compartments: anterior (dorsiflexor), lateral (fibular), and posterior (plantarflexor) (Fig. 5.13C). The posterior compartment is further subdivided by the **transverse intermuscular septum**, separating superficial and deep plantarflexor muscles.

Venous Drainage of Lower Limb

The lower limb has superficial and deep veins; the superficial veins are in the subcutaneous tissue, and the deep veins are deep to (beneath) the deep fascia and accompany all major arteries. Superficial and deep veins have valves, which are more numerous in deep veins.

SUPERFICIAL VEINS OF LOWER LIMB

The two major superficial veins in the lower limb are the *great and small saphenous veins* (Fig. 5.14A & B). Most of their tributaries are unnamed.

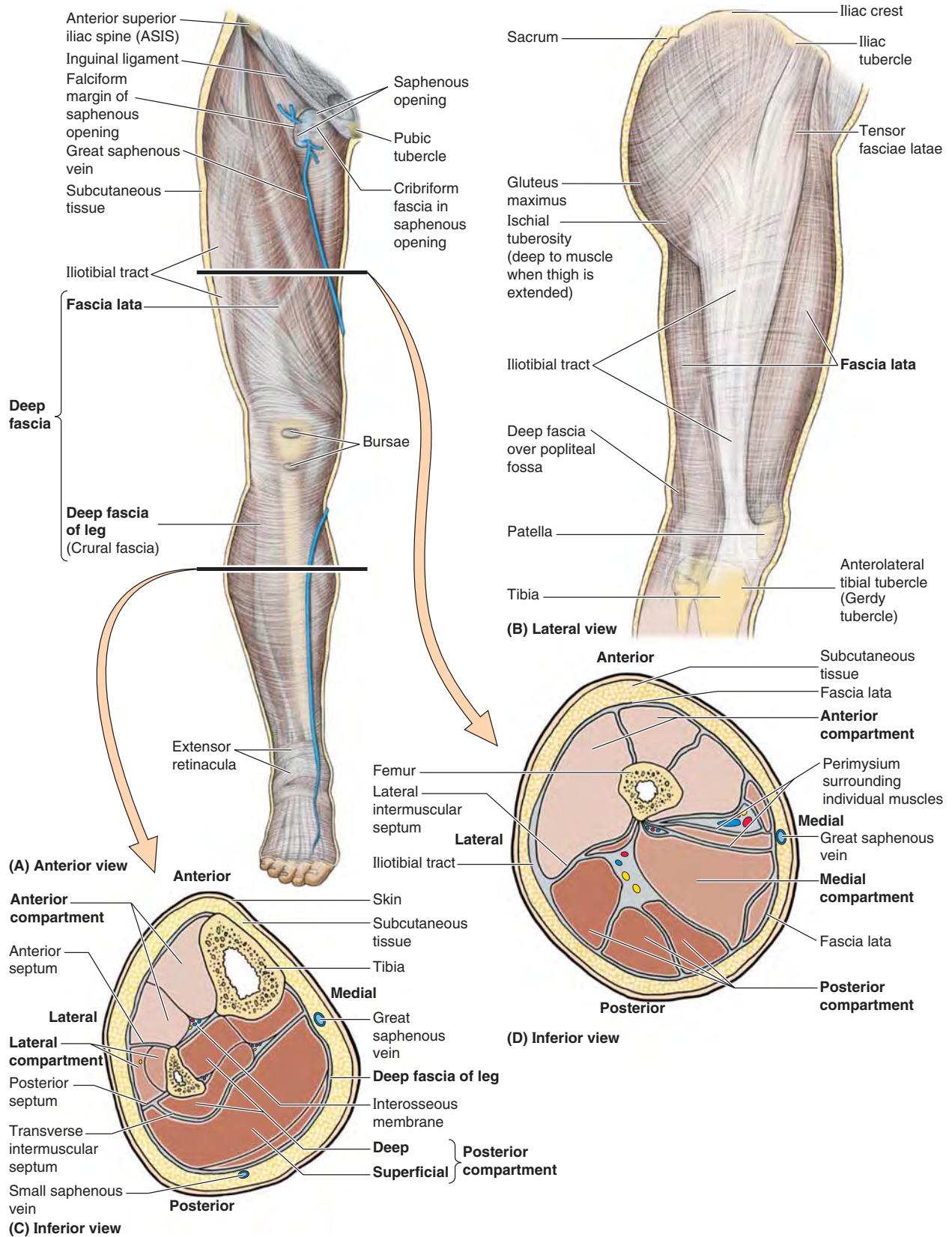


FIGURE 5.13. Fascia, intermuscular septa, and fascial compartments of lower limb. A. The anterior skin and subcutaneous tissue have been removed to reveal the deep fascia. B. The fascia lata is reinforced laterally by longitudinal fibers of the iliotibial tract, the common aponeurotic tendon of the gluteus maximus and tensor fasciae latae. C and D. The fascial compartments of the thigh and leg, containing muscles sharing common functions and innervation, are demonstrated in transverse sections.

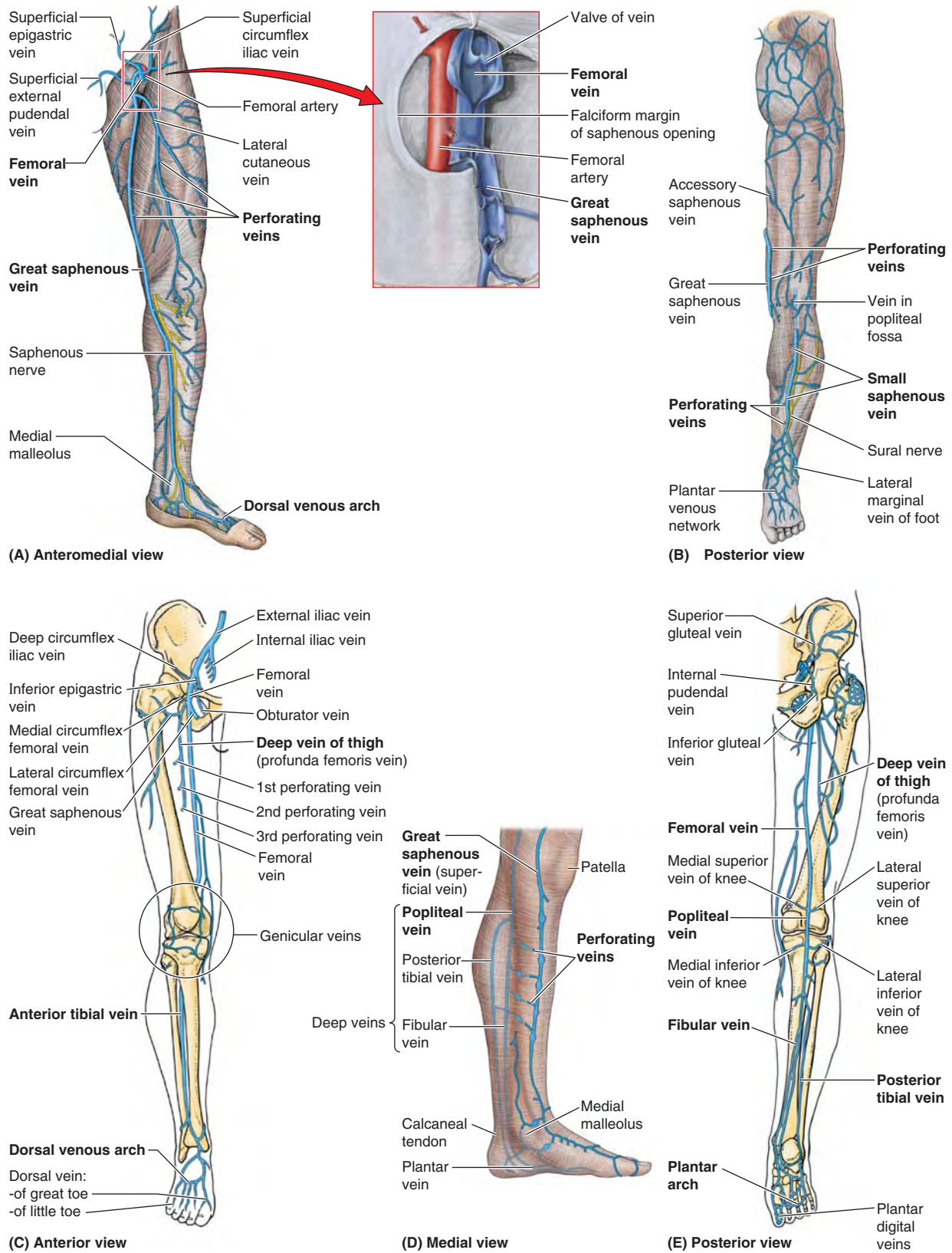


FIGURE 5.14. Veins of lower limb. The veins are divided into superficial (A and B) and deep (C and E) groups. The superficial veins, usually unaccompanied, course within the subcutaneous tissue; the deep veins are internal to the deep fascia and usually accompany arteries. **A, inset.** The proximal ends of the femoral and great saphenous veins are opened and spread apart to show the valves. Although depicted as single veins in parts C and E, the deep veins usually occur as duplicate or multiple accompanying veins. **D.** Multiple perforating veins pierce the deep fascia to shunt blood from the superficial veins to the deep veins.

The **great saphenous vein** is formed by the union of the *dorsal vein of the great toe* and the *dorsal venous arch of the foot*. The great saphenous vein:

- Ascends anterior to the medial malleolus.
- Passes posterior to the medial condyle of the femur (about a hand's breadth posterior to the medial border of the patella) (see Fig. 5.15A).
- Anastomoses freely with the small saphenous vein.
- Traverses the saphenous opening in the fascia lata.
- Empties into the femoral vein.

The great saphenous vein has 10–12 valves, which are more numerous in the leg than in the thigh. These valves are usually located just inferior to the perforating veins (Fig. 5.14A). The perforating veins also have valves.

Venous valves are cusps (flaps) of endothelium with cup-like *valvular sinuses* that fill from above. When they are full, the valve cusps occlude the lumen of the vein, thereby preventing reflux of blood distally, making flow unidirectional. The valvular mechanism also breaks the column of blood in the saphenous vein into shorter segments, reducing back pressure. Both effects make it easier for the *musculoventous pump* (discussed in the Introduction) to overcome the force of gravity to return the blood to the heart.

As it ascends in the leg and thigh, the great saphenous vein receives numerous tributaries and communicates in several locations with the small saphenous vein. Tributaries from the medial and posterior aspects of the thigh frequently unite to form an **accessory saphenous vein** (Fig. 5.14B). When present, this vein becomes the main communication between the great and small saphenous veins.

Also, fairly large vessels, the **lateral** and **anterior cutaneous veins**, arise from networks of veins in the inferior part of the thigh and enter the great saphenous vein superiorly, just before it enters the femoral vein. Near its termination, the great saphenous vein also receives the superficial circumflex iliac, superficial epigastric, and external pudendal veins (Fig. 5.14A).

The **small saphenous vein** arises on the lateral side of the foot from the union of the *dorsal vein of the little toe* with the *dorsal venous arch* (Fig. 5.14B & C). The small saphenous vein:

- Ascends posterior to the lateral malleolus as a continuation of the lateral marginal vein.
- Passes along the lateral border of the calcaneal tendon.
- Inclines to the midline of the fibula and penetrates the deep fascia.
- Ascends between the heads of the gastrocnemius muscle.
- Empties into the popliteal vein in the popliteal fossa.

Although many tributaries are received by the saphenous veins, their diameters remain remarkably uniform as they ascend the limb. This is possible because the blood received by the saphenous veins is continuously shunted from these superficial veins in the subcutaneous tissue to the deep veins internal to the deep fascia by means of many perforating veins.

The **perforating veins** penetrate the deep fascia close to their origin from the superficial veins and contain valves that allow blood to flow only from the superficial veins to the deep veins. The perforating veins pass through the deep fascia at an oblique angle so that when muscles contract and the pressure increases inside the deep fascia, the perforating veins are compressed. Compression of these veins also prevents blood from flowing from the deep to the superficial veins. This pattern of venous blood flow—from superficial to deep—is important for proper venous return from the lower limb because it enables muscular contractions to propel blood toward the heart against gravity (**musculoventous pump**—see Fig. 1.25 in Introduction).

DEEP VEINS OF LOWER LIMB

Deep veins accompany all the major arteries and their branches. Instead of occurring as a single vein in the limbs (although they are frequently illustrated as one and are often referred to as a single vein), the **accompanying veins** (*L. venae comitantes*) usually occur as paired, frequently interconnecting veins that flank the artery they accompany (Fig. 5.14C & E). *They are contained within a vascular sheath with the artery*, whose pulsations also help compress and move blood in the veins.

Although the *dorsal venous arch* drains primarily via the saphenous veins, perforating veins penetrate the deep fascia, forming and continually supplying an **anterior tibial vein** in the anterior leg. **Medial** and **lateral plantar veins** from the plantar aspect of the foot form the **posterior tibial** and **fibular veins** posterior to the medial and lateral malleoli (Fig. 5.14C–E). All three deep veins from the leg flow into the popliteal vein posterior to the knee, which becomes the femoral vein in the thigh. Veins accompanying the perforating arteries of the deep artery of the thigh drain blood from the thigh muscles and terminate in the **deep vein of the thigh** (*L. vena profunda femoris*), which joins the terminal portion of the femoral vein (Fig. 5.14C & E). The femoral vein passes deep to the inguinal ligament to become the external iliac vein.

Because of the effect of gravity, blood flow is slower when a person stands quietly. During exercise, blood received by the deep veins from the superficial veins is propelled by muscular contraction to the femoral and then the external iliac veins. Flow in the reverse direction is prevented if the valves are competent. The deep veins are more variable and anastomose much more frequently than the arteries they accompany. Both superficial and deep veins can be ligated if necessary.

Lymphatic Drainage of Lower Limb

The lower limb has superficial and deep lymphatic vessels. The **superficial lymphatic vessels** converge on and accompany the saphenous veins and their tributaries (Fig. 5.15A). The lymphatic vessels accompanying the great saphenous vein end in the vertical group of **superficial inguinal lymph nodes**. Most lymph from these nodes passes directly to the **external iliac lymph nodes**, located along the external iliac

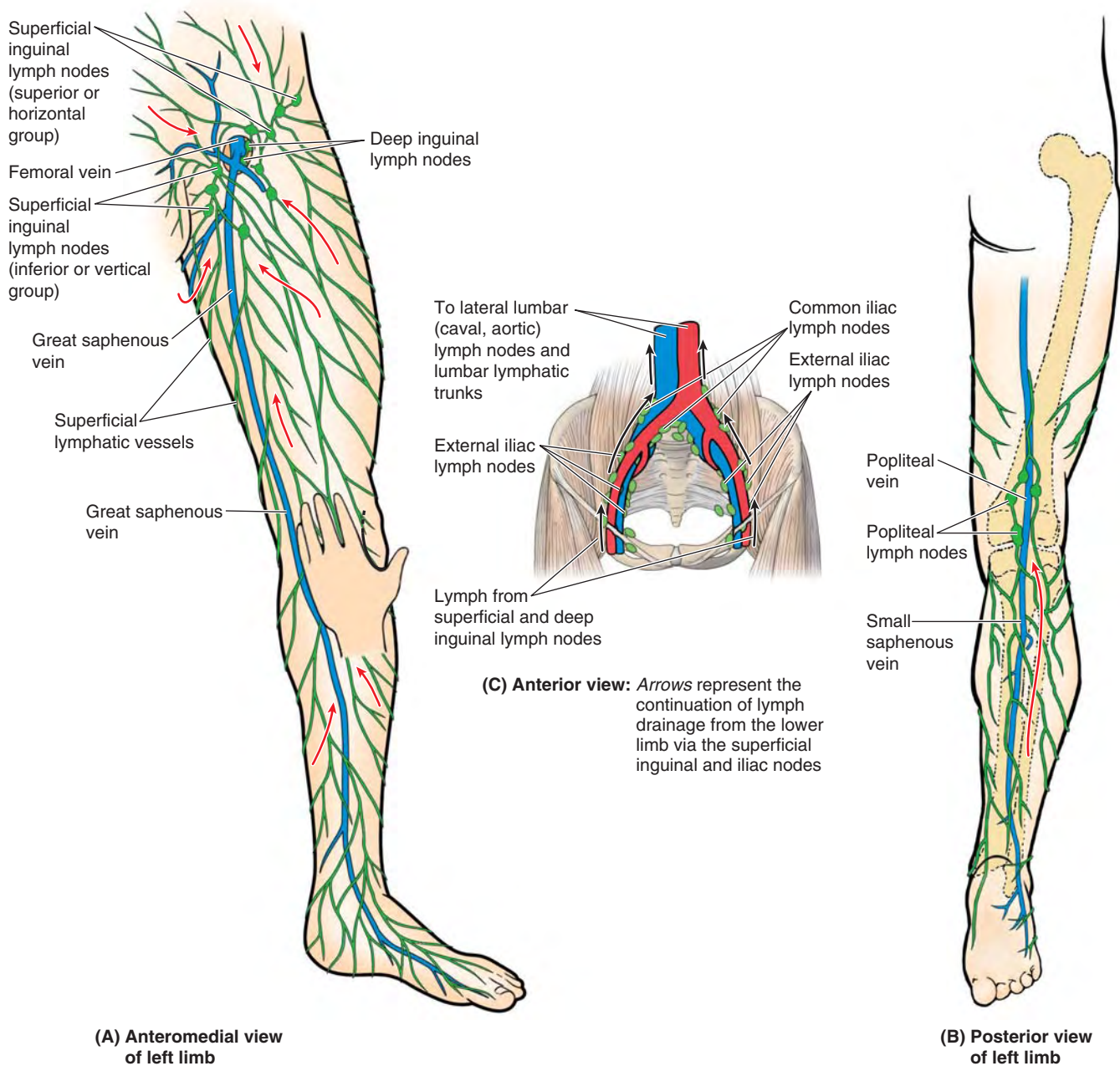


FIGURE 5.15. Superficial veins and lymphatics of lower limb. **A.** The superficial lymphatic vessels converge toward and accompany the great saphenous vein, draining into the inferior (vertical) group of superficial inguinal lymph nodes. The great saphenous vein passes anterior to the medial malleolus, approximately a hand's breadth posterior to the patella. **B.** Superficial lymphatic vessels of the lateral foot and posterolateral leg accompany the small saphenous vein and drain initially into the popliteal lymph nodes. The efferent vessels from these nodes join other deep lymphatics, which accompany the femoral vessels to drain into the deep inguinal lymph nodes. **C.** Lymph from the superficial and deep inguinal lymph nodes traverses the external and common iliac nodes before entering the lateral lumbar (aortic) lymph nodes and the lumbar lymphatic trunk.

vein. Some also passes to the **deep inguinal lymph nodes**, located under the deep fascia on the medial aspect of the femoral vein. The lymphatic vessels accompanying the small saphenous vein enter the **popliteal lymph nodes**, which surround the popliteal vein in the fat of the popliteal fossa (Fig. 5.15B).

Deep lymphatic vessels from the leg accompany deep veins and also enter the popliteal lymph nodes. Most lymph from these nodes ascends through deep lymphatic vessels to

the *deep inguinal lymph nodes*. Lymph from the deep nodes passes to the external and common iliac lymph nodes and then enters the **lumbar lymphatic trunks** (Fig. 5.15C).

Cutaneous Innervation of Lower Limb

Cutaneous nerves in the subcutaneous tissue supply the skin of the lower limb (Fig. 5.16; Table 5.1). These nerves, except for some proximal unisegmental nerves arising from the T12

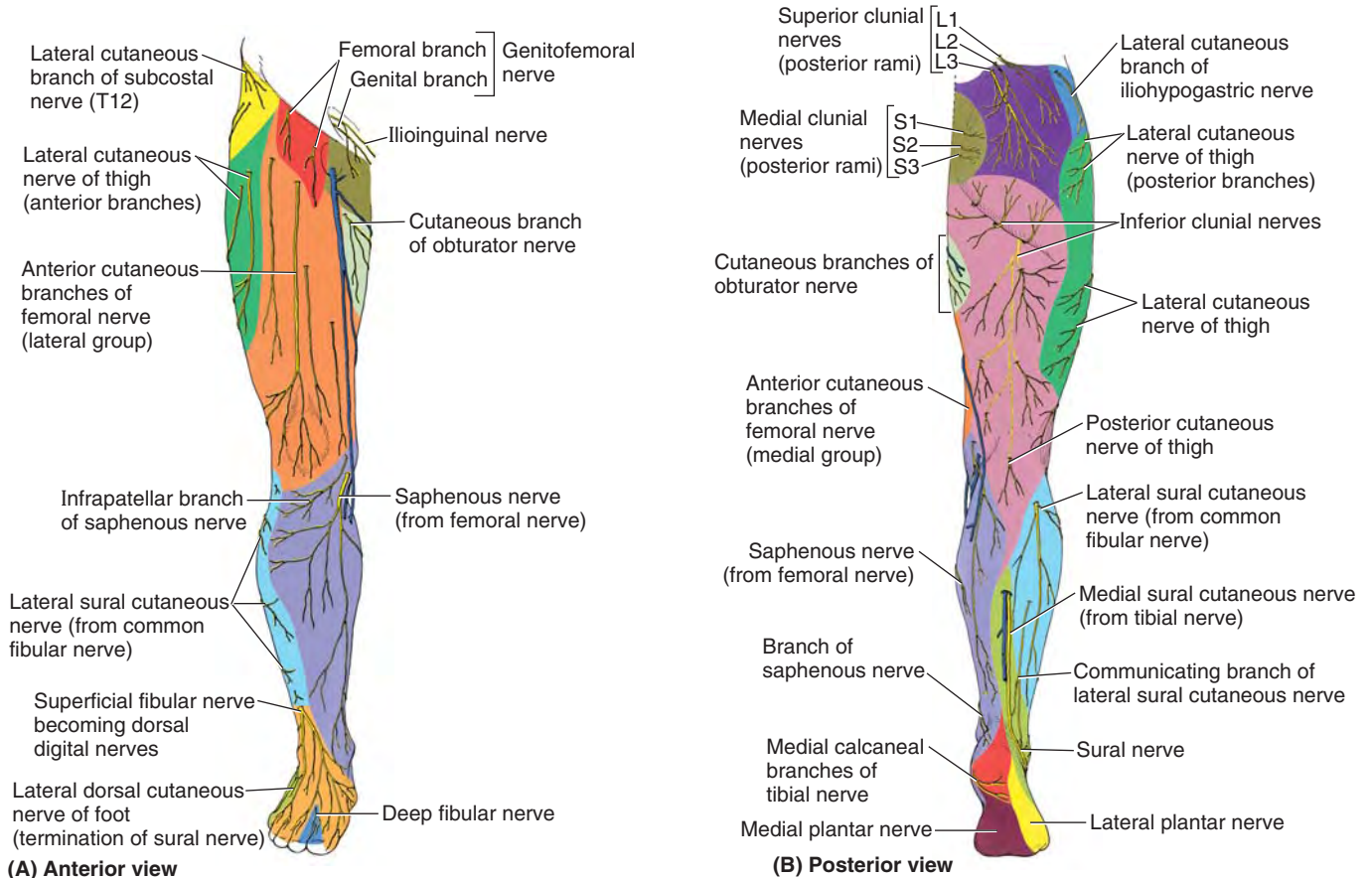


FIGURE 5.16. Cutaneous nerves of lower limb.

TABLE 5.1. CUTANEOUS NERVES OF LOWER LIMB

| Nerve | Origin (Contributing Spinal Nerves) | Course | Distribution in Lower Limb |
|-------------------------------------|--|--|--|
| Subcostal | T12 anterior ramus | Courses along inferior border of 12th rib; lateral cutaneous branch descends over iliac crest | Lateral cutaneous branch supplies skin of hip region inferior to anterior part of iliac crest and anterior to greater trochanter |
| Ilioypogastric | Lumbar plexus (L1; occasionally T12) | Parallels iliac crest; divides into lateral and anterior cutaneous branches | Lateral cutaneous branch supplies superolateral quadrant of buttock |
| Ilioinguinal | Lumbar plexus (L1; occasionally T12) | Passes through inguinal canal; divides into femoral and scrotal or labial branches | Femoral branch supplies skin over medial femoral triangle |
| Genitofemoral | Lumbar plexus (L1–L2) | Descends anterior surface of psoas major; divides into genital and femoral branches | Femoral branch supplies skin over lateral part of femoral triangle; genital branch supplies anterior scrotum or labia majora |
| Lateral cutaneous nerve of thigh | Lumbar plexus (L2–L3) | Passes deep to inguinal ligament, 2–3 cm medial to anterior superior iliac spine | Supplies skin on anterior and lateral aspects of thigh |
| Anterior cutaneous branches | Lumbar plexus via femoral nerve (L2–L4) | Arise in femoral triangle; pierce fascia lata along path of sartorius muscle | Supply skin of anterior and medial aspects of thigh |
| Cutaneous branch of obturator nerve | Lumbar plexus via obturator nerve, anterior branch (L2–L4) | Following its descent between adductors longus and brevis, anterior division of obturator nerve pierces fascia lata to reach skin of thigh | Skin of middle part of medial thigh |

TABLE 5.1. CUTANEOUS NERVES OF LOWER LIMB (Continued)

| Nerve | Origin (Contributing Spinal Nerves) | Course | Distribution in Lower Limb |
|------------------------------------|--|--|--|
| Posterior cutaneous nerve of thigh | Sacral plexus (S1–S3) | Enters gluteal region via infrapiriform portion of greater sciatic foramen deep to gluteus maximus; then descends deep to fascia lata | Terminal branches pierce fascia lata to supply skin of posterior thigh and popliteal fossa |
| Saphenous nerve | Lumbar plexus via femoral nerve (L3–L4) | Traverses adductor canal but does not pass through adductor hiatus; crossing medial side of knee deep to sartorius tendon | Skin on medial side of leg and foot |
| Superficial fibular nerve | Common fibular nerve (L4–S1) | Courses through lateral compartment of leg; after supplying fibular muscles, perforates deep fascia of leg | Skin of anterolateral leg and dorsum of foot, excluding web between great and 2nd toes |
| Deep fibular nerve | Common fibular nerve (L5) | After supplying muscles on dorsum of foot, pierces deep fascia superior to heads of 1st and 2nd metatarsals | Skin of web between great and 2nd toes |
| Sural nerve | Tibial and common fibular nerves (S1–S2) | Medial sural cutaneous branch of tibial nerve and lateral sural cutaneous branch of fibular nerve merge at varying levels on posterior leg | Skin of posterolateral leg and lateral margin of foot |
| Medial plantar nerve | Tibial nerve (L4–L5) | Passes between first and second layers of plantar muscles; then between medial and middle muscles of first layer | Skin of medial side of sole, and plantar aspect, sides, and nail beds of medial 3½ toes |
| Lateral plantar nerve | Tibial nerve (S1–S2) | Passes between first and second layers of plantar muscles; then between middle and lateral muscles of first layer | Skin of lateral sole, and plantar aspect, sides, and nail beds of lateral 1½ toes |
| Calcaneal nerves | Tibial and sural nerves (S1–S2) | Lateral and medial branches of tibial and sural nerves, respectively, over calcaneal tuberosity | Skin of heel |
| Superior clunial nerves | L1–L3 posterior rami | Penetrate thoracodorsal fascia; course laterally and inferiorly in subcutaneous tissue | Skin overlying superior and central parts of buttock |
| Medial clunial nerves | S1–S3 posterior rami | Emerge from dorsal sacral foramina; directly enter overlying subcutaneous tissue | Skin of medial buttock and intergluteal cleft |
| Inferior clunial nerves | Posterior cutaneous nerve of thigh (S2–S3) | Arise deep to gluteus maximus; emerge from beneath inferior border of muscle | Skin of inferior buttock (overlying gluteal fold) |

or L1 spinal nerves, are branches of the *lumbar* and *sacral plexuses*. The areas of skin supplied by the individual spinal nerves, including those contributing to the plexuses, are called **dermatomes**. The dermatomal (segmental) pattern of skin innervation is retained throughout life but is distorted by limb lengthening and the torsion of the limb that occurs during development (Figs. 5.2 and 5.17).

Although simplified into distinct zones in dermatome maps, adjacent dermatomes overlap, except at the **axial line**, the line of junction of dermatomes supplied from discontinuous spinal levels. The cutaneous nerves of the lower limb are illustrated in Figure 5.16 and their origin (including contributing spinal nerves), course, and distribution are listed in Table 5.1.

Motor Innervation of Lower Limb

Somatic motor (general somatic efferent) fibers traveling in the same mixed peripheral nerves that convey sensory fibers to the cutaneous nerves transmit impulses to the muscles of the lower limb. The unilateral embryological muscle mass receiving innervation from a single spinal cord segment or spinal nerve comprise a **myotome**. Lower limb muscles usually receive motor fibers from several spinal cord segments or nerves. Thus, most muscles are composed of more than one myotome, and most often multiple spinal cord segments are involved in producing the movement of the lower limb (Fig. 5.18).

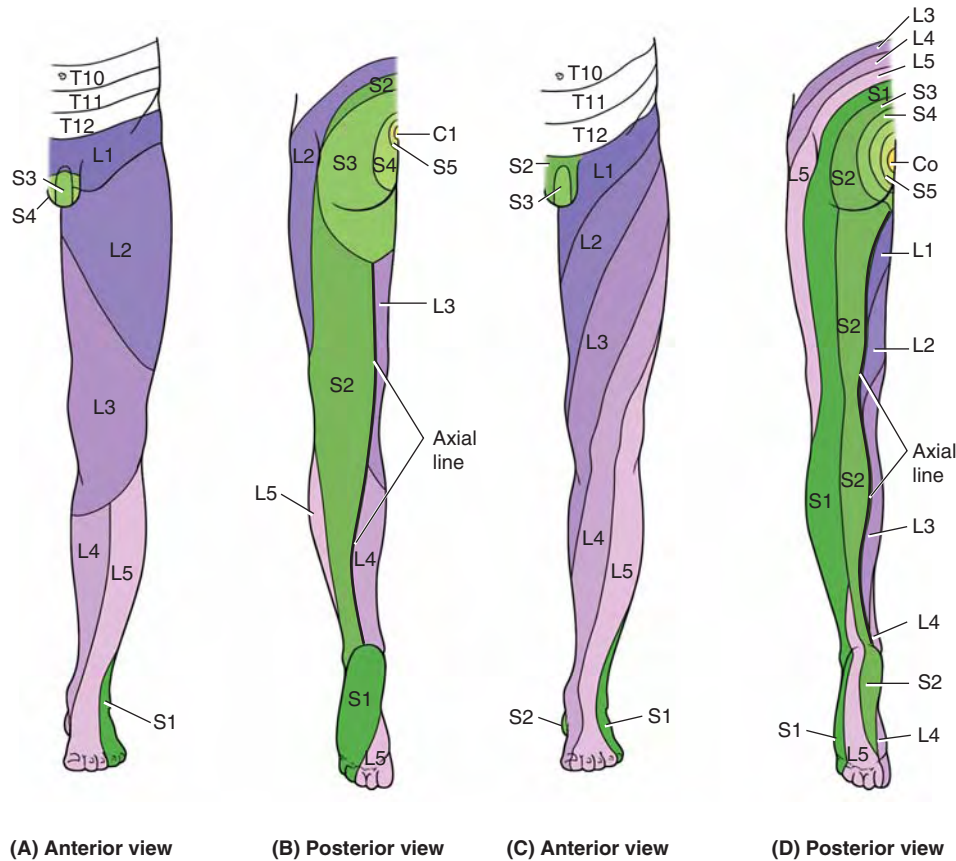


FIGURE 5.17. Dermatomes of lower limb. The dermatomal or segmental pattern of distribution of sensory nerve fibers persists despite the merging of spinal nerves in plexus formation during development. Two different dermatome maps are commonly used. **A and B.** The dermatome pattern of the lower limb according to Foerster (1933) is preferred by many because of its correlation with clinical findings. **C and D.** The dermatome pattern of the lower limb according to Keegan and Garrett (1948) is preferred by others for its aesthetic uniformity and obvious correlation with development. Although depicted as distinct zones, adjacent dermatomes overlap considerably, except along the axial line.

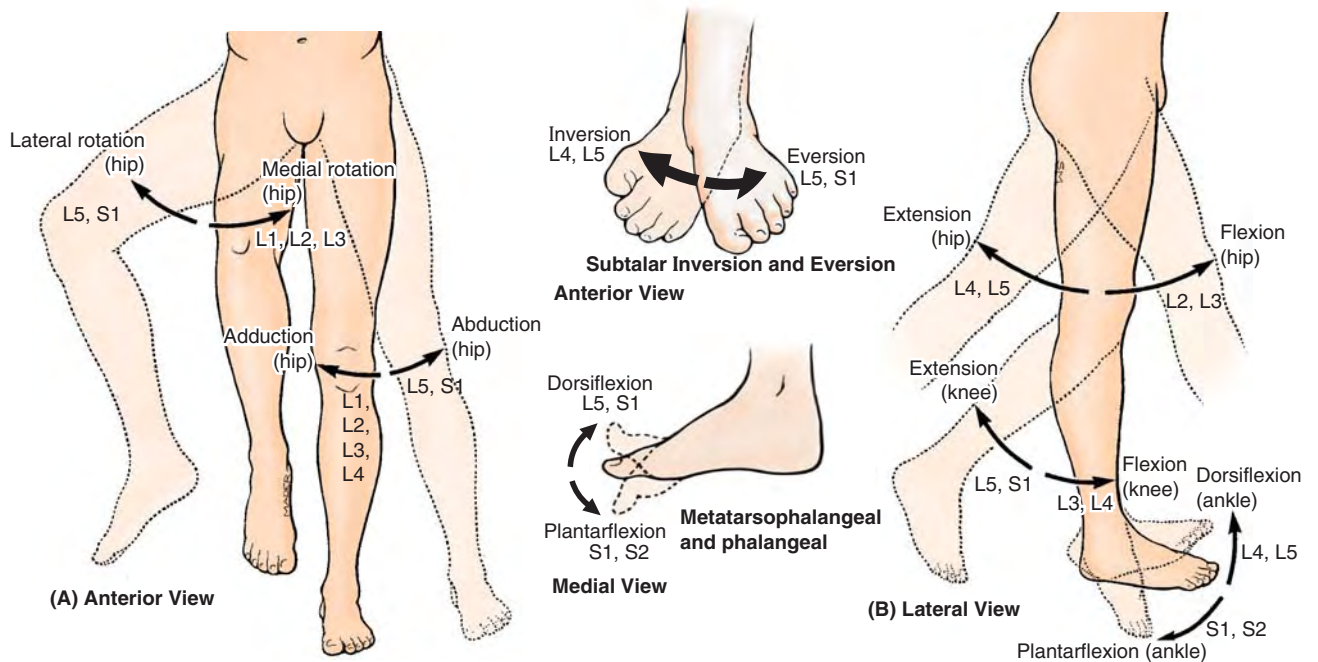


FIGURE 5.18. Myotomes: segmental innervation of muscle groups and movements of lower limb. The level of spinal cord injury or nerve impingement may be determined by the strength and ability to perform particular movements.

FASCIA, VEINS, LYMPHATICS, AND CUTANEOUS NERVES OF LOWER LIMB

Compartment Syndromes and Fasciotomy



The fascial compartments of the lower limbs are generally closed spaces, ending proximally and distally at the joints. Trauma to muscles and/or vessels in the compartments from burns, sustained intense use of muscles, or blunt trauma may produce hemorrhage, edema, and inflammation of the muscles. Because the septa and deep fascia of the leg forming the boundaries of the leg compartments are strong, the increased volume consequent to any of these processes increases intracompartmental pressure.

The pressure may reach levels high enough to compress structures significantly in the compartment(s) concerned. The small vessels of muscles and nerves (*vasa nervorum*) are particularly vulnerable to compression. Structures distal to the compressed area may become ischemic and permanently injured (e.g., loss of motor function in muscles whose blood supply and/or innervation is affected). Increased pressure in a confined anatomical space adversely affects the circulation and threatens the function and viability of tissue within or distally, constituting **compartment syndromes**.

Loss of distal leg pulses is an obvious sign of arterial compression, as is lowering of the temperature of tissues distal to the compression. A **fasciotomy** (incision of overlying fascia or a septum) may be performed to relieve the pressure in the compartment(s) concerned.

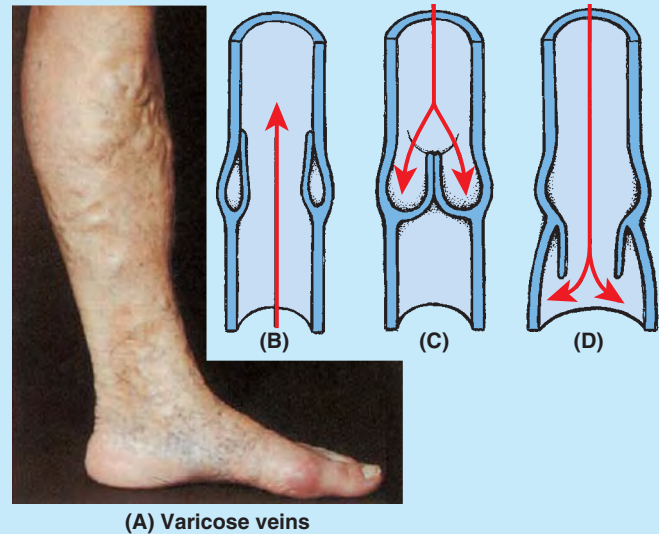
Varicose Veins, Thrombosis, and Thrombophlebitis



Frequently, the great saphenous vein and its tributaries become **varicose** (dilated so that the cusps of their valves do not close). *Varicose veins* are common in the posteromedial parts of the lower limb and may cause discomfort (Fig. B5.11A). In a healthy vein, the valves allow blood to flow toward the heart (B) while keeping blood from flowing away from the heart (C). Valves in varicose veins (D) are incompetent due to dilation or rotation and no longer function properly. As a result, blood flows inferiorly in the veins, producing varicose veins.

Deep venous thrombosis (DVT) of one or more of the deep veins of the lower limb is characterized by swelling, warmth, and *erythema* (inflammation and infection). **Venous stasis** (stagnation) is an important cause of thrombus formation. Venous stasis can be caused by:

- Incompetent, loose fascia that fails to resist muscle expansion, diminishing the effectiveness of the musculovenous pump.



(A) Varicose veins

FIGURE B5.11.

- External pressure on the veins from bedding during a prolonged hospital stay or from a tight cast or bandage.
- Muscular inactivity (e.g., during an overseas aircraft flight).

DVT with inflammation around the involved veins (**thrombophlebitis**) may develop. A large thrombus that breaks free from a lower limb vein may travel to a lung, forming a **pulmonary thromboembolism** (obstruction of a pulmonary artery). A large embolus may obstruct a main pulmonary artery and may cause death.

Saphenous Vein Grafts



The great saphenous vein is sometimes used for coronary arterial bypasses because (1) it is readily accessible, (2) a sufficient distance occurs between the tributaries and the perforating veins so that usable lengths can be harvested, and (3) its wall contains a higher percentage of muscular and elastic fibers than do other superficial veins.

Saphenous vein grafts are used to bypass obstructions in blood vessels (e.g., in an intracoronary thrombus). When part of the great saphenous vein is removed for a bypass, the vein is inverted so that the valves do not obstruct blood flow in the venous graft. Because there are so many other leg veins, removal of the great saphenous vein rarely produces a significant problem in the lower limb or seriously affects circulation, provided the deep veins are intact. In fact, removal of this vein may facilitate the superficial to deep drainage pattern to take advantage of the musculovenous pump.

Saphenous Cutdown and Saphenous Nerve Injury



Even when it is not visible in infants, in obese people, or in patients in shock whose veins are collapsed, the great saphenous

vein can always be located by making a skin incision anterior to the medial malleolus (Fig. 5.14A). This procedure, called a **saphenous cutdown**, is used to insert a cannula for prolonged administration of blood, plasma expanders, electrolytes, or drugs.

The saphenous nerve accompanies the great saphenous vein anterior to the medial malleolus. Should this nerve be cut during a saphenous cutdown or caught by a ligature during closure of a surgical wound, the patient may complain of pain or numbness along the medial border of the foot.

Enlarged Inguinal Lymph Nodes



Lymph nodes enlarge when diseased. **Abrasions** and minor sepsis, caused by pathogenic microorganisms or their toxins in the blood or other tissues, may produce moderate enlargement of the superficial inguinal lymph nodes (**lymphadenopathy**) in otherwise healthy people. Because these enlarged nodes are located in subcutaneous tissue, they are usually easy to palpate.

When inguinal lymph nodes are enlarged, their entire field of drainage—the trunk inferior to the umbilicus, including the perineum, as well as the entire lower limb—should be examined to determine the cause of their enlargement. In female patients, the relatively remote possibility of metastasis of cancer from the uterus should also be considered because some lymphatic drainage from the uterine fundus may flow along lymphatics accompanying the round ligament

of the uterus through the inguinal canal to reach the superficial inguinal lymph nodes. All palpable lymph nodes should also be examined.

Regional Nerve Blocks of Lower Limbs



Interruption of the conduction of impulses in peripheral nerves (nerve block) may be achieved by making perineural injections of anesthetics close to the nerves whose conductivity is to be blocked.

The femoral nerve (L2–L4) can be blocked 2 cm inferior to the inguinal ligament, approximately a finger's breadth lateral to the femoral artery. **Paresthesia** (tingling, burning, tickling) radiates to the knee and over the medial side of the leg if the saphenous nerve (terminal branch of femoral) is affected.

Abnormalities of Sensory Function



In most instances, a peripheral nerve sensitizing an area of skin represents more than one segment of the spinal cord. Therefore, to interpret abnormalities of peripheral sensory function, peripheral nerve distribution of the major cutaneous nerves must be interpreted as anatomically different from dermatome distribution of the spinal cord segments (Fig. 5.17). Neighboring dermatomes may overlap.

Pain sensation is tested by using a sharp object and asking the patient if pain is felt. If there is no sensation, the spinal cord segment(s) involved can be determined.

The Bottom Line

FASCIA, EFFERENT VESSELS, AND CUTANEOUS NERVES OF LOWER LIMB

Fascia: The lower limb is invested by subcutaneous tissue and deep fascia. ♦ The former insulates, stores fat, and provides passage for cutaneous nerves and superficial vessels (lymphatics and veins). ♦ The deep fascia of the thigh (fascia lata) and leg (crural fascia) (1) surround the thigh and leg, respectively, limiting outward bulging of muscles and facilitating venous return in deep veins; (2) separate muscles with similar functions and innervation into compartments; and (3) surround individual muscles, allowing them to act independently.

♦ Modifications of the deep fascia include openings that allow the passage of neurovascular structures (e.g., the saphenous opening) and thickenings that retain tendons close to the joints they act on (retinacula).

Veins: The veins of the lower limb include both superficial (in the subcutaneous tissue) and deep (internal to the deep fascia) veins. ♦ The superficial great and small saphenous veins mainly drain the integument or skin and, via many perforating veins, continuously shunt blood to the deep veins accompanying the arteries. ♦ Deep veins are subject to muscle compression (musculovenous pump) to aid venous return. ♦ All lower limb veins have valves to overcome the effects of gravity.

Lymphatic vessels: Most lymph from the lower limb drains via lymphatics that follow the superficial veins (e.g., the saphenous veins) to the superficial inguinal nodes. ♦ Some lymphatics follow deep veins to deep inguinal nodes. Lymph drainage from the lower limb then passes deep to the external and common iliac nodes of the trunk.

Cutaneous nerves: The cutaneous innervation of the lower limb reflects both the original segmental innervation of the skin via separate spinal nerves in its dermatomal pattern, and the result of plexus formation in the distribution of multisegmental peripheral nerves. ♦ Most innervation of the thigh is supplied by lateral and posterior cutaneous nerves of the thigh and anterior cutaneous branches of the femoral nerve, the names of which describe their distribution. The latter branches also supply most of the medial aspect of the thigh. ♦ The innervation of the leg and dorsum of the foot is supplied by saphenous (anteromedial leg), sural (posterolateral leg), and fibular nerves (anterolateral leg and dorsum of foot). ♦ The plantar aspect (sole) of the foot is supplied by calcaneal branches of the tibial and sural nerves (heel region) and the medial and lateral plantar nerves; the areas of distribution of the latter are demarcated by a line bisecting the 4th toe.

POSTURE AND GAIT

The lower limbs function primarily in standing and walking. Typically the actions of lower limb muscles are described as if the muscle were acting in isolation, which rarely occurs.

In this book, including the comments in the tables, the role of each muscle (or of the functional group of which it is a member) is described in typical activities, especially standing and walking. It is important to be familiar with lower limb movements and concentric and eccentric contractions of muscles, as described in the Introduction, and to have a basic understanding of the processes of standing and walking.

Standing at Ease

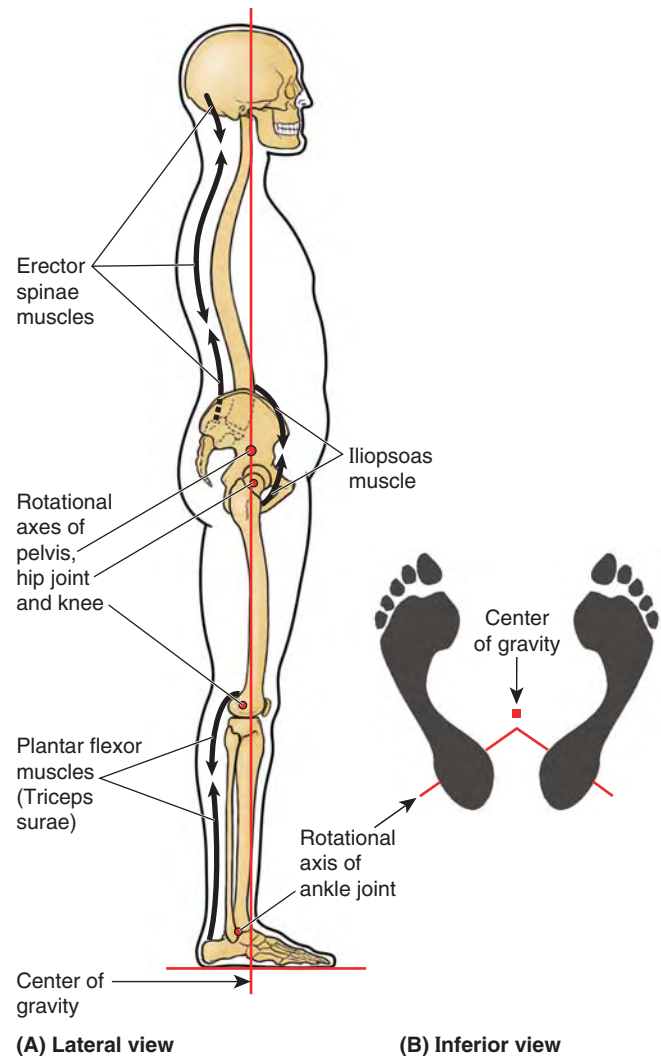
When a person is standing at ease with the feet slightly apart and rotated laterally so the toes point outward, only a few of the back and lower limb muscles are active (Fig. 5.19). The mechanical arrangement of the joints and muscles are such that a minimum of muscular activity is required to keep from falling. In the stand-easy position, the hip and knee joints are extended and are in their most stable positions (maximal contact of articular surfaces for weight transfer, with supporting ligaments taut).

The ankle joint is less stable than the hip and knee joints, and the line of gravity falls between the two limbs just anterior to the axis of rotation of the ankle joints. Consequently, a tendency to fall forward (*forward sway*) must be countered periodically by bilateral contraction of the calf muscles (plantarflexion). The spread or splay of the feet increases lateral stability. However, when *lateral sway* occurs, it is countered by the hip abductors (acting through the iliotibial tract). The fibular collateral ligament of the knee joint and the evertor muscles of one side act with the thigh adductors, tibial collateral ligament, and invertor muscles of the contralateral side.

Walking: The Gait Cycle

Locomotion is a complex function. The movements of the lower limbs during walking on a level surface may be divided into alternating swing and stance phases, illustrated in Figure 5.20 and described in Table 5.2. The **gait cycle** consists of one cycle of swing and stance by one limb. The **stance phase** begins with a **heel strike** (Fig. 5.20A), when the heel strikes the ground and begins to assume the body's full weight (loading response), and ends with a *push off* by the forefoot (Fig. 5.20G)—a result of plantarflexion. (See the blue box "Absence of Plantarflexion," p. 607).

The **swing phase** begins after push off when the toes leave the ground and ends when the heel strikes the ground. The swing phase occupies approximately 40% of the walking cycle and the stance phase, 60%. The stance phase of walking is longer than the swing phase because it begins and ends with relatively short periods (each 10% of the cycle) of double support (both feet are contacting the ground) as the weight is transferred from one side to the other, with a more



(A) Lateral view

(B) Inferior view

FIGURE 5.19. Relaxed standing. **A.** The relationship of the line of gravity to the transverse rotational axes of the pelvis and lower limb in the relaxed standing (stand-easy) position is demonstrated. Only minor postural adjustments, mainly by the extensors of the back and the plantarflexors of the ankle, are necessary to maintain this position because the ligaments of the hip and knee are being tightly stretched to provide passive support. **B.** A bipedal platform is formed by the feet during relaxed standing. The weight of the body is symmetrically distributed around the center of gravity, which falls in the posterior third of a median plane between the slightly parted and laterally rotated feet, anterior to the rotational axes of the ankle joints.

extended period of single support (only one foot on the ground bearing all body weight) in between as the contralateral limb swings forward. In **running**, there is no period of double support; consequently, the time and percentage of the gait cycle represented by the stance phase are reduced.

Walking is a remarkably efficient activity, taking advantage of gravity and momentum so that a minimum of physical exertion is required. Most energy is used (1) in the eccentric contraction of the dorsiflexors during the beginning (**loading response**) phase of stance (Fig. 5.20B) as the heel is lowered

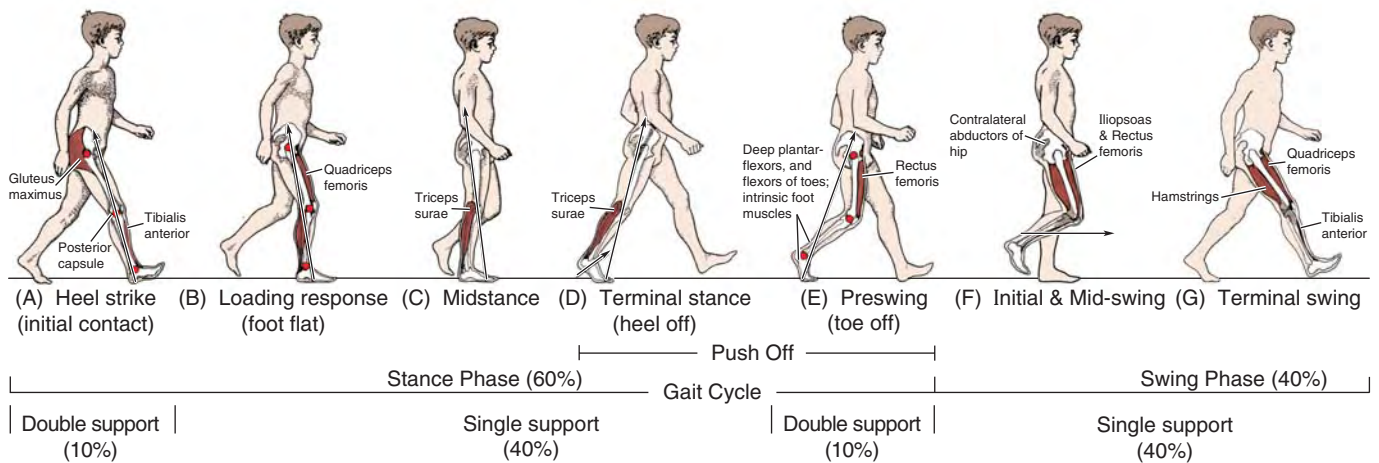


FIGURE 5.20. Gait cycle. The activity of one limb between two repeated events of walking. Eight phases are typically described, two of which have been combined in (F) for simplification.

TABLE 5.2. MUSCLE ACTION DURING GAIT CYCLE

| | Phase of Gait | Mechanical Goals | Active Muscle Groups | Examples |
|---------------------------------------|--------------------------------------|---|---|---|
| STANCE PHASE | Heel strike (initial contact) | Lower forefoot to ground | Ankle dorsiflexors (eccentric contraction) | Tibialis anterior |
| | | Continue deceleration (reverse forward swing) | Hip extensors | Gluteus maximus |
| | | Preserve longitudinal arch of foot | Intrinsic muscles of foot | Flexor digitorum brevis |
| | Long tendons of foot | | Tibialis anterior | |
| | Loading response (flat foot) | Accept weight | Knee extensors | Quadriceps |
| | | Decelerate mass (slow dorsiflexion) | Ankle plantarflexors | Triceps surae (soleus and gastrocnemius) |
| | | Stabilize pelvis | Hip abductors | Gluteus medius and minimus; tensor fasciae latae |
| | | Preserve longitudinal arch of foot | Intrinsic muscles of foot | Flexor digitorum brevis |
| | Long tendons of foot | | Tibialis posterior; long flexors of digits | |
| | Midstance | Stabilize knee | Knee extensors | Quadriceps |
| | | Control dorsiflexion (preserve momentum) | Ankle plantarflexors (eccentric contraction) | Triceps surae (soleus and gastrocnemius) |
| | | Stabilize pelvis | Hip abductors | Gluteus medius and minimus; tensor fasciae latae |
| | | Preserve longitudinal arch of foot | Intrinsic muscles of foot | Flexor digitorum brevis |
| | Long tendons of foot | | Tibialis posterior; long flexors of digits | |
| | Terminal stance (heel off) | Accelerate mass | Ankle plantarflexors (concentric contraction) | Triceps surae (soleus and gastrocnemius) |
| Stabilize pelvis | | Hip abductors | Gluteus medius and minimus; tensor fasciae latae | |
| Preserve arches of foot; fix forefoot | | Intrinsic muscles of foot | Adductor hallucis | |
| | | Long tendons of foot | Tibialis posterior; long flexors of digits | |

TABLE 5.2. MUSCLE ACTION DURING GAIT CYCLE (Continued)

| | Phase of Gait | Mechanical Goals | Active Muscle Groups | Examples |
|----------------------------------|--------------------|---|--|---|
| STANCE PHASE (cont'd.) | Preswing (toe off) | Accelerate mass | Long flexors of digits | Flexor hallucis longus; flexor digitorum longus |
| | | Preserve arches of foot; fix forefoot | Intrinsic muscles of foot | Adductor hallucis |
| | | | Long tendons of foot | Tibialis posterior; long flexors of digits |
| | | Decelerate thigh; prepare for swing | Flexor of hip (eccentric contraction) | Iliopsoas; rectus femoris |
| SWING PHASE | Initial swing | Accelerate thigh; vary cadence | Flexor of hip (concentric contraction) | Iliopsoas; rectus femoris |
| | | Clear foot | Ankle dorsiflexors | Tibialis anterior |
| | Midswing | Clear foot | Ankle dorsiflexors | Tibialis anterior |
| | Terminal swing | Decelerate thigh | Hip extensors (eccentric contraction) | Gluteus maximus; hamstrings |
| | | Decelerate leg | Knee flexors (eccentric contraction) | Hamstrings |
| | | Position foot | Ankle dorsiflexors | Tibialis anterior |
| | | Extend knee to place foot (control stride); prepare for contact | Knee extensors | Quadriceps |

to the ground following heel strike and (2) especially at the end of stance (**terminal stance**; Fig. 5.20D) as the plantarflexors concentrically contract, pushing the forefoot (metatarsals and phalanges) down to produce push off, thus providing most of the propulsive force.

During the last part of the stance phase (**push off** or *toe off*; Fig. 5.20E), the toes flex to grip the ground and augment the push off initiated from the ball of the foot (sole underlying the heads of the medial two metatarsals). The long flexors and intrinsic muscles of the foot stabilize the forefoot and toes so that the effect of plantarflexion at the ankle and flexion of the toes is maximized.

The swing phase also involves flexion of the hip so that the free limb accelerates faster than the forward movement of the body. During **initial swing** (Fig. 5.20F), the knee flexes almost simultaneously, owing to momentum (without expenditure of energy), followed by dorsiflexion (lifting the forefoot up) at the ankle joint. The latter two movements have the effect of shortening the free limb so that it will clear the ground as it swings forward. By **midswing**, knee extension is added to the flexion and momentum of the thigh to realize anterior swing fully.

The extensors of the hip and flexors of the knee contract eccentrically at the end of swing phase (**terminal swing**; Fig. 5.20G) to decelerate the forward movement, while extensors of the knee (quadriceps) contract as necessary to extend the leg for the desired length of stride and to position the foot (present the heel) for heel strike.

Contraction of the knee extensors is maintained through the heel strike into the loading phase to absorb shock and keep the knee from buckling until it reaches full extension. Because the unsupported side of the hip tends to drop during the swing phase (which would negate the effect of limb shortening), abductor muscles on the supported side contract strongly during the single support part of the stance phase (Fig. 5.20F & G), pulling on the fixed femur to resist the tilting and keep the pelvis level. The same muscles also rotate (advance) the contralateral side of the pelvis forward, concurrent with the swing of its free limb.

Of course, all these actions alternate from side to side with each step. The extensors of the hip normally make only minor contributions to level walking. Primarily, the hip is passively extended by momentum during stance, except when accelerating or walking fast, and becomes increasingly active with increase in slope (steepness) during walking uphill or up stairs. Concentric hip flexion and knee extension are used during the swing phase of level walking and so are not weight-bearing actions; however, they are affected by body weight when their eccentric contraction is necessary for deceleration or walking downhill or down stairs.

Stabilization and resilience are important during locomotion. The invertors and evertors of the foot are principal stabilizers of the foot during the stance phase. Their long tendons, plus those of the flexors of the digits, also help support the arches of the foot during the stance phase, assisting the intrinsic muscles of the sole.

ANTERIOR AND MEDIAL REGIONS OF THIGH

Organization of Proximal Lower Limb

During evolution, the development of a prominent gluteal region is closely associated with the assumption of bipedalism and an erect posture. The prominent gluteal region is unique to humans. Modification of the shape of the femur necessary for bipedal walking and running (specifically the “bending” of the bone, creating the angle of inclination and the trochanters, p. 518) allows the superior placement of the abductors of the thigh into the gluteal region.

The remaining thigh muscles are organized into three compartments by intermuscular septa that pass deeply between the muscle groups from the inner surface of the fascia lata to the linea aspera of the femur (see Fig. 5.13D). The compartments are *anterior or extensor*, *medial or adductor*, and *posterior or flexor*, so named on the basis of their location or action at the knee joint. Generally, the anterior group is innervated by the femoral nerve, the medial group by the obturator nerve, and the posterior group by the tibial portion of the sciatic nerve. Although the compartments vary in absolute and relative size depending on the level, the anterior compartment is the largest overall and includes the femur.

To facilitate continuity and follow an approach commonly used in dissection courses, the anterior and medial compartments of the thigh are addressed initially, followed by continuous examination of the posterior aspect of the proximal limb: gluteal region and posterior thigh. This approach is then continued by consideration of the popliteal fossa and leg.

Anterior Thigh Muscles

The large **anterior compartment of the thigh** contains the **anterior thigh muscles**, the *flexors of the hip* (Fig. 5.21A–D) and *extensors of the knee* (Fig. 5.21E–I). For attachments, nerve supply, and main actions of these muscles, see Tables 5.3.I and 5.3.II. The anterior thigh muscles include the pectineus, iliopsoas, sartorius, and quadriceps femoris.¹

The major muscles of the anterior compartment tend to atrophy (diminish) rapidly with disease, and physical therapy is often necessary to restore strength, tone, and symmetry with the opposite limb after immobilization of the thigh or leg.

PECTINEUS

The **pectineus** is a flat quadrangular muscle located in the anterior part of the superomedial aspect of the thigh (Fig. 5.21A & B; Table 5.3.I). It often appears to be composed of two layers, superficial and deep, and these are generally innervated by two different nerves. Because of the dual nerve supply and the muscle’s actions (the pectineus adducts and flexes the thigh and

¹ Because of its anterior position, the tensor fasciae latae is often studied with the anterior thigh muscles for convenience (i.e., when the cadaver is supine); however, it is actually part of the gluteal group and will be included with that group in this book.

assists in medial rotation of the thigh), it is actually a transitional muscle between the anterior and medial compartments.

ILIOPSOAS

The **iliopsoas** is the chief flexor of the thigh, the most powerful of the hip flexors with the longest range. Although it is one of the body’s most powerful muscles, it is relatively hidden, with most of its mass located in the posterior wall of the abdomen and greater pelvis. Its broad lateral part, the **iliacus**, and its long medial part, the **psoas major**, arise from the iliac fossa and lumbar vertebrae, respectively (Fig. 5.21C; Table 5.3.I). Thus it is the only muscle attached to the vertebral column, pelvis, and femur. It is in a unique position not only to produce movement but to stabilize (fixate). However, it can also perpetuate and even contribute to deformity and disability when it is malformed (especially if it is shortened), dysfunctional, or diseased.

Concentric contraction of the iliopsoas typically moves the free limb, producing flexion at the hip to lift the limb and initiate its forward swing during walking (i.e., during the preswing and initial swing phases) as the opposite limb accepts weight (Fig. 5.20E & F) or to elevate the limb during climbing. However, it is also capable of moving the trunk. Bilateral contraction of the iliopsoas muscles initiates flexion of the trunk at the hip on the fixed thigh—as when (incorrectly) doing sit-ups—and decreases the lumbar lordosis (curvature) of the vertebral column. It is active during walking downhill, its eccentric contraction resisting acceleration.

The iliopsoas is also a postural muscle, active during standing in maintaining normal lumbar lordosis (and indirectly the compensatory thoracic kyphosis; see Chapter 4) and resisting hyperextension of the hip joint (see Fig. 5.19).

SARTORIUS

The **sartorius**, the “tailor’s muscle” (L. *sartus*, patched or repaired), is long and ribbon-like. It passes lateral to medial across the superoanterior part of the thigh (Fig. 5.21D; Table 5.3.I). The sartorius lies superficially in the anterior compartment, within its own relatively distinct fascial sheath. It descends inferiorly as far as the medial side of the knee.

The sartorius, the longest muscle in the body, acts across two joints. It flexes the hip joint and participates in flexion of the knee joint. It also weakly abducts the thigh and laterally rotates it. The actions of both sartorius muscles bring the lower limbs into the cross-legged sitting position. None of the actions of the sartorius is strong; therefore, it is mainly a synergist, acting with other thigh muscles that produce these movements.

QUADRICEPS FEMORIS

The **quadriceps femoris** (L., four-headed femoral muscle) forms the main bulk of the anterior thigh muscles and collectively constitutes the largest and one of the most powerful muscles in the body. It covers almost all the anterior aspect and sides of the femur (Fig. 5-21E–I). The quadriceps femoris (usually shortened to quadriceps) consists of four parts: (1) rectus femoris, (2) vastus lateralis, (3) vastus intermedius, and

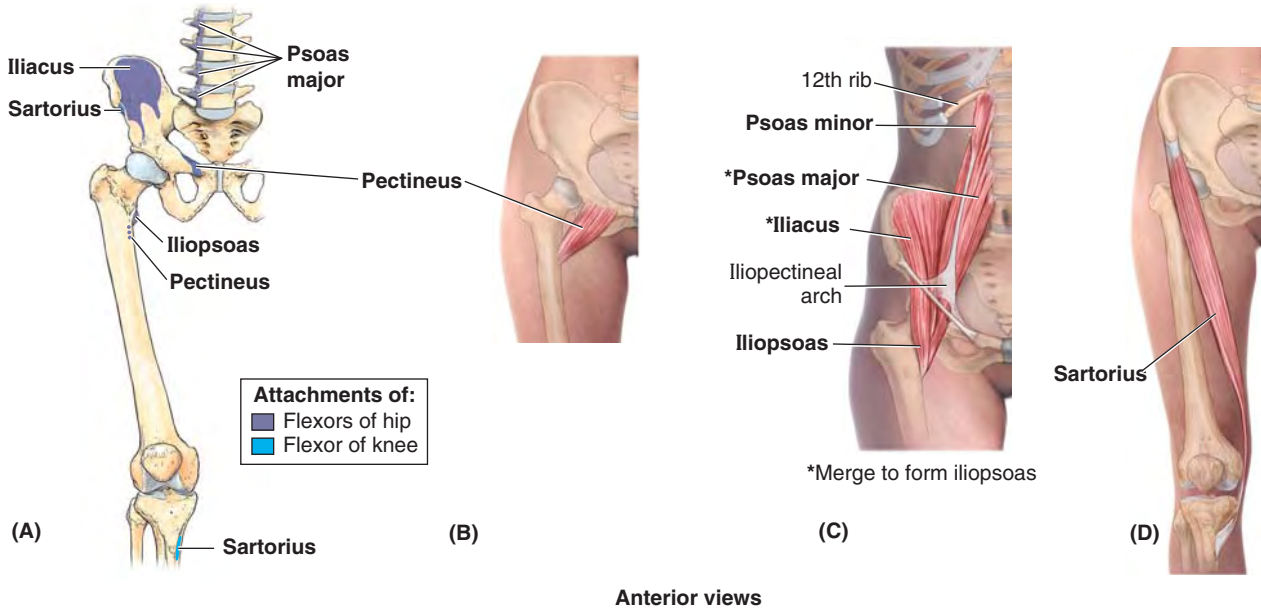


FIGURE 5.21. Muscles of anterior thigh: flexors of hip joint.

TABLE 5.3.I. MUSCLES OF ANTERIOR THIGH: FLEXORS OF HIP JOINT

| Muscle | Proximal Attachment ^a | Distal Attachment | Innervation ^b | Main Action(s) |
|---|--|--|--|---|
| Pectineus (Fig. 5.21A & B) | Superior ramus of pubis | Pectineal line of femur, just inferior to lesser trochanter | Femoral nerve (L2, L3); may receive a branch from obturator nerve | Adducts and flexes thigh; assists with medial rotation of thigh |
| Iliopsoas (Fig. 5.21A & C) Psoas major | Sides of T12–L5 vertebrae and discs between them; transverse processes of all lumbar vertebrae | Lesser trochanter of femur | Anterior rami of lumbar nerves (L1, L2, L3) | Act conjointly in flexing thigh at hip joint and in stabilizing this joint ^c |
| Psoas minor | Sides of T12–L1 vertebrae and intervertebral discs | Pectineal line, iliopectineal eminence via iliopectineal arch | Anterior rami of lumbar nerves (L1, L2) | |
| Iliacus | Iliac crest, iliac fossa, ala of sacrum, and anterior sacroiliac ligaments | Tendon of psoas major, lesser trochanter, and femur distal to it | Femoral nerve (L2, L3) | |
| Sartorius (Fig. 5.21A & D) | Anterior superior iliac spine and superior part of notch inferior to it | Superior part of medial surface of tibia | Femoral nerve (L2, L3) | Flexes, abducts, and laterally rotates thigh at hip joint; flexes leg at knee joint, (medially rotating leg when knee is flexed) ^d |

^a The Latin word *insertio* means *attachment*. The terms insertion and origin (L. *origo*) have not been used here (or elsewhere) since they change with function.

^b The spinal cord segmental innervation is indicated (e.g., “L1, L2, L3” means that the nerves supplying the psoas major are derived from the first three lumbar segments of the spinal cord). Numbers in boldface (**L1, L2**) indicate the main segmental innervation. Damage to one or more of the listed spinal cord segments or to the motor nerve roots arising from them results in paralysis of the muscles concerned.

^c The psoas major is also a postural muscle that helps control the deviation of the trunk and is active during standing.

^d The four actions of the sartorius (L. *sartor*, tailor) produce the once common cross-legged sitting position used by tailors, hence the name.

(4) vastus medialis. Collectively, the quadriceps is a two-joint muscle capable of producing action at both the hip and knee.

The quadriceps is the great extensor of the leg. Concentric contraction of the quadriceps to extend the knee against gravity is important during rising from sitting or squatting, climbing and walking up stairs, and for acceleration and projection

(running and jumping) when it is lifting or moving the body’s weight. Consequently, it may be three times stronger than its antagonistic muscle group, the hamstrings.

In level walking, the quadriceps muscles become active during the termination of the swing phase, preparing the knee to accept weight (Fig. 5.20G; Table 5.2). The quadriceps is

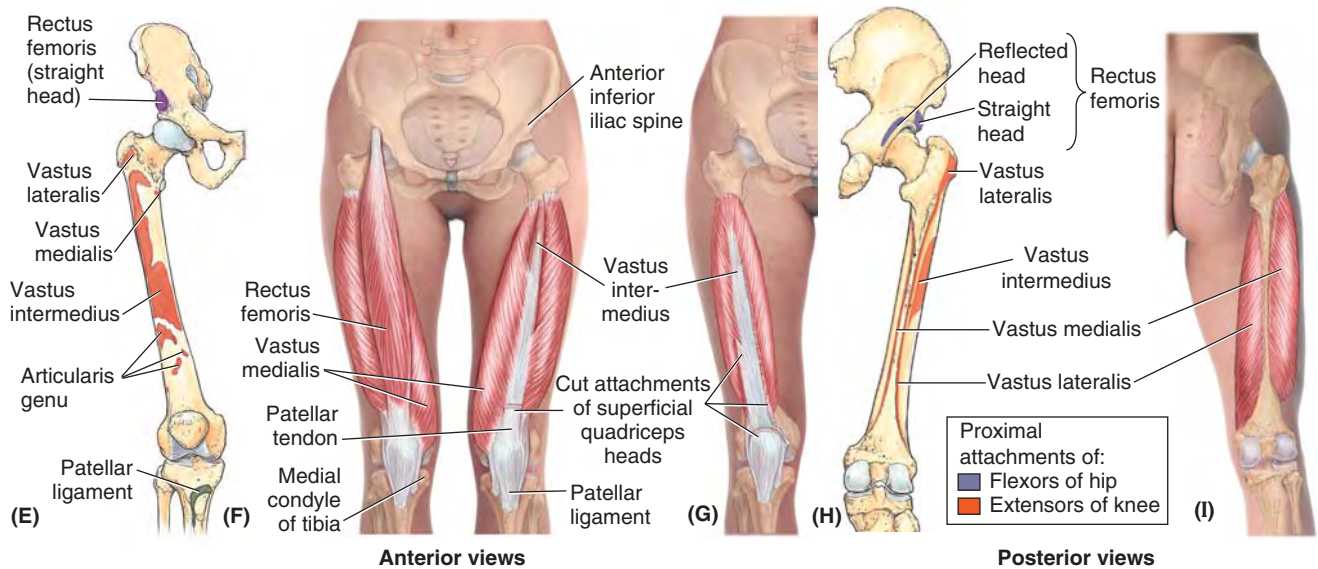


FIGURE 5.21. Muscles of anterior thigh (*continued*): extensors of knee.

TABLE 5.3.II. MUSCLES OF ANTERIOR THIGH: EXTENSORS OF KNEE

| Muscle | Proximal Attachment | Distal Attachment | Innervation ^a | Main Action |
|-----------------------------------|--|--|------------------------------------|---|
| Quadriceps femoris (Fig. 5.21E–H) | | | | |
| Rectus femoris | Anterior inferior iliac spine and ilium superior to acetabulum | Via common tendinous (quadriceps tendon) and independent attachments to base of patella; indirectly via patellar ligament to tibial tuberosity; medial and lateral vasti also attach to tibia and patella via aponeuroses (medial and lateral patellar retinacula) | Femoral nerve (L2, L3 , L4) | Extend leg at knee joint; rectus femoris also steadies hip joint and helps iliopsoas flex thigh |
| Vastus lateralis | Greater trochanter and lateral lip of linea aspera of femur | | | |
| Vastus medialis | Intertrochanteric line and medial lip of linea aspera of femur | | | |
| Vastus intermedius | Anterior and lateral surfaces of shaft of femur | | | |

^aThe spinal cord segmental innervation is indicated (e.g., “L1, L2, L3” means that the nerves supplying the quadriceps femoris are derived from the first three lumbar segments of the spinal cord). Numbers in boldface (**L3**, **L4**) indicate the main segmental innervation. Damage to one or more of the listed spinal cord segments or to the motor nerve roots arising from them results in paralysis of the muscles concerned.

primarily responsible for absorbing the jarring shock of heel strike, and its activity continues as the weight is assumed during the early stance phase (loading response). It also functions as a fixator during bent-knee sports, such as skiing and tennis, and contracts eccentrically during downhill walking and descending stairs.

The tendons of the four parts of the quadriceps unite in the distal portion of the thigh to form a single, strong, broad **quadriceps tendon** (Fig. 5.21F). The **patellar ligament** (L. *ligamentum patellae*), attached to the tibial tuberosity, is the continuation of the quadriceps tendon in which the patella is embedded. The *patella* is thus the largest sesamoid bone in the body.

The medial and lateral vasti muscles also attach independently to the patella and form aponeuroses, the **medial** and

lateral patellar retinacula, which reinforce the joint capsule of the knee joint on each side of the patella en route to attachment to the anterior border of the tibial plateau. The retinacula also play a role in keeping the patella aligned over the patellar surface of the femur.

The **patella** provides a bony surface that is able to withstand the compression placed on the quadriceps tendon during kneeling and the friction occurring when the knee is flexed and extended during running. The patella also provides additional leverage for the quadriceps in placing the tendon more anteriorly, farther from the joint's axis, causing it to approach the tibia from a position of greater mechanical advantage. The inferiorly directed apex of the patella indicates the level of the joint plane of the knee when the leg is extended and the patellar ligament is taut.

*Testing the quadriceps*² is performed with the person in the supine position with the knee partly flexed. The person extends the knee against resistance. During the test, contraction of the rectus femoris should be observable and palpable if the muscle is acting normally, indicating that its nerve supply is intact.

Rectus Femoris. The **rectus femoris** received its name because it runs straight down the thigh (L. *rectus*, straight). Because of its attachments to the hip bone and tibia via the patellar ligament (Fig. 5.21E & F), it *crosses two joints*; hence it is capable of flexing the thigh at the hip joint and extending the leg at the knee joint. The rectus femoris is the only part of the quadriceps that crosses the hip joint, and as a hip flexor it acts with and like the iliopsoas during the preswing and initial swing phases of walking (Fig. 5.20F; Table 5.2).

The ability of the rectus femoris to extend the knee is compromised during hip flexion, but it does contribute to the extension force during the toe off phase of walking, when the thigh is extended. It is particularly efficient in movements combining knee extension and hip flexion from a position of hip hyperextension and knee flexion, as in the preparatory position for kicking a soccer ball. The rectus femoris is susceptible to injury and avulsion from the anterior inferior iliac spine during kicking, hence the name “kicking muscle.” A loss of function of the rectus femoris may reduce thigh flexion strength by as much as 17%.

Vastus Muscles. The names of the three large **vastus muscles** (*vasti*) indicate their position around the femoral shaft (Fig. 5.21E–I; Table 5.3.II):

² There are entire texts dedicated to the testing of muscles. We are providing only a few important examples useful to primary care health professionals.

- **Vastus lateralis**, the largest component of the quadriceps, lies on the lateral side of the thigh.
- **Vastus medialis** covers the medial side of the thigh.
- **Vastus intermedius** lies deep to the rectus femoris, between the vastus medialis and vastus lateralis.

It is difficult to isolate the function of the three vastus muscles.

The small, flat **articularis genu** (articular muscle of the knee), a derivative of the vastus intermedius, usually consists of a variable number of muscular slips that attach superiorly to the inferior part of the anterior aspect of the femur and inferiorly to the synovial membrane of the knee joint and the wall of the *suprapatellar bursa* (Figs. 5.21E and 5.22). The articularis genu muscle pulls the synovial membrane superiorly during extension of the leg, thereby preventing folds of the membrane from being compressed between the femur and the patella within the knee joint.

Medial Thigh Muscles

The muscles of the medial compartment of the thigh comprise the **adductor group**, consisting of the adductor longus, adductor brevis, adductor magnus, gracilis, and obturator externus (Fig. 5.23). In general, they attach proximally to the anteroinferior external surface of the bony pelvis (pubic bone, ischiopubic ramus, and ischial tuberosity) and adjacent obturator membrane, and distally to the linea aspera of the femur (Fig. 5.23A; Table 5.4)

All adductor muscles, except the “hamstring part” of the adductor magnus and part of the pectineus are supplied by the *obturator nerve* (L2–L4). The hamstring part of the adductor magnus is supplied by the tibial part of the sciatic

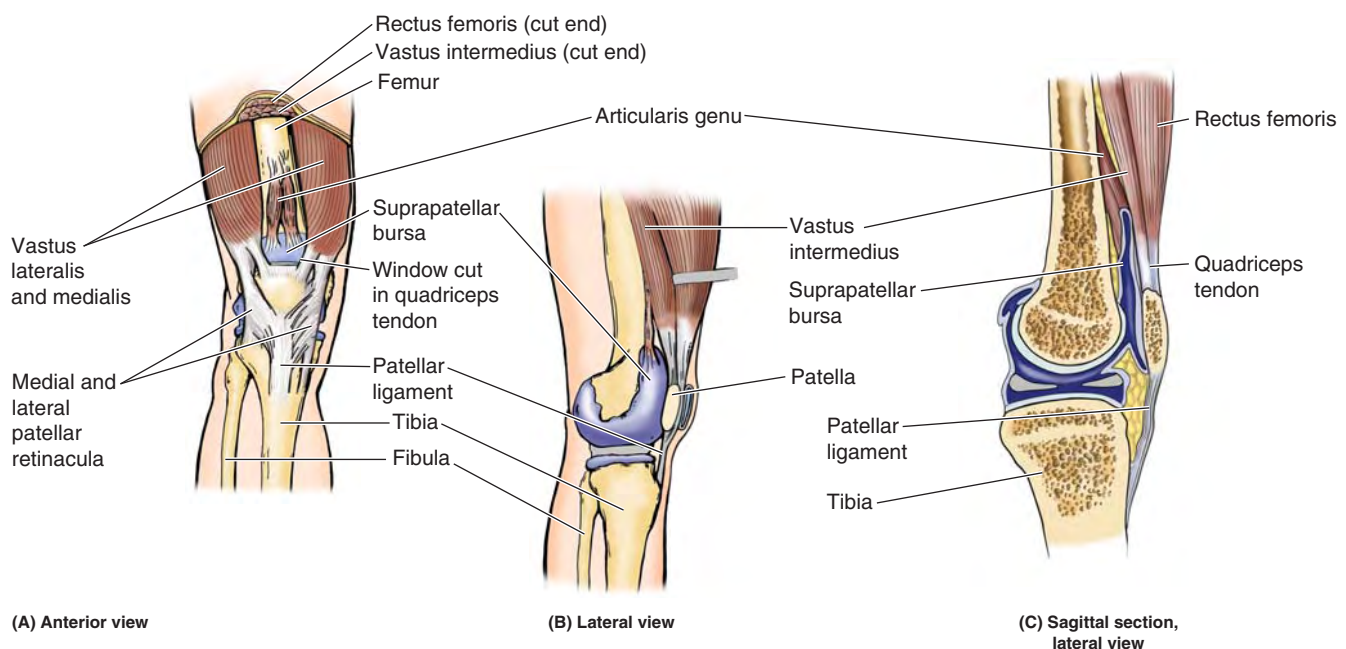


FIGURE 5.22. Suprapatellar bursa and articularis genu. In A and B, the suprapatellar bursa, normally a potential space extending between the quadriceps and the femur (exaggerated for schematic purposes in C), is depicted as if injected with latex.

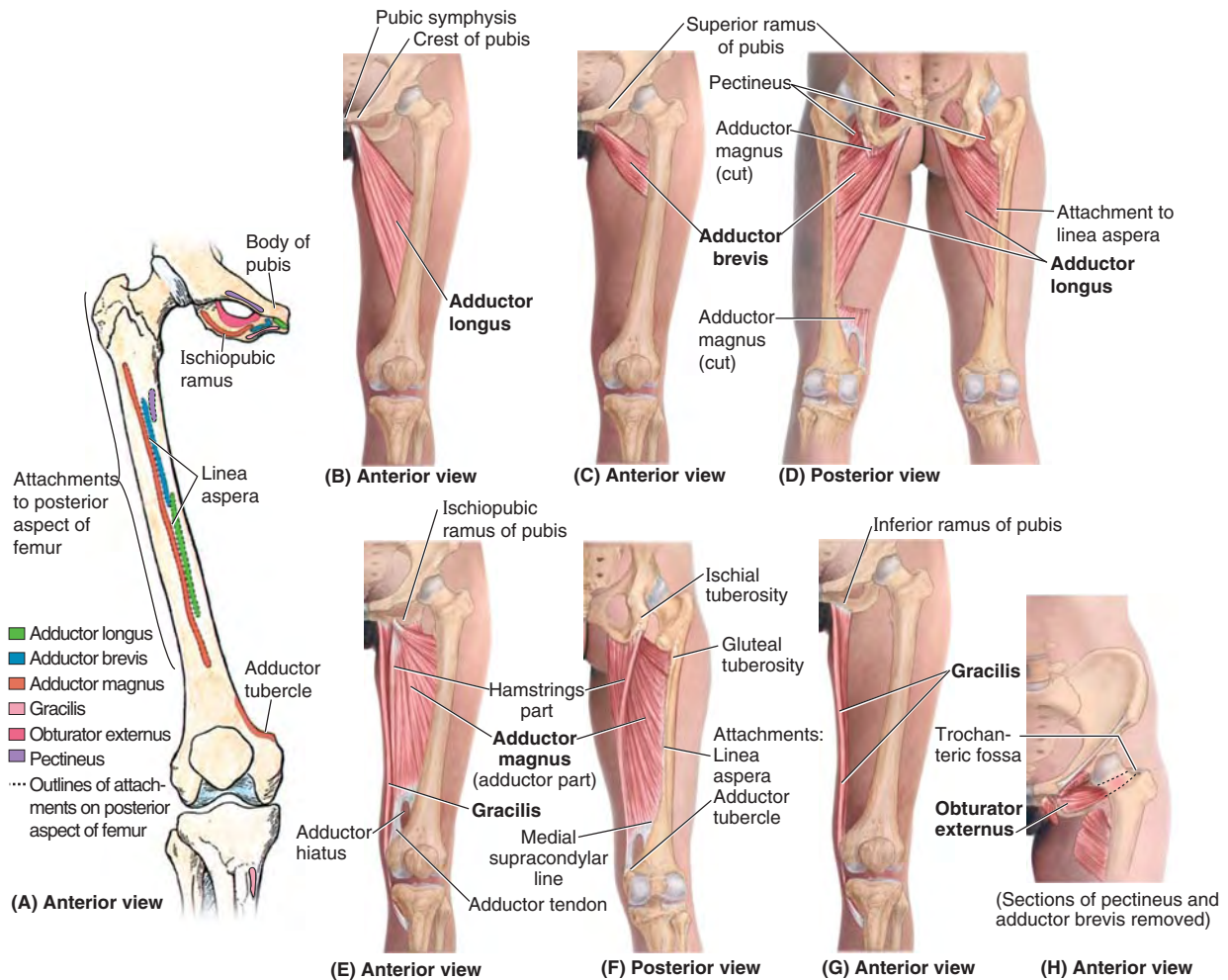


FIGURE 5.23. Muscles of medial thigh: adductors of thigh.

TABLE 5.4. MUSCLES OF MEDIAL THIGH: ADDUCTORS OF THIGH

| Muscle ^a | Proximal Attachment | Distal Attachment | Innervation ^b | Main Action |
|--------------------------------------|---|--|---|--|
| Adductor longus (Fig. 5.23E & G) | Body of pubis inferior to pubic crest | Middle third of linea aspera of femur | Obturator nerve, branch of, anterior division (L2, L3 , L4) | Adducts thigh |
| Adductor brevis (Fig. 5.23F & G) | Body and inferior ramus of pubis | Pectineal line and proximal part of linea aspera of femur | | Adducts thigh; to some extent flexes it |
| Adductor magnus (Fig. 5.23C, D, & G) | Adductor part: inferior ramus of pubis, ramus of ischium Hamstrings part: ischial tuberosity | Adductor part: gluteal tuberosity, linea aspera, medial supracondylar line Hamstring part: adductor tubercle of femur | Adductor part: obturator nerve (L2, L3 , L4), branches of posterior division Hamstring part: tibial part of sciatic nerve (L4) | Adducts thigh Adductor part: flexes thigh Hamstrings part: extends thigh |
| Gracilis (Fig. 5.23H) | Body and inferior ramus of pubis | Superior part of medial surface of tibia. | Obturator nerve (L2 , L3) | Adducts thigh; flexes leg; helps rotate leg medially |
| Obturator externus | Margins of obturator foramen and obturator membrane | Trochanteric fossa of femur | Obturator nerve (L3, L4) | Laterally rotates thigh; steadies head of femur in acetabulum |

^a Collectively, the five muscles listed are the adductors of the thigh, but their actions are more complex (e.g., they act as flexors of the hip joint during flexion of the knee joint and are active during walking).

^b The spinal cord segmental innervation is indicated (e.g., “L2, L3, L4” means that the nerves supplying the adductor longus are derived from the second to fourth lumbar segments of the spinal cord). Numbers in boldface (**L3**) indicate the main segmental innervation. Damage to one or more of the listed spinal cord segments or to the motor nerve roots arising from them results in paralysis of the muscles concerned.

nerve (L4). The details of their attachments, nerve supply, and actions of the muscles are provided in Table 5.4.

ADDUCTOR LONGUS

The **adductor longus** is a large, fan-shaped muscle and is the most anteriorly placed of the adductor group. The triangular long adductor arises by a strong tendon from the anterior aspect of the body of the pubis just inferior to the pubic tubercle (apex of triangle) and expands to attach to the linea aspera of the femur (base of triangle) (Fig. 5.23A & B); in so doing it covers the anterior aspects of the adductor brevis and the middle of the adductor magnus.

ADDUCTOR BREVIS

The **adductor brevis**, the short adductor, lies deep to the pectineus and adductor longus where it arises from the body and inferior ramus of the pubis. It widens as it passes distally to attach to the superior part of the linea aspera (Fig. 5.23A, C, & D).

As the obturator nerve emerges from the obturator canal to enter the medial compartment of the thigh, it splits into an anterior and a posterior division. The two divisions pass anterior and posterior to the adductor brevis. This unique relationship is useful in identifying the muscle during dissection and in anatomical cross-sections.

ADDUCTOR MAGNUS

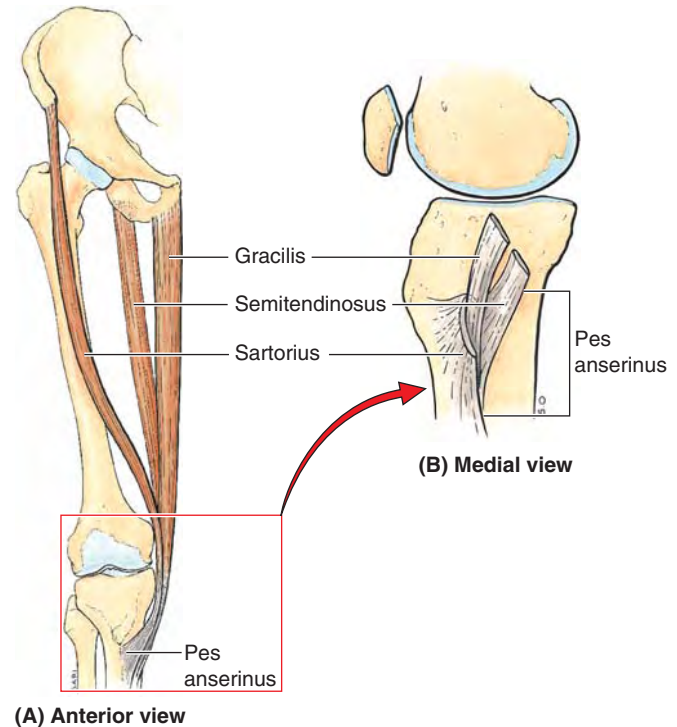
The **adductor magnus** is the largest, most powerful, and most posterior muscle in the adductor group. This adductor is a composite, triangular muscle with a thick, medial margin that has an *adductor part* and a *hamstring part*. The two parts differ in their attachments, nerve supply, and main actions (Table 5.4).

The adductor part fans out widely for aponeurotic distal attachment along the entire length of the linea aspera of the femur, extending inferiorly onto the medial supracondylar ridge (Fig. 5.23A, E, & F). The hamstring part has a tendinous distal attachment to the adductor tubercle.

GRACILIS

The **gracilis** (L., slender) is a long, strap-like muscle and is the most medial muscle of the thigh. It is the most superficial of the adductor group and the weakest member. It is the only one of the group to cross the knee joint as well as the hip joint. The gracilis joins with two other two-joint muscles from the other two compartments (the *sartorius* and *semitendinosus* muscles) (Fig. 5.24). Thus the three muscles are innervated by three different nerves. They have a common tendinous insertion, the **pes anserinus** (L., goose's foot), into the superior part of the medial surface of the tibia.

The gracilis is a synergist in adducting the thigh, flexing the knee, and rotating the leg medially when the knee is flexed. It acts with the other two “pes anserinus” muscles to add sta-



(A) Anterior view

FIGURE 5.24. Pes anserinus. A. Contributing muscles. B. Converging tendons forming pes anserinus.

bility to the medial aspect of the extended knee, much as the gluteus maximus and tensor fasciae latae do via the iliotibial tract on the lateral side.

OBTURATOR EXTERNUS

The **obturator externus** is a flat, relatively small, fan-shaped muscle that is deeply placed in the superomedial part of the thigh. It extends from the external surface of the obturator membrane and surrounding bone of the pelvis to the posterior aspect of the greater trochanter, passing directly under the acetabulum and neck of the femur (Fig 5.23H).

ACTIONS OF ADDUCTOR MUSCLE GROUP

From the anatomical position, the main action of the adductor group is to pull the thigh medially, toward or past the median plane. Three adductors (longus, brevis, and magnus) are used in all movements in which the thighs are adducted (e.g., pressed together when riding a horse).

They are also used to stabilize the stance when standing on both feet, to correct a lateral sway of the trunk, or when there is a side-to-side shift of the surface on which one is standing (rocking a boat, standing on a balance board). They are also used in kicking with the medial side of the foot in soccer and in swimming. Finally, they contribute to flexion of the extended thigh and extension of the flexed thigh when running or against resistance.

The adductors as a group constitute a large muscle mass. Although they are important in many activities, it has been

shown that a reduction of as much as 70% in their function will result in only a slight to moderate impairment of hip function (Markhede and Stener, 1981).

Testing of the medial thigh muscles is performed while the person is lying supine with the knee straight. The person adducts the thigh against resistance, and if the adductors are normal, the proximal ends of the gracilis and adductor longus can easily be palpated.

ADDUCTOR HIATUS

The **adductor hiatus** is an opening or gap between the aponeurotic distal attachment of the adductor part of the adductor magnus and the tendinous distal attachment of the hamstring part (Fig. 5.23E). The adductor hiatus transmits the femoral artery and vein from the adductor canal in the thigh to the popliteal fossa posterior to the knee. The opening is located just lateral and superior to the adductor tubercle of the femur.

Neurovascular Structures and Relationships in Anteromedial Thigh

FEMORAL TRIANGLE

The **femoral triangle**, a subfascial formation, is a triangular landmark useful in dissection and in understanding relationships in the groin (Fig. 5.25A & B). In living people it appears as a triangular depression inferior to the inguinal ligament when the thigh is flexed, abducted, and laterally rotated (Fig. 5.25A). The femoral triangle is bounded (Fig 5.25B):

- Superiorly by the *inguinal ligament* (thickened inferior margin of external oblique aponeurosis) that forms the *base of the femoral triangle*.
- Medially by the lateral border of the adductor longus.
- Laterally by the sartorius; the *apex* of the femoral triangle is where the medial border of the sartorius crosses the lateral border of the adductor longus.

The muscular *floor of the femoral triangle* is formed by the iliopsoas laterally and the pectineus medially. The *roof of the femoral triangle* is formed by the fascia lata and cribriform fascia, subcutaneous tissue, and skin.

The inguinal ligament actually serves as a flexor retinaculum, retaining structures that pass anterior to the hip joint against the joint during flexion of the thigh. Deep to the inguinal ligament, the **retro-inguinal space** (created as the inguinal ligament spans the gap between the two bony prominences to which it is attached, the ASIS and pubic tubercle) is an important passageway connecting the trunk/abdominopelvic cavity to the lower limb (Fig 5.26A & B).

The retro-inguinal space is divided into two compartments (*L. lacunae*) by a thickening of the iliopsoas fascia, the **iliopectineal arch**, which passes between the deep surface of the inguinal ligament and the *iliopubic eminence* (see Fig. 5.6B). Lateral to the iliopectineal arch is the **muscular compartment of the retro-inguinal space**, through which the ilio-

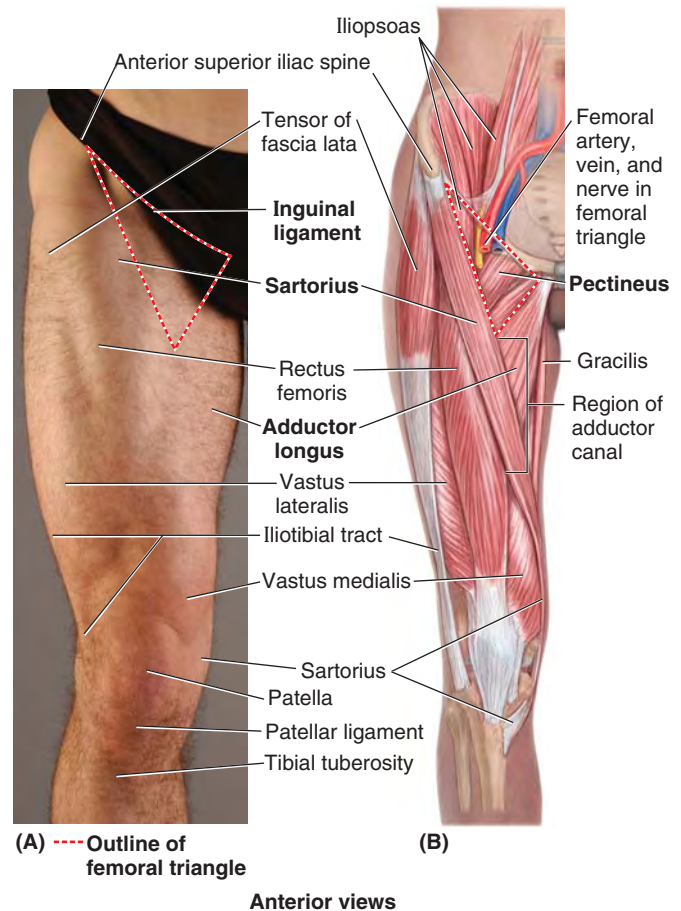


FIGURE 5.25. Surface anatomy of femoral triangle. A. Surface anatomy. B. Underlying structures.

psoas muscle and femoral nerve pass from the greater pelvis into the anterior thigh (Fig. 5.26A & B). Medial to the arch, the **vascular compartment of the retro-inguinal space** allows passage of the major vascular structures (veins, artery, and lymphatics) between the greater pelvis and the femoral triangle of the anterior thigh. As they enter the femoral triangle, the names of the vessels change from *external iliac* to *femoral*.

The contents of the femoral triangle, from lateral to medial, are (Figs. 5.26B and 5.27A & B) the:

- Femoral nerve and its (terminal) branches.
- Femoral sheath and its contents:
 - Femoral artery and several of its branches.
 - Femoral vein and its proximal tributaries (e.g., the great saphenous and deep femoral veins).
 - Deep inguinal lymph nodes and associated lymphatic vessels.

The femoral triangle is bisected by the femoral artery and vein, which pass to and from the adductor canal inferiorly at the triangle's apex (Fig. 5.27A). The **adductor canal** is an intermuscular passageway deep to the sartorius by which the major neurovascular bundle of the thigh traverses the middle third of the thigh (Figs. 5.27B and 5.30).

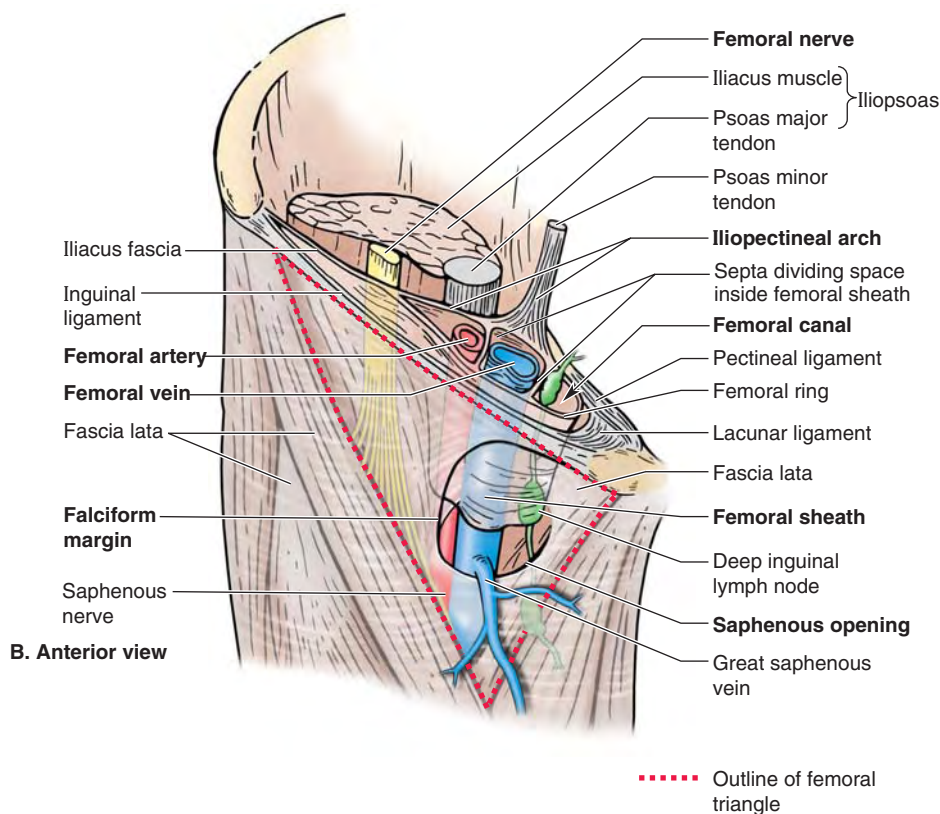
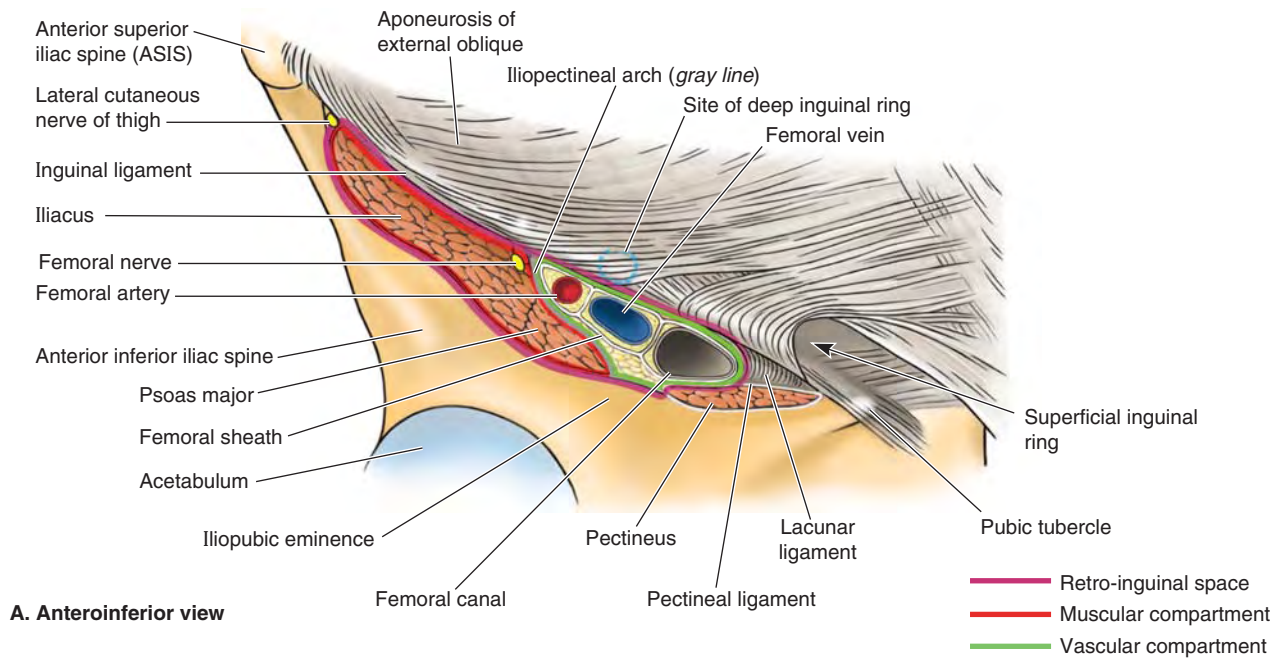


FIGURE 5.26. Retro-inguinal space; structure and contents of femoral sheath. **A.** Compartments of retro-inguinal space and structures traversing them to enter femoral triangle. **B.** This dissection of superior end of anterior aspect of the right thigh demonstrates the distal continuation of the structures cut in **A.** Note the compartments within the femoral sheath. The proximal end (abdominal opening) of the femoral canal is the femoral ring.

FEMORAL NERVE

The **femoral nerve** (L2–L4) is the largest branch of the lumbar plexus. The nerve originates in the abdomen within the psoas major and descends posterolaterally through the pelvis to approximately the midpoint of the inguinal ligament (Figs. 5.26B and 5.27A). It then passes deep to this lig-

ament and enters the femoral triangle, lateral to the femoral vessels.

After entering the femoral triangle, the femoral nerve divides into several branches to the anterior thigh muscles. It also sends articular branches to the hip and knee joints and provides several cutaneous branches to the anteromedial side of the thigh (Table 5.1).

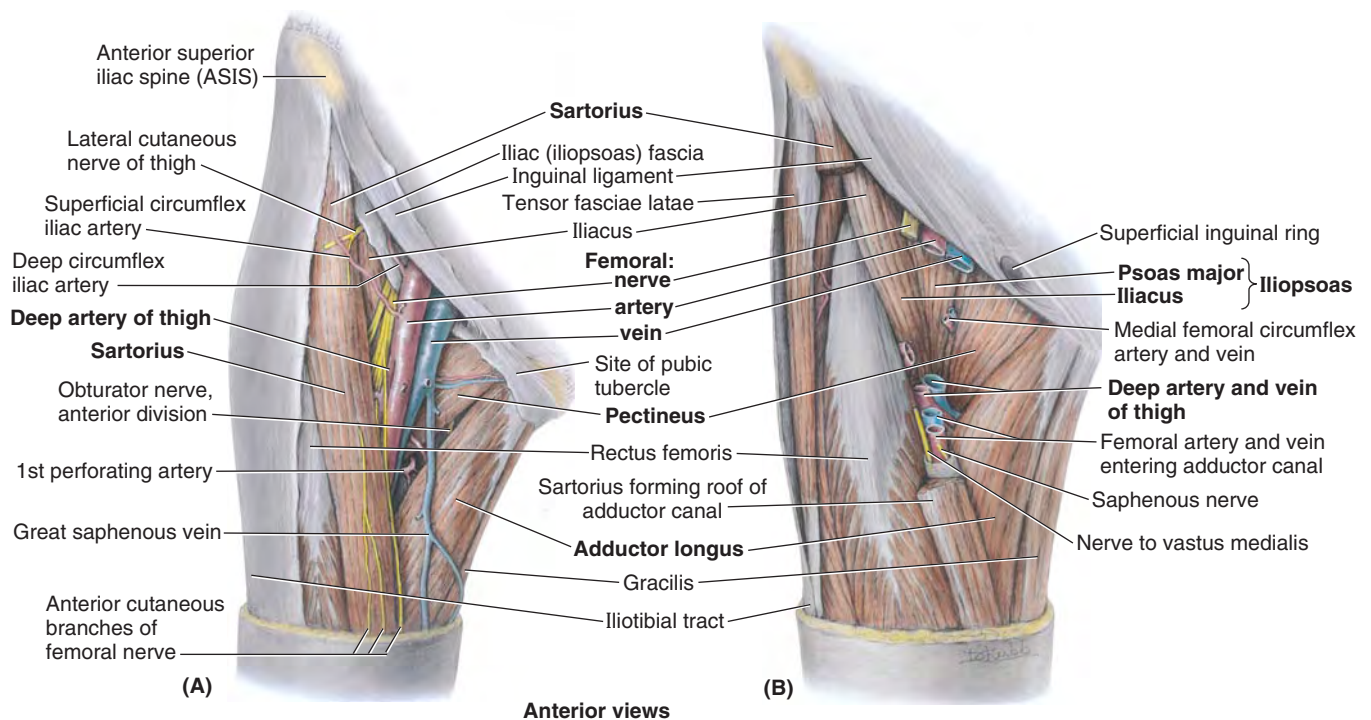


FIGURE 5.27. Structures of femoral triangle. **A.** The boundaries and contents of femoral triangle. The triangle is bound by the inguinal ligament superiorly, the adductor longus medially, and the sartorius laterally. The femoral nerve and vessels enter the base of the triangle superiorly and exit from its apex inferiorly. **B.** In this deeper dissection, sections have been removed from the sartorius and femoral vessels and nerve. Observe the muscles forming the floor of the femoral triangle: the iliopsoas laterally and the pectineus medially. Of the neurovascular structures at the apex of the femoral triangle, the two anterior vessels (femoral artery and vein) and the two nerves enter the adductor canal (anterior to adductor longus), and the two posterior vessels (deep artery and vein of thigh) pass deep (posterior) to the adductor longus.

The terminal cutaneous branch of the femoral nerve, the **saphenous nerve**, descends through the femoral triangle, lateral to the femoral sheath containing the femoral vessels (Figs. 5.26B and 5.27A). The saphenous nerve accompanies the femoral artery and vein through the adductor canal and becomes superficial by passing between the sartorius and gracilis when the femoral vessels traverse the adductor hiatus at the distal end of the canal. It runs anteroinferiorly to supply the skin and fascia on the anteromedial aspects of the knee, leg, and foot.

FEMORAL SHEATH

The **femoral sheath** is a funnel-shaped fascial tube of varying length (usually 3–4 cm) that passes deep to the inguinal ligament, lining the vascular compartment of the retro-inguinal space (Fig. 5.28). It terminates inferiorly by blending with the adventitia of the femoral vessels. The sheath encloses proximal parts of the femoral vessels and creates the femoral canal medial to them (Figs. 5.26B and 5.28B).

The femoral sheath is formed by an inferior prolongation of transversalis and iliopsoas fascia from the abdomen. The femoral sheath does not enclose the femoral nerve because it passes through the muscular compartment. When a long femoral sheath occurs (extends farther distally), its medial wall is pierced by the great saphenous vein and lymphatic vessels (Fig. 5.28).

The femoral sheath allows the femoral artery and vein to glide deep to the inguinal ligament during movements of the hip joint.

The femoral sheath lining the vascular compartment is subdivided internally into three smaller compartments by vertical septa of extraperitoneal connective tissue that extend from the abdomen along the femoral vessels (Figs. 5.26B and 5.28B). The compartments of the femoral sheath are the:

- *Lateral compartment* for the femoral artery.
- *Intermediate compartment* for the femoral vein.
- *Medial compartment*, which constitutes the femoral canal.

The **femoral canal** is the smallest of the three compartments of the femoral sheath. It is conical and short (approximately 1.25 cm) and lies between the medial edge of the femoral sheath and the femoral vein. The femoral canal:

- Extends distally to the level of the proximal edge of the saphenous opening.
- Allows the femoral vein to expand when venous return from the lower limb is increased, or when increased intra-abdominal pressure causes a temporary stasis in the vein (as during a *Valsalva maneuver*, i.e., taking a breath and holding it, often while bearing down).
- Contains loose connective tissue, fat, a few lymphatic vessels, and sometimes a deep inguinal lymph node (lacunar node).

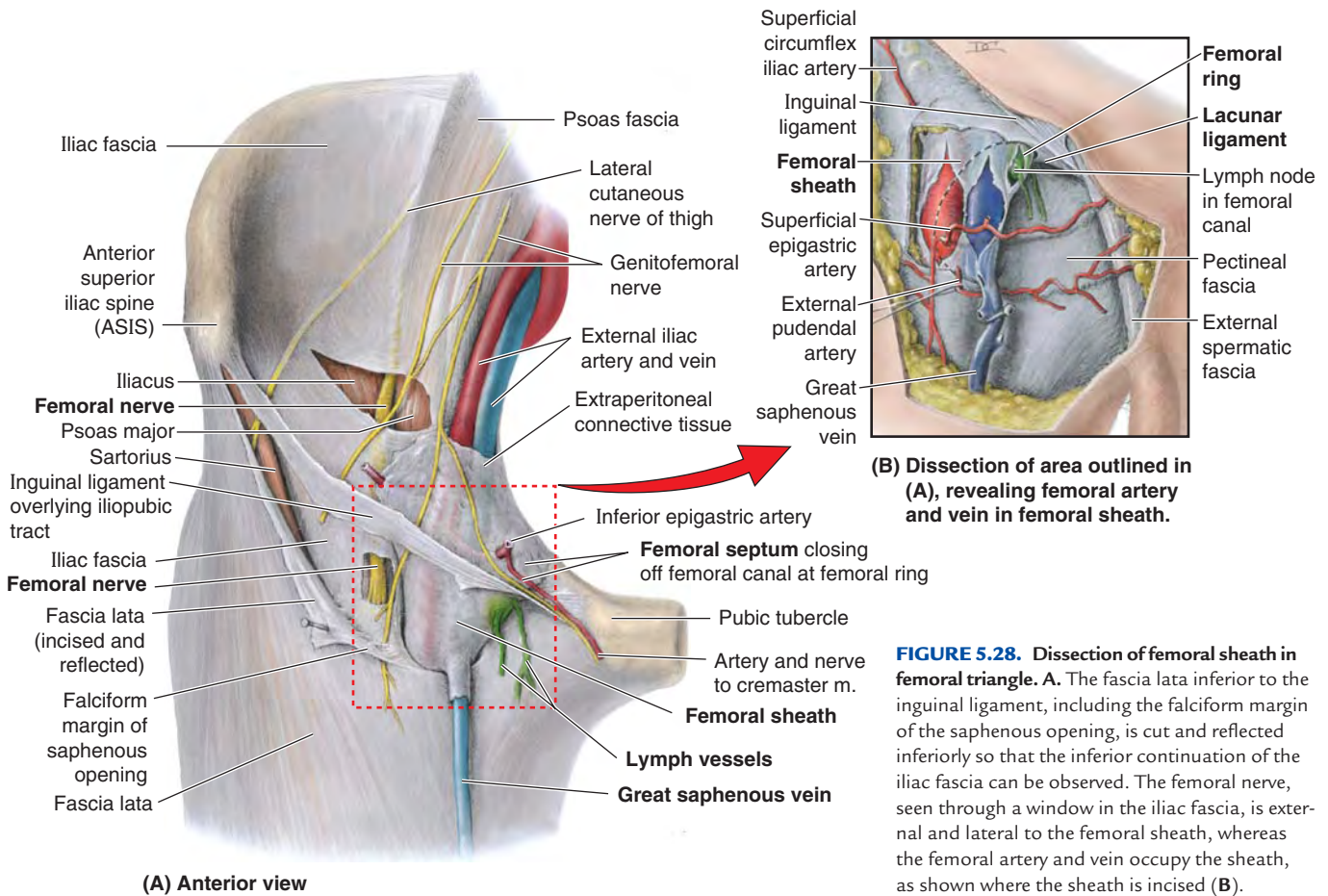


FIGURE 5.28. Dissection of femoral sheath in femoral triangle. **A.** The fascia lata inferior to the inguinal ligament, including the falciform margin of the saphenous opening, is cut and reflected inferiorly so that the inferior continuation of the iliac fascia can be observed. The femoral nerve, seen through a window in the iliac fascia, is external and lateral to the femoral sheath, whereas the femoral artery and vein occupy the sheath, as shown where the sheath is incised (**B**).

The base of the femoral canal is the oval **femoral ring** formed by the small (approximately 1 cm wide) proximal opening at its abdominal end. This opening is closed by extraperitoneal fatty tissue that forms the transversely oriented **femoral septum** (Fig. 5.28A). The abdominal surface of the septum is covered by parietal peritoneum. The femoral septum is pierced by lymphatic vessels connecting the inguinal and external iliac lymph nodes.

The boundaries of the femoral ring are (Fig. 5.26B):

- Laterally, the vertical septum between the femoral canal and femoral vein.
- Posteriorly, the superior ramus of the pubis covered by the pectineus muscle and its fascia.
- Medially, the lacunar ligament.
- Anteriorly, the medial part of the inguinal ligament.

FEMORAL ARTERY

Details concerning the origin, course, and distribution of the arteries of the thigh are illustrated in Figure 5.29 and described in Table 5.5.

The **femoral artery**, the continuation of the external iliac artery distal to the inguinal ligament, is the primary artery of the lower limb (Figs. 5.26–29; Table 5.5). It enters the **femoral triangle** deep to the midpoint of the inguinal liga-

ment (midway between the ASIS and the pubic tubercle), lateral to the femoral vein (Fig. 5.30A). The pulsations of the femoral artery are palpable within the triangle because of its relatively superficial position deep (posterior) to the fascia lata. It lies and descends on the adjacent borders of the iliopsoas and pectineus muscles that form the floor of the triangle. The superficial epigastric artery, superficial (and sometimes the deep) circumflex iliac arteries, and the superficial and deep external pudendal arteries arise from the anterior aspect of the proximal part of the femoral artery.

The **deep artery of the thigh** (*L. arteria profunda femoris*) is the largest branch of the femoral artery and the chief artery to the thigh (Fig. 5.29). It arises from the lateral or posterior side of the femoral artery in the femoral triangle. In the middle third of the thigh, where it is separated from the femoral artery and vein by the adductor longus (Figs. 5.27B and 5.30B), it gives off perforating arteries that wrap around the posterior aspect of the femur (Fig. 5.29; Table 5.5). The perforating arteries supply muscles of all three fascial compartments (adductor magnus, hamstrings, and vastus lateralis).

The **circumflex femoral arteries** encircle the uppermost shaft of the femur and anastomose with each other and other arteries, supplying the thigh muscles and the superior (proximal) end of the femur. The **medial circumflex femoral artery** is especially important because it supplies

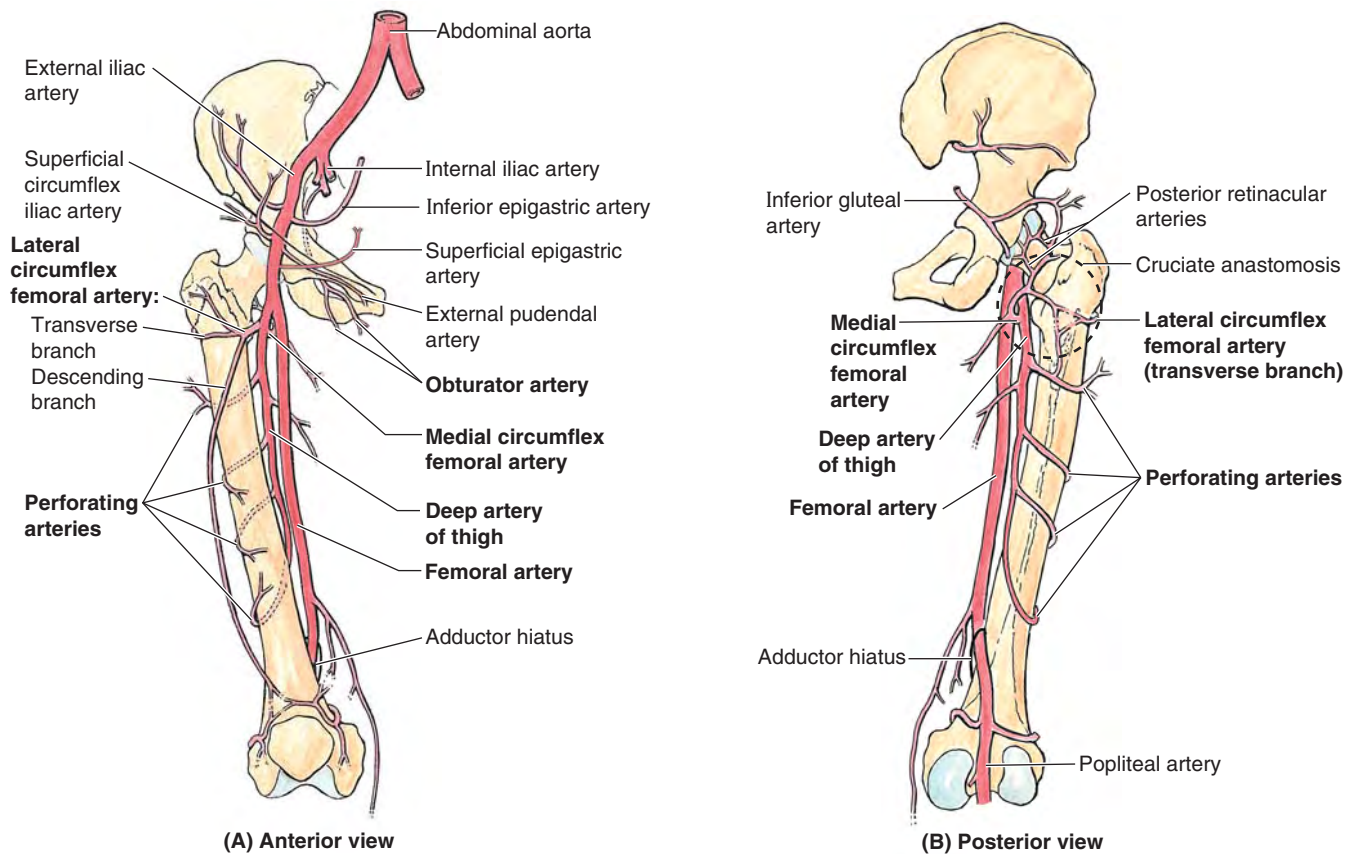


FIGURE 5.29. Arteries of anterior and medial thigh.

TABLE 5.5. ARTERIES OF ANTERIOR AND MEDIAL THIGH

| Artery | Origin | Course | Distribution |
|----------------------------|---|---|--|
| Femoral | Continuation of external iliac artery distal to inguinal ligament | Descends through femoral triangle bisecting it; then courses through adductor canal; terminates as it traverses adductor hiatus, where its name becomes popliteal artery | Branches supply anterior and anteromedial aspects of thigh |
| Deep artery of thigh | Femoral artery 1–5 cm inferior to inguinal ligament | Passes deeply between pectineus and adductor longus; descending posterior to latter on medial side of femur | Three to four perforating arteries pass through adductor magnus muscle, winding around femur to supply muscles in medial, posterior, and lateral part of anterior compartments |
| Medial circumflex femoral | Deep artery of thigh; may arise from femoral artery | Passes medially and posteriorly between pectineus and iliopsoas; enters gluteal region and gives rise to posterior retinacular arteries; then terminates by dividing into transverse and ascending branches | Supplies most of blood to head and neck of femur; transverse branch takes part in cruciate anastomosis of thigh; ascending branch joins inferior gluteal artery |
| Lateral circumflex femoral | | Passes laterally deep to sartorius and rectus femoris, dividing into ascending, transverse, and descending arteries | Ascending branch supplies anterior part of gluteal region; transverse branch winds around femur; descending branch joins genicular periarticular anastomosis |
| Obturator | Internal iliac artery or (in ~20%) as an accessory or replaced obturator artery from the inferior epigastric artery | Passes through obturator foramen; enters medial compartment of thigh and divides into anterior and posterior branches, which pass on respective sides of adductor brevis | Anterior branch supplies obturator externus, pectineus, adductors of thigh, and gracilis; posterior branch supplies muscles attached to ischial tuberosity |

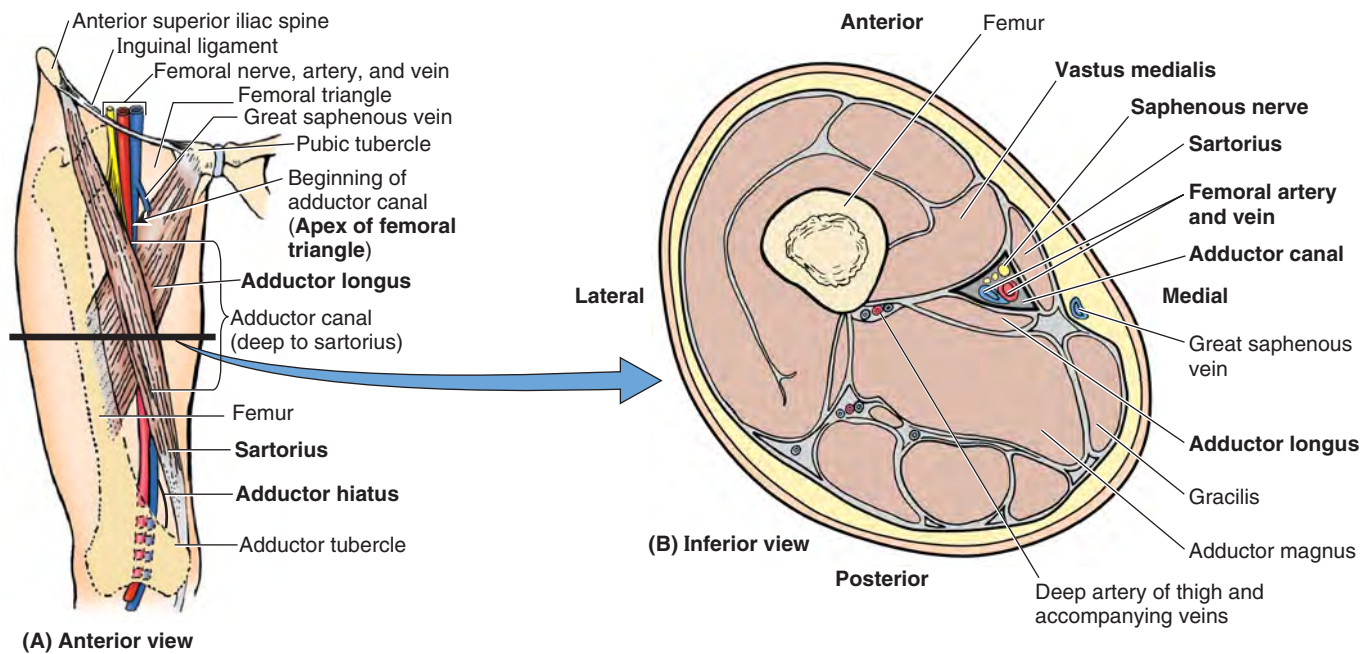


FIGURE 5.30. Adductor canal in medial part of middle third of thigh. **A.** Orientation drawing showing the adductor canal and the level of the section shown in **B.** **B.** This transverse section of the thigh shows the muscles bounding the adductor canal and its neurovascular contents.

most of the blood to the head and neck of the femur via its branches, the **posterior retinacular arteries**. The retinacular arteries are often torn when the femoral neck is fractured or the hip joint is dislocated. The **lateral circumflex femoral artery**, less able to supply the femoral head and neck as it passes laterally across the thickest part of the joint capsule of the hip joint, mainly supplies muscles on the lateral side of the thigh.

Obturator Artery. The **obturator artery** helps the deep artery of the thigh supply the adductor muscles via anterior and posterior branches, which anastomose. The posterior branch gives off an acetabular branch that supplies the head of the femur.

FEMORAL VEIN

The **femoral vein** is the continuation of the popliteal vein proximal to the adductor hiatus. As it ascends through the adductor canal, the femoral vein lies posterolateral and then posterior to the femoral artery (Figs. 5.26B and 5.27A & B). The femoral vein enters the femoral sheath lateral to the femoral canal and ends posterior to the inguinal ligament, where it becomes the external iliac vein.

In the inferior part of the femoral triangle, the femoral vein receives the deep vein of the thigh, the great saphenous vein, and other tributaries. The *deep vein of the thigh*, formed by the union of three or four perforating veins, enters the femoral vein approximately 8 cm inferior to the inguinal ligament and approximately 5 cm inferior to the termination of the great saphenous vein.

ADDUCTOR CANAL

The **adductor canal** (subsartorial canal; Hunter canal) is a long (approximately 15 cm), narrow passageway in the middle third of the thigh. It extends from the apex of the femoral triangle, where the sartorius crosses over the adductor longus, to the *adductor hiatus* in the tendon of the adductor magnus (Fig. 5.30A).

The adductor canal provides an *intermuscular passage* for the femoral artery and vein, the saphenous nerve, and the slightly larger nerve to vastus medialis, delivering the femoral vessels to the popliteal fossa where they become popliteal vessels.

The *adductor canal is bounded* (Fig. 5.30B):

- Anteriorly and laterally by the vastus medialis.
- Posteriorly by the adductors longus and magnus.
- Medially by the sartorius, which overlies the groove between the above muscles, forming the roof of the canal.

In the inferior third to half of the canal, a tough subsartorial or vastoadductor fascia spans between the adductor longus and the vastus medialis muscles, forming the anterior wall of the canal deep to the sartorius. Because this fascia has a distinct superior margin, novices dissecting in this area commonly assume when they see the femoral vessels pass deep to this fascia that they are traversing the adductor hiatus. The *adductor hiatus*, however, is located at a more inferior level, just proximal to the medial supracondylar ridge. This hiatus is a gap between the aponeurotic adductor and the tendinous hamstrings attachments of the adductor magnus (Fig. 5.23E).

Surface Anatomy of Anterior and Medial Regions of Thigh

In fairly muscular individuals, some of the bulky anterior thigh muscles can be observed. The prominent muscles are the *quadriceps* and *sartorius*, whereas laterally the tensor of the fascia lata is palpable as is the *iliotibial tract* to which this muscle attaches (Fig. 5.31A).

Three of the four parts of the *quadriceps* are visible or can be approximated (Fig. 5.31A & B). The fourth part (*vastus intermedius*) is deep and almost hidden by the other muscles and cannot be palpated.

The *rectus femoris* may be easily observed as a ridge passing down the thigh when the lower limb is raised from the floor while sitting. Observe the large bulges formed by the *vastus lateralis* and *medialis* at the knee (Fig. 5.31B). The *patellar ligament* is easily observed, especially in thin people, as a thick band running from the patella to the tibial tuberosity. You can also palpate the *infrapatellar fat pads*, the masses of loose fatty tissue on each side of the patellar ligament.

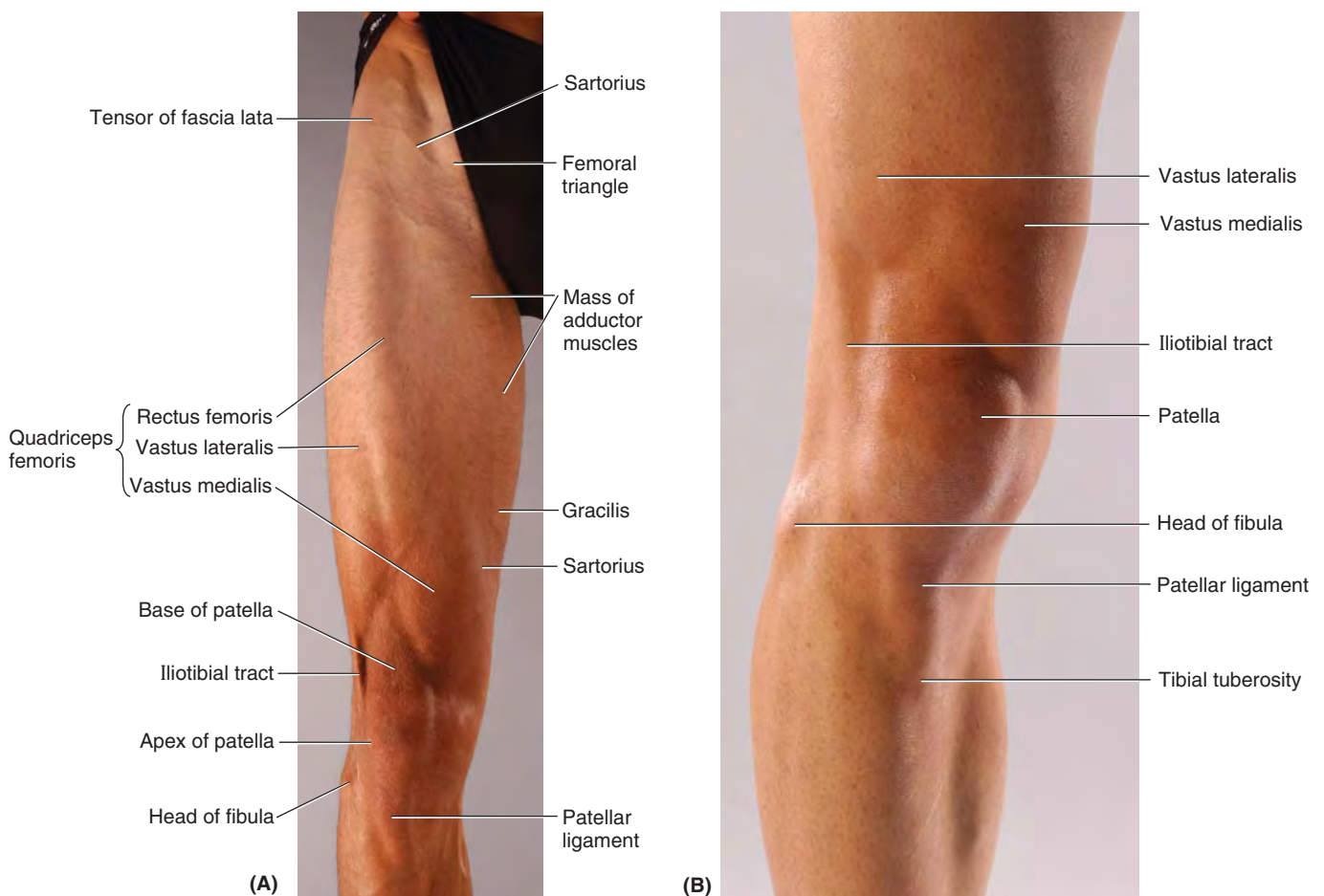
On the medial aspect of the inferior part of the thigh, the *gracilis* and *sartorius* muscles form a well-marked prominence,

which is separated by a depression from the large bulge formed by the *vastus medialis* (Fig. 5.31A). Deep in this depressed area, the *large tendon of the adductor magnus* can be palpated as it passes to its attachment to the adductor tubercle of the femur.

Measurements of the lower limb are taken to detect shortening (e.g., resulting from a femoral fracture). To make such measurements, compare the affected limb with the corresponding limb. Real limb shortening is detected by comparing the measurements from the ASIS to the distal tip of the medial malleolus on both sides.

To determine if the shortening is in the thigh, the measurement is taken from the top of the ASIS to the distal edge of the lateral femoral condyle on both sides. Keep in mind that small differences between the two sides—such as a difference of 1.25 cm in total length of the limb—may be normal.

The proximal two thirds of a line drawn from the midpoint of the inguinal ligament to the *adductor tubercle* when the thigh is flexed, abducted, and rotated laterally represents the course of the *femoral artery* (Fig. 5.30A). The proximal third of the line represents this artery as it passes through the *femoral triangle*, whereas the middle third represents the artery while



Anterior views

FIGURE 5.31. Surface anatomy of anterior and medial thigh.

it is in the *adductor canal*. Approximately 3.75 cm along this line distal to the inguinal ligament, the deep artery of the thigh arises from the femoral artery.

The *femoral vein* is:

- Medial to the femoral artery at the base of the femoral triangle (indicated by inguinal ligament).
- Posterior to the femoral artery at the apex of the femoral triangle.
- Posterolateral to the artery in the adductor canal.

The *femoral triangle*, in the superoanterior aspect of the thigh, is not a prominent surface feature in most people. When some people sit cross-legged, the sartorius and adductor longus stand out, delineating the femoral triangle. The sur-

face anatomy of the femoral triangle is clinically important because of its contents.

The *femoral artery* can be felt pulsating just inferior at the midinguinal point. When you palpate the femoral pulse, the *femoral vein* is just medial, the femoral nerve is a finger's breadth lateral, and the *femoral head* is just posterior. The femoral artery runs a 5-cm superficial course through the femoral triangle before it is covered by the sartorius in the adductor canal.

The *great saphenous vein* enters the thigh posterior to the medial femoral condyle and passes superiorly along a line from the adductor tubercle to the *saphenous opening*. The central point of this opening, where the great saphenous vein enters the femoral vein, is located 3.75 cm inferior and 3.75 cm lateral to the pubic tubercle.

ANTERIOR AND MEDIAL REGIONS OF THIGH

Hip and Thigh Contusions



Sports broadcasters and trainers refer to a “hip pointer,” which is a *contusion of the iliac crest* that usually occurs at its anterior part (e.g., where the sartorius attaches to the ASIS). This is one of the most common injuries to the hip region, usually occurring in association with collision sports, such as the various forms of football, ice hockey, and volleyball.

Contusions cause bleeding from ruptured capillaries and infiltration of blood into the muscles, tendons, and other soft tissues. The term *hip pointer* may also refer to avulsion of bony muscle attachments, for example, of the sartorius or rectus femoris to the anterior superior and inferior iliac spines, respectively, of the hamstrings from the ischium. However, these injuries should be called *avulsion fractures*.

Another term commonly used is “charley horse,” which may refer either to the cramping of an individual thigh muscle because of ischemia or to contusion and rupture of blood vessels sufficient enough to form a *hematoma*. The injury is usually the consequence of tearing of fibers of the rectus femoris; sometimes the quadriceps tendon is also partially torn. The most common site of a thigh hematoma is in the quadriceps. A charley horse is associated with localized pain and/or muscle stiffness and commonly follows direct trauma (e.g., a stick slash in hockey or a tackle in football).

Psoas Abscess



The psoas major arises in the abdomen from the intervertebral discs, the sides of the T12–L5 vertebrae, and their transverse processes (see Fig. B2.35, p. 321). The medial arcuate ligament of the diaphragm arches obliquely over the proximal part of the psoas major. The trans-

versalis fascia on the internal abdominal wall is continuous with the psoas fascia, where it forms a fascial covering for the psoas major that accompanies the muscle into the anterior region of the thigh.

There is a resurgence of tuberculosis (TB) in Africa, Asia, and elsewhere. A retroperitoneal *pyogenic infection* (pus-forming) in the abdomen or greater pelvis, characteristically occurring in association with TB of the vertebral column, or secondary to regional enteritis of the ileum (*Crohn disease*), may result in the formation of a **psoas abscess**. When the abscess passes between the psoas and its fascia to the inguinal and proximal thigh regions, severe pain may be referred to the hip, thigh, or knee joint. A psoas abscess should always be considered when edema occurs in the proximal part of the thigh. Such an abscess may be palpated or observed in the inguinal region, just inferior or superior to the inguinal ligament, and may be mistaken for an indirect inguinal hernia or a femoral hernia, an enlargement of the inguinal lymph nodes, or a saphenous varix. The lateral border of the psoas is commonly visible in radiographs of the abdomen; an obscured psoas shadow may be an indication of abdominal pathology.

Paralysis of Quadriceps



A person with **paralyzed quadriceps muscles** cannot extend the leg against resistance and usually presses on the distal end of the thigh during walking to prevent inadvertent flexion of the knee joint.

Weakness of the vastus medialis or vastus lateralis, resulting from arthritis or trauma to the knee joint, can result in abnormal patellar movement and loss of joint stability.

Chondromalacia Patellae



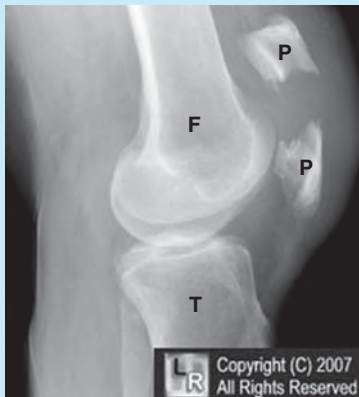Chondromalacia patellae (runner's knee) is a common knee problem for marathon runners. Such overstraining of the knee region can also occur in

running sports such as basketball. The soreness and aching around or deep to the patella results from *quadriceps imbalance*. Chondromalacia patellae may also result from a blow to the patella or extreme flexion of the knee (e.g., during squatting when power lifting).

Patellar Fractures



A direct blow to the patella may fracture it into two or more fragments (Fig B5.12). **Transverse patellar fractures** may result from a blow to the knee or sudden contraction of the quadriceps (e.g., when one slips and attempts to prevent a backward fall). The proximal fragment is pulled superiorly with the quadriceps tendon, and the distal fragment remains with the patellar ligament.



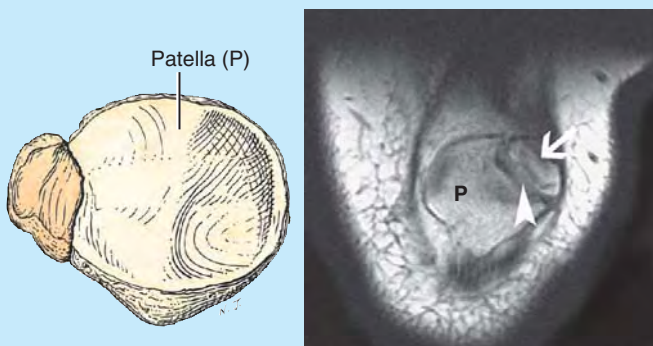
Femur (F), Patella (P), Tibia (T)

FIGURE B5.12.

Abnormal Ossification of Patella



The patella is cartilaginous at birth. It ossifies during the 3rd–6th years, frequently from more than one ossification center. Although these centers usually coalesce and form a single bone, they may remain separate on one or both sides, giving rise to a **bipartite** or **tripartite patella** (Fig. B5.13). An unwary observer might interpret this



(A) Bipartite patella

(B) Coronal MRI image of bipartite patella (arrow = bipartite segment; arrowhead = false “fracture” line)

FIGURE B5.13.

condition on a radiograph or CT as a patellar fracture. Ossification abnormalities are nearly always bilateral; therefore, diagnostic images should be examined from both sides. If the defects are bilateral, the defects are likely ossification abnormalities.

Patellar Tendon Reflex



Tapping the patellar ligament with a reflex hammer (Fig. B5.14) normally elicits the **patellar reflex** (“knee jerk”). This myotatic (deep tendon) reflex is routinely tested during a physical examination by having the person sit with the legs dangling. A firm strike on the ligament with a reflex hammer usually causes the leg to extend. If the reflex is normal, a hand on the person’s quadriceps should feel the muscle contract. This tendon reflex tests the integrity of the femoral nerve and the L2–L4 spinal cord segments.

Tapping the ligament activates muscle spindles in the quadriceps. Afferent impulses from the spindles travel in the femoral nerve to the L2–L4 segments of the spinal cord. From here, efferent impulses are transmitted via motor fibers in the femoral nerve to the quadriceps, resulting in a jerk-like contraction of the muscle and extension of the leg at the knee joint.

Diminution or absence of the patellar tendon reflex may result from any lesion that interrupts the innervation of the quadriceps (e.g., peripheral nerve disease).

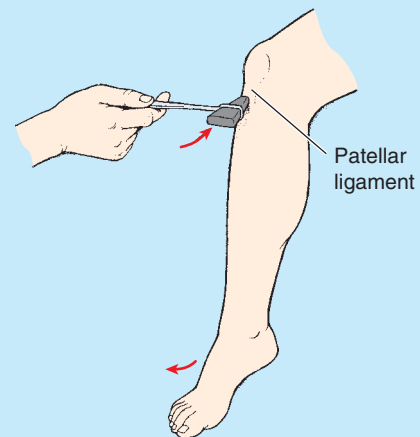


FIGURE B5.14.

Transplantation of Gracilis



Because the gracilis is a relatively weak member of the adductor group of muscles, it can be removed without noticeable loss of its actions on the leg. Surgeons often transplant the gracilis, or part of it, with its nerve and blood vessels to replace a damaged muscle in the hand, for example. Once the muscle is transplanted, it soon produces good digital flexion and extension.

Freed from its distal attachment, the muscle has also been relocated and repositioned to create a replacement for a non-functional external anal sphincter.

Groin Pull



Sports broadcasters refer to a “pulled groin” or “groin injury.” These terms mean that a strain, stretching, and probably some tearing of the proximal attachments of the anteromedial thigh muscles have occurred. The injury usually involves the flexor and adductor thigh muscles. The proximal attachments of these muscles are in the inguinal region (groin), the junction of the thigh and trunk.

Groin pulls usually occur in sports that require quick starts (e.g., sprinting and base stealing in baseball) or extreme stretching (e.g., gymnastics).

Injury to Adductor Longus



Muscle strains of the *adductor longus* may occur in horseback riders and produce pain (rider’s strain). Ossification sometimes occurs in the tendons of these muscles because the horseback riders actively adduct their thighs to keep from falling from their animals. The areas of the ossified tendons are sometimes called “riders’ bones.”

Palpation, Compression, and Cannulation of Femoral Artery



The initial part of the femoral artery, proximal to the branching of the deep artery of the thigh, is superficial in position, making it especially accessible and useful for a number of clinical procedures. Some vascular surgeons refer to this part of the femoral artery as the *common femoral artery* and to its continuation distally as the *superficial femoral artery*. This terminology is not recommended by the Federative International Committee on Anatomical Terminology because it is a deep artery. The term is not used in this book because it may cause misunderstanding.

With the person lying in the supine position, the *femoral pulse* may be palpated midway between the ASIS and the pubic symphysis (Fig. B5.15A & B). By placing the tip of the little finger (of the right hand when dealing with the right side) on the ASIS and the tip of the thumb on the pubic tubercle, the femoral pulse can be palpated with the midpalm just inferior to the midpoint of the inguinal ligament by pressing firmly. Normally the pulse is strong; however, if the common or external iliac arteries are partially occluded, the pulse may be diminished.

Compression of the femoral artery may also be accomplished at this site by pressing directly posteriorly against the superior pubic ramus, *psoas major*, and femoral head (Fig. B5.15C). Compression at this point will reduce blood flow through the femoral artery and its branches, such as the deep artery of the thigh.

The femoral artery may be cannulated just inferior to the midpoint of the inguinal ligament. In *left cardiac (cardiac) angiography*, a long, slender catheter is inserted into the artery and passed up the external iliac artery, common iliac artery, and aorta to the left ventricle of the heart. This same

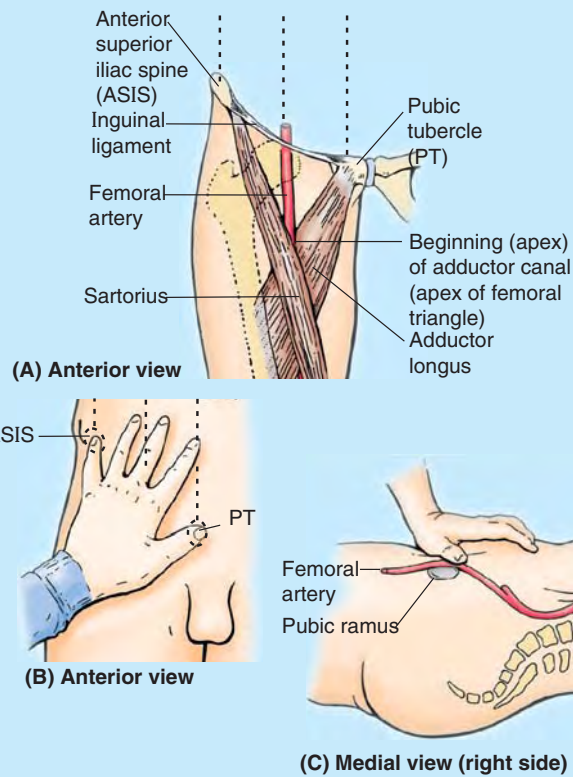


FIGURE B5.15.

approach is used to visualize the coronary arteries in *coronary arteriography*.

Blood may also be taken from the femoral artery for *blood gas analysis* (the determination of oxygen and carbon dioxide concentrations and pressures with the pH of the blood by laboratory tests).

Laceration of Femoral Artery



The superficial position of the femoral artery in the femoral triangle makes it vulnerable to traumatic injury, especially laceration. Commonly, both the femoral artery and vein are lacerated in anterior thigh wounds because they lie close together. In some cases, an *arteriovenous shunt* occurs as a result of communication between the injured vessels.

When it is necessary to ligate the femoral artery, anastomosis of branches of the femoral artery with other arteries that cross the hip joint may supply blood to the lower limb. The *cruciate anastomosis* is a four-way common meeting of the medial and lateral circumflex femoral arteries with the inferior gluteal artery superiorly and the first perforating artery inferiorly posterior to the femur (Fig. 5.29; Table 5.5), occurring less often than its frequent mention implies.

Potentially Lethal Misnomer



Clinical staff, some vascular laboratories, and even some text and reference books use the term “superficial femoral vein” when referring to the femoral

vein before it is joined by the accompanying veins of the deep artery of the thigh (deep femoral veins). Some primary care physicians may not have been taught and/or may not realize that the so-called superficial femoral vein is actually a deep vein and that acute thrombosis of this vessel is potentially life threatening. The adjective *superficial* should not be used because it implies that this vein is a superficial vein. Most *pulmonary emboli* originate in deep veins, not in superficial veins. The risk of embolism can be greatly reduced by anticoagulant treatment. The use of imprecise language here creates the possibility that an acute thrombosis of this truly deep vessel could be overlooked as an acute clinical issue, and a life-threatening situation created.

Saphenous Varix



A localized dilation of the terminal part of the great saphenous vein, called a **saphenous varix** (L. dilated vein), may cause edema in the femoral triangle. A saphenous varix may be confused with other groin swellings such as a psoas abscess; however, a varix should be considered when varicose veins are present in other parts of the lower limb.

Location of Femoral Vein



The femoral vein is not usually palpable but its position can be located inferior to the inguinal ligament by feeling the pulsations of the femoral artery, which is immediately lateral to the vein. In thin people, the femoral vein may be close to the surface and may be mistaken for the great saphenous vein. *It is important therefore to know that the femoral vein has no tributaries at this level*, except for the great saphenous vein that joins it approximately 3 cm inferior to the inguinal ligament. In *varicose vein operations*, it is obvi-

ously important to identify the great saphenous vein correctly and not tie off the femoral vein by mistake.

Cannulation of Femoral Vein



To secure blood samples and take pressure recordings from the chambers of the right side of the heart and/or from the pulmonary artery and to perform *right cardiac angiography*, a long, slender catheter is inserted into the femoral vein as it passes through the femoral triangle. Under fluoroscopic control, the catheter is passed superiorly through the external and common iliac veins into the inferior vena cava and right atrium of the heart. *Femoral venous puncture* may also be used for the administration of fluids.

Femoral Hernias



The femoral ring is a weak area in the anterior abdominal wall that normally is of a size sufficient to admit the tip of the little finger. The femoral ring is the usual originating site of a **femoral hernia**, a protrusion of abdominal viscera (often a loop of small intestine) through the femoral ring into the femoral canal. A femoral hernia appears as a mass, often tender, in the femoral triangle, *inferolateral to the pubic tubercle* (Fig. B5.16).

The hernia is bounded by the femoral vein laterally and the lacunar ligament medially. The hernial sac compresses the contents of the femoral canal (loose connective tissue, fat, and lymphatics) and distends the wall of the canal. Initially, the hernia is small because it is contained within the canal, but it can enlarge by passing inferiorly through the saphenous opening into the subcutaneous tissue of the thigh.

Femoral hernias are more common in females because of their wider pelvises. *Strangulation of a femoral hernia* may

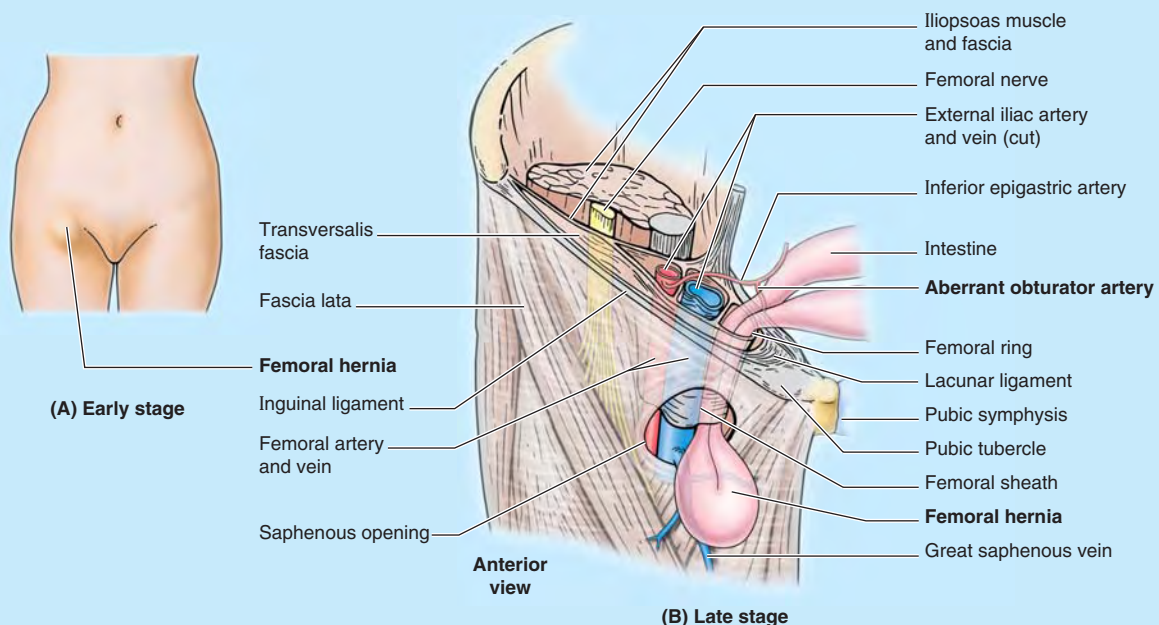


FIGURE B5.16.

occur because of the sharp, rigid boundaries of the femoral ring, particularly the concave margin of the lacunar ligament. Strangulation of a femoral hernia interferes with the blood supply to the herniated intestine. This vascular impairment may result in *necrosis* (death of the tissues).

Replaced or Accessory Obturator Artery



An enlarged pubic branch of the inferior epigastric artery either takes the place of the obturator artery (**replaced obturator artery**) or joins it as an **accessory obturator artery** in approximately 20% of people (Fig. B5.17). This artery runs close to or across the femoral ring to reach the obturator foramen and could be closely related to the neck of a femoral hernia. Consequently, this artery could be involved in a *strangulated femoral hernia*. Surgeons placing staples during endoscopic repair of both inguinal and femoral hernias must also be vigilant concerning the possible presence of this common arterial variant.

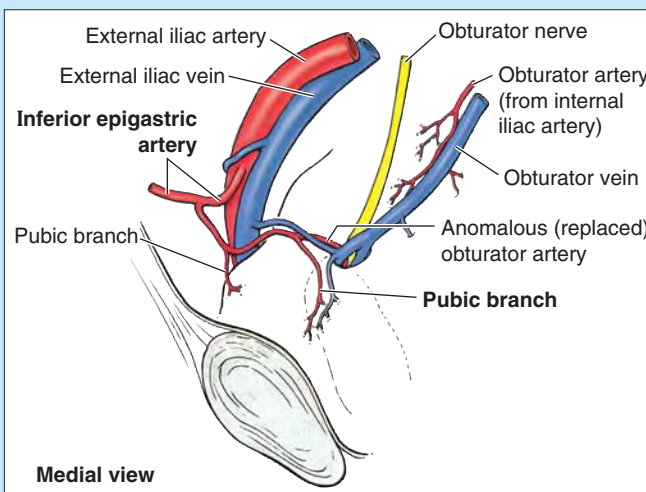


FIGURE B5.17.

The Bottom Line

ANTERIOR AND MEDIAL COMPARTMENTS OF THIGH

Anterior compartment: This large anterior compartment includes the flexors of the hip and extensors of the knee, with most muscles innervated by the femoral nerve. ♦ The quadriceps femoris accounts for most of the mass of this compartment. It surrounds the femur on three sides and has a common tendon of attachment to the tibia, which includes the patella as a sesamoid bone. ♦ Major muscles of this compartment atrophy rapidly with disease or disuse, requiring physical therapy to retain or restore function.

Medial compartment: The muscles of this compartment attach proximally to the anteroinferior bony pelvis and distally to the linea aspera of the femur. ♦ These muscles are adductors of the thigh, innervated primarily by the obturator nerve. Use of these muscles as prime movers is relatively limited. ♦ The primary neurovascular bundle of the thigh, like that of the arm, is placed on the medial side of the limb for protection.

Neurovascular structures and relationships in antero-medial thigh:

In the upper third of the thigh, the neurovascular bundle is most superficial as it enters deep to the inguinal ligament. This relatively superficial position is important for clinical procedures. ♦ Although they are essentially adjacent, the femoral nerve traverses the muscular lacunae of the subinguinal space, whereas the femoral vessels traverse the vascular lacunae within the femoral sheath. ♦ The femoral vessels bisect the femoral triangle, where the primary vessels of the thigh, the deep artery and vein of the thigh, arise and terminate, respectively. ♦ The femoral nerve per se terminates within the femoral triangle. However, two of its branches, a motor branch (nerve to vastus medialis) and sensory branch (saphenous nerve), are part of the neurovascular bundle that traverses the adductor canal in the middle third of the thigh. ♦ The vascular structures then pass through the adductor hiatus, becoming popliteal in name and location in the distal thigh/posterior knee region.

GLUTEAL AND POSTERIOR THIGH REGIONS

Gluteal Region: Buttocks and Hip Region

Although the demarcation of the trunk and lower limb is abrupt anteriorly at the inguinal ligament, posteriorly the gluteal region is a large transitional zone between the trunk

and limb. Physically part of the trunk, functionally the gluteal region is definitely part of the lower limb.

The **gluteal region** is the prominent area posterior to the pelvis and inferior to the level of the iliac crests (the buttocks) and extending laterally to the posterior margin of the greater trochanter (Fig. 5.32). The hip region overlies the greater trochanter laterally, extending anteriorly to the ASIS. Some definitions include both buttock and hip region as part of the gluteal region, but the two parts are commonly distinguished. The *intergluteal cleft* (natal cleft) is the groove that separates

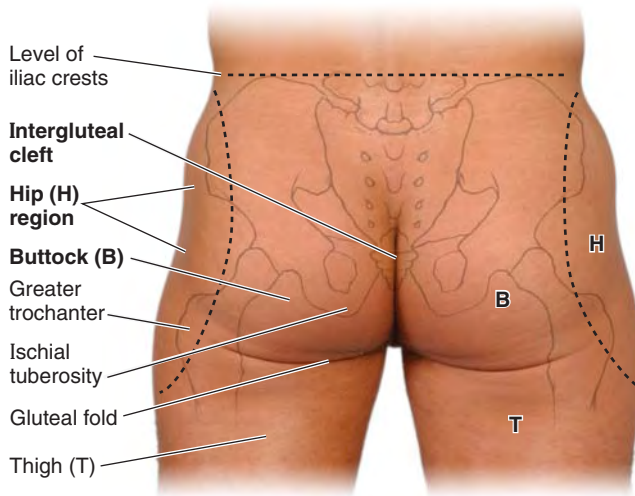


FIGURE 5.32. Gluteal region, comprising buttocks and hip region.

the buttocks from each other. The **gluteal muscles** (gluteus maximus, medius, and minimus and tensor fasciae latae) form the bulk of the region. The *gluteal fold* demarcates the inferior boundary of the buttock and the superior boundary of the thigh.

GLUTEAL LIGAMENTS

The parts of the bony pelvis—hip bones, sacrum, and coccyx—are bound together by dense ligaments (Fig. 5.33). The **posterior sacroiliac ligament** is continuous inferiorly with the sacrotuberous ligament. The **sacrospinous ligament**

extends across the sciatic notch of the hip bone, converting the notch into a foramen that is further subdivided by the **sacrospinous ligament** and *ischial spine*, creating the greater and lesser sciatic foramina. The **greater sciatic foramen** is the passageway for structures entering or leaving the pelvis (e.g., sciatic nerve), whereas the **lesser sciatic foramen** is the passageway for structures entering or leaving the perineum (e.g., pudendal nerve).

It is helpful to think of the greater sciatic foramen as the “door” through which all lower limb arteries and nerves leave the pelvis and enter the gluteal region. The *piriformis muscle* (Fig. 5.34D–G; Table 5.6) also enters the gluteal region through the greater sciatic foramen and fills most of it.

Muscles of Gluteal Region

The **muscles of the gluteal region** (Fig. 5.35) share a common compartment but are organized into two layers, superficial and deep:

- The **superficial layer** consists of the three large overlapping glutei (maximus, medius, and minimus) and the tensor fasciae latae (Figs. 5.34A, C–E, & J and 5.35). These muscles all have proximal attachments to the posterolateral (external) surface and margins of the ala of the ilium and are mainly extensors, abductors, and medial rotators of the thigh.
- The **deep layer** consists of smaller muscles (piriformis, obturator internus, superior and inferior gemelli, and quadratus femoris) covered by the inferior half of the gluteus maximus (Figs. 5.34F–I and 5.35). They all have distal attachments on or adjacent to the intertrochanteric

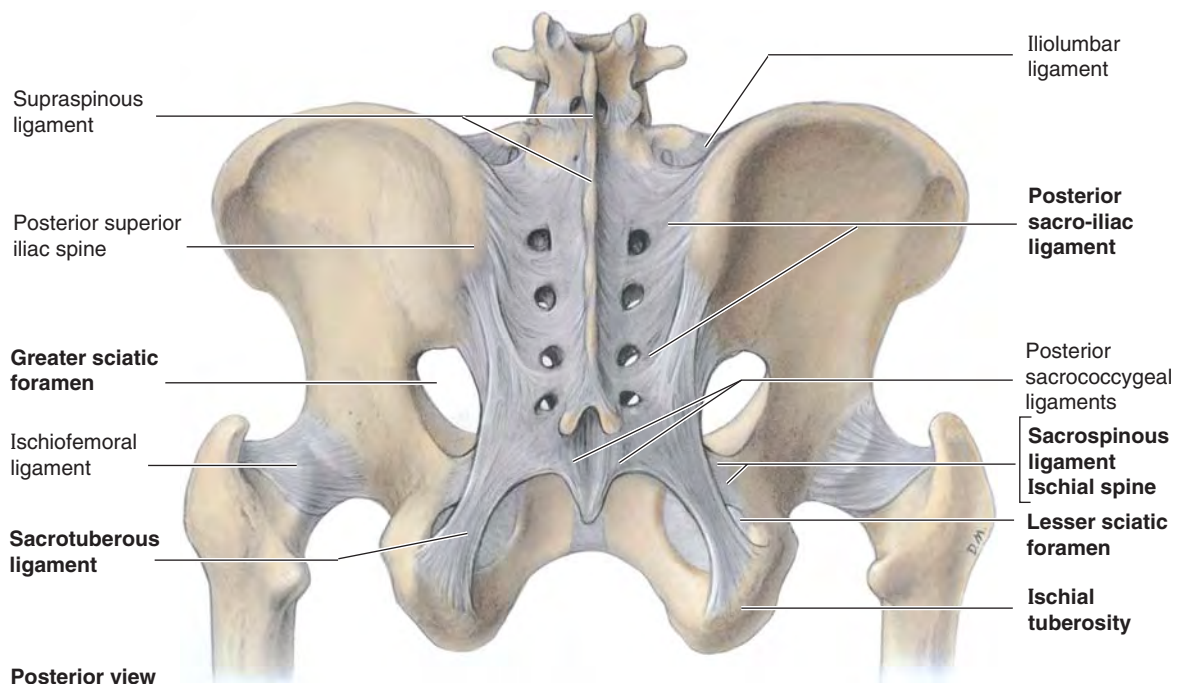


FIGURE 5.33. Ligaments of pelvic girdle. The sacrotuberous and sacrospinous ligaments convert the greater and lesser sciatic notches into foramina.

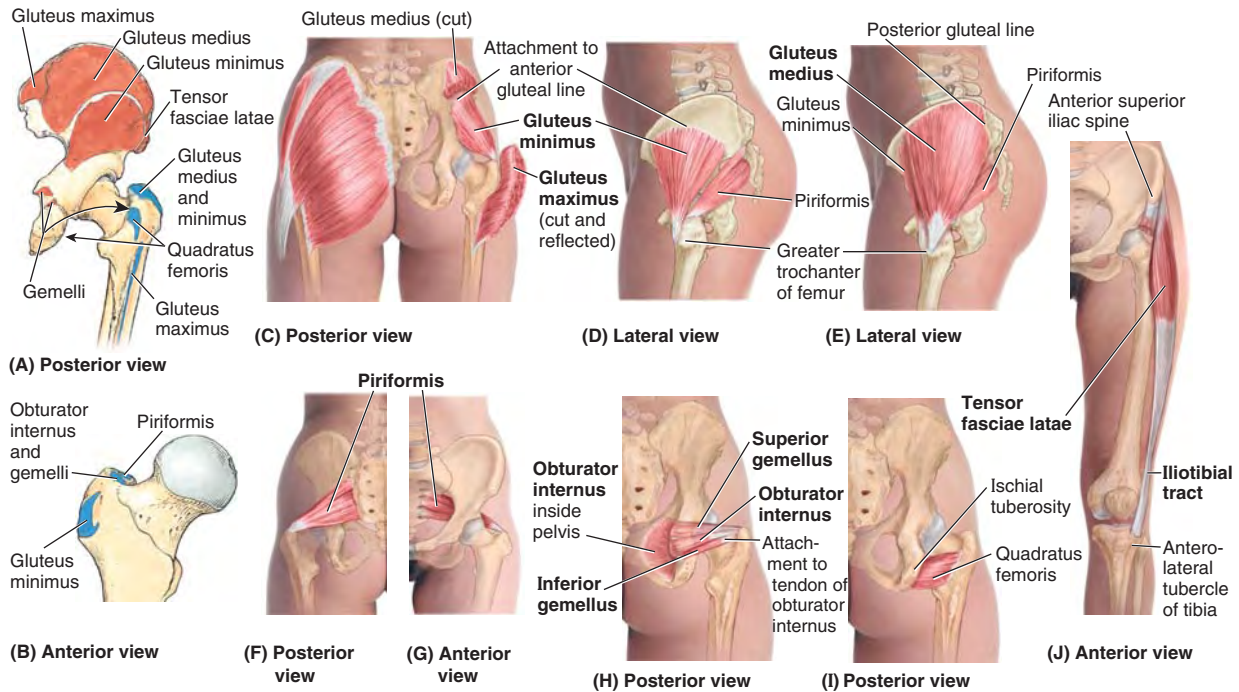


FIGURE 5.34. Muscles of gluteal region: abductors and lateral rotators.

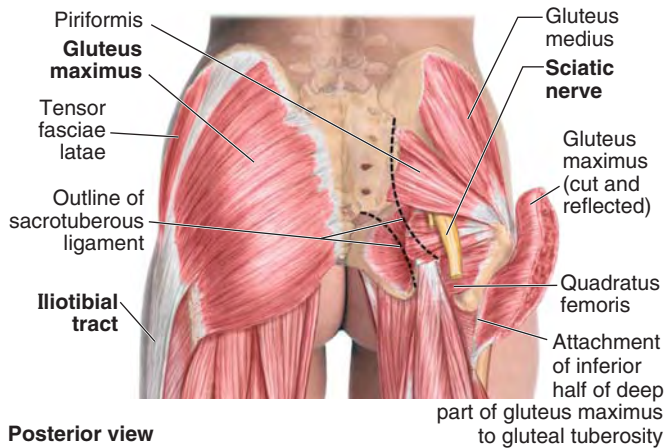
TABLE 5.6. MUSCLES OF GLUTEAL REGION: ABDUCTORS AND ROTATORS OF THIGH

| Muscle | Proximal Attachment | Distal Attachment | Innervation ^a | Main Action |
|--|--|--|---|---|
| Gluteus maximus (Fig. 5.34A & C) | Ilium posterior to posterior gluteal line; dorsal surface of sacrum and coccyx; sacrotuberous ligament | Most fibers end in iliotibial tract, which inserts into lateral condyle of tibia; some fibers insert on gluteal tuberosity | Inferior gluteal nerve (L5, S1 , S2) | Extends thigh (especially from flexed position) and assists in its lateral rotation; steadies thigh and assists in rising from sitting position |
| Gluteus medius (Fig. 5.34A, C, & E) | External surface of ilium between anterior and posterior gluteal lines | Lateral surface of greater trochanter of femur | Superior gluteal nerve (L5, S1) | Abduct and medially rotate thigh; keep pelvis level when ipsilateral limb is weight-bearing and advance opposite (un-supported) side during its swing phase |
| Gluteus minimus (Fig. 5.34A–D) | External surface of ilium between anterior and inferior gluteal lines | Anterior surface of greater trochanter of femur | | |
| Tensor of fascia lata (Fig. 5.34J) | Anterior superior iliac spine; anterior part of iliac crest | Iliotibial tract, which attaches to lateral condyle of tibia | | |
| Piriformis (Fig. 5.34F & G) | Anterior surface of sacrum; sacrotuberous ligament | Superior border of greater trochanter of femur | Branches of anterior rami of S1 , S2 | Laterally rotate extended thigh and abduct flexed thigh; steady femoral head in acetabulum |
| Obturator internus (Fig. 5.34H) | Pelvic surface of obturator membrane and surrounding bones | Medial surface of greater trochanter (trochanteric fossa) of femur ^b | Nerve to obturator internus (L5, S1) | |
| Superior and inferior gemelli (Fig. 5.34H) | Superior: ischial spine Inferior: ischial tuberosity | Medial surface of greater trochanter (trochanteric fossa) of femur ^b | Superior gemellus: same nerve supply as obturator internus Inferior gemellus: same nerve supply as quadratus femoris | |
| Quadratus femoris (Fig. 5.34I) | Lateral border of ischial tuberosity | Quadrate tubercle on intertrochanteric crest of femur and area inferior to it | Nerve to quadratus femoris (L5, S1) | |
| | | | | Laterally rotates thigh ^c ; steadies femoral head in acetabulum |

^a The spinal cord segmental innervation is indicated (e.g., “S1, S2” means that the nerves supplying the piriformis are derived from the first two sacral segments of the spinal cord). Numbers in boldface (**S1**) indicate the main segmental innervation. Damage to one or more of the listed spinal cord segments or to the motor nerve roots arising from them results in paralysis of the muscles concerned.

^b The gemelli muscles blend with the tendon of the obturator internus as it attaches to the greater trochanter of the femur.

^c There are six lateral rotators of the thigh: piriformis, obturator internus, superior and inferior gemelli, quadratus femoris, and obturator externus. These muscles also stabilize the hip joint.



Posterior view

FIGURE 5.35. Muscles of gluteal region: superficial and deep dissections.

crest of the femur. These muscles are lateral rotators of the thigh, but they also stabilize the hip joint, working with the strong ligaments of the hip joint to steady the femoral head in the acetabulum.

The attachments of these muscles are illustrated in Figure 5.34A–J, and their innervation and main actions are described in Table 5.6.

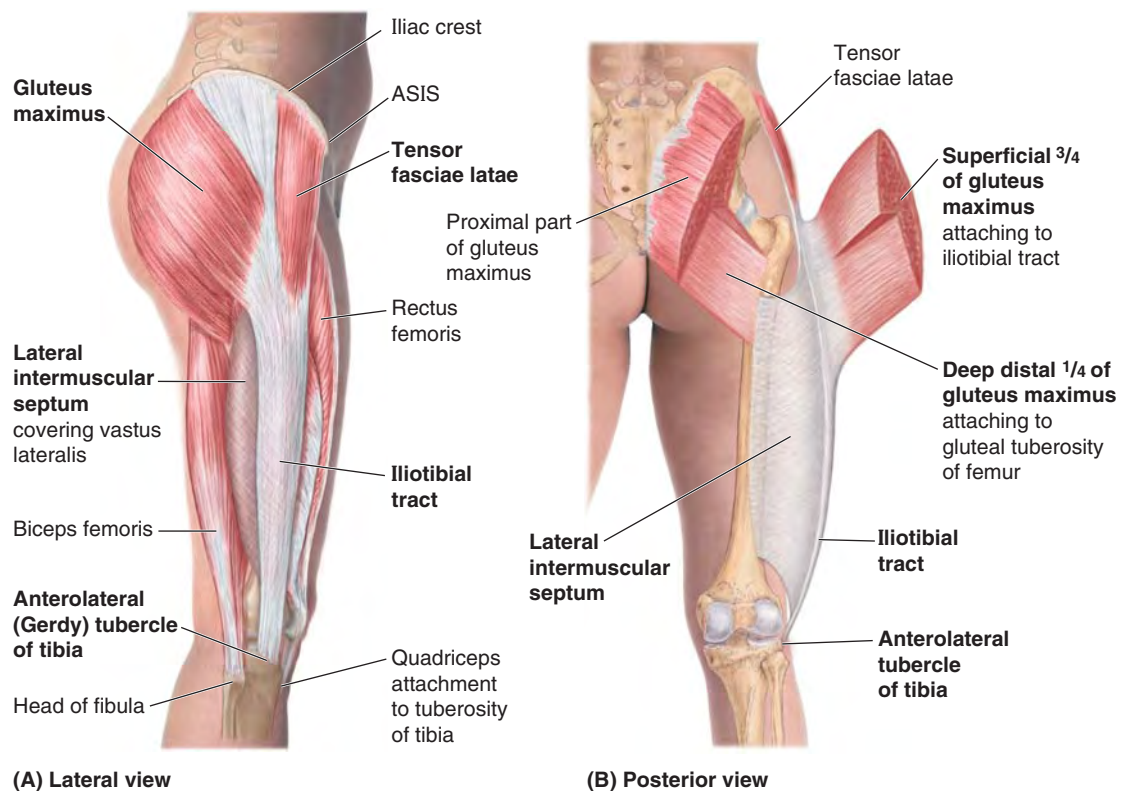
GLUTEUS MAXIMUS

The **gluteus maximus** is the most superficial gluteal muscle (Figs. 5.34C and 5.35). It is the largest, heaviest, and most coarsely fibered muscle of the body. The gluteus maximus covers all of the other gluteal muscles, except for the antero-superior third of the gluteus medius.

The *ischial tuberosity* can be felt on deep palpation through the inferior part of the muscle, just superior to the medial part of the gluteal fold (see Fig. 5.32). When the thigh is flexed, the inferior border of the gluteus maximus moves superiorly, leaving the ischial tuberosity subcutaneous. You do not sit on your gluteus maximus; you sit on the fatty fibrous tissue and the ischial bursa that lie between the ischial tuberosity and skin.

The gluteus maximus slopes inferolaterally at a 45° angle from the pelvis to the buttock. The fibers of the superior and larger part of the gluteus maximus and superficial fibers of its inferior part insert into the *iliotibial tract* and indirectly, via the lateral intermuscular septum, into the linea aspera of the femur (Fig. 5.36A & B). Some deep fibers of the inferior part of the muscle (roughly the deep anterior and inferior quarter) attach to the *gluteal tuberosity* of the femur.

The inferior gluteal nerve and vessels enter the deep surface of the gluteus maximus at its center. It is supplied by both the inferior and superior gluteal arteries. In the superior part of its course, the *sciatic nerve* passes deep to the gluteus maximus (Fig. 5.35).



(A) Lateral view

(B) Posterior view

FIGURE 5.36. Gluteus maximus and tensor of fascia lata. Shown are superficial (A) and deep (B) views of the lateral musculofibrous complex formed by the tensor fasciae latae and gluteus maximus muscles and their shared aponeurotic tendon, the iliotibial tract. The iliotibial tract is continuous posteriorly and deeply with the dense lateral intermuscular septum.

The main actions of the gluteus maximus are extension and lateral rotation of the thigh. When the distal attachment of the gluteus maximus is fixed, the muscle extends the trunk on the lower limb. Although it is the strongest extensor of the hip, it acts mostly when force is necessary (rapid movement or movement against resistance). The gluteus maximus functions primarily between the flexed and standing (straight) positions of the thigh, as when rising from the sitting position, straightening from the bending position, walking uphill and up stairs, and running. It is used only briefly during casual walking and usually not at all when standing motionless.

Paralysis of the gluteus maximus does not seriously affect walking on level ground. Verify this by placing your hand on your buttock when walking slowly. The gluteus maximus contracts only briefly during the earliest part of the stance phase (from heel strike to when the foot is flat on the ground, to resist further flexion as weight is assumed by the partially flexed limb) (Fig. 5.20A and Table 5.2). If you climb stairs and put your hand on your buttock, you will feel the gluteus maximus contract strongly.

Because the iliotibial tract crosses the knee and attaches to the anterolateral tubercle of the tibia (Gerdy) (Figs. 5.34J and 5.36A & B), the gluteus maximus and tensor fasciae latae together are also able to assist in making the extended knee stable, but they are not usually called on to do so during normal standing. Because the iliotibial tract attaches to the femur via the lateral intermuscular septum, it does not have the freedom necessary to produce motion at the knee.

Testing the gluteus maximus is performed when the person is prone with the lower limb straight. The person tightens the buttock and extends the hip joint as the examiner observes and palpates the gluteus maximus.

Gluteal Bursae. Gluteal bursae (L., purses) separate the gluteus maximus from adjacent structures (Fig. 5.37). Bursae are membranous sacs lined by a synovial membrane containing a capillary layer of slippery fluid resembling egg white. Bursae are located in areas subject to friction (e.g., where the iliotibial tract crosses the greater trochanter). The purpose of bursae is to reduce friction and permit free movement. Usually three bursae are associated with the gluteus maximus:

1. The **trochanteric bursa** separates superior fibers of the gluteus maximus from the greater trochanter. This bursa is commonly the largest of the bursae formed in relation to bony prominences and is present at birth. Other such bursae appear to form as a result of postnatal movement.
2. The **ischial bursa** separates the inferior part of the gluteus maximus from the ischial tuberosity; it is often absent.
3. The **gluteofemoral bursa** separates the iliotibial tract from the superior part of the proximal attachment of the vastus lateralis.

See the blue boxes “Trochanteric Bursitis” and “Ischial Bursitis” on p. 581.

GLUTEUS MEDIUS AND GLUTEUS MINIMUS

The smaller gluteal muscles, **gluteus medius** and **gluteus minimus**, are fan shaped, and their fibers converge in the same

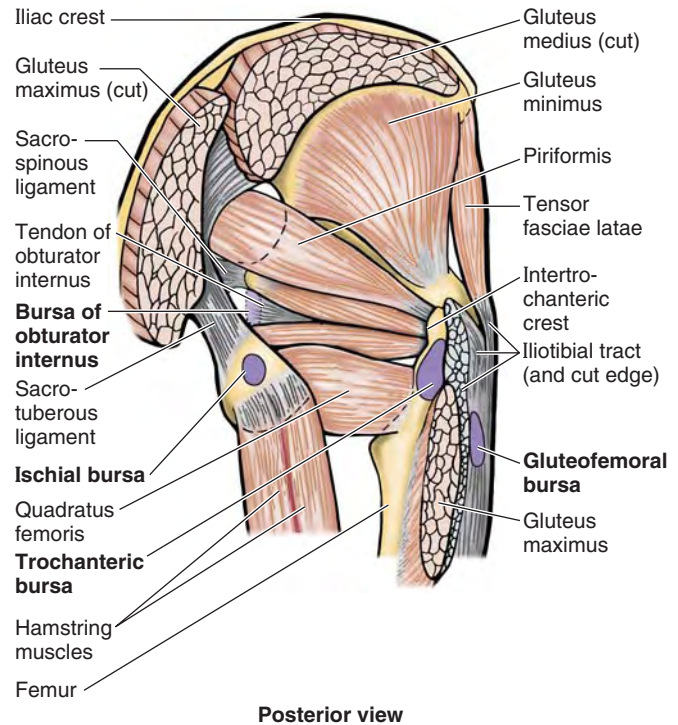


FIGURE 5.37. Gluteal muscles and bursae. Three bursae (trochanteric, gluteofemoral, and ischial) usually separate the gluteus maximus from underlying bony prominences. The bursa of the obturator internus underlies the tendon of the obturator internus.

manner toward essentially the same target (Figs. 5.34C–E, 5.35, 5.37, and 5.38). They share the same actions and nerve supply (Table 5.6) and are supplied by the same blood vessel, the superior gluteal artery. The gluteus minimus and most of the gluteus medius lie deep to the gluteus maximus on the external surface of the ilium. The gluteus medius and minimus abduct or stabilize the thigh and rotate it medially (Fig. 5.20F and 5.39; Table 5.2).

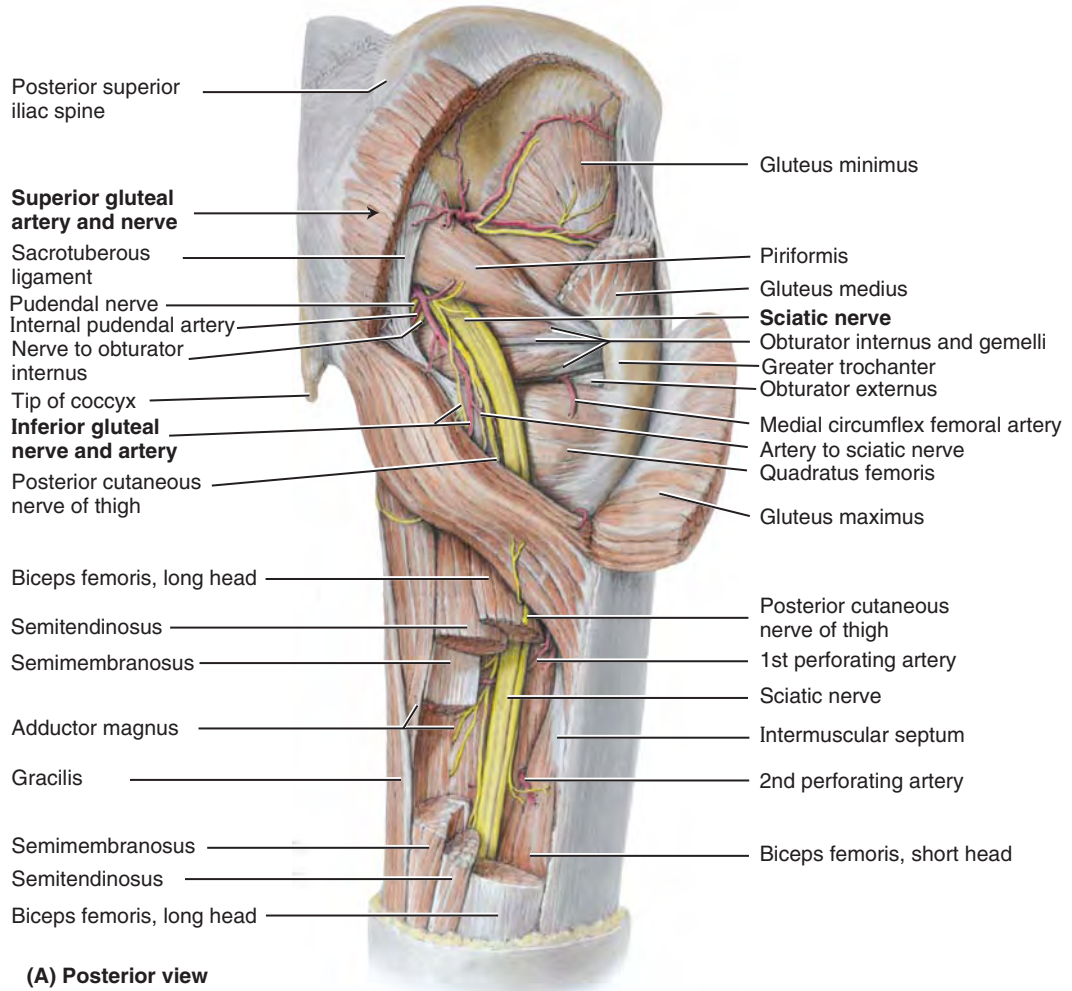
Testing the gluteus medius and minimus is performed while the person is side-lying with the test limb uppermost and the lowermost limb flexed at the hip and knee for stability. The person abducts the thigh without flexion or rotation against straight downward resistance. The gluteus medius can be palpated inferior to the iliac crest, posterior to the tensor fasciae latae, which is also contracting during abduction of the thigh.

TENSOR FASCIAE LATAE

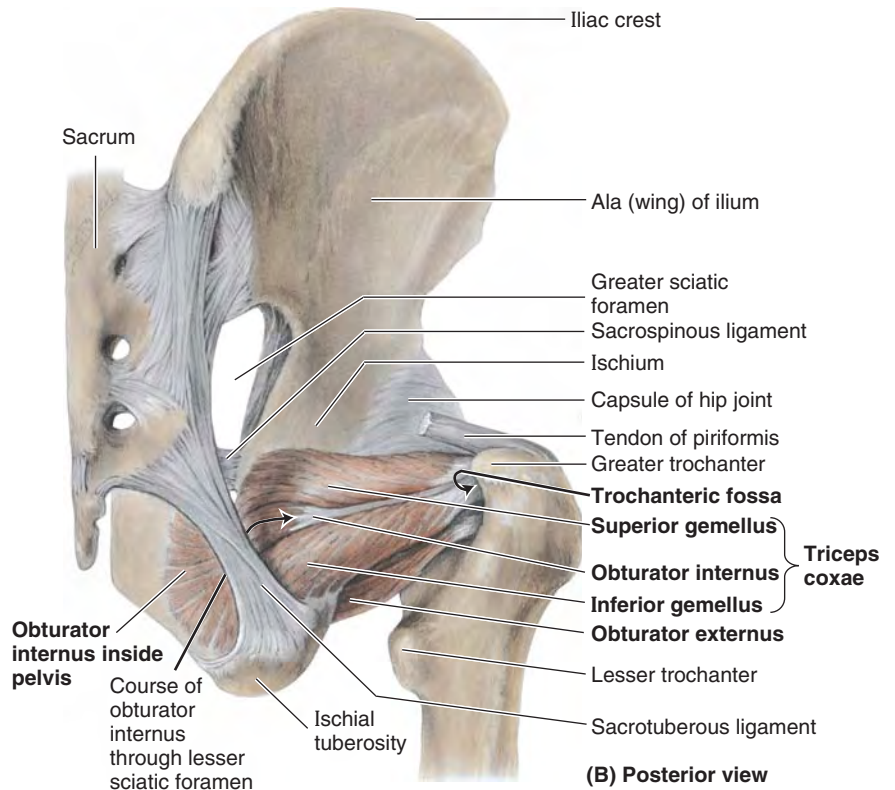
The **tensor fasciae latae** is a fusiform muscle approximately 15 cm long that is enclosed between two layers of fascia lata (Figs. 5.34C & J, 5.36, and 5.37). Its attachments, innervation, and action are provided in Table 5.6.

The tensor fasciae latae and the superficial and anterior part of the gluteus maximus share a common distal attachment to the *anterolateral tubercle of the tibia* via the *iliotibial tract*, which acts as a long aponeurosis for the muscles.

(text continues on p. 569)



(A) Posterior view



(B) Posterior view

FIGURE 5.38. Dissection of gluteal region and posterior thigh. A. Most of the gluteus maximus and medius are removed, and segments of the hamstrings are excised, to reveal the neurovascular structures of the gluteal region and proximal posterior thigh. The sciatic nerve runs deep (anterior) to and is protected by the overlying gluteus maximus initially and then the biceps femoris. B. This dissection shows some of the lateral rotators of the thigh. The components of the triceps coxae share a common attachment into the trochanteric fossa adjacent to that of the obturator externus.

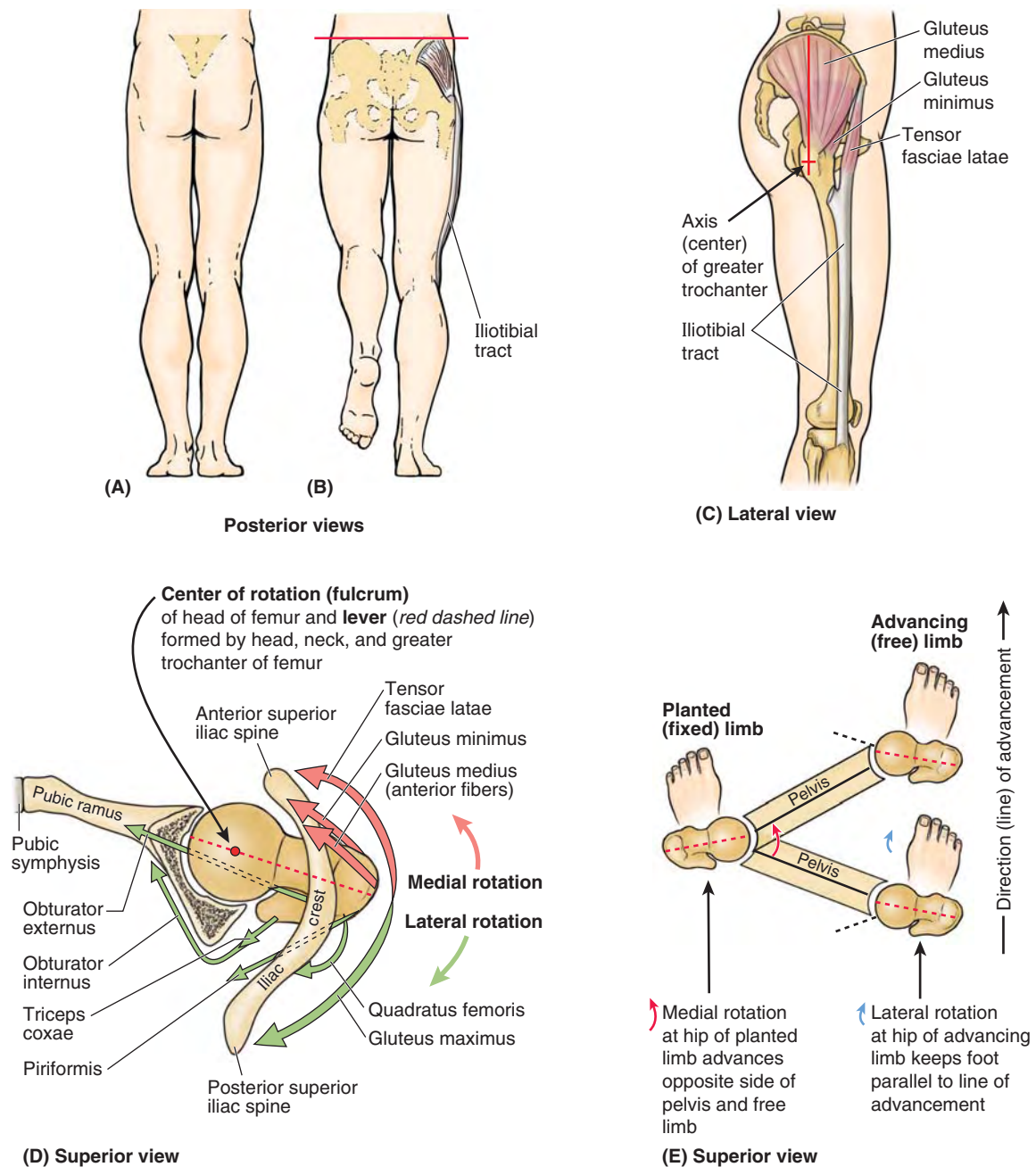


FIGURE 5.39. Action of abductors/medial rotators of thigh in walking. **A and B.** The role of the abductors (gluteus medius and minimus, tensor fasciae latae) is demonstrated. When the weight is on both feet (**A**), the pelvis is evenly supported and does not sag. When the weight is borne by one limb (**B**), the muscles on the supported side fix the pelvis so that it does not sag to the unsupported side. Keeping the pelvis level enables the non-weight-bearing limb to clear the ground as it is brought forward during the swing phase. **C and D.** The role of the rotators of the thigh is demonstrated in lateral (**C**) and superior (**D**) views. Note that most abductors—the tensor fasciae latae, gluteus minimus, and most (the anterior fibers) of the gluteus medius—lie anterior to the lever provided by the axis of the head, neck, and greater trochanter of the femur to rotate the thigh around the vertical axis traversing the femoral head. The superior view of the right hip joint (**D**) includes the superior pubic ramus, acetabulum, and iliac crest; the inferior part of the ilium has been removed to reveal the head and neck of the femur. The lines of pull of the rotators of the hip are indicated by arrows, demonstrating the antagonistic relationship resulting from their positions relative to the lever and the center of rotation (fulcrum). The medial rotators pull the greater trochanter anteriorly and the lateral rotators pull the trochanter posteriorly, resulting in rotation of the thigh around the vertical axis. Note that all of these muscles also pull the head and neck of the femur medially into the acetabulum, strengthening the joint. In walking (**E**), the same muscles that act unilaterally during the stance phase (planted limb) to keep the pelvis level via abduction can simultaneously produce medial rotation at the hip joint, advancing the opposite unsupported side of the pelvis (augmenting advancement of the free limb). The lateral rotators of the advancing (free) limb act during the swing phase to keep the foot parallel to the direction (line) of advancement.

However, unlike the gluteus maximus, the tensor fasciae latae is served by the superior gluteal neurovascular bundle. Despite its gluteal innervation and shared attachment, this tensor is primarily a flexor of the thigh because of its anterior location; however, it generally does not act independently.

To produce flexion, the tensor fasciae latae acts in concert with the iliopsoas and rectus femoris. When the iliopsoas is paralyzed, the tensor fasciae latae undergoes hypertrophy in an attempt to compensate for the paralysis. It also works in conjunction with other abductor/medial rotator muscles (gluteus medius and minimus) (Fig. 5.39). It lies too far anteriorly to be a strong abductor and thus probably contributes primarily as a synergist or fixator.

The tensor fasciae latae tenses the fascia lata and iliotibial tract. Because the iliotibial tract is attached to the femur via the lateral intermuscular septum, the tensor produces little if any movement of the leg (Fig. 5.36B). However, when the knee is fully extended, it contributes to (increases) the extending force, adding stability, and plays a role in supporting the femur on the tibia when standing if lateral sway occurs. When the knee is flexed by other muscles, the tensor fasciae latae can synergistically augment flexion and lateral rotation of the leg.

The abductors/medial rotators of the hip joint play an essential role during locomotion, advancing and preventing the sagging of the unsupported side of the pelvis during walking, as illustrated and explained in Figure 5.39. The supportive and action-producing functions of the abductors/medial rotators depend on normal:

- Muscular activity and innervation from the superior gluteal nerve.
- Articulation of the hip joint components.
- Strength and angulation of the femoral neck.

PIRIFORMIS

The pear-shaped **piriformis** (L. *pirum*, a pear) is located partly on the posterior wall of the lesser pelvis and partly posterior to the hip joint (Figs. 5.34F & G, 5.35, and 5.37; Table 5.6). The piriformis leaves the pelvis through the *greater sciatic foramen*, almost filling it, to reach its attachment to the superior border of the *greater trochanter*.

Because of its key position in the buttock, the *piriformis* is the landmark of the gluteal region. The piriformis provides the key to understanding relationships in the gluteal region because it determines the names of the blood vessels and nerves (Fig. 5.38A):

- The superior gluteal vessels and nerve emerge superior to it.
- The inferior gluteal vessels and nerve emerge inferior to it.

See the blue box “Injury to Sciatic Nerve,” p. 582.

OBTURATOR INTERNUS AND GEMELLI

The **obturator internus** and the **superior** and **inferior gemelli** (L. *geminus*, small twin) form a tricipital (three-

headed) muscle, the **triceps coxae** (triceps of the hip), which occupies the gap between the piriformis and the quadratus femoris (Figs. 5.34H, 5.35, 5.37, and 5.38A & B). The common tendon of these muscles lies horizontally in the buttock as it passes to the greater trochanter of the femur.

The attachments, action, and innervation are described in Table 5.6. The *obturator internus* is located partly in the pelvis, where it covers most of the lateral wall of the lesser pelvis (Fig. 5.38B). It leaves the pelvis through the *lesser sciatic foramen*, makes a right-angle turn (Figs. 5.38B and 5.39D), becomes tendinous, and receives the distal attachments of the gemelli before attaching to the medial surface of the greater trochanter (trochanteric fossa).

The small *gemelli* are narrow, triangular extrapelvic reinforcements of the obturator internus. Although the inferior gemellus receives separate innervation from the nerve to the quadratus femoris, it is more realistic to consider these three muscles as a unit (i.e., as the *triceps coxae*) because they are incapable of independent action.

The **bursa of the obturator internus** allows free movement of the muscle over the posterior border of the ischium, where the border forms the lesser sciatic notch and the trochlea over which the tendon glides as it turns (Fig. 5.37).

QUADRATUS FEMORIS

The **quadratus femoris** is a short, flat quadrangular muscle located inferior to the obturator internus and gemelli (Figs. 5.34I, 5.35, 5.37, and 5.38A). True to its name, the quadratus femoris is a rectangular muscle; it is a strong lateral rotator of the thigh.

OBTURATOR EXTERNUS

Based on its location (posterior to the pectineus and the superior ends of the adductor muscles) and its innervation (*obturator nerve*), the obturator externus was described earlier in this chapter with the medial thigh muscles (Fig. 5.23H; Table 5.4). However, it functions as a lateral rotator of the thigh, and its distal attachment is visible only during dissection of the gluteal region (Fig. 5.38B) or hip joint. Thus it is mentioned again in this context.

Its belly lies deep in the proximal thigh, with its tendon passing inferior to the neck of the femur and deep to the quadratus femoris on the way to its attachment to the trochanteric fossa of the femur (Figs. 5.38A and 5.39D). The obturator externus, with other short muscles around the hip joint, stabilizes the head of the femur in the acetabulum. It is most effective as a lateral rotator of the thigh when the hip joint is flexed.

Posterior Thigh Region

The **posterior thigh muscles** and their attachments are illustrated in Figure 5.40 and their attachments, innervation, and actions are described in Table 5.7. Three of the four

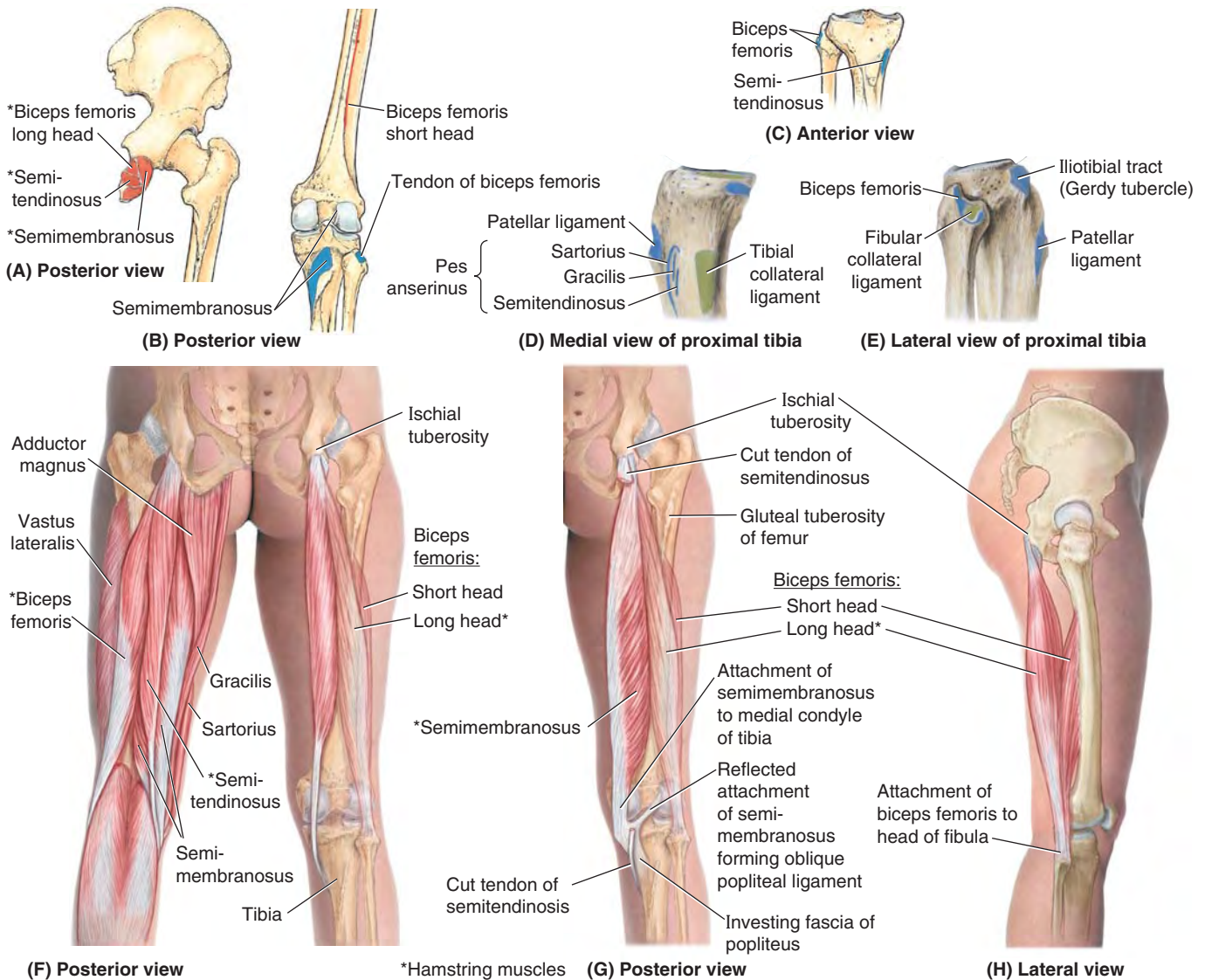


FIGURE 5.40. Muscles of posterior thigh: extensors of hip and flexors of knee.

TABLE 5.7. MUSCLES OF POSTERIOR THIGH: EXTENSORS OF HIP AND FLEXORS OF KNEE

| Muscle ^a | Proximal Attachment | Distal Attachment | Innervation ^b | Main Action |
|---------------------|---|---|---|--|
| Semitendinosus | Ischial tuberosity | Medial surface of superior part of tibia | Tibial division of sciatic nerve part of tibia (L5, S1, S2) | Extend thigh; flex leg and rotate it medially when knee is flexed; when thigh and leg are flexed, these muscles can extend trunk |
| Semimembranosus | | Posterior part of medial condyle of tibia; reflected attachment forms oblique popliteal ligament (to lateral femoral condyle) | | |
| Biceps femoris | Long head: ischial tuberosity Short head: linea aspera and lateral supracondylar line of femur | Lateral side of head of fibula; tendon is split at this site by fibular collateral ligament of knee | Long head: tibial division of sciatic nerve (L5, S1, S2) Short head: common fibular division of sciatic nerve (L5, S1, S2) | Flexes leg and rotates it laterally when knee is flexed; extends thigh (e.g., accelerating mass during first step of gait). |

^a Collectively these three muscles are known as hamstrings.

^b The spinal cord segmental innervation is indicated (e.g., "L5, S1, S2" means that the nerves supplying the semitendinosus are derived from the fifth lumbar segment and first two sacral segments of the spinal cord). Numbers in boldface (**L5, S1**) indicate the main segmental innervation. Damage to one or more of the listed spinal cord segments or to the motor nerve roots arising from them results in paralysis of the muscles concerned.

muscles in the posterior aspect of the thigh are *hamstrings*. The **hamstring muscles** (Figs. 5.40A–D and 5.41B) are: (1) *semitendinosus*, (2) *semimembranosus*, and (3) *biceps femoris* (long head). The hamstring muscles (“hamstrings” for short) share common features:

- Proximal attachment to the ischial tuberosity deep to the gluteus maximus (Fig. 5.40A).

- Distal attachment to the bones of the leg (Fig. 5.40B–E).
- Thus they span and act on two joints, producing extension at the hip joint and flexion at the knee joint.
- Innervation by the tibial division of the sciatic nerve.

The long head of the biceps femoris meets all these conditions, but the short head of the biceps, the fourth muscle of the posterior compartment, fails to meet any of them.

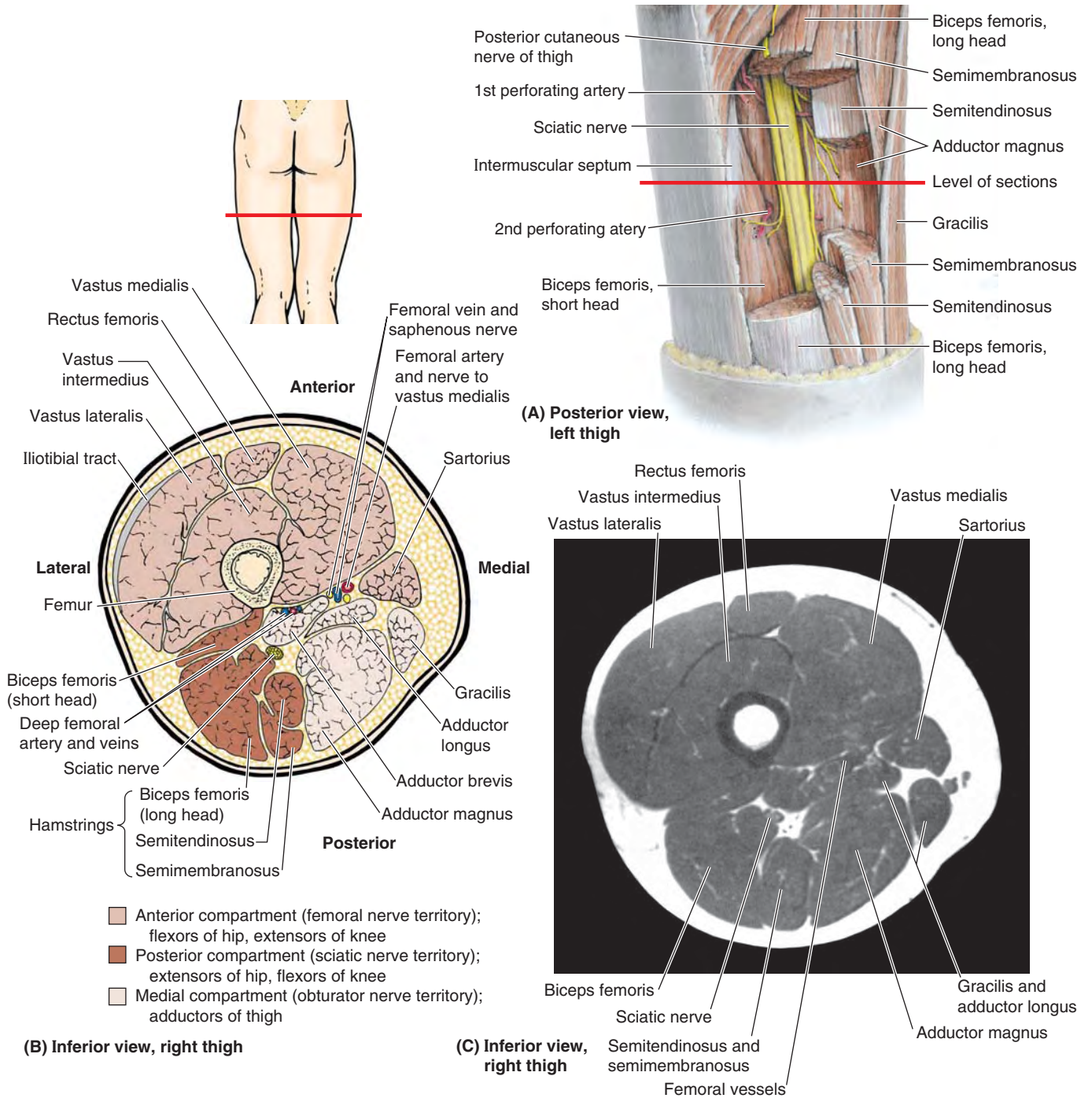


FIGURE 5.41. Muscles and fascial compartments of thigh. A. Segments of the hamstring muscles are excised to reveal the sciatic nerve. The level of the sections shown in parts B and C is indicated. B. An anatomical transverse section through the middle thigh, 10–15 cm inferior to the inguinal ligament. The three compartments of the thigh are demonstrated in different shades of color. Note that each has its own nerve supply and functional group(s) of muscles. C. Transverse MRI of the right thigh corresponding to B. (Courtesy of Dr. W. Kucharczyk, Chair of Medical Imaging, Faculty of Medicine, University of Toronto and Clinical Director of the Tri-Hospital Resonance Centre, Toronto, Ontario, Canada.)

The hamstrings received their name because it is common to tie hams (pork thighs) up for curing and/or smoking with a hook around these muscle tendons. This also explains the expression “hamstringing the enemy” by slashing these tendons lateral and medial to the knees.

The two actions of the hamstrings cannot be performed maximally at the same time: full flexion of the knee requires so much shortening of the hamstrings that they cannot provide the additional contraction that would be necessary for simultaneous full extension of the thigh; similarly, full extension of the hip shortens the hamstrings so they cannot further contract to act fully on the knee. When the thighs and legs are fixed, the hamstrings can help extend the trunk at the hip joint. They are active in thigh extension under all situations except full flexion of the knee, including maintenance of the relaxed standing posture (standing at ease). A person with paralyzed hamstrings tends to fall forward because the gluteus maximus muscles cannot maintain the necessary muscle tone to stand straight.

The hamstrings are the hip extensors involved in walking on flat ground, when the gluteus maximus demonstrates minimal activity. However, rather than producing either hip extension or knee flexion per se during normal walking, the hamstrings demonstrate most activity when they are eccentrically contracting, resisting (decelerating) hip flexion and knee extension during terminal swing (between midswing and heel strike) (see Fig. 5.20G; Table 5.2).

The length of the hamstrings varies, but this is usually a matter of conditioning. In some people, they are not long enough to allow them to touch their toes when the knees are extended. Routine stretch exercise can lengthen these muscles and tendons.

To test the hamstrings, the person flexes their leg against resistance. Normally, these muscles—especially their tendons on each side of the popliteal fossa—should be prominent as they bend the knee (see Fig. 5.48C).

SEMITENDINOSUS

The **semitendinosus**, as its name indicates, is half tendinous (Fig. 5.40F). It has a fusiform belly that is usually interrupted by a tendinous intersection and a long, cord-like tendon that begins approximately two thirds of the way down the thigh. Distally, the tendon attaches to the medial surface of the superior part of the tibia as part of the *pes anserinus* formation in conjunction with the tendinous insertions of the sartorius and gracilis.

SEMIMEMBRANOSUS

The **semimembranosus** is a broad muscle that is also aptly named because of the flattened membranous form of its proximal attachment to the ischial tuberosity (Fig. 5.40G; Table 5.7). The tendon of the semimembranosus forms around the middle of the thigh and descends to the posterior part of the medial condyle of the tibia.

The semimembranosus tendon divides distally into three parts: (1) a direct attachment to the posterior aspect of the medial tibial condyle, (2) a part that blends with the popliteal fascia, and (3) a reflected part that reinforces the intercondylar part of the joint capsule of the knee as the **oblique popliteal ligament** (Fig. 5.40G; see also Fig. 5.58B).

When the knee is flexed to 90°, the tendons of the medial hamstrings or “semi-” muscles (semitendinosus and semimembranosus) pass to the medial side of the tibia. In this position, contraction of the medial hamstrings (and of synergists including the gracilis, sartorius, and popliteus) produces a limited amount (about 10°) of medial rotation of the tibia at the knee. The two medial hamstrings are not as active as the lateral hamstring, the biceps femoris, which is the “work-horse” of extension at the hip (Hamill and Knutzen, 2008).

BICEPS FEMORIS

The fusiform **biceps femoris**, as its name indicates, has two heads: a *long head* and a *short head* (Fig. 5.40F–H). In the inferior part of the thigh, the long head becomes tendinous and is joined by the short head. The rounded common tendon of these heads attaches to the head of the fibula and can easily be seen and felt as it passes the knee, especially when the knee is flexed against resistance.

The **long head of the biceps femoris** crosses and provides protection for the sciatic nerve after it descends from the gluteal region into the posterior aspect of the thigh (Figs. 5.38A and 5.41A–C). When the sciatic nerve divides into its terminal branches, the lateral branch (common fibular nerve) continues this relationship, running with the biceps tendon.

The **short head of the biceps femoris** arises from the lateral lip of the inferior third of the linea aspera and supracondylar ridge of the femur (Fig. 5.38B & H). Whereas the hamstrings have a common nerve supply from the tibial division of the sciatic nerve, *the short head of the biceps is innervated by the fibular division* (Table 5.7). Because each of the two heads of the biceps femoris has a different nerve supply, a wound in the posterior thigh with nerve injury may paralyze one head and not the other.

When the knee is flexed to 90°, the tendons of the lateral hamstring (biceps), as well as the iliotibial tract, pass to the lateral side of the tibia. In this position, contraction of the biceps and tensor fasciae latae produces about 40° lateral rotation of the tibia at the knee. Rotation of the flexed knee is especially important in snow skiing.

Neurovascular Structures of Gluteal and Posterior Thigh Regions

Several important nerves arise from the *sacral plexus* and either supply the gluteal region (e.g., superior and inferior gluteal nerves) or pass through it to supply the perineum and thigh (e.g., the pudendal and sciatic nerves, respectively). Figure 5.42 depicts the nerves of the gluteal region and posterior thigh, and Table 5.8 describes their origin, course, and distribution.

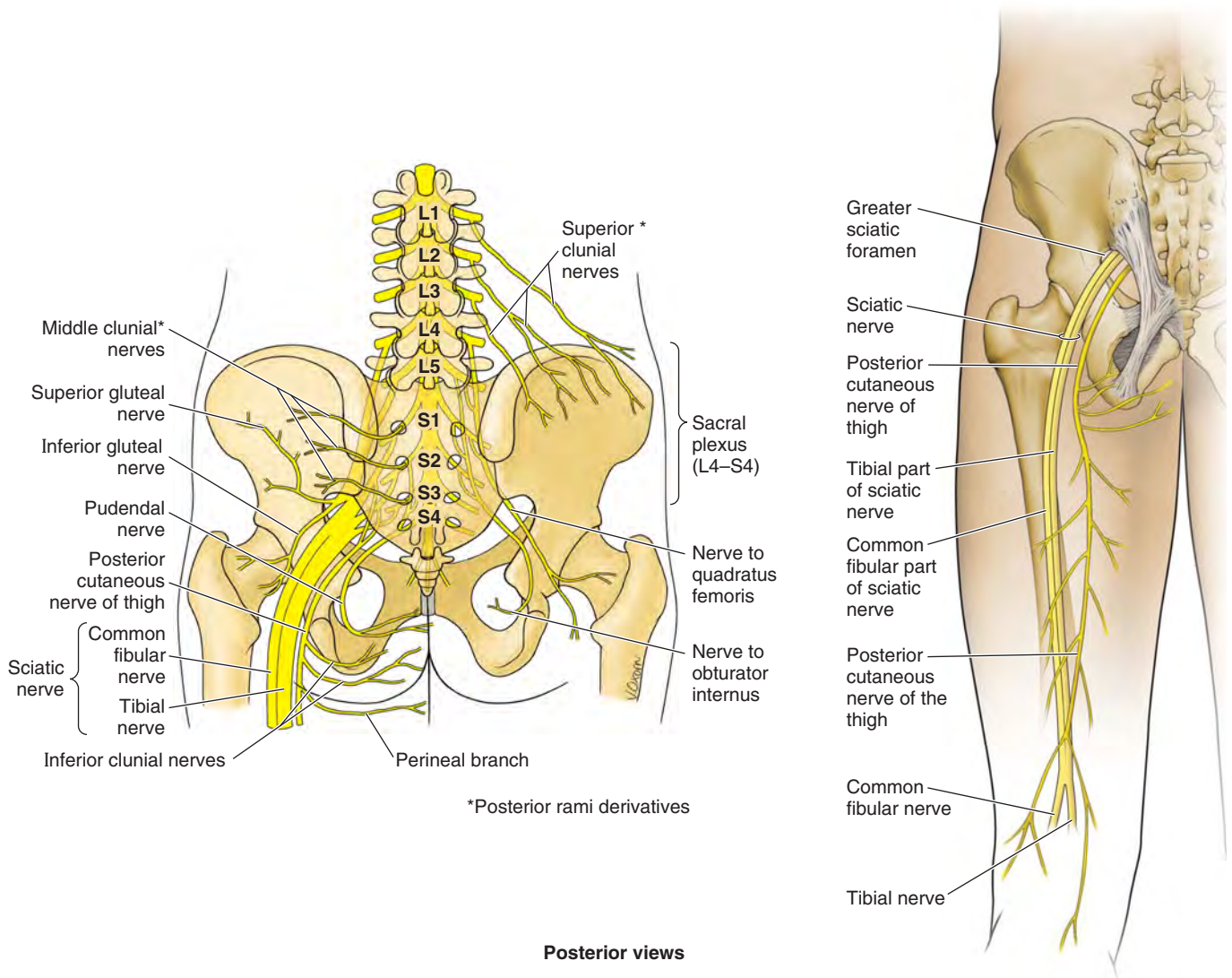


FIGURE 5.42. Nerves of the gluteal and posterior thigh regions.

TABLE 5.8. NERVES OF GLUTEAL AND POSTERIOR THIGH REGIONS

| Nerve | Origin | Course | Distribution |
|----------|---|---|--|
| Clunial | | | |
| Superior | As lateral cutaneous branches of posterior rami of L1–L3 spinal nerves | Pass inferolaterally across iliac crest | Supply skin of superior buttock as far as tubercle of iliac crest |
| Middle | As lateral cutaneous branches of posterior rami of S1–S3 spinal nerves | Exit through posterior sacral foramina and pass laterally to gluteal region | Supply skin over sacrum and adjacent area of buttock |
| Inferior | Posterior cutaneous nerve of thigh (anterior rami of S2–S3 spinal nerves) | Emerges from inferior border of gluteus maximus and ascends superficial to it | Supplies skin of inferior half of buttock as far as greater trochanter |

TABLE 5.8. NERVES OF GLUTEAL AND POSTERIOR THIGH REGIONS (Continued)

| Nerve | Origin | Course | Distribution |
|------------------------------------|--|---|---|
| Sciatic | Sacral plexus (anterior and posterior divisions of anterior rami of L4–S3 spinal nerves) | Enters gluteal region via greater sciatic foramen inferior to piriformis and deep to gluteus maximus; descends in posterior thigh deep to biceps femoris; bifurcates into tibial and common fibular nerves at apex of popliteal fossa | Supplies no muscles in gluteal region; supplies all muscles of posterior compartment of thigh (tibial division supplies all but short head of biceps, which is supplied by common fibular division) |
| Posterior cutaneous nerve of thigh | Sacral plexus (anterior and posterior divisions of anterior rami of S1–S3 spinal nerves) | Enters gluteal region via greater sciatic foramen inferior to piriformis and deep to gluteus maximus, emerging from inferior border of latter; descends in posterior thigh deep to fascia lata | Supplies skin of inferior half of buttock (through inferior clunial nerves), skin over posterior thigh and popliteal fossa, and skin of lateral perineum and upper medial thigh (via its perineal branch) |
| Superior gluteal | Sacral plexus (posterior divisions of anterior rami of L4–S1 spinal nerves) | Enters gluteal region via greater sciatic foramen superior to piriformis; courses laterally between gluteus medius and minimus as far as tensor fasciae latae | Innervates gluteus medius, gluteus minimus, and tensor fasciae latae muscles |
| Inferior gluteal | Sacral plexus (posterior divisions of anterior rami of L5–S2 spinal nerves) | Enters gluteal region via greater sciatic foramen inferior to piriformis and deep to inferior part of gluteus maximus, dividing into several branches | Supplies gluteus maximus |
| Nerve to quadratus femoris | Sacral plexus (anterior divisions of anterior rami of L4–S1 spinal nerves) | Enters gluteal region via greater sciatic foramen inferior to piriformis, deep (anterior) to sciatic nerve | Innervates hip joint, inferior gemellus, and quadratus femoris |
| Pudendal | Sacral plexus (anterior divisions of anterior rami of S2–S4 spinal nerves) | Exits pelvis via greater sciatic foramen inferior to piriformis; descends posterior to sacrospinous ligament; enters perineum through lesser sciatic foramen | Supplies no structures in gluteal region or posterior thigh (principal nerve to perineum) |
| Nerve to obturator internus | Sacral plexus (posterior divisions of anterior rami of L5–S2 spinal nerves) | Exits pelvis via greater sciatic foramen inferior to piriformis; descends posterior to sacrospinous ligament; enters perineum through lesser sciatic foramen | Supplies superior gemellus and obturator internus |

CLUNIAL NERVES

The skin of the gluteal region is richly innervated by **superior, middle, and inferior clunial nerves** (*L. clunes*, buttocks). These superficial nerves supply the skin over the iliac crest, between the posterior superior iliac spines, and over the iliac tubercles. Consequently, these nerves are vulnerable to injury when bone is taken from the ilium for grafting.

DEEP GLUTEAL NERVES

The *deep gluteal nerves* are the superior and inferior gluteal nerves, sciatic nerve, nerve to quadratus femoris, posterior cutaneous nerve of the thigh, nerve to obturator internus, and pudendal nerve (Figs. 5.38A and 5.42; Table 5.8). All of these nerves are branches of the sacral plexus and leave the pelvis through the greater sciatic foramen. Except for the superior gluteal nerve, they all emerge inferior to the piriformis.

Superior Gluteal Nerve. The **superior gluteal nerve** runs laterally between the gluteus medius and minimus with the deep branch of the superior gluteal artery. It divides into a superior branch that supplies the gluteus medius and an inferior branch that continues to pass between the gluteus

medius and the gluteus minimus to supply both muscles and the tensor fasciae latae.

See the blue box “Injury to Superior Gluteal Nerve” on p. 581.

Inferior Gluteal Nerve. The **inferior gluteal nerve** leaves the pelvis through the greater sciatic foramen, inferior to the piriformis and superficial to the sciatic nerve, accompanied by multiple branches of the inferior gluteal artery and vein. The inferior gluteal nerve also divides into several branches, which provide motor innervation to the overlying gluteus maximus.

Sciatic Nerve. The **sciatic nerve** is the largest nerve in the body and is the continuation of the main part of the *sacral plexus*. The branches (rami) converge at the inferior border of the piriformis to form the sciatic nerve, a thick, flattened band approximately 2 cm wide. The sciatic nerve is the most lateral structure emerging through the greater sciatic foramen inferior to the piriformis.

Medial to the sciatic nerve are the inferior gluteal nerve and vessels, the internal pudendal vessels, and the pudendal nerve. The sciatic nerve runs inferolaterally under cover of the gluteus maximus, midway between the greater trochanter

and ischial tuberosity. The nerve rests on the ischium and then passes posterior to the obturator internus, quadratus femoris, and adductor magnus muscles. The sciatic nerve is so large that it receives a named branch of the inferior gluteal artery, the **artery to the sciatic nerve**.

The sciatic nerve supplies no structures in the gluteal region. It supplies the posterior thigh muscles, all leg and foot muscles, and the skin of most of the leg and foot. It also supplies the articular branches to all joints of the lower limb. The sciatic nerve is really two nerves, the *tibial nerve*, derived from anterior (preaxial) divisions of the anterior rami, and the *common fibular nerve*, derived from posterior (postaxial) divisions of the anterior rami, which are loosely bound together in the same connective tissue sheath (Figs. 5.42 and 5.43A).

The tibial and common fibular nerves usually separate in the distal thigh (Fig. 5.42B); however, in approximately 12% of people, the nerves separate as they leave the pelvis (Fig. 5.43A). In these cases, the tibial nerve passes inferior to the piriformis, and the common fibular nerve pierces this muscle or passes superior to it (Fig. 5.43B & C).

Nerve to Quadratus Femoris. The **nerve to the quadratus femoris** leaves the pelvis anterior to the sciatic nerve and obturator internus and passes over the posterior surface of the hip joint (Fig. 5.42). It supplies an articular branch to

this joint and innervates the inferior gemellus and quadratus femoris muscles.

Posterior Cutaneous Nerve of Thigh. The **posterior cutaneous nerve of the thigh** supplies more skin than any other cutaneous nerve (Fig. 5.42B). Its fibers from the anterior divisions of S2 and S3 supply the skin of the perineum via its *perineal branch*. Some of the fibers from the posterior divisions of the anterior rami of S1 and S2 supply the skin of the inferior part of the buttock (via the *inferior clunial nerves*). Other fibers continue inferiorly in branches that supply the skin of the posterior thigh and proximal part of the leg. Unlike most nerves bearing the name *cutaneous*, the main part of this nerve lies deep to the deep fascia (fascia lata), with only its terminal branches penetrating the subcutaneous tissue for distribution to the skin.

Pudendal Nerve. The **pudendal nerve** is the most medial structure to exit the pelvis through the greater sciatic foramen. It descends inferior to the piriformis, posterolateral to the sacrospinous ligament, and enters the perineum through the lesser sciatic foramen to supply structures in this region. The pudendal nerve supplies no structures in the gluteal region or posterior thigh, and is discussed in detail in Chapter 3.

Nerve to Obturator Internus. The **nerve to the obturator internus** arises from the anterior divisions of the anterior rami of the L5–S2 nerves and parallels the course of the pudendal nerve (Fig. 5.42A). As it passes around the base of the ischial spine, it supplies the superior gemellus. After entering the perineum via the lesser sciatic foramen, it supplies the obturator internus muscle.

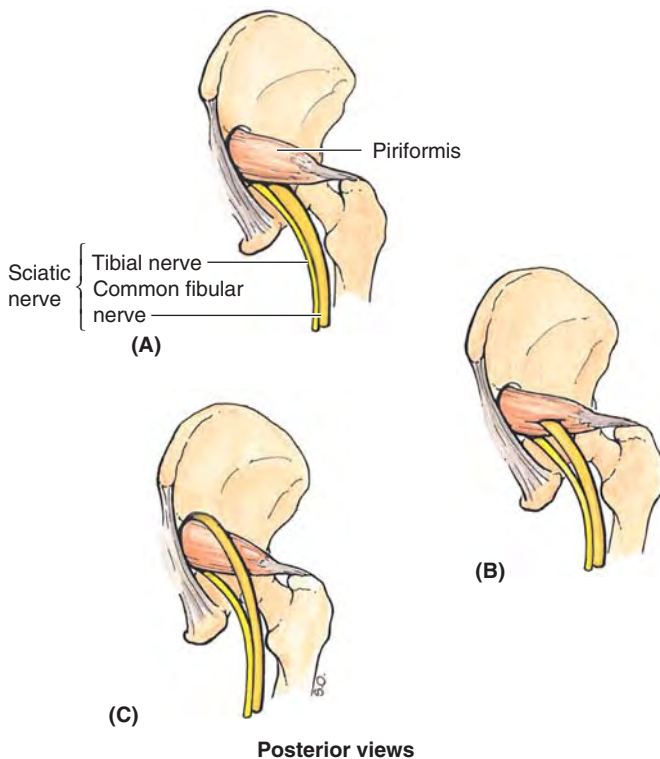


FIGURE 5.43. Relationship of sciatic nerve to piriformis. **A.** The sciatic nerve usually emerges from the greater sciatic foramen inferior to the piriformis. **B.** In 12.2% of 640 limbs studied by Dr. J. C. B. Grant, the sciatic nerve divided before exiting the greater sciatic foramen; the common fibular division (yellow) passed through the piriformis. **C.** In 0.5% of cases, the common fibular division passed superior to the muscle, where it is especially vulnerable to injury during intragluteal injections.

ARTERIES OF GLUTEAL AND POSTERIOR THIGH REGIONS

The **arteries of the gluteal region** arise, directly or indirectly, from the *internal iliac arteries*, but the patterns of origin of the arteries are variable (Figs. 5.38A and 5.44; Table 5.9). The major branches of the internal iliac artery that supply or traverse the gluteal region are the (1) superior gluteal artery, (2) inferior gluteal artery, and (3) internal pudendal artery. The posterior compartment of the thigh has no major artery exclusive to the compartment; it receives blood from multiple sources: inferior gluteal, medial circumflex femoral, perforating, and popliteal arteries.

Superior Gluteal Artery. The **superior gluteal artery** is the largest branch of the internal iliac artery and passes posteriorly between the lumbosacral trunk and the S1 nerve. This artery leaves the pelvis through the greater sciatic foramen, superior to the piriformis, and divides immediately into superficial and deep branches. The *superficial branch* supplies the gluteus maximus and skin over the proximal attachment of this muscle. The *deep branch* supplies the gluteus medius, gluteus minimus, and tensor fasciae latae. The superior gluteal artery anastomoses with the inferior gluteal and medial circumflex femoral arteries.

Inferior Gluteal Artery. The **inferior gluteal artery** arises from the internal iliac artery and passes posteriorly through the parietal pelvic fascia, between the S1 and the S2

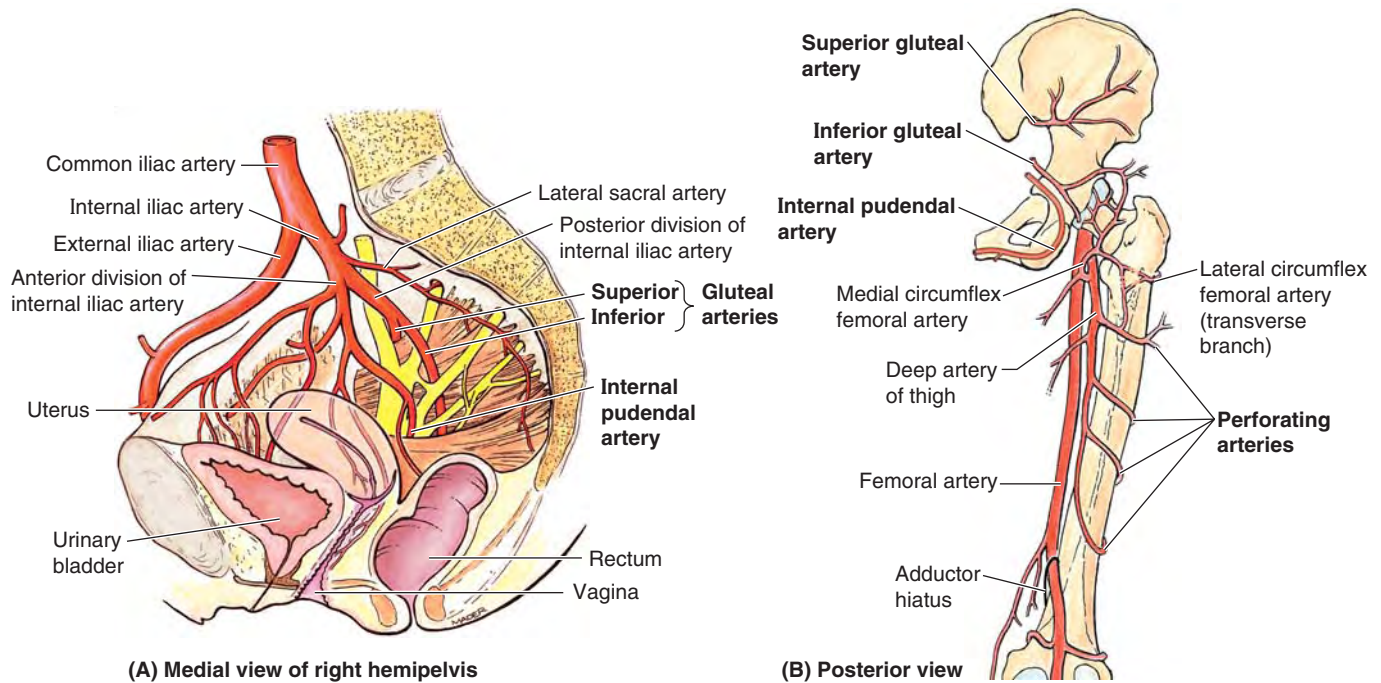


FIGURE 5.44. Arteries of the gluteal and posterior thigh regions.

TABLE 5.9. ARTERIES OF GLUTEAL AND POSTERIOR THIGH REGIONS

| Artery ^a | Course | Distribution |
|---------------------|--|---|
| Superior gluteal | Enters gluteal region through greater sciatic foramen superior to piriformis; divides into superficial and deep branches; anastomoses with inferior gluteal and medial circumflex femoral arteries (not shown in Fig. 5.44) | Superficial branch: supplies gluteus maximus Deep branch: runs between gluteus medius and minimus and supplies them and tensor fasciae latae |
| Inferior gluteal | Enters gluteal region through greater sciatic foramen inferior to piriformis; descends on medial side of sciatic nerve; anastomoses with superior gluteal artery and participates in cruciate anastomosis of thigh, involving first perforating artery of deep femoral and medial and lateral circumflex arteries (not shown in Fig. 5.44) | Supplies gluteus maximus, obturator internus, quadratus femoris, and superior parts of hamstrings |
| Internal pudendal | Enters gluteal region through greater sciatic foramen; descends posterior to ischial spine; enters perineum through lesser sciatic foramen | Supplies external genitalia and muscles in perineal region; does not supply gluteal region |
| Perforating | Enters posterior compartment by perforating aponeurotic portion of adductor magnus attachment and medial intermuscular septum; after providing muscular branches to hamstrings, continues to anterior compartment by piercing lateral intermuscular septum | Supplies majority (central portions) of hamstring muscles, then continues to supply vastus lateralis in anterior compartment |

^aAll of these arteries arise from the internal iliac artery (see Fig. 5.29 for an anterior view).

(or S2 and S3) nerves. The inferior gluteal artery leaves the pelvis through the greater sciatic foramen, inferior to the piriformis. It enters the gluteal region deep to the gluteus maximus and descends medial to the sciatic nerve.

The inferior gluteal artery supplies the gluteus maximus, obturator internus, quadratus femoris, and superior parts of the hamstrings. It anastomoses with the superior gluteal artery and frequently but not always participates in the *cruciate anastomosis of the thigh*, involving the first perforating arteries of the deep artery of the thigh and the medial and lateral circumflex femoral arteries (Table 5.5). These vessels all

participate in supplying the structures of the proximal posterior thigh.

Before birth, the inferior gluteal artery is the major artery of the posterior compartment, traversing its length and becoming continuous with the popliteal artery. This part of the artery diminishes, however, persisting postnatally as the *artery to the sciatic nerve*.

Internal Pudendal Artery. The **internal pudendal artery** arises from the internal iliac artery and lies anterior to the inferior gluteal artery. Its course parallels that of the pudendal nerve, entering the gluteal region through the greater

sciatic foramen inferior to the piriformis. The internal pudendal artery leaves the gluteal region immediately by crossing the ischial spine/sacrospinous ligament and enters the perineum through the lesser sciatic foramen. Like the pudendal nerve, it supplies the skin, external genitalia, and muscles in the perineal region. It does not supply any structures in the gluteal region or posterior thigh.

Perforating Arteries. There are usually four **perforating arteries** of the deep artery of the thigh, three arising in the anterior compartment and the fourth being the terminal branch of the deep artery itself (Fig. 5.44; Table 5.9). The perforating arteries are large vessels, unusual in the limbs for their transverse, intercompartmental course.

Surgeons operating in the posterior compartment are careful to identify them to avoid inadvertent injury. They perforate the aponeurotic portion of the distal attachment of the adductor magnus to enter the posterior compartment. Within the posterior compartment, they typically give rise to muscular branches to the hamstrings and anastomotic branches that ascend or descend to unite with those arising superiorly or inferiorly from the other perforating arteries or the inferior gluteal and popliteal artery.

A continuous anastomotic arterial chain thus extends from the gluteal to popliteal regions, which gives rise to additional branches to muscles and to the sciatic nerve. After giving off their posterior compartment branches, the perforating arteries pierce the lateral intermuscular septum to enter the anterior compartment, where they supply the vastus lateralis muscle.

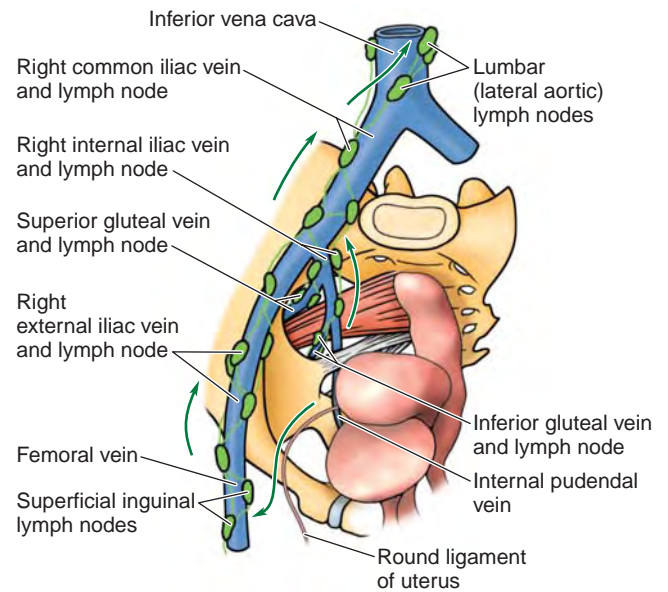
VEINS OF GLUTEAL AND POSTERIOR THIGH REGIONS

The **gluteal veins** are tributaries of the internal iliac veins that drain blood from the gluteal region. The **superior and inferior gluteal veins** accompany the corresponding arteries through the greater sciatic foramen, superior and inferior to the piriformis, respectively (see Fig. 5.45A). They communicate with tributaries of the femoral vein, thereby providing alternative routes for the return of blood from the lower limb if the femoral vein is occluded or has to be ligated.

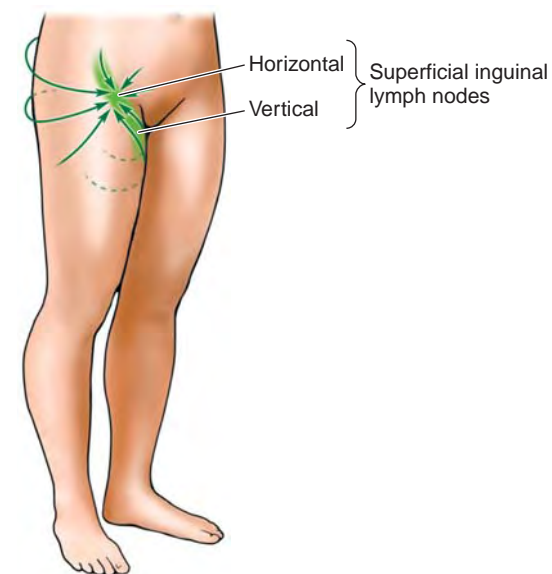
The **internal pudendal veins** accompany the internal pudendal arteries and join to form a single vein that enters the internal iliac vein. These veins drain blood from the external genitalia or pudendum (*L. pudere*, to be ashamed). *Perforating veins* accompany the arteries of the same name to drain blood from the posterior compartment of the thigh into the *deep vein of the thigh*. The perforating veins, like the arteries, usually communicate inferiorly with the popliteal vein and superiorly with the inferior gluteal vein.

LYMPHATIC DRAINAGE OF GLUTEAL AND THIGH REGIONS

Lymph from the deep tissues of the buttocks follows the gluteal vessels to the **superior and inferior gluteal lymph nodes** and from them to the **internal, external, and common iliac lymph nodes** (Fig. 5.45A) and from them to the **lateral lumbar (aortic/caval) lymph nodes**.



(A) Deep lymphatic drainage from gluteal and thigh regions



(B) Superficial lymphatic drainage from gluteal region and thigh

FIGURE 5.45. Lymphatic drainage of gluteal and thigh regions. A. Lymph from the deep tissues of the gluteal region enters the pelvis along the gluteal veins, draining to the superior and inferior gluteal lymph nodes; from them, it passes to the iliac and lateral lumbar (caval/aortic) lymph nodes. B. Lymph from superficial tissues of the gluteal region passes initially to the superficial inguinal nodes, which also receive lymph from the thigh. Lymph from all the superficial inguinal nodes passes via efferent lymphatic vessels to the external and common iliac and right and left lumbar (caval/aortic) lymph nodes, draining via lumbar lymphatic trunks to the cisterna chyli and the thoracic duct.

Lymph from the superficial tissues of the gluteal region enters the *superficial inguinal lymph nodes*, which also receive lymph from the thigh (Fig. 5.45A & B). All the superficial inguinal nodes send efferent lymphatic vessels to the external iliac lymph nodes.

In terms of the vascular supply to the lower limb as a whole, the majority of the arterial blood coming to the limb and most of the venous blood and lymph exiting from it pass along the more protected anteromedial aspect of the limb.

Flexor muscles are generally better protected than are extensor muscles, the latter being exposed and therefore vulnerable in the flexed, defensive (fetal) position (vertebral column and limbs flexed).

Surface Anatomy of Gluteal and Posterior Thigh Regions

The skin of the gluteal region is usually thick and coarse, especially in men, whereas the skin of the thigh is relatively thin

and loosely attached to the underlying subcutaneous tissue. A line joining the *highest points of the iliac crests* (Fig. 5.46A) crosses the L4–L5 intervertebral (IV) disc and is a useful landmark when a *lumbar puncture* is performed (see Chapter 4), indicating the middle of the *lumbar cistern*.

The *intergluteal cleft*, beginning inferior to the apex of the sacrum, is the deep groove between the buttocks. It extends as far superiorly as the S3 or S4 segment. The *coccyx* is palpable in the superior part of the intergluteal cleft.

The *posterior superior iliac spines (PSIS)* are located at the posterior extremities of the iliac crests, and may be difficult to palpate; however, their position can always be located at the bottom of the permanent skin dimples approximately 3.75 cm from midline (Fig. 5.46B). A line joining these dim-

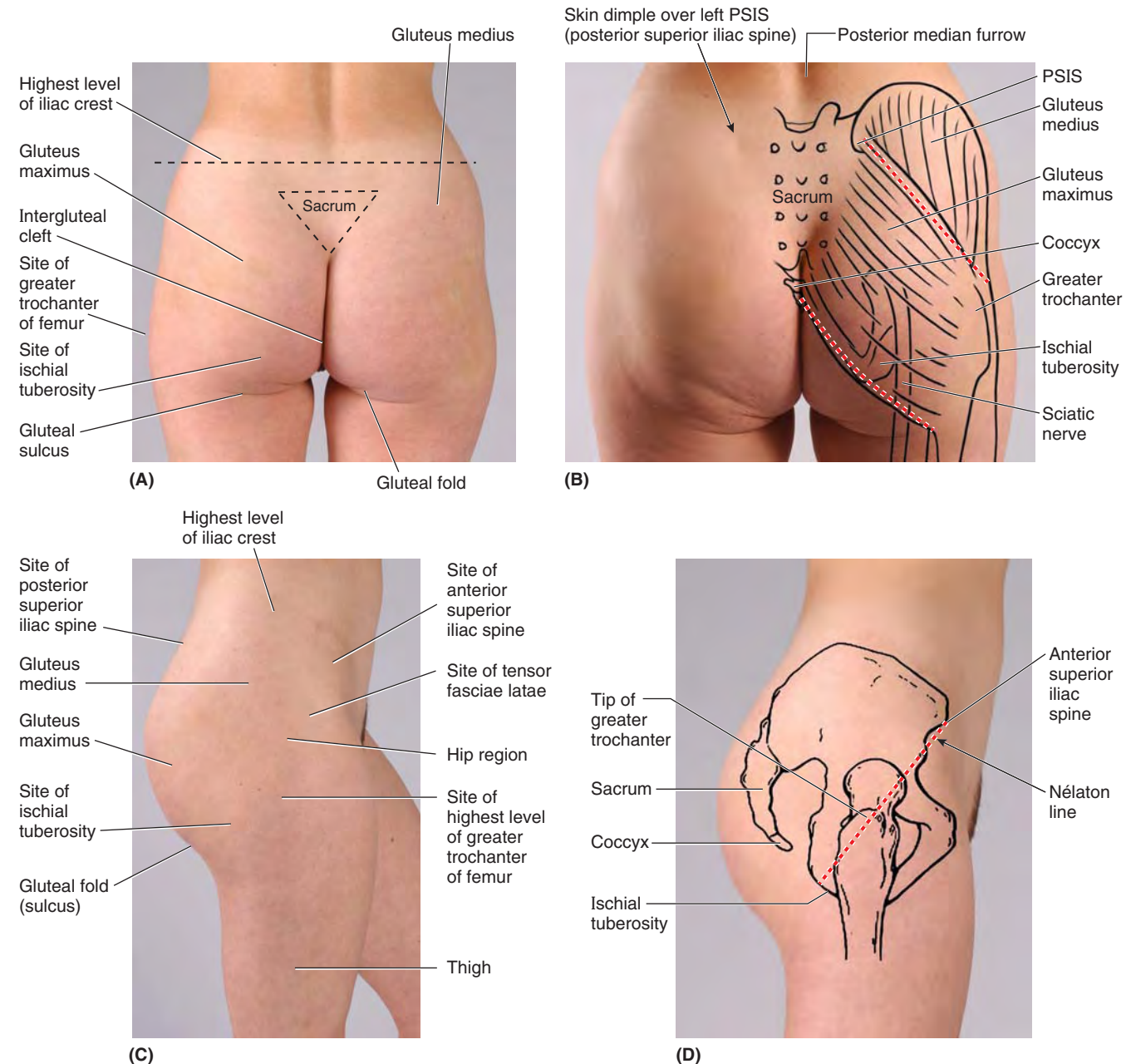


FIGURE 5.46. Surface anatomy of the gluteal region.

ples, often more visible in women than in men, passes through the S2 spinous process, indicating the level of the lowest limit of the *dural sac*, the middle of the sacroiliac joints, and the bifurcation of the common iliac arteries.

The location of only two of the gluteal muscles can be observed. The *gluteus maximus* covering most structures in the gluteal region can be felt to contract when straightening up from bending over. The inferior edge of this large muscle is located just superior to the *gluteal fold*, which contains a variable amount of subcutaneous fat (Fig. 5.46A & C). The gluteal fold disappears when the hip joint is flexed. The degree of prominence of the gluteal fold changes in certain abnormal conditions, such as *atrophy of the gluteus maximus*. An imaginary line drawn from the coccyx to the ischial tuberosity indicates the inferior edge of the gluteus maximus (Fig. 5.46B). Another line drawn from the PSIS to a point slightly superior to the greater trochanter indicates the superior edge of this muscle.

The **gluteal sulcus**, the skin crease inferior to the gluteal fold, delineates the buttock from the posterior aspect of the thigh (Fig. 5.46A & B). When the thigh is extended as in the figures, the *ischial tuberosity* is covered by the inferior part of the gluteus maximus; however, the tuberosity is easy to pal-

pate when the thigh is flexed because the gluteus maximus slips superiorly off the tuberosity, which is then subcutaneous. Feel the ischial tuberosity as you bend to sit.

The superior part of the *gluteus medius* can be palpated between the superior part of the gluteus maximus and the iliac crest (Figs. 5.46B and 5.47A & B). The gluteus medius of one buttock can be felt when all the body weight shifts onto the ipsilateral limb (the one on the same side).

The *greater trochanter*, the most lateral bony point in the gluteal region, may be felt on the lateral aspect of the hip, especially its inferior part (Fig. 5.46A–C). It is easier to palpate when you passively abduct your lower limb to relax the gluteus medius and minimus. The top of the trochanter lies approximately a hand's breadth inferior to the tubercle of the iliac crest.

The prominence of the trochanter increases when a dislocated hip causes atrophy of the gluteal muscles and displacement of the trochanter. A line drawn from the ASIS to the ischial tuberosity (*Nélaton line*), passing over the lateral aspect of the hip region, normally passes over or near the top of the greater trochanter (Fig. 5.46D). The trochanter can be felt superior to this line in a person with a dislocated hip or a fractured femoral neck. The *lesser trochanter* is palpable with dif-

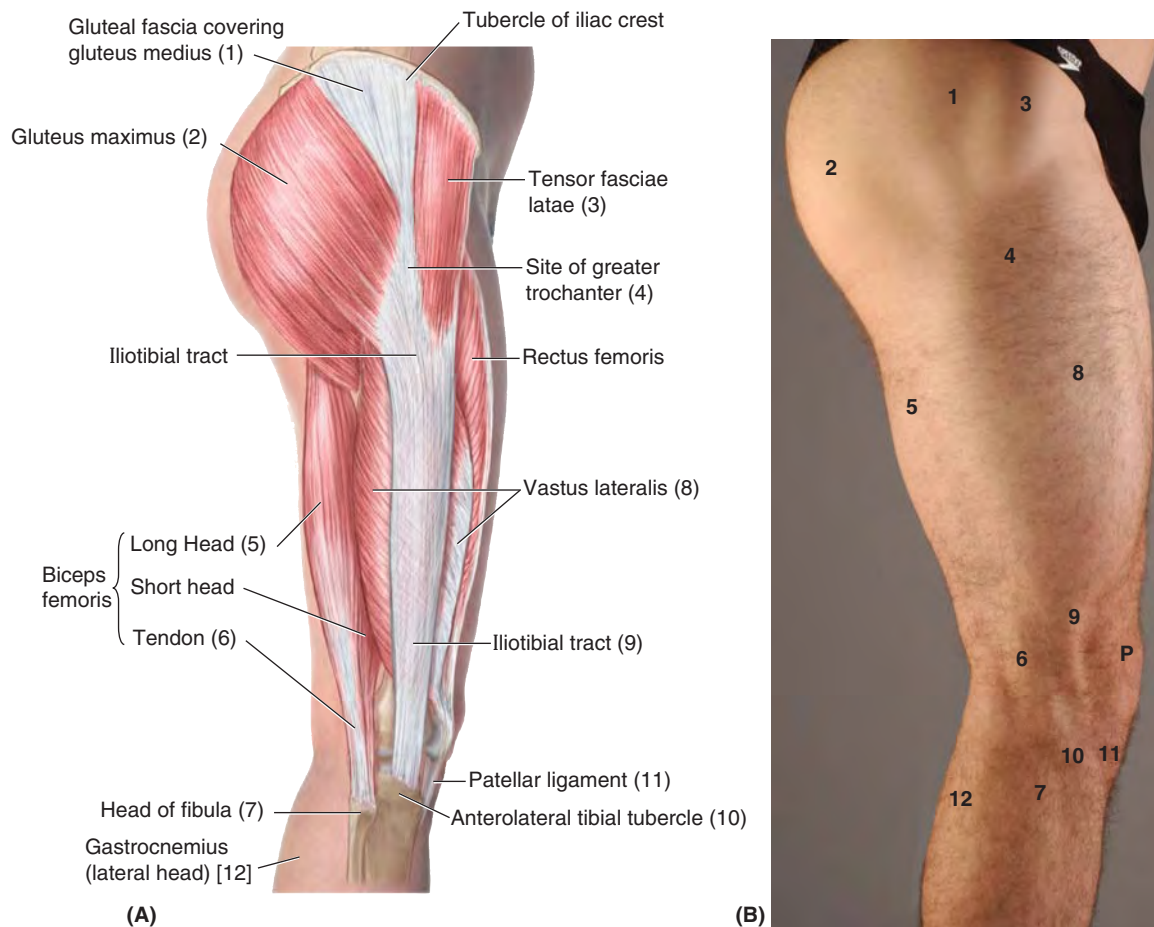


FIGURE 5.47. Surface anatomy of the hip region and lateral thigh.

ficuity from the posterior aspect when the thigh is extended and rotated medially.

The surface marking of the superior border of the piriformis is indicated by a line joining the skin dimple formed by the posterior superior iliac spine to the superior border of the greater trochanter of the femur (Fig. 5.48A).

The *sciatic nerve*, the most important structure inferior to the piriformis, is represented by a line that extends from a point midway between the greater trochanter and the ischial tuberosity (Fig. 5.48A) down the middle of the posterior aspect of the thigh (Fig. 5.48B). The level of the bifurcation of the sciatic nerve into the tibial and common fibular nerves

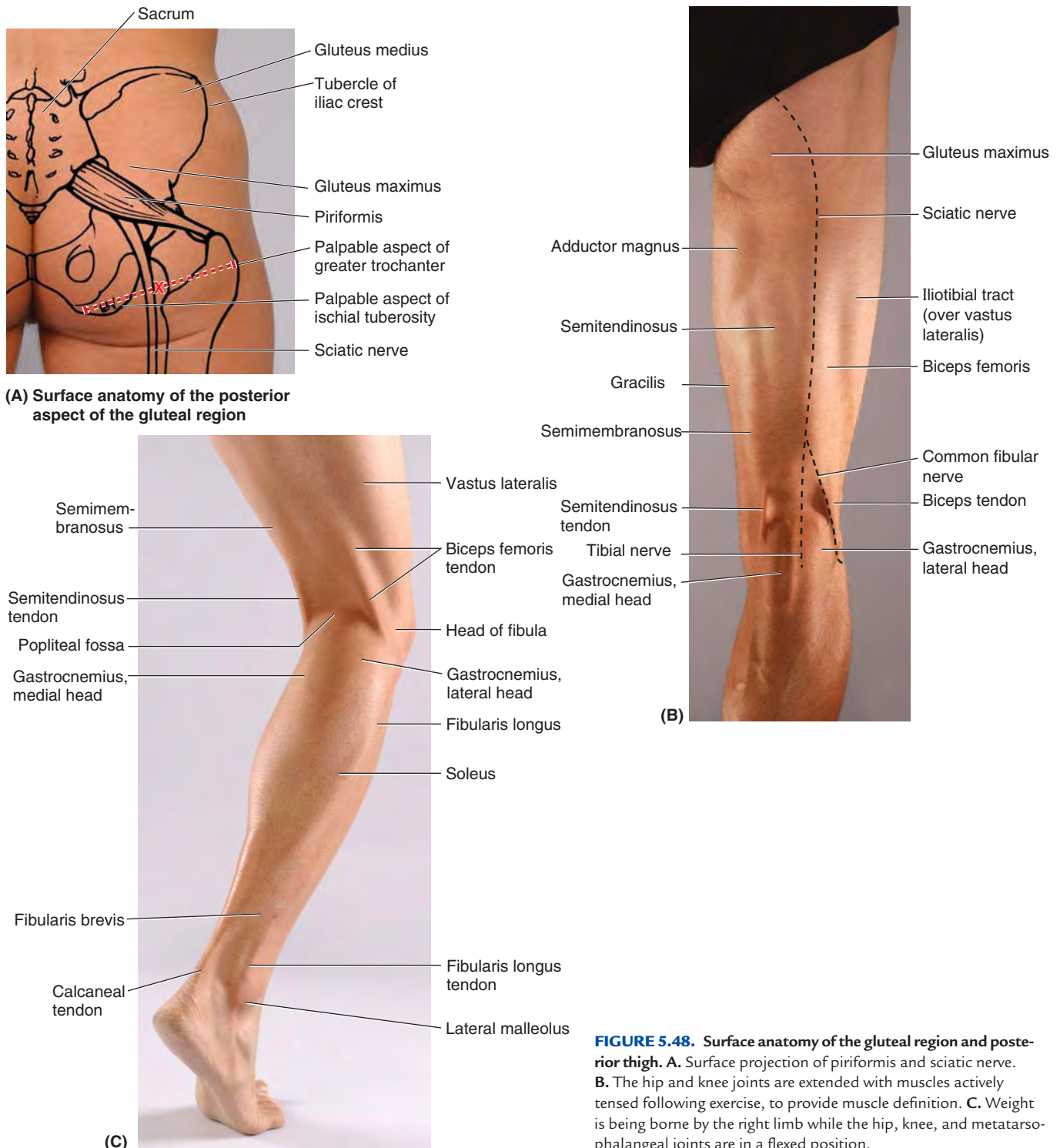


FIGURE 5.48. Surface anatomy of the gluteal region and posterior thigh. **A.** Surface projection of piriformis and sciatic nerve. **B.** The hip and knee joints are extended with muscles actively tensed following exercise, to provide muscle definition. **C.** Weight is being borne by the right limb while the hip, knee, and metatarsophalangeal joints are in a flexed position.

varies. The separation usually occurs between the middle and inferior third of the thigh. Less commonly, the division of the sciatic nerve occurs as it passes through the greater sciatic foramen. The sciatic nerve stretches when the thigh is flexed and the knee is extended, and it relaxes when the thigh is extended and the knee is flexed.

The *tibial nerve* bisects the popliteal fossa, and the *common fibular nerve* follows the biceps femoris that covers it.

The *hamstrings* can be felt as a group as they arise from the ischial tuberosity and extend along the lateral and posterior aspects of the thigh (Fig. 5.48B & C). The *iliotibial tract*, the fibrous band that reinforces the fascia lata laterally, can be observed on the lateral aspect of the thigh as it passes to the *lateral tibial condyle* (Fig. 5.47A & B).

While sitting down with your lower limb extended, raise your heel off the floor and feel the anterior border of the iliotibial tract passing a finger's breadth posterior to the lateral

border of the patella. Note that the iliotibial tract is prominent and taut when the heel is raised and indistinct when the heel is lowered.

The *tendons of the hamstrings* can be observed and palpated at the borders of the *popliteal fossa*, the depression between the tendons at the back of the flexed knee (Fig. 5.48B & C). The *biceps femoris tendon* is on the lateral side of the fossa. The most lateral tendon on the medial side when the knee is flexed against resistance is the *semimembranosus tendon*.

While sitting on a chair with your knee flexed, press your heel against the leg of the chair and feel your biceps femoris tendon laterally and trace it to the head of the fibula. Also feel the narrow and more prominent *semitendinosus tendon* medially, which pulls away from the semimembranosus tendon that attaches to the superomedial part of the tibia.

See the blue box “Hamstring Injuries” below.

GLUTEAL AND POSTERIOR THIGH REGIONS

Trochanteric Bursitis



Trochanteric bursitis, inflammation of the trochanteric bursa (see Fig. 5.37), may result from repetitive actions such as climbing stairs while carrying heavy objects, or running on a steeply elevated treadmill. These movements involve the gluteus maximus and move the superior tendinous fibers repeatedly back and forth over the bursae of the greater trochanter. Trochanteric bursitis causes deep diffuse pain in the lateral thigh region.

This type of **friction bursitis** is characterized by point tenderness over the great trochanter; however, the pain radiates along the iliotibial tract that extends from the iliac tubercle to the tibia (see Figs. 5.36 and 5.39C). This thickening of the fascia lata receives tendinous reinforcements from the tensor fasciae latae and gluteus maximus muscles. The pain from an inflamed trochanteric bursa, usually localized just posterior to the greater trochanter, is generally elicited by manually resisting abduction and lateral rotation of the thigh while the person is lying on the unaffected side.

Ischial Bursitis



Recurrent microtrauma resulting from repeated stress (e.g., as from cycling, rowing, or other activities involving repetitive hip extension while seated) may overwhelm the ability of the ischial bursa (see Fig. 5.37) to dissipate applied stress. The recurrent trauma results in inflammation of the bursa (**ischial bursitis**).

Ischial bursitis is a *friction bursitis* resulting from excessive friction between the ischial bursae and the ischial tuberosities. Localized pain occurs over the bursa, and the pain increases with movement of the gluteus maximus. Cal-

cification may occur in the bursa with chronic bursitis. Because the ischial tuberosities bear the body's weight during sitting, these pressure points may lead to *pressure sores* in debilitated people, particularly paraplegic persons with poor nursing care.

Hamstring Injuries



Hamstring strains (pulled and/or torn hamstrings) are common in individuals who run and/or kick hard (e.g., in running, jumping, and quick-start sports such as baseball, basketball, football, and soccer). The violent muscular exertion required to excel in these sports may avulse (tear) part of the proximal tendinous attachments of the hamstrings to the ischial tuberosity. Hamstring strains are twice as common as quadriceps strains.

Usually thigh strains are accompanied by contusion (bruise) and tearing of muscle fibers, resulting in rupture of the blood vessels supplying the muscles. The resultant *hematoma* is contained by the dense stocking-like fascia lata.

Tearing of hamstring fibers is often so painful when the athlete moves or stretches the leg that the person falls and writhes in pain. These injuries often result from inadequate warming up before practice or competition.

Avulsion of the ischial tuberosity at the proximal attachment of the biceps femoris and semitendinosus may result from forcible flexion of the hip with the knee extended (e.g., kicking a football). (See Fig. B5.1 and the blue box “Injuries of Hip Bone” on p. 526.)

Injury to Superior Gluteal Nerve



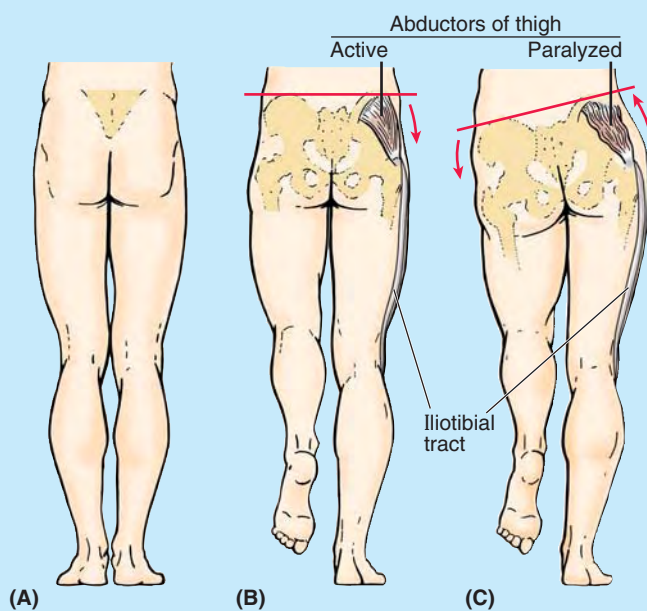
Injury to this nerve results in a characteristic motor loss, resulting in a disabling *gluteus medius limp*, to compensate for weakened abduction of the thigh by

the gluteus medius and minimus, and/or a *gluteal gait*, a compensatory list of the body to the weakened gluteal side. This compensation places the center of gravity over the supporting lower limb. Medial rotation of the thigh is also severely impaired. When a standing person is asked to lift one foot off the ground and stand on one foot, the gluteus medius and minimus normally contract as soon as the contralateral foot leaves the floor, preventing tipping of the pelvis to the unsupported side (Fig. B5.18A & B).

When a person who has suffered a lesion of the superior gluteal nerve is asked to stand on one leg, the pelvis on the unsupported side descends (Fig. B5.18B), indicating that the gluteus medius and minimus on the supported side are weak or non-functional. This sign is referred to clinically as a *positive Trendelenburg test*. Other causes of this sign include *fracture of the greater trochanter* (the distal attachment of gluteus medius) and *dislocation of the hip joint*.

When the pelvis descends on the unsupported side, the lower limb becomes, in effect, too long and does not clear the ground when the foot is brought forward in the swing phase of walking. To compensate, the individual leans away from the unsupported side, raising the pelvis to allow adequate room for the foot to clear the ground as it swings forward. This results in a characteristic “waddling” or *gluteal gait*.

Other ways to compensate is to lift the foot higher as it is brought forward, resulting in the so-called *steppage gait*, or to swing the foot outward (laterally), the so-called swing-out gait. These same gaits are adopted to compensate for the *footdrop* that results from common fibular nerve paralysis. (See these abnormal gaits illustrated in Fig. B5.20 of the blue box “Injury to Common Fibular Nerve and Footdrop,” p. 605.)



Posterior views

FIGURE B5.18.

Anesthetic Block of Sciatic Nerve



Sensation conveyed by the sciatic nerve can be blocked by the injection of an anesthetic agent a few centimeters inferior to the midpoint of the line joining the posterior superior iliac spine (PSIS) and the superior border of the greater trochanter. Paresthesia radiates to the foot because of anesthesia of the plantar nerves, which are terminal branches of the tibial nerve derived from the sciatic nerve.

Injury to Sciatic Nerve



A pain in the buttock may result from compression of the sciatic nerve by the piriformis muscle (*piriformis syndrome*). Individuals involved in sports that require excessive use of the gluteal muscles (e.g., ice skaters, cyclists, and rock climbers) and women are more likely to develop this syndrome. In approximately 50% of cases, the histories indicate trauma to the buttock associated with hypertrophy and *spasm of the piriformis*. In the approximately 12% of people in whom the common fibular division of the sciatic nerve passes through the piriformis (Fig. 5.43B), this muscle may compress the nerve.

Complete section of the sciatic nerve is uncommon. When this injury occurs, the leg is useless because extension of the hip is impaired, as is flexion of the leg. All ankle and foot movements are also lost.

Incomplete section of the sciatic nerve (e.g., from stab wounds) may also involve the inferior gluteal and/or the posterior femoral cutaneous nerves. Recovery from a lesion of the sciatic nerve is slow and usually incomplete.

With respect to the sciatic nerve, the buttock has a *side of safety* (its lateral side) and a *side of danger* (its medial side). Wounds or surgery on the medial side of the buttock may injure the sciatic nerve and its branches to the hamstrings (semitendinosus, semimembranosus, and biceps femoris) on the posterior aspect of the thigh. Paralysis of these muscles results in impairment of thigh extension and leg flexion.

Intragluteal Injections



The gluteal region is a common site for intramuscular (IM) injection of drugs. **Gluteal IM injections** penetrate the skin, fascia, and muscles. The gluteal region is a common injection site because the muscles are thick and large; consequently, they provide a substantial volume for absorption of injected substances by intramuscular veins. It is important to be aware of the extent of the gluteal region and the safe region for giving injections. Some people restrict the area of the buttock to the most prominent part. This misunderstanding may be dangerous because the sciatic nerve lies deep to this area (Fig. B5.19A).

Injections into the buttock are safe only in the superolateral quadrant of the buttock or superior to a line extending from the PSIS to the superior border of the greater trochanter (approximating the superior border of the gluteus maximus).

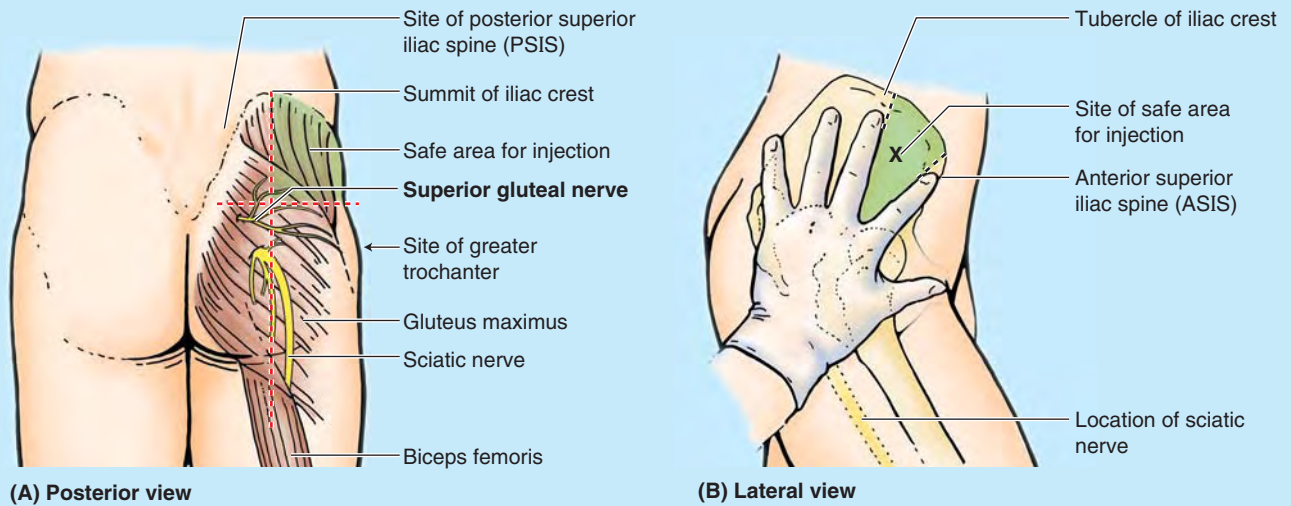


FIGURE B5.19.

IM injections can also be given safely into the anterolateral part of the thigh, where the needle enters the tensor fasciae latae (see Fig. 5.47A) as it extends distally from the iliac crest and ASIS. The index finger is placed on the ASIS, and the fingers are spread posteriorly along the iliac crest until the tubercle of the crest is felt by the middle finger (Fig. B5.19B).

An IM injection can be made safely in the triangular area between the fingers (just anterior to the proximal joint of the middle finger) because it is superior to the sciatic nerve. Complications of improper technique include nerve injury, hematoma, and abscess formation.

The Bottom Line

GLUTEAL AND POSTERIOR THIGH REGIONS

Gluteal region: The femur is bent at the angle of inclination, creating a relatively transverse lever formed by the proximal femur. ♦ This enables superior placement of the abductors of the thigh and provides mechanical advantage for the deeper medial and lateral rotators of the thigh, critical for bipedal locomotion. ♦ Despite their designations, the abductors/medial rotators (the superficial gluteal muscles) are most active during the stance phase when they simultaneously elevate and advance the contralateral unsupported side of the pelvis during ambulation. ♦ The lateral rotators (deep gluteal muscles) of the unsupported side rotate the free limb during the swing phase so that the foot remains parallel to the line of advancement.

Posterior femoral region: Although they have only about two thirds the strength of the gluteus maximus, the hamstrings are the main extensors of the hip used in normal walking. ♦ The hamstrings are two-joint muscles, and their concentric contraction produces either extension of the hip or flexion of the knee. ♦ However, in walking, the hamstrings are most active in eccentrically contracting to decelerate hip flexion and knee extension during terminal swing. ♦ The hamstrings also rotate the flexed knee. ♦ If resistance to hip extension is increased or more vigorous extension is required, the gluteus maximus is called into action.

Neurovascular structures of gluteal and posterior femoral regions: Because it overlies the major doorway

(greater sciatic foramen) by which derivatives of the sacral plexus exit the bony pelvis, the gluteal region includes a disproportionate number of nerves of all sizes, both motor and sensory. ♦ Fortunately, most nerves are in the inferomedial quadrant; thus properly administered IM injections avoid these structures. ♦ Because the sciatic nerve includes fibers from the L4–S3 spinal nerves, it is affected by the most common nerve compression syndromes (e.g., radiculopathies [disorders] of the L4 and L5 spinal nerve roots; see Chapter 4). ♦ Even though occurring outside the lower limb per se, these syndromes result in sciatica—pain that radiates down the lower limb along the course of the sciatic nerve and its terminal branches. ♦ Pain experienced in the lower limb may not necessarily arise from a problem in the limb! ♦ Arteries and veins serving the gluteal region and the proximal part of the posterior compartment of the thigh are branches and tributaries of the internal iliac artery and vein that pass to and from the region via the greater sciatic foramen. ♦ All but the superior gluteal vessels exit the greater sciatic foramen inferior to the piriformis muscle. ♦ Although the pudendal vessels follow the same route, they traverse the gluteal region only briefly en route to and from the perineum via the lesser sciatic foramen. ♦ The posterior compartment of the thigh does not have a major artery coursing through it with primary responsibility for the compartment. Rather, branches from several arteries in other compartments supply it.

POPLITEAL FOSSA AND LEG

Popliteal Region

The **popliteal fossa** is a mostly fat-filled compartment of the lower limb. Superficially, when the knee is flexed, the popliteal fossa is evident as a diamond-shaped depression posterior to the knee joint (Fig. 5.49). The size of the gap between the hamstring and gastrocnemius muscles is misleading, however, in terms of the actual size and extent of the fossa. Deeply, it is much larger than the superficial depression indicates because the heads of the gastrocnemius forming the inferior boundary superficially form a roof over the inferior half of the deep part. When the knee is extended, the fat within the fossa protrudes through the gap between muscles, producing a rounded elevation flanked by shallow longitudinal grooves overlying the hamstring tendons. In dissection, if the heads of the gastrocnemius are separated and retracted (Fig. 5.50), a much larger space is revealed.

Superficially, the popliteal fossa is bounded:

- Superolaterally by the biceps femoris (superolateral border).
- Superomedially by the semimembranosus, lateral to which is the semitendinosus (superomedial border).
- Inferolaterally and inferomedially by the lateral and medial heads of the gastrocnemius, respectively (inferolateral and inferomedial borders).
- Posteriorly by skin and *popliteal fascia* (roof).

Deeply, the superior boundaries are formed by the diverging medial and lateral supracondylar lines of the femur. The inferior boundary is formed by the soleal line of the tibia (Fig. 5.4B). These boundaries surround a relatively large diamond-shaped floor (anterior wall), formed by the **popliteal surface of the femur** superiorly, the posterior aspect of the joint capsule of the knee joint centrally, and the **investing popliteus fascia** covering the popliteus muscle inferiorly (Fig. 5.51).

The *contents of the popliteal fossa* (Figs. 5.49B, 5.50, and 5.51) include the:

- Termination of the small saphenous vein.
- Popliteal arteries and veins and their branches and tributaries.

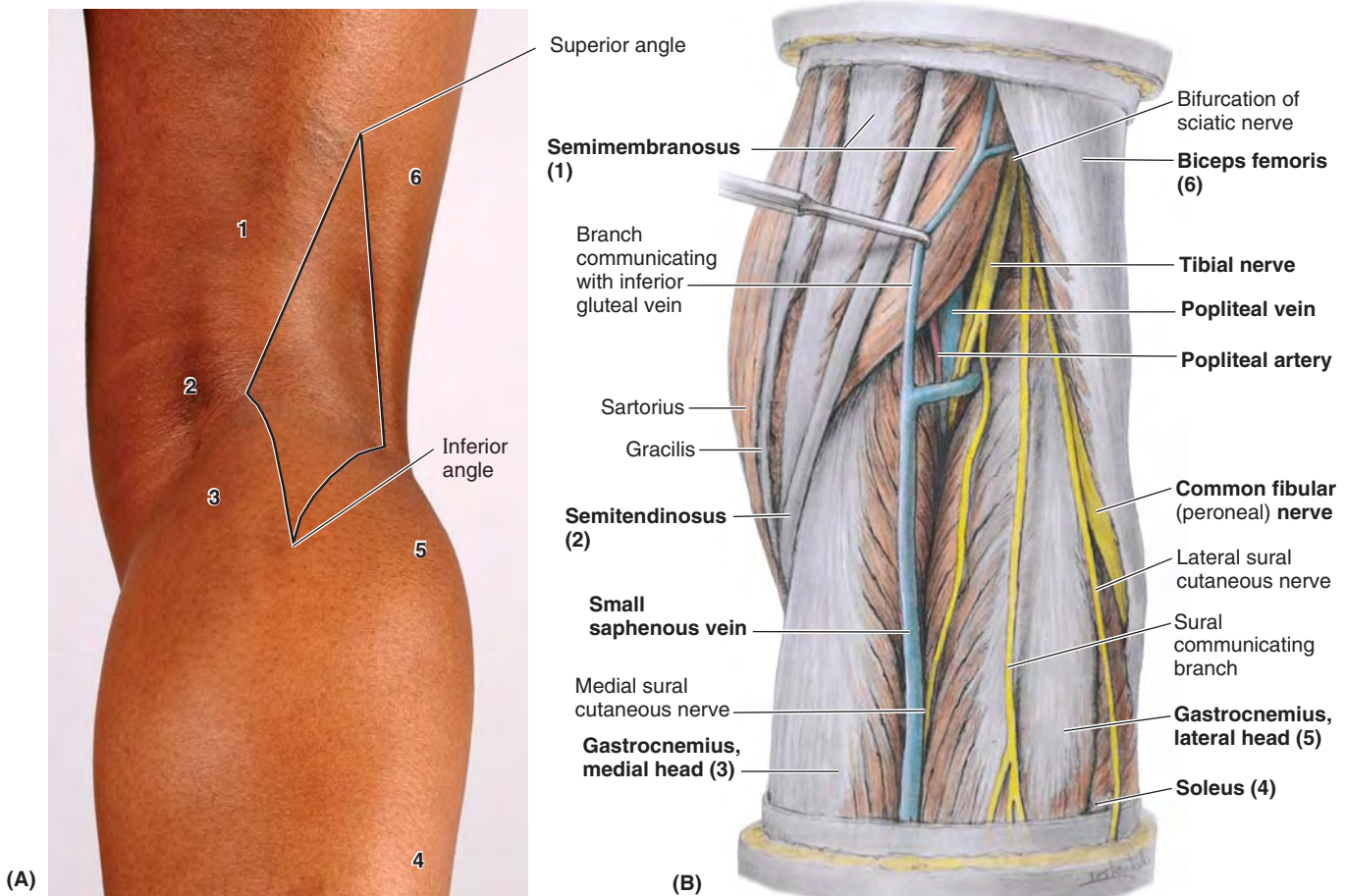
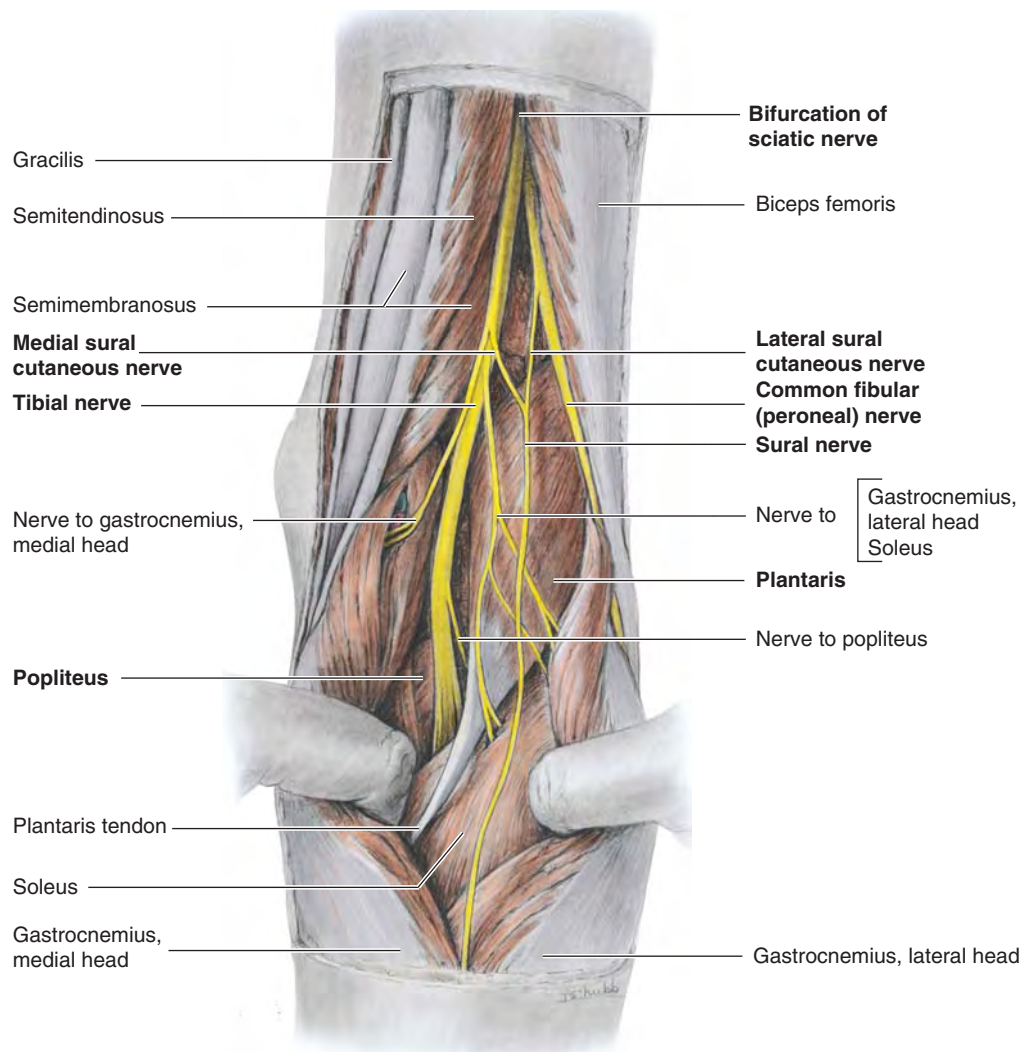


FIGURE 5.49. Superficial popliteal region. **A.** Numbers on the surface anatomy refer to structures identified in **B**. The diamond-shaped gap in the roof of the popliteal fossa, formed by the overlying muscles, is outlined. **B.** Superficial dissection of the popliteal region showing the muscles that cover most of the popliteal fossa.



Posterior view

FIGURE 5.50. Exposure of popliteal fossa and nerves in it. The two heads of the gastrocnemius muscle have been separated and are being retracted. The sciatic nerve separates into its components at the apex of the popliteal fossa (or higher; Fig. 5.43B). The common fibular nerve courses along the medial border of the biceps femoris. All the motor branches arising from the tibial nerve, except one, arise from the lateral side; consequently, in surgery it is safer to dissect on the medial side. The level at which the medial and lateral sural nerves merge to form the sural nerve—occurring high here—is quite variable; it may even occur at the level of the ankle.

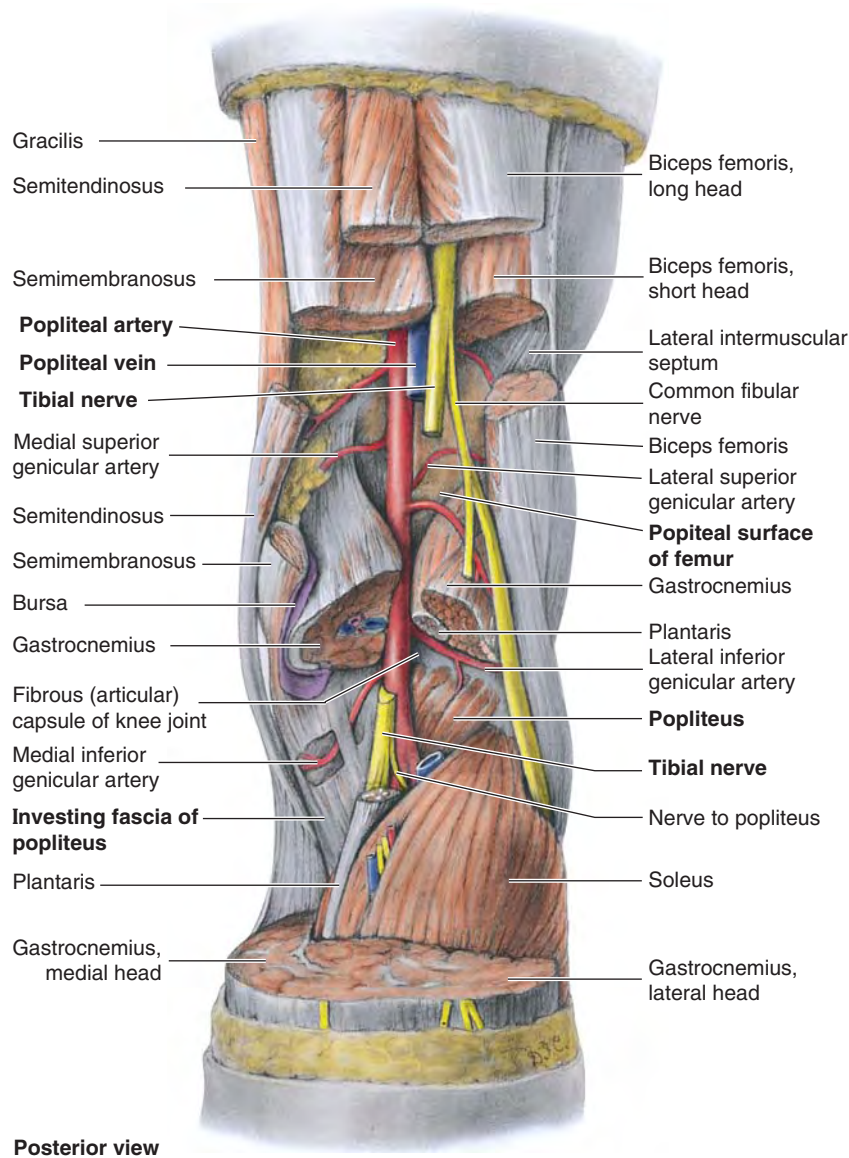
- Tibial and common fibular nerves.
- Posterior cutaneous nerve of thigh (see Fig. 5.42B).
- Popliteal lymph nodes and lymphatic vessels (see Fig. 5.15B).

FASCIA OF POPLITEAL FOSSA

The *subcutaneous tissue* (superficial fascia) overlying the popliteal fossa (see Figs. 5.13B and 5.14B) contains the small saphenous vein (unless it has penetrated the deep fascia of the leg at a more inferior level) and three cutaneous nerves: the terminal branch(es) of the *posterior cutaneous nerve of the thigh* and the *medial* and *lateral sural cutaneous nerves*.

The **popliteal fascia** is a strong sheet of deep fascia, continuous superiorly with the *fascia lata* and inferiorly with the *deep fascia of the leg*. The popliteal fascia forms a protective covering for neurovascular structures passing from the thigh through the popliteal fossa to the leg, and a relatively loose but functional retaining “retinaculum” (retaining band) for the hamstring tendons. Often the fascia is pierced by the small saphenous vein.

When the leg extends, the fat within the fossa is relatively compressed as the popliteal fascia becomes taut, and the semimembranosus muscle moves laterally, providing further protection to the contents of the fossa.



Posterior view

FIGURE 5.51. Deep dissection of popliteal fossa. The popliteal artery runs on the floor of the fossa, formed by the popliteal surface of the femur, the joint capsule of the knee, and the popliteus fascia.

The contents, most important the popliteal artery and lymph nodes, are most easily palpated with the knee semi-flexed. Because of the deep fascial roof and osseofibrous floor, the fossa is a relatively confined space. Many disorders produce swelling of the fossa, making knee extension painful. (See the blue boxes “Popliteal Abscess and Tumor” and “Popliteal Aneurysm and Hemorrhage” on p. 604, and “Popliteal Cysts” on p. 665.)

NEUROVASCULAR STRUCTURES AND RELATIONSHIPS IN POPLITEAL FOSSA

All important neurovascular structures that pass from the thigh to the leg do so by traversing the popliteal fossa. Progressing

from superficial to deep (posterior to anterior) within the fossa, as in dissection, the nerves are encountered first, then the veins. The arteries lie deepest, directly on the surface of the femur, joint capsule, and *investing fascia of the popliteus* forming the floor of the fossa (Fig. 5.52).

Nerves in Popliteal Fossa. The *sciatic nerve* usually ends at the superior angle of the popliteal fossa by dividing into the tibial and common fibular nerves (Figs. 5.49B, 5.50, and 5.51).

The **tibial nerve** is the medial, larger terminal branch of the sciatic nerve derived from anterior (preaxial) divisions of the anterior rami of the L4–S3 spinal nerves. *The tibial nerve is the most superficial of the three main central components of the popliteal fossa* (i.e., nerve, vein, and artery); however, it is

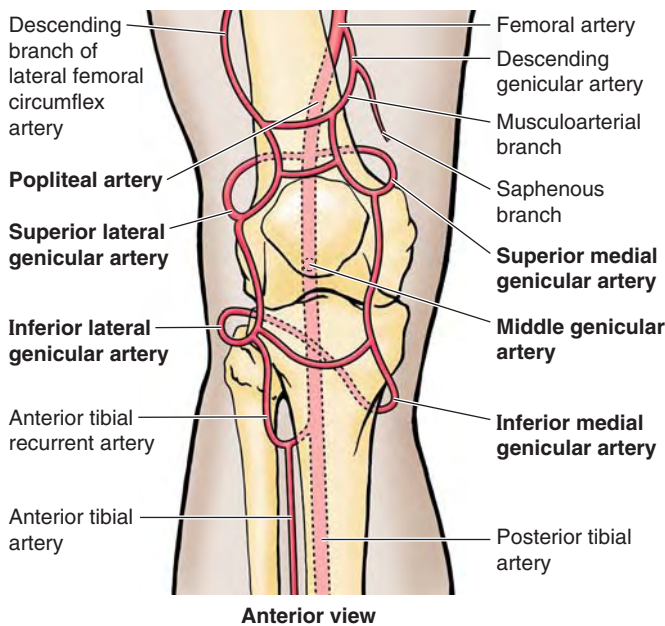


FIGURE 5.52. Genicular anastomosis. The many arteries making up the periarticular anastomosis around the knee provide an important collateral circulation for bypassing the popliteal artery when the knee joint has been maintained too long in a fully flexed position or when the vessels are narrowed or occluded.

still in a deep and protected position. The tibial nerve bisects the fossa as it passes from its superior to its inferior angle.

While in the fossa, the tibial nerve gives branches to the soleus, gastrocnemius, plantaris, and popliteus muscles. The **medial sural cutaneous nerve** is also derived from the tibial nerve in the popliteal fossa. It is joined by the **sural communicating branch of the common fibular nerve** at a highly variable level to form the *sural nerve*. This nerve supplies the lateral side of the leg and ankle.

The **common fibular (peroneal) nerve** is the lateral, smaller terminal branch of the sciatic nerve derived from posterior (postaxial) divisions of the anterior rami of the L4–S2 spinal nerves. The common fibular nerve begins at the superior angle of the popliteal fossa and follows closely the medial border of the biceps femoris and its tendon along the superolateral boundary of the fossa. The nerve leaves the fossa by passing superficial to the lateral head of the gastrocnemius and then passes over the posterior aspect of the head of the fibula. The *common fibular nerve winds around the neck of the fibula* and divides into its terminal branches.

The most inferior branches of the *posterior cutaneous nerve of the thigh* supply the skin that overlies the popliteal fossa (see Fig 5.42B). The nerve traverses most of the length of the posterior compartment of the thigh deep to the fascia lata; only its terminal branches enter the subcutaneous tissue as cutaneous nerves.

Blood Vessels in Popliteal Fossa. The **popliteal artery**, the continuation of the femoral artery (Figs. 5.51 and 5.52), begins when the latter passes through the adductor hiatus. The popliteal artery passes inferolaterally through the

fossa and ends at the inferior border of the popliteus by dividing into the anterior and posterior tibial arteries. The deepest (most anterior) structure in the fossa, the popliteal artery, runs in close proximity to the joint capsule of the knee as it spans the intercondylar fossa.

Five genicular branches of the popliteal artery supply the capsule and ligaments of the knee joint. The genicular arteries are the **superior lateral, superior medial, middle, inferior lateral, and inferior medial genicular arteries** (Fig. 5.52). They participate in the formation of the periarticular **genicular anastomosis**, a network of vessels surrounding the knee that provides collateral circulation capable of maintaining blood supply to the leg during full knee flexion, which may kink the popliteal artery. Other contributors to this important genicular anastomosis are the:

- **Descending genicular artery**, a branch of the femoral artery, superomedially.
- **Descending branch of the lateral femoral circumflex artery**, superolaterally.
- **Anterior tibial recurrent artery**, a branch of the anterior tibial artery, inferolaterally.

Muscular branches of the popliteal artery supply the hamstring, gastrocnemius, soleus, and plantaris muscles. The superior muscular branches of the popliteal artery have clinically important anastomoses with the terminal part of the deep femoral and gluteal arteries.

The **popliteal vein** begins at the distal border of the popliteus as a continuation of the *posterior tibial vein* (Fig. 5.51). Throughout its course, the vein lies close to the popliteal artery, lying superficial to it and in the same fibrous sheath. The popliteal vein is initially posteromedial to the artery and lateral to the tibial nerve. More superiorly, the popliteal vein lies posterior to the artery, between this vessel and the overlying tibial nerve. Superiorly, the popliteal vein, which has several valves, becomes the *femoral vein* as it traverses the adductor hiatus. The *small saphenous vein* passes from the posterior aspect of the lateral malleolus to the popliteal fossa, where it pierces the deep popliteal fascia and enters the popliteal vein.

Lymph Nodes in Popliteal Fossa. The **superficial popliteal lymph nodes** are usually small and lie in the subcutaneous tissue. A lymph node lies at the termination of the small saphenous vein and receives lymph from the lymphatic vessels that accompany this vein (see Fig. 5.15B). The **deep popliteal lymph nodes** surround the vessels and receive lymph from the joint capsule of the knee and the lymphatic vessels that accompany the deep veins of the leg. The lymphatic vessels from the popliteal lymph nodes follow the femoral vessels to the *deep inguinal lymph nodes*.

Anterior Compartment of Leg

ORGANIZATION OF LEG

The bones of the leg (*tibia* and *fibula*) that connect the knee and ankle, and the three fascial compartments (*anterior, lateral, and posterior compartments of the leg*), formed by the

anterior and posterior intermuscular septa, the interosseous membrane, and the two leg bones to which they attach, were discussed at the beginning of this chapter and are illustrated in cross-section in Figure 5.53. The muscles of each compartment share common functions and innervations.

The **anterior compartment of the leg**, or *dorsiflexor (extensor) compartment*, is located anterior to the *interosseous membrane*, between the lateral surface of the shaft of the tibia and the medial surface of the shaft of the fibula, and anterior to the intermuscular septum that connects them.

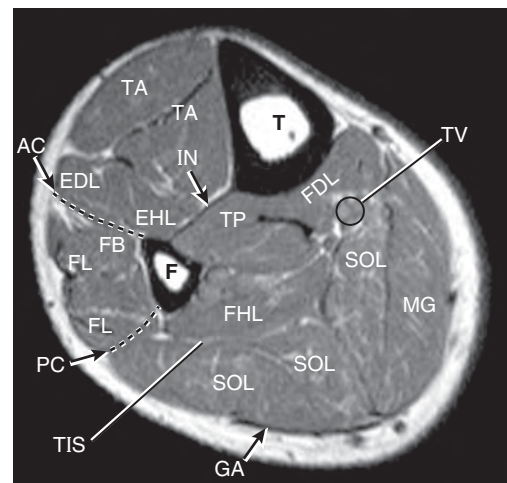
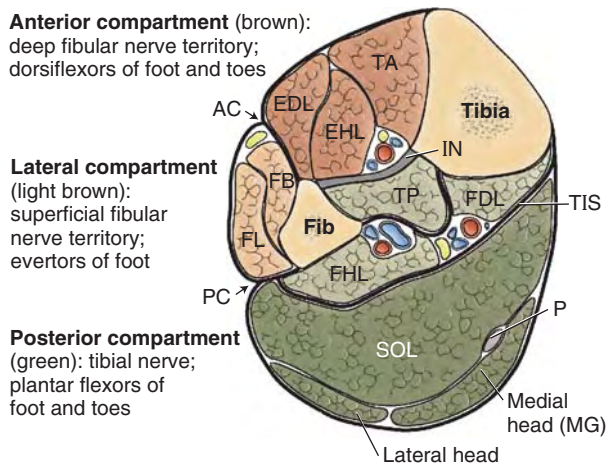
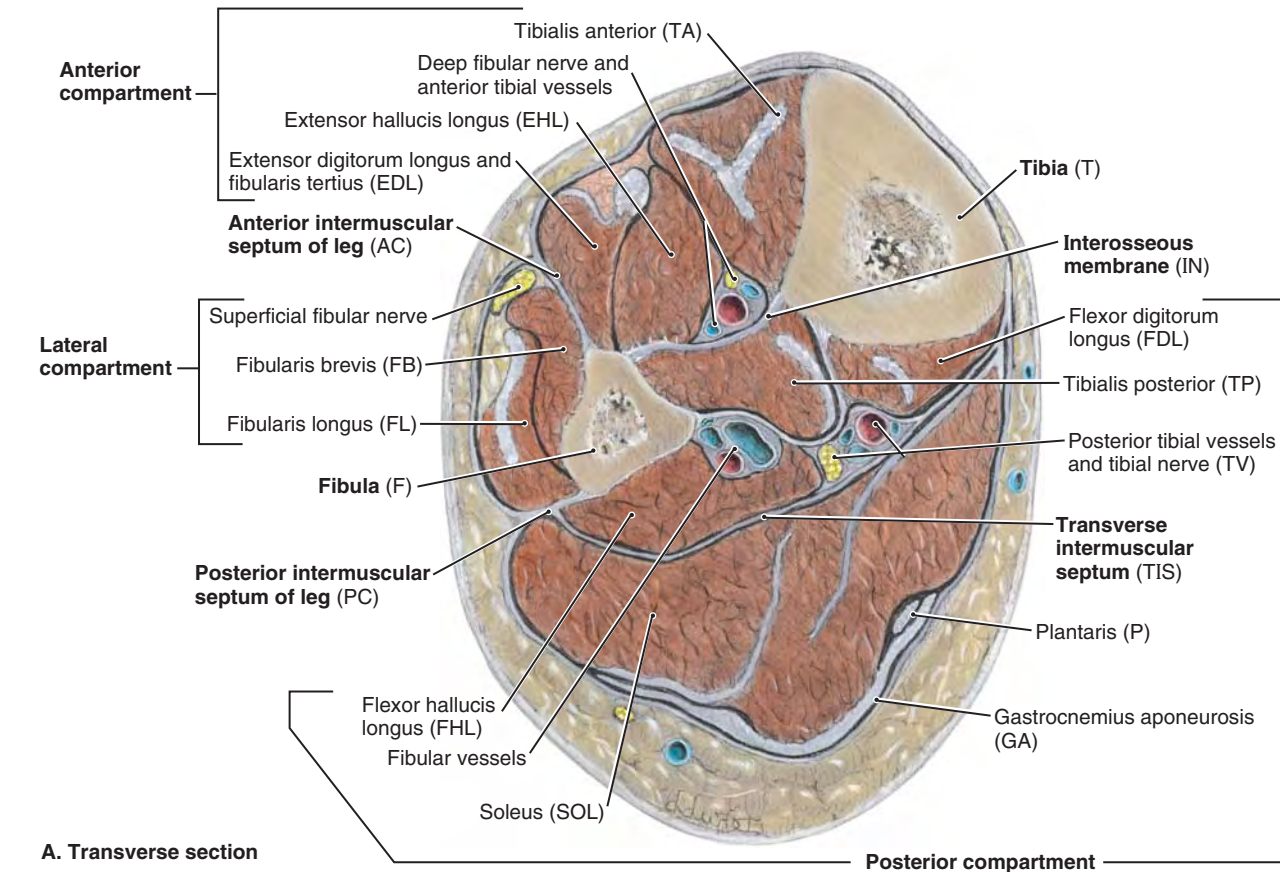


FIGURE 5.53. Compartments of leg at midcalf level in transverse anatomical section. **A.** The anterior (dorsiflexor or extensor) compartment contains four muscles (the fibularis tertius lies inferior to the level of this section). The lateral (fibular) compartment contains two evtor muscles. The posterior (plantarflexor or flexor) compartment, containing seven muscles, is subdivided by an intracompartmental transverse intermuscular septum into a superficial group of three (two of which are commonly tendinous/aponeurotic at this level) and a deep group of four. The popliteus (part of the deep group) lies superior to the level of this section. **B.** Overview of compartments of leg. **C.** MRI of the leg. Abbreviations are defined in the labels for parts **A** and **B**.

The anterior compartment is bounded anteriorly by the *deep fascia of the leg* and skin. The deep fascia overlying the anterior compartment is dense superiorly, providing part of the proximal attachment of the muscle immediately deep to it. With unyielding structures on three sides (the two bones and the interosseous membrane) and a dense fascia on the remaining side, the relatively small anterior compartment is especially confined and therefore most susceptible to *compartment syndromes* (see the blue box “Containment and Spread of Compartmental Infections in the Leg,” p. 605).

Inferiorly, two band-like thickenings of the fascia form **retinacula** that bind the tendons of the anterior compartment muscles before and after they cross the ankle joint, preventing them from bowstringing anteriorly during dorsiflexion of the joint (Fig. 5.54):

1. The **superior extensor retinaculum** is a strong, broad band of deep fascia, passing from the fibula to the tibia, proximal to the malleoli.
2. The **inferior extensor retinaculum**, a Y-shaped band of deep fascia, attaches laterally to the anterosuperior surface of the calcaneus. It forms a strong loop around the tendons of the fibularis tertius and the extensor digitorum longus muscles.

MUSCLES OF ANTERIOR COMPARTMENT OF LEG

The four muscles in the anterior compartment of the leg are the *tibialis anterior*, *extensor digitorum longus*, *extensor hallucis longus*, and *fibularis tertius* (Figs. 5.53A & B and 5.55; Table 5.10). These muscles pass and insert anterior to the transversely oriented axis of the ankle (talocrural) joint and, therefore, are **dorsiflexors of the ankle joint**, elevating the forefoot and depressing the heel. The long extensors also pass along and attach to the dorsal aspect of the digits and are thus extensors (elevators) of the toes.

Although it is a relatively weak and short movement—only about a quarter the strength of plantarflexion (Soderberg, 1986), with a range of about 20° from neutral—dorsiflexion is actively used in the swing phase of walking, when concentric contraction keeps the forefoot elevated to clear the ground as the free limb swings forward (see Fig. 5.20F & G and Table 5.2). Immediately after, in the stance phase, eccentric contraction of the *tibialis anterior* controls the lowering of the forefoot to the floor following heel strike (see Fig. 5.20A and Table 5.2). The latter is important to a smooth gait and is important to deceleration (braking) relative to running and walking downhill. During standing, the dorsiflexors reflexively pull the leg (and thus the center of gravity) anteriorly on the fixed foot when the body starts to lean (the center of gravity begins to shift too far) posteriorly. When descending a slope, especially if the surface is loose (sand, gravel, or snow), dorsiflexion is used to “dig in” one’s heels.

Tibialis Anterior. The **tibialis anterior (TA)**, the most medial and superficial dorsiflexor, is a slender muscle that lies against the lateral surface of the tibia (Figs. 5.53 and 5.56).

The long tendon of TA begins halfway down the leg and descends along the anterior surface of the tibia. Its tendon passes within its own synovial sheath deep to the superior and inferior extensor retinacula (Fig. 5.54) to its attachment on the medial side of the foot. In so doing, its tendon is located farthest from the axis of the ankle joint, giving it the most mechanical advantage and making it the strongest dorsiflexor. Although antagonists at the ankle joint, TA and the *tibialis posterior* (in the posterior compartment) both cross the subtalar and transverse tarsal joints to attach to the medial border of the foot. Thus they act synergistically to invert the foot.

To test the TA, the person is asked to stand on the heels or dorsiflex the foot against resistance; if normal, its tendon can be seen and palpated.

Extensor Digitorum Longus. The **extensor digitorum longus (EDL)** is the most lateral of the anterior leg muscles (Figs. 5.53–5.56). A small part of the proximal attachment of the muscle is to the lateral tibial condyle; however, most of it attaches to the medial surface of the fibula and the superior part of the anterior surface of the interosseous membrane (Fig. 5.55A; Table 5.10).

The muscle becomes tendinous superior to the ankle, forming four tendons that attach to the phalanges of the lateral four toes. A common synovial sheath surrounds the four tendons of the EDL (plus that of the *fibularis tertius*) as they diverge on the dorsum of the foot and pass to their distal attachments (Fig. 5.54B).

Each tendon of EDL forms a membranous *extensor expansion* (dorsal aponeurosis) over the dorsum of the proximal phalanx of the toe, which divides into two lateral bands and one central band (Fig. 5.54A). The central band inserts into the base of the middle phalanx, and the lateral slips converge to insert into the base of the distal phalanx.

To test the EDL, the lateral four toes are dorsiflexed against resistance; if acting normally, the tendons can be seen and palpated.

Fibularis Tertius. The **fibularis tertius (FT)** is a separated part of EDL, which shares its synovial sheath (Figs. 5.54 and 5.56). Proximally, the attachments and fleshy parts of the EDL and FT are continuous; however, distally the FT tendon is separate and attaches to the 5th metatarsal, not to a phalanx (Fig. 5.55F; Table 5.10). Although FT contributes (weakly) to dorsiflexion, it also acts at the subtalar and transverse tarsal joints, contributing to eversion (pronation) of the foot. It may play a special proprioceptive role in sensing sudden inversion and then contracting reflexively to protect the anterior tibiofibular ligament, the most commonly sprained ligament of the body. FT is not always present.

Extensor Hallucis Longus. The **extensor hallucis longus (EHL)** is a thin muscle that lies deeply between the TA and EDL at its superior attachment to the middle half of the fibula and interosseous membrane (Fig. 5.55E; Table 5.10). EHL rises to the surface in the distal third of the leg, passing deep to the extensor retinacula (Figs. 5.54 and 5.56). It courses distally along the crest of the dorsum of the foot to the great toe.

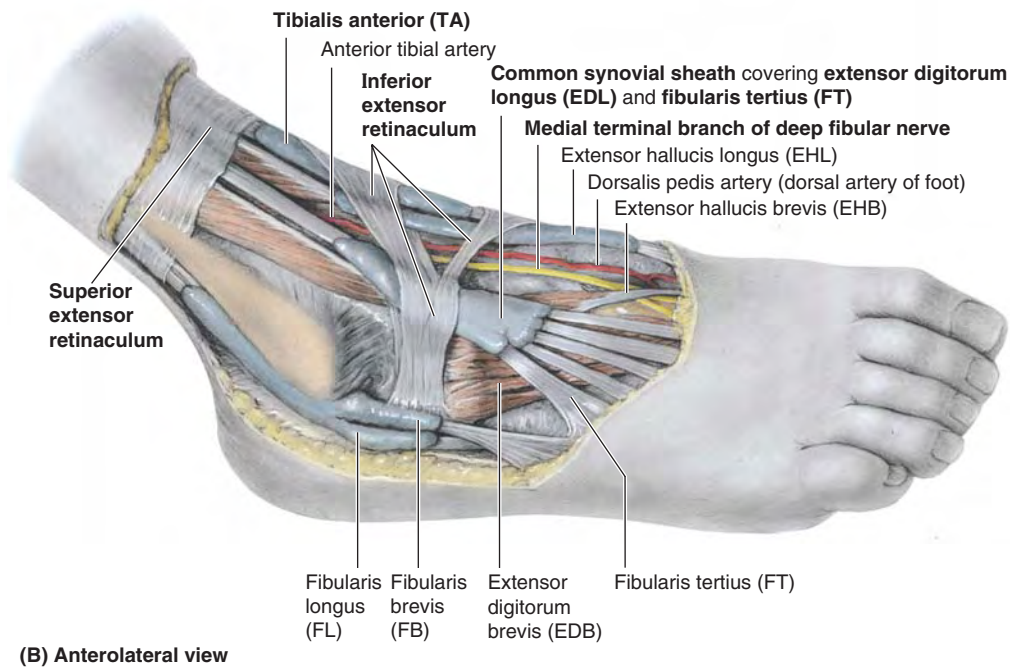
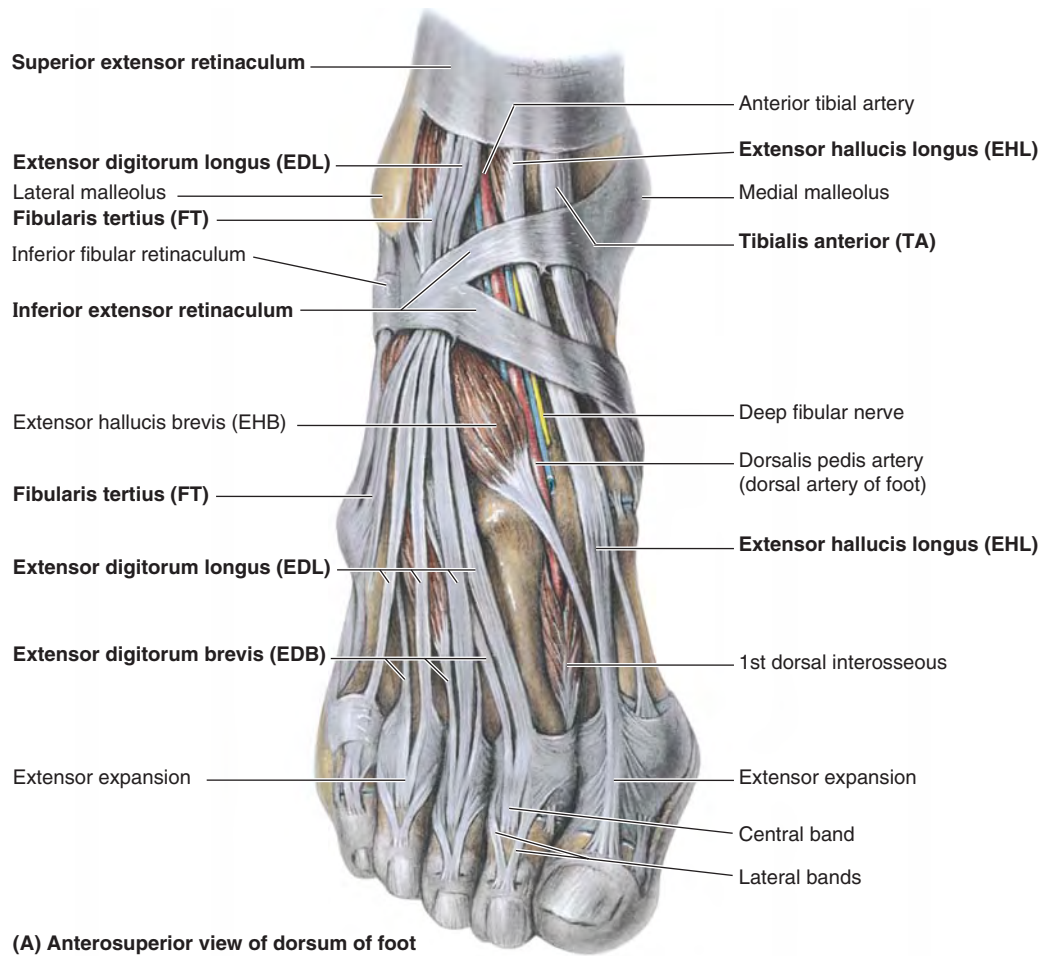


FIGURE 5.54. Dissections of foot. These dissections demonstrate the continuation of the anterior and lateral leg muscles into the foot. The thinner portions of the deep fascia of the leg have been removed, leaving the thicker portions that make up the extensor and fibular retinacula, which retain the tendons as they cross the ankle. **A.** The vessels and nerves are cut short. At the ankle, the vessels and the deep fibular nerve lie midway between the malleoli and between the tendons of the long dorsiflexors of the toes. **B.** Synovial sheaths surround the tendons as they pass beneath the retinacula of the ankle.

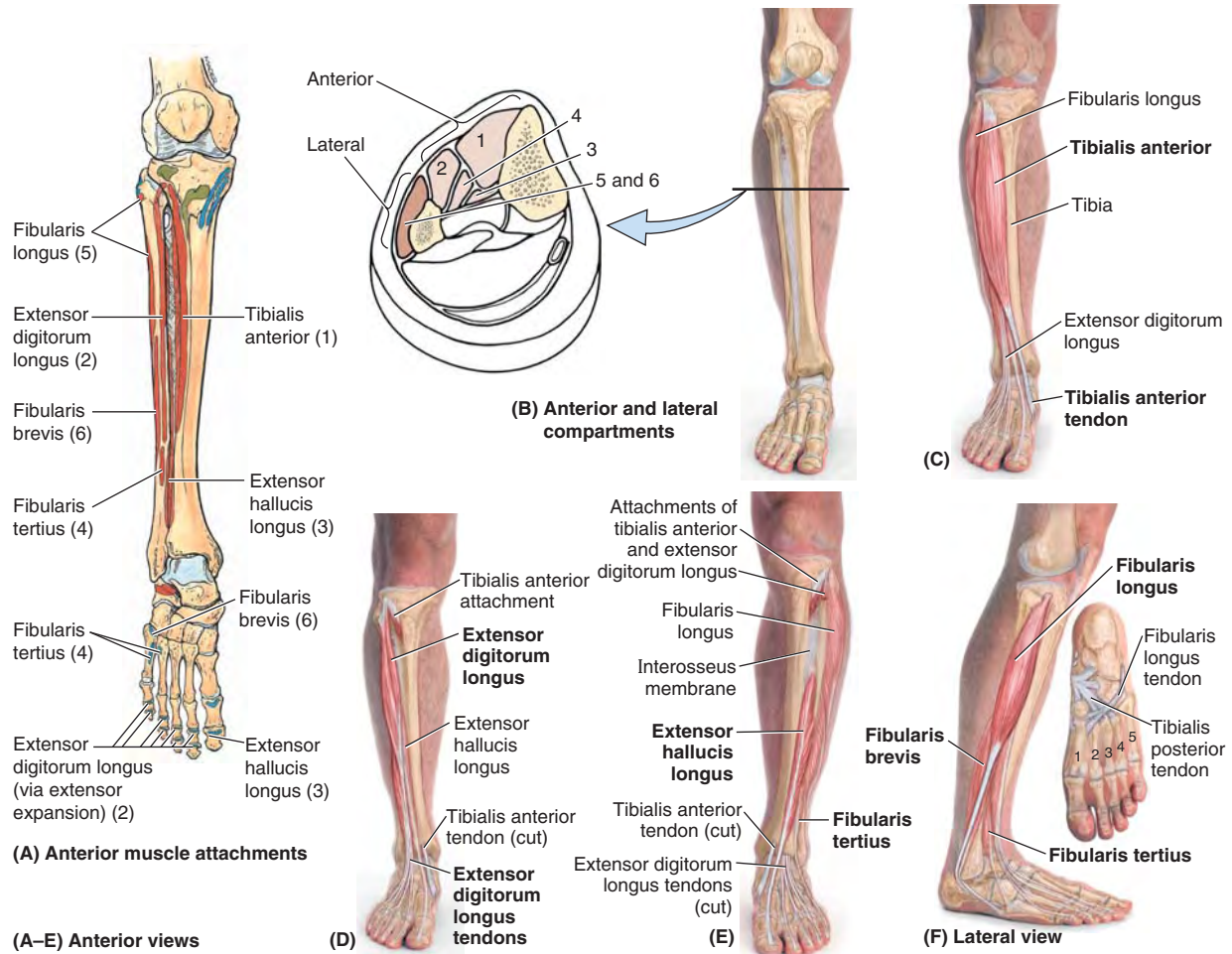


FIGURE 5.55. Muscles of anterior and lateral compartments of leg.

TABLE 5.10. MUSCLES OF ANTERIOR AND LATERAL COMPARTMENTS OF LEG

| Muscle ^a | Proximal Attachment | Distal Attachment | Innervation ^b | Main Action |
|--|--|---|--|---|
| Anterior compartment Tibialis anterior (1) | Lateral condyle and superior half of lateral surface of tibia and interosseous membrane | Medial and inferior surfaces of medial cuneiform and base of 1st metatarsal | Deep fibular nerve (L4, L5) | Dorsiflexes ankle and inverts foot |
| Extensor digitorum longus (2) | Lateral condyle of tibia and superior three quarters of medial surface of fibula and interosseous membrane | Middle and distal phalanges of lateral four digits | | Extends lateral four digits and dorsiflexes ankle |
| Extensor hallucis longus (3) | Middle part of anterior surface of fibula and interosseous membrane | Dorsal aspect of base of distal phalanx of great toe (hallux) | | Extends great toe and dorsiflexes ankle |
| Fibularis tertius (4) | Inferior third of anterior surface of fibula and interosseous membrane | Dorsum of base of 5th metatarsal | | Dorsiflexes ankle and aids in eversion of foot |
| Lateral compartment Fibularis longus (5) | Head and superior two thirds of lateral surface of fibula | Base of 1st metatarsal and medial cuneiform | Superficial fibular nerve (L5, S1, S2) | Everts foot and weakly plantarflexes ankle |
| Fibularis brevis (6) | Inferior two thirds of lateral surface of fibula | Dorsal surface of tuberosity on lateral side of base of 5th metatarsal | | |

^a Numbers refer to Figure 5.55A & B.

^b The spinal cord segmental innervation is indicated (e.g., "L4, L5" means that the nerves supplying the tibialis anterior are derived from the fourth and fifth lumbar segments of the spinal cord). Numbers in boldface (L4) indicate the main segmental innervation. Damage to one or more of the listed spinal cord segments or to the motor nerve roots arising from them results in paralysis of the muscles concerned.

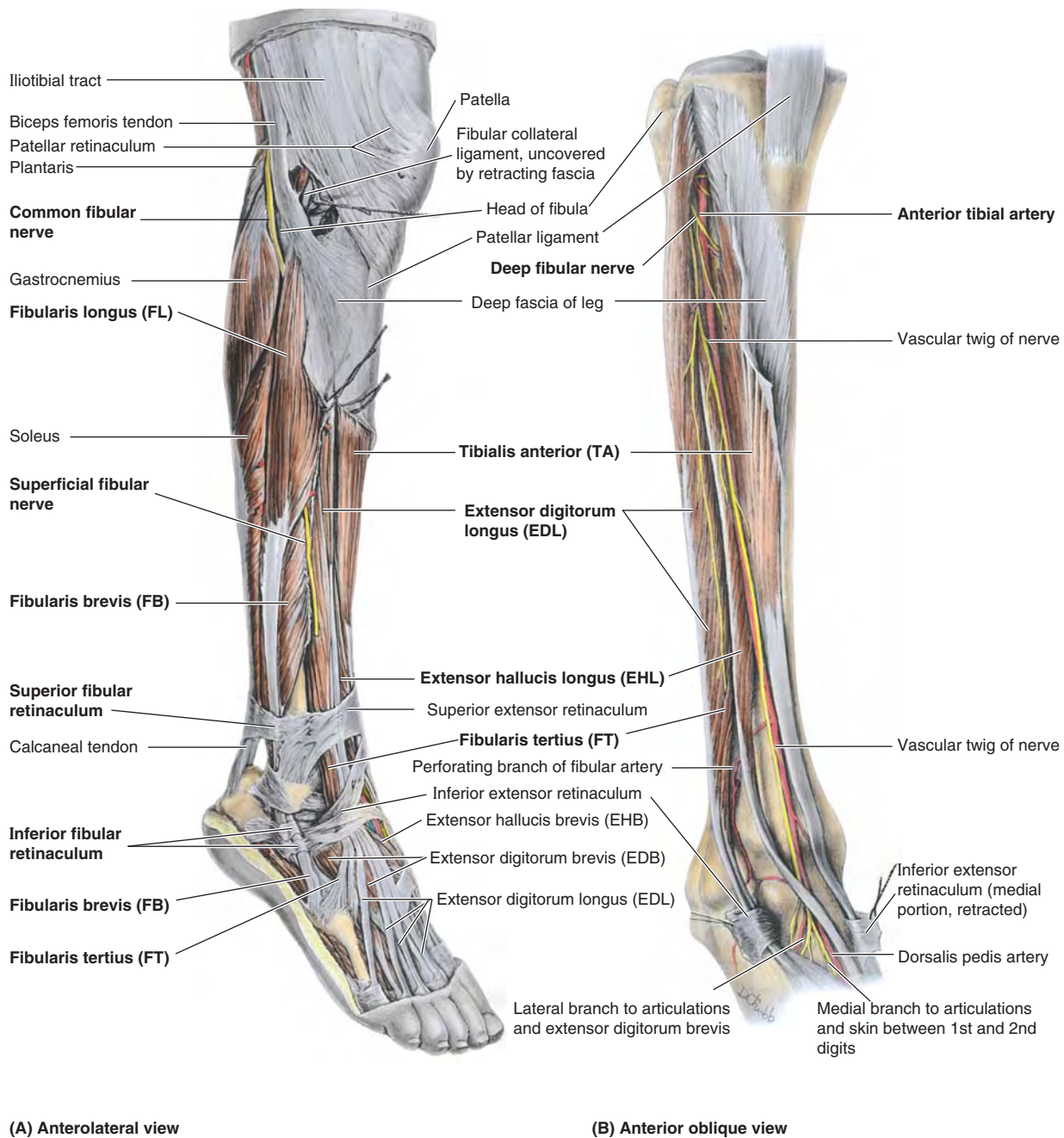


FIGURE 5.56. Dissections of anterior and lateral compartments of leg. **A.** This dissection shows the muscles of the anterolateral leg and dorsum of the foot. The common fibular nerve, coursing subcutaneously across the lateral aspect of the head and neck of the fibula, is the most commonly injured peripheral nerve. **B.** In this deeper dissection of the anterior compartment, the muscles and inferior extensor retinaculum are retracted to display the arteries and nerves.

To test the EHL, the great toe is dorsiflexed against resistance; if acting normally, its entire tendon can be seen and palpated.

NERVE OF ANTERIOR COMPARTMENT OF LEG

The **deep fibular (peroneal) nerve** is the nerve of the anterior compartment (Figs. 5.53A, 5.56B, and 5.57; Table 5.11). It is one of the two terminal branches of the common fibular

nerve, arising between the fibularis longus muscle and the neck of the fibula. After its entry into the anterior compartment, the deep fibular nerve accompanies the anterior tibial artery, first between the TA and EDL and then between the TA and EHL. The deep fibular nerve then exits the compartment, continuing across the ankle joint to supply intrinsic muscles (extensors digitorum and hallucis brevis) and a small area of the skin of the foot. A lesion of this nerve results in an inability to dorsiflex the ankle (footdrop).

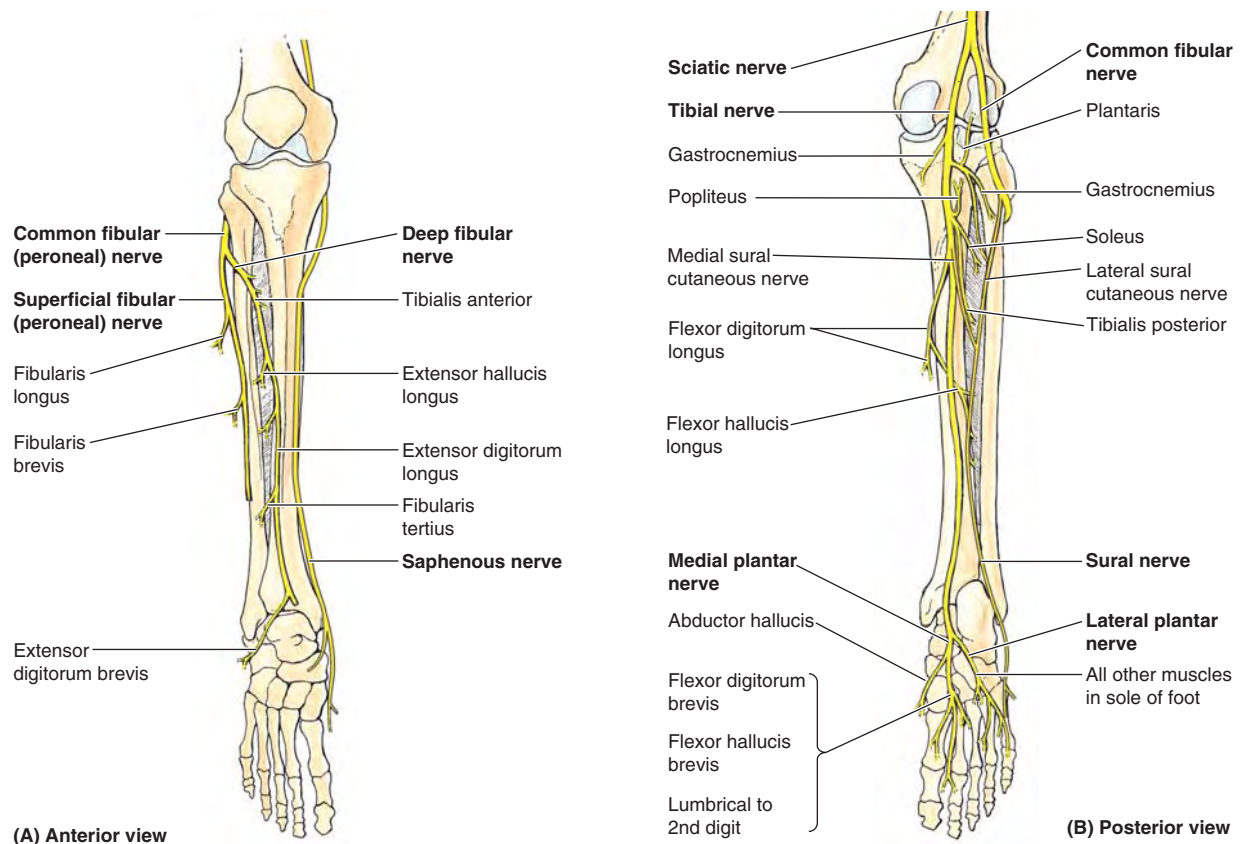


FIGURE 5.57. Nerves of leg.

TABLE 5.11. NERVES OF LEG

| Nerve | Origin | Course | Distribution in Leg |
|--------------------------------|---|--|---|
| Saphenous | Femoral nerve | Descends with femoral vessels through femoral triangle and adductor canal and then descends with great saphenous vein | Supplies skin on medial side of ankle and foot |
| Sural | Usually arises from both tibial and common fibular nerves | Descends between heads of gastrocnemius and becomes superficial at middle of leg; descends with small saphenous vein and passes inferior to lateral malleolus to lateral side of foot | Supplies skin on posterior and lateral aspects of leg and lateral side of foot |
| Tibial | Sciatic nerve | Forms as sciatic bifurcates at apex of popliteal fossa; descends through popliteal fossa and lies on popliteus; runs inferiorly on tibialis posterior with posterior tibial vessels; terminates beneath flexor retinaculum by dividing into medial and lateral plantar nerves | Supplies posterior muscles of leg and knee joint |
| Common fibular (peroneal) | Sciatic nerve | Forms as sciatic bifurcates at apex of popliteal fossa and follows medial border of biceps femoris and its tendon; passes over posterior aspect of head of fibula and then winds around neck of fibula deep to fibularis longus, where it divides into deep and superficial fibular nerves | Supplies skin on lateral part of posterior aspect of leg via the lateral sural cutaneous nerve; also supplies knee joint via its articular branch |
| Superficial fibular (peroneal) | Common fibular nerve | Arises between fibularis longus and neck of fibula and descends in lateral compartment of leg; pierces deep fascia at distal third of leg to become subcutaneous | Supplies fibularis longus and brevis and skin on distal third of anterior surface of leg and dorsum of foot |
| Deep fibular (peroneal) | Common fibular nerve | Arises between fibularis longus and neck of fibula; passes through extensor digitorum longus and descends on interosseous membrane; crosses distal end of tibia and enters dorsum of foot | Supplies anterior muscles of leg, dorsum of foot, and skin of first interdigital cleft; sends articular branches to joints it crosses |

ARTERY IN ANTERIOR COMPARTMENT OF LEG

The **anterior tibial artery** supplies structures in the anterior compartment (Figs. 5.53A, 5.58B, and 5.59; Table 5.12). The smaller terminal *branch of the popliteal artery*, the anterior tibial artery, begins at the inferior border of the popliteus muscle (i.e., as the popliteal artery passes deep to the tendinous

arch of the soleus). The artery immediately passes anteriorly through a gap in the superior part of the *interosseous membrane* to descend on the anterior surface of this membrane between the TA and EDL muscles. At the ankle joint, midway between the malleoli, the anterior tibial artery changes names, becoming the *dorsalis pedis artery* (dorsal artery of the foot).

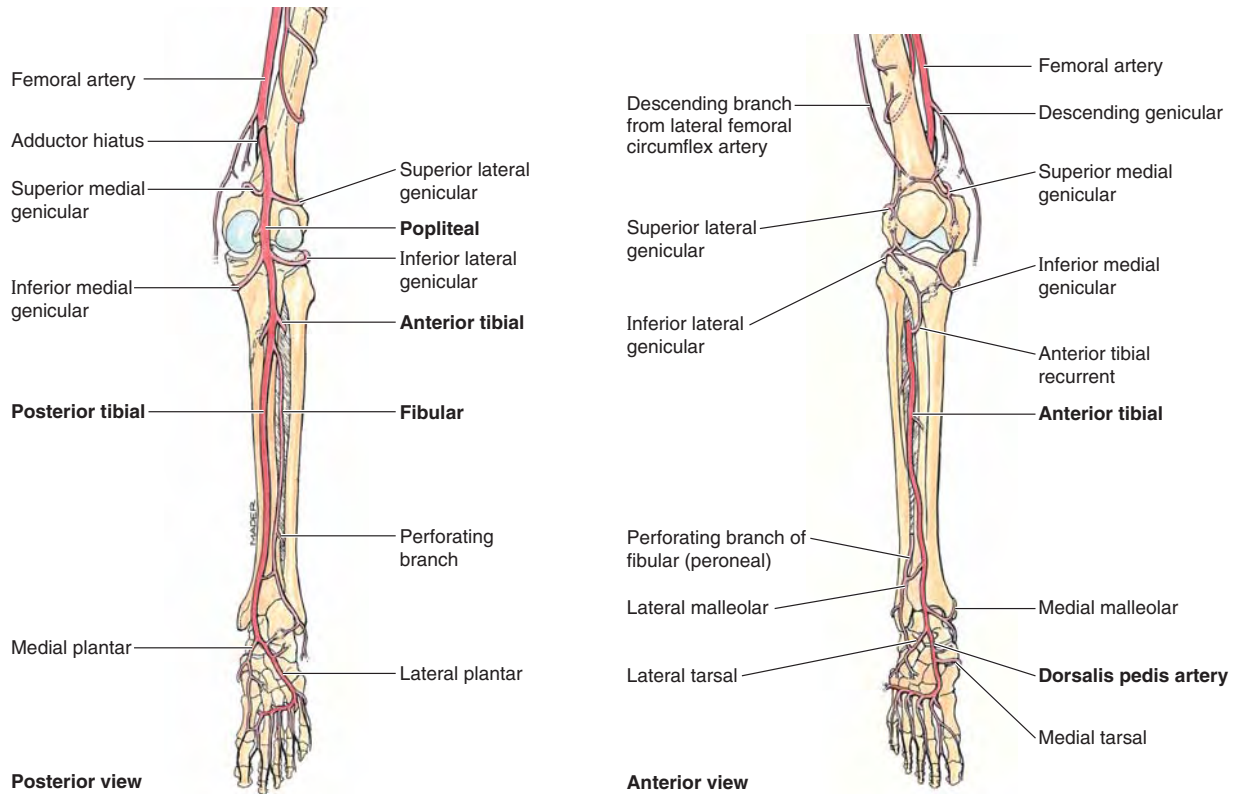


FIGURE 5.58. Arteries of leg.

TABLE 5.12. ARTERIES OF LEG

| Artery | Origin | Course | Distribution in Leg |
|--|--|--|--|
| Popliteal | Continuation of femoral artery at adductor hiatus in adductor magnus | Passes through popliteal fossa to leg; ends at lower border of popliteus muscle by dividing into anterior and posterior tibial arteries | Superior, middle, and inferior genicular arteries to both lateral and medial aspects of knee |
| Anterior tibial | Popliteal | Passes between tibia and fibula into anterior compartment through gap in superior part of interosseous membrane and descends this membrane between tibialis anterior and extensor digitorum longus | Anterior compartment of leg |
| Dorsalis pedis (Dorsal artery of foot) | Continuation of anterior tibial artery distal to inferior extensor retinaculum | Descends anteromedially to first interosseous space and divides into plantar and arcuate arteries | Muscles on dorsum of foot; pierces first dorsal interosseous muscles as deep plantar artery to contribute to formation of plantar arch |
| Posterior tibial | Popliteal | Passes through posterior compartment of leg and terminates distal to flexor retinaculum by dividing into medial and lateral plantar arteries | Posterior and lateral compartments of leg; circumflex fibular branch joins anastomoses around knee; nutrient artery passes to tibia |
| Fibular | Posterior tibial | Descends in posterior compartment adjacent to posterior intermuscular septum | Posterior compartment of leg: perforating branches supply lateral compartment of leg |

through the inferior compartment—inferior to the *fibular trochlea* on the calcaneus—and enters a groove on the anteroinferior aspect of the cuboid bone (see Fig. 5.11D). It then crosses the sole of the foot, running obliquely and distally to reach its attachment to the 1st metatarsal and medial cuneiform bones (see Fig. 5.11B). When a person stands on one foot, the FL helps steady the leg on the foot.

Fibularis Brevis. The **fibularis brevis (FB)** is a fusiform muscle that lies deep to the FL, and, true to its name, the FB is shorter than its partner in the lateral compartment (Figs. 5.53, 5.55F, and 5.56A; Table 5.10). Its broad tendon grooves the posterior aspect of the lateral malleolus and can be palpated inferior to it. The narrower tendon of the FL lies on that of the FB and does not contact the lateral malleolus. The tendon of the FB traverses the superior compartment of the inferior fibular retinaculum, passing superior to the fibular trochlea of the calcaneus; it can be easily traced to its distal attachment to the base of the 5th metatarsal (Fig. 5.11D). The tendon of the *fibularis tertius*, a slip of muscle from the extensor digitorum longus, often merges with the tendon of the FB (Fig. 5.56A). Occasionally, however, the fibularis tertius passes anteriorly to attach directly to the proximal phalanx of the 5th digit.

NERVES IN LATERAL COMPARTMENT OF LEG

The **superficial fibular (peroneal) nerve**, a terminal branch of the common fibular nerve, is the nerve of the lateral compartment (Figs. 5.43A, 5.56A, and 5.57A; Table 5.11). After supplying the FL and FB, the superficial fibular nerve continues as a cutaneous nerve, supplying the skin on the distal part of the anterior surface of the leg and nearly all the dorsum of the foot.

BLOOD VESSELS IN LATERAL COMPARTMENT OF LEG

The lateral compartment does not have an artery coursing through it. Instead, perforating branches and accompanying veins supply blood to and drain blood from the compartment. Proximally, perforating branches of the anterior tibial artery penetrate the anterior intermuscular septum. Inferiorly, perforating branches of the *fibular artery* penetrate the posterior intermuscular septum, along with their accompanying veins (*L. venae comitantes*) (Figs. 5.58 and 5.59; Table 5.12).

Posterior Compartment of Leg

The **posterior compartment of the leg (plantarflexor compartment)** is the *largest of the three leg compartments* (Fig. 5.53A). The posterior compartment and the muscles within it are divided into superficial and deep subcompartments/muscle groups by the *transverse intermuscular septum*. The tibial nerve and posterior tibial and fibular vessels supply both parts of the posterior compartment but run in the deep subcompartment deep (anterior) to the transverse intermuscular septum.

The larger **superficial subcompartment** is the least confined compartmental area. The smaller **deep subcompartment**, like the anterior compartment, is bounded by the two leg bones and the *interosseous membrane* that binds them together, plus the transverse intermuscular septum. Therefore, the deep subcompartment is quite tightly confined. Because the nerve and blood vessels supplying the entire posterior compartment and the sole of the foot pass through the deep subcompartment, when swelling occurs it leads to a compartment syndrome that has serious consequences, such as muscular necrosis (tissue death) and paralysis.

Inferiorly, the deep subcompartment tapers as the muscles it contains become tendinous. The transverse intermuscular septum ends as reinforcing transverse fibers that extend between the tip of the medial malleolus and the calcaneus to form the **flexor retinaculum** (see Fig. 5.61). The retinaculum is subdivided deeply, forming separate compartments for each tendon of the deep muscle group, as well as for the tibial nerve and posterior tibial artery as they bend around the medial malleolus.

Muscles of the posterior compartment produce *plantarflexion* at the ankle, *inversion* at the subtalar and transverse tarsal joints, and *flexion* of the toes. **Plantarflexion** is a powerful movement (four times stronger than dorsiflexion) produced over a relatively long range (approximately 50° from neutral) by muscles that pass posterior to the transverse axis of the ankle joint. Plantarflexion develops thrust, applied primarily at the ball of the foot, that is used to propel the body forward and upward and is the major component of the forces generated during the push-off (heel off and toe off) parts of the stance phase of walking and running (see Fig. 5.20D & E; Table 5.2).

SUPERFICIAL MUSCLE GROUP IN POSTERIOR COMPARTMENT

The superficial group of *calf muscles* (muscles forming prominence of “calf” of posterior leg) includes the *gastrocnemius*, *soleus*, and *plantaris*. Details concerning their attachments, innervation, and actions are provided in Figure 5.60A–E and Table 5.13.I). The gastrocnemius and soleus share a common tendon, the *calcaneal tendon*, which attaches to the calcaneus. Collectively these two muscles make up the three-headed **triceps surae** (*L. sura*, calf) (Figs. 5.60 and 5.61A). This powerful muscular mass tugs on the lever provided by the calcaneal tuberosity, elevating the heel and thus depressing the forefoot, generating as much as 93% of the plantarflexion force.

The large size of the gastrocnemius and soleus muscles is a human characteristic that is directly related to our upright stance. These muscles are strong and heavy because they lift, propel, and accelerate the weight of the body when walking, running, jumping, or standing on the toes.

The **calcaneal tendon** (*L. tendo calcaneus*, Achilles tendon) is the most powerful (thickest and strongest) tendon in the body. Approximately 15 cm in length, it is a continuation of the flat aponeurosis formed halfway down the calf where the bellies of the gastrocnemius terminate (Figs. 5.60D & E and 5.61).

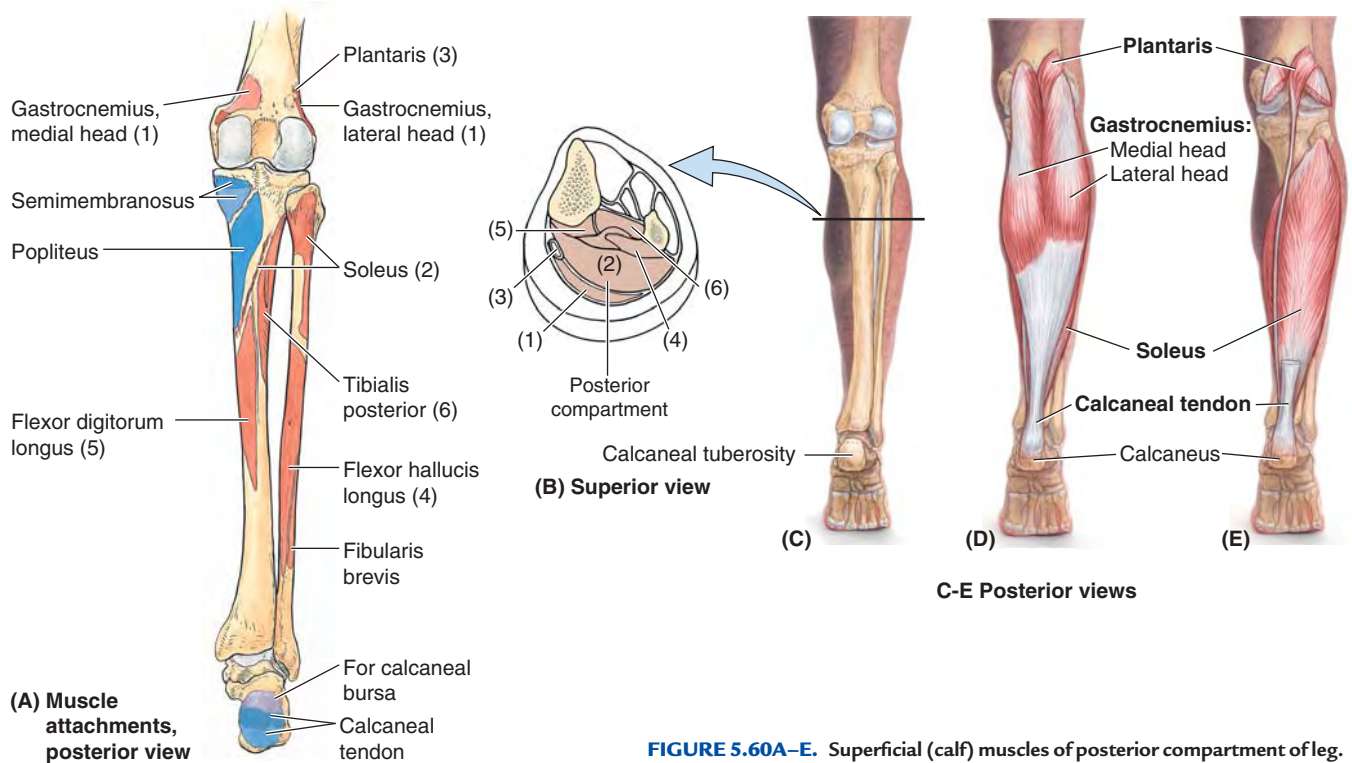


FIGURE 5.60A–E. Superficial (calf) muscles of posterior compartment of leg.

TABLE 5.13.I. SUPERFICIAL MUSCLES OF POSTERIOR COMPARTMENT OF LEG

| Muscle ^a | Proximal Attachment | Distal Attachment | Innervation ^b | Main Action |
|---------------------|---|---|--------------------------|---|
| Gastrocnemius (1) | Lateral head: lateral aspect of lateral condyle of femur | Posterior surface of calcaneus via calcaneal tendon | Tibial nerve (S1, S2) | Plantarflexes ankle when knee is extended; raises heel during walking; flexes leg at knee joint |
| | Medial head: popliteal surface of femur; superior to medial condyle | | | |
| Soleus (2) | Posterior aspect of head and superior quarter of posterior surface of fibula; soleal line and middle third of medial border of tibia; and tendinous arch extending between the bony attachments | | | |
| Plantaris (3) | Inferior end of lateral supracondylar line of femur; oblique popliteal ligament | | | Weakly assists gastrocnemius in plantarflexing ankle |

^a Numbers refer to Figure 5.60A.

^b The spinal cord segmental innervation is indicated (e.g., “S1, S2” means that the nerves supplying these muscles are derived from the first and second sacral segments of the spinal cord). Damage to one or more of the listed spinal cord segments or to the motor nerve roots arising from them results in paralysis of the muscles concerned.

The aponeurosis receives fleshy fibers of the soleus directly on its deep surface proximally but thickens as the soleus fibers become tendinous inferiorly. The tendon thus becomes thicker (deeper) but narrower as it descends until it becomes essentially round in cross-section superior to the calcaneus. It then expands as it inserts centrally on the posterior surface of the *calcaneal tuberosity*. The calcaneal tendon typically spirals a quarter turn (90°) during its descent, so that the gastrocnemius fibers attach laterally and the soleal fibers attach medially. This arrangement is thought to be significant to the tendon’s elastic ability to absorb energy (shock) and recoil, releasing the energy

as part of the propulsive force it exerts. Although they share a common tendon, the two muscles of the triceps surae are capable of acting alone, and often do so: “You stroll with the soleus but win the long jump with the gastrocnemius.”

To test the *triceps surae*, the foot is plantarflexed against resistance (e.g., by “standing on the toes,” in which case body weight [gravity] provides resistance). If normal, the calcaneal tendon and triceps surae can be seen and palpated.

A *subcutaneous calcaneal bursa*, located between the skin and the calcaneal tendon, allows the skin to move over the taut tendon. A deep *bursa of the calcaneal tendon* (retrocal-

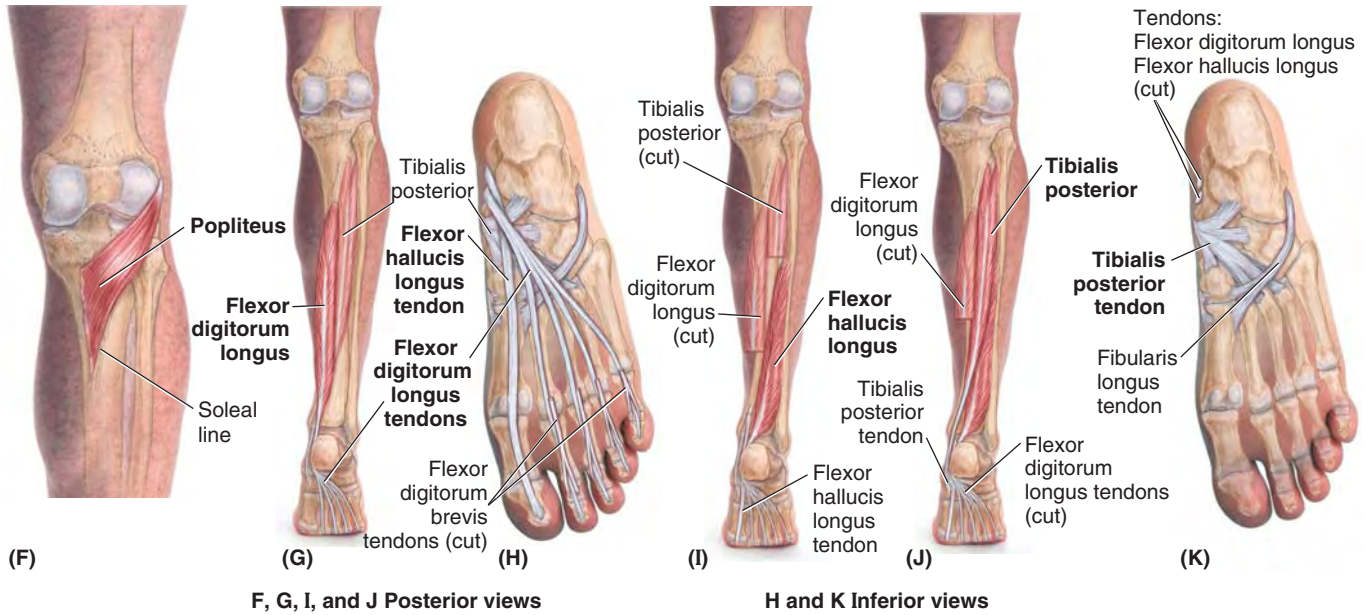


FIGURE 5.60F-K. Deep muscles of posterior compartment of leg.

TABLE 5.13.II. DEEP MUSCLES OF POSTERIOR COMPARTMENT OF LEG

| Muscle ^a | Proximal Attachment | Distal Attachment | Innervation ^b | Main Action |
|-----------------------------|--|---|---------------------------|---|
| Popliteus | Lateral surface of lateral condyle of femur and lateral meniscus | Posterior surface of tibia, superior to soleal line | Tibial nerve (L4, L5, S1) | Weakly flexes knee and unlocks it by rotating femur 5° on fixed tibia; medially rotates tibia of unplantar limb |
| Flexor hallucis longus (4) | Inferior two thirds of posterior surface of fibula; inferior part of interosseous membrane | Base of distal phalanx of great toe (hallux) | Tibial nerve (S2, S3) | Flexes great toe at all joints; weakly plantarflexes ankle; supports medial longitudinal arch of foot |
| Flexor digitorum longus (5) | Medial part of posterior surface of tibia inferior to soleal line; by a broad tendon to fibula | Bases of distal phalanges of lateral four digits | | Flexes lateral four digits; plantarflexes ankle; supports longitudinal arches of foot |
| Tibialis posterior (6) | Interosseous membrane; posterior surface of tibia inferior to soleal line; posterior surface of fibula | Tuberosity of navicular, cuneiform, cuboid, and sustentaculum tali of calcaneus; bases of 2nd, 3rd, and 4th metatarsals | Tibial nerve (L4, L5) | Plantarflexes ankle; inverts foot |

^a Numbers refer to Figure 5.60A.

^b The spinal cord segmental innervation is indicated (e.g., “S2, S3” means that the nerves supplying the flexor hallucis longus are derived from the second and third sacral segments of the spinal cord). Damage to one or more of the listed spinal cord segments or to the motor nerve roots arising from them results in paralysis of the muscles concerned.

canal bursa), located between the tendon and the calcaneus, allows the tendon to glide over the bone.

Gastrocnemius. The **gastrocnemius** is the most superficial muscle in the posterior compartment and forms the proximal, most prominent part of the *calf* (Figs. 5.60D and 5.61A; Table 5.13.I). It is a fusiform, two-headed, two-joint muscle with the medial head slightly larger and extending more distally than its lateral partner. The heads come together at the inferior margin of the popliteal fossa, where they form the inferolateral and inferomedial boundaries of

this fossa. Because its fibers are largely of the white, fast-twitch (type 2) variety, contractions of the gastrocnemius produce rapid movements during running and jumping. It is recruited into action only intermittently during symmetrical standing.

The gastrocnemius crosses and is capable of acting on both the knee and the ankle joints; however, it cannot exert its full power on both joints at the same time. It functions most effectively when the knee is extended (and is maximally activated when knee extension is combined with dorsiflexion,

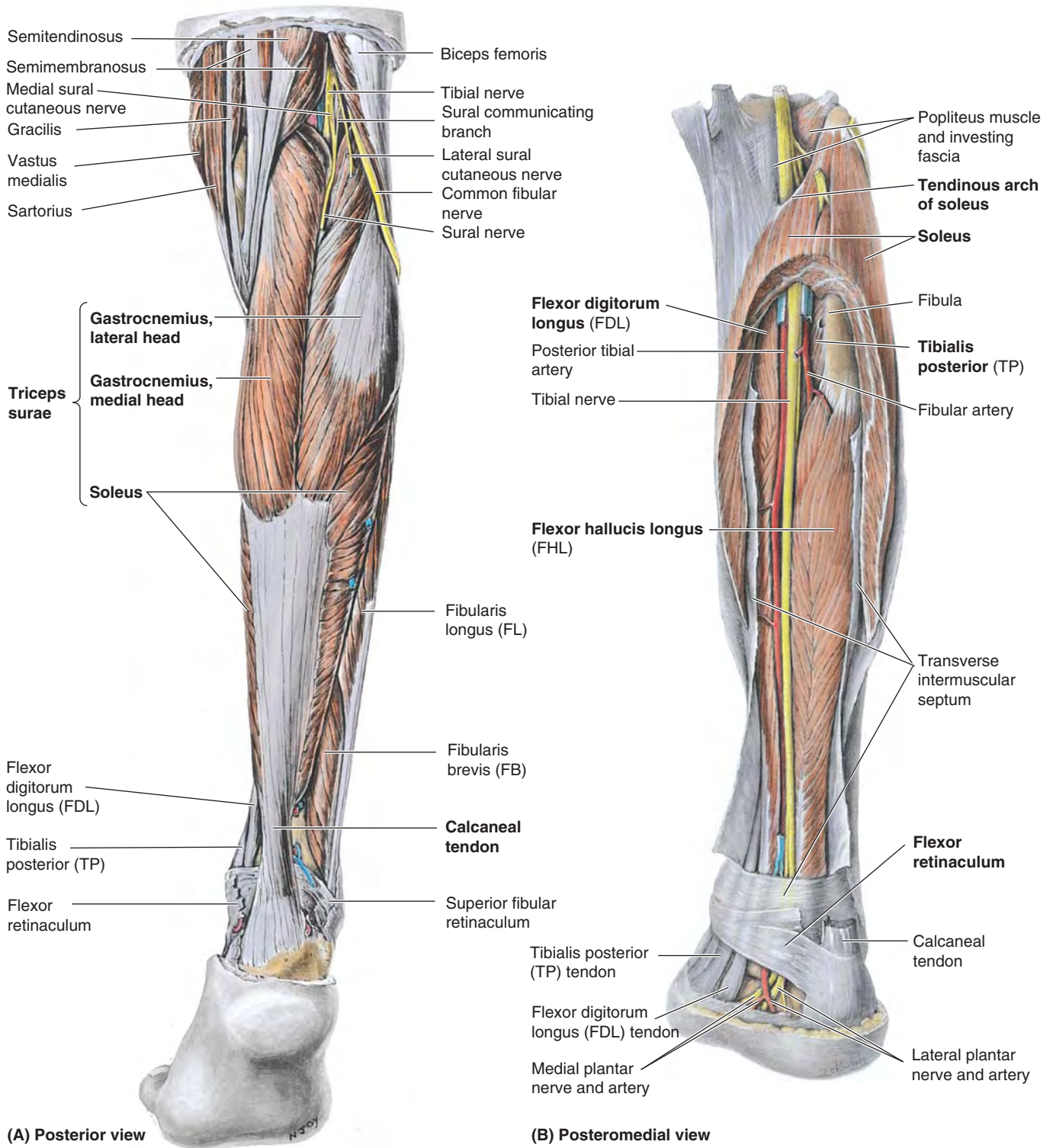


FIGURE 5.61. Dissections of posterior aspect of leg. **A.** Superficial dissection. Except for the retinacula in the ankle region, the deep fascia has been removed to reveal the nerves and muscles. The three heads of the triceps surae muscle attach distally to the calcaneus via the spiraling fibers of the calcaneal tendon. **B.** Deep dissection. The gastrocnemius and most of the soleus are removed, leaving only a horseshoe-shaped section of the soleus close to its proximal attachments and the distal part of the calcaneal tendon. The transverse intermuscular septum has been split to reveal the deep muscles, vessels, and nerves.

as in the sprint start). It is incapable of producing plantarflexion when the knee is fully flexed.

Soleus. The **soleus** is located deep to the gastrocnemius and is the “workhorse” of plantarflexion (Figs. 5.60E and 5.61A & B; Table 5.13.I). It is a large muscle, flatter than the gastrocnemius, that is named for its resemblance to a sole—the flat fish that reclines on its side on the sea floor. The soleus has a continuous proximal attachment in the shape of an inverted U to the posterior aspects of the fibula and tibia and a tendinous arch between them, the **tendinous arch of soleus** (L. *arcus tendineus soleus*) (Figs. 5.60A and 5.61B). The popliteal artery and tibial nerve exit the popliteal fossa by passing through this arch, the popliteal artery simultaneously bifurcating into its terminal branches, the anterior and posterior tibial arteries.

The soleus can be palpated on each side of the gastrocnemius when the individual is standing on their tiptoes. The soleus may act with the gastrocnemius in plantarflexing the ankle joint; it cannot act on the knee joint and acts alone when the knee is flexed. Soleus has many parts (3) each with fiber bundles in different direction.

When the foot is planted, the soleus pulls posteriorly on the bones of the leg. This is important to standing because the line of gravity passes anterior to the leg’s bony axis. The soleus is thus an antigravity muscle (the predominant plantarflexor for standing and strolling), which contracts antagonistically but cooperatively (alternately) with the dorsiflexor muscles of the leg to maintain balance. Composed largely of red, fatigue-resistant, slow-twitch (type 1) muscle fibers, it is a strong but relatively slow plantarflexor of the ankle joint, capable of sustained contraction. Electromyography (EMG) studies show that during symmetrical standing, the soleus is continuously active.

Plantaris. The **plantaris** is a small muscle with a short belly and a long tendon (Figs. 5.50, 5.53A, and 5.60A & E; Table 5.13.I). This vestigial muscle is absent in 5–10% of people and is highly variable in size and form when present (most commonly a tapering slip about the size of the small finger). It acts with the gastrocnemius but is insignificant as either a flexor of the knee or a plantarflexor of the ankle.

The plantaris has been considered to be an organ of proprioception for the larger plantarflexors, as it has a high density of muscle spindles (receptors for proprioception). Its long, slender tendon is easily mistaken for a nerve (and hence dubbed by some as the “freshman’s nerve”).

The plantaris tendon runs distally between the gastrocnemius and soleus (Figs. 5.53A and 5.60B) and occasionally suddenly ruptures with a painful *pop* during activities such as racquet sports. Because of its minor role, the plantaris tendon can be removed for grafting (e.g., during reconstructive surgery of the tendons of the hand) without causing disability.

DEEP MUSCLE GROUP IN POSTERIOR COMPARTMENT

Four muscles make up the deep group in the posterior compartment of the leg (Figs. 5.53, 5.61B, 5.62–5.64;

Table 5.13.II): *popliteus*, *flexor digitorum longus*, *flexor hallucis longus*, and *tibialis posterior*. The popliteus acts on the knee joint, whereas the other muscles plantarflex the ankle with two continuing on to flex the toes. However, because of their smaller size and the close proximity of their tendons to the axis of the ankle joint, the “non-triceps” plantarflexors collectively produce only about 7% of the total force of plantarflexion, and in this the fibularis longus and brevis are most significant. When the calcaneal tendon is ruptured, these muscles cannot generate the power necessary to lift the body’s weight (i.e., to stand on the toes).

The two muscles of the posterior compartment that pass to the toes are crisscrossed—that is, the muscle attaching to the great toe (*flexor hallucis longus*) arises laterally (from the fibula) in the deep subcompartment, and the muscle attaching to the lateral four toes (*flexor digitorum longus*) arises medially (from the tibia) (Fig. 5.40). Their tendons cross in the sole of the foot.

Popliteus. The **popliteus** is a thin, triangular muscle that forms the inferior part of the floor of the popliteal fossa (Figs. 5.51, 5.32, 5.60A & F, and 5.62; Table 5.13.II). Proximally, its tendinous attachment to the lateral aspect of the lateral femoral condyle and its broader attachment to the lateral meniscus occur between the fibrous layer and the synovial membrane of the joint capsule of the knee. The apex of its fleshy belly emerges from the joint capsule of the knee joint. It has a fleshy distal attachment to the tibia that is covered by popliteal fascia reinforced by a fibrous expansion from the semimembranosus muscle.

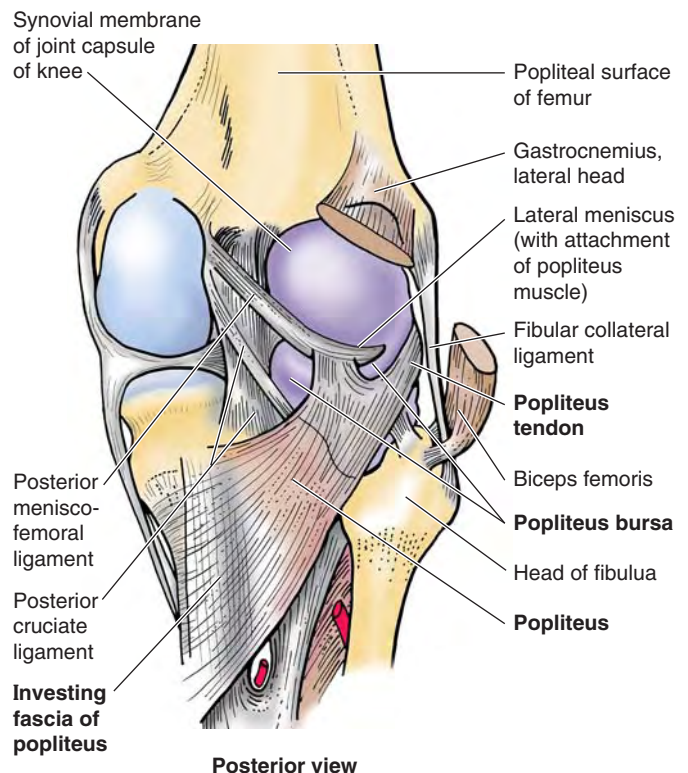


FIGURE 5.62. Deep dissection of popliteal fossa and posterior knee joint.

The popliteus is insignificant as a flexor of the knee joint *per se*; but during flexion at the knee, it assists in pulling the lateral meniscus of the knee joint posteriorly, a movement otherwise produced passively by compression (as it is for the medial meniscus). When a person is standing with the knee partly flexed, the popliteus contracts to assist the posterior cruciate ligament (PCL) in preventing anterior displacement of the femur on the inclined tibial plateau.

The **popliteus bursa** lies deep to the popliteus tendon (Fig. 5.62). When standing with the knees locked in the fully extended position, the popliteus acts to rotate the femur laterally 5° on the tibial plateaus, releasing the knee from its close-packed or locked position so that flexion can occur. When the foot is off the ground and the knee is flexed, the popliteus can aid the medial hamstrings (the “semimuscles”) in rotating the tibia medially beneath the femoral condyles.

Flexor Hallucis Longus. The **flexor hallucis longus** (FHL) is a powerful flexor of all of the joints of the great toe. Immediately after the triceps surae has delivered the thrust of plantarflexion to the *ball of the foot* (the prominence of the sole underlying the heads of the 1st and 2nd metatarsals), the FHL delivers a final thrust via flexion of the great toe for the preswing phase (toe off) of the gait cycle (see Fig. 5.20E; Table 5.2). When barefoot, this thrust is delivered by the great toe; but with soled shoes on, it becomes part of the thrust of plantarflexion delivered by the forefoot.

The tendon of the FHL passes posterior to the distal end of the tibia and occupies a shallow groove on the posterior surface of the talus, which is continuous with the groove on the

plantar surface of the sustentaculum tali (Figs. 5.60H–K and 5.63A & B; Table 5.13.II). The tendon then crosses deep to the tendon of the flexor digitorum longus in the sole of the foot. As it passes to the distal phalanx of the great toe, the FHL tendon runs between two *sesamoid bones* in the tendons of the flexor hallucis brevis (Fig. 5.63B). These bones protect the tendon from the pressure of the head of the 1st metatarsal bone.

To test the FHL, the distal phalanx of the great toe is flexed against resistance; if normal, the tendon can be seen and palpated on the plantar aspect of the great toe as it crosses the joints of the toe.

Flexor Digitorum Longus. The **flexor digitorum longus** (FDL) is smaller than the FHL, even though it moves four digits (Figs. 5.60G–K, 5.61B, and 5.63A & B; Table 5.13.II). It passes diagonally into the sole of the foot, superficial to the tendon of the FHL. However, its direction of pull is realigned by the *quadratus plantae muscle*, which is attached to the posterolateral aspect of the FDL tendon as it divides into four tendons (Figs. 5.60H and 5.63B), which in turn pass to the distal phalanges of the lateral four digits.

To test the FDL, the distal phalanges of the lateral four toes are flexed against resistance; if they are acting normally, the tendons of the toes can be seen and palpated.

Tibialis Posterior. The **tibialis posterior** (TP), the deepest (most anterior) muscle in the posterior compartment, lies between the FDL and the FHL in the same plane as the tibia and fibula within the deep subcompartment (Figs. 5.60J & K, 5.61B, and 5.63A & B; Table 5.13.II). Distally, the TP attaches primarily to the navicular bone (in close proximity to the high

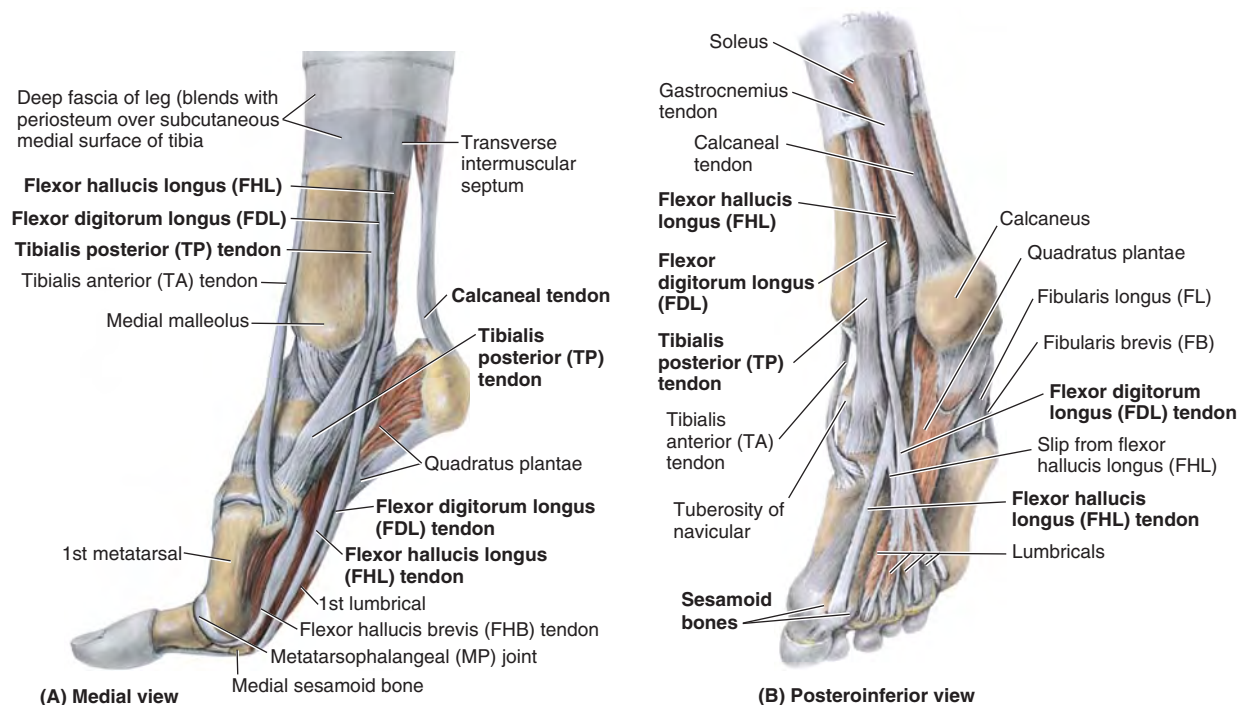


FIGURE 5.63. Dissection demonstrating continuation of plantarflexor tendons. **A.** The foot is raised as in the push-off phase of walking, demonstrating the position of the plantarflexor tendons as they cross the ankle. Observe the sesamoid bone acting as a “foot stool” for the 1st metatarsal, giving it extra height and protecting the flexor hallucis longus tendon. **B.** This view demonstrates the disposition of the deep plantarflexor tendons in the sole of the foot.

point of the medial longitudinal arch of the foot) but has attachments to other tarsal and metatarsal bones.

The TP is traditionally described as an inverter of the foot. Indeed, when the foot is off the ground, it can act synergistically with the TA to invert the foot, their otherwise antagonistic functions canceling each other out. However, the primary role of the TP is to support or maintain (fix) the medial longitudinal arch during weight-bearing; consequently, the muscle contracts statically throughout the stance phase of gait (see Fig. 5.20A–E; Table 5.2; see also Fig. 5.103C & E). In so doing, it acts independently of the TA because, once the foot is flat on the ground after heel strike, that muscle is relaxed during the stance phase (the dorsiflexion that occurs as the body passes over the planted foot is passive), unless braking requires its eccentric contraction.

While standing (especially on one foot), however, the two muscles may cooperate to depress the lateral side of the foot and pull medially on the leg as needed to counteract lateral leaning for balance.

To test the TA, the foot is inverted against resistance with the foot in slight plantarflexion; if normal, the tendon can be seen and palpated posterior to the medial malleolus.

NERVES IN POSTERIOR COMPARTMENT

The *tibial nerve* (L4, L5, and S1–S3) is the larger of the two terminal branches of the *sciatic nerve* (Fig. 5.57B; Table 5.11). It runs vertically through the popliteal fossa with the popliteal artery, passing between the heads of the gastrocnemius, the two structures exiting the fossa by passing deep to the tendinous arch of the soleus (Fig. 5.61B).

The tibial nerve supplies all muscles in the posterior compartment of the leg (Figs. 5.53A and 5.61B; Table 5.11). At the ankle, the nerve lies between the tendons of the FHL and the FDL. Posteroinferior to the medial malleolus, the tibial nerve divides into the medial and lateral plantar nerves. A branch of the tibial nerve, the *medial sural cutaneous nerve*, is usually joined by the *sural communicating branch of the common fibular nerve* to form the *sural nerve* (see Figs. 5.49B, 5.50, and 5.57). This nerve supplies the skin of the lateral and posterior part of the inferior third of the leg and the lateral side of the foot. Articular branches of the tibial nerve supply the knee joint, and medial calcaneal branches supply the skin of the heel.

ARTERIES IN POSTERIOR COMPARTMENT

The **posterior tibial artery**, the larger and more direct terminal branch of the popliteal artery, provides the blood supply to the posterior compartment of the leg and to the foot (Figs. 5.53A, 5.58, 5.61B, and 5.64; Table 5.12). It begins at the distal border of the popliteus as the popliteal artery passes deep to the tendinous arch of the soleus and simultaneously bifurcates into its terminal branches. Close to its origin, the posterior tibial artery gives rise to its largest branch, the *fibular artery*, which runs lateral and parallel to it, also within the deep subcompartment.

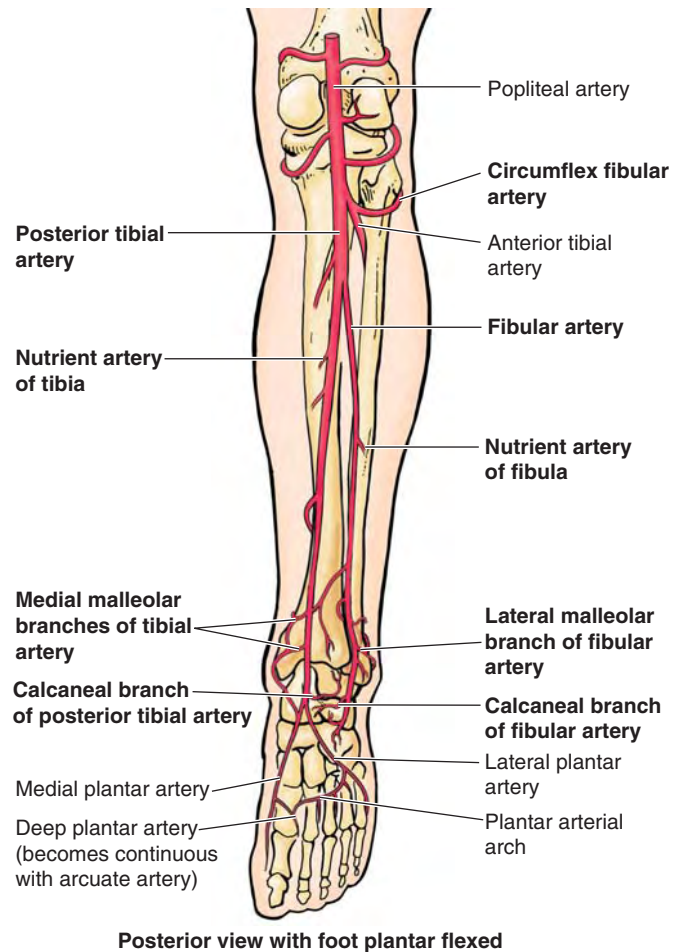


FIGURE 5.64. Arteries of knee, posterior leg, and sole of foot.

During its descent, the posterior tibial artery is accompanied by the tibial nerve and veins. The artery runs posterior to the medial malleolus, from which it is separated by the tendons of the TP and FDL (Fig. 5.61B). Inferior to the medial malleolus, it runs between the tendons of the FHL and FDL. Deep to the flexor retinaculum and the origin of the abductor hallucis, the posterior tibial artery divides into *medial and lateral plantar arteries*, the arteries of the sole of the foot.

The **fibular** (peroneal) **artery**, the largest and *most important branch of the tibial artery*, arises inferior to the distal border of the popliteus and the tendinous arch of the soleus (Figs. 5.58A, 5.61B, and 5.64; Table 5.12). It descends obliquely toward the fibula and passes along its medial side, usually within the FHL. The fibular artery gives muscular branches to the popliteus and other muscles in both the posterior and the lateral compartments of the leg. It also gives rise to the **nutrient artery of the fibula** (Fig. 5.64).

Distally, the fibular artery gives rise to a perforating branch and terminal lateral malleolar and calcaneal branches. The perforating branch pierces the *interosseous membrane* and passes to the dorsum of the foot, where it anastomoses with the arcuate artery. The *lateral calcaneal branches* supply the heel, and the *lateral malleolar branch* joins other malleolar

branches to form a periarticular *arterial anastomosis of the ankle*.

The **circumflex fibular artery** arises from the origin of the anterior or posterior tibial artery at the knee and passes laterally over the neck of the fibula to the anastomoses around the knee.

The **nutrient artery of tibia**, the largest nutrient artery in the body, arises from the origin of the anterior or posterior tibial artery. It pierces the tibilis posterior, to which it sup-

plies branches, and enters the nutrient foramen in the proximal third of the posterior surface of the tibia.

Surface Anatomy of Leg

The **tibial tuberosity** is an easily palpable elevation on the anterior aspect of the proximal part of the tibia, approximately 5 cm distal to the apex of the patella (Fig. 5.65A & B). The tuberosity indicates the level of the head of the fibula

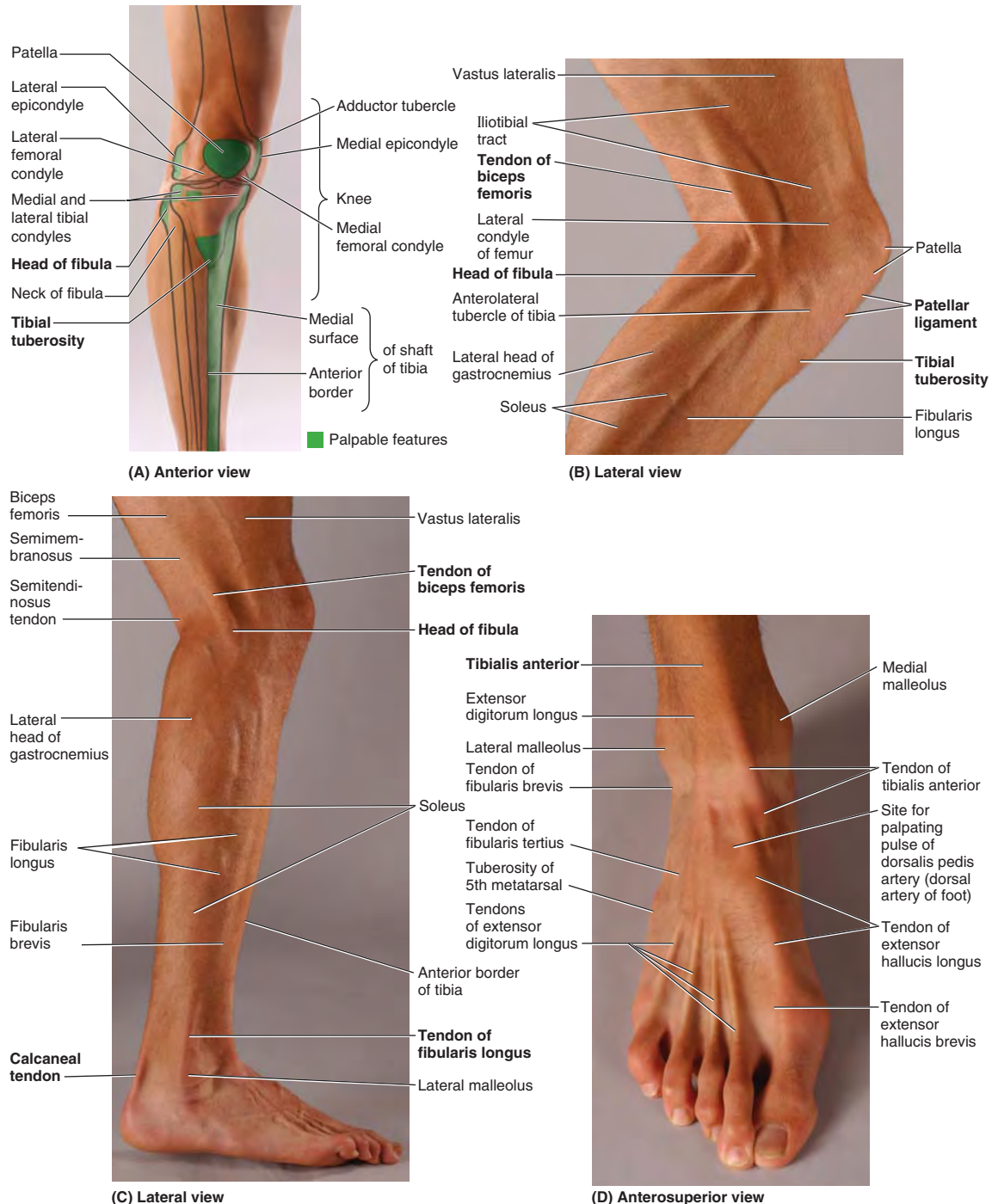


FIGURE 5.65. Surface anatomy of the leg. **A.** Standing at ease. **B and C.** Knee is flexed while weight-bearing. **D.** Extensors and flexors of toes are being contracted simultaneously, demonstrating extensor tendons without elevating toes from ground.

and the bifurcation of the popliteal artery into the anterior and posterior tibial arteries.

The *patellar ligament* may be felt as it extends from the inferior border of the apex of the patella. It is most easily felt when the knee is extended. When the knee flexes to a right angle, a depression may be felt on each side of the patellar ligament. The joint cavity is superficial in these depressions.

The *head of the fibula* is subcutaneous and may be palpated at the posterolateral aspect of the knee, at the level of the tibial tuberosity. The *neck of the fibula* can be palpated just distal to the head.

The *tendon of the biceps femoris* may be traced by palpating its distal attachment to the lateral side of the head of the fibula (Fig. 5.65B & C). This tendon and the head and neck of the fibula guide the examining finger to the *common fibular nerve* (Fig. 5.61A). The nerve is indicated by a line along the biceps femoris tendon, posterior to the head of the fibula, and around the lateral aspect of the fibular neck to its anterior aspect, just distal to the fibular head. Here it can be rolled against the fibular neck with the fingertips.

The *anterior border of the tibia* is sharp, subcutaneous, and easily followed distally by palpation from the tibial tuberosity to the medial malleolus (Fig. 5.65A–D). The *medial surface of the shaft of the tibia* is also subcutaneous, except at its proximal end. Its inferior third is crossed obliquely by the great saphenous vein as it passes proximally to the medial aspect of the knee.

The *tibialis anterior (TA)* lies superficially and is easily palpable just lateral to the anterior border of the tibia. As the foot is inverted and dorsiflexed, the large *tendon of the TA* can be seen and palpated as it runs distally and slightly medially over the anterior surface of the ankle joint to the medial side of the foot (Fig. 5.65D). If the 1st digit is dorsiflexed, the *tendon of the EHL* can be palpated just lateral to the tendon of TA. The *tendon of the EHB* may also be visible.

As the toes are dorsiflexed, the *tendons of the EDL* can be palpated lateral to the extensor hallucis longus and followed

to the four lateral digits. The *tendon of the FT* may be palpable lateral to the tendons of the EDL, especially when the foot is dorsiflexed and everted.

The *shaft of the fibula* is subcutaneous only in its distal part, proximal to the lateral malleolus; this is the common site of fractures. The *medial* and *lateral malleoli* are subcutaneous and prominent. Palpate them, noting that the tip of the lateral malleolus extends farther distally and posteriorly than the medial malleolus.

The *fibularis longus (FL)* is subcutaneous throughout its course (Fig. 5.65C). The tendons of this muscle and the *fibularis brevis (FB)* are palpable when the foot is everted as they pass around the posterior aspect of the lateral malleolus. These tendons may be followed anteriorly along the lateral side of the foot. The tendon of the FL runs as far anteriorly as the cuboid and then disappears by turning into the sole of the foot. The *tendon of the FB* may be traced to its attachment to the base of the 5th metatarsal.

The *calcaneal tendon* can be easily followed to its attachment to the calcaneal tuberosity, the posterior part of the calcaneus. The ankle joint is fairly superficial in the depression on each side of the calcaneal tendon. The *heads of the gastrocnemius* are easily recognizable in the superior part of the calf of the leg (Fig. 5.65B & C). The *soleus* can be palpated deep to and at the sides of the superior part of the calcaneal tendon. The *triceps surae* (soleus and gastrocnemius) is easy to palpate when the individual is standing on the toes. The soleus can be distinguished from the gastrocnemius during squatting (flexing the knees while standing on toes) because flexion of the knee to approximately 90° makes the gastrocnemius flaccid; plantarflexion in this position is maintained by the soleus. The deep muscles of the posterior compartment are not easily palpated, but their tendons can be observed just posterior to the medial malleolus, especially when the foot is inverted and the toes are flexed.

POPLITEAL FOSSA AND LEG

Popliteal Abscess and Tumor



Because the deep popliteal fascia is strong and limits expansion, pain from an abscess or tumor in the popliteal fossa is usually severe. *Popliteal abscesses* tend to spread superiorly and inferiorly because of the toughness of the popliteal fascia.

Popliteal Pulse



Because the popliteal artery is deep, it may be difficult to feel the *popliteal pulse*. Palpation of this pulse is commonly performed with the person in the prone position with the knee flexed to relax the popliteal fascia and hamstrings. The pulsations are best felt in the infe-

rior part of the fossa where the popliteal artery is related to the tibia. Weakening or loss of the popliteal pulse is a sign of a femoral artery obstruction.

Popliteal Aneurysm and Hemorrhage



A **popliteal aneurysm** (abnormal dilation of all or part of the popliteal artery) usually causes edema and pain in the popliteal fossa. A popliteal aneurysm may be distinguished from other masses by palpable pulsations (*thrills*) and abnormal arterial sounds (*bruits*) detectable with a stethoscope. Because the artery lies deep to the tibial nerve, an aneurysm may stretch the nerve or compress its blood supply (*vasa vasorum*). Pain from such nerve compression is usually referred, in this case to the skin overlying the medial aspect of the calf, ankle, or foot.

Because the artery is closely applied to the popliteal surface of the femur and the joint capsule, fractures of the distal femur or dislocations of the knee may rupture the artery, resulting in hemorrhage. Furthermore, because of their proximity and confinement within the fossa, an injury of the artery and vein may result in an **arteriovenous fistula** (communication between an artery and a vein). Failure to recognize these occurrences and to act promptly may result in the loss of the leg and foot.

If the femoral artery must be ligated, blood can bypass the occlusion through the genicular anastomosis and reach the popliteal artery distal to the ligation (see Fig. 5.52).

Injury to Tibial Nerve



Injury to the tibial nerve is uncommon because of its deep and protected position in the popliteal fossa; however, the nerve may be injured by deep lacerations in the fossa. *Posterior dislocation of the knee joint* may also damage the tibial nerve. *Severance of the tibial nerve* produces paralysis of the flexor muscles in the leg and the intrinsic muscles in the sole of the foot. People with a tibial nerve injury are unable to plantarflex their ankle or flex their toes. Loss of sensation also occurs on the sole of the foot.

Containment and Spread of Compartmental Infections in the Leg



The fascial compartments of the lower limbs are generally closed spaces, ending proximally and distally at the joints. Because the septa and deep fascia of the leg forming the boundaries of the leg compartments are strong, the increased volume consequent to infection with *suppuration* (formation of pus) increases intracompartmental pressure. Inflammations within the anterior and posterior compartments of the leg spread chiefly in a distal direction; however, a purulent (pus-forming) infection in the lateral compartment of the leg can ascend proximally into the popliteal fossa, presumably along the course of the fibular nerve. Fasciotomy may be necessary to relieve compartmental pressure and debride (remove by scraping) pockets of infection.

Tibialis Anterior Strain (Shin Splints)



Shin splints—edema and pain in the area of the distal two thirds of the tibia—result from repetitive microtrauma of TA, which causes small tears in the periosteum covering the shaft of the tibia and/or of fleshy attachments to the overlying deep fascia of the leg. Shin splints are a mild form of the anterior compartment syndrome.

Shin splints commonly occur during traumatic injury or athletic overexertion of muscles in the anterior compartment, especially TA, by untrained persons. Often persons who lead sedentary lives develop shin splints when they participate in walk-a-thons (long-distance walks).

Shin splints also occur in trained runners who do not warm up and cool down sufficiently. Muscles in the anterior compartment swell from sudden overuse, and the edema and muscle–tendon inflammation reduce the blood flow to the muscles. The swollen muscles are painful and tender to pressure.

Fibularis Muscles and Evolution of the Human Foot



Whereas the feet of anthropoids (higher primates) are inverted so that they walk on the outer border of the foot, feet of humans are relatively everted (pronated) so that the soles lie more fully on the ground. This pronation is the result, at least in part, of the medial migration of the distal attachment of the fibularis longus across the sole of the foot and the development of a fibularis tertius that is attached to the base of the 5th metatarsal. These features are unique to the human foot.

Injury to Common Fibular Nerve and Footdrop



Because of its superficial position, *the common fibular is the nerve most often injured in the lower limb*, mainly because it winds subcutaneously around the fibular neck, leaving it vulnerable to direct trauma. This nerve may also be severed during fracture of the fibular neck or severely stretched when the knee joint is injured or dislocated.

Severance of the common fibular nerve results in flaccid paralysis of all muscles in the anterior and lateral compartments of the leg (dorsiflexors of ankle and evertors of foot). The loss of dorsiflexion of the ankle causes **footdrop**, which is further exacerbated by unopposed inversion of the foot. This has the effect of making the limb “too long”: The toes do not clear the ground during the swing phase of walking (Fig. B5.20A).

There are several other conditions that may result in a lower limb that is “too long” functionally, for example, pelvic tilt (see Fig. B5.18C) and spastic paralysis or contraction of the soleus. There are at least three means of compensating for this problem:

1. A *waddling gait*, in which the individual leans to the side opposite the long limb, “hiking” the hip (Fig. B5.20B).
2. A *swing-out gait*, in which the long limb is swung out laterally (abducted) to allow the toes to clear the ground (Fig. B5.20C).
3. A high-stepping *steppage gait*, in which extra flexion is employed at the hip and knee to raise the foot as high as necessary to keep the toes from hitting the ground (Fig. B5.20D).

Because the dropped foot makes it difficult to make the heel strike the ground first as in a normal gait, a steppage gait is commonly employed in the case of flaccid paralysis. Sometimes an extra “kick” is added as the free limb swings forward

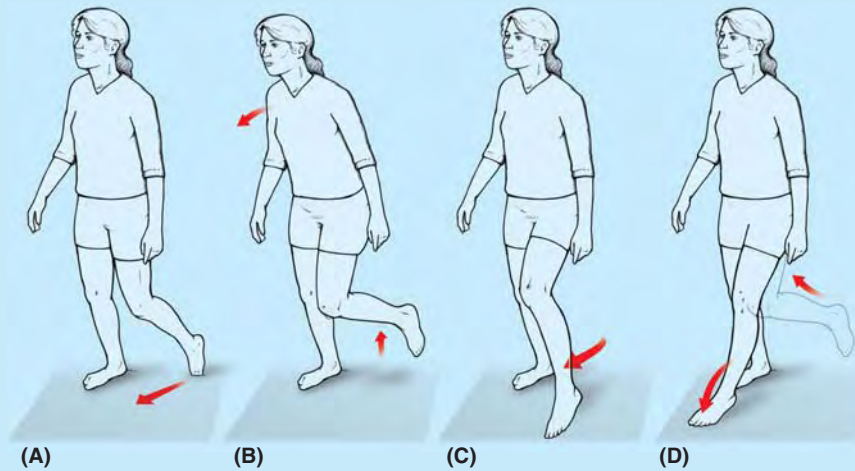



FIGURE B5.20.

in an attempt to flip the forefoot upward just before setting the foot down.


The braking action normally produced by eccentric contraction of the dorsiflexors is also lost in flaccid paralysis foot-drop. Therefore, the foot is not lowered to the ground in a controlled manner after heel strike; instead the foot slaps the ground suddenly, producing a distinctive *clop* and greatly increasing the shock both received by the forefoot and transmitted up the tibia to the knee. Individuals with a common fibular nerve injury may also experience a variable loss of sensation on the anterolateral aspect of the leg and the dorsum of the foot.

Deep Fibular Nerve Entrapment

 Excessive use of muscles supplied by the deep fibular nerve (e.g., during skiing, running, and dancing) may result in muscle injury and edema in the anterior compartment. This entrapment may cause compression of the deep fibular nerve and pain in the anterior compartment.

Compression of the nerve by tight-fitting ski boots, for example, may occur where the nerve passes deep to the inferior extensor retinaculum and the EHB (see Fig 5.54A). Pain occurs in the dorsum of the foot and usually radiates to the web space between the 1st and 2nd toes. Because ski boots are a common cause of this type of nerve entrapment, this condition has been called the “ski boot syndrome”; however, the syndrome also occurs in soccer players and runners and can also result from tight shoes.

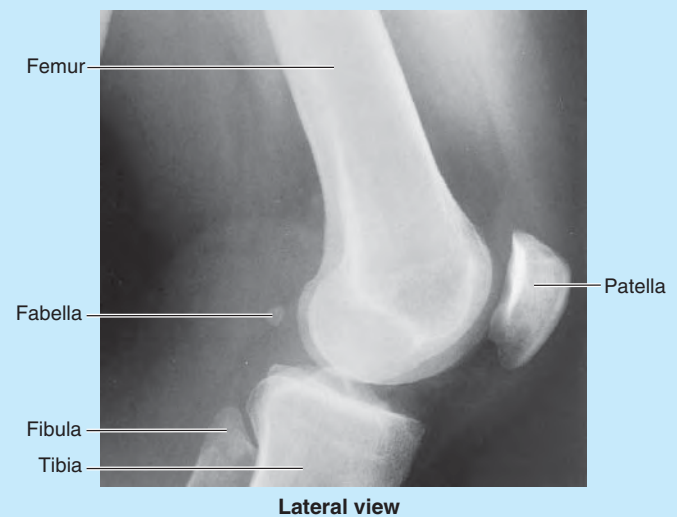
Superficial Fibular Nerve Entrapment

 Chronic ankle sprains may produce recurrent stretching of the superficial fibular nerve, which may cause pain along the lateral side of the leg and the dorsum of the ankle and foot. Numbness and *paresthesia* (tickling or tingling) may be present and increase with activity.

Fabella in Gastrocnemius




Close to its proximal attachment, the lateral head of the gastrocnemius contains a sesamoid bone, the *fabella* (L., bean), which articulates with the lateral femoral condyle and is visible in lateral radiographs of the knee in 3–5% of people (Fig. B5.21).



Lateral view


FIGURE B5.21.

Calcaneal Tendinitis

 Inflammation of the calcaneal tendon constitutes 9–18% of running injuries. Microscopic tears of collagen fibers in the tendon, particularly just superior to its attachment to the calcaneus, result in *tendinitis*, which causes pain during walking, especially when wearing rigid-soled shoes. Calcaneal tendinitis often occurs during repetitive activities, especially in individuals who take up running

after prolonged inactivity or suddenly increase the intensity of their training, but it may also result from poor footwear or training surfaces.


Ruptured Calcaneal Tendon

 Rupture of the calcaneal tendon is often sustained by poorly conditioned people with a history of *calcaneal tendinitis*. The injury is typically experienced as an audible snap during a forceful push off (plantarflexion with the knee extended) followed immediately by sudden calf pain and sudden dorsiflexion of the plantarflexed foot. In a completely ruptured tendon, a gap is palpable, usually 1–5 cm proximal to the calcaneal attachment. The muscles affected are the gastrocnemius, soleus, and plantaris.

Calcaneal tendon rupture is probably the most severe acute muscular problem of the leg. Individuals with this injury cannot plantarflex against resistance (cannot raise the heel from the ground or balance on the affected side), and passive dorsiflexion (usually limited to 20° from neutral) is excessive.

Ambulation is possible only when the limb is laterally (externally) rotated, rolling over the transversely placed foot during the stance phase without push off. Bruising appears in the malleolar region, and a lump usually appears in the calf owing to shortening of the triceps surae. In older or non-athletic people, non-surgical repairs are often adequate, but surgical intervention is usually advised for those with active lifestyles.

Calcaneal Tendon Reflex

 The ankle jerk reflex, or triceps surae reflex, is a **calcaneal tendon reflex**. It is a myotatic reflex elicited while the person's legs are dangling over the side of the examining table. The calcaneal tendon is struck briskly with a reflex hammer just proximal to the calcaneus (Fig. B5.22). The normal result is plantarflexion of the ankle joint. *The calcaneal tendon reflex tests the S1 and S2 nerve roots*. If the S1 nerve root is injured or compressed, the ankle reflex is virtually absent.

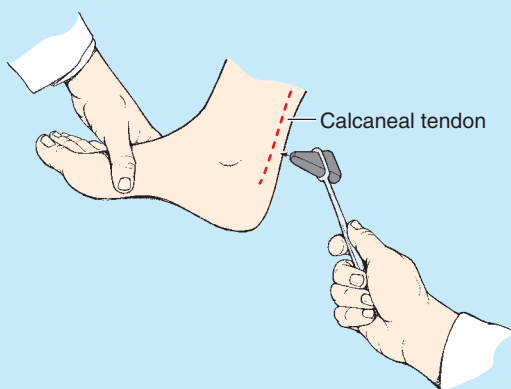




FIGURE B5.22.


Absence of Plantarflexion

 If the muscles of the calf are paralyzed, the calcaneal tendon is ruptured, or normal push off is painful, a much less effective and efficient push off (from the midfoot) can still be accomplished by the actions of the gluteus maximus and hamstrings in extending the thigh at the hip joint and the quadriceps in extending the knee. Because push off from the forefoot is not possible (in fact, the ankle will be passively dorsiflexed as the body's weight moves anterior to the foot), those attempting to walk in the absence of plantarflexion often rotate the foot as far laterally (externally) as possible during the stance phase to disable passive dorsiflexion and allow a more effective push off through hip and knee extension exerted at the midfoot.

Gastrocnemius Strain

 *Gastrocnemius strain* (tennis leg) is a painful acute injury resulting from partial tearing of the medial belly of the gastrocnemius at or near its musculotendinous junction, often seen in individuals older than 40 years of age. It is caused by overstretching the muscle by concomitant full extension of the knee and dorsiflexion of the ankle joint. Usually, an abrupt onset of stabbing pain is followed by edema and spasm of the gastrocnemius.

Calcaneal Bursitis

 *Calcaneal bursitis* (retroachilles bursitis) results from inflammation of the deep bursa of the calcaneal tendon located between the calcaneal tendon and the superior part of the posterior surface of the calcaneus (Fig. B5.23). Calcaneal bursitis causes pain posterior to the heel and occurs quite commonly during long-distance running, basketball, and tennis. It is caused by excessive friction on the bursa as the tendon continuously slides over it.

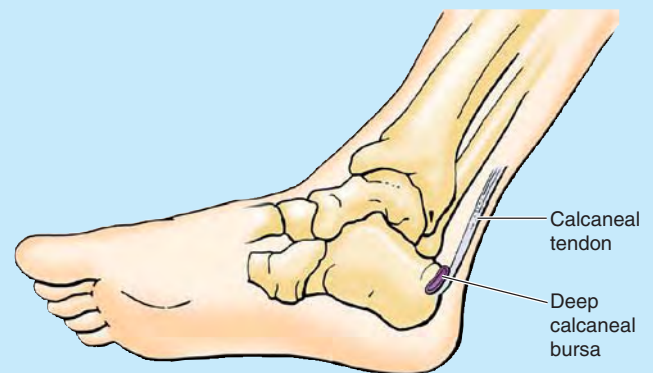



FIGURE B5.23.

Venous Return From Leg

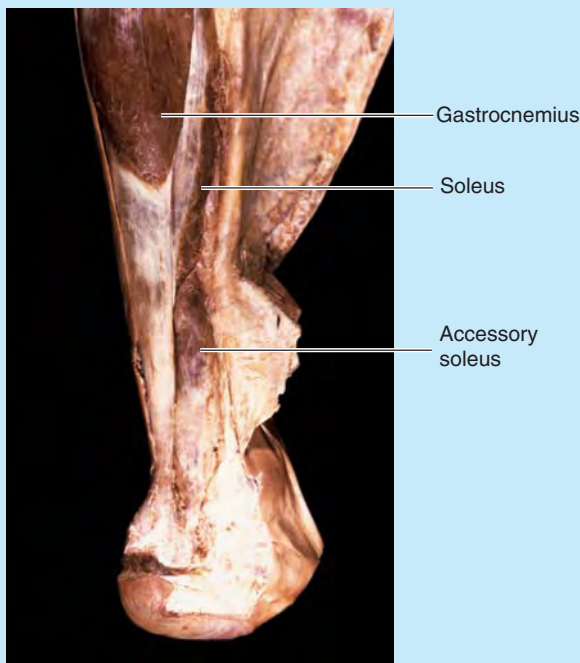
 A venous plexus deep to the triceps surae is involved in the return of blood from the leg. When a person is standing, the venous return from the leg depends

largely on the muscular activity of the triceps surae (see “Venous Drainage of Lower Limb,” p. 532). Contraction of the calf muscles pumps blood superiorly in the deep veins. The efficiency of the calf pump is improved by the deep fascia that invests the muscles like an elastic stocking.

Accessory Soleus



An accessory soleus is present in approximately 3% of people (Fig. B5.24). The accessory muscle usually appears as a distal belly medial to the calcaneal tendon. Clinically, an accessory soleus may be associated with pain and edema during prolonged exercise.



Posterior view

FIGURE B5.24.

Posterior Tibial Pulse



The posterior tibial pulse can usually be palpated between the posterior surface of the medial malleolus and the medial border of the calcaneal tendon (Fig. B5.25). Because the posterior tibial artery passes deep to the flexor retinaculum, it is important when palpating this pulse to have the person invert the foot to relax the retinaculum. Failure to do so may lead to the erroneous conclusion that the pulse is absent.

Both arteries are examined simultaneously for equality of force. Palpation of the posterior tibial pulses is essential for examining patients with occlusive *peripheral arterial disease*. Although posterior tibial pulses are absent in approximately 15% of normal young people, absence of posterior tibial pulses is a sign of occlusive peripheral arterial disease in people older than 60 years. For example, *intermittent claudication*, characterized by leg pain and cramps, develops during walking and disappears after rest. These conditions result from ischemia of the leg muscles caused by narrowing or occlusion of the leg arteries.

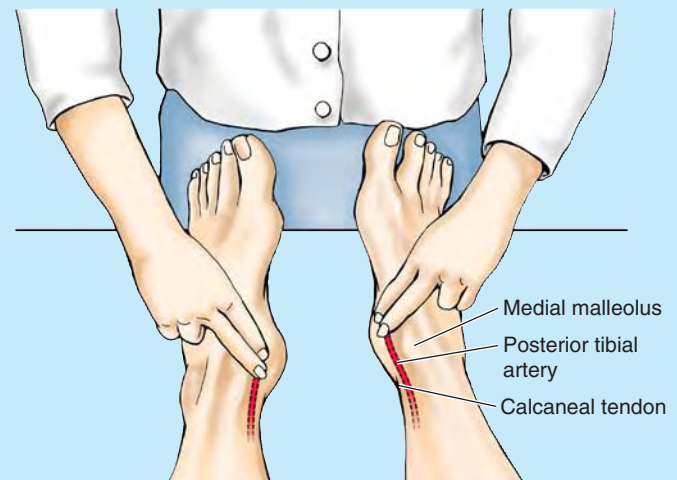


FIGURE B5.25.

The Bottom Line

POPLITEAL FOSSA AND LEG

Popliteal fossa: The popliteal fossa is a fat-filled and relatively confined compartment posterior to the knee that is traversed by all neurovascular structures passing between the thigh and the leg. ♦ The sciatic nerve bifurcates at the apex of the fossa, with the common fibular nerve passing laterally along the biceps tendon. ♦ The tibial nerve, popliteal vein, and popliteal artery bisect the fossa—in that order, from superficial (posterior) to deep (anterior). ♦ Genicular branches of the popliteal artery form a periarticular genicular anastomosis around the knee, providing collateral circulation to maintain blood flow in all positions of the knee.

Anterior compartment of leg: The anterior compartment, confined by mostly unyielding bones and membranes, is susceptible to compartment syndromes. ♦ The contained muscles are ankle dorsiflexors/toe extensors that are active in walking as they (1) concentrically contract to raise the forefoot to clear the ground during the swing phase of the gait cycle and (2) eccentrically contract to lower the forefoot to the ground after the heel strike of the stance phase. ♦ The deep fibular nerve and anterior tibial artery course within and supply the anterior compartment. ♦ Injury of the common or deep fibular nerve results in **footdrop**.

Lateral compartment of leg: The small lateral compartment contains the primary evertors of the foot and the superficial fibular nerve that supplies them. ♦ Because no artery courses within the compartment, perforating branches from the anterior tibial and fibular arteries (and their accompanying veins) penetrate the intermuscular septa to supply (and drain) blood. ♦ Eversion is used to support/depress the medial foot during the toe off of the stance phase and to resist inadvertent inversion, preventing injury.

Posterior compartment of leg: The posterior or plantar-flexor compartment is subdivided by the transverse intermuscular septum into superficial and deep subcompartments. ♦ In the superficial subcompartment, the gastrocnemius and

soleus muscles (triceps surae) share a common tendon (the calcaneal tendon, the body's strongest tendon). ♦ The triceps surae provides the power of plantarflexion that propels the body in walking and plays a major role in running and jumping via push off. ♦ The deep muscles in the posterior compartment augment the plantar flexor action through flexion of the digits and support of the longitudinal arches of the foot. ♦ The contents of the posterior compartment are supplied by the tibial nerve and two arteries, the (medial) posterior tibial and fibular arteries. ♦ All three structures (tibial nerve and two arteries) course within the confined deep subcompartment, where swelling may have profound consequences for the entire posterior compartment, the distal lateral compartment, and the foot.

FOOT

The clinical importance of the *foot* is indicated by the considerable amount of time primary care physicians devote to foot problems. *Podiatry* is the specialized field that deals with the study and care of the feet.

The *ankle* refers to the narrowest and malleolar parts of the distal leg, proximal to the dorsum and heel of the foot, including the ankle joint. The foot, distal to the ankle, pro-

vides a platform for supporting the body when standing and has an important role in locomotion.

The *skeleton of the foot* consists of 7 *tarsals*, 5 *metatarsals*, and 14 *phalanges* (Fig. 5.66). The foot and its bones may be considered in terms of three anatomical and functional zones (see Fig. 5.11C):

- The **hindfoot:** talus and calcaneus.
- The **midfoot:** navicular, cuboid, and cuneiforms.
- The **forefoot:** metatarsals and phalanges.

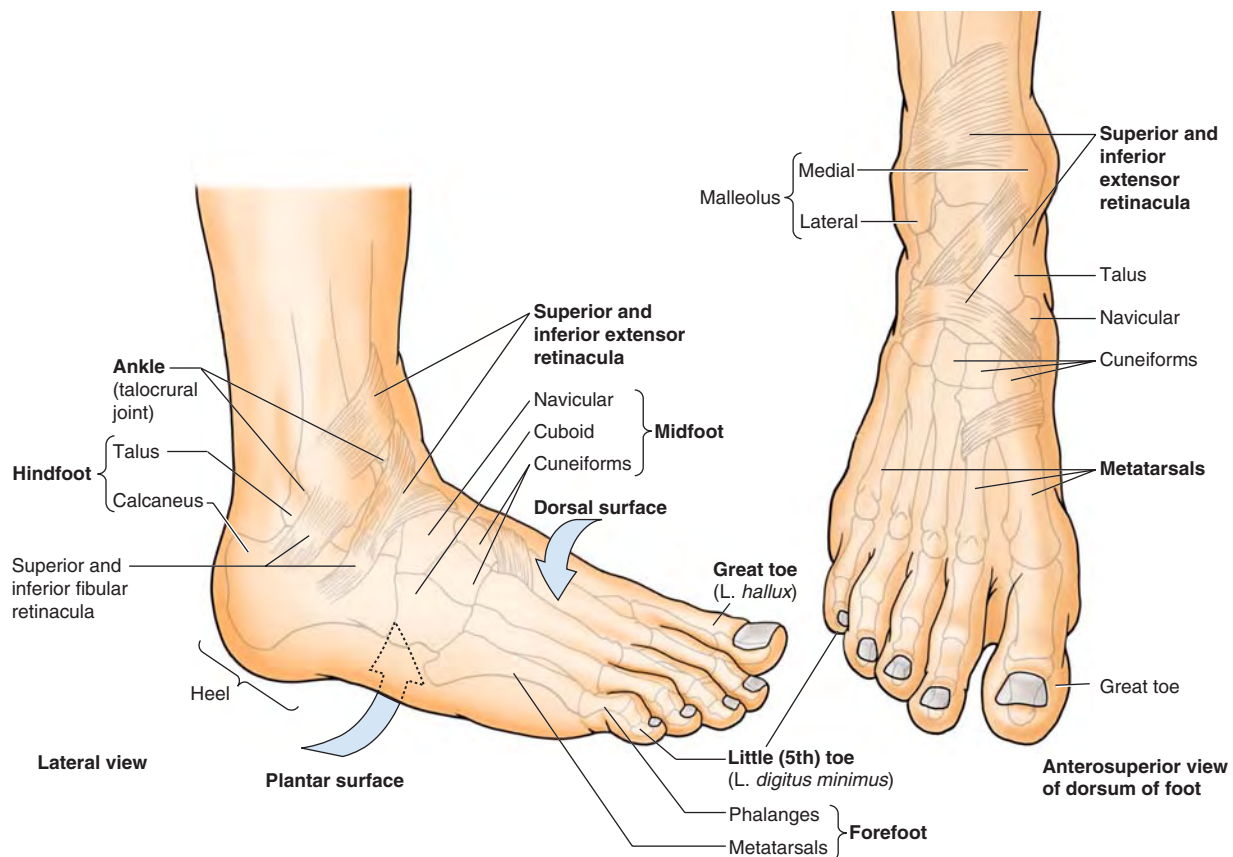


FIGURE 5.66. Surfaces, parts, bones, and retinacula of ankle and foot. The disposition of the bones of the foot and the superior and inferior extensor and fibular retinacula relative to surface features are demonstrated.

The part/region of the foot contacting the floor or ground is the **sole** (L. *planta*) or *plantar region* (L. *regio plantaris*). The part directed superiorly is the *dorsum of the foot* (L. *dorsum pedis*) or **dorsal region of the foot** (L. *regio dorsalis pedis*). The sole of the foot underlying the calcaneus is the *heel* or **heel region** (L. *regio calcanea*), and the sole underlying the heads of the medial two metatarsals is the **ball of the foot**. The **great toe** (L. *hallux*) is also the **1st toe** (digit of foot, L. *digitus primus*), and the **little toe** (L. *digitus minimus*) is also the **5th toe**.

Skin and Fascia of Foot

Marked variations occur in the thickness (strength) and texture of skin, subcutaneous tissue (superficial fascia), and deep fascia in relationship to weight-bearing and distribution, ground contact (grip, abrasion), and the need for containment or compartmentalization.

SKIN AND SUBCUTANEOUS TISSUE

The *skin of the dorsum of the foot* is much thinner and less sensitive than skin on most of the sole. The *subcutaneous tissue* is loose deep to the dorsal skin; therefore, *edema* (G. *oidēma*, a swelling) is most marked over this surface, especially anterior to and around the medial malleolus. The skin over the major weight-bearing areas of the sole—the heel, lateral margin, and ball of the foot—is thick. The subcutaneous tissue in the sole is more fibrous than in other areas of the foot.

Fibrous septa—highly developed *skin ligaments* (retinacula cutis)—divide this tissue into fat-filled areas, making it a shock-absorbing pad, especially over the heel. The skin ligaments also anchor the skin to the underlying deep fascia (plantar aponeurosis), improving the “grip” of the sole. The skin of the sole is hairless and sweat glands are numerous; the entire sole is sensitive (“ticklish”), especially the thinner-skinned area underlying the arch of the foot.

DEEP FASCIA OF FOOT

The *deep fascia of the dorsum of the foot* is thin where it is continuous proximally with the *inferior extensor retinaculum* (Fig. 5.67A). Over the lateral and posterior aspects of the foot, the deep fascia is continuous with the **plantar fascia**, the deep fascia of the sole (Fig. 5.67B & C). The plantar fascia has a thick central part and weaker medial and lateral parts.

The thick, central part plantar fascia forms the strong *plantar aponeurosis*, longitudinally arranged bundles of dense fibrous connective tissue investing the central plantar muscles. It resembles the palmar aponeurosis of the palm of the hand but is tougher, denser, and elongated.

The plantar fascia holds the parts of the foot together, helps protect the sole from injury, and helps support the longitudinal arches of the foot.

The **plantar aponeurosis** arises posteriorly from the calcaneus and functions like a superficial ligament. Distally, the longitudinal bundles of collagen fibers of the aponeurosis

divide into five bands that become continuous with the **fibrous digital sheaths** that enclose the flexor tendons that pass to the toes. At the anterior end of the sole, inferior to the heads of the metatarsals, the aponeurosis is reinforced by transverse fibers forming the **superficial transverse metatarsal ligament**.

In the midfoot and forefoot, vertical *intermuscular septa* extend deeply (superiorly) from the margins of the plantar aponeurosis toward the 1st and 5th metatarsals, forming the three *compartments of the sole* (Fig. 5.67C):

1. The **medial compartment of the sole** is covered superficially by thinner *medial plantar fascia*. It contains the abductor hallucis, flexor hallucis brevis, the tendon of the flexor hallucis longus, and the medial plantar nerve and vessels.
2. The **central compartment of the sole** is covered superficially by the dense *plantar aponeurosis*. It contains the flexor digitorum brevis, the tendons of the flexor hallucis longus and flexor digitorum longus plus the muscles associated with the latter, the quadratus plantae and lumbricals, and the adductor hallucis. The lateral plantar nerve and vessels are also located here.
3. The **lateral compartment of the sole** is covered superficially by the thinner *lateral plantar fascia* and contains the abductor and flexor digiti minimi brevis.

In the forefoot only, a fourth compartment, the **interosseous compartment of the foot**, is surrounded by the plantar and dorsal interosseous fascias. It contains the metatarsals, the dorsal and plantar interosseous muscles, and the deep plantar and metatarsal vessels. Whereas the plantar interossei and plantar metatarsal vessels are distinctly plantar in position, the remaining structures of the compartment are located intermediate between the plantar and dorsal aspects of the foot.

A fifth compartment, the **dorsal compartment of the foot**, lies between the dorsal fascia of the foot and the tarsal bones and the dorsal interosseous fascia of the midfoot and forefoot. It contains the muscles (extensors hallucis brevis and extensor digitorum brevis) and neurovascular structures of the dorsum of the foot.

Muscles of Foot

Of the 20 individual muscles of the foot, 14 are located on the plantar aspect, 2 are on the dorsal aspect, and 4 are intermediate in position. From the plantar aspect, muscles of the sole are arranged in four layers within four compartments. The muscles of the foot are illustrated in Figures 5.68A–J and 5.69, and their attachments, innervation, and actions are described in Table 5.14.

Despite their compartmental and layered arrangement, the plantar muscles function primarily as a group during the support phase of stance, maintaining the arches of the foot (see Fig. 5.20B–E; Table 5.2). They basically resist forces that tend to reduce the longitudinal arch as weight is received at the heel (posterior end of the arch) and then transferred to the ball of the foot and great toe (anterior end of the arch).

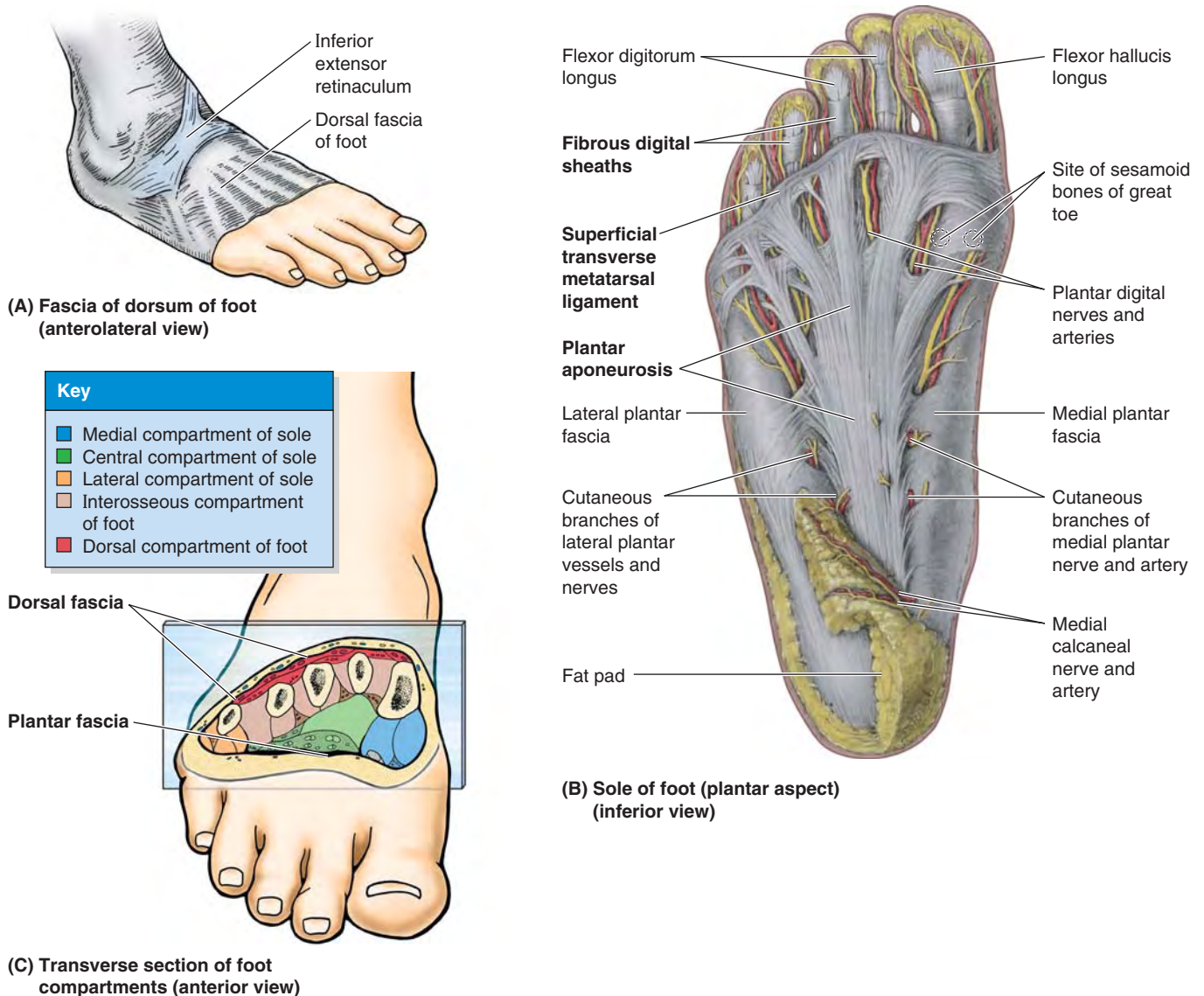


FIGURE 5.67. Fascia and compartments of foot. **A.** The skin and subcutaneous tissue have been removed to demonstrate the deep fascia of the leg and dorsum of the foot. **B.** The deep plantar fascia consists of the thick plantar aponeurosis and the thinner medial and lateral plantar fascia. Thinner parts of the plantar fascia have been removed, revealing the plantar digital vessels and nerves. **C.** The bones and muscles of the foot are surrounded by the deep dorsal and plantar fascia. A large central and smaller medial and lateral compartments of the sole are created by intermuscular septa that extend deeply from the plantar aponeurosis.

The muscles become most active in the later portion of the movement to stabilize the foot for propulsion (push off), a time when forces also tend to flatten the foot's transverse arch. Concurrently, they are also able to refine further the efforts of the long muscles, producing supination and pronation in enabling the platform of the foot to adjust to uneven ground.

The muscles of the foot are of little importance individually because fine control of the individual toes is not important to most people. Rather than producing actual movement, they are most active in fixing the foot or in increasing the pressure applied against the ground by various aspects of the sole or toes to maintain balance.

Although the adductor hallucis resembles a similar muscle of the palm that adducts the thumb, despite its name the adductor hallucis is probably most active during the push-off phase of stance in pulling the lateral four metatarsals toward the great toe, fixing the transverse arch of the foot, and resisting forces that would spread the metatarsal heads as weight and force are applied to the forefoot (Table 5.2).

In Table 5.14, note that the:

- **P**lantar interossei **A**dduct (**PAD**) and arise from a single metatarsal as unipennate muscles.
- **D**orsal interossei **A**bbduct (**DAB**) and arise from two metatarsals as bipennate muscles.

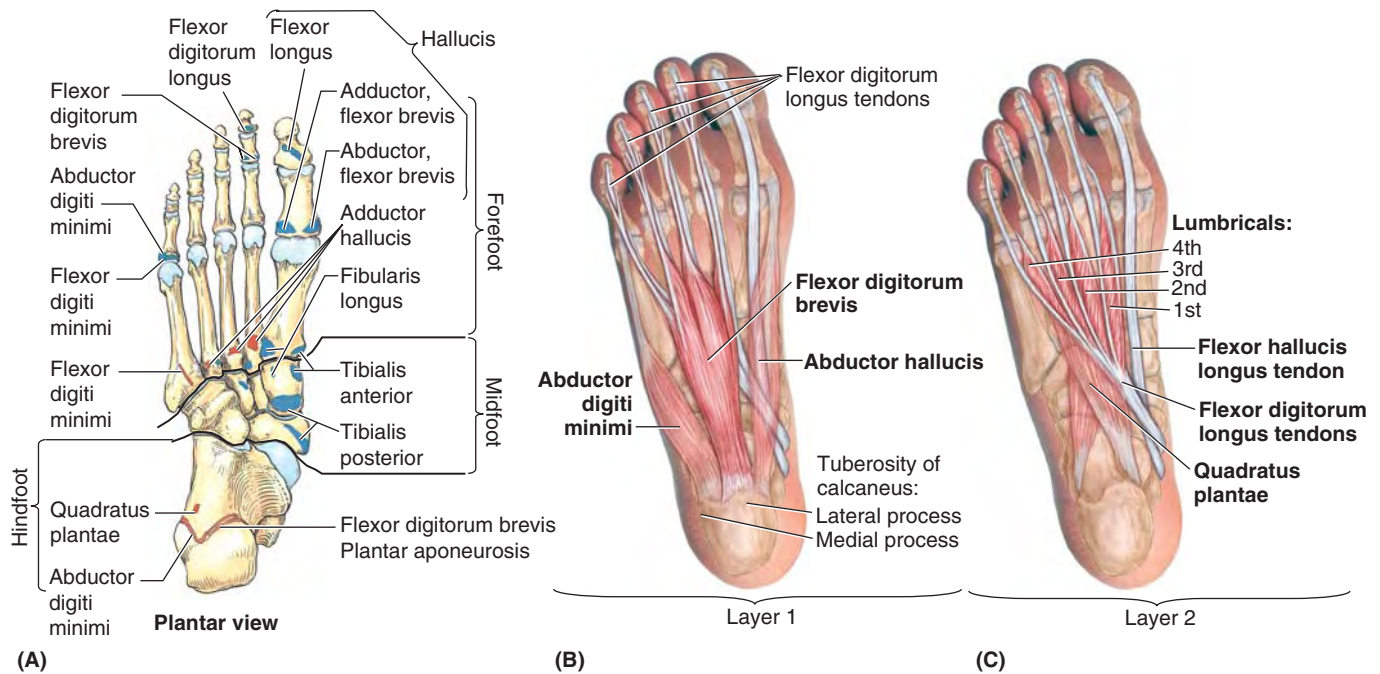


FIGURE 5.68A–C. Muscles of foot: 1st and 2nd layers of sole.

TABLE 5.14.I. MUSCLES OF FOOT: 1ST AND 2ND LAYERS OF SOLE

| Muscle | Proximal Attachment | Distal Attachment | Innervation ^a | Main Action ^b |
|-------------------------|---|--|---|--|
| 1st layer | | | | |
| Abductor hallucis | Medial tubercle of tuberosity of calcaneus; flexor retinaculum; plantar aponeurosis | Medial side of base of proximal phalanx of 1st digit | Medial plantar nerve (S2, S3) | Abducts and flexes 1st digit (great toe, hallux) |
| Flexor digitorum brevis | Medial tubercle of tuberosity of calcaneus; plantar aponeurosis; intermuscular septa | Both sides of middle phalanges of lateral four digits | Medial plantar nerve (S2, S3) | Flexes lateral four digits |
| Abductor digiti minimi | Medial and lateral tubercles of tuberosity of calcaneus; plantar aponeurosis; intermuscular septa | Lateral side of base of proximal phalanx of 5th digit | Lateral plantar nerve (S2, S3) | Abducts and flexes little toe (5th digit) |
| 2nd layer | | | | |
| Quadratus plantae | Medial surface and lateral margin of plantar surface of calcaneus | Posterolateral margin of tendon of flexor digitorum longus | Lateral plantar nerve (S2, S3) | Assists flexor digitorum longus in flexing lateral four digits |
| Lumbricals | Tendons of flexor digitorum longus | Medial aspect of expansion over lateral four digits | Medial one: medial plantar nerve (S2, S3) | Flex proximal phalanges, extend middle and distal phalanges of lateral four digits |
| | | | Lateral three: lateral plantar nerve (S2, S3) | |

^aThe spinal cord segmental innervation is indicated (e.g., “S2, S3” means that the nerves supplying the abductor hallucis are derived from the second and third sacral segments of the spinal cord). Damage to one or more of the listed spinal cord segments or to the motor nerve roots arising from them results in paralysis of the muscles concerned.

^bDespite individual actions, the primary function of the intrinsic muscles of the sole of the foot is to resist flattening or maintain the arch of the foot.

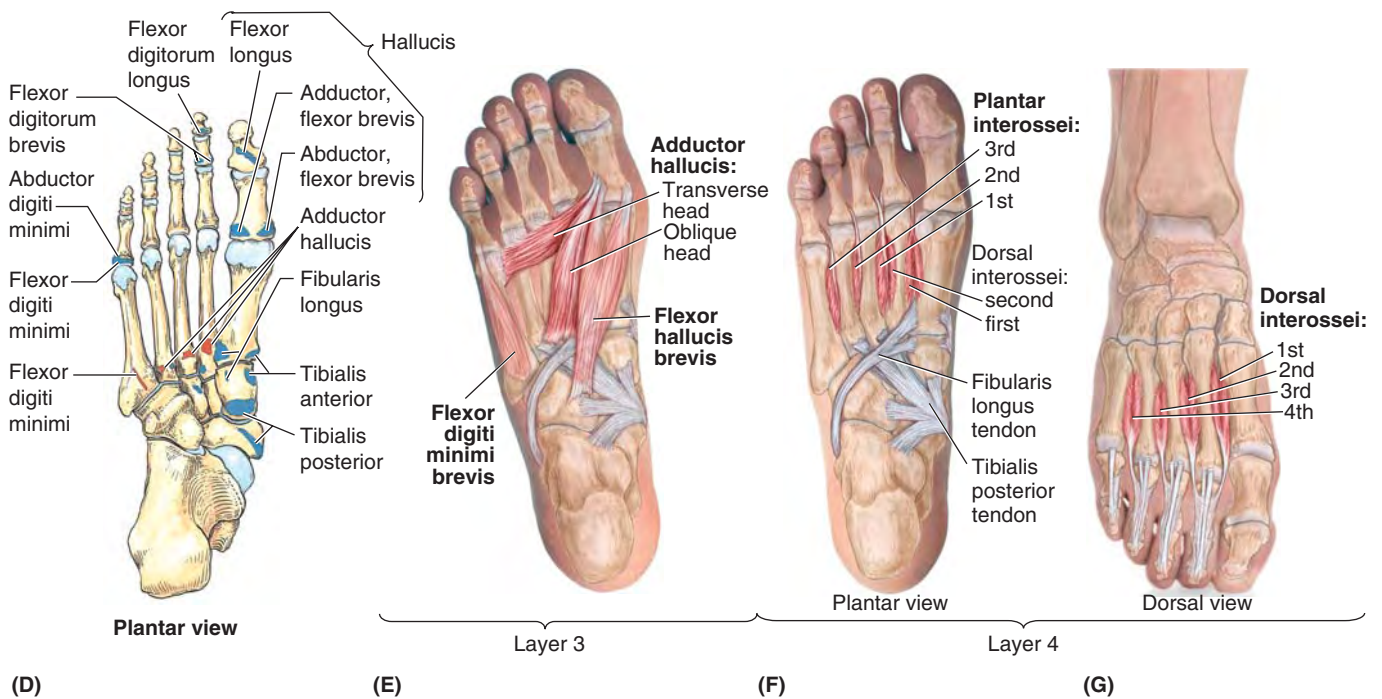


FIGURE 5.68D–G. Muscles of foot: 3rd and 4th layers of sole.

TABLE 5.14.II. MUSCLES OF FOOT: 3RD AND 4TH LAYERS OF SOLE

| Muscle | Proximal Attachment | Distal Attachment | Innervation ^a | Main Action ^b |
|------------------------------------|--|---|--|--|
| 3rd layer | | | | |
| Flexor hallucis brevis | Plantar surfaces of cuboid and lateral cuneiforms | Both sides of base of proximal phalanx of 1st digit | Medial plantar nerve (S2, S3) | Flexes proximal phalanx of 1st digit |
| Adductor hallucis | Oblique head: bases of metatarsals 2–4 | Tendons of both heads attach to lateral side of base of proximal phalanx of 1st digit | Deep branch of lateral plantar nerve (S2, S3) | Traditionally said to adduct 1st digit; assists in transverse arch of foot by metatarsals medially |
| | Transverse head: plantar ligaments of metatarsophalangeal (MTP) joints | | | |
| Flexor digiti minimi brevis | Base of 5th metatarsal | Base of proximal phalanx of 5th digit | Superficial branch of lateral plantar nerve (S2, S3) | Flexes proximal phalanx of 5th digit, thereby assisting with its flexion |
| 4th layer | | | | |
| Plantar interossei (three muscles) | Bases and medial sides of metatarsals 3–5 | Medial sides of bases of phalanges of 3rd–5th digits | Lateral plantar nerve (S2, S3) | Adduct digits (2–4) and flex metatarsophalangeal joints |
| Dorsal interossei (four muscles) | Adjacent sides of metatarsals 1–5 | 1st: medial side of proximal phalanx of 2nd digit; | Lateral plantar nerve (S2, S3) | Abduct digits (2–4) and flex metatarsophalangeal joints |
| | | 2nd–4th: lateral sides of 2nd–4th digits | | |

^a The spinal cord segmental innervation is indicated (e.g., “S2, S3” means that the nerves supplying the flexor hallucis brevis are derived from the second and third sacral segments of the spinal cord). Damage to one or more of the listed spinal cord segments or to the motor nerve roots arising from them results in paralysis of the muscles concerned.

^b Despite individual actions, the primary function of the intrinsic muscles of the sole of the foot is to resist flattening or maintain the arch of the foot.

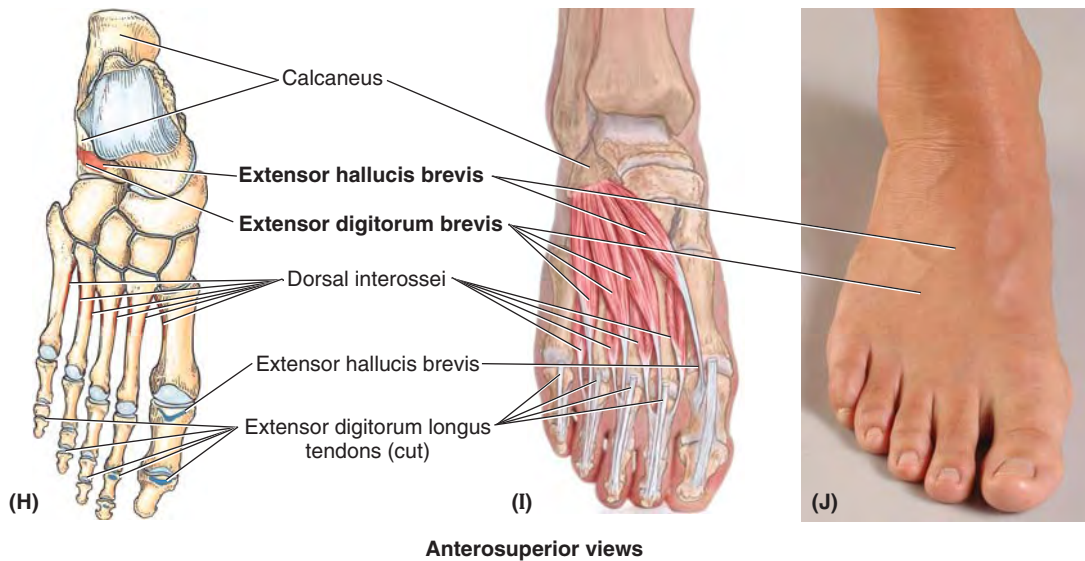


FIGURE 5.68H–J. Muscles of foot: dorsum of foot.

TABLE 5.14.III. MUSCLES OF FOOT: DORSUM OF FOOT

| Muscle | Proximal Attachment | Distal Attachment | Innervation ^a | Main Action |
|---------------------------|---|--|--|--|
| Extensor digitorum brevis | Calcaneus (floor of tarsal sinus); interosseous talocalcaneal ligament; stem of inferior extensor retinaculum | Long extensor tendons of four medial digits (toes 2–4) | Deep fibular nerve (L5 or S1, or both) | Aids the extensor digitorum longus in extending the four medial toes at the metatarsophalangeal and interphalangeal joints |
| Extensor hallucis brevis | In common with extensor digitorum brevis (above) | Dorsal aspect of base of proximal phalanx of great toe (digit 1) | | Aids the extensor hallucis longus in extending the great toe at the metatarsophalangeal joint |

^aThe spinal cord segmental innervation is indicated (e.g., “L5 or S1” means that the nerve supplying the extensor digitorum brevis is derived from either the fifth lumbar segment or first sacral segment of the spinal cord). Damage to one or more of the listed spinal cord segments or to the motor nerve roots arising from them results in paralysis of the muscles concerned.

There are two neurovascular planes between the muscle layers of the sole of the foot (Figs. 5.69 and 5.70B): (1) a superficial one between the 1st and the 2nd muscular layers and (2) a deep one between the 3rd and the 4th muscular layers. The *tibial nerve* divides posterior to the medial malleolus into the *medial* and *lateral plantar nerves* (Figs. 5.61B, 5.71, and 5.72; Table 5.15). These nerves supply the intrinsic muscles of the plantar aspect of the foot.

The medial plantar nerve courses within the medial compartment of the sole between the 1st and 2nd muscle layers. Initially, the lateral plantar artery and nerve run laterally between the muscles of the 1st and 2nd layers of plantar muscles (Figs. 5.69C and 5.70B). Their deep branches then pass medially between the muscles of the 3rd and 4th layers (Fig. 5.70B).

Two closely connected muscles on the dorsum of the foot are the **extensor digitorum brevis (EDB)** and **extensor hallucis brevis (EHB)** (Figs. 5.54A & B and 5.56A). The EHB is actually part of the EDB. These thin, broad muscles form a fleshy mass on the lateral part of the dorsum of the foot, anterior to the lateral malleolus. Its small fleshy belly may be felt when the toes are extended.

Neurovascular Structures and Relationships in Foot

NERVES OF FOOT

The cutaneous innervation of the foot is supplied (Fig. 5.72; Table 5.15):

- Medially by the *saphenous nerve*, which extends distally to the head of 1st metatarsal.
- Superiorly (dorsum of foot) by the *superficial* (primarily) and *deep fibular nerves*.
- Inferiorly (sole of foot) by the *medial and lateral plantar nerves*; the common border of their distribution extends along the 4th metacarpal and toe or digit. (This is similar to the pattern of innervation of the palm of the hand.)
- Laterally by the *sural nerve*, including part of the heel.
- Posteriorly (heel) by *medial and lateral calcaneal branches* of the tibial and sural nerves, respectively.

(text continues on p. 617)

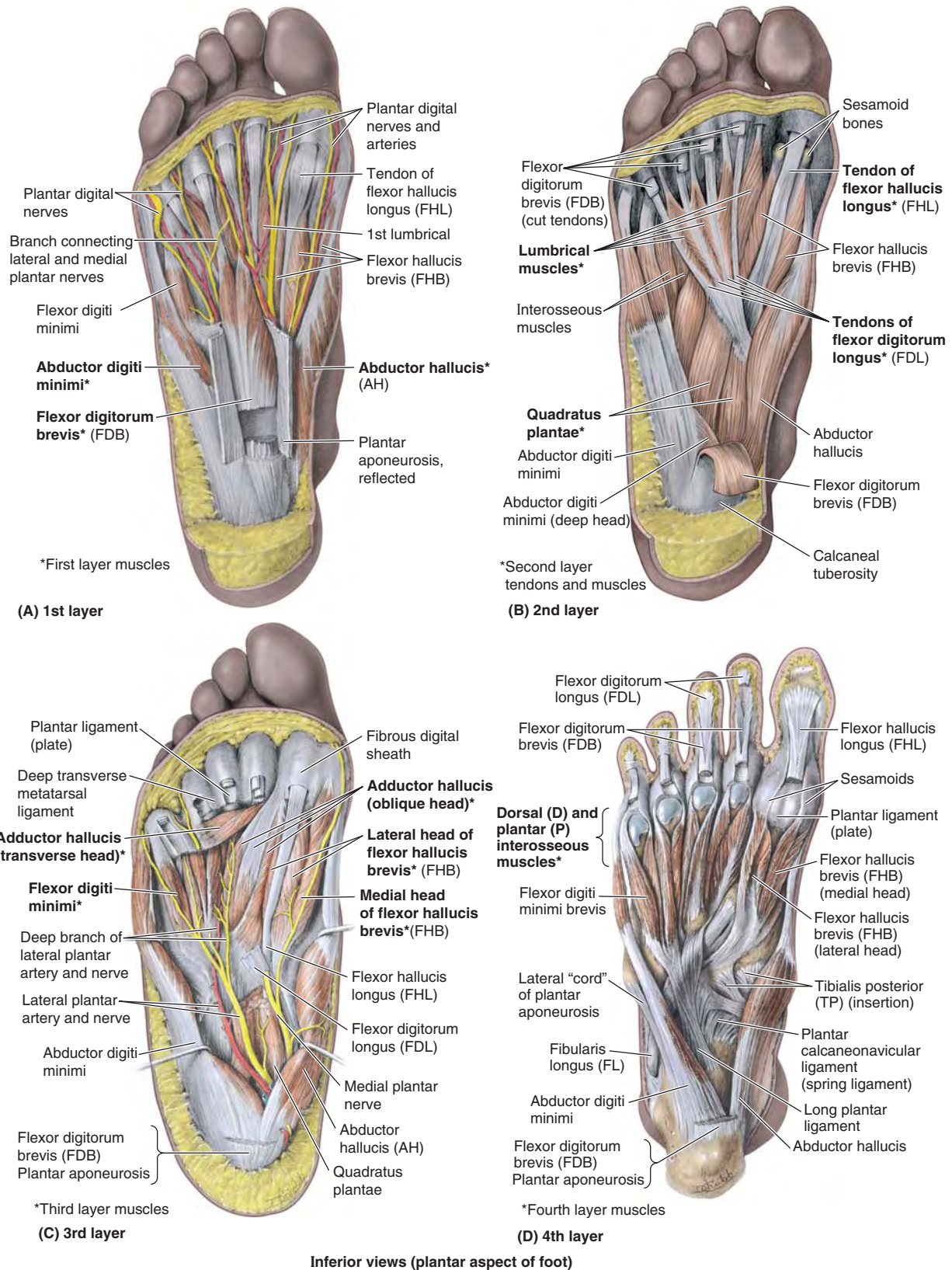


FIGURE 5.69. Layers of plantar muscles. **A.** The 1st layer consists of the abductors of the large and small toes and the short flexor of the toes. **B.** The 2nd layer consists of the long flexor tendons and associated muscles: four lumbricals and the quadratus plantae. **C.** The 3rd layer consists of the flexor of the little toe and the flexor and adductor of the great toe. Also demonstrated are the neurovascular structures that course in a plane between the 1st and 2nd layers. **D.** The 4th layer consists of the dorsal and plantar interosseous muscles.

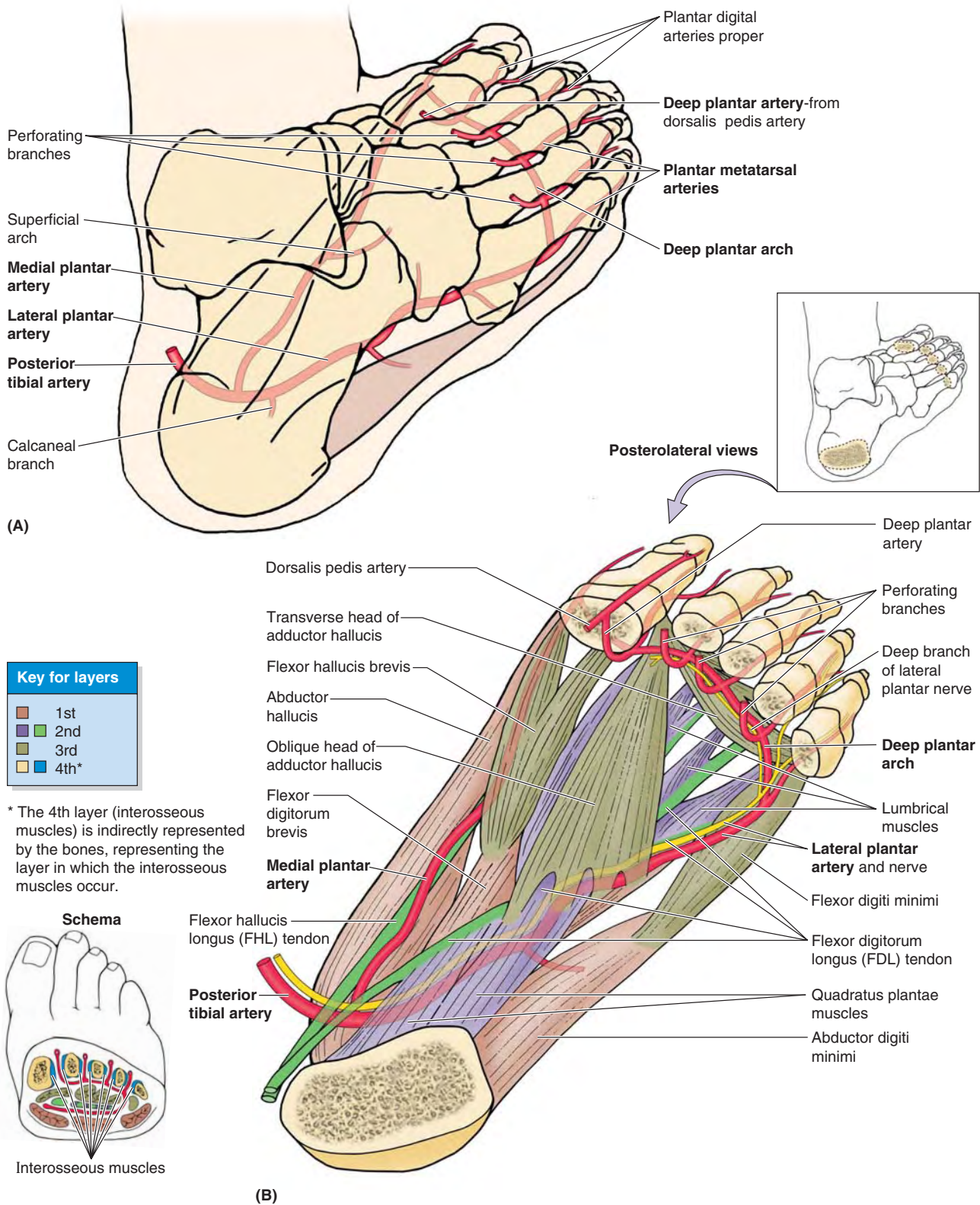


FIGURE 5.70. Arteries and muscle layers of foot. A and B. The posterior tibial artery terminates as it enters the foot by dividing into the medial and lateral plantar arteries. Observe the distal anastomoses of these vessels with the deep plantar artery from the dorsal artery of the foot and the perforating branches to the arcuate artery on the dorsum of the foot (see Fig. 5.73). Note that the plantar arteries enter and run in the plane between the 1st and the 2nd layers, with the lateral plantar artery passing from medial to lateral. The deep branches of the artery then pass from lateral to medial between the 3rd and the 4th layers.

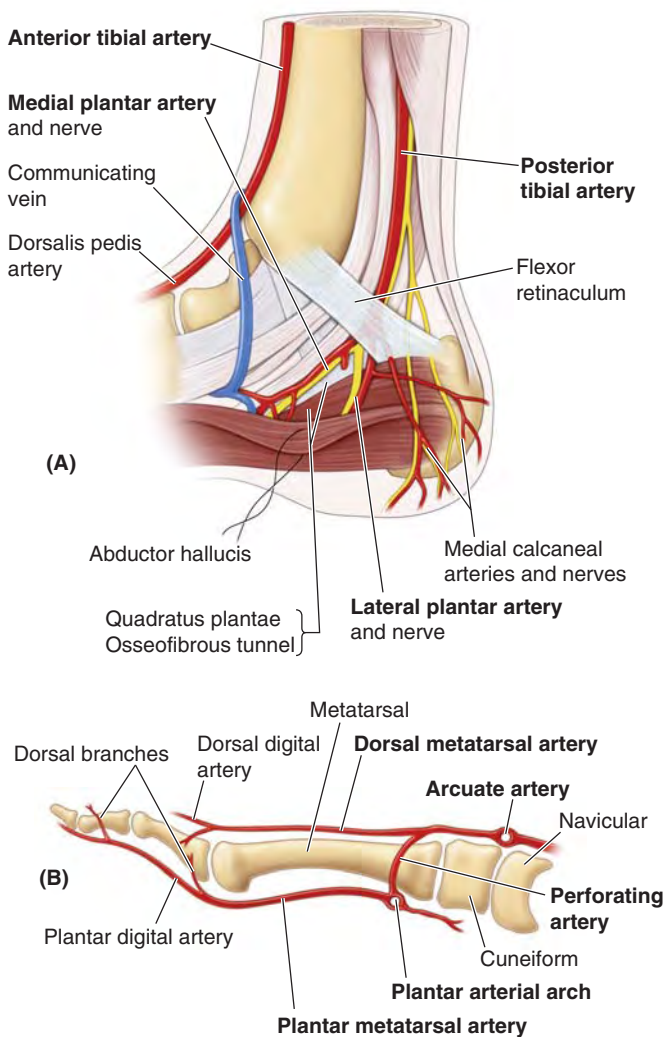


FIGURE 5.71. Arteries of foot: branching and communicating. **A.** Branching of the parent neurovascular structures that give rise to plantar vessels and nerves. **B.** The arteries of the midfoot and forefoot resemble those of the hand in that (1) arches on the two aspects give rise to metatarsal (metacarpal) arteries, which in turn give rise to digital arteries; (2) the dorsal arteries are exhausted before reaching the distal ends of the toes or digits, so the plantar (palmar) digital arteries send branches dorsally to supply the distal dorsal aspects of the digits, including the nail beds; and (3) perforating branches extend between the metatarsals (metacarpals) forming anastomoses between the arches of each side.

Saphenous Nerve. The *saphenous nerve* is the longest and most widely distributed cutaneous branch of the femoral nerve; it is the only branch to extend beyond the knee (Fig. 5.72A; Table 5.15; see also Fig. 5.74B). In addition to supplying the skin and fascia on the anteromedial aspect of the leg, the saphenous nerve passes anterior to the medial malleolus to the dorsum of the foot, where it supplies articular branches to the ankle joint and continues to supply skin along the medial side of the foot as far anteriorly as the head of the 1st metatarsal.

Superficial and Deep Fibular Nerves. After coursing between and supplying the fibular muscles in the lateral compartment of the leg, the *superficial fibular nerve* emerges as a cutaneous nerve about two thirds of the way down the leg. It then supplies the skin on the anterolateral aspect of the leg and

divides into the **medial** and **intermediate dorsal cutaneous nerves**, which continue across the ankle to supply most of the skin on the dorsum of the foot. Its terminal branches are the dorsal digital nerves (common and proper) that supply the skin of the proximal aspect of the medial half of the great toe and that of the lateral three and a half digits.

After supplying the muscles of the anterior compartment of the leg, the *deep fibular nerve* passes deep to the extensor retinaculum and supplies the intrinsic muscles on the dorsum of the foot (extensors digitorum and hallucis longus) and the tarsal and tarsometatarsal joints. When it finally emerges as a cutaneous nerve, it is so far distal in the foot that only a small area of skin remains available for innervation: the web of skin between and contiguous sides of the 1st and 2nd toes. It innervates this area as the **1st common dorsal (and then proper dorsal) digital nerve(s)**.

Medial Plantar Nerve. The **medial plantar nerve**, the larger and more anterior of the two terminal branches of the tibial nerve, arises deep to the flexor retinaculum. It enters the sole of the foot by passing deep to the abductor hallucis (AH) (Figs. 5.69C and 5.71A). It then runs anteriorly between the AH muscle and the flexor digitorum brevis (FDB), supplying both with motor branches on the lateral side of the medial plantar artery (Fig. 5.69A & C). After sending motor branches to the flexor hallucis brevis (FHB) and 1st lumbrical muscle, the medial plantar nerve terminates near the bases of the metatarsals by dividing into three sensory branches (*common plantar digital nerves*). These branches supply the skin of the medial three and a half digits (including the dorsal skin and nail beds of their distal phalanges), and the skin of the sole proximal to them. Compared to the other terminal branch of the tibial nerve, the medial plantar nerve supplies more skin area but fewer muscles. Its distribution to both skin and muscles of the foot is comparable to that of the median nerve in the hand.

Lateral Plantar Nerve. The **lateral plantar nerve**, the smaller and more posterior of the two terminal branches of the tibial nerve, also courses deep to the AH (Fig. 5.71A) but runs anterolaterally between the 1st and 2nd layers of plantar muscles, on the medial side of the lateral plantar artery (Fig. 5.69C). The lateral plantar nerve terminates as it reaches the lateral compartment, dividing into superficial and deep branches (Fig. 5.72B; Table 5.15).

The *superficial branch* divides, in turn, into two **plantar digital nerves** (one common and one proper) that supply the skin of the plantar aspects of the lateral one and a half digits, the dorsal skin and nail beds of their distal phalanges, and skin of the sole proximal to them. The *deep branches of the lateral plantar nerve* course with the plantar arterial arch between the 3rd and the 4th muscle layers.

The superficial and deep branches supply all muscles of the sole not supplied by the medial plantar nerve. Compared to the medial plantar nerve, the lateral plantar nerve supplies less skin area but more individual muscles. Its distribution to both skin and muscles of the foot is comparable to that of the ulnar nerve in the hand (Chapter 6). The medial and lateral plantar nerves also provide innervation to the plantar aspects of all the joints of the foot.

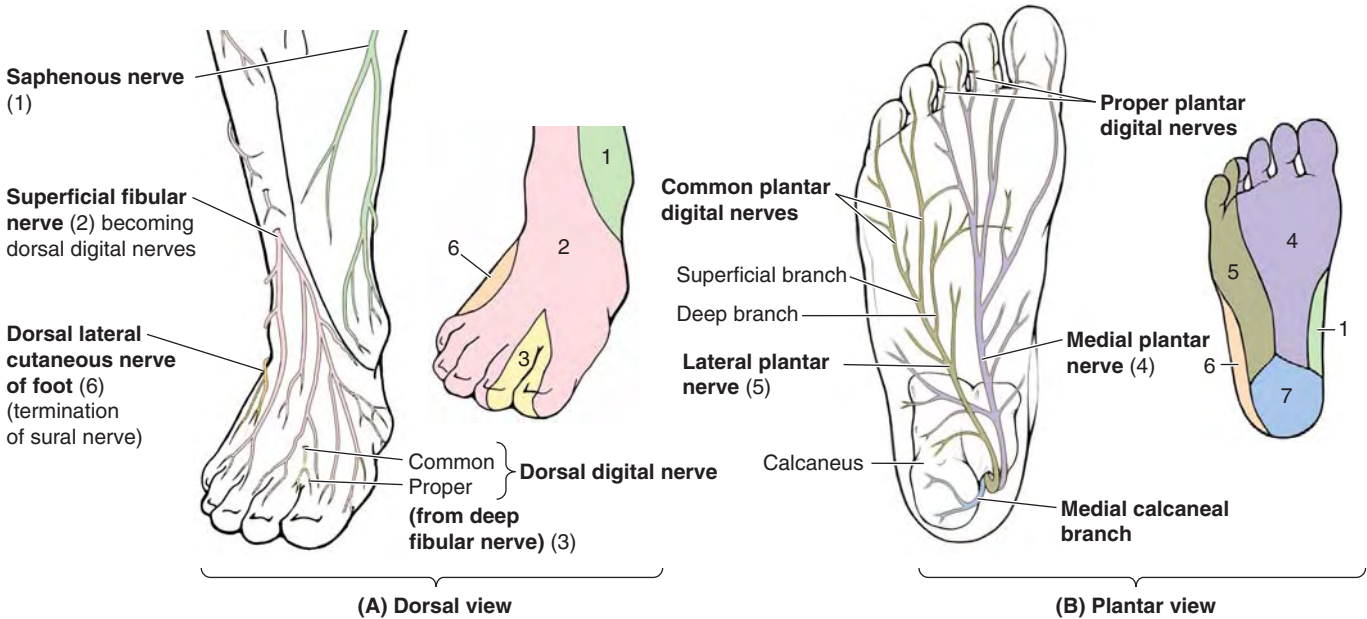


FIGURE 5.72. Nerves of foot.

TABLE 5.15. NERVES OF FOOT

| Nerve ^a | Origin | Course | Distribution in Foot |
|-------------------------|---|---|--|
| Saphenous (1) | Femoral nerve | Arises in femoral triangle and descends through thigh and leg; accompanies great saphenous vein anterior to medial malleolus; ends on medial side of foot | Supplies skin on medial side of foot as far anteriorly as head of 1st metatarsal |
| Superficial fibular (2) | Common fibular nerve | Pierces deep fascia in distal third of leg to become cutaneous; then sends branches to foot and digits | Supplies skin on dorsum of foot and all digits, except lateral side of 5th and adjoining sides of the 1st and 2nd digits |
| Deep fibular (3) | | Passes deep to extensor retinaculum to enter dorsum of foot | Supplies extensor digitorum brevis and skin on contiguous sides of 1st and 2nd digits |
| Medial plantar (4) | Larger terminal branch of tibial nerve | Passes distally in foot between abductor hallucis and flexor digitorum brevis; divides into muscular and cutaneous branches | Supplies skin of medial side of sole of foot and sides of first three digits; also supplies abductor hallucis, flexor digitorum brevis, flexor hallucis brevis, and first lumbrical |
| Lateral plantar (5) | Smaller terminal branch of tibial nerve | Passes laterally in foot between quadratus plantae and flexor digitorum brevis muscles; divides into superficial and deep branches | Supplies quadratus plantae, abductor digiti minimi, digiti minimi brevis; deep branch supplies plantar and dorsal interossei, lateral three lumbricals, and adductor hallucis; supplies skin on sole lateral to a line splitting 4th digit |
| Sural (6) | Usually arises from both tibial and common fibular nerves | Passes inferior to the lateral malleolus to lateral side of foot | Lateral aspect of hindfoot and midfoot |
| Calcaneal branches (7) | Tibial and sural nerves | Pass from distal part of the posterior aspect of leg to skin on heel | Skin of heel |

^a Numbers refer to Figure 5.72.

Sural Nerve. The **sural nerve** is formed by union of the *medial sural cutaneous nerve* (from the tibial nerve) and *sural communicating branch of the common fibular nerve*, respectively (see Fig. 5.57B; Table 5.11). The level of junction of these branches is variable; it may be high (in the popliteal fossa) or low (proximal to heel). Sometimes the branches do not join and, therefore, no sural nerve is formed. In these people, the skin normally innervated by the sural nerve is supplied by the medial and lateral sural cutaneous branches. The sural nerve accompanies the small saphenous vein and enters the foot posterior to the lateral malleolus to supply the ankle joint and skin along the lateral margin of the foot (Fig. 5.72A; Table 5.15).

ARTERIES OF FOOT

The arteries of the foot are terminal branches of the anterior and posterior tibial arteries (Figs. 5.71A and 5.73), respectively: the dorsalis pedis and plantar arteries.

Dorsalis Pedis Artery. Often a major source of blood supply to the forefoot (e.g., during extended periods of standing), the **dorsalis pedis artery** (dorsal artery of foot) is the *direct continuation of the anterior tibial artery*. The dorsalis pedis artery begins midway between the malleoli and

runs anteromedially, deep to the inferior extensor retinaculum between the extensor hallucis longus and the extensor digitorum longus tendons on the dorsum of the foot.

The dorsalis pedis artery passes to the first interosseous space, where it divides into the 1st dorsal metatarsal artery and a **deep plantar artery**. The latter passes deeply between the heads of the first dorsal interosseous muscle to enter the sole of the foot, where it joins the lateral plantar artery to form the *deep plantar arch*. The course and destination of the dorsal artery and its major continuation, the deep plantar artery, are comparable to the radial artery of the hand, which completes a deep arterial arch in the palm.

The **lateral tarsal artery**, a branch of the dorsalis pedis artery, runs laterally in an arched course beneath the EDB to supply this muscle and the underlying tarsals and joints. It anastomoses with other branches, such as the arcuate artery.

The **1st dorsal metatarsal artery** divides into branches that supply both sides of the great toe and the medial side of the 2nd toe.

The **arcuate artery** runs laterally across the bases of the lateral four metatarsals, deep to the extensor tendons, to reach the lateral aspect of the forefoot where it may anastomose with the lateral tarsal artery to form an arterial loop. The arcuate artery gives rise to the **2nd, 3rd, and 4th dorsal**

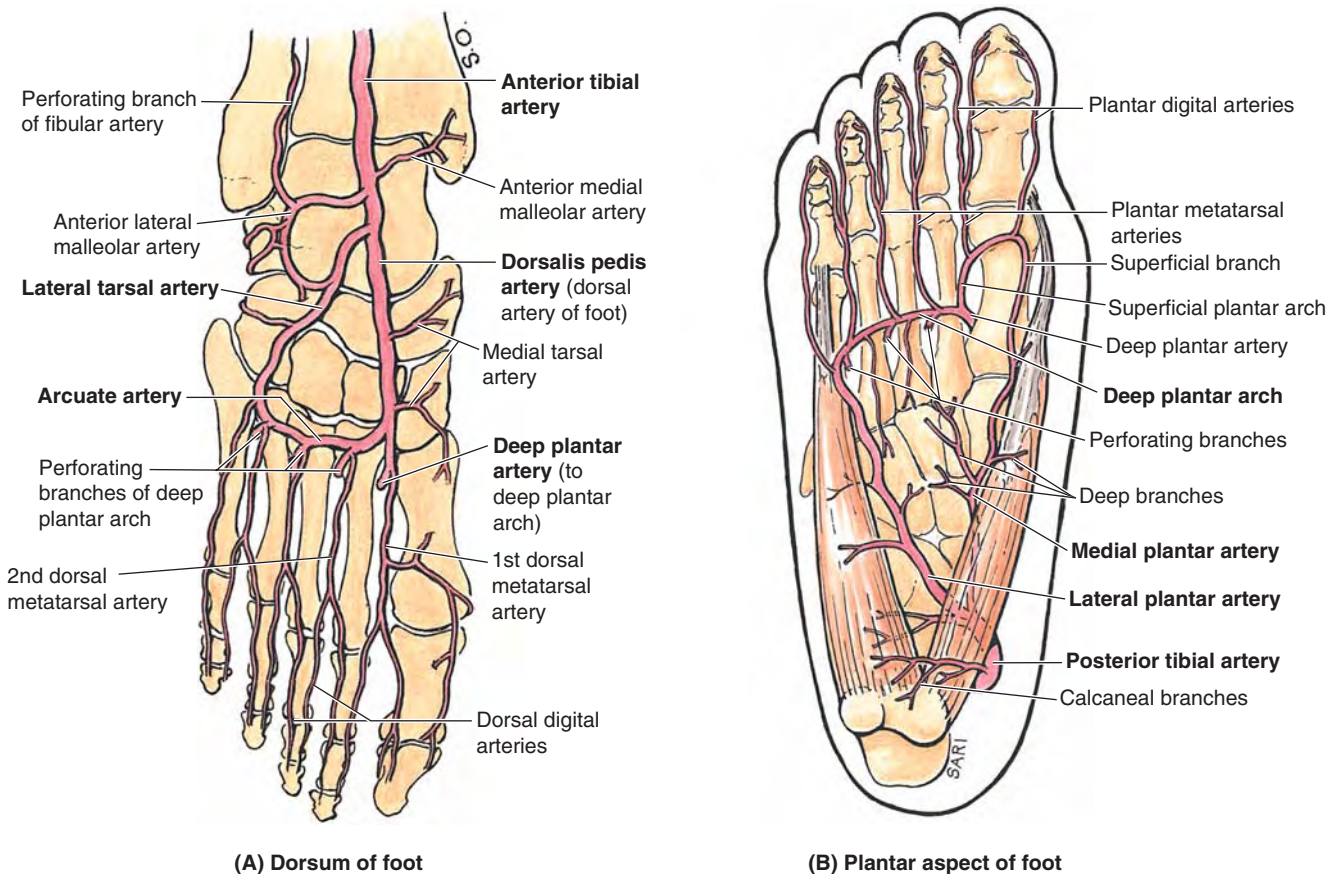


FIGURE 5.73. Arteries of foot: overview. **A.** The anterior tibial artery becomes the dorsalis pedis artery when it crosses the talocrural joint. **B.** The medial and lateral plantar arteries are terminal branches of the posterior tibial artery. The deep plantar artery and perforating branches of the deep plantar arch provide anastomoses between the dorsal and the plantar arteries.

metatarsal arteries. These vessels run distally to the clefts of the toes and are connected to the plantar arch and to the plantar metatarsal arteries by *perforating branches* (Figs. 5.70A & B, 5.71B, and 5.73A & B). Distally, each dorsal metatarsal artery divides into two **dorsal digital arteries** for the dorsal aspect of the sides of adjoining toes (Fig. 5.73A); however, these arteries generally end proximal to the distal interphalangeal joint (Fig. 5.71B) and are replaced by or receive replenishment from dorsal branches of the plantar digital arteries.

ARTERIES OF SOLE OF FOOT

The sole of the foot has a prolific blood supply that is derived from the posterior tibial artery, which divides deep to the flexor retinaculum (Figs. 5.69A, 5.71A, and 5.73B). The terminal branches pass deep to the *abductor hallucis* (AH) as the medial and lateral plantar arteries, which accompany the similarly named nerves.

Medial Plantar Artery. The **medial plantar artery** is the smaller terminal branch of the posterior tibial artery. It gives rise to a deep branch (or branches) that supplies mainly muscles of the great toe. The larger superficial branch of the medial plantar artery supplies the skin on the medial side of the sole and has digital branches that accompany digital branches of the medial plantar nerve, the more lateral of which anastomose with medial plantar metatarsal arteries. Occasionally, a **superficial plantar arch** is formed when the superficial branch anastomoses with the lateral plantar artery or the deep plantar arch.

Lateral Plantar Artery. The **lateral plantar artery**, much larger than the medial plantar artery, arises with and accompanies the nerve of the same name (Figs. 5.69C, 5.70B, 5.71A, and 5.73B). It runs laterally and anteriorly, at first deep to the AH and then between the FDB and quadratus plantae.

The lateral plantar artery arches medially across the foot with the deep branch of the lateral plantar nerve to form the **deep plantar arch**, which is completed by union with the *deep plantar artery*, a branch of the dorsalis pedis artery. As it crosses the foot, the deep plantar arch gives rise to four **plantar metatarsal arteries**; three **perforating branches**; and many branches to the skin, fascia, and muscles in the sole. The plantar metatarsal arteries divide near the base of the proximal phalanges to form the **plantar digital arteries**, supplying the adjacent digits; the more medial metatarsal arteries are joined by superficial digital branches of the medial plantar artery. The plantar digital arteries typically provide most of the blood reaching the distal toes, including the nail bed, via perforating and dorsal branches (Fig. 5.71B)—an arrangement that also occurs in the fingers.

VENOUS DRAINAGE OF FOOT

As in the rest of the lower limb, there are both superficial and deep veins in the foot. The *deep veins* take the form of interanastomosing paired veins accompanying all arteries

internal to the deep fascia (Fig. 5.74A). The *superficial veins* are subcutaneous and unaccompanied by arteries (Fig. 5.74B). Unlike the leg and thigh, however, the venous drainage of the foot is primarily to the major superficial veins, both from the deep accompanying veins and other smaller superficial veins.

Perforating veins begin the one-way shunting of blood from superficial to deep veins, a pattern essential to operation of the *musculo-venous pump*, proximal to the ankle joint. Most blood is drained from the foot through the superficial veins.

Dorsal digital veins continue proximally as **dorsal metatarsal veins**, which also receive branches from **plantar digital veins**. These veins drain to the **dorsal venous arch of the foot**, proximal to which a **dorsal venous network** covers the remainder of the dorsum of the foot. Both the arch and the network are located in the subcutaneous tissue.

For the main part, superficial veins from a **plantar venous network** either drain around the medial border of the foot to converge with the medial part of the dorsal venous arch and network to form a **medial marginal vein**, which becomes the *great saphenous vein*, or drain around the lateral margin to converge with the lateral part of the dorsal venous arch and network to form the **lateral marginal vein**, which becomes the *small saphenous vein*.

Perforating veins from the great and small saphenous veins then continuously shunt blood deeply as they ascend to take advantage of the musculo-venous pump.

LYMPHATIC DRAINAGE OF FOOT

The lymphatics of the foot begin in subcutaneous plexuses. The collecting vessels consist of superficial and deep lymphatic vessels that follow the superficial veins and major vascular bundles, respectively.

Superficial lymphatic vessels are most numerous in the sole. The *medial superficial lymphatic vessels*, larger and more numerous than the lateral ones, drain the medial side of the dorsum and sole of the foot (Fig. 5.75A). These vessels converge on the *great saphenous vein* and accompany it to the vertical group of *superficial inguinal lymph nodes*, located along the vein's termination, and then to the *deep inguinal lymph nodes* along the proximal femoral vein. The *lateral superficial lymphatic vessels* drain the lateral side of the dorsum and sole of the foot. Most of these vessels pass posterior to the lateral malleolus and accompany the small saphenous vein to the popliteal fossa, where they enter the *popliteal lymph nodes*.

The *deep lymphatic vessels* from the foot follow the main blood vessels: fibular, anterior and posterior tibial, popliteal, and femoral veins. The deep vessels from the foot also drain into the popliteal lymph nodes. Lymphatic vessels from them follow the femoral vessels, carrying lymph to the deep inguinal lymph nodes. From the deep inguinal nodes, all lymph from the lower limb passes deep to the inguinal ligament to the *iliac lymph nodes*.

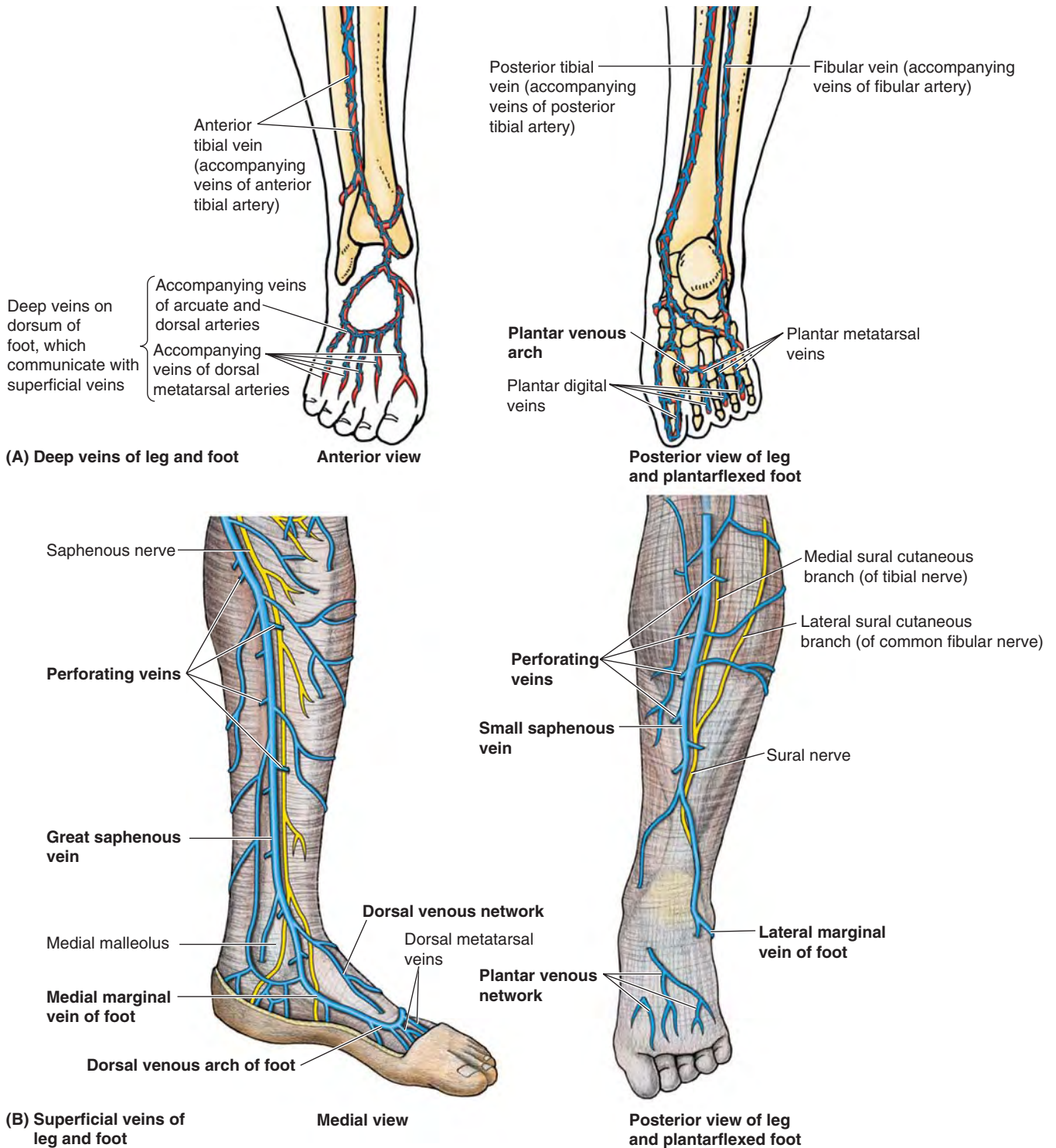


FIGURE 5.74. Veins of leg and foot. A. The deep veins accompany the arteries and their branches; they anastomose frequently and have numerous valves. B. The main superficial veins drain into the deep veins as they ascend the limb by means of perforating veins so that muscular compression can propel blood toward the heart against the pull of gravity. The distal great saphenous vein is accompanied by the saphenous nerve, and the small saphenous vein is accompanied by the sural nerve and its medial root (medial sural cutaneous nerve).

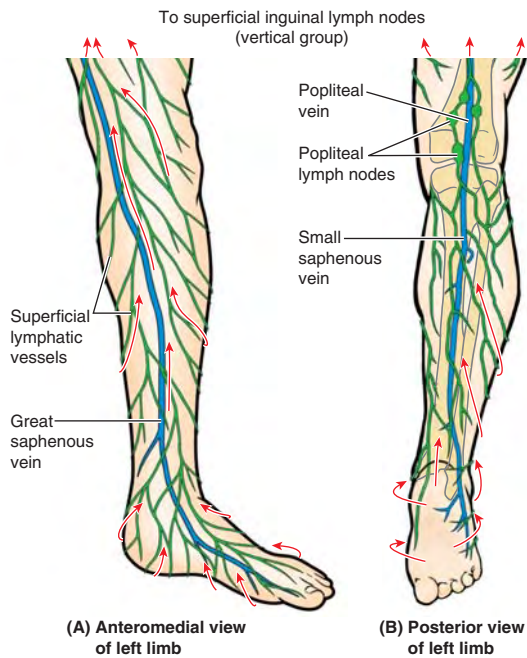


FIGURE 5.75. Lymphatic drainage of foot. Lymphatic drainage from the sole drains dorsally and proximally. **A.** Superficial lymphatic vessels from the medial foot drain are joined by those from the anteromedial leg in draining to the superficial inguinal lymph nodes via lymphatics that accompany the great saphenous vein. **B.** Superficial lymphatic vessels from the lateral foot join those from the posterolateral leg, converging to vessels accompanying the small saphenous vein and draining into the popliteal lymph nodes.

Surface Anatomy of Ankle Region and Foot

The tendons in the ankle region can be identified satisfactorily only when their muscles are acting. If the foot is actively inverted, the *tendon of the tibialis posterior* may be palpated as it passes posterior and distal to the medial malleolus, then superior to the talar shelf, to reach its attachment to the tuberosity of the navicular (Fig. 5.76A–C). Hence the tibialis posterior tendon is the guide to the navicular. The tendon of the tibialis posterior also indicates the site for palpating the *posterior tibial pulse* (halfway between the medial malleolus and the calcaneal tendon).

The tendons of the fibularis longus and brevis may be followed distally, posterior and inferior to the lateral malleolus, and then anteriorly along the lateral aspect of the foot (Fig. 5.76D & E). The *fibularis longus tendon* can be palpated as far as the cuboid, and then it disappears as it turns into the sole. The *fibularis brevis tendon* can easily be traced to its attachment to the dorsal surface of the tuberosity on the base of the 5th metatarsal. This tuberosity is located at the middle of the lateral border of the foot. With toes actively extended, the small fleshy *belly of the extensor digitorum brevis* may be seen and palpated anterior to the lateral malleolus. Its position should be observed and palpated so that it may not be mistaken subsequently for an abnormal edema.

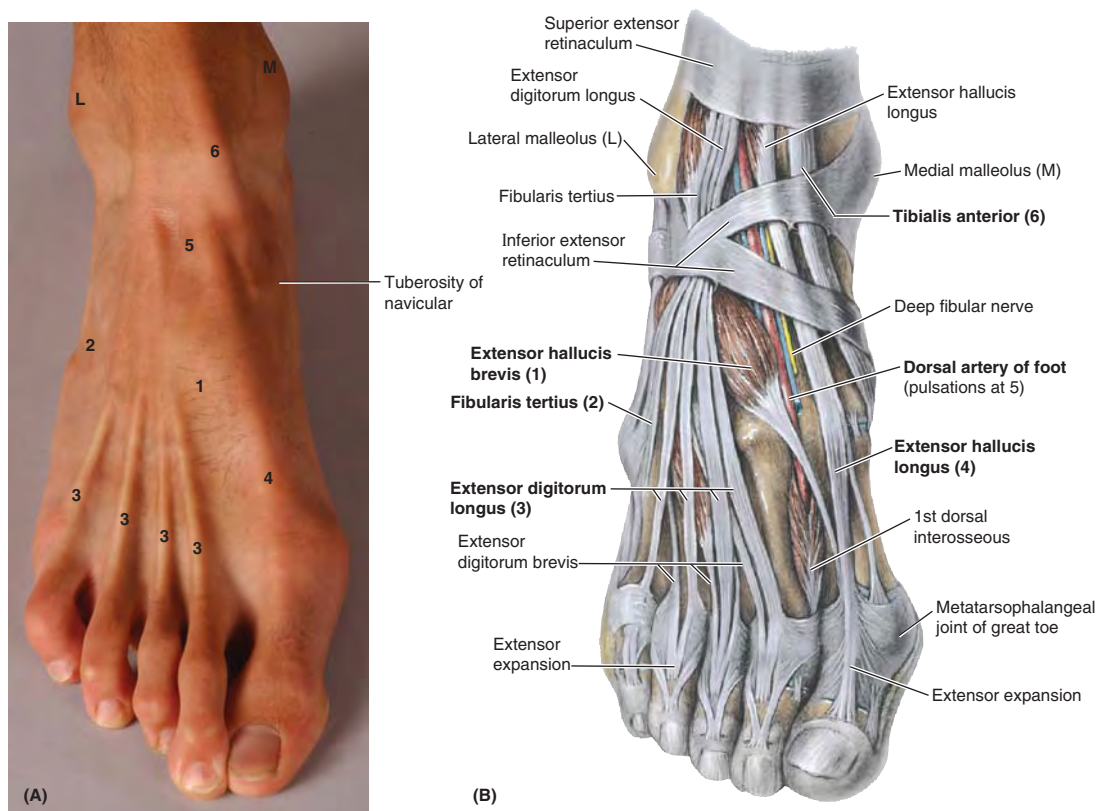
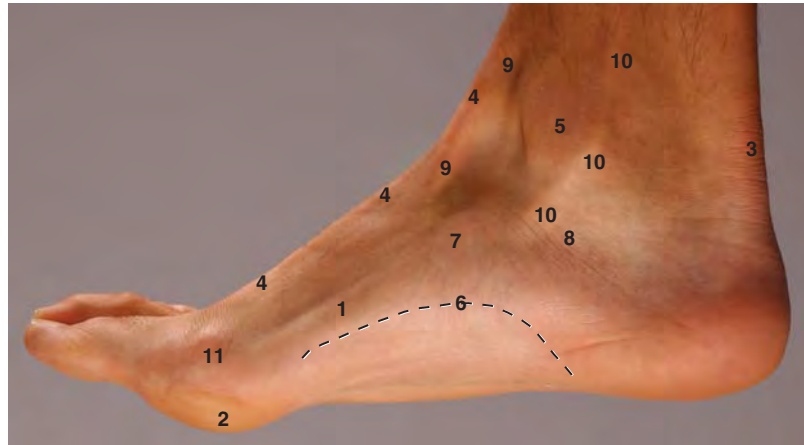

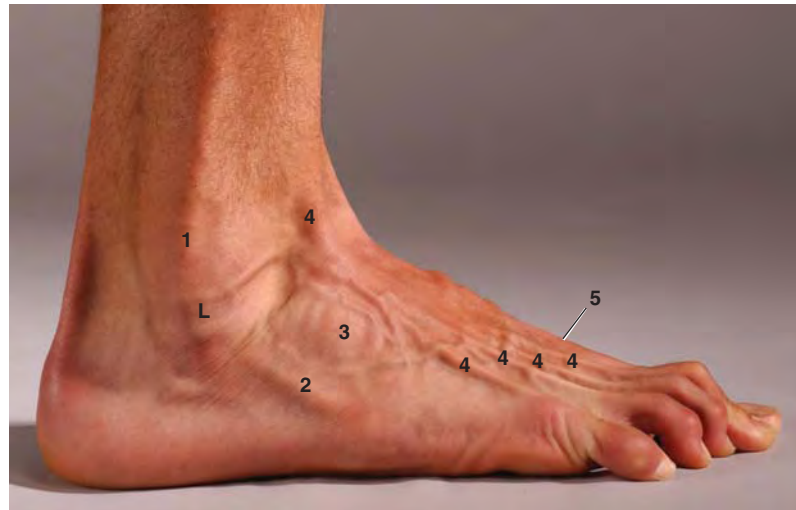
FIGURE 5.76. Surface anatomy of the foot. **A.** Visible features. **B.** Underlying structures.

Key for (C):

- 1 Abductor hallucis
- 2 Ball of foot
- 3 Calcaneal tendon
- 4 Extensor hallucis longus tendon
- 5 Medial malleolus
- 6 Medial longitudinal arch of foot
- 7 Navicular tuberosity
- 8 Sustentaculum tali
- 9 Tibialis anterior tendon
- 10 Tibialis posterior tendon
- 11 Head of 1st metatarsal



(C) Medial view



(D) Lateral view

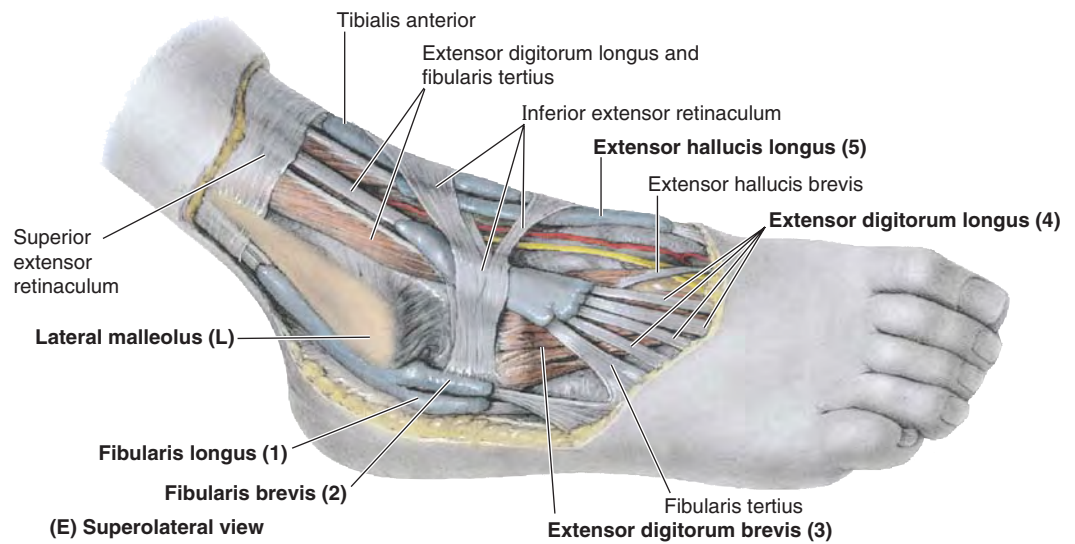


FIGURE 5.76. Surface anatomy of the foot (continued). C and D. Visible features. E. Underlying structures. Numbers in parentheses in (E) refer to structures identified in (D).

The tendons on the anterior aspect of the ankle (from medial to lateral side) are easily palpated when the foot is dorsiflexed (Fig. 5.76A–C):

- The large *tendon of the tibialis anterior* leaves the cover of the superior extensor tendon, from which level the tendon is invested by a continuous synovial sheath; the tendon may be traced to its attachment to the 1st cuneiform and the base of the 1st metatarsal.

- The *tendon of the extensor hallucis longus*, obvious when the great toe is dorsiflexed against resistance, may be followed to its attachment to the base of the distal phalanx of the great toe.
- The *tendons of the extensor digitorum longus* may be followed easily to their attachments to the lateral four toes.
- The *tendon of the fibularis tertius* may also be traced to its attachment to the base of the 5th metatarsal. This muscle is of minor importance and may be absent.

FOOT

Plantar Fasciitis



Inflammation of the plantar fascia—*plantar fasciitis*—is often caused by an overuse mechanism. It may result from running and high-impact aerobics, especially when inappropriate footwear is worn. Plantar fasciitis is the most common hindfoot problem in runners. It causes pain on the plantar surface of the foot and heel. The pain is often most severe after sitting and when beginning to walk in the morning. It usually dissipates after 5–10 minutes of activity and often recurs again following rest.

Point tenderness is located at the proximal attachment of the aponeurosis to the medial tubercle of the calcaneus and on the medial surface of this bone. The pain increases with passive extension of the great toe and may be further exacerbated by dorsiflexion of the ankle and/or weight-bearing.

If a *calcaneal spur* (abnormal bony process) protrudes from the medial tubercle, plantar fasciitis is likely to cause pain on the medial side of the foot when walking (Fig. B5.26).

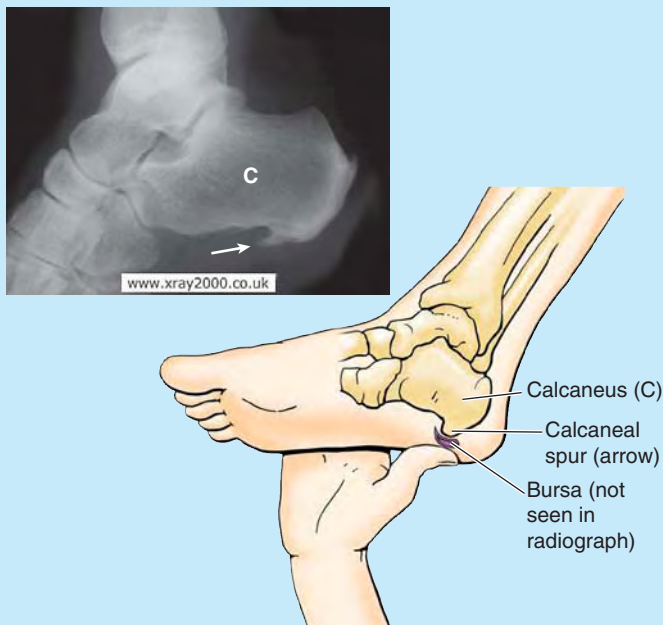


FIGURE B5.26.

Usually a bursa develops at the end of the spur that may also become inflamed and tender.

Infections of Foot



Foot infections are common, especially in seasons, climates, and cultures where shoes are less commonly worn. A neglected puncture wound may lead to an extensive deep infection, resulting in swelling, pain, and fever.

Deep infections of the foot often localize within the compartments between the muscular layers. A well-established infection in one of the enclosed fascial or muscular spaces usually requires surgical incision and drainage. When possible, the incision is made on the medial side of the foot, passing superior to the abductor hallucis to allow visualization of critical neurovascular structures, while avoiding production of a painful scar in a weight-bearing area.

Contusion of Extensor Digitorum Brevis



Functionally, the EDB and EHB muscles are relatively unimportant. Clinically, knowing the location of the belly of the EDB is important for distinguishing it from abnormal edema. Contusion and tearing of muscle's fibers and associated blood vessels result in a *hematoma*, producing edema anteromedial to the lateral malleolus. Most people who have not seen this inflamed muscle assume they have a severely sprained ankle.

Sural Nerve Grafts



Pieces of the sural nerve are often used for nerve grafts in procedures such as repairing nerve defects resulting from wounds. The surgeon is usually able to locate this nerve in relation to the small saphenous vein (Fig. 5.74B). Because of the variations in the level of formation of the sural nerve, the surgeon may have to make incisions in both legs, and then select the better specimen.

Anesthetic Block of Superficial Fibular Nerve



After the superficial fibular nerve pierces the deep fascia to become a cutaneous nerve, it divides into medial and intermediate cutaneous nerves. In thin people, these branches can often be seen or felt as ridges under the skin when the foot is plantarflexed. Injections of an anesthetic agent around these branches in the ankle region, anterior to the palpable portion of the fibula, anesthetizes the skin on the dorsum of the foot (except the web between and adjacent surfaces of the 1st and 2nd toes) more broadly and effectively than more local injections on the dorsum of the foot for superficial surgery.

Plantar Reflex



The **plantar reflex** (L4, L5, S1, and S2 nerve roots) is a myotatic (deep tendon) reflex that is routinely tested during neurologic examinations. The lateral aspect of the sole of the foot is stroked with a blunt object, such as a tongue depressor, beginning at the heel and crossing to the base of the great toe. The motion is firm and continuous but neither painful nor ticklish. Flexion of the toes is a normal response. Slight fanning of the lateral four toes and dorsiflexion of the great toe is an abnormal response (*Babinski sign*), indicating brain injury or cerebral disease, except in infants. Because the corticospinal tracts are not fully developed in newborns, a Babinski sign is usually elicited and may be present until children are 4 years of age (except in infants with a brain injury or cerebral disease).

Medial Plantar Nerve Entrapment



Compressive irritation of the medial plantar nerve as it passes deep to the flexor retinaculum or curves deep to the abductor hallucis may cause aching, burning, numbness, and tingling (paresthesia) on the medial side of the sole and in the region of the navicular tuberosity. *Medial plantar nerve compression* may occur during repetitive eversion of the foot (e.g., during gymnastics and running). Because of its frequency in runners, these symptoms have been called “jogger’s foot.”

Palpation of Dorsalis Pedis Pulse



The *dorsalis pedis artery pulse* is evaluated during a physical examination of the peripheral vascular system. Dorsalis pedis pulses may be palpated with the feet slightly dorsiflexed. The pulses are usually easy to palpate because these dorsal arteries are subcutaneous and

pass along a line from the extensor retinaculum to a point just lateral to the EHL tendons (Swartz, 2006) (Fig. B5.27). A diminished or absent dorsalis pedis pulse usually suggests vascular insufficiency resulting from arterial disease. The five *P signs of acute arterial occlusion* are **pain**, **pallor**, **paresthesia**, **paralysis**, and **pulselessness**. Some healthy adults (and even children) have *congenitally non-palpable dorsalis pedis pulses*; the variation is usually bilateral. In these cases, the dorsalis pedis artery is replaced by an enlarged perforating fibular artery.

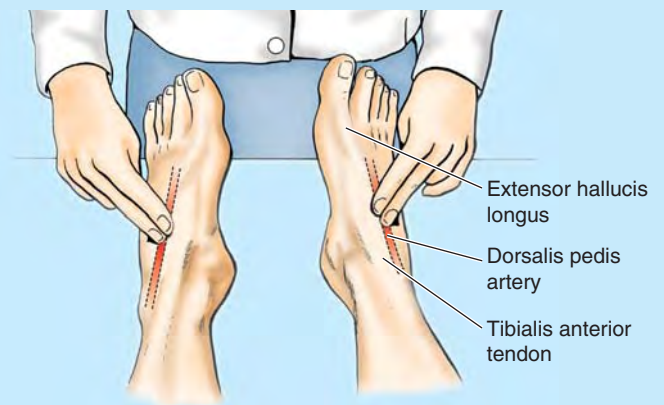


FIGURE B5.27.

Hemorrhaging Wounds of Sole of Foot



Puncture wounds of the sole of the foot involving the deep plantar arch and its branches usually result in severe bleeding, typically from both ends of the cut artery because of the abundant anastomoses. Ligation of the deep arch is difficult because of its depth and the structures that surround it.

Lymphadenopathy



Infections of the foot may spread proximally, causing enlargement of the popliteal and inguinal lymph nodes (*lymphadenopathy*). Infections on the lateral side of the foot initially produce enlargement of popliteal lymph nodes (*popliteal lymphadenopathy*); later, the inguinal lymph nodes may enlarge.

Inguinal lymphadenopathy without popliteal lymphadenopathy can result from infection of the medial side of the foot, leg, or thigh; however, enlargement of these nodes can also result from an infection or tumor in the vulva, penis, scrotum, perineum, and gluteal region and from terminal parts of the urethra, anal canal, and vagina.

The Bottom Line

FOOT

Muscles of foot: The intrinsic muscles of the plantar surface of the foot are arranged in four layers and divided into four fascial compartments. ♦ A tough plantar aponeurosis overlies the central compartment, passively contributing to arch maintenance and, along with firmly bound fat, protecting the vessels and nerves from compression. ♦ There is similarity to the arrangement of muscles in the palm of the hand, but the muscles of the foot generally respond as a group rather than individually, acting to maintain the longitudinal arch of the foot or push a portion of it harder against the ground to maintain balance. ♦ The movements of abduction and adduction produced by the interossei are toward or away from the 2nd digit. ♦ The foot has two intrinsic muscles on its dorsum that augment the long extensor muscles. ♦ The plantar intrinsic muscles function throughout the stance phase of gait, from heel strike to toe off, resisting forces that tend to spread the arches of the foot. ♦ These muscles are especially active in fixing the medial forefoot for the propulsive push off.

Nerves of foot: The plantar intrinsic muscles are innervated by the medial and lateral plantar nerves, whereas the dorsal muscles are innervated by the deep fibular nerve. ♦ Most of the dorsum of the foot receives cutaneous innervation from the *superficial fibular nerve*, the exception being the skin of the web between and the adjacent sides of the 1st and 2nd toes. The latter receives innervation from the *deep fibular nerve* after it supplies the muscles on the dorsum of the foot. ♦ The skin of the medial and lateral sides of the foot is innervated by the *saphenous* and *sural nerves*, respectively. ♦ The plantar aspect of the foot receives innervation from the larger medial and smaller *lateral plantar nerves*. ♦ The *medial plantar nerve* supplies more skin (the plantar aspect of the medial three and half toes and adjacent sole) but fewer muscles (the medial half

and 1st lumbrical muscles only) than the lateral plantar nerve. ♦ The lateral plantar nerve supplies the remaining muscles and skin of the plantar aspect. ♦ The distribution of the medial and lateral plantar nerves is comparable to that of the median and ulnar nerves in the palm.

Arteries of foot: The dorsal and plantar arteries of the foot are terminal branches of the anterior and posterior tibial arteries, respectively. ♦ The *dorsalis pedis* artery supplies all of the dorsum of the foot and, via the arcuate artery, the proximal dorsal aspect of the toes. It also contributes to formation of the deep plantar arch via its terminal deep plantar artery. ♦ The smaller medial and larger lateral plantar arteries supply the plantar aspect of the foot, the latter running in vascular planes between the 1st and 2nd layers and then, as the plantar arch, the 3rd and 4th layers of the intrinsic muscles. ♦ Anastomoses between the *dorsalis pedis* and the plantar arteries are abundant and important for the health of the foot. ♦ Except for the scarcity of a superficial plantar arch, the arterial pattern of the foot is similar to that of the hand.

Efferent vessels of foot: Venous drainage of the foot primarily follows a superficial route, draining to the dorsum of the foot and then medially via the great saphenous vein or laterally via the small saphenous veins. ♦ From these veins, blood is shunted by perforating veins to the deep veins of the leg and thigh that participate in the musculovenous pump. ♦ The lymphatics carrying lymph from the foot drain toward and then along the superficial veins draining the foot. ♦ Lymph from the medial foot follows the great saphenous vein and drains directly to superficial inguinal lymph nodes. ♦ Lymph from the lateral foot follows the small saphenous vein and drains initially to the popliteal lymph nodes and then by deep lymphatic vessels to the deep inguinal nodes.

JOINTS OF LOWER LIMB

The joints of the lower limb include the articulations of the pelvic girdle—lumbosacral joints, sacroiliac joints, and pubic symphysis, which are discussed in Chapter 3. The remaining joints of the lower limb are the hip joints, knee joints, tibiofibular joints, ankle joints, and foot joints (Fig. 5.77).

Hip Joint

The **hip joint** forms the connection between the lower limb and the pelvic girdle (Fig. 5.77A). It is a strong and stable multiaxial ball and socket type of synovial joint. The head of the femur is the ball, and the acetabulum is the socket (Fig. 5.78). The hip joint is designed for stability over a wide range of movement. Next to the glenohumeral (shoulder) joint, it is

the most movable of all joints. During standing, the entire weight of the upper body is transmitted through the hip bones to the heads and necks of the femurs.

ARTICULAR SURFACES OF HIP JOINT

The round head of the femur articulates with the cup-like acetabulum of the hip bone (Figs. 5.77–5.80). The *head of the femur* forms approximately two thirds of a sphere. Except for the pit or *fovea for the ligament of the femoral head*, all of the head is covered with articular cartilage, which is thickest over weight-bearing areas.

The *acetabulum*, a hemispherical hollow on the lateral aspect of the hip bone, is formed by the fusion of three bony parts (see Fig. 5.5). The heavy, prominent **acetabular rim** of the acetabulum consists of a semilunar articular part cov-

(text continues on p. 629)

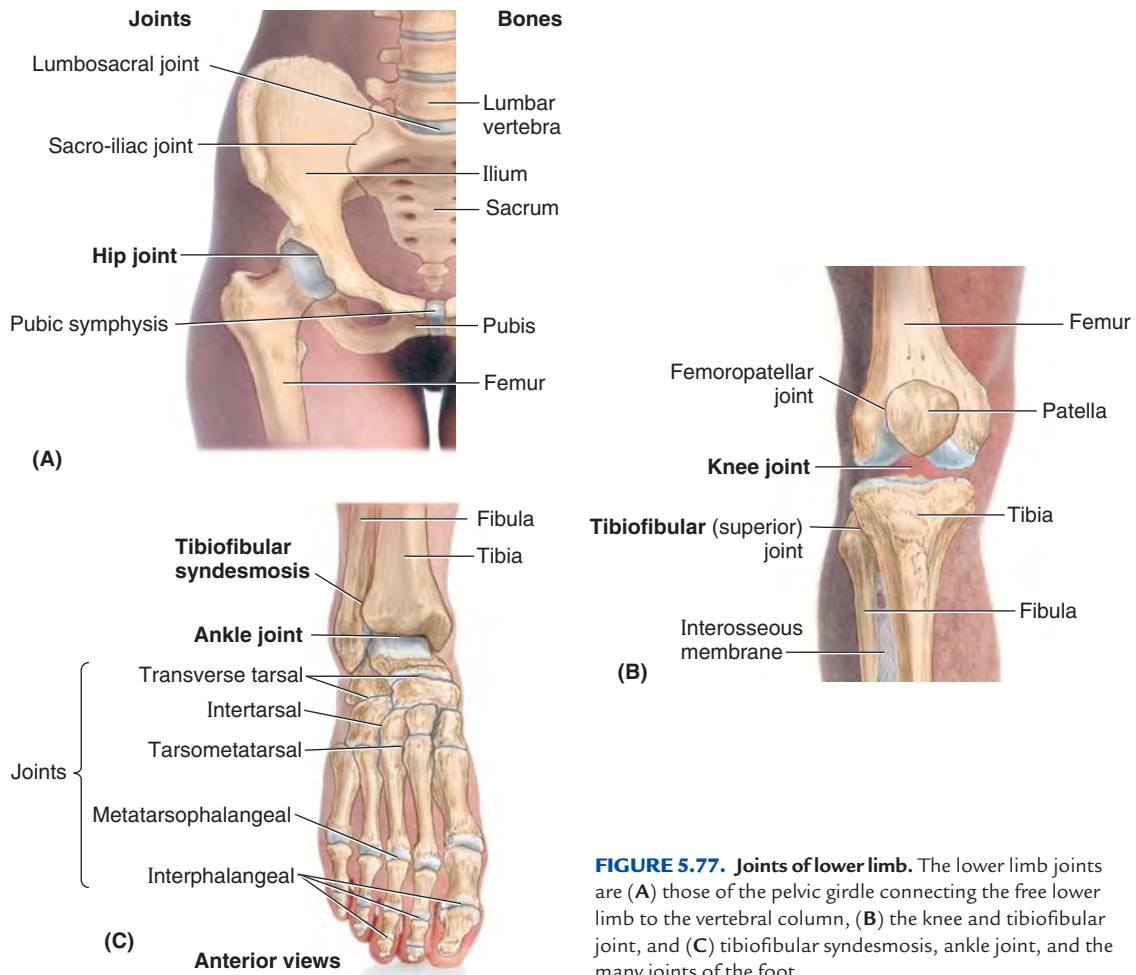


FIGURE 5.77. Joints of lower limb. The lower limb joints are (A) those of the pelvic girdle connecting the free lower limb to the vertebral column, (B) the knee and tibiofibular joint, and (C) tibiofibular syndesmosis, ankle joint, and the many joints of the foot.

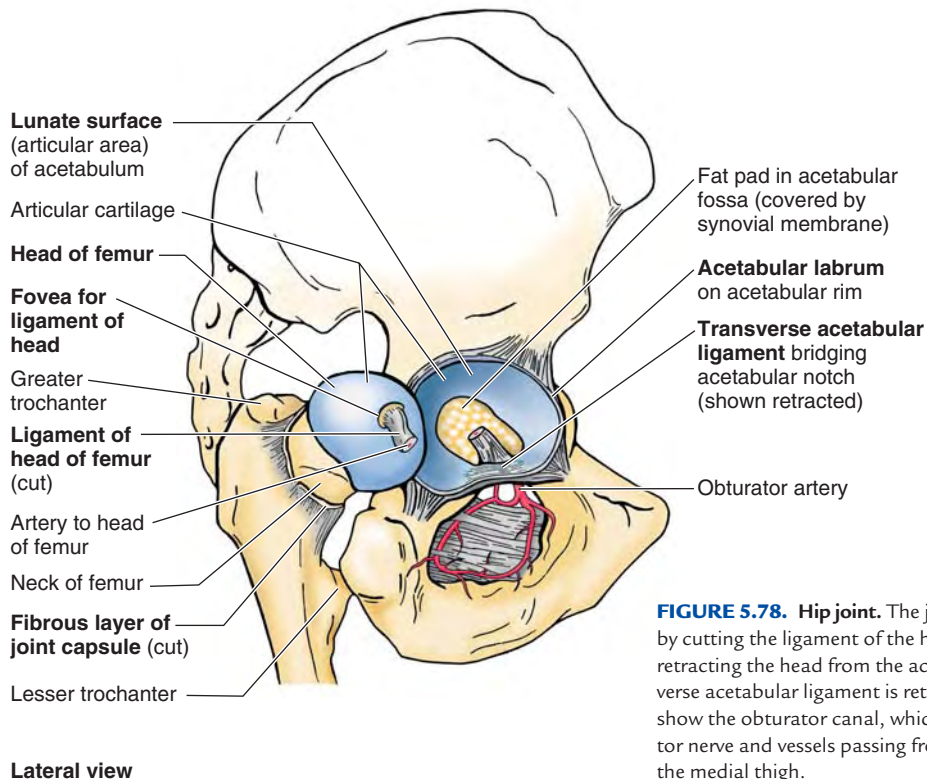


FIGURE 5.78. Hip joint. The joint was disarticulated by cutting the ligament of the head of the femur and retracting the head from the acetabulum. The transverse acetabular ligament is retracted superiorly to show the obturator canal, which transmits the obturator nerve and vessels passing from the pelvic cavity to the medial thigh.

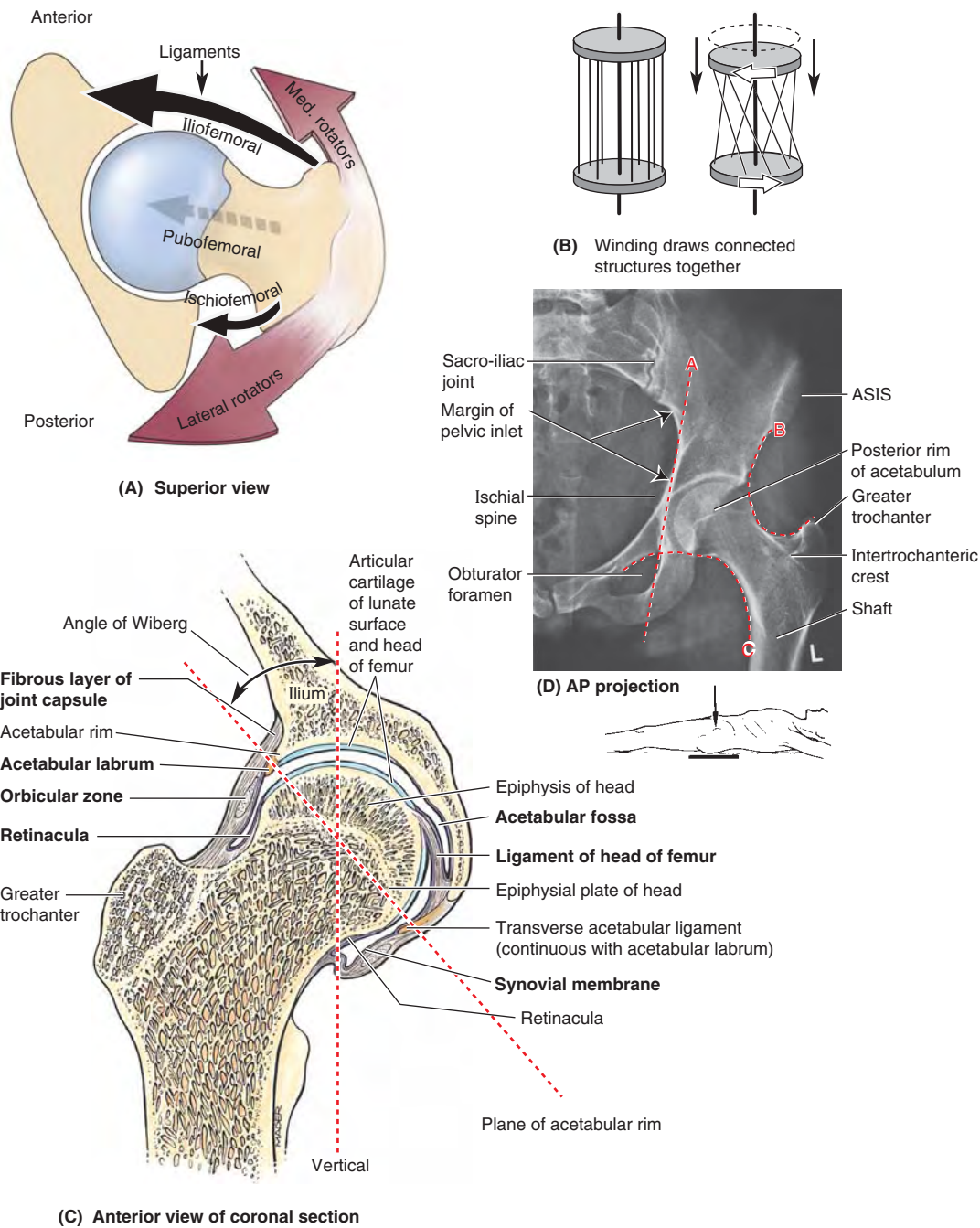
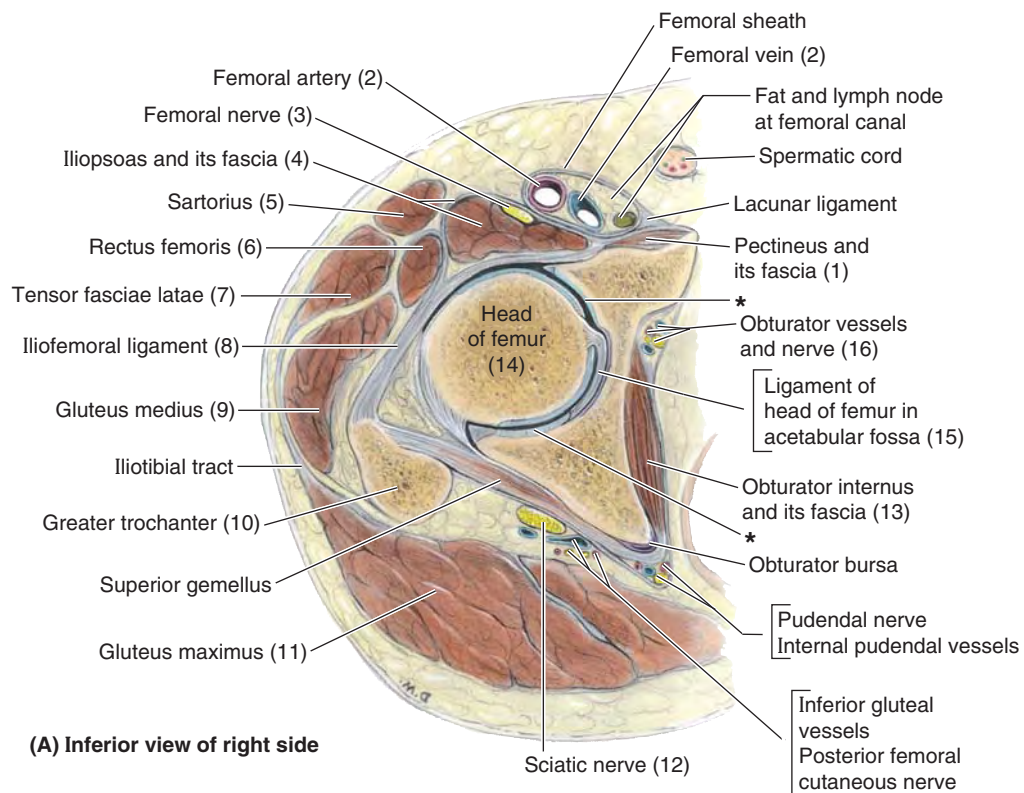
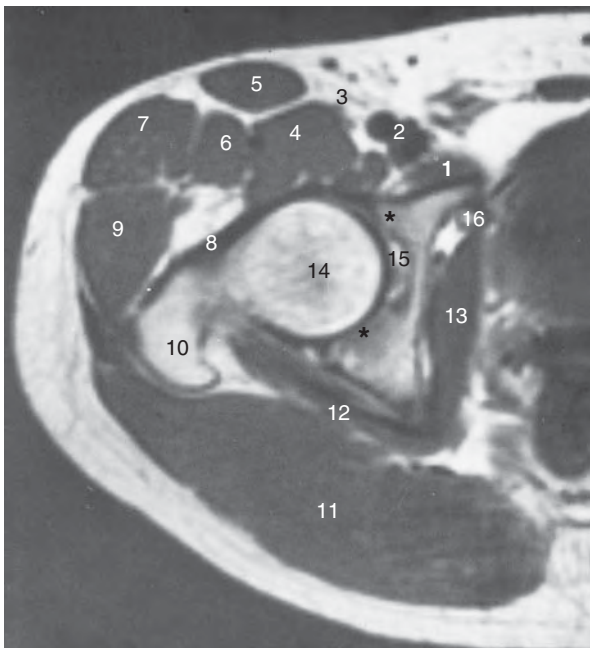


FIGURE 5.79. Factors increasing stability of hip joint. **A.** This superior view of the hip joint demonstrates the medial and reciprocal pull of the periarticular muscles (medial and lateral rotators; reddish brown arrows) and intrinsic ligaments of the hip joint (black arrows) on the femur. Relative strengths are indicated by arrow width: Anteriorly, the muscles are less abundant but the ligaments are robust; posteriorly, the muscles predominate. **B.** Parallel fibers linking two discs resemble those making up the tube-like fibrous layer of the hip joint capsule. When one disc (the femur) rotates relative to the other (the acetabulum), the fibers become increasingly oblique and draw the two discs together. Similarly, extension of the hip joint winds (increases the obliquity of) the fibers of the fibrous layer, pulling the head and neck of the femur tightly into the acetabulum, increasing the stability of the joint. Flexion unwinds the fibers of the capsule. **C.** In this coronal section of hip joint, the acetabular labrum and transverse acetabular ligament, spanning the acetabular notch (and included in the plane of section here), extend the acetabular rim so that a complete socket is formed. Thus the acetabular complex engulfs the head of the femur. The epiphysis of the femoral head is entirely within the joint capsule. The thick weight-bearing bone of the ilium normally lies directly superior to the head of the femur for efficient transfer of weight to the femur (Fig. 5.3). The angle of Wiberg (see text) is used radiographically to determine the degree to which the acetabulum overhangs the head of the femur. **D.** Several different lines and curvatures are used in the detection of hip abnormalities (dislocations, fractures, or slipped epiphyses). The Kohler line (A) is normally tangential to the pelvic inlet and the obturator foramen. The acetabular fossa should lie lateral to this line. A fossa that crosses the line suggests an acetabular fracture with inward displacement. The Shenton line (B) and the iliofemoral line (C) should appear in a normal AP radiograph as smooth, continuous lines that are bilaterally symmetrical. The Shenton line is a radiographic indication of the angle of inclination (ASIS = anterior superior iliac spine).



(A) Inferior view of right side



(B) Inferior view of right side

* Lunate surface of acetabulum

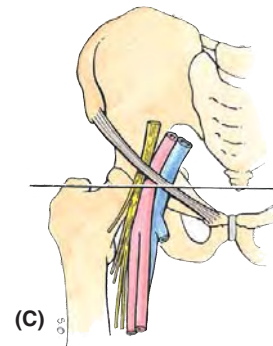


FIGURE 5.80. Sectional and radiographic anatomy of gluteal region and proximal anterior thigh at level of hip joint. **A** and **B**. A descriptive drawing and transverse (axial MRI) study of an anatomical section of the thigh are shown. Numbers in parentheses in **(A)** refer to structures identified in **(B)**. **C**. The orientation drawing shows the level of the section.

ered with articular cartilage, the **lunate surface of the acetabulum** (Figs. 5.78–5.80). The acetabular rim and lunate surface form approximately three quarters of a circle; the missing inferior segment of the circle is the **acetabular notch**.

The lip-shaped **acetabular labrum** (*L. labrum*, lip) is a fibrocartilagenous rim attached to the margin of the acetabulum, increasing the acetabular articular area by nearly 10%.

The **transverse acetabular ligament**, a continuation of the acetabular labrum, bridges the acetabular notch (Figs. 5.78 and 5.79C). As a result of the height of the rim and labrum, more than half of the femoral head fits within the acetabulum (Figs. 5.79C and 5.80). Thus during dissection, the femoral head must be cut from the acetabular rim to enable disarticulation of the joint. Centrally a deep non-articular part, called the

acetabular fossa, is formed mainly by the ischium (Figs. 5.78, 5.79C, and 5.80). This fossa is thin walled (often translucent) and continuous inferiorly with the acetabular notch.

The articular surfaces of the acetabulum and femoral head are most congruent when the hip is flexed 90°, abducted 5°, and rotated laterally 10° (the position in which the axis of the acetabulum and the axis of the femoral head and neck are aligned), which is the quadruped position!

In other words, in assuming the upright position, a relatively small degree of joint stability was sacrificed to maximize weight-bearing when erect. Even so, the hip joint is our most stable joint, owing also to its complete ball and socket construction (depth of socket); the strength of its joint capsule; and the attachments of muscles crossing the joint, many of which are located at some distance from the center of movement (Palastanga et al., 2002).

JOINT CAPSULE OF HIP JOINT

The hip joints are enclosed within strong **joint capsules**, formed of a loose external *fibrous layer* (fibrous capsule) and an internal *synovial membrane* (Fig. 5.79C). Proximally, the fibrous layer attaches to the acetabulum, just peripheral to the rim to which the labrum is attached, and to the transverse acetabular ligament (Figs. 5.79C and 5.81A, C, & D). Distally, the fibrous layer attaches to the femoral neck only anteriorly at the *intertrochanteric line* and root of the greater trochanter (Fig. 5.81B). Posteriorly, the fibrous layer crosses the neck proximal to the *intertrochanteric crest* but is not attached to it.

Most fibers of the fibrous layer of the capsule take a spiral course from the hip bone to the intertrochanteric line of the femur, but some deep fibers pass circularly around the neck, forming the **orbicular zone** (Fig. 5.79C and 5.81D). Thick parts of the fibrous layer form the **ligaments of the hip joint**, which pass in a spiral fashion from the pelvis to the femur (Fig. 5.81A, C, & D). Extension winds the spiraling ligaments and fibers more tightly, constricting the capsule and drawing the femoral head tightly into the acetabulum (Fig. 5.79B). The tightened fibrous layer increases the stability of the joint, but restricts extension of the joint to 10–20° beyond the vertical position. Flexion increasingly unwinds the spiraling ligaments and fibers. This permits considerable flexion of the hip joint with increasing mobility.

Of the three intrinsic ligaments of the joint capsule below, it is the first one that reinforces and strengthens the joint:

- *Anteriorly and superiorly* is the strong, Y-shaped **iliofemoral ligament**, which attaches to the anterior inferior iliac spine and the acetabular rim proximally and the intertrochanteric line distally (Fig. 5.81A & C). Said to be the body's strongest ligament, the iliofemoral ligament specifically prevents hyperextension of the hip joint during standing by screwing the femoral head into the acetabulum via the mechanism described above.

- *Anteriorly and inferiorly* is the **pubofemoral ligament**, which arises from the obturator crest of the pubic bone and passes laterally and inferiorly to merge with the fibrous layer of the joint capsule (Fig. 5.81A). This ligament blends with the medial part of the iliofemoral ligament and tightens during both extension and abduction of the hip joint. The pubofemoral ligament prevents overabduction of the hip joint.
- *Posteriorly* is the **ischiofemoral ligament**, which arises from the ischial part of the acetabular rim (Fig. 5.81D). The weakest of the three ligaments, it spirals superolaterally to the femoral neck, medial to the base of the greater trochanter.

The relative size, strengths, and positions of the three ligaments of the hip joint are shown in Figure 5.79A. The ligaments and periarticular muscles (the medial and lateral rotators of the thigh) play a vital role in maintaining the structural integrity of the joint.

Both muscles and ligaments pull the femoral head medially into the acetabulum, and they are reciprocally balanced when doing so. The medial flexors, located anteriorly, are fewer, weaker, and less mechanically advantaged, whereas the anterior ligaments are strongest. Conversely, the ligaments are weaker posteriorly where the medial rotators are abundant, stronger, and more mechanically advantaged.

In all synovial joints, a synovial membrane lines the internal surfaces of the fibrous layer, as well as any intracapsular bony surfaces not lined with articular cartilage. Thus in the hip joint, where the fibrous layer attaches to the femur distant from the articular cartilage covering the femoral head, the **synovial membrane of the hip joint** reflects proximally along the femoral neck to the edge of the femoral head. Longitudinal synovial folds (**retinacula**) occur in the synovial membrane covering the femoral neck (Fig. 5.79C). Subsynovial **retinacular arteries** (branches of the medial, and a few of the lateral, circumflex femoral artery) that supply the femoral head and neck course within the synovial folds (Fig. 5.82).

The **ligament of the head of the femur** (Figs. 5.78, 5.79C, 5.80, and 5.82), primarily a synovial fold conducting a blood vessel, is weak and of little importance in strengthening the hip joint. Its wide end attaches to the margins of the acetabular notch and the transverse acetabular ligament; its narrow end attaches to the *fovea for the ligament of the head*.

Usually, the ligament contains a small artery to the head of the femur. A *fat pad* in the acetabular fossa fills the part of the acetabular fossa that is not occupied by the ligament of the femoral head (Fig. 5.78). Both the ligament and the fat pad are covered with synovial membrane. The malleable nature of the fat pad permits it to change shape to accommodate the variations in the congruity of the femoral head and acetabulum, as well as changes in the position of the ligament of the head during joint movements. A *synovial protrusion* beyond the free margin of the joint capsule onto the posterior aspect of the femoral neck forms a bursa for the obturator externus tendon (Fig. 5.81D).

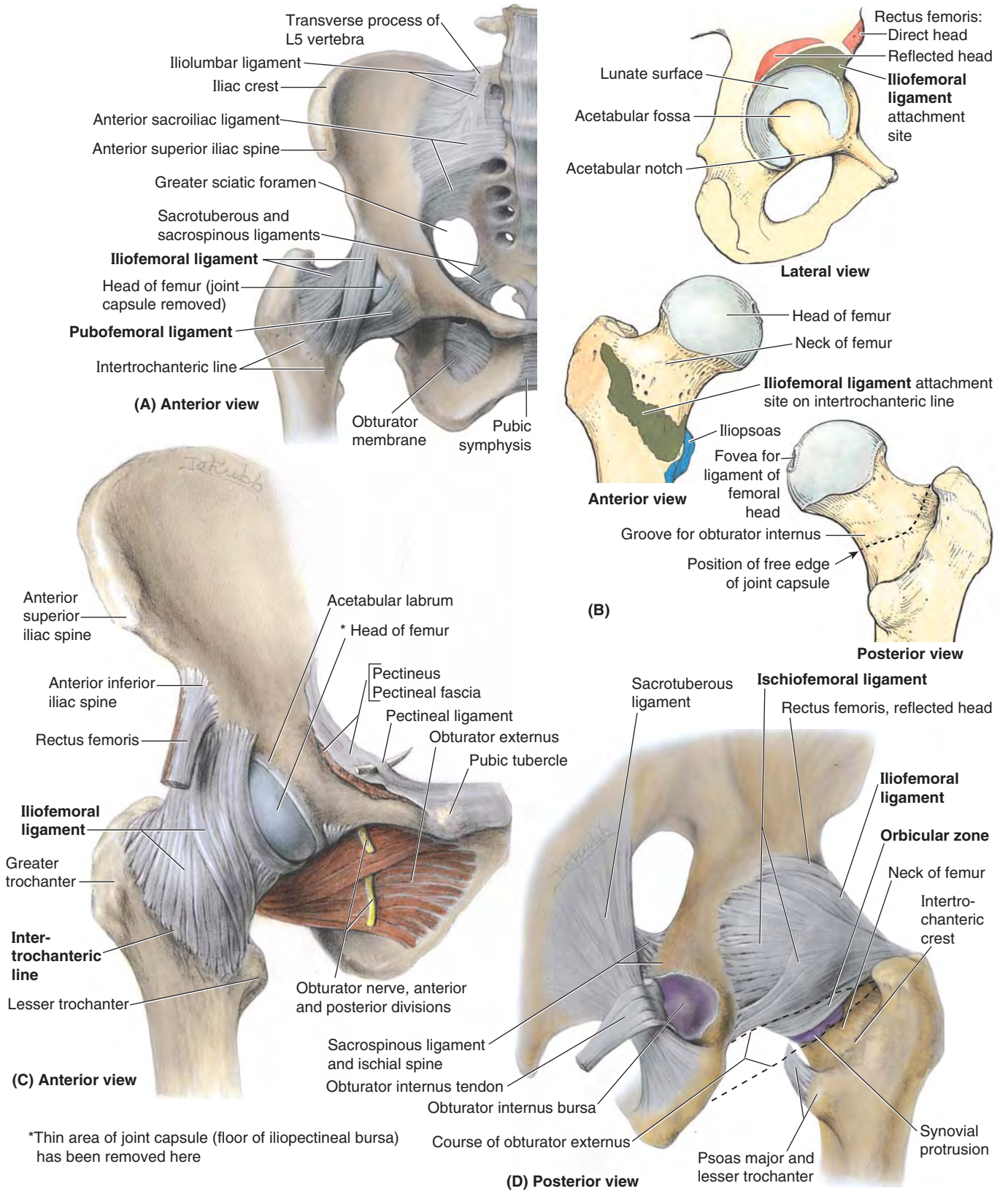


FIGURE 5.81. Ligaments of pelvis and hip joint. A. Weight transfer from the vertebral column to the pelvic girdle is a function of the sacroiliac ligaments. Weight transfer at the hip joint is accomplished primarily by the disposition of the bones, with the ligaments limiting the range of movement and adding stability. B. Articulating surfaces of hip joint and sites of attachment and tendinous relationships of iliofemoral ligaments and joint capsule. C. Iliofemoral ligament. D. The ischiofemoral ligament. Because the joint capsule does not attach to the posterior aspect of the femur, the synovial membrane protrudes from the joint capsule, forming the obturator externus bursa to facilitate movement of the tendon of the obturator externus (shown in part C) over the bone.

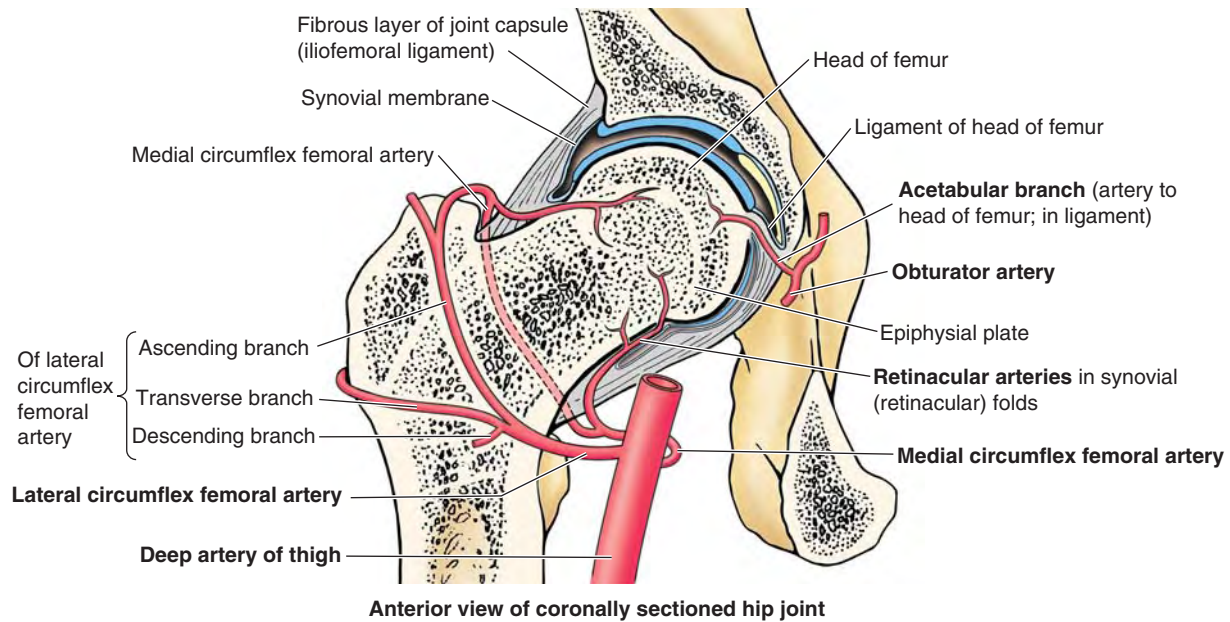


FIGURE 5.82. Blood supply of head and neck of femur. Branches of the medial and lateral circumflex femoral arteries, branches of the deep artery of the thigh, and the artery to the femoral head (a branch of the obturator artery) supply the head and neck of the femur. In the adult, the medial circumflex femoral artery is the most important source of blood to the femoral head and adjacent (proximal) neck.

MOVEMENTS OF HIP JOINT

Hip movements are flexion–extension, abduction–adduction, medial–lateral rotation, and circumduction (Fig. 5.83). Movements of the trunk at the hip joints are also important, such as those occurring when a person lifts the trunk from the supine position during sit-ups or keeps the pelvis level when one foot is off the ground.

The degree of flexion and extension possible at the hip joint depends on the position of the knee. If the knee is flexed, relaxing the hamstrings, the thigh can be actively flexed until it almost reaches the anterior abdominal wall and can reach it via further passive flexion. Not all of this movement occurs at the hip joint; some results from flexion of the vertebral column. During extension of the hip joint, the fibrous layer of the joint capsule, especially the iliofemoral ligament, is taut; therefore, the hip can usually be extended only slightly beyond the vertical except by movement of the bony pelvis (flexion of lumbar vertebrae).

From the anatomical position, the range of abduction of the hip joint is usually somewhat greater than for adduction. About 60° of abduction is possible when the thigh is extended, and more when it is flexed. Lateral rotation is much more powerful than medial rotation.

The main muscles producing movements of the hip joint are listed in Figure 5.83B. Note that:

1. The *iliopsoas* is the strongest flexor of the hip.
2. In addition to its function as an adductor, the *adductor magnus* also serves as a flexor (anterior or aponeurotic part) and an extensor (posterior or hamstrings part).
3. Several muscles participate in both flexion and adduction (*pectineus* and *gracilis* as well as all three “adductor” muscles).

4. In addition to serving as abductors, the anterior portions of the *gluteus medius* and *minimus* are also medial rotators.
5. The *gluteus maximus* serves as the primary extensor from the flexed to the straight (standing) position, and from this point posteriorly, extension is achieved primarily by the hamstrings. The *gluteus maximus* is also a lateral rotator.

BLOOD SUPPLY OF HIP JOINT

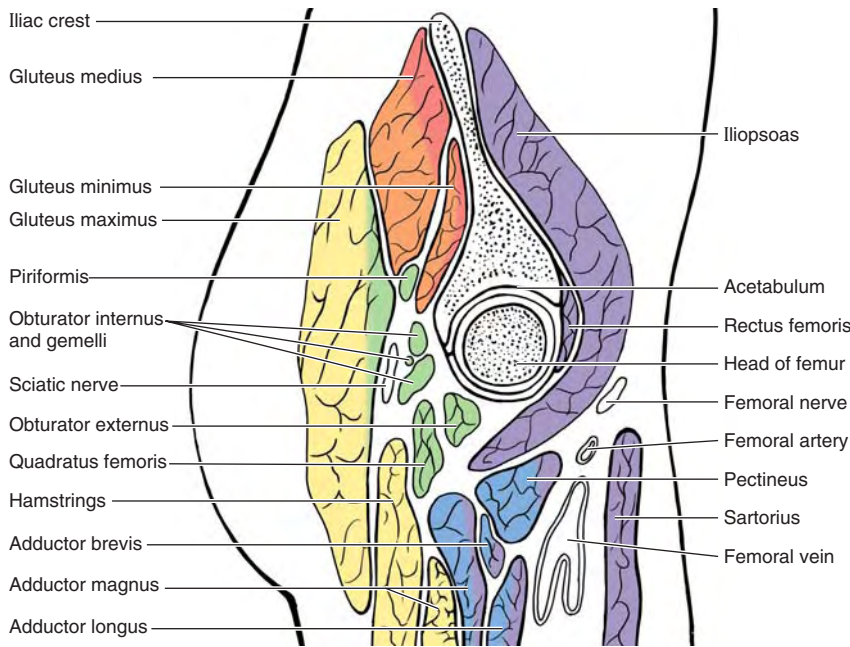
Arteries supplying the hip joint (Fig. 5.82) include the following:

- The *medial* and *lateral circumflex femoral arteries*, which are usually branches of the *deep artery of the thigh* but occasionally arise as branches of the *femoral artery*.
- The **artery to the head of the femur**, which is a branch of the obturator artery of variable size; it traverses the ligament of the head.

The main blood supply of the hip joint is from the *retinacular arteries* arising as branches of the circumflex femoral arteries. Retinacular arteries arising from the medial circumflex femoral artery are most abundant, bringing more blood to the head and neck of the femur because they are able to pass beneath the unattached posterior border of the joint capsule. Retinacular arteries arising from the lateral circumflex femoral must penetrate the thick iliofemoral ligament and are smaller and fewer.

NERVE SUPPLY OF HIP JOINT

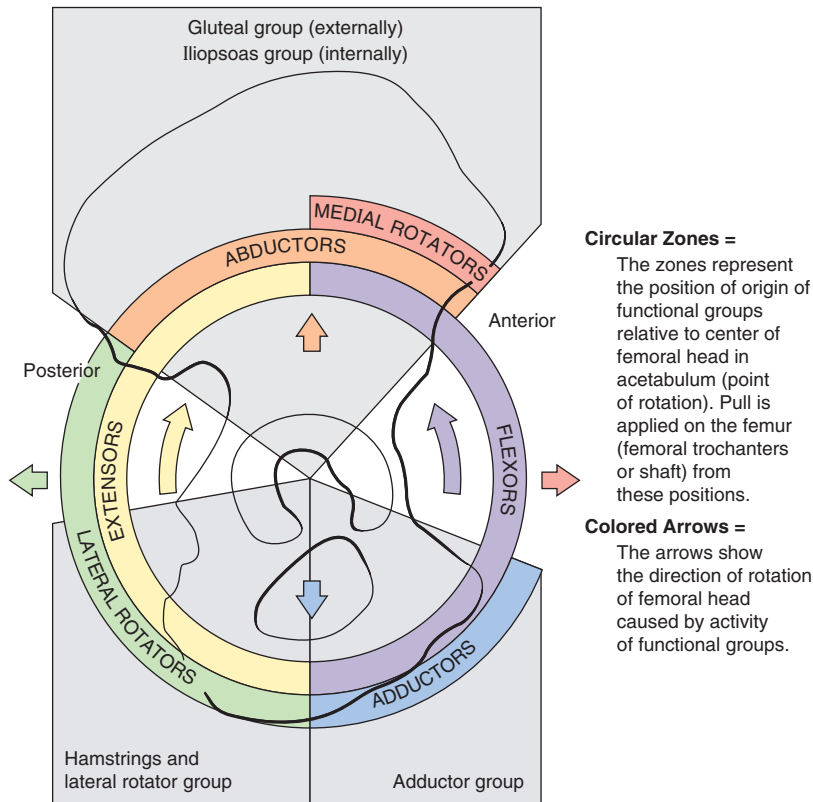
Hilton’s law states that the nerves supplying the muscles extending directly across and acting at a given joint also innervate the joint. Articular rami arise from the intramuscular rami



(A) Lateral view of sagittal section through femoral head

Functional groups of muscles acting at hip joint

| |
|--|
| Flexors |
| Iliopsoas Sartorius Tensor fasciae latae Rectus femoris Pectineus Adductor longus Adductor brevis Adductor magnus—anterior part Gracilis |
| Adductors |
| Adductor longus Adductor brevis Adductor magnus Gracilis Pectineus Obturator externus |
| Lateral rotators |
| Obturator externus Obturator internus Gemelli Piriformis Quadratus femoris Gluteus maximus |
| Extensors |
| Hamstrings: Semitendinosus Semimembranosus Long head, biceps femoris Adductor magnus—posterior part Gluteus maximus |
| Abductors |
| Gluteus medius Gluteus minimus Tensor fasciae latae |
| Medial rotators |
| Gluteus medius Gluteus minimus Tensor fasciae latae |



(B) Diagrammatic lateral view

FIGURE 5.83. Relations of hip joint and muscles producing movements of joint. A. Sagittal section of the hip joint showing the muscles, vessels, and nerves related to it. The muscles are color coded to indicate their function(s). Applying Hilton’s law, it is possible to deduce the innervation of the hip joint by knowing which muscles directly cross and act on the joint and their nerve supply. B. The relative positions of the muscles producing movements of the hip joint and the direction of the movement are demonstrated.

of the muscular branches and directly from named nerves. A knowledge of the nerve supply of the muscles and their relationship to the joints can allow one to deduce the nerve supply of many joints. Possible deductions regarding the hip joint and its muscular relationships include (Fig. 5.83):

- Flexors innervated by the femoral nerve pass anterior to the hip joint; the anterior aspect of the hip joint is innervated by the femoral nerve (directly and via articular rami of the muscular branches to the pectineus and rectus femoris).
- Lateral rotators pass inferior and posterior to the hip joint; the inferior aspect of the joint is innervated by the obturator nerve (directly and via articular rami of the muscular branch to the obturator externus), and the posterior aspect is innervated by the nerve to the quadratus femoris.
- Adductors innervated by the superior gluteal nerve pass superior to the hip joint; the superior aspect of the joint is innervated by the superior gluteal nerve.

Pain perceived as coming from the hip joint may be misleading because pain can be referred from the vertebral column.

Knee Joint

The **knee joint** is our largest and most superficial joint. It is primarily a hinge type of synovial joint, allowing flexion and extension; however, the hinge movements are combined with gliding and rolling and with rotation about a vertical axis. Although the knee joint is well constructed, its function is commonly impaired when it is hyperextended (e.g., in body contact sports, such as ice hockey).

ARTICULATIONS, ARTICULAR SURFACES, AND STABILITY OF KNEE JOINT

Relevant anatomical details of the involved bones, including their articulating surfaces, were discussed in “Bones of Lower Limb,” p. 512. The articular surfaces of the knee joint are characterized by their large size and their complicated and incongruent shapes. The knee joint consists of three articulations (Figs. 5.84 and 5.85):

- Two **femorotibial articulations** (**lateral** and **medial**) between the lateral and the medial femoral and tibial condyles.
- One intermediate **femoropatellar articulation** between the patella and the femur.

The fibula is not involved in the knee joint.

The knee joint is relatively weak mechanically because of the incongruence of its articular surfaces, which has been compared to two balls sitting on a warped tabletop. The stability of the knee joint depends on (1) the strength and actions of the surrounding muscles and their tendons and (2) the ligaments that connect the femur and tibia. Of these supports, the muscles are most important; therefore, many sport injuries are preventable through appropriate conditioning and training.

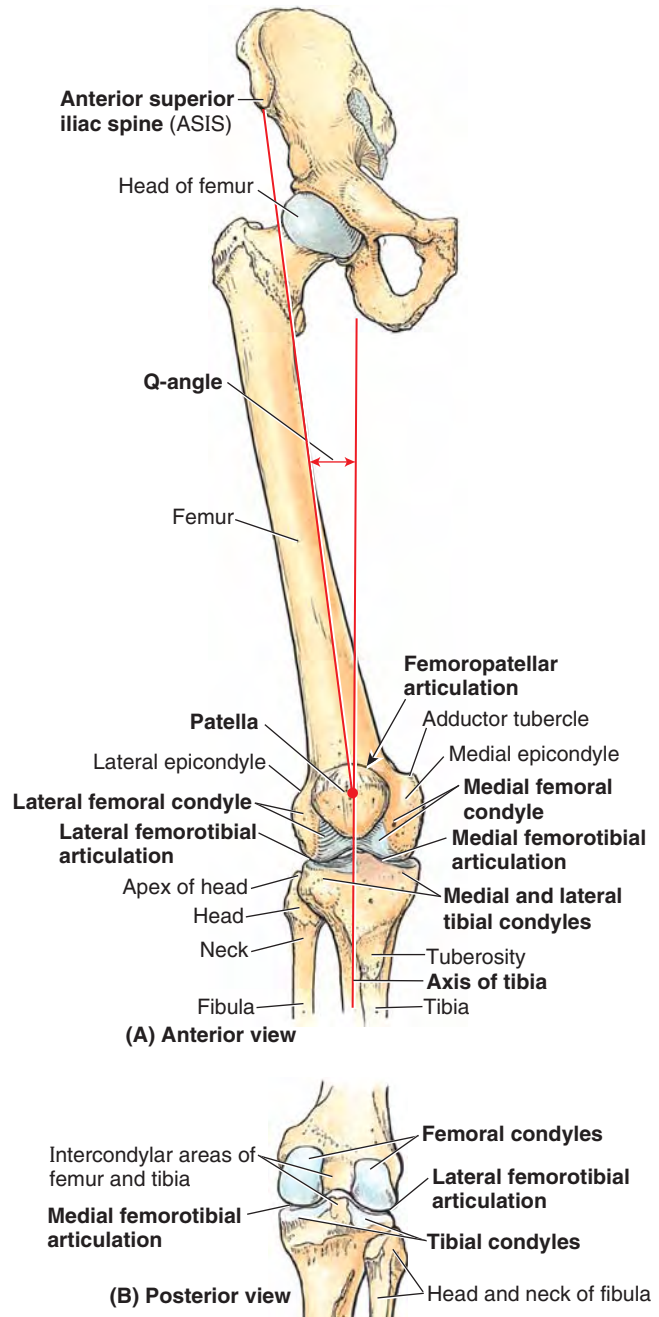
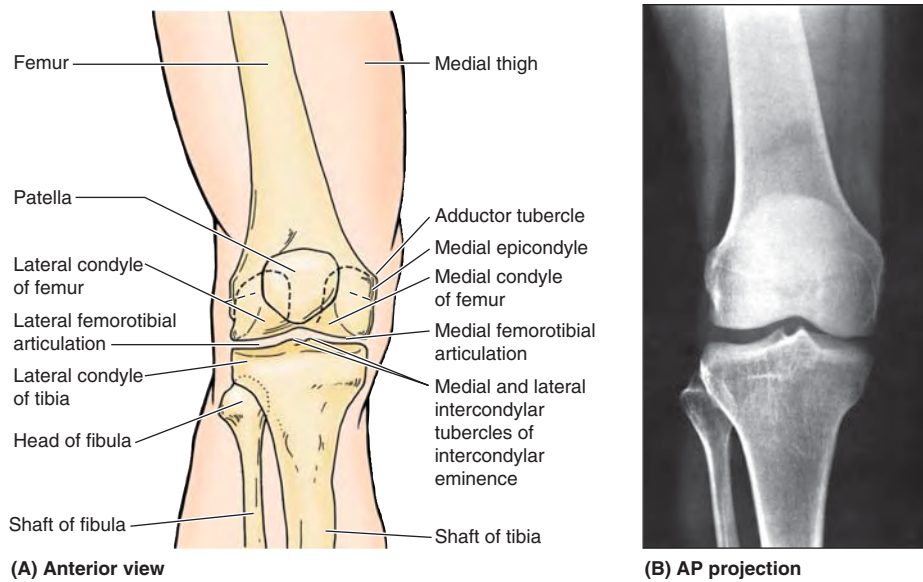


FIGURE 5.84. Bones of knee joint. **A** The bones articulating at the knee joint are shown. The hip bone and proximal femur are included to demonstrate the Q-angle, determined during physical examination to indicate alignment of the femur and tibia and to evaluate valgus or varus stress at the knee. **B**. The bones and bony features of the posterior aspect of the knee joint and knee are shown.

The most important muscle in stabilizing the knee joint is the large *quadriceps femoris*, particularly the inferior fibers of the vastus medialis and lateralis (Fig. 5.86A). The knee joint functions surprisingly well after a ligament strain if the quadriceps is well conditioned.

The erect, extended position is the most stable position of the knee. In this position the articular surfaces are most



----- Posterior aspect of condyles

FIGURE 5.85. Radiography of knee joint. **A** and **B.**

The orientation drawing depicts the structures visible in the AP radiograph of the right knee joint.

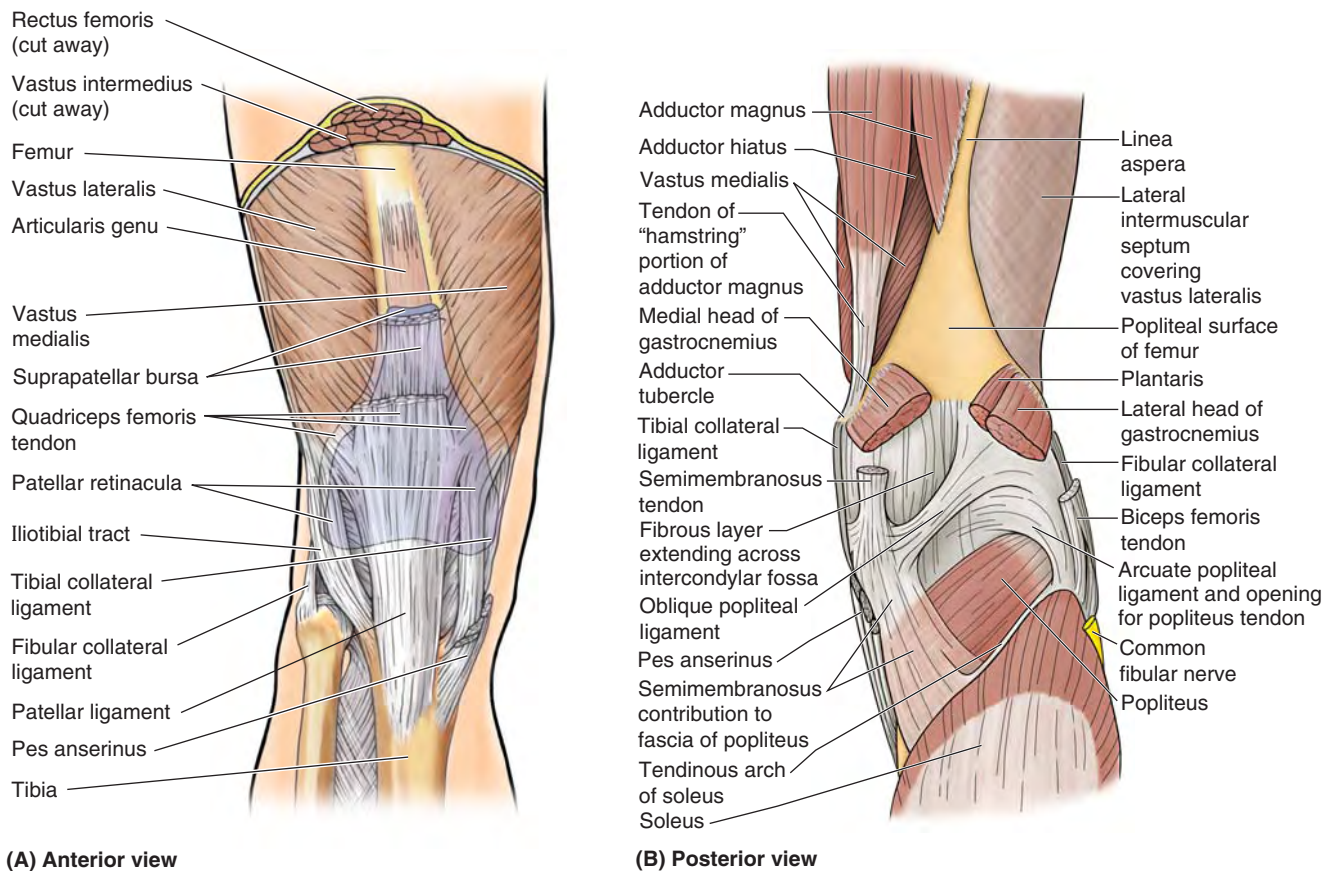


FIGURE 5.86. External aspect of joint capsule of knee. The fibrous layer of the joint capsule is relatively thin in some places and thickened in others to form reinforcing intrinsic (capsular) ligaments. **A.** Modifications of the anterior aspect and sides of the fibrous layer include the patellar retinacula, which attach to the sides of the quadriceps tendon, patella, and patellar ligament, and incorporation of the iliotibial tract (laterally) and the medial collateral ligament (medially). **B.** The hamstring and gastrocnemius muscles and the posterior intermuscular septum have been cut and removed to expose the adductor magnus, lateral intermuscular septum, and the floor of the popliteal fossa. Posterior modifications of the fibrous layer include the oblique and arcuate popliteal ligaments and a perforation inferior to the arcuate popliteal ligament to allow passage of the popliteus tendon.

congruent (contact is minimized in all other positions), the primary ligaments of the joint (collateral and cruciate ligaments) are taut, and the many tendons surrounding the joint provide a splinting effect.

JOINT CAPSULE OF KNEE JOINT

The **joint capsule of the knee joint** is typical in consisting of an external *fibrous layer of the capsule* (fibrous capsule) and an internal *synovial membrane* that lines all internal surfaces of the articular cavity not covered with articular cartilage. The fibrous layer has a few thickened parts that make up intrinsic ligaments, but for the main part, it is thin and is actually incomplete in some areas. The fibrous layer attaches to the femur superiorly, just proximal to the articular margins of the condyles. Posteriorly, the fibrous layer encloses the condyles and the *intercondylar fossa* (Fig. 5.86B). The fibrous layer has an opening posterior to the lateral tibial condyle to allow the tendon of the popliteus to pass out of the joint capsule to attach to the tibia. Inferiorly, the fibrous layer attaches to the margin of the superior articular surface (tibial plateau) of the tibia, except where the tendon of the popliteus crosses the bone (Figs. 5.86A & B and 5.87A). The quadriceps tendon, patella, and patellar ligament replace the fibrous layer anteriorly—that is, the fibrous layer is continuous with the lateral and medial margins of these structures, and there is no separate fibrous layer in the region of these structures (Figs. 5.86A and 5.87A).

The extensive *synovial membrane of the capsule* lines all surfaces bounding the articular cavity (the space containing synovial fluid) not covered by articular cartilage (Fig. 5.87A & B). Thus it attaches to the periphery of the articular cartilage covering the femoral and tibial condyles; the posterior surface of the patella; and the edges of the *menisci*, the fibrocartilaginous discs between the tibial and the femoral articular surfaces. It lines the internal surface of the fibrous layer laterally and medially, but centrally it becomes separated from the fibrous layer.

From the posterior aspect of the joint, the synovial membrane reflects anteriorly into the intercondylar region, covering the cruciate ligaments and the **infrapatellar fat pad**, so that they are excluded from the articular cavity. This creates a median **infrapatellar synovial fold**, a vertical fold of synovial membrane that approaches the posterior aspect of the patella, occupying all but the most anterior part of the intercondylar region. Thus it almost subdivides the articular cavity into right and left femorotibial articular cavities; indeed, this is how arthroscopic surgeons consider the articular cavity. Fat-filled **lateral** and **medial alar folds** cover the inner surface of fat pads that occupy the space on each side of the patellar ligament internal to the fibrous layer.

Superior to the patella, the knee joint cavity extends deep to the vastus intermedius as the suprapatellar bursa (Figs. 5.86A and 5.88A & B). The synovial membrane of the joint capsule is continuous with the synovial lining of this bursa. This large bursa usually extends approximately 5 cm superior

to the patella; however, it may extend halfway up the anterior aspect of the femur. Muscle slips deep to the vastus intermedius form the *articular muscle of the knee*, which attaches to the synovial membrane and retracts the bursa during extension of the knee (see Figs. 5.22 and 5.86A).

EXTRACAPSULAR LIGAMENTS OF KNEE JOINT

The joint capsule is strengthened by five extracapsular or capsular (intrinsic) ligaments: patellar ligament, fibular collateral ligament, tibial collateral ligament, oblique popliteal ligament, and arcuate popliteal ligament (Fig. 5.86A & B). They are sometimes called *external ligaments* to differentiate them from internal ligaments, such as the cruciate ligaments.

The *patellar ligament*, the distal part of the quadriceps tendon, is a strong, thick fibrous band passing from the apex and adjoining margins of the patella to the tibial tuberosity (Fig. 5.86A). The patellar ligament is the anterior ligament of the knee joint. Laterally, it receives the *medial* and *lateral patellar retinacula*, aponeurotic expansions of the vastus medialis and lateralis and overlying deep fascia. The retinacula make up the joint capsule of the knee on each side of the patella (Figs. 5.86A and 5.87A) and play an important role in maintaining alignment of the patella relative to the patellar articular surface of the femur. The oblique placement of the femur and/or line of pull of the quadriceps femoris muscle relative to the axis of the patellar tendon and tibia, assessed clinically as the *Q-angle*, favors lateral displacement of the patella (Fig. 5.84).

The *collateral ligaments of the knee* are taut when the knee is fully extended, contributing to stability while standing (Fig. 5.88A & D). As flexion proceeds, they become increasingly slack, permitting and limiting (serving as check ligaments for) rotation at the knee.

The **fibular collateral ligament (FCL;** lateral collateral ligament), a cord-like extracapsular ligament, is strong. It extends inferiorly from the lateral epicondyle of the femur to the lateral surface of the fibular head (Fig. 5.88A & C). The tendon of the popliteus passes deep to the FCL, separating it from the lateral meniscus. The tendon of the biceps femoris is split into two parts by this ligament (Fig. 5.88A).

The **tibial collateral ligament (TCL;** medial collateral ligament) is a strong, flat, intrinsic (capsular) band that extends from the medial epicondyle of the femur to the medial condyle and the superior part of the medial surface of the tibia (Fig. 5.88D & E). At its midpoint, the deep fibers of the TCL are firmly attached to the medial meniscus. The TCL, weaker than the FCL, is more often damaged. As a result, the TCL and medial meniscus are commonly torn during contact sports such as football and ice hockey.

The **oblique popliteal ligament** is a recurrent expansion of the tendon of the semimembranosus that reinforces the joint capsule posteriorly as it spans the intracondylar fossa (Fig. 5.86B). The ligament arises posterior to the medial tibial condyle and passes superolaterally toward the lateral femoral condyle, blending with the central part of the posterior aspect of the joint capsule.

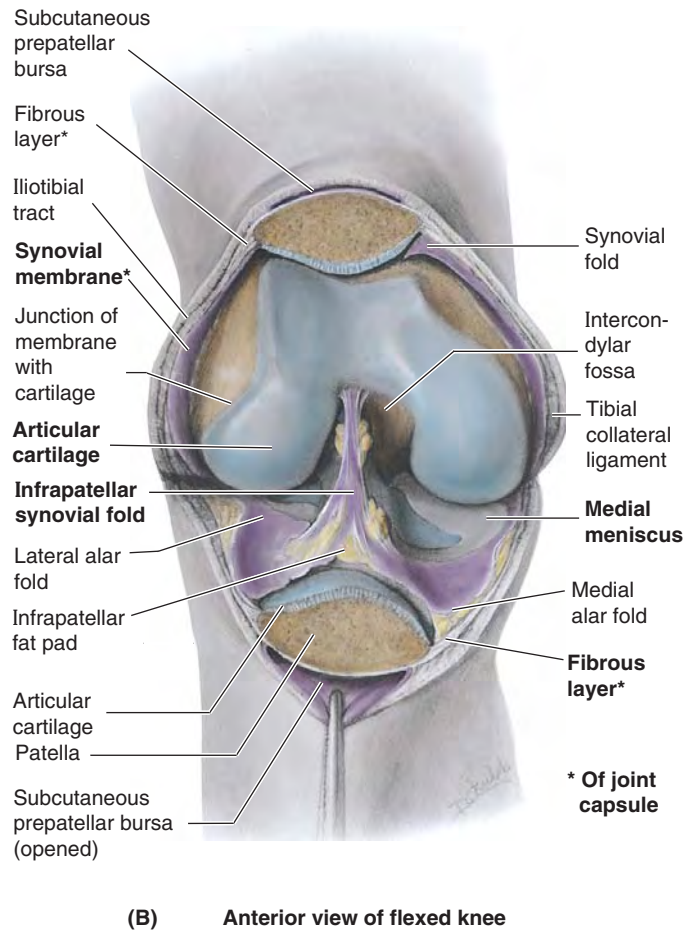
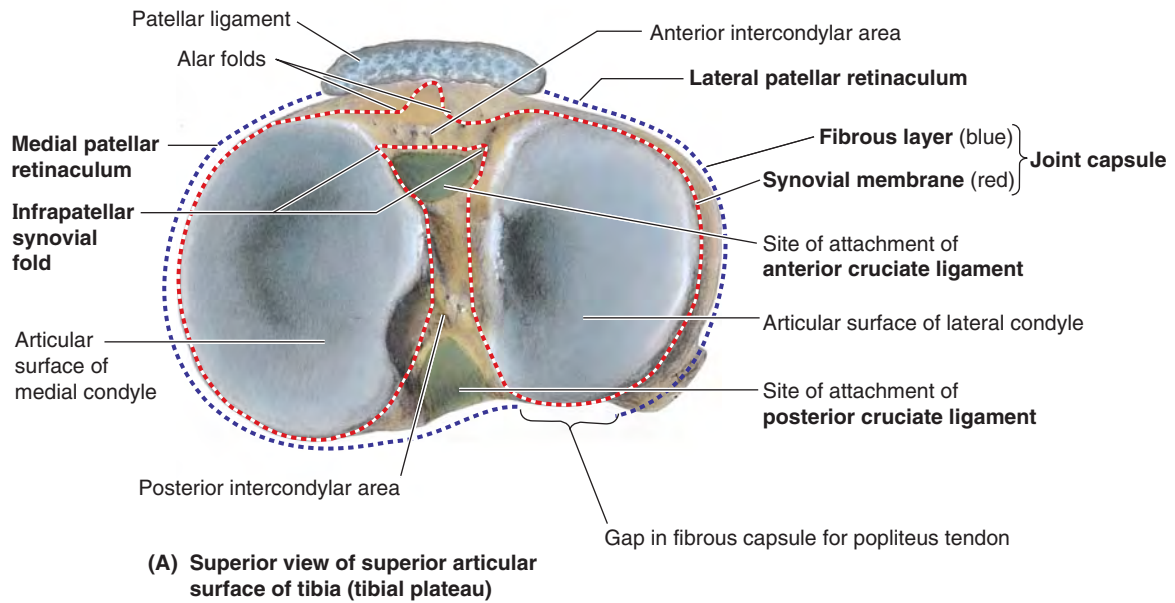


FIGURE 5.87. Internal aspect of joint capsule of knee: layers, articular cavity, and articular surfaces. A. The attachments of the fibrous layer and synovial membrane to the tibia are shown. Note that although they are adjacent on each side, they part company centrally to accommodate intercondylar and infrapatellar structures that are intracapsular (inside the fibrous layer) but extra-articular (excluded from the articular cavity by synovial membrane). B. The joint capsule was incised transversely, the patella was sawn through, and then the knee was flexed, opening the articular cavity. The infrapatellar fold of synovial membrane encloses the cruciate ligaments, excluding them from the joint cavity. All internal surfaces not covered with or made of articular cartilage (blue, or gray in the case of the menisci) are lined with synovial membrane (mostly purple, but transparent and colorless where it is covering non-articular surfaces of the femur).

The **arcuate popliteal ligament** also strengthens the joint capsule posterolaterally. It arises from the posterior aspect of the fibular head, passes superomedially over the tendon of the popliteus, and spreads over the posterior surface of the knee joint. Its development appears to be inversely

related to the presence and size of a fabella in the proximal attachment of the lateral head of gastrocnemius (see blue box “Fabella in Gastrocnemius” on p. 606). Both structures are thought to contribute to posterolateral stability of the knee.

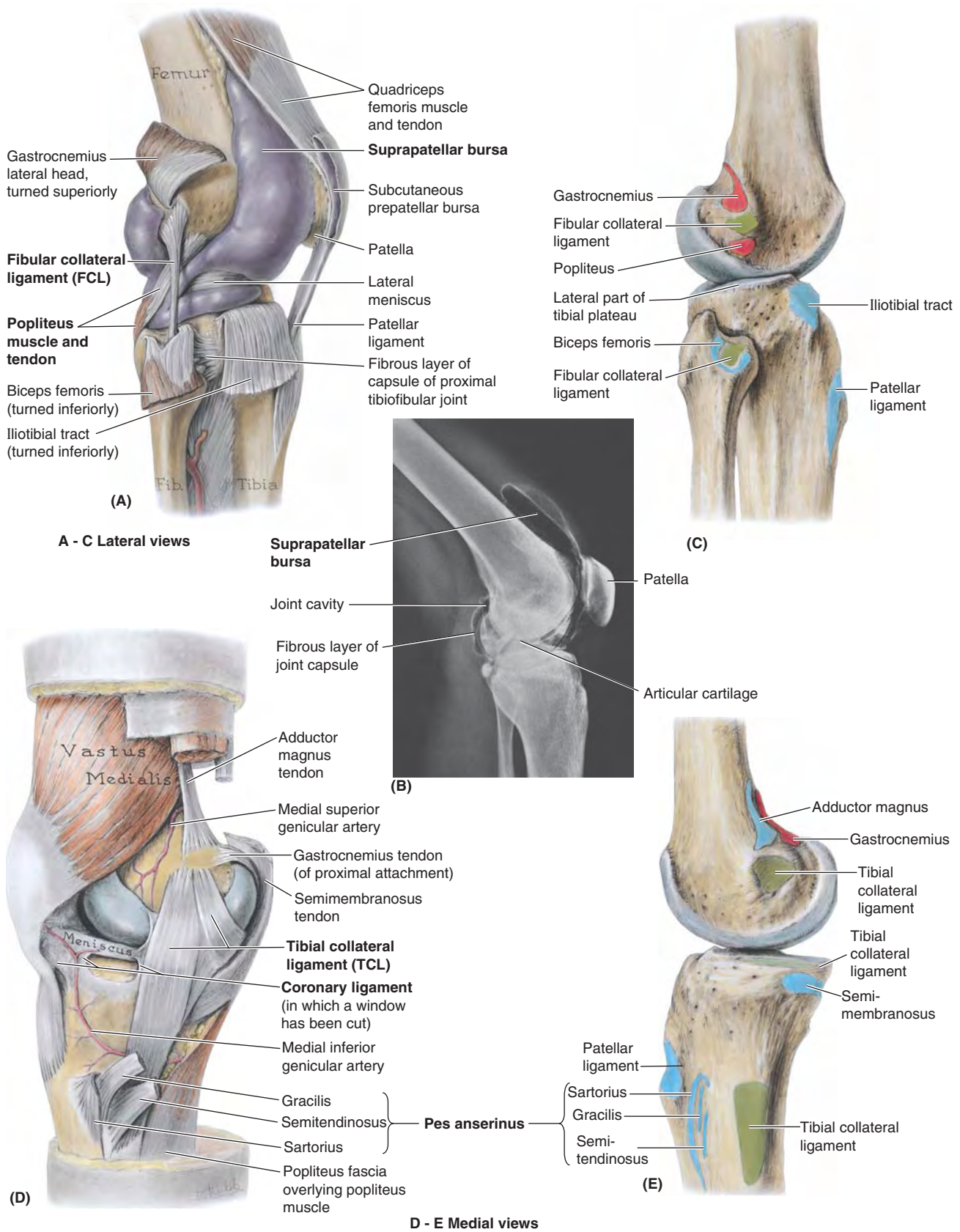


FIGURE 5.88. Collateral ligaments and bursae of knee joint. **A.** Fibular collateral ligament. Purple latex was injected to demonstrate the extensive and complex articular cavity. The cavity/synovial membrane extends superiorly deep to the quadriceps, forming the suprapatellar bursa. **B.** Arthrogram, knee joint slightly flexed. The suprapatellar bursa is inflated with CO₂. **C.** The attachment sites of the FCL (green) and related muscles (red, proximal; blue, distal). **D.** Tibial collateral ligament (isolated from the fibrous layer of the joint capsule, of which it is a part). **E.** The attachment sites of the TCL and related muscles.

INTRA-ARTICULAR LIGAMENTS OF KNEE JOINT

The intra-articular ligaments within the knee joint consist of the cruciate ligaments and menisci. The tendon of the popliteus is also intra-articular during part of its course.

The **cruciate ligaments** (*L. crux*, a cross) crisscross within the joint capsule of the joint but outside the synovial cavity (Figs. 5.89 and 5.90). The cruciate ligaments are located in the center of the joint and cross each other obliquely, like the letter X. During medial rotation of the tibia on the femur, the

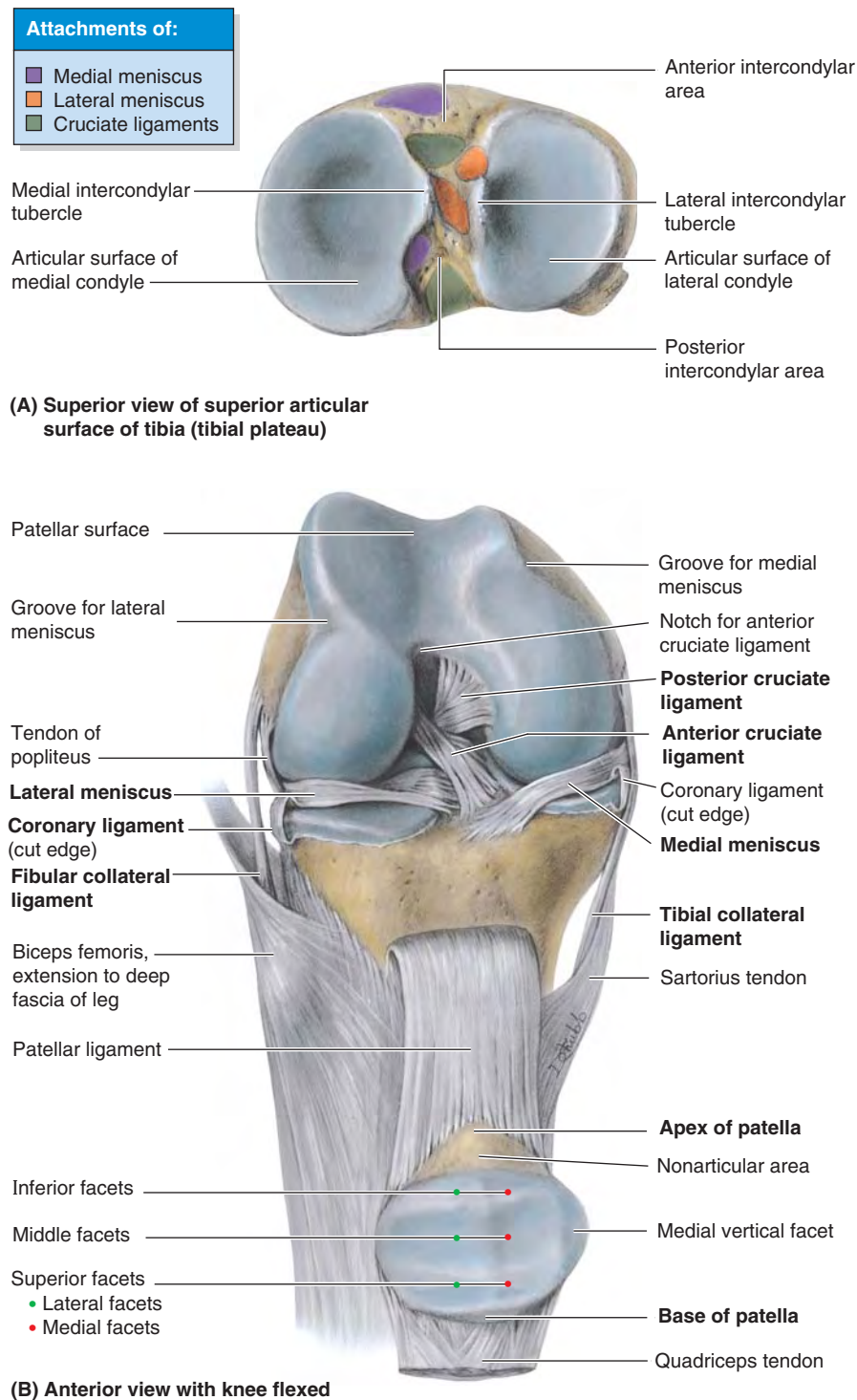


FIGURE 5.89. Cruciate ligaments of knee joint. A. Superior aspect of the superior articular surface of the tibia (tibial plateau) showing the medial and lateral condyles (articular surfaces) and the intercondylar eminence between them. The sites of attachment of the cruciate ligaments are colored *green*; those of the medial meniscus, *purple*; and those of the lateral meniscus, *orange*. B. The quadriceps tendon has been severed and the patella (within the tendon and its continuation, the patellar ligament) has been reflected inferiorly. The knee is flexed to demonstrate the cruciate ligaments.

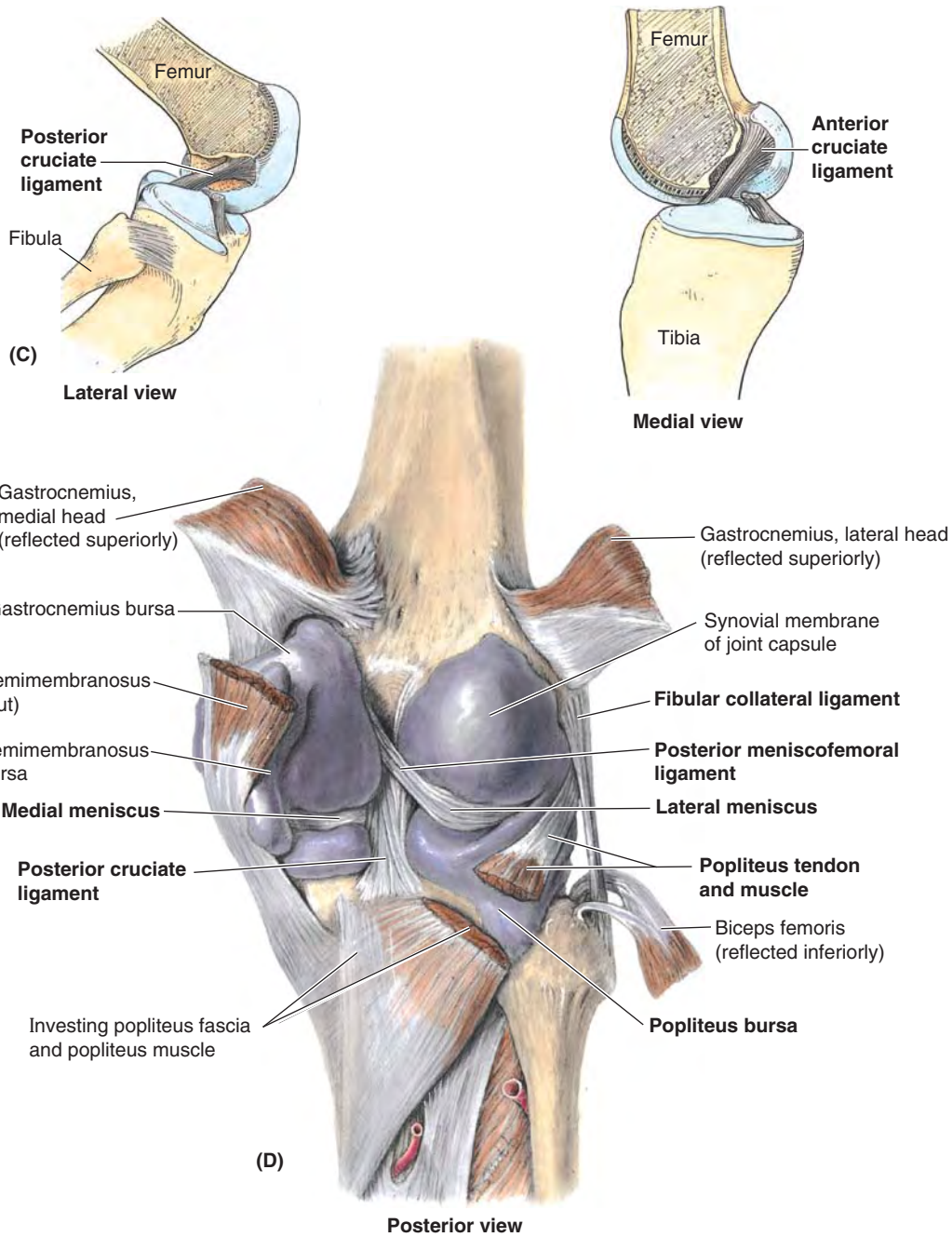


FIGURE 5.89. Cruciate ligaments of knee joint (continued). C. In these lateral and medial views, the femur has been sectioned longitudinally and the near half has been removed with the proximal part of the corresponding cruciate ligament. The lateral view demonstrates how the posterior cruciate ligament resists anterior displacement of the femur on the tibial plateau. The medial view demonstrates how the anterior cruciate ligament resists posterior displacement of the femur on the tibial plateau. D. Both heads of the gastrocnemius are reflected superiorly, and the biceps femoris is reflected inferiorly. The articular cavity has been inflated with purple latex to demonstrate its continuity with the various bursae and the reflections and attachments of the complex synovial membrane.

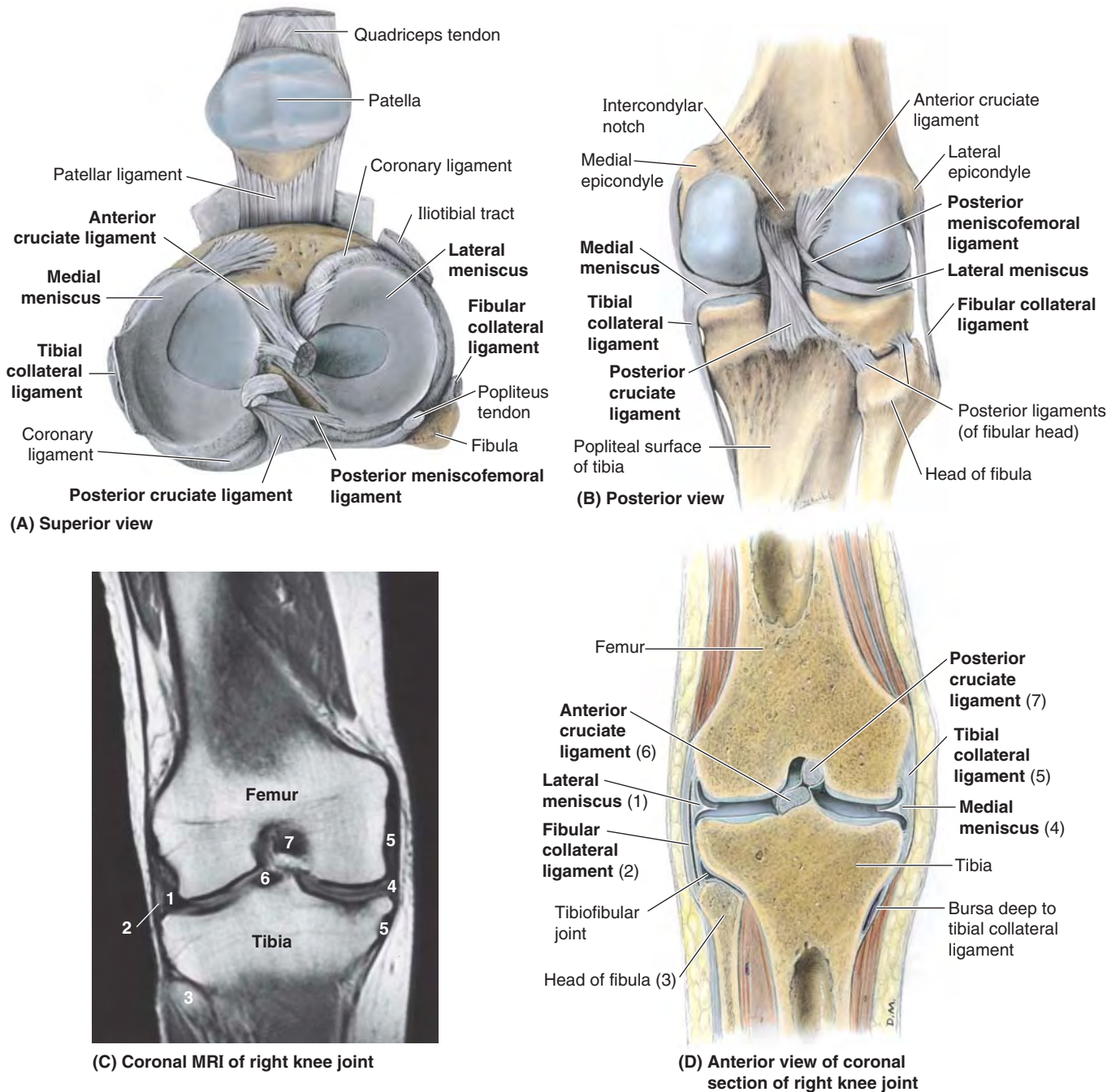


FIGURE 5.90. Menisci of knee joint. **A.** The quadriceps tendon is cut, and the patella and patellar ligament are reflected inferiorly and anteriorly. The menisci, their attachments to the intercondylar area of the tibia, and the tibial attachments of the cruciate ligaments are shown. **B.** The band-like tibial collateral ligament is attached to the medial meniscus. The cord-like fibular collateral ligament is separated from the lateral meniscus. The posterior meniscofemoral ligament attaches the lateral meniscus to the medial femoral condyle. **C and D.** The numbers on the MRI study refer to the structures labeled in the corresponding anatomical coronal section. (Part **C** courtesy of Dr. W. Kucharczyk, Chair of Medical Imaging, University of Toronto, and Clinical Director of Tri-Hospital Magnetic Resonance Centre, Toronto, Ontario, Canada.)

cruciate ligaments wind around each other; thus the amount of medial rotation possible is limited to about 10°. Because they become unwound during lateral rotation, nearly 60° of lateral rotation is possible when the knee is flexed approximately 90°, the movement being ultimately limited by the TCL. The chiasm (point of crossing) of the cruciate ligaments serves as the pivot for rotatory movements at the knee. Because of their oblique orientation, in every position one cruciate ligament, or parts of one or both ligaments, is tense. It is the cruciate ligaments that maintain contact with the femoral and tibial articular surfaces during flexion of the knee.

The **anterior cruciate ligament (ACL)**, the weaker of the two cruciate ligaments, arises from the anterior intercondylar area of the tibia, just posterior to the attachment of the medial meniscus (Fig. 5.89A). The ACL has a relatively poor blood supply. It extends superiorly, posteriorly, and laterally to attach to the posterior part of the medial side of the lateral condyle of the femur (Fig. 5.89C). It limits posterior rolling (turning and traveling) of the femoral condyles on the tibial plateau during flexion, converting it to spin (turning in place). It also prevents posterior displacement of the femur on the tibia and hyperextension of the knee joint. When the joint is flexed at a right angle, the tibia cannot be pulled anteriorly (like pulling out a drawer) because it is held by the ACL.

The **posterior cruciate ligament (PCL)**, the stronger of the two cruciate ligaments, arises from the posterior intercondylar area of the tibia (Fig. 5.89A & D). The PCL passes superiorly and anteriorly on the medial side of the ACL to attach to the anterior part of the lateral surface of the medial condyle of the femur (Fig. 5.89B & C). The PCL limits anterior rolling of the femur on the tibial plateau during extension, converting it to spin. It also prevents anterior displacement of the femur on the tibia or posterior displacement of the tibia on the femur and helps prevent hyperflexion of the knee joint. In the weight-bearing flexed knee, the PCL is the main stabilizing factor for the femur (e.g., when walking downhill).

The **menisci of the knee joint** are crescentic plates (“wafers”) of fibrocartilage on the articular surface of the tibia that deepen the surface and play a role in shock absorption (Fig. 5.90). The menisci (*G. meniskos*, crescent) are thicker at their external margins and taper to thin, unattached edges in the interior of the joint. Wedge shaped in transverse section, the menisci are firmly attached at their ends to the *intercondylar area of the tibia* (Fig. 5.89A). Their external margins attach to the joint capsule of the knee. The **coronary ligaments** are portions of the joint capsule extending between the margins of the menisci and most of the periphery of the tibial condyles (Fig. 5.89B and 5.90A). A slender fibrous band, the **transverse ligament of the knee**, joins the anterior edges of the menisci, crossing the anterior intercondylar area (Fig. 5.89A) and tethering the menisci to each other during knee movements.

The **medial meniscus** is C shaped, broader posteriorly than anteriorly (Fig. 5.90A). Its anterior end (horn) is attached to the anterior intercondylar area of the tibia, anterior to the

attachment of the ACL (Figs. 5.89A & B and 5.90A). Its posterior end is attached to the posterior intercondylar area, anterior to the attachment of the PCL. The medial meniscus firmly adheres to the deep surface of the TCL (Figs. 5.88D and 5.90A–D). Because of its widespread attachments laterally to the tibial intercondylar area and medially to the TCL, the medial meniscus is less mobile on the tibial plateau than is the lateral meniscus.

The **lateral meniscus** is nearly circular, smaller, and more freely movable than the medial meniscus (Fig. 5.90A). The tendon of the popliteus has two parts proximally. One part attaches to the lateral epicondyle of the femur and passes between the lateral meniscus and inferior part of the lateral epicondylar surface of the femur (on the tendon’s medial aspect) and the FCL that overlies its lateral aspect (Figs. 5.88A and 5.89B & D). The other, more medial part of the popliteal tendon attaches to the posterior limb of the lateral meniscus. A strong tendinous slip, the **posterior meniscofemoral ligament**, joins the lateral meniscus to the PCL and the medial femoral condyle (Figs. 5.89D and 5.90A & B).

MOVEMENTS OF KNEE JOINT

Flexion and extension are the main knee movements; some rotation occurs when the knee is flexed. The main movements of the knee joint are illustrated in Figure 5.91 and the muscles producing them and relevant details are provided in Table 5.16.

When the knee is fully extended with the foot on the ground, the knee passively “locks” because of medial rotation of the femoral condyles on the tibial plateau (the “screw-home mechanism”). This position makes the lower limb a solid column and more adapted for weight-bearing. When the knee is “locked,” the thigh and leg muscles can relax briefly without making the knee joint too unstable. To unlock the knee, the popliteus contracts, rotating the femur laterally about 5° on the tibial plateau so that flexion of the knee can occur.

Movements of Menisci. Although the rolling movement of the femoral condyles during flexion and extension is limited (converted to spin) by the cruciate ligaments, some rolling does occur, and the point of contact between the femur and the tibia moves posteriorly with flexion and returns anteriorly with extension. Furthermore, during rotation of the knee, one femoral condyle moves anteriorly on the corresponding tibial condyle while the other femoral condyle moves posteriorly, rotating about the cruciate ligaments. The menisci must be able to migrate on the tibial plateau as the points of contact between femur and tibia change.

BLOOD SUPPLY OF KNEE JOINT

The arteries supplying the knee joint are the 10 vessels that form the periarticular **genicular anastomoses** around the knee: the genicular branches of the femoral, popliteal, and anterior and posterior recurrent branches of the anterior tibial recurrent and circumflex fibular arteries (Figs. 5.92 and 5.93B). The middle genicular branches of the popliteal artery

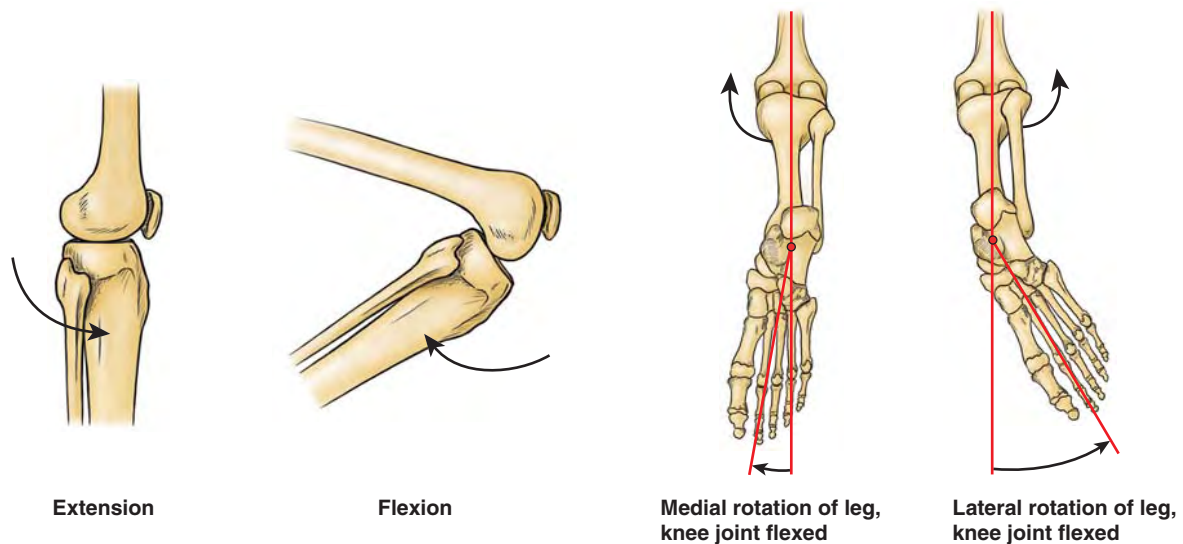


FIGURE 5.91. Movements of knee joint.

TABLE 5.16. MOVEMENTS OF KNEE JOINT AND MUSCLES PRODUCING THEM

| Movement | Degrees Possible | Muscles Producing Movement | | Factors Limiting (Checking) Movement | Comments |
|------------------|--|---|---|---|--|
| | | Primary | Secondary | | |
| Extension | | Quadriceps femoris | Weakly: tensor of fascia lata | Anterior edge of lateral meniscus contacts shallow groove between tibial and patellar surfaces of femoral condyles; anterior cruciate ligament contacts groove in intercondylar fossa | Ability of quadriceps to produce extension is most effective when hip joint is extended; flexion diminishes its efficiency |
| Flexion | 120° (hip extended); 140° (hip flexed); 160° passively | Hamstrings (semitendinosus, semimembranosus, long head of biceps); short head of biceps | Gracilis, sartorius, gastrocnemius, popliteus | Calf of leg contacts thigh; length of hamstrings is also a factor—more knee flexion is possible when hip joint is flexed; cannot fully flex knee when hip is extended | Normally, role of gastrocnemius is minimal, but in presence of a supracondylar fracture, it rotates (flexes) distal fragment of femur |
| Medial rotation | 10° with knee flexed; 5° with knee extended | Semitendinosus and semimembranosus when knee is flexed; popliteus when non-bearing knee is extended | Gracilis, sartorius | Collateral ligaments, loose during flexion without rotation, become taut at limits of rotation | When extended knee is bearing weight, action of popliteus laterally rotates femur; when not bearing weight, popliteus medially rotates patella |
| Lateral rotation | 30° | Biceps femoris when knee is flexed | | Collateral ligaments become taut; anterior cruciate ligament becomes wound around posterior cruciate ligament | At end of rotation, with no opposition, tensor of fascia lata can assist in maintaining position |

penetrate the fibrous layer of the joint capsule and supply the cruciate ligaments, synovial membrane, and peripheral margins of the menisci.

INNERVATION OF KNEE JOINT

Reflecting Hilton's law, the nerves supplying the muscles crossing (acting on) the knee joint also supply the joint (Fig. 5.93D); thus articular branches from the femoral (the branches

to the vasti), tibial, and common fibular nerves supply its anterior, posterior, and lateral aspects, respectively. In addition, however, the obturator and saphenous (cutaneous) nerves supply articular branches to its medial aspect.

BURSAE AROUND KNEE JOINT

There are at least 12 bursae around the knee joint because most tendons run parallel to the bones and pull lengthwise across

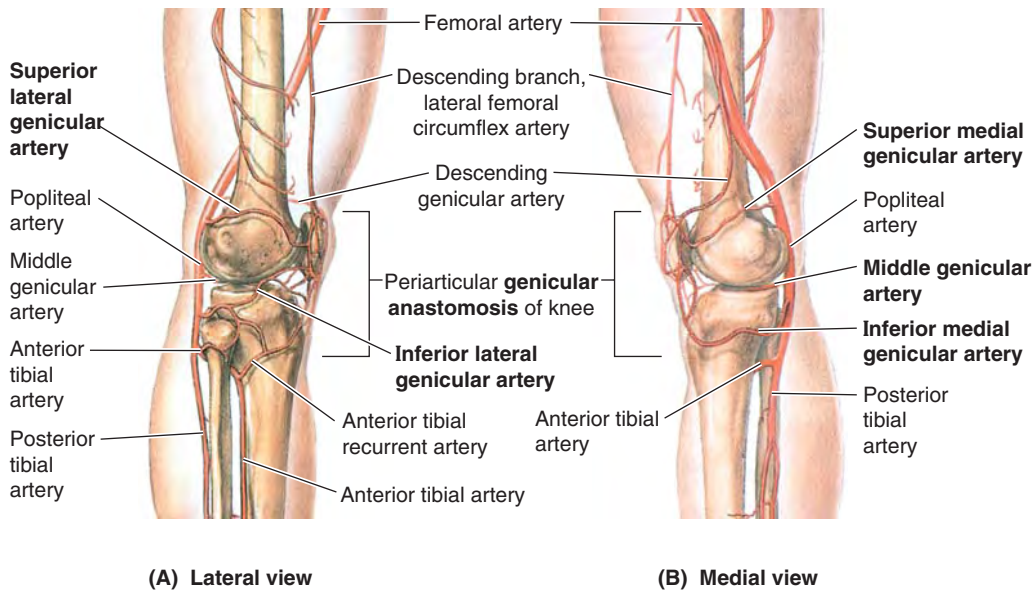


FIGURE 5.92. Arterial anastomoses around knee. In addition to providing collateral circulation, the genicular arteries of the genicular anastomosis supply blood to the structures surrounding the joint as well as to the joint itself (e.g., its joint or articular capsule). Compare these views with the anterior view in Figure 5.93B.

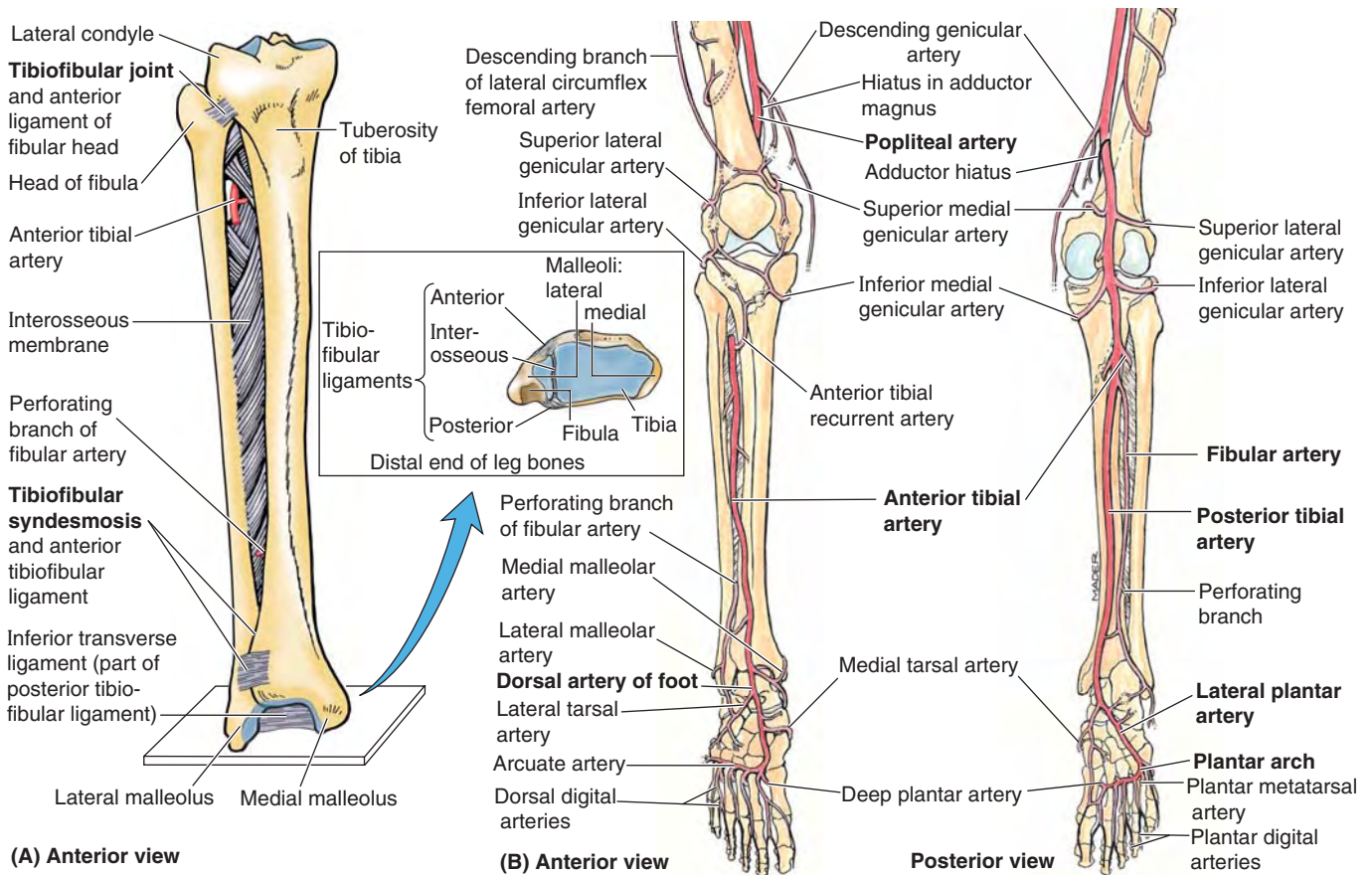


FIGURE 5.93. Joints and neurovascular structures of leg and foot. **A.** The tibiofibular articulations include the synovial tibiofibular joint and the tibiofibular syndesmosis; the latter is made up of the interosseous membrane of the leg and the anterior and posterior tibiofibular ligaments. The oblique direction of the fibers of the interosseous membrane, primarily extending inferolaterally from the tibia, allows slight upward movement of the fibula but resists downward pull on it. **B.** The arterial supply of the joints of the leg and foot is demonstrated. Periarticular anastomoses surround the knee and ankle.

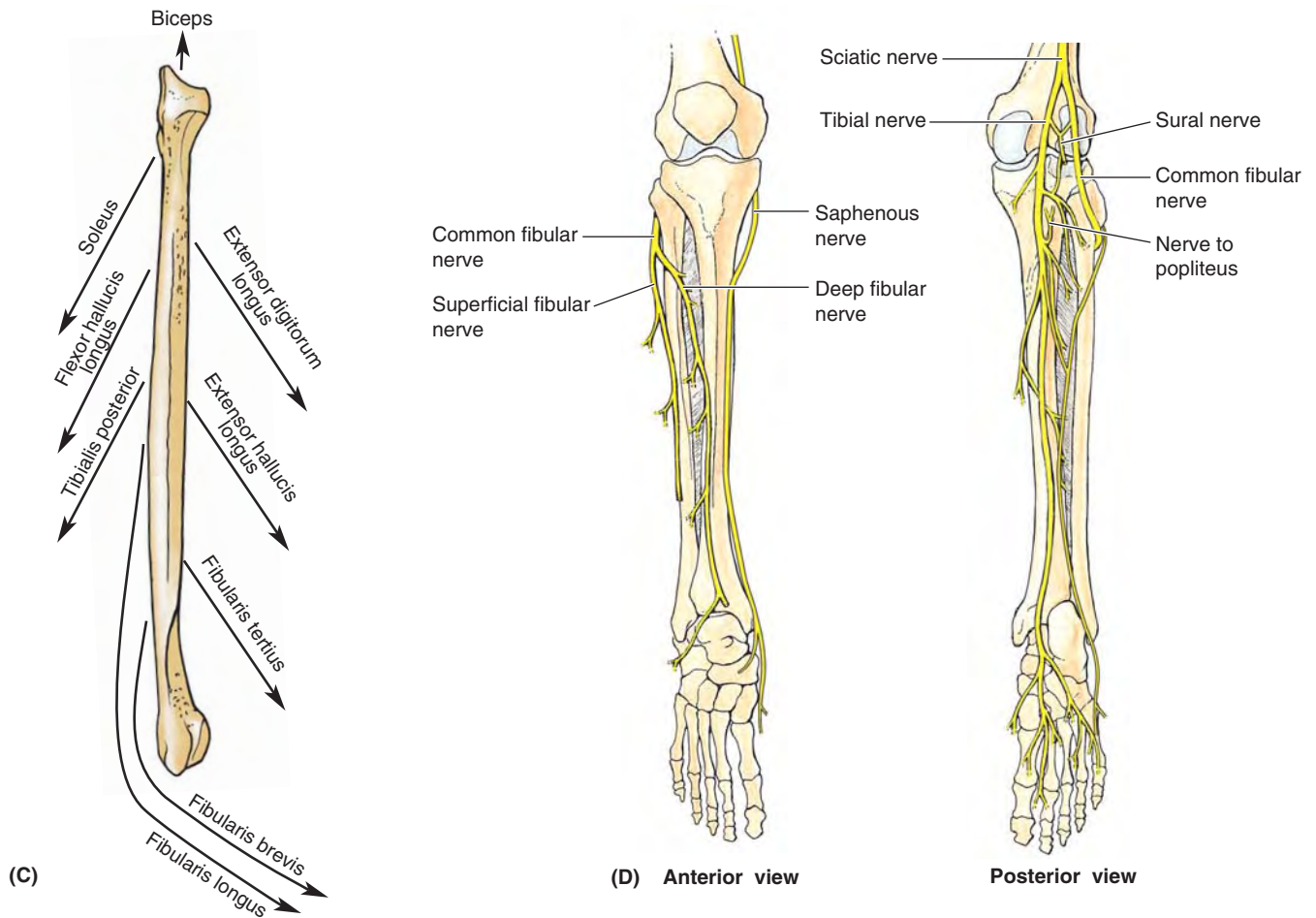


FIGURE 5.93. Joints and neurovascular structures of leg and foot (continued). C. Of the nine muscles attached to the fibula, all except one exert a downward pull on the fibula. D. The nerve supply of the leg and foot is demonstrated. Starting with the knee and progressing distally in the limb, cutaneous nerves become increasingly involved in providing innervation to joints, taking over completely in the distal foot and toes.

the joint during knee movements. The main bursae of the knee are illustrated in Figure 5.94 and described in Table 5.17.

The **subcutaneous prepatellar** and **infrapatellar bursae** are located at the convex surface of the joint, allowing the skin to be able to move freely during movements of the knee (see Figs. 5.87B and 5.88A).

Four bursae communicate with the synovial cavity of the knee joint: suprapatellar bursa, popliteus bursa (deep to the distal quadriceps), anserine bursa (deep to the tendinous distal attachments of the sartorius, gracilis, and semitendinosus), and gastrocnemius bursa (Figs. 5.88A and 5.89D). The large **suprapatellar bursa** (Figs. 5.86A and 5.88A) is especially important because an infection in it may spread to the knee joint cavity. Although it develops separately from the knee joint, the bursa becomes continuous with it.

Tibiofibular Joints

The tibia and fibula are connected by two joints: the *tibiofibular joint* and the *tibiofibular syndesmosis* (inferior tibiofibular joint). In addition, an *interosseous membrane* joins the

shafts of the two bones (Fig. 5.93A). The fibers of the interosseous membrane and all ligaments of both tibiofibular articulations run inferiorly from the tibia to the fibula. Thus the membrane and ligaments strongly resist the downward pull placed on the fibula by eight of the nine muscles attached to it (Fig. 5.93C). However, they allow slight upward movement of the fibula that occurs when the wide (posterior) end of the trochlea of the talus is wedged between the malleoli during dorsiflexion at the ankle. Movement at the superior tibiofibular joint is impossible without movement at the inferior tibiofibular syndesmosis.

The anterior tibial vessels pass through a hiatus at the superior end of the interosseous membrane (Fig. 5.93A & B). At the inferior end of the membrane is a smaller hiatus through which the perforating branch of the fibular artery passes.

TIBIOFIBULAR JOINT

The **tibiofibular joint** (superior tibiofibular joint) is a plane type of synovial joint between the flat facet on the fibular head and a similar articular facet located posterolaterally on

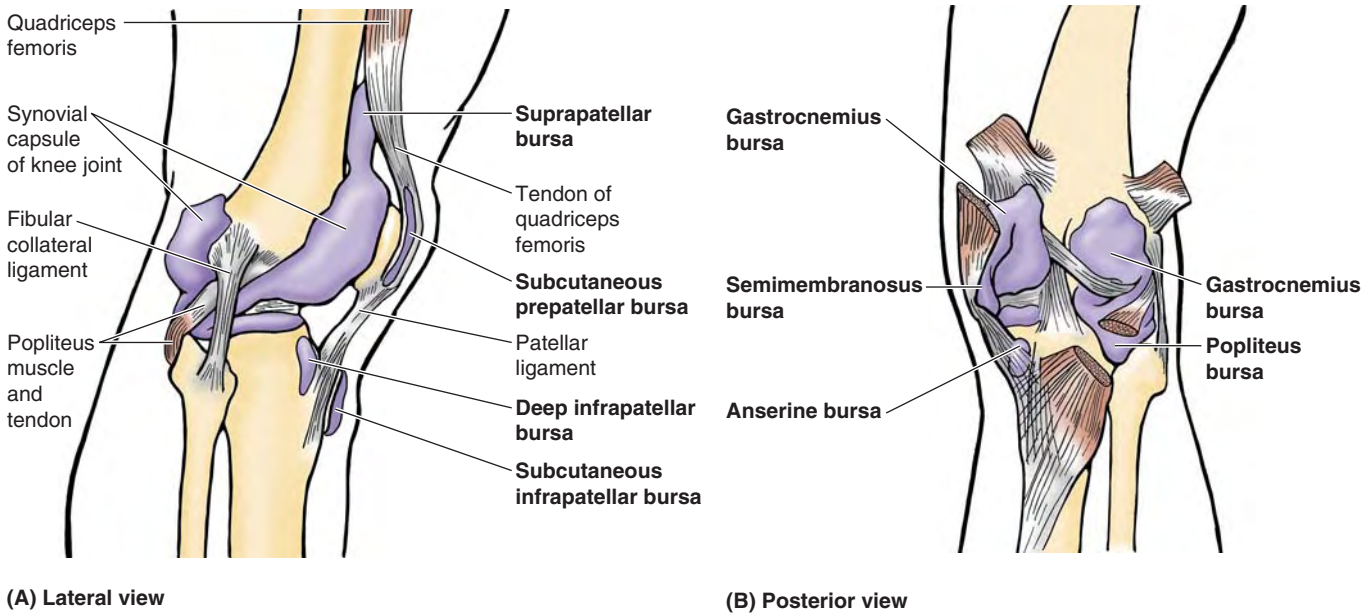


FIGURE 5.94. Bursae around knee joint and proximal leg.

TABLE 5.17. BURSAE AROUND KNEE JOINT

| Bursae | Locations | Comments |
|----------------------------|--|--|
| Suprapatellar | Between femur and tendon of quadriceps femoris | Held in position by articular muscle of knee; communicates freely with (superior extension of) synovial cavity of knee joint |
| Popliteus | Between tendon of popliteus and lateral condyle of tibia | Opens into synovial cavity of knee joint inferior to lateral meniscus |
| Anserine | Separates tendons of sartorius, gracilis, and semitendinosus from tibia and tibial collateral ligament | Area where tendons of these muscles attach to tibia; resembles a goose's foot (<i>L. pes anserinus</i>) |
| Gastrocnemius | Deep to proximal attachment of tendon of medial head of gastrocnemius | An extension of synovial cavity of knee joint |
| Semimembranosus | Between medial head of gastrocnemius and semimembranosus tendon | Related to distal attachment of semimembranosus |
| Subcutaneous prepatellar | Between skin and anterior surface of patella | Allows free movement of skin over patella during movements of leg |
| Subcutaneous infrapatellar | Between skin and tibial tuberosity | Helps knee withstand pressure when kneeling |
| Deep infrapatellar | Between patellar ligament and anterior surface of tibia | Separated from knee joint by infrapatellar fat pad |

the lateral tibial condyle (Figs. 5.90B & D and 5.93A). A tense joint capsule surrounds the joint and attaches to the margins of the articular surfaces of the fibula and tibia. The joint capsule is strengthened by *anterior* and *posterior ligaments of the fibular head*, which pass superomedially from the fibular head to the lateral tibial condyle (Fig. 5.90B). The joint is crossed posteriorly by the tendon of the popliteus. A pouch of synovial membrane from the knee joint, the *popliteus bursa* (Fig. 5.94; Table 5.17), passes between the tendon of the popliteus and the lateral condyle of the tibia. About

20% of the time, the bursa also communicates with the synovial cavity of the tibiofibular joint, enabling transmigration of inflammatory processes between the two joints.

Movement. Slight movement of the joint occurs during dorsiflexion of the foot as a result of wedging of the trochlea of the talus between the malleoli (see “Articular Surfaces of Ankle Joint,” p. 647).

Blood Supply. The arteries of the superior tibiofibular joint are from the inferior lateral genicular and anterior tibial recurrent arteries (Figs. 5.92A and 5.93B).

Nerve Supply. The nerves of the tibiofibular joint are from the common fibular nerve and the nerve to the popliteus (Fig. 5.93D).

TIBIOFIBULAR SYNDESMOSIS

The **tibiofibular syndesmosis** is a compound fibrous joint. It is the fibrous union of the tibia and fibula by means of the *interosseous membrane* (uniting the shafts) and the *anterior, interosseous, and posterior tibiofibular ligaments* (the latter making up the **inferior tibiofibular joint**, uniting the distal ends of the bones). The integrity of the inferior tibiofibular joint is essential for the stability of the ankle joint because it keeps the lateral malleolus firmly against the lateral surface of the talus.

Articular Surfaces and Ligaments. The rough, triangular articular area on the medial surface of the inferior end of the fibula articulates with a facet on the inferior end of the tibia (Fig. 5.93A). The strong deep **interosseous tibiofibular ligament**, continuous superiorly with the interosseous membrane, forms the principal connection between the tibia and the fibula. The joint is also strengthened anteriorly and posteriorly by the strong external **anterior and posterior tibiofibular ligaments**. The distal deep continuation of the posterior tibiofibular ligament, the **inferior transverse (tibiofibular) ligament**, forms a strong connection between the distal ends of the tibia (medial malleolus) and the fibula (lateral malleolus). It contacts the talus and forms the posterior “wall” of a square socket (with three deep walls and a shallow or open anterior wall), the **malleolar mortise**, for the trochlea of the talus. The lateral and medial walls of the mortise are formed by the respective malleoli (Fig. 5.95).

Movement. Slight movement of the joint occurs to accommodate wedging of the wide portion of the trochlea of the talus between the malleoli during dorsiflexion of the foot.

Blood Supply. The arteries are from the perforating branch of the fibular artery and from medial malleolar branches of the anterior and posterior tibial arteries (Fig. 5.93B).

Nerve Supply. The nerves to the syndesmosis are from the deep fibular, tibial, and saphenous nerves (Fig. 5.93D).

Ankle Joint

The **ankle joint** (talocrural articulation) is a hinge-type synovial joint. It is located between the distal ends of the tibia and the fibula and the superior part of the talus (Figs. 5.95 and 5.96). The ankle joint can be felt between the tendons on the anterior surface of the ankle as a slight depression, approximately 1 cm proximal to the tip of the medial malleolus.

ARTICULAR SURFACES OF ANKLE JOINT

The distal ends of the tibia and fibula (along with the inferior transverse part of the posterior tibiofibular ligament) (Fig. 5.93A) form a *malleolar mortise* into which the pulley-shaped *trochlea of the talus* fits (Figs. 5.95B and 5.96). The trochlea (L., pulley) is the rounded superior articular surface of the talus (see Fig. 5.99C). The medial surface of the lateral malleolus articulates with the lateral surface of the talus. The tibia articulates with the talus in two places:

1. Its inferior surface forms the roof of the malleolar mortise, transferring the body's weight to the talus.
2. Its medial malleolus articulates with the medial surface of the talus.

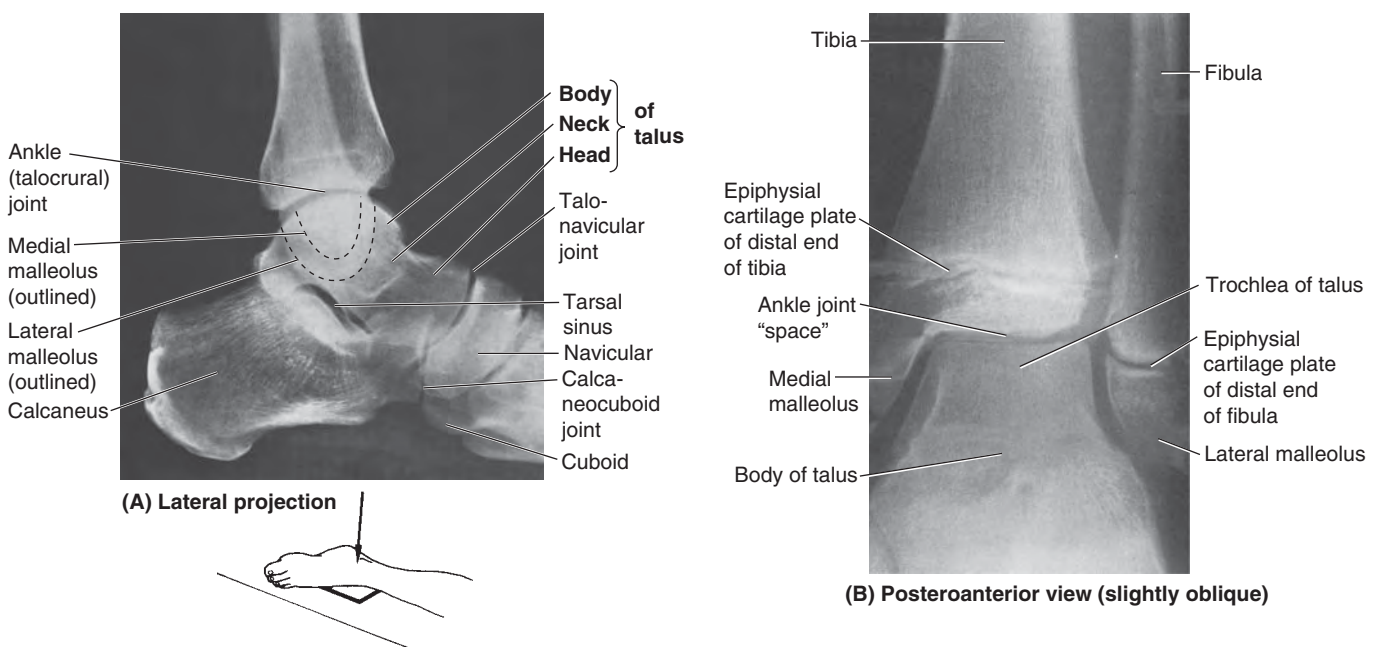


FIGURE 5.95. Ankle joint demonstrated radiographically. **A.** Left ankle (courtesy of Dr. P. Bobechko and Dr. E. Becker, Department of Medical Imaging, University of Toronto, Toronto, Ontario, Canada.) **B.** Ankle joint of 14-year-old boy. Epiphysal cartilage plates are evident at this age.

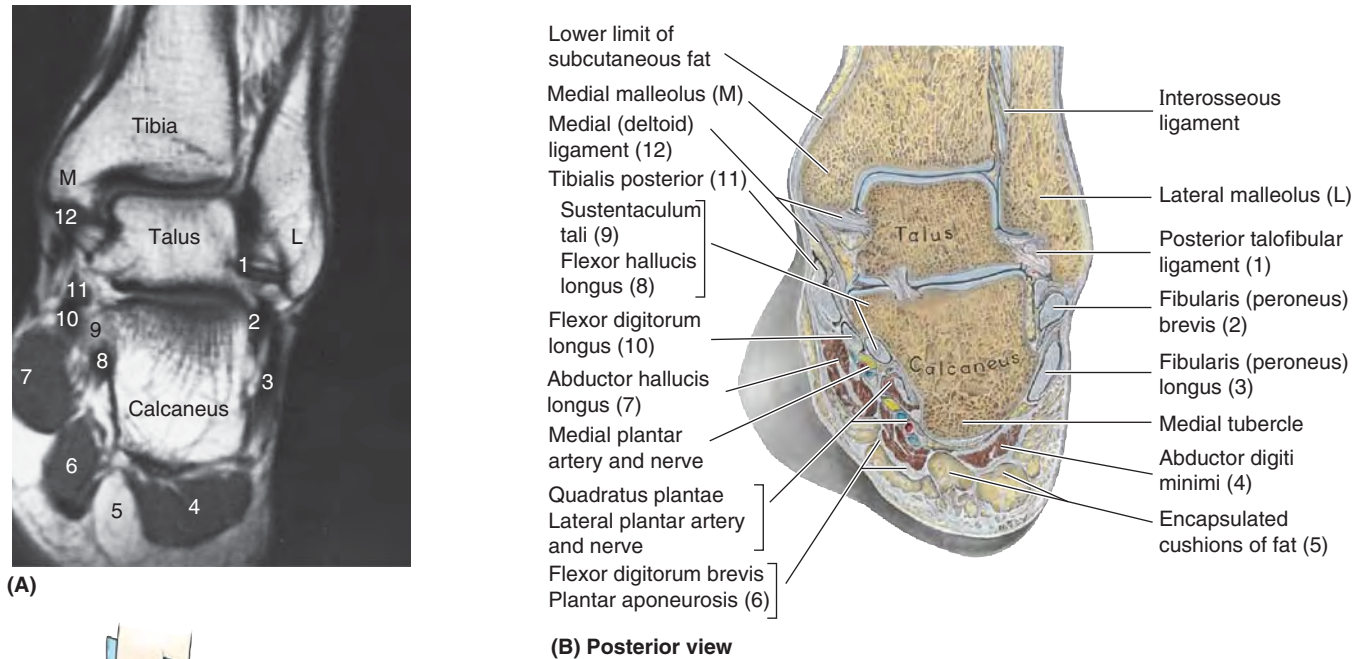


FIGURE 5.96. Sectional anatomy of ankle region. A and B. The orientation drawing depicts the structures visible in the MRI of the ankle. (Courtesy of Dr. W. Kucharczyk, Professor and Chair of Medical Imaging, University of Toronto, and Clinical Director of Tri-Hospital Magnetic Resonance Centre, Toronto, Ontario, Canada.)

The malleoli grip the talus tightly as it rocks in the mortise during movements of the joint. The grip of the malleoli on the trochlea is strongest during dorsiflexion of the foot (as when “digging in one’s heels” when descending a steep slope or during tug-of-war) because this movement forces the wider, anterior part of the trochlea posteriorly between the malleoli, spreading the tibia and fibula slightly apart. This spreading is limited especially by the strong interosseous tibiofibular ligament as well as the anterior and posterior tibiofibular ligaments that unite the tibia and fibula (Figs. 5.96 and 5.97).

The *interosseous ligament* is deeply placed between the nearly congruent surfaces of the tibia and fibula; although demonstrated in the inset for Figure 5.93A, the ligament can actually be observed only by rupturing it or in a cross-section.

The ankle joint is relatively unstable during plantarflexion because the trochlea is narrower posteriorly and, therefore, lies relatively loosely within the mortise. It is during plantarflexion that most injuries of the ankle occur (usually as a result of sudden, unexpected—and therefore inadequately resisted—inversion of the foot).

JOINT CAPSULE OF ANKLE JOINT

The **joint capsule of the ankle joint** is thin anteriorly and posteriorly but is supported on each side by strong *lateral and medial (collateral) ligaments* (Figs. 5.97 and 5.98; thin areas

of the capsule have been removed in Fig. 5.97, leaving only the reinforced parts—the ligaments—and a synovial fold). Its fibrous layer is attached superiorly to the borders of the articular surfaces of the tibia and the malleoli and inferiorly to the talus. The synovial membrane is loose and lines the fibrous layer of the capsule. The synovial cavity often extends superiorly between the tibia and the fibula as far as the interosseous tibiofibular ligament.

LIGAMENTS OF ANKLE JOINT

The ankle joint is reinforced laterally by the **lateral ligament of the ankle**, a compound structure consisting of three completely separate ligaments (Fig. 5.97A & B):

1. **Anterior talofibular ligament**, a flat, weak band that extends anteromedially from the lateral malleolus to the neck of the talus.
2. **Posterior talofibular ligament**, a thick, fairly strong band that runs horizontally medially and slightly posteriorly from the malleolar fossa to the lateral tubercle of the talus.
3. **Calcaneofibular ligament**, a round cord that passes posteroinferiorly from the tip of the lateral malleolus to the lateral surface of the calcaneus.

The joint capsule is reinforced medially by the large, strong **medial ligament of the ankle** (deltoid ligament) that attaches proximally to the medial malleolus (Fig. 5.98). The

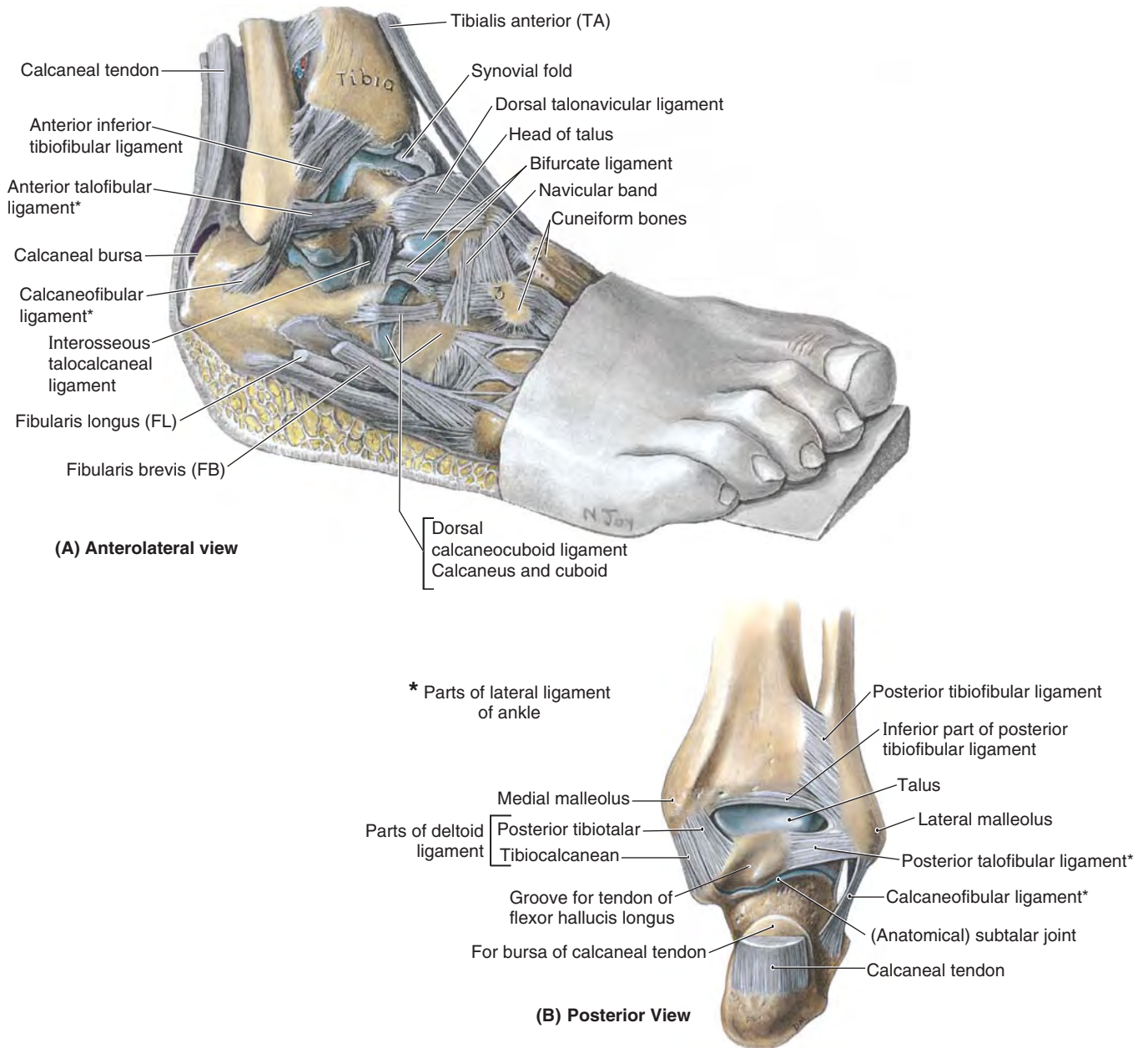


FIGURE 5.97. Dissection of ankle joint and joints of inversion and eversion. In (A), the foot has been inverted (by placing a wedge under the foot) to demonstrate the articular surfaces and make the lateral ligaments taut.

medial ligament fans out from the malleolus, attaching distally to the talus, calcaneus, and navicular via four adjacent and continuous parts: the **tibionavicular part**, the **tibiocalcaneal part**, and the **anterior** and **posterior tibiotalar parts**. The medial ligament stabilizes the ankle joint during eversion and prevents subluxation (partial dislocation) of the joint.

MOVEMENTS OF ANKLE JOINT

The main movements of the ankle joint are dorsiflexion and plantarflexion of the foot, which occur around a transverse axis passing through the talus (Fig. 5.99B). Because the narrow end of the trochlea of the talus lies loosely between the

malleoli when the foot is plantarflexed, some “wobble” (small amounts of abduction, adduction, inversion, and eversion) is possible in this unstable position.

- *Dorsiflexion of the ankle* is produced by the muscles in the anterior compartment of the leg (see Table 5.10). Dorsiflexion is usually limited by the passive resistance of the triceps surae to stretching and by tension in the medial and lateral ligaments.
- *Plantarflexion of the ankle* is produced by the muscles in the posterior compartment of the leg (see Table 5.13). In toe dancing by ballet dancers, for example, the dorsum of the foot is in line with the anterior surface of the leg.

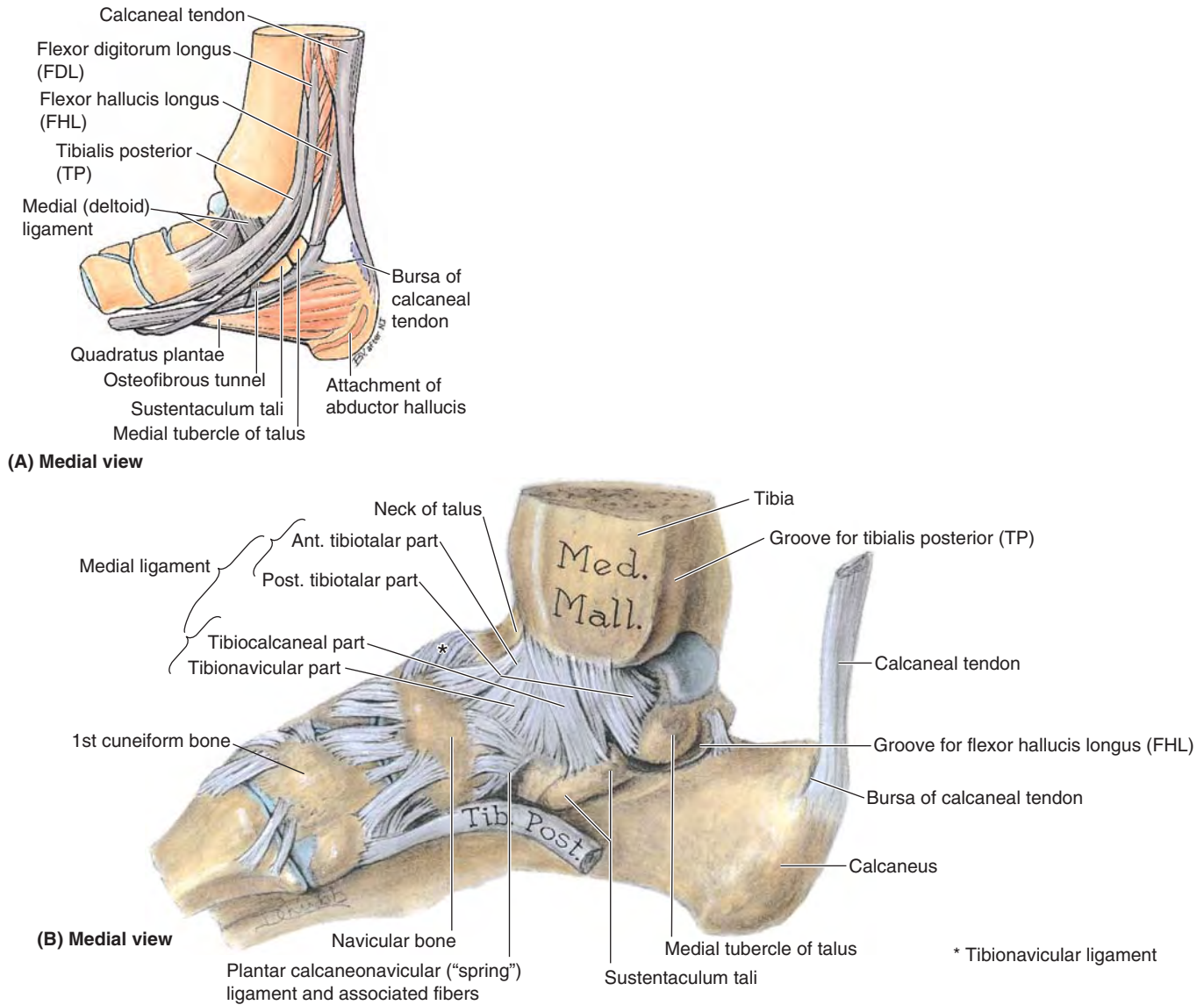


FIGURE 5.98. Tendons and ligaments on medial aspect of ankle and foot. **A.** The relationships of the flexor tendons to the medial malleolus and sustentaculum tali are shown as they descend the posterolateral aspect of the ankle region and enter the foot. Except for the part tethering the flexor hallucis longus tendon, the flexor retinaculum has been removed. **B.** The four parts of the medial (deltoid) ligament of the ankle are demonstrated in this dissection.

BLOOD SUPPLY OF ANKLE JOINT

The arteries are derived from malleolar branches of the fibular and anterior and posterior tibial arteries (Fig. 5.93B).

NERVE SUPPLY OF ANKLE JOINT

The nerves are derived from the tibial nerve and the deep fibular nerve, a division of the common fibular nerve (Fig. 5.93D).

Foot Joints

The many joints of the foot involve the tarsals, metatarsals, and phalanges (Fig. 5.99; Table 5.18). The important inter-

tarsal joints are the *subtalar (talocalcaneal) joint* and the *transverse tarsal joint (calcaneocuboid and talonavicular joints)*. Inversion and eversion of the foot are the main movements involving these joints. The other intertarsal joints (e.g., *intercuneiform joints*) and the *tarsometatarsal* and *intermetatarsal joints* are relatively small and are so tightly joined by ligaments that only slight movement occurs between them. In the foot, flexion and extension occur in the forefoot at the metatarsophalangeal and interphalangeal joints (Fig. 5.100A & B; Table 5.19). Inversion is augmented by flexion of the toes (especially the great and 2nd toes), and eversion by their extension (especially of the lateral toes). All bones of the foot proximal to the metatarsophalangeal joints are united by dorsal and plantar ligaments. The bones of the

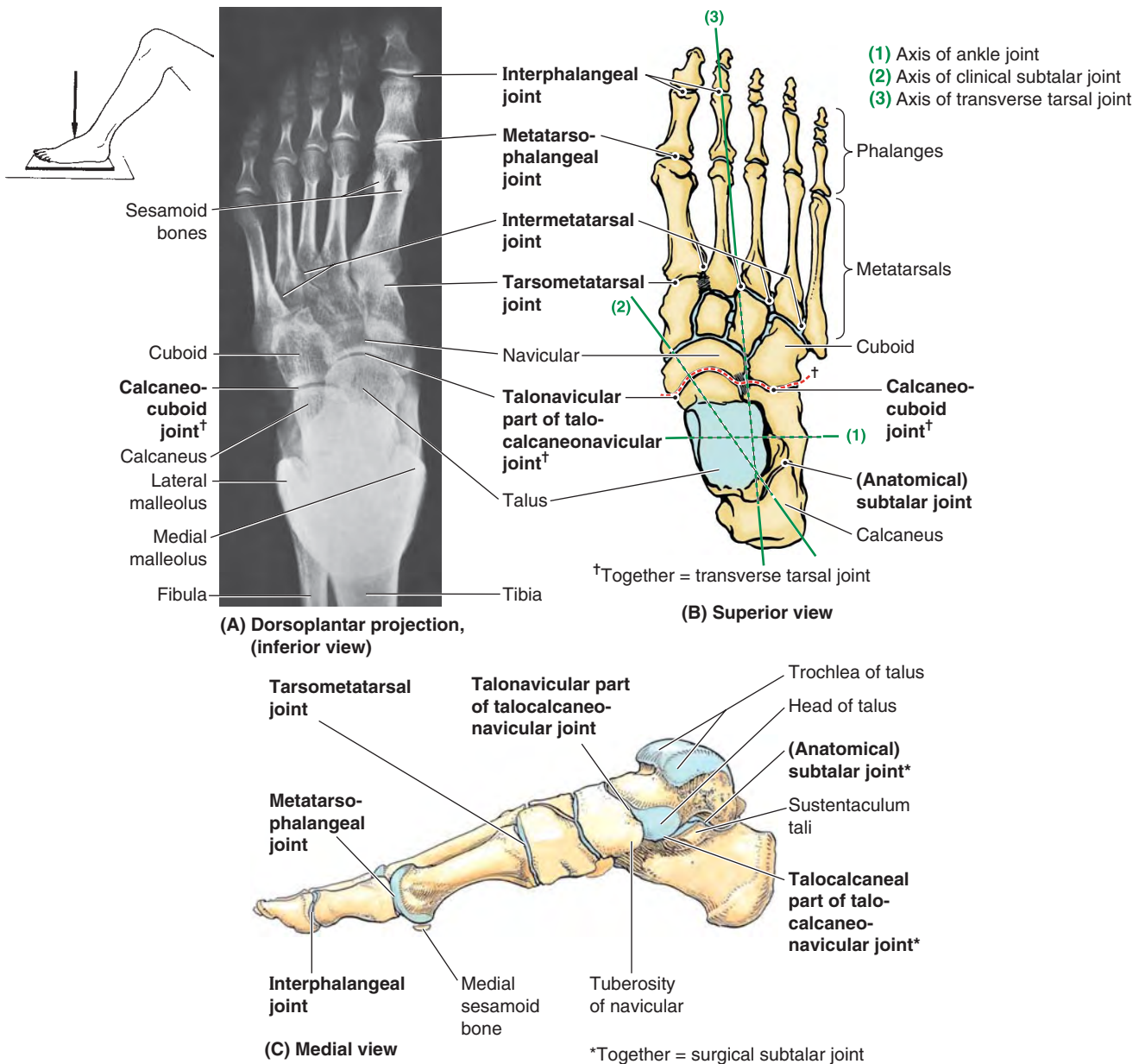


FIGURE 5.99. Joints of foot.

metatarsophalangeal and interphalangeal joints are united by lateral and medial collateral ligaments.

The **subtalar joint** occurs where the talus rests on and articulates with the calcaneus. The *anatomical subtalar joint* is a single synovial joint between the slightly concave posterior calcaneal articular surface of the talus and the convex posterior articular facet of the calcaneus (Figs. 5.96B and 5.97B). The joint capsule is weak but is supported by medial, lateral, posterior, and interosseous *talocalcaneal ligaments* (Figs. 5.96B and 5.97A). The **interosseous talocalcaneal ligament** lies within the *tarsal sinus*, which separates the subtalar and talocalcaneonavicular joints and is especially

strong. Orthopaedic surgeons use the term *subtalar joint* for the compound functional joint consisting of the anatomical subtalar joint plus the **talocalcaneal part of the talocalcaneonavicular joint**. The two separate elements of the *clinical subtalar joint* straddle the talocalcaneal interosseous ligament. Structurally, the anatomical definition is logical because the anatomical subtalar joint is a discrete joint, having its own joint capsule and articular cavity. Functionally, however, the clinical definition is logical because the two parts of the compound joint function as a unit; it is impossible for them to function independently. The subtalar joint (by

(text continues on p. 654)

TABLE 5.18. JOINTS OF FOOT

| Joint | Type | Articulating Surfaces | Joint Capsule | Ligaments | Movements | Blood Supply | Nerve Supply |
|---|--|--|---|--|--|---|--|
| Subtalar (talocalcaneal, anatomical subtalar joint) | Plane synovial joint | Inferior surface of body of talus (posterior calcaneal articular facet) articulates with superior surface (posterior talar articular surface) of calcaneus | Fibrous layer of joint capsule is attached to margins of articular surfaces | Medial, lateral, and posterior talocalcaneal ligaments support capsule; interosseous talocalcaneal ligament binds bones together | Inversion and eversion of foot | Posterior tibial and fibular arteries | Plantar aspect: medial or lateral plantar nerve Dorsal aspect: deep fibular nerve |
| Talocalcaneonavicular | Synovial joint; talonavicular part is ball and socket type | Head of talus articulates with calcaneus and navicular bones | Joint capsule incompletely encloses joint | Plantar calcaneonavicular (spring) ligament supports head of talus | Gliding and rotatory movements possible | Anterior tibial artery via lateral tarsal artery, a branch of dorsal artery of foot | |
| Calcaneocuboid | Plane synovial joint | Anterior end of calcaneus articulates with posterior surface of cuboid | Fibrous capsule encloses joint | Dorsal calcaneocuboid ligament, plantar calcaneocuboid, and long plantar ligaments support joint capsule | Inversion and eversion of foot; circumduction | | |
| Cuneonavicular joint | | Anterior navicular articulates with posterior surfaces of cuneiforms | Common capsule encloses joints | Dorsal and plantar cuneonavicular ligaments | Little movement occurs | | |
| Tarsometatarsal | | Anterior tarsal bones articulate with bases of metatarsal bones | Separate joint capsules enclose each joint | Dorsal, plantar, and interosseous tarsometatarsal ligaments bind bones together | Gliding or sliding | | Deep fibular; medial and lateral plantar nerves; sural nerve |
| Intermetatarsal | Plane synovial joint | Bases of metatarsal bones articulate with each other | Separate joint capsules enclose each joint | Dorsal, plantar, and interosseous intermetatarsal ligaments bind lateral four metatarsal bones together | Little individual movement occurs | Lateral metatarsal artery (a branch of dorsal artery of foot) | Digital nerves |
| Metatarsophalangeal | Condylloid synovial joint | Heads of metatarsal bones articulate with bases of proximal phalanges | | Collateral ligaments support capsule on each side; plantar ligament supports plantar part of capsule | Flexion, extension, and some abduction, adduction, and circumduction | | |
| Interphalangeal | Hinge synovial joint | Head of one phalanx articulates with base of one distal to it | | Collateral and plantar ligaments support joints | Flexion and extension | | |

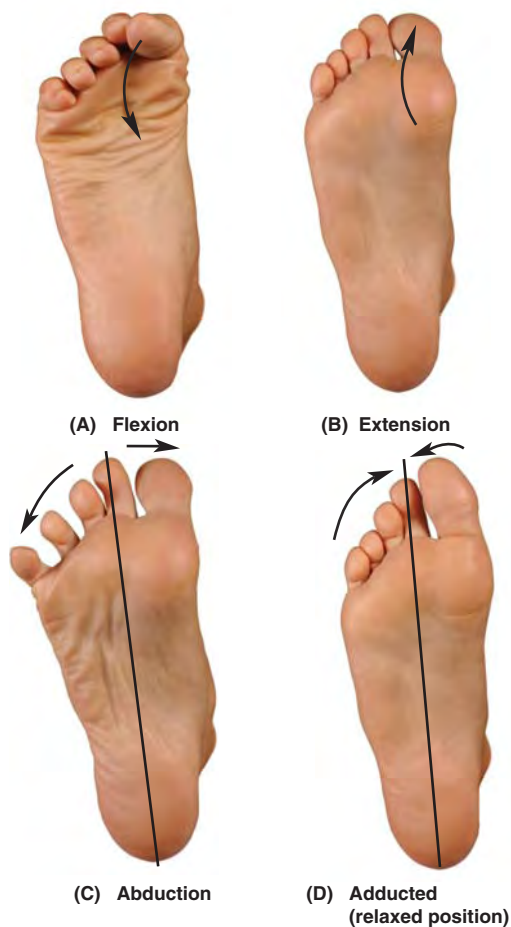


FIGURE 5.100. Movements of joints of forefoot.

TABLE 5.19. MOVEMENTS OF JOINTS OF FOREFOOT AND MUSCLES PRODUCING THEM

| Movement (letters refer to Fig. 5.100) | Muscles ^a |
|--|---|
| Metatarsophalangeal joints | |
| Flexion (A) | Flexor digitorum brevis Lumbricals Interossei Flexor hallucis brevis Flexor hallucis longus Flexor digit minimi brevis Flexor digitorum longus |
| Extension (B) | Extensor hallucis longus Extensor digitorum longus Extensor digitorum brevis |
| Abduction (C) | Abductor hallucis Abductor digiti minimi Dorsal interossei |
| Adduction (D) | Adductor hallucis Plantar interossei |
| Interphalangeal joints | |
| Flexion (fig. A) | Flexor hallucis longus Flexor digitorum longus Flexor digitorum brevis Quadratus plantae |
| Extension (fig. B) | Extensor hallucis longus Extensor digitorum longus Extensor digitorum brevis |

^a Muscles in boldface are chiefly responsible for the movement; the other muscles assist them.

either definition) is where the majority of inversion and eversion occurs, around an axis that is oblique.

The **transverse tarsal joint** is a compound joint formed by two separate joints aligned transversely: the **talonavicular part of the talocalcaneonavicular joint** and the **calcaneocuboid joint** (Fig. 5.99B & C). At this joint, the midfoot and forefoot rotate as a unit on the hindfoot around a longitudinal (AP) axis, augmenting the inversion and eversion movements occurring at the clinical subtalar joint. Transection across the transverse tarsal joint is a standard method for *surgical amputation of the foot*.

MAJOR LIGAMENTS OF FOOT

The major ligaments of the plantar aspect of the foot (Fig. 5.101) are the:

- **Plantar calcaneonavicular ligament** (spring ligament), which extends across and fills a wedge-shaped gap between the talar shelf and the inferior margin of the posterior articular surface of the navicular (Fig. 5.101A & B). The spring ligament supports the head of the talus and plays important roles in the transfer of weight from the talus and in maintaining the longitudinal arch of the foot, of which it is the keystone (superiormost element).
- **Long plantar ligament**, which passes from the plantar surface of the calcaneus to the groove on the cuboid. Some of its fibers extend to the bases of the metatarsals, thereby forming a tunnel for the tendon of the fibularis longus (Fig. 5.101A). The long plantar ligament is important in maintaining the longitudinal arch of the foot.
- **Plantar calcaneocuboid ligament** (short plantar ligament), which is located on a plane between the plantar calcaneonavicular and the long plantar ligaments (Fig. 5.101B). It extends from the anterior aspect of the inferior surface of the calcaneus to the inferior surface of the cuboid. It is also involved in maintaining the longitudinal arch of the foot.

ARCHES OF FOOT

If the feet were more rigid structures, each impact with the ground would generate extremely large forces of short duration (shocks) that would be propagated through the skeletal system. Because the foot is composed of numerous bones connected by ligaments, it has considerable flexibility that allows it to deform with each ground contact, thereby absorbing much of the shock. Furthermore, the tarsal and metatarsal bones are arranged in longitudinal and transverse arches passively supported and actively restrained by flexible tendons that add to the weight-bearing capabilities and resiliency of the foot. Thus much smaller forces of longer duration are transmitted through the skeletal system.

The arches distribute weight over the pedal platform (foot), acting not only as shock absorbers but also as springboards for propelling it during walking, running, and jumping. The resilient arches add to the foot's ability to adapt to

changes in surface contour. The weight of the body is transmitted to the talus from the tibia. Then it is transmitted posteriorly to the calcaneus and anteriorly to the “ball of the foot” (the sesamoids of the 1st metatarsal and the head of the 2nd metatarsal), and that weight/pressure is shared laterally with the heads of the 3rd–5th metatarsals as necessary for balance and comfort (Fig. 5.102). Between these weight-bearing points are the relatively elastic arches of the foot, which become slightly flattened by body weight during standing. They normally resume their curvature (recoil) when body weight is removed.

The **longitudinal arch of the foot** is composed of medial and lateral parts (Fig. 5.103). Functionally, both parts act as a unit with the transverse arch of the foot, spreading the weight in all directions. The **medial longitudinal arch** is higher and more important than the lateral longitudinal arch (Fig. 5.103A & B). The medial longitudinal arch is composed of the calcaneus, talus, navicular, three cuneiforms, and three metatarsals. *The talar head is the keystone of the medial longitudinal arch.* The tibialis anterior, attaching to the 1st metatarsal and medial cuneiform, helps strengthen the medial longitudinal arch. The fibularis longus tendon, passing from lateral to medial, also helps support this arch (Fig. 5.103C & E). The **lateral longitudinal arch** is much flatter than the medial part of the arch and rests on the ground during standing (Fig. 5.103B & D). It is made up of the calcaneus, cuboid, and lateral two metatarsals.

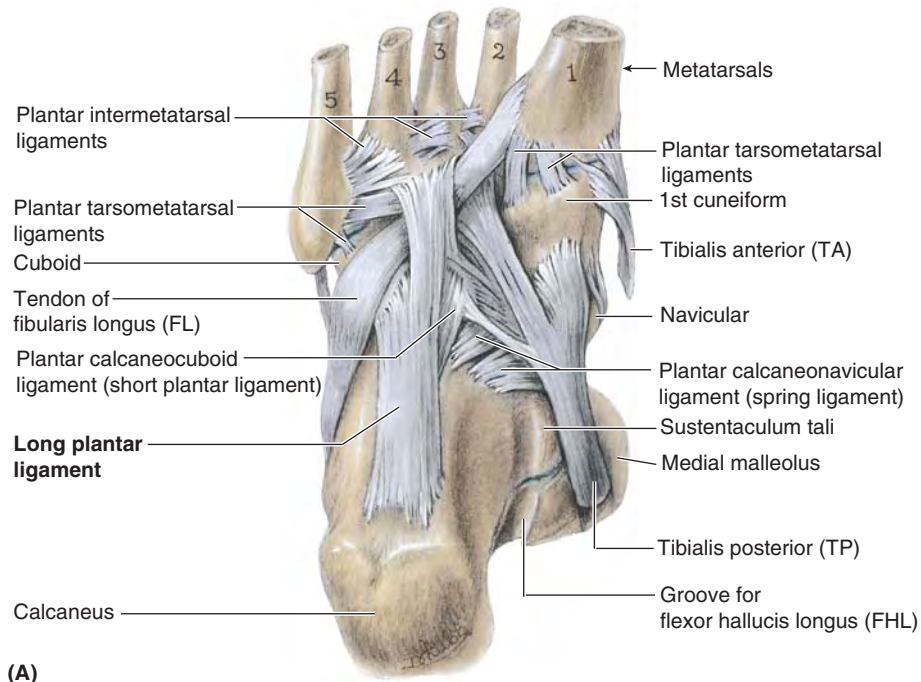
The **transverse arch of the foot** runs from side to side (Fig. 5.103C). It is formed by the cuboid, cuneiforms, and bases of the metatarsals. The medial and lateral parts of the longitudinal arch serve as pillars for the transverse arch. The tendons of the fibularis longus and tibialis posterior, crossing under the sole of the foot like a stirrup (Fig. 5.103C), help maintain the curvature of the transverse arch. The integrity of the bony arches of the foot is maintained by both passive factors and dynamic supports (Fig. 5.103E).

Passive factors involved in forming and maintaining the arches of the foot include:

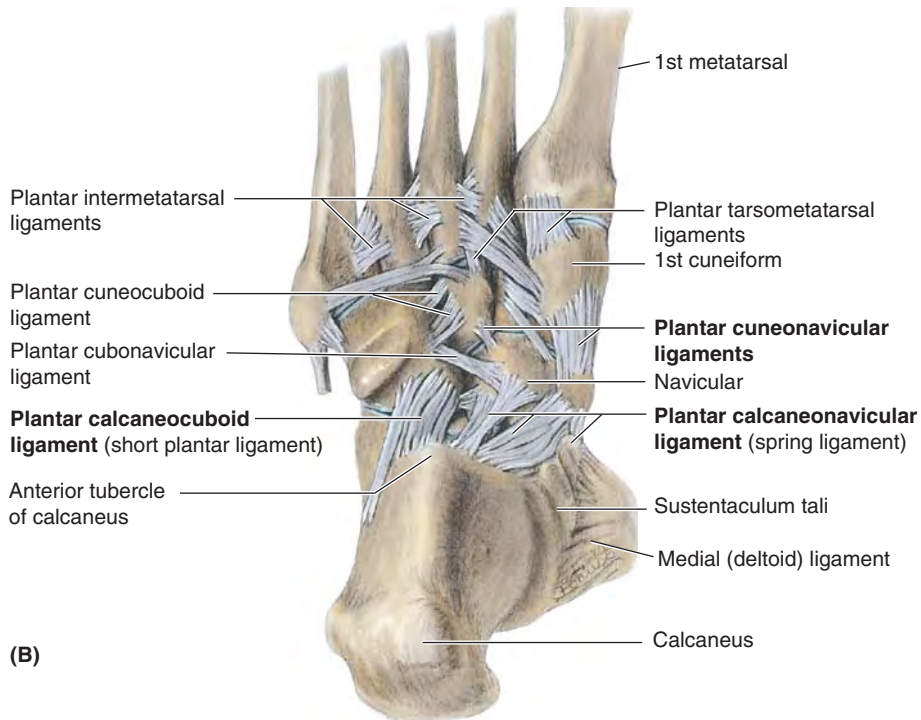
- The shape of the united bones (both arches, but especially the transverse arch).
- Four successive layers of fibrous tissue that bowstring the longitudinal arch (superficial to deep):
 1. Plantar aponeurosis.
 2. Long plantar ligament.
 3. Plantar calcaneocuboid (short plantar) ligament.
 4. Plantar calcaneonavicular (spring) ligament.

Dynamic supports involved in maintaining the arches of the foot include:

- Active (reflexive) bracing action of intrinsic muscles of foot (longitudinal arch).
- Active and tonic contraction of muscles with long tendons extending into foot:
 - Flexors hallucis and digitorum longus for the longitudinal arch.



(A)



(B)

Plantar views

FIGURE 5.101. Plantar ligaments. A and B. Sequential stages of a deep dissection of the sole of the right foot showing the attachments of the ligaments and the tendons of the long evertor and invertor muscles.

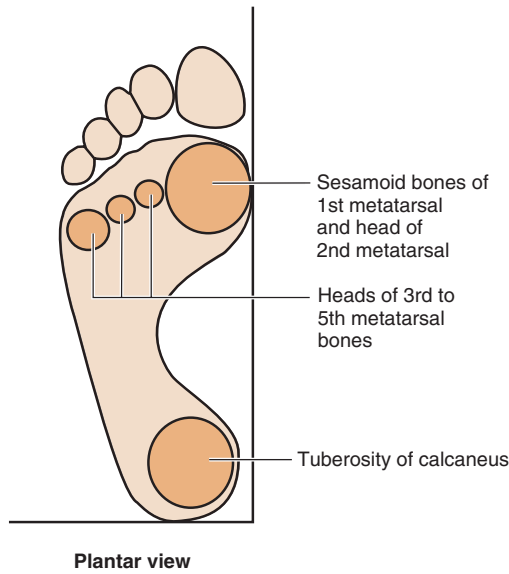


FIGURE 5.102. Weight-bearing areas of foot. Body weight is divided approximately equally between the hindfoot (calcaneus) and the forefoot (heads of the metatarsals). The forefoot has five points of contact with the ground: a large medial one that includes the two sesamoid bones associated with the head of the 1st metatarsal and the heads of the lateral four metatarsals. The 1st metatarsal supports the major share of the load, with the lateral forefoot providing balance.

- Fibularis longus and tibialis posterior for the transverse arch.

Of these factors, the plantar ligaments and the plantar aponeurosis bear the greatest stress and are most important in maintaining the arches of the foot.

Surface Anatomy of Joints of Knee, Ankle, and Foot

The **knee region** is between the thigh and the leg (Fig. 5.104A). Superior to it are the large bulges formed by the *vasta lateralis* and *medialis*. Superiolateral to the knee is the *iliotibial tract*, which can be followed inferiorly to the *anterolateral (Gerdy) tubercle of the tibia*. The *patella*, easily palpated and moveable from-side-to-side during extension, lies anterior to the *femoral condyles* (palpable to each side of the middle of the patella). Extending from the *apex of the patella*, the *patellar ligament* is easily visible, especially in thin people, as a thick band attached to the prominent *tibial tuberosity*. The *plane of the knee joint*, between femoral condyles and tibial plateau, may be palpated on each side of the junction of patellar apex and ligament when the knee is extended. Laterally, the *head of the fibula* is readily located by following the *tendon of the biceps femoris* inferiorly. The tendon is particularly prominent when the knee is partially flexed (Fig. 5.104B). The *fibular collateral ligament* may be palpated as a cord-like structure superior to the fibular head and anterior to biceps tendon, when the knee is fully flexed.

The prominences of the *lateral and medial malleoli* provide an approximation of the *axis of the ankle joint* (Fig. 5.104C–E). When the ankle is plantarflexed, the *anterior border of the distal end of the tibia* is palpable proximal to the malleoli, providing an indication of the joint plane of the ankle joint. The *sustentaculum tali*, approximately 2 cm distal to the tip of the medial malleolus, is best felt by palpating it from below where it is somewhat obscured by the *tendon of the flexor digitorum longus*, which crosses it. On the lat-

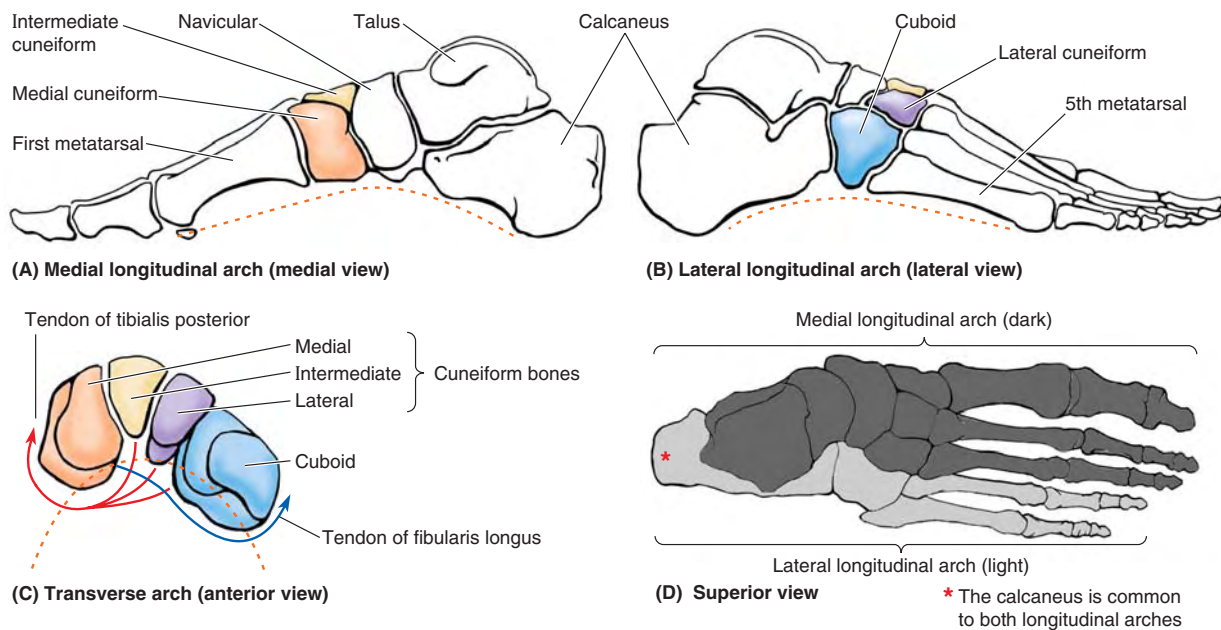
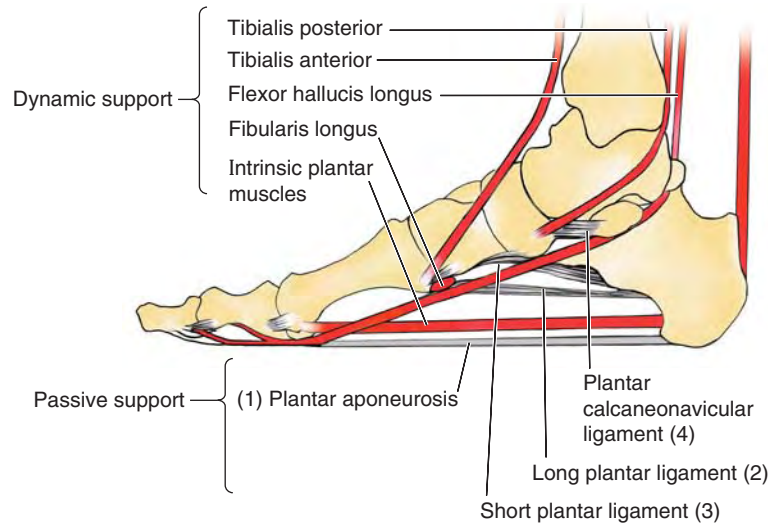


FIGURE 5.103. Arches of foot. A and B. The medial longitudinal arch is higher than the lateral longitudinal arch, which may contact the ground when standing erect. C. The transverse arch is demonstrated at the level of the cuneiforms, receiving stirrup-like support from a major invertor (tibialis posterior) and evtor (fibularis longus). D. The components of the medial (dark gray) and lateral (light gray) longitudinal arches are indicated. The calcaneus (medium gray) is common to both. The medial arch is primarily weight-bearing, whereas the lateral arch provides balance.



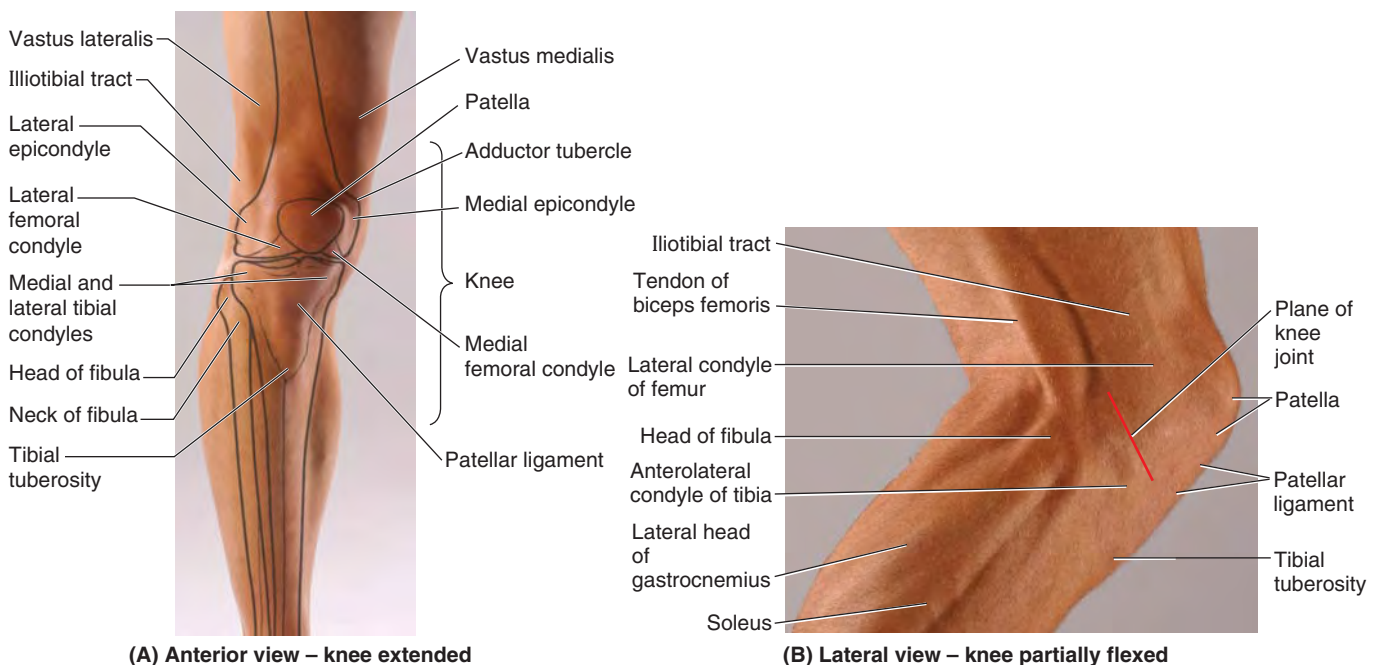
(E) Medial longitudinal arch (medial view)

FIGURE 5.103. Arches of foot (continued). E. The active (red lines) and passive (gray) supports of the longitudinal arches are represented. There are four layers of passive support (1–4).

eral side, when the foot is inverted, the lateral margin of the **anterior surface of the calcaneus** is uncovered and palpable. This indicates the site of the *calcaneocuboid joint*. When the foot is plantarflexed, the *head of the talus* is exposed. Palpate it dorsal to where the anterior surface of the calcaneus is felt. The *calcaneal tendon* at the posterior aspect of the ankle is easily palpated and traced to its attachment to the *calcaneal tuberosity*. In the depression on each side of the tendon, the ankle joint is superficial. When the joint is overfilled with fluid, these depressions may be obliterated. The *transverse tarsal joint* is indicated by a line from the posterior

aspect of the tuberosity of the navicular to a point halfway between the lateral malleolus and the tuberosity of the 5th metatarsal.

The **metatarsophalangeal joint of the great toe** lies distal to the knuckle formed by the head of the 1st metatarsal. *Gout*, a metabolic disorder, commonly causes edema and tenderness of this joint, as does *osteoarthritis* (degenerative joint disease). Severe pain in the 1st metatarsophalangeal joint is called *podagra* (from G. *pous* + G. *agra*, a seizure). Often the 1st metatarsophalangeal joint is the first one affected by arthritis.



(A) Anterior view – knee extended

(B) Lateral view – knee partially flexed

FIGURE 5.104. Surface anatomy of the joints of the knee, leg, ankle, and foot.

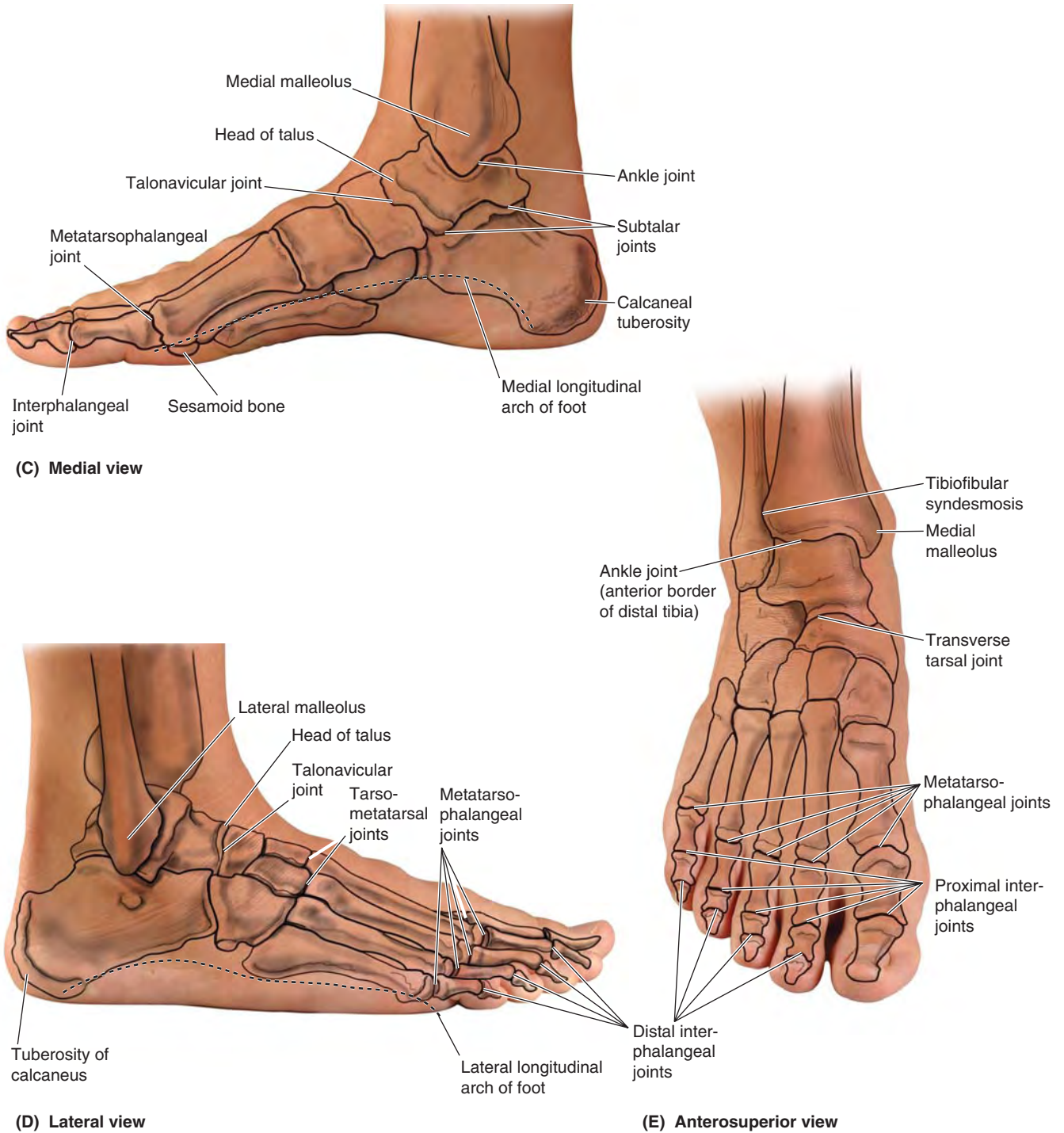


FIGURE 5.104. Surface anatomy of the joints of the knee, leg, ankle, and foot (continued).

JOINTS OF LOWER LIMB

Bipedalism and Congruity of Articular Surfaces of Hip Joint



The acetabulum is directed inferiorly, laterally, and anteriorly in humans. The weight-bearing iliac portion of the acetabular rim overlies the femoral head, which is important for transfer of weight to the femur in the erect (standing/walking) position (Figs. 5.77A and 5.79C).

Consequently, of the positions commonly assumed by humans, the hip joint is mechanically most stable when a person is bearing weight, as when lifting a heavy object, for example. Decreases in the degree to which the ilium overlies the femoral head (detectable radiographically as the *angle of Wiberg*—Fig. 5.79C & D) may indicate joint instability.

Because of the anterior direction the axis of the acetabulum and the posterior direction of the axis of the femoral head and neck as it extends laterally (owing to the torsion angle—discussed earlier on page. 518), there is an angle of 30–40° between their axes (Fig. B5.28). Consequently, the articular surfaces of the head and acetabulum are not fully congruent in the erect (bipedal) posture. The anterior part of the femoral head is “exposed” and articulates mostly with the joint capsule (Figs. 5.79C, 5.80, 5.81A & C, and 5.84). Nonetheless, rarely is >40% of the available articular surface of the femoral head in contact with the surface of the acetabulum in any position.

Relative to other joints and in view of the large size of the hip joint, this is extensive contact, contributing considerably to the joint’s great stability.

Fractures of Femoral Neck



Fractures of the neck of the femur (unfortunately referred to as “fractured hips,” implying that the hip bone is broken) are uncommon in most contact sports because the participants are usually young and the femoral neck is strong in people <40 years of age. When they do occur in this age group, these fractures usually result from high-energy impacts (e.g., during race-car accidents, skiing, trampoline, and equestrian events) when the lower limb is extended and the force of the impact is transmitted to the hip joint, even if applied at some distance from the joint. For example, if the foot is firmly braced against the car floor with the knee locked or if the knee is braced against the dashboard during a head-on collision, the force of the impact may be transmitted superiorly and produce a femoral neck fracture. Femoral neck fractures are especially common in individuals >60 years, especially in women, because their femoral necks are more often weak and brittle as a result of *osteoporosis* (Fig. B5.29). Fractures of the femoral neck are often intracapsular, and realignment of the neck fragments requires internal skeletal fixation.

Fractures of the femoral neck cause lateral rotation of the lower limb. Fractures of the femoral neck often disrupt the blood supply to the head of the femur. Most of the blood to the head and neck of the femur is supplied by the medial circumflex femoral artery (Fig. 5.82). The retinacular arteries arising from this artery are often torn when the femoral neck is fractured or the hip joint is dislocated. Following some femoral neck fractures, the artery to the ligament of the femoral head may be the only remaining source of blood to the proximal fragment. This artery is frequently inadequate

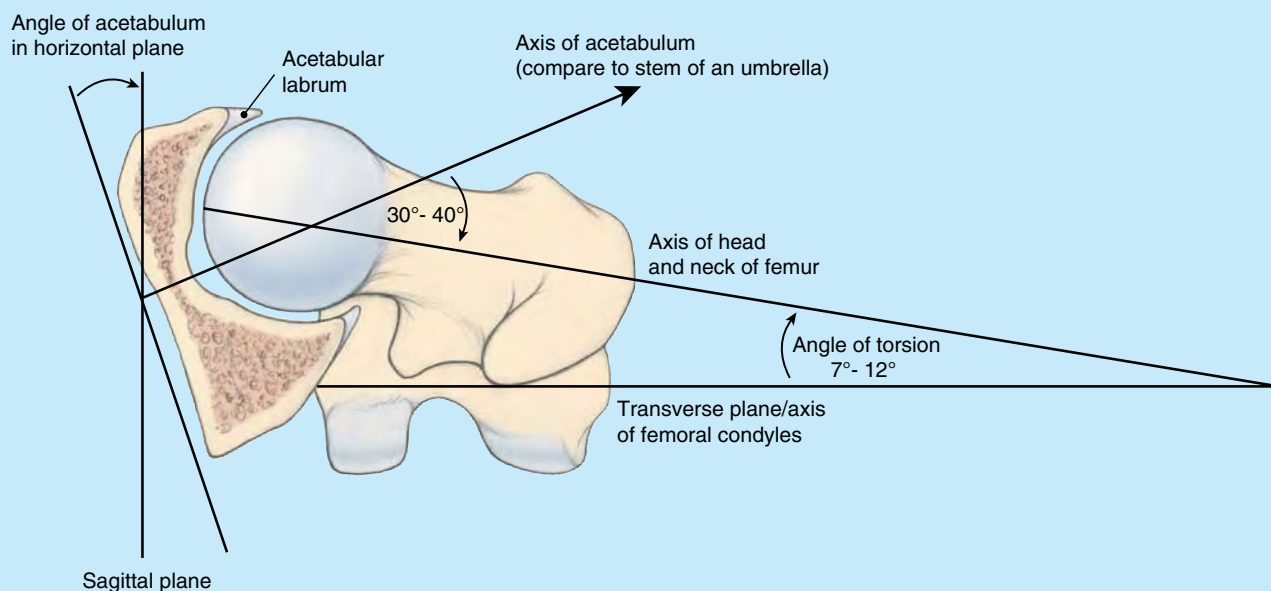


FIGURE B5.28.

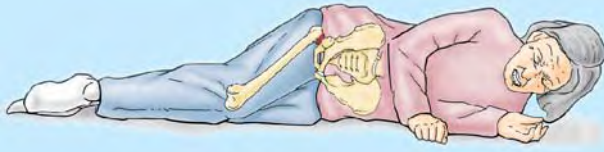


FIGURE B5.29.

for maintaining the femoral head; consequently, the fragment may undergo *aseptic vascular necrosis*.

Surgical Hip Replacement



Although the hip joint is strong and stable, it is subject to severe traumatic injury and degenerative disease. *Osteoarthritis of the hip joint*, characterized by pain, edema, limitation of motion, and erosion of articular cartilage, is a common cause of disability (Fig. B5.30A). During hip replacement, a metal prosthesis anchored to the person's femur by bone cement replaces the femoral head and neck (Fig. B5.30B). A plastic socket cemented to the hip bone replaces the acetabulum.

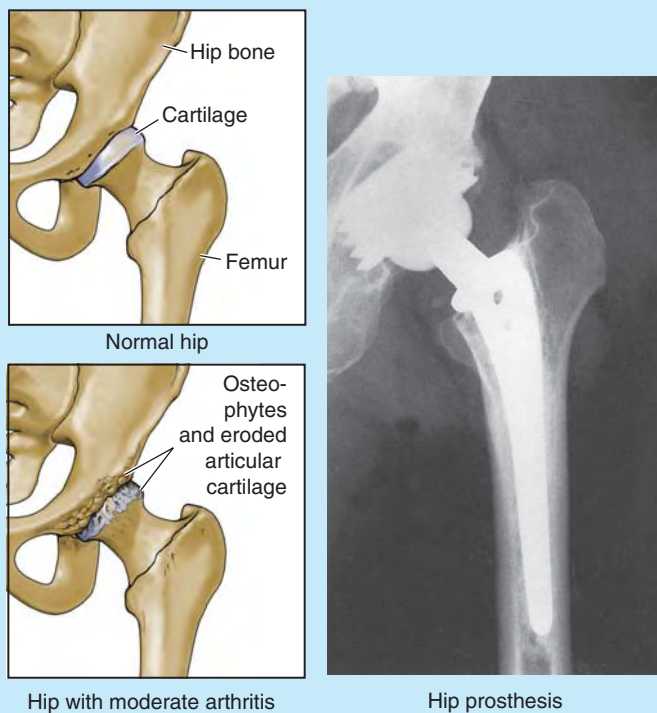


FIGURE B5.30.

Necrosis of Femoral Head in Children



In children, traumatic dislocations of the hip joint disrupt the artery to the head of the femur. Fractures that result in separation of the superior femoral epiphysis (the growth plate between the femoral head and neck) are also likely to result in an inadequate blood supply to the femoral head and in *post-traumatic avascular necrosis of the head*. As a result,

incongruity of the joint surfaces develops, and growth at the epiphysis is retarded. Such conditions, most common in children 3–9 years of age, produce hip pain that may radiate to the knee.

Dislocation of Hip Joint



Congenital dislocation of the hip joint is common, occurring in approximately 1.5 per 1000 live births; it is bilateral in approximately half the cases. Girls are affected at least eight times more often than boys (Salter, 1999). Dislocation occurs when the femoral head is not properly located in the acetabulum. Inability to abduct the thigh is characteristic of congenital dislocation. In addition, the affected limb appears (and functions as if it is) shorter because the dislocated femoral head is more superior than on the normal side, resulting in a positive *Trendelenburg sign* (hip appears to drop on one side during walking). Approximately 25% of all cases of arthritis of the hip in adults are the direct result of residual defects from congenital dislocation of the hip.

Acquired dislocation of the hip joint is uncommon because this articulation is so strong and stable. Nevertheless, dislocation may occur during an automobile accident when the hip is flexed, adducted, and medially rotated, the usual position of the lower limb when a person is riding in a car.

Posterior dislocations of the hip joint are most common. A head-on collision that causes the knee to strike the dashboard may dislocate the hip when the femoral head is forced out of the acetabulum (Fig. B5.31A). The joint capsule ruptures

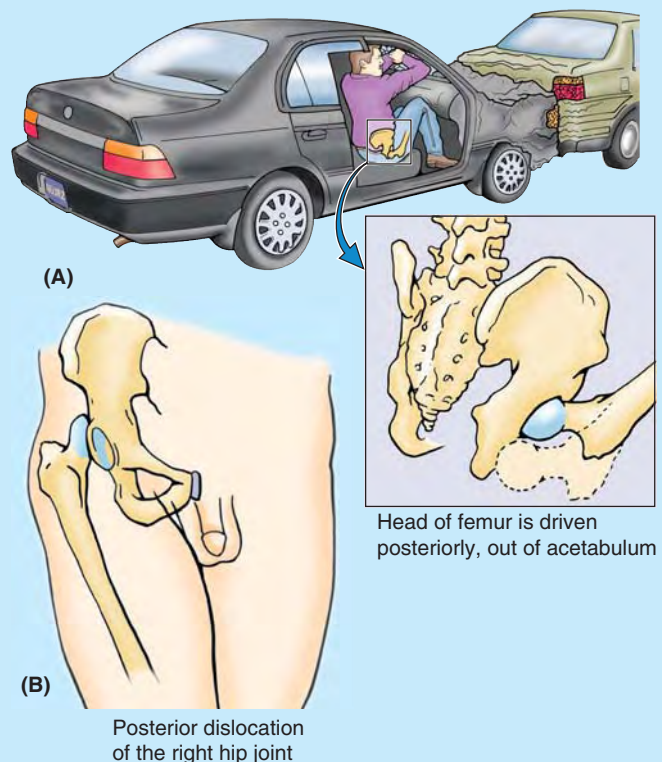


FIGURE B5.31.

inferiorly and posteriorly, allowing the femoral head to pass through the tear in the capsule and over the posterior margin of the acetabulum onto the lateral surface of the ilium, shortening and medial rotating the limb (Fig. B5.31B).

Because of the close relationship of the *sciatic nerve* to the hip joint (Fig. 5.80A), it may be injured (stretched and/or compressed) during posterior dislocations or fracture–dislocations of the hip joint. This kind of injury may result in paralysis of the hamstrings and muscles distal to the knee supplied by the sciatic nerve. Sensory changes may also occur in the skin over the posterolateral aspects of the leg and over much of the foot because of injury to sensory branches of the sciatic nerve.

Anterior dislocation of the hip joint results from a violent injury that forces the hip into extension, abduction, and lateral rotation (e.g., catching a ski tip when snow skiing). In these cases, the femoral head is inferior to the acetabulum. Often, the acetabular margin fractures, producing a *fracture–dislocation of the hip joint*. When the femoral head dislocates, it usually carries the acetabular bone fragment and acetabular labrum with it. These injuries also occur with posterior dislocations.

Genu Valgum and Genu Varum



The femur is placed diagonally within the thigh, whereas the tibia is almost vertical within the leg, creating an angle at the knee between the long axes of the bones (Fig. B5.32A). The angle between the two bones, referred to clinically as the **Q-angle**, is assessed by drawing a line from the ASIS to the middle of the patella and extrapolating a second (vertical) line passing through the middle of the patella and tibial tuberosity (Fig. 5.84). The Q-angle is typically greater in adult females, owing to their wider pelvises. When normal, the angle of the femur within the thigh places the middle of the knee joint directly inferior to the head of

the femur when standing, centering the weight-bearing line in the intercondylar region of the knee (Fig. B5.32A).

A medial angulation of the leg in relation to the thigh, in which the femur is abnormally vertical and the Q-angle is small, is a deformity called **genu varum** (bowleg) that causes unequal weight-bearing: The line of weight-bearing falls medial to the center of the knee (Fig. B5.32B). Excess pressure is placed on the medial aspect of the knee joint, which results in **arthrosis** (destruction of knee cartilages), and the fibular collateral ligament is overstressed (Fig. B.32D). A lateral angulation of the leg (large Q-angle, $>17^\circ$) in relation to the thigh (exaggeration of the knee angle) is called **genu valgum** (knock-knee) (Fig. B5.32C). Because of the exaggerated knee angle in genu valgum, the weight-bearing line falls lateral to the center of the knee. Consequently, the tibial collateral ligament is overstretched, and there is excess stress on the lateral meniscus and cartilages of the lateral femoral and tibial condyles. The patella, normally pulled laterally by the tendon of the vastus lateralis, is pulled even farther laterally when the leg is extended in the presence of genu valgum so that its articulation with the femur is abnormal.

Children commonly appear bowlegged for 1–2 years after starting to walk, and knock-knees are frequently observed in children 2–4 years of age. Persistence of these abnormal knee angles in late childhood usually means congenital deformities exist that may require correction. Any irregularity of a joint eventually leads to wear and tear (arthrosis) of the articular cartilages and degenerative joint changes (**osteoarthritis [arthrosis]**).

Patellar Dislocation



When the patella is dislocated, it nearly always dislocates laterally. Patellar dislocation is more common in women, presumably because of their greater

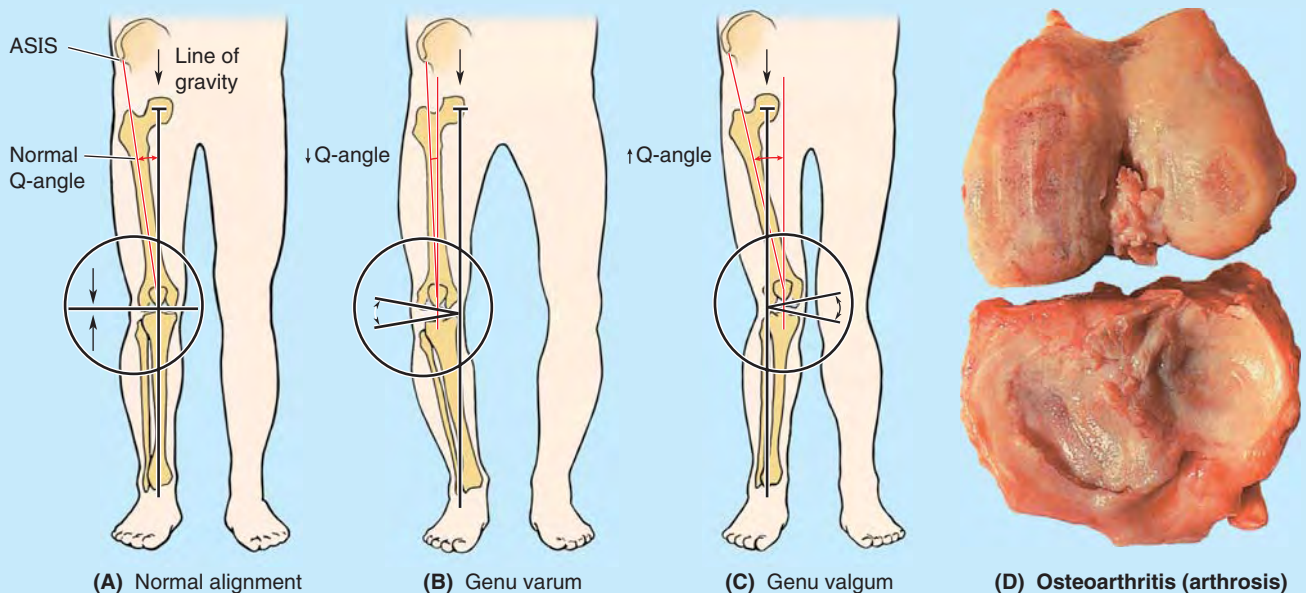



FIGURE B5.32.


Q-angle, which, in addition to representing the oblique placement of the femur relative to the tibia, represents the angle of pull of the quadriceps relative to the axis of the patella and tibia (the term *Q-angle* was actually coined in reference to the angle of pull of the quadriceps). The tendency toward lateral dislocation is normally counterbalanced by the medial, more horizontal pull of the powerful vastus medialis. In addition, the more anterior projection of the lateral femoral condyle and deeper slope for the larger lateral patellar facet provide a mechanical deterrent to lateral dislocation. An imbalance of the lateral pull and the mechanisms resisting it result in abnormal tracking of the patella within the patellar groove and chronic patellar pain, even if actual dislocation does not occur.

Patellofemoral Syndrome

 Pain deep to the patella often results from excessive running, especially downhill; hence, this type of pain is often called “runner’s knee.” The pain results from repetitive microtrauma caused by abnormal tracking of the patella relative to the patellar surface of the femur, a condition known as the **patellofemoral syndrome**. This syndrome may also result from a direct blow to the patella and from **osteoarthritis of the patellofemoral compartment** (degenerative wear and tear of articular cartilages). In some cases, strengthening of the vastus medialis corrects *patellofemoral dysfunction*. This muscle tends to prevent lateral dislocation of the patella resulting from the Q-angle because the vastus medialis attaches to and pulls on the medial border of the patella. Hence, weakness of the vastus medialis predis-

poses the individual to the patellofemoral dysfunction and patellar dislocation.

Knee Joint Injuries

 Knee joint injuries are common because the knee is a low-placed, mobile, weight-bearing joint, serving as a fulcrum between two long levers (thigh and leg). Its stability depends almost entirely on its associated ligaments and surrounding muscles.

The knee joint is essential for everyday activities such as standing, walking, and climbing stairs. It is also a main joint for sports that involve running, jumping, kicking, and changing directions. To perform these activities, the knee joint must be mobile; however, this mobility makes it susceptible to injuries.

The most common knee injuries in contact sports are *ligament sprains*, which occur when the foot is fixed in the ground (Fig. B5.33A). If a force is applied against the knee when the foot cannot move, ligament injuries are likely to occur. The tibial and fibular collateral ligaments (TCL and FCL) are tightly stretched when the leg is extended, normally preventing disruption of the sides of the knee joint.

The firm attachment of the TCL to the medial meniscus is of considerable clinical significance because tearing of this ligament frequently results in concomitant tearing of the medial meniscus. The injury is frequently caused by a blow to the lateral side of the extended knee or excessive lateral twisting of the flexed knee that disrupts the TCL and concomitantly tears and/or detaches the medial meniscus from the joint capsule (Fig. B5.33A). This injury is common

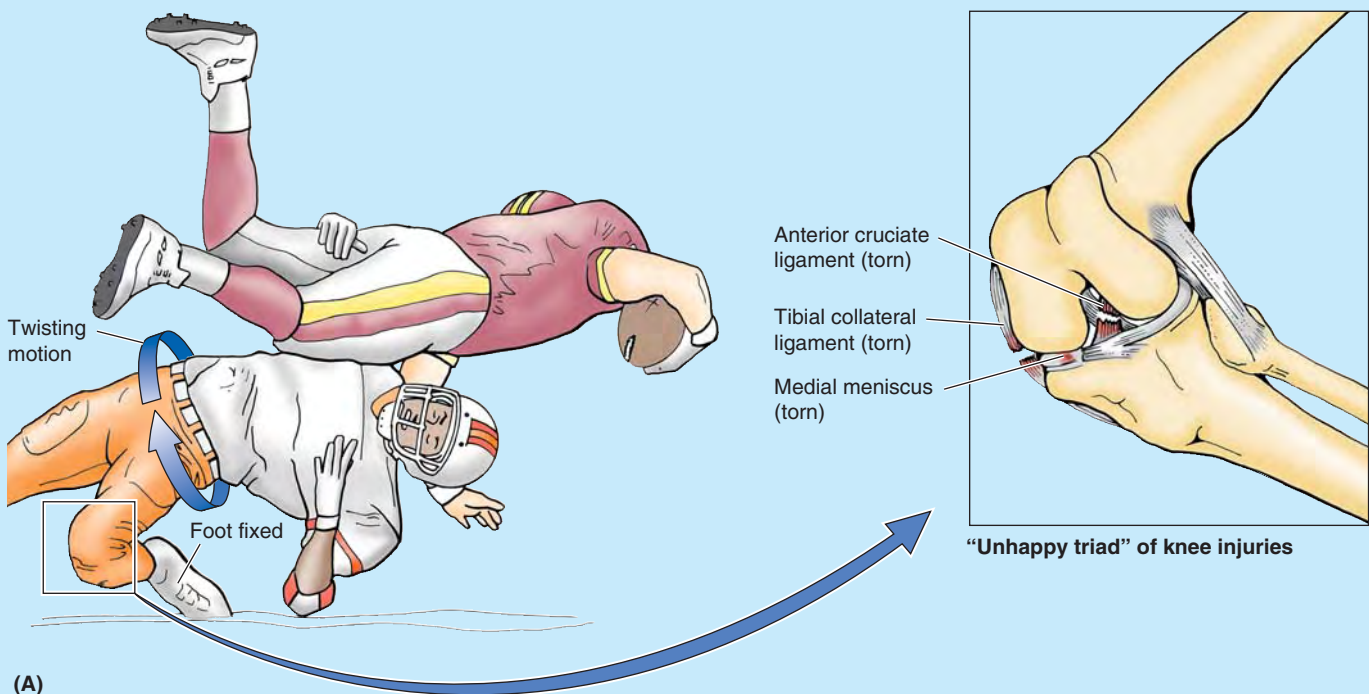
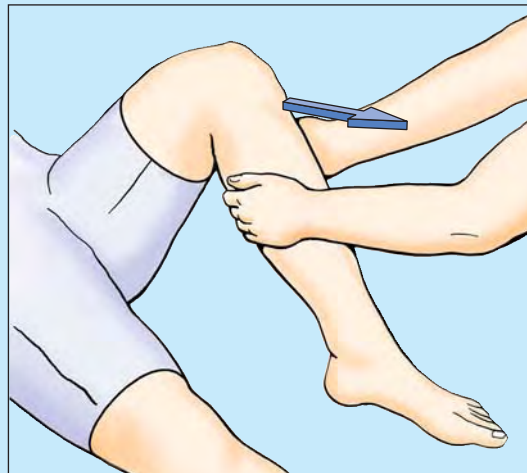
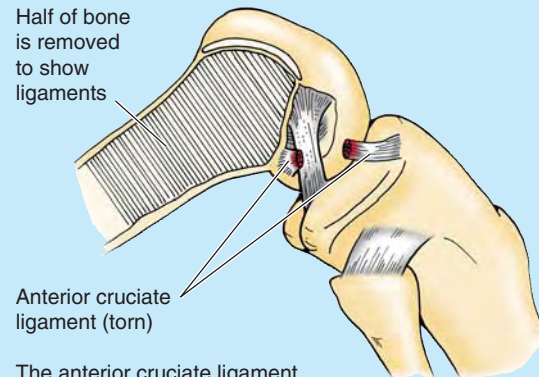


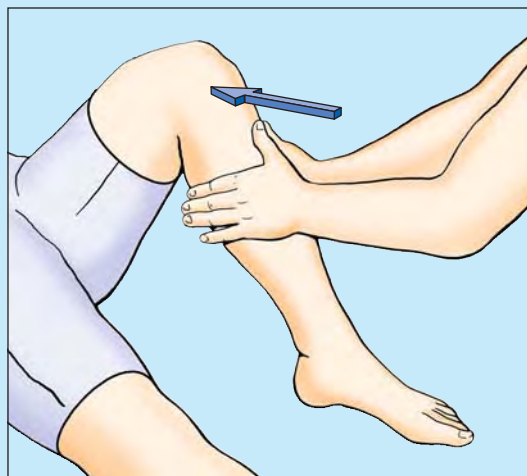
FIGURE B5.33.



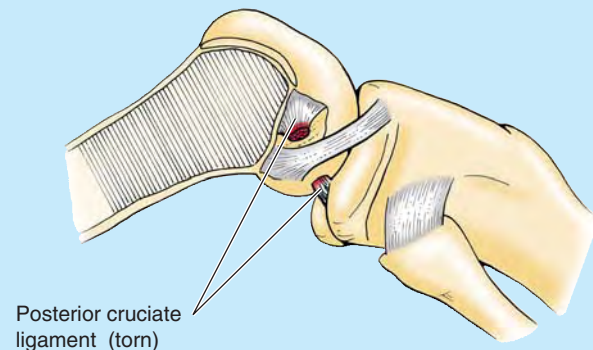
(B) Anterior drawer sign (ACL)



The anterior cruciate ligament prevents the femur from sliding posteriorly on the tibia and hyperextension of the knee and limits medial rotation of the femur when the foot is on the ground, and the leg is flexed.



(C) Posterior drawer sign (PCL)



The posterior cruciate ligament prevents the femur from sliding anteriorly on the tibia, particularly when the knee is flexed.

FIGURE B5.33. (continued).

in athletes who twist their flexed knees while running (e.g., in basketball, the various forms of football, and volleyball). The ACL, which serves as a pivot for rotatory movements of the knee and is taut during flexion, may also tear subsequent to the rupture of the TCL, creating an “unhappy triad” of knee injuries.

Hyperextension and severe force directed anteriorly against the femur with the knee semiflexed (e.g., a cross-body block in football) may tear the ACL. ACL ruptures are also common knee injuries in skiing accidents. This injury causes the free tibia to slide anteriorly under the fixed femur, known as the **anterior drawer sign** (Fig. B5.33B), tested clinically via the *Lachman test*. The ACL may tear away from the femur or tibia; however, tears commonly occur in the midportion of the ligament.

Although strong, PCL ruptures may occur when a player lands on the tibial tuberosity with the knee flexed (e.g., when knocked to the floor in basketball). PCL ruptures usually occur in conjunction with tibial or fibular ligament tears.

These injuries can also occur in head-on collisions when seat belts are not worn and the proximal end of the tibia strikes the dashboard. PCL ruptures allow the free tibia to slide posteriorly under the fixed femur, known as **the posterior drawer sign** (Fig. B5.33C).

Meniscal tears usually involve the medial meniscus. The lateral meniscus does not usually tear because of its mobility. *Pain on lateral rotation of the tibia* on the femur indicates injury of the lateral meniscus (Fig. B5.34A), whereas *pain on medial rotation of the tibia* on the femur indicates injury of the medial meniscus (Fig. B5.34B). Most meniscal tears occur in conjunction with TCL or ACL tears. Peripheral meniscal tears can often be repaired or may heal on their own because of the generous blood supply to this area. Meniscal tears that do not heal or cannot be repaired are usually removed (e.g., by arthroscopic surgery). Knee joints from which the menisci have been removed suffer no loss of mobility; however, the knee may be less stable and the tibial plateaus often undergo inflammatory reactions.

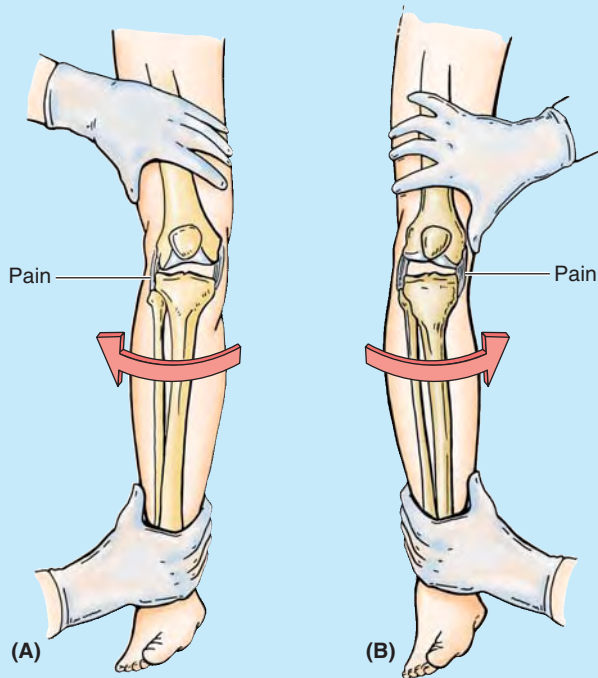


FIGURE B5.34.

Arthroscopy of Knee Joint

Arthroscopy is an endoscopic examination that allows visualization of the interior of the knee joint cavity with minimal disruption of tissue (Fig. B5.35). The arthroscope and one (or more) additional cannula(e) are inserted through tiny incisions, known as *portals*. The second cannula is for passage of specialized tools (e.g., manipulative probes or forceps) or equipment for trimming, shaping, or removing damaged tissue. This technique allows removal of torn menisci, loose bodies in the joint (such as bone chips), and *débridement* (the excision of devitalized articular cartilaginous material) in advanced cases of arthritis. Ligament repair or replacement may also be performed using an arthroscope. Although general anesthesia is usually preferable, knee arthroscopy can be performed using local or regional anesthesia. During arthroscopy, the articular cavity of the knee must be treated essentially as two separate (medial and lateral) femorotibial articulations owing to the imposition of the synovial fold around the cruciate ligaments.

Aspiration of Knee Joint

Fractures of the distal end of the femur or lacerations of the anterior thigh may involve the suprapatellar bursa and result in infection of the knee joint. When the knee joint is infected and inflamed, the amount of synovial fluid may increase. **Joint effusions**, the escape of fluid from blood or lymphatic vessels, results in increased amounts of fluid in the joint cavity. Because the

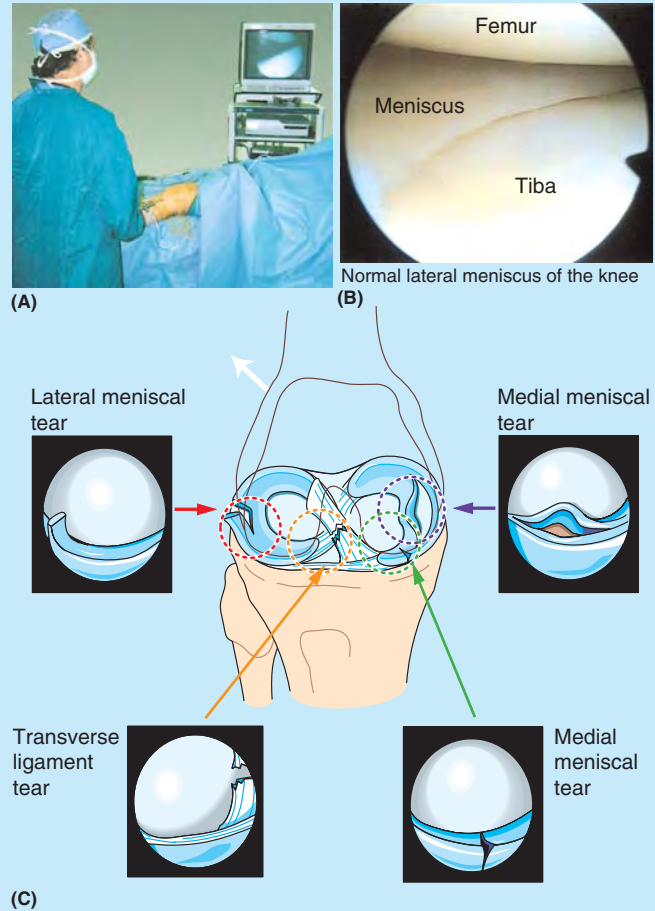


FIGURE B5.35.

suprapatellar bursa communicates freely with the synovial cavity of the knee joint, fullness of the thigh in the region of the suprapatellar bursa may indicate increased synovial fluid. This bursa can be aspirated to remove the fluid for examination. *Direct aspiration of the knee joint* is usually performed with the patient sitting on a table with the knee flexed. The joint is approached laterally, using three bony points as landmarks for needle insertion: the anterolateral tibial (Gerdy) tubercle, the lateral epicondyle of the femur, and the apex of the patella. In addition to being the route for aspiration of serous and sanguineous (bloody) fluid, this triangular area also lends itself to drug injection for treating pathology of the knee joint.

Bursitis in Knee Region

Prepatellar bursitis is caused by friction between the skin and the patella; however, the bursa may also be injured by compressive forces resulting from a direct blow or from falling on the flexed knee. If the inflammation is chronic, the bursa becomes distended with fluid and forms a swelling anterior to the knee. This condition has been called “housemaid’s knee” (Fig. B5.36); however, other

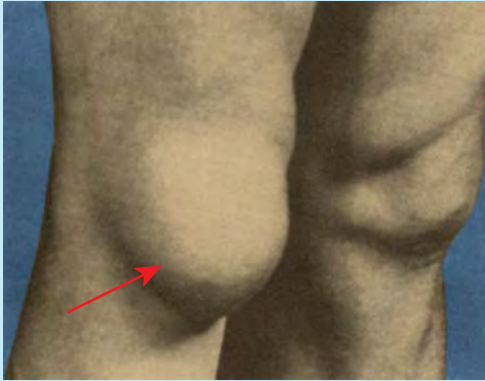



FIGURE B5.36.

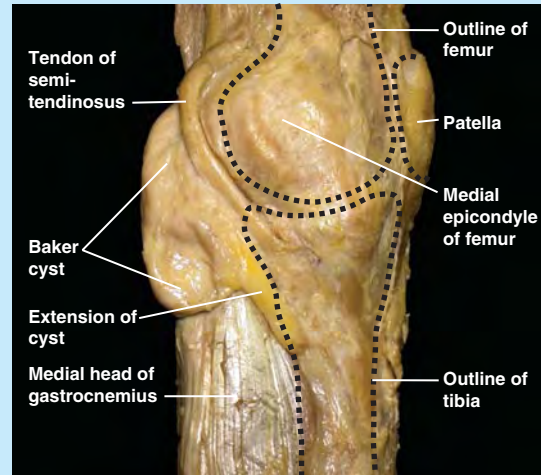
people who work on their knees without knee pads, such as hardwood floor and rug installers, may also develop prepatellar bursitis.

Subcutaneous infrapatellar bursitis is caused by excessive friction between the skin and the tibial tuberosity; the edema occurs over the proximal end of the tibia. This condition was formerly called “clergyman’s knee” because of frequent genu-flecting (L. *genu*, knee); however, it occurs more commonly in roofers and floor tilers if they do not wear knee pads. *Deep infrapatellar bursitis* results in edema between the patellar ligament and the tibia, superior to the tibial tuberosity. The inflammation is usually caused by overuse and subsequent friction between the patellar tendon and the structures posterior to it, the infrapatellar fat pad and tibia (Anderson et al., 2000). Enlargement of the deep infrapatellar bursa obliterates the dimples normally occurring on each side of the patellar ligament when the leg is extended.

Abrasions or penetrating wounds may result in *suprapatellar bursitis*, an infection caused by bacteria entering the bursa from the torn skin. The infection may spread to the cavity of the knee joint, causing localized redness and enlarged popliteal and inguinal lymph nodes.

Popliteal Cysts

 *Popliteal cysts* (Baker cysts) are abnormal fluid-filled sacs of synovial membrane in the region of the popliteal fossa. A popliteal cyst is almost always a complication of chronic knee joint effusion. The cyst may be a herniation of the gastrocnemius or semimembranosus bursa through the fibrous layer of the joint capsule into the popliteal fossa, communicating with the synovial cavity of the knee joint by a narrow stalk (Fig. B5.37). Synovial fluid may also escape from the knee joint (*synovial effusion*) or a bursa around the knee and collect in the popliteal fossa. Here it forms a new synovial-lined sac, or popliteal cyst. Popliteal cysts are common in children but seldom cause symptoms. In adults, popliteal cysts can be large, extending as far as the midcalf, and may interfere with knee movements.



Medial view of dissection of left knee

FIGURE B5.37.

Knee Replacement



If a person’s knee is diseased, resulting from osteoarthritis, for example, an artificial knee joint may be inserted (*total knee replacement arthroplasty*) (Fig. B5.38). The artificial knee joint consists of plastic and metal components that are cemented to the femoral and tibial bone ends after removal of the defective areas. The combination of metal and plastic mimics the smoothness of cartilage on cartilage and produces good results in “low-demand” people who have a relatively sedentary life. In “high-demand” people who are active in sports, the bone–cement junctions may break down, and the artificial knee components may loosen; however, improvements in bioengineering and surgical technique have provided better results.

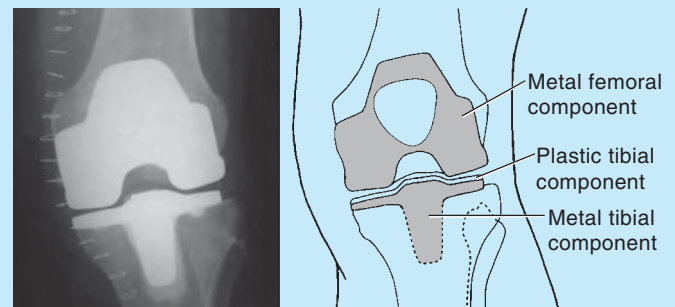


FIGURE B5.38.

Ankle Injuries



The ankle is the most frequently injured major joint in the body. *Ankle sprains* (torn fibers of ligaments) are most common. A sprained ankle is nearly always an *inversion injury*, involving twisting of the weight-bearing plantarflexed foot. The person steps on an uneven surface and the foot is forcibly inverted. *Lateral ligament sprains*

occur in sports in which running and jumping are common, particularly basketball (70–80% of players have had at least one sprained ankle). The lateral ligament is injured because it is much weaker than the medial ligament and is the ligament that resists inversion at the talocrural joint. The *anterior talofibular ligament*—part of the lateral ligament—is most vulnerable and most commonly torn during ankle sprains, either partially or completely, resulting in instability of the ankle joint (Fig. B5.39). The *calcaneofibular ligament* may also be torn. In severe sprains, the lateral malleolus of the fibula may be fractured. *Shearing injuries fracture the lateral malleolus* at or superior to the ankle joint. *Avulsion fractures* break the malleolus inferior to the ankle joint; a fragment of bone is pulled off by the attached ligament(s).

A **Pott fracture–dislocation of the ankle** occurs when the foot is forcibly everted (Fig. B5.40). This action pulls on the extremely strong medial ligament, often tearing off the medial malleolus. The talus then moves laterally, shearing off the lateral malleolus or, more commonly, breaking the fibula superior to the tibiofibular syndesmosis. If the tibia is carried anteriorly, the posterior margin of the distal end of the tibia is also sheared off by the talus, producing a “trimalleolar fracture.” In applying this term to this injury, the entire distal end of the tibia is erroneously considered to be a “malleolus.”

Tibial Nerve Entrapment



The tibial nerve leaves the posterior compartment of the leg by passing deep to the flexor retinaculum in the interval between the medial malleolus and the calcaneus (Fig. 5.71A). Entrapment and compression of the tibial nerve (*tarsal tunnel syndrome*) occurs when there is edema and tightness in the ankle involving the synovial sheaths

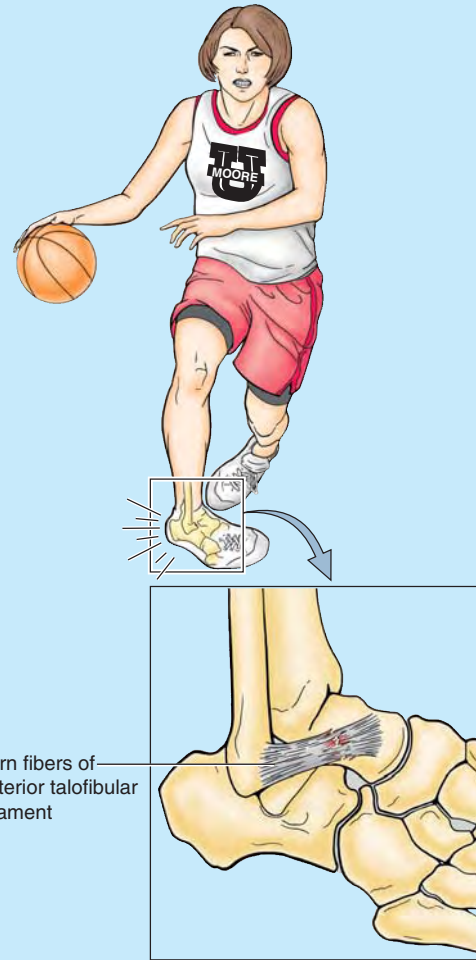


FIGURE B5.39.

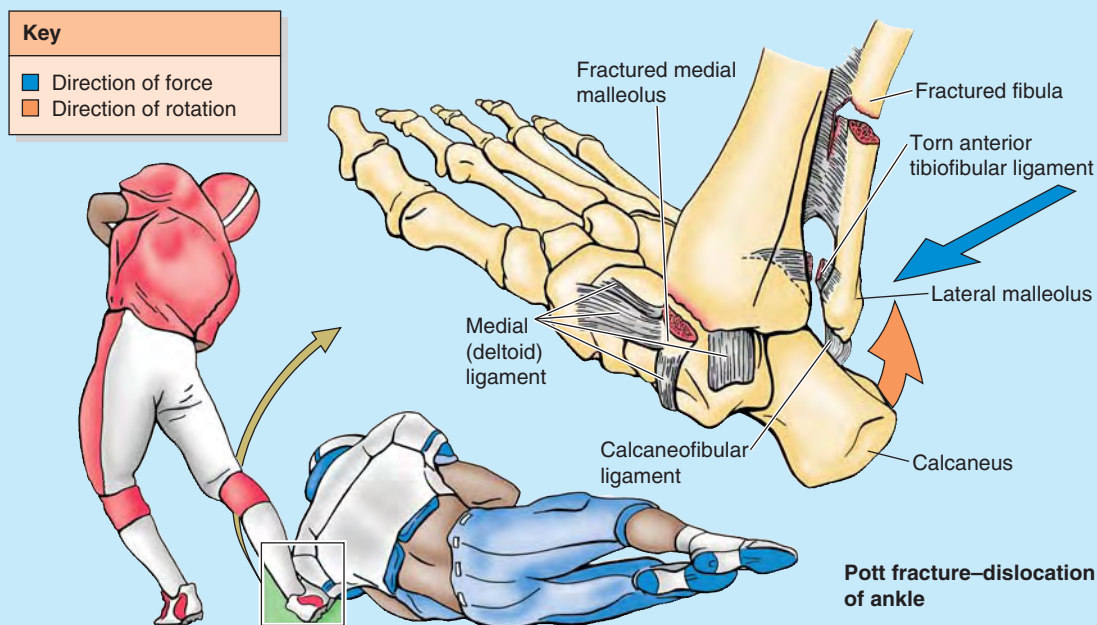


FIGURE B5.40.

of the tendons of muscles in the posterior compartment of the leg. The area involved is from the medial malleolus to the calcaneus, and the heel pain results from compression of the tibial nerve by the flexor retinaculum.

Hallux Valgus



Hallux valgus is a foot deformity caused by pressure from footwear and degenerative joint disease; it is characterized by lateral deviation of the great toe (Fig. B5.41). The **L** in **valgus** indicates **lateral deviation**. In some people, the painful deviation is so large that the great toe overlaps the 2nd toe (Fig. B5.41A), and there is a decrease in the medial longitudinal arch. Such deviation occurs especially in females, and its frequency increases with age. These individuals cannot move their 1st digit away from their 2nd digit because the sesamoids under the head of the 1st metatarsal are usually displaced and lie in the space between the heads of the 1st and 2nd metatarsals (Fig. B5.41B). The 1st metatarsal shifts medially and the sesamoids shift laterally. Often the surrounding tissues swell and the resultant pressure and friction against the shoe cause a subcutaneous bursa to form; when tender and inflamed, the bursa is called a **bunion** (Fig. B5.41A). Often hard **corns** (inflamed areas of thick skin) also form over the proximal interphalangeal joints, especially of the little toe.

Hammer Toe



Hammer toe is a foot deformity in which the proximal phalanx is permanently and markedly dorsiflexed (hyperextended) at the metatarsophalangeal joint and the middle phalanx strongly plantarflexed at the proximal interphalangeal joint. The distal phalanx of the digit is often also hyperextended. This gives the digit (usually the 2nd) a hammer-like appearance (Fig. B5.42A). This deformity of one or more toes may result from weakness of the lumbrical and interosseous muscles, which flex the metatarsophalangeal joints and extend the interphalangeal joints. A **callosity** or **callus**, hard thickening of the keratin layer of

the skin, often develops where the dorsal surface of the toe repeatedly rubs on the shoe.

Claw Toes



Claw toes are characterized by hyperextension of the metatarsophalangeal joints and flexion of the distal interphalangeal joints (Fig. B5.42B). Usually, the lateral four toes are involved. Callosities develop on the dorsal surfaces of the toes because of pressure of the shoe. They may also form on the plantar surfaces of the metatarsal heads and the toe tips because they bear extra weight when claw toes are present.

Pes Planus (Flatfeet)



The flat appearance of the foot before age 3 is normal and results from the thick subcutaneous fat pad in the sole. As children get older, the fat is lost, and a normal medial longitudinal arch becomes visible (Fig. B5.42C). Flatfeet can either be *flexible* (flat, lacking a medial arch, when weight-bearing but normal in appearance when not bearing weight [Fig. B5.42D]) or *rigid* (flat even when not bearing weight). The more common *flexible flatfeet* result from loose or degenerated intrinsic ligaments (inadequate passive arch support). Flexible flatfoot is common in childhood but usually resolves with age as the ligaments grow and mature. The condition occasionally persists into adulthood and may or may not be symptomatic.

Rigid flatfeet with a history that goes back to childhood are likely to result from a bone deformity (such as a fusion of adjacent tarsal bones). *Acquired flatfeet* (“fallen arches”) are likely to be secondary to dysfunction of the tibialis posterior (dynamic arch support) owing to trauma, degeneration with age, or denervation. In the absence of normal passive or dynamic support, the plantar calcaneonavicular ligament fails to support the head of the talus. Consequently, the head of the talus displaces inferomedially and becomes prominent (Fig. B5.42D, red arrow). As a result, some flattening of the

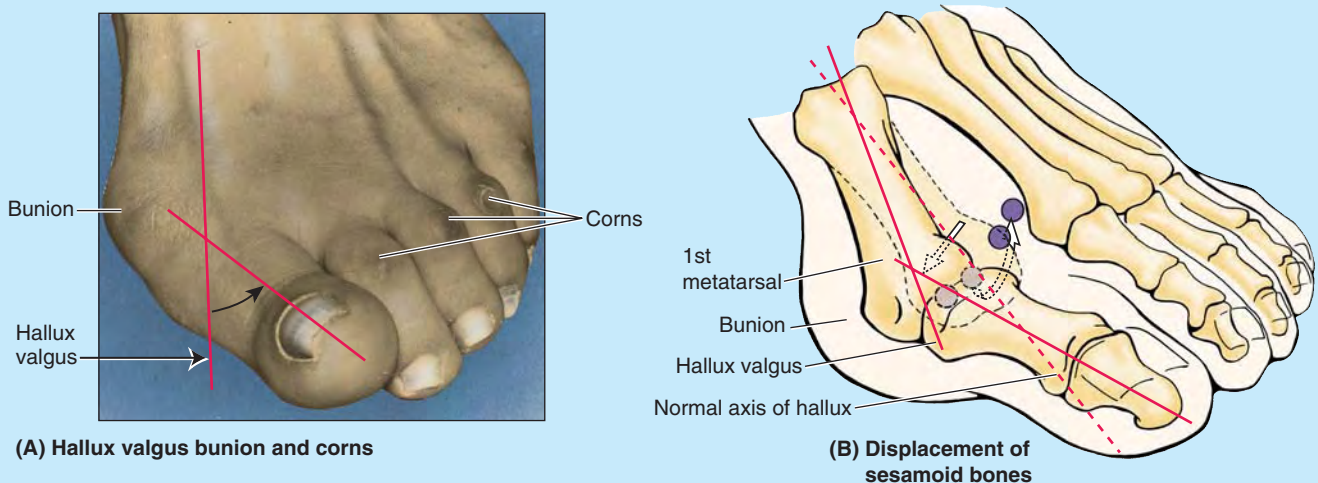


FIGURE B5.41.

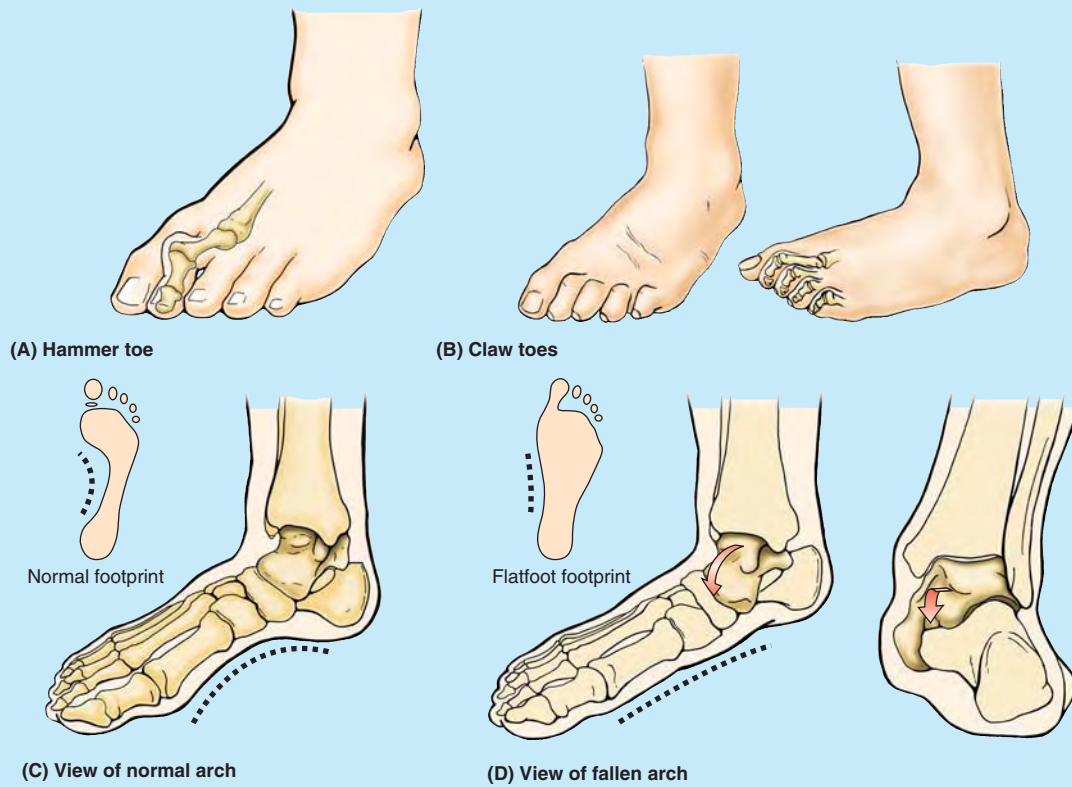


FIGURE B5.42.

medial part of the longitudinal arch occurs, along with lateral deviation of the forefoot. Flatfeet are common in older people, particularly if they undertake much unaccustomed standing or gain weight rapidly, adding stress on the muscles and increasing the strain on the ligaments supporting the arches.

Clubfoot (Talipes equinovarus)



Clubfoot refers to a foot that is twisted out of position. Of the several types, all are *congenital* (present at birth). *Talipes equinovarus*, the common type (2 per 1000 live births), involves the subtalar joint; boys

are affected twice as often as girls. The foot is inverted, the ankle is plantarflexed, and the forefoot is adducted (turned toward the midline in an abnormal manner) (Fig. B5.43). The foot assumes the position of a horse's hoof, hence the prefix "equino" (*L. equinus*, horse). In half of those affected, both feet are malformed. A person with an uncorrected clubfoot cannot put the heel and sole flat and must bear the weight on the lateral surface of the forefoot. Consequently, walking is painful. The main abnormality is shortness and tightness of the muscles, tendons, ligaments, and joint capsules on the medial side and posterior aspect of the foot and ankle.

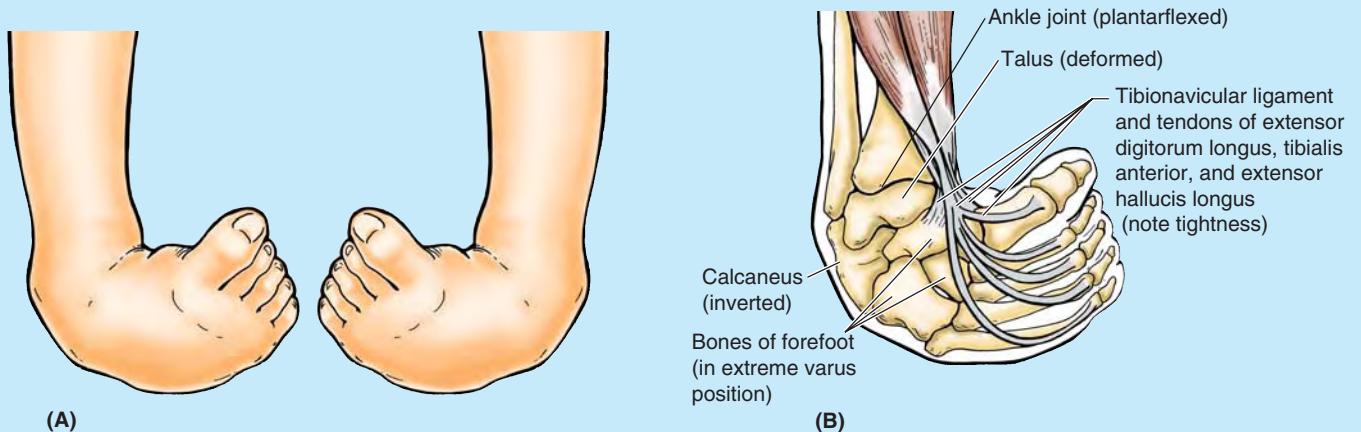


FIGURE B5.43.

The Bottom Line

JOINTS OF LOWER LIMB

Hip joint: The hip joint is the strongest and most stable joint.

◆ Its stability results from (1) the mechanical strength of its ball and (deep) socket construction, allowing extensive articular surface contact; (2) its strong joint capsule; and (3) its many surrounding muscles. ◆ However, it remains vulnerable, especially in older age, because of the angle of the femoral neck (inclination) and close association of the blood supply of the femoral head to the neck. Thus fractures result in avascular necrosis of the femoral head. ◆ Major movements of the hip joint include flexion and extension, possible over a wide range; medial and lateral rotation with abduction are part of every step of normal, bipedal walking.

Knee joint: The knee is a hinge joint with a wide range of motion (primarily flexion and extension, with rotation increasingly possible with flexion). ◆ It is our most vulnerable joint owing to its incongruous articular surfaces and the mechanical disadvantage resulting from bearing the body's weight plus momentum while serving as a fulcrum between two long levers.

◆ Compensation is attempted by several features, including (1) strong intrinsic, extracapsular, and intracapsular ligaments; (2) splinting by many surrounding tendons (including the ilio-tibial tract); and (3) menisci that fill the spatial void, providing mobile articular surfaces. ◆ Of particular clinical importance are (1) collateral ligaments that are taut during (and limit) extension and are relaxed during flexion, allowing rotation for which they serve as check ligaments; (2) cruciate ligaments that maintain the joint during flexion, providing the pivot for rotation; and (3) the medial meniscus that is attached to the tibial collateral ligament and is frequently injured because of this attachment.

Tibiofibular joints: The tibiofibular joints include a proximal synovial joint, an interosseous membrane, and a distal tibiofibular syndesmosis, consisting of anterior, interosseous, and poste-

rior tibiofibular ligaments. ◆ Together these joints make up a compensatory system that allows a slight upward movement of the fibula owing to forced transverse expansion of the malleolar mortise (deep square socket) during maximal dorsiflexion of the ankle. ◆ All fibrous tibiofibular connections run downward from tibia to fibula, allowing this slight upward movement while strongly resisting the downward pull applied to the fibula by the contraction of eight of the nine muscles attached to it.

Ankle joint: The ankle (talocrural) joint is composed of a superior mortise, formed by the weight-bearing inferior surface of the tibia and the two malleoli, which receive the trochlea of the talus. ◆ The ankle joint is maintained medially by a strong, medial (deltoid) ligament, and a much weaker lateral ligament. ◆ The lateral ligament (specifically its anterior talofibular ligament component) is the most frequently injured ligament of the body. ◆ Injury occurs primarily by inadvertent inversion of the plantarflexed, weight-bearing foot. ◆ About 70° of dorsiflexion and plantarflexion is possible at the ankle joint, in addition to which small amounts of wobble occur in the less stable plantarflexed position.

Joints of foot: Functionally, there are three compound joints in the foot: (1) the clinical subtalar joint between the talus and the calcaneus, where inversion and eversion occur about an oblique axis; (2) the transverse tarsal joint, where the midfoot and forefoot rotate as a unit on the hindfoot around a longitudinal axis, augmenting inversion and eversion; and (3) the remaining joints of the foot, which allow the pedal platform (foot) to form dynamic longitudinal and transverse arches. ◆ The arches provide the resilience necessary for walking, running, and jumping, and are maintained by four layers of passive, fibrous support plus the dynamic support provided by the intrinsic muscles of the foot and the long fibular, tibial, and flexor tendons.



References and Suggested Readings are located in Appendix A and online at <http://thepoint.lww.com/COA6e>, where you will also find helpful study tools, including USMLE-style questions, case studies, images, and more!