

**Zaporizhzhia state medical university**  
**Department of phthisiology and pulmonology**

**R.M. Yasinskyi**

# **CLINICAL FORMS OF TUBERCULOSIS**

**STUDY GUIDE**

**for practical classes for students – foreign citizens of 4<sup>th</sup> course  
on speciality «Phthisiology»**

**Zaporizhzhia 2016**

**UDC: 616.24-002.5-03(075.8)=111**

**ББК: 55.4Я73**

**Y31**

*Recommended of Zaporizhzhia state medical university Central Methodological Council as study guide for practical classes on speciality «Phthiology» for students – foreign citizens of 4<sup>th</sup> course. The report №1 from 29.09.2016.*

**The reviewers:**

**Prosvetov Yuri Vasilovich** – the head of phthiology and pulmonology department of state institution «Zaporizhzhia medical academy of postgraduate education of Ministry of healthy of Ukraine», MD, professor.

**Ryabokon Olena Vyacheslavivna** – the head of infectious diseases department of Zaporizhzhia state medical university, MD, professor.

**Yasinskyi R. M.**

**Y31** Clinical forms of tuberculosis : study guide for practical classes for students – foreign citizens of 4<sup>th</sup> course on speciality "Phthiology"/ R. M. Yasinskyi. – Zaporizhzhia : [ZSMU], 2016. – 81 p.

The study guide is made according to the work program of phthiology for students – foreign citizens of 4th courses for practical classes. The manual described the clinical features, radiological signs, diagnostic criteria and main principles of differential diagnosis in primary, secondary pulmonary tuberculosis. There is review of most frequent extrapulmonary tuberculosis clinical forms.

## THE LIST OF ABBREVIATIONS

**AFB** – Acid fast bacilli  
**BBB**–blood-brain barrier  
**Cat** – category  
**CNS** – central nervous system  
**Coh** – cohorta  
**CSF** – cerebro-spinal fluid  
**CT**– computer tomography  
**Destr** – destruction  
**EBTB** – endobronchial tuberculosis  
**L** – lymphocytes  
**LTBI** – latent tuberculosis infection  
**MBT** – mycobacterium tuberculosis  
**MDR-TB** – multi-drug resistant tuberculosis  
**MG** – molecular genetic  
**NA** – not applicable  
**PMN**– polymorphonuclear cells  
**RifTB** – Rifampicin resistant tuberculosis  
**RMDR** – risk of MDR  
**TB** – tuberculosis  
**TBM** – tuberculosis meningitis  
**TNF- $\alpha$**  – tumor necrosis factor  $\alpha$   
**WBC** – white blood count  
**XDR-TB** – extensively drug-resistant tuberculosis.

## CONTENT

The list of abbreviations	3
Content	4
The introduction	6
1. Making tuberculosis diagnosis	7
2. Radiological syndroms	12
2.1. Abnormal pulmonary pattern syndrome	12
2.2. Lung`s roots pathology	13
2.3. Focal shadow	13
2.4. Infiltrative shadow	14
2.5. Disseminative syndrome	15
2.6. Rounded shadow	15
2.7. Ring-like shadow	17
2.8. Increased enlightenment of the lung fields	17
2.9. Mediastinal pathology syndrome	18
2.10. Free fluid in the pleural cavity	18
3. Primary tuberculosis	21
3.1. Para-specific reactions (tuberculosis ‘masks’)	21
3.2. Primary tuberculosis clinical forms	24
3.2.1. Primary tuberculosis complex	26
3.2.2. Tuberculosis of intrathoracic lymphatic nodes	32
3.2.3. Tuberculosis without established localization (tuberculosis intoxication)	35
4. Secondary tuberculosis	36
4.1. Miliary tuberculosis	36
4.2. Disseminated lung tuberculosis	38
4.3. Focal (nidus) tuberculosis	41
4.4. Infiltrative tuberculosis	43
4.5. Caseous pneumonia	49

4.6.	Tuberculoma	51
4.7.	Fibrous-cavernous tuberculosis	54
4.8.	Cirrhotic tuberculosis	58
5.	Extrapulmonary tuberculosis	61
5.1.	Tuberculosis of meninges and central nervous system	61
5.1.1.	Tuberculosis meningitis	63
5.1.2.	Brain tuberculoma	68
5.1.3.	Tuberculosis brain abscess	69
5.1.4.	Tuberculosis encephalopathy	69
5.2.	Tuberculosis pleurisy	69
5.3.	Endobronchial tuberculosis (EBTB)	74
	References	79

## THE INTRODUCTION

Study Guide is devoted to the actual problem of modern of phthisiology – clinical forms of tuberculosis. Despite the fact, that this theme refers to classical phthisiology, recently observed disease course pathomorphosis, which greatly complicates tuberculosis differential diagnosis. Due to the fact that the tuberculosis epidemic in our time remains relevant, as well as through accession HIV, clinicians have to deal with extrapulmonary lesions often. The differential diagnosis of tuberculosis in persons with concomitant diseases is more difficult. That's why, for the formation of clinical thinking university medical student requires knowledge on the current clinical course of tuberculosis.

Study guide has a great practical importance because it allows students to evaluate the complexity of tuberculosis clinical forms and to contribute finding ways to improve differential diagnostic results.

## 1. MAKING TUBERCULOSIS DIAGNOSIS

### Definitions

***Bacteriologically confirmed case of tuberculosis (TB)***– A patient from whom a biological specimen is positive by smear microscopy culture or WHO-approved rapid diagnostic test (such as Xper MTB/RIF). All such cases should be notified, regardless of whether TB treatment is started.

***Clinically diagnosed case of TB*** –A patient who does not fulfil the criteria for bacteriologically confirmed TB but has been diagnosed with active TB by a clinician or other medical practitioner who has decided to give the patient a full course of TB treatment. This definition includes cases diagnosed on the basis of X-ray abnormalities or suggestive histology and extrapulmonary cases without laboratory confirmation. Clinically diagnosed cases subsequently found to be bacteriologically positive (before or after starting treatment) should be reclassified as bacteriologically confirmed.

***Case of pulmonary TB*** –Any bacteriologically confirmed or clinically diagnosed case of TB involving the lung parenchyma or the tracheobronchial tree. Miliary TB is classified as pulmonary TB because there are lesions in the lungs. Tuberculous intra-thoracic lymphadenopathy (mediastinal and/or hilar) or tuberculous pleural effusion, without radiographic abnormalities in the lungs, constitute a case of extrapulmonary TB. A patient with both pulmonary and extrapulmonary TB should be classified as a case of pulmonary TB.

***Case of extrapulmonary TB*** –Any bacteriologically confirmed or clinically diagnosed case of TB involving organs other than the lungs, e.g. pleura, lymph nodes, abdomen, genitourinary tract, skin, joints and bones, meninges.

Clinical diagnosis of tuberculosis consists of:

- type of tuberculosis case,
- data of diagnosing,
- clinical form of TB,
- phase of TB,

- presence of destructions (Destr “0”, “+”, “-“),
- bacterial excretion (MBT “0”, “+”, “-“, M “0”, “+”, “-“ (microscopy by Zhiel Neelsen), MG “0”, “+”, “-“ (PCR-method), Rif “0”, “+”, “-“ (resistance to Rifampicin by PCR-method), C “0”, “+”, “-“ (cultural methods)
- resistance to drugs “0”, “+”, “-“ with drugs names,
- histology investigation “0”, “+”, “-“,
- category,
- cohort of patients (1, 2, 3, 4, it depends on treatment start time).

### **Types of TB cases**

***New case of TB*** –A patient who has never been treated for TB or has taken anti-TB drugs for less than one month.

***Previously treated case of TB*** –A patient who has been treated for one month or more with anti-TB drugs in the past. Retreatment cases are further classified by the outcome of their most recent course of treatment into four categories.

1. ***Relapse*** patients have previously been treated for TB, were declared cured or treatment completed at the end of their most recent course of treatment, and are now diagnosed with a recurrent episode of TB (either a true relapse or a new episode of TB caused by reinfection).

2. ***Treatment after failure*** patients have previously been treated for TB and their most recent course of treatment failed i.e. they had a positive sputum smear or culture result at month 5 or later during treatment.

3. ***Treatment after loss to follow-up*** patients have previously been treated for TB and were declared ‘lost to follow-up’ at the end of their most recent course of treatment.

4. ***Other previously treated patients*** are those who have previously been treated for TB but whose outcome after their most recent course of treatment is unknown or undocumented.



Case of ***multidrug-resistant TB (MDR-TB)*** –TB that is resistant to two first-line drugs: isoniazid and rifampicin.

Case of ***rifampicin-resistant TB (RifTB)*** –A patient with TB that is resistant to rifampicin detected using phenotypic or genotypic methods, with or without resistance to other anti-TB drugs. It includes any resistance to rifampicin, whether mono-resistance, multidrug resistance, polydrug resistance or extensive drug resistance.

Case of ***extensively drug-resistant TB (XDR-TB)*** –TB, that is resistant to isoniazid, rifampicin, at least one fluoroquinolone and aminoglycosid.

Case of **risk of MDR (RMDR)** – TB in cases, while patient has contact with MDR patient, but hasn't results of bacteriological investigation yet, or has negative bacteriological result.

### **Clinical forms of pulmonary tuberculosis**

There such clinical forms of pulmonary TB, as milliary, disseminated, focal, infiltrative, tuberculoma, caseous pneumonia, fibrous-cavernous, cirrhotic tuberculosis, primary tuberculosis complex.

### **Clinical forms of extra-pulmonary tuberculosis**

It depends on the affected organ. Miliary tuberculosis, tuberculosis of intrathoracic lymph nodes, bronchial TB, pleural effusion considers as pulmonary process in lung lesions cases.

### **Phases of TB**

There are such TB process phases: infiltration, decay (corresponding Destruction +), contamination, resorption, seals, scarring and calcification. Infiltration, decay and contamination characterize tubercular activity changes in patients. Resorption, seals, scarring and calcification (calcination) means decreasing of active tuberculosis process in dynamics with a tendency to stabilization.

### **Categories of patients**

Category 1 (Cat1) includes patients with newly (firstly) diagnosed pulmonary tuberculosis with bacterioexcretion and with ***disseminative*** and

*severe forms* of pulmonary or extrapulmonary tuberculosis without bacterioexcretion.

To the *disseminative forms* of TB belong processes, occupying two or more segments of lungs or located in two or more organs.

*Severe forms* of TB (in the absence of bacterioexcretion) include processes with severe tuberculosis intoxication, febrile body temperature, destruction of the lungs, and patients with tuberculous meningitis, disseminated (miliary) tuberculosis, tuberculous pericarditis, peritonitis, pleurisy (with severe course), tuberculosis of the spine with neurological complications, tuberculosis of digestive, urinary and reproductive organs.

Category 2 (Cat2) includes any cases of pulmonary and extrapulmonary tuberculosis register for re-treatment (patients previously treated for more than 1 month), including relapse (with and without bacterioexcretion), treatment after interruption, treatment after failure, others).

Category 3 (Cat 3) includes patients with newly diagnosed limited (less than 2 segments) tuberculosis without bacterioexcretion and patients with newly diagnosed extrapulmonary TB, which is not included in the 1 category. This category includes children with tuberculosis intoxication, tuberculosis of intrathoracic lymph nodes or primary tuberculous complex in the calcination stage where process activity saved.

Category 4 (Cat4) includes patients with chemo-drug resistant tuberculosis and its risk.

Category 5 (Cat5) includes dispensary contingents with risk of tuberculosis getting sick and its recurrence.

### **Diagnosis examples**

- 1) New case of TB (01.02.2016) upper lobe of right lung (infiltrative), contamination phase, Destr +, MBT+, M+, MG+, Rif-, C+, Resist-, Hist0, Cat 1, Coh 1 (2016).

- 2) Relapse of TB (01.04.2016) lungs (disseminative), infiltration phase, Destr-, MBT+, M-, MG+, Rif-, C0, Resist0, Hist0, Cat 2, Coh 2 (2016).
- 3) MDR-TB (05.12.2015) left lung (caseous pneumonia), contamination phase, Destr+, MBT+, M+, MG0, Rif0, C+, Resist+ (HRES), Resist 2+ (EtOfx), infiltrative TB of B1B2B6 (bronchi) of right lungs with 2 stage of B2B6 stenosis, Hist0, Cat 4 (New case of TB), Coh 4 (2015).

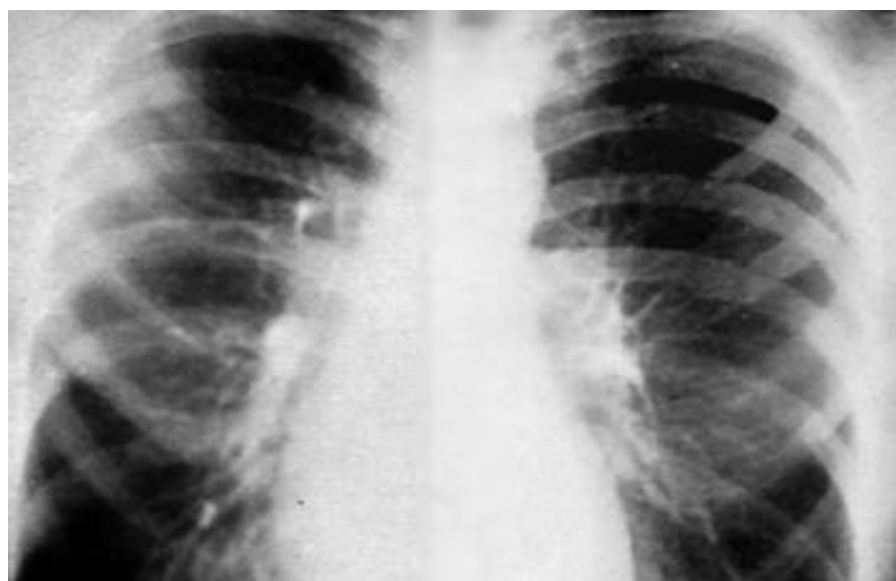
## 2. RADIOLOGICAL SYNDROMS

To explain radiological features of tuberculosis clinical form we must understand radiological syndroms. There are 10 syndroms: abnormal pulmonary pattern, lung roots pathology, focal shadow, infiltrative shadow, disseminative syndrome, rounded shadow, ring-like shadow, increased enlightenment of the lung fields, mediastinal pathology and free fluid in the pleural cavity.

### 2.1. Abnormal pulmonary pattern syndrome

This symptom is manifested in the form of several options:

- Increased and enriching the lung picture (at inflammatory processes, collagenous diseases, tumor, pneumoconiosis, sarcoidosis, vascular lesions with symptoms of congestion and interstitial edema);
- deformation of lung pattern (at formation of inflammatory infiltrates, peri-bronchial inflammation, cicatricial due to wrinkling certain segments, the interparticle pathology and partial internal connective tissues, lung`s fibrosis with chronic venous stasis, the appearance of a thin mesh picture at hemosiderosis, the formation of numerous small ring shadows at scleroderma);
- weakening of lung`s pattern (in diffuse pulmonary dissemination, picture 1, development of numerous small cavities);

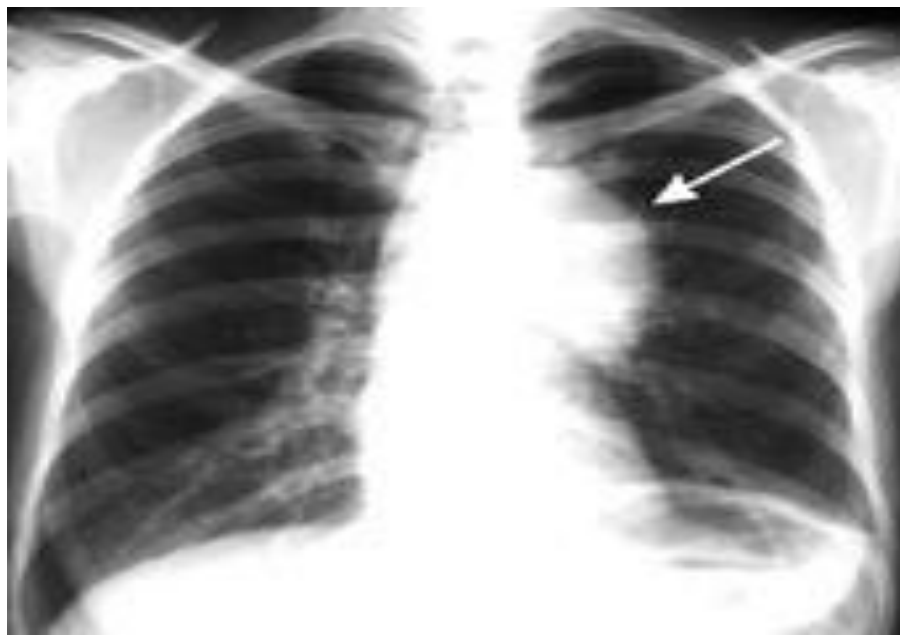


Picture 1. Weakening of lung`s pattern

- depletion of the picture (at inflating the lungs, lung arterial nets hypoplasia);
- unusual elements of the picture.

## **2.2. Lung`s roots pathology**

Manifested with increase, deformation, increase the intensity and root of the lung shade structures violation, associated with vascular or bronchial lymph nodes disorders. Changes root of the lung occur when tuberculosis internal thoracic lymph nodes, sarcoidosis, lymphosarcoma, central cancer, lymphogranulomatosis, nonspecific inflammation (basal pneumonia), aortic aneurysm, expanding the trunk of pulmonary blood vessels in heart diseases with hypertension in the pulmonary circulation (mitral stenosis) and at primary pulmonary hypertension, benign tumors (thymoma), retrosternal goiter, acute childhood diseases (measles, scarlet fever) and others, picture 2.

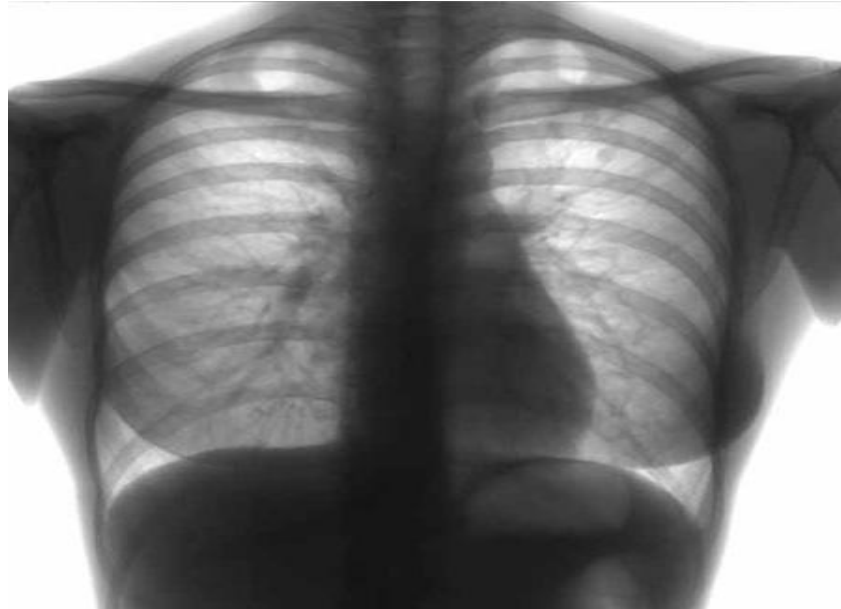

**Picture 2. Lung`s roots pathology**

## **2.3. Focal shadow**

Characterized by one or more shades (up to 10), round or irregular shapes, up to 1 cm in diameter, which can have a different intensity and are usually placed in a limited space in one or both lungs (picture 3). Symptom “focal shadow” is a manifestation of many diseases, occurring with lesions of the lung

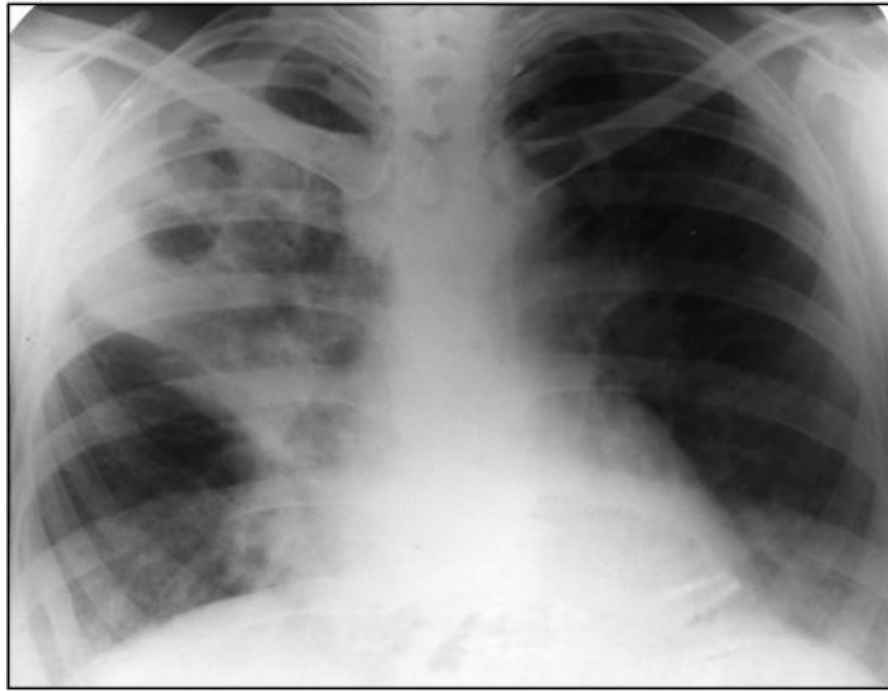parenchyma. Inflammation (bacterial and viral acute pneumonia, tuberculosis, fungal lesions), benign and malignant tumors, vascular disorders, collagen diseases, blood diseases, reticular and lymphoid tissues are the main pathological processes that accompanied the emergence of focal shadows, the formation of which results in the local disappearance of air from the alveoli.



**Picture 3. Focal shadow**

#### **2.4. Infiltrative shadow**

This syndrome characterized by shadow areas of more than 1 cm, round or irregular shape, which has no clear contours (picture 4). Depending on the severity there are syndrome “limited infiltrative shadow” in size from lobules up to lobe, and the syndrome of “total infiltrative syndrome”, which is characterized by the size of the shadow over 1 share for total blackout of all lung fields. Infiltrative changes in the lungs are the most widespread (50%) among other pulmonary diseases. Causes of this syndrome may be inflammation, tumor process, atelectasis, pulmonary infarction, hematoma, accompanied by hypoventilation. This syndrome can develop at congenital defects – lobe hypoplasia and aplasia.



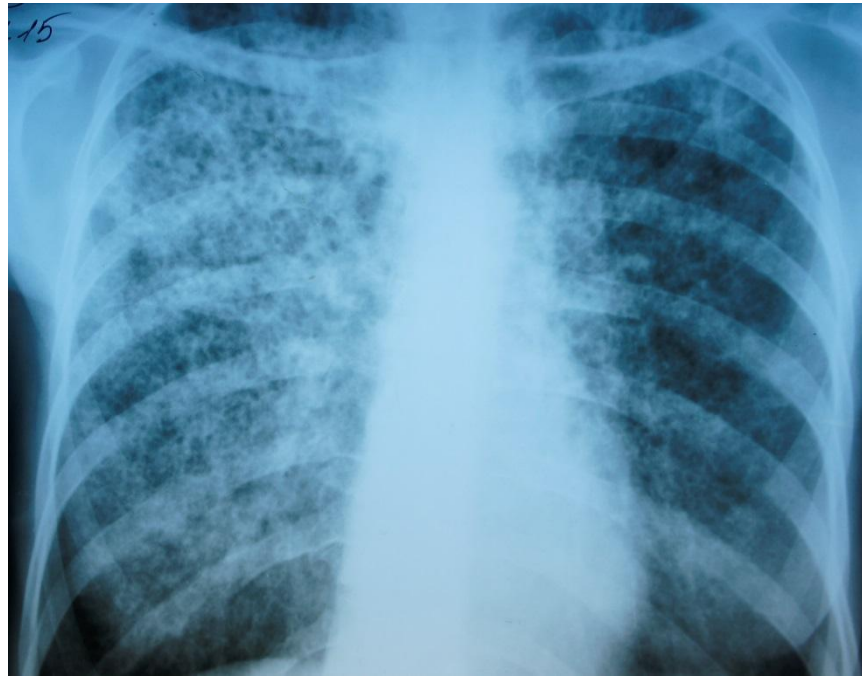Picture 4. **Lung`s infiltration**

### **2.5. Disseminative syndrome**

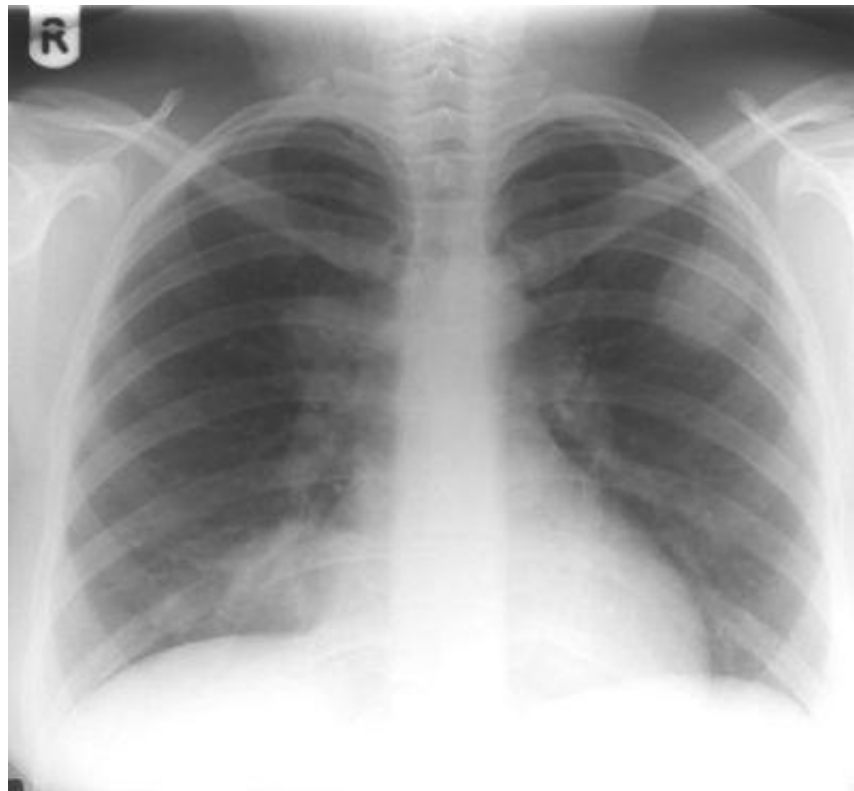
Characterized by multiple focal and retinal shadows of varying intensity to 1 cm in diameter, that are placed on a large lung`s length the and are usually bilateral (picture 5). There are more than 200 diseases of different aetiology and genesis, accompanied by disseminative syndrome in the lungs. Depending on the etiology and pathogenesis all diseases are divided into: 1) infectious-inflammatory (bacterial, viral, mycobacterial, fungal), 2) the tumor; 3) parasitic; 4) pneumoconiosis; 5) allergic; 6) collagenoses; 7) an inhaled and aspiration; 8) congenital constitutional; 9) metabolic-toxic; 10) reticulo-endothelial and hematopoietic; 11) cardiovascular; 12) traumatic; 13) unknown etiology.

### **2.6. Rounded shadow**

Characterized by volume spherical or oval formation of correct, incorrect or polycyclic forms with clear or blurred contours more than 1 cm in diameter (picture 6). It may be tuberculoma, nonspecific round pneumonia, eosinophilic rounded infiltrate, cancer, benign tumors (neurinoma, hemangioma, arteriovenous aneurysm, adenoma, veins varicose), tumors of bronchi, asperhiloma, retention cyst, Echinococcus.



Picture 5. Lung's dissemination

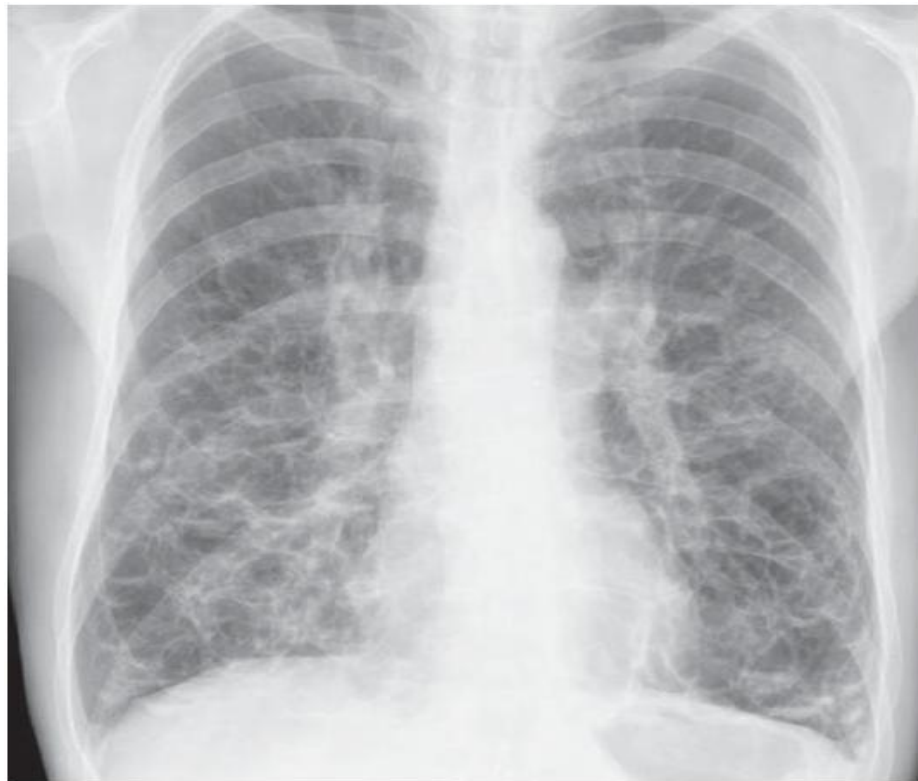

Picture 6. Rounded shadow



## 2.7. Ring-like shadow

It is characterized by rounded enlightenment, which is surrounded by a ring-like shadow (picture 7). Enlightenment in the lung may be due to lack of lung tissue and replacement of air with restriction tissue defect from the surrounding areas of wall or capsule. The cavity of the lungs may have primary (congenital cysts air, emphysematous bullae, bronchiectasis) or secondary (decay or inflammatory infiltrate tumors, cleaning parasitic cysts, tumors traumatic penetration in the interstitial tissue) nature.

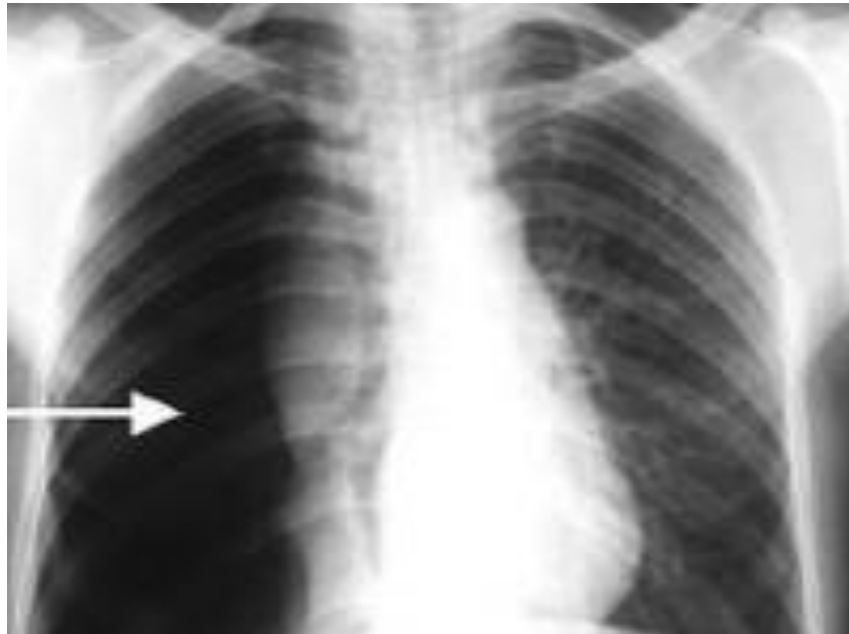

Picture 7. Ring-like syndrome

## 2.8. Increased enlightenment of the lung fields

It includes varying prevalence of enlightenment, not limited by ring-like shadow and is located in the lungs or in the pleural cavity (picture 8). Symptom can be caused by: defects in lung tissue (pneumothorax); degenerative-dystrophic changes of intrapulmonary bronchial artery branches with presence of capillary or venous stasis; violation of bronchial patency as a result of chronic inflammation in them, increased viscosity of bronchial secretions, bronchial

compression for inflammatory, neoplastic and sclerotic processes in the lung parenchyma; congenital bronchial pathology; adaptive reactions after lung resection.



Picture 8. **Increased enlightenment of the lung fields**

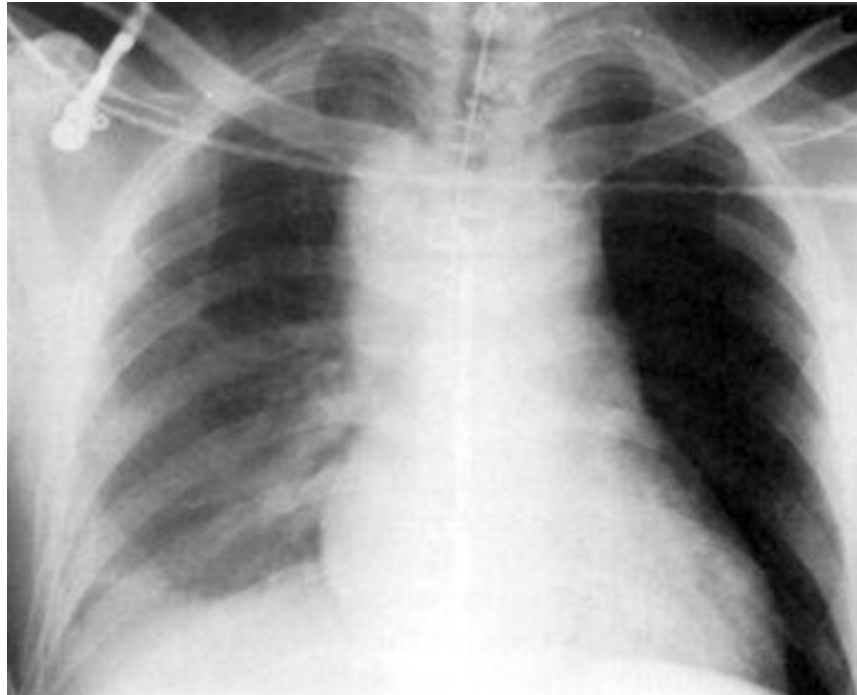
### **2.9. Mediastinal pathology syndrome**

It manifested by changing the mediastinum form or position (picture 9). This syndrome may be present at fibrosis, cirrhosis, after lung's resection, lung's agenesis, lung atelectasis, in the presence of air or fluid in the pleural cavity, at diaphragmatic hernia, sometimes in large lung tumors or giant lungs cyst cases, at the bronchial tumors and enthetic bodies. Mediastinum forms changing (extension) may be at mediastinal cysts and tumors, inflammatory processes (acute, chronic, mediastinitis encysted abscess of the mediastinum).

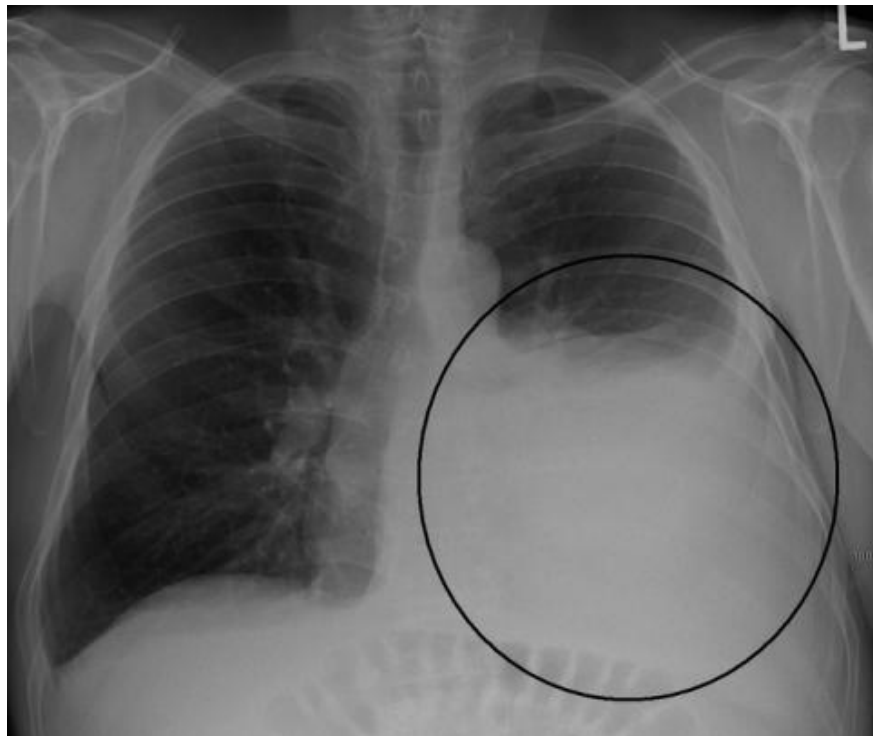
### **2.10. Free fluid in the pleural cavity**

It characterized by a one- or two-way shadow areas of different sizes, with the predominant placement in the lower divisions, with oblique upper limit (picture 10). Depending on the position of the body section blackout can change the location. Pleural effusions are divided into exudate and transudate. Transudate resulting in increase of capillary pressure, or in decrease of oncotic pressure of blood plasma. The transudate nature pleural fluid has in

congestive heart failure, liver cirrhosis, hydrothorax, glomerulonephritis, myxedema cases.



**Picture 9. Mediastinal pathology syndrome**



**Picture 10. Fluid in pleural cavity**

The most frequent cause of exudative pleurisy of different etiology is increased permeability of the pleural surfaces for protein and decreased oncotic pressure gradient. The second reason is the lymphatic outflow reduction from the pleural cavity. A third reason could be a pressure reduction in the pleural cavity.

Pleural effusion may develop in lung cancer, breast cancer, lymphoma, lymphogranulomatosis, benign and malignant pleural mesothelioma, bacterial pneumonia, tuberculosis, fungal infections (aspergillosis, cryptococcosis, actinomycosis) and parasitic diseases (amebiasis, echinococcosis) at viral, infections, pulmonary embolism, pancreatitis, hepatic and subdiaphragmatic abscess, at collagen diseases (rheumatism, systemic lupus erythematosus, Wegener's granulomatosis), rupture of thoracic lymphatic duct.

### **3. PRIMARY TUBERCULOSIS**

There are some features of primary TB:

- 1) development of the disease after the first meeting of the body with infection;
- 2) sensitization and allergy, immediate hypersensitivity reactions;
- 3) prevalence of exudative-necrotic changes;
- 4) tendency to hematogenous and lymphogenic generalization;
- 5) para-specific reactions such as vasculitis, arthritis, serositis etc.
- 6) mostly children getting sick, although the disease occurs in adolescents and adults.

### **3.1. Para-specific reactions (tuberculosis “masks”)**

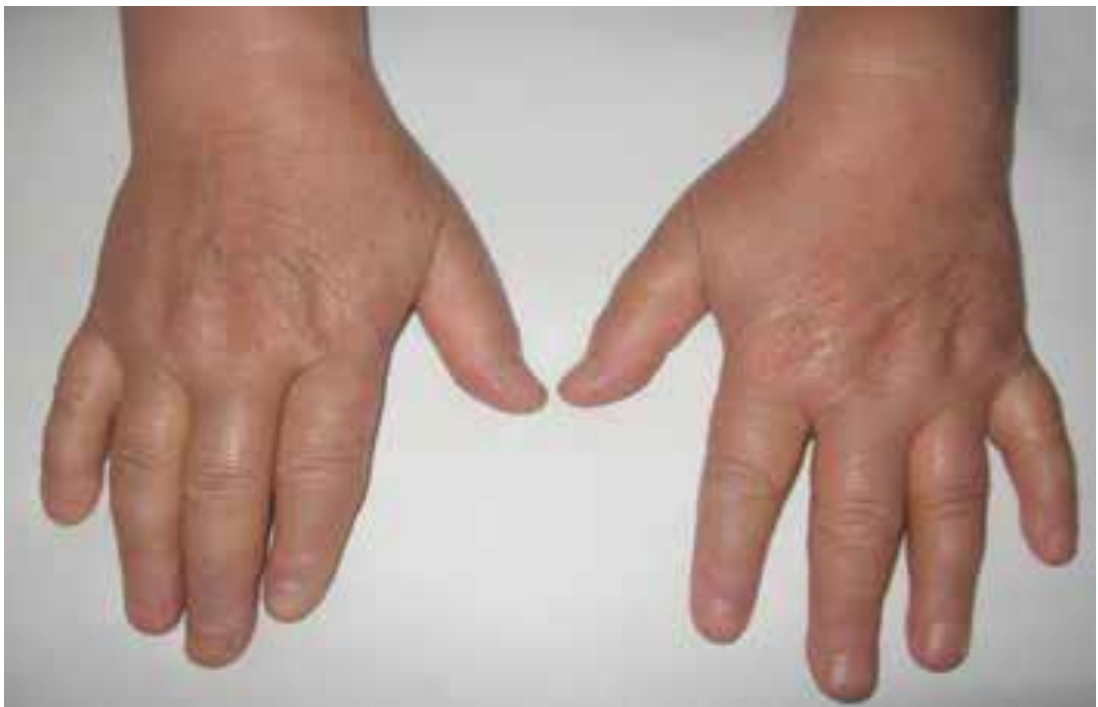In primary tuberculosis there are situations where the disease occurs more on the type of therapeutic, hematological, rheumatologic disease. This is due to the fact that the body is infected TB patient responsible development of vasculitis and allergic reactions.

- 1) The most frequently tuberculosis in active phase occurs in such frequent, long, unusual flu-like illness without clearly expressed inflammation of the upper respiratory tract and causes the patient's family outbreaks of influenza states – itsa “flu-like” tuberculosis mask (picture 11).



Picture 11. “Flu-like” TB mask

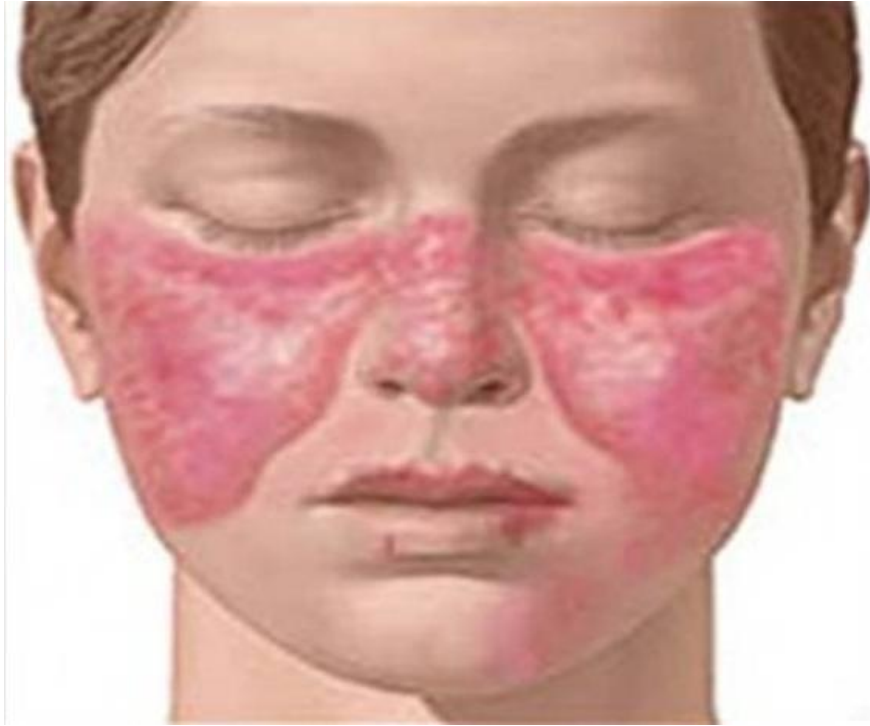- 2) The second frequency is “pneumonic” mask. This is repeated recurrent pneumonia, especially in the same lung place with torpent course, having atypical clinic and course, difficult to treated, slowly resolved with the formation of small focal and fibrotic changes.
- 3) Tuberculosis can begin on type “rheumatic” mask, called “Poncet`s disease” (picture 12). It manifested a long course articular syndrome with pain, swelling, breach of mobility in the joints with deformation, ankylosis. When X-rays there are typical signs of rheumatoid arthritis. There no efficiency after antirheumatic therapy in “Poncet`s disease” cases, no complications such as endocarditis. Only TB positive tuberculin tests, specific X-ray changes and the effect of specific therapy allows to confirm the diagnosis of tuberculosis.



Picture 12. **Poncet`s disease**

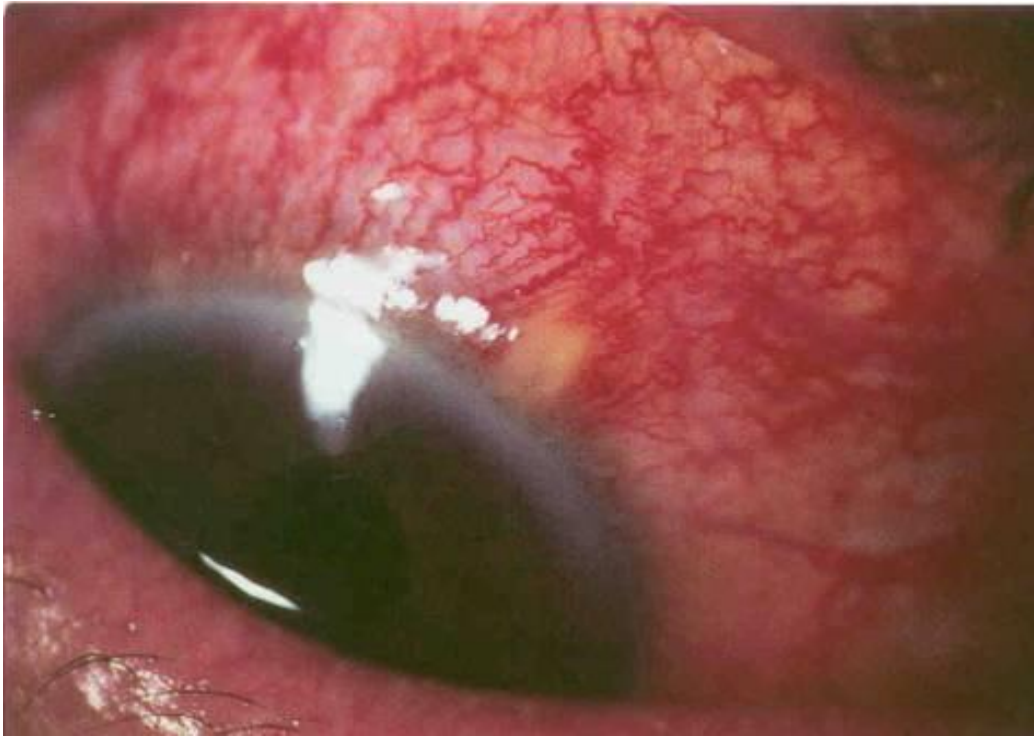- 4) “Neurological” TB mask manifests as long, persistent neuralgia, which can not be usually treated, especially for intercostal and sciatic nerves, but without signs of compression (osteochondrosis) or inflammatory lesions nerve (a radiculitis).

- 5) “Lupus-like” mask manifests typical erythema on the face in the form of "butterfly" (picture 13), trophic disorders, arthralgia, leukopenia, sharply increased ESR, sometimes specific blood cells and antibodies to DNA are finding.



Picture 13. “Lupus-like” TB mask

- 6) “Hematological” mask of tuberculosis occurs with bone marrow hypoplasia, leukopenia, anemia, thrombocytopenia, sometimes with leukemoid reactions. Often manifests lymphadenopathy, splenomegaly, B12-deficiency anemia and hypoplastic anemia.
- 7) Keratoconjunctivitis phlyctenular. Most often its tubercular-allergic process in children with broncho-adenitis and tuberculosis of the lymph nodes, and other allergic reactions. On the bulbar conjunctiva and cornea near the limbus there are single or multiple inflammatory nodules of yellowish-pink color with a bunch of the blood vessels that are often completely resolve, but sometimes disintegrate with the formation of ulcers followed by replacement with connective tissue (picture 14) .



Picture 14. **Keratoconjunctivitis phlyctenular**

### 3.2. Primary tuberculosis clinical forms

The primary site of infection in the lungs is called the Ghon focus. It either enlarges as disease progresses or, much more commonly, undergoes healing. Healing may result in a visible scar that may be dense and contain foci of calcification. During the early stage of infection, organisms commonly spread via lymphatic channels to regional hilar and mediastinal lymph nodes and via the bloodstream to more distant sites in the body. The combination of the Ghon focus and affected lymph nodes is known as the Ranke complex. The initial infection is usually clinically silent. In approximately 5% of infected individuals, immunity is inadequate and clinically active disease develops within 1 year of infection, a condition known as progressive primary infection. For most infected individuals, however, TB remains clinically and microbiologically latent for many years. In approximately 5% of the infected population, endogenous reactivation of latent infection develops many years after the initial infection (this has also been called “postprimary TB”). The reactivation TB tends to involve predominantly the apical and posterior segments of the upper lobes and the



superior segments of the lower lobes. This location is likely due to a combination of relatively higher oxygen tension and impaired lymphatic drainage in these regions. As distinct from primary infection site, in which healing is the rule, reactivation TB tends to progress. The main abnormalities are progressive extension of inflammation and necrosis, frequently with development of communication with the airways and cavity formation. The endobronchial spread of necrotic material from a cavity may result in TB infection in the same or in other lobes. Hematogenous dissemination may result in miliary TB.

Primary TB has been considered to be mainly a disease of infancy and childhood. The most common radiographic abnormalities of primary TB in infancy and childhood are intra-thoracic lymph node enlargement, pleural effusion, and lower lobe lung lesions. Primary TB can also occur in adults and hence a shift toward delayed presentation in adults may be related to a decrease in childhood exposure and an increasing number of immunocompromised hosts. Primary tuberculosis in adolescents and adults tends to manifest itself as lung parenchymal lesions in the upper lobes or superior segments of the lower lobes. In addition, pleural effusion or mediastinal lymph node enlargement is occasional. Cavitation, usually within area of consolidation, can also occur in adolescent or adult primary TB as in our cases. Early cavitation in primary TB is more common and occurs more quickly in adults than in any other age group. Therefore, primary TB in adolescents and adults can manifest upper lobe cavitory consolidation without mediastinal or hilar lymph node enlargement or pleural effusion, and thus show traditionally regarded typical chest radiographic findings of reactivation TB with remote infection.

The initial parenchymal focus of TB may enlarge and result in an area of airspace consolidation or, more commonly, undergo healing by transformation of the granulomatous tissue into mature fibrous tissue. Primary TB occurs most commonly in children but is being seen with increasing frequency in adults. The most common abnormality in children is lymph node enlargement, which is seen in 90–95% of cases. The lymphadenopathy is usually unilateral and located

in the hilum or the paratracheal region. On computer tomography (CT), the enlarged nodes typically show central low attenuation, which represents caseous necrosis, and peripheral rim enhancement, which represents the vascular rim of the granulomatous inflammatory tissue.

Airspace consolidation, related to parenchymal granulomatous inflammation and usually unilateral, is evident radiographically in approximately 70% of children with primary TB. It shows no predilection for any particular lung zone. On CT, the parenchymal consolidation in primary TB is most commonly dense and homogeneous but may also be patchy, linear, nodular, or masslike.

Pleural effusion is usually unilateral and on the same side as the primary focus of TB. The effusion may be large and occur in patients without evidence of parenchymal disease on chest radiographs.

So, primary tuberculosis has the following features:

- more frequently in children,
- expressed sensitization,
- the presence of paraspecific reactions,
- tendency to hematogenous and lymphogenous dissemination
- expressed lymphotropic character of lesion,
- the ability to self-healing.

### **3.2.1. Primary tuberculosis complex**

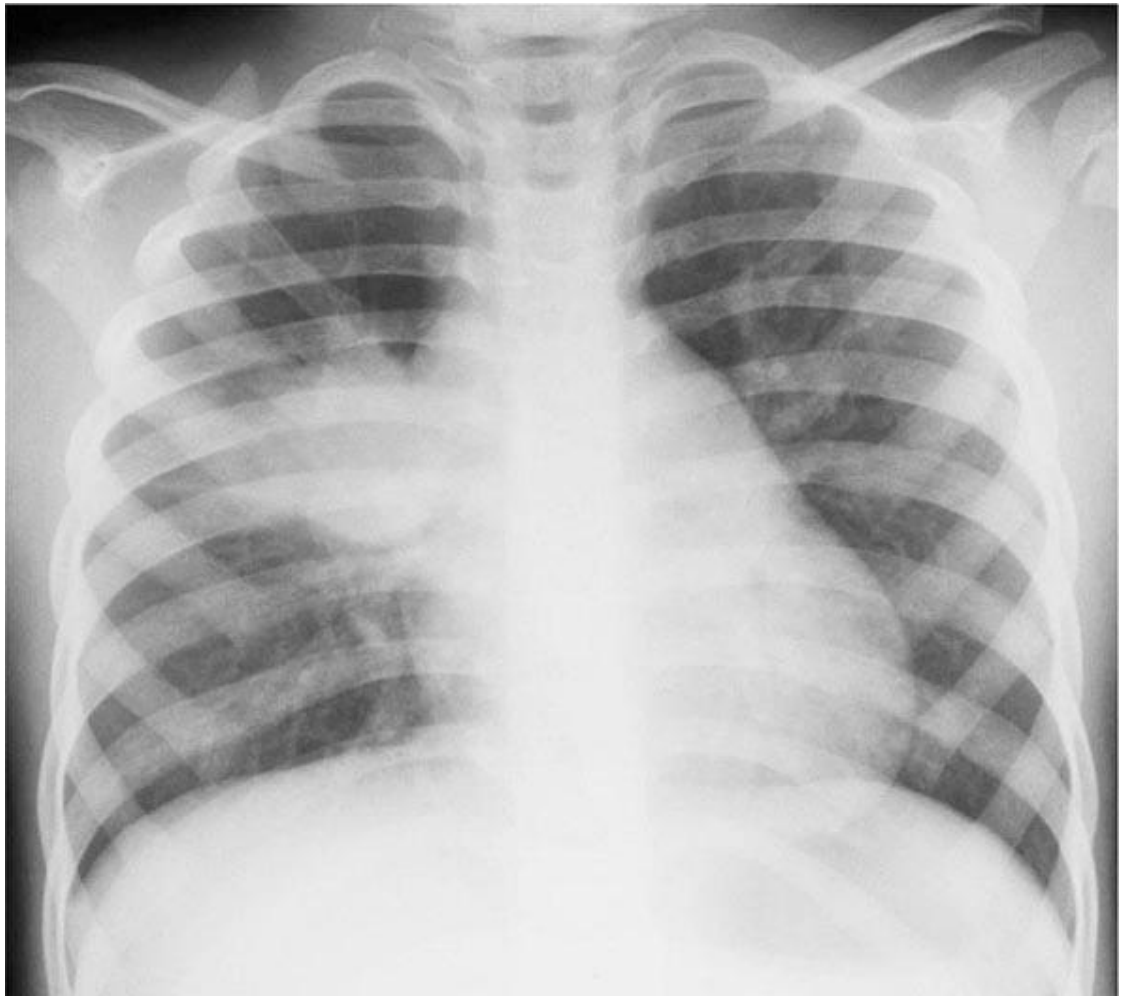
Primary tuberculosis complex is characterized by the development of inflammatory changes in the lungs, intrathoracic lymph node lesions and lymphangitis. Most often it is observed in children and much less in 18-25 years aged people. Clinical manifestations of primary tuberculosis complex depend on the phase of the process, its course characteristics and organism's reactivity.

Its course can be oligosymptomatic but, more often there are signs of tuberculosis intoxication, especially in the dissemination process on serous membrane (pleurisy, polyserositis) and bronchi cases. Lymphadenitis,

hepatolienal syndrome, paraspecific reactions can be observed. Primary tuberculosis complex appear before the tuberculin tests “virage”.

It starts gradually, usually with the symptoms of intoxication, subfebrile temperature, in some cases – with acute rise in temperature to 38-39°C that in 2-3 weeks becomes subfebrile. There are moderate cough and sputum excretion. Over the affected areas on the lungs dullness of pulmonary sound observed by percussion, weakened hard breathing, dry or wet wheezing by auscultation. There are mycobacteria tuberculosis in the sputum or bronchial scourage in some cases.

Classic primary tuberculosis complex consists of three main elements: lung`s, intrathoracic lymphatic nodes lesions and lymphangitis which they are bound (picture 15).



Picture 15. **Primary tuberculosis complex**

Pneumonia (lobar or segmental) changes into diffused form, that depends on hyperergic reactions and incomplete differential process in lungs of small children. Elder children have small primary foci in lungs, whereas others have various complications of primary tuberculosis complex.

During the examination of a child enlarged peripheral lymph nodes (cervical, axillary) dense, mobile, without perifocal inflammation are found out in surrounding tissues. If the pneumonic focus is large, the corresponding half of thorax lags in breathing. Dullness of percussion tone and fine moist rales are heard above the focus. If lung focuses are small, there are no physical changes.

Blood examination reveals moderate leucocytosis with shift of neutrophil formula to the left, eosinopenia, monopenia and increased of ESR.

Diagnostics. An anamnesis is very important for making the diagnosis of primary complex especially indicating contact with an eliminator of bacilli and positive tuberculin tests. The conversion of tuberculin tests is especially valuable. When the primary complex is latest and active, the conversion shows hyperergic tuberculin reactions. It is very important to examine presence of mycobacterium tuberculosis in sputum and lavage waters from bronchi and stomach. X-ray examinations reveal fresh pulmonary foci with accompanying adenitis.

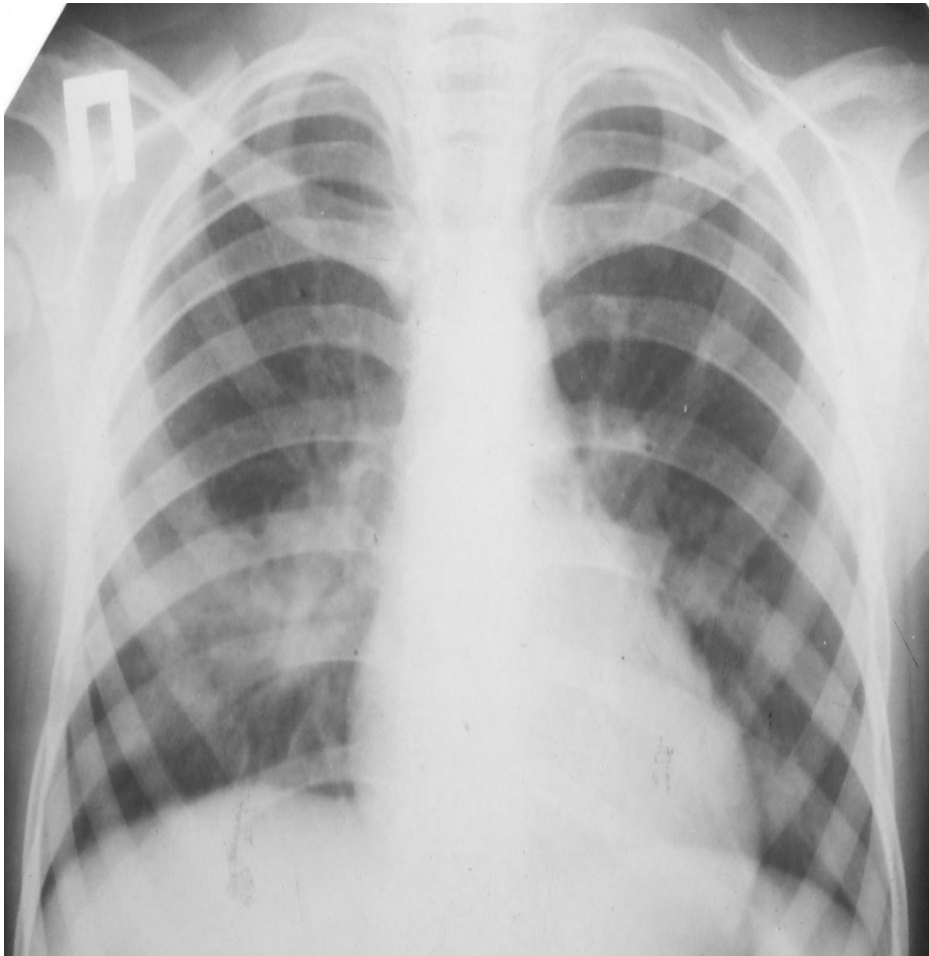
### **Radiographic picture of a primary tuberculosis complex.**

The classical primary complex consists of three basic components: pulmonic, lymphadenitis and lymphangitis connecting them. However a phase of infiltration passes before bipolarity becomes distinct on antero-posterior radiograph. An infiltration represents rather intensive opacity connected to a lung's root, sometimes it is deposited on the lung root. As a rule, infiltration is not homogeneous. Its borders are dim. The vessels and bronchi appear through infiltration. The sizes of infiltrations are various and depend on a degree of lung's damage; they can be lobar, segmental and bronchopulmonary. The primary complex is located in the top and middle lung segments more often. At dissolving the sub-pleural localization of infiltration more distinctly is visible.

**The primary complex has four stages of development:**

I stage – pneumonic (picture 16). On general view X-ray three components of a complex are visible:

1) the focus in lung tissue by the size 2-4 cm. in diameter or more, of oval or irregular form, various intensity (more often - average and even high), with an indistinct, obscure contour;

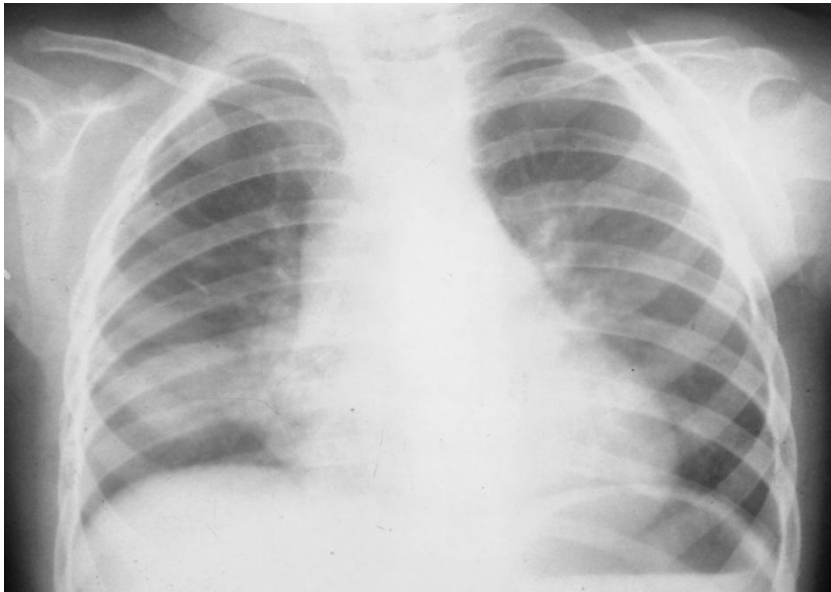


**Picture 16. Primary tuberculosis complex: 1 stage.**

2) the flow out to a root – lymphangitis, which is defined as linear tension bars from focus to the root;

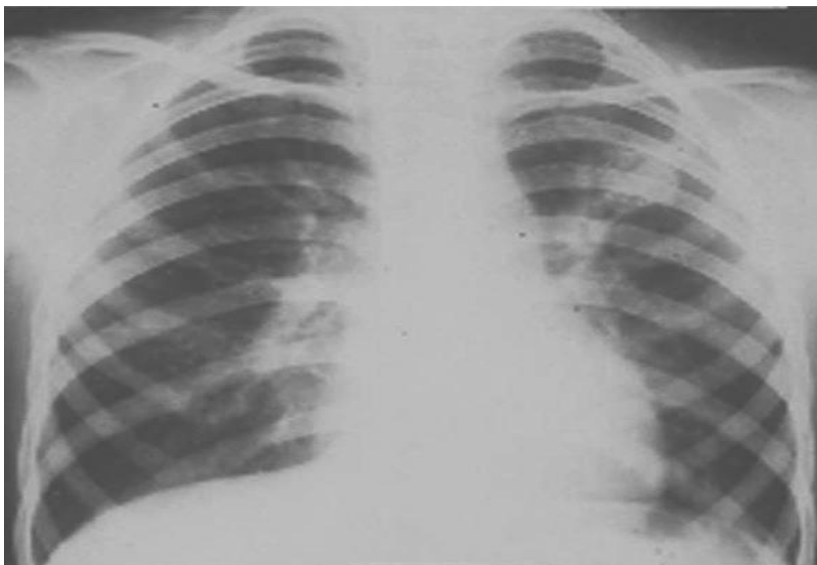
3) in a root – enlarged infiltrated lymphatic nodes. The root is represented to be extended, its structure is blurry, the intensity is increased. The contours outlining lymphatic nodes, or are dim, or more precisely depict the increased nodes.

II stage – resorption (picture 17). The size of the focus in lung tissue decreases, its intensity raises, the contours become precise. The flow out to a root and infiltration of lymphatic nodes decreases.



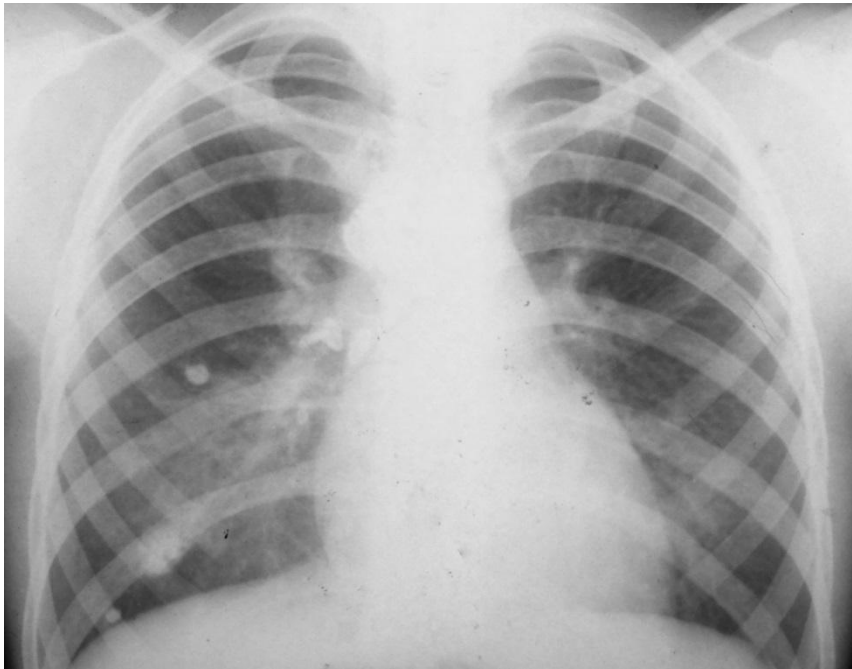
Picture 17. **Primary tuberculosis complex: 2 stage.**

III stage – condensation (picture 18). On a place of focus area remains with the size up to 1 cm, inside of it inclusions of calcinations appear as fine spots of sharp intensity. Same spots of calcinations are noticeable and in lymphatic nodes of the lung root. Thin tension bars are determined between the focus and the root.



Picture 18. **Primary tuberculosis complex: 3 stage.**

IV stage – calcination (picture 19). The focus in lung tissue becomes even smaller, more densely, of high intensity, with distinct contour, frequently rugged and rough. Calcinations are intensified also in root lymphatic nodes. Calcinations in certain cases are represented by solid, dense formations, in others - they have less intensive shadows of inclusions, which testify about incomplete calcifications of the focus and preservation of caseous regions in it.



**Picture 19. Primary tuberculosis complex: 4 stage.**

At favorable course of primary tuberculous complex with time calcification increases up to ossification at the place of former caseosis located in peripheral parts of lungs. This is Gohn's focus.

When primary complex is revealed in time and the patient receives valuable treatment, frequently could be achieved complete dissolution of pathological changes in lung tissue and in root, with complete restoration of their initial structure.

The greatest difficulties arise at diagnosing tubercular intoxication and small forms of lymphatic nodes tuberculosis. At absence on chest x-ray obvious pathological signs of lymphatic nodes high profile is given computer

tomography, allowing to visualize insignificantly increased lymphatic nodes and deposits of calcium salts.

**Primary tuberculosis complex complications:**

- Lung`s destruction;
- bronchial lesions,
- atelectasis development in other parts of the lungs,
- lymphogenous hematogenous dissemination,
- the transition to primary tuberculosis with chronic course.

**Primary tuberculosis complex differential diagnosis:**

- pneumonia,
- influenza,
- acute respiratory infections,
- indigestion,
- infectious diseases.

**3.2.2. Tuberculosis of intrathoracic lymphatic nodes.**

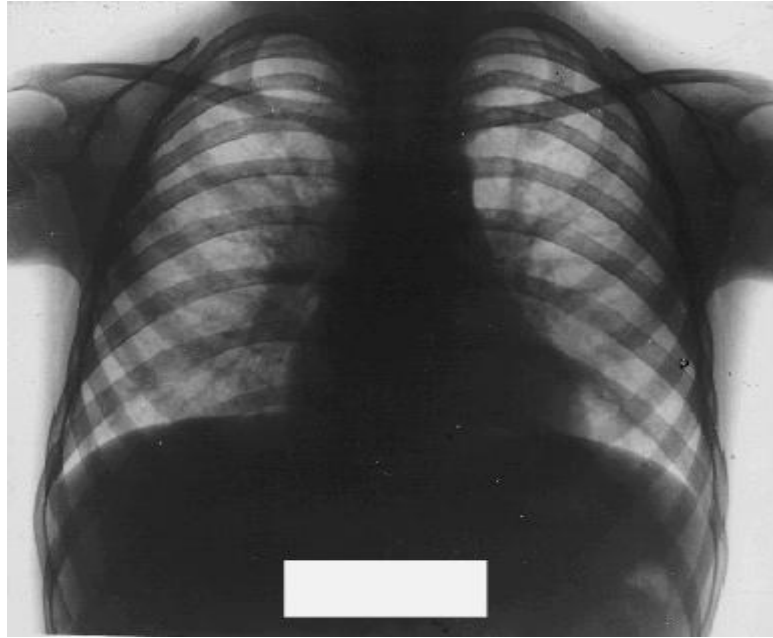
A tubercular disease of the lung root lymphatic nodes and mediastinum are named bronchoadenitis. Tuberculosis of intrathoracic lymph nodes is the result of tuberculosis primary infection of children, adolescents and young adults. Rarely it is the result of endogenous reactivation of tuberculosis changes that have occurred in the intrathoracic lymph nodes. Bronchoadenitis at tuberculosis are unilateral and bilateral. There are infiltrative, tumor-like and so-called "small" variations tuberculosis of intrathoracic lymph nodes.

**Infiltrative bronchoadenitis.** Infiltrative forms characterized not only by nodes increase, as well as the development of infiltrative changes in the surrounding lung tissue (picture 20). The clinical feature is intoxication signs domination.

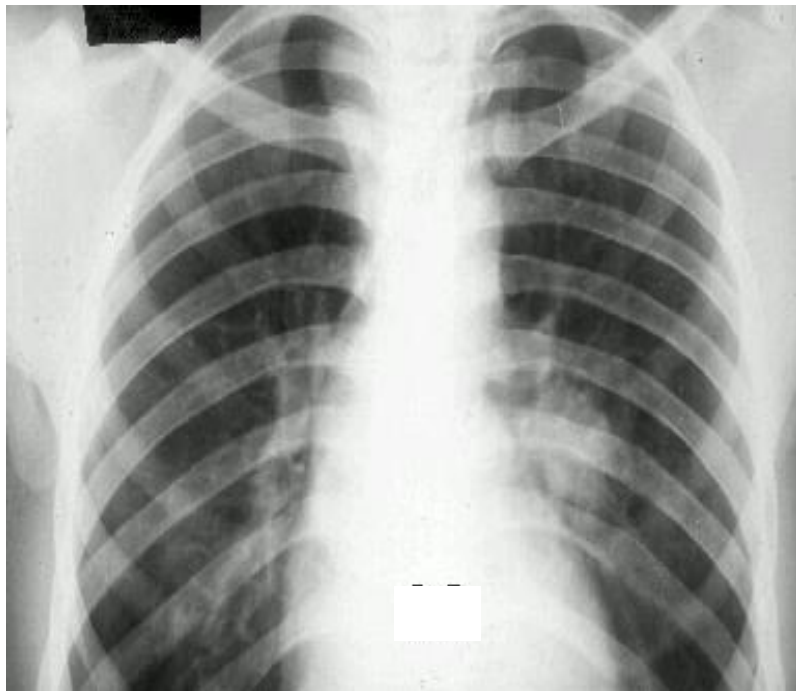
**Tumor-like bronchoadenitis.** Tumor-like tuberculosis of intra-thoracic lymph nodes is a variant of primary tuberculosis when the lymph nodes caseous prevails and when is increasing the size of some of the lymph nodes or their



groups, when expressed clinical manifestations and a penchant for complicated course (affecting the bronchi, bronchopulmonary lesions, bronchogenic, lymphogenic and hematogenous dissemination, pleurisy). The contours of the lymph nodes on radiographs and tomograms are clear (picture 21).



Picture 20. **Infiltrative tuberculosis bronchoadenitis.**



Picture 21. **Tumor-like tuberculosis bronchoadenitis.**

**"Small" tuberculosis variants** of intrathoracic lymph nodes are characterized by their low magnification. X-ray diagnostic of "small" variations of the disease is possible only by circumstantial evidence (reduced root shadow structure, dual contour of median shadow and enrichment lung pattern within the root zone in a limited area). A clinical manifestation is moderate intoxication.

In case of late detection and ineffective treatment transition to primary tuberculosis with chronic course possible, it characterized by long wavy course by polymorphism of morphological changes in lymph nodes (calcification, fibrotic and inflammatory changes together).

**Tuberculosis bronchoadenitis complications:**

- pleural inflammatory reaction,
- specific bronchial lesions with the development of segmental atelectasis or lung`s lobe atelectasis,
- dissemination to the lungs and other organs.

**Tuberculosis bronchoadenitis differential diagnosis:**

- anomalies and malformations, defect location the odd vein, congenital heart defects involving the expansion of the pulmonary artery, aortic aneurysm,
- nonspecific inflammatory processes: paravertebral pneumonia, acute childhood diseases (measles, whooping cough) disease of viral etiology (adenoviruses, influenza),
- granulomatosis(sarcoidosis),
- benign and malignant neo-formations: the central basal carcinoma, teratoma and dermoid cysts, hyperplasia of the thymus, retrosternal goiter, neurogenic tumors lymphogranulomatosis, lymphocytic leukemia, lymphosarcoma.

### **3.2.3. Tuberculosis without established localization (tuberculosis intoxication)**

Tuberculosis without established localization occurs in children infected with TB, and in cases of the primary TB infection development without local manifestations which is confirmed by X-ray and other methods. Tuberculous intoxication is manifested in children with newly positive reaction to the tuberculin that enhanced during the observation, as well as hyperergic reactions.

It is characterized by the activity of tuberculosis, which is manifested as general condition worsening, periodic subfebrile fever, appetite loss, the appearance of neurovegetative disorders (nervous excitement or depression, headache, tachycardia), a slight increase in the lymph nodes (mikro-poliadenitis) with peryadenitis symptoms, slight enlargement of the liver, rarely the spleen, cardiac physiological growth or deficiency of body weight, a tendency to intercurrent diseases, changes in the blood picture (slight acceleration of erythrocyte sedimentation rate, shift of neutrophils to the left, eosinophilia, lymphopenia) changes in immunological status (decrease in the number of T-lymphocytes and their functional activity).

The specificity of these functional disorders must be confirmed by a thorough examination of the child in order to exclude non-specific diseases.

TB of unknown localization does not mean the same as latent TB infection (LTBI) in children, because it's not tuberculosis, but only means that children infected with *Mycobacterium*. Manifestations of LTBI in children should consider all cases of positive tuberculin tests, including virage and hyperergic tuberculosis reaction.

The diagnosis of "tuberculosis without established localization (tuberculous intoxication in children)" should be established in exceptional cases where it is impossible to determine the localization of tuberculosis. However, always follows try to set the localization process, including the use computer tomography of suspicious localisations.

## 4. SECONDARY TUBERCULOSIS

### 4.1. Miliary tuberculosis

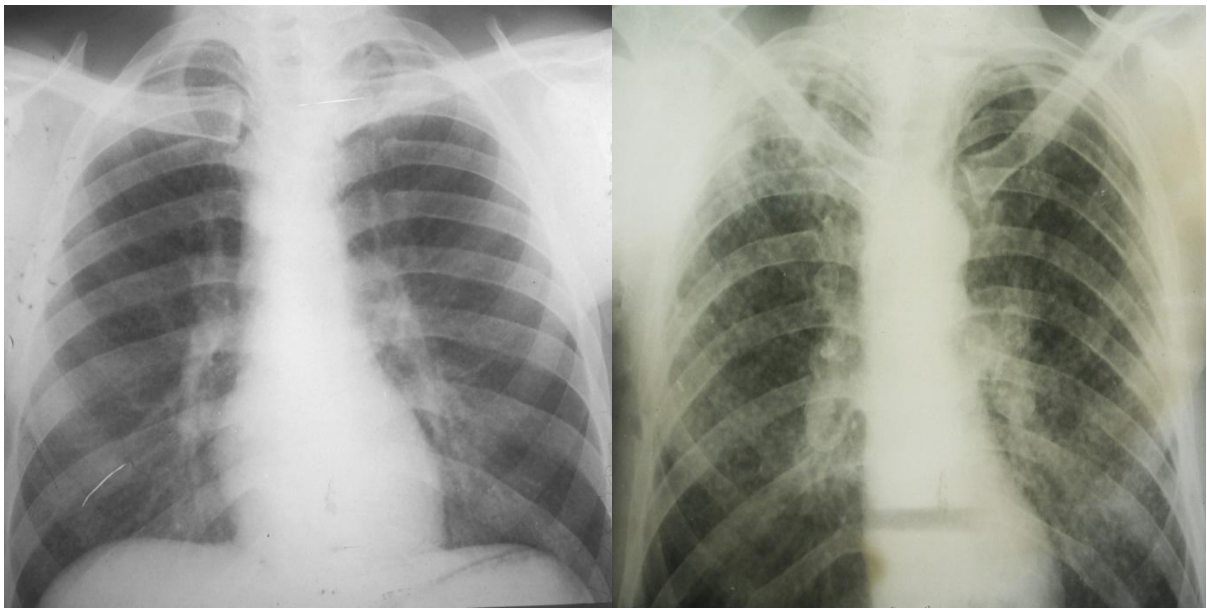
Miliary tuberculosis - hematogenous, almost always generalized tuberculosis, characterized by uniformly dense rash of small as millet grain, TB tubercles in the lungs. It is usually the generalized lesions formation in the lungs, liver, spleen, intestine, brain membranes. Rarely miliary tuberculosis lesions occur only as the lungs lesion.

All foci are mainly of exudative or productive nature. Infection also goes into systemic circulation with the formation of lesions in the lungs, liver, spleen, intestine, brain membranes in miliary tuberculosis cases.

Clinically miliary tuberculosis is divided into five types:

- 1) *Acute tuberculosis (miliary) sepsis* - areactive acute tuberculous sepsis. The patient's condition is extremely difficult. The disease occurs by type of septicemia. The clinical picture is similar to typhus-like form but occurs quickly with a severe intoxication, rapid dysfunction of organs and systems. Patients fainting. After a few days by the complete lack of defenses with negative tuberculin tests, leukopenia, agranulocytosis, death occurs.
- 2) *Acute miliary tuberculosis - typhus-like form*. In this form of acute miliary tuberculosis miliary tubercles are in almost all organs - lungs, heart, kidneys, serous membranes, liver and others. The main symptom is severe general condition of the patient. The disease begins suddenly, after moderate prodromal phenomena (fatigue, headache) and is accompanied by high body temperature to 40° C and above, which is remitting or hectic character, sweating, tachycardia, cyanosis moderate. Gradually these phenomena increase, dyspnea and signs of intoxication become the most difficult. Disturbed consciousness appears with the progression. Manifestations of affection of other organs and systems are not much expressed. Tympanic sound, signs of diffuse bronchitis of perifocal origin by percussion of the lungs is

determined, sometimes crackling determined by auscultation. There are too little sputum. In the early stages of the disease (the first 7-14 days) shadow could not be determined, but there is a general reduction of air in the lungs - a symptom of "web", then there are diffuse, evenly distributed, often along the vessels, small low-intensity shadows, mostly in diameter 1-2 mm appears, but when they merge it may be determined shadows to 5-10 mm (picture 22).



Picture 22. **Miliary tuberculosis.**

Leukopenia, lymphopenia, an-eosinophilia, agranulocytosis, sometimes anemia observed in blood. Tuberculin test may be negative because of anaergy.

- 3) *Acute miliary tuberculosis - meningeal form.* More often observed in children with primary tuberculosis, although occurs in adults. Severe symptoms of infection and intoxication. There are marked sharp headache, exacerbated with the least disturbance from the first days. Disturbed consciousness with increased intracranial pressure. Then symptoms of cranial nerve paresis and paralysis of the central type align, after hyperkinesia, speech disorder emerging.

- 4) *Acute miliary tuberculosis - pulmonary form.* It manifested with sharply increasing dyspnea, cyanosis, dry cough, tachycardia on a background of severe intoxication. There emphysema and pulmonary box-like percussion sound in the lungs. Auscultation determined weakened or hard breathing, sometimes dry and small bubblingwet wheezing. X-ray reveal a total dissemination of small low-intensity foci mostly with a diameter of 1-2 mm.
- 5) *Chronic miliary tuberculosis.* It has very poor clinical manifestations, they are often not noticeable for patient. Sometimes there is a periodic subfebrilitet, shortness of breath on exertion. Multiple miliary foci of varying intensity defined on radiographs of the lungs.

**Miliary tuberculosis differential diagnosis:**

- infectious diseases: typhoid, measles, sepsis, meningitis different etiology,
- malignant neoplasms: miliary carcinosis, lung cancer lymphangitis, lymphogranulomatosis,
- collagenoses: systemic lupus erythematosus, dermatomyositis, systemic sclerosis, polyarteritis nodosa, rheumatic fever,
- Wegener's granulomatosis, Goodpasture's syndrome, histiocytosis X.

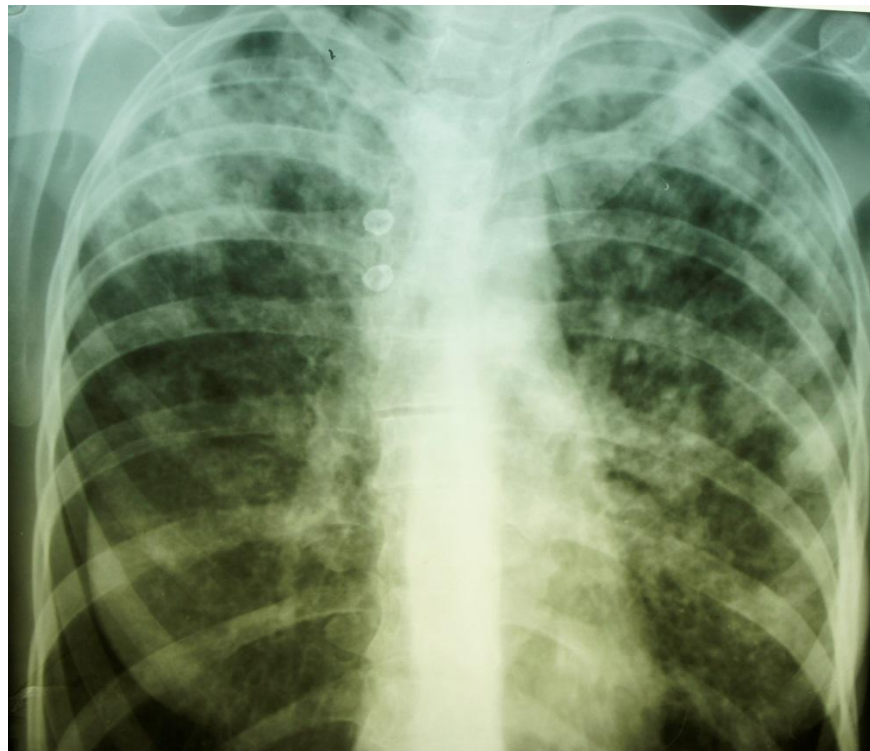
#### **4.2. Disseminated lung tuberculosis**

Disseminated tuberculosis –it is a clinical form of tuberculosis that is characterized by multiple, polymorphic, usually in both lungs, lesions of hematogenous, lymphogenous or mixed nature dissemination, various and productive relation of exudative inflammation, acute, subacute or chronic course.

Variants of disseminated tuberculosis are distinguished by pathogenesis and clinical features. Depending on the Mycobacterium tuberculosis spread it may be hematogenous and lymph-bronchiogenic disseminated tuberculosis. Both may be acute, subacute and chronic beginning of the disease.

Acute disseminated tuberculosis of haematogenous genesis is often manifested as miliary, which is isolated in individual clinical form.

Subacute disseminated tuberculosis develops slowly; it is characterized by severe symptoms of intoxication. In subacute disseminated tuberculosis of hematogenous genesis there is focal dissemination of the same type localized in the upper and cortical regions of the lungs. In cases of the lymphogenous genesis foci groups located in the basal and lower regions of the lungs on the background of significant lymphangitis with involvement in a process of deep and peripheral lymphatic network of the lungs (picture 23).



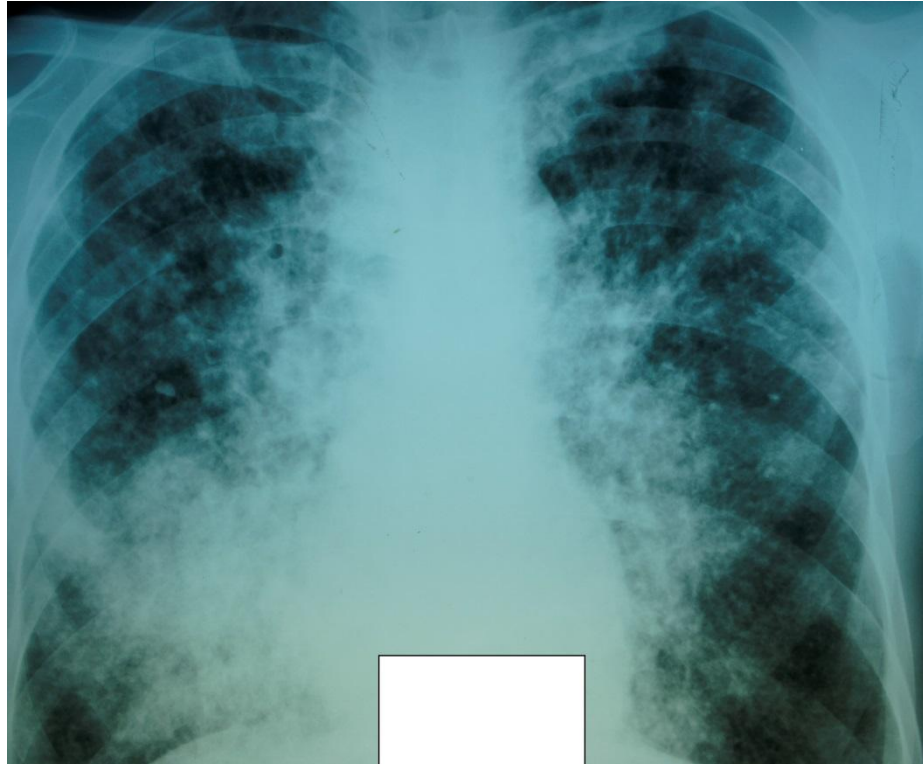Picture 23. **Subacute disseminated tuberculosis.**

Thin walled cavity with perifocal inflammation that detected poorly on the background of lesions with subacute disseminated tuberculosis can be formed. Cavens located on symmetric parts of the lungs often, these formations are called "stamped cavities."

Chronic disseminated tuberculosis most often has hematogenous genesis. It is characterized by apical-caudal process spreading. There are may be serial lesions of various organs and systems in the chronic form. Chronic disseminated

tuberculosis has a fluctuating course when intoxication symptoms partially extinguished in remission, while the the flash process they amplified. It may be pulmonary and extrapulmonary local lesions.

X-ray determined different sizes and densities foci. More dense foci are located in upper lungs parts (picture 24).



Picture 23. **Subacute disseminated tuberculosis.**

At any stage of the disease cavities can occur in one or in both lungs. Foci and destructive formations detect on the background of deformed lung pattern, pneumosclerosis, bronchiectasis and emphysema. Untimely recognized chronic disseminated tuberculosis, as well as ineffective treated for some time can move into fibro-cavernous pulmonary tuberculosis.

*Not should be considered as a manifestation of disseminated tuberculosis dissemination, formed as a result of bronchogenic dropouts from infiltration, which broken up; when fibro-cavernous pulmonary tuberculosis; in case of aspiration pneumonia after pulmonary bleeding; during lymph node caseous breaking through the bronchus, they should be defined as the phase of the concerned process.*



### **Disseminated tuberculosis differential diagnosis.**

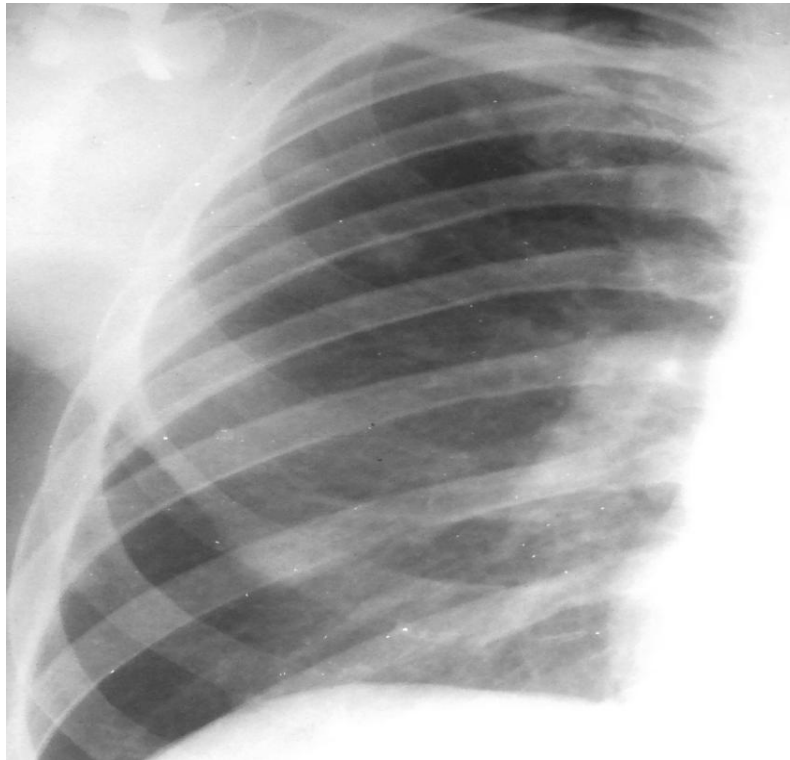
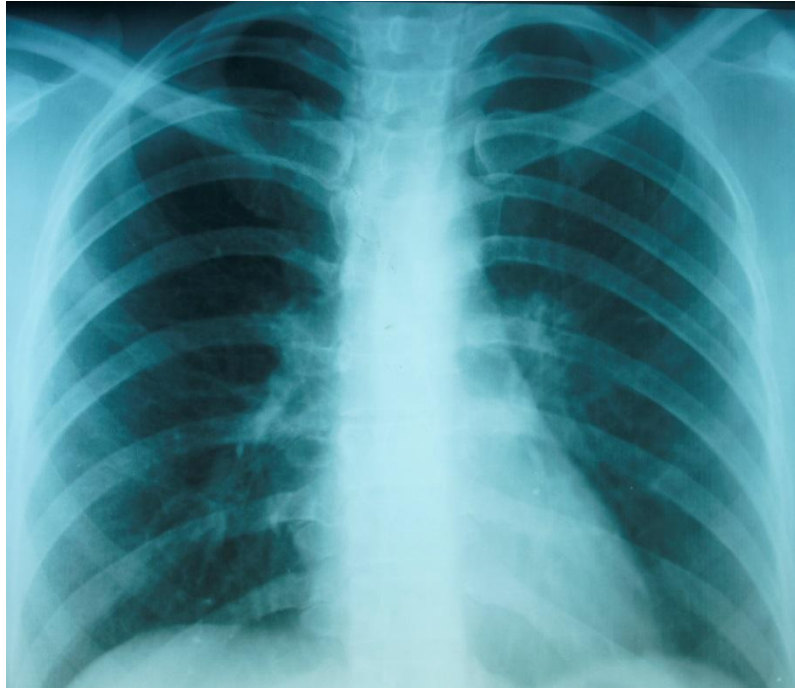
There are over than 200 diseases of different aetiology and genesis, accompanied symptom of "dissemination" in the lungs, pathognomonic clinical and radiographic signs that characterize them does not exist.

- miliary lung`s carcinomatosis, bronchoalveolar cancer, lung cancer lymphangitis,
- bacterial and viral pneumonia, eosinophilic pneumonia,
- sarcoidosis,
- lung collagenoses (systemic lupus erythematosus, dermatomyositis, systemic sclerosis, polyarteritis nodosa, rheumatoid arthritis, rheumatism),
- Wegener's granulomatosis,
- Goodpasture's syndrome,
- pneumoconiosis (silicosis, silicatosi, etc.),
- histiocytozom X,
- diffuse primary amyloidosis of the lungs, etc.

### **4.3. Focal (nidus) tuberculosis**

Focal pulmonary tuberculosis –it is a clinical form of tuberculosis, characterized by oligosymptomatic course and the availability different genesis and durability of existence small (up to 10 mm in diameter) mainly productive nature of the lesions within 1-2 segments in one or both lungs. Focal forms include both those that have recently emerged, acute (soft-focal) processes with foci up to 10 mm and older (fibro-focal) formations of pronounced signs of activity of the process.

**Acute focal tuberculosis** is characterized by focal soft shadows with slightly fuzzy edges (picture 24). If there are significant changes in perifocal lung tissue it should be defined as infiltrative pulmonary tuberculosis.



Picture 24. **Focal tuberculosis.**

**Fibrous-focal tuberculosis** manifested with the presence of dense foci sometimes with the inclusion of lime, fibrotic changes in the form of bands and areas of hyperventilation. During the exacerbation is also possible emergence of acute soft lesions. In nidus tuberculosis intoxication signs and "broncho-

pulmonary" symptoms usually occur in patients in exacerbation, in the phase of infiltration or disintegration.

### **Focal tuberculosis differential diagnosis.**

- inflammation processes: pneumonia, retention filled cysts,
- malignant tumors: a form of peripheral lung cancer, bronchioles-alveolar cancer,
- metastatic tumors: chorionepiteliomae, tumors of the kidneys,
- benign tumors: peripheral lung adenoma, hamarto-chondroma,
- parasitic lesions: focal form of alveolar echinococcosis,
- traumatic lesions: lung contusion,
- anomalies and malformations of cardiovascular origin: aneurysms of small branches of the pulmonary arteries, peripheral lung varicose veins.

## **4.4. Infiltrative tuberculosis**

Infiltrative tuberculosis of the lungs it is a specific exudative-pneumonic process stretching over 10 mm with a tendency to a progressive course. Clinical manifestations of infiltrative tuberculosis depend on the prevalence of infiltrative-inflammatory (perifocal and caseous necrotic) changes in the lungs. It is one of the most common forms of pulmonary tuberculosis (30-40%). In the pathogenesis and morphology of infiltrative pulmonary tuberculosis inflammatory and allergic reaction on a hyper-sensitization of lung tissue background plays a significant role.

Endogenous source of exacerbation infiltrate is encapsulated, calcified foci, multiple sclerosis and residual hematogenous seedings. Infiltration occurs as the progression of acute lesions if they were around of perifocal inflammation and they merged together.

Infiltrative pulmonary tuberculosis on a radiograph is determined by shade diameter over 10 mm, which has a number of features:

- Localization in 1, 2 or 6 segments (on the anteroposterior radiograph);

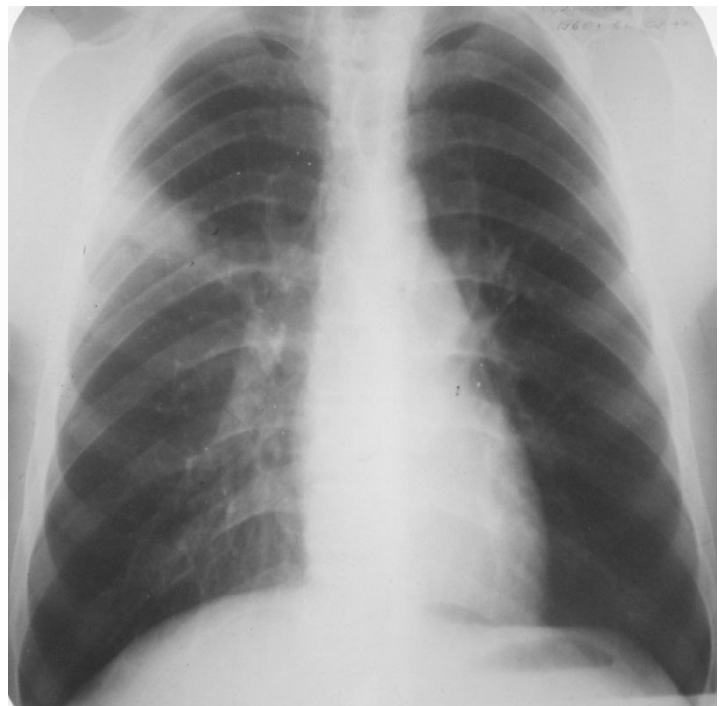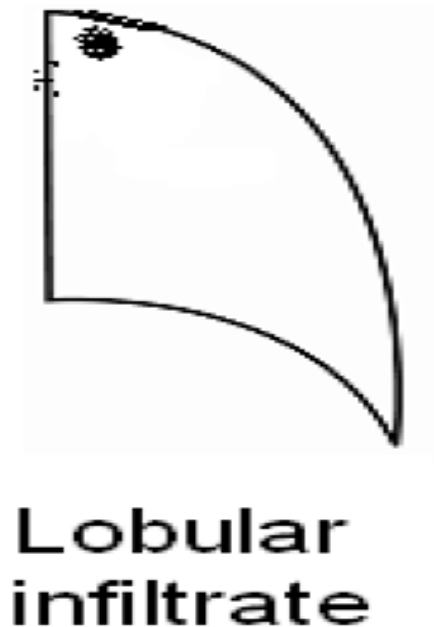
- Inhomogeneous structure due to intensive foci on the background or due to old fibro-focal formations around which developed infiltrate, or with cheesy tricks;

- Focal shadows with indistinct contours around the infiltrate in the same or other lung as a result of lymphogenous or bronchogenic dissemination;

- "Track" to the root as double bronchial walls strips from the infiltration - diagnosed with tuberculous infiltrate in a phase of decay.

There are such clinical and radiological variants of infiltrative pulmonary tuberculosis: lobular infiltrate, periscissuritis, cloud-like infiltrate, round infiltrate, lobar infiltrate.

**Lobular infiltrate.** It has asymptomatic or mild symptoms of intoxication, determined without physical changes and bacterial excretion. Radiologically it is characterized by the presence of focus diameter of 1 to 3 cm in I or II lung's segments, limited, improperly stretched towards the root. External contours of infiltrate are unclear. It seems to be consisting of several large acute foci that have merged (picture 25).



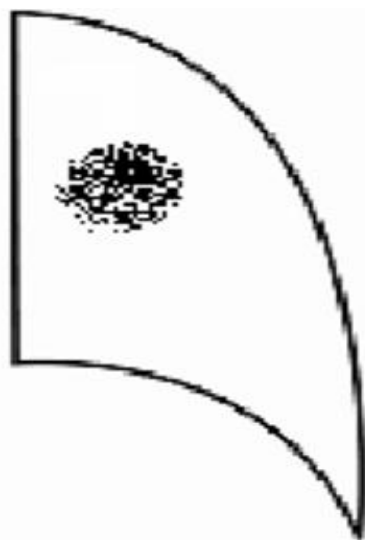
Picture 25. **Lobular infiltrate.**

**Round infiltrate.** Disease begins acutely looks like pneumonia, flu or fever of unknown etiology. Sometimes the first clinical manifestation of the disease is hemoptysis or pulmonary hemorrhage. Rounded infiltration manifested not strongly defined intoxication syndrome - general weakness, malaise, increased fatigue, sweating and subfebrile temperature.

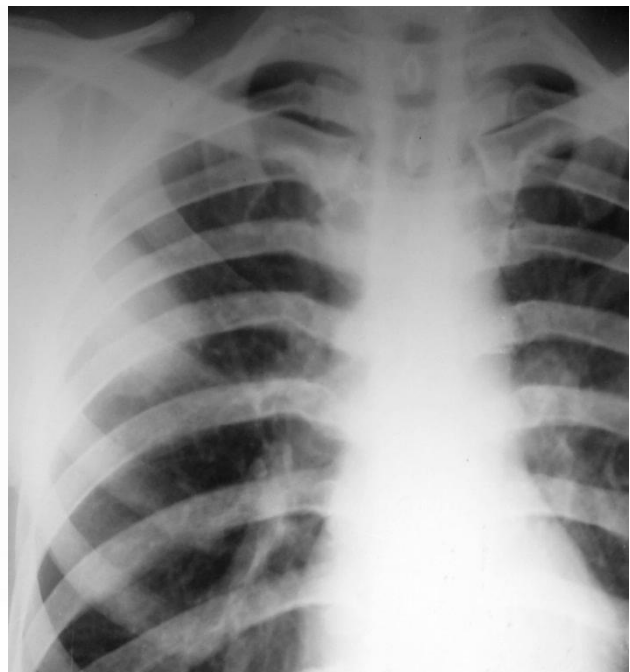Almost half of the patients it occurs covertly and not accompanied by general and local disorders symptoms. In this case the process determined mainly by preventive x-ray. Most often hidden or oligosymptomatic beginning of disease occurs in 18-25 years aged people. The general condition of these patients is mainly passable. Physical changes in the lungs often absent or poorly defined.

Moderate leukocytosis, increasing the number of band neutrophils, lymphopenia, increased ESR in hemogram in the initial phase of the disease observed. In 1/2 cases *Mycobacterium tuberculosis* in sputum and bronchial washed water defined. Sometimes there are elastic fibers, cholesterol crystals, lime both of mycobacteria in the sputum or bronchial washed water.

Radiologically this type infiltrate looks without clear contours, irregular round or oval, 1.5-2.5 cm in diameter or more (picture 26).



Round infiltrate

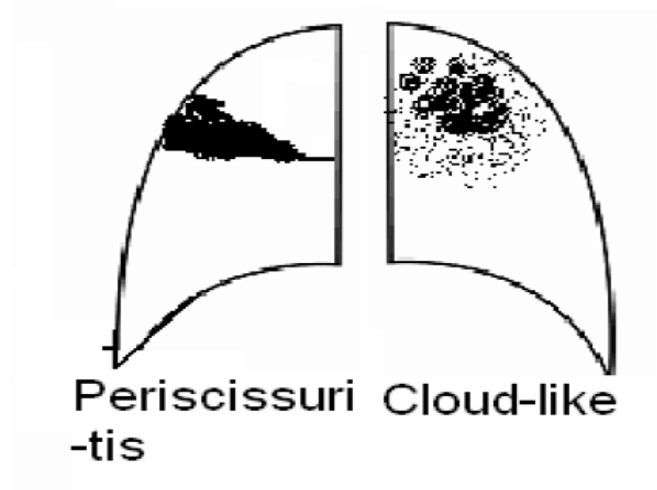


Picture 26. **Round infiltrate.**

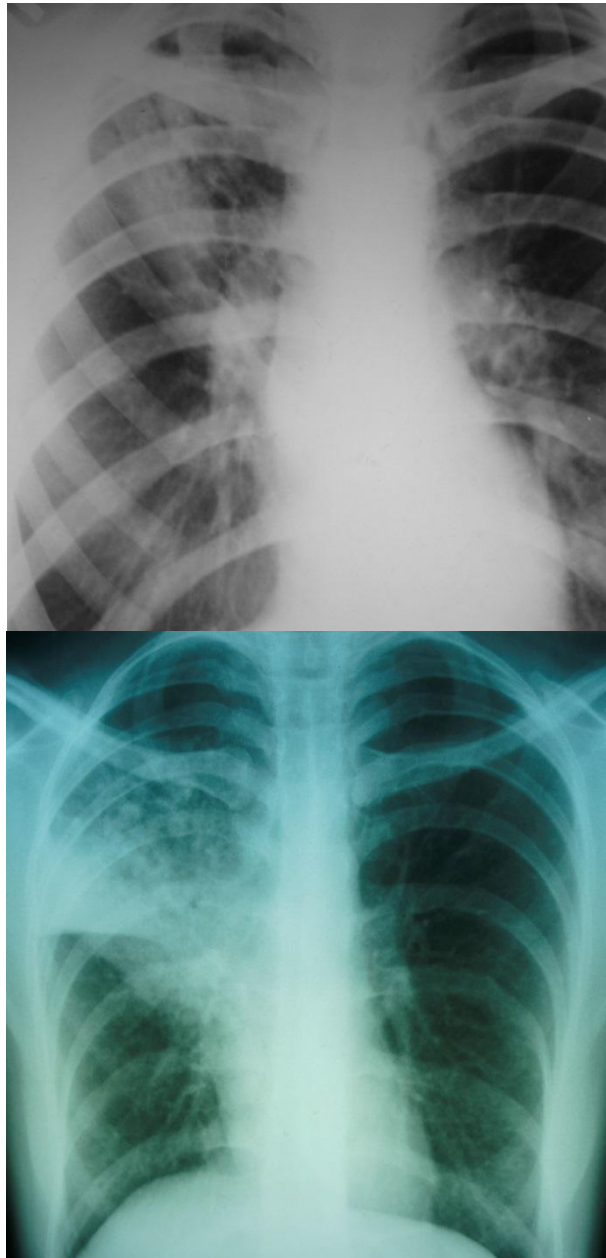
It located in the I, II, VI segments of the lungs. Inflammatory "track" get away from it to root of the lung. Bronchopneumonia on its background is often defined. More dense or calcified foci, small areas of decay, bands and scar formation, pleural changes by tomographic investigation of infiltrates can be detected that allowing clarify the pathogenesis and pathologic substrate infiltration.

If the disease progresses, the intoxication symptoms appear and grow, increased cough with sputum, haemoptysis or bleeding occurs, dulling becomes more intense and catarrhal changes zone in the lungs become more widespread. Leukocytosis, increasing the number of band neutrophils is noted. Increase of perifocal inflammation and signs of decay with the formation of cavities determined radiologically. The cavity becomes oval or rounded zone of perifocal inflammation on the periphery. Due to bronchial seeding in different parts of the lungs solitary or numerous foci appear.

**Cloud-like infiltrate and periscissuritis.** Radiologically it looks like irregular blackout without clear boundaries. The process is localized in one or two segments, often localized in the upper lobe, but lately lower-partial localization of process often marked that looks like a nonspecific focal pneumonia. Infiltration, localized along the interparticle gap, and sometimes is associated with the root of the lung, has a clear, smooth contour, defined as periscissuritis (pictures 27-28).



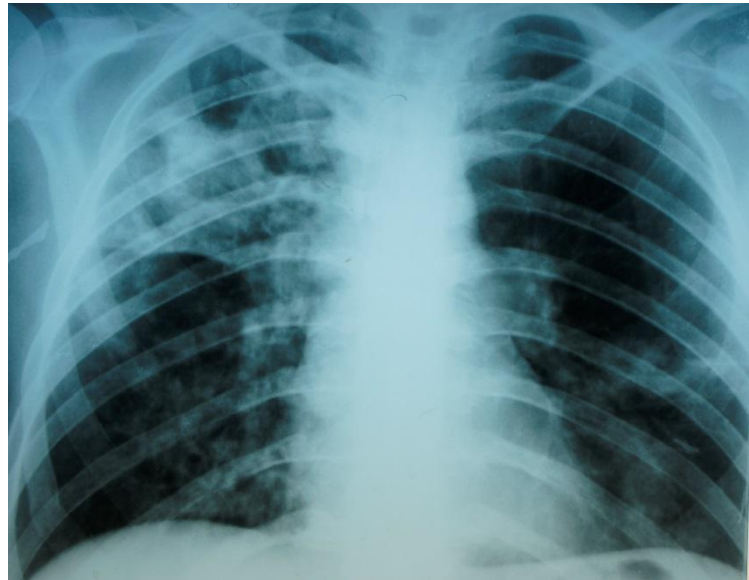

Picture 27. Scheme of cloud-like infiltrate and periscissuritis.



Picture 28. **X-rays of cloud-like infiltrate and periscissuritis.**

The top is directed to the root of the lung, and the base - on the outside. It's line that passes through interparticle pleura, clear, and opposite is blurred and transitions without sharp contour to a little changed lung tissue. In tomogram on the infiltrative changes background reveal single or numerous foci of dense shadow, strands of compacted peribronchial and perivascular connective tissue, destructions.

**Lobar infiltrate** covers all or most of the lung's lobe (picture 29).



Picture 29. **Lobar infiltrate.**

Depending on the process localization X-ray picture of lobar infiltrate is different. If upper lobe of the right lung affected wedge shadow with apex at the lungs root and a broad base in the lateral section on anteroposterior radiographs defined. Middle-lobe process appears as a triangle with a broad base in the mediastinum and the apex directed to the outside. Infiltration shadow in the middle lobe in the lateral projection looks like a triangle with wedge apex in the lung's root. Lobar shadow of the right lower lobe in direct projection usually has blurred the external boundary that adjacent it's broad base to the lower part of mediastinum and diaphragm and connects with the root of the lung. Lobar infiltrate in some cases is likely to intensify a complete blackout (homogeneous lobar infiltrate); in others – there are centrally located massive consolidation and foci in the lung tissue, with single cavity decay often; in the third - in the area of consolidation appears many small cavities in tomography.

There are small intoxication and broncho-pulmonary symptoms in 1/2 cloud-like infiltrate cases, 50 % patients have no clinical signs.

Clinically periscissuritis and lobar infiltrate mainly characterized by acute manifestation, severe symptoms of intoxication and high fever. Bronchial



breathing, wet small- or medium-bubble wheezing in lobar infiltrate cases are determined.

Leukocytosis, lymphopenia, eosinopenia appears in the blood. In massive infiltrative process in lungs cases tuberculin reaction mostly normo-ergic, at least hyperergic, that indicating a dissociation between general and local sensitivity of lung tissue.

#### **Infiltrative tuberculosis differential diagnosis.**

- pneumonia of different nature: lobar, Friedlander's, staphylococcal, virus, mycoplasmal, legionellas and other,
- lung`ssyphilis,
- malignant tumors: pneumonia-like form of lung cancer,
- allergic processes: volatile pulmonary eosinophilic infiltration,
- fungi lesions: aspergillosis pneumonia, actinomycosis, candidiasis,
- histoplasmosis, cryptococcosis, coccidia-mycosis of lungs,
- vascular lesions: pulmonary infarction.

#### **4.5. Caseous pneumonia**

Caseous pneumonia is a specific acute pneumonia, which is characterized by rapidly growing caseous-necrotic changes and severe course, often rapidly progressive, leading to fatal outcome. Caseous pneumonia often occurs on the background of old TB lesions, foci and sclerosis, mostly occurs in young age patients with immunobiological resistance failure or in elderly people in sharply reduced reactivity. Following risk factors contribute to the development of caseous pneumonia - deep malnutrition with exhaustion, diabetes, massive infection of highly virulent *Mycobacterium tuberculosis*. The disease is characterized by acute manifestation of high fever and rapidly increasing symptoms of intoxication. It looks like croupous pneumonia in the initial period.

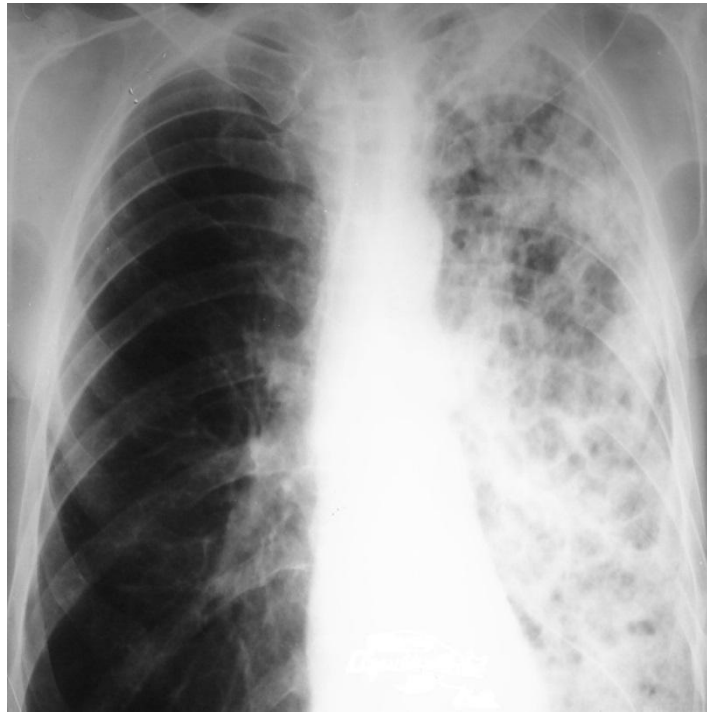Caseous pneumonia characterized by the predominance of caseous changes over perifocal inflammation. Thus there acinar, lobular or lobar pneumonia may develop. Rich in protein fluid accumulated in the alveoli,

with the increased number of phagocytes, white blood cells and fibrin. The lung's lobe in this place is exposed to rapid necrosis cheesy. Caseous necrosis and further rejection of cheesy masses leads to the formation of multiple cavities or giant cavern of decay that occupies the entire lobe.

An important role in the pathogenesis plays severe immune deficiency, characterized by deep structural and metabolic changes and apoptosis of immune cells. These specific inflammation cells can not resist the excessive microbial load, as a little functionally active and are not viable, so they rapidly and in great numbers destroyed, creating conditions for rapid and massive multiplication of *Mycobacterium tuberculosis*.

Patients complain of chest pain, shortness of breath cough with a sputum. Cyanosis of the lips, acrocyanosis and cutting tachycardia determined. A significant dulling or dull percussion sound of the affected lung section is determined by percussion. There are significant number of mixed wet wheeze on the background a much weakened breathing or amphora breathing, listen over a large area caverns by auscultation. There are significant changes in the hemogram of toxic nature. Tuberculin tests are poorly defined or negative. Caseous pneumonia characterized massive bacterial excretion.

Caseous pneumonia lesions occupy at least two lobes of the lungs, but bilateral lesions often noted. Caseous pneumonia radiographically looks like irregular and often diffuse blackout large areas without significant changes in its volume at the beginning. It is possible to detect some more dense foci, projections of bronchi, areas enlightenment arising out of rapid decay of cheesy masses in some places. Complete homogeneous blackout due particularly the associated atelectasis. X-ray may also detect disseminated and confluent large solitary infiltrates, often with irregular, blurred contours in which in the future, with the rapid dilution of cheesy masses formed a giant cavities or a large number of small cavities (picture 30).



Picture 30. **Caseous pneumonia.**

#### **Caseous pneumonia differential diagnosis.**

- pneumonia of different nature: lobar, Friedlander's, staphylococcal, virus, mycoplasmal, legionellas and other,
- gangrene of the lungs,
- lung`ssyphilis,
- malignant tumors: pneumonia-like form of lung cancer,
- fungi lesions: aspergillosis pneumonia, actinomycosis, candidiasis,
- histoplasmosis, cryptococcosis, coccidia-mycosis of lungs,
- vascular lesions: pulmonary infarction,
- atelectasis of different etiology.

#### **4.6. Tuberculoma**

It is clinical form of pulmonary tuberculosis, unifying substrates of different origin, which is characterized by rounded caseous formation in the lungs more than 1 cm in diameter, surrounded by granulation and fibrous tissue

and mainly productive nature of the inflammatory response. Tuberculoma may be single and multiple. There also small (up to 2 cm in diameter), medium (2-4 cm) and large (more than 4 cm in diameter) tuberculomas.

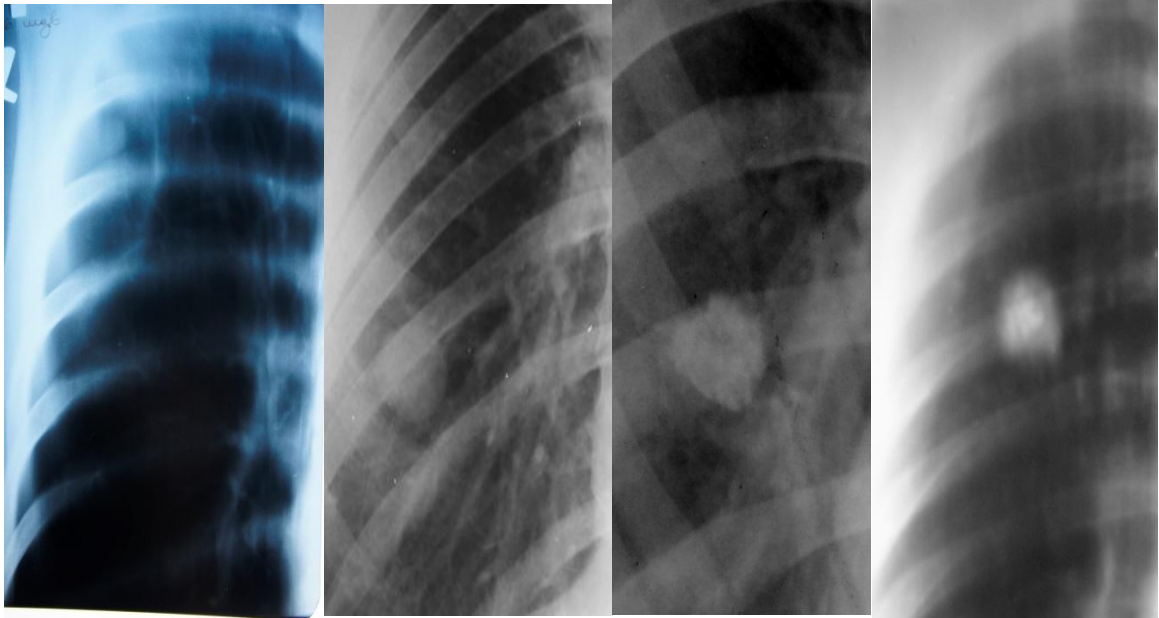
There are 5 types of tuberculomas:

- 1) Homogeneous - product of involution infiltrative tuberculosis, if perifocal inflammation resorbed and around the infiltrate consisting of caseous necrosis and granulation tissue capsule is formed.
- 2) Infiltrative-pneumonic type - product of tuberculous infiltration involution and represents as specific pneumonia rounded focus of limited areas of caseous necrosis with a tendency to productive reaction.
- 3) Conglomerate type - formed by multiple foci and (or) tuberculomas merging.
- 4) Layered - formed by the sharpening of old TB lesions and the gradual achievement tuberculoma's size or because of a single or multiple homogeneous tuberculoma sharpening with following stabilization of the process.
- 5) Pseudo-tuberculoma (blocked cavity) - a formation similar to tuberculoma that can be formed because of disturbed bronchi passability through cavities and as a result of filled cavity with cheesy masses, lymph, cellular elements.

Clinical and radiographic signs of pulmonary tuberculoma are oligosymptomatic, depending on the version of the course. It may be a cough, sputum discharge, fatigue, weight loss, subfebrilitet in tuberculoma patients. Pain in the chest can occur when the peripheral location tuberculomas and associated with pleura involvement in the process, pain is often acute, compounded with a deep breath, but comparatively quickly passed.

There is rounded shadow with clear contours on X-ray. Important role in tuberculomas diagnostics and phase of their activity plays a dynamic of X-ray observations. X-ray picture depends on pathologic tuberculomas structure,

appearance, age and process phase. Tuberculoma that recently emerged and if small size has more homogeneous character and a rounded shape (picture 31). With significant disease duration and large tuberculomas sizes their form often irregularly rounded or oval with heterogeneous structure.



Picture 31. **Tuberculomas.**

In such cases, on tuberculoma periphery, different sizes calcified inclusion of more dense often detected. Tuberculoma mainly localized in the cortical regions of the lungs, often in I, II and VI segments. This causes rapid pleura involvement in process, there are usually pleura-pulmonary scars, costal pleura consolidations at tuberculomas.

There are different sizes foci and fibrotic changes not far from tuberculoma (in 80% cases). In addition, in cases of homogeneous tuberculoma in the intercostal space may note symptoms of compression parallel to the near rib. An important radiological sign of pulmonary tuberculoma is a feature of the of its shadow structure. Some inclusions of calcified foci may be observed in the focus, which are caused by fibrosis and hyalinosis or conversely, areas of enlightenment associated with cheesy masses melting and focus disintegration.

The cavities formed in tuberculoma, have their own characteristics: they are irregular shapes are defined as small marginal areas of a crescent enlightenment, like a slit forms. Cavities are eccentric, often they are near

draining bronchus orifice; sometimes they contain sequestration-like inclusion and calcifications. If conglomerate tuberculoma there are multiple decay of small-focal character, these small cavities confluence of forming one large, centrally located cavity. When tuberculoma disintegrates, there are get away "track" to the root of the lung, which is formed by perivascular and peribronchial inflammation and viewed as pair strip of draining bronchus.

*In comparison with cavity tuberculoma's decay has extensive thickness wall with diameter more than diameter of decay. Further, as caseous mass resorption and tuberculoma emptying, it turns into a cavern, which wall is tuberculoma's capsule.*

Mycobacterium tuberculosis can be determined in the sputum of patients with lung tuberculoma in numerous studies. Changes may be missing in blood, even at tuberculoma's progression. However, often there is a small increase of band neutrophils, moderate lymphocytosis and slight acceleration of ESR.

### **Tuberculoma's clinical course.**

**Progressive**, in which at some stage of the disease decay, perifocal inflammation around tuberculoma, bronchogenic seeding of the lung tissue that surrounds tuberculoma are formed.

**Stable**, when absence of radiographic changes during monitoring of patients.

**Retrogressive**, when rare sharpening, with no signs of tuberculoma's increase, that the contrast is characterized by its slow decrease with subsequent foci formation in place tuberculoma (of foci group), fibrosis or a combination of these changes.

### **Tuberculoma's differential diagnosis.**

- nonspecific inflammations: rounded pneumonia, lung abscess, bronchogenic cysts of lungs;
- malignant tumors: a peripheral form of lung cancer, especially at an early stage, nodular form of broncho-alveolar cancer, sarcoma,

- benign tumors: hamarto-chondroma, peripheral lung adenoma,
- parasitic diseases: echinococcus cyst,
- a fungal diseases: aspergilloma,
- anomalies and malformations of blood vessels of the lungs: arteriovenous lungs aneurysm.

#### **4.7. Fibrous-cavernous tuberculosis**

Fibrous-cavernous pulmonary tuberculosis is characterized by fibrous cavities, the development of fibrosis in the lung tissue, foci of bronchogenic dropout of different age in the same and/or opposite lung, with permanent or periodic bacterioexcretion, with chronic wavy, usually progressive course.

At fibrous-cavernous tuberculosis draining cavity bronchi often affected, there are other morphological changes in the lungs, fibrosis, emphysema and bronchiectasis. Fibrous-cavernous pulmonary tuberculosis is caused by progression of the infiltrative pulmonary and disseminated tuberculosis, caseous pneumonia, tuberculomas, primary tuberculosis complex and etc. The prevalence of changes in the lungs may be different; the process is one-sided or two-sided with the presence of one or many cavities.

Fibro-cavernous pulmonary tuberculosis cavity wall consists of 3 layers. *Inner layer* - pyogenic, contains weight cheese necrosis, pus, mucus, a significant number of *Mycobacterium tuberculosis*. The *middle layer* consists of a specific granulation tissue. When unfavorable course of tuberculosis granulation may convert to pyogenic layer. Granulation can be converted and into fibrous tissue. *External layer* is fibrous, which gradually transforms into healthy lung tissue. During sharpening of tuberculosis around the cavity there is a zone of perifocal inflammation.

The cavity has the spherical or ellipsoidal form in most cases. It's presented as ring-like shadow. The thickness of the wall cavity is caused by fibrous capsule and perifocal inflammation. Cavity combined with bronchial tubes through which sputum goes away. In case of bronchi drainage function

disturbance fluid accumulated in the cavity. Horizontal level appears on the radiograph.

Clinical manifestations of fibro-cavernous tuberculosis are very varied. Patients suffered from intoxication and lung complaints, the intensity of which depends on course of the process. They are caused not only tuberculosis, as well as changes in lung tissue around the cavity, complications that developed. Intensification of voice by palpation is determined in these patients. The reduction of lung's sound over cavities by percussion determined in most cases, over large cavern there tympanitis. Bronchial breathing and wet wheezing over the cavity can be listening, in a limited area - over large cavities amphora breathing can be listening by auscultation.

There are 3 variants of clinical course of fibro-cavernous pulmonary tuberculosis:

- 1) limited and relatively stable, when through chemotherapy following some process stabilization and exacerbation can be absent for several years;
- 2) progressive fibro-cavernous tuberculosis, characterized by exacerbations and remissions changes, the periods between them can be short or long, in acute inflammation there are new areas with the emergence of more cavities, sometimes there is total destruction of the lungs;
- 3) in some not effectively treated patients progressive course concludes with caseous pneumonia; fibro-cavernous tuberculosis with the presence of various complications (pulmonary heart disease, amyloidosis, recurrent hemoptysis and pulmonary hemorrhage, exacerbated by non-specific infection (bacterial and fungal).

***X-ray features*** of fibrous-cavernous tuberculosis:

1. The presence of thick, sometimes deformed ring-like shadows with clear internal contours surrounded by fibrous strands and during exacerbations the process –by infiltrative zone.



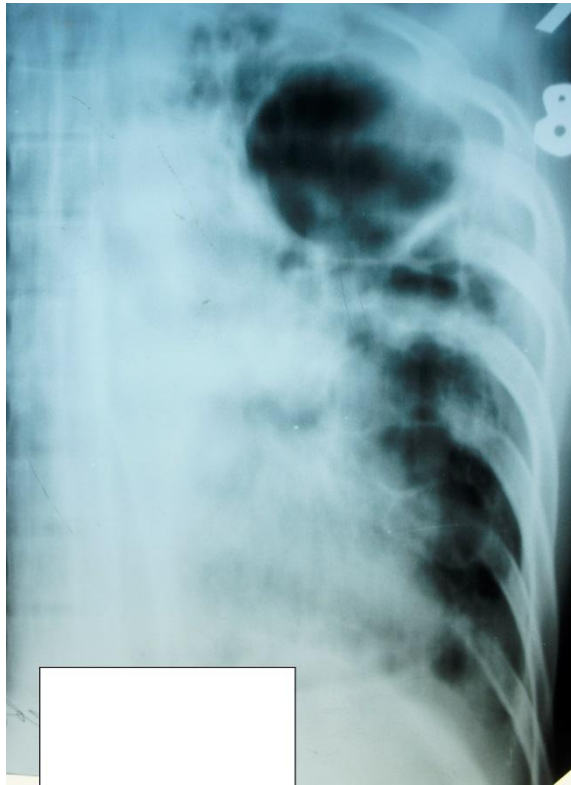2. The roots of the lungs deformed.
3. Intercostal spaces are narrowed.
4. The old cavern usually is located in the upper lungs. Below, in the same or other lung there are focal or infiltrative shadows (the result of bronchogenic dissemination), which can be in the center of enlightenment irregular due to decay.

Depending on the severity of inflammatory changes in the wall cavity, its thickness and contours character distinguish such cavities: pneumonic, flexible, rigid and fibrous.

Pneumonic cavity formed from the infiltration with destructions and has very precise internal and indistinct external contours. Cavity wall thickness depends on the area of infiltration and perifocal inflammation.

Flexible cavity formed of pneumonic at a favorable disease course when there is a further reduction of caseous mass and perifocal infiltration decrease. The wall thickness of the cavity is decreased, and the contours become clearer.

Further regression process with good drainage function of bronchi can go towards forming a cavity that is granulated, followed by the formation of stellate or linear scar or a small fire. In case of drainage function of bronchi disturbance, occlusion of its cheesy masses or as a result of inflammatory bronchial stenosis occurs valve mechanism and cavity inflated, increasing in size. The thickness of the wall decreases (picture 32).



Picture 32. **Fibrous-cavernous tuberculosis.**

If fibro-cavernous process was the result of disseminated pulmonary tuberculosis, the process saves certain symmetry: thick ring-like shadows of old cavities placed symmetrically in fibro modified upper parts of the lungs. Below varying intensity foci are determined, pulled up roots ("branches weeping willows"). The lower parts of the lungs increased brightness, emphysematous.

#### **Fibrous-cavernous tuberculosis differential diagnosis.**

- non-specific and specific inflammation: lung abscess, lung cysts with manure, syphilitic gum,
- malignant processes: cavitary form of peripheral lung cancer, lymphogranulomatosis,
- fungal diseases: aspergilloma, candidiasis,
- degenerative processes: III stage of dust pneumoconiosis.

#### **4.8. Cirrhotic tuberculosis.**

Cirrhotic tuberculosis is characterized by significant growth of scar tissue, among which active tuberculous lesions remain, causing periodic exacerbation and possible miserable bacterial excretion. Cirrhotic tuberculosis may be segmental and lobar, limited and disseminated, single- and double-sided, it is characterized by the development of bronchiectasis, emphysema, there are symptoms of pulmonary and cardiopulmonary failure in cirrhotic tuberculosis.

Cirrhotic changes, established in cases with presence of fibrous cavity bronchogenic seeding and repeated prolonged bacterioexcretion, is classified as fibro-cavernous tuberculosis. From cirrhotic tuberculosis must be distinguished cirrhosis of the lungs, which are after-tuberculosis changes with no signs of activity. Cirrhosis of lung attributed to residual changes after clinical recovery.

Cirrhotic tuberculosis characterized by the development of connective tissue in the lung and pleura resulting of fibro-cavernous, chronic disseminated, massive infiltrative pulmonary tuberculosis, pleura lesions, tuberculosis of intrathoracic lymph nodes complicated with bronchopulmonary lesions involution.

Cirrhotic changed lobe is reduced in volume, pleura over it thickened. Connective tissue consolidation of lung tissues changed position and structure of the bronchi and blood vessels of the lungs. Bronchi not only change their position, but become deformed, so that may be bronchiectasis. Small vessels partly clogged in the affected area, and sometimes expanded, which causes frequent bleeding. Position of the mediastinum changed dramatically: mediastinal organs pulled to the side of cirrhotic changed lung.

So, cirrhotic tuberculosis include processes with saved tuberculosis lung abnormalities with clinical manifestations of process activity, susceptibility to periodic exacerbations with miserable bacterial excretion.

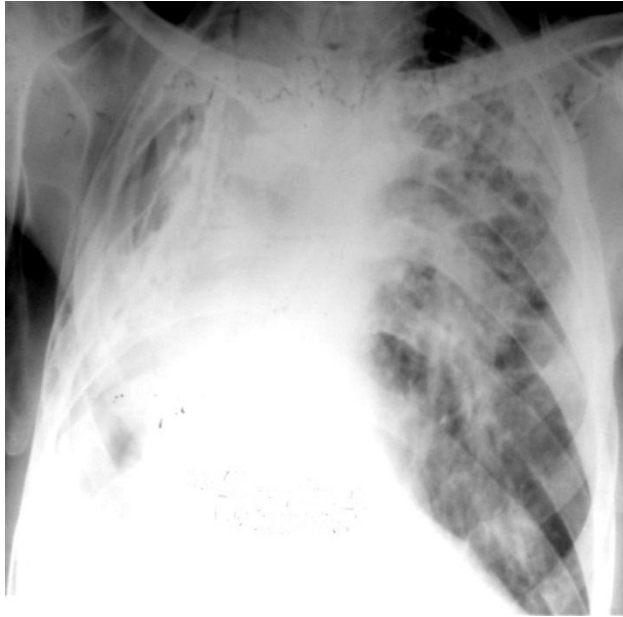
Cirrhotic tuberculosis may be segmental and lobar, limited and disseminated, unilateral and bilateral; it is characterized by the development of bronchiectasis, emphysema and has symptoms of pulmonary and cardiopulmonary failure.

In patients with cirrhotic pulmonary tuberculosis mostly observed such complaints: shortness of breath, cough with sputum, chest pain, intoxication complaints that mostly moderate. There is lagging chest when breathing because of lung on the side of cirrhotic process shrinkage, hemi-thorax reduction in the volume, ribs standing is horizontal and intercostal spaces decrease, mediastinum shifts to the more affected side, there are deformations of bronchi and bronchiectasis. Intensification voice trembling over cirrhotic changed parts of the lungs determined by palpation, dullness – by percussion, significantly weakened breathing, and dry "squeaky" wheezing – by auscultation.

Radiographic signs of cirrhotic tuberculosis are intensive blackout because of pneumosclerosis, on it`s background there bands from the roots to the peripheral regions of the lungs due to a significant proliferation of connective tissue structures, decrease hemi-thorax in the volume, shift of the mediastinum in the more affected side, deformation roots of the lungs and bronchi (picture 33).

**Cirrhotic tuberculosis differential diagnosis.**

- meta-pneumonic pneumosclerosis, pneumo-cirrhosis,
- siliko-tuberculosis, silicosis and other pneumoconiosis,
- respiratory sarcoidosis of stage III,
- fibrosing alveolitis of,
- atelectasis of different genesis: adenoma of the bronchus,



**Picture 33. Cirrhotic tuberculosis.**

- agenesis, aplasia, hypoplasia of the lungs,
- progressive interstitial fibrosis: Hamman-Rich disease,
- encysted pleurisy,
- fibrothorax after pneumonectomy.

## 5. EXTRAPULMONARY TUBERCULOSIS

### 5.1. Tuberculosis of meninges and central nervous system

Tuberculosis of meninges and the central nervous system (CNS) begins from the moment of haematogenic dissemination of mycobacterium tuberculosis (MBT) to the nervous system and structures surrounding the brain or spinal cord and causing meningitis.

In the largest prospective epidemiological study on CNS tuberculosis, the chance of developing CNS tuberculosis was 1,0% among tuberculosis cases from 1970 to 2001 in a Canadian cohort.

Several *risk factors for CNS tuberculosis* have been identified:

- children and HIV-coinfected patients,
- malnutrition,
- recent measles in children,
- alcoholism,
- malignancies,
- the use of immunosuppressive agents in adults.

Studies conducted in developed countries have also identified that foreign-born individuals (individuals born outside of developed countries) are overrepresented among CNS tuberculosis cases.

CNS tuberculosis accounted for 3,2% of tuberculosis deaths in 1993 (Spain), a rate that had steadily declined over the previous 20 years. In a large study in Taiwan, 1,5% of tuberculosis deaths between 1997 and 2001 were attributable to CNS disease, a percentage that had increased from previous years.

**Pathogenesis of CNS tuberculosis.** Prior to the actual containment of the infection, bacilli are filtered into draining lymph nodes, and there exists a low-level bacteremia in which *M. tuberculosis* disseminates to distant sites in the body. This hematogenous seeding occurs most frequently in regions of the body that are highly oxygenated, including the brain. A complex interplay of host immune factors and *M. tuberculosis* virulence factors in the end determines

whether or not the infection is contained and whether, or to what extent, the dissemination of the bacilli leads to clinical disease.

For CNS tuberculosis, the disease begins with the development of small tuberculous foci (Rich foci) in the brain, spinal cord, or meninges. The location of these foci and the capacity to control them ultimately determine which form of CNS tuberculosis occurs. CNS tuberculosis manifests itself primarily as tuberculous meningitis (TBM) and less commonly as tuberculous encephalitis, intracranial tuberculoma, or a tuberculous brain abscess.

In nearly every case, there was a meningeal focus where bacilli gained access to the subarachnoid space and induced meningitis. A caseating vascular focus, the "Rich focus," in the brain cortex or the meninges is the key pathway for the tubercle bacilli to enter the subarachnoid space. This method of entry is in contrast to the direct hematogenous spread typically observed in acute bacterial meningitis.

Disseminated tuberculosis plays an important role in the development of TBM in children, inasmuch as disseminated tuberculosis increases the probability that a Rich focus will develop, thus enhancing the chances of a fortuitous rupture of the lesion, leading to clinical TBM.

The cytokine tumor necrosis factor alpha (TNF- $\alpha$ ) is critical in the neuropathogenesis of *M. tuberculosis*. Although TNF- $\alpha$  plays a definitive role in granuloma formation and containment of mycobacterial infections, local CNS production of TNF- $\alpha$  leads to altered blood-brain barrier (BBB) permeability and cerebrospinal fluid (CSF) leukocytosis and has been implicated in fostering the progression of TBM.

A distinctive characteristic of *M. tuberculosis* is its capacity to enter and replicate within macrophages. Within the CNS, microglial cells are the resident macrophages, and as such, human microglial cells are productively infected with *M. tuberculosis* and are the principal target in the CNS.

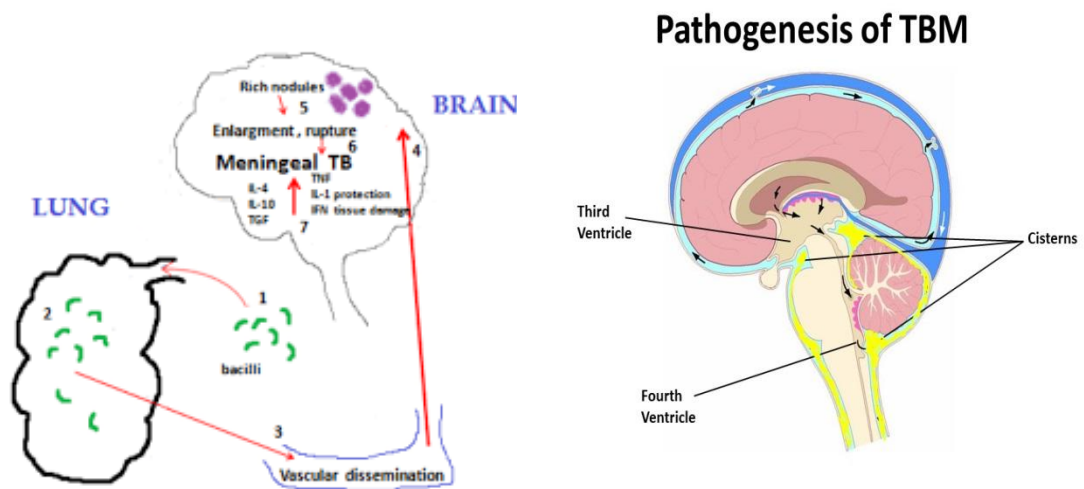
### 5.5.1. Tuberculosis meningitis (TBM).

TBM – it is the inflammation of meninges. Up to 80 % of patients with tuberculous meningitis either have traces of early acquired tuberculosis of other localizations, or active tuberculosis of other site.

*Pathogenesis of the tuberculous meningitis.* The main route of MBT infiltration into the meninges is the hematogenous route. At the same time the damage of meninges proceeds in two phases:

1. During the first phase, in primary tuberculosis, the sensitization of an organism develops, MBT break through BBM and infection of vascular plexuses of the piamater takes place.

2. During the second phase MBT from vascular plexuses, penetrate into the liquor, invoke specific inflammation of piamater at the base of brain – bacillary meningitis (picture 34).



Picture 34. TBM pathogenesis.

After the release of tubercle bacilli from granulomatous lesions into the subarachnoid space, a dense gelatinous exudate forms; it is most florid in the interpeduncular fossa and suprasellar region anteriorly, and it may extend throughout the prepontine cistern and surround the spinal cord. This exudate envelops arteries and cranial nerves, creating a bottleneck in the flow of cerebrospinal fluid at the level of the tentorial opening, which leads to



hydrocephalus. The exudate contains erythrocytes, neutrophils, and macrophages, followed by lymphocytes in more mature exudates. The Rich foci typically follow the vascular pattern and are located both in the meninges and in the brain parenchyma. Of note, Rich foci are not preferentially distributed to the basilar areas of the brain where the exudate is typically located. The localization of the tuberculous exudate to the basilar area is hypothesized to be simply a result of the normal flow pattern of CSF.

The most serious consequence of TBM, however, is the development of vasculitis in the vessels of the circle of Willis, the vertebrobasilar system, and the perforating branches of the middle cerebral artery, resulting in infarctions in the distribution of these vessels. Direct contact of the exudate with the brain surface causes a border zone reaction that damages the underlying brain tissue.

*Clinical features of TBM.* There are three main forms of tuberculosis of the meninges and central nervous system:

- Basal tuberculous meningoencephalitis occurs in 60-70% of cases. This classic form has not changed to this day, but can course atypically on background of indiscriminate antibiotic treatment of persons with the unclear etiology disease. The brain matter, cranial nerves and the brain substance are affected in this form.
- Basal tuberculous meningitis observed in 26-32% of cases and is characterized by a combination of meningeal syndrome with brain nerve base damage and related inflammatory changes in cerebrospinal fluid. They also include weakly expressed forms in which cranial nerves are not affected.
- Meningo-encephalomyelitis occurs in 4-6% of cases, can occur in two forms that differ only in initial symptoms:
  1. rising, where the first manifestations of the disease symptoms of myelo-radiculo-neuritis, urination disorders. Meningeal symptoms are joined later (a few weeks or even months). This group of patients has psychomotor agitation, as one of the first distribution

process in the brain signs. Rising meningo-encephalomyelitis is very difficult to diagnose at the beginning.

2. descending meningoencephalomyelitis characterized process spread from the base of the brain to the spinal cord membranes and predominance in the clinical picture of the disease symptoms of membranes and substance of the brain and spinal cord.

TBM is typically a subacute disease. A prodromal phase of low-grade fever, malaise, headache, dizziness, vomiting, and/or personality changes may persist for a few weeks, after which patients can then develop more severe headache, altered mental status, stroke, hydrocephalus, and cranial neuropathies. Seizures are uncommon manifestations of TBM in adults and when present should prompt the clinician to consider alternate diagnoses such as bacterial or viral meningitis or cerebral tuberculoma; in contrast, seizures are commonly seen in children with TBM, occurring in up to 50% of pediatric cases. The clinical features of TBM are the result of basilar meningeal fibrosis and vascular inflammation.

Classic features of bacterial meningitis, such as stiff neck and fever, may be absent. When allowed to progress without treatment, coma and death almost always ensue. In survivors of TBM, neurologic sequelae may occur that include mental retardation in children, sensorineural hearing loss, hydrocephalus, cranial nerve palsies, stroke-associated lateralizing neurological deficits, seizures, and coma (table 1).

The diagnosis of TBM can be difficult and may be based only on clinical and preliminary CSF findings without definitive microbiologic confirmation.

Certain clinical characteristics such as longer duration of symptoms (> six days), moderate CSF pleiocytosis, and the presence of focal deficits increase the probability of TBM.

Table 1.

**Clinical features of tuberculous meningitis in children and adults**

	Children	Adults
Symptoms	Early symptoms are non-specific and include fever, cough, vomiting, malaise and weight loss. Duration of symptoms >6 days Seizures more common in children than in adults	Prodromal period with low-grade fever, malaise, weight loss followed by gradual onset of headache (1–2 weeks). Worsening headache, vomiting, confusion, coma. Duration of symptoms $\geq$ 6 days
Clinical findings	Apathy, irritability, meningitis, reduced level of consciousness, bulging anterior fontanelle (infants), VI cranial nerve palsy, optic atrophy, abnormal movements and focal neurological signs, e.g. hemiplegia	Neck stiffness, confusion, coma Cranial nerve palsies—VI, III, IV Focal neurological signs, e.g. monoplegia, hemiplegia, paraplegia Urinary retention
CSF findings	Usually clear and colourless, raised white cell count ( $0,5-1 \times 10^9/l$ ) with neutrophils and lymphocytes Raised protein (0,5–2,5 g/l) CSF to plasma glucose ratio <0,5 in 95 % of cases	High opening pressure >25 cm H <sub>2</sub> O in 50 % of cases, usually clear and colourless Raised white cell count ( $0,05-1 \times 10^9/l$ ) with neutrophils and lymphocytes Raised protein (0,5–2,5 g/l) CSF to plasma glucose ratio <0,5 in 95% of cases

*Characteristic CSF findings of TBM include the following:*

-the CSF, at first, looks clear but may form a 'spider's web clot on standing,

- lymphocytic-predominant pleiocytosis. Total whitecell counts are usually between 100 and 500 cells/ $\mu$ L (norma is up to 5).Very early in the disease, lower counts and neutrophilpredominance may be present,

- elevated protein levels, typically between 100 and500 mg/dL (or 1,0-2,0 g/l), (norma is 0,15-0,45 g/l),

- low glucose, usually less than 45mg/dL or CSF: plasmaratio <0,5.

-at the bacteriology examination MBT are revealed only in 10% cases if volume of CSFis sufficient (10-12 ml). The method of centrifuge flotation during 30 minutes on high speedcan reveal MBT in CSF in 90% cases.

*Differential diagnosis.* The main conditions to be differentiated are bacterial meningitis, viral meningitis, and HIV-related cryptococcal meningitis. In the first two, the onset is much more acute. Cryptococcal meningitis may have a much slower onset. A family history of tuberculosis, or the finding of tuberculosis somewhere else in the body, makes tuberculous meningitis much more likely. But the best evidence comes from examination of the CSF obtained by lumbar puncture (table 2).

Table 2.

**CSF parameters in meningitis of different etiology**

Parameter	Norma	Bacterial meningitis	Viral meningitis	Fungal meningitis	TB meningitis
Opening pressure (mm H <sub>2</sub> O)	□ 180	200-500	NA	>250	NA
WBC count	0-5	100-20000 (mean 800)	5-500 (mean 80)	20-2000 (mean 100)	5-2000 (mean 200)
WBC differential	No predominance	>80 % PMN	>50 % L, □ 20 PMN	>50 % L	>80 % L
Protein (mg/dl)	15-45	100-500	30-150	40-150	>50
Glucosae (mg/dl)	45-100 (1/2 of serum)	≤40 (□ 40 %)	30-70	30-70	□ 45 (□ 40 %)
Gram stain (% +)	NA	60-90	-	-	37-87 (AFB)

AFB- acid fast bacilli,  
 L – lymphocytes,  
 NA – not applicable,  
 PMN – polymorphonuclear cells,  
 WBC – white blood cells.

*Prognosis.* Fatal outcome is certain if the patient does not receive treatment. The earlier meningitis is diagnosed and treated, the more likely is the patient to recover without serious permanent damage. The clearer the state of consciousness when treatment is started, the better the prognosis. If the patient is in coma, the prognosis for complete recovery is poor.

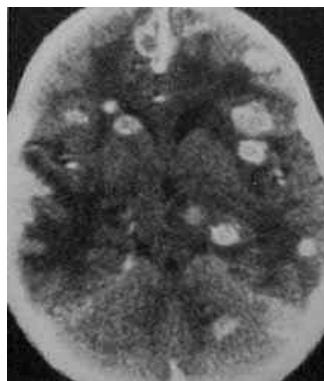
### 5.1.2. Brain tuberculoma.

Tuberculomas are thought to arise when tubercles in the brain parenchyma enlarge without rupturing into the subarachnoid space. As such, they often occur in the absence of TBM but certainly may occur along with TBM. They more commonly arise as solitary lesions, but multiple tuberculomas are seen. Tuberculomas of the brain show a typical granulomatous reaction consisting of epithelioid cells and giant cells mixed with predominantly lymphocytes around a central area of caseating necrosis. Any liquefaction of the central area of necrosis contains clear or straw-colored fluid, as opposed to pus.

In the early stages it is much smaller, the later - greater; the average diameter of brain tuberculoma is 0,5-1 cm, although the size can reach 4 cm. Mostly there are solitary brain tuberculoma, although there may be multiple (35-40 %).

The disease begins with a prodromal period to an average of 1-2 months. The first clinical signs are weakness, lethargy, asthenia, conduct disorder, lethargy, tearfulness, irritability. The beginning of the disease can be acute with the rapid increase of symptoms and subacute with prolonged asymptomatic symptoms-less course and with slow progression of some disease symptoms. If there is supratentorial tuberculoma disease manifested with focal symptoms, irritation in the form of convulsive attacks and hallucinations.

Diagnosis is based on anamnesis (presence of tuberculosis, slow disease course, remission) and these clinics, X-ray, electro-encephalography, echoencephalography, computer tomography (picture 35).



Picture 35. Multiple tuberculosis tuberculoma.

### **5.1.3. Tuberculosis brain abscess.**

Brain abscess formation is a rare manifestation of CNS tuberculosis. Tuberculous brain abscess develops either from parenchymal tubercular granulomas or via the spread of tuberculous foci from the meninges and is characterized by an encapsulated collection of pus containing viable bacilli without evidence of the classic tubercular granuloma and must be distinguished from granuloma with central caseation and liquefaction mimicking pus. Brain abscesses can arise as solitary or multiple lesions. Grossly and radiographically, a tuberculous brain abscess has a much thicker abscess wall than a pyogenic brain abscess. Histopathological findings suggest that the inflammatory reaction in the abscess wall is predominantly vascular granulation tissue containing acute and chronic inflammatory cells and bacilli in the pus or abscess wall.

The clinical course is similar to tuberculosis tuberculoma.

### **5.1.4. Tuberculosis encephalopathy.**

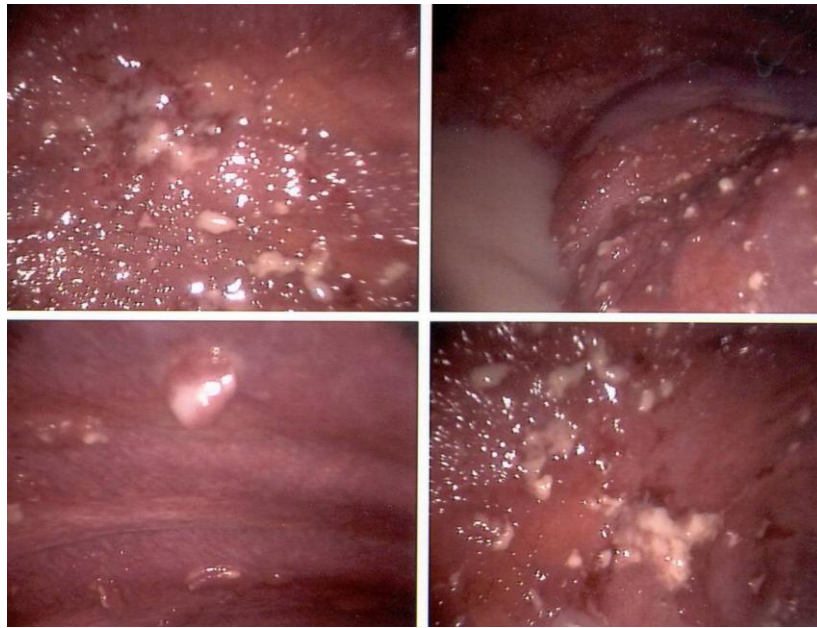It belongs to a group of tuberculous allergic manifestations. It occurs in children and adolescents. The main symptoms include disorders of consciousness and coma.

## **5.2. Tuberculosis pleurisy**

The pleurisy, is the inflammation of pleura. Two basic forms of pleurisy are distinguished: dry or fibrinous (pleuritis sicca, fibrinosa), and exudative (picture 36) (pleuritis exudativa).

*Pathogenesis.* During tuberculosis the pleura is involved in the process of inflammation at penetration in infection by the contact way, through the lymph or the blood. The involvement of pleura in various pathological processes is conditioned by close anatomic topographical connections of visceral and parietal pleura with lung tissue, intrathoracic lymphatic nodes. The pleura, having barrier

function, reacts to various pathophysiological changes of the body. Therefore, the developments of inflammatory or allergic processes take place.



Picture 36. **Exudative pleuritis.**

Exudative inflammatory reaction of the pleura is connected with increased permeability of the blood and lymphatic capillaries of the lung cortical layer and pleura itself. These capillaries make way for a liquid part of blood into intra tissue fissures, superficial layers of pleura and there from, with the help negative pressure, into pleural cavity.

Lymphagenic pleurisy. The tubercular infection can affect subpleural lymphatic nodes. Accumulating in the nodes *Mycobacterium tuberculosis*, some are bricked up and are eliminated and the rest of MBT, keeping their virulence, are distributed along lymph vessels causes subpleural cortical lymphangitis or the exudative pleurisy.

Hematogenic pleurisy. The hematogenic spreading of MBT into the pleural cavity promotes development of tubercles on the pleura. The initial focus is an active tubercular process in mediastinum lymphatic nodes.

The contact way of MBT dissemination arises at active tuberculosis of lymphatic mediastinum nodes, with defeat of visceral pleura.

Fibrinous pleurisy (dry pleurisy). At the fibrinous pleurisy on the pleura at first, gentle layer occurs, of fibrinous structure, which could easily remove. Further the fibrinous pellicle of yellowish or yellowish-gray color is formed.

Purulent pleurisy (empyema) from the very beginning arises as purulent very rare, but more often it develops after serous-fibrinous inflammation of the pleura. The process usually happens unilateral and mainly settles down in basal or posterior part of the pleural cavity. The purulent pleurisy is observed at bursting out of caseous masses from lung into the pleural cavity, bronchopleural fistulas and etc. Hemorrhagic pleurisy accompanied by penetration of exudates containing a significant impurity of erythrocytes into pleural cavity.

Chronic pleurisy. More often chronic course of the pleurisy is observed at pleural empyema. In these cases exudates condense, dissociate, turn in cheesy mass or thin gruel with presence of cholesterol crystals; the microorganisms can disappear. The pleural membranes are considerably thickened and dense, sometimes with focal petrification and even ossification. The significant sediments of calcified masses are especially typical for tubercular empyema. The pleural empyema can lead to purulent – resorption fever, sepsis, exhaustion, amyloidosis of internal organs. Sometimes long, chronic current is observed at serous-fibrotic and fibrotic pleurisy.

During acute and chronic pleurisies the significant accumulation of exudates in the pleural cavity causes the atelectasis in appropriate lung and the mediastinum organs are displaced in the opposite side.

There are three variants of tuberculous exudative pleurisy.

1. Allergic pleurisy occurs in patients with primary tuberculosis or an exacerbation of chronic primary infection. This pleurisy often has no local manifestations of the basis disease. Clinically allergic pleurisy characterized by acute development with a significant temperature reaction and rapid accumulation of fluid in the pleural cavity.
2. Perifocal pleurisy is the result of pleural sheets involvement in the inflammatory process in the presence of located subcortical active



lesions of tuberculosis or bronchopulmonary lymph nodes. Character of fluid is often fibrinous or sero-fibrinous, which often causes the clinical picture of a local dry pleurisy. There are different tuberculosis changes in lung`s tissue.

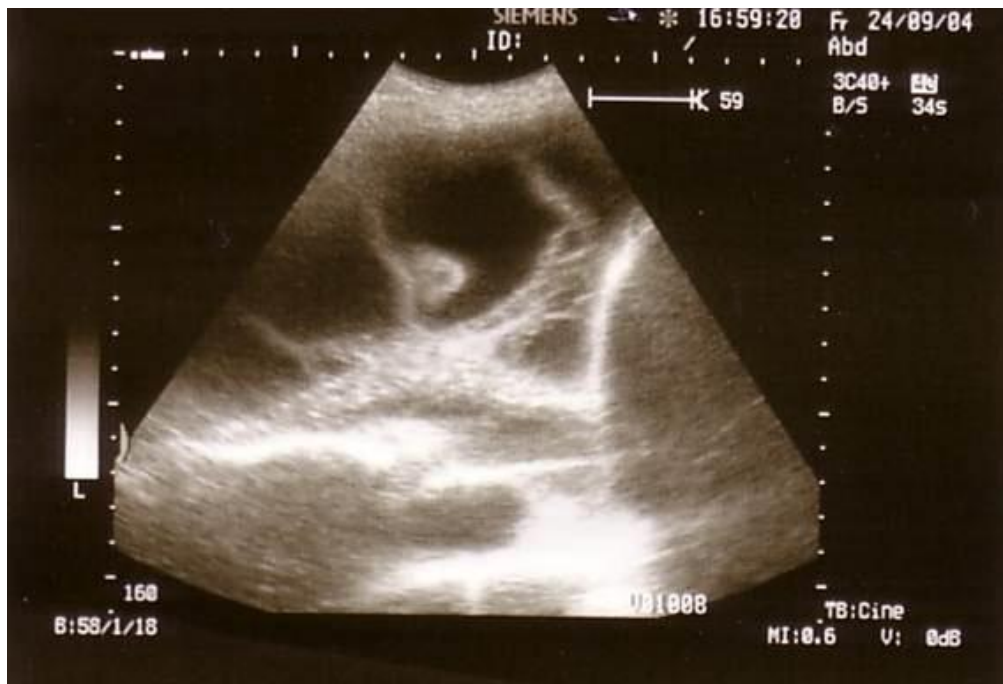3. Pleural tuberculosis develops as a result of bacteremia as during primary infection when pleural tuberculosis may be the only manifestation of the disease, and secondary genesis connected with other clinical forms of pulmonary tuberculosis. Pleural infection is possible and in case of break to the pleural cavity peripheral located cavity or rupture of pleural adhesions. Morphologically on the surface of the pleura: 1) dissemination multiple small foci; 2) single large focus; 3) extensive caseous necrosis defined. In tuberculous pleural lesions MBT are often founded in pleural fluid.

**Clinical features.** Tuberculous pleurisy usually presents as an acute illness. The most common presenting symptoms are nonproductive cough and pleuritic chest pain. Other symptoms include fever, night sweats, weight loss, malaise, and dyspnea varying in severity according to the size of effusion. As a general rule, an acute illness is more likely to occur in younger patients who are more immunocompetent.

Radiological effusion is likely to intense homogeneous darkening of the lower parts of the lungs oblique upper line that goes outside and above, inward and downward. Over exudate determined less intense strip of blackout associated with the compression of the lungs. When a large amount of fluid in the pleural cavity the shadows can hide almost all lung and make invisible changes in it. If pleural fluid encysted because of pleural connections, X-ray picture of pleural effusion loses its characteristic, it is varied depending on the position of fluid in the pleural cavity and connection`s character (picture 37).

**Diagnosis.** The definitive diagnosis of tuberculous pleurisy depends upon the demonstration of tubercle bacilli in the sputum, pleural fluid, or pleural biopsy specimens. The diagnosis can also be established with demonstration of

classical granulomas in the pleura or reasonable certainty by demonstrating elevated levels of adenosine deaminase (ADA) or interferon-gamma (IFN- $\gamma$ ) in the pleural fluid.



**Picture 37. Ultrasound detection of multiple chambers in pleuritis exudativa tuberculosis.**

For diagnosis pleural fluid inspection should be done. Fluid in tuberculosis pleurisy has the exsudate character with a specific gravity more than 1,018, a high content of protein - more than 30 g/l (often exceeding 50 g/l). Fluid is predominantly serous, less often - purulent or hemorrhagic. During the accumulation of fluid in tuberculosis neutrophils (50-60 %) can prevail lymphocytes (20%), there are also little eosinophils, red blood cells, mesothelial cells in serous fluid. Further cyto-gram is characterized by a sharp increase in lymphocytes (90-95%) (table 3).

If necessary, to clarify the etiology of pleurisy thoracoscopy and pleural biopsy performed.

The differential diagnosis of pleural effusions viewed in picture 38.

Table 3.

**Pleural fluid parameters in pleurisy of different etiology**

<b>Parameters</b>	<b>Tuberculosis pleural effusion</b>	<b>Malignant pleural effusion</b>	<b>Post- pneumonic pleural effusion</b>	<b>Transudate pleural effusion</b>
<b>Specific gravity</b>	1018-1026	1015-1022	1020-1029	1011-1015
<b>pH</b>	6,9-7,4	7-7,8	6,9-7,1	7,1-7,4
<b>Total Leucocyte count</b>	780-2500	720-1130	11200-19500	80-310
<b>Segmental, %</b>	20-45	55-99	62-84	60-83
<b>Lymphocyte, %</b>	55-80	10-45	9-14	17-40
<b>Glucosae (mg/dl)</b>	45-79	43-90	25-36	48-100
<b>Protein (g/dl)</b>	3,2-6,6	3,5-6,1	4,6-7,3	1,8-2,8
<b>Protein fluid/serum ratio</b>	>0,5	>0,5	>0,5	□0,5
<b>LDH (lactate dehydrogenase)</b>	>2/3 of serum	>2/3 of serum	>2/3 of serum	□2/3 of serum
<b>LDH fluid/serum ratio</b>	>0,6	>0,6	>0,6	□0,6
<b>ADA, U/l</b>	>70	□40	□40	≤10
<b>IFN-γ, pg/ml</b>	>140	□140	□140	≤100

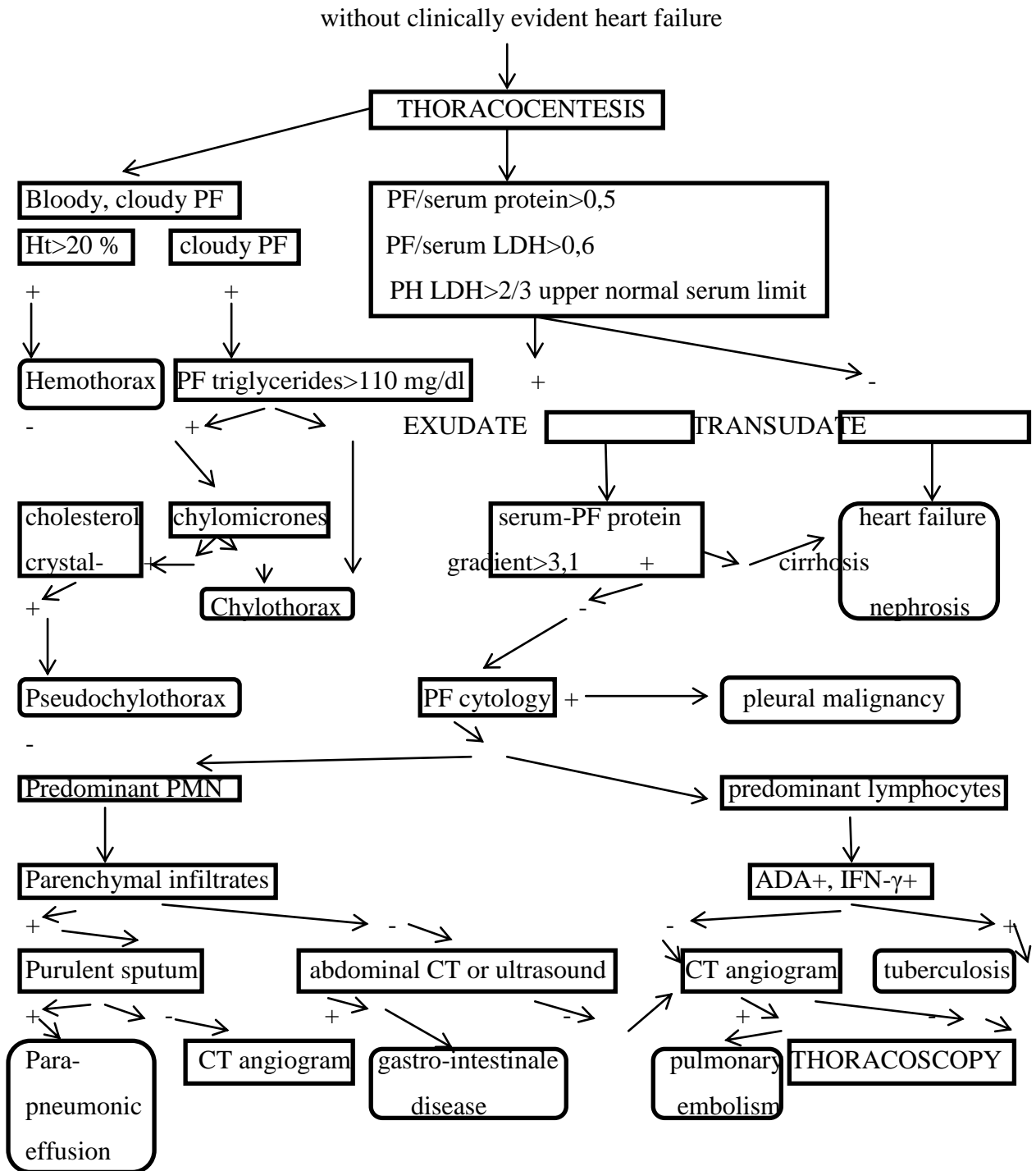
**Enobronchial tuberculosis (EBTB)**

Five potential mechanisms have been suggested for the development of endobronchial infection due to *M. tuberculosis*:

- direct extension from adjacent parenchymal focus;
- implantation of organisms from the infected sputum;
- hematogenous dissemination;
- lymph node erosion into the bronchus;
- through lymphatic drainage from parenchyma to the peribronchial region.

EBTB may have insidious onset, simulating bronchogenic carcinoma, or may be acute, mimicking asthma, foreign body aspiration and pneumonia. Symptoms of EBTB may develop even after completion of therapy.

Pleural effusion (>1 cm height on X-ray or ultrasound or CT)
--



PF – pleural fluid,

Picture 38. **Pleural effusion differential diagnosis.**

Endobronchial tuberculosis can present with a variety of nonspecific signs and symptoms, which include cough (usually nonproductive), dyspnea, anorexia, weight loss, hemoptysis, chest pain, and hoarseness. The barking cough

that is not responsive to an antitussive medication, but responds to steroids along with antituberculosis treatment may be a feature of EBTB. Localized wheezing can occur if there is a stenosing effect by the endobronchial lesion. Bronchorrhea can occur in active endobronchial tuberculosis. Sputum production is variable. Hemoptysis may occur but is seldom massive. Lymph node rupture may cause chest pain that may be sharp or dull in sternal or parasternal region. Dyspnea is often associated with atelectasis of the lung.

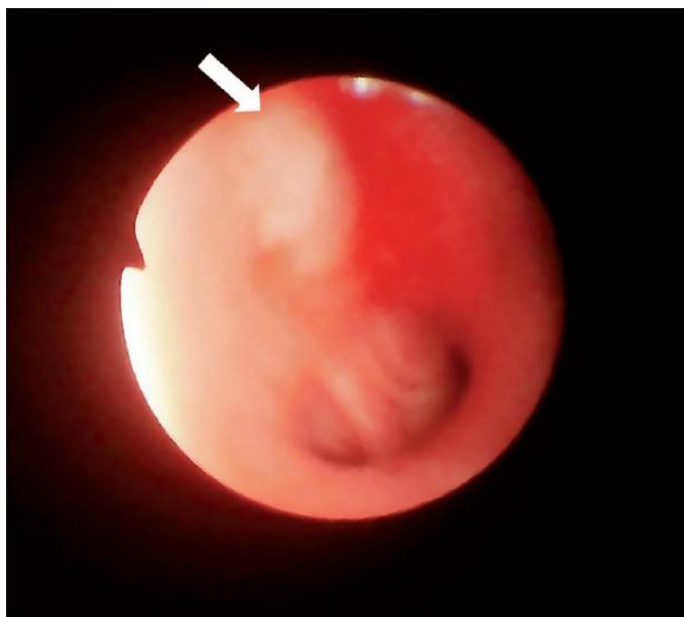Physical examination may reveal diminished breath sounds and localized low-pitched wheeze or rhonchi. Up to 25 to 35% of EBTB patients may have features of collapse. Classical monophonic wheeze may be heard in about 15% of the patients. There may be expectoration of tracheal cartilage. Dull and sharp chest pain can occur anteriorly due to enlargement and rupture of the lymph nodes. Constitutional symptoms including fever, weight loss, anorexia and night sweats are not usually prominent in EBTB. Serious sequelae especially with tracheal involvement such as respiratory failure, collapse of dependent portion of lungs, failure of endobronchial intubation, or death by suffocation have been reported.

**Diagnosis:** Although sputum examination is the essential and first step towards the diagnosis of EBTB, bronchoscopy and computed tomography are the methods of choice for accurate diagnosis of bronchial involvement and assessment for surgical intervention. Fiberoptic bronchoscopy is indicated in patients in whom chest radiographs, physical signs or symptoms suggest the possibility of endobronchial tuberculosis (picture 39).

10 to 20 percent patients with EBTB may have a normal chest radiograph. Thus, a clear chest radiograph does not exclude the diagnosis of endobronchial TB!

Bronchoscopic sampling has been the key to the diagnosis of EBTB, producing more than 90 percent yield on smear as well as on culture. In diagnosing EBTB, the experienced bronchoscopist is required. Even if biopsy fails to supply tangible results, the bronchoscopic changes, supported by clinical

and radiological findings, may be sufficient to establish the diagnosis of EBTB. A bronchoscopic biopsy is the most reliable method for diagnosing EBTB, because a needle aspiration can provide only a cytological diagnosis. However, needle aspiration can be used for obtaining materials from segments of a lobe where the forceps cannot reach. Different bronchoscopic specimens including biopsy, brushing and washings should be obtained as practicable. These specimens provide variable yield. Bronchial biopsy may be positive in 35% to 84% patients. Similarly, bronchial washings have also yielded variable results ranging from 10% to 37,5%.



**Picture 39. Caseating mass occluding upper division of left upper lobe bronchus with inflamed mucosa.**

A widely accepted classification defining EBTB by fibreoptic bronchoscopy has the following seven subtypes:

- actively caseating,
- edematous-hyperemic,
- fibrostenotic,
- tumorous,
- granular,
- ulcerative,

- non-specific bronchitis.

The prominent lymphnodes are seen as grayish-yellow masses through the bronchial mucosa. Hemorrhage, granulation tissue fistula formation and caseous material draining into bronchus may also be seen. Early bronchoscopic findings consist of erythema, mucosal granularity including discrete submucosal tubercles, and shallow mucosal ulcers. Findings suggestive of more advanced disease are deep ulcers, hyperplastic inflammatory polyps, tumour like collections of granulation tissue and bronchial stenosis. The exudative lesion consists of mucosal erythema, swelling and white caseous exudates with or without granulation tissue. The lesions are described as ulcerative when bronchial mucosa shows predominantly ulcerations. The cicatricial lesions have hypertrophic mucosa and distorted lumen with or without polypoid lesions. The bronchoglandular lesions are manifested as one or more eccentric round indentations into bronchial lumen on bronchoscopic examination. Such lesions have involvement of peribronchial or paratracheal lymph node(s). Diffuse mucosal congestion with edema (suggestive of inflammation) and mass lesion are most common bronchoscopic findings.

**REFERENCES**

1. Ревматоид Понсе: диагноз или миф? Два клинических случая и обзор литературы [Текст] / М.С. Пртопопов [и др.] // Практическая медицина. – 2013. – Т. 1, № 1-2. – С. 80-87.
2. A case of Ponset`s disease (tuberculous rheumatism) [Text] / H. Ideguchi [et all.] // Rheumatol Int. – 2009. – Vol. 29. – P. 1097-1099.
3. Bhargava, A.D. Tuberculous rheumatism (Poncet`s disease) – a case series [Text] / A.D. Bhargava, A.N. Malaviya, A. Kumar // Ind J Tub. – 1998. – Vol. 45. – P. 215-219.
4. Central nervous system tuberculosis: pathogenesis and clinical aspects [Text] / R.B. Rock [et all.] // Clinical microbiology reviews. – 2008. – Vol. 21, № 2. – P. 243-261.
5. Chest radiographic findings in primary pulmonary tuberculosis: observations from high school outbreaks [Text] / W.J. Koh [et all.] // Korean J Radiol. – 2010. – Vol. 11 (6). – P. 612-617.
6. Clinical picture of pulmonary tuberculosis at the end of the second millennium [Text] / I. Grbak, S. Smolcic, D. Jurmon, S. Broz // Acta Clin Criat. – 2000. – Vol. 39. – P. 175-179.
7. Diagnosis of three cases of endobronchial tuberculosis presenting as unresolved pneumonia, following fiberoptic bronchoscopic biopsy [Text] / P.P. Roy [et all.] // Lung India. – 2010. – Vol. 27, № 3. – P. 185-188.
8. Diagnosis of tuberculous meningitis: clinical and laboratory parameters [Text] / A.I. Bhigjee [et all.] // International journal of infectious diseases. – 2007. – Vol. 11. – P. 348-354.
9. Frank, W. Tuberculous pleural effusion [Electronic resource] / W. Frank // Tuberculosis – current issues in diagnosis and management. <http://dx.doi.org/105772/54955>.



10. Frankel, A. Cutaneous tuberculosis. A practical case report and review for the dermatologist [Text] / A. Frankel, C. Penrose, J. Emer // *Clinical aesthetic.* – 2009. – Vol. 2, № 10. – P. 19-27.
11. Frcp, Y.I. Pulmonary tuberculosis – a review of clinical features and diagnosis in 232 cases [Text] / Y.I. Frcp // *Med J Malaysia.* – 2004. – Vol. 59, № 1. – P. 56-64.
12. Inal, E.E. A case of Ponset`s disease: tuberculous rheumatism [Text] / E.E. Inal, D. Keskin, H. Bodur // *Turk J Phys Med Rehab.* – 2015. – Vol. 61. – P. 77-79.
13. Isabel, B.E. Pathogenesis and immune response in tuberculous meningitis [Text] / B.E. Isabel, H.P. Rogellio // *Malays J Med Sci.* – 2014. – Vol. 21 (1). – P. 4-10.
14. Jeon, D. Tuberculous pleurisy: an update [Text] / D. Jeon // *Tuberculosis and respiratory diseases.* – 2014. – Vol. 76. – P. 153-159.
15. Jeong, Y.J. Pulmonary tuberculosis: up-to-date imaging and management [Text] / Y.J. Jeong, K.S. Lee // *AJR.* – 2008. – Vol. 191. – P. 833-844.
16. Koshechkin, V.A. Tuberculosis. Textbook [Text] / V.A. Koshechkin, Z.A. Ivanova // Moscow, 2008: GEOTAR-Media. – 272 p.
17. Koski R.R. Etiology and management of chronic meningitis [Text] / R.R. Koski, D.V. Loo // *US Pharm.* – 2010. – Vol. 35 (1). – P. 2-8.
18. Light, R.W. Update on tuberculous pleural effusion [Text] / R.W. Light // *Respirology.* – 2010. – Vol. 15. – P. 451-458.
19. Marx, G.E. Tuberculous meningitis: diagnosis and treatment overview [Electronic resource] / G.E. Marx, E.D. Chan // *Tuberculosis research and treatment.* – 2011. – Vol. 2011. – doi: 10.1155/2011/798764. Article ID: 798764. – 9 p.
20. Merchant, S. Tuberculosis of the genito-urinary system – urinary tract tuberculosis: renal tuberculosis – part 1 [Text] / S. Merchant, A. Bharti, N. Merchant // *Indian J Radiol Imaging.* – 2013. – Vol. 23 (1). – P. 46-63.
21. Neki, N.S. Endobronchial tuberculosis: an overview [Text] / N.S. Neki // *Ann Pak Inst Med Sci.* – 2013. – Vol. 9 (3). – P. 105-109.

22. Ngan, V. Cutaneous tuberculosis [Electronic resource] / V. Ngan // [www.dermnetnz.org](http://www.dermnetnz.org).
23. Ocular tuberculosis (TB) – Asia Pacific [Electronic resource] // [www.aaopt.org/topic-detail/ocular-tuberculosis-tb-asia-pacific-2](http://www.aaopt.org/topic-detail/ocular-tuberculosis-tb-asia-pacific-2).
24. Porcel, J.M. Diagnostic approach to pleural effusion in adults [Text] / J.M. Porcel, R.W. Light // American family physician. – 2006. – Vol. 73, № 7. – P. 1211-1220.
25. Radiological findings of pulmonary tuberculosis in infants and young children [Text] / A. Khatami [et al.] // Iran J Radiol. – 2008. – Vol. 5 (4). – P. 231-234.
26. Role of interleukin-6, gamma interferon and adenosine deaminase markers in management of pleural effusion patients [Text] / M.A.M. Marie [et al.] // West Indian Med J. – 2013. – Vol. 62 (9). – P. 803-807.
27. Significance of adenosine deaminase in diagnosing tuberculous pleural effusion [Text] / K.C. Devkota [et al.] // Nepal Med Coll J. – 2012. – Vol. 14 (2). – P. 149-152.
28. Smiljc, S. Clinical and radiographic characteristics of pulmonary tuberculosis [Text] / S. Smiljc, B. Radovic // Med Pregl. – 2012. – Vol. LXV (5-6). – P. 196-199.
29. Swaminathan, S. Extra-pulmonary tuberculosis [Text] / S. Swaminathan, G. Narandran // Medicine update. – 2005. – P. 651-655.
30. The validity of cerebrospinal fluid parameters for the diagnosis of tuberculous meningitis [Text] / L. Solari [et al.] // International journal of infectious diseases. – 2013. – P. 1111-1115.
31. Torok, M.E. Tuberculous meningitis: advances in diagnosis and treatment [Text] / M.E. Torok // British medical bulletin. – 2015. – Vol. 113. – P. 117-131.