

# Histology of Indeterminate Leprosy<sup>1</sup>

Liu Tze-Chun, Yen Li-Zung, Ye Gan-yun, and Dung Gu-Jing<sup>2</sup>

The histology of the earliest skin lesion of leprosy is chronic, non-specific inflammation, so-called indeterminate leprosy. It is always difficult to diagnose by the pathologist as leprosy at this stage. This paper presents a study of the histopathology of 20 cases which had been firmly diagnosed as indeterminate leprosy in the past in our department.

## MATERIALS AND METHODS

Twenty cases were skin biopsied. The sections were routinely stained with hematoxylin and eosin (H&E) and by the Wade-Fite method. Some of the sections were restained, and some of the specimens were reexamined by making serial sections. Recently we have also used an aldehyde-fuschin stain in order to observe and count the number of mast cells. In each biopsy the area occupied by the infiltrate was measured in all high-power microscopic fields and compared with the total area of the dermis in the biopsy specimen. In this way the proportion of the dermis occupied by the infiltrate was determined.

## RESULTS

**Clinical manifestations.** Of the 20 cases, 17 were male and 3 were female; the youngest patient was 11 years old and the oldest 58. The great majority of the skin lesions were described clinically as being faint, hypopigmented macules. They occurred mainly on the limbs and were less frequent on the face or trunk. Additional clinical information is presented in Table 1.

**Distribution of bacilli in the lesions.** Of the 20 cases studied all showed bacilli in the

lesions. The bacilli were located mainly in small nerves (Fig. 1). Bacilli were frequently found in other areas, such as in the histiocytes of the infiltrate and in the sub-epidermal zone (Fig. 2). Bacilli could occasionally be encountered even in arrector pili muscle, hair follicle, or epidermal cells.

**Morphometry of the area of the infiltrate.** In each case, the area of the dermis occupied by the infiltrate was measured microscopically. In 70% of the cases, more than 5% of the dermis was involved. Involvement of 5% to 10% of the dermis was most frequent. Considering all of the cases, a mean of 5.3% of the dermis was involved by the infiltrate (Table 2).

**Infiltrate cells.** Histiocytes and lymphocytes were the predominant non-specific infiltrate cells. In two cases there were some histiocytes transforming into epithelioid cells, corresponding to the so-called "pre-tuberculoid" stage of the disease (Fig. 3). One case had scanty plasma cells. Neutrophils were not found in any of these cases. In every case mast cells could be found in dermal nerves. The average number of mast cells in 12 cases was 17.2 per high-powered microscopic field. The number of mast cells seemed to be inversely proportional to the size of the infiltrated area.

**Skin appendages.** Lesions of skin appendages, such as atrophy and disorganization of arrector pili muscle and sweat glands, were frequently found. Occasionally there was fibrosis and fibrous encapsulation of pilosebaceous glands apart from infiltration. The degree of infiltration present varied with different skin appendages, even in the same case. Infiltrates around sweat glands were seen most commonly. Arrector pili muscle was involved in only half of the cases. The amount of infiltration around sweat glands was much lower than that in arrector pili muscle. None of these variations were significant, however (Table 3).

**Histopathology of cutaneous nerves.** As a rule, small cutaneous nerves in the deep dermis or in the vicinity of sweat glands were found with prominent changes. The

<sup>1</sup> Received for publication on 4 May 1981; accepted for publication in revised form on 26 January 1982.

<sup>2</sup> Liu Tze-Chun, Associate Professor of Pathology, Chung Shan Medical College, Canton; Yen Li-Zung, Pathologist, Institute of Dermatology, Chinese Academy of Medical Sciences, Ye Gan-yun, Deputy Director, Institute of Dermatology, Kwangtung Province; Dung Gu-Jing, Instructor of Dermatology, Department of Dermatology, Chung Shan Medical College, People's Republic of China.

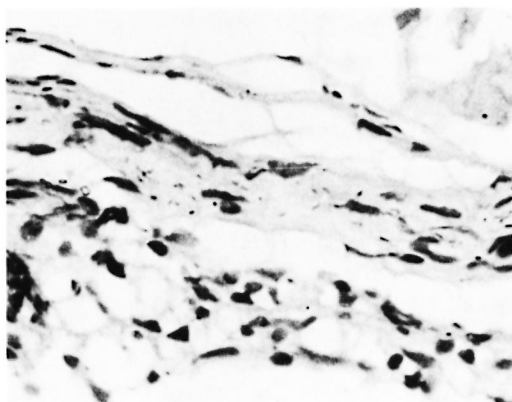


FIG. 1. Bacilli in dermal nerve (Wade-Fite,  $\times 400$ ).

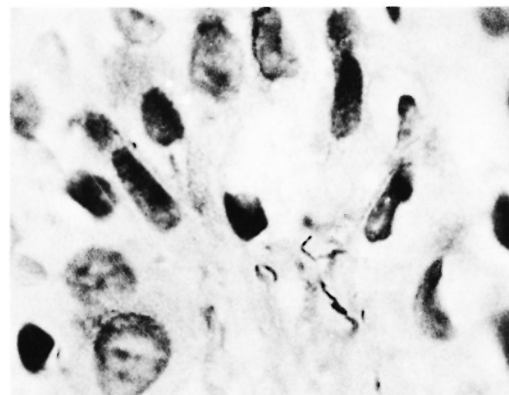


FIG. 2. Bacilli in subepidermal zone (Wade-Fite,  $\times 480$ ).

most common change was round cell infiltration around the perineurium (17 cases). In three cases where the infiltration was more marked, there were some infiltrative cells found within the nerve bundle, with disorganization of the nerve fibers by edema, the contour of the perineurium being not well defined. There were eight cases showing disturbed proliferation of Schwann cells, with hypertrophy, deformity, and disturbed arrangement of their nuclei, leading to thickening of the nerves. Four cases also showed fibrosis of the perineurium with the formation of connective tissue centripetally surrounding the dermal nerves. As noted above, these lesions could be observed simultaneously in the same case. For example, infiltration within nerve bundles was always associated with infiltration of the

surrounding perineurium. In two cases no dermal nerves were detected microscopically, and the diagnosis was made by finding acid-fast bacilli at other sites in the specimens. A dermal nerve in one case was free of infiltrate, but under Wade-Fite stain, many acid-fast bacilli could be seen (Table 4).

**Histology of the epidermal lesions.** Five cases (25%) showed epidermal lesions. These included slight atrophy, vacuole formation (Fig. 4), hyperplasia, spongiosis, liquefaction, and more than one of these lesions were encountered simultaneously in the same case (Table 5).

#### DISCUSSION

Although indeterminate leprosy may develop into lepromatous or tuberculoid leprosy during the course of its evolution, it still retains the actual meaning of indeterminate as the earliest lesion of leprosy. The concept that the area of the infiltrate should

TABLE 1. *Clinical manifestations of indeterminate leprosy (20 cases).*

	Number of cases
Number of skin lesions	
Single	4
Multiple	6
Unknown	10
Patterns of skin lesions	
Hypopigmented macule	19
Pale brown macule	1
Superficial nerves	
Thickened	7
Not thickened	7
Unknown	6

TABLE 2. *The area of the dermis occupied by the infiltrate in indeterminate leprosy (20 cases).*

Percent of dermis occupied by the infiltrate	Number of cases (% of total cases)
$\geq 10\%$	5 (25%)
5-10	9 (45%)
3.3-5	4 (20%)
2.5-3.3	1 (5%)
$\leq 2.5$	1 (5%)

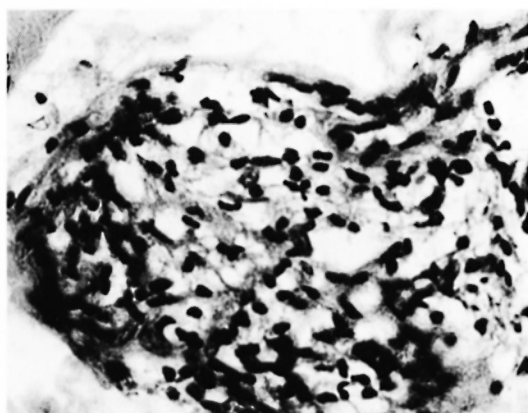


FIG. 3. Infiltrates composing of histiocytes and lymphocytes (H & E, ×400).

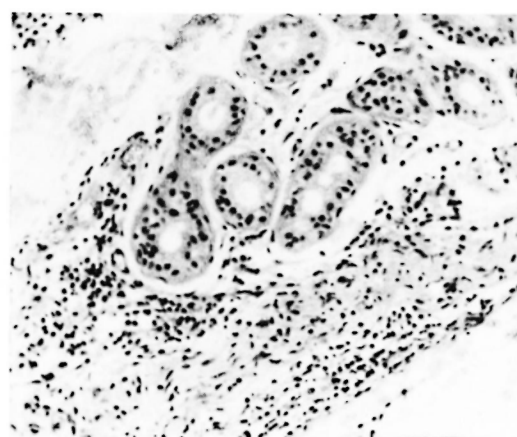


FIG. 4. Dermal nerve showing marked infiltration (H & E, ×240).

not exceed one twentieth (5%) of the area of the dermis as a critical criterion for the diagnosis of indeterminate leprosy is not valid. In this series there were only five cases (20%) in which the infiltrates occupied less than 5% of the dermis. The area occupied by the infiltrate in the remaining cases was variable.

Studies of indeterminate leprosy can provide clues on the route of transmission and the mode of invasion of leprosy bacilli. Some of the present cases showed intra-epithelial vacuole formation and infiltration. In one case leprosy bacilli were found in epithelial cells. These observations support the view of epidermal invasion of leprosy bacilli (6). On the other hand, some

cases showed multiple skin lesions and multiple foci of infiltration in the dermis, suggesting the result of infection transmitted through the blood stream. In other cases the infiltrates were more localized around dermal nerves, skin appendages, and small blood vessels. Infiltrates surrounding nerve terminals have been demonstrated earlier by us (10). These observations give sound evidence that leprosy bacilli can be transmitted through an ascending neuritis from nerve terminals of the skin.

Although there is histologic evidence for each of the above three routes of infection with *Mycobacterium leprae*, we consider neurological invasion and extension to be the most important. It is doubtful that vacuolation and infiltration of the epidermis is an early manifestation of leprosy because a) these lesions are non-specific in character and may appear in other skin diseases, b) no acid-fast bacilli can be found in the vacuole, and c) this lesion is always asso-

TABLE 3. Lesions of skin appendages in indeterminate leprosy.

	Number evaluated	Number of cases (% of total evaluated)
Arrector pili muscle	17	
No changes		9 (53%)
Inflammatory infiltration		7 (41%)
Atrophy		1 (6%)
Sweat Glands	15	
No changes		5 (33%)
Inflammatory infiltration		10 (67%)
Pilosebaceous glands	18	
No changes		10 (55%)
Inflammation		5 (28%)
Perifibrosis		3 (17%)

TABLE 4. Lesions of dermal nerves in indeterminate leprosy (18 cases evaluated).

	Number of cases (% of total evaluated)
No change	1 (6%)
Perineural infiltration	17 (94%)
Infiltration within nerves	5 (28%)
Hyperplasia of Schwann cells	8 (44%)
Perineural fibrosis	4 (22%)

ciated with infiltration in the dermis in the same section. In a few cases leprosy bacilli can be identified between epidermal cells. It is possible that these bacilli are spreading along nerve terminals downward to the dermal papillary layer, thus giving support to the invasion of intraepithelial nerve terminals by leprosy bacilli. Klingmueller (4) could not find any axon above the basal layer of the epidermis in his study. However, Allenby, *et al.* (1) found that stripping off the keratinized layer could rapidly induce ingrowth of axons into the epidermis. Because of this, a slight injury to the skin would provide a condition suitable for invasion of the epidermis by leprosy bacilli.

*M. leprae* are the only bacteria that can parasitize and destroy peripheral nerve tissue (2). In indeterminate leprosy, dermal nerves show infiltration around the perineurium and within nerve bundles, hyperplasia of Schwann cells, and perineurial fibrosis, all of which are non-specific reactions. So far as we know, the Schwann cell is a target cell susceptible to injury by *M. leprae*. Microscopically, no pronounced changes could be found in dermal nerves in the early stages. On the other hand, soluble antigen could have been emitted from the Schwann cells, eliciting infiltration around the dermal nerve as a constant lesion. Furthermore, destruction of Schwann cells by leprosy bacilli may lead to reactive hyperplasia of Schwann cells with disorganization and an increase of the cellular components within nerve bundles as a result (7). This lesion serves as a main point for the differential diagnosis between leprosy and other causes of chronic dermatitis. The perineurium, which is regarded as a barrier, can only give way when the infiltration surrounding the perineurium is severe. At that point, inflammatory cells can immigrate into the nerve tissue. Otherwise, infiltration within nerve bundles is essentially never seen. Perineurial fibrosis can be explained as a kind of reactive hyperplasia. We found in all cases that the dermal nerves were more easily detected adjacent to the sweat glands. That is possibly the reason for the infiltrates being more frequently found around sweat glands. Damage to the dermal nerves may lead to atrophy of the epidermis, the lesion which was once considered as a hallmark in the diagnosis of indeterminate leprosy by Has-

TABLE 5. Lesions of the epithelium in indeterminate leprosy (20 cases evaluated).

	Number of cases (% of total evaluated)
No change	15 (75%)
Slight atrophy	1 (5%)
Epithelial hyperplasia	0 —
Spongiosis	2 (10%)
Vacuolar formation	3 (15%)
Basal cell liquefaction	2 (10%)
Hyperpigmentation	0 —

selman (3). This would help in our differential diagnosis.

Ridley (8) noted that the numbers of mast cells within infiltrates of indeterminate leprosy were increased, but there was no actual measurement to support his observation. Based on counting the number of the mast cells and statistical analysis, we have demonstrated that mast cells are markedly increased in the lesions of indeterminate leprosy and are far more numerous in indeterminate cases than in any other type of leprosy (3).

#### SUMMARY

Skin biopsies from 20 patients with indeterminate leprosy were studied histopathologically. The most common clinical manifestation of the disease was a hypopigmented macule. In most cases, 5% to 10% of the dermis was occupied by the infiltrate. Sweat glands were involved in two thirds of the cases, and approximately half the biopsies showed involvement of arrector pili muscle and pilosebaceous glands. Ninety-five percent of the cases had involvement of the dermal nerves, with perineural infiltration being the most common finding. Twenty-five percent of the cases showed lesions of the epithelium.

#### RESUMEN

Se hizo el estudio histopatológico de 20 biopsias de piel de pacientes con lepra indeterminada. La manifestación más común de la enfermedad fue la presencia de una mácula hipopigmentada. En la mayoría de los casos, del 5 al 10% de la dérmis estuvo ocupada por el infiltrado celular. En 2/3 de los casos, las glándulas sudoríparas se vieron involucradas, y en aproximadamente la mitad de las biopsias hubo afección de los

músculos piloerectores y de las glándulas pilosebáceas. El 95% de los casos tuvieron alteración de los nervios dérmicos, siendo la infiltración perineural el hallazgo más común. En el 25% de los casos se observaron lesiones del epitelio.

### RÉSUMÉ

On a étudié les aspects histopathologiques de biopsies cutanées obtenues chez vingt malades atteints de lèpre indéterminée. La manifestation clinique de la maladie la plus fréquente a consisté en une macule hypopigmentée. Dans la plupart des cas, de 5 à 10% du derme étaient occupés par l'infiltrat. Les glandes sudoripares étaient atteintes dans deux-tiers des cas, et environ la moitié des biopsies témoignait d'une atteinte des muscles érecteurs des poils et des glandes pilosebácees. Dans 95% des cas, on a observé une atteinte des nerfs du derme, avec comme observation la plus habituelle une infiltration perineurale. Les lésions de l'épithélium étaient présentes chez 25% des malades.

### REFERENCES

1. ALLENBY, C. F., PALMER, E. and WEDDEL, G. Changes in the dermis of human hairy skin resulting from stripping the keratinized layer off the epidermis. *Z. Zellforsch.* **69** (1966) 566-572.
2. BINFORD, C. H. The histologic recognition of the early lesions of leprosy. *Int. J. Lepr.* **39** (1971) 225-230.
3. HASSELMAN, C. M. Histopathology in early leprosy. *Int. J. Lepr.* **31** (1963) 516.
4. KLINGMUELLER, G. The submicroscopic pathologic anatomy of leprosy. *Int. J. Lepr.* **39** (1971) 269-271.
5. LIU TZ-CHUN. Observation of mast cells in leprids. *Chinese J. Dermatol.* **14** (1981) 22-25.
6. NAYAR, A., NARAYANAN, J. S. and JOB, C. K. Histopathological study of early skin lesions in leprosy. *Arch. Path.* **94** (1972) 199-204.
7. PEARSON, J. M. H. and ROSS, W. F. Nerve involvement in leprosy, pathology, differential diagnosis and principles of management. *Lepr. Rev.* **46** (1975) 199-212.
8. RIDLEY, D. S. Pathology and bacteriology of early lesions in leprosy. *Int. J. Lepr.* **39** (1971) 216-224.
9. RIDLEY, D. S. The pathology of the early skin lesion in leprosy. *J. Pathol.* **111** (1973) 191-206.
10. WONG, Z. Y. Changes of nerve terminals in skin of leprids. *Chinese J. Dermatol.* **9** (1963) 83-88.