

Simultaneous Upgrading Reaction and Erythema Nodosum Leprosum in a Patient with Lepromatous Leprosy^{1,2}

Charles K. Job, Robert R. Jacobson, and Robert C. Hastings³

“Reaction” is a clinical term which has been used to identify an acute, immunologically mediated inflammatory phase in a leprosy patient irrespective of the classification of the disease. In lepromatous leprosy, erythema nodosum leprosum (ENL) is a well-described clinical and pathological entity (^{1, 5, 7, 15}), and it shows signs and symptoms of acute inflammatory reactions in various organs of the body, such as the skin, lymph nodes, nerves, joints, eyes and testes. In nonlepromatous patients, the acute episode usually manifests itself as an exacerbation of the leprosy lesions which, in due course, results in the regression of the lesions or progression of the disease, depending on whether the reaction is upgrading or downgrading (^{10, 12}). ENL is not confined entirely to lepromatous leprosy patients. An occasional borderline lepromatous patient can also develop ENL (⁶). Although it is theoretically possible to demonstrate ENL and an upgrading reaction simultaneously in a patient, to our knowledge such a case has never been reported. In this paper we describe for the first time a lepromatous patient having an ENL reaction coexisting with an upgrading reaction.

CASE REPORT

The subject of the study is a 42-year-old male with a history of lepromatous leprosy since 1960 who had had intermittent treatment with dapsone. Several skin biopsies from this patient were studied every year from 1977 to 1985, except during 1979 and

1980. There were seven biopsies in all. Although the clinical details are meager, all the information available is presented.

The skin biopsies were all fixed in 10% Formalin and were processed for paraffin sections. Five micron sections were prepared and stained with hematoxylin and eosin (H&E) and a modified Fite's stain for acid-fast bacilli (³). The biopsies were classified according to the modified Ridley-Jopling classification of Job and Chacko, in which the mid-borderline patients are included in the borderline lepromatous group and with the addition of a purely neural group (²).

HISTOPATHOLOGICAL STUDIES

Skin biopsy no. 1. The first biopsy was examined in June 1977. The site of the biopsy was not known, but the sections showed skin and subcutaneous tissue. The epidermis had proliferation of the prickle cells but the rete pegs were obliterated. There was a clear zone beneath the epidermis separating a granuloma in the dermis occupying nearly 60% of the tissue. The granuloma was composed of large collections of macrophages with a foamy cytoplasm (Fig. 1). In the deep dermis there were focal areas showing infiltration of the macrophage collections with neutrophils (Fig. 2). Proliferating capillaries were also identified in the granuloma with a marked increase in vascularity. In some areas the granuloma extended into the subcutaneous tissue. Acid-fast staining showed large clumps of bacilli with a bacterial index (BI) of 6+, according to Ridley's scale (¹¹). The morphological index (MI) was 0% (Fig. 3). A diagnosis of lepromatous leprosy with chronic erythema nodosum leprosum (ENL) was made.

Skin biopsy no. 2. In October 1978, another skin biopsy was taken from a plaque-like lesion on the left thigh of the patient. It was mentioned that the patient had a history of ENL.

¹ Wayne M. Meyers, M.D., Ph.D., kindly served as Editor in regard to the submission, review, revision, and acceptance of this manuscript.

² Received for publication on 29 January 1988; accepted for publication in revised form on 13 April 1988.

³ C. K. Job, B.Sc., M.D., F.R.C.Path., F.A.M.S., Chief, Pathology Research Department; R. R. Jacobson, M.D., Ph.D., Chief, Clinical Branch; R. C. Hastings, M.D., Ph.D., Chief, Laboratory Research Branch, GWL Hansen's Disease Center, Carville, Louisiana 70721, U.S.A.

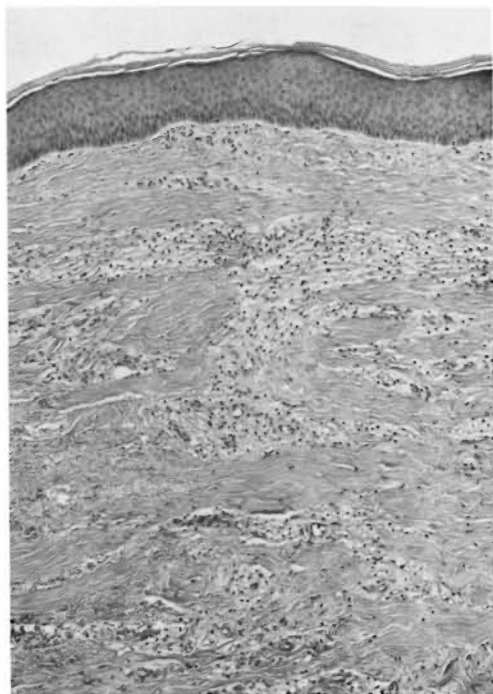


FIG. 1. Photomicrograph showing skin infiltrated by a granuloma composed almost entirely of foamy macrophages (H&E $\times 80$).

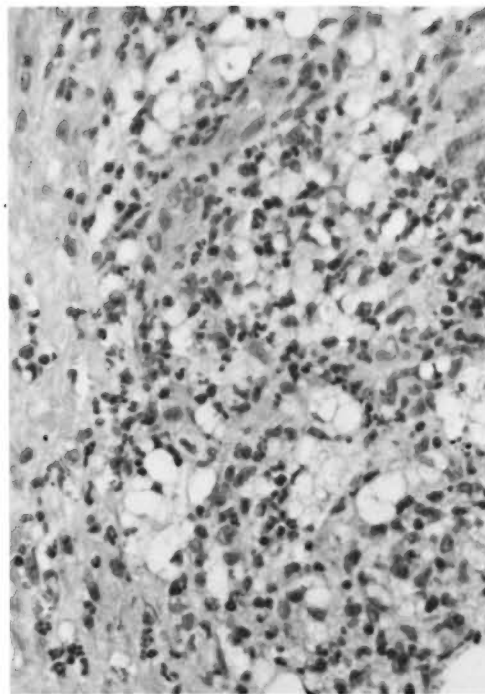


FIG. 2. Photomicrograph of an area in the deep dermis showing large collection of foamy macrophages infiltrated by many neutrophils (H&E $\times 260$).

The histopathological picture of the skin was similar to that described in the previous biopsy. However, there was no evidence of ENL in the sections. The macrophage granuloma showed many giant cells; some of them were of the foreign body type, many were foamy giant cells (Fig. 4). The cytoplasm of the macrophages showed marked vacuolation. The granuloma occupied nearly 60% of the tissue. Acid-fast staining showed a BI of 6+ with a MI of 0%.

Skin biopsy no. 3. Two years later, in February 1981, a third biopsy was taken from a plaque on the left upper leg. In addition to dapsone, the patient had now received rifampin for an unknown period.

The histopathological appearance had not changed. It showed foamy giant cells and foreign body giant cells. The granuloma occupied about 25% of the dermis. The BI varied from 1+ in the superficial dermis to 5+ in the deep dermis and subcutaneous tissue; the MI was 0%.

Skin biopsy no. 4. In December 1982, a fourth biopsy from the left anterior thigh was taken. It was said that the patient had

received dapsone, rifampin, and thalidomide. The sections showed focal collections of a mixture of foamy macrophages and lymphocytes infiltrating the dermis and occupying less than 10% of the tissue. The subcutaneous tissue also showed small focal infiltrations with macrophages. The BI was 4+; the MI, 0%.

Skin biopsy no. 5. In May 1983, a fifth biopsy was taken from the right anterior thigh. The patient was receiving rifampin, dapsone, and thalidomide. The histopathological appearance was characteristic of resolving lepromatous disease with a flattened epidermis, a clear zone beneath it separating it from a small, foamy macrophage granuloma in the dermis. No acid-fast bacilli (AFB) were seen.

Skin biopsy no. 6. In October 1984, a skin biopsy taken from the left thigh showed the most interesting histopathological appearance, the subject of the present paper. It was said at that time that the patient had lepromatous leprosy with ENL, and was receiving dapsone, rifampin, and thalidomide.

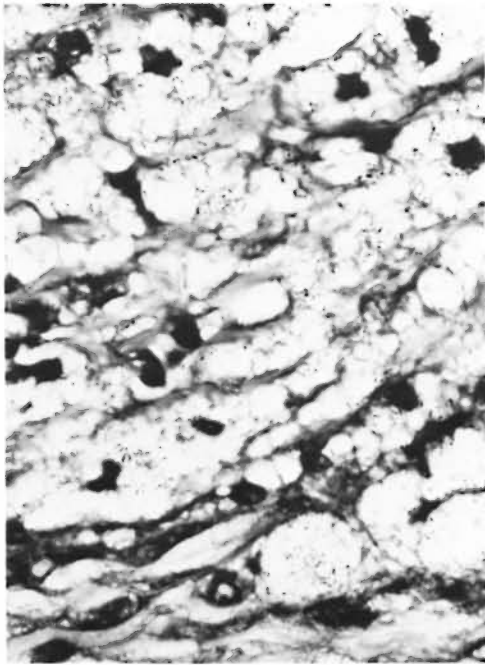


FIG. 3. Photomicrograph showing foamy cells containing numerous broken and granular AFB (modified Fite's stain $\times 700$).

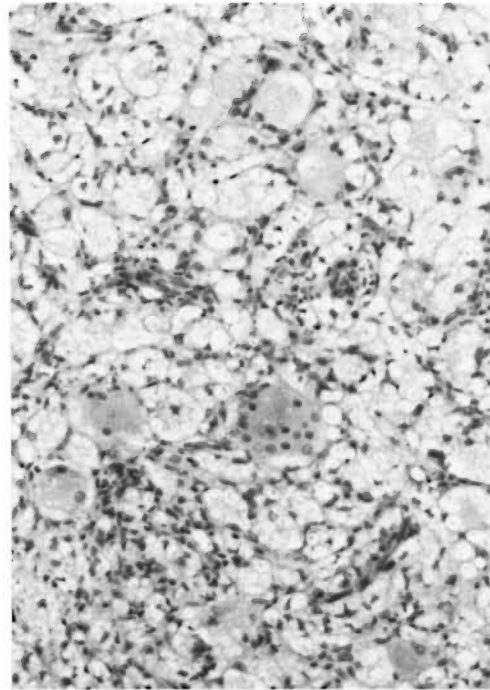


FIG. 4. Photomicrograph showing vacuolated macrophages and several foamy giant cells often present in advanced lepromatous leprosy (H&E $\times 175$).

The sections showed areas of atrophy and hyperplasia in the epidermis. Nearly 70% of the dermis was replaced by an inflammatory granuloma composed of focal areas of macrophages infiltrated by collections of neutrophils forming microabscesses (Fig. 5). The microabscesses were surrounded by a palisade of epithelioid cells (Fig. 6). In the middle of the neutrophil collections there were large vacuoles. In the deep dermis, granulomas composed of many epithelioid cells, lymphocytes, and giant cells were also present (Fig. 7). In the subcutaneous fat there were small focal collections of foamy macrophages. Acid-fast staining showed numerous AFB inside the large vacuoles (Fig. 8) and foamy macrophages. The BI showed considerable variation from field to field, ranging from 0 to 5+. The histopathological appearance was consistent with lepromatous leprosy undergoing an upgrading reaction simultaneously with an ENL reaction.

Skin biopsy no. 7. In December 1985, a skin biopsy was taken from the left knee of this patient who was reported at that time to have ENL clinically.

The sections showed proliferation of the epithelium and focal collections of macrophages and lymphocytes around skin adnexa with many neutrophils among them. Acid-fast staining showed no organisms. This appearance was consistent with a resolving phase of ENL in a patient with lepromatous leprosy.

DISCUSSION

The first skin biopsy in 1977 showed large collections of macrophages with a foamy cytoplasm containing AFB with a BI of 6+. In addition, there were many scattered neutrophils and a sprinkling of lymphocytes. This histopathologic appearance is characteristic of lepromatous leprosy with ENL in the chronic or healing phase. The skin biopsy from the left anterior thigh, done 5 years later in December 1982, showed a reduction in the BI to 4+, and the skin biopsy from the right anterior thigh done 6 months later showed no acid-fast organisms. It is very uncommon for the BI to go down from 4+ to 0+ in a period of 6 months in lepromatous leprosy. Therefore, it is reasonable to infer that this patient showed dif-

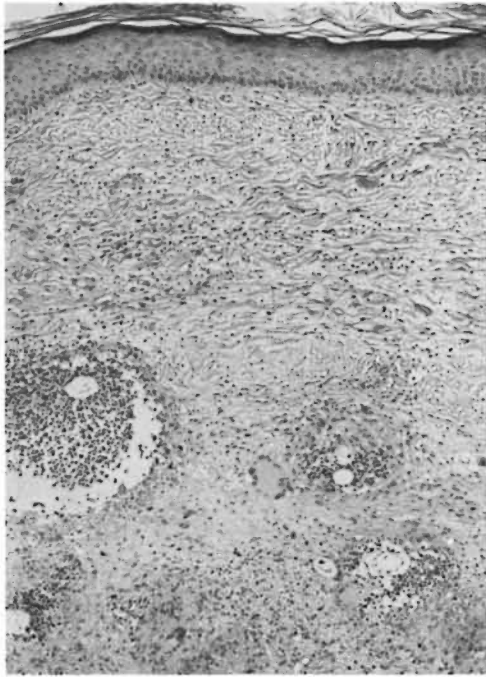

FIG. 5. Photomicrograph showing several microabscesses encircled by epithelioid cell collections (H&E $\times 175$).

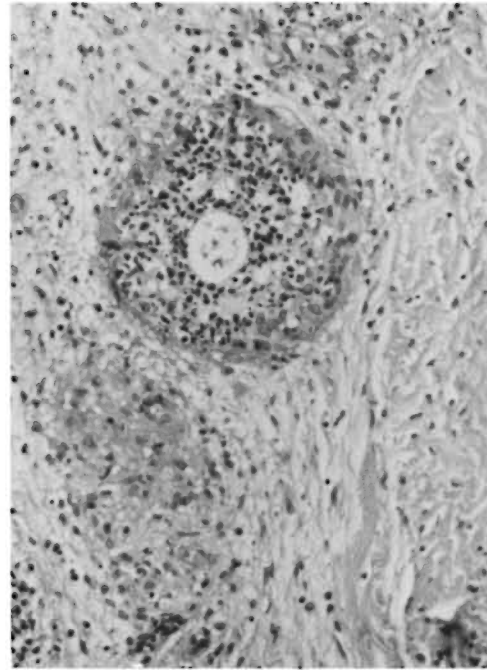


FIG. 6. High-power photomicrograph clearly showing epithelioid cell collections surrounding neutrophils (H&E $\times 175$).

ferent degrees of immunity in different areas of the body unlike a true lepromatous patient.

The skin biopsy obtained from the left thigh in October 1984 showed large vacuoles containing numerous granular AFB surrounded by neutrophils forming microabscesses. The microabscesses were bordered by a palisade of epithelioid cells. There were also other areas in the deep dermis with tuberculoid granulomas composed of numerous epithelioid cells and giant cells. In 1955 Wade (¹⁴) reported that lepromatous patients during sulfone therapy developed focal lesions clinically resembling ENL nodules but histologically showing a tuberculoid granuloma. He described this condition as "induced tuberculoid reaction" and also coined the term "reversal reaction" because he thought that these patients were secondary lepromatous patients who had evolved from the borderline spectrum and that it was their attempt during antileprosy therapy to return from the lepromatous state to the more resistant borderline or tuberculoid stage.

The unusual feature in this case is the presence of neutrophils infiltrating macrophage granulomas, typical of ENL, in addition to the "induced tuberculoid reaction." To date the pathogenesis of reactions in leprosy is unclear. It has been suggested that ENL is an immune complex disease like an Arthus' phenomenon (¹⁶). It has also been shown that the immune complex formation, unlike in the Arthus' reaction, was extravascular (¹³). Recently, there has been an emphasis on enhanced T-cell response to *Mycobacterium leprae* in lepromatous patients developing ENL (^{8,9}). The tuberculoid granulomas found in nonlepromatous patients are delayed hypersensitivity granulomas in response to antigens of *M. leprae*, and a reactive episode in them is only seen as an intensified hypersensitivity reaction attributed to a rapid increase in cell-mediated immunity.

This patient with lepromatous leprosy during the ENL reaction also developed a delayed hypersensitivity reaction to *M. leprae*. We are unable to offer an adequate explanation for this unusual manifestation.

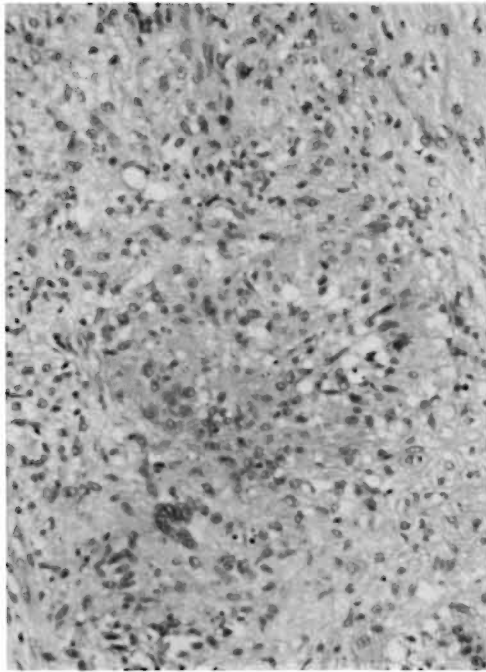


FIG. 7. Photomicrograph of an area in the deep dermis containing an epithelioid cell granuloma (H&E $\times 175$).

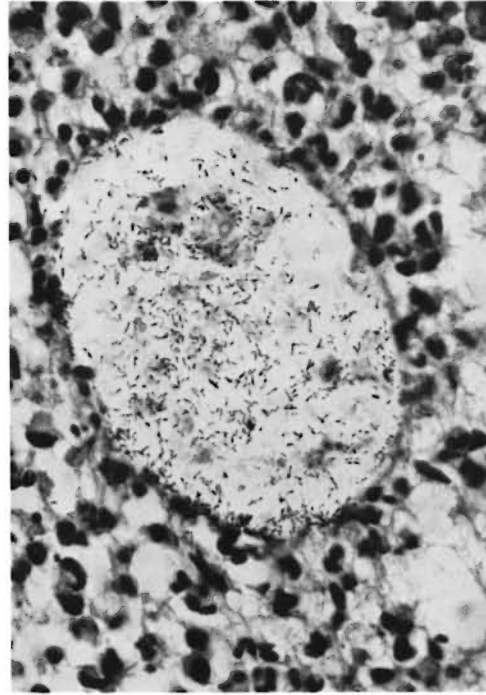


FIG. 8. Photomicrograph showing a vacuole containing numerous granular AFB surrounded by neutrophils (modified Fite's stain $\times 700$).

The upgrading was apparently a transient phase, because the biopsy done in December 1985 showed a lepromatous granuloma with evidence of ENL. A viral infection was reported to have produced a granulomatous reaction in lepromatous nude mice (⁴). Could it be that this patient had a concomitant viral infection which initiated a transient, tuberculoid-type granulomatous reaction?

SUMMARY

A case of lepromatous leprosy with erythema nodosum leprosum (ENL) undergoing treatment with dapsone, rifampin, and thalidomide developed focal tuberculoid granulomas in the ENL lesions. This is the first report known to the authors of a lepromatous leprosy patient in whom ENL and an upgrading reaction occurred simultaneously.

RESUMEN

Un paciente con lepra lepromatosa con eritema nodoso leproso (ENL), en tratamiento con dapsona, rifampina y talidomida, desarrolló granulomas tuberculoideos focales en las lesiones ENL. Este es el primer reporte conocido por los autores, de un paciente con

lepra lepromatosa donde ocurrieron simultáneamente una reacción de tipo ENL y una reacción reversa (con mejoría).

RÉSUMÉ

Un cas de lèpre lépromateuse avec érythème noueux lépreux (ENL), sous traitement par la dapsona, la rifampicine, et la thalidomide, a développé des granulomes tuberculoïdes en foyers dans les lésions d'ENL. Ceci est le premier rapport connu par les auteurs d'un malade atteint de lèpre lépromateuse chez lequel sont survenus simultanément un érythème noueux lépreux et une réaction dite "upgrading reaction."

Acknowledgments. We are grateful to Mr. John Marcell for technical work, Mr. Gregory T. McCormick for assistance in photographic work, and Ms. Mary M. Jackson for secretarial help.

REFERENCES

1. IYER, C. G. S. and NATH, P. B. Histopathological features of reactions in lepromatous leprosy. *Lepr. India* **37** (1965) 4-9.
2. JOB, C. K. and CHACKO, C. J. G. A simplified 6-group classification of leprosy. *Lepr. India* **54** (1982) 26-32.

3. JOB, C. K. and CHACKO, C. J. G. A modification of Fite's stain for demonstration of *M. leprae* in tissue sections. *Indian J. Lepr.* **58** (1986) 17-18.
4. JOB, C. K., CHEHL, S. and HASTINGS, R. C. Bacillary clearance in a lepromatoid nude mouse following an infection with mouse hepatitis virus. *Lepr. India* **55** (1983) 177-178.
5. JOB, C. K., GUDE, S. and MACADEN, V. P. Erythema nodosum leprosum, a clinico-pathological study. *Int. J. Lepr.* **32** (1964) 177-184.
6. KARAT, A. B. A., JOB, C. K. and KARAT, S. Erythema nodosum leprosum in borderline leprosy; report of a case. *Int. J. Lepr.* **35** (1967) 17-24.
7. MABALAY, M. C., HELWIG, E. B., TOLENTINO, J. G. and BINFORD, C. H. The histopathology and histochemistry of erythema nodosum leprosum. *Int. J. Lepr.* **33** (1965) 28-49.
8. MODLIN, R. L., GEBHARD, J. F., TAYLOR, C. R. and REA, T. H. *In situ* characterization of T lymphocyte subsets in the reactional states of leprosy. *Clin. Exp. Immunol.* **53** (1983) 17-24.
9. RAO, T. D. and RAO, P. R. Enhanced cell-mediated immune responses in erythema nodosum leprosum reactions of leprosy. *Int. J. Lepr.* **55** (1987) 36-41.
10. RIDLEY, D. S. Reactions in leprosy. *Lepr. Rev.* **40** (1969) 77-81.
11. RIDLEY, D. S. *Skin Biopsy in Leprosy*. Basle: Ciba-Geigy Ltd., 1977, p. 54.
12. RIDLEY, D. S. and RADIA, K. B. The histologic course of reactions in borderline leprosy and their outcome. *Int. J. Lepr.* **49** (1981) 383-392.
13. RIDLEY, M. J. and RIDLEY, D. S. The immunopathology of erythema nodosum leprosum; the role of extravascular complexes. *Lepr. Rev.* **54** (1983) 95-107.
14. WADE, H. W. A tuberculoid like reaction in lepromatous leprosy, a reactional reversal phenomenon. *Int. J. Lepr.* **23** (1955) 443-446.
15. WATER, M. F. R., TURK, J. L. and WEMAMBU, S. N. C. Mechanism of reactions in leprosy. *Int. J. Lepr.* **39** (1971) 417-428.
16. WEMAMBU, S. N. C., TURK, J. L., WATERS, M. F. R. and REES, R. J. W. Erythema nodosum leprosum; a clinical manifestation of the Arthus phenomenon. *Lancet* **2** (1969) 933-935.