

THE SKIN LESIONS OF NEURAL LEPROSY
IV. OBSERVATIONS IN MADRAS,
SOUTH INDIA

BY H. W. WADE, M.D.,
Medical Director, American Leprosy Foundation
Culion, Philippine Islands

R. G. COCHRANE, M.D.,
Medical Officer,

AND M. PAUL RAJ, L.M.P.
Assistant Medical Officer
Lady Willingdon Leper Settlement
Chingleput, Madras

The present report concerns an extension, to patients of the Indian race, of the study of the leprides that has been dealt with in the preceding articles of this series. Besides the original objective of determining conclusively the essential nature of such lesions, the purpose has been to contribute if possible to an understanding of variations of the disease in different races. To that end the present writers undertook, in the early part of 1936, a joint investigation of the skin lesions among the patients in the Lady Willingdon Settlement near Madras. This study, besides confirming previous observations on leprides in patients in the Philippines and China, has permitted a considerable extension of the inquiry, particularly as regards the less exuberant forms of these lesions.

MATERIAL STUDIED

This material differs in certain respects from that of the preceding studies. With regard to the lesions—aside from the factor of regional variations—all but a few of the patients were resident in an institution that admits neural cases, and in many of them their condition had become more or less modified. With regard to the work, the circumstances permitted relatively detailed investigation of the cases, and multiple specimens were taken from a considerable number of them—actually 93 from the 42 cases here dealt with, the maximum being 5, the average 2.2. A technician and the necessary equipment having been brought to India from Culion, histological sections of a majority of the

specimens removed were examined on the spot and checked with the patients, thus permitting direct correlation of the clinical and histological conditions.

The patients selected for study included all of those with the more frank tuberculoid lesions that were found in about 600 of the approximately 700 inmates, and others to provide a representative selection of the lesser leprides. The group comprised forty-nine cases, including two which had been classified on admission as cutaneous because of positive bacteriological findings, but seven are not considered here; two with lesions that were transitional or converted to the lepromatous state and five with very slight or undeveloped ones will be dealt with elsewhere. The sex distribution is 36 males and 6 females, a fact of no significance. The age distribution is: under 9 years, 2 cases; 10-14 years, 15 cases; 15-19 years, 13 cases; 20-29 years, 5 cases; 30 or over, 6 cases. There may have been a tendency to accept young applicants for admission to this institution, but it seems apparent that leprides of the more interesting kinds are especially prone to occur in young persons.

These patients were examined two or three times and clinical notes were made as precisely as was possible to us at the time, and follow-up observations have been made recently on the cases that were then available. In some instances special search was made for enlarged nerves as is done in the Calcutta clinic. Bacteriological examinations were made by the scraped-incision method on all but four patients, from 6 to 13 smears being made per case (average 8), including smears from both ear lobes and the nasal mucosa on both sides in all instances. As many of the photographs as possible were taken before the surgical work was done, and several cases were rephotographed later because of changes that had taken place in the interim.

Most of the specimens were removed and sectioned during the period of a month when the senior author was absent; those taken after the patients were re-examined were processed at Culion. The examinations were made as previously in this study, using 10, 15 or 20 serially-cut sections on five slides, one of them stained for bacilli. When indicated another and larger series (from 50 to 200 and more sections) was made; in several instances changes were thus found that were not present in the original set. The specimens in general were more adequate than ordinarily, usually including the upper part of the subdermis, to which the pathological process often extends even in slight-appearing lesions.

PRESENTATION OF FINDINGS

The cases are grouped, under the classification used in previous reports of this series, according to the principal lesions that were biopsied: the multiple specimens that were taken do not neces-

sitate, for present purposes, dealing with them differently. For the most part they are presented very briefly; the voluminous notes accumulated, though potentially valuable for detailed study of future changes in the individual cases, could not profitably be given in detail. For comparison, occasional references will be made informally to cases studied in Cebu and China, or to illustrations in the corresponding reports.

In summary, the cases are classified as follows:

Major tuberculoid, active to residual.....	7
Minor tuberculoid and intermediate.....	6
Papulate (minor tuberculoid).....	5 18
Simple, active to residual:	
(a) With relatively large macules, well-defined unless residual	9
(b) With more numerous, smaller macules, usually well-defined	6
(c) With more or less ill-defined of otherwise less typical lesions	9 24
TOTAL.....	42

This group is unusual in this series of studies, first, in that the number of "intermediate" and papulate lesions permits special consideration of them, and, second, because of the particular attention given to the "simple" leprides. The latter will be presented and discussed separately from the others.

I. CLINICALLY TUBERCULOID LESIONS

The seven *major tuberculoid* cases range from an unusually severe generalized "reaction" condition (not infrequently seen in Calcutta) to an apparently healed, residual stage, classified solely on the history. They present interesting differences from those studied elsewhere, and special attention was paid the nerve changes. The six cases classified as *minor tuberculoid* are, as a whole, in sharp contrast with those studied in China, representing the condition even more poorly than did the Cebu group. The five *papulate* cases illustrate the retrogressive varieties of that class. With them might perhaps have been included some of the preceding cases, and some of the early ("lichenoid") lesions not discussed here. The essential data on the cases of these subgroups are summarized in Table 1, and further notes are given in the following section.

MAJOR TUBERCULOID LESIONS

The most interesting of the seven cases in this category is the one with acute reaction, which represented about the extreme of that condition as it occurs in this region. It underwent considerable

change in the month that it was under our joint observation, and has retrogressed since then.

CASE 1.—There were (May 10) numerous prominent red, thick lesions, the largest ones with central resolution, confined almost entirely to the face (Fig. 1) and extremities. Left ear extensively affected, the right only in a small area. Nasal septum and turbinates red and swollen, the left side quite blocked. Involvement of hands, including palms, especially noteworthy (Figs. 3 and 4). *History:* Onset ten years previously with macule on one arm, others appearing four years later. Admitted shortly thereafter (1930), presenting several noninfiltrated macules, mostly not anesthetic. Nose and one macule bacteriologically positive; all subsequent examinations negative. Five years afterwards (five months before our examination) the new condition was initiated with a flare-up of the face lesions, followed by others at intervals, including (obviously) new ones. Complaint of joint and nerve pain; fever denied.

Neurology: Ulnar and peroneal nerves enlarged and tender, the former far up the arm. Left great auricular nerve large and prominent, in part nodulate, probably caseous; the right much smaller but with a small lump at the lower end. Dorsal nerves of both hands and several on the arms enlarged and tender, the former probably necrotic. Both infrapatellars enlarged. On the feet and elsewhere nerves located by sensitiveness to pressure. No polyneuritic sequelae except extensive anesthesia of the feet and legs. Most skin lesions sensitive to pain; touch sense also usually unaffected. A decided tendency to hyperesthesia in the infiltrated parts.

Progress: Three weeks later (May 30) lesions subsiding, less swollen and red, all conspicuously scaling (Figs. 2 to 4). This made conspicuous the narrow active marginal zones of some of the large lesions with inactive centers, the lesions of the palms, and irregular bands on the legs that previously had not been noticeable in the hard, tense, shiny skin. Patient debilitated and put to bed; temperature irregular, part of the time slightly raised, on one occasion reaching 101°F.

Bacteriology: Negative in seven smears, from the infiltrated parts of ears, the swollen nasal mucosa, and three skin lesions (two near biopsy scars on face). *Histology:* The first two specimens, from cheek and chin, show the usual changes of marked active tuberculoid lesions. A later one, from a scaling lesion, show the same with considerable disturbance of the epidermis in various stages short of actual erosion. The part of the great auricular that was removed shows marked fibrotic tuberculoid changes but no necrosis; it does not include the nodulation.

The involvement of the nasal mucosa in the above case is unusual. That of the hands, including the palms, was peculiarly conspicuous in this group of patients, two others having it.

In **CASE 2** the hands were the only parts with major-grade changes (Figs. 5 and 6), though lichenoid ones had recently appeared elsewhere. The index fingers were particularly affected, the lesions full and active. In **CASE 3** the first lesions had appeared on the hands (both little fingers), but when examined they had retrogressed to about the state seen in Fig. 7. Specimens

TABLE 1.—Summary of clinically tuberculoid lesions examined.

Explanation: "B+" refers to positive bacteriological findings; other cases negative. "PN" refers to polyneuritic sequelae other than acroteric anesthesia, the most advanced being stated. "(P+)", "(P0)", "(P-)" and "(P?)" refer to subsequent progress: lesions increased, unchanged, diminished and unknown, respectively. "(S)" indicates examination of extra serial sections.

Case No.	Sex and age	Duration and residence	Clinical features with special reference to biopsied lesions	Histological findings
<i>Major tuberculoid lesions</i>				
1	M 16	10 yrs. (4 mos.) 1 mo.	Marked, generalized, reaction. <i>a</i> Cheek. <i>b</i> Chin. <i>c</i> Arm. Scaling; reaction subsiding. <i>d</i> Nerve, great auricular. (P-) Figs. 1-4.	<i>a, b</i> Tuberculoid, marked. <i>c</i> Same; more superficial disturbance. <i>d</i> Fibrotic tuberculoid, without necrosis.
2	M 14	6 mos. 2 mos.	Marked, hands only (lichenoid elsewhere). <i>a</i> Hand, dorsal. <i>b</i> Finger, palmar. <i>c</i> Nerve, dorsal radial. (P-) Figs. 5 & 6.	<i>a, b</i> Tuberculoid, marked. <i>c</i> Tuberculoid, with caseation.
3	F 30	1 yr. 4 mos.	Moderate, hands only. <i>a</i> Wrist, dorsal. <i>b</i> Palm. <i>c</i> Nerve, arm. (P?)	<i>a, b</i> Tuberculoid, fairly marked. <i>c</i> Tuberculoid, with caseation.
4	M 12	8 yrs. 1 yr.	Moderate, retrogressive, wrist (minor elsewhere). <i>a</i> Wrist. <i>b</i> Nerve, radial. (P-) Figs. 7 & 8.	<i>a</i> Tuberculoid, fairly marked. <i>b</i> Fibrotic tuberculoid, without necrosis.
5	M 11	3 yrs. 1 yr.	Moderate, retrogressive, hand and leg only. <i>a</i> Leg. <i>b</i> Nerve, infrapatellar. (P-) Figs. 9 & 10.	<i>a</i> Tuberculoid, fairly marked. <i>b</i> Tuberculoid, with caseation.
6	M 21	5 yrs. 1 yr.	Retgressed (healed?) atrophic areas. <i>a</i> Arm. <i>b</i> Loin. (P?) Fig. 11.	<i>a</i> Tuberculoid, trace only. <i>b</i> Do, very slight infiltration, etc.
7	F 10	8 mos. 0	Slight, active, leg only. <i>a</i> Annular lesion. <i>b</i> Surrounding area (minor). (P?) Fig. 12.	<i>a</i> Tuberculoid, fairly marked. <i>b</i> Do, relatively slight.

TABLE 1.—Continued

Case No.	Sex and age	Duration and residence	Clinical features with special reference to biopsied lesions	Histological findings
8	M 30+	5 yrs. 10 mos.	<i>Minor and intermediate tuberculoid lesions</i> Slight. Marginal elevation in pale macules. <i>a</i> Chest. <i>b</i> Scapula. <i>c</i> Same, central area. (P?) Fig. 13.	<i>a, b</i> Tuberculoid, slight to moderate. <i>c</i> Tuberculoid, trace only, residual.
9	M 12	3 yrs. 9 mos.	Slight. Recent, reddish, coarsely granular, abdomen (x); larger, dry, scaling macules elsewhere. (P?) Fig. 15 and 16.	(x) Tuberculoid, slight to moderate, active; considerable foci superficially.
10	F 13	? 3 mos.	Slight. Two, small, slightly reddish, coarsely granular; (also lichenoid). <i>a</i> Arm. <i>b</i> Leg. (P?).	<i>a, b</i> Tuberculoid, slight to moderate, mostly superficial.
11	F 5	3 yrs. 2 mos.	Slight; atrophic tendency. (x) Early, hazy, finely papulate. (P-) Fig. 17 & 18.	(x) Tuberculoid, slight to moderate; small, isolated foci superficially.
12	M 35	15 yrs. 3 yrs.	Slight. Numerous large macules, residual and active. (x) Scapular, coarsely granular, slight erythema. PN: ulcer. (P+).	Tuberculoid, slight to moderate, superficial foci prominent; apparently active. B+ (extremely few bacilli).
13	F 10	5 yrs. 3 mos.	Modified retrogressive simple. (x) Arm, thickened, finely papulate part. (P?) Fig. 14.	Tuberculoid, moderate; a considerable amount superficial.
14	M 16	6 yrs. 3 yrs.	<i>Papulate (minor tuberculoid) lesions</i> Multiple, mostly retrogressive, multipapulate, "spotty"; active? (Also lichenoid). <i>a</i> Arm, spotty. <i>b</i> Shoulder, spotty lichenoid. (P?) Figs. 19 & 20.	<i>a</i> Tuberculoid, very slight, (S); slight infiltration. <i>b</i> Similar. (In a part of <i>a</i> a complicating banal subacute inflammatory condition.)

15	M 14	4 yrs. 1 yr.	Retrogressive, bimarinate, multipapulate; "spotty" tendency. (x) Loin (three specimens). B+ (two places, near scars). (P-) Fig. 21.	(x) Tuberculoid, trace; slight to moderate infiltration in one specimen only; others residual. (No bacilli found, repeated examinations.)
16	M 15	6 yrs. 5 mos.	Some retrogressive, in part finely papulate; others recent, active? <i>a</i> Arm, papulate. <i>b</i> Abdomen, simple, rough-surfaced. <i>c</i> Nerve, dorsal ulnar. PN: atrophy. (P?) Fig. 22.	<i>a</i> Tuberculoid, slight to moderate; notable superficial foci. <i>b</i> Tuberculoid, slight; little superficial. <i>c</i> Tuberculoid, fibro-caseous.
17	M 17	10 yrs. 1 yr.	Residual? Sparsely fine-papulate. <i>a</i> Arm, papulate. <i>b</i> Back, faint, diffuse, reddish (?). PN: contracture. (P0).	<i>a</i> Tuberculoid, very slight; no papulation (S). <i>b</i> Slight infiltration only (S).
18	M 11	3 yrs. 1 yr.	Residual? Sparsely fine-papulate (also lichenoid). (x) Arm. B+ (P?).	(x) Tuberculoid, trace, no papulation (S); slight infiltration. (No bacilli found, repeated examinations.)

from the palmar surfaces in these cases show no peculiarity, the condition being similar to that in the dorsal surfaces of the same cases.

The three other cases classed as major tuberculoid showed various degrees of retrogression of the lesions.

In CASE 4 there was a considerably reduced macule on the wrist (Fig. 7). This was a mixed case as regards the type of lesions, for there were others of evidently minor grade, the most marked on the face (Fig. 8). In CASE 5 there were two lesions, one on the leg (Fig. 9) that was more reduced than in the last case, probably inactive (clinically and histologically), and one on the hand (Fig. 10) that, though more scarred centrally, was more infiltrated marginally and probably still active. In CASE 6 there were several lesions all of which seemed nearly if not completely healed, with superficial atrophy but no actual scarring (Fig. 11). The condition would ordinarily be assumed to result from a minor-grade lesion (cf. Fig. 18), but originally (a year before) these lesions were definitely of the major class. In consonance with the actual appearance, only a "trace" of tuberculoid change is present (two specimens, serial sections).

The lesion examined in the following case was interesting in that there was an apparently secondary major-grade eruption in a much larger, ill-defined area of less severity.

In this case (CASE 7), the major lesion, a small, purplish, annular lepride, of moderate degree but eroded and crusted in parts, with central retrogression (very similar to Case 21, Fig. 17, of the China group), was located above the ankle (Fig. 12). The pathological changes, fairly marked, are specially localized in the superficial zone. The outer lesion could be distinguished only at its upper portion on the leg, chiefly by the palpable deep infiltration; the specimen from that part shows relatively slight changes but more than was expected, involving all levels. This lesion was actually a deep-seated, inconspicuous minor tuberculoid one which had started eight months previously as a small, nonelevated patch that spread; the annular lesion had appeared six months later inside the area that had been covered by the first one.

Enlarged nerves.—Enlargement of cutaneous nerves in relation to the skin lesions was a conspicuous feature of these cases, and biopsy specimens were removed from four of them.

The findings in Case 1 have been given. In Case 2 the dorsal radials of both hands were greatly enlarged and could be followed far up the arms; the biopsied nerve (scar seen in Fig. 5) was caseous tuberculoid. In Case 3 the four dorsal nerves of the hands were moderately enlarged (one biopsied above the lesion, left arm); no others found; ulnars and peroneals not greatly enlarged. The specimen shows caseation. In Case 4 the dorsal ulnar on the right hand (biopsied) was moderately enlarged; the right ulnar at the elbow considerably enlarged and sensitive, the left one not. Right dorsal radial palpable; one nerve on arm barely palpable, sensitive. A small one under the lesion on the right foot and ankle. The biopsied nerve was fibrotic rather than caseous. In Case 5 the dorsal ulnar above the hand lesion was greatly enlarged, probably necrotic; radial palpable but small.

Infrapatellar above leg lesion visible (Fig. 11); though not very large it proved to be caseous. No other enlarged nerves found. In Case 6 both dorsal nerves on both hands were considerably enlarged, left radial palpable high on the forearm. Both ulnars enlarged far up, one tender; both peroneals enlarged. (No biopsy.) In Case 7 no nerve was palpable above the lesion on the left leg, but there was a very large one (sural?) under the affected area, and one on the other leg in relation to a lesion of the heel. (No biopsy.)

Later developments.—There has been great improvement in the cases that were active when examined and that have remained under observation.

In Case 1 the lesions have gradually subsided, though those of the face still show slight infiltration. The great auricular nerve, of which a part was removed, is no longer enlarged or tender. Three bacteriological examinations since biopsy (9 to 11 smears) were completely negative. In Case 2, though untreated, the lesions on the backs of the hands have almost disappeared, and those on the palms are not distinguishable. The index fingers are no longer spindle-shaped. The dorsal radials are still greatly enlarged but not tender; they are possibly smaller than before, especially the right one that had a fusiform swelling. In Case 4 all lesions have subsided markedly; none has obvious micropapulation, and the one on the back of right wrist is almost gone. Nerve at wrist still enlarged. In Case 5 the lesion on the hand is no longer raised and infiltrated, though the ulnar branch under it is still enlarged. The same is true of the infrapatellar; one above the patella is enlarged and slightly tender. No new lesions; general condition good. The other three cases have dropped from sight.

MINOR TUBERCULOID AND INTERMEDIATE LESIONS

Our failure to find any good example of a well-developed minor grade lesion was quite unexpected. In clinical appearance most of the six cases discussed here were really intermediate between minor and papulate or simple, though the pathological changes were relatively marked. In only one was there typical elevation of the edges of the macules, as seen in several of the China cases.

CASE 8 had several pale macules some of which, in parts, were marginally infiltrated and irregular (Fig. 13), rather like the outer lesion in Case 7, above, and undoubtedly slowly progressive. Despite their condition, specimens from the margins of two of them show relatively slight tuberculoid changes. In a specimen from the central part of one of these areas the changes are much less, practically residual.

The lesions in the other five cases were unusual in the very moderate degree of their elevation and particularly as regards the evident focal concentration of the process in the most superficial zone, producing irregularity of the surface that was sometimes so gross that it could no longer be called "granular" or "pebbled" but was actually micropapulate. These lesions may be considered as intermediate.

CASE 9 had on the abdomen a small, fairly recent macule, reddish and obviously active, of coarsely granular surface (coarsening of the grain rather than actual papulation), and with rather diffuse infiltration, more marginal than central (Fig. 15). Histologically there is rather less than the usual "moderate" degree of tuberculoid change, with superficial foci that explain the outward appearance. On the thighs (Fig. 16) were old macules very similar to those of China case No. 26.

CASE 10 had several lesions (some lichenoid) of which the two largest were fairly similar, clinically and histologically, to that of the preceding case, but so small that they were almost completely removed by biopsy.

CASE 11 was peculiar in that, though some of the lesions showed infiltrated marginal zones with coarsely irregular surfaces, in none was the infiltration as marked as would be expected from the degrees of atrophy which they showed (Fig. 18). Below the shoulder was a small, ill-defined lesion evidently representing an early stage of the others, of micropapulate appearance throughout; two months later, when biopsied, it was more definitely hypopigmented but still diffusely outlined (Fig. 17). The specimen shows moderate-degree tuberculoid changes, with subepidermal foci obviously representing the micropapulation but no evident peculiarity to explain the unusual tendency to superficial atrophy. These lesions have progressed slightly.

CASE 12 belongs in this class because parts of some of the numerous, widely distributed old lesions were distinctly infiltrated, elevated and very rough, and slightly erythematous. The specimen is histologically similar to the others of this group, but a very few (2 or 3) bacilli can be found in each section. This is the only specimen from the tuberculoid-class cases that was positive. Unfortunately, the patient had to be hospitalized (removal of a metatarsal) and no photographs could be made. The disease has progressed since the examination more than in any other case.

CASE 13 would go into the finely papulate group (along with Case 16) were it not for the presence of deep infiltration in a part of a lesion on the arm (Fig. 14). A specimen from that part shows a fairly marked degree of tuberculoid change in all levels, a considerable amount of it being subepidermal, as usual.

Nerve changes.—No greatly enlarged nerves were noticed in any of these cases, but one fairly large one was present under a macule on the arm in Case 9. More than that cannot be said, as these patients were not particularly examined in this respect.

Later developments.—It is of interest that in both of the minor tuberculoid cases that have remained in the settlement the disease has progressed, slightly in one and rather markedly in the other. The other patients left before any noteworthy change occurred.

In Case 11 the biopsied lesion on the shoulder has progressed slightly, becoming more obvious than before, though others show retrogression. In Case 13 the biopsied lesion and another one near it are more infiltrated than before, clinically more of the major grade than the minor. A recent biopsy specimen shows a decided increase in the degree of the tuberculoid condition.

PAPULATE MINOR TUBERCULOID LESIONS

The six cases placed here were, as stated, of the retrogressive type, some of the lesions being so thoroughly recovered as to seem almost residual. Examination of the nerves was neglected in most of these cases, but a nerve specimen was taken from one. Only one patient has remained in the institution long enough to provide recent follow-up data.

CASE 14 had lesions that showed a confusion of activity, or attempted activity, and retrogression. A few were recent, including several more or less lichenoid ones, one spotty (high on the shoulder, Fig. 19), another somewhat similar to Fig. 16 of the Cebu report. On the arms were otherwise residual areas indicated chiefly by a few widely spaced papules (Fig. 20), the whole rather like Cebu Fig. 23. On one arm near the shoulder (Fig. 19) and one leg were multipapulate spotty areas on the order of Cebu Figs. 26 and 27. A specimen from the arm lesion shows slight tuberculoid and infiltrative changes, inactive in appearance, with no evidence of papulation except at one place where there is a complicating subacute inflammatory condition.

CASE 15 had a macule (Fig. 21) that was irregularly papulate in the lower portion, somewhat similar to Cebu Fig. 27 but without deep infiltration. It was a broad, annular bimarginate band, limited inwardly as well as outwardly (more smoothly in the former part) by narrow, very slightly elevated zones. Three specimens from this one lesion (all sectioned serially) show at most only rather slight cellular infiltration with a very few tuberculoid foci at widely separated levels, none that could have caused a papulation. The lesions in this case have now faded decidedly, in spite of the fact that two smears taken soon after the biopsy were found positive (sections negative, however) and some lesions were increasing at that time.

CASE 16 represented a nice example of a partly residual lesion with multiple fine papulations in the marginal zone of one part (Fig. 22). Histologically rather more than slight tuberculoid, with superficial foci undoubtedly representing papulations. A specimen from a small "simple" lesion on the abdomen, pale, with perceptible elevation and some irregularity of the surface, shows less change. One from the right dorsal ulnar nerve shows the usual tuberculoid changes with some necrosis.

In CASES 17 and 18 the lesions biopsied, both on the arms, were nearly identical—areas so fully recovered in appearance that for the most part their outlines could not be traced definitely, but with scattered fine papulations here and there, in some instances a trifle palish. The photographs do not show enough to justify reproducing. In the specimen from Case 17 are very slight tuberculoid changes but no focus that could have produced a papule; on the other hand numbers of the hair follicles show gaping and apparent retraction that must have contributed to irregularity of the surface. The specimen from Case 18 shows less abnormality, but the case was not a wholly arrested one, for one smear from the nose and (surprisingly) one from the apparently residual arm lesion were reported positive, bacilli few.

The nerve findings in Case 17 illustrate what may sometimes be found in relation with quite inconspicuous skin lesions: Left

supraclavicular, above a skin lesion, palpable and tender; dorsal radial on the left hand considerably enlarged and tender (those on right hand not, despite the presence of a skin lesion); left ulnar also considerably enlarged and sensitive.

DISCUSSION OF THE TUBERCULOID GROUPS

The number of frank tuberculoid cases found in this institution was small. The major cases constituted barely one percent of the population immediately concerned, and only one case with minor lesions of ordinary type was found, excluding those that also had major ones. The impression gained is that at least the major variety occurs less frequently in this region than around Calcutta, though it is to be said that, since the condition has been especially looked for, more cases have been seen than previously. Future observations on new cases should show whether or not there is a local difference in incidence of that and other kinds of tuberculoid leprides.

We have also to consider the effect of residence in the settlement, which should be expected to reduce the apparent severity of all grades of these lesions. However, most of the patients come voluntarily, and because space is at a premium the admission of cases is largely selective, so it would be expected that there would be a tendency to weight the population in favor of rather than against patients with the more severe and conspicuous forms of the disease. For the most part patients stay only as long as they wish, and by no means all of them take treatment regularly, so on the whole the effect of hospitalization may not be as great as might be expected. Nevertheless, it seems significant that on averaging roughly the time of residence of the cases studied (about 1.5 years for the entire lot), that of the tuberculoid group is but 0.8 years as compared with 2.2 years for those with the simple lesions yet to be discussed. It may be that the latter are induced to stay longer because of a greater prevalence among them of polyneuritic sequelae that stigmatize or otherwise handicap them, but it seems probable that in some cases the lesions which when seen were of "simple" appearance may previously have been more exuberant.

Among the major cases the main feature so far as this study is concerned is the multiplicity and degree of frank involvement of cutaneous nerves, shown histologically to be tuberculoid, with or without caseation necrosis. This involvement is much more striking and apparently more constant in the major form than in the lesser ones, in keeping with its generally more invasive char-

acter. Similar nerve changes have been observed in cases studied in China and in Cebu, but the impression remains that they are especially common and marked in India.

The question has been raised in a previous report (China cases) as to how frequently the major form of the disease arises by progressive evolution of lesser forms, and how often by abrupt onset of apparent "reaction" nature. One case, originally an atypical minor one, has progressed since the examination until it now seems more of the major type. This development has not been stressed heretofore, though it may be of fairly frequent occurrence.

The majority of the cases discussed as minor tuberculoid are, morphologically, more or less intermediate between the variety as ordinarily seen and the papulate and simple groups, but they differ clinically from the latter ones in their evident activity, and histologically in the degree of pathological change. Much of the pathology was in the deeper levels and not very evident to the eye, which emphasizes the necessity of combining palpation with inspection in classifying lesions.

The degree of residual surface change (atrophy) seen in the lesions shown in Figs. 16 and 17 is of interest as indicating an unusually injurious effect of the process in the superficial zone. Comparing them with the one shown in Fig. 11, it would not be evident that the latter resulted from a more severe lesion. It has previously been noted (China cases, especially No. 14, Figs. 11 and 12) that the amount of atrophy that results from these leprides is no criterion of their original degree. On the other hand when, as in Case 4 (Figs. 9 and 10), actual scarring occurs, indicating real injury of the dermis, it can probably always be ascribed to a major-degree lesion. The degree of recovery of the atrophy seen in Figs. 11 and 17 is of interest as indicating regeneration of the injured elements, referring particularly to the fine superficial elastic fibers which the tuberculoid process seems to affect particularly.

Considering together all the lesions with more or less papulate tendency, there may be said to be two groups of them. One kind is progressive, showing obvious activity and an apparent attempt to evolve to a more marked form. The other kind is retrogressive, with apparent attempts in the more or less isolated foci to maintain activity in spite of the factors that tend to overcome the process. This does not imply, however, that all such active cases will necessarily go on to the frank minor stage unless interfered with, or that the retrogressive ones have necessarily been of that kind.

Recognizing two classes of papulate lesions, active and retrogressive, it seems desirable to be precise in our appreciation of what should be called papulate in contradistinction to the "granular" or "pebbled" condition. Papulation is caused by focal concentration of the tuberculoid process under the epidermis at points that are usually more or less well separated, though papules may adjoin or actually fuse. The granular or pebbled condition is a more or less general exaggeration and modification of the natural grain of the skin, consequent on filling and enlargement of the papillae by a relatively diffuse condition. When this goes to the point of abolishing the papillary structure of the skin, a less irregular-surfaced minor tuberculoid lesion results.

Some of the papulate lesions are readily distinguished from granular-surfaced ones by the size and separation of the papulations. However, unless some standard is adopted with regard to the characters mentioned, as is the practice of dermatologists, distinction may sometimes be difficult. Definite papulations may be seen in active lesions such, for example, as those illustrated in Figs. 14, 15 and 16, which are primarily granular; they might, perhaps, be called "granulo-papulate," but their characteristics relate them to the minor tuberculoid class.

The lesions in which distinct papules occur on a noninfiltrated base seem, as a class, to be of retrogressive nature (cf. Cebu report). The influence that tends to overcome the process predominates, but the papules represent spasmodic efforts to progress in spite of that influence. There may be great differences in individual lesions, as in Case 14, and in cases with such lesions new foci may develop (as high on the shoulder, Fig. 19), though that effort may be cut short promptly. The retrogressive trend continuing, a lesion may come to have only a few papulations, as in Fig. 20, in which the otherwise complete recovery of the macule indicates the stubborn persistence of papuleformation.

There is an anomaly in that two of our evidently retrogressive papulate cases were reported bacteriologically positive in smears. In Case 15 two smears from near the biopsy scars were positive, and in Case 18 one from the nasal mucosa on one side and another from the apparently quite residual arm macule; in all instances the bacilli were few, and the other smears were negative. It is possible that these findings were due to technical error, but we are not inclined to that explanation. The possibility that the surgical interference stimulated the condition has to be con-

sidered, because the smears were taken a month and more after removal of the specimens, in which no bacilli have been found, but there was no clinical evidence of such change, then or later.

II. CLINICALLY SIMPLE MACULES

Cases with only simple leprides actually predominate in our group—24 out of 42. These lesions vary widely in morphology, but the most important differences are with regard to activity, the phases being “active” or progressive or presumably so, or quiescent or retrogressive, or more or less residual. In the examination consideration was given to six features: (a) the presence and degree of hypochromia; (b) the definiteness and regularity of outline; (c) the presence of erythema, marginal or diffuse; (d) the character of the surface, whether smooth or irregular; (e) the presence, location and degree of visible elevation of the surface, and (f) thickening or increased density (induration) as perceived by palpation.

Hypopigmentation is not stressed in our records, for it may be slight in an actively progressing lesion and relatively marked in a quiescent one, though recovery is an indication of healing. Diffusion of the outline, which refers mainly to the color change, is of interest in both very early and atypical lesions and in retrogressive ones. Erythema was not common in these cases, which were predominantly quiescent. When it was at all marked it was of course considered the principal sign of activity; but in some instances it was so slight as to be difficult to perceive and of uncertain significance. Elevation was sometimes quite patent, but often it could be perceived only in an oblique light and was not demonstrable photographically. Palpable induration when present was never more than slight in lesions that could be put in the simple category. Unfortunately for precision, the characters of elevation and thickening were not estimated separately but were recorded as a combined feature, “infiltration.”¹

We have arrived at no subclassification of these lesions. If any useful division of them is to be made it must be done on the basis of clinical observation primarily, though of course with an understanding of their pathology such as we have tried to obtain. For present purposes, and with no implication of classification, we have divided them into the following three groups on the basis of morphology, and have arranged them secondarily within those groups according to such evidence of activity as was observed.

¹In the interests of accuracy the term “infiltration” might well be reserved for the microscopic condition, since there may be perceptible elevation or evident increase of density without histological infiltrative changes.

- (a) Cases in which the macules, taking the condition as a whole, were relatively few, large, and well-defined.
- (b) Cases with more numerous macules of smaller size, which in general may be expected to be of shorter duration than the first.
- (c) Cases with more or less atypical lesions.

ILLUSTRATIVE CASES

The principal data on these cases are given in Table 2. To illustrate them we have selected photographs which are fairly representative of the lesions examined except the most residual of them, the pictures of which show little or nothing definite.

Cases with fewer, larger macules.—The loin lesion of CASE 19 was not very pale and the erythema was of course too slight to show, but the elevation is distinct (Fig. 23). The tuberculoid change and cellular infiltration are slight, but the condition does not seem inactive. The specimen from a shoulder lesion seems quite inactive, more or less residual, with only sub-tuberculoid changes in the unimportant foci of cellular infiltration.

The two lesions of CASE 20 are well illustrated in Fig. 24, which demonstrates more clearly than any other the maximum degree of marginal elevation in simple leprides. This is most evident in the lower part, but the upper part (biopsied) was somewhat elevated and the condition was thought to be actually spreading there. Sections show rather slight but apparently active infiltration, chiefly superficial, with only a trace of tuberculoid change. This is in contrast with the findings in the shoulder lesion of the preceding case, which clinically seemed very similar.

The lesions of CASES 21 and 24 (Figs. 25 and 26), the latter of which seemed more quiescent than the former, with less marginal infiltration, were both thought to be active in part and were examined in two places. In both of them the pathology was so slight, even in the slightly elevated, supposedly active parts, that they bordered on residual. (The lesions of CASES 22 and 23 are intermediate between these in appearance, with quite as little pathology; the others of this large-lesion group were not photographed or were too residual to show.)

Cases with more numerous, smaller lesions.—In only one of these cases, CASE 29, did the lesions seem definitely active; the numerous small ones, far from distinct in the photograph (Fig. 27), had appeared recently as a result of recrudescence of the disease. The specimen (larger lesion, scar seen) shows relatively much tuberculoid change and moderate cellular infiltration.

In CASE 30 the lesions on the back (Fig. 28) were small to medium sized; there were numerous small ones anteriorly. Those of CASES 31 and 32 were of similar type and appearance (Fig. 29). One small area on the side in CASE 33 (Fig. 30) shows well its more well-defined ones; larger areas below are more residual. In all of the specimens from these patients the changes are slight. Two from a lesion of CASE 34, though it is too indistinct in the picture to reproduce, shows a similar degree of pathology.

Cases with more or less atypical lesions.—Of this group, CASE 35 had peculiar extensive lesions on the back differing markedly from the ordinary macules, being broad, symmetrically arranged, slightly elevated bands (Fig. 31).

The two uppermost curved up from below to encircle the scapulae; another, lower down, appeared as an inverted V, and still lower a straight one ran across the back. They were all rather diffusely outlined, showed no resolution, and had an odd, slight sheen, suspicious of lepromatous change. Smears were negative, however, and the microscopic picture does not differ from that of ordinary simple macules, though it is rather more marked than usual.

This band-like arrangement, with a tendency to follow the lines of the ribs, was also seen in less degree in CASES 36 and 37 (Figs. 32 and 33). In the former the lesions were not very distinct, but, unexpectedly, the tuberculoid element is about as marked as in Case 35. On the other hand one of the paler, oddly irregular small areas in Case 37 has much less change.

CASE 38 had, among smaller, indefinite lesions, a diffusely outlined, inconspicuous area on each side of the chest and a large, poorly differentiated one over the abdomen (Fig. 34). The specimen from the chest lesion shows moderate infiltration and slight tuberculoid; two from the area on the abdomen (sites marked by scars) both show a practically residual condition. (The lesions of CASES 39 and 40, rather diffuse, show up no better.)

CASES 41 and 42 are of interest in that they had been found bacteriologically positive on admission (and therefore classified as cutaneous under a previous administration), and the latter was still positive when examined. In appearance (Figs. 35 and 36) the lesions are clear-cut leprides. The microscopic picture of the specimen from the former is not typical but has no suggestion of being other than a lepride. Two specimens from the latter case, on the other hand, are quite typical; bacilli are not found in the sections though one of the smears was reported positive. These cases were probably never of the cutaneous type. In both the lesions have decreased.

Nerve enlargement.—Only seven of these cases were specially examined for enlargement of cutaneous nerves. In most of them none was found. In two the radial branches on the hands were enlarged, but not the ulnar branches. A nerve specimen removed from one of them (Case 39) proved to be tuberculoid, without necrosis. No evidence of a skin lesion could be found on the hands.

Subsequent changes.—In nine cases the patients were lost to sight too soon for any change to have been observed or expected.

Explanation of Table 2.—"Infiltrated" without qualification, implies a relatively marked degree of the condition as explained; "faint" is the limit of perceptibility. Infiltration and erythema are marginal only, unless otherwise indicated. Descriptions of lesions refer only to the parts biopsied. The indicated degrees of tuberculoid change and cellular infiltration are roughly estimated and are strictly relative within this group of leprides; the most marked (or "much") would be slight for the clinically tuberculoid leprides. For the tuberculoid changes "slight" signifies a few tuberculoid foci in all sections, "trace" means foci too few to be found in all sections. "Subtuberculoid" means the presence of foci too small or too undifferentiated to be called definitely tuberculoid. Differentiation of small (lymphoid) and large (macrophage) round-cell elements of infiltration is not made, and fibrotic and other residual changes are not detailed; but those elements are involved in the opinions regarding activity, which, however, are tentative. Symbols as in Table 1.

TABLE 2.—Summary of cases with clinically simple lesions biopsied.
(Explanation of table: Symbols as in Table 1. Further explanation at bottom of preceding page.)

Case No.	Sex and age	Duration and residence	Clinical features with special reference to biopsied lesions	Histological findings
19	M 11	7 yrs. 6 mos.	A. Cases with fever, larger macules. Several large pale macules. <i>a</i> Loin, infiltrated, slightly reddish; <i>b</i> Shoulder "infiltrated." (P?) Fig. 23.	<i>a</i> Tuberculoid "much", infiltration slight; active? <i>b</i> Less; subtuberculoid, infiltration very slight; residual?
20	M 15	9 yrs. 5 mos.	Two large pale macules. <i>a</i> Chest, slight infiltration and erythema. <i>b</i> Back, similar. (P-) Fig. 24.	<i>a</i> Tuberculoid trace infiltration slight (S); active? <i>b</i> Tuberculoid trace, infiltration slight, but more (S); active.
21	M 17	4 yrs. 2 yrs.	Marginate macule, buttock. <i>a</i> Margin, slightly infiltrated, finely granular. <i>b</i> Healed center. (P?) Fig. 25.	<i>a</i> Tuberculoid slight, infiltration slight; residual? <i>b</i> Similar but less; residual?
22	F 15	10 yrs. 4 yrs.	Several macules, inactive? Loin, moderately pale, flat. (P0).	Subtuberculoid very slight infiltration (S); residual.
23	M 12	3 yrs. 1 yr.	A few inactive (?) macules. <i>a</i> Buttock, slightly infiltrated, irregular surfaced. <i>b</i> Back, slightly pale, flat, inactive. (P-).	<i>a</i> Tuberculoid trace, infiltration slight (S); residual? <i>b</i> Very slight infiltration only (S); residual.
24	M 14	4 yrs. 2 yrs.	Several slightly pale, mostly inactive. <i>a</i> Thigh, slightly infiltrated part. <i>b</i> Do, flat part. <i>c</i> Buttock, residual? (P-) Fig. 26.	<i>a</i> Subtuberculoid, very slight infiltration (S); residual. <i>b</i> Tuberculoid, trace, infiltration slight (S); residual? <i>c</i> Very slight infiltration only (S); residual.

25	M (?)	(Long) (?)	Extensive old macules, active (?) in parts. Back, slightly infiltrated (P?).	Tuberculoïd slight, infiltration slight; residual?
26	M (?)	(Long) (?)	Multiple macules, some active (?). Back, slightly infiltrated. (P?).	No tuberculoïd or significant infiltrative changes (S); residual.
27	M 19	11 yrs. 5 yrs.	Extensive macules, partly pale, inactive. Shoulder, flat. PN: ulcers. B+ (P?).	Tuberculoïd slight, infiltration slight; residual?
28	M 16	5 yrs. 1 yr.	Several faintly pale diffuse areas residual. Abdomen (as described). PN, atrophy. (P?)	No tuberculoïd or significant infiltrative changes (S); residual.
29	M 23	6 yrs. 4 yrs.	B. Cases with more numerous, smaller macules. Very numerous, very small macules, recent, active. Chest, large, slightly raised and irregular-surfaced. PN, deformities. (P?) Fig. 27.	Tuberculoïd and infiltration relatively marked; active.
30	M 16	8 yrs. 18 mos.	Numerous pale macules, many slightly infiltrated. Loin, active? B+ (chest lesion). (P-) Fig. 28.	Tuberculoïd very slight, infiltration slight (S); active?
31	M 7	3 yrs. 1 yr.	Rather small, pale macules (also lichenoid). a Loin, slightly infiltrated and erythematous. b Buttock, similar. (P0).	a Tuberculoïd slight, "much" infiltration; active. b Subtuberculoïd, slight infiltration (S); active?
32	F 12	4 yrs. 10 mos.	Numerous small macules, many markedly pale; wide zone slightly infiltrated and erythematous. a Scapular. b Do, center, retrogressed. PN, contractures. (P?) Fig. 29.	a Tuberculoïd slight, much infiltration; active? b Tuberculoïd slight, infiltration slight; residual?

TABLE 2.—Continued

Case No.	Sex and age	Duration and residence	Clinical features with special reference to biopsied lesions	Histological findings
33	M 13	5 yrs. 4 yrs.	Some macules recent, active, many more or less residual. <i>a</i> Subscapular, very small, faintly and uniformly infiltrated; active? <i>b</i> Loin, similar (?) <i>c</i> Hip, large, similar part. <i>d</i> Do, flat part, inactive? (P0) Fig. 17.	<i>a</i> Tuberculoid slight, much infiltration (S); active. <i>b</i> No significant change (S); residual. <i>c</i> Tuberculoid trace, infiltration slight (S); residual? <i>d</i> Tuberculoid trace, infiltration slight (S); residual?
34	M 22	(?) 10 mos.	Numerous small macules, indefinite to slightly pale and raised; inactive. <i>a</i> Abdomen, slightly infiltrated. <i>b</i> Do, flat, PN, contractures. (P0). C. Cases with more or less atypical lesions	<i>a</i> Tuberculoid slight, infiltration slight; active? <i>b</i> Tuberculoid trace, infiltration very slight (S); residual.
35	M 18	8 yrs. 4 yrs.	Many lesions, moderately pale, somewhat diffuse; some broad, slightly shiny bands. <i>a</i> Scapular, infiltrated. <i>b</i> Suprascapular, flat, inactive? PN. deformity. (P0) Fig. 31.	<i>a</i> Tuberculoid and infiltration relatively marked; active. (B+) <i>b</i> Tuberculoid slight, infiltration slight; active? (B+).
36	F 12	4 yrs. 9 mos.	Several lesions, mostly indefinite, some in bands; inactive? Subscapular, slightly pale and infiltrated; inactive? (P0) Fig. 32.	Tuberculoid relatively marked, infiltration slight; active?
37	M 50	12 yrs. 5 yrs.	Several small lesions, pale, irregular, diffused, slightly infiltrated and granular. Back, entire lesion. PN, deformities. (P0) Fig. 33.	Tuberculoid trace, infiltration slight (S); active?

38	M 50	20 yrs. 4 yrs.	Several. <i>a</i> Chest, moderately pale infiltrated. <i>b</i> Abdomen, slightly pale and infiltrated. <i>c</i> Do, indistinct flat part. (P+) Fig. 34.	<i>a</i> Tuberculoid slight, relatively marked infiltration (S); active? <i>b</i> Tuberculoid trace, infiltration slight (S); residual? <i>c</i> Similar but less (S); residual.
39	M 24	1 yr. (new)	Several small, moderately pale, slightly infiltrated and more or less erythematous but diffuse. Scapular, small lesion. (P?).	Very slight infiltration only; residual.
40	M 16	8 yrs. 3 yrs.	Extensive merged macules, slightly and uniformly pale. <i>a</i> Subscapular, slightly infiltrated. <i>b</i> Lumbar, similar. PN, contractures. (P0).	<i>a</i> Insignificant infiltration only (S); residual. <i>b</i> Tuberculoid trace, infiltration slight (S); active?
41	M 30	6 yrs. 1 yr.	Few extensive macules, moderately pale, not infiltrated but spreading. (Originally B+) Shoulder. (P-) Fig. 35.	Tuberculoid slight (atypical), relatively marked infiltration; active?
42	M 18	6 yrs. 2 yrs.	Extensive pale macules, well-defined, slightly raised. (B+, few.) Secondary neural? <i>a</i> Arm, slightly raised. <i>b</i> Chest, similar. B+ (slight, several places). (P-) Fig. 36.	<i>a</i> Subtuberculoid, slight infiltration (S); active? <i>b</i> Insignificant infiltration only (S); residual. (No lepromatous changes; no bacilli found.)

In six there has been definite retrogression of lesions. In eight no change has been noted. In only one (Case 38) has there been definite progression. This involved lesions on the back, not examined by us, which became more marked and definite for a few months, though they subsided somewhat after that.

DISCUSSION OF THE SIMPLE MACULES

The outstanding feature of the findings in this group of lesions is the virtually constant occurrence of the tuberculoid condition in slight degree, decreasing with retrogression. The fact had been fairly well demonstrated in previous studies, but not enough cases had been studied to permit drawing definite conclusions. In Table 3 are summarized the findings with respect to that condition in all the specimens examined. All of those in the last three groups were re-sectioned serially.

TABLE 3.—*Tuberculoid changes in the specimens examined.*

1. Specimens recorded tuberculoid (much).....	5
2. Specimens recorded tuberculoid, slight.....	12
3. Specimens recorded tuberculoid, trace.....	12
4. Specimens recorded subtuberculoid only.....	4
5. Specimens without any tuberculoid change.....	8
TOTAL, specimens (24 cases).....	41

The general understanding that lesions of this class show only banal chronic inflammatory changes having been shown to be erroneous, the question remains whether *any* active leprotic macules may be without tuberculoid change. So far as the cases here dealt with are concerned, involving only well-established macules, the specimens that showed no trace of that change were evidently residual. To ascertain more clearly the trend in this material, the relations of degree of infiltration and of tuberculoid change in all the specimens, are shown in Table 4.

Without wishing to stress the point unduly, particularly in view of unavoidable variations in estimating the degrees of infiltration and tuberculoid, it may be said that in general they are closely related. All specimens in which there was relatively much infiltration had more than a trace of tuberculoid change, and none of those with "slight" infiltration lacked at least subtuberculoid foci, and only 2 out of 22 had as little as that. On the other hand no lesion without tuberculoid change had more than very slight infiltration, or any suggestion of activity. There is not as close a parallel in the upper left portion of the table as in the lower right part, but that is to be expected because infiltration

is often relatively more marked than tuberculoid development, especially in active lesions.

With regard to the "subtuberculoid" group, it is probable that the changes indicated represent either incompletely differentiated tuberculoid foci or residual remnants—usually, in this material, the latter. This opinion is supported by the fact that in 10 of the 11 lesions in the "trace" group tuberculoid foci were not found until extra serial sections were examined; in most of them only subtuberculoid foci were found in the original sections.

TABLE 4.—*Relation of degrees of cellular infiltration and tuberculoid change in the specimens examined.*

Cellular infiltration	Tuberculoid changes					Total
	Much ^a	Slight	Trace	Subtbd	None	
Much ^a ...	2	5	—	—	—	7
Slight...	2	8	10	2	—	22
Less....	—	—	1	3	8	12
TOTAL..	4	13	11	5	8	41

^a "Much" signifies relatively much, for the type of lesion concerned.

The conclusion seems unavoidable that the tuberculoid condition is a typical, essential element of all of the simple leprides, though the degree of it is slight in comparison with that seen in any of the clinically tuberculoid leprides, even of relatively low degree. As a matter of fact it is possible that persons familiar only with the pathology of the more conspicuous (major) ones might overlook the least grades of that change, which may very well explain the prevalent idea of the pathology of the simple macules. However, as has been said before, study of large series of leprides of all grades reveals all degrees of the condition, with certain variations in character that evidently depend upon the state of the process. We need only mention here certain technical requirements previously discussed—the necessity of taking adequate specimens from suitable places, and of proper processing and thorough examination of them.

Considerable interest attaches to the question of the clinical distinction between active lesions and inactive or retrogressive ones. That question involves consideration of the pathological changes, but a final answer to it involves careful clinical follow-up, over long periods, of patients in whom the process is not

interfered with by artificial conditions. It is true that detailed tabular analysis of our data shows that it is frequently possible to evaluate by clinical examination the relative degrees of pathological changes present in a lesion. This is seen especially in comparing multiple specimens taken from apparently active and inactive parts of the same lesion (either different parts of the margin, or margin and center), or from separate lesions of the same patient that show similar differences. But it is also true that comparisons of lesions, especially those from different patients, which according to our notes were apparently intermediate between those extremes shows wide inconsistencies. While in a general way those with decreasing degrees of apparent severity of activity show decreasing degrees of microscopic changes, variations are found that indicate marked inaccuracies in our estimation of the lesions. It is evident that there is need of greater precision of observation, and of estimating and understanding elevation, actual thickening or induration, and changes of texture.

It should be appreciated for example that the edge of an area may be perceptibly though slightly elevated without any significant infiltrative change in sections, and such lesions may fail to progress. From the microscopic appearances it seems that dilatation of lymphatic spaces and perhaps low-grade edema may cause slight elevation. On the other hand, considerable infiltrative changes may be found in lesions that have little or no perceptible elevation, and such lesions may progress. It may be suggested that, with experience, careful palpation may perhaps give as much information as visual inspection, consideration being given the effect of more or less permanent changes of residual nature that are left by the process.

SUMMARY

In extension of the study of the leprides in different races, lesions of 42 Indian cases of neural-type leprosy at the Lady Willingdon Leper Settlement in Madras have been examined. Those of 7 cases are classified as major tuberculoid, 6 as minor tuberculoid or intermediate, 5 as retrogressive papulate, and the remaining 24 as simple. As regards activity, these lesions varied from active to residual.

The group differs from those previously studied in the Philippines and China in that there is relative predominance of micropapulate and simple lesions, which difference permits extending the observations on those forms. On the whole the

clinical features are not essentially different from those of the previous groups, though there are noteworthy differences.

Of the major tuberculoid group one case was in severe reaction and underwent interesting changes. Three cases were unusual in that the hands, including the palmar surfaces, were involved; in two of them the first lesions appeared there. Cutaneous nerve involvement was particularly prominent and specimens were taken from five cases; all showed tuberculoid changes, three with caseation.

There was a striking paucity of typical minor tuberculoid leprides, and in five of the cases so classified the lesions were in a sense intermediate with the micropapulate form. The cases placed in the papulate class were of the retrogressive kind, some practically residual, but one especially with attempted progression of the process. The nature of these varieties is discussed.

In the many cases with simple leprides—large and small, few and many, active and residual, typical and atypical—there was much variety but no evident basis for distinct subclassification of the lesions. Taken as a whole they evidence a distinct correlation as regards the pathological changes between the definitely active and definitely inactive ones, but between those extremes there are wide inconsistencies. It is evident that there is need of more accurate appreciation and evaluation of their morphological features.

The findings support the conclusion previously arrived at that tuberculoid change, of correspondingly slight degree, is an essential element of the clinically simple leprides as well as of the frankly tuberculoid varieties. Despite lack of precision in evaluating the degrees of the clinical and histological features, it seems clear that that of the tuberculoid change usually parallels in a general way that of activity or retrogression. In no instance when the lesion appeared definitely to be clinically active, or when there was round-cell infiltration of degree or kind that suggested progressive activity, were tuberculoid changes absent; they were wholly absent only in retrogressed or residual lesions.

DESCRIPTION OF PLATES

PLATE 37

FIG. 1. Thickened major tuberculoid patches, plaque-like and marginate in a reaction state, on cheek and chin. Marked enlargement of the great auricular nerve, evidently with necrosis in one part. Case 1.

FIG. 2. The same patient three weeks later, lesions scaling. Biopsy scars on cheek and chin; also over the great auricular, the nodular part of which was not removed. The skin specimens from this patient show typical marked tuberculoid; nerve specimen fibrotic tuberculoid, not caseous.

FIG. 3. Hands of same patient, dorsal aspect, in the scaling stage. The index fingers are especially involved and thickened.

FIG. 4. Palmar aspect of the hands of the same patient. The swelling of the right index finger is apparent but there is little evidence of involvement of the surface; a small part of the second finger is scaling. Extensive scaling of the left palm.

FIG. 5. Marked major tuberculoid involvement of the hands, dorsal surface; Case 2. Index fingers chiefly involved, with extension upward on hands and to the left second finger. Second and third fingers of the right hand also affected, but to a much less degree. Histologically typical marked tuberculoid, the biopsied nerve with caseation necrosis.

FIG. 6. Palmar aspect of the hands of the same patient, the extent of the affection indistinguishable. Histological changes (biopsy site marked) not essentially different from the dorsal surface.

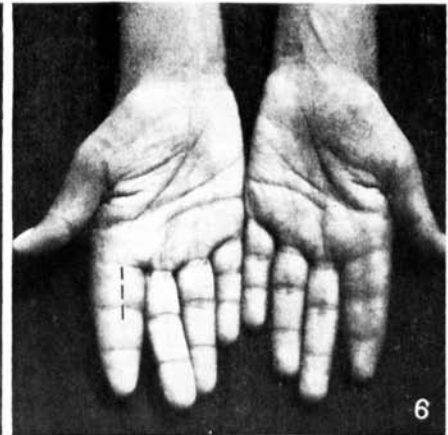
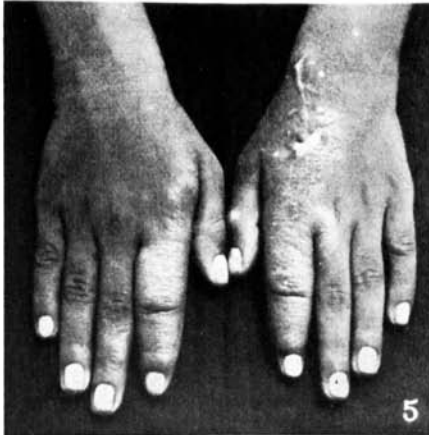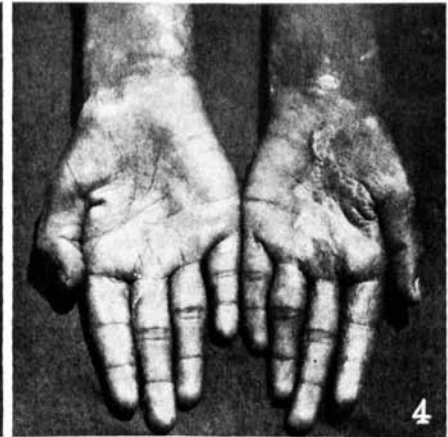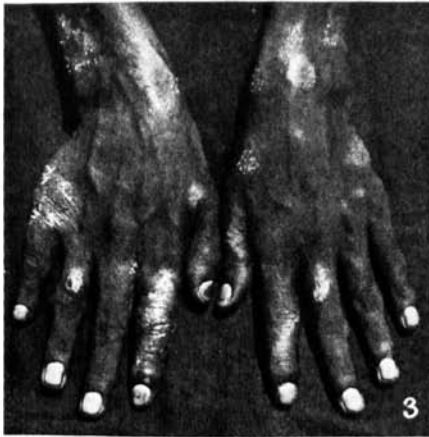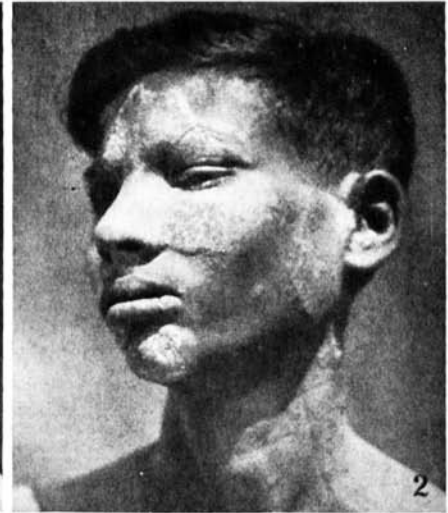


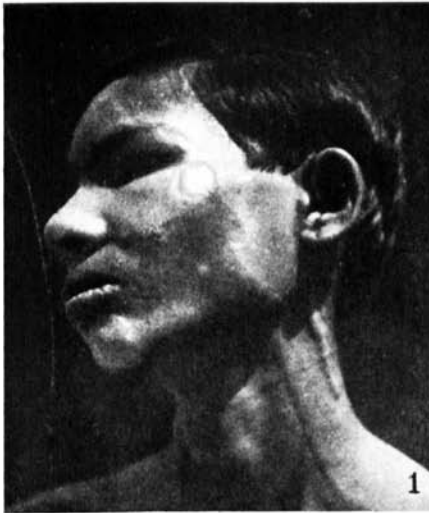PLATE 37

PLATE 38

FIG. 7. A somewhat retrogressed major tuberculoid lesion of the lower forearm, originally much thicker and red; Case 4. The process has extended downward over the hand, lateral half, but here the lesion is relatively slight and was never definitely raised except at the advancing edge. Histologically fairly marked tuberculoid (biopsy site marked); the nerve fibro-tuberculoid, not necrotic.

FIG. 8. Face of the same patient, showing an evidently minor grade macule (not biopsied) extending from the chin onto the cheek. No perceptible enlargement of the great auricular.

FIG. 9. A much-retrogressed major tuberculoid macule below the knee; Case 5. Somewhat scarred, with no evident of progression, histologically it still shows fairly marked tuberculoid change. Enlarged infrapatellar nerve visible (arrow).

FIG. 10. Major tuberculoid lesion of the hand, same case. Unlike that of Case 4 (Fig. 7) and the other lesion of the same patient (Fig. 9), it is extending as of that degree, at least on the hand, and healing with considerable atrophy and actual scarring. (No biopsy.)

FIG. 11. Markedly atrophic areas on the arm; Case 6. Caused by raised, erythematous, major tuberculoid patches which have subsided with only superficial damage, resembling more the results of minor degree lesions (cf. Fig. 18). Areas of recovery in the upper patch, presumably indicating regeneration of the superficial elastic-tissue fibers. The specimen (scar seen) shows a practically residual condition, with only a trace of tuberculoid change.

FIG. 12. An unusual, apparently secondary, small annular major lesion, slightly eroded but not of marked degree, clinically or histologically; Case 7. It is located in a large area that had previously been covered by a lesion of less degree, now outlined only in its upper portion (indicated by arrows) by an irregular zone, slightly elevated, considerably infiltrated (palpation), showing histologically moderate-degree tuberculoid changes.

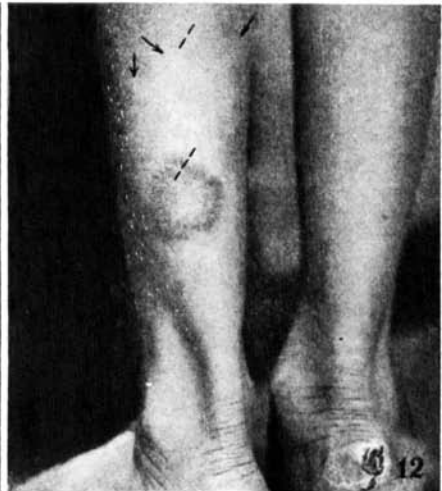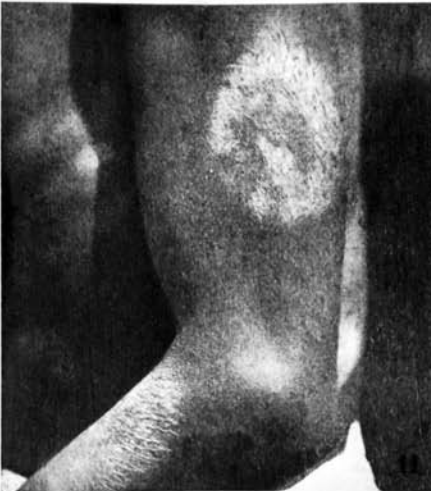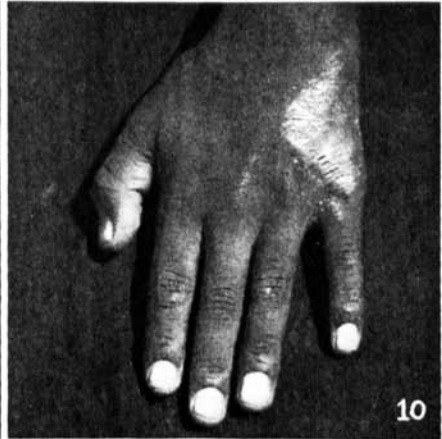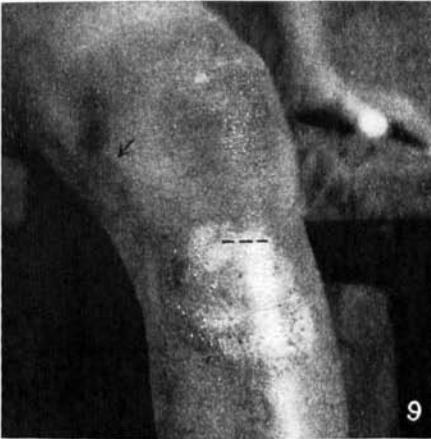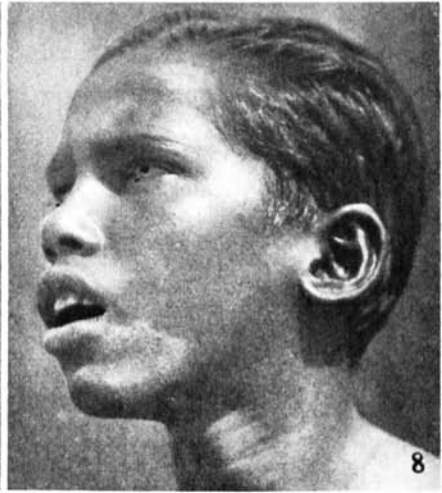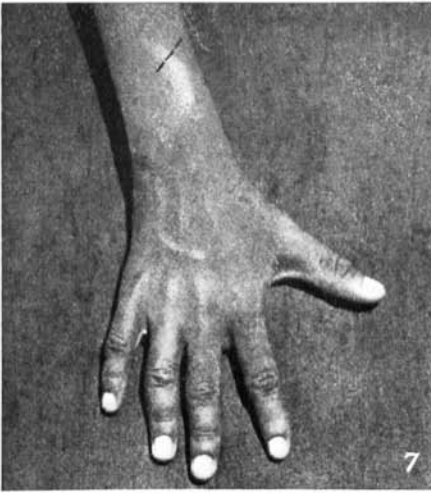


PLATE 39

FIG. 13. Large pale macules, marginally infiltrated, slight degree minor tuberculoid, retrogressive; Case 8. There is some smooth marginal elevation, more evident in the shoulder lesion than elsewhere. Specimens from the margins of two lesions show rather slight tuberculoid changes; one from the central area of one (scapular, both scars seen) shows only a trace, residual.

FIG. 14. Lesions of the arm; Case 13. These would be classed as micro-papulate but for the degree of deeper infiltration in the portion of the margin which was biopsied (scar seen). Sections show tuberculoid changes of moderate degree, rather more than expected.

FIG. 15. A small, recent, active but low-grade minor tuberculoid lesion on the abdomen; Case 9. Somewhat indurated but not much elevated, the surface coarsely granular, more from exaggeration of the grain than from actual papulation. Histologically rather slight tuberculoid, of active appearance, with superficial foci that explain the rough surface. (Cf. Fig. 16.)

FIG. 16. Large areas on thighs, same patient, due to the same process as the abdominal lesion. Less active (probably quiescent), margins elevated only in parts and not sharply demarked at the edge, but with an unusual degree of hyperkeratosis and desquamation. (Not biopsied.)

FIG. 17. A very small, very recent, atypical, slightly hypochromic, diffusely outlined area (1.5 cm.) with fine papulations a little paler than the rest; Case 11. Believed to have started as a "lichenoid" condition (one such area was present elsewhere). Sections show rather slight tuberculoid changes, with isolated superficial foci. (See Fig. 18.)

FIG. 18. Markedly atrophic macules on hip, arm and buttock, same case, due to the seemingly slight-degree process seen in an early stage in Fig. 17. The arm and hip lesions, probably quiescent, show centrally great improvement from the atrophic condition. (Not biopsied.)

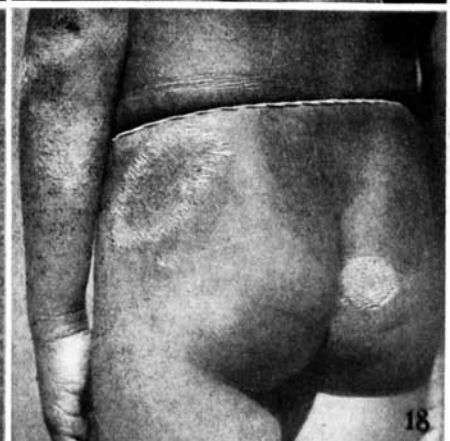
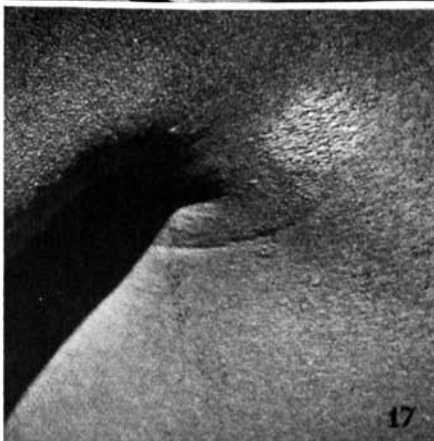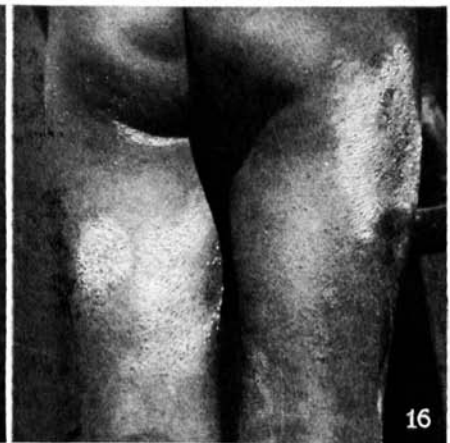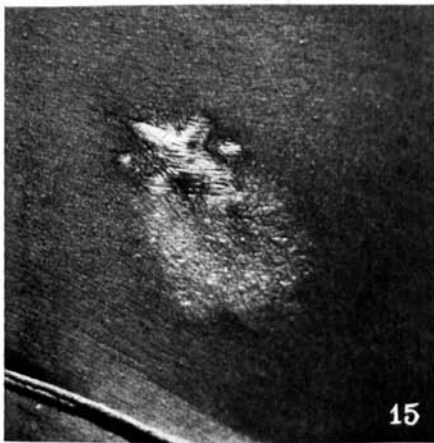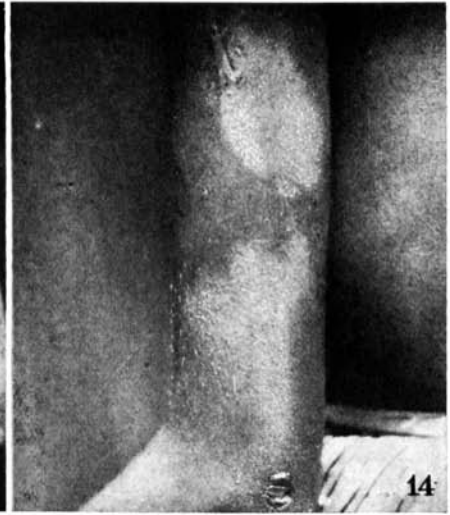


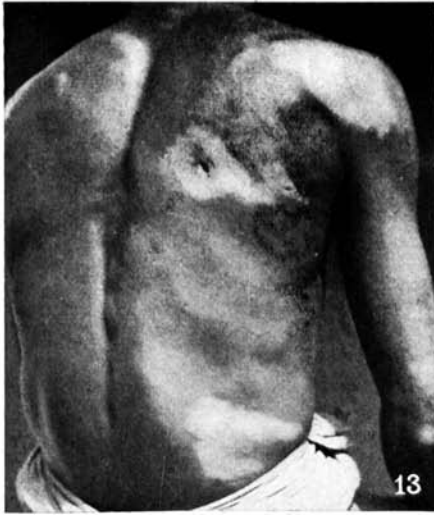PLATE 40

FIG. 19. A rather coarsely and somewhat sparsely papulate, not wholly inactive lesion high on the upper arm; Case 14. The papules are in hazy spots ("spotty" lesion), though many such spots are not papulate. A recent spotty lichenoid group is seen high on the shoulder, and a contrasting lesion is seen in Fig. 20. Specimen from the place indicated shows only slight tuberculoid change.

FIG. 20. An almost completely residual macule on the arm of the same patient, the outline indicated by a few widely separated discrete papules and small hazy spots. (Not biopsied.) The several papules at the elbow are probably of different nature (Nichol's phrynoderma?).

FIG. 21. An irregularly hypochromic, broad-marginate (actually bimarginate) macule of "spotty" character, multipapulate below; Case 15. Of three specimens taken at different places only one shows an occasional tuberculoid focus ("trace") with rather slight cellular infiltration; the others are practically negative.

FIG. 22. A macule of the arm which in part of its margin has many very fine papulations, other parts residual; Case 16. The specimen shows rather slight tuberculoid, with notable superficial foci.

FIG. 23. A simple macule, extensive, irregular and moderately hypochromic, covering the buttocks and extending irregularly up onto the right loin; Case 19. The part on the right has a narrow, slightly reddish, definitely elevated margin. Sections show tuberculoid change of relatively considerable degree, probably active.

FIG. 24. An apparently active simple macule, scapular region; Case 20. Distinct marginal elevation below (about the maximum for simple leprides), slightly elevated and more irregular above, where it was biopsied. Microscopically rather more than slight infiltration, suggestive of activity, but only traces of tuberculoid change.

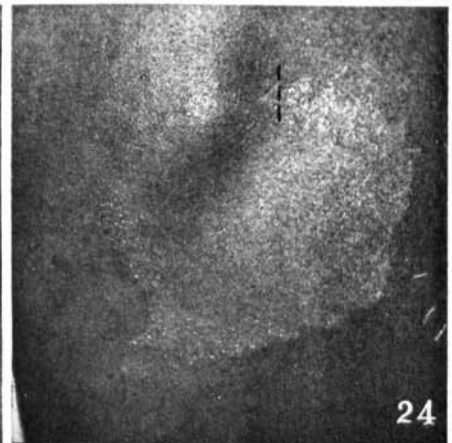
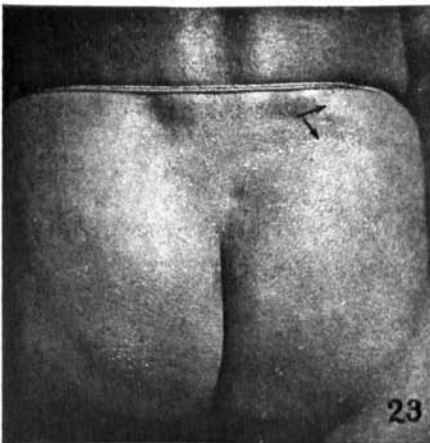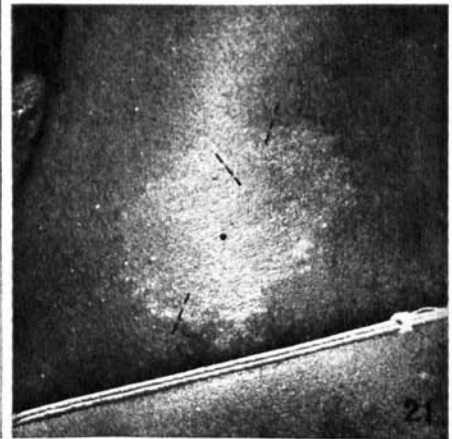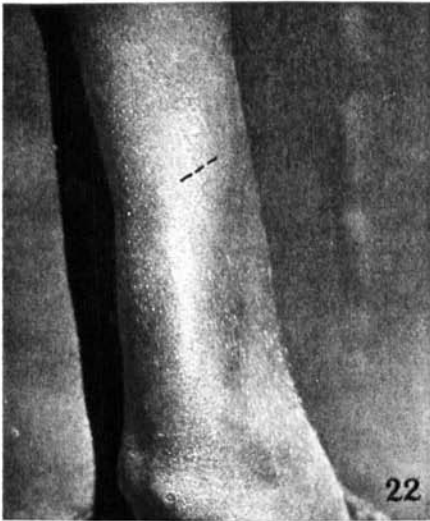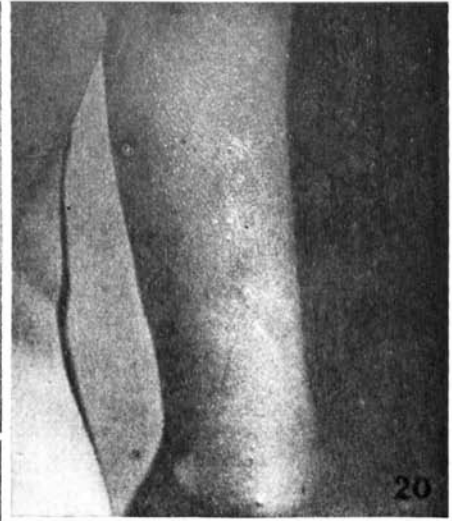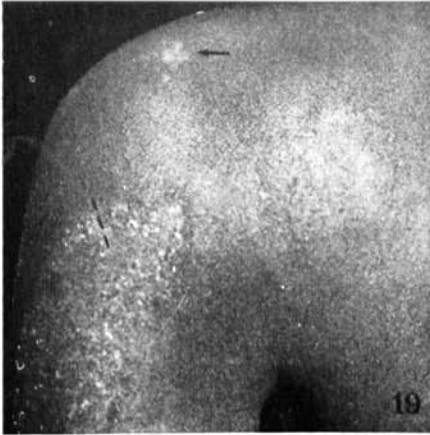


PLATE 41

FIG. 25. A simple macule of the buttock, marginally slightly elevated; Case 21. Similar in appearance to Fig. 24, but with less elevation. A specimen from the supposedly active upper edge shows slight tuberculoid, not suggestive of activity; one from the partly resolved central area shows similar changes but of less degree and more definitely residual.

FIG. 26. A more quiescent-looking macule than the preceding ones but not residual, very slightly elevated in the lower portion only; Case 24. Unexpectedly, a specimen from the upper, flat part of the margin shows more abnormality than the one from the lower part; the latter seemed probably residual, the former not.

FIG. 27. Multiple small, moderately hypopigmented, slightly elevated lesions resulting from recent recrudescence in a supposedly recovered case; Case 29. Specimen from the edge of a relatively large area on the chest (scar seen) shows a considerable degree of tuberculoid change for this type of lesion, the whole suggestive of activity.

FIG. 28. Multiple simple macules, small to medium size, on back; Case 30. Rather pale, irregular in outline, those on the lower back especially slightly raised, for the most part marginally. (The appearance of paleness is well shown, if not somewhat exaggerated, by use of panchromatic film.) Specimen from the small area indicated shows slight infiltration and very slight tuberculoid changes.

FIG. 29. Multiple simple macules; Case 32. Rather similar to those of the preceding case, recorded as moderately to markedly hypochromic but less definite in the photograph. (Nonpanchromatic film was used, satisfactory for detail but not as good for demonstrating moderate hypochromia.) Specimen from the margin of a scapular lesion (obscured by local application), shows slight changes of the usual kind. Another from central area (scar shown) has somewhat less, with less suggestion of possible activity.

FIG. 30. Showing one of the several small, slightly elevated, presumably nonquiescent macules; also extensive older, more varied lesions, partly quite residual; Case 33. Sections of a very small one, subscapular, removed entire, show moderate infiltration with slight tuberculoid, possibly active. Three other specimens (sites indicated by arrows, two scars seen) show much less change, more residual.

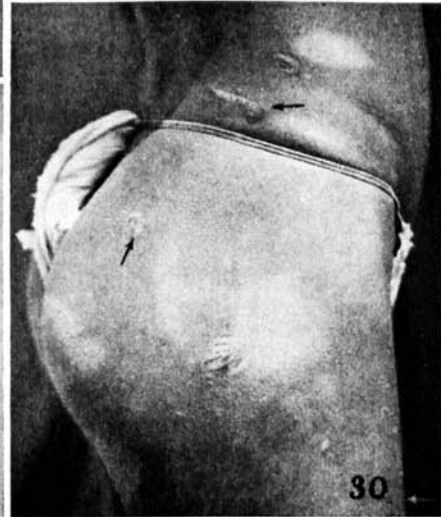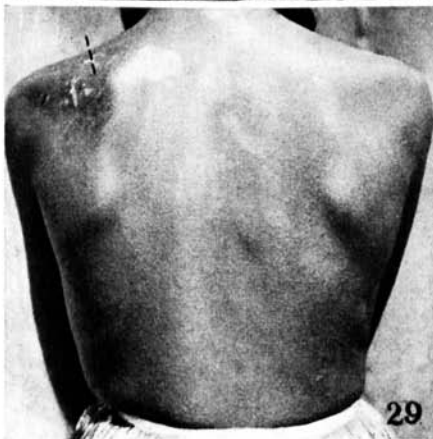
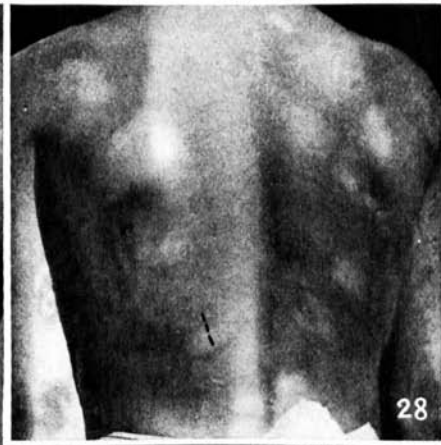
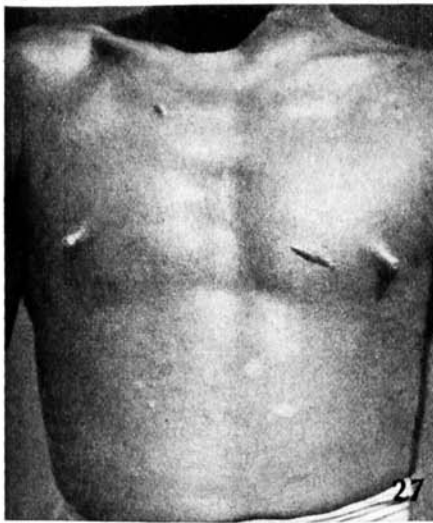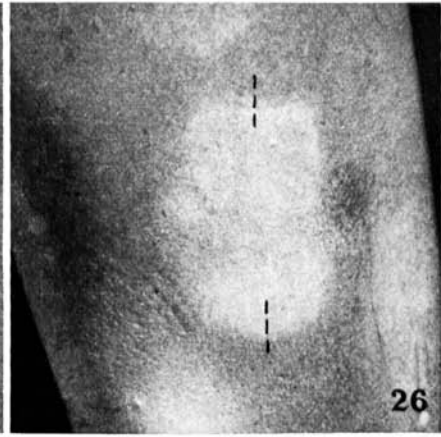
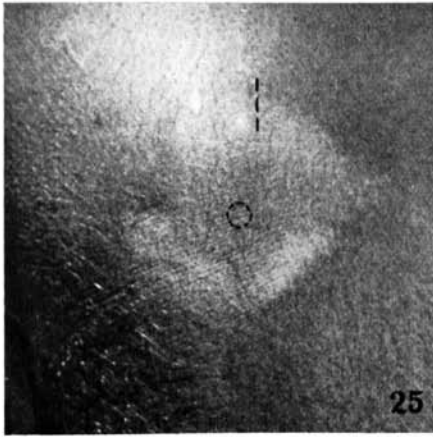


PLATE 41

PLATE 42

FIG. 31. Peculiar broad band-like lesions; Case 35. These zones, moderately hypochromic, slightly elevated, rather diffusely limited and without resolution, encircle the scapulae and cross the back; other, more ordinary macules elsewhere. Suspected of possibly having undergone lepromatous transformation, but two specimens show the usual tuberculoid changes.

FIG. 32. Less distinct macules over the back; Case 36. Some of them are elongate, tending to follow the line of the ribs (cf. Fig. 31). Sections (biopsy site indicated) show relatively much tuberculoid changes, decidedly more than was expected.

FIG. 33. Unusual small, pale, irregular patches over the back, Case 37. Slightly elevated in parts, with an oblique line of them along the lower ribs (cf. preceding figs.). A small area removed (scar seen) shows slight cellular infiltration, with a trace of tuberculoid; lesions probably wholly inactive.

FIG. 34. Two diffusely outlined, slightly and generally elevated macules on the chest, one on each side, and a large, peculiar-looking area on the abdomen, faintly hypochromic and very indefinitely outlined; Case 38. Specimen from the right chest (site indicated) shows slight changes of the usual kind; two from the abdomen (scars seen) show only residual traces of them.

FIG. 35. Extensive, well-defined, typical-looking, nonelevated macules on arm and body; Case 41. Classified as cutaneous on admission because found bacteriologically positive. Negative when biopsied. The specimen (shoulder) shows moderate infiltration, with slight tuberculoid change of somewhat atypical appearance; no suggestion of a lepromatous condition.

FIG. 36. Extensive simple macules of ordinary appearance, in part very slightly elevated at the edges; Case 42. Bacteriologically positive on admission and a few bacilli still to be found. However, two specimens from chest and shoulder show only residual or nearly residual changes, without any suggestion of a lepromatous condition.

