

INFECTION OF THE HAMSTER (*CRICETUS CRICETUS*)
WITH HUMAN LEPROSY, WITH BACILLEMIA *

BY H. C. DE SOUZA-ARAÚJO, M.D., DR. P.H.

From the Instituto Oswaldo Cruz

Rio de Janeiro, Brazil

In February, 1928, I made my first attempt to transmit human leprosy to laboratory animals, and the results obtained in about three years of experimentation were communicated to the Royal Society of Tropical Medicine and Hygiene, at London, in 1931 (7). In those experiments I used fresh emulsions of lepromata enucleated without skin from more than twenty patients, and many lots of animals were inoculated. Different inocula of the same kind showed strikingly different degrees of virulence. First and last, results were obtained that were comparable with those published by Nicolle (1906), Sugai (1909), Duval (1910), Reenstierna (1926) and others. Furthermore, I also obtained lesions not previously described by other workers, namely, tumor-like growths in the abdominal viscera, and cutaneous nodules with alopecia.

The report of those experiments was summarized in the *American Journal of Tropical Medicine* by Soule and McKinley, and it is not necessary to go into details here. Suffice it to say that "systemic infection" (Adler) was obtained in 92 percent of the mice and in 66 percent of the rats inoculated. Of the mice infected, 62 percent presented epiploic nodules, 14 percent granulomata, and 14 percent abscesses in the internal organs.

In later work I was able to confirm these results, but never to obtain generalization of the infection, or leprosy lesions comparable to those found in man. It has been said (Rogers) that hairy animals are not suitable for such experiments. At any rate, my experience enabled me to regard critically any work on this subject.

When Adler's first communication, entitled "Inoculation of human leprosy into Syrian hamster," appeared in 1937 (1), I was sceptical. He said that until then there had not been reported any experiment resulting in heavy infection of an animal inoculated with material from human leprosy. That claim was not

*Read before the 8th American Scientific Congress, Section V., Washington, D. C., May 16th, 1940, to which the author was an official delegate.

correct; in my experiments with various animals I had obtained much more than he had with his hamsters.

Adopting the method of subcutaneous embedding or grafting, he inoculated, in July, 1937, four splenectomized hamsters (*Cricetus auratus*). Thirty-nine days after inoculation one died and was not examined. Another, ill of abortus, was sacrificed (August 31). Imbedded in the abdominal muscles was found a nodule, 1 cm. in diameter, which I believe was formed by reaction around the embedded fragment of leproma. Smears of this nodule showed clusters of typical leprosy bacilli. Smears from the abrasions developed on the abdominal skin as well as of the liver were also positive. The fact that bacilli were found in liver smears, Adler held to prove that "a systemic as well as local infection had been established."

The other two animals were then sacrificed. In the third one there was found, adhering to the abdominal wall, a fibrous nodule 1 cm. in diameter. Smears from this nodule, as well as from the connective tissue around it, were positive for acid-fast bacilli; those from the viscera were negative. In the fourth hamster a leproma had been implanted into the muscles of the left thigh. The embedded material had disappeared. The corresponding inguinal lymph node was enlarged, caseous and rich in acid-fast bacilli.

On the basis of these facts, Adler said that in three animals there was "heavy infection," complicated with "systemic infection" in one of them—all that within six weeks—and he arrived at the conclusion that the Syrian hamster is susceptible to human leprosy.

At the leprosy congress held in Cairo in March, 1938, he presented another paper upon these experiments (2), in which he said that "there was definite multiplication of bacteria at the site of inoculation." Local multiplication of leprosy bacilli is very easy to obtain, even in the more resistant animals, after embedding pieces of lepromas in their muscles. I have often obtained the same multiplication in artificial media around the planted leproma tissue (6). Adler did not produce granulomata or abscesses in the internal organs of his hamsters, though three of four of them had also been inoculated intraperitoneally with leproma suspension.

In January of the same year Burnet (3), at the Institut Pasteur of Tunis, inoculated six young hamsters (*C. auratus*) by implantation of human lepromata between the skin and muscles of the abdominal wall, three of them being splenectomized at the time. On the 220th day after inoculation all six animals were killed. In only one of them—and that one had been reinoculated—was "development of leprosy" recognized. That animal was one of the three not splenectomized, and Burnet concluded that that operation was not necessary to obtain infection. According to his description and to illustrations of a later report (4), there was

formation of a subcutaneous granuloma, starting in the implant, with beginning generalization of the infection in the lymph nodes, spleen, liver and kidneys; but he, also, failed to obtain granulomata in the viscera.

Burnet says: "La masse souscutanée possède la structure d'un léprome," which is a considerable progress upon Adler's experiments. In his conclusions he says:

Le hamster est réceptif pour la lèpre humaine... C'est un premier pas décisif dans la reproduction expérimentale de la lèpre chez un animal de laboratoire.

PERSONAL EXPERIMENTS

On September 11th, 1939, I obtained with Dr. Evandro Chagas ten hamsters, imported from Germany, all adult males, belonging to the species *Cricetus cricetus* (Fig. 1), which had not yet been used for leprosy experiments. They were healthy and very wild and were kept apart, each in a metallic cage. They were fed with cooked potatoes, bananas and sliced oranges. All ten were inoculated on the same day, five with human leprosy and five with murine leprosy. A preliminary report of the results has already been published (8). Only the experiment with human leprosy will be dealt with here.

Five hamsters were inoculated with a fresh leproma emulsion, 1 cc. subcutaneously in the right axilla and 1 cc. intraperitoneally. Thirty-seven days later one died, but nothing abnormal was discovered on examination. The animal was fatty. Smears taken from internal organs were negative for acid-fast bacilli.

On the 75th day (November 25, 1939), the four remaining animals were reinoculated subcutaneously in the axilla with 2 cc. of a fresh leproma emulsion. This inoculum and this route were adopted because they are the most successful in experimental rat leprosy. On December 22nd one of the animals presented an ulceration at the right angle of the mouth, was thin, depressed, sleepy, and with raised hairs. Some days later it was paraplegic and showed irregular alopecia. On February 20th, 1940, it was killed.

Because I had obtained bacillemia in rats infected experimentally with Stefansky's bacillus, I anesthetized the animal with ether and bled it from the heart. A part of the blood taken was inoculated into common media, without results. The rest of it was diluted with 5 percent sodium citrate and centrifuged, and the sediment was washed with distilled water and centrifuged again.

The sediment was smeared on new slides and stained by Ziehl-Neelsen method. Microscopical examination of these slides revealed the most beautiful clumps of Hansen bacillus that I have ever seen in blood. The first five photomicrographs in Fig. 2 illustrate this observation.

The animal was then killed, 163 days after the first inoculation. No macroscopic lesions were found. Smears from the fatty axillary reticulum, which presented the appearance of gelatinous edema (Burnet), and from the liver, spleen and kidneys, were positive for acid-fast bacilli. The central nervous system of this animal was examined and inoculated by Dr. J. C. Teixeira to ascertain whether or not any virus was present. The result was negative. The internal organs were sent to Dr. C. Magarinos Torres, chief of the section of anatomic-pathology of our institute. He reported having found inflammatory reactions, without formation of lepromata.

On March 20th, 1940, 192 days after the first inoculation, two of the remaining animals were bled from the heart in a similar manner; the third one was unfortunately lost during transportation from the animal house, which is at some distance from the laboratory. From one of them 3 cc. of blood was obtained, and a part of it was inoculated subcutaneously into three mice. Only a very small amount of blood was obtained from the other one.

A part of each blood specimen was treated with sodium citrate and centrifuged as before. Examination of the smears proved that both animals were infected by the Hansen bacillus, with bacilemia. On April 15th they were reinoculated, and two days later (when last seen before this report was prepared) they were well.

The longer the observation, the better will be the results. The formation of internal granulomata requires much time; the experimental infection with Stefansky's bacillus requires from six to twelve months to produce characteristic lepromata.

✓ CONCLUSIONS

The work here reported differs from that of Adler and of Burnet in the following points:

1. The species of hamster utilized was *Cricetus cricetus* instead of *Cricetus auratus*.
2. The inoculum used was fresh emulsion of lepromata instead of fragments of the same.
3. The method of inoculation was subcutaneous, in the axilla, instead of embedding in the abdominal wall.

4. Bacillemia was discovered in three of the hamsters by heart bleeding.

5. Two of the animals so examined were reinoculated and left under observation.

ADDENDUM

Of the two hamsters left under observation at the time this paper was written, one died on May 2nd, with a caseous nodule in the axilla. Smears from the kidneys and liver were positive for acid-fast bacilli, though they were very few. The other viscera were negative. The last hamster died on June 10th with alopecia of the back. Smears from the kidneys and liver of this animal, also, showed a few acid-fast bacilli. Smears from other viscera and the blood were negative.

With regard to the three mice inoculated on March 20th with heart's blood of hamster No. 1 (inoculation made subcutaneously over the abdomen), one died 7 days later and was not autopsied because in bad condition. The second one died on April 26th, about five weeks after inoculation. Smears of lymph nodes and liver were positive, bacilli few; those of other viscera were negative. The third mouse died on July 26th, four months after inoculation, with a cervical ulcer the exudate of which contained a few acid-fast bacilli. The lymph nodes were hypertrophic. Smears of the heart's blood, centrifuged, were 2+, those of the liver and kidneys 1+, the others negative. These facts confirm the conclusion that bacillemia had occurred in the hamsters inoculated with human leprosy.

REFERENCES

- (1) ADLER, S. Inoculation of human leprosy into Syrian hamster. *Lancet* 2 (1937) 714-715.
- (2) ADLER, S. Human leprosy in the Syrian hamsters. *Internat. Jour. Lep.* 6 (1938) 467 (abstract).
- (3) BURNET, E. Inoculation positive de la lèpre humaine au hamster. *Compt. rend. Acad. Sci.* 207 (1938) 690-692.
- (4) BURNET, E. Inoculation positive de la lèpre humaine au hamster. Inoculation négative a d'autres rongeurs. *Arch. Inst. Pasteur Tunis* 27 (1938) 327-340.
- (5) SOULE, M. H. AND MCKINLEY, E. B. Cultivation of *B. leprae*, with experimental lesions in monkeys. *American Jour. Trop. Med.* 12 (1932) 1-36.
- (6) DE SOUZA-ARAÚJO, H. C. II. Essais de culture du *Mycobacterium leprae* (*Coccothrix leprae* Lutz, 1886). Isolement à partir d'un lèp-

- romé d'un actinomyces. *Actinomyces lepromatis* n. sp. Compt. rend. Soc. Biol. **100** (1929) 937-939; also Mem. Inst. Oswaldo Cruz **22** (1929) 145-152 (English, pp. 153-160).
- (7) DE SOUZA-ARAÚJO, H. C. Experimental leprosy. Trans. Roy. Soc. Trop. Med. & Hyg. **24** (1931) 577-598.
- (8) DE SOUZA-ARAÚJO, H. C. Inoculação positiva da lepra humana no hamster (*Cricetus cricetus*), com bacillemia. Brasil-med. **54** (1940) 249-252.

DESCRIPTION OF PLATE

PLATE 5

FIG. 1. *Cricetus cricetus*, imported from Germany.

FIG. 2. Photomicrographs 1 to 5 are of bacilli found in smears of the blood obtained by puncture of the heart of hamsters inoculated with human leprosy. Nos. 6 and 7 are of smears from the spleen and liver containing Hansen bacilli.




FIG. 1

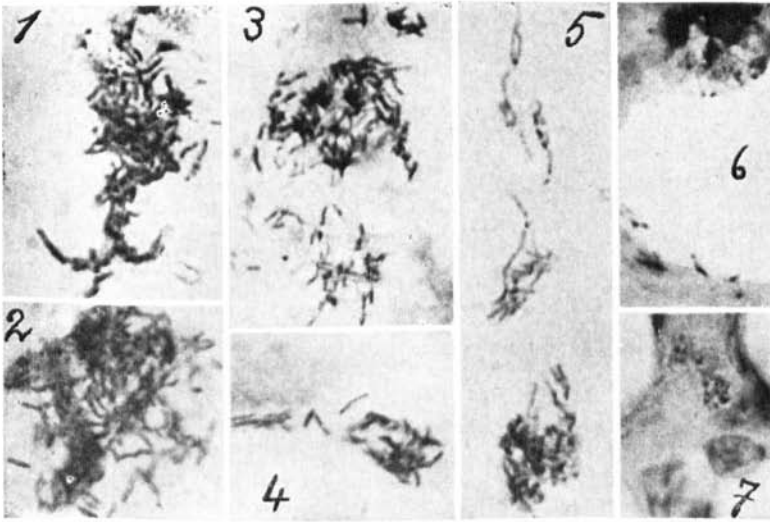


FIG. 2