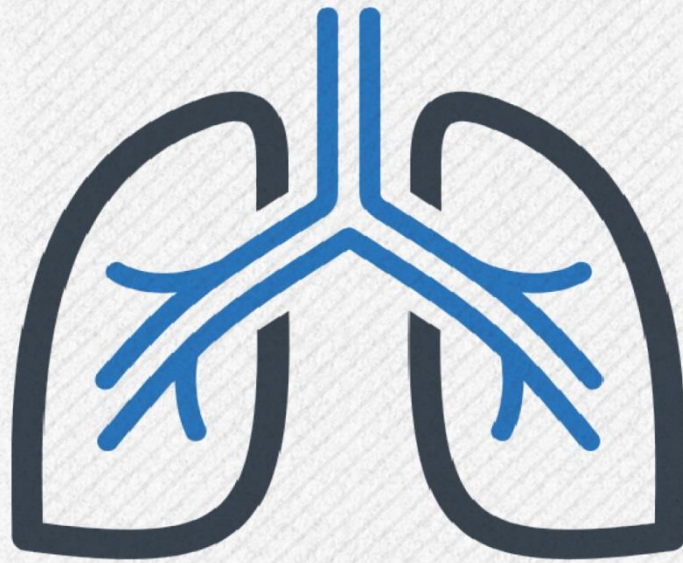
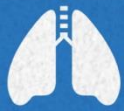


Respiratory system
Anatomy



sheet



handout



slides

Number

Lab #2

Doctor

Mohammad Hisham Al-Mohtaseb

Done by

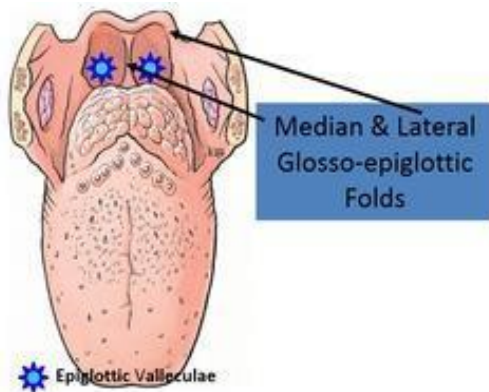
Mahmod Rahhal

corrected by

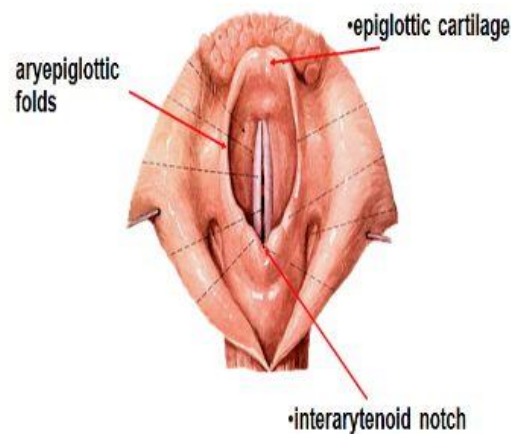
Ammar Ramadan

PART 1:

- Notice the epiglottis and the tongue.
- They are connected medially through the “median Glosso-epiglottic fold”, and on the lateral sides through “lateral Glosso-epiglottic folds”.
- A depression between the medium and the lateral folds; “Valleculae”.

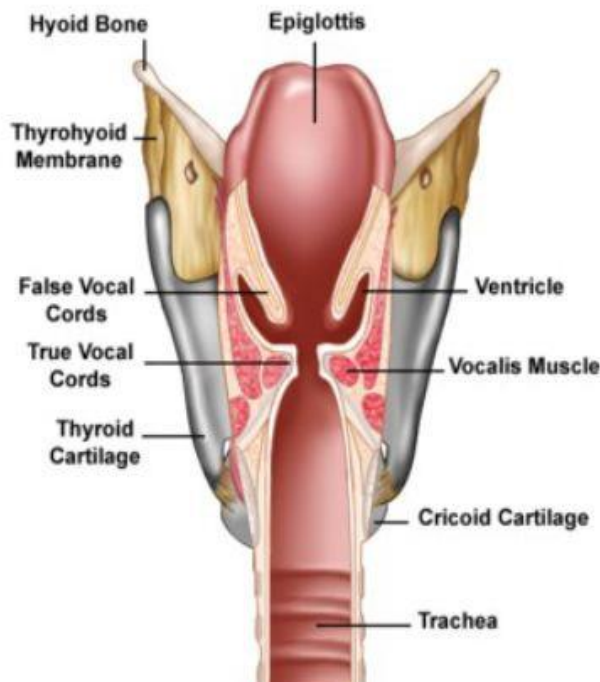


- Inlet of the larynx and its boundaries:
 - Above: free edge of epiglottis
 - Sides: Aryepiglottic fold (which is part of Aryepiglottic muscle)



- During deglutition; the bolus of food pushes the epiglottis downward, and the larynx move upward causing closure of the larynx.

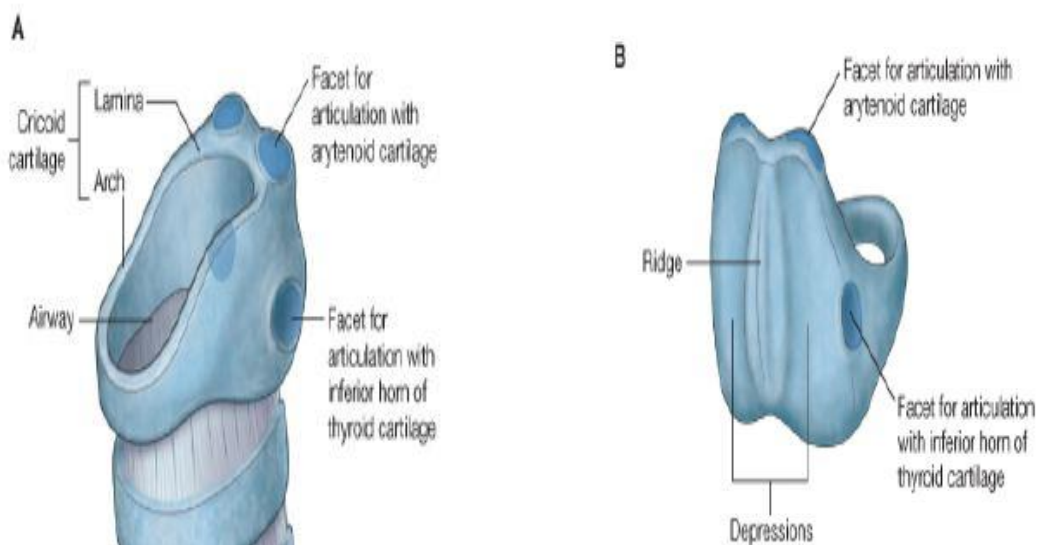
- Next we will observe the vocal cords, the ventricle, the saccule and related structures.



- The doctor focused so much on this part (ventricle, saccule...) !

- It's very important to know the location of the ventricles and saccules.
- Saccules have mucus glands that secrete mucus to lubricate the true vocal cords
- Above the ventricle: False vocal cord
- Below the ventricle: True vocal cord

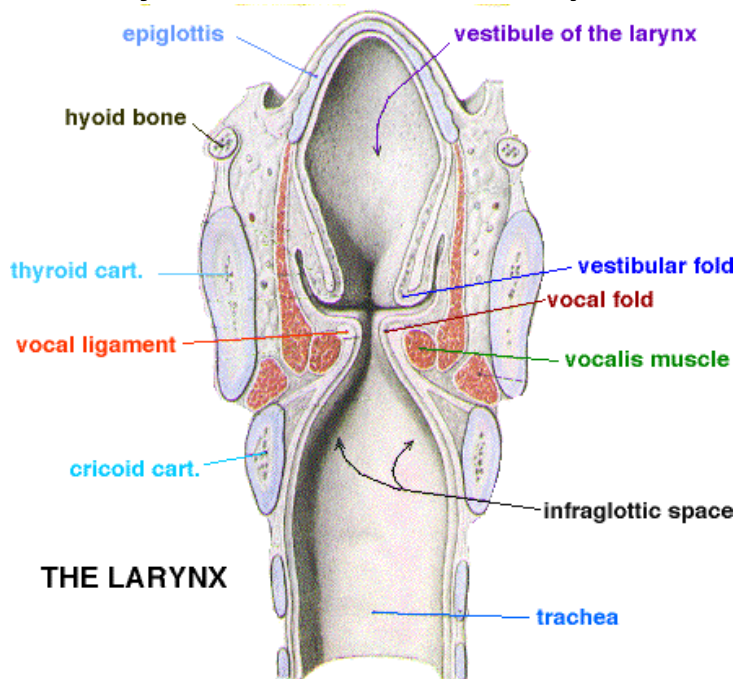
- Next, a brief look at the cricoid cartilage and its parts:



A: Anterior view, you can see the arch of cricoid.

B: Posteriorly, the lamina of cricoid
(more details about cricoid cartilage soon)

- **The Larynx is divided into three parts:**



1- Vestibule: from the inlet to the false vocal cord.

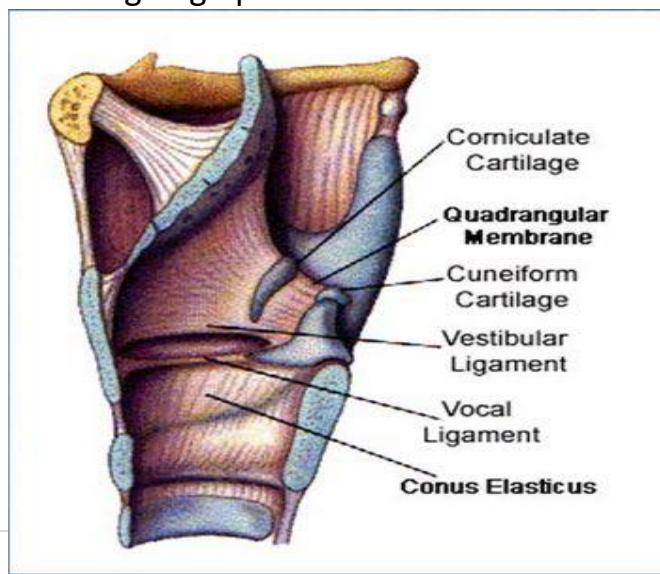
2- Glottis (middle) compartment: between the false and the true vocal cord.
(The ventricle)

3- Infra-glottic (inferior) compartment: below the true vocal cord.

- **There are two intrinsic membranes in the larynx:**

1- Quadrangular membrane: extends from the lateral aspects of the epiglottis, to the arytenoid cartilage on each side (up to down).
-Forms the false vocal cord.

2- Conus elasticus (cricothyroid membrane): arises from the cricoid arch and going upward to form the true vocal cord (down to up).

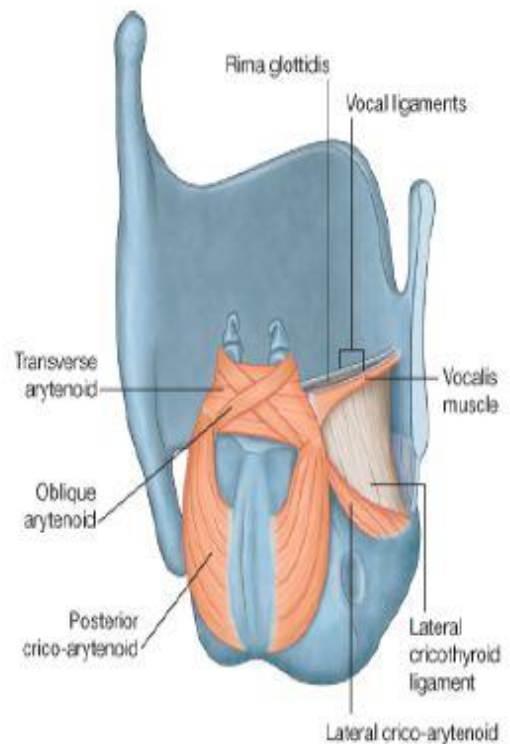


- This is really important!
- For extra figures; check slide (21-24).

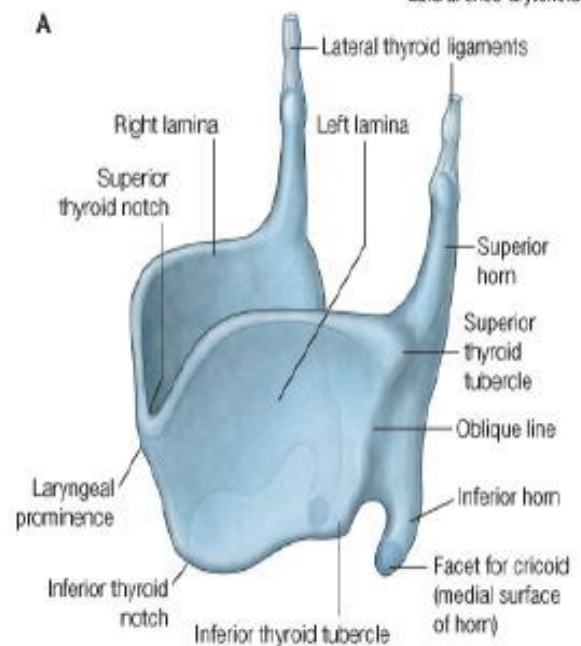
- **Comparison between the true and the false vocal cords:**

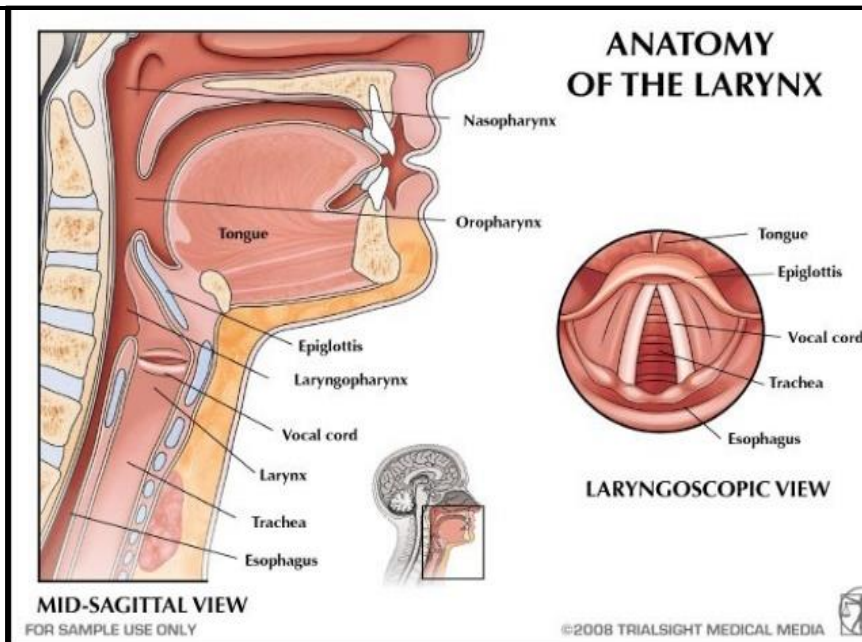
True	False
Stratified squamous non-keratinized	Pseudo-stratified columnar with goblet cells (respiratory epithelium)
Has vocal ligament; which is the upper border of Conus elasticus	Has vestibular ligament which is the lower border of the Quadrangular membrane
Avascular (white in color)	Vascular (red)
Has the “vocalis” muscle which relaxes the vocal cord	
No submucosa	

- Notice the “posterior cricoarytenoid muscle” which extends from the lamina of cricoid cartilage (posterior depression) to the muscular process of arytenoid cartilage:



- Notice the parts of the thyroid cartilage including the 2 lamina; which meet anteriorly, also the laryngeal prominence, and superior & inferior horns of thyroid.





- Notice the pharynx (naso, oro, and laryngo) And the inlet of the larynx

- **Now the cricothyroid muscle and its attachments:**

- Extends from the anterolateral surfaces of cricoid, to the thyroid cartilage.
- **Has Oblique and straight fibers.**
- When contracts; it pulls the thyroid forward, increasing the tension in the vocal cord; producing high pitch sound.
- The only, muscle supplied by “external laryngeal nerve”.

*** Dr. Almohtaseb finished by focusing on certain points: (epiglottis and its connection with the tongue, the inlet of larynx, the ventricle and the saccule, true and false cords, and Aryepiglottic fold)

PART 2: (INTRINSIC MUSCLES OF LARYNX)

- In general, the intrinsic muscles control two things **1-** patency of airway (opened or closed) **2-** phonation.
- All are supplied by recurrent laryngeal nerve **except** for cricothyroid.
- All are paired **except** one “transvers arytenoid”

- **Cricothyroid muscle:**

- Extends from the anterolateral surfaces of cricoid, to the thyroid cartilage.
- Has Oblique and straight fibers.
- When contracts; it pulls the thyroid forward (or you can say anteriorly and downward), increasing the tension in the vocal cord; producing

high pitch sound.

- The only, muscle supplied by “external laryngeal nerve”.

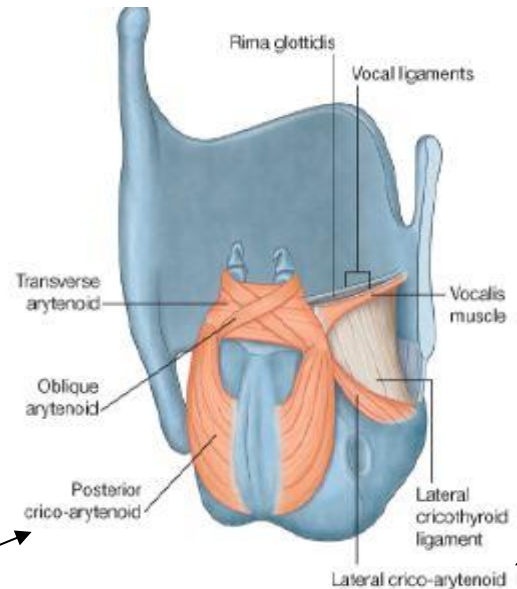
- **Muscles between cricoid & Arytenoid:**

1- Posterior cricoarytenoids: originate from the depression in the posterior lamina of cricoid and extends superiorly and laterally to be inserted in the muscular process of arytenoid (the posteriolateral part of arytenoid)

- When contracts; lateral rotation of the arytenoids causing opening of the airways. Also abduction in the vocal cord.

2- Lateral cricoarytenoids: originate from the upper border of cricoid arch and run posteriorly and upward to be inserted to the muscular process of arytenoid.

- When contracts; internal rotation of the arytenoids causing closure of the airways. Also adduction of the vocal cord.



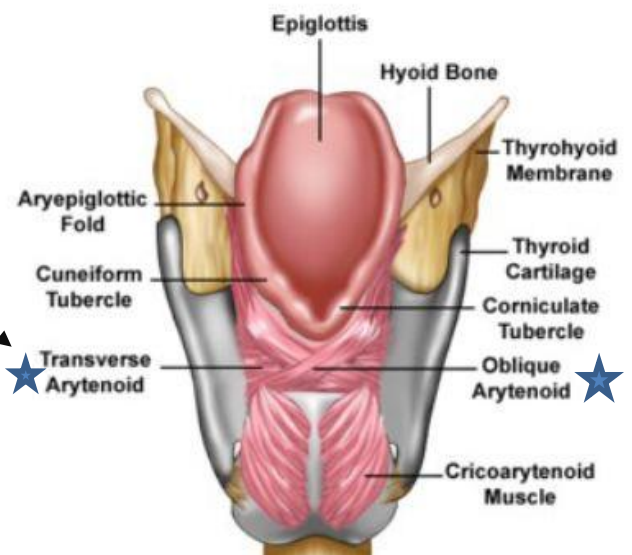
- **Muscles between the two arytenoids:**

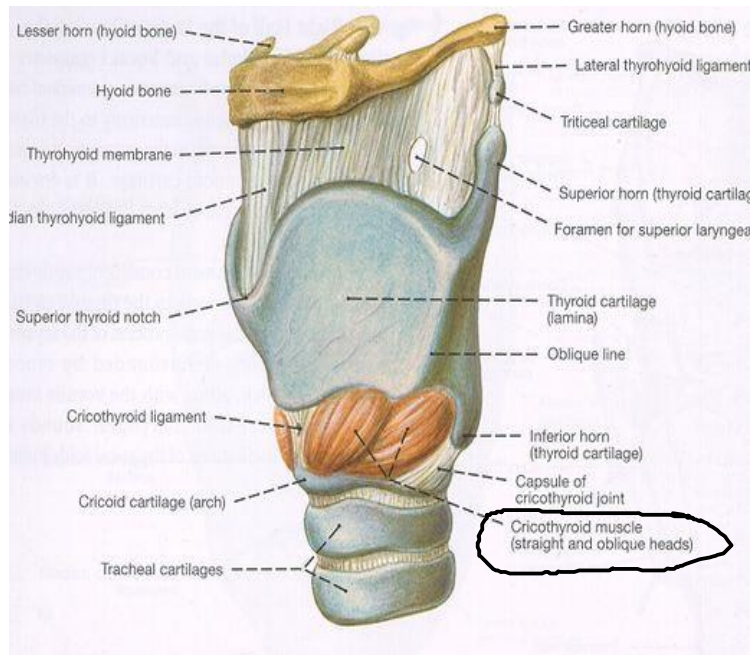
1- Transvers arytenoid:

- Extends from the muscular process of one arytenoid to the muscular process of the opposite arytenoid.
- Single ☹️
- Action: adduction of arytenoids causing closure of Rima glottidis.
- **Helps in phonation.**

2- Oblique arytenoid:

- Extends from the muscular process of arytenoid to be inserted to the apex of the opposite arytenoid and goes around it.
- **Fibers of this muscle continue as Aryepiglottic fold to the epiglottis (important).**
- **Adduct both arytenoids (close the airway completely)**
- Used when we produce the sound of the “ء”



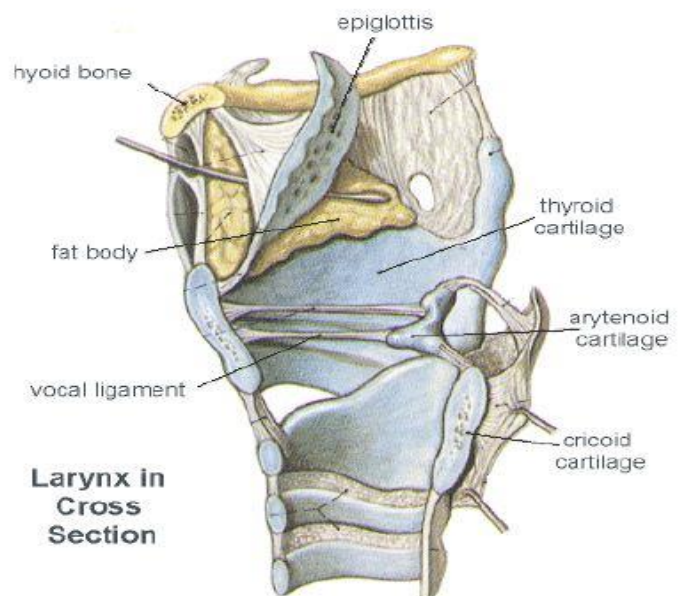


- This is cricothyroid muscle.
- Notice the oblique and the straight fibers.

- **Thyroarytenoid (Vocalis):**
 - Extends from the inner surface of thyroid to the arytenoid cartilage. (Hard to be seen!).
 - When contracts; pulls the arytenoids anteriorly causing loosening (relaxation) of the vocal cord producing low pitch sound.
 - It has 2 heads going to the arytenoid.
 - The part of it that is going from the thyroid angle to the arytenoid cartilage (Vocal process of arytenoid) is called vocalis.
 - The other head goes to the epiglottis called thyroepiglottic muscle.

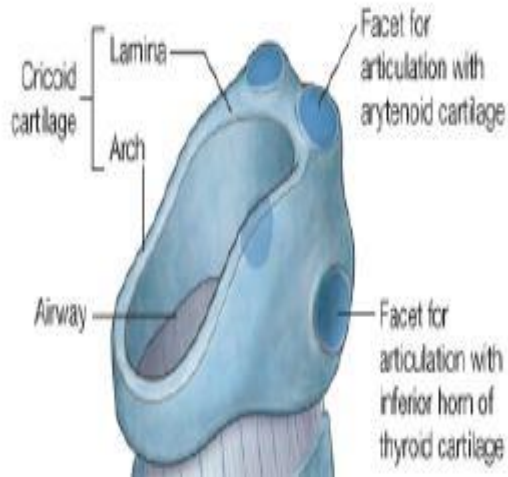
PART 3:

- 1- Pictures showing the cartilages of the larynx and its continuation with the trachea; which is a C-shaped hyaline cartilage.
 - 2- 3 large cartilages; epiglottis, thyroid, cricoid.
- Note that all cartilages of the larynx are hyaline type of cartilage except the epiglottis which is an elastic cartilage.

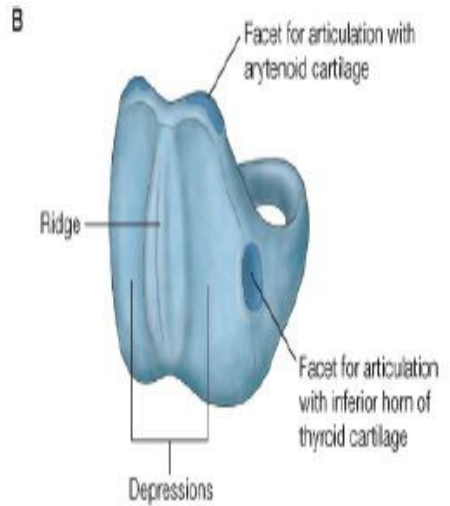


3- Parts of cricoid cartilage:

- Arch
- Lamina: has 2 facets superiorly for arytenoid cartilage. And 2 facets laterally for the inferior horns of thyroid cartilage.
- Posteriorly; it has 2 depressions for muscles attachment (post. Cricoarytenoids)



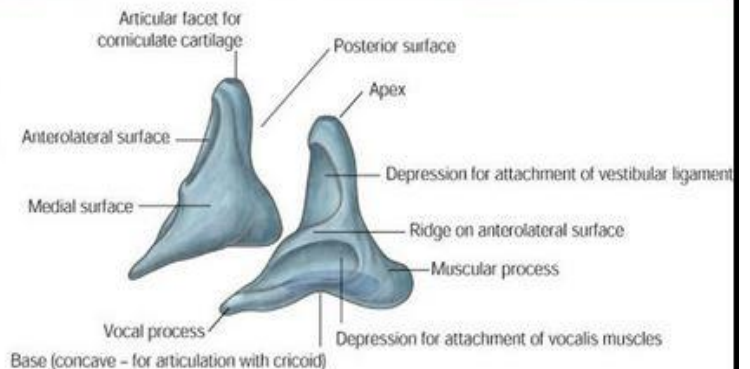
Anterior view



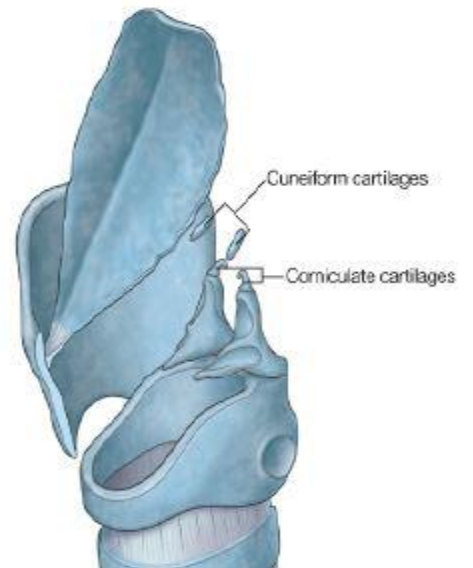
Posterior view

4- Parts Arytenoid cartilage: (important)

- Has 2 processes; muscular process (lateral) and vocal process (anterior).
- Has a rotating movement above cricoid cartilage

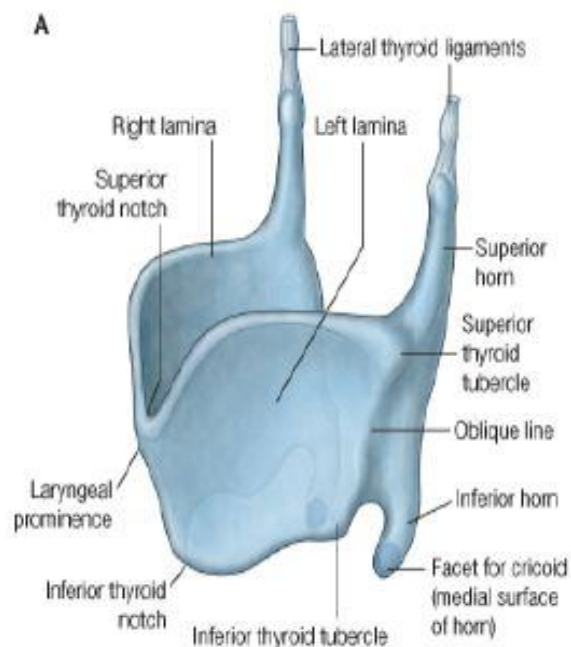


● Notice the corniculate (To which the aryepiglottic fold attaches) and cuneiform cartilages in the aryepiglottic fold (this cartilage strengthen the fold) .



5- Parts of thyroid cartilage:

- Two lamina that meet anteriorly, and the most superior point of the site of fusion is called the laryngeal prominence.
- The epiglottis is attached to the thyroid through a stalk (ligament) called thyro-epiglottic ligament.



- Epiglottis is an elastic cartilage.
- During deglutition; the epiglottis move down and the larynx move up closing the inlet of the larynx

GOOD LUCK