

Lecture 9

Breast Cancer



432 Pathology Team

Done By: Latifah Al-Fahad & Manar Al-Eid

Reviewed By: Abdulrahman AL-Zahrani

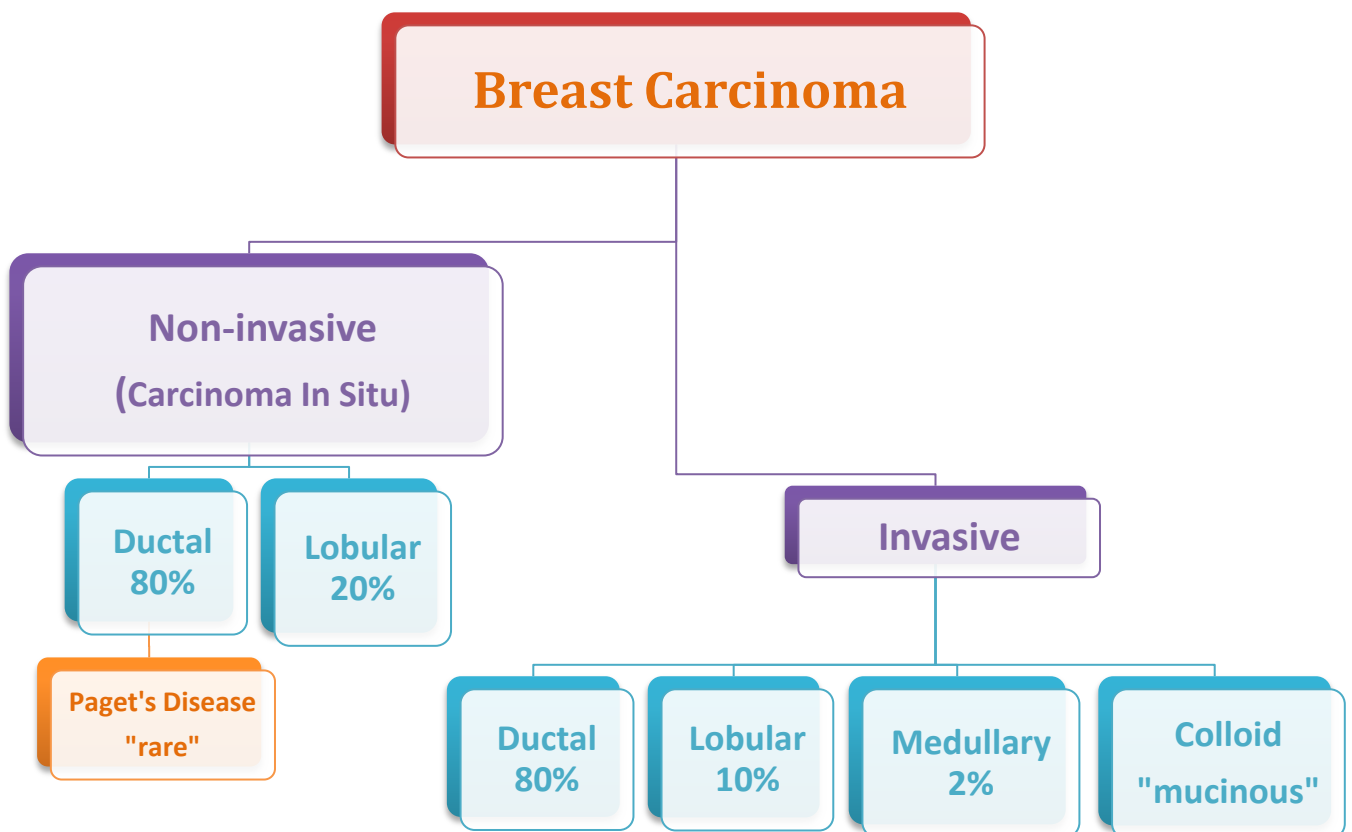
Reproductive Block



Color Index: Female notes are in Green. Male notes are in Blue. Red is important. Orange is explanation.

Breast Cancer

Mind Map:



Helpful Video (Thanks to Heba Alsharif):
<https://drive.google.com/file/d/0B9J8xbkwItPITGNmMmI0TnVQM28/edit?usp=sharing>

Breast Carcinoma

- The most common malignancy of breast is carcinoma (majority are adenocarcinomas)
- Carcinoma of the breast is the most common cancer in women
- Women who lives to age 90 has a one in eight chance to have breast cancer
- **Mammographic screening** increased dramatically the detection of **small invasive cancers**
- DCIS (**Ductal Carcinoma in Situ**) by itself is almost exclusively detected by mammography, so the incidence of DCIS is increased with the use of mammography. (It doesn't mean that DCIS actual cases are increasing, it means that **MORE** cases of DCIS have been detected. Furthermore, calcification is a usual finding in DCIS, making it more diagnosable by mammography).
- The number of women with an advanced cancer is markedly decreased.
- The mortality rate started to decline. Currently only **20% of the women with breast cancer are expected to die of the disease.**

Benefits of Mammography

Breast Cancer: Risk Factors

- **Age:** increase incidence of breast cancer older women. **Breast cancer is rare before 25 yrs, except familial forms.** **Majority** (77%) of cases occur in **women >50 yrs.** of age. (The rate is 1:8)
- **Age at Menarche:** The younger a women age at menarche, the higher her risk of breast cancer.
- **First Live birth:** The earlier a woman has her first birth, the lower her lifetime risk for breast cancer. A woman who has her first birth after 30 years has an increased risk.
- **First Degree relative with Breast Cancer:**
 - o Women with history of cancer in first degree relative (mother, sister, aunt or daughter) are at higher risk of breast cancer. The risk increases with the number of affected first degree relatives.
 - o **NOTE:** majority of cancers occur in women without such history.
 - o At least two genes that predispose to breast cancer have been identified—**BRCA 1 and 2**
- **Breast Biopsy:** Atypical hyperplasia increases the risk for breast cancer
- **Race:** Overall incidence of breast cancer is lower in African American women. Generally Caucasian have the highest rate of breast cancers. (**White more than black however black cancer is more aggressive**)

- **Estrogen Exposure:** Factors associated with exposure to increased levels of estrogen have been shown to increase a woman's risk for breast cancer. These factors include early age at menarche, late age at menopause, nulliparity and late age at first child-birth. Also postmenopausal hormone replacement slightly increases the risk.
- **Radiation exposure:** Higher rate of breast cancer.
- **History of breast cancer:** Women who have had a breast cancer have a 10-fold increased risk of developing a second primary breast cancer.
- **History of Other Cancer:** A history of cancer in the other breast or a history of ovarian or endometrial cancer.
- **Geographic influence:** Breast cancer is more common in Western industrialized countries than in developing countries. Four to seven times in USA and Europe higher than those in other countries.
- **Benign Breast Disease:** As noted previously women with certain types of benign breast disease are at risk.
- **Dietary factors** e.g. high fat intake and excessive alcohol consumption, and exposure to ionizing radiation have also been proposed as risk factors.
- **Obesity:** may play a role.
- **Exercise:** some studies showed decreased risk with exercise.
- **Breast feeding:** the longer the women breast feed, the lower the risk.
- **Environmental toxins:** pesticides.
- **Tobacco:** Not associated with breast cancer, but associated with the development of peri-ductal mastitis, or sub-areolar abscess.

REMEMBER:

- I. A mnemonic for the most important risk factors is R-BEAM (R: relatives, B: 1st Child Birth + Breastfeeding, E: Estrogen, A: age and M: 1st Menarche)
- II. You could sub-classify the risk factors in: Genetic, hormonal and environmental.

1. The etiology of breast cancer in most women is unknown but most likely is due to a combination of the risk factors listed above i.e. genetic, hormonal and environmental factors
2. The major risk factors being hormonal and genetic (family history).
3. Breast carcinomas can, therefore, be divided into sporadic cases, possibly related to hormonal exposure, and hereditary cases, associated with family history or germ-line mutations.

1. Hereditary Breast Cancer:

A family history of breast cancer in a first-degree relative is reported in 13% of women with the disease. About 25% of familial cancers (or around 3% of all breast cancers) can be attributed to two highly penetrant autosomal-dominant genes: **BRCA1 and BRCA2**.

2. Sporadic Breast Cancer

The major risk factors for sporadic breast cancer **are related to hormone exposure**: gender, age at menarche and menopause, reproductive history, breast-feeding, and exogenous estrogens. **The majority** of these cancers occur in **postmenopausal** women and **over expression of estrogen**.

Breast Carcinoma: Classification

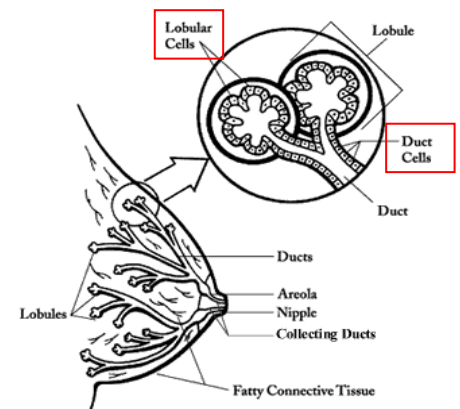
- Almost all (majority) are **Adenocarcinoma**.
- Divided into:
 - I. Carcinoma in situ (non-invasive)
 - II. Invasive carcinoma

Carcinoma in Situ

This is epithelial **proliferation that is still confined** to the TDLU (**terminal ductal-lobular unit**), has **not invaded beyond the basement membrane** and is therefore **incapable of metastasis**.

There are two subtypes:

- Ductal carcinoma in situ (DCIS) or intraductal carcinoma **80%**.
- Lobular carcinoma in situ (LCIS). The incidence in autopsy studies is about **20%**.



1. Ductal Carcinoma In Situ

- 1) By definition DCIS is a group of neoplastic lesions that are **non-invasive** and have proliferating malignant cells within the duct system but **do not** breach the underlying basement membrane.
- 2) They have a very **high risk of development of subsequent invasive carcinoma**.
- 3) The tumor **distends and distorts the ducts**.
- 4) DCIS occurs throughout the age range of breast carcinoma with **mean age** at diagnosis **between 50 and 59 years**, similar to the mean age of women with invasive ductal carcinoma.
- 5) Often **multifocal**—malignant population **can spread** widely through the duct system without breaching the basement membrane.
- 6) Women with DCIS are **at risk of recurrent DCIS following treatment**.
- 7) **Mammography is a very sensitive** diagnostic procedure for detecting DCIS, as a **substantial proportion is not palpable**.
- 8) Mammographically detected **microcalcifications** are found in 72% to 98% of DCIS.
- 9) Rapidly increased in the past two decades.
- 10) Half of mammographically detected cancers.
- 11) Most frequently as a **calcifications**.
- 12) Less frequently as a density or a vaguely palpable mass or nipple discharge.

REMEMBER:

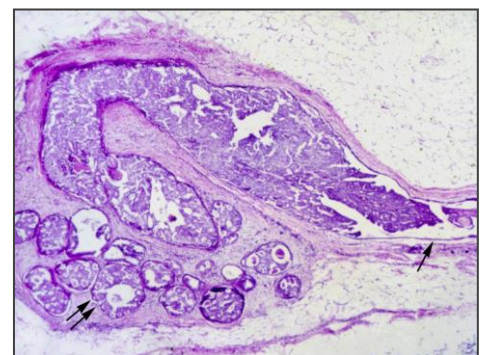
- DCIS is more common than LCIS.
- DCIS has a high chance of recurrence.
- The calcifications frequently seen with DCIS are **dystrophic**, making it more sensitive to mammography.

Subtypes of DCIS

Different patterns/subtypes of DCIS can be seen e.g.

- A) Comedo (**central necrosis**) (if we left it 100% invasion)
- B) Cribriform (cells arranged around “punched-out” spaces); papillary.
- C) Micropapillary
- D) Solid (cells fill spaces)

DCIS can be of different grades i.e. low, intermediate and high grade (e.g. comedo=high)



NOTE: The names of these subtypes are far more important than the description. The name helps predict the **clinical behavior** of the DCIS.

Clinical Behavior of DCIS

May vary depending on the subtype and the grade

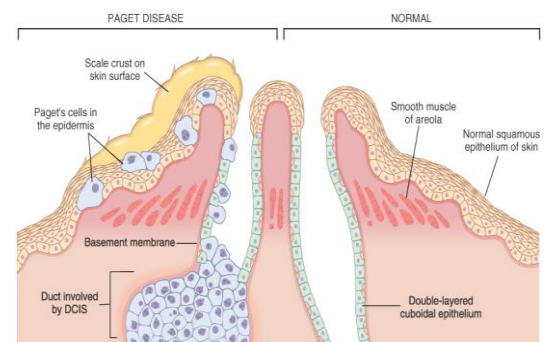
- **Comedocarcinoma** has essentially a **100%** chance of becoming invasive if left untreated.
- **Pure cribriform/micropapillary** carries only a **30%** chance of becoming invasive carcinoma.

Treatment

- Wide local excision
- mastectomy

Paget's disease

Paget's disease of the breast (known also as Paget's disease of the nipple, and is totally different from that of the bone) is a **rare type of breast cancer** that is characterized by a red, scaly lesion on the nipple and surrounding areola (1 to 2 %).



- Paget's disease of the nipple presents with an **eczematous area of the nipple**, which may be subtle or form an obviously eroded, weeping lesion.
- Pruritus is common, **might be mistaken for Eczema**, presents as a unilateral **erythematous eruption with a scale crust**.
- Malignant cells, referred to as **Paget cells** and are found scattered **in the epidermis**.
- The histologic hallmark of Paget's disease of the nipple is the **infiltration of the epidermis** by large **ductal neoplastic cells** with abundant clear or pale cytoplasm and nuclei with prominent nucleoli. The cells usually stain **positively for mucin**.
- Paget cells extend **from DCIS** within the ductal system into nipple skin **without crossing the basement membrane**
- Palpable mass is present in **50 to 60%** of women with Paget disease indicating an underlying invasive carcinoma. **(If the cell crossed the basement membrane)**.

REMEMBER:

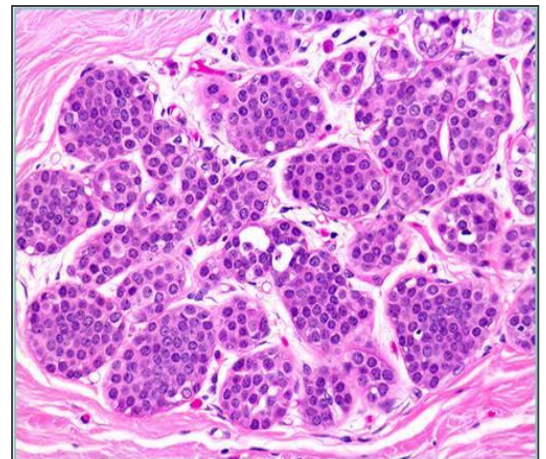
- Paget's disease could be invasive and break the basement membrane.
- **The presentation could be with or without a mass (if no mass, the lesions are usually weeping lesions i.e. exuding fluid).**
- Paget's cells are mucin positive.

2. Lobular Carcinoma In Situ

- Always an **incidental finding** in a biopsy performed for another reason.
- **Infrequent** (1% to 6%) of all carcinomas.
- **Bilateral** in 20% to 40% of women when both breasts are biopsied.
- LCIS is frequently **multicentric** and bilateral and subsequent carcinomas occur at equal frequency in both breasts.
- Lobular carcinoma in situ (LCIS) **does not form a palpable mass** and cannot be detected clinically, felt at operation or seen grossly on pathological examination.
- Although LCIS may have microcalcifications, these are infrequent and so mammography has **not** been useful for detecting it.

Histology:

Monomorphic population of small, rounded, loosely cohesive cells fills and expands the acini of a lobule. The underlying lobular architecture can still be recognized.



Lobules are distended and filled by malignant cells with no evidence of invasion.

Clinical behavior of LCIS

If LCIS is left untreated, about **30% of women develop an invasive cancer** within 20 years of diagnosis. The invasive cancer may be ductal or lobular. LCIS is a marker of increased cancer in both breasts.

Breast Carcinoma

Invasive Breast Carcinoma

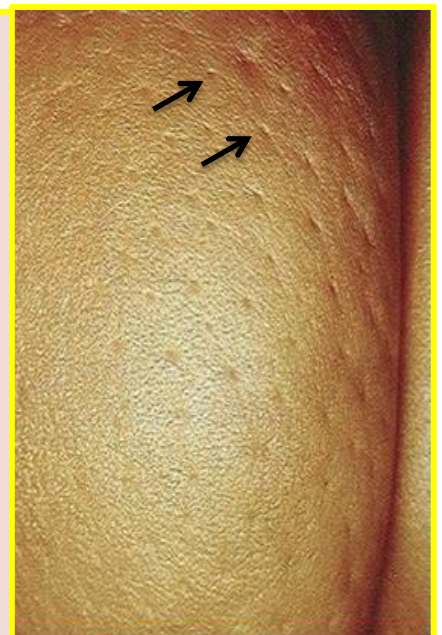- * Invasive breast carcinoma is tumor that has **extended across the basement membrane**
- * This permits access to lymphatics and vessels and -> potential distant metastases ->a lethal outcome.
- * There are several different types of invasive carcinoma:
 - 1- Ductal 80% (NOS= No Otherwise Specified)
 - 2- Lobular 10%
 - 3- tubular 6%
 - 4-Mucinous(Colloid) 2%
 - 5- Medullary 2%
 - 6- Papillary 1%
 - 7- Metaplastic Carcinoma 1%

Clinical Features:

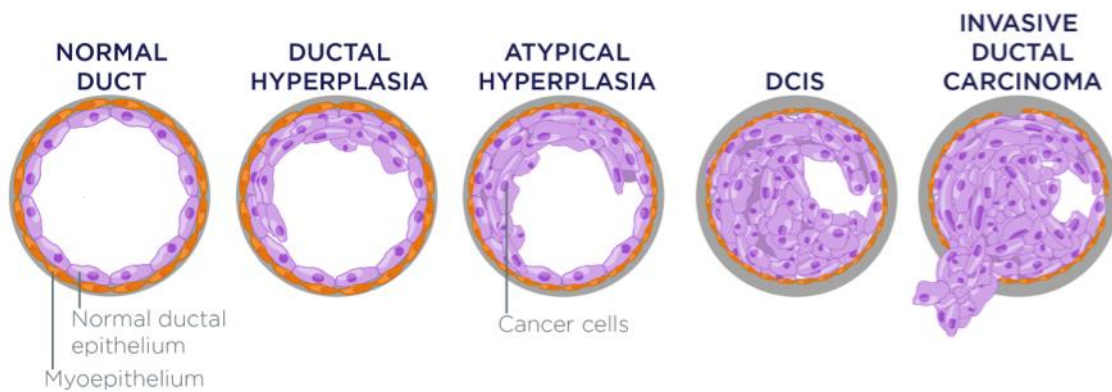
- ✘ Palpable mass
- ✘ ½ of the patients will have axillary lymph node metastases.
- ✘ Larger carcinomas may be fixed to the chest wall or cause **dimpling*** of the skin.
- ✘ Lymphatics may become so involved as to block the local area of skin drainage and cause lymphedema and thickening of the skin, a change referred to as **peau d'orange**.
- ✘ When the tumor involves the central portion of the breast, **retraction of the nipple may develop**.

NOTE:

- ***Dimpling:** If the breast is not completely round but pulls in at some points. →
- In older women undergoing mammography, invasive carcinomas most commonly present as a density.
- Invasive carcinomas presenting as mammographic calcifications without an associated density are usually very small in size.
- The term **"inflammatory carcinoma"** refers to the clinical presentation of a carcinoma extensively involving dermal lymphatics, resulting in an enlarged erythematous breast. The diagnosis is made on **clinical grounds** and does not correlate with a specific histologic type of carcinoma.



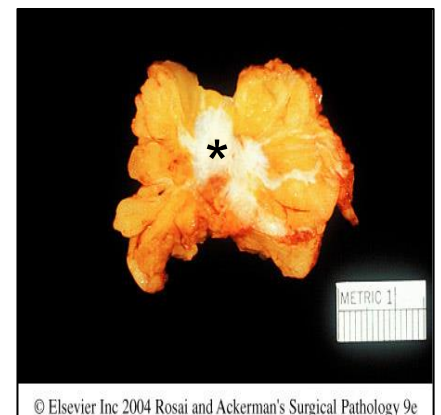
I-Invasive Ductal Carcinoma



- * The **commonest** type -80% (MCQ question)
- * Most of these tumors excite a fibroblastic stromal reaction to the invading tumor cells producing **a palpable mass** with **hard** consistency (scirrhous carcinoma)
- * The tumor shows an infiltrative attachment to the surrounding structures and may cause **dimpling** of the skin (due to traction on suspensory ligaments) or **nipple retraction**

Grossly:

- Firm, hard, **white** and have an irregular border.
- Cut surface shows *stellate infiltration and in the center there are small foci of chalky white stroma and occasionally calcifications.
- Characteristic grating sound when cut or scraped.
- Could be soft and well demarcated



© Elsevier Inc 2004 Rosai and Ackerman's Surgical Pathology 9e

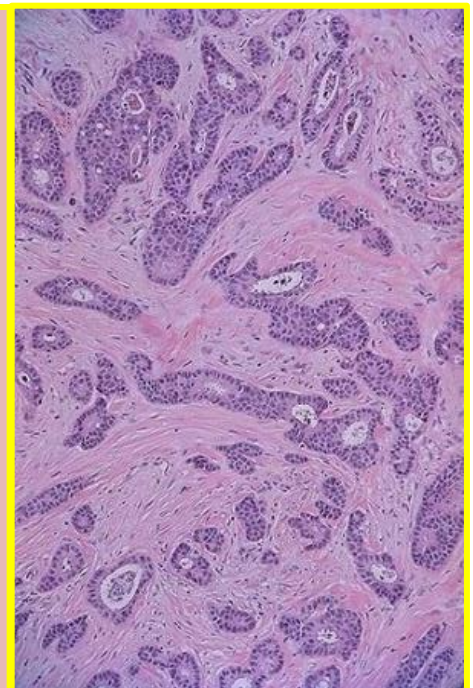
Histologically:

The tumor cells are **larger** than normal epithelium, and can assume a variety of patterns such as glandular formation, cords of cells, broad sheets of cells or a mixture of all these, usually within a dense stroma.

The tumors range from:

- 1- Well differentiated, in which there is glandular formation
- 2- Poorly differentiated containing solid sheets of pleomorphic neoplastic cells

Carcinomas associated with a large amount of DCIS require large excisions with wide margins to reduce local recurrences.



II-Invasive Lobular Carcinoma

- I. 2nd most common 10%
- II. may occur alone or with ductal carcinoma
- III. Bilateral- Multicentric
- IV. The amount of stromal reaction to the tumor varies from:
Dense***desmoplasia** too little reaction and therefore, the presentation varies from a discrete (**single**) mass to a subtle (**weak**), diffuse indurated area.

Grossly:

Firm-Hard-irregular margins.

Histologically:

- Single infiltrating cells, often one cell width (**Indian file pattern**) which is the infiltration of single rows of tumor cells.
- No tubules or papillary formation.
- In about 10% of cases (**up to 20%**), tumors have mixed features of invasive ductal and lobular carcinomas.

III-Medullary Carcinoma “mimics the benign condition”

- **Well circumscribed mass** - foci of necrosis and hemorrhage.
- May be mistaken clinically and radiologically for fibroadenoma.
- It does not produce any fibroblastic (**desmoplastic**) reaction and therefore is soft and fleshy (**encephaloid**).
- Microscopically, the tumor is composed of **solid sheets of malignant cells** and frequent **mitoses**. There is **scant fibrous stroma**. **Lymphocytes** and **plasma cells** surround the tumor cells.

REMEMBER:

- **Dismoplasia**: is the growth of fibrous connective tissue in an area of the body where it doesn't normally appear.
- **Encephaloid**: Refers to resembling the material of the brain (soft and non-fibrous).
- Lymphocytic infiltration is seen in **Seminoma, Dysgerminoma, and Medullary carcinoma**.

IV- Colloid Carcinoma/ Mucinous carcinoma

- * In **older women**. (**Has a good prognosis**).
- * It is sharply **circumscribed**, lacks fibrous stroma and is slow growing.
- * Is soft and **gelatinous** and has a glistening (**shinning**) cut surface.
- * It may be in pure mucinous or mixed in which it is associated with other types of invasive breast carcinoma.

NOTE: Histologically: The mucinous tumor is composed of small islands of tumor cells (occasionally forming glands), and isolated tumor cells floating in pools of extracellular mucin.

Prognostic Factors of Breast Cancer

Major factors:

- 1) **Invasive or In situ disease:** carcinoma in situ can't metastasize and Breast cancer deaths associated with DCIS are due to the subsequent development of invasive carcinoma. Usually, DCIS will be cured. In contrast, ½ of invasive carcinomas will have metastasized locally or distantly at the time of the diagnosis.
- 2) **Distant metastasis:** Once distant metastases are present, cure is unlikely. Favored sites for dissemination are the lungs, bones, liver, adrenals, brain, and meninges.
- 3) **Lymph node metastasis:** Axillary lymph node status is the most important prognostic factor for invasive carcinoma in the absence of distant metastases. The clinical assessment of nodal involvement is very inaccurate; therefore, biopsy is necessary for accurate assessment. With no involvement, the 10-year disease-free survival rate is close to 70% to 80%; the rate falls to 35% to 40% with one to three positive nodes and 10% to 15% in the presence of more than 10 positive nodes.
- 4) **Tumor Size:** The size of the carcinoma is the 2nd most important prognostic factor. The risk of axillary lymph node metastases increases with the size of the carcinoma.

NOTE:

All the above parameters are used to stage the tumor. Stage is a combination of *size, lymph node status and distant metastasis*. Tumor size less than 2 cm is associated with a favorable prognosis. *The single most important prognostic indicator is the lymph node status.* Negative lymph nodes have the best prognosis. Involvement of 1 to 3 lymph nodes has an intermediate prognosis and 4 or more positive nodes have the worse prognosis.

- 5) **Locally advanced disease:** Tumors invading into skin or skeletal muscle are frequently associated with distant disease.
- 6) **Inflammatory Carcinoma:** Women presenting with the clinical appearance of breast swelling and skin thickening have a particularly poor prognosis with a 3-year survival rate of only 3% to 10%.

Minor Factors

- ❄ **Histologic Subtype:** Infiltrating ductal and lobular carcinomas have the worst prognosis. Medullary and mucinous have intermediate and tubular and cribriform have the most favorable prognoses.
- ❄ **Tumor Grade:** according to A- the amount of well-formed tubules, B- the degree of nuclear pleomorphism, and C- the mitotic rate. The most commonly used grading system is (*Bloom Richardson*). There are three grades with grade 1 having better prognosis and grade 3 having poorer prognosis.
- ❄ **Estrogen and Progesterone receptors:**
 - 50% to 85% of carcinomas express estrogen receptors; such tumors are more common in postmenopausal women.
 - Such hormone positive cancers have better prognosis. They respond well to specific chemotherapeutic drugs e.g. Tamoxifen. Therefore reporting of ER/PR positivity is important when reporting breast cancer.
- ❄ **HER2/neu.** (Human epidermal growth factor receptor 2 or c-erb B2 or neu) is a glycoprotein overexpressed in 20% to 30% of breast carcinomas. Many studies have shown that overexpression of HER2/neu is associated with a poor prognosis. In addition, ongoing studies have shown that HER2/neu-overexpressing tumors respond very well to hormonal or anthracycline chemotherapy regimens e.g. Trastuzumab (Herceptin). Therefore evaluation of HER2/neu is important when reporting breast cancer in order to help decide the chemotherapy plan.
- ❄ **Lymphovascular invasion:** Tumor cells may be seen within vascular spaces (either lymphatics or small capillaries) surrounding tumors. This finding is strongly associated with the presence of lymph node metastases and is a poor prognostic factor in women without lymph node metastases.
- ❄ **Proliferative rates:** (the faster the growth, the worse the prognosis).

Stromal Tumors (from the stroma)

1-Fibroadenoma

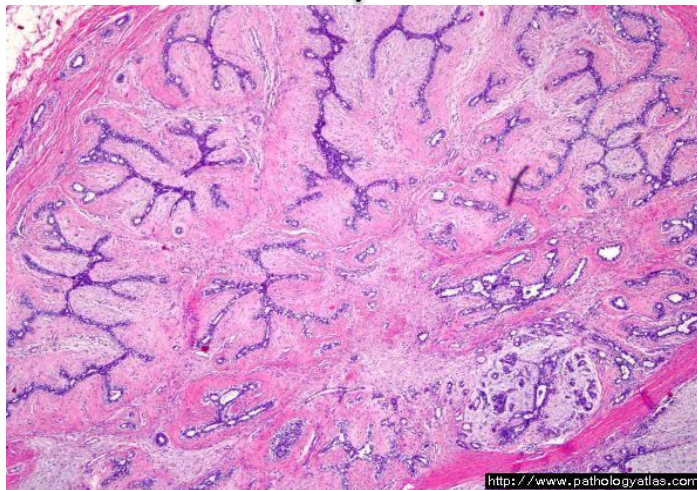
- ★ **Common**-usually Solitary. (Most common neoplastic process of the breast).
- ★ **Benign** proliferation of both epithelial and stromal elements.
- ★ Common before age **30 (young Females)**.
- ★ Firm, mobile lump (“breast mouse”), Giant forms can occur, especially in younger patients.
- ★ It may increase in size during pregnancy and regress after menopause. (Usually, they don’t do a surgery except if the tumor is big and bothers the patient).
- ★ Rarely, carcinoma may arise within a fibroadenoma. The predominant type has been lobular carcinoma.

Grossly:

Spherical nodules- well-circumscribed – movable (breast mouse)
The cut surface is pearl-white and whorled.

Histologically:

The tumor is composed of a mixture of **ducts and fibrous connective tissue**.



2-Phylloides tumor (could be benign-malignant or intermediate)

- ✘ Arise from intralobular stroma – common in 6th decade. (Stromal over growth).
- ✘ Palpable mass- rarely metastasize
- ✘ Must be excised with wide margins to avoid the high risk of local recurrences. **The majority are low-grade tumors “locally”**. Rare high-grade lesions behave aggressively, with frequent local recurrences and distant hematogenous metastases in about one third of cases.

Summary (from Robbins Basic Pathology)***Breast Carcinoma***

- The lifetime risk of developing breast cancer for an American woman is 1 in 8.
- A majority (75%) of breast cancers are diagnosed after the age of 50.
- Risk of developing breast cancer is related to estrogen exposure, genetic factors, long duration between menarche and menopause, atypical proliferative lesions, and family history of breast cancer in a first-degree relative, particularly if the disease was multifocal or in a premenopausal woman.
- About 10% of all breast cancers are caused by inherited mutations; BRCA1 and BRCA2 genes account for one third of the cases associated with single-gene mutations.
- Ductal carcinoma in situ (DCIS) is a precursor to invasive ductal carcinoma and typically is found on mammographic examination as calcifications. When carcinoma develops in a woman with a previous diagnosis of DCIS, it usually is an invasive ductal carcinoma in the same breast.
- Lobular carcinoma in situ (LCIS) frequently is an incidental finding and usually is not associated with calcifications. When carcinoma develops in a woman with a previous diagnosis of LCIS, it may occur in the affected or unaffected breast and usually is invasive lobular carcinoma but may be invasive ductal carcinoma.
- The natural history of breast carcinoma is long, with metastases sometimes appearing decades after the initial diagnosis.
- Prognosis is most dependent on tumor size, lymph node involvement, distant metastasis at presentation, tumor grade, and histologic type.
- Estrogen and progesterone receptor status and expression of HER2/NEU are used primarily to determine response to treatment. Estrogen receptor-expressing tumors are more likely to respond to tamoxifen. HER2/NEU-overexpressing tumors often are treated with trastuzumab.

Summary

Carcinoma In Situ	Ductal (80%)	<p>Non-invasive but high risk of development of invasive carcinoma Often multifocal and can spread widely. High risk of recurrence following treatment. Calcifications are frequent and very mammography sensitive. Subtypes: comedo, cribiform, micropapillary and. Solid. The 1st has 100% chance to turn into invasive carcinoma if untreated.</p>	
		<p>Paget's disease: mucin positive Paget cells are ductal neoplastic cells that infiltrate the epidermis. Might be mistaken for Eczema, presents as a unilateral erythematous eruption. Could be invasive.</p>	
	Lobular (20%)	<p>Infrequent, multicentric and bilateral. Does not form a palpable mass and cannot be detected clinically. Microcalcifications are infrequent and so mammography is not used. 30% of women develop an invasive cancer, if untreated.</p>	
Invasive Carcinoma	Ductal (80%)	<p>Produce a palpable mass with hard consistency. It may cause skin dimpling or nipple retraction.</p>	<p>Gross: stellate infiltration. Histology: cells are larger than normal epithelium</p>
	Lobular (10%)	<p>May occur alone or with ductal carcinoma Bilateral-Multicentric. Dense desmoplasia to little reaction (presentation varies)</p>	<p>Gross: firm/hard irregular margins Histology: Single infiltrating cells (Indian file pattern)</p>
	Medullary (2%)	<p>Mistaken for fibroadenoma. Soft and fleshy (encephaloid).</p>	<p>Gross: well circumscribed. Histology: presence of Lymphocytes and plasma cells surround tumor cells.</p>
	Colloid (Mucinous)	<p>In older women. (Has a good prognosis). Slow growing, soft and gelatinous.</p>	<p>Gross: sharply circumscribed. Histology: small islands of tumors cells floating in extracellular mucin.</p>

Questions

1/ A 53-year-old woman discovers a lump in her breast and physical examination confirms a mass in the lower, outer quadrant of the left breast. Mammography demonstrates an ill-defined, stellate density measuring 1 cm. Needle aspiration reveals malignant ductal epithelial cells. A modified radical mastectomy is performed. Which of the following cellular markers would be the most useful to evaluate before considering therapeutic options for this patient?

- (A) Collagenase
- (B) Estrogen receptors
- (C) Galactosyltransferase
- (D) Lysosomal acid hydrolases

2/ Upon self-examination, a 53-year-old woman discovers a lump in her left breast. Physical examination reveals a palpable lump about 1 cm in diameter in the outer quadrant of the left breast. No palpable lymph nodes are found in the axilla. Mammography reveals an ill-defined, stellate density measuring 1 cm in the left breast. Fine-needle aspiration of the mass discloses malignant epithelial cells. A partial mastectomy is performed and shows invasive ductal adenocarcinoma. Which of the following is the most important prognostic factor for this patient?

- (A) Estrogen receptor status of the tumor tissue
- (B) Histologic grade of the tumor
- (C) Inherited BRCA1 gene mutation
- (D) Status of the axillary lymph nodes

3/ A 52-year-old woman presents with a 3-month history of a palpable breast mass. Physical examination confirms a 1-cm nodule in the upper outer quadrant of the right breast. A biopsy reveals small cuboidal cells, with round nuclei and prominent nucleoli. The cells are arranged in single cell columns, between strands of connective tissue. Which of the following is the appropriate diagnosis?

- (A) Ductal carcinoma in situ
- (B) Invasive ductal carcinoma, tubular type
- (C) Invasive lobular carcinoma
- (D) Lobular carcinoma in situ

Answers:

- 1- B
- 2- D
- 3- C

اللهم إني استودعك ما قرأت و ما حفظت و ما تعلمت فرده عليّ عند حاجتي إليه انك على كل شيء قدير

If there is any mistake or feedback please contact us on: 432PathologyTeam@gmail.com

