

Current approach to cerebrospinal fluid rhinorrhea diagnosis and management

Abstract

Cerebrospinal fluid (CSF) rhinorrhea clinical approach and therapeutic techniques are rapidly growing and the literature is almost daily enriched with new studies, techniques, and trials. In this article I tried to collect, summarize and organize the updates on this topic from the English literature, and deliver it in a clinical approach manner with suggested algorithm and clarifying illustration so it can be easily understood by the readers and applied by those who are dealing with such cases.

Volume 7 Issue 1 - 2017

Ibrahim Sumaily

Otorhinolaryngologist Asir central Hospital, Saudi Arabia

Correspondence: Ibrahim Sumaily Otorhinolaryngologist Asir central Hospital Abha KSA, Saudi Arabia, Tel +966504621902, Email sumaily.i@gmail.com

Received: April 11, 2017 | **Published:** May 02, 2017

Introduction

CSF Rhinorrhea is defined as the presence of CSF within the nasal cavity as a result of abnormal communication between the subarachnoid space and the extracranial space. See Figure 1. This communication can be as a result of each of the following:

- Traumatic: Trauma (80-90%) is the most common cause of CSF leak either due to head injury or iatrogenic.¹⁻⁴
- Spontaneous leaks either secondary to raised intracranial pressure or with normal intracranial pressure.⁵⁻⁸
- Congenital⁹ either due Encephaloceles or persistent craniopharyngeal canal.
- Miscellaneous causes include erosion of the skull base by tumors, infection, mucocele, and following radiation. The diagnosis of CSF Rhinorrhea is established on 3 main aspects:

Clinical

- History: duration, characters of the leaking fluid (taste & consistency, aggravating factors), meningeal symptoms, trauma, previous surgery.
- Physical examination: Complete ear, nose, throat, head and neck examination, cranial nerves assessment, and Fiberoptic evaluation of the nasal cavity looking for the site of the leak (commonly in cribriform plate, ethmoid roof, sphenoid sinus wall, frontal sinus posterior table).

Laboratory

- CSF analysis of the fluid.
- Glucose concentration is >30mg/dl. Neither sensitive nor specific.¹²
- Beta-2 transfer in is the gold standard (sensitivity of 94% to 100%, and specificity of 98% to 100%), unfortunately not available in many centers, needs 5-7days.¹⁰

Imaging

This can be classified into primary and secondary:

Primary (helpful in the detection of most of the leaks).^{10,11}

- MRI cisternography: heavily T2-weighted, fast spin-echo, fat-

saturated sequences. Better in prone position with Valsalva maneuver. FLAIR sequence is very useful in differentiating CSF (change to dark) from sinus secretions (persist whitish) without the need for contrast.^{13,14} Intrathecal injection of 0.5ml of gadopentetate dimeglumine, diluted in 3-5ml of CSF can be added for more details.

- HRCT: Can show the bony defect and, if there is, any protruding soft tissue through it, and also accumulating fluid if any. And in some cases pneumocephalus may be seen. Its sensitivity is 88.25 to 93%.¹⁵ It is less sensitive in detecting the exact site of the leak when there are multiple fractures.¹⁶
- Combination of both HRCT and MRI-cisternography provide higher sensitivity and specificity, but usually it is not cost effective and sometimes its time consuming to wait for both to be ready. So, starting with HRCT is advised.^{12,13,17}

Secondary (useful if primary modalities failed to show the site of the leak):¹²

- CT-Cisternography with an intrathecal injection of nonionic iodinated myelographic contrast medium usually localizes the CSF leak. For a precise localization submillimetric cuts is the role. Pre- & post-cisternography images Hounsfield scale units should be compared. If more than 50% increase, it is leak. It can be a single investigational modality.¹⁸ It is better to have direct coronal cuts rather than reconstructed cuts.
- Intrathecal fluorescein^{19,20,21} where 0.1 ml of 10% fluorescein is diluted in 10ml of CSF and injected into the subarachnoid space over a period of 10 minutes, then nasal endoscopy to be done 30 minutes later, fluid can be seen by routine xenon light. If not, use blue-light filter setting. Sensitivity 57.7-85.6%, specificity is 100%²². There is risk of developing seizures due to fluorescein.²³ So, the use of low concentration of fluorescein, slow administrations, and 24hours supervision are advised prophylactic measures. This diagnostic modality is not approved by United States Food and Drug Administration yet.

Radionuclide cisternography by radioactive isotopes (indium-111 (¹¹¹In)) injection either into the lumbar or suboccipital subdural and nasal pledgets in various high-risk areas. Head scans are acquired 2, 6, 12, and 24 hours. And follow-up scans after 48- or 72-hours. It is useful in the detection of intermittent CSF fluid leaks with sensitivity range of 50 to 100%, and specificity 100%. It is relatively poor in

exact localization, therefore it is reserved for complex cases when the diagnosis is in question.²⁴

- c. Nasal endoscopy²⁵. The last choice is to explore the nasal cavity and paranasal sinuses via and endoscopic sinus surgery looking for the leak and the defect site. Valsalva maneuver and jugular compression could improve detection rate(Figure 2).

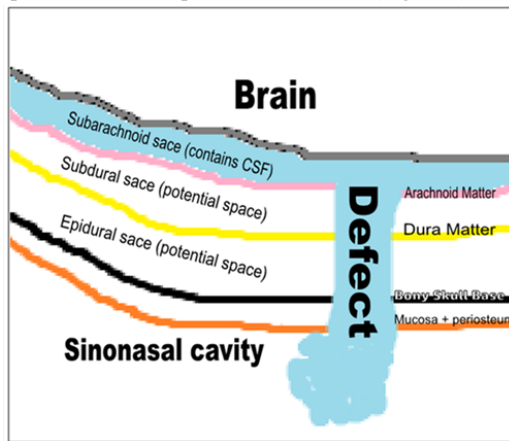


Figure 1 Content of the anterior skull base and the defect site where CSF leaks to sinonasal cavity.

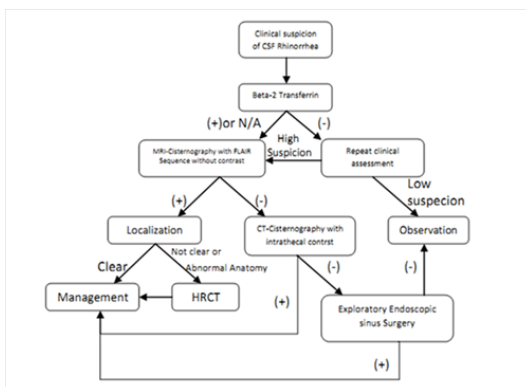


Figure 2 Suggested algorithmic approach for CSF rhinorrhea.

Management

Management can be classified as conservative and interventional:

1. Conservative management, for 2-4 weeks,²⁶ especially for traumatic leaks. In form of Acetazolamide,²⁷ laxatives, and the prophylactic antibiotics. As well as bed rest with head elevated, avoidance of sneezing, heavy lifting and straining. Lumbar drain can be useful.
2. Interventional Management is used in spontaneous leaks and in cases where conservative measures failed. It has a varying success rate according to the technique:

Intracranial approach

70 to 90% success rate. Combined intracranial extradural and intradural approach allows the visualization and repair of the entire anterior skull base. The intracranial approach is indicated in the following conditions:^{2,28-30}

- i. Extensive bone defects in the cranial base.
- ii. Multiple fractures of the ethmoid bone and the posterior wall of the frontal sinus.

- iii. Associated intracranial lesions requiring surgery.

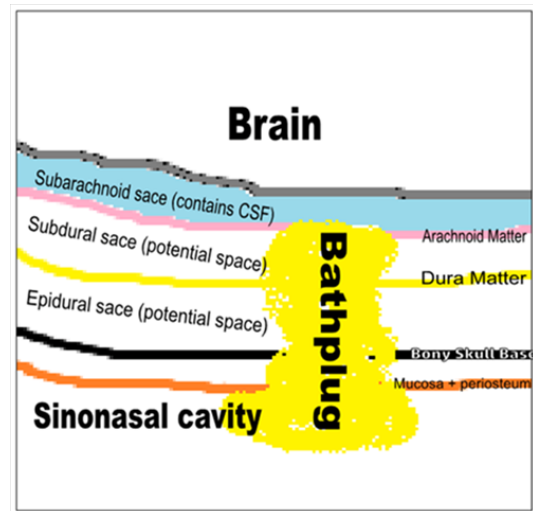


Figure 3 Bath-plug technique. The plug can be fat graft.

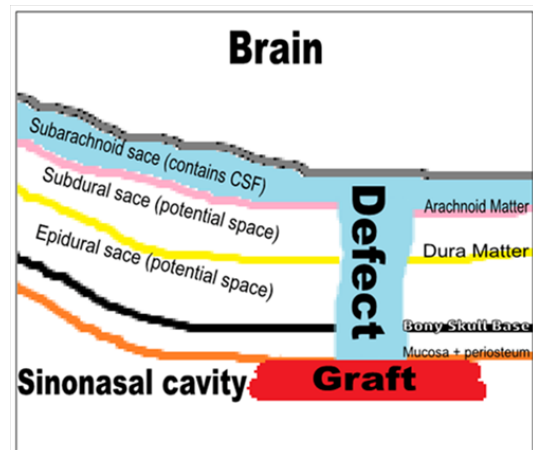


Figure 4 Overlay technique, where the graft is applied as a lining for the roof of the sinonasal cavity.

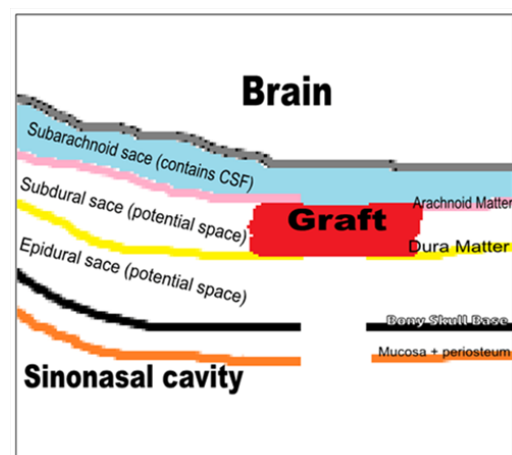


Figure 5 Intradural underlay technique, where the graft is applied in the subdural space.

CSF leak is severe, recurrent, or not amenable to the endoscopic treatment.

- i. Procedure: up to date, no studies on the types of craniotomy and which type is preferred.³¹ For a frontobasilar defects a bicoronal frontal craniotomy can be used, the dura is opened, the brain is gently retracted, localize the defect site, remove any bony shrapnel, cover the defect with the graft or with a pedicled periosteal flap which can be sutured to the defect site dura, for a water tight sealing use a tissue glue material, the dura is closed either edge to edge or to the periosteum if a pedicled periosteal flap is used, the frontal bone is returned in place and the wound is sutured.³²
- ii. Disadvantages:¹² This approach has a relatively less success rate, high risk of anosmia, risk of postoperative intracerebral hemorrhage, cerebral edema, epilepsy, frontal lobe dysfunction, osteomyelitis, and external scar. Because of these risks the patient may need longer hospitalization and delayed return to the normal activity. Also with this approach it is difficult to approach sphenoid sinus rhinorrhea.

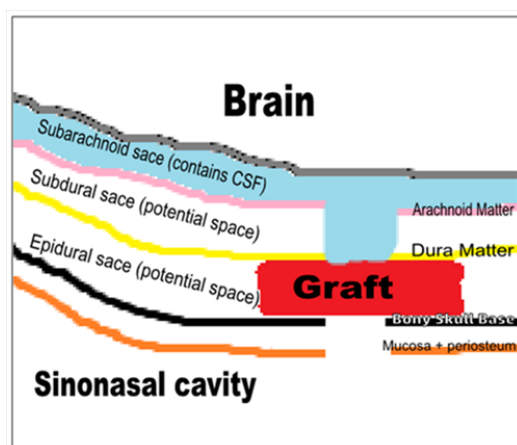


Figure 6 Extradural underlay technique, where the graft is applied in the epidural space.

Extracranial approaches

- i. Open sinus surgery² where the defect site can be approached via external ethmoidectomy or frontal sinusotomy. This approach is useful for larger defects (> 5cm) and frontal sinus posterior wall defects.
- ii. Endoscopic Technique: This approach has a much less morbidity,³³ therefore less hospital stay. It has a higher success rates, 87-100% in first attempt, 94-100% in second attempt.^{4,34-36} Also it carries much less risk of injury to olfactory fossa. With the help of the endoscope, this approach has easy access, precision, and accuracy of the surgery. For all of this advantages, nowadays, it is the procedure of choice,³⁷⁻³⁹ especially in cases where there is small defects in the sphenoid sinus, cribriform plate, anterior and posterior ethmoid sinus. Control of intracranial pressure is helpful for success of this procedure.⁴⁰ In cases of frontal sinus defects, the modified Lethrop approach is useful either alone or with endoscopic approach.⁴¹⁻⁴³

Preparations

Use navigation.⁴⁴ 30cm length scope is better. If using intraoperative fluorescein, a blue filter for the light source may aid in the identification of the defect. The mucosa is completely stripped away from the defect for at least 5mm in all the directions. Encephaloceles need to be reduced by using bipolar electrocautery

at the stalk. Several Graft materials can be used; cartilage, bone, mucoperichondrium, septal mucosa, turbinate, fascia, abdominal fat, conchal cartilage, free tissue, pedicle tissue or composite grafts. The uses of the various types of graft materials do not seem to alter the outcome.^{4,45,46,47} Different ways of applying the graft; Bathplug see (Figure 3) where a fat plug with a specifically secured vicryl suture into the intradural space,⁴⁸ Composite mucochondrial flap, for larger defects,⁴⁹ Middle turbinate, composite bone/mucosa, for moderate and large defects,⁴² Inferior turbinate graft for defects > 2cm.⁵⁰

Technique^{12,51}

Either Overlay where the graft is applied within the nasal/sinus cavity to seal the defect or underlay where the graft is applied beyond the skull base. In the underlay technique it can be either epidural or intradural, where the results are almost equal but the intradural technique is relatively difficult. If the dura is widely opened and massive intraoperative CSF leakage is encountered, direct suturing of the dura is better.^{52,53,54} Nowadays sandwich technique, by combining intradural and extradural grafts, is the trend among the experts and seen to add more security to the sealing of CSF and augments the results of repair.⁵⁵ Laser tissue welding is an experimental technique that has been found to create an above-average-strength seal without significant inflammatory sequelae.⁵⁶ Tissue sealants to add stability to a multilayered repair. Apply gel foam between the graft and the nasal pack. Remove the pack in 3-5days. Tissue glue can obviate the need for packing.⁵⁷ Bed rest 3-5days with head elevation and antibiotic is recommended.

Adjuvant Technique, lumbar drain: Not in all cases.⁵⁸ Useful in cases of frontal and sphenoid sinus defects with or without meningocele or encephalocele,^{59,60,61} and in those with high ICP. It can be kept for 3-5days.

Complications of endoscopic techniques include meningitis (0.3%), brain abscess (0.9%), subdural hematoma (0.3%), smell disorders (0.6%), and headache (0.3%). These possible complications are much less when compared to Craniotomy.⁶⁰

The recurrence of CSF rhinorrhea occurs in up to 50%.⁶² Causes include spontaneous CSF rhinorrhea, elevated body mass index, extensive skull base defects, middle age, female gender, diabetic patients, in cases of multiple leaks, those with high intracranial pressure.^{63,64,65} Frontal sinus leak and the lateral sphenoid leaks repair have the highest failure rate (44%).⁶⁶ In order to prevent recurrence, exact localization of the defect and proper technique, graft choice and Differentiating between high and low flow leaks are essential.⁶⁷⁻⁷⁰ Also, early detection of high ICP, (20 cm H₂O), and applying a lumbar drain will decrease the risk of recurrence.⁷¹ Prophylactic universal sellar reconstruction in cases of pituitary surgery found to decrease the risk of recurrence.^{72,73}

Conclusion

CSF rhinorrhea⁷¹⁻⁷⁷ most commonly due to trauma where conservative measures are useful and the chance of spontaneous healing is high. In cases of iatrogenic and spontaneous leaks, it is less likely to heal with conservative measures. So, treating these cases early is recommended to prevent life-threatening sequelae. Beta-2 transfer in is the gold standard in the diagnosis of a CSF leak. MRI with FLAIR sequence is very useful and specific diagnostic and localizing technique without risk of contrast or radiation exposure, and therefore can be the first single diagnostic⁷⁹ modality. Endoscopic management is the most useful approach for most of the cases. Conservative⁸⁰⁻⁸²

measures are advised to be utilized postoperatively for most of the cases to avoid failure, which is commonly attributed to inadequate exposure intraoperatively and non appropriate care postoperatively.

Acknowledgments

None.

Conflicts of interest

Author declares there are no conflicts of interest.

Funding

None.

References

1. Abuabara A. Cerebrospinal fluid rhinorrhea: Diagnosis and management. *Med Oral Patol Oral Cir Bucal*. 2007;12(5):E397–400.
2. Bell RB, Dierks EJ, Homer L, et al. Management of cerebrospinal fluid leak associated with craniomaxillofacial trauma. *J Oral Maxillofac Surg*. 2004;62(6):676–684.
3. Platt MP, Parnes SM. Management of unexpected cerebrospinal fluid leak during endoscopic sinus surgery. *Curr Opin Otolaryngol Head Neck Surg*. 2009;17(1):28–32.
4. Bumm K, Heupel J, Bozzato A, et al. Localization and infliction pattern of iatrogenic skull base defects following endoscopic sinus surgery at a teaching hospital. *Auris Nasus Larynx*. 2009;36(6):671–676.
5. Schlosser RJ, Woodworth BA, Wilensky EM, et al. Spontaneous cerebrospinal fluid leaks: A variant of benign intracranial hypertension. *Ann Otol Rhinol Laryngol*. 2006;115(7):495–500.
6. Schlosser RJ, Bolger WE. Spontaneous nasal cerebrospinal fluid leaks and empty sella syndrome: A clinical association. *Am J Rhinol*. 2003;17(2):91–96.
7. Lopatin AS, Kapitanov DN, Potapov AA. Endonasal endoscopic repair of spontaneous cerebrospinal fluid leaks. *Arch Otolaryngol Head Neck Surg*. 2003;129(8):859–863.
8. Banks CA, Palmer JN, Chiu AG, et al. Endoscopic closure of CSF rhinorrhea: 193 cases over 21 years. *Otolaryngol Head Neck Surg*. 2009;140(6):826–833.
9. Kim S, Park CH, Park K. Cerebrospinal fluid rhinorrhea caused by a congenital defect of stapes mimicking otorrhea: Radionuclide cisternographic findings. *Clin Nucl Med*. 2000;25(8):634–635.
10. Chan DT, Poon WS, IP CP, et al. How useful is glucose detection in diagnosing cerebrospinal fluid leak? The rational use of CT and Beta-2 transferrin assay in detection of cerebrospinal fluid fistula. *Asian J Surg*. 2004;27(1):39–42.
11. Philips BJ, Meguer JX, Redman J, et al. Factors determining the appearance of glucose in upper and lower respiratory tract secretions. *Intensive Care Med*. 2003;29(12):2204–2210.
12. Yadav YR, Parihar V, Janakiram N, et al. Endoscopic management of cerebrospinal fluid rhinorrhea. *Asian Journal of Neurosurgery*. 2016;11(3):183–193.
13. Mostafa BE, Khafagi A. Combined HRCT and MRI in the Detection of CSF Rhinorrhea. *Skull Base*. 2004;14(3):157–162.
14. Al-Sebeih K, Karagiozov K, Elbeltagi A, et al. Non-traumatic cerebrospinal fluid rhinorrhea: Diagnosis and management. *Ann Saudi Med*. 2005;24(6):453–458.
15. Schuknecht B, Simmen D, Briner HR, et al. Nontraumatic skull based effects with spontaneous CSF rhinorrhea and arachnoid herniation: Imaging findings and correlation with endoscopic sinus surgery in 27 patients. *AJNR Am J Neuroradiol*. 2008;29(3):542–549.
16. Selcuk H, Albayram S, Ozer H, et al. Intrathecal gadolinium-enhanced MR cisternography in the evaluation of CSF leakage. *AJNR Am J Neuroradiol*. 2010;31(1):71–75.
17. Psaltis AJ, Schlosser RJ, Banks CA, et al. A systematic review of the endoscopic repair of cerebrospinal fluid leaks. *Otolaryngol Head Neck Surg*. 2012;147(2):196–203.
18. Kirtane MV, Gautham K, Upadhyaya SR. Endoscopic CSF rhinorrhea closure: Our experience in 267 cases. *Otolaryngol Head Neck Surg*. 2005;132(2):208–212.
19. Gendeh BS, Wormald PJ, Forer M, et al. Endoscopic repair of spontaneous cerebro-spinal fluid rhinorrhoea: A report of 3 cases. *Med J Malaysia*. 2002;57(4):503–508.
20. Bateman N, Mason J, Jones NS. Use of fluorescein for detecting cerebrospinal fluid rhinorrhoea: A safe technique for intrathecal injection. *ORL J Otorhinolaryngol Relat Spec*. 1999;61:131–132.
21. Lund VJ. Endoscopic management of cerebrospinal fluid leaks. *Am J Rhinol*. 2002;16:17–23.
22. Seth R, Rajasekaran K, Benninger MS, et al. The utility of intrathecal fluorescein in cerebrospinal fluid leak repair. *Otolaryngol Head Neck Surg*. 2010;143(5):626–632.
23. Anari S, Waldron M, Carrie S. Delayed absence seizure: A complication of intrathecal fluorescein injection. A case report and literature review. *Auris Nasus Larynx*. 2007;34(4):515–518.
24. Lloyd KM, Del Gaudio JM, Hudgins PA. Imaging of skull base cerebrospinal fluid leaks in adults. *Radiology*. 2008;248(3):725–736.
25. Presutti L, Mattioli F, Villari D, et al. Transnasal endoscopic treatment of cerebrospinal fluid leak: 17 years' experience. *Acta Otorhinolaryngol Ital*. 2009;29(4):191–196.
26. Wen W, Xu G, Zhang X, et al. Surgical management of cerebrospinal fluid rhinorrhea. *Zhonghua Er Bi Yan Hou Ke Za Zhi*. 2002;37(5):366–369.
27. Chaaban MR, Illing E, Riley KO, et al. Acetazolamide for high intracranial pressure cerebrospinal fluid leaks. *Int Forum Allergy Rhinol*. 2013;3(9):718–721.
28. Scholsem M, Scholtes F, Collignon F, et al. Surgical management of anterior cranial base fractures with cerebrospinal fluid fistulae: A single-institution experience. *Neurosurgery*. 2008;62(2):463–469.
29. Tosun F, Gonul E, Yetiser S, et al. Analysis of different surgical approaches for the treatment of cerebrospinal fluid rhinorrhea. *Minim Invasive Neurosurg*. 2005;48(6):355–360.
30. Darakchiev BJ, Pensak ML. Cerebrospinal fluid dynamics in skull base surgery. *Curr Opin Otolaryngol Head Neck Surg*. 2004;12(5):404–407.
31. Ziu M, Savage JG, Jimenez DF. Diagnosis and treatment of cerebrospinal fluid rhinorrhea following accidental traumatic anterior skull base fractures. *Neurosurgical focus*. 2012;32(6):E3.1
32. Alexander A, Mathew J, Varghese AM, et al. Endoscopic Repair of CSF Fistulae: A Ten Year Experience. *J Clin Diagn Res*. 2016;10(8):MC01–MC04.
33. Nyquist GG, Anand VK, Mehra S, et al. Endoscopic endonasal repair of anterior skull base Nontraumatic cerebrospinal fluid leaks, meningoceles, and encephaloceles. *J Neurosurg*. 2010;113(5):961–966.
34. Briggs RJ, Wormald PJ. Endoscopic Transnasal intradural repair of anterior skull base cerebrospinal fluid fistulae. *J Clin Neurosci*. 2004;11(6):597–599.
35. Locatelli D, Rampa F, Acchiardi I, et al. Endoscopic endonasal approaches for repair of cerebrospinal fluid leaks: Nine-year experience. *Neurosurgery*. 2006;58(4 Suppl 2):ONS-246–256.

36. Landeiro JA, Flores MS, Lázaro BC, et al. Surgical management of cerebrospinal fluid rhinorrhea under endoscopic control. *Arq Neuropsiquiatr*. 2004;62:827–831.
37. Golusinski W, Waśniewska E, Kulczyński B. Endoscopic reconstruction of the anterior skull base in cerebrospinal rhinorrhea. *OtolaryngolPol*. 2003; 57(1):75–79.
38. Kirtane MV, Gautham K, Upadhyaya SR. Endoscopic CSF rhinorrhea closure: Our experience in 267 cases. *Otolaryngol Head Neck Surg*. 2005;132(2):208–212.
39. Virk JS, Elmihyeh B, Stamatoglou C, et al. Optimising outcomes in the management of spontaneous cerebrospinal fluid rhinorrhoea. *Rhinology*. 2013;51(3):268–274.
40. Woodworth BA, Palmer JN. Spontaneous cerebrospinal fluid leaks. *Curr Opin Otolaryngol Head Neck Surg*. 2009;17:59–65.
41. Shi JB, Chen FH, Fu QL, et al. Frontal sinus cerebrospinal fluid leaks: Repairing 15 patients using an endoscopic surgical approach. *ORL J Otorhinolaryngol Relat Spec*. 2010;72(1):56–62.
42. Becker SS, Duncavage JA, Russell PT. Endoscopic endonasal repair of difficult-to-access cerebrospinal fluid leaks of the frontal sinus. *Am J Rhinol Allergy*. 2009;23(2):181–184.
43. Gendeh BS, Mazita A, Selladurai BM, et al. Endonasal endoscopic repair of anterior skull base fistulas: The Kuala Lumpur experience. *J Laryngol Otol*. 2005;119(11):866–874.
44. Paludetti G, Sergi B, Rigante M, et al. New techniques and technology to repair cerebrospinal fluid rhinorrhea. *Acta Otorhinolaryngol Ital*. 2004;24(3):130–136.
45. Marks SC (1998) Middle turbinate graft for repair of cerebral spinal fluid leaks. *Am J Rhinol* 12(6): 417-419.
46. Lanza DC, O'Brien DA, Kennedy DW. Endoscopic repair of cerebrospinal fluid fistulae and encephaloceles. *Laryngoscope*. 1996;106(9 pt 1):1119–1125.
47. Castelnovo P, Mauri S, Locatelli D, et al. Endoscopic repair of cerebrospinal fluid rhinorrhea: Learning from our failures. *Am J Rhinol*. 2005;15(5):333–342.
48. Wormald PJ, McDonogh M. Bath-plug' technique for the endoscopic management of cerebrospinal fluid leaks. *J Laryngol Otol*. 1999;111(11):1042–1046.
49. Friedman M, Venkatesan TK, Caldarelli DD (1995) Composite mucochondral flap for repair of cerebrospinal fluid leaks. *Head Neck* 17(5): 414-418.
50. Cassano M, Felippu A. Endoscopic treatment of cerebrospinal fluid leaks with the use of lower turbinate grafts: A retrospective review of 125 cases. *Rhinology*. 2009;47(4):362–368.
51. Ricardo L Carrau, Carl H Snyderman, et al. Complications of Endoscopic Sinus Surgery: CSF Leak; Operative Otolaryngology: Head and Neck Surgery; Eugene N. Myers; Elsevier Health Sciences; ISBN. 2008;9781437720839.
52. Oakley GM, Orlandi RR, Woodworth BA, et al. Management of cerebrospinal fluid rhinorrhea: an evidence-based review with recommendations. *Int Forum Allergy Rhinol*. 2016;6(1):17–24.
53. Nishioka H, Izawa H, Ikeda Y, et al. Dural suturing for repair of cerebrospinal fluid leak in Transnasal transsphenoidal surgery. *Acta Neurochir (Wien)*. 2009;151(11):1427–1430.
54. Ahn JY, Kim SH. A new technique for dural suturing with fascia graft for cerebrospinal fluid leakage in transsphenoidal surgery. *Neurosurgery*. 2009;65(6 Suppl):65–71.
55. Saafan ME, Albirmawy OA, Tomoum MO. Sandwich grafting technique for endoscopic endonasal repair of cerebrospinal fluid rhinorrhoea. *European Archives of Oto-Rhino-Laryngology* . 2014;271(5):1073–1079.]
56. Cukurova I, Cetinkaya EA, Aslan IB, et al. Endonasal endoscopic repair of ethmoid roof cerebrospinal fluid fistula by suturing the dura. *Acta Neurochir (Wien)*. 2008;150(9):897–900.
57. Dusick JR, Mattozo CA, Esposito F, et al. BioGlue for prevention of postoperative cerebrospinal fluid leaks in transsphenoidal surgery: A case series. *Surg Neurol*. 2006;66(4):371–376.
58. Casiano RR, Jassir D. Endoscopic cerebrospinal fluid rhinorrhea repair: Is a lumbar drain necessary? *Otolaryngol Head Neck Surg*. 1999;121(6):745–750.
59. Lee TJ, Huang CC, Chuang CC, et al. Transnasal endoscopic repair of cerebrospinal fluid rhinorrhea and skull base defect: Ten-year experience. *Laryngoscope*. 2004;114(8):1475–1481.
60. Hegazy HM, Carrau RL, Snyderman CH, et al. Transnasal endoscopic repair of cerebrospinal fluid rhinorrhea: A meta-analysis. *Laryngoscope*. 2000;110(7):1166–1172.
61. Martín-Martín C, Martínez-Capoccioni G, Serramito-García R, et al. Surgical challenge: endoscopic repair of cerebrospinal fluid leak. *BMC Res Notes*. 2012;5:459.
62. Mirza S, Thaper A, Mc Clelland L, et al. Sinonasal cerebrospinal fluid leaks: Management of 97 patients over 10 years. *Laryngoscope*. 2005;115(10):1774–1777.
63. Lindstrom DR, Toohill RJ, Loehrl TA, et al. Management of cerebrospinal fluid rhinorrhea: The Medical College of Wisconsin experience. *Laryngoscope*. 2004;114(6):969–974.
64. Schlosser RJ, Wilensky EM, Grady MS, et al. Elevated intracranial pressures in spontaneous cerebrospinal fluid leaks. *Am J Rhinol*. 2003;17(4):191–195.
65. Woodworth BA, Prince A, Chiu AG, et al. Spontaneous CSF leaks: A paradigm for definitive repair and management of intracranial hypertension. *Otolaryngol Head Neck Surg*. 2008;138(6):715–720.
66. Meier JC, Bleier BS. Novel techniques and the future of skull base reconstruction. *Adv Otorhinolaryngol*. 2013;74:174–183.
67. Carrau RL, Snyderman CH, Kassam AB. The management of cerebrospinal fluid leaks in patients at risk for high-pressure hydrocephalus. *Laryngoscope*. 2005;115(2):205–212.
68. Sautter NB, Batra PS, Citardi MJ. Endoscopic management of sphenoid sinus cerebrospinal fluid leaks. *Ann Otol Rhinol Laryngol*. 2008; 117(1):32–39.
69. Anverali JK, Hassaan AA, Saleh HA. Endoscopic modified Lothrop procedure for repair of lateral frontal sinus cerebrospinal fluid leak. *J Laryngol Otol* . 2009;123(1):145–147.
70. Purkey MT, Woodworth BA, Hahn S, et al. Endoscopic repair of supraorbital ethmoid cerebrospinal fluid leaks. *ORL J Otorhinolaryngol Relat Spec*. 2009;71(2):93–98.
71. McCoul ED, Anand VK, Singh A, et al. Long-term effectiveness of a reconstructive protocol using the nasoseptal flap after endoscopic skull base surgery. *World Neurosurg*. 2014; 81(1):136–143.
72. Sanders-Taylor C, Anaizi A, Kosty J, et al. Sellar Reconstruction and Rates of Delayed Cerebrospinal Fluid Leak after Endoscopic Pituitary Surgery. *J Neurol Surg B Skull Base*. 2015;76(4):281–285.
73. El Shazly AA, El Wardany MA, Abo El Ezz TA. Sellar repair with autologous muscle and composite septal cartilage grafts for treatment of cerebrospinal fluid leakage following trans-sphenoidal pituitary surgery. *Asian Journal of Neurosurgery*. 2016;11(4):433–439.