

**ORIGINAL****Immunohistochemical investigation of the coma blister and its pathogenesis**

Masayuki Kashiwagi<sup>1</sup>, Akiko Ishigami<sup>2</sup>, Kenji Hara<sup>1</sup>, Aya Matsusue<sup>1</sup>, Brian Waters<sup>1</sup>, Mio Takayama<sup>1</sup>, Itsuo Tokunaga<sup>2</sup>, Akiyoshi Nishimura<sup>2</sup>, and Shin-ichi Kubo<sup>1</sup>

<sup>1</sup>Department of Forensic Medicine, Faculty of Medicine, Fukuoka University, Fukuoka, Japan, <sup>2</sup>Department of Forensic Medicine, Institute of Health Biosciences, the University of Tokushima, Graduate School, Tokushima, Japan

**Abstract :** The erythematous patches and vesicles that are observed in coma patients, usually from an overdose of medication, are known as coma blisters. However, it is unknown whether the degenerated sweat gland is a necrosis or apoptosis. We immunohistochemically examined such skin lesions to investigate the characteristics and pathogenesis of the coma blister. Skin lesions were obtained from a forensic autopsy case, a woman in her thirties, of caffeine intoxication. Those lesions were observed in the left femoral, the lower left thigh, and the right knee. Histologically, the skin lesions showed that the keratinocytes had necrosed and the epidermis was thin in some areas. Eccrine sweat gland degeneration was observed. Obvious inflammatory cell infiltrations were not detected. Immunohistochemically, we stained each skin lesion against CD3, CD8, CD45RO, cytokeratin, 70 kD heat shock protein, ubiquitin, 150 kD oxygen regulated protein, and caspase-cleaved keratin 18 neo-epitope M30. They were also stained with an in situ apoptosis detection kit. Degenerated sweat glands featured CD45RO and M30 immunoreactivity. Immunohistochemical staining for CD45RO, CK-L, and M30 might be useful to observe sweat gland degeneration in the coma blister. Therefore, the apoptosis might be related to coma blisters and sweat gland degenerations. *J. Med. Invest.* 60 : 256-261, August, 2013

**Keywords :** coma blister, sweat gland degeneration, apoptosis, intoxication, forensic autopsy cases

**INTRODUCTION**

In forensic autopsy cases, when there are spiloplaxia and vesicles on the body surface, those regions are suspected as having thermal trauma or frostbite congelation (1). Although traditionally associated with barbiturate overdose, they can be seen in the setting of coma due to other etiologies. The vesicles observed by Holzer in cases of barbiturate intoxication have been known for a long time (2).

Received for publication June 18, 2013 ; accepted July 29, 2013.

Address correspondence and reprint requests to Shin-ichi Kubo, 7-45-1 Nanakuma, Jonan-ku, Fukuoka 814-0180, Japan and Fax : +81-92-801-4266.

Both Dr. Kashiwagi and Dr. Ishigami had equal contribution to this manuscript.

The erythematous patches and vesicles that are observed in coma patients, usually from an overdose of medication, are known in the dermatology field as coma blisters (3-5). Recently, it had been reported that a similar spiloplaxia and vesicles are also observed in non-coma cases (6, 7). Therefore, the pathogenesis of those skin lesions is unclear.

In this study, histologically and immunohistochemically, we examined the skin lesions such as spiloplaxia and vesication, observed in forensic autopsy cases. We also investigated the histological and immunohistological characteristics of the coma blister, especially sweat gland degeneration.

## MATERIALS AND METHODS

### *Skin samples*

Skin region samples of bullae and/or discoloration from a forensic autopsy case, and normal skin were collected from other autopsy cases, as follows.

**Case outline :** A female in her thirties was caring for her bedridden mother. One day in November, the mother's care manager visited their house, however, there was no response and none of the doors were locked. The care manager notified the police, and the policeman entered the house and found the daughter dead on her back in her bedroom.

**Autopsy findings :** The decedent was 159.7 cm in height and 43.0 kg in weight. Postmortem lividity was intense on the back. Spiloplaxia with excoriation and spiloplaxia with a red halo were observed in the precordial region. The spiloplaxia with the red halo were observed in the left femoral region. Blisters surrounded by rims of erythema were observed in the left femoral region, the lower left thigh, and the right knee (Fig. 1). The blister on the right knee was 1.0 cm in diameter (Fig. 2). Obvious abnormalities, such as hemorrhages were not observed in the

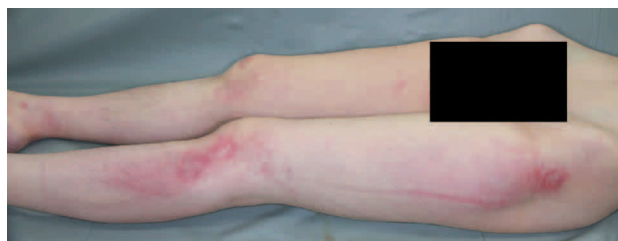

Fig. 1 Blisters surrounded by rims of erythema were observed in the left femoral region, the lower left thigh, and the right knee.

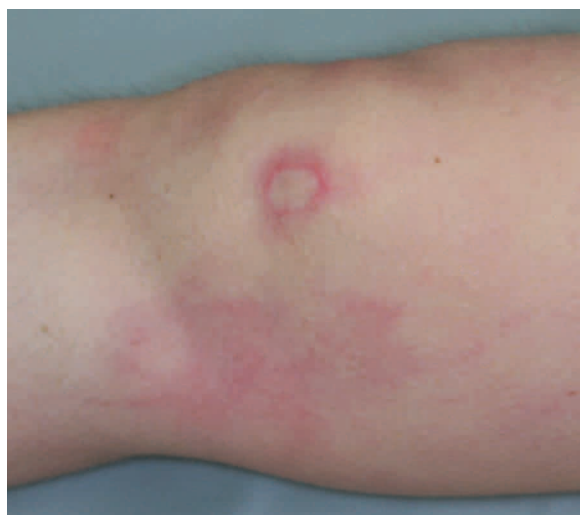

Fig. 2 Blister surrounded by rims of erythema on the right knee

subcutaneous region of these wounds. Five hundred and fifty ml of urine had collected in the bladder. There was no fatal trauma or disease observed.

Autopsy also revealed that postmortem interval (PMI) was suspected for 4 days.

**Toxicological analysis :** Caffeine, ibuprofen, bromovalerylurea, bromoisovaleric acid, and ethoxybenzoic acid were detected in the blood. Caffeine, ibuprofen, bromovalerylurea, ethenzamide, ethoxybenzoic acid, and salicylamide were detected in the urine. Quantitative analysis revealed that ibuprofen, bromovalerylurea, and caffeine were 26, 11, and 52  $\mu\text{g/g}$  in the blood, respectively.

### *Immunohistochemical examinations*

Histological and immunohistochemical examinations of the skin lesions were performed. The samples were fixed in 10% phosphate buffered formalin and embedded in paraffin. Sections of 4  $\mu\text{m}$  thickness were stained with Hematoxylin-eosin (HE).

Immunohistochemically, CD3 (Dako, Japan), CD8 (Leica Microsystems, Germany), CD45RO (Dako, Japan), Cytokeratin, Wide Spectrum Screening (CK-W) (Dako, Japan), Cytokeratin, High Molecular Weight (keratin 34 $\beta$ E12) (CK-H) (Dako, Japan), and Cytokeratin 8, Low Molecular Weight (CK-L) (Dako, Japan), 70 kD heat shock protein (HSP70) (Amersham, USA), ubiquitin (Ub) (DAKO, Japan), 150 kD oxygen regulated protein (ORP150) (Abcom, UK) and caspase-cleaved keratin 18 neo-epitope M30 (M30) (PREVIVA AB, Sweden) were observed using a labeled streptavidin biotin (LSAB)/ horse radish peroxidase (HRP) technique (HISTOFINE SAB-PO kit, Nichirei, Japan), following the manufacturer's instructions. Staining specificity was checked using negative control slides omitting the primary antibody. Additionally, tissue specimens other than positive control tissues were used in a negative control study.

To detect the apoptosis, skin samples were stained by the terminal deoxynucleotidyl transferase-mediated deoxyuridine triphosphate nick end labeling (TUNEL) method with ApopTag<sup>®</sup> peroxidase in situ Apoptosis Detection Kit (Takara Bio Inc., Japan), also according to the manufacturer's instructions.

## RESULTS

Histological examination of the skin lesions from the right knee showed necrosed keratinocytes and the epidermis was thin in some areas. Subepidermal

vesicles were observed in the blister. In the secretory cells of the eccrine sweat glands, eosinophilic homogenization of the cytoplasm and pyknosis or absence of nuclei were observed (Fig. 3).

Summary of the immunoreactivities in the degenerated sweat glands is shown in Table 1.

The degenerated sweat glands showed good immunoreactivities for CK-W and CK-H just like the control. However, the typical immunoreactivity for CK-L decreased (Figs. 4). Weak CD45RO immunoreactivity was observed (Fig. 5). However, no immunoreactivities for HSP70, Ub, or ORP 150 were observed.

Further, apoptosis was not detected by the TUNEL method. Otherwise, mild degenerated sweat glands showed partial M30 immunoreactivity (Fig. 6).

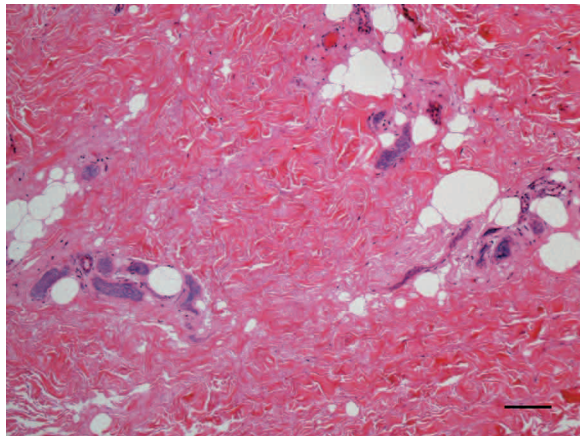
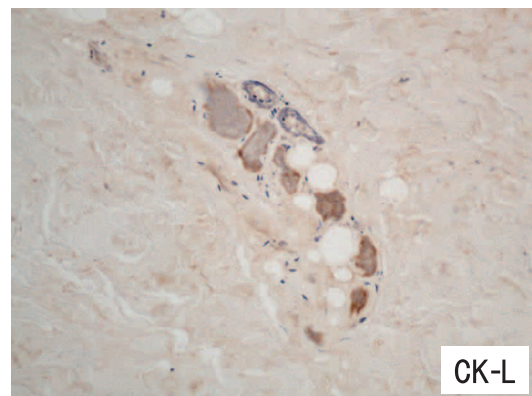
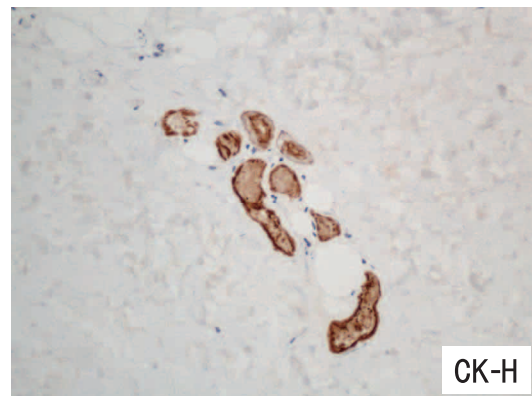
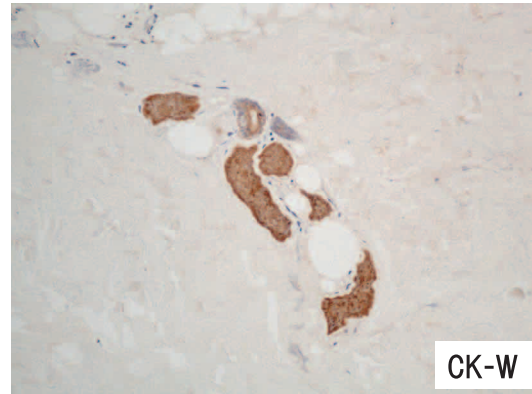


Fig. 3 In the secretory cells of the eccrine sweat glands, eosinophilic homogenization of the cytoplasm and pyknosis or absence of nuclei were observed (right knee). Length of bar indicates 50  $\mu$ m.

Table 1 Immunoreactivities in the degenerated sweat glands

Antigens	Lesion	Control
<i>Inflammatory cell markers</i>		
CD3	-	-
CD8	-	-
CD45RO	+	-
<i>Keratin markers</i>		
CK-W	+	+
CK-H	+	+
CK-L	$\pm$	+
<i>Stress markers</i>		
HSP70	-	-
Ub	-	-
ORP150	-	-
<i>Apoptosis markers</i>		
M30	+	-
TUNEL	-	-



Figs. 4 The degenerated sweat glands showed good immunoreactivities for CK-W and CK-H just like the control, but decreased the typical immunoreactivity for CK-L.

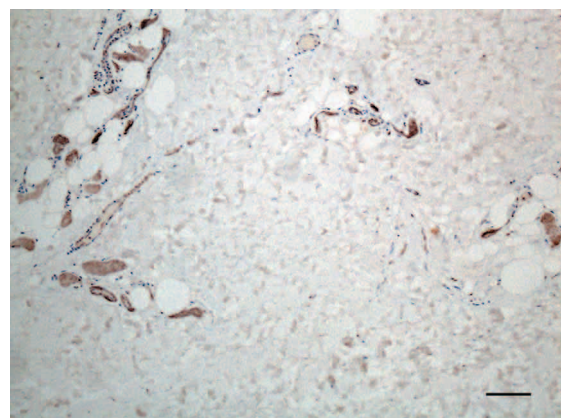


Fig. 5 The degenerated eccrine sweat glands showed weak CD45RO immunoreactivity (right knee). Length of bar indicates 50  $\mu$ m.



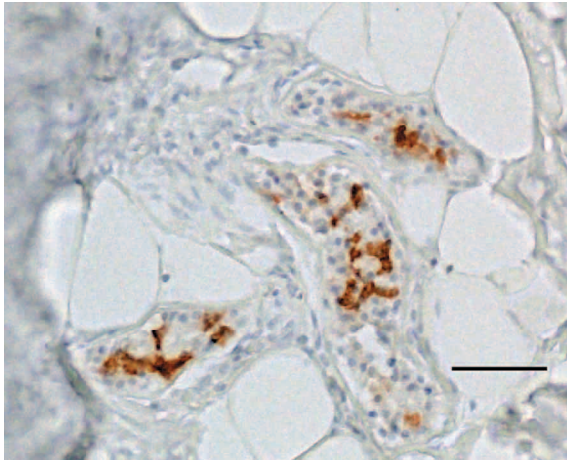


Fig. 6 The mild degenerated sweat glands showed partial M30 immunoreactivity (chest). Length of bar indicates 50  $\mu$ m.

## DISCUSSION

Skin blisters with underlying sweat gland necrosis were first reported by Larrey in 1812 occurring in comatose patients after carbon monoxide intoxication (8). Since then, most previously reported cases with characteristic bullous skin lesions and sweat gland necrosis were comatose secondary to an overdosage of drugs (3-5, 9), carbon monoxide poisoning (10), alcohol toxicity (11), or central nervous system disorders (12) such as hypoglycemia (13) or diabetic ketoacidosis (14). Similar clinical and histopathologic features can also be observed in cases with non-drug-induced coma (6, 15), and in such cases can be interpreted as a drug side effect in the absence of coma (7). Therefore, local pressure, hypoxia, and/or drug toxicity are contributing factors to the formation of coma blisters and sweat gland necrosis (10, 16-20). However, the underlying pathogenesis remains unclear.

Histochemical analysis revealed features similar to those reported in the literature (6, 7, 15, 18). However, inflammatory infiltration, often reported to be observed around the vessels in drug-induced coma (18), was not observed in this case.

In this study, immunohistochemical analysis revealed that sweat gland degeneration was CK-W positive. This result agrees with Setterfield's report (21). CK-L is known to be immunopositive in secretory cells, such as eccrine gland (22-24). Degenerated sweat gland was shown the decreased immunoreactivity for CK-L.

In addition, CD45RO immunoreactivity might suggested a connection between sweat gland degeneration and the inflammatory infiltration participation

of monocytes, macrophages and/or granulocytes (25). CD3 and CD8 immunoreactivities were not observed in sweat gland regions, suggesting less relation to T-cell filtration (26, 27).

Degenerated epidermis and sweat gland degeneration observed in coma blisters were described as necrosis in almost all previous literature (4, 5, 7, 11) and it was the same even after the apoptosis was defined (28). However, a coma blister was observed in a case of DNA fragmentation in one report (29).

During epithelial cell apoptosis, intermediate filaments are reorganized and keratin 18 is cleaved by caspases to liberate M30, one of the most specific and earliest detected indications of apoptosis (30-32). The TUNEL method detects single-stranded (33) and double-stranded breaks associated with apoptosis. Drug-induced DNA damage is not identified by the TUNEL assay unless it is coupled to the apoptotic response (34). In addition, this technique can detect early-stage apoptosis in systems where chromatin condensation has begun and strand breaks are fewer, even before the nucleus undergoes major morphological changes (34, 35).

In this study, the apoptosis was detected by M30 but not by the TUNEL method. This result was not contradicted, because the nucleus had undergone severe morphological changes in the degenerated sweat gland, and the skin lesions were obtained from drug-intoxication cases. Therefore, the apoptosis might be involved in the sweat gland degenerations of coma blisters.

In this study, no sweat gland degenerations were observed except the regions of coma blister. And sweat gland degeneration was not observed in other cases which were suspected in same PMI. So, the sweat gland degeneration was considered as specific for coma blister.

Immunohistochemical staining for CD45RO, CK-L, and M30 might be useful in observing the sweat gland degeneration in coma blisters. There are not so many forensic autopsy cases of the coma blister. Before this study, we found only one case of coma blisters in a case of a female in her twenties with barbiturate intoxication. Prospective studies would be useful to further elucidate the underlying pathogenesis.

## CONCLUSIONS

We investigated the characteristic bullous skin lesions without local pressure after overdosage of

drugs. Microscopically, sweat gland degeneration was observed. Immunohistochemical examination of CD45RO, CK-L, and M30 might be useful for the diagnosis of coma blisters. Further, apoptosis might be involved in coma blisters and sweat gland degenerations.

## CONFLICTS OF INTEREST

We declare that the presenting authors have no conflicts of interest.

## REFERENCES

1. Di Maio DJ, Di Maio VJM : *Foresic Pathology. Deaths due to Fire.* CRC Press LLC, Florida, 1993, pp.327-341
2. Holzer FJ : *Leichenbefunde nach Schlafmittelvergiftung.* Dtsch Z Gesamte Gerichtl Med 34 : 307-321, 1940
3. Beveridge GW, Lawson AAH : Occurrence of bullous lesions in acute barbiturate Intoxication. *Br Med J* 1(5438) : 835-837, 1965
4. Varma AJ, Fisher BK, Sarin MK : Diazepam-induced coma with bullae and eccrine sweat gland necrosis. *Arch Intern Med* 137(9) : 1207-1210, 1977
5. Herschthal D, Robinson MJ : Blisters of the skin in coma induced by amitriptyline and clorazepate dipotassium. Report of a case with underlying sweat gland necrosis. *Arch Dermatol* 115(4) : 499, 1979
6. Kato N, Ueno H, Mimura M : Histopathology of cutaneous changes in non-drug-induced coma. *Am J Dermatopathol* 18(4) : 344-350, 1996
7. Ferrelli C, Sulica VI, Aste N, Atzori L, Pinna M, Biggio P : Drug-induced sweat gland necrosis in a non-comatose patient : a case presentation. *J Eur Acad Dermatol Venereol* 17(4) : 443-445, 2003
8. Larrey DJ : *Memoires de Chirurgie Militaire et Campagnes.* Smith and Buisson, Paris, 1812, Vol. 3, pp.13
9. Holten C : Cutaneous phenomena in acute barbiturate poisoning. *Acta Derm Venereol Suppl (Stockh)* 32(29) : 162-168, 1952
10. Mandy S, Ackerman AB : Characteristic traumatic skin lesions in drug-induced coma. *JAMA* 213(2) : 253-256, 1970
11. You MY, Yun SK, Ihm W : Bullae and sweat gland necrosis after an alcoholic deep slumber. *Cutis* 69(4) : 265-268, 2002
12. Arndt KA, Mihm MC Jr, Parrish JA : Bullae : a cutaneous sign of a variety of neurologic diseases. *J Invest Dermatol* 60(5) : 312-320, 1973
13. Raymond LW, Cohen AB : "Barbiturate blisters" in a case of severe hypoglycaemic coma. *Lancet* 2(7780) : 764, 1972
14. Mehregan DR, Daoud M, Rogers RS 3rd : Coma blisters in a patient with diabetic ketoacidosis. *J Am Acad Dermatol* 27(2 Pt 1) : 269-270, 1992
15. Kim KJ, Suh HS, Choi JH, Sung KJ, Moon KC, Koh JK : Two cases of coma-associated bulla with eccrine gland necrosis in patients without drug intoxication. *Acta Derm Venereol* 82(5) : 378-380, 2002
16. Wenzel FG, Horn TD : Nonneoplastic disorders of the eccrine glands. *J Am Acad Dermatol* 38(1) : 1-17, 1998
17. Adebahr G : Hautveränderungen bei schlafmittelvergiftung. *Landarzt* 30 : 130-138, 1963
18. Sánchez Yus E, Requena L, Simón P : Histopathology of cutaneous changes in drug-induced coma. *Am J Dermatopathol* 15 : 208-216, 1993
19. Achten G, Ledoux-Corbusier M, Thys JP : Carbon monoxide poisoning and cutaneous lesions. *Ann Dermatol Syphiligr (Paris)* 98(4) : 421-428, 1971
20. Sorensen BF : Skin symptoms in acute narcotic intoxication. *Dan Med Bull* 10 : 130-131, 1963
21. Setterfield JF, Robinson R, MacDonald D, Calonje E : Coma-induced bullae and sweat gland necrosis following clobazam, *Clin Exp Dermatol* 25(3) : 215-218, 2000
22. Bártek J, Vojtěšek B, Stasková Z, Bártková J, Kerekés Z, Rejthar A, Kovarik J : A series of 14 new monoclonal antibodies to keratins : characterization and value in diagnostic histopathology. *J Pathol* 164(3) : 215-224, 1991
23. Tsubura A, Okada H, Sasaki M, Dairkee SH, Morii S : Immunohistochemical demonstration of keratins 8 and 14 in benign tumours of the skin appendage. *Virchows Arch A Pathol Anat Histopathol* 418(6) : 503-507, 1991
24. Antley CM, Carrington PR, Mrak RE, Smoller BR : Grover's disease (transient acantholytic dermatosis) : relationship of acantholysis to acrosyringia. *J Cutan Pathol* 25(10) : 545-549, 1998
25. Sewell WA, Cooley MA, Hegen M : CD45

- Workshop Panel Report. In : Kishimoto T, *et al.*, eds. Leucocyte Typing VI, White Cell Differentiation Antigens. Garland Publishing Inc, New York, 1997, pp.499-502
26. Chetty R, Gatter K : CD3 : structure, function, and role of immunostaining in clinical practice. *J Pathol* 173(4) : 303-307, 1994
  27. Mason DY, Cordell JL, Gaulard P, Tse AG, Brown MH : Immunohistological detection of human cytotoxic/suppressor T cells using antibodies to a CD8 peptide sequence. *J Clin Pathol* 45(12) : 1084-1088, 1992
  28. Kerr JF, Wyllie AH, Currie AR : Apoptosis : a basic biological phenomenon with wide-ranging implications in tissue kinetics. *Br J Cancer* 26(4) : 239-257, 1972
  29. Sato K, Kon S : A case of coma blister with DNA fragmentation in the malpighian layer. *JPN J Dermatol* 106(6) : 905-911, 1996
  30. Caulín C, Salvesen GS, Oshima RG : Caspase cleavage of keratin 18 and reorganization of intermediate filaments during epithelial cell apoptosis. *J Cell Biol* 138(6) : 1379-1394, 1997
  31. Leers MP, Kölgen W, Björklund V, Bergman T, Tribbick G, Persson B, Björklund P, Ramaekers FC, Björklund B, Nap M, Jörnvall H, Schutte B : Immunocytochemical detection and mapping of a cytokeratin 18 neo-epitope exposed during early apoptosis. *J Pathol* 187(5) : 567-572, 1999
  32. Bantel H, Ruck P, Gregor M, Schulze-Osthoff K : Detection of elevated caspase activation and early apoptosis in liver diseases. *Eur J Cell Biol* 80(3) : 230-239, 2001
  33. Stratos I, Madry H, Rotter R, Weimer A, Graff J, Cucchiarini M, Mittlmeier T, Vollmar B : Fibroblast growth factor-2-overexpressing myoblasts encapsulated in alginate spheres increase proliferation, reduce apoptosis, induce adipogenesis, and enhance regeneration following skeletal muscle injury in rats. *Tissue Eng Part A* 17(21-22) : 2867-2877, 2011
  34. Wang L, Ohishi T, Shiraki A, Morita R, Akane H, Ikarashi Y, Mitsumori K, Shibutani M : Developmental exposure to manganese chloride induces sustained aberration of neurogenesis in the hippocampal dentate gyrus of mice. *Toxicol Sci* 127(2) : 508-521, 2012
  35. Hori T, Gardner LB, Chen F, Baine AM, Hata T, Uemoto S, Nguyen JH : Impact of hepatic arterial reconstruction on orthotopic liver transplantation in the rat. *J Invest Surg* 25(4) : 242-252, 2012