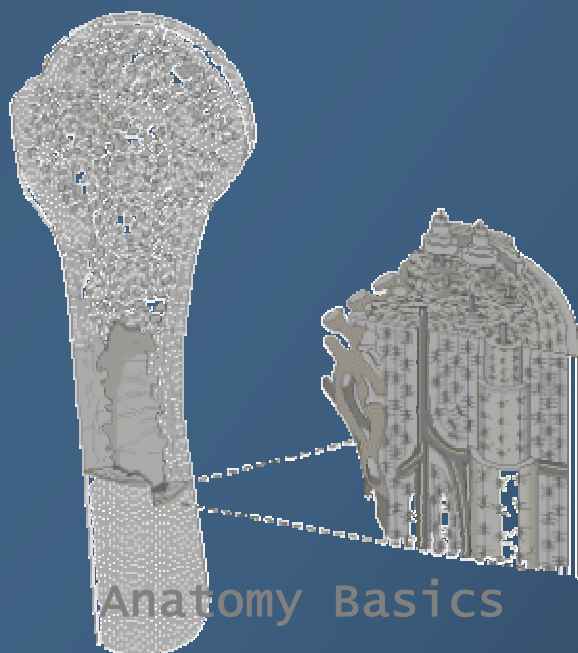


Juraj Artner (ed.)

# ATLAS OF HUMAN SKELETAL ANATOMY

Artner Juraj  
Pekny Petr

Gergelova Katarina



Anatomy Basics

2003

© J. ARTNER, [WWW.JURAJARTNER.COM](http://WWW.JURAJARTNER.COM), 2002

## The Basics

# Introduction to Skeletal Anatomy

J. ARTNER

### Contents

- |                                     |                         |
|-------------------------------------|-------------------------|
| 1.1. Introduction                   | 1.6. Osteology          |
| 1.2. Anatomic Nomenclature          | 1.7. Bone Histology     |
| 1.3. Regions of the Body            | 1.8. Types of Bones     |
| 1.4. Tissues of the Body            | 1.9. The Human Skeleton |
| 1.5. Planes, Directions & Positions | 1.A. Clinical Aspects   |

### 1.1. Introduction

Man has always been fascinated by the interior of his body. The first written documents to survive are clay tablets from around 4000BC in Nineveh. The ancient Egyptians had specialized knowledge in some areas of human anatomy, which they used in mummification and, to a limited degree, surgery. Other great cultures, like the Inuit and the Australian aborigines, developed during their hunting a detailed knowledge of mammalian anatomy. The paintings of the inner parts of humans had through a large period of most civilizations spiritual, religious and mystic components, often with unrealistic body proportions and parts. Although they are for today's medical sciences useless, they reflected the achievement of anatomic wisdom and the progress of medical anatomy as a growing science. For a long period of time, the anatomy knowledge was a hidden treasure, waiting to be explored. The invention of the printing press in the 15<sup>th</sup> century, and the development of woodcut and copper-plate engraving, made it possible to publish multiple copies of illustrated anatomy works, to teach anatomy and to eradicate the past errors. One of the most popular works from the following time was Andreas

Vesalius's *De Humani Corporis Fabrica* (1543), which was a revolutionary step forward in the anatomy. Vesalius could correct most ancient writing's and anatomic illustration's errors by his dissection studies and direct observations.



Fig. 1.1.: Portrait of Andreas Vesalius

*De Humani Corporis Fabrica* became the founding text of modern anatomy, and inspired many scientists, who compared their results with existing texts, corrected errors, and produced new texts with illustrations. The production of images based on dissection became a central component of scientific anatomy.

With the scientific progress of the last centuries, the accuracy of anatomy images grown. The development of microscopes allowed us to see and

determine the macroscopic- invisible structures of tissues. The development of diagnostic and visualization techniques like the x- ray, CT or MR allowed us to see all structures of the body and their topographic relationship.



Fig. 1.2.: Title page illustration for *De Humani Corporis Fabrica* by Jan Stephan van Calcar, showing an anatomy dissection lesson with Vesalius. (Paris, Bibl. de l'Academie nationale de medecine)

The term *anatomy* comes from the Greek and Latin “to cut up” or to dissect. It is the study of body structures and the basis of medical knowledge.

Today's anatomy is divided into subdivision like the macroscopic and the microscopic anatomy, also called *histology*. The field of the macro-anatomy, also called *Gross anatomy* is to study all visible structures, the field of histology is to study tissues and their (micro) structures. Other specialized anatomic subdivisions are:

*Surface anatomy*: studies structures on or immediately underlying the surface of the body

*Systematic anatomy*: studies various systems of which the human body is composed

*Topographical (regional) anatomy*: studies the organs and tissues in relation to one another

*Embryology*: studies the development of tissues and organs

*Cytology*: studies the cells and cellular structure

## 1.2. Anatomic Nomenclature

Toward the end of the 19<sup>th</sup> century, about 50000 anatomical names were in use for some 5000 structures in the human body. By 1895, a list of anatomic terms had been prepared and was accepted by scientists at Basle, known as the Basle Nomina anatomica. The list consisted of about 4500 Latin terms. It was the first important step in the development of an international scientific language. The list was modified since then several times.

In Paris in 1955, international agreement was reached on a Latin system of nomenclature based largely on the Basle Nomina anatomica. Since then, international medical publications should use the standardized Latin terminology for anatomic descriptions.

The following chapters explain the most common anatomic terms and descriptions. They are the basis for the learning and further understanding of anatomy.

### 1.3. Regions of the Body

The human body consists of the following parts (*Partes corporis*):

*Caput*- the head

*Collum*- the neck

*Thorax*- the chest

*Abdomen*- the stomach

*Pelvis*- the pelvis

*Membrum superius*- the arm(s)

*Membrum inferius*- the leg(s)

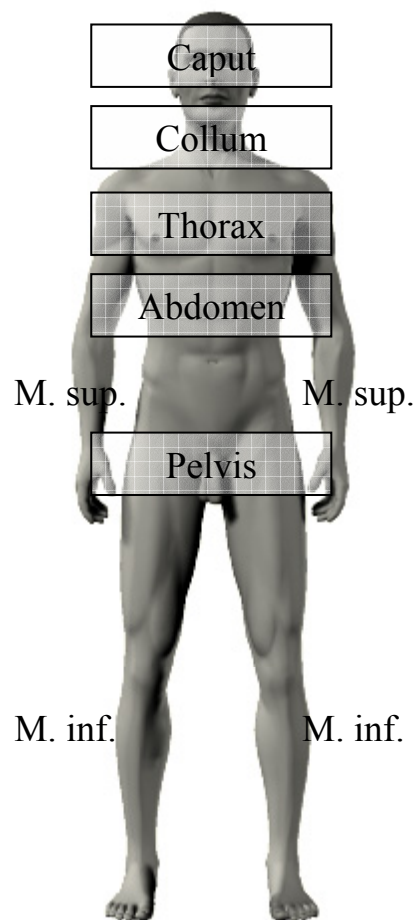


Fig. 1.3.: Parts of the human body.

The regions (*Regiones corporis*) are described similar to body parts but more specific. Their anatomic borders consist of skeletal, muscular and surface components. Their knowledge is important in medical practice, for example to describe localizations of pain on patients.

The regions of the head (*Regiones capitis*) are *Regio facialis* (facial), *Regio frontalis* (forehead), *Regio parietalis* (area above the parietal bone), *Regio temporalis* (area above the temporal bone) and *Regio occipitalis* (area above the occipital bone).

*Regio facialis* is further divided into a *Regio orbitalis* (area above the bones of the eye socket), *Regio nasalis* (nose), *Regio oralis* (mouth), *Regio buccalis* (cheek), *Regio zygomatica* (area above the cheekbone), *Regio infraorbitalis* (area under the eye socket) and a *Regio mentalis* (chin).

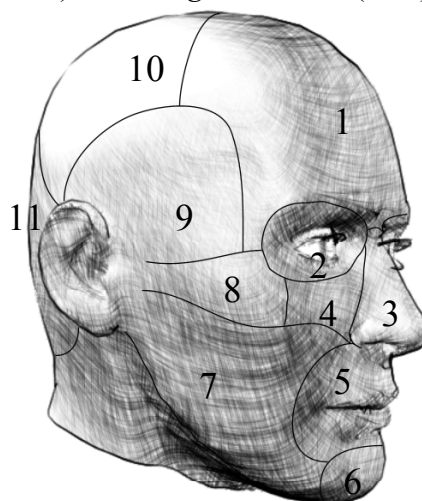


Fig. 1.4.: *Regiones capitis*

Reg. frontalis (1), Reg. orbitalis (2), Reg. nasalis (3), Reg. infraorbitalis (4), Reg. oralis (5), Reg. mentalis (6), Reg. buccalis (7), Reg. zygomatica (8), Reg. temporalis (9), Reg. parietalis (10), Reg. occipitalis (11)

The regions of the neck (*Regiones cervicales*) can be described by finding the *Regio sternocleidomastoidea*, above the muscle of the same name (*Musculus sternocleidomastoideus*; origin at the upper part of the sternoclavicular joint; insertion at the *Processus mastoideus* of the skull base). The muscle and the

corresponding *Regio* divide the neck into central neck regions and the side regions (*Regiones cervicales laterales*), with a fluent transition into the back region of the neck (*Regio cervicalis posterior*; syn.: *Regio nuchalis*) over the *Musculus trapezius*.

The central neck regions are the following: *Trigonum submentale* (submental triangle) is located between the chin (*Regio mentalis*), *Os hyoideum*, between the frontal part of the digastric muscle (*Venter anterior M. digastrici*; origin at the inner side of *Processus mastoideus* of the skull base; insertion at the inner side of *Mandibula*= jaw bone), and the middle axe of the neck. The *Trigonum musculare* (muscular triangle) is located directly under the *Trigonum submentale*, marked by the middle axe of the neck, the lower parts of *Musculus sternocleidomastoideus* and *Musculus omohyoideus* (origin at the upper part of the shoulder blade=*Scapula*; insertion at *Os hyoideum*). The *Trigonum submandibulare* is located between *Musculus digastricus* and the area above the *Mandibula* (jaw bone). *Trigonum caroticum* is located between the back part of *Musculus digastricus*, *M. sternocleidomastoideus* and the upper part of *M. omohyoideus*.

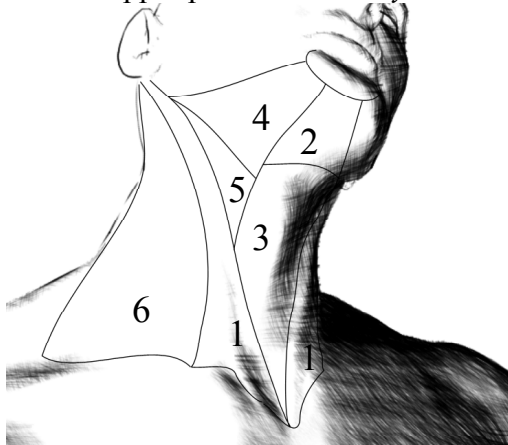


Fig. 1.5.: Regiones cervicales  
Reg. sternocleidomastoidea (1), Tr. submentale (2), Tr. musculare (3), Tr.

submandibulare (4), Tr. caroticum (5), R. cervicalis lateralis (6)

The *Regiones pectorales* of the *Thorax* (regions of the chest) are marked by the following borders:

The upper border represents the *Clavicula* (collarbone), *Regio deltoidea* above the *Musculus deltoideus* (the side border), and the *Arcus costalis* (the curve of the lowest ribs) at the bottom. Due to the different sexual characteristics are the regions of the chest different in female and male.

*Regio praesternalis* above the *Sternum* (breastbone) exists in female and male individuals. *Regio pectoralis* is located on both sides of this area, marked by the *Musculus pectoralis major* (large breast muscle; origin at *Clavicula*, sides of *Sternum* and the first 4-6 ribs; insertion at the upper part of *Humerus*= upper arm). At the side of this region is the area of the armpit (*Regio axillaris*), located between the *Regio pectoralis* and the upper arm.

*Trigonum claviopectoralis* is a triangular area, marked by *Regio deltoidea* (Area above the *Musculus deltoideus*; origin at *Scapula* and *Clavicula*; insertion at *Humerus*), *Regio pectoralis* and *Clavicula*.

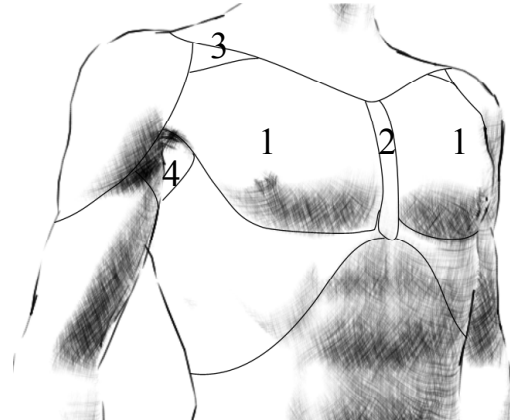


Fig. 1.6.: Regiones pectorales  
Reg. pectoralis (1), Reg. praesternalis (2), Tr. claviopectoralis (3), Reg. axillaris (4)

Female individuals have a *Regio mammaria* above the lower parts of *Regio pectoralis*, marked by the breast borders.

The back of *Thorax* is divided into three regions, a *Regio vertebralis* above the spinal column (*Columna vertebralis*), *Regio scapularis* above *Scapula*, and *Regio subscapularis* between *Regio scapularis*, *vertebralis* and the last ribs.

The regions of the stomach (*Regiones abdominales*) can be described by using virtual lines: a vertical line through the middle of *Clavicula* (medioclavicular line), a horizontal line through the halfway between upper *Sternum* and the upper genital region (the horizontal layer is called *Planum transpyloricum*), and a horizontal line between the humps of the pelvic bone (*Tuberculum iliacum*) on both sides (the horizontal layer is called *Planum intertuberculare*).

*Regio epigastrica* is located right under the *Processus xiphoideus* (at the bottom of *Sternum*) of the skeletal *Thorax*, marked by *Planum transpyloricum* at the bottom, and the medioclavicular lines on both sides.

*Regio hypochondriaca* is located on both sides of *Regio epigastrica*, marked also by *Thorax*, the medioclavicular line and *Planum transpyloricum*. *Regio umbilicalis* (area around the belly) is marked by medioclavicular lines on both sides, by *Planum transpyloricum* at the top and *Planum intertuberculare* at the bottom.

*Regio lateralis* is located on both sides of *Regio umbilicalis*, marked by *Planum transpyloricum*, *Planum intertuberculare* and medioclavicular lines on both sides.

*Regio pubica* is located under the *Regio umbilicalis*, with a flowing transition into the lower located non-abdominal genital region (*Regio urogenitalis*). *Regio inguinalis* is

located at both sides of *Regio pubica*, marked by *Planum intertuberculare* at the top and the course of the groin ligament (*Ligamentum inguinale*; between the frontal upper spine of the pelvic bone= *Spina iliaca anterior superior* to the hump of the pubic bone= *Tuberculum pubicum*) at the bottom.

The abdominal back can be divided into three areas. The first area is the *Regio vertebralis*, a continuation of the *Regio vertebralis* of *Thorax*, with a flowing transition into *Regio sacralis* at the bottom. The third area, *Regio lumbaris* (syn. *lumbalis*), is located at both sides of the abdominal *Regio vertebralis* and marked by the *Regio glutaealis* (of the leg) at the bottom.

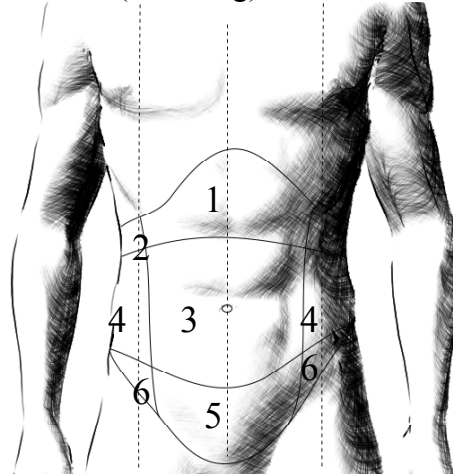


Fig. 1.7.: *Regiones abdominales*  
Reg. epigastrica (1), Reg. hypochondriaca (2), Reg. umbilicalis (3), Reg. lateralis (4), Reg. pubica (5), Reg. inguinalis (6)

The arm consists of the following regions (*Regiones membri superioris*): *Regio deltoidea* (located above the *Musculus deltoideus*; origin at *Scapula* and *Clavicula*; insertion at *Humerus*) is followed downwards by *Regio brachialis anterior* and *posterior* (*Brachium*= the upper arm, anterior= frontal part, posterior= back part) and *Regio cubitalis anterior* and *posterior*

(*Cubitus*= the elbow area) above the elbow joint (*Articulatio cubiti*). The forearm region (*Regio antebrachialis anterior* and *posterior*) ends at the area above the wrist (*Carpus*; *Regio carpalis anterior* and *posterior*). The hand (*Manus*) can be divided into a frontal part (palm) and a back (*Palma* and *Dorsum manus*). It can be further divided into a *Thenar* (the ball of the thumb), a *Hypothenar* (the ball of the last finger), a *Metacarpus* area (above the metacarpal bones), and the fingers (*Digiti*: I- *Pollex*, II- *Index*, III- *Digitus medius*, IV- *Digitus anularis*, and V- *Digitus minimus*).

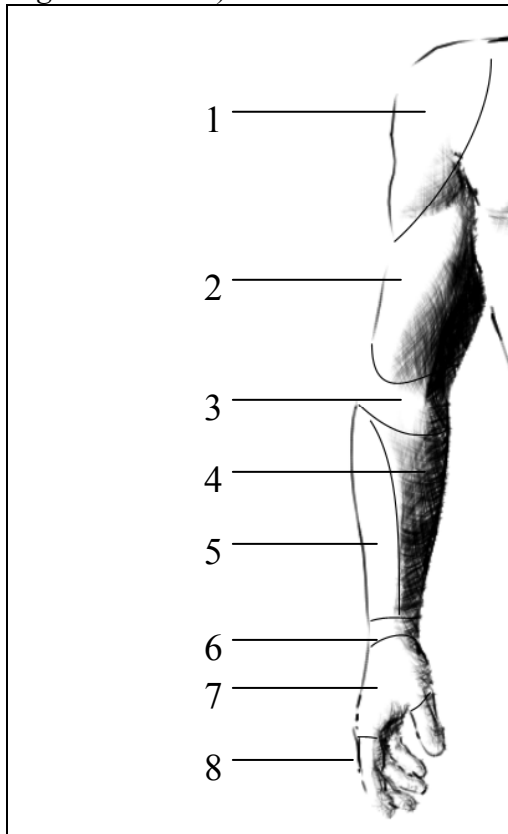


Fig. 1.8.: Regiones membri superioris  
Reg. deltoidea (1), Reg. brachialis anterior (2), Reg. cubitalis anterior (3), Reg. antebrachialis anterior (4) and posterior (5), Reg. carpalis anterior et posterior (6), Dorsum manus (7), Digiti, in this illustration pointing at Digitus secundus= Index (8)

The regions of the leg (*Regiones membri inferioris*) begin under *Regio inguinalis* on the front side and under *Regio lumbaris* on the back.

The front side of the *Femur* (thigh) is called *Regio femoralis anterior*, the back side is covered by *Regio glutaeealis* above the *Musculus glutaeeus maximus* (origin at *Os ilium*, *Os sacrum* and *Os coccygis*= the coccyx; insertion at *Femur* and *Tractus iliotibialis*) and *Regio femoralis posterior*, divided by *Sulcus glutaeealis* (bottom furrow).

*Regio femoralis anterior* contains a region inside, called *Trigonum femorale*, marked by *Musculus sartorius* (origin at the frontal upper spine of the pelvic bone= *Spina iliaca anterior superior*; insertion at upper *Tibia*) and *Musculus adductor longus* (origin at the pubic bone= *Os pubis*; insertion at the back shaft of *Femur* bone= *Linea aspera*) at the sides and *Regio inguinalis* at the top. The area around the knee joint is called *Regio genus (anterior and posterior)*.

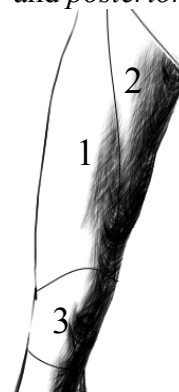


Fig. 1.9.: Regiones femoralis et genus  
Reg. femoralis anterior (1), Tr. femorale (2), Reg. genus anterior (3)

The lower leg (*Crus*) begins under this area, consisting of *Regio cruralis anterior* and *posterior* (the calf area is also called *Sura* or *Regio suralis*). The area of the heel is called *Regio calcanea (Calx)*. The foot (*Pes*) can be divided into an upper area (*Dorsum*

*pedis*), directed against the body, and a bottom area= the sole (*Planta pedis*), directed against the ground.

The foot can be further divided, similar to the hands, into a *Tarsus*, *Metatarsus* and *Digiti* (Toes; I= *Hallux*, II= *Digitus secundus*, III= *Digitus tertius*, IV= *Digitus quartus*, V= *Digitus minimus*).

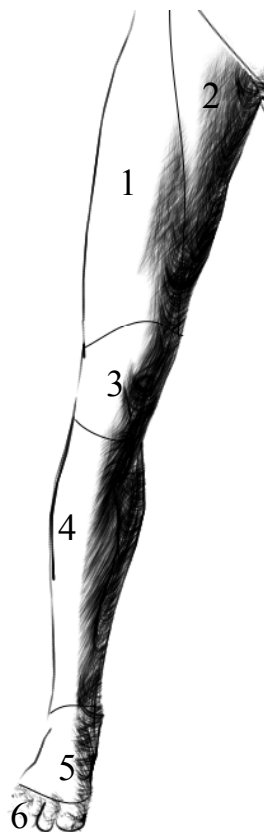


Fig. 1.10.: Regiones membri inferioris  
Reg. femoralis anterior (1), Tr. femorale (2), Reg. genus anterior (3), Reg. cruralis anterior (4), Dorsum pedis (5), Digiti (6)

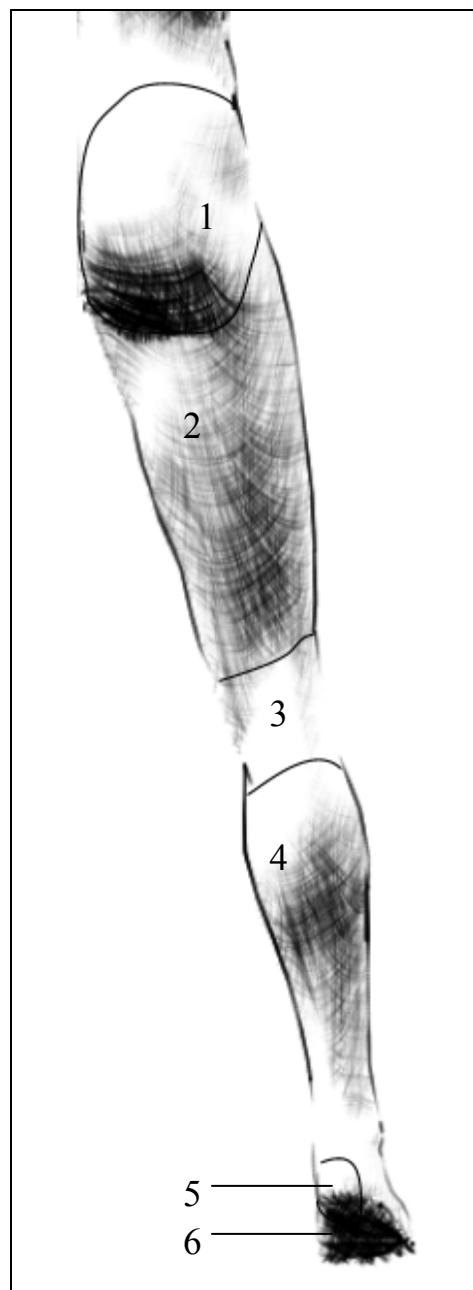


Fig. 1.11.: Regiones membri inferioris  
Reg. glutealis (1), Reg. femoralis posterior (2), Reg. genus posterior (3), Reg. cruralis posterior= Reg. suralis (4), Reg. calcanea (5), Planta pedis (6)



## 1.4. Tissues of the Body

Tissues are defined as cells (and ground substance) acting together in the performance of a special body functions.

The primary tissue categories of the human body are epithelial, connective, muscle, and nervous. The blood could be also seen as a special tissue type.

*Epithelial tissues* are composed of closely aggregated cells and their extracellular matrix, forming a protecting barrier around and in the body. Further functions of epithelial tissues are absorption of nutrients and secretion of substances. Cells may be joined to a single layer (for example alveolar epithelia in lungs, which provide a little diffusion distance for the oxygen) or as multiple layers (for example skin epithelia). The type of cells may vary from cuboidal (for example in kidney tubules) to columnar (for example in the digestive tract) to flattened squamous cells (for example in blood vessels).

Epithelial cells can also form glands, which secrete their products into ducts (exocrine glands) or into blood vessels (endocrine glands).

*Connective tissues* provide support, protection and stability, produce blood cells and fill (empty) spaces. The cells are separated by extracellular matrix (produced by themselves), consisting of fibre proteins like collagen or elastin, glycoproteins, glycosaminoglycans and tissue fluids. The extracellular matrix is responsible for the stable or elastic tissue function. Types of connective tissue are:

*Loose connective tissue* (around blood vessels, groups of muscle cells,...), which is well vascularized and flexible but not very resistant to stretch.

*Dense connective tissue* (in ligaments and tendons) has many collagen fibers

arranged in bundles, is less flexible, but much stronger than the loose connective tissue.

*Elastic connective tissue* (in ligaments) has more bundles of elastic fibers than collagen fibers.

*Reticular connective tissue* (as a supportive framework for bone marrow and lymphatic tissue) consists of reticular fibers, produced by special cells (reticulocytes).

*Adipose tissue* is a special type of connective tissue specialized to lipid (fat) storage, formed by large cells (adipocytes) with small extracellular matrix. It can be divided into a yellow (anywhere in a adults body) and a brown (infants) adipose tissue. Yellow adipose tissue stores lipids, provides thermic and mechanic isolation and body shape. Brown adipose tissue generates heat by utilizing fatty acids.

*Cartilage* is a connective tissue with a solid extracellular matrix, specialized to bear mechanical stress. The cells (chondrocytes) are embedded in the matrix. There are three types of cartilage, classified according to the type of fiber in the matrix.

*Hyaline cartilage* (found at the ends of the long bones and ribs, and forms the fetal skeleton that is later ossified and becomes bone) has a matrix with only very fine collagenous fibers.

*Elastic cartilage* (found at the auricle of the ear, ear canal, eustachian tube, and epiglottis) has a matrix containing many elastic fibers.

*Fibrocartilage* (found in the intervertebral discs and the knee joint) contains a dense network of collagen fibers with a good resistance to tension and pressure.

*Bone tissue* is the forming component of the skeletal system, protecting inner body cavities, providing movement (as a lever, by converting muscle

contractions into movements) and blood cell formation, and storing minerals like calcium (which give the bone the specific rigidity). More specific information about the bone tissue will be described in chapter 1.7. Osteology.

*Muscular tissue* is composed of fibers, which contain contractile actin and myosin filaments. They allow the muscle to provide contractions, movement or to turn body parts, depending on the location, the origin and the insertion of the muscle. Three types of muscles can be found in human body, depending on the microscopic appearance, location and function:

*Skeletal muscle*, which is under voluntary control, is attached to the bones and moving body parts.

*Smooth muscle*, found in organs and vessels, is under control of the autonomous nervous system (involuntary).

*Cardiac muscle* is located in heart, is striated like skeletal muscle (histology), but it is under control of the autonomous nervous system (involuntary) like the smooth muscle

*Nervous tissue* is distributed through the whole body, consisting of cells (called Neurons) with fibers (called Dendrites if conducting signals to Neuron body from and Axons if conducting signals to the periphery), specialized in communication and signal transmission, and of cells (Schwann cells and Glia), which encircle and isolate the fibers. The nervous network system is divided into a central nervous system (brain and spinal cord) and into a peripheral nervous system (covering all body parts).

## 1.5. Planes, Directions and Positions

In order to describe positions and orientations of structures of the human body in three dimensions, the body is supposed to be in standing position, looking forward, arms at sides with palms of the hands pointing forward, and feet together pointing forward.

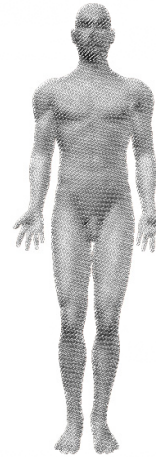

Fig. 1.12.: Standard anatomic position

To describe topographic relationships of structures or parts to other structures in body, we use following terms:

The terms *superior* or *cranial* (*cephalic*) indicate that a structure is located at a higher level or closer to head. The opposite of these are the terms *inferior* or *caudal*, which indicate that a structure is located at a lower level or downwards. In case of the limbs, the terms *proximal* and *distal* indicate the level or the relative distance from the attached end of the limb (for example: the arm in standard anatomic position; *proximal* would mean near to the shoulder; *distal* would mean further away or located lower).

The terms *anterior* or *ventral* indicate a relation to the front of the body or a structure. The terms *posterior* or *dorsal* indicate that a structure is located near to the back of body.

The terms *medial* and *lateral* refer to a structures position in relation to the medial plane (or the long axis) of the body or a structure (*medial*: toward midline; *lateral*: away from midline or located at the side).

The terms *superficial* or *profundal* are used to describe a position or location relative to the surface of areas, structures or tissues. The term *superficial* indicates that a structure is located close to the surface of a tissue,

the term *profundal* indicates, that it is located deeper.

The terms *internal* and *external* describe a structure's position or a view in relation to inner and outer surfaces (for example in organs or cavities).

The term *ipsilateral* indicates that two structures are located at same side of body. The term *contralateral* indicates the opposite (opposite side of body).

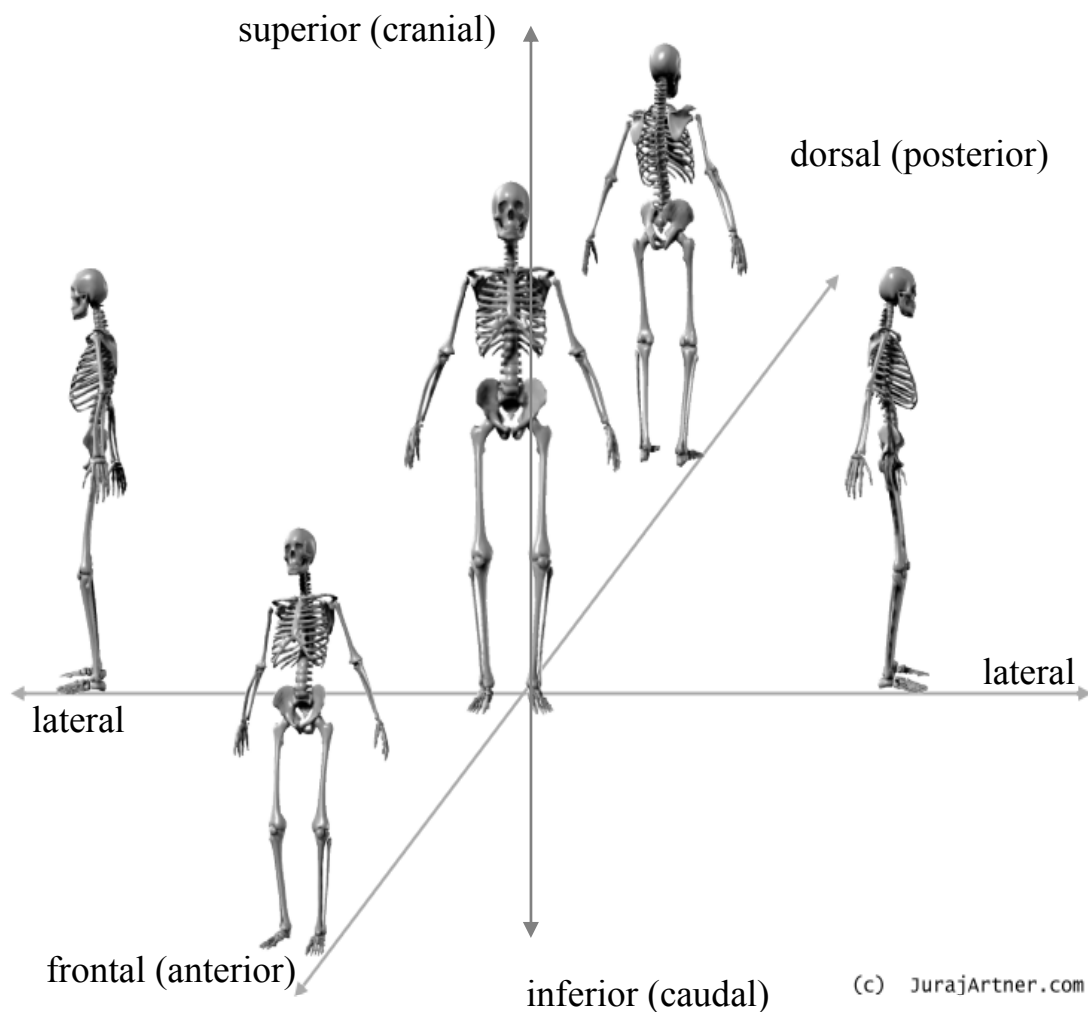


Fig. 1.13.: Positions, relative locations and directions

Because of different presentations of body structures in images (for example illustration, x-ray, or Ct), it is important to know the planes of reference:

The *sagittal (median) plane* is a vertical *anteroposterior* plane, which divides the body into right and left halves. Slices paralleling this plane are

called *paramediansagittal* or *parasagittal* planes.

The *frontal* (or *coronal*) *plane* stands at right angle to the *sagittal plane* and divides body into *anterior* and *posterior* halves.

The *transverse* (or *horizontal*) *plane* stands perpendicular to the *sagittal* and *coronal* plane and divides the body into superior and inferior halves. In case of an organ or other body structure, the *horizontal plane* is at right angle to the long axis of that structure (cross section).

It is also possible to make oblique planes (for example MR- tomography special cuts), which lie at any other angles.

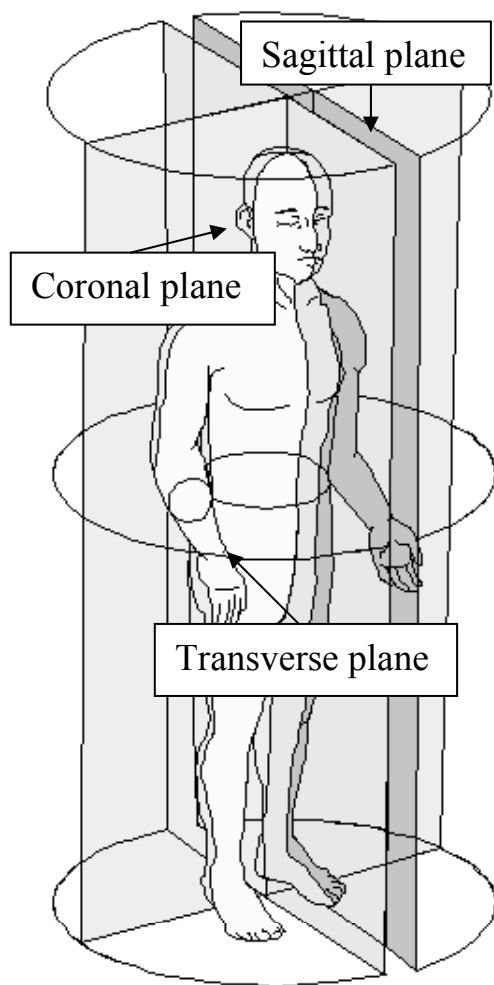


Fig. 1.14.: Planes of the human body

When describing body or a structure in three dimensions, there are six standard perspectives, which can be also put together or mixed (example: a view from behind and the base) if following the rules of three dimensional presentations (a useful help is to put the body into a virtual cube).

The following perspectives were first described on skulls but can be used for the whole body.

The perspective from in front is called *Norma frontalis*, from behind called *Norma occipitalis* or *dorsalis*. The side perspective is called *Norma lateralis*.

*Norma basalis* (or *basilaris*) is the perspective from the base, *Norma verticalis* from above. Like already mentioned, two perspectives can be put together to achieve an oblique view of some structures (for example *posterolateral* view).

Some authors use also the terms *Aspectus* or *Facies* to describe a perspective of a view (*Aspectus inferior, superior, anterior, posterior, lateralis* or *Facies interna, externa, inferior, superior, anterior, posterior* and *lateralis*).

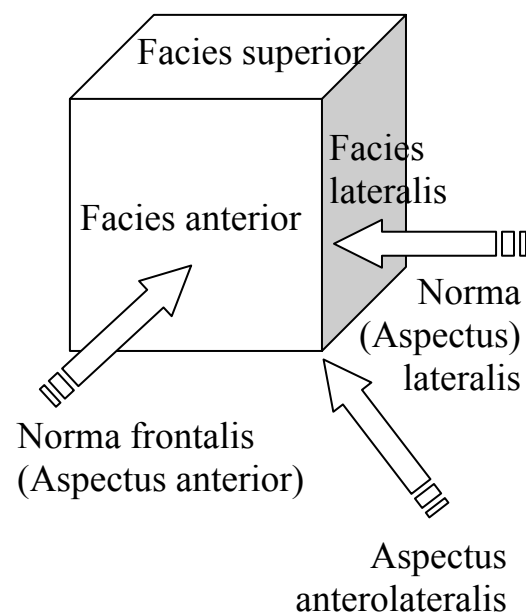


Fig. 1.15.: Examples for views, areas and perspectives

## 1.6. Osteology

Osteology as a science, a subdivision of anatomy, surgery, orthopedics and many other clinical fields is focusing on the study of bone tissue.

Two different bone components can be found (macroscopically) at human bones: one dense in texture (*Substantia*

*compacta* or compact bone tissue) at the outer parts of bones (thick wall at the shaft of long bones, thin layer at the ends), the other consists of thin fibers and sheets of bone, trabeculae, which form a reticular, spongy like network at the ends of long bones (*Substantia spongiosa*, *trabecular* or *cancellous bone* tissue) and in vertebrae.

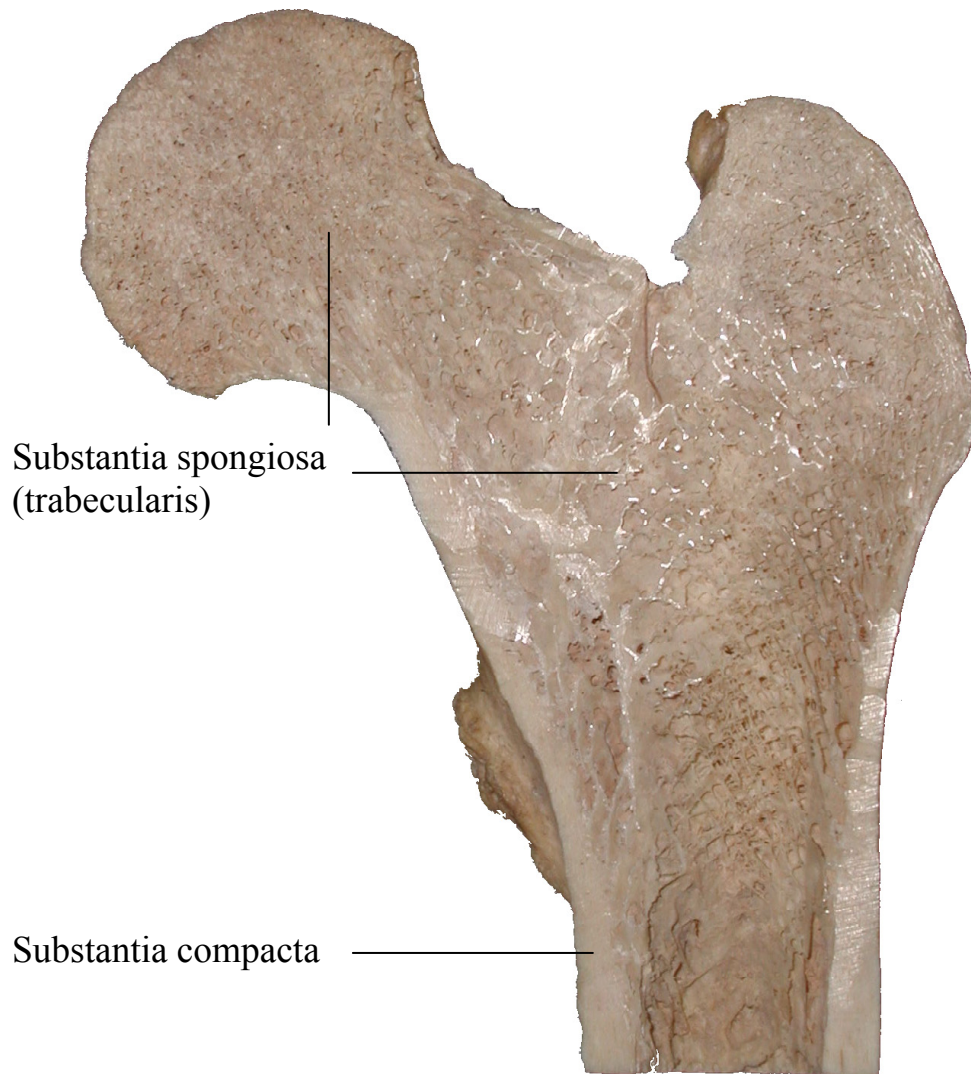


Fig. 1.16.: Frontal section through the head of Femur (bone of the thigh)

© Pekny P., 2002

*Substantia compacta* (cortical bone) is found primary in the shaft of long bones and forms the outer shell around *Substantia spongiosa* (cancellous bone) at the end of joints. The inner parts of the head are filled with spongy bone tissue.

The gross structure of a long bone can be divided into the following regions:

- *Epiphysis* with articular (joint) cartilages
- *Diaphysis*
- *Metaphysis*
- *Epiphyseal (growth) plate (Physis)* in actively growing bones

*Epiphysis* is located at the ends of long bones, between articular cartilages and the growth plate. It is present at each end of long limb bones. Exceptions are the metacarpal and metatarsal bones, bones of the fingers and toes (*Phalanges*), the ribs (*Costae*) and the collarbones (*Clavicula*), where the *Epiphysis* is at only one end present. The interior of this region is filled with spongy trabecular bone tissue with only a thin external cover of compact bone.

*Diaphysis* is the shaft of long bones. It is located between both *Metaphyses* and consists of compact bone walls and an inner cavity (*Cavitas medullaris*), filled with the bone marrow.



Fig. 1.17.: Diaphysis of a long bone  
© Pekny P., 2002

*Metaphysis* is located between the growth plate and the *Diaphysis*. The cortical bone thins here relative to the *Diaphysis*.

The *growth plate (Physis)*, separating the *Epiphysis* from the *Metaphysis* in growing bones, is the zone of ossification (bone growth). In adult bones (which are fully- grown) only a scar is present.

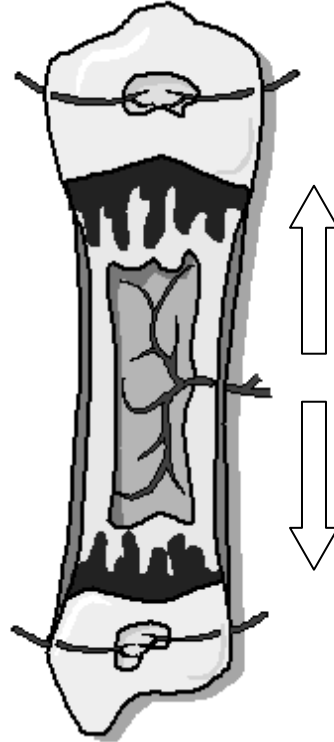


Fig. 1.18.: Development of long bones  
The arrows show the direction of the endochondral ossification within a hyaline cartilage model, which provides a template of the shape of the bone to be formed. In the next step, the cartilage is replaced by bone. This type of ossification is found in long and short bones, but not in flat bones.

Further macroscopically visible structures, like *Foramina* (holes in a bone through which nerves or nutritive vessels pass), *Processus* (bony prominences), *Tuberositas* (raised and rough elevations of bone to which a ligament, tendon, or muscle attaches), *Spinae* (sharp lumps), *Tuberculum* (rounded lumps), *Sulci* (grooves), *Incisurae* (incisions) and *Fossae*

(depressions) will be described for each bone in further chapters.

The external surface of bones (except the articular cartilages) is surrounded by a thin layer of dense connective

tissue and *Osteoprogenitor cells* (see next chapter), called *Periosteum*. It is anchored to the bony surface by *Sharpey fibers (fibrae)* that penetrate into the bone.

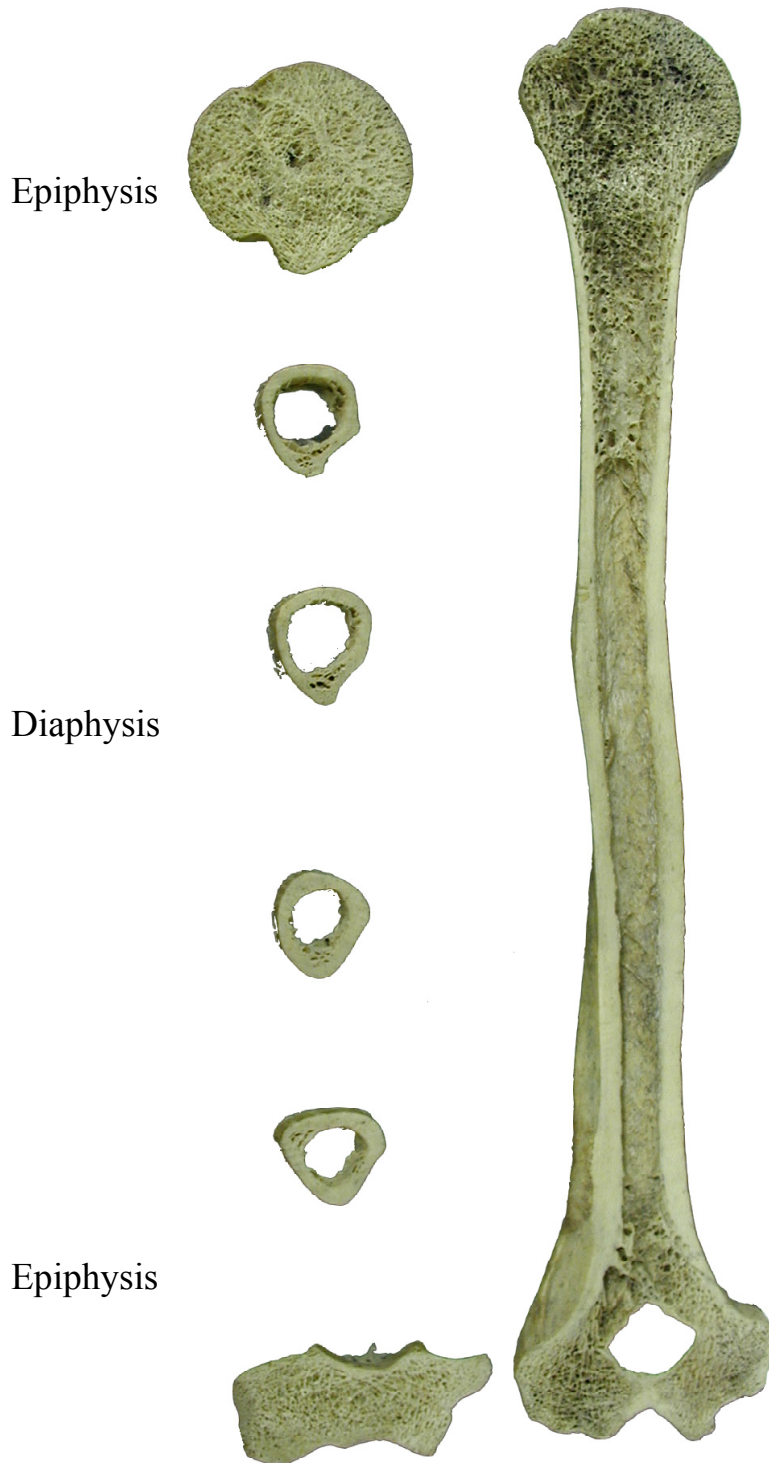


Fig. 1.19.: Frontal and horizontal sections through Humerus

The articular cartilage (*Cartilago articularis*) is located at joints, movable areas where bones are in contact with other bones. The function of the articular cartilage (hyaline cartilage) is to provide a smooth contact surface in a joint (*Facies articularis*). It consists, similar to other connective tissues of cells (*Chondrocytes*) and extracellular matrix, but has in contrast to other tissues no vascularization (vessels) and nutrients have to diffuse from *synovial fluid* (nutrient rich fluid in the joint capsule). Therefore the cartilage is more susceptible to damages, than most other tissues. We will discuss joints and joint-associated structures for each articulation separately.

### 1.7. Bone Histology

Like all connective tissues, cartilage and bone consist of cells and extracellular *matrix*.

The matrix consists of fibers (collagen, reticular, and elastic) and amorphous ground substance, which contains proteoglycans, abundant calcium and phosphorus, bicarbonate, citrate, magnesium, potassium, sodium and hyaluronic acid in the bone tissue, which is called *Osteoid* before it becomes calcified and hard.

The cells of the bone tissue can be classified by their function and activity.

*Osteoblasts* which are located on the surface of bone or *Osteoid* produce the extracellular matrix and enzymes needed for the calcification of the matrix (*Osteoid*). After an *Osteoblast* is encased (covered) by *Osteoid matrix* produced by itself, it becomes an *Osteocyte*. When the extracellular matrix becomes hard it is located in a small cavity, called *Lacuna* and contacts its neighboring *Osteocytes* through thin cellular extensions, lying

in small bony ducts or canals, called *Canaliculi*.

*Osteocytes* have a reduced synthetic and mitotic activity (cell division). In most cases they stay at their location until they die. In some cases they can reactivate into *Osteoblasts* by returning into the *Osteoprogenitor* cell stage and further differentiation.

The third cell types are the multinucleated *Osteoclasts*, derived from the *monocytic-macrophage system* (cells specialized in eating and digestion of bacteria, cell structures, etc...). They are responsible for the bone resorption and bone remodeling during life. The resorption craters, *Osteoclasts* are lying in during the matrix resorption are called *Howship lacunae*.

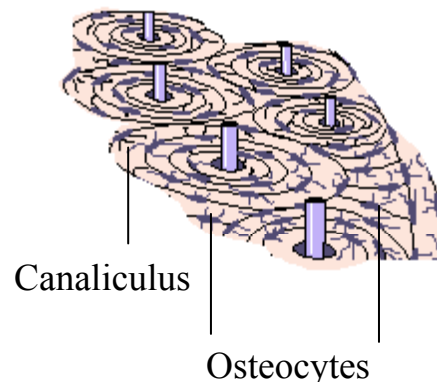


Fig. 1.20.: Osteocytes in Lacunae  
Also in picture: Canaliculi around Osteocytes, Lamellae, and Haversian channels with central vessels (explained in text)

The components of bone tissue are in compact bones organized into strong units, called *Osteons* or *Haversian systems*, lamellar cylinders along the long axis of bones with an average diameter of 0,05mm.

Each *Haversian system* consists of a central canal (*Haversian canal* or *Canalis centralis Havers*), surrounded



by concentric thin plates of bony tissue (*Lamellae*). The lamellae are held together by oblique (Sharpey) and reticular fibers between them. The *Lacunae* are also situated between the *Lamellae*, occupied by *Osteocytes*. Small communication canals (through *Lamellae*) between two *Lacunae* are called *Canaliculi*.

The *Haversian canal* contains one or two blood vessels and thin nerve filaments. It communicates with the bone marrow cavity (*Cavitas medullaris*) and the *Periosteum* (outside of bone) through oblique canals (*Volkman canals*, which penetrate the lamellar structures).

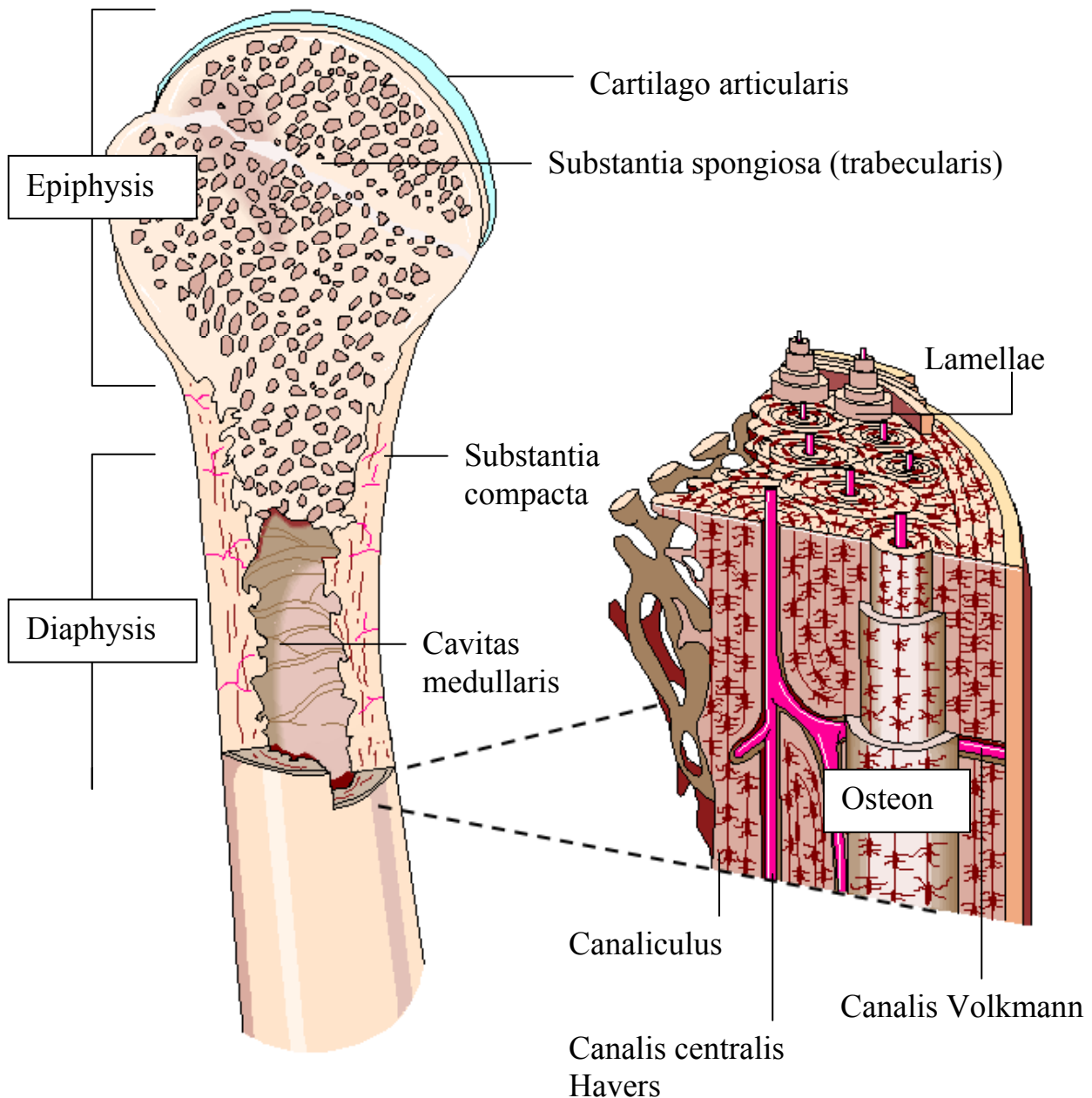


Fig. 1.21.: Structures of long bone  
Microscopic view of compact bone tissue with Haversian systems

Some *Haversian systems* can be incomplete (*interstitial lamellae*), for example non- circular. Such systems are remnants left behind from former *Haversian systems* by bone remodeling during life.

### 1.8. Types of Bones

Based on shape, bones (*Ossa*) can be classified as follows:

Long bones (*Ossa longa*) are longer than they are wide, are tubular in shape and have two ends. The long cylindrical body (*Corpus*, *Diaphysis*) consists of compact bone and has a central medullar cavity. The ends consist of spongy bone surrounded by a thin layer of compact bone. Typical long bones are the tubular bones of the limbs (*Humerus*, *Radius*, *Ulna*, *Femur*...).

Short bones (*Ossa brevia*) are cubical in shape. They consist of spongy bone covered by a thin layer of compact bone. *Ossa brevia* can be found in the wrist and ankle (*Carpus* and *Tarsus*).

Flat bones (*Ossa plana*) are thin and have broad surfaces. They are composed of two layers of compact bone tissue enclosing between them a variable quantity of cancellous bone (called in the skull bones *Diploe* with inner and outer table). The *Diploe* can be locally absorbed and become pneumatic in some skull bones, forming inner bone cavities filled with air (*Sinus*). Such pneumatic skull bones are also called *Ossa pneumatici*. The flat bones are *Os coxae* (the hip bone), *Scapula* (shoulder blade), *Sternum* (breastbone), *Costae* (ribs), and some skull bones (*Os frontale*, *Os occipitale*, *Os parietale*...).

Irregular bones (*Ossa irregularia*) cannot be grouped into the upper categories because of their shape. They consist of spongy bone covered by a thin layer of compact bone. Irregular bones are the *Vertebrae*, *Os sacrum*, *Mandibula*, *Os sphenoidale*...

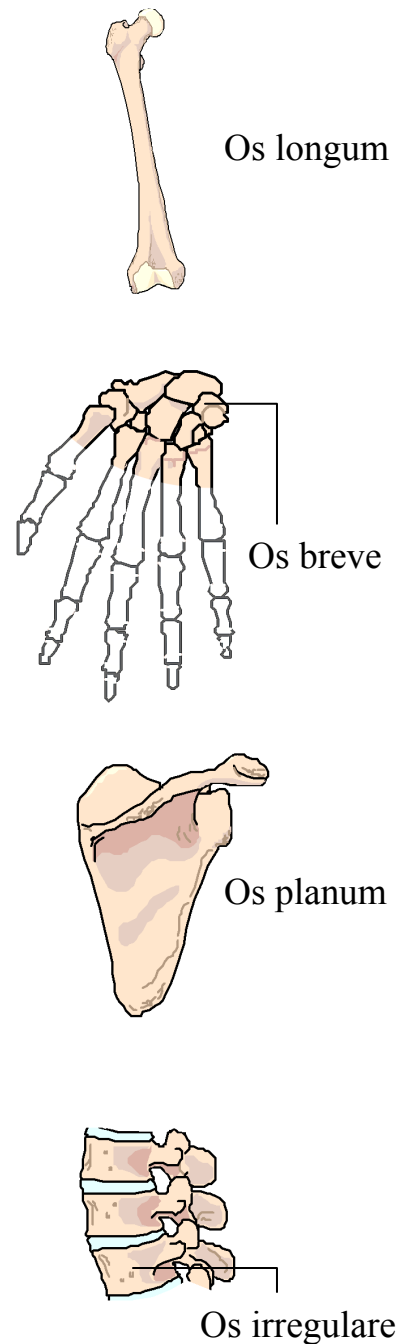


Fig. 1.22.: Types of bones

Sesamoid bones (*Ossa sesamoidea*) are a special type of bones which occur in tendons. A typical sesamoid bone is the *Patella* of the knee. According to some authors *Patella* can also belong to the group of short or flat bones.

### 1.9. The Human Skeleton

Bones are forming a protective and supportive framework, the skeleton. The functions of the skeleton are the following:

The skeletal system protects and stabilizes inner structures like thoracic organs (lungs, heart) or the brain it acts as a lever to provide movements by muscular contractions and supports the body's upright posture, it produces blood cells in marrow (*Haematopoiesis*) and stores almost all body calcium.

The skeleton of an adult consists of 206 bones. This number must be seen as a variable because of possible variations in the number of the ribs, the sacral vertebrae or of the sesamoid bones.

Following the body axis, the skeleton may be divided into an *axial skeleton*, which consists of the bones of the skull, the hyoid bone, the vertebral column and the thoracic cage, and into an *appendicular skeleton*, consisting of the pectoral- and the pelvic girdle and of the bones of the upper- and the lower limbs.

One of the most important skeletal parts is the skull (*Cranium*) consisting of 22 flat and irregular bones, separated from each other by immovable joints called *Suturae*. Its primary function is the protection of the brain, lying in a bony cavity.

At the skull- base, skull is in contact with the vertebral column (*Columna vertebralis*), which extends from the

skull to the pelvis. The vertebral column normally consists of 26 irregular bones, separated from each other by fibrous pads called *Disci intervertebrales*, which protect the vertebral column by making the contact surfaces smoother and by absorbing shocks.

The primary function of the vertebral column is the protection of the spine (*Medulla spinalis*), the supporting of standing posture of the body and of the thoracic cage. The 12 pairs of ribs (*Costae*) of the thoracic cage (*Thorax*) are fixed to the sides of *Vertebrae*, contacting at the front of the thoracic cage the breastbone (*Sternum*). One collarbone (*Clavicula*) is attached at each side of the upper frontal parts of *Sternum*, contacting the shoulder blade (*Scapula*), located at the upper parts of the thoracic backside.

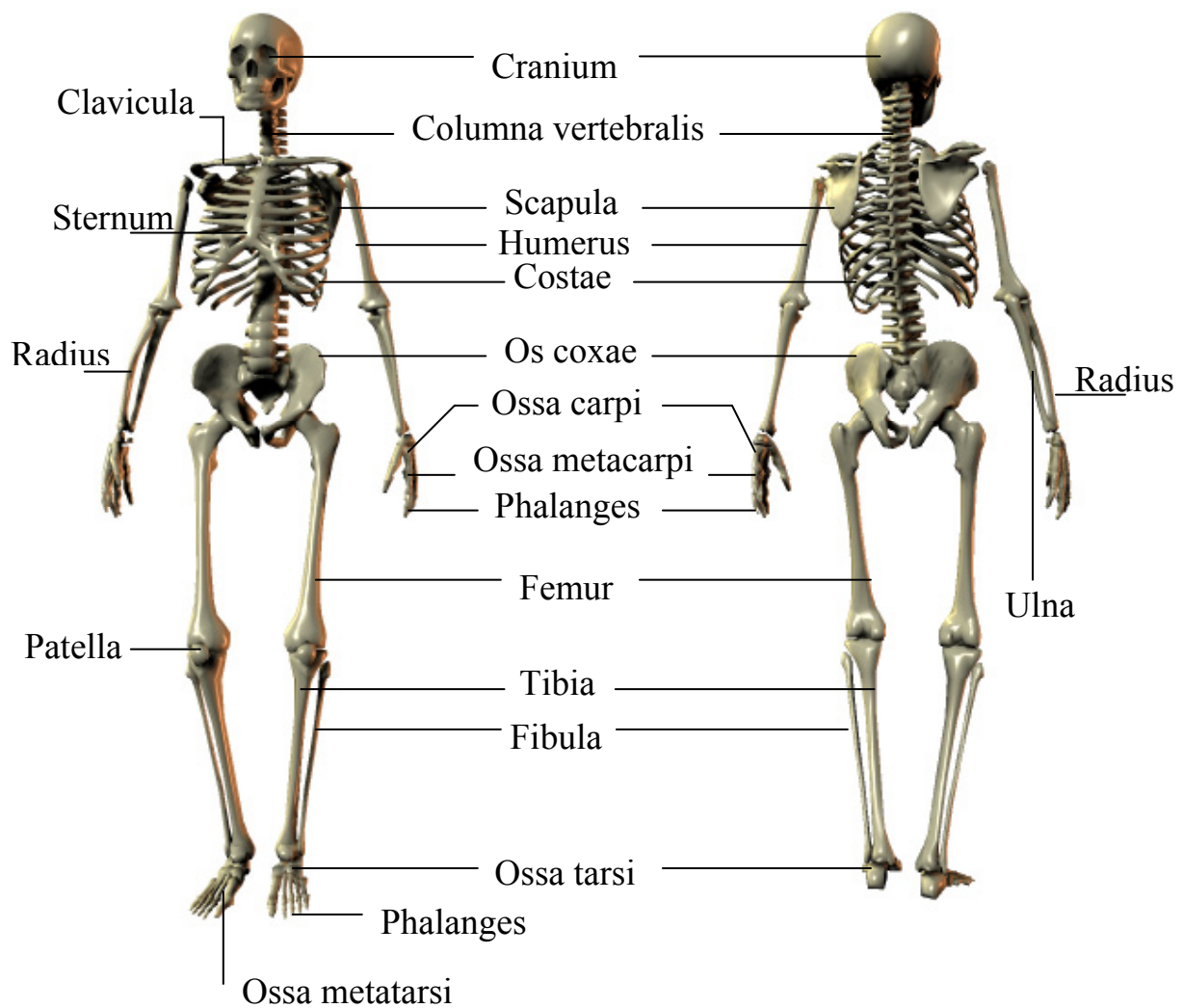
The limbs begin with the contact of *Scapula* to the upper arm bone (*Humerus*) at the height of the upper chest, and with the contact of the pelvic girdle (consisting of three bones, which are attached to the sacral vertebral column) with the thigh bone (*Femur*) at the height of pelvis on both sides.

*Humerus* has contact to two bones, *Radius* and *Ulna*. In standard anatomic position, *Ulna* is located medialward and *Radius* lateralward. Both bones form with their distal ends a forked articulation surface for the proximal carpal bones (*Ossa carpi*). There are eight *Ossa carpi* on both sides. The distal carpal bones have contact to the five metacarpal bones (*Ossa metacarpi*), which have contacts to the proximal finger bones (*Phalanges*). With the exception of the (first) thumb, consisting of two *Phalanges*, each finger consists of three *Phalanges*. Additional sesamoid bones can occur at the medial portion of the first *Phalanx*.

The distal end of *Femur* has contacts to three bones, the medialward located *Tibia*, the lateralward located *Fibula*, and the *Patella*, located in front of the distal *Femur* end. *Tibia* and *Fibula* form with their distal ends, similar to the bones of the forearm, a forked articulation surface for the proximal tarsal bone called *Talus*. The distal row

of the following six tarsal bones (*Ossa tarsi*) has contacts to five metatarsal bones (*Ossa metatarsi*).

The bone distribution in the toes is similar to the fingers of the hand. There are only two *Phalanges* following the first *Os metatarsale*, every other toe has three *Phalanges*.



[c] JurajArtner.com

Fig. 1.23.: Models of the human skeleton, Aspectus anterior and posterior

Seven additional bones should be mentioned for the completeness of the skeleton: The hyoid bone (*Os hyoideum*), located under the frontal part of the skull above the larynx, and the three small auditory bones (*Ossicula auditoria*) at each side, hidden in cavities in temporal bones of the skull.

### 1.A. Clinical Aspects

This chapter deals with the question “Why is anatomy so important for doctors?” or “Why should I know about human anatomy?”

We will try to put more such chapters or clinical cases to the following work to show how anatomy can be used in practice (and why a medicine student should know it).

Every day doctors are confronted with patients with broken bones (fractures). A fracture is an interruption of bone continuity and needs (with the exception of very little fractures) to be corrected.

A doctor's first step in the diagnosis is the inspection of the area (searching for possible edges under the skin, open fractures, bleedings, and additional injuries of nerves, vessels or soft tissues). The next step in the diagnosis is always an x-ray, where an image is developed by different ray- absorptions in structures.

Computer tomography is similar to this procedure, which is often used in diagnosis of skull fractures and bleedings or other complicated fractures. A computer tomography image is a horizontal cut through the body at a specific height (horizontal planes).

In both cases a good knowledge of topographic anatomy is needed.

The therapy comes after the diagnosis which can be in case of some fractures a reposition of fragments and a plaster, in other cases surgical fracture stabilization. It does not matter which therapy type we choose, in both cases a second x-ray for the control of therapy (reposition) success has to be made.

The diagnosis and therapy of benign and malignant tumors is the next example. The knowledge of the exact tumors location, expansion and dignity is the base for the further radiotherapy or the surgical treatment.

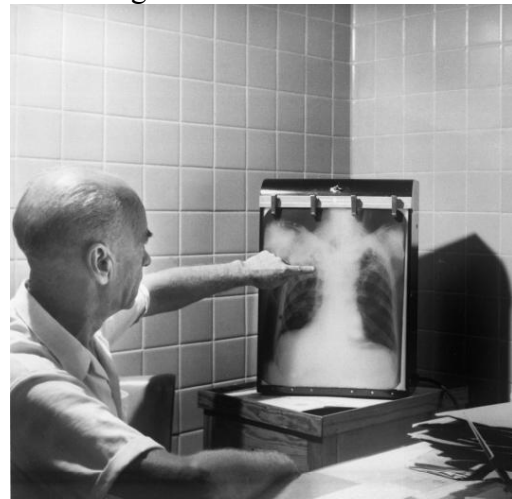


Fig. 1.24.: Image of a physician, showing a suspicious area located in the upper right lung; (Image is public property, acquired from the National Health Image Library, US)

As you can see, the clinical visualization methods (x-ray, ct, mr, angiography...) are the doctor's little helpers, but the knowledge must be achieved through intensive study. It can be achieved only by studying, visualization and practice.

We hope that this chapter and the next chapters will help you to understand and learn anatomy.

## References

- (1) Waldeyer, A. *Anatomie des Menschen*; De Gruyter: Berlin, 2002;
- (2) Feneis, H. *Anatomisches Bildwörterbuch der internationalen Nomenklatur*; Thieme: Stuttgart, 1993;
- (3) Wolf-Heidegger, G. *Atlas der Human Anatomie*; Karger: Basel, 1990;
- (4) Platzer, W. *Atlas der topographischen Anatomie*; Thieme: Stuttgart, 1982;
- (5) Anderson, J. *Grant's atlas of anatomy*; Williams & Wilkins: Baltimore, 1983;
- (6) Williams *Gray's Anatomy of the Human Body*; Churchill Livingstone: 1995;
- (7) Benninghoff, A., Göttler, K. *Makroskopische und Mikroskopische Anatomie des Menschen*; Urban & Schwarzenberg: München, 1994;
- (8) Kahle, W., Leonhardt, H., Platzer, W. *Taschenatlas der Anatomie*; Thieme: Stuttgart, 1979;