

Radioanatomie du thorax

www.e-anatomy.org

Hélène ROPION, mars 2010
Radiologie Brabois adultes

THORAX

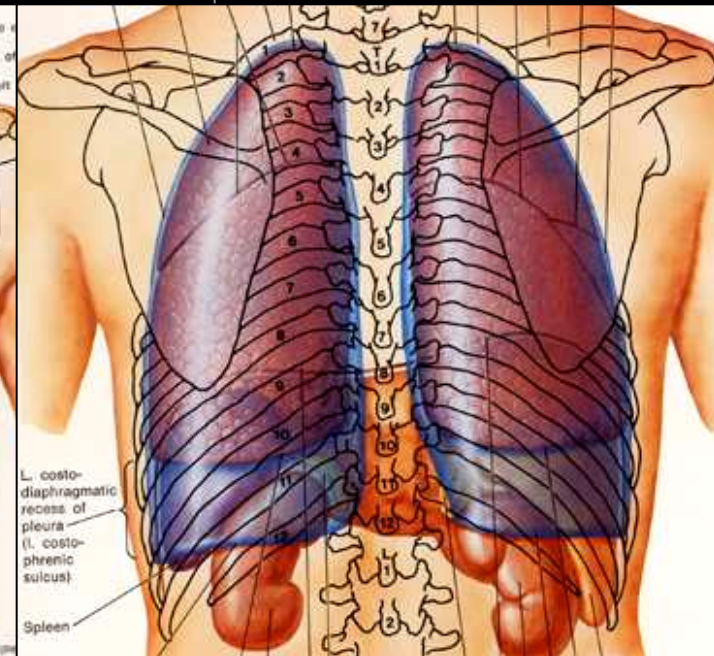
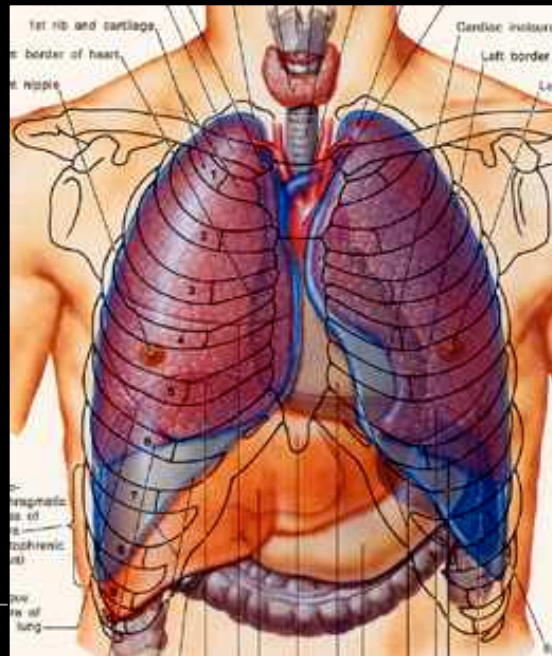
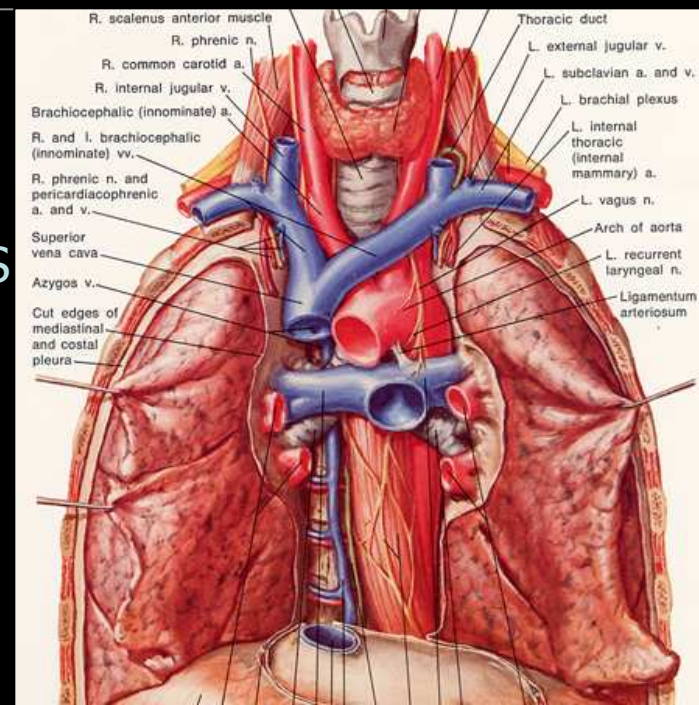
1/ RADIOANATOMIE PULMONAIRE ET DES BRONCHES

2/ RADIOANATOMIE DU MEDIASTIN

- VAISSEAUX
- CŒUR
- ŒSOPHAGE
- CHAINES GANGLIONNAIRES

3/ PAROI THORACIQUE

- PLEVRE
- COTES





1/ RADIOANATOMIE PULMONAIRE ET DES BRONCHES

ANATOMIE de l' ARBRE TRACHEO-BRONCHIQUE

Trachée conduit semi rigide anneaux cartilagineux en avant

membrane fibreuse postérieure

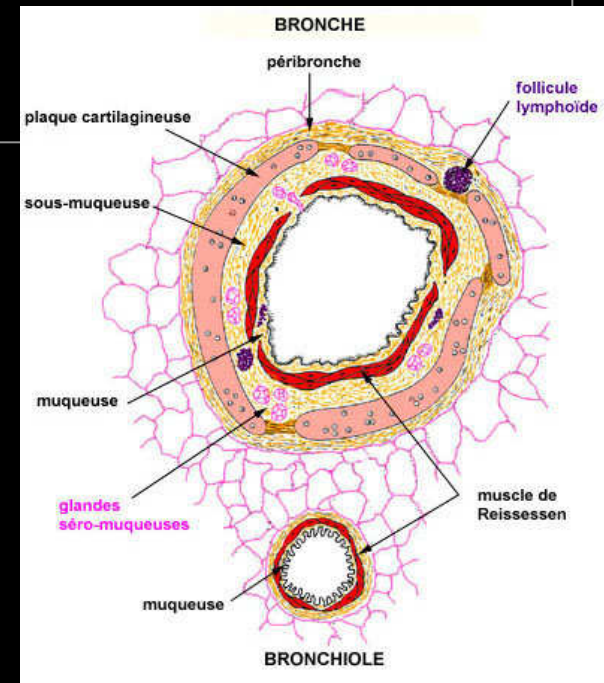
sous glottique à carène

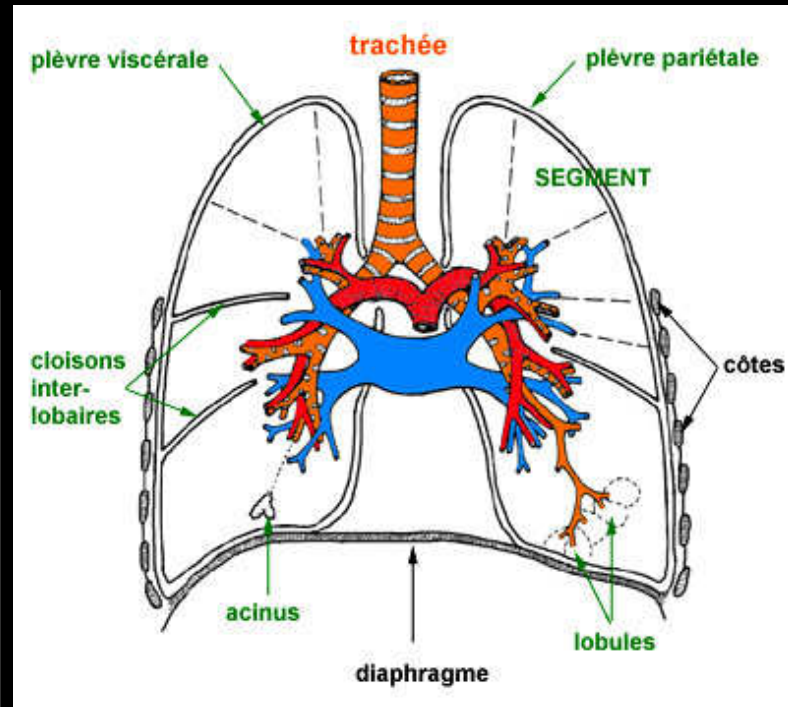
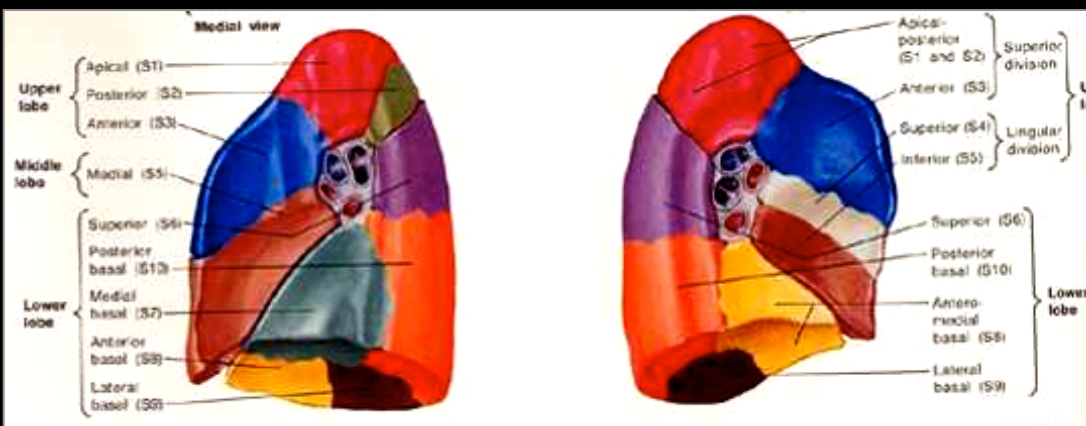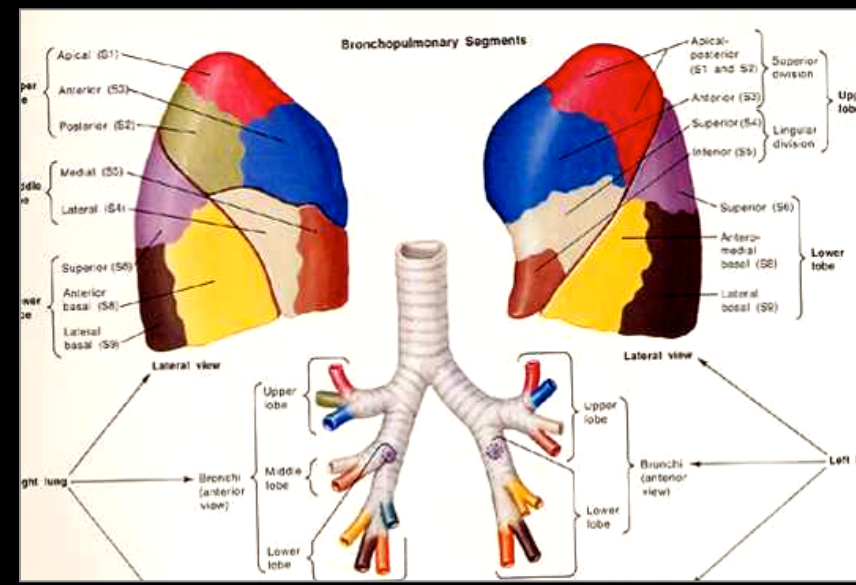
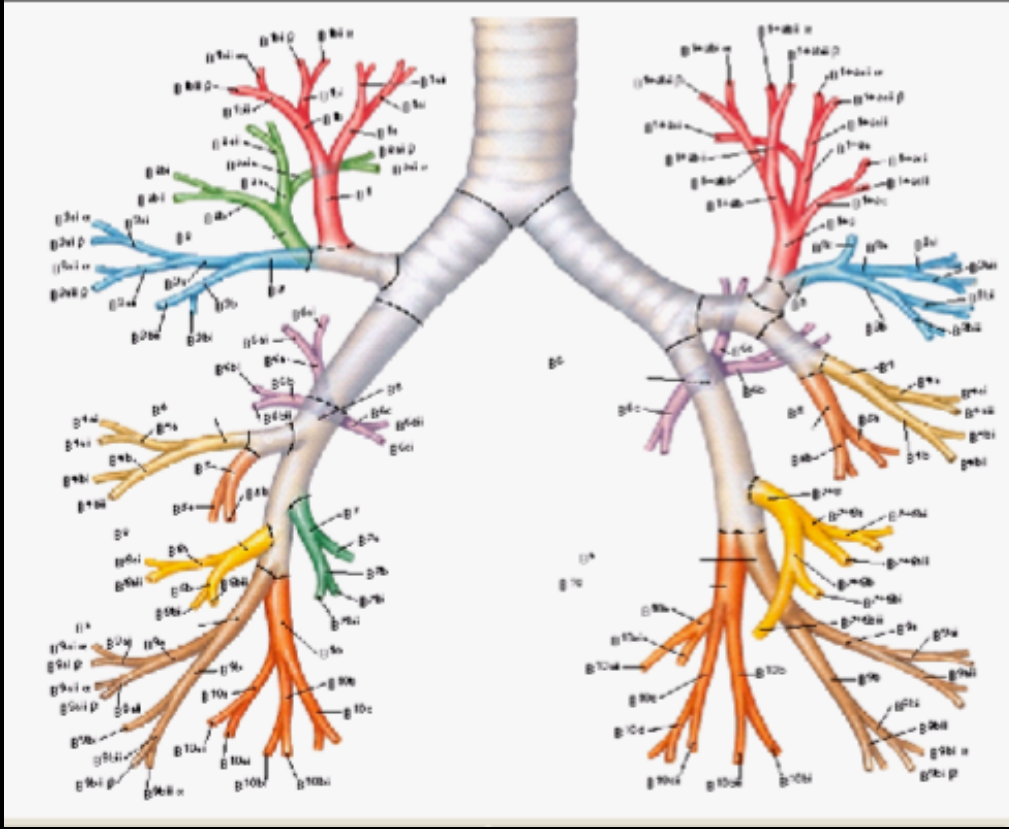
diamètre inférieur à 30 mm

Bronches

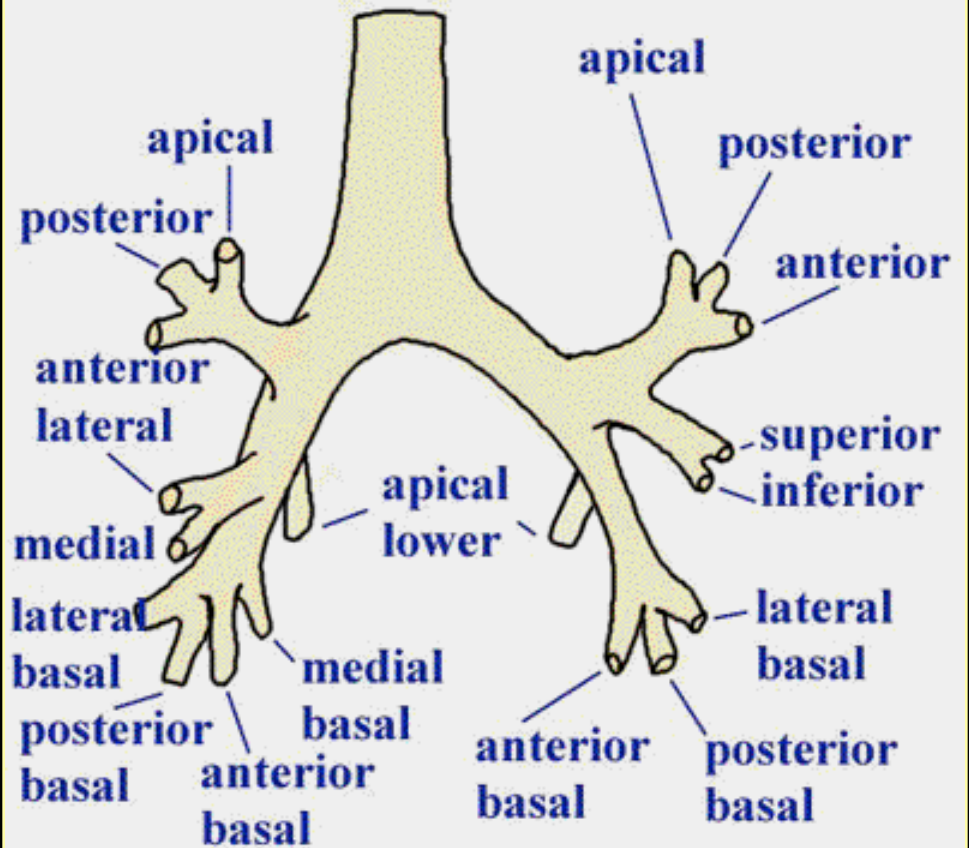
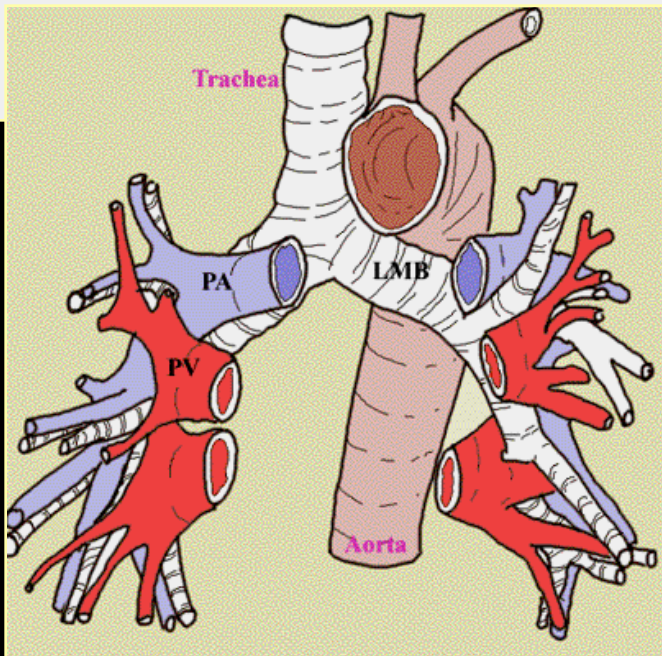
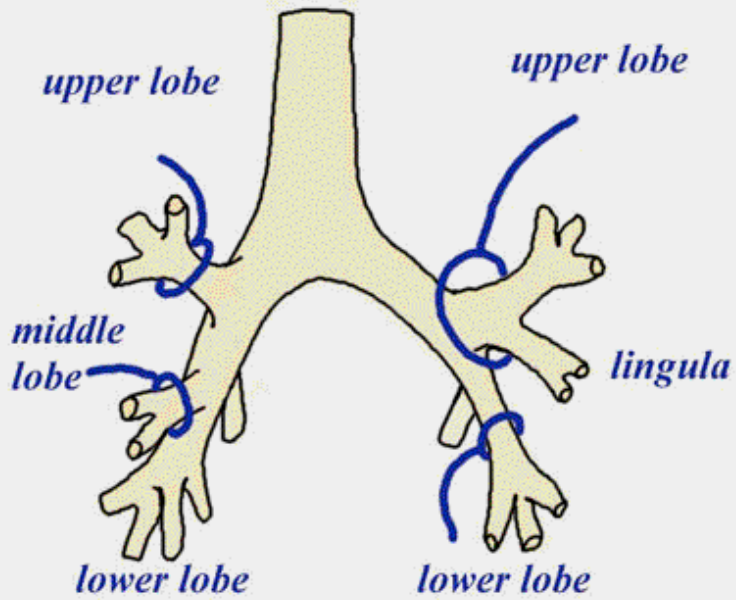
cartilage + m. lisse + fibres élastiques

élastine et collagène alvéoles

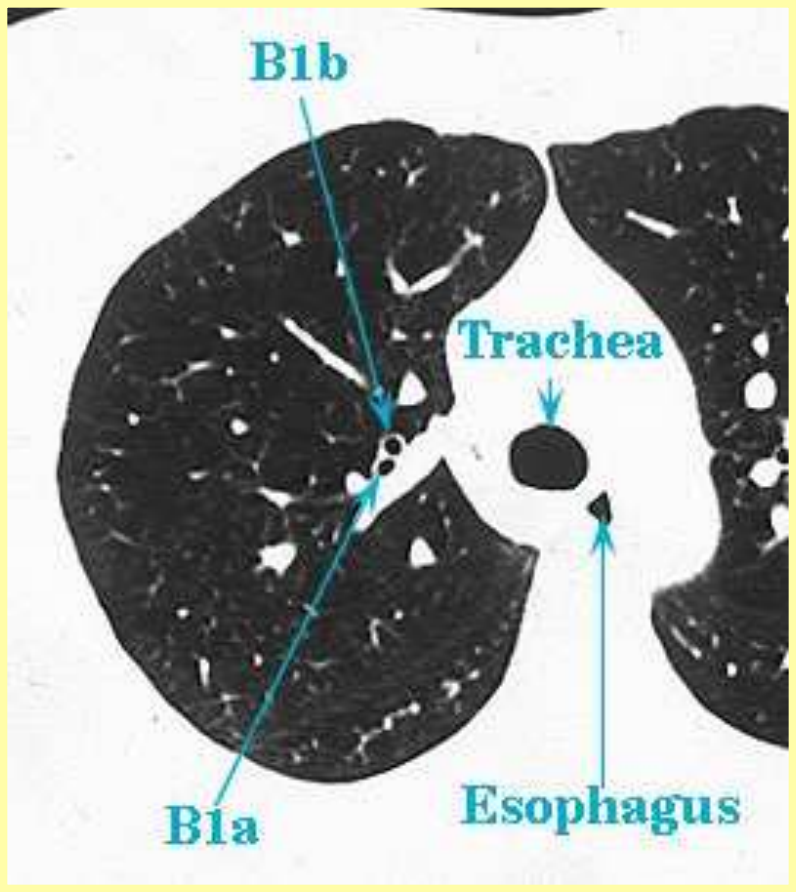
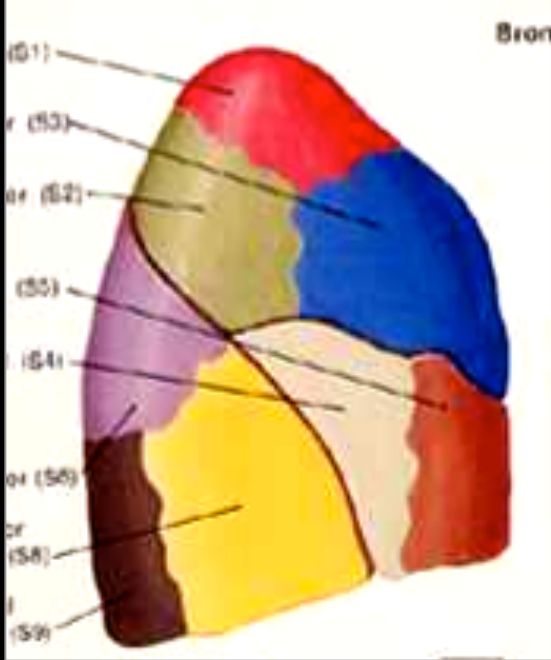




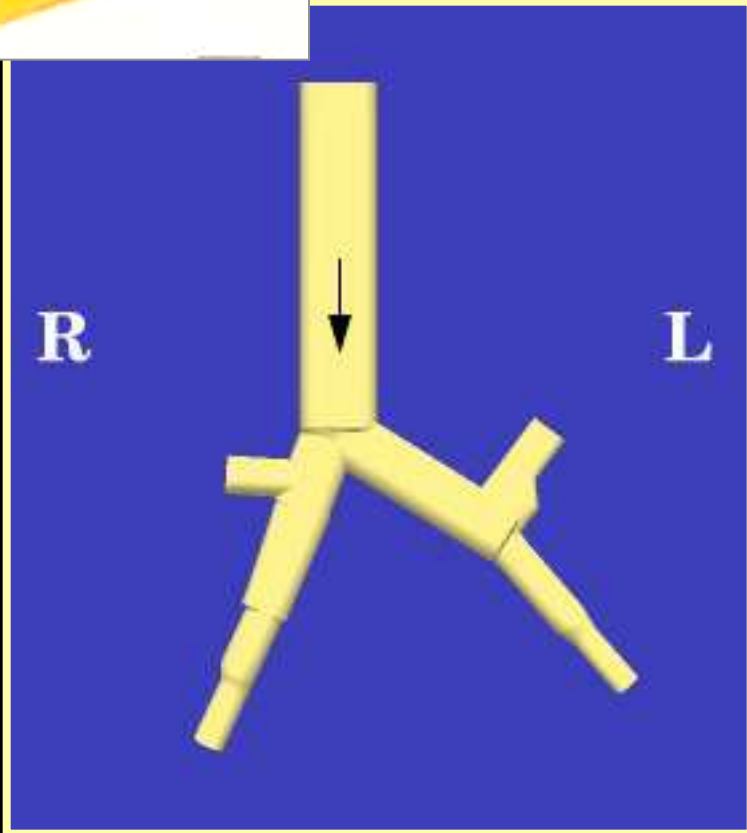
Systeme bronchique

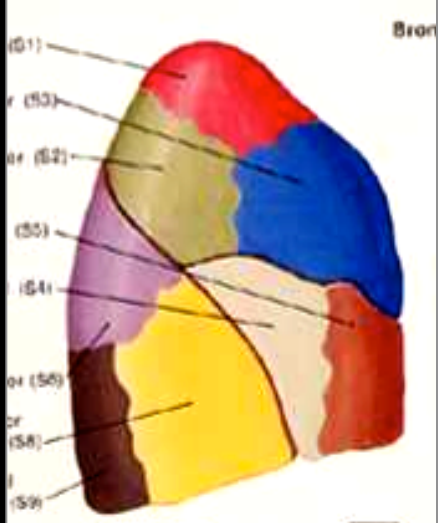


POUMON DROIT



B1 apical



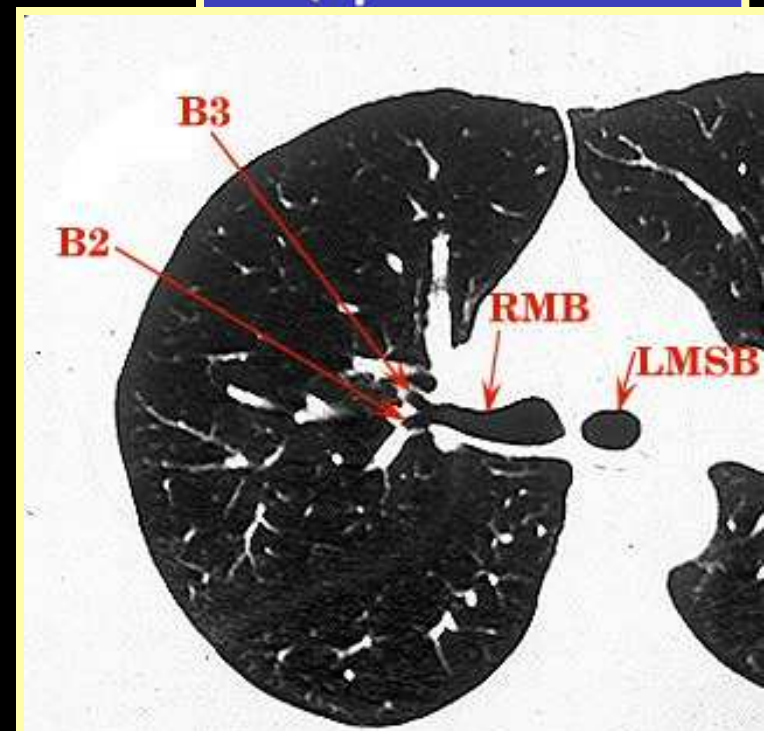
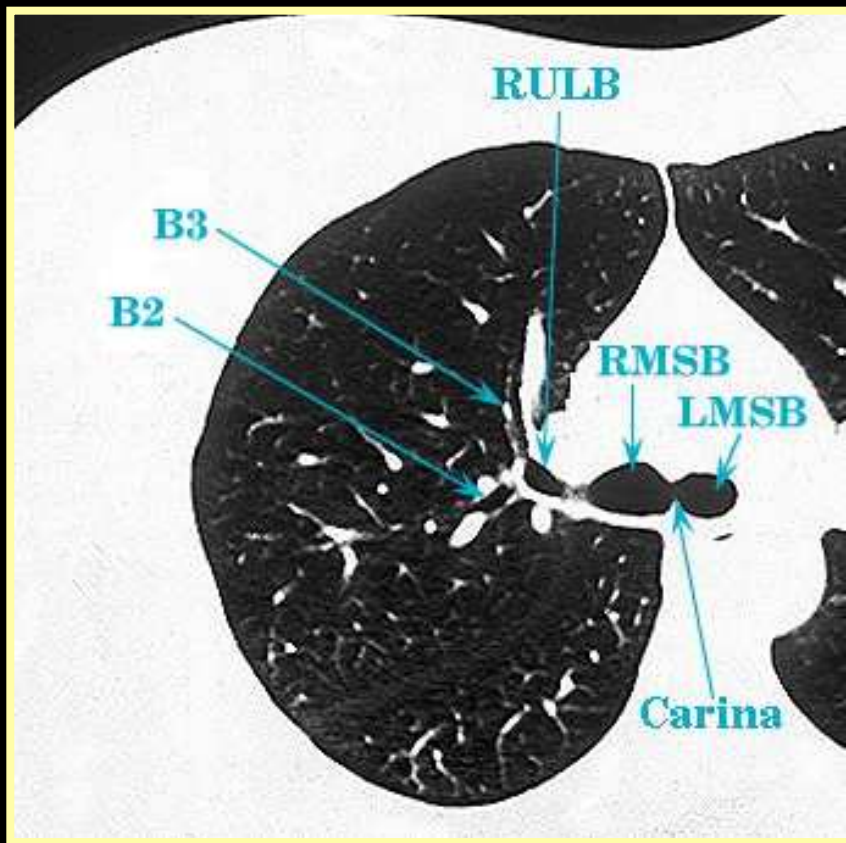
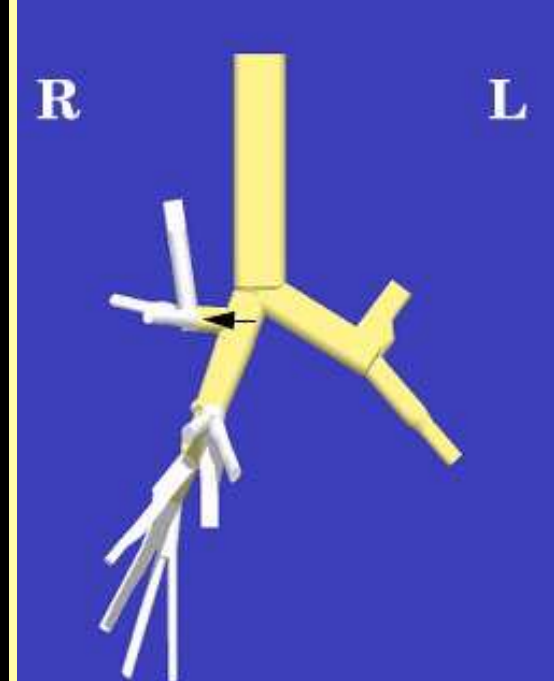


Bronche lobaire supérieure droite

B1 apical

B2 postérieur

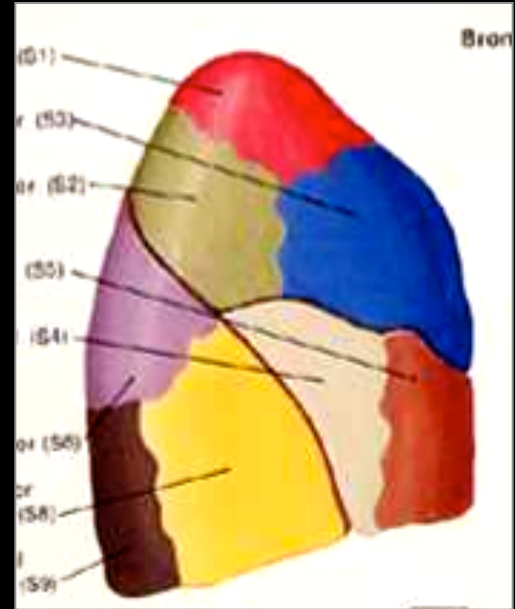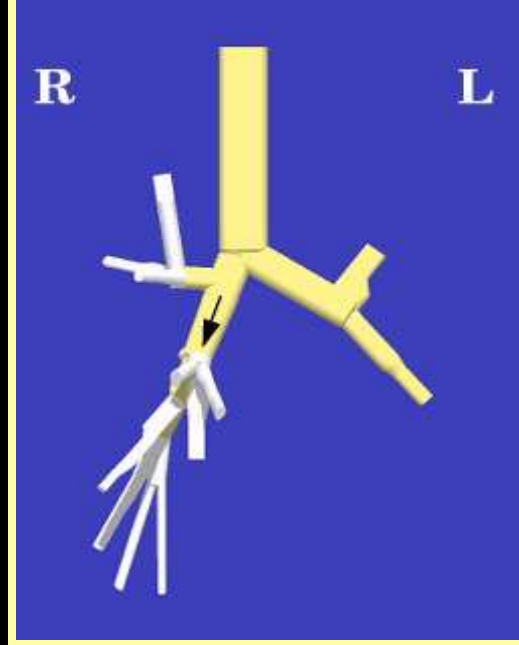
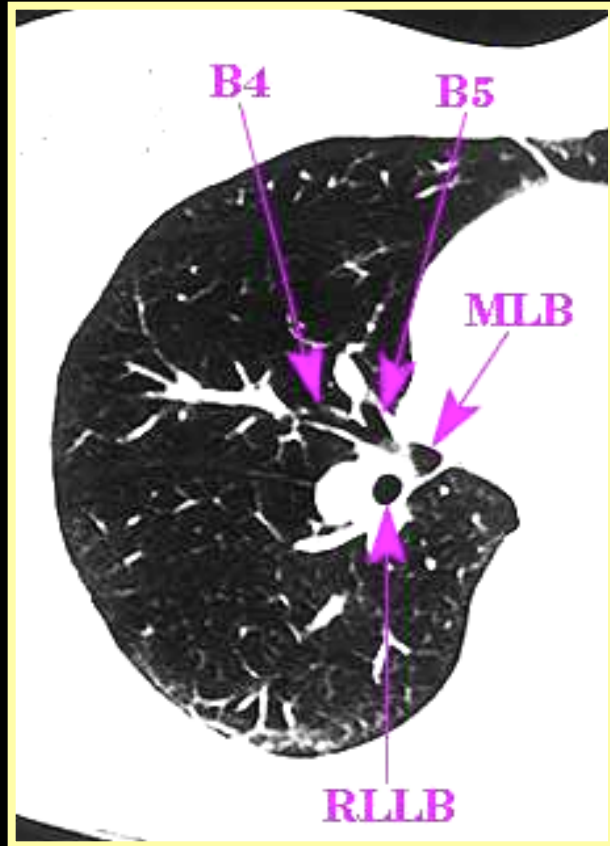
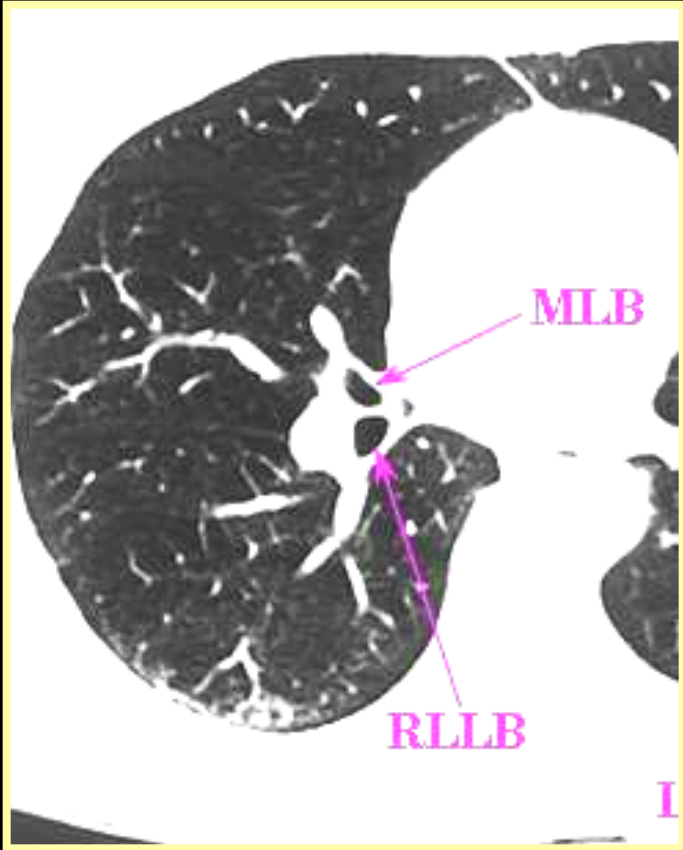
B3 antérieur

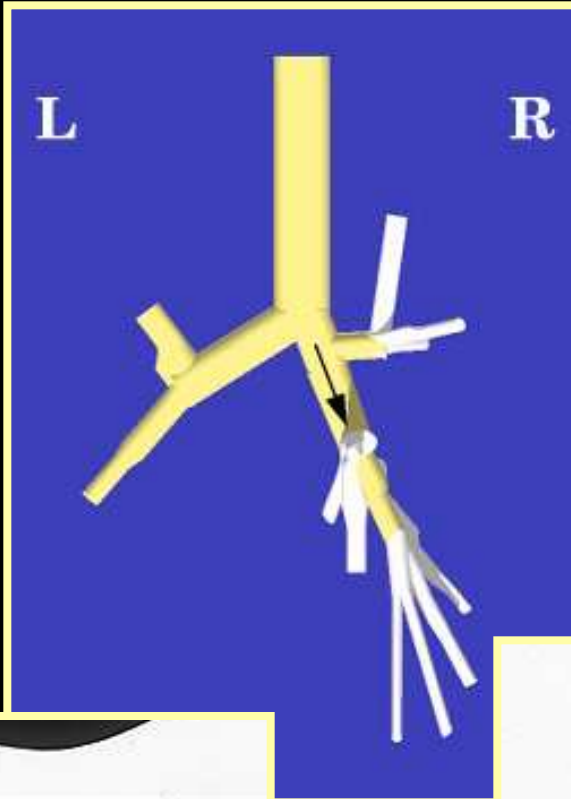
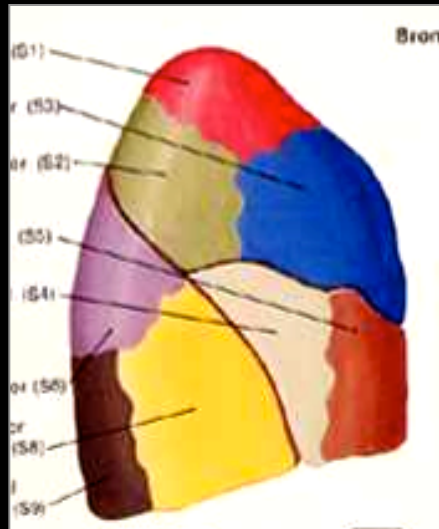


Bronche lobaire moyenne

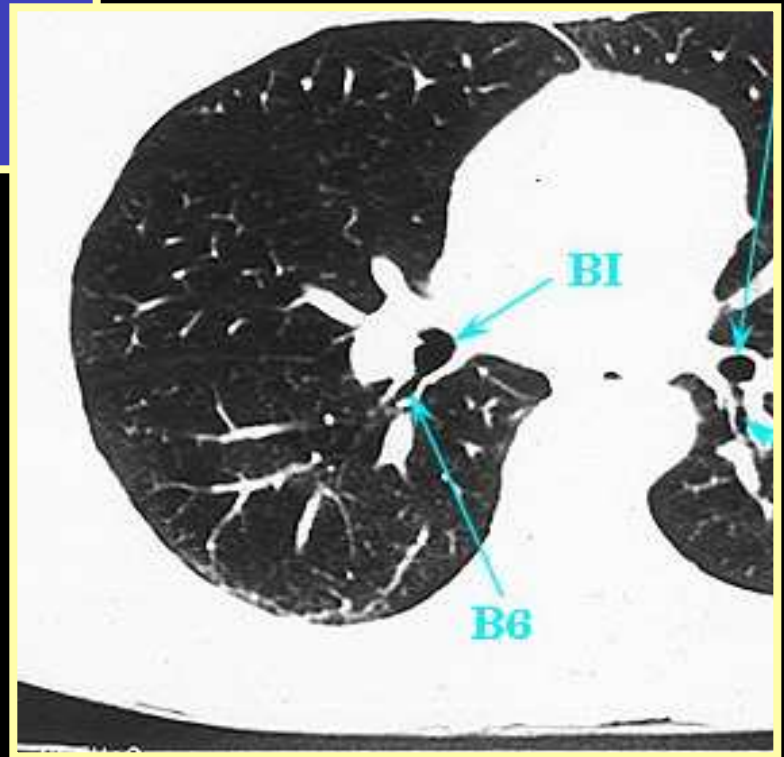
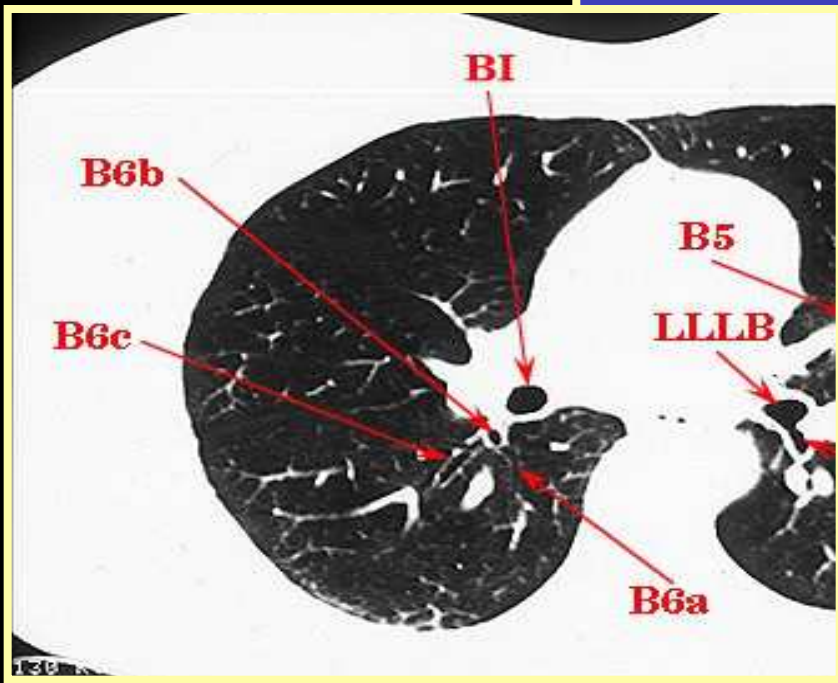
B4 latéral

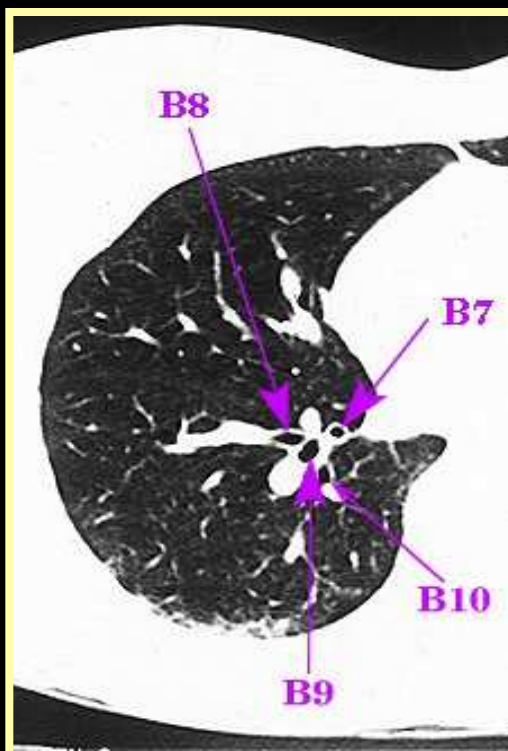
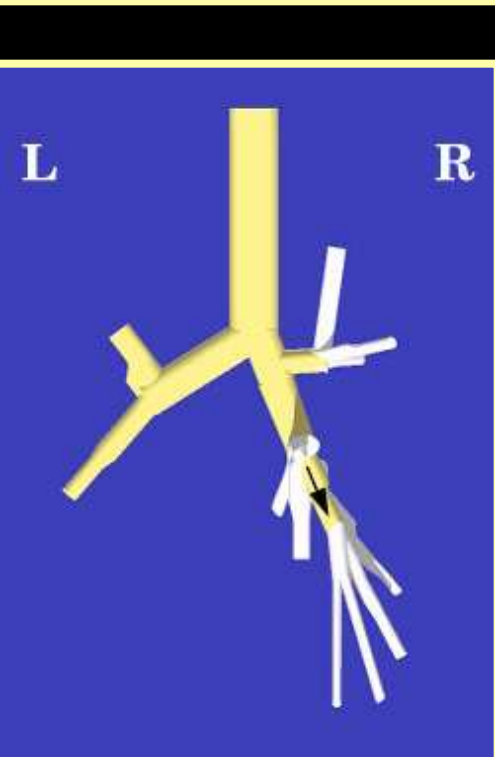
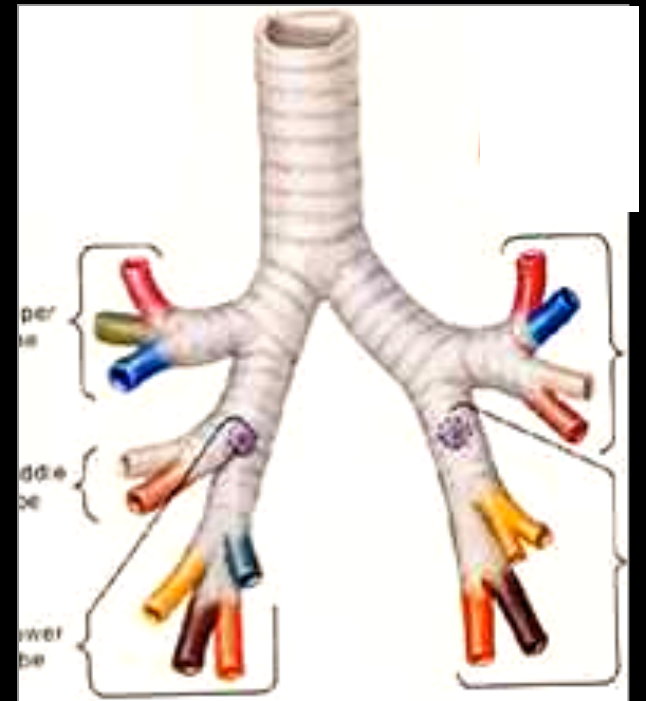
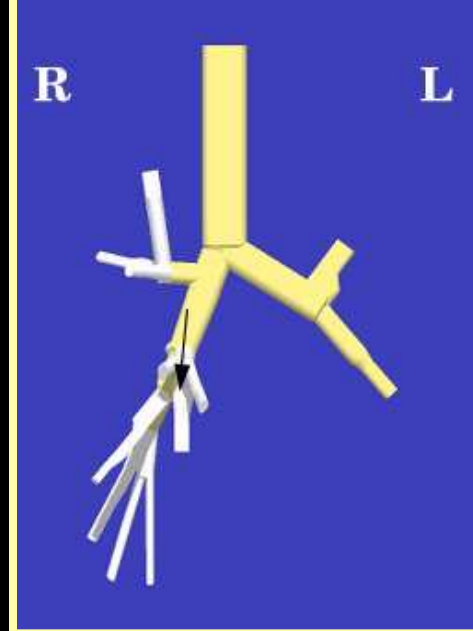
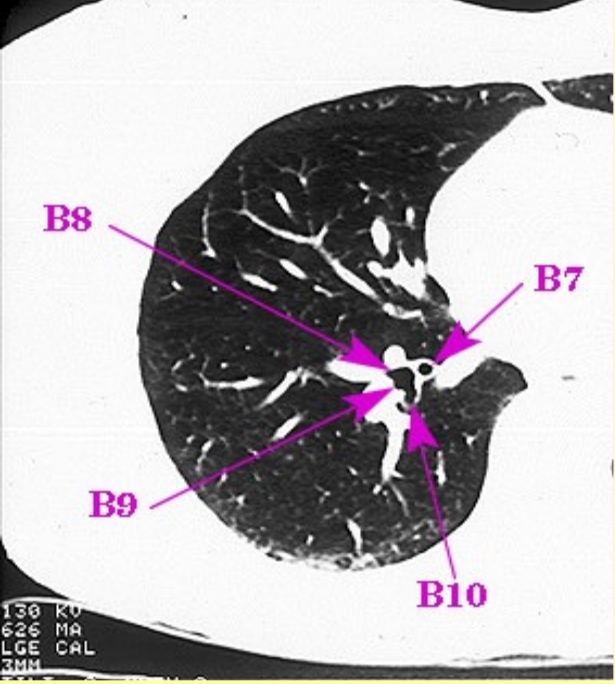
B5 médial



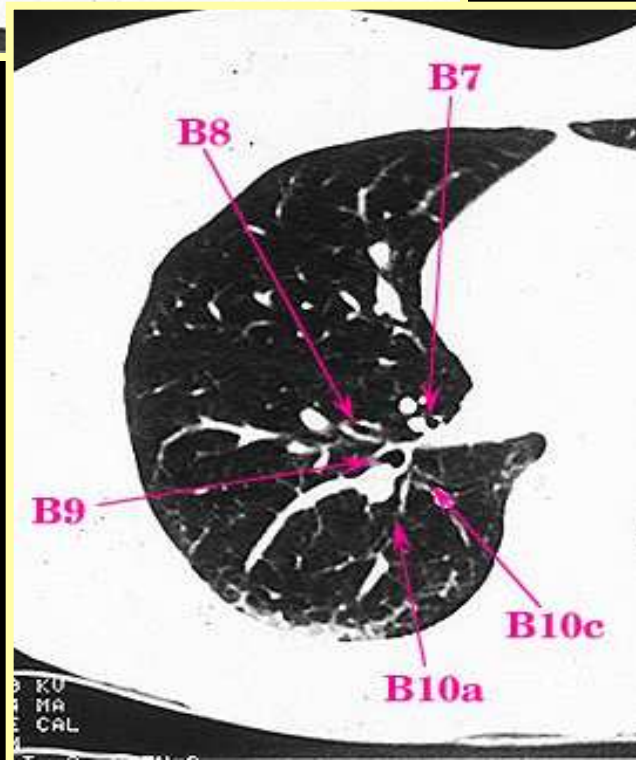
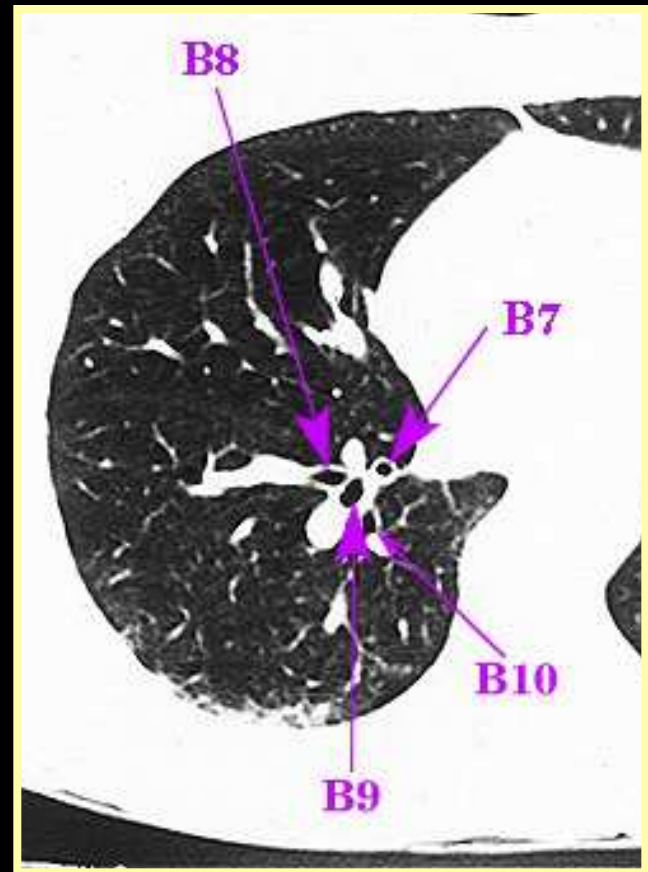
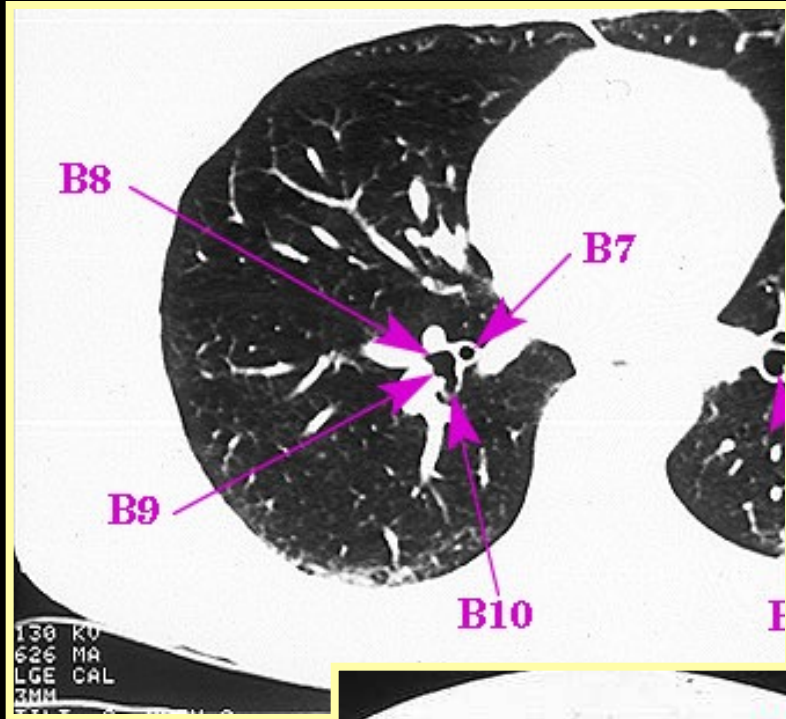

Bronche lobaire inférieure droite
B6 supérieur





B7 médiale basale
B8/B9/B10 tronc commun
antérobasal
Latérobasal
postérobasal



B7 médiale

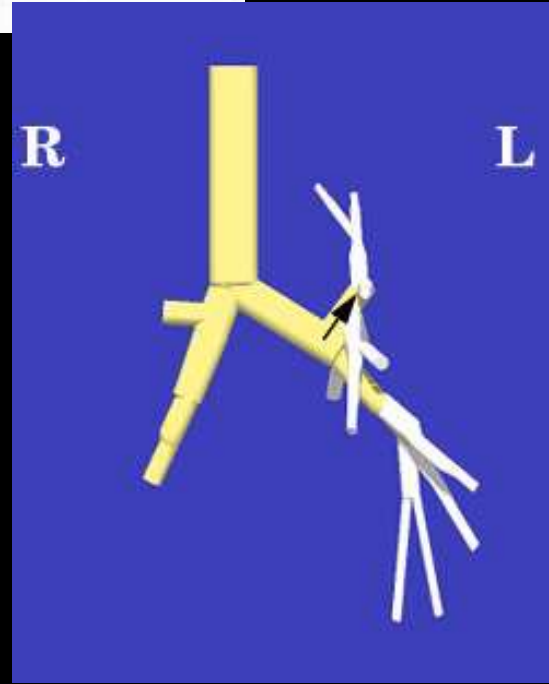
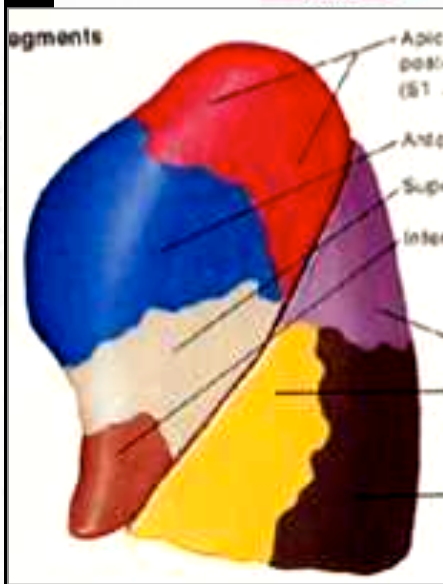
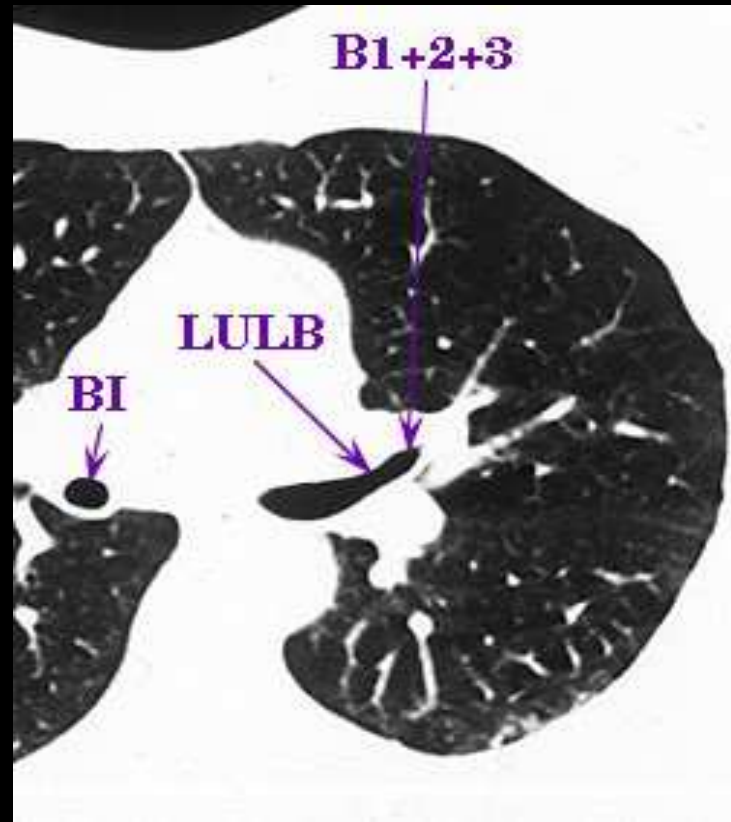
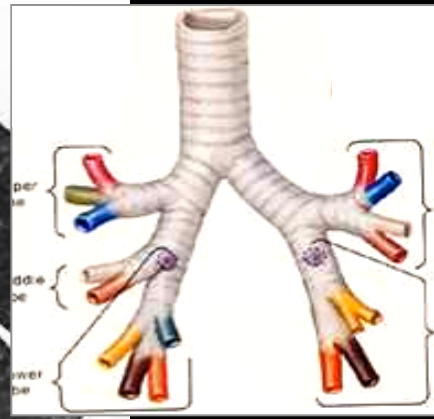
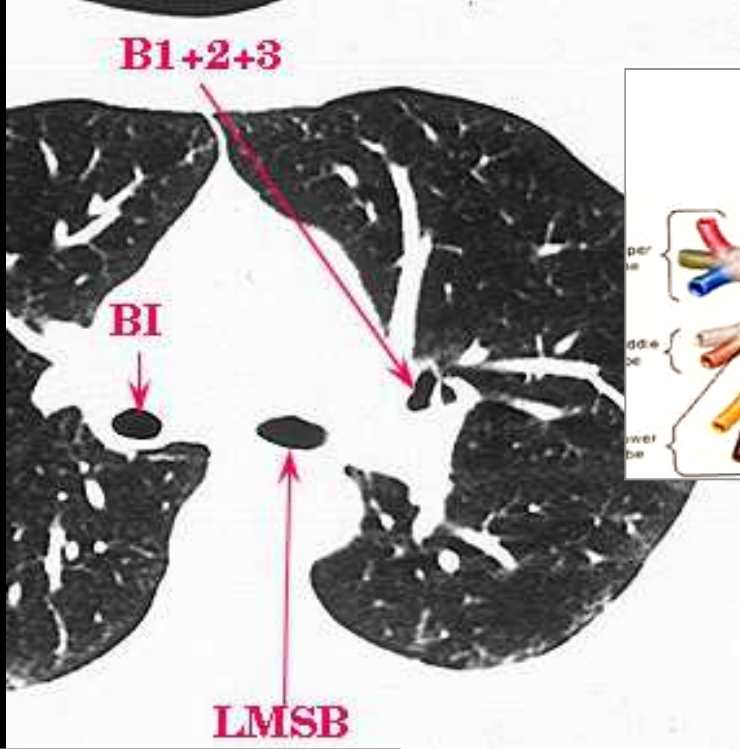
B8 antérobasal

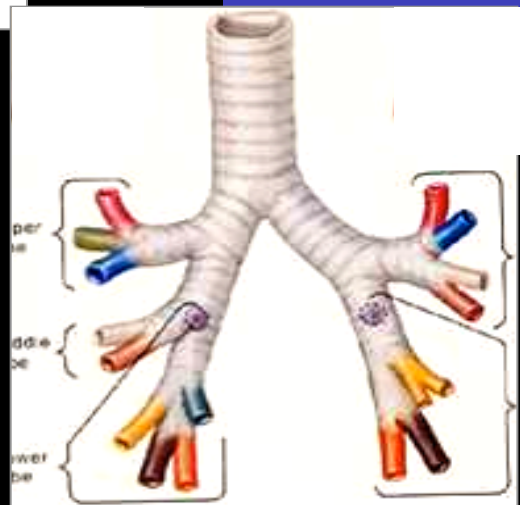
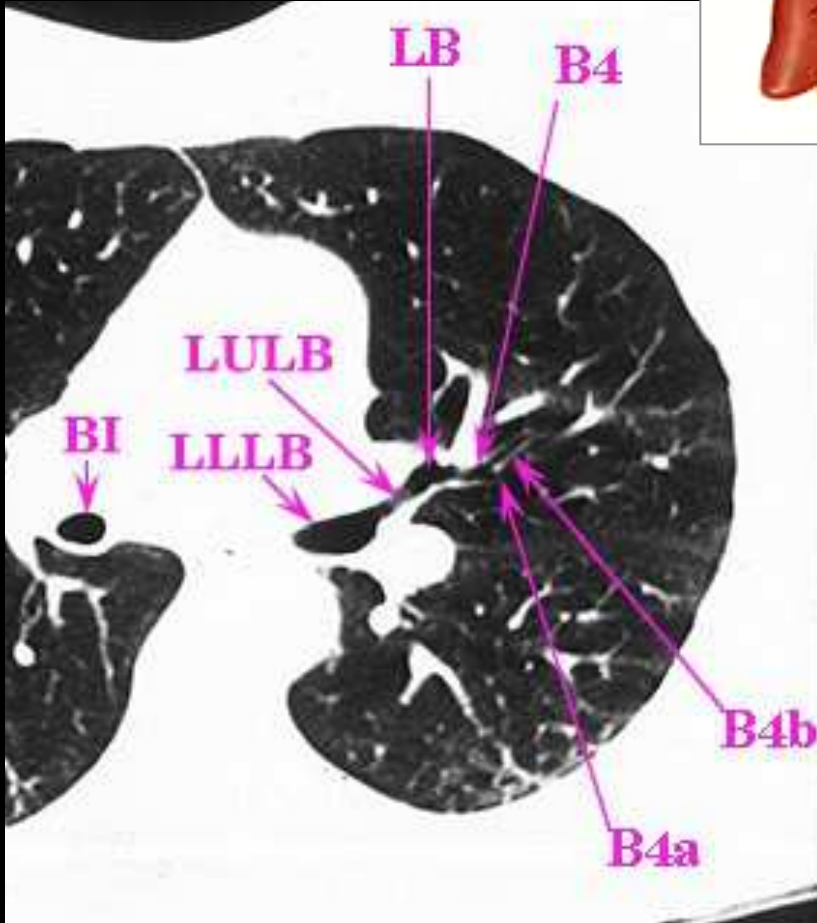
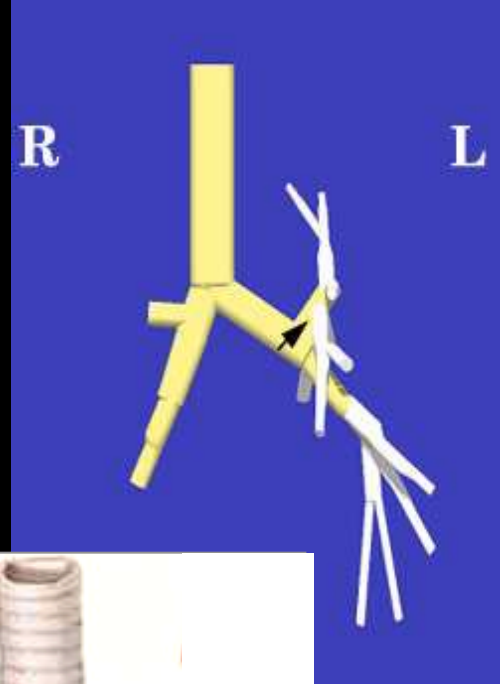
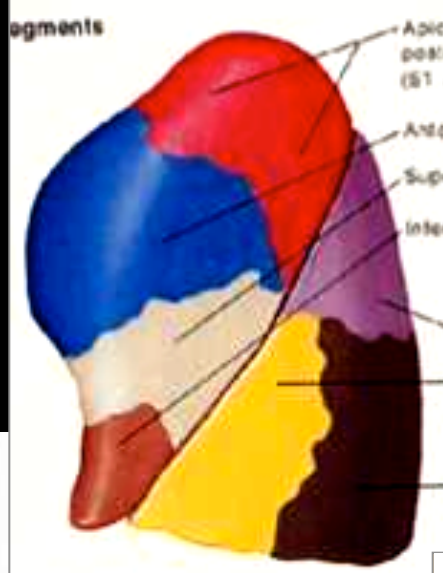
B9 latérobasal

B10 postérobasal

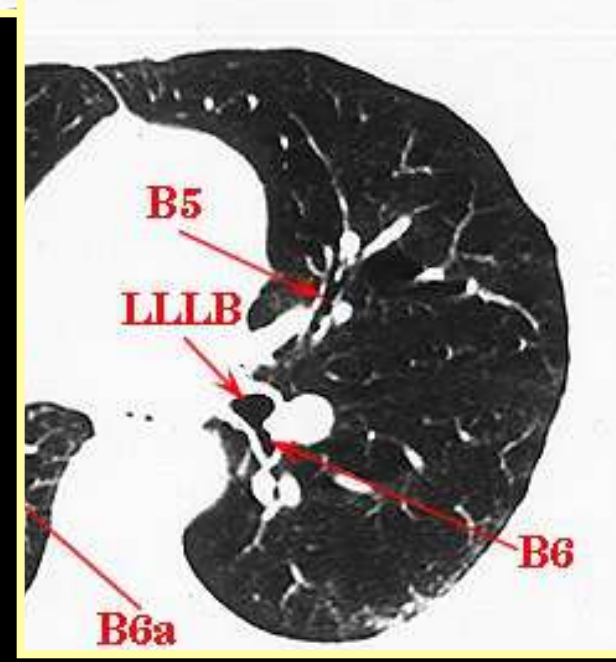
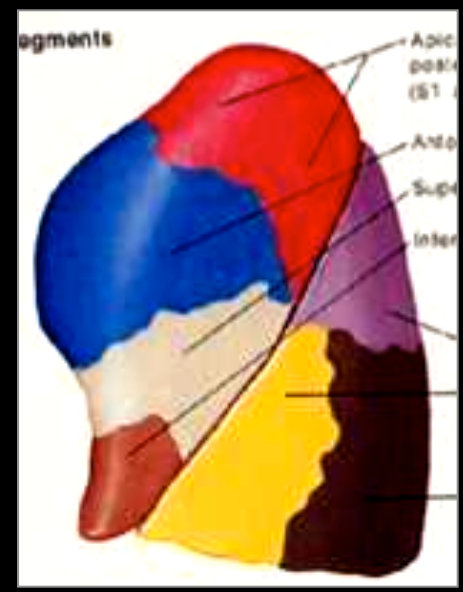
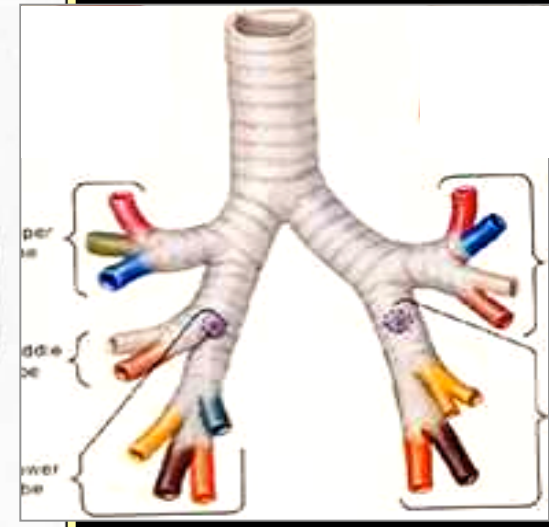
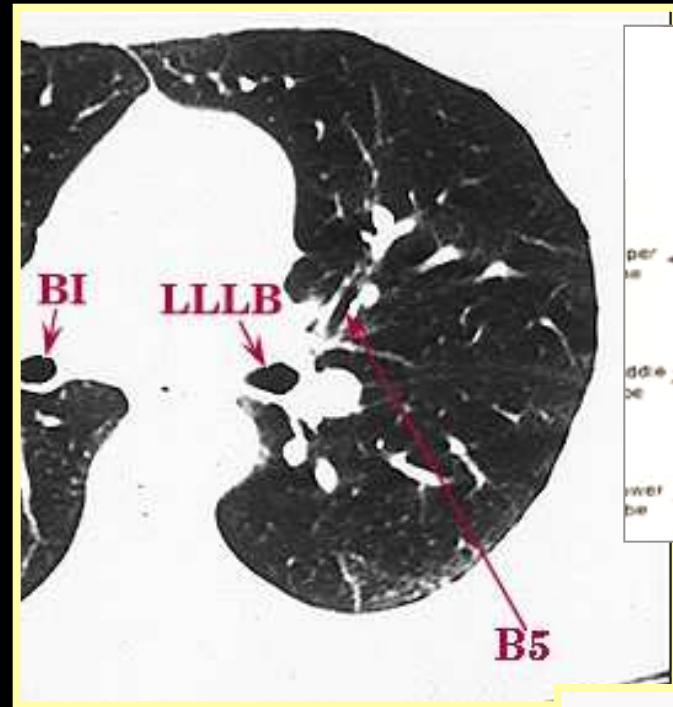
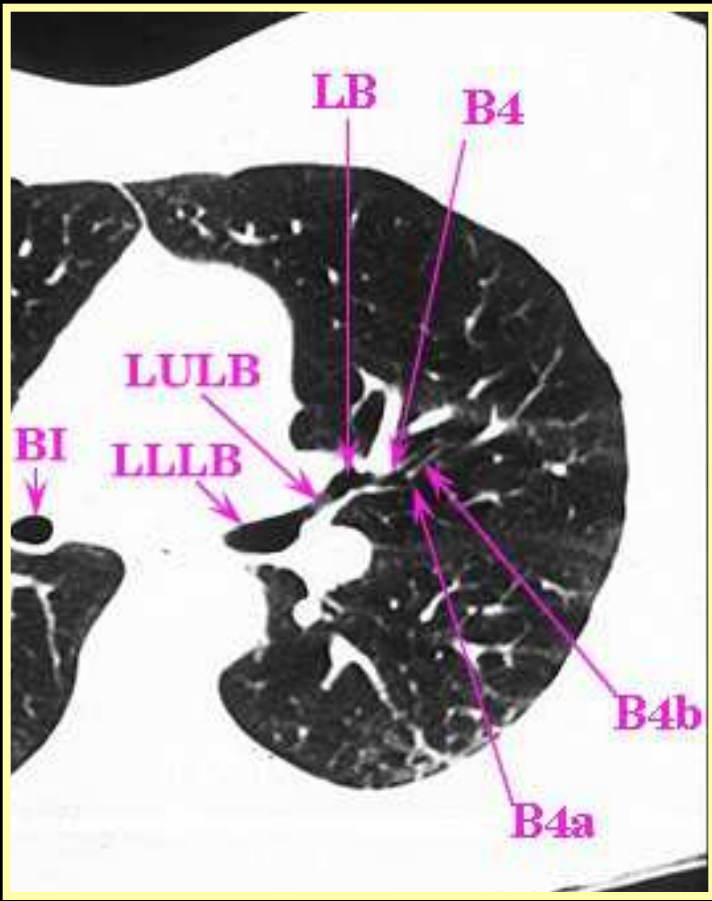
POUMON GAUCHE

Bronche Lobaire Supérieure
B1+2 apical postérieur
B3 antérieur
= culmen



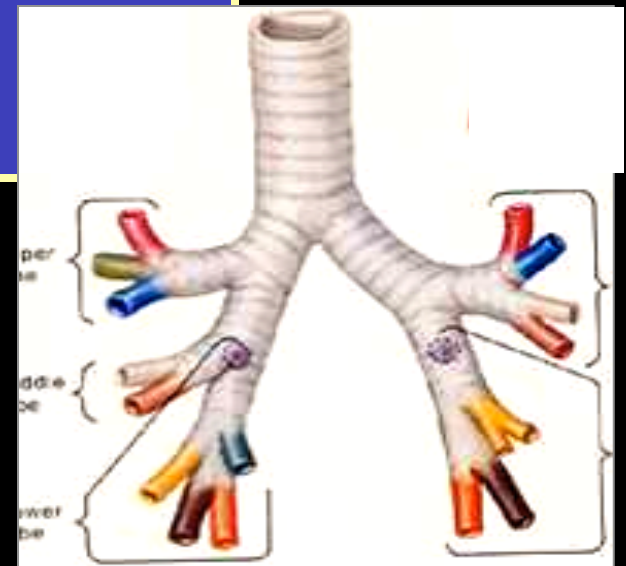
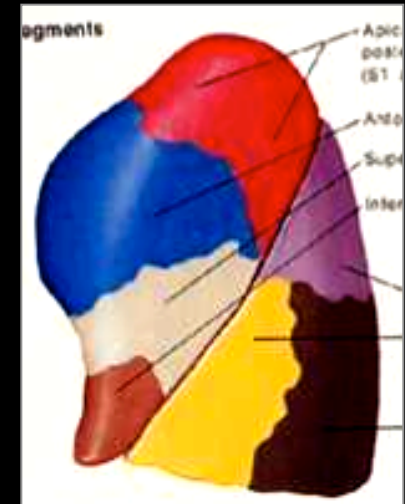
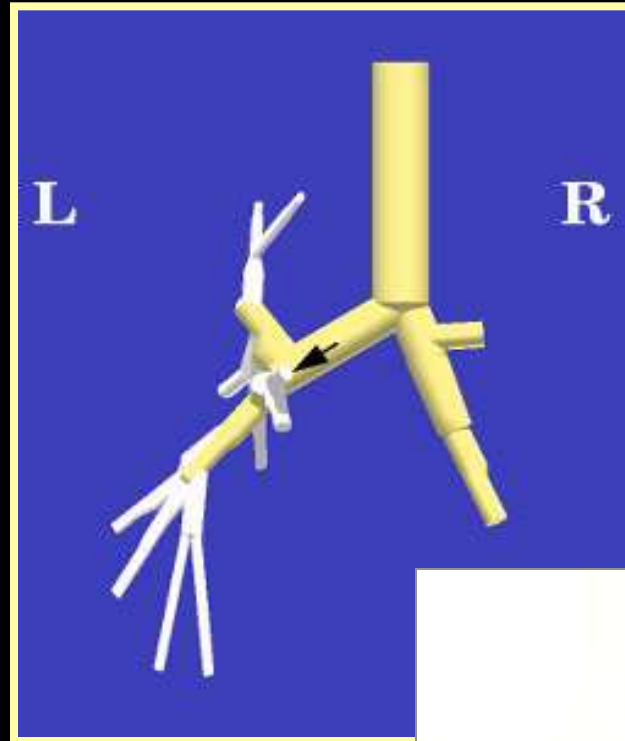
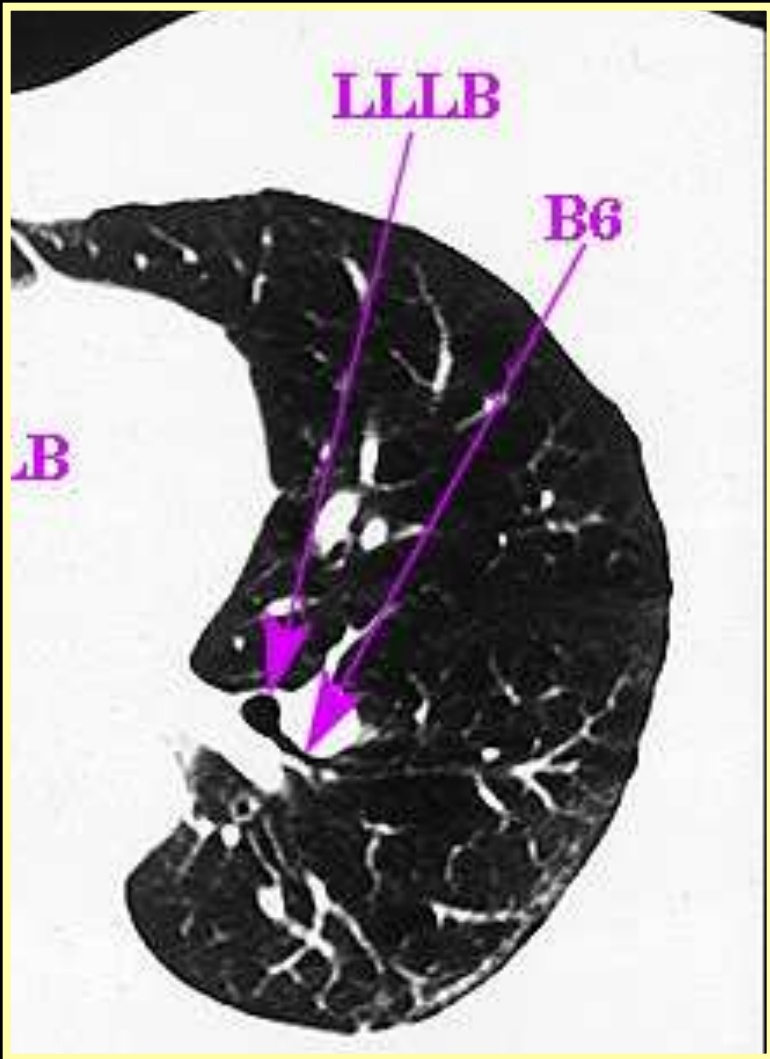


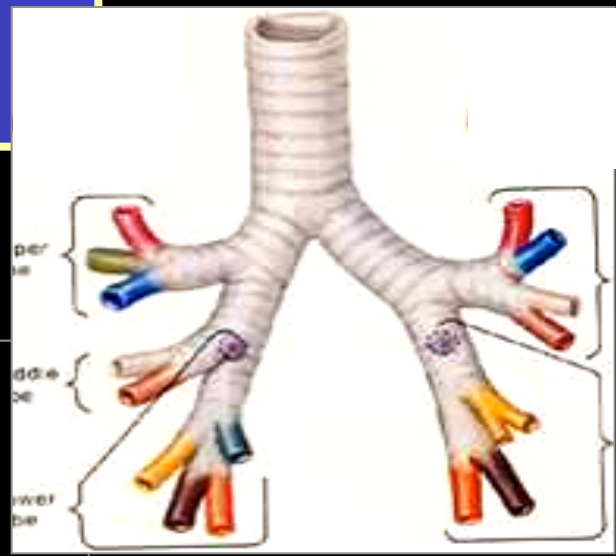
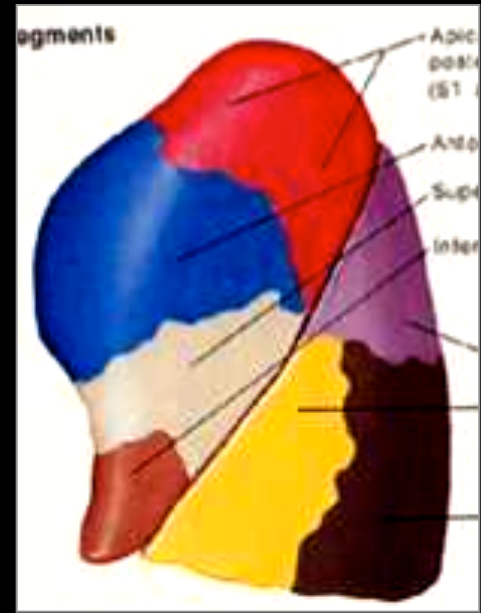

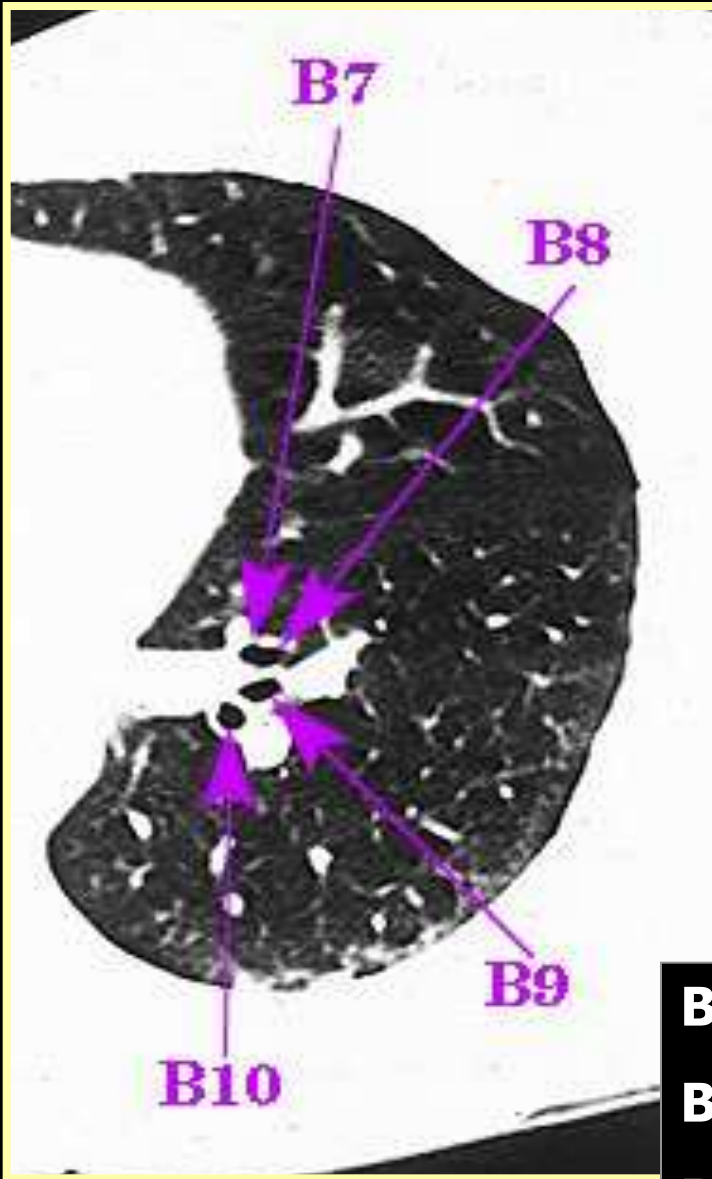
Bronche lobaire supérieure:
Bronche linguale (tronc commun)
B4 linguale supérieur



**Bronches segmentaires
lingulaires**
B4 supérieure
B5 inférieure

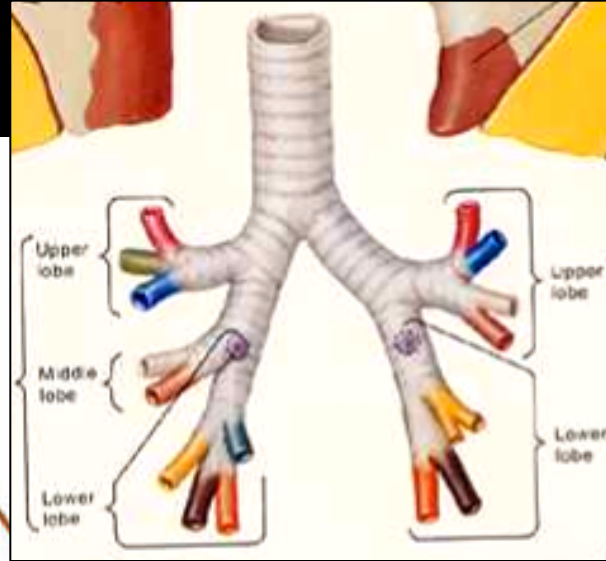
Bronche lobaire inférieure G B6 segmentaire supérieure





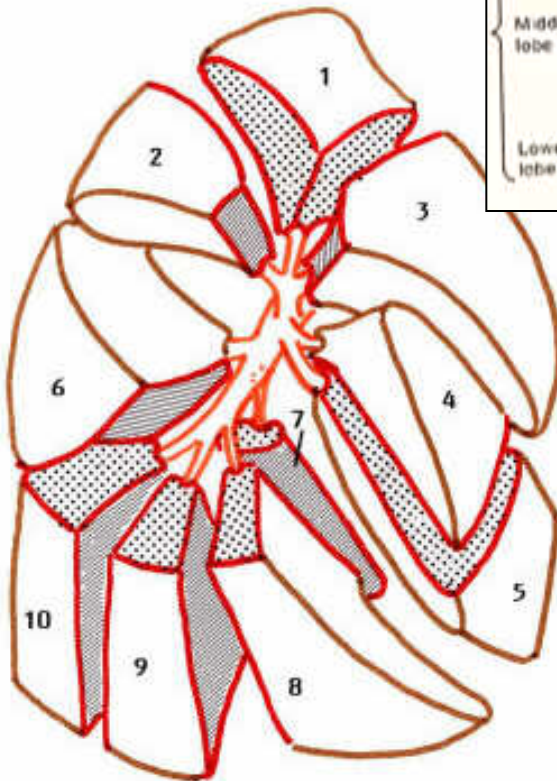
B6 supérieur
B7-8 antéro médial
B9 latéral
B10 postéro basal

SEGMENTATION PULMONAIRE



POUMON DROIT

AV
BS



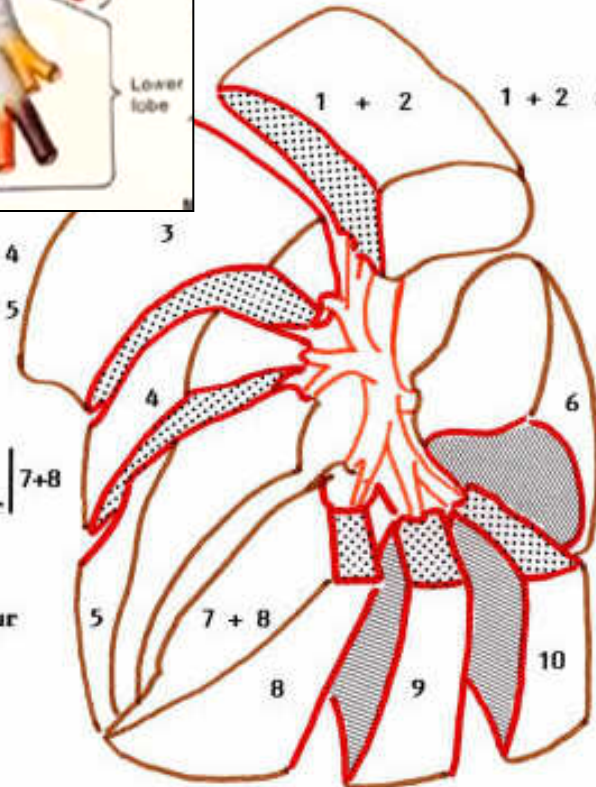
1, 2....., 10 : Nomenclature chiffrée de Boyden

- 4. Latéral Super 4
- 5. Médial Infér 5
- 6. Supérieur (apical du LI)
- 7. Basal médial
- 8. Basal antérieur
- 9. Basal latéral
- 10. Basal postérieur

7+8

POUMON GAUCHE

AV
BS

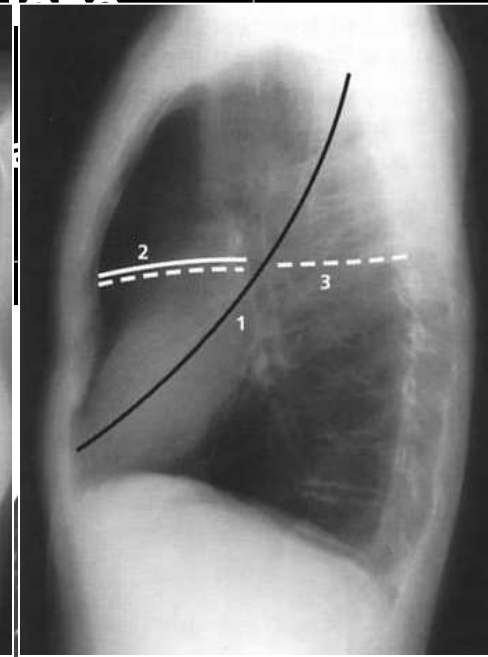
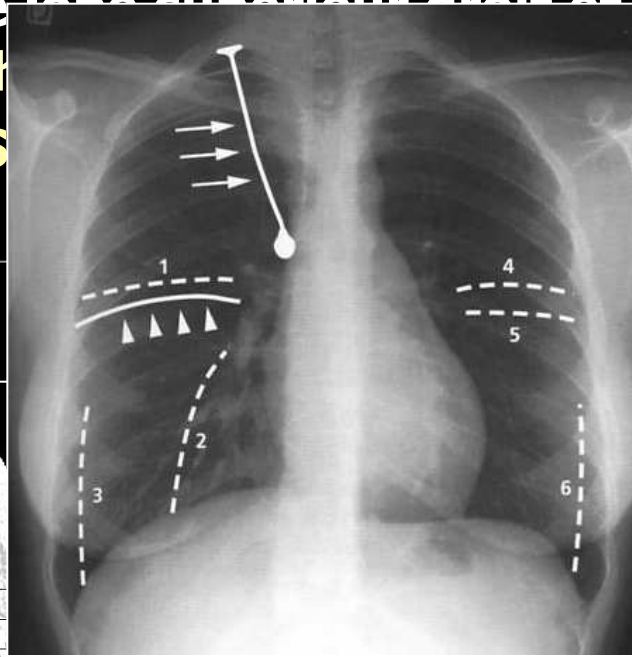
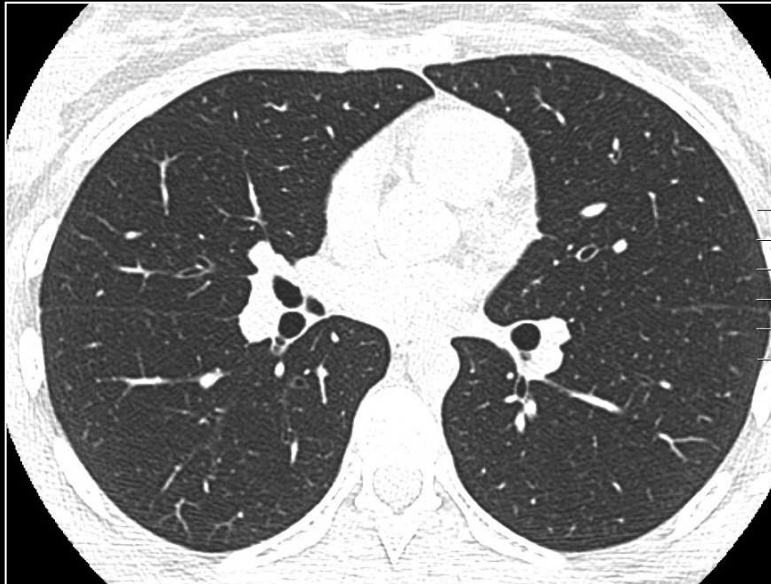

7 + 8 basal antéro-médial

1 + 2 Apico-postérieur

LES SCISSURES

- La plèvre viscérale s'insinue dans les scissures
- **GRANDES SCISSURES** entre les lobes supérieur et inférieur et sont obliques
- **PETITE SCISSURE** entre le lobe supérieur droit et lobe moyen et est proche de l'arc costal
- **SCISSURES ACCESSOIRES** la scissure verticale externe et la scissure verticale interne



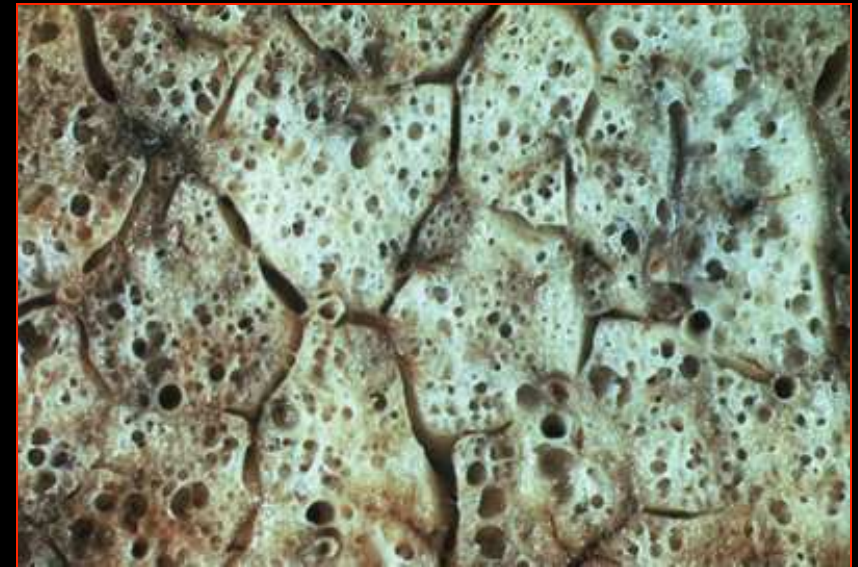
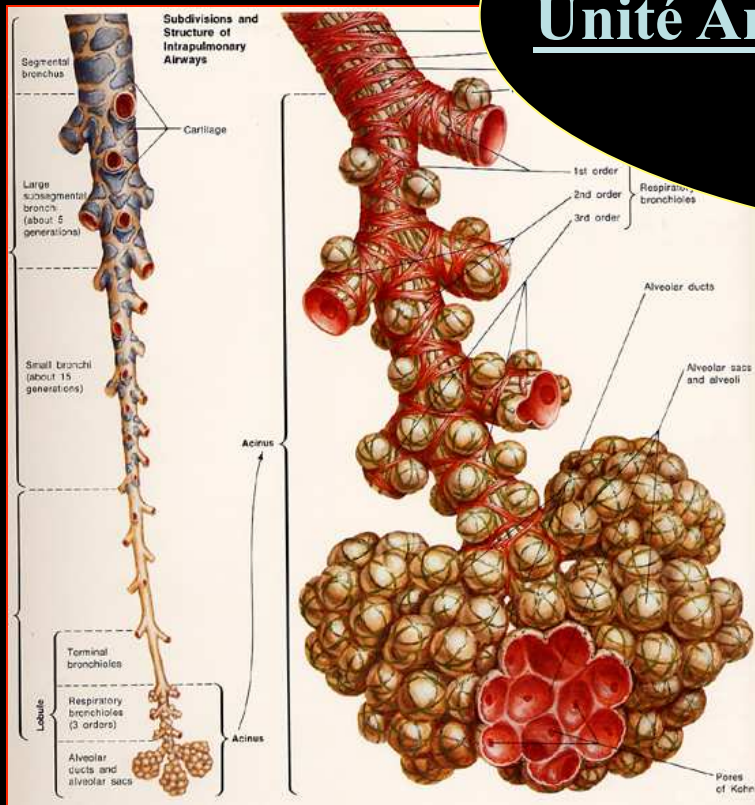
- 1.Scissure du segment S6 droit
- 2.Scissure para-cardiaque droite
- 3.Scissure verticale externe gauche
- 4.Scissure linguale
- 5.Scissure du segment S6 gauche
- 6.Scissure verticale externe gauche

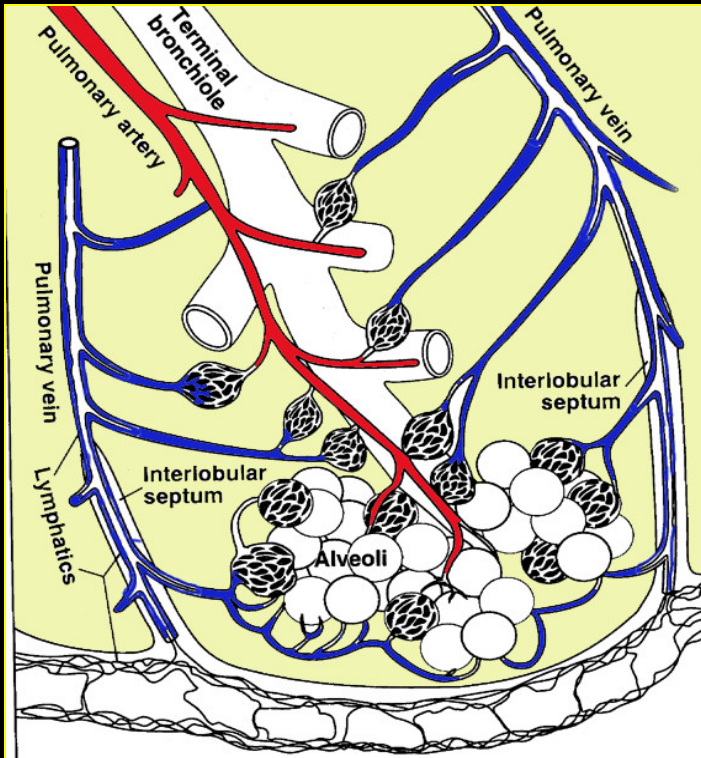
Imagerie du Lobule Secondaire

- grâce au **Scanner Haute Résolution** (coupes millimétriques)

Lobule II de Miller

Unité Anatomique et Fonctionnelle du poumon
Polyédrique, 1 à 1,5 cm
Contient 3 à 5 acini





Bronchiole centrolobulaire

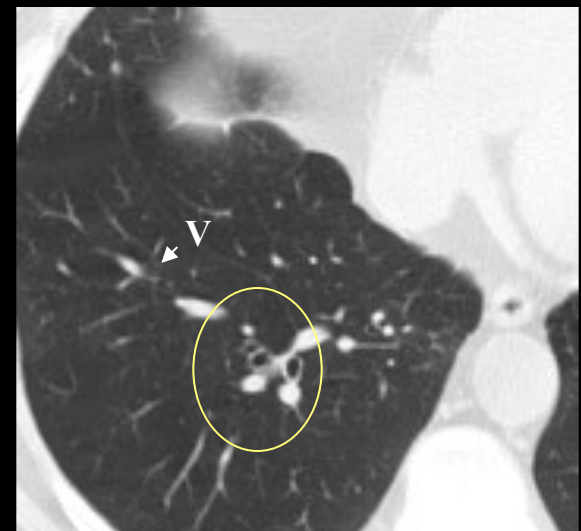
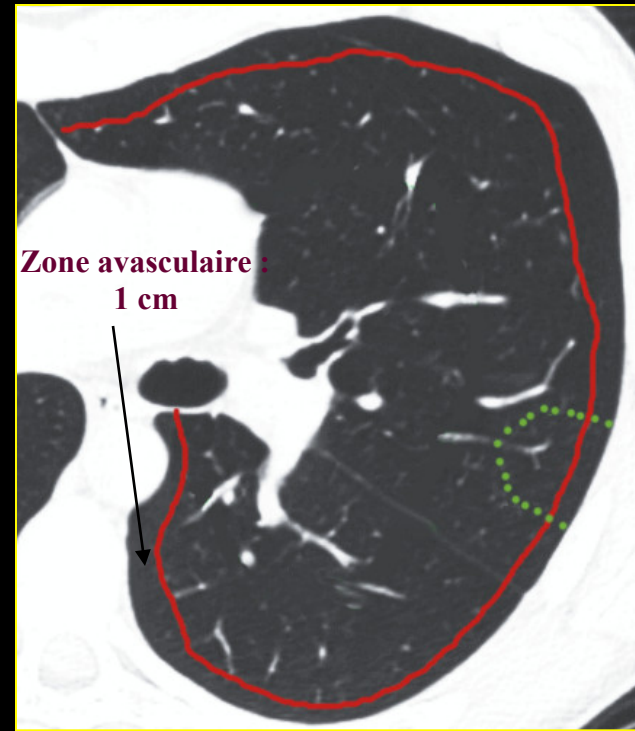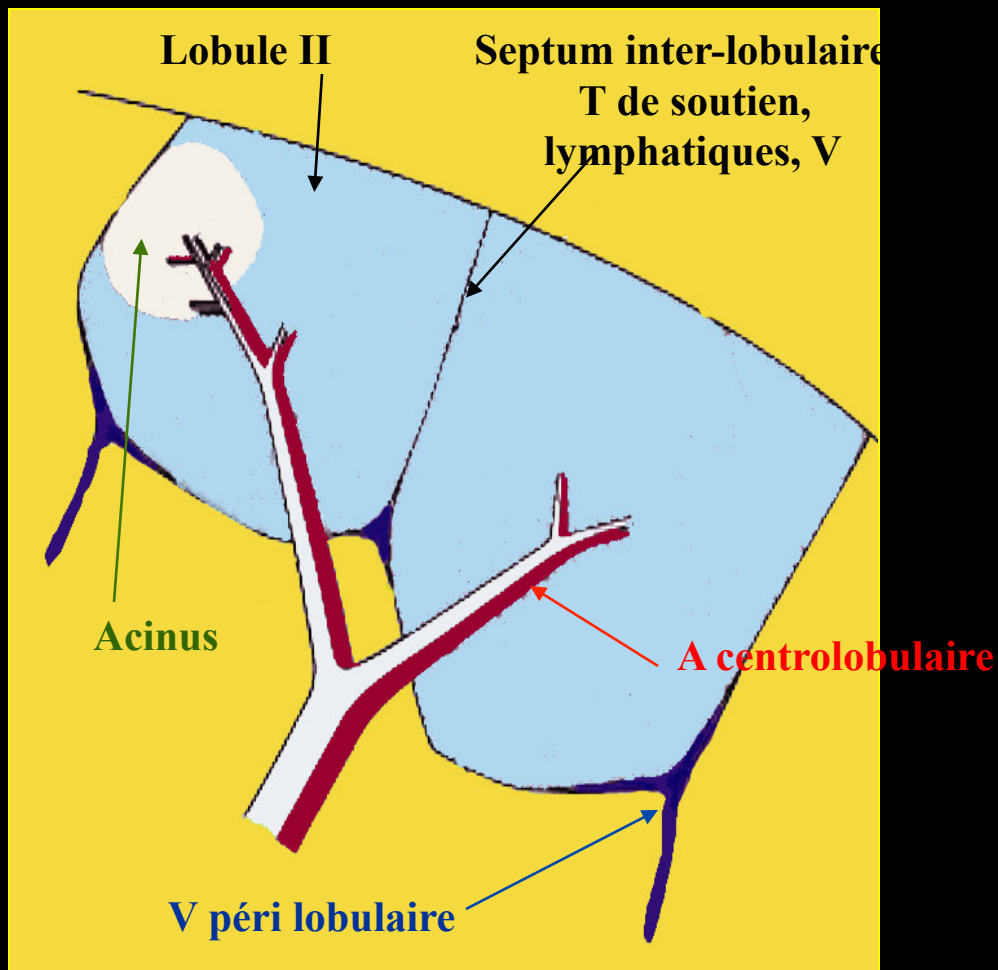


Bronchioles terminales



**Bronchioles respiratoires/ bordées
d' alvéoles (=acinus ou lobule primaire
de Miller)**

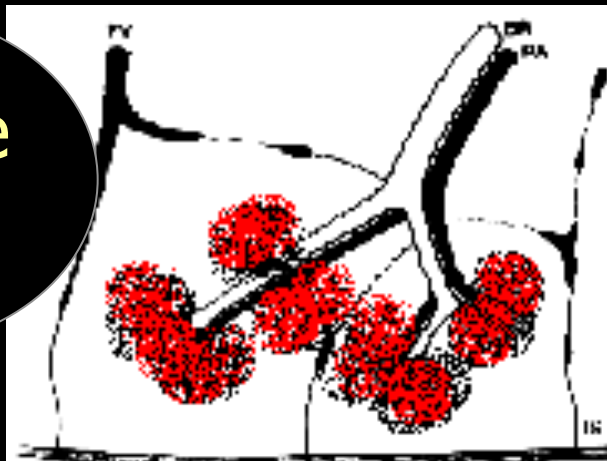- ✓ **Membrane Air/Sang** : Échanges gazeux alvéolo-capillaires
- ✓ **Secteur Interstitiel** (de soutien) :
 - Inter et péri lobulaire (V et lymphatiques)
 - Sous pleural
 - Péri Bronchovasculaire (jusqu' au hile)
- ✓ **Secteur aérique** : alvéolaire, bronchique



A l'état normal :
Bronchioles et septa non vus, en périphérie
A. visualisées plus loin que V.

Différentes atteintes pulmonaires

Aérique
Alvéoles,
Bronches

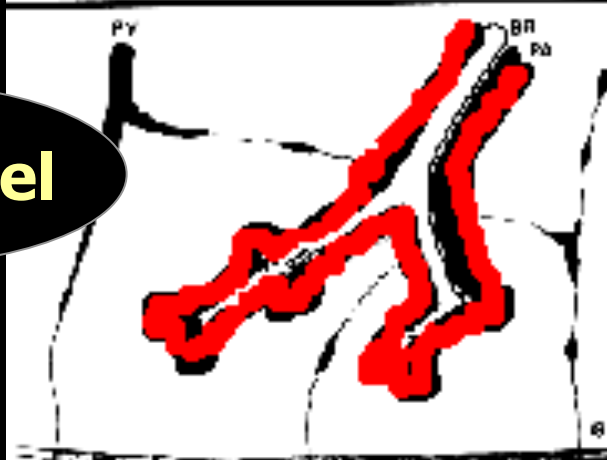

Centilobular

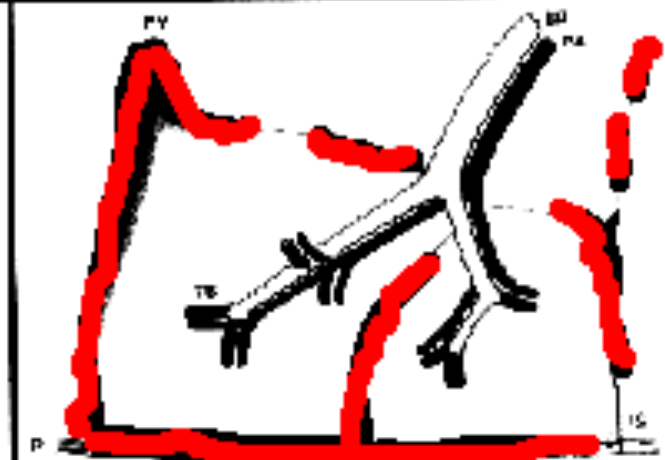

Panlobular

Interstitiel

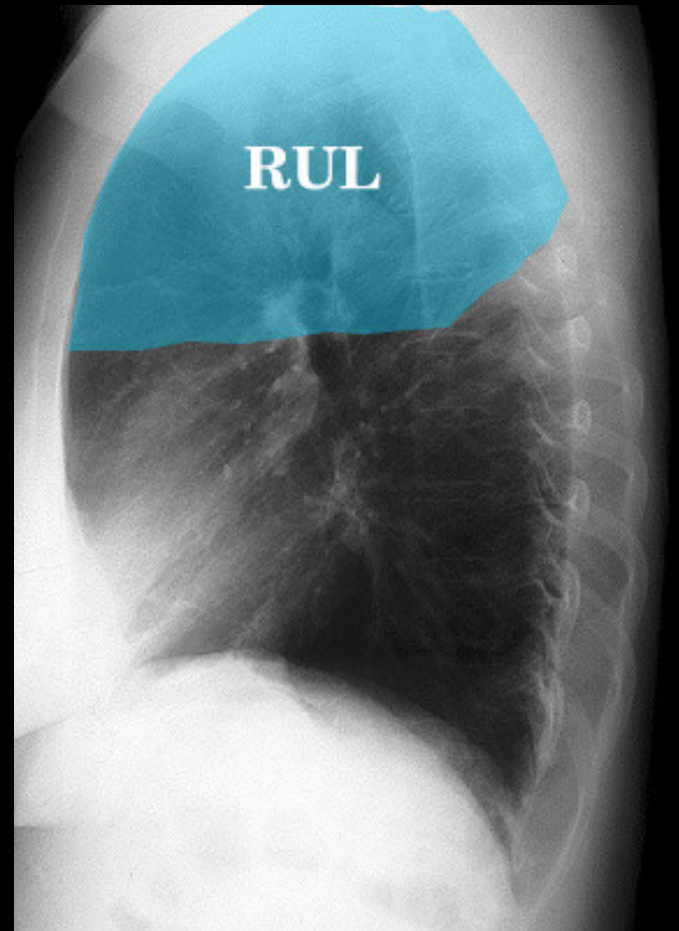
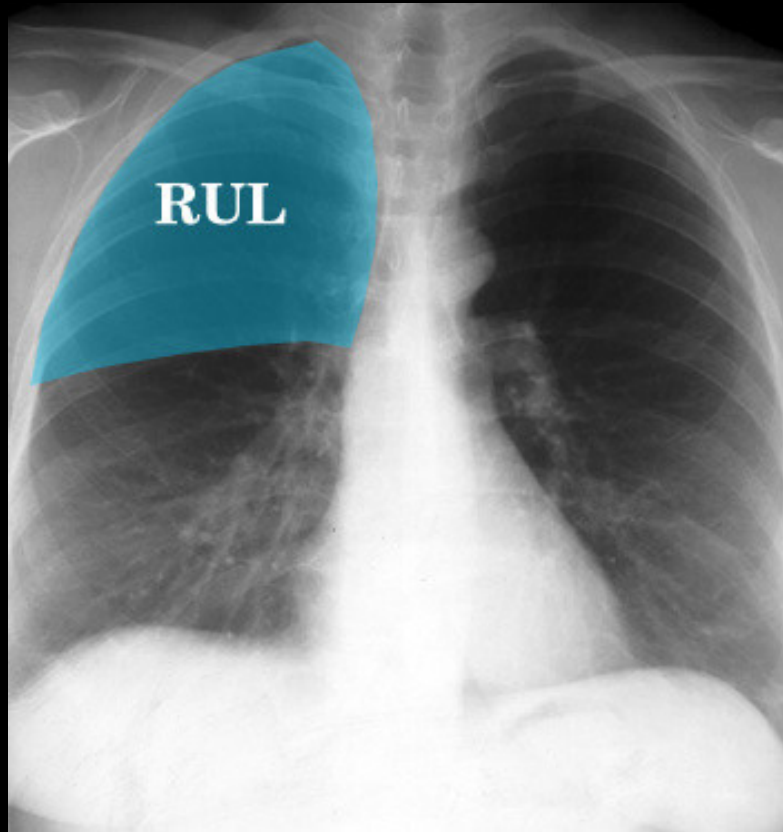


T. Soutien péri-broncho-vascul

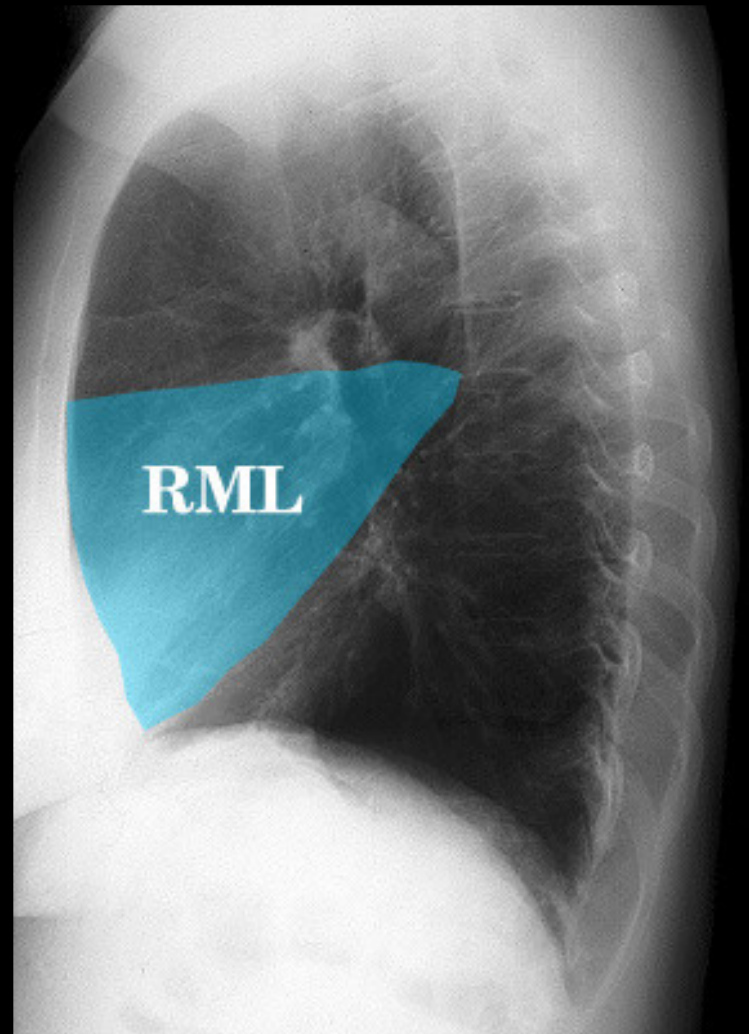
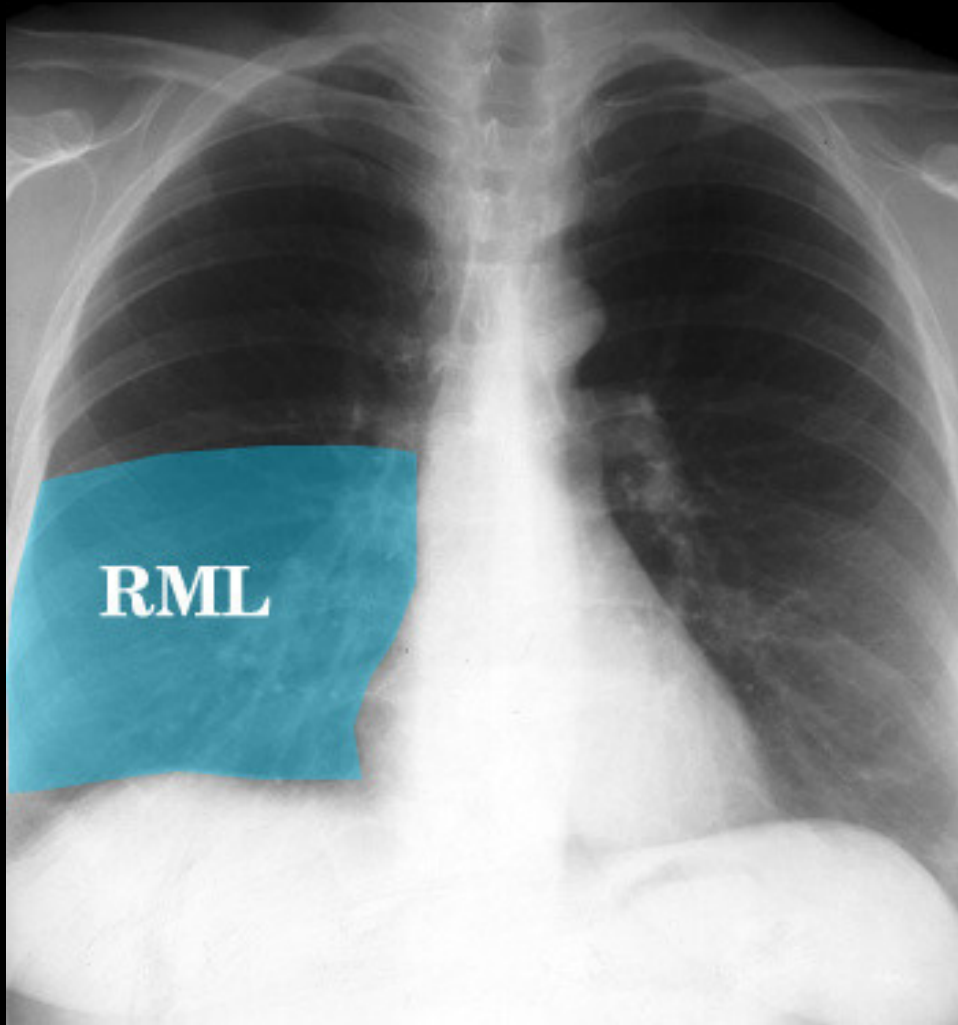


Septal (Perilobular)

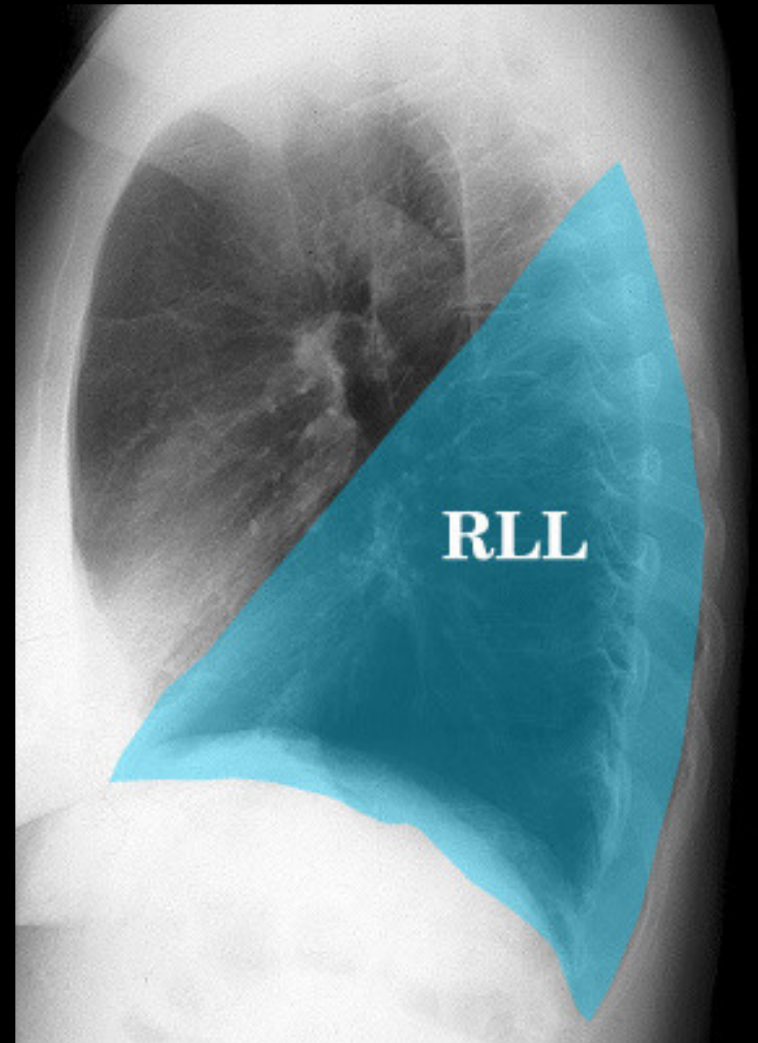
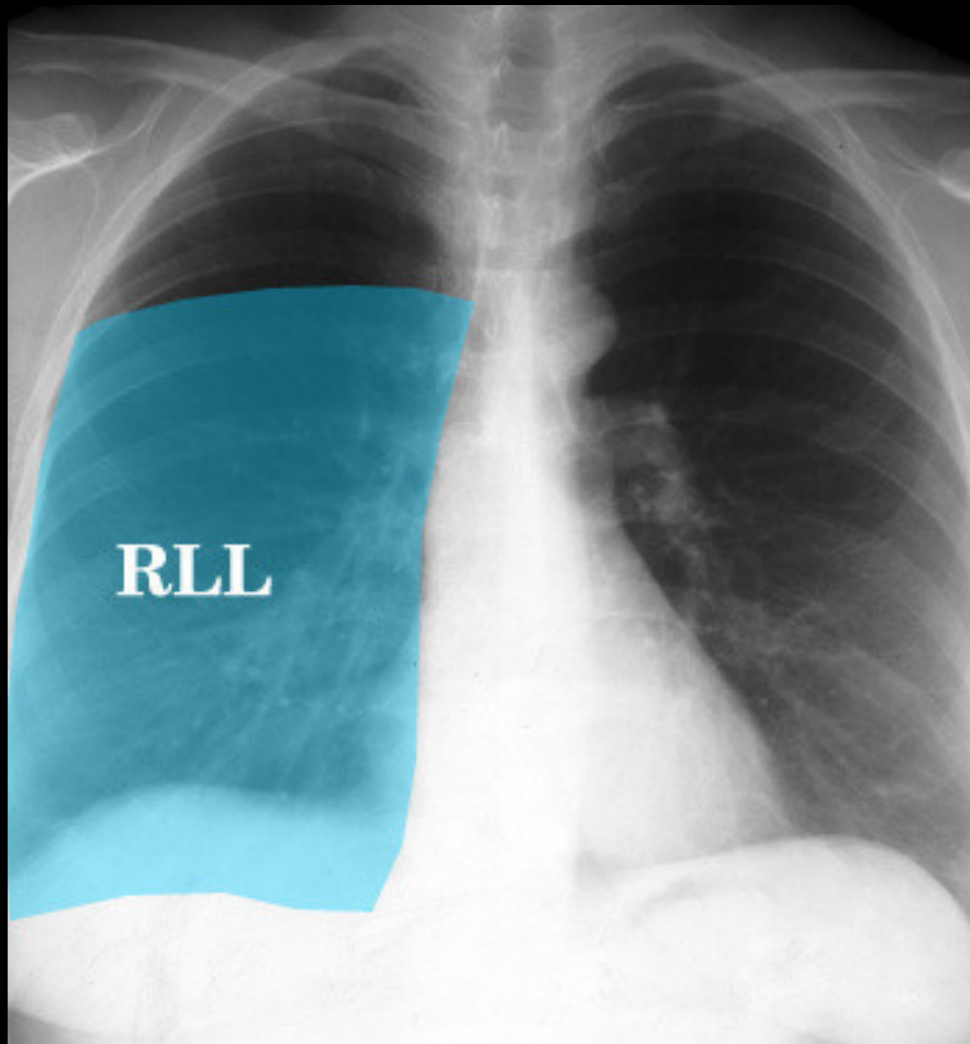
Radiographie standard



Lobe supérieur droit

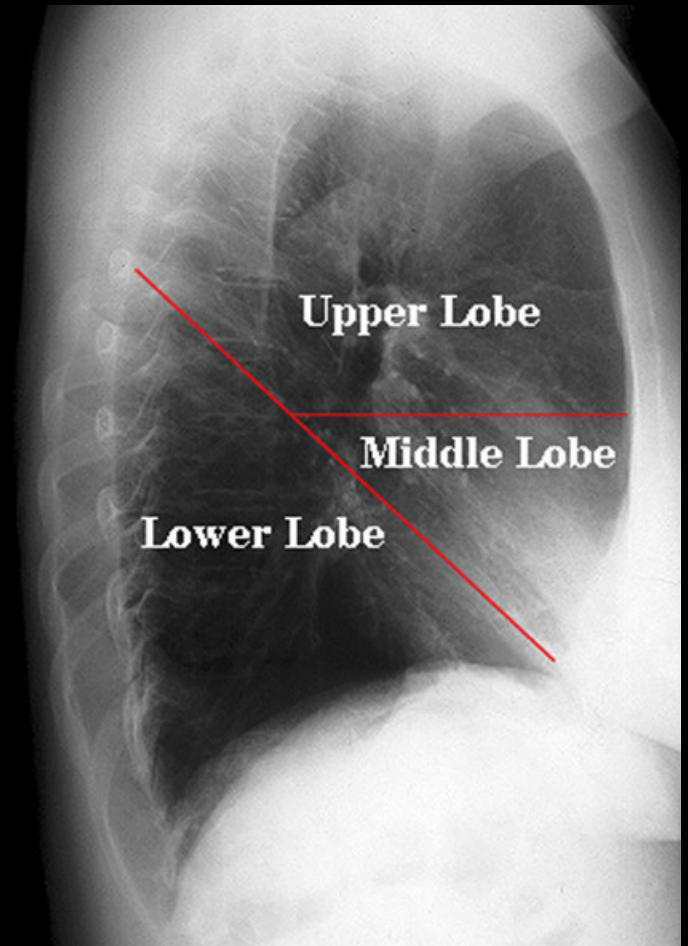
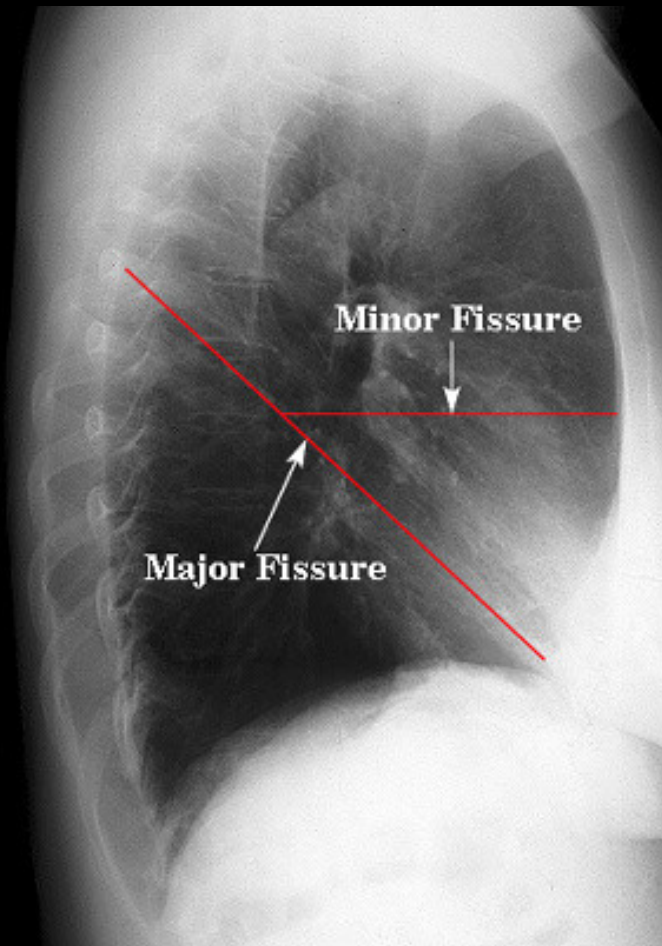


Lobe moyen



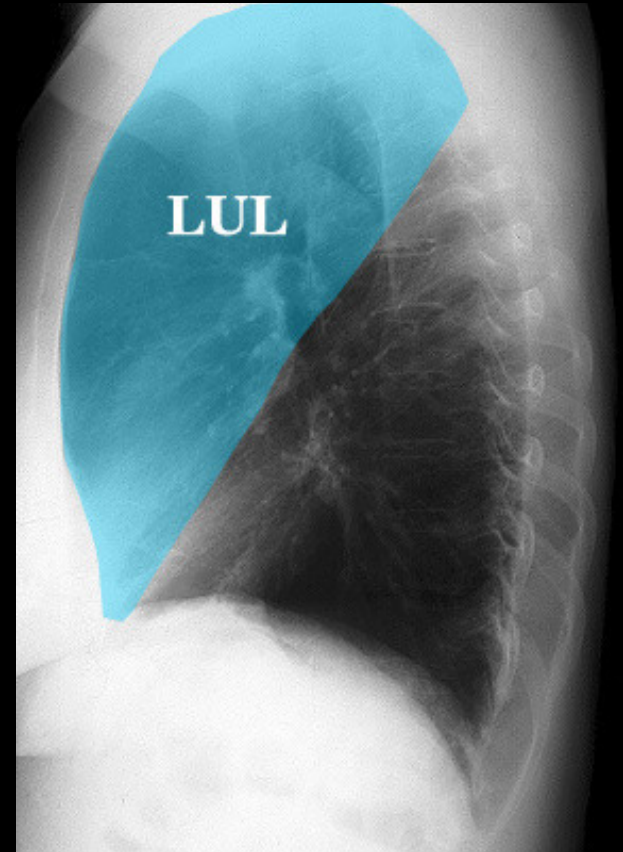
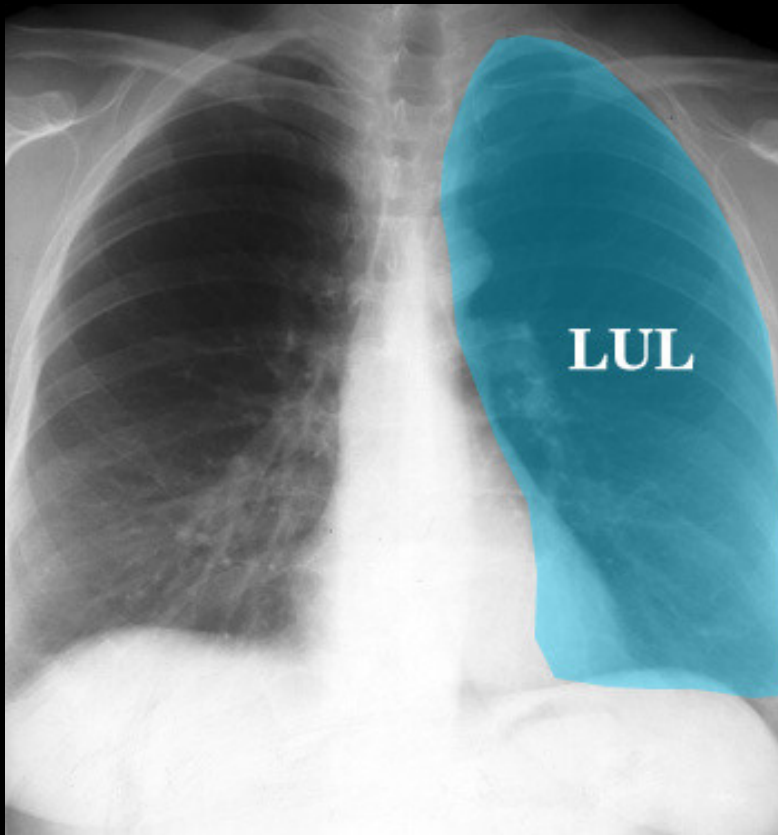
Lobe inférieur droit

A droite: les scissures

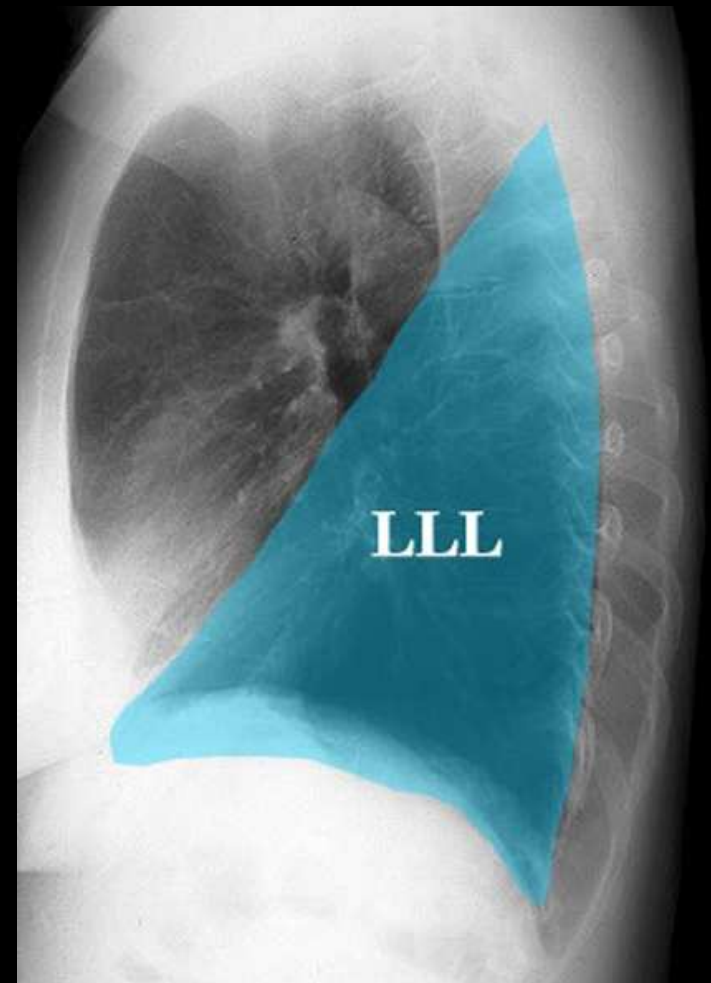
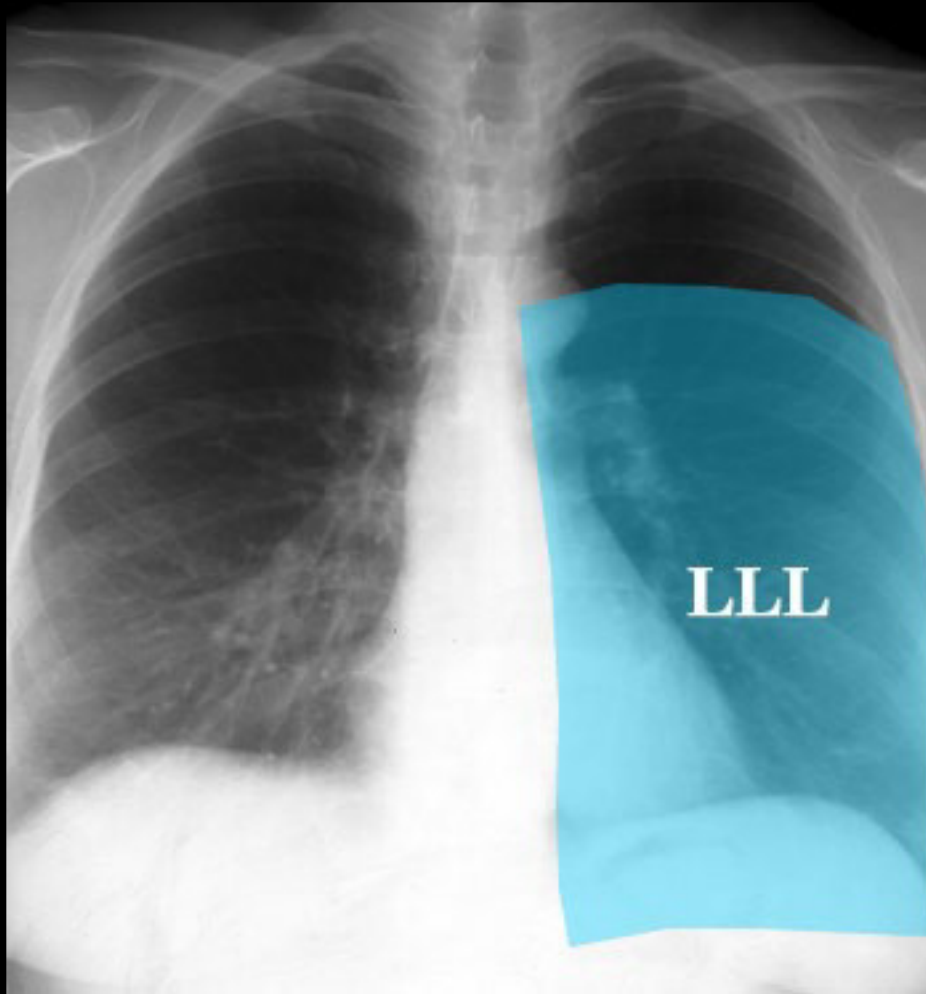


Application : Le signe de la silhouette de Felson

- 2 structures de tonalité hydrique se confondent si elles sont situées dans le même plan
- De grande valeur pour la détermination topographique d'une opacité intra thoracique qu'elle soit médiastinale ou pulmonaire : en effet deux opacités qui se silhouettent (en effaçant leur bord) se trouvent sur un même plan.
- ex : opacité dans le lobe moyen effaçant le bord droit du coeur.

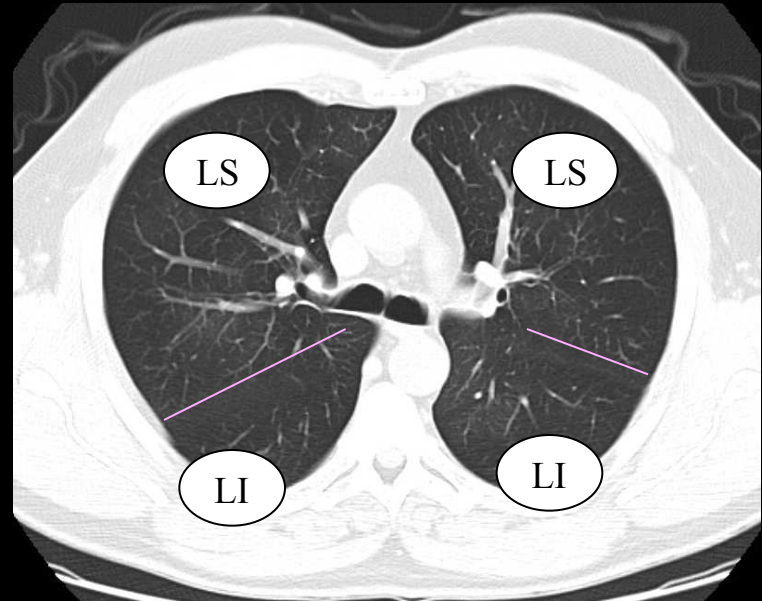
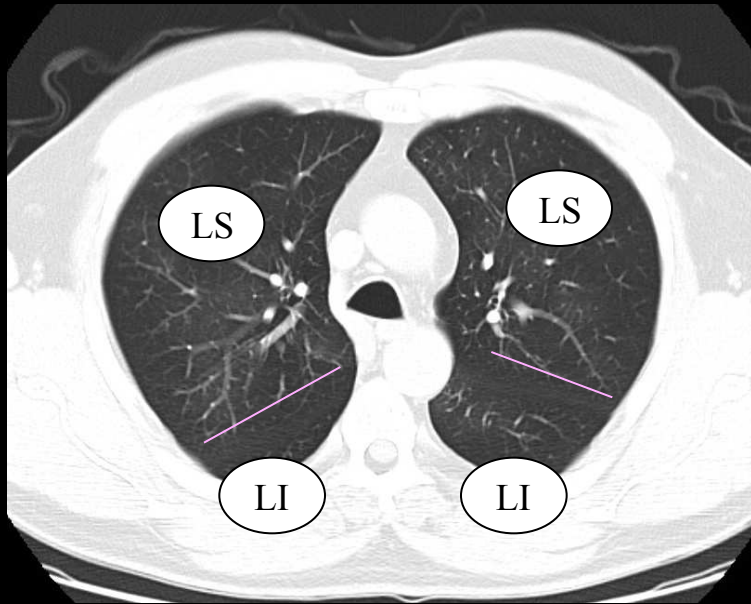
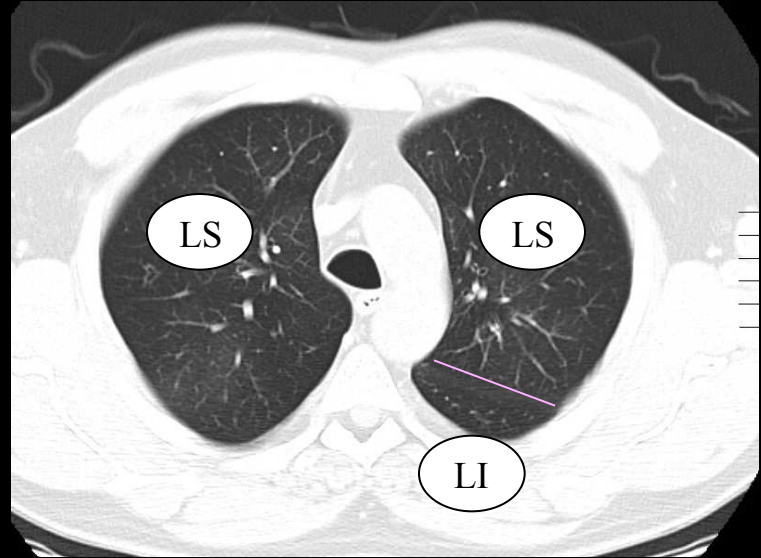
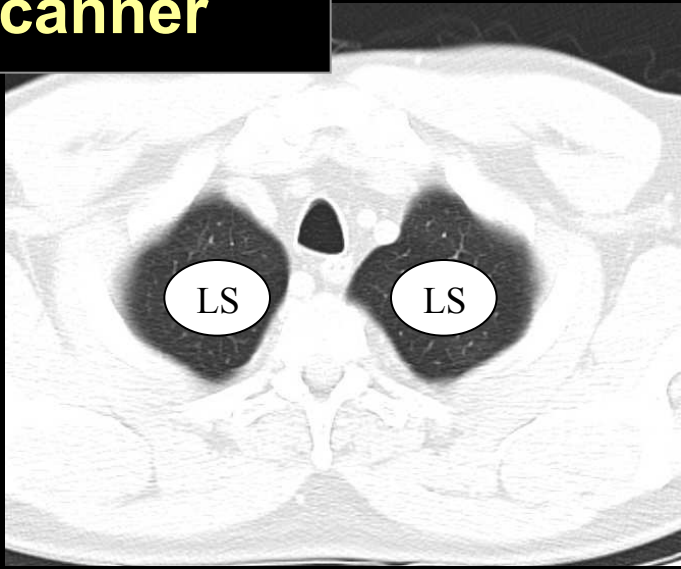


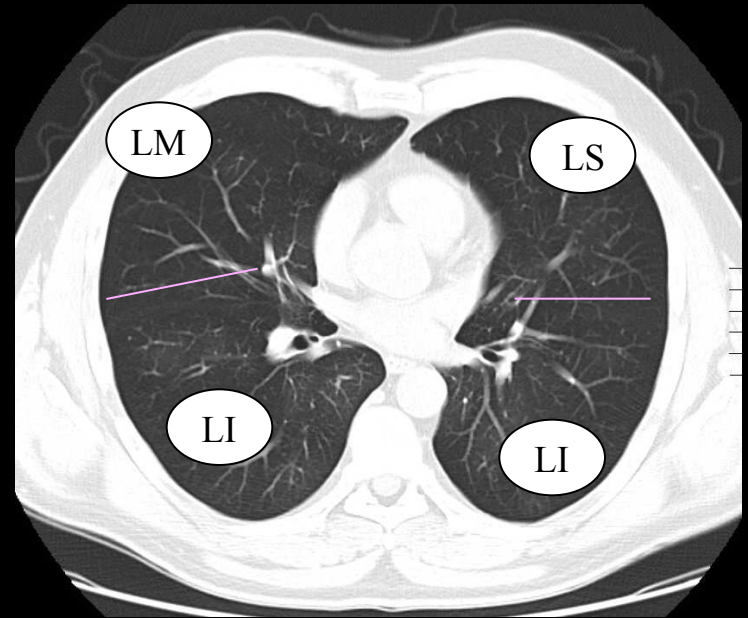
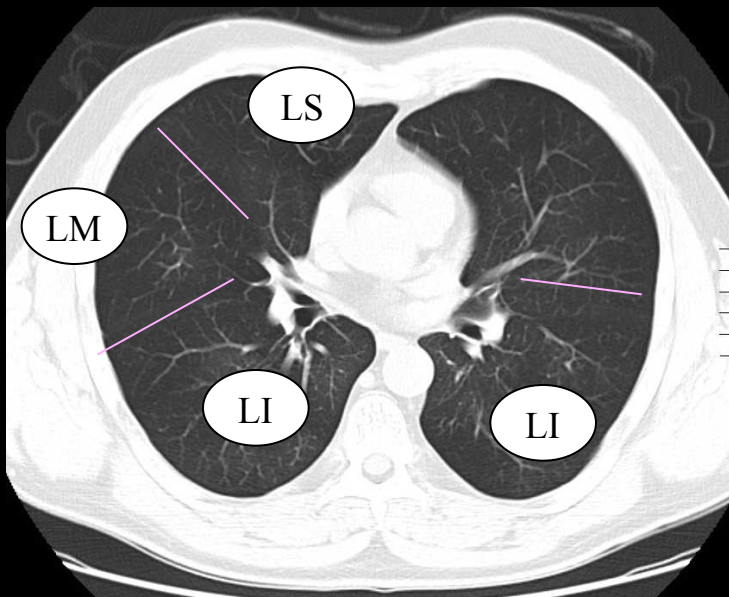
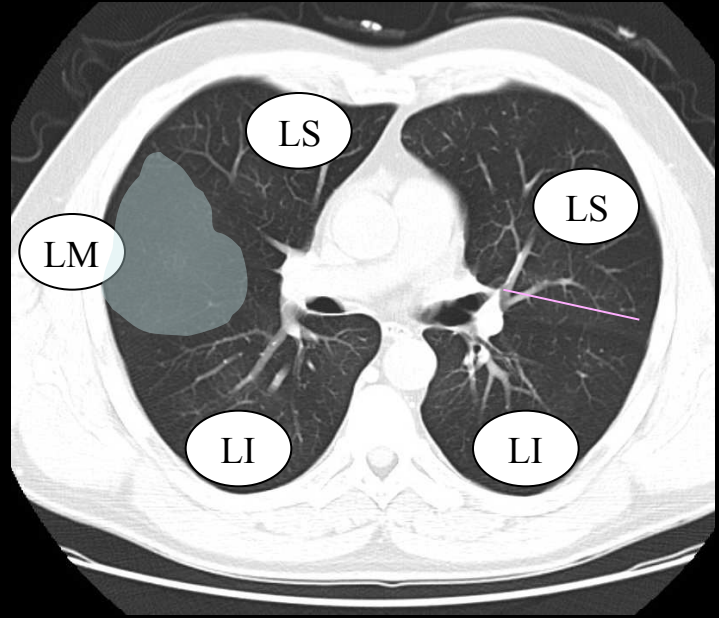
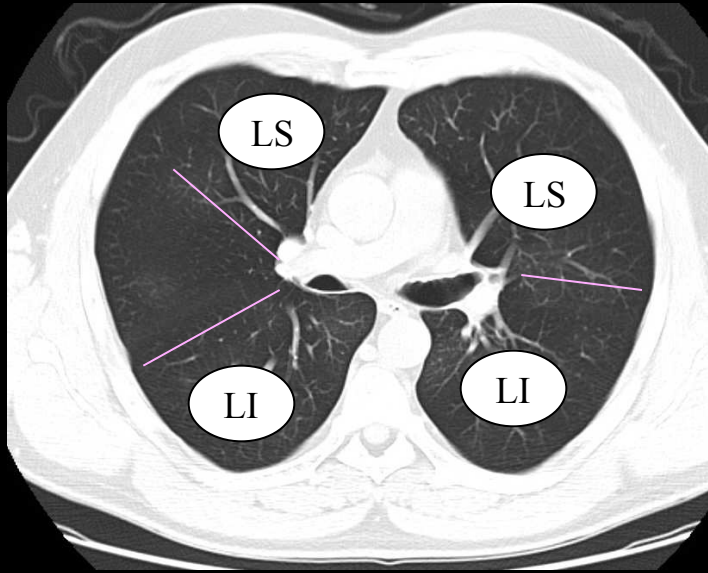
Lobe supérieur gauche

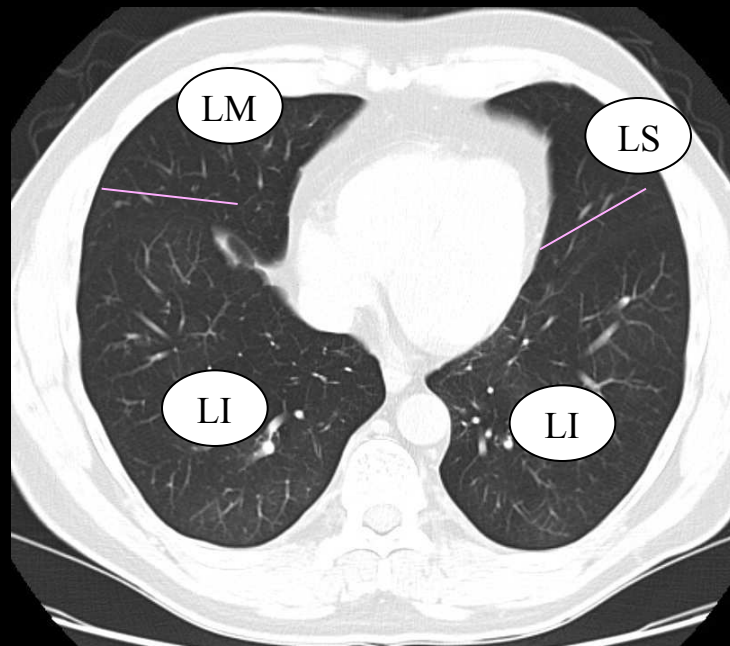
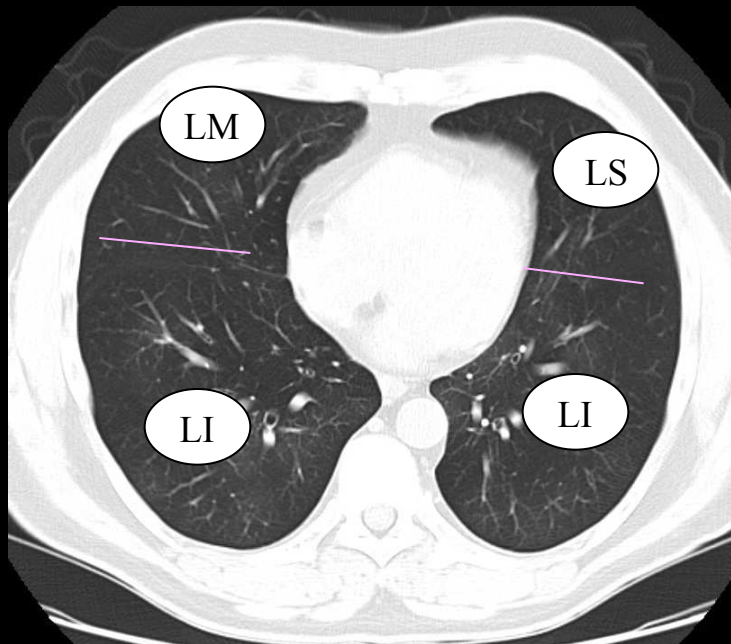
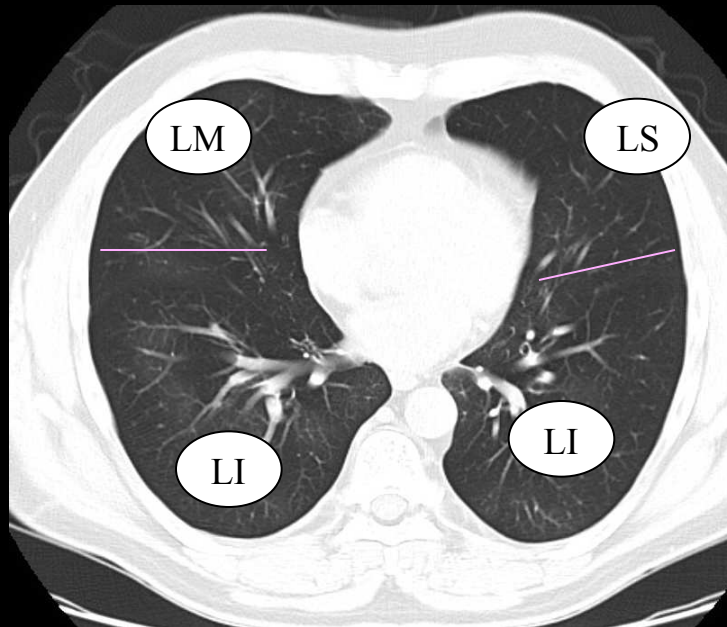
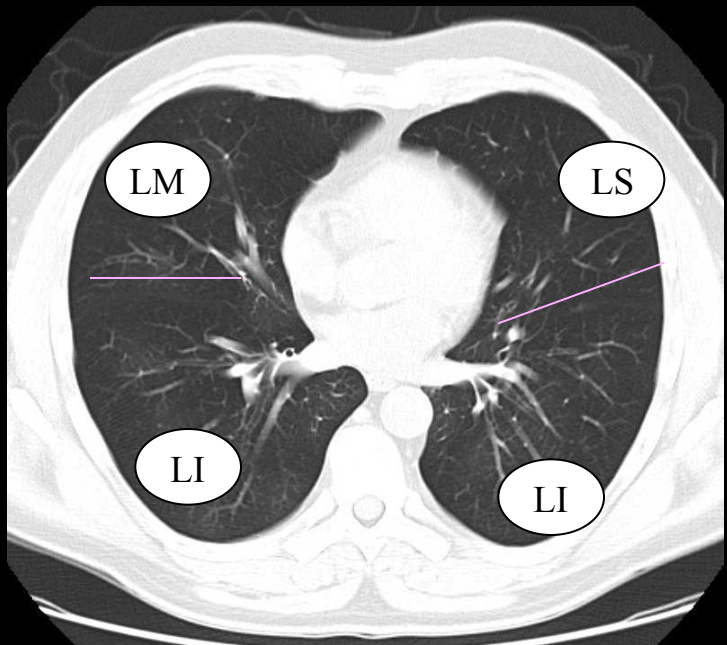


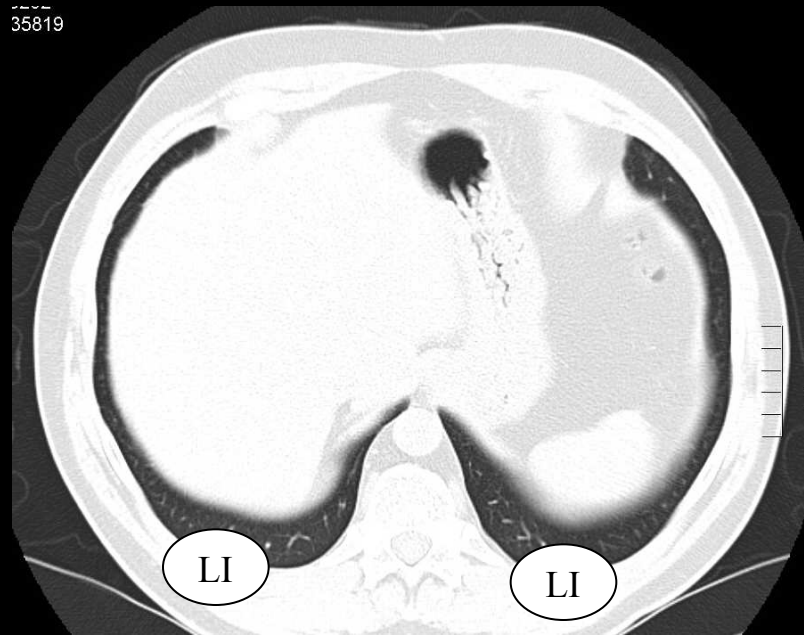
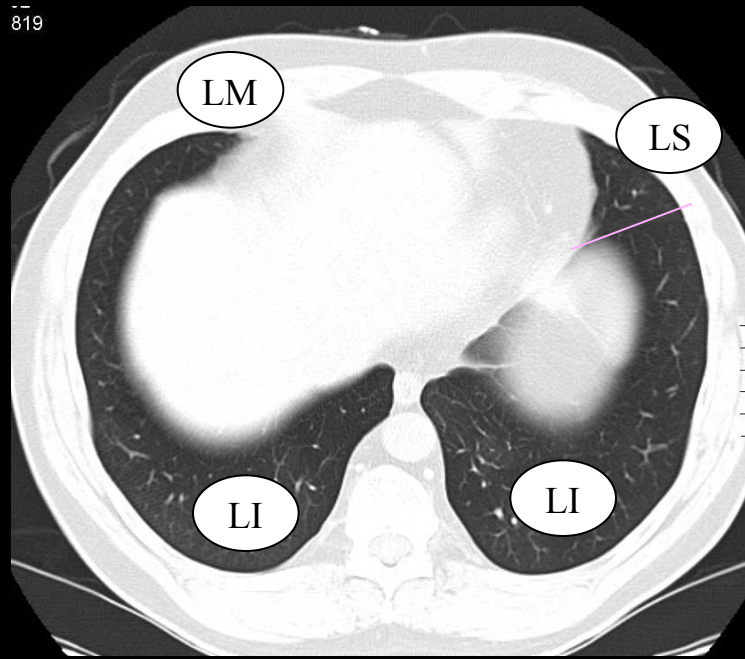
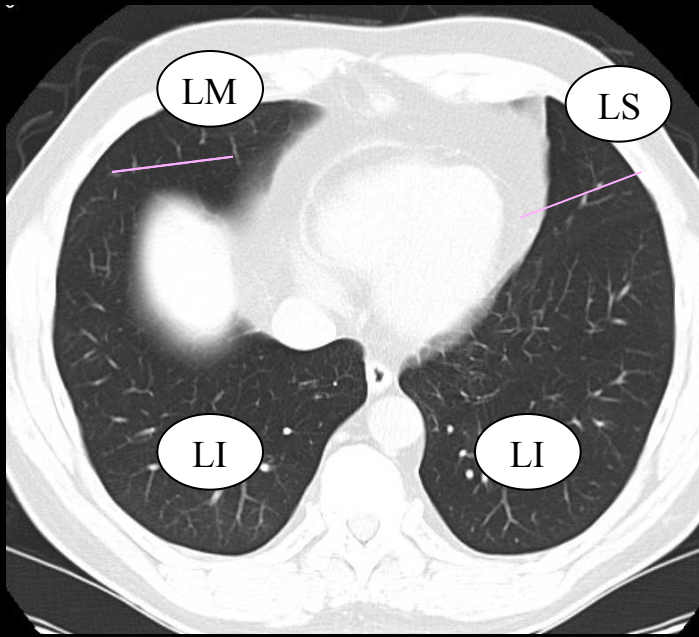
Lobe inférieur gauche

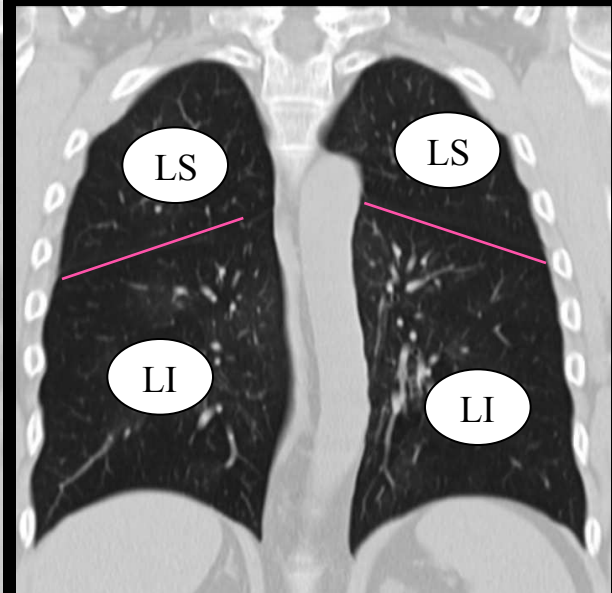
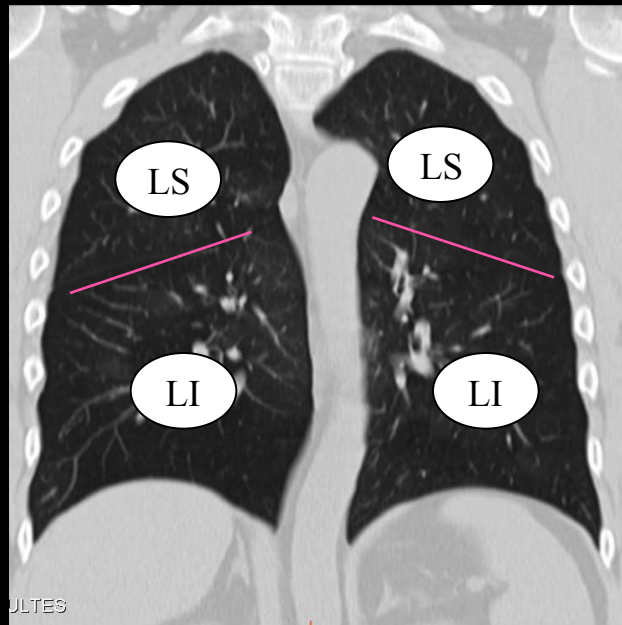
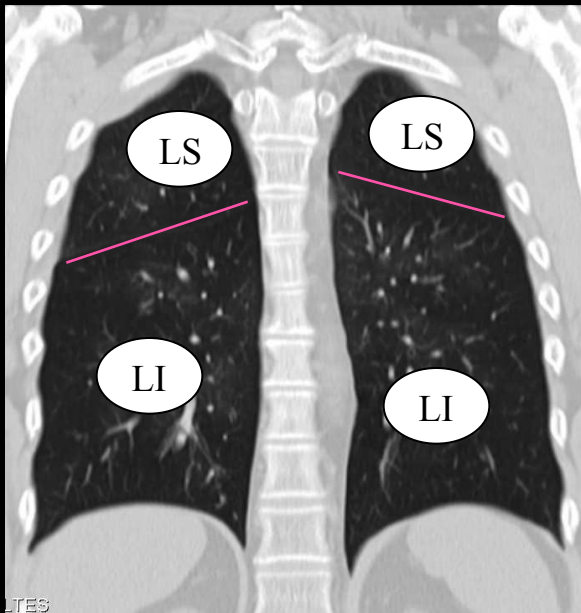
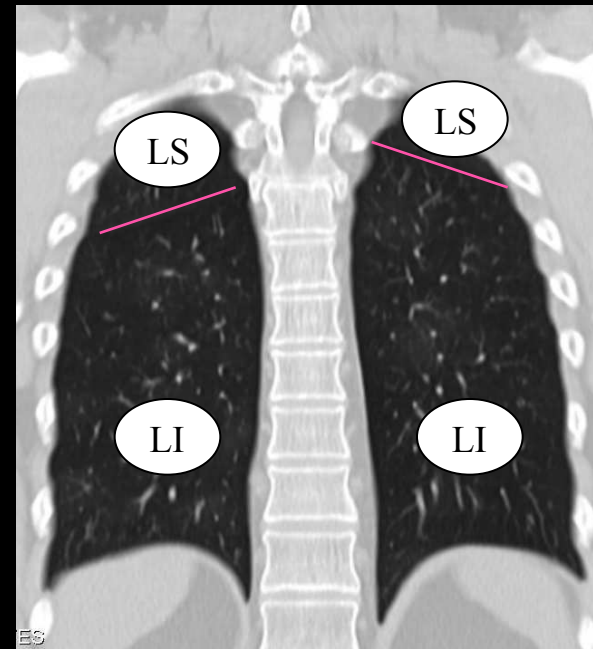
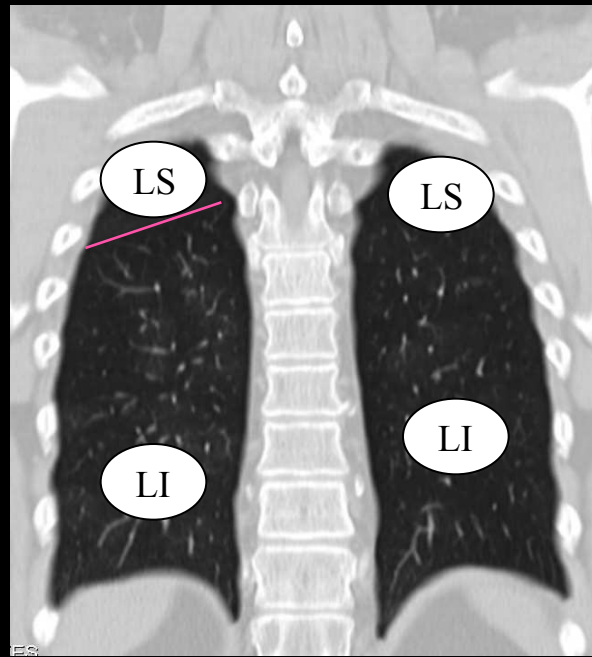
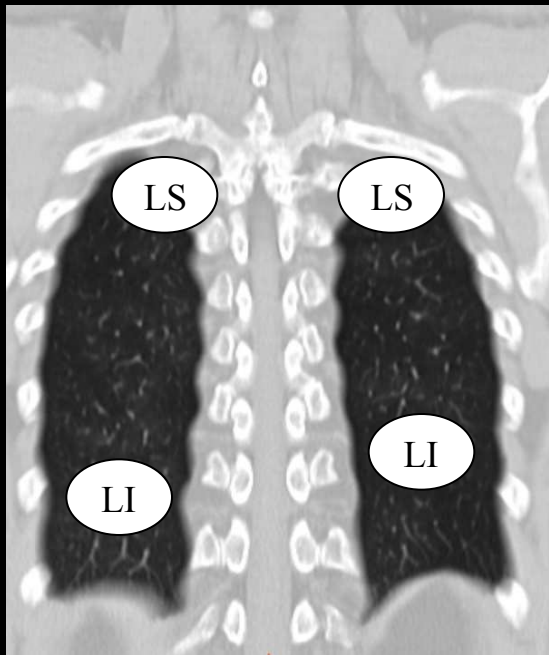
Scanner

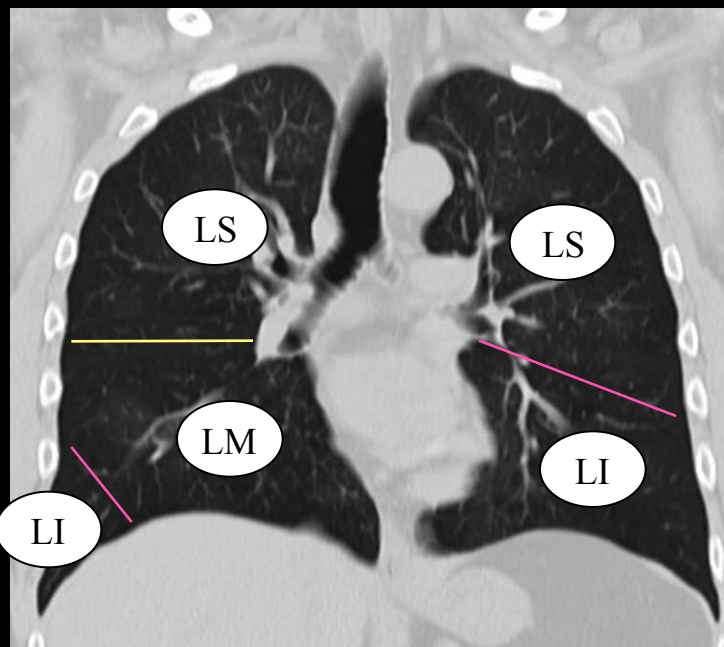
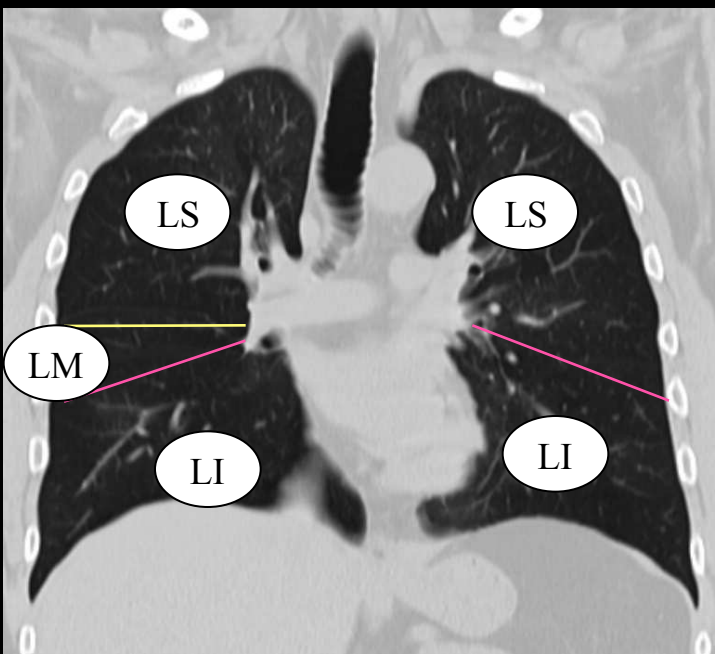
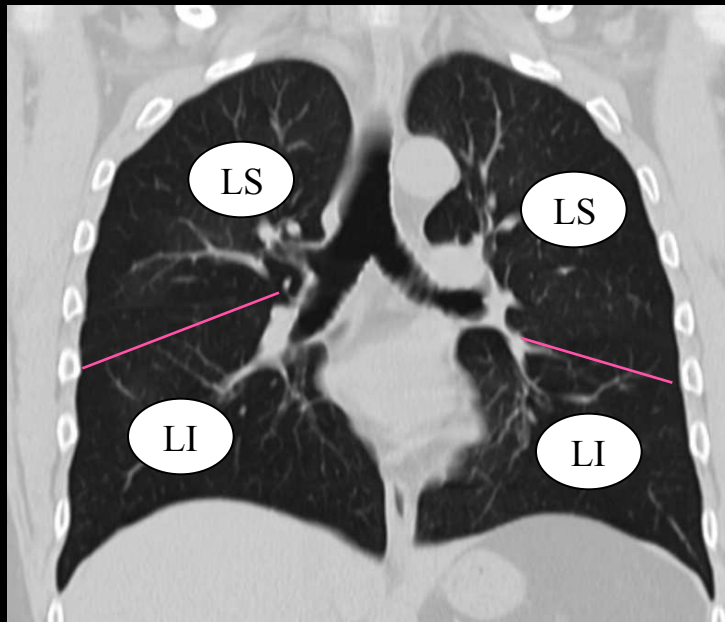
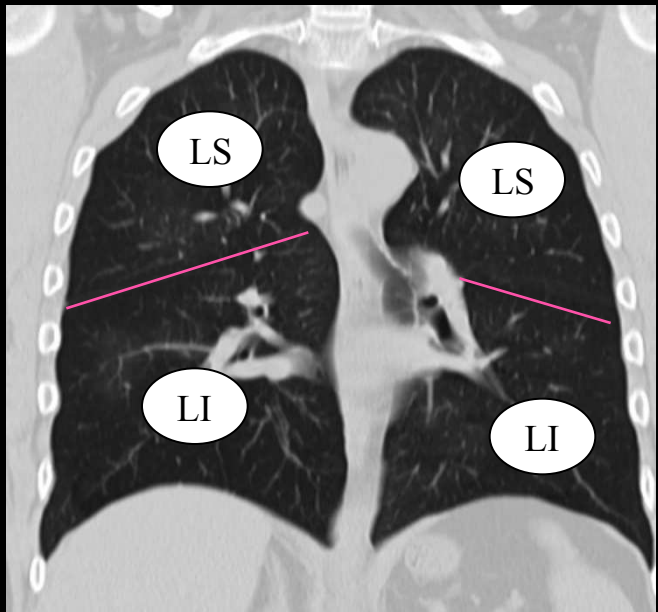


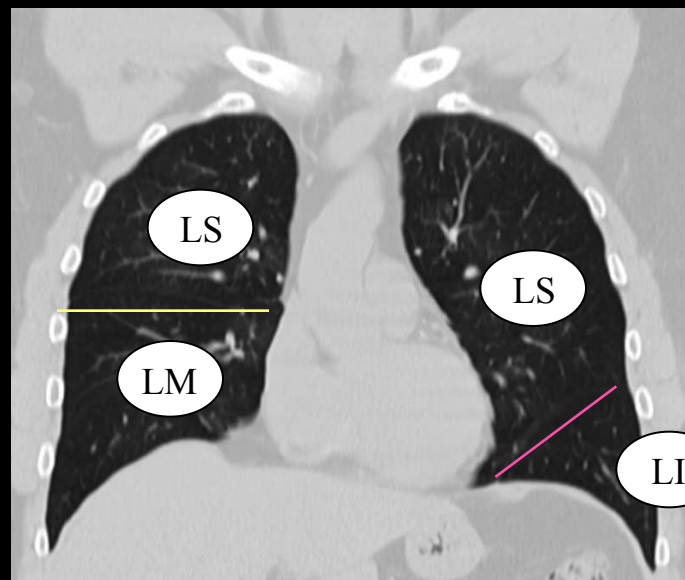
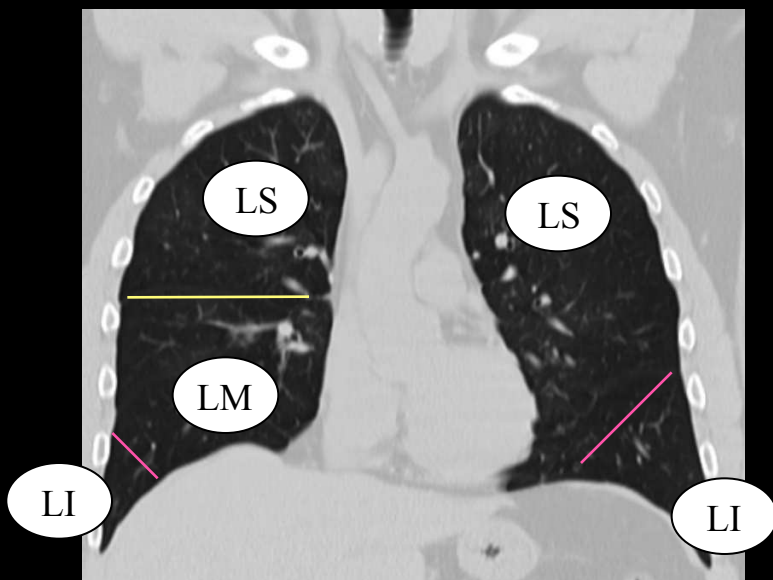
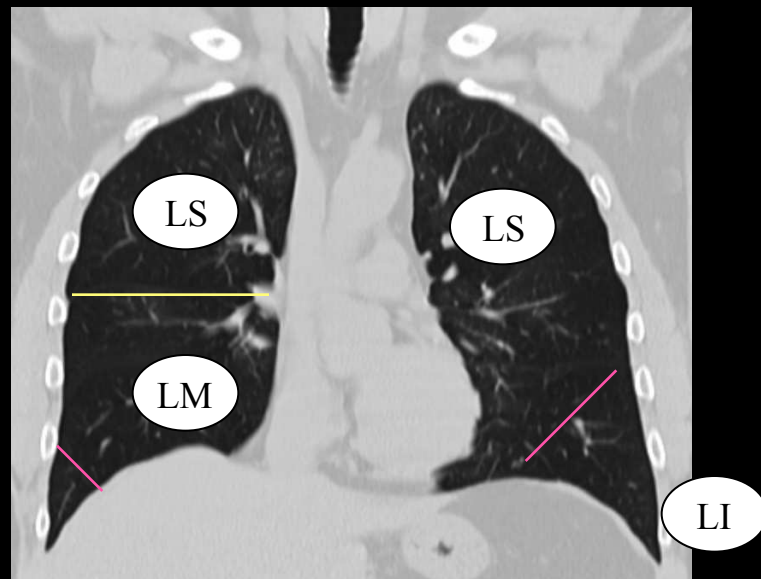
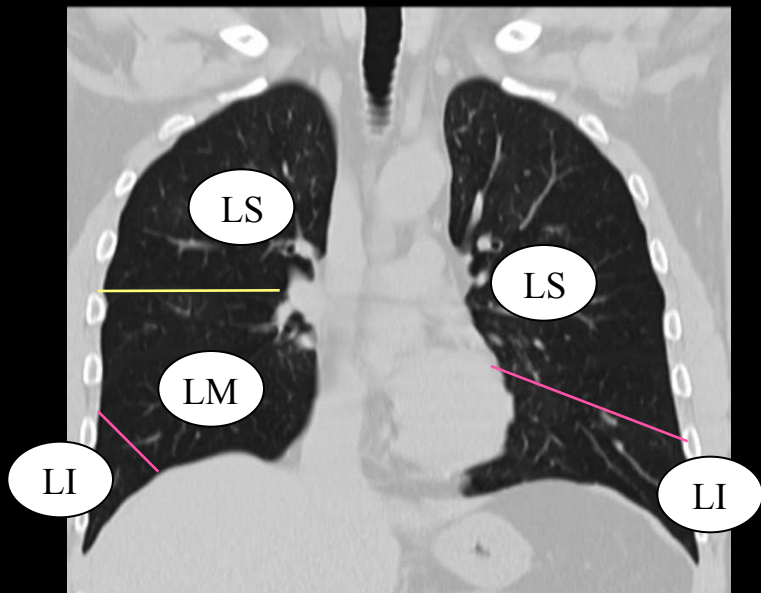






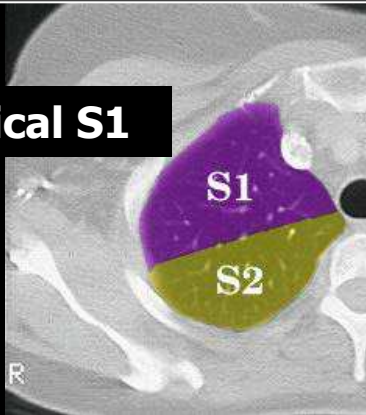




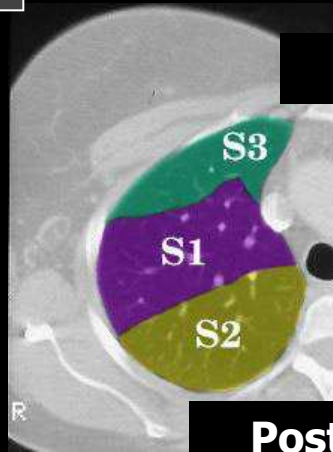


POUMON DROIT

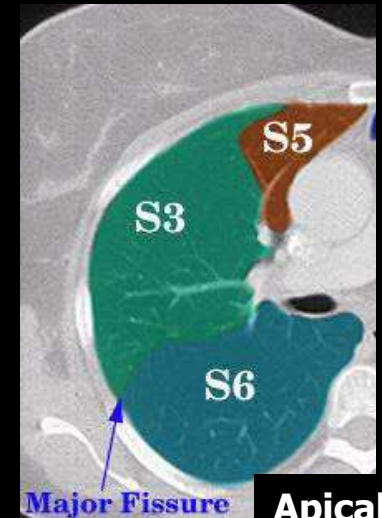
Apical S1



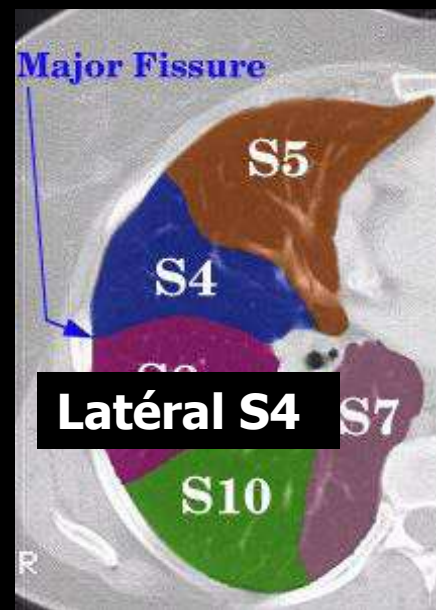
Antérieur S3



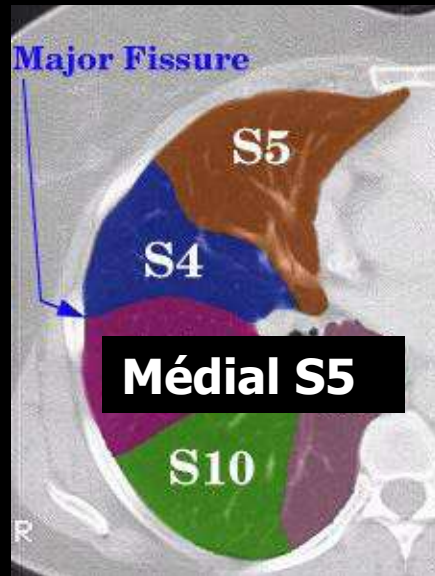
Postérieur S2



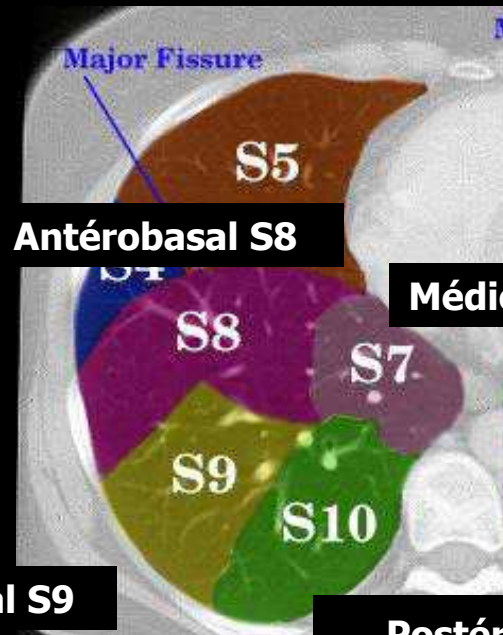
Apical S6



Latéral S4



Médial S5



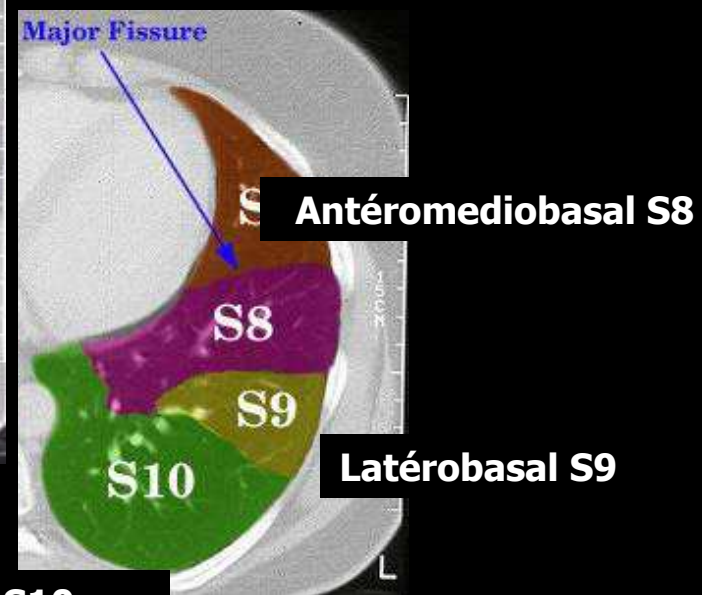
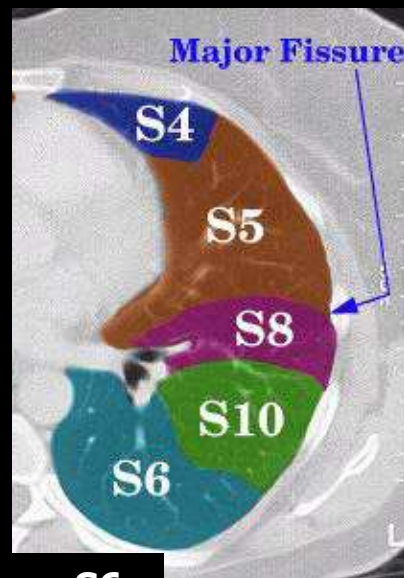
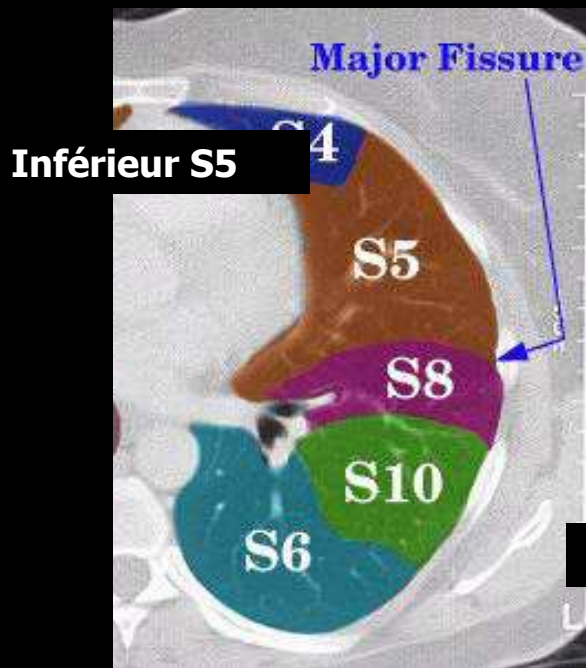
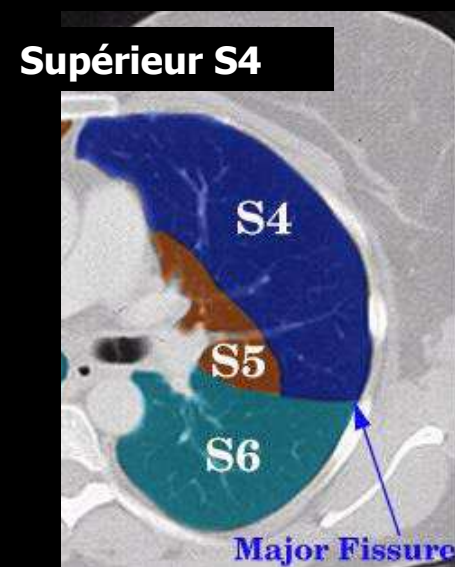
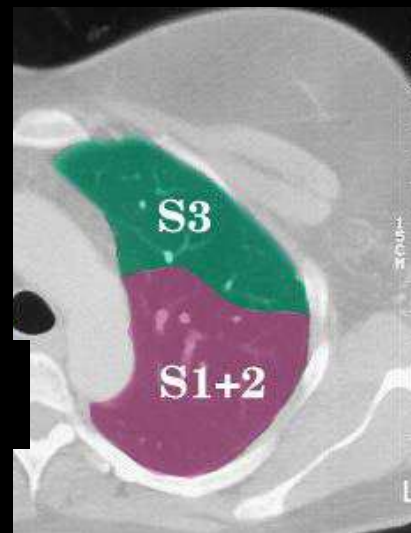
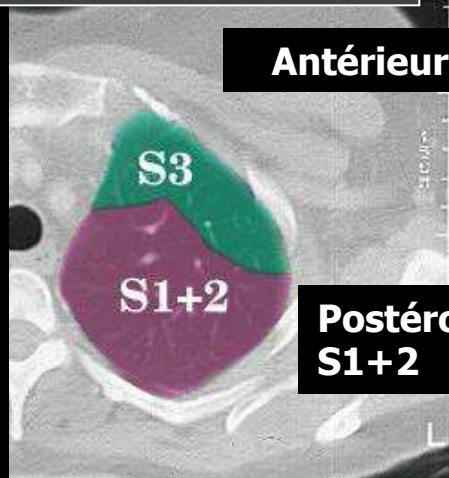
Antérobasal S8

Médiobasal S7

Latérobasal S9

Postérobasal S10

POUMON GAUCHE

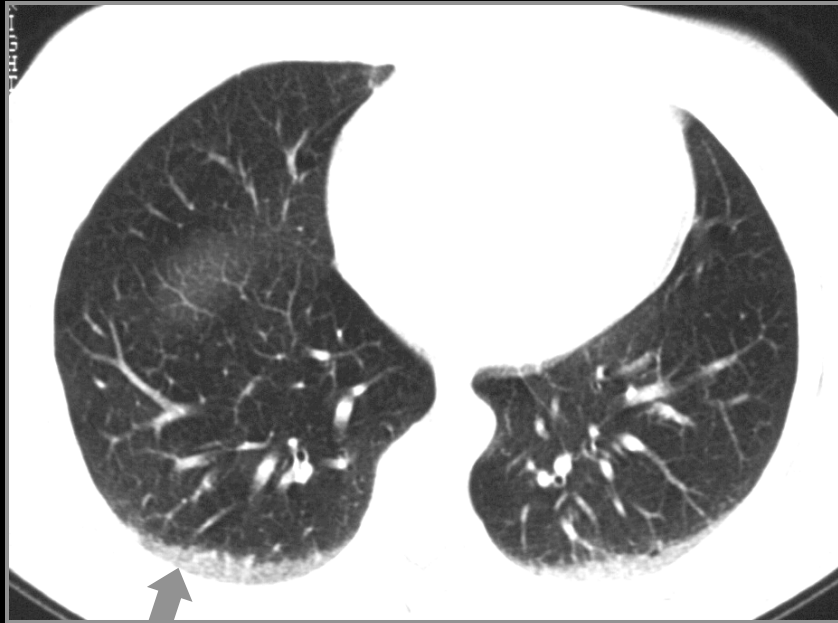


Postérobasal S10



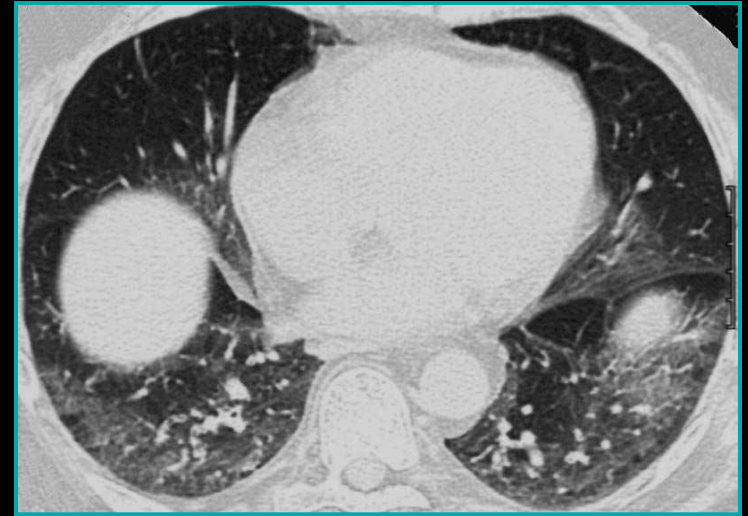
**UN PEU DE PATHOLOGIE ET
VARIATIONS ANATOMIQUES...**

Stase Physiologique

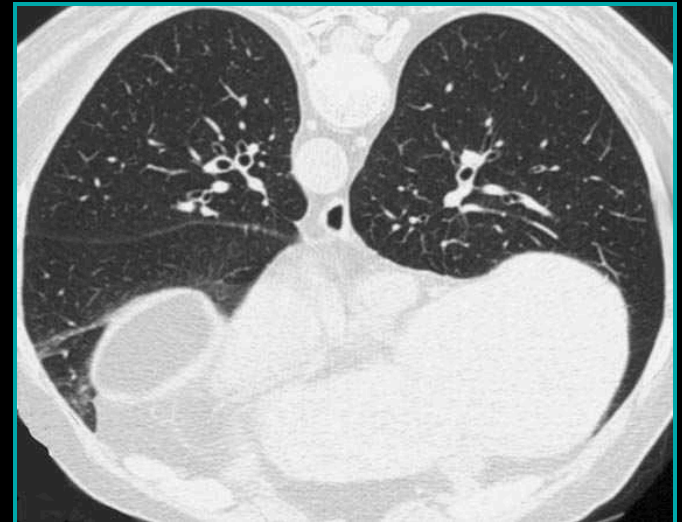


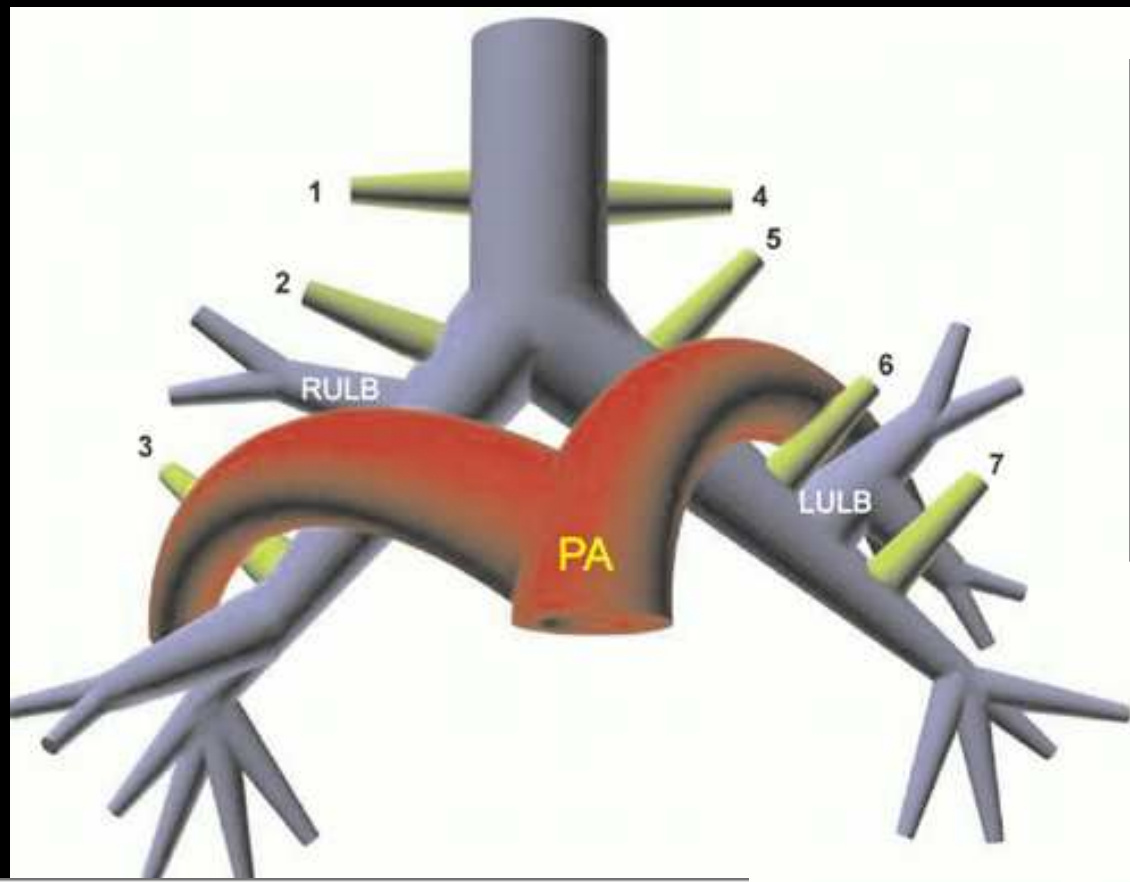
Territoires
Déclives

inspiration



procubitus



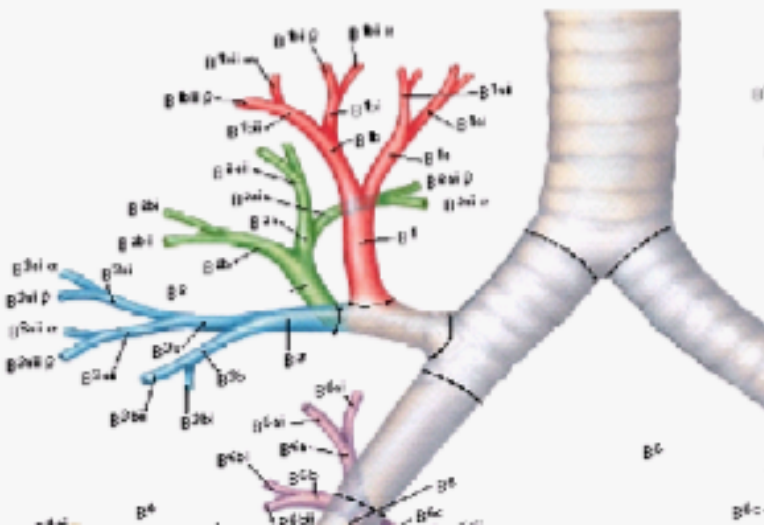


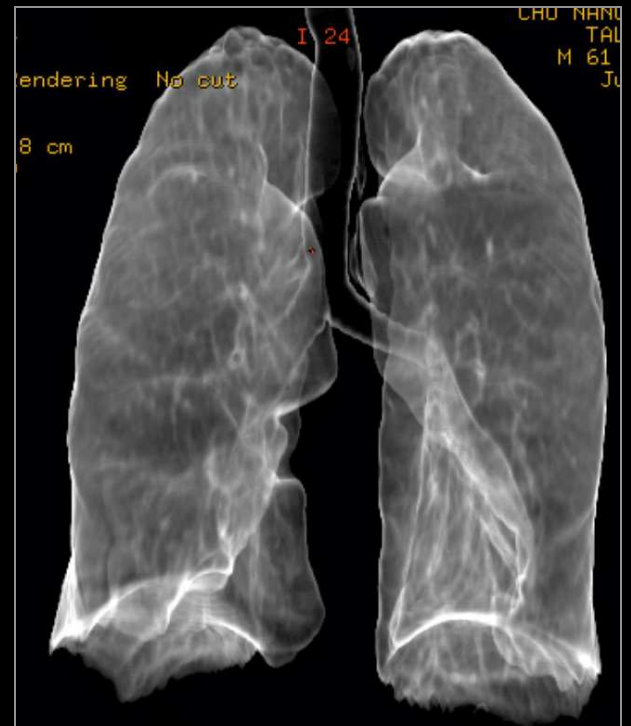
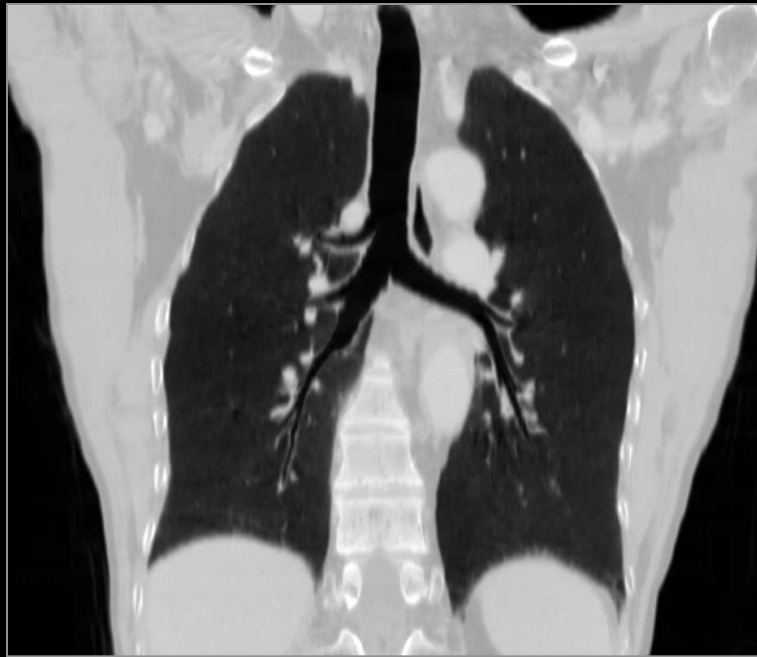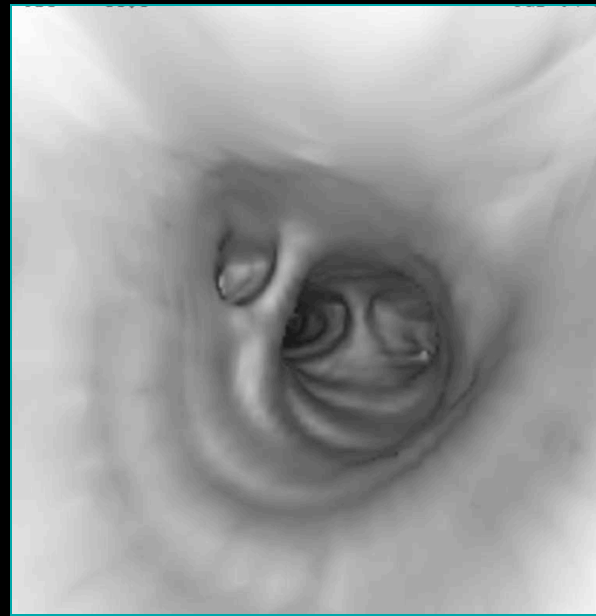
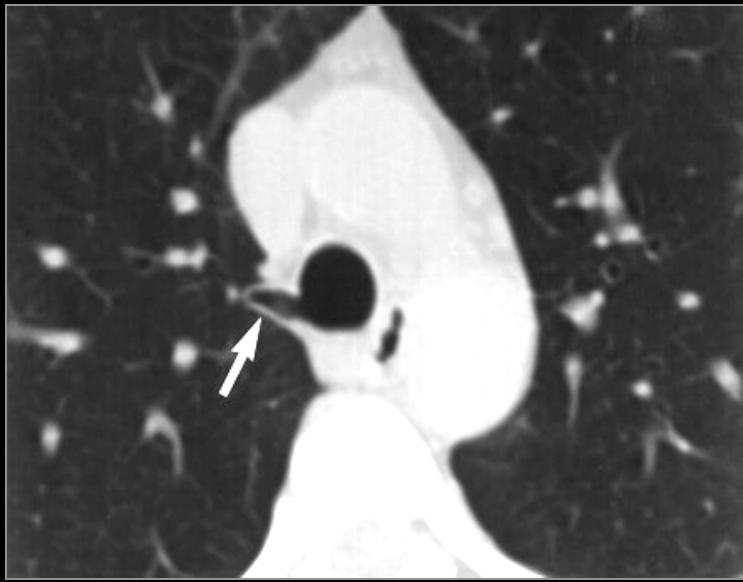
Bronche ectopique

Les plus fréquentes 2%

Origine déplacée

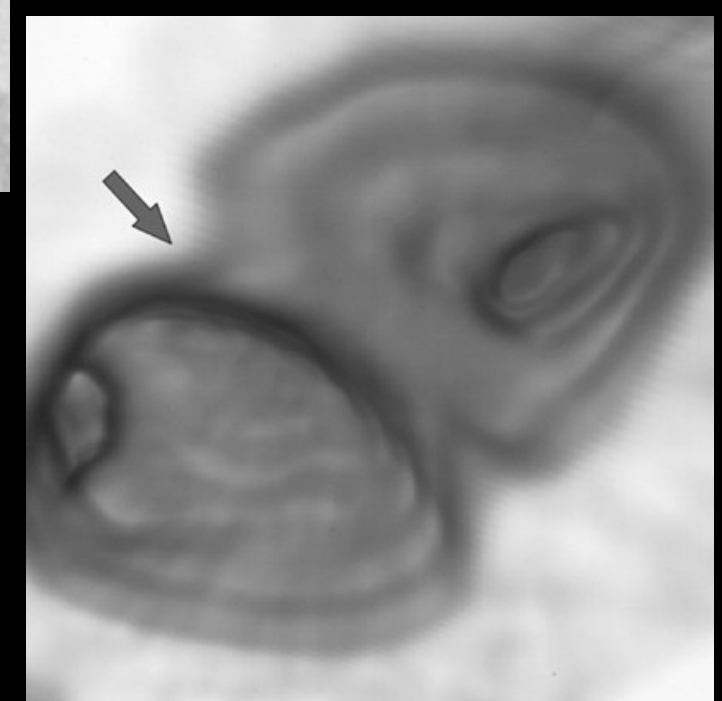
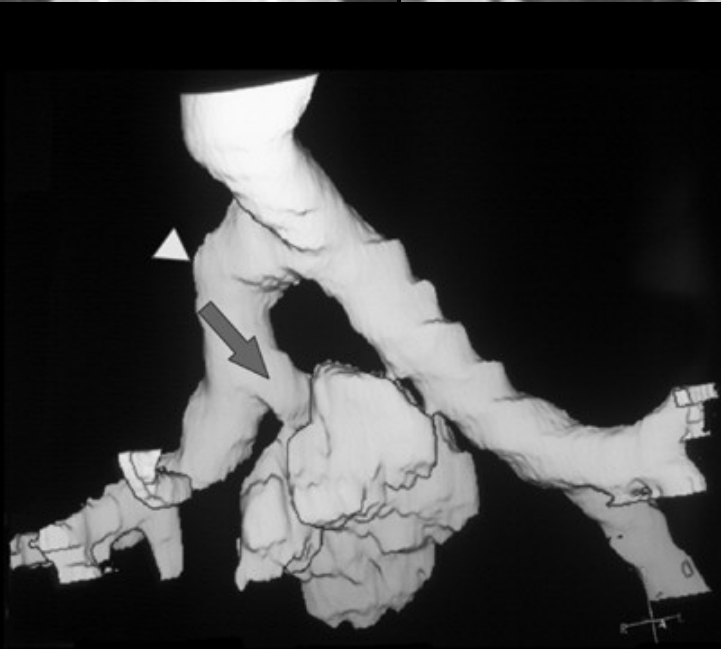
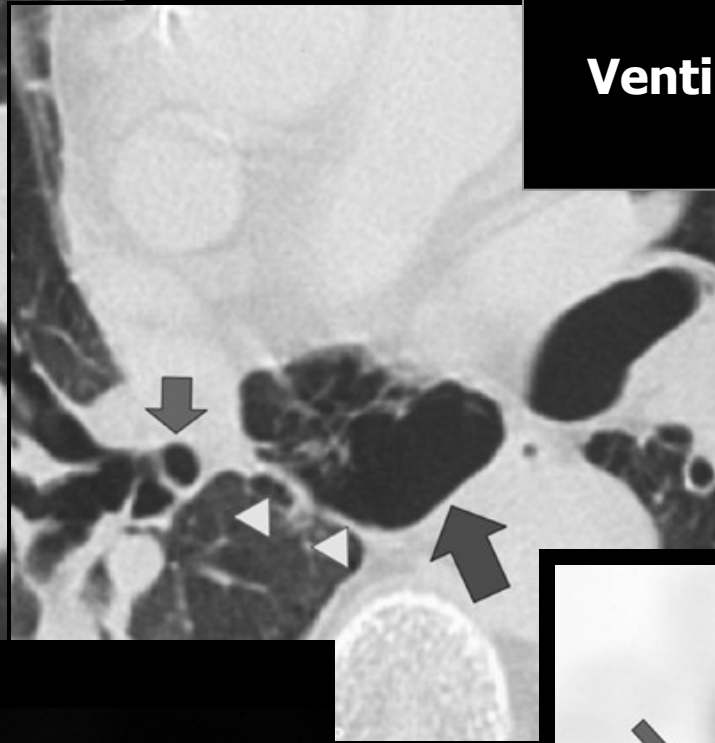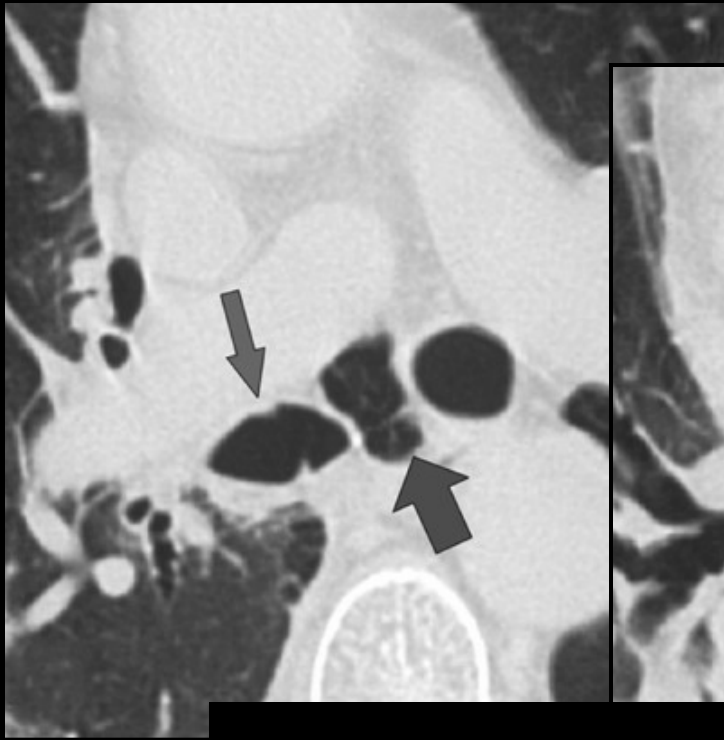
drainage territoire normal
anatomiquement





Bronche surnuméraire

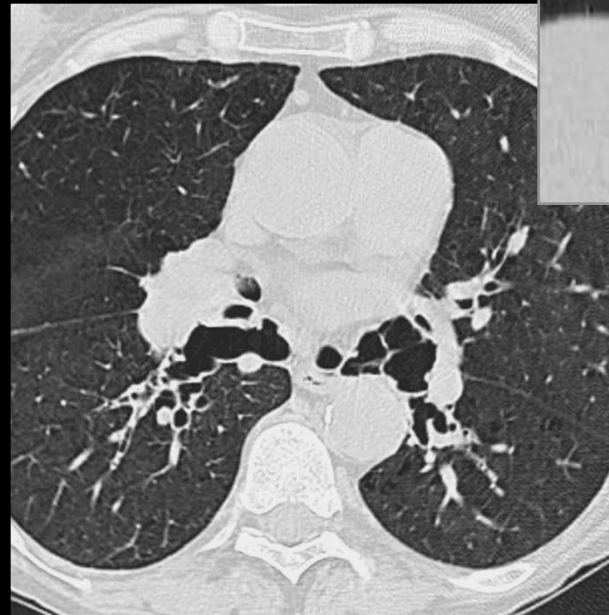
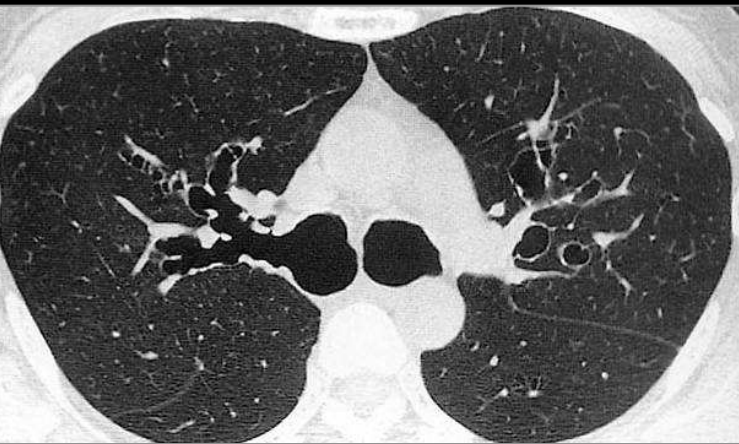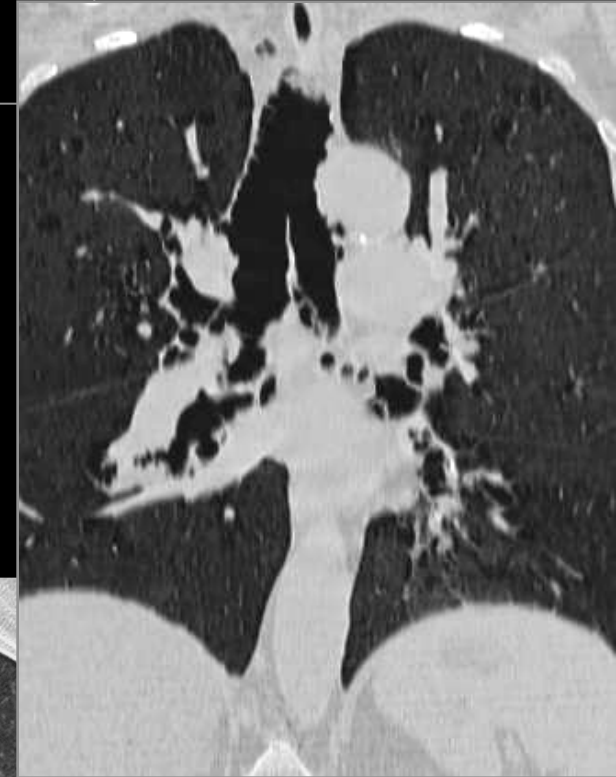
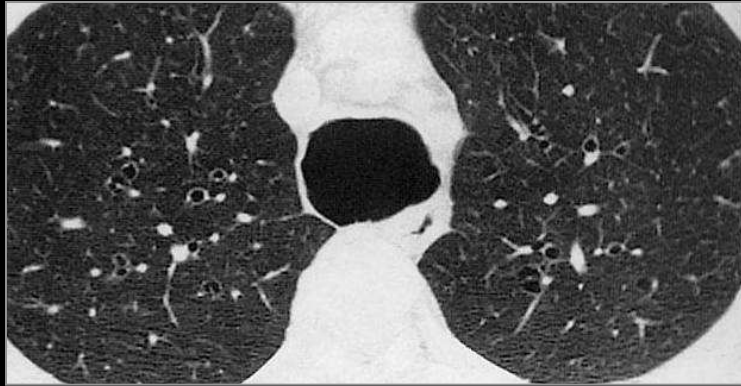Ventilation d'un territoire supplémentaire



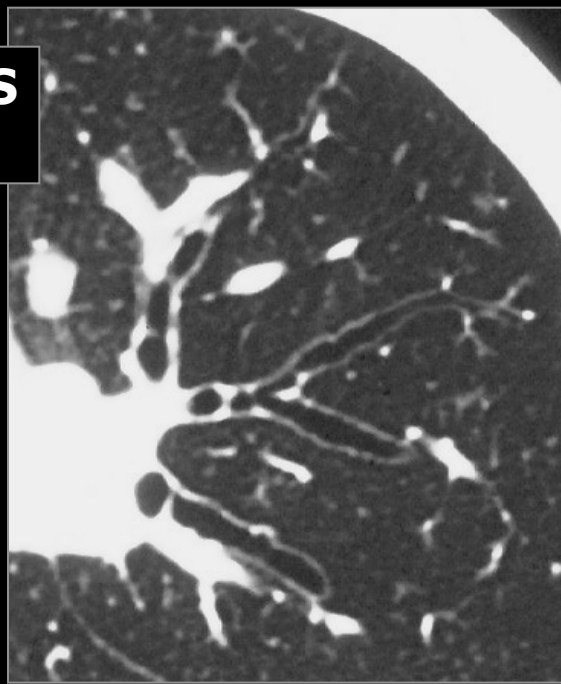
Trachéobronchomégalie (maladie de Mounier-Kuhn)

Maladie des tissus musc. et élastiques

Maladie intrinsèque VA ou associée à maladie Ehler Danlos



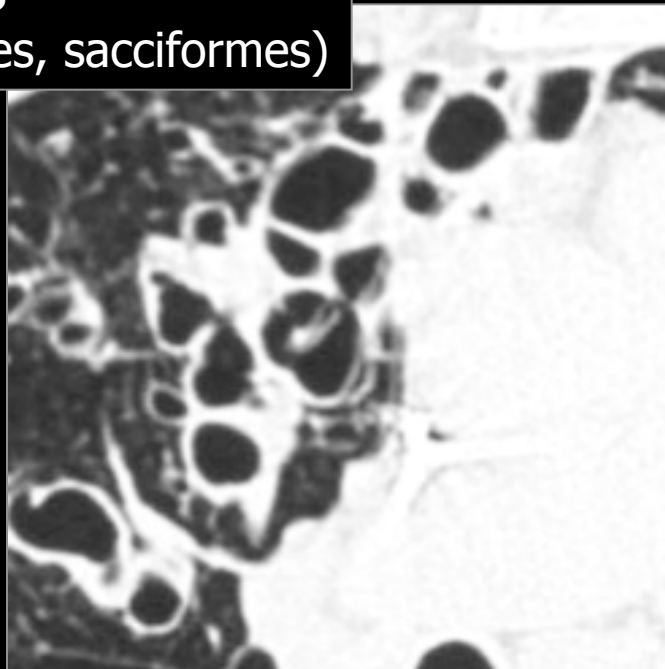
CYLINDRIQUES
(= fusiformes)



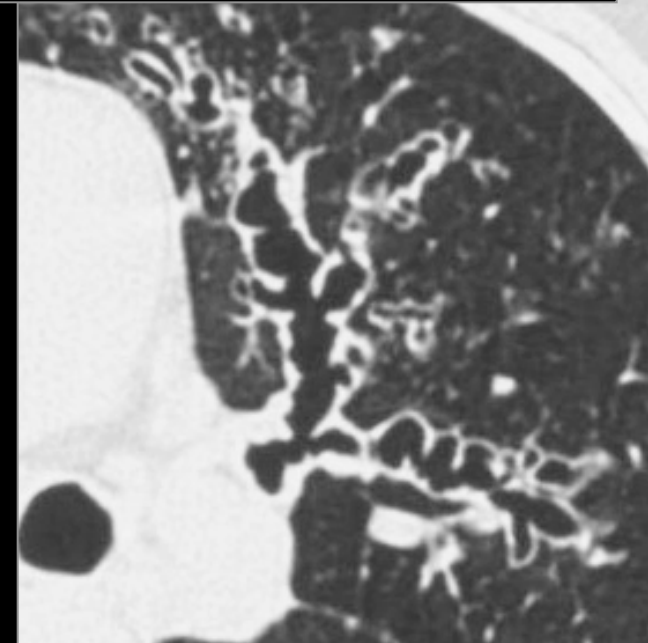
Bronchiectasies
Classification de Reid
(1950)

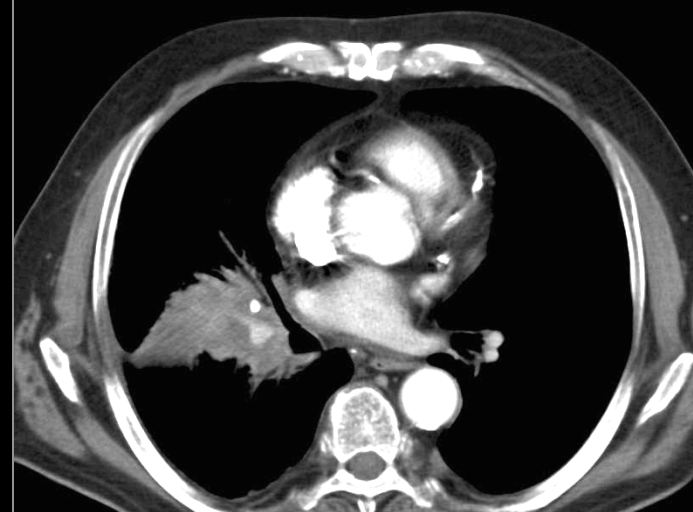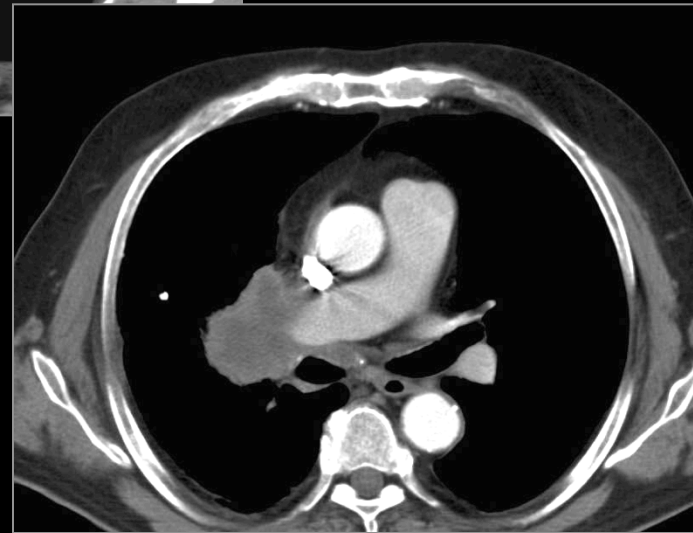
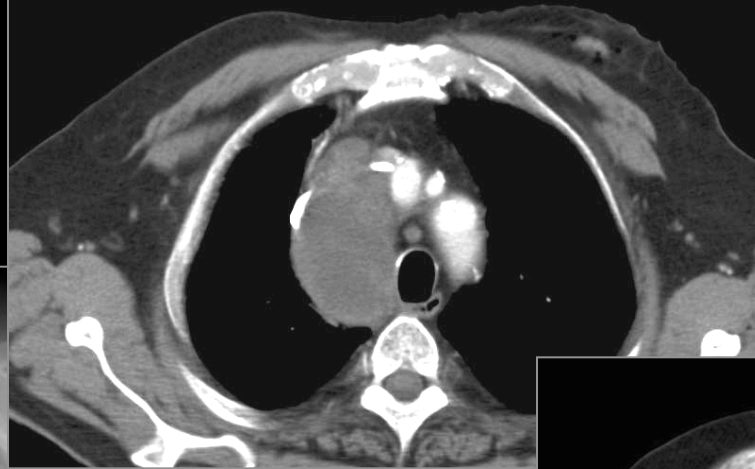
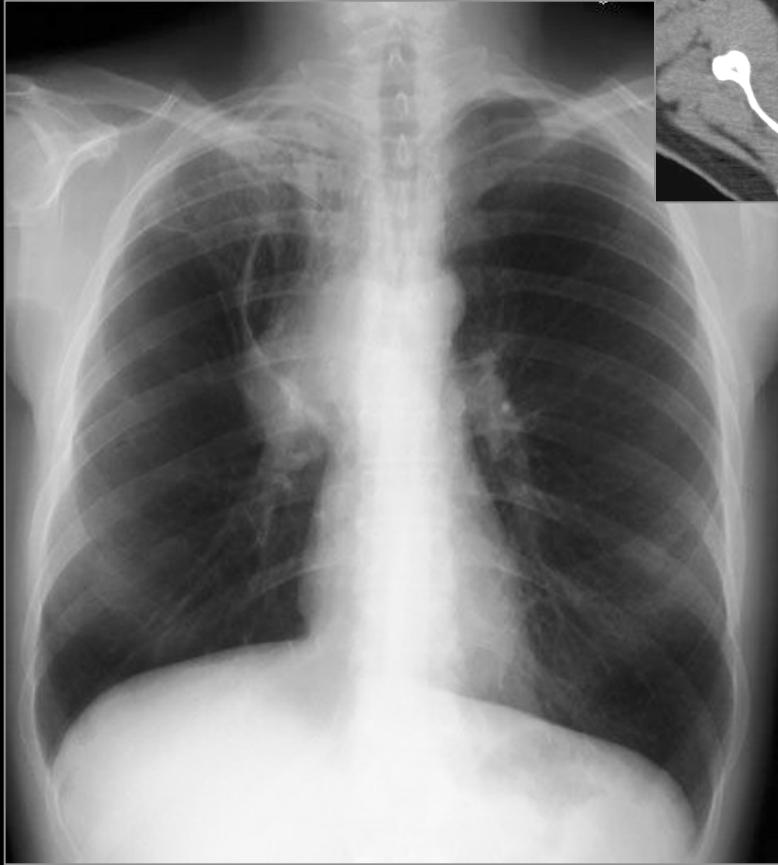


KYSTIQUES
(= ampullaires, sacciformes)

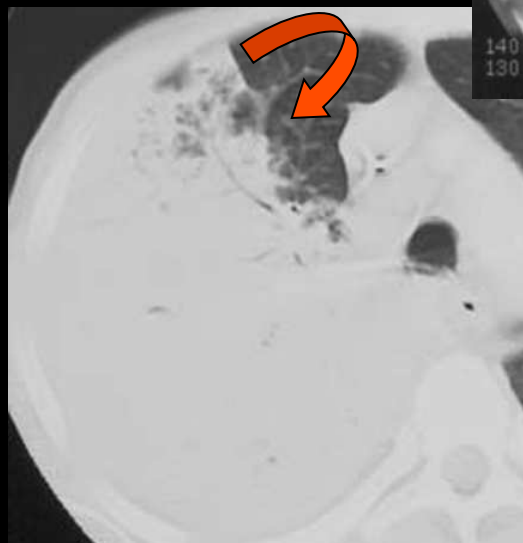
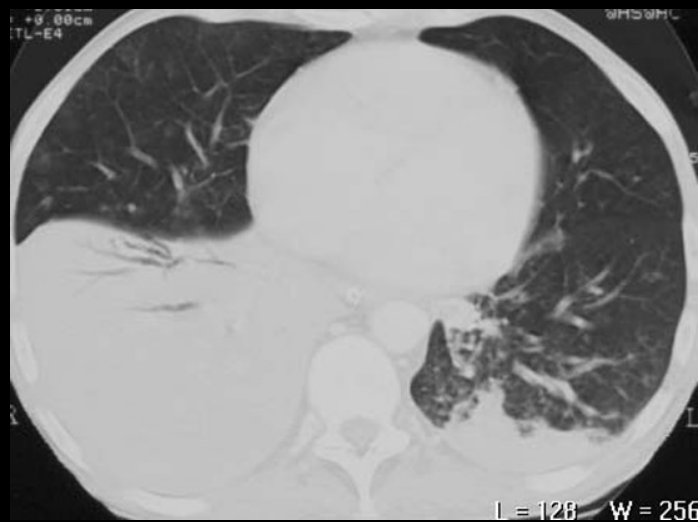
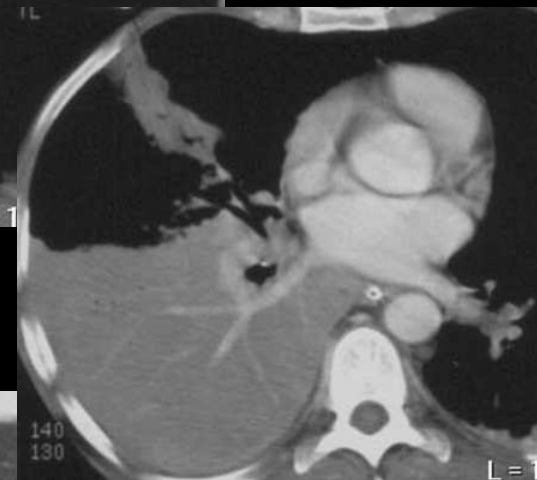
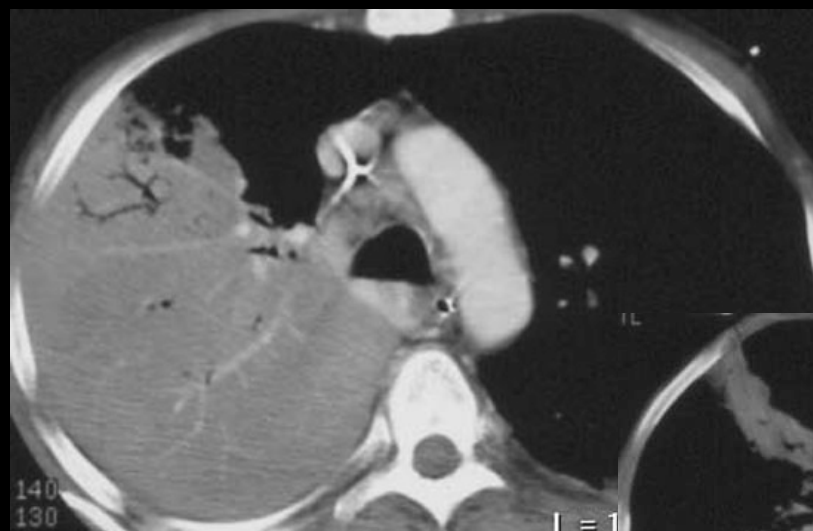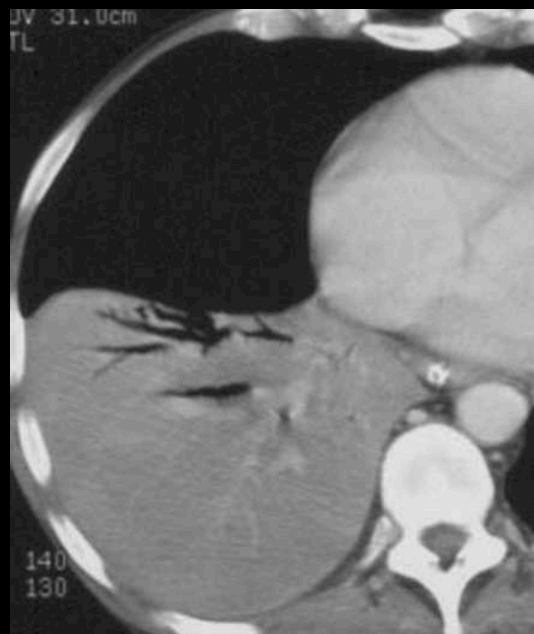VARIQUEUSES
(= moniliformes, en grappe)

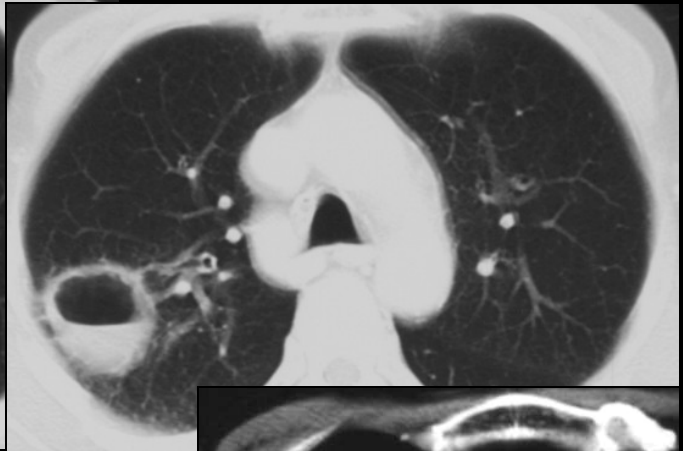
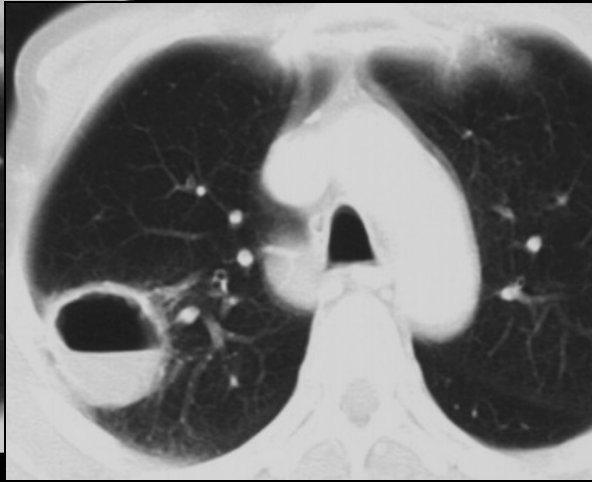
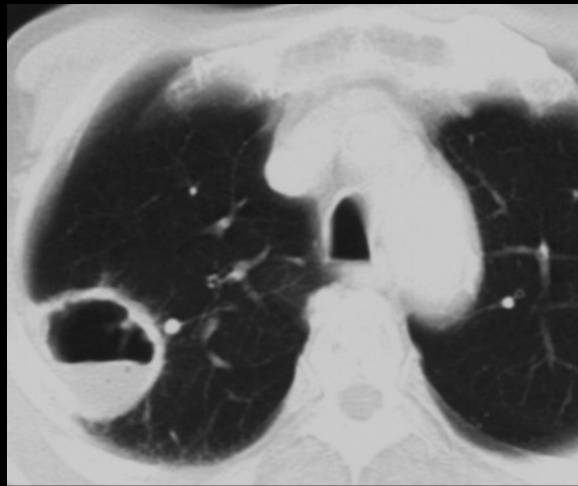


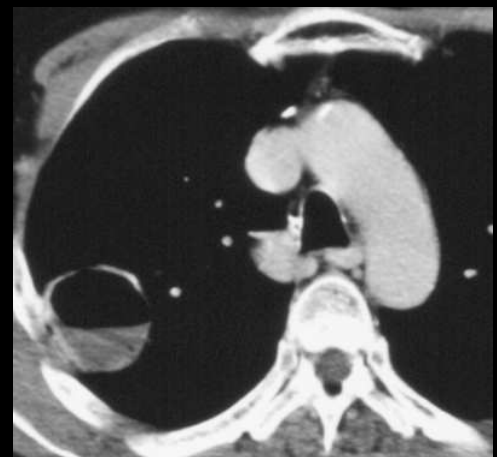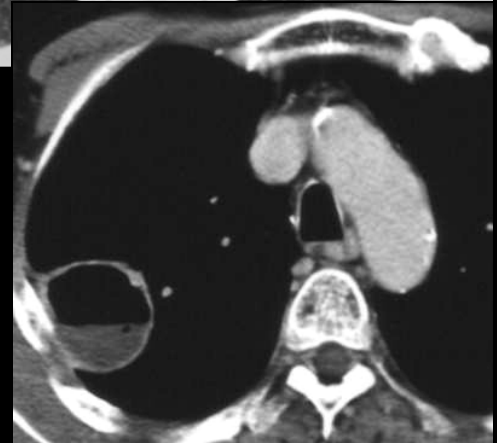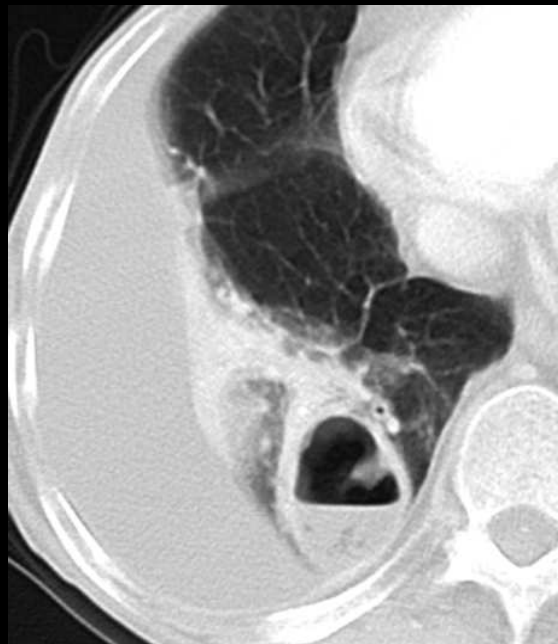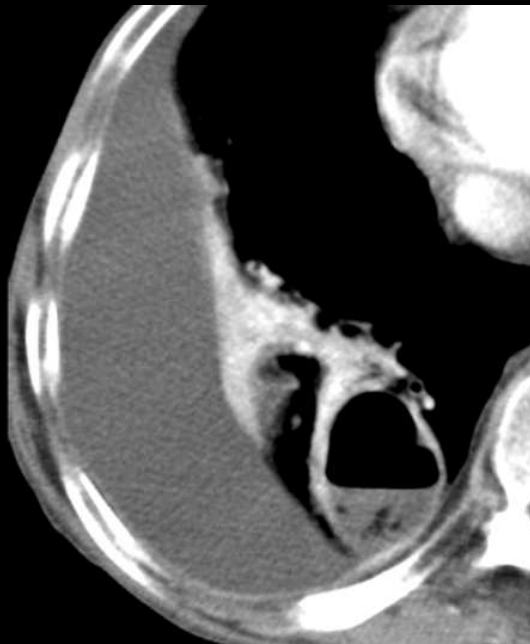Scissure azygos et carcinome à petites cellules

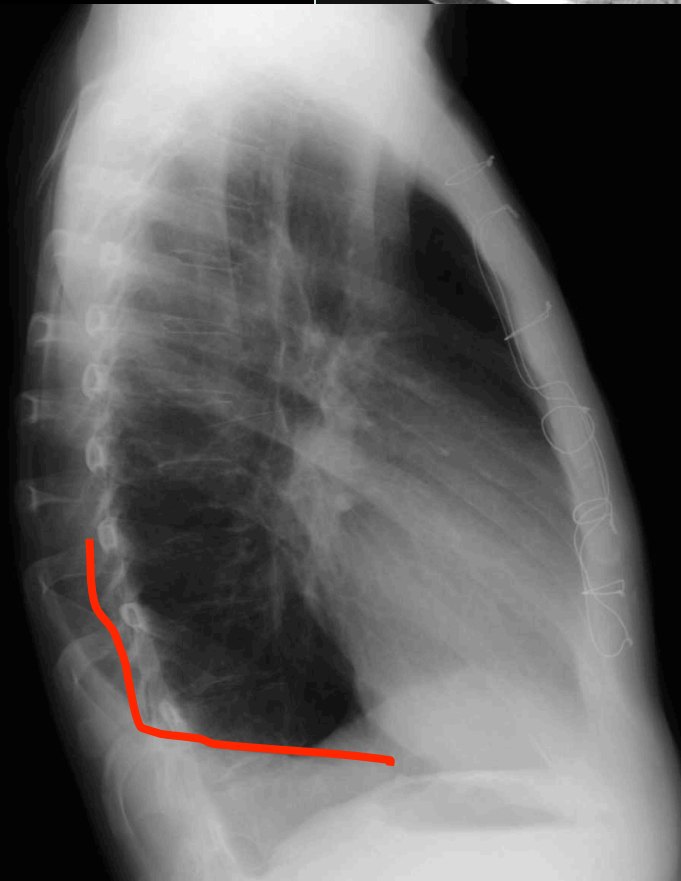
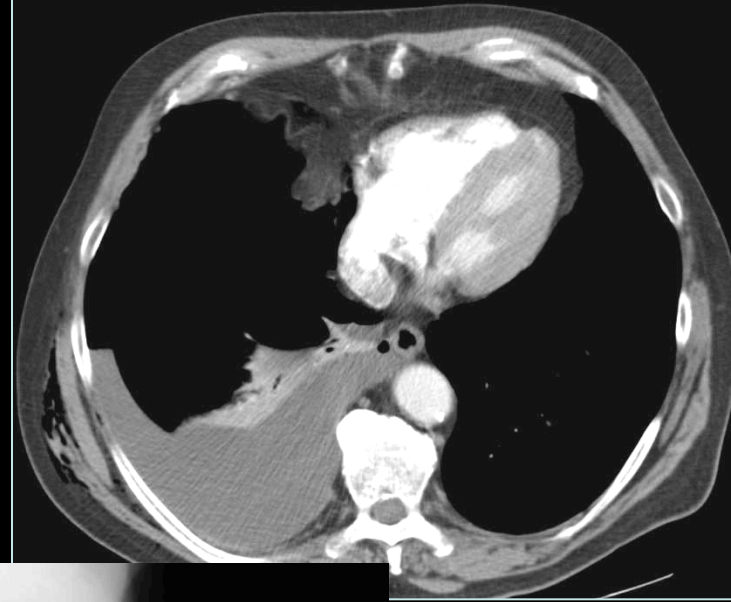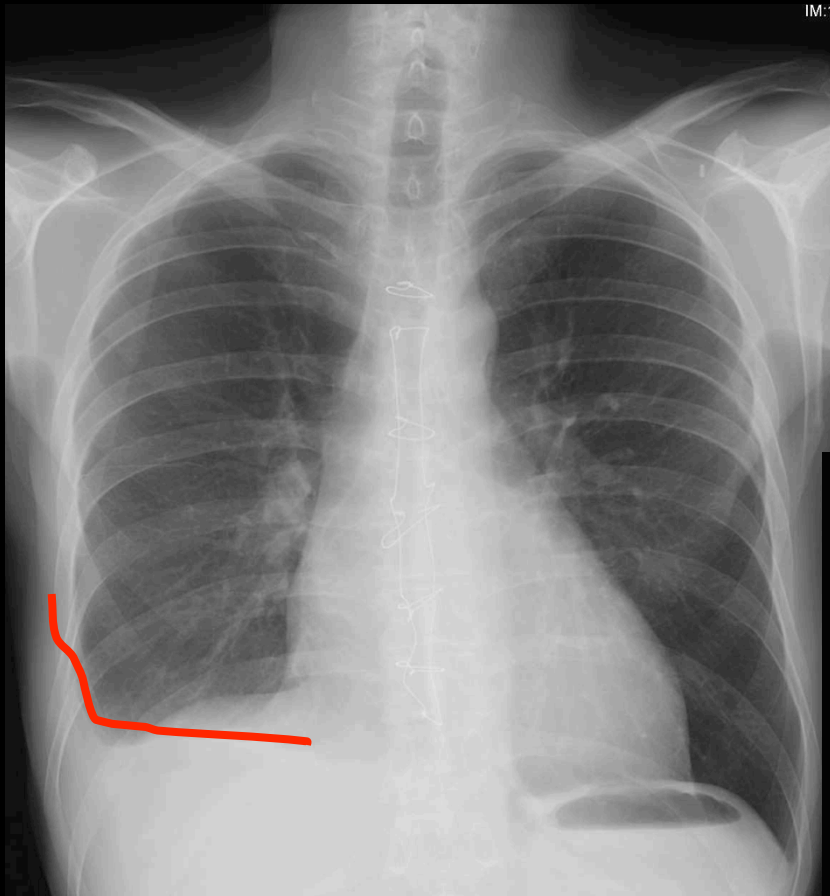


PFLA du lobe inférieur (hépatisation)

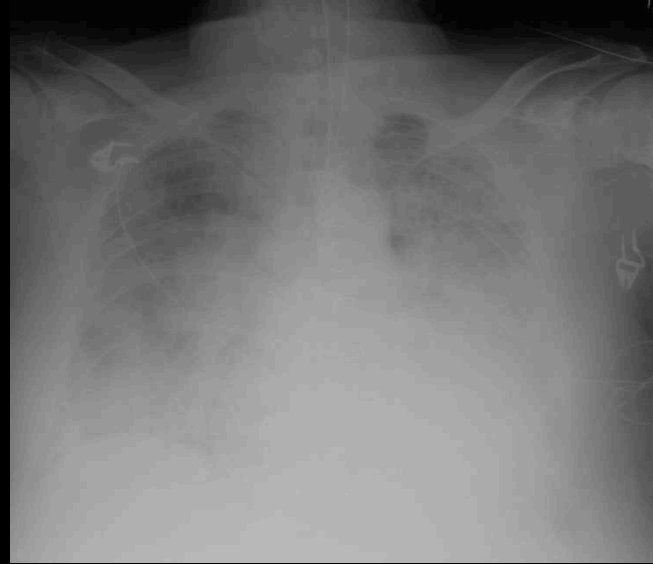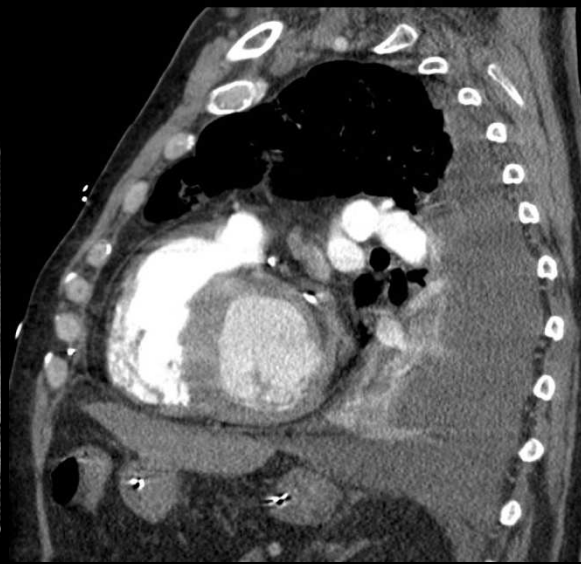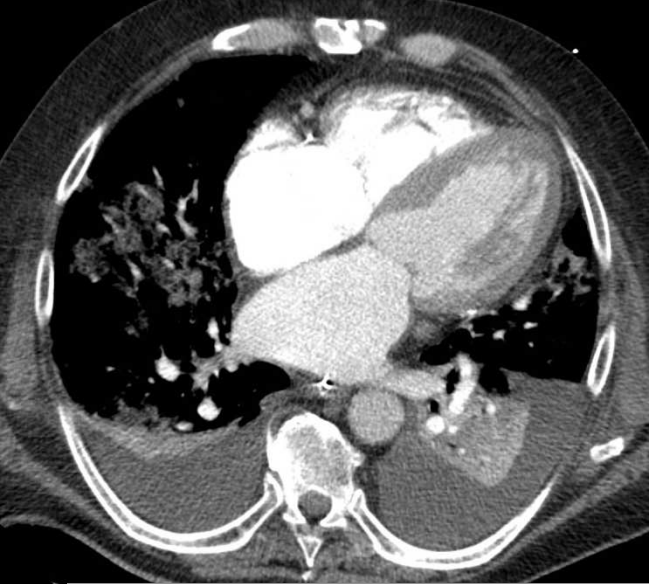


abcès du poumon

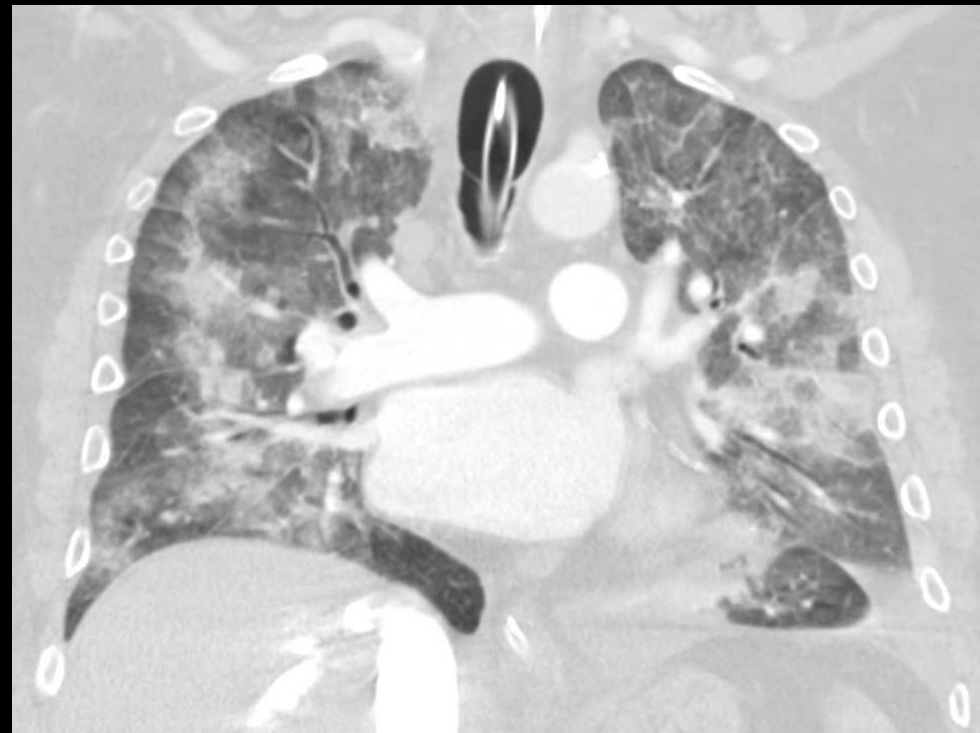
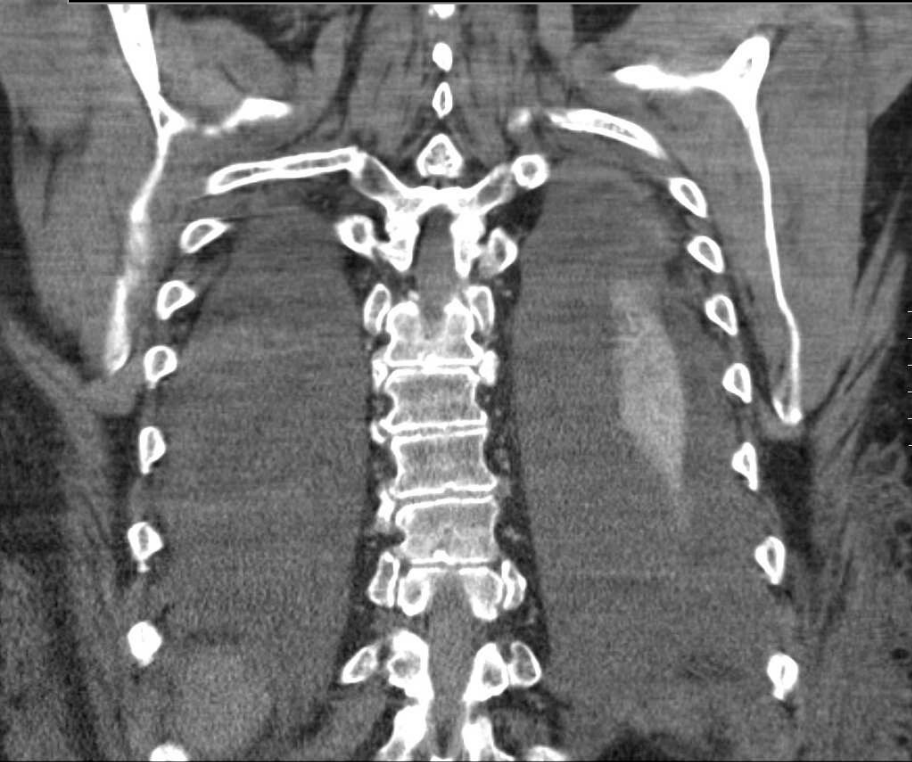


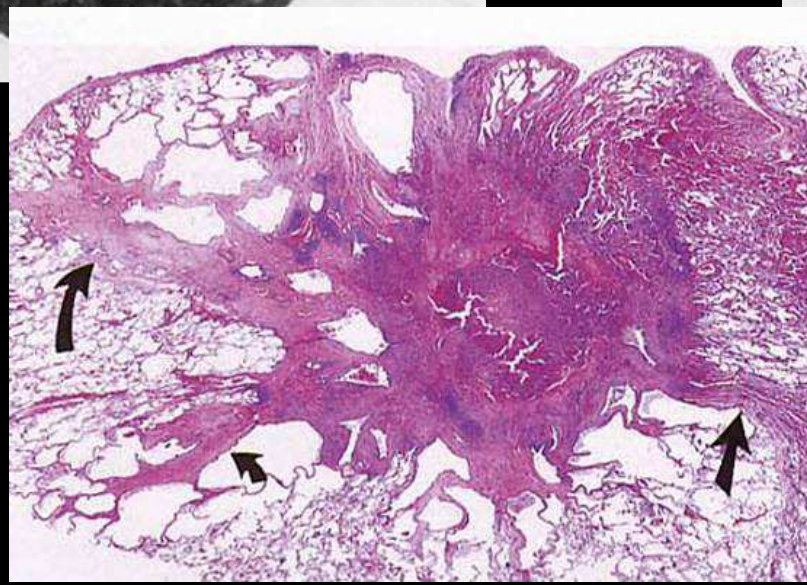
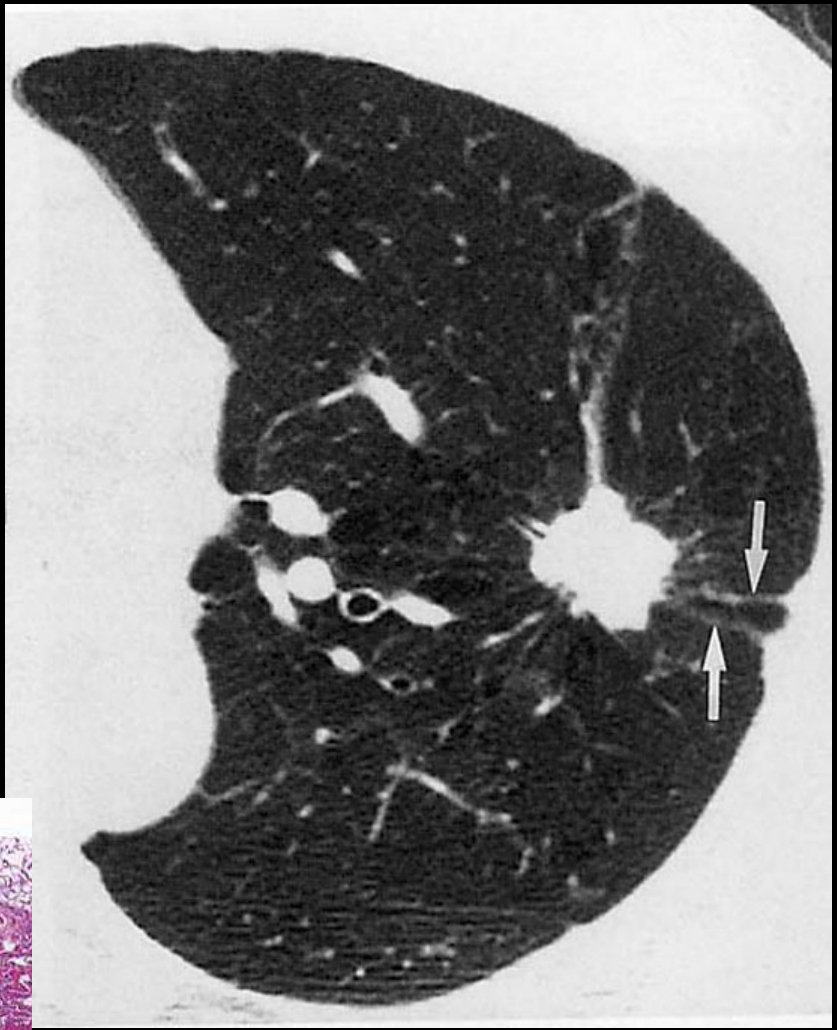
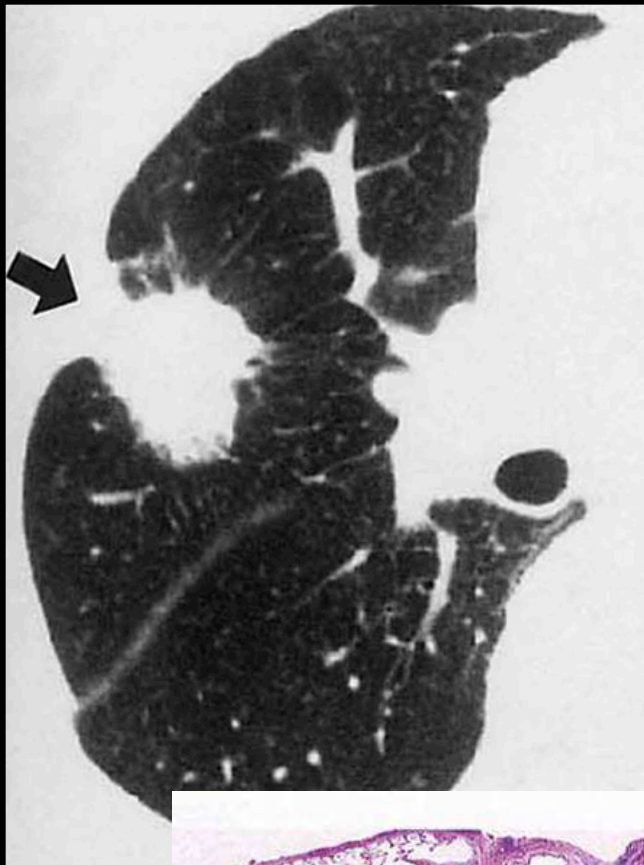
**Épanchement pleural
droit**



Pleurésie bilatérale décompensation cardiaque

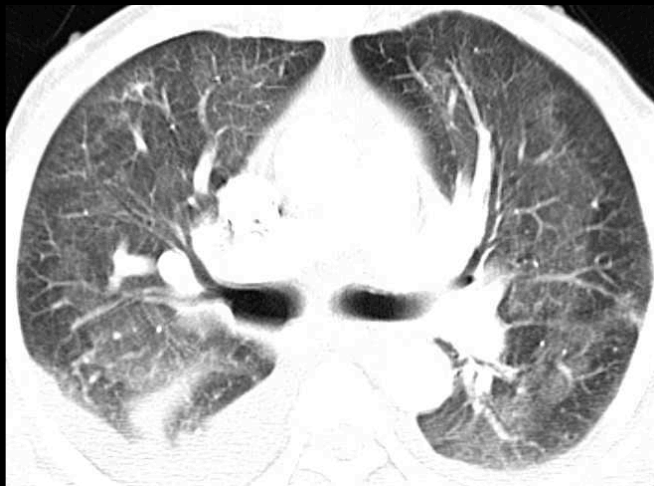



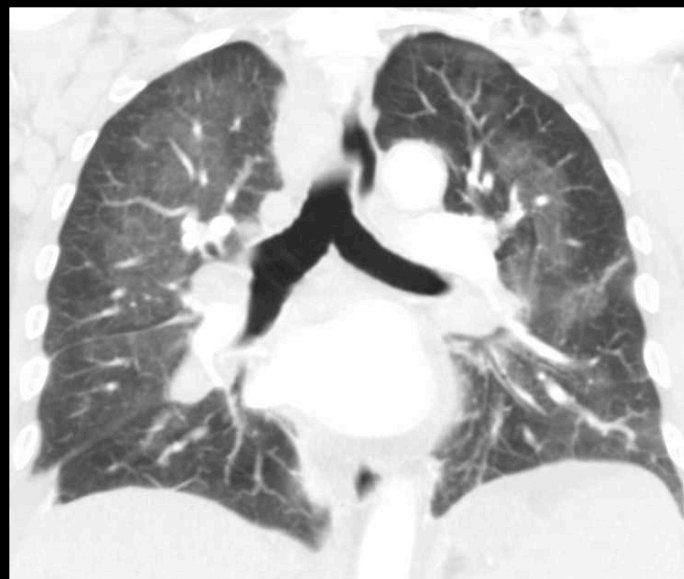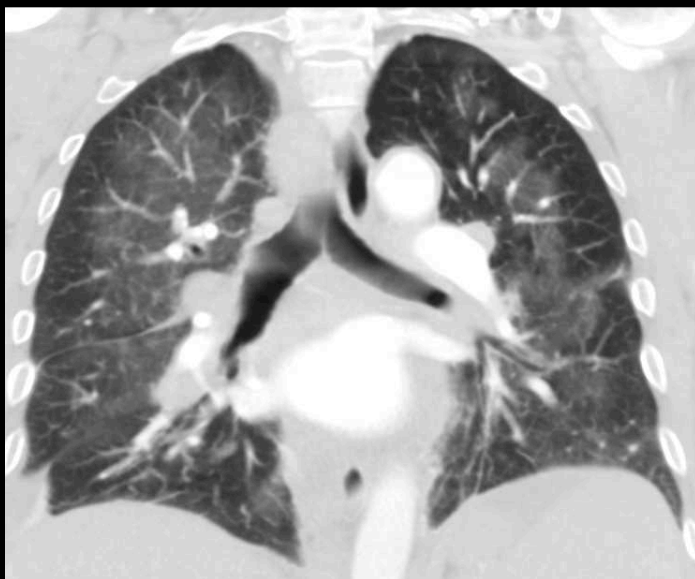**adénocarcinomes
infiltration et rétraction de
la plèvre**

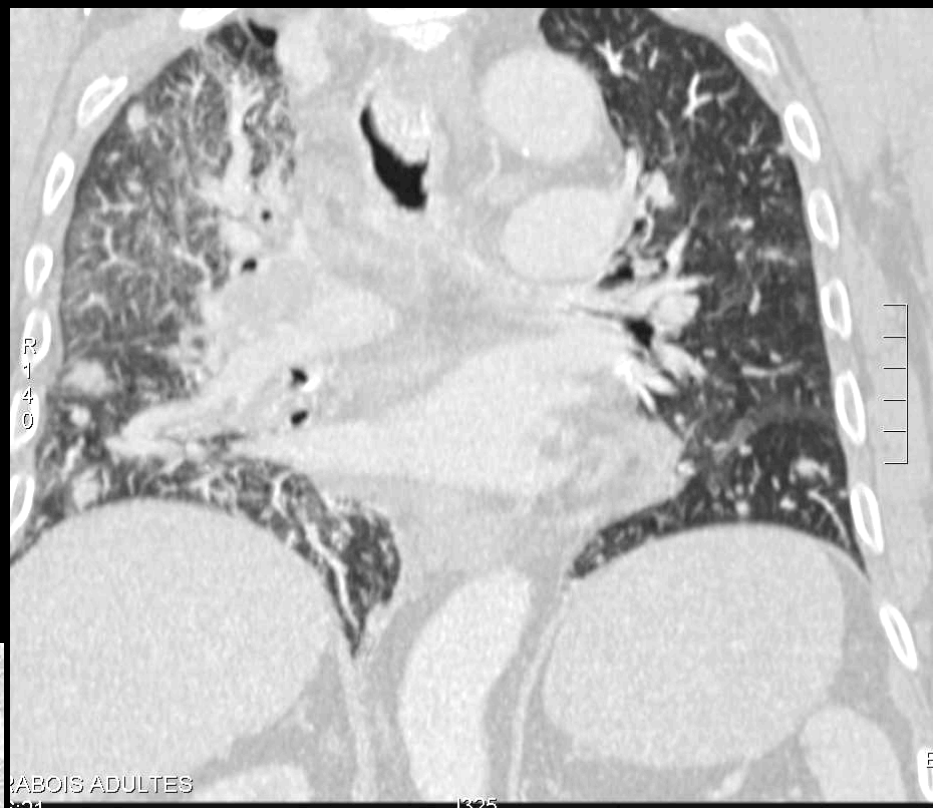
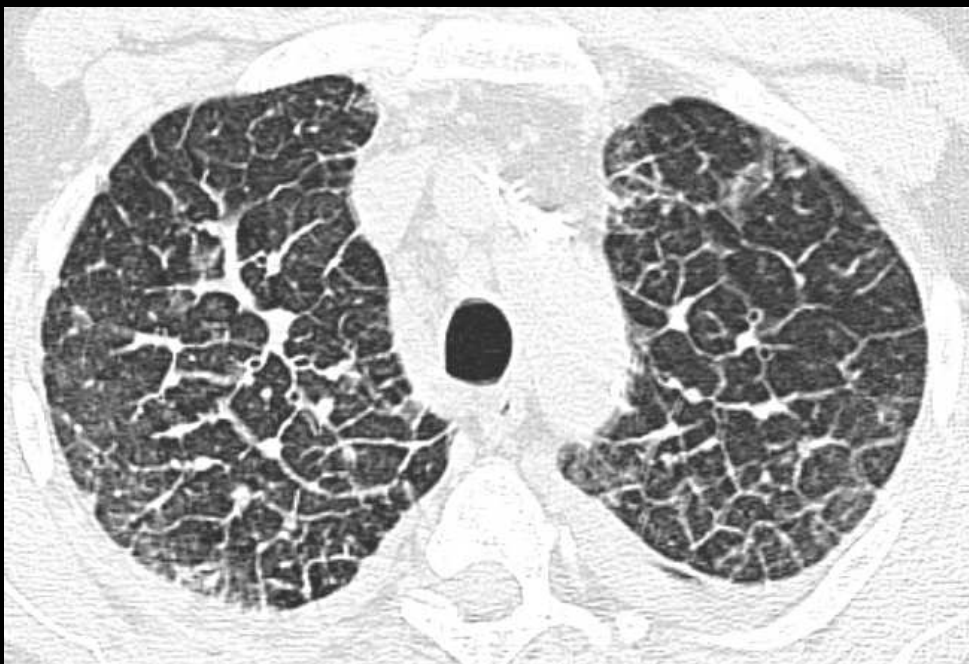
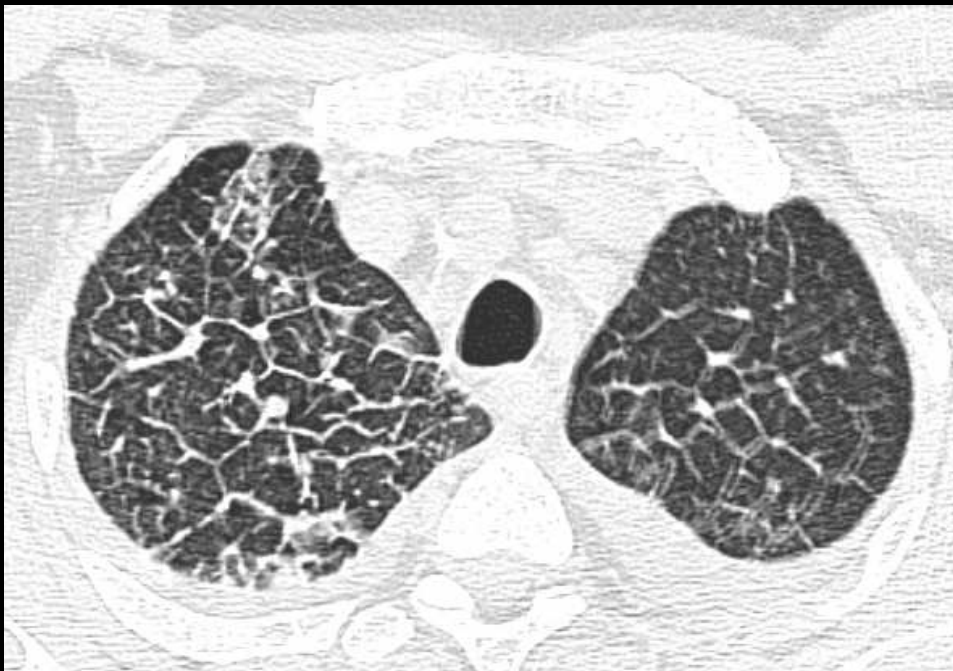

Atteinte parenchymateuse interstitielle...

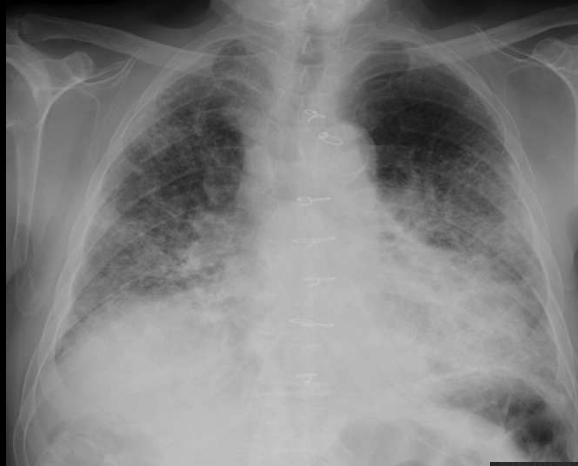

stade précoce aspect de surcharge en verre dépoli interstitielle péri hilare bilatérale

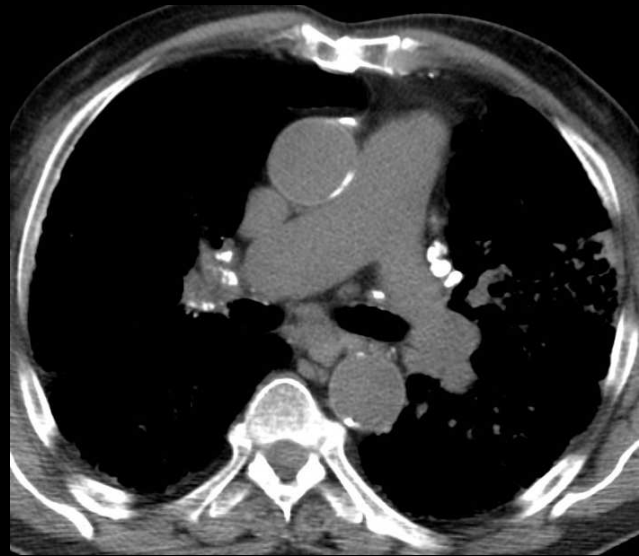
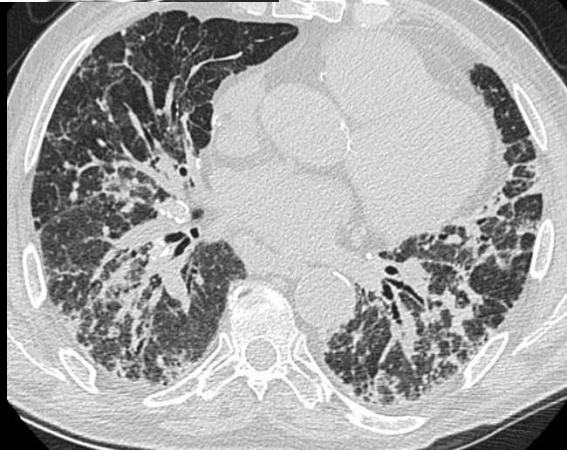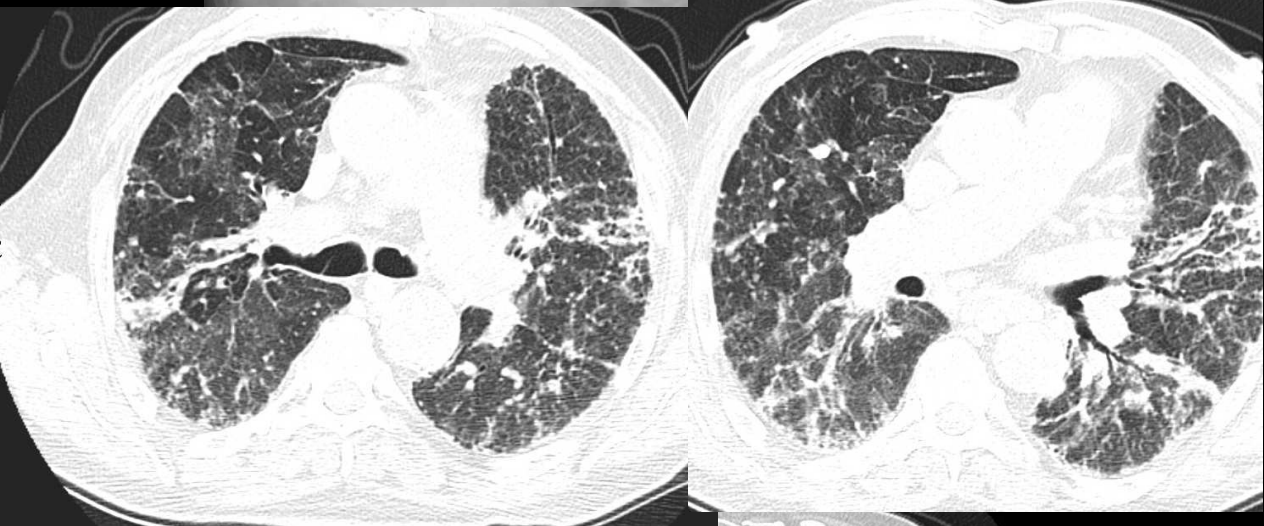
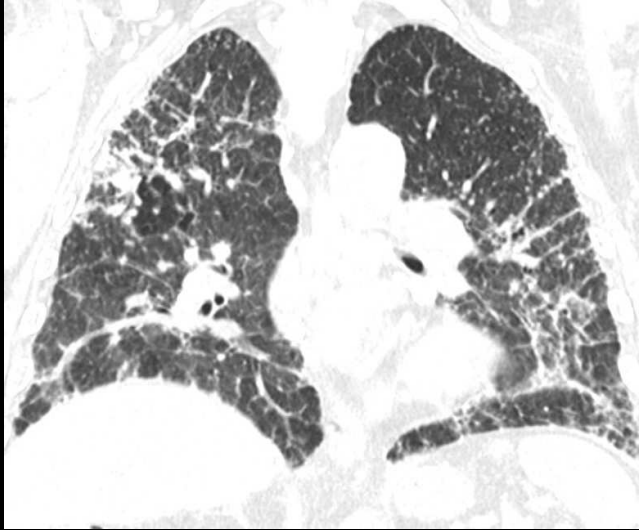




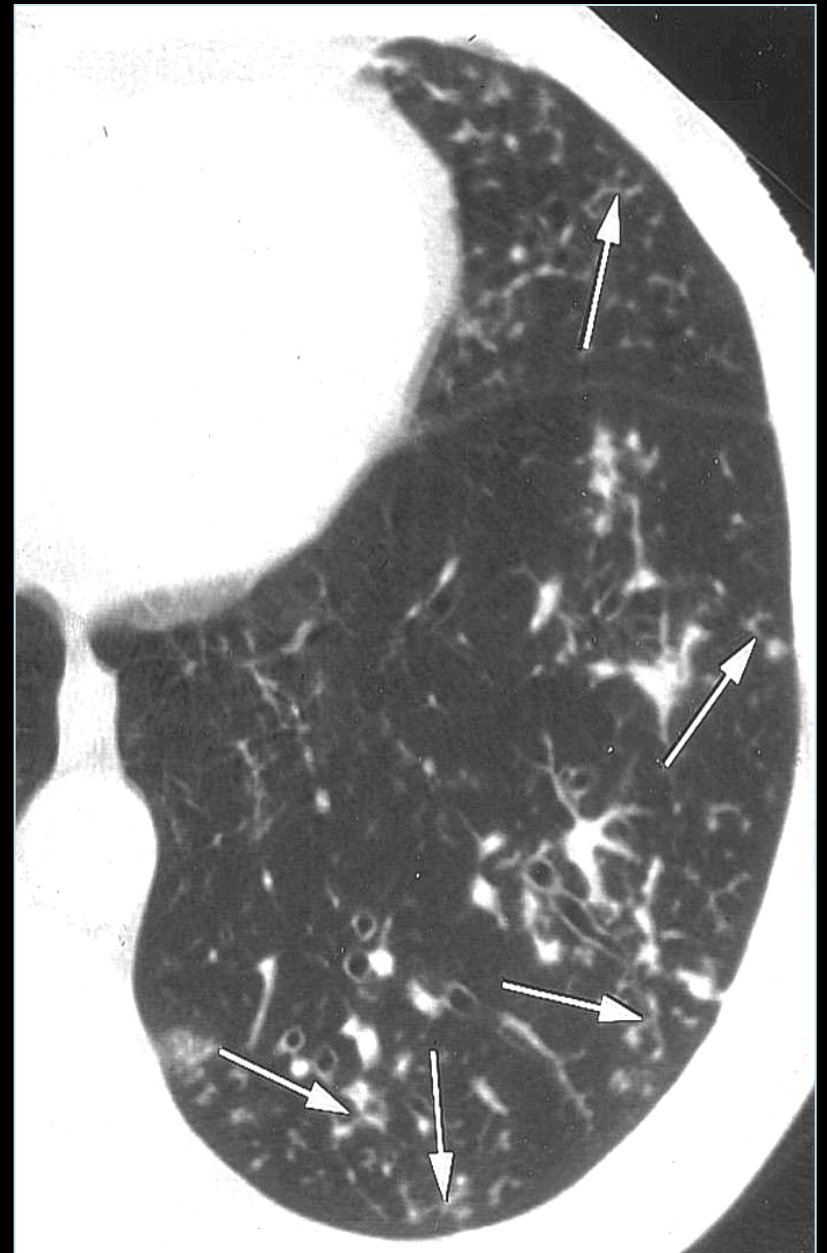
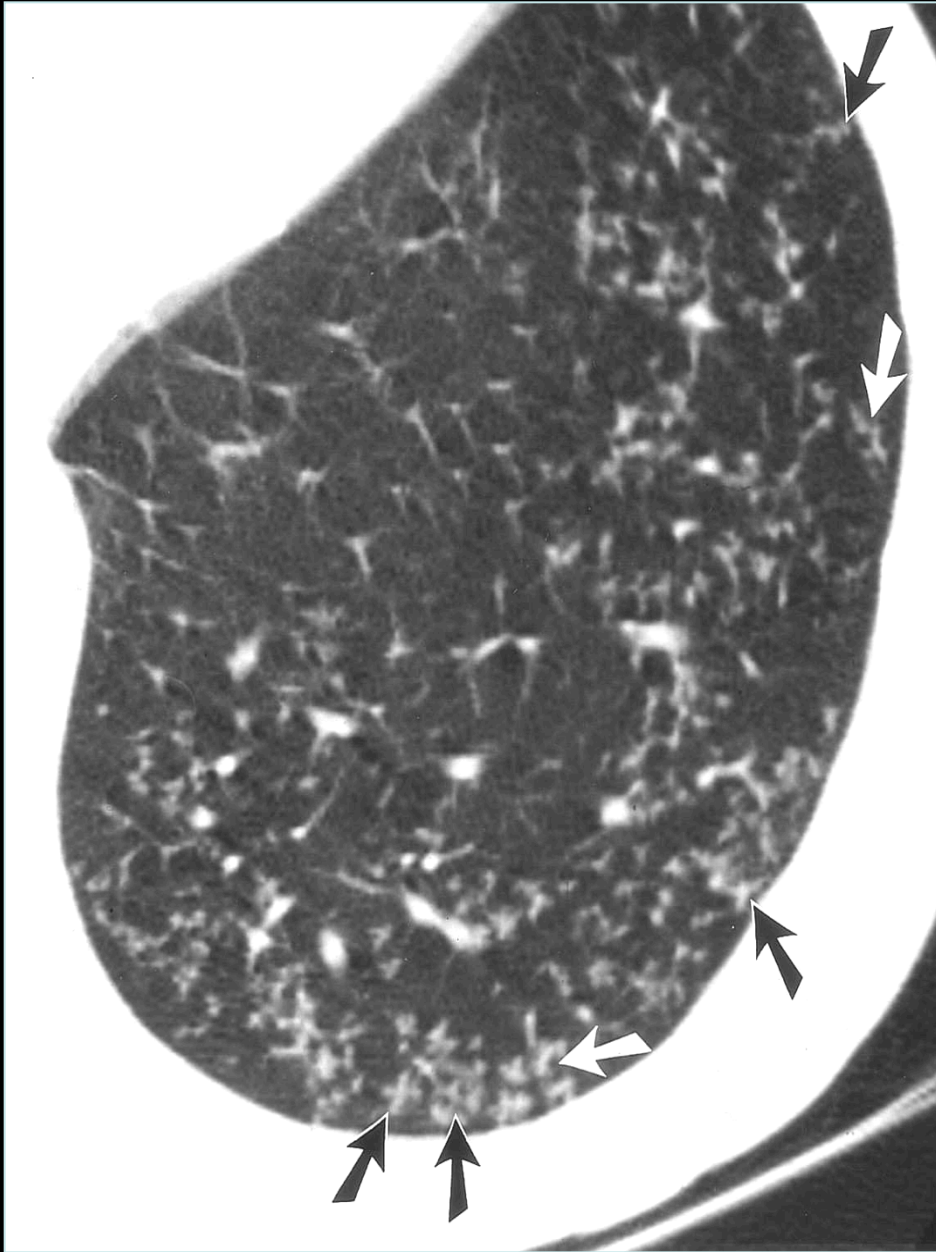
**Épaississements des
septas et
micronodules :
lymphangite**



silicose

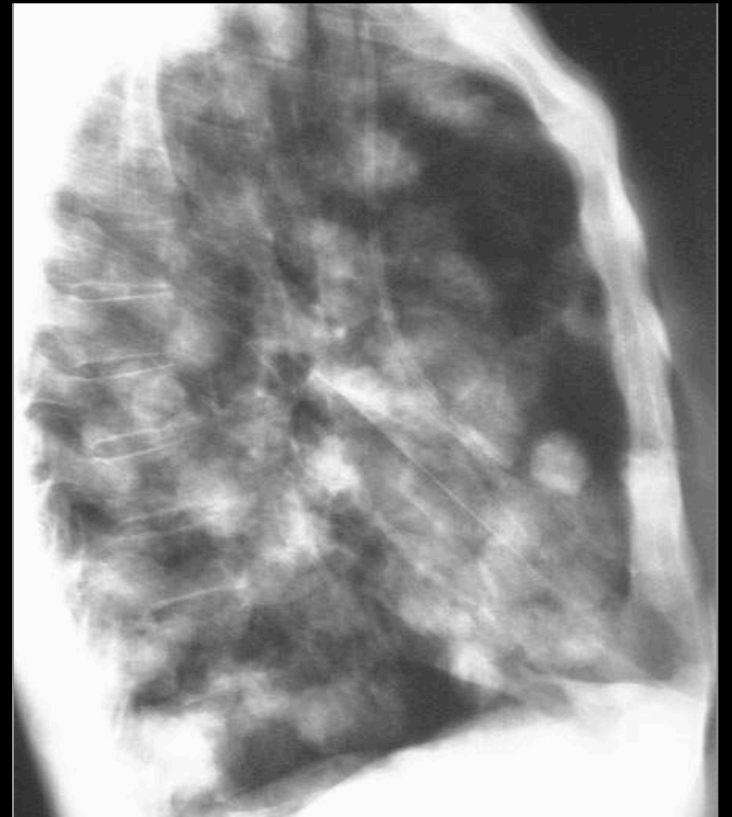
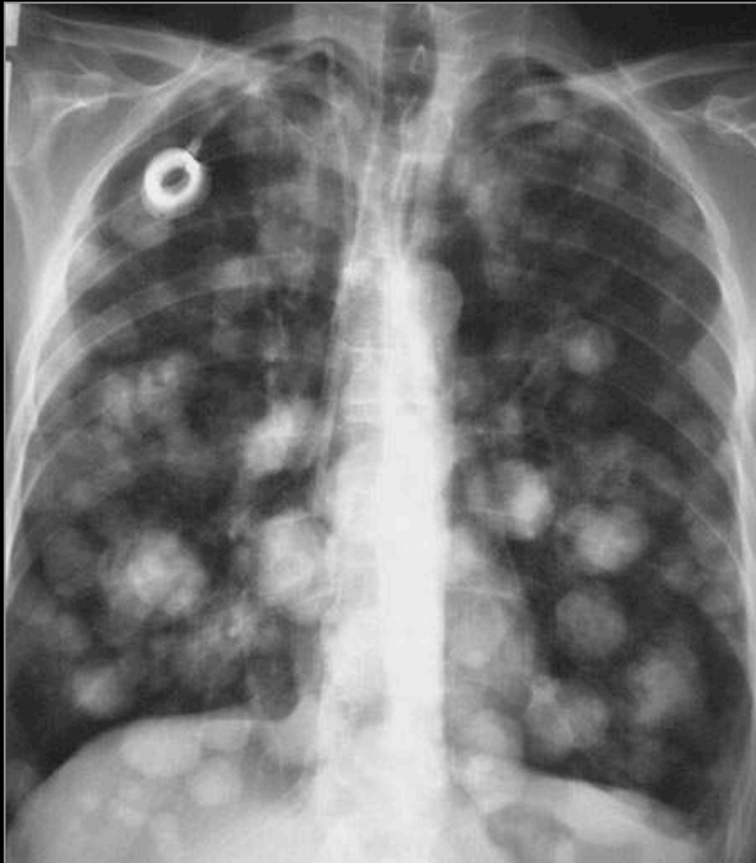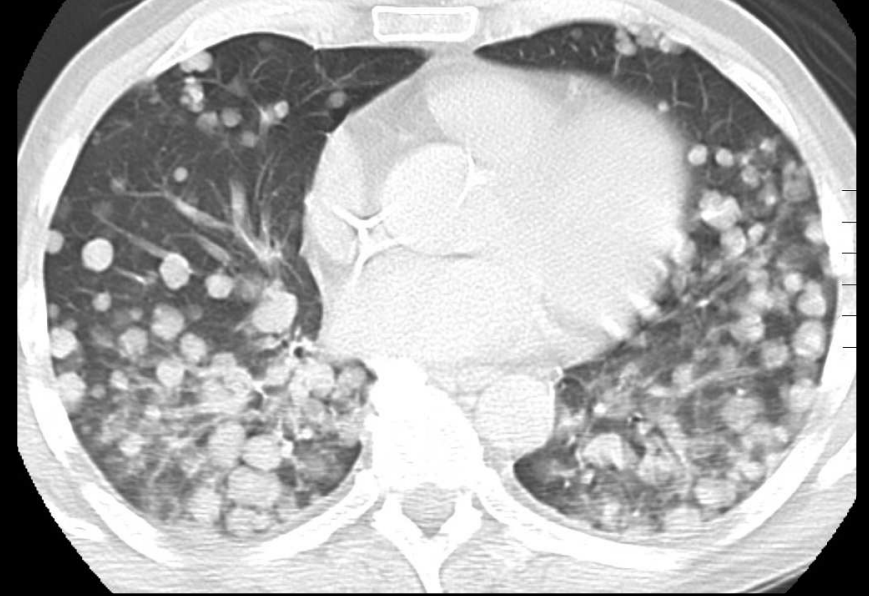


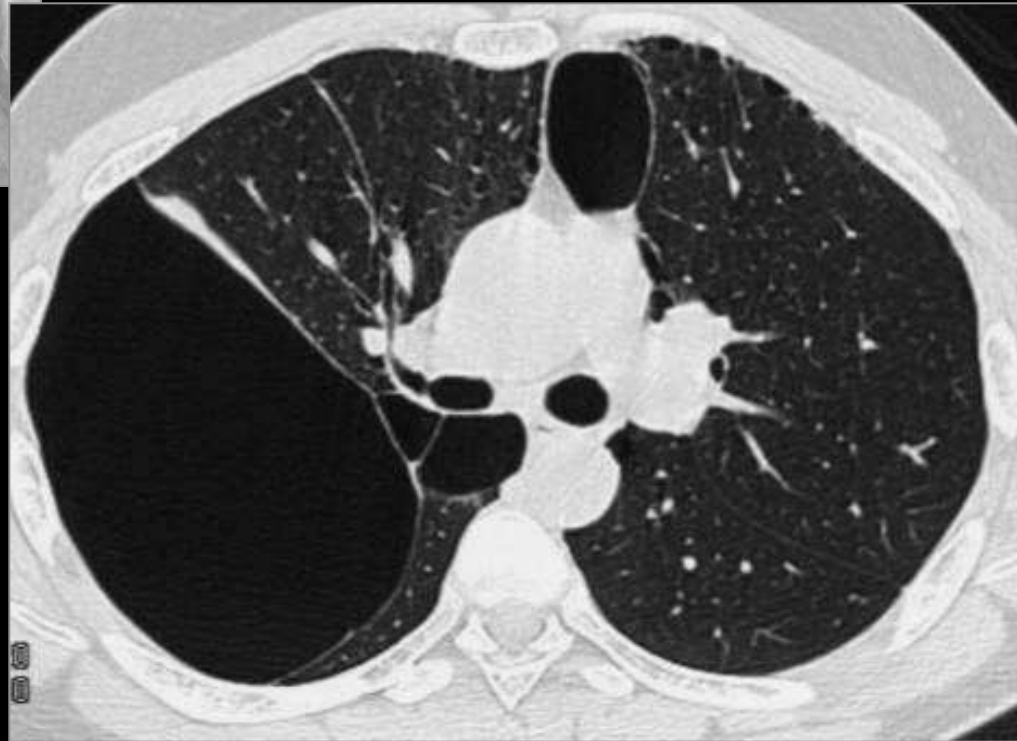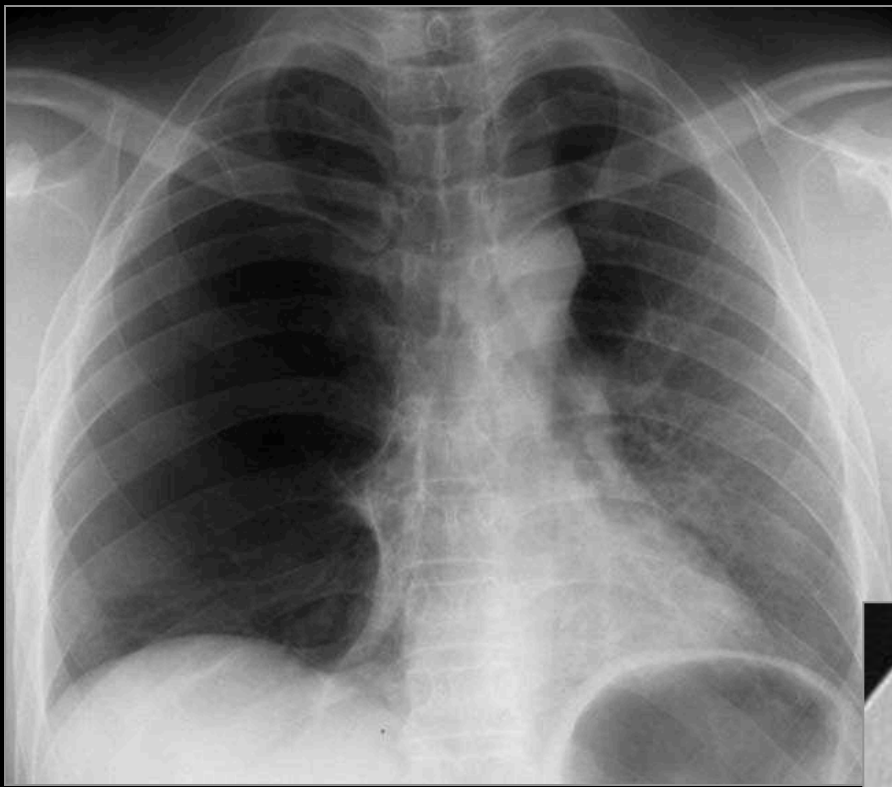
Bronchiolite bactérienne



Opacités macro nodulaires

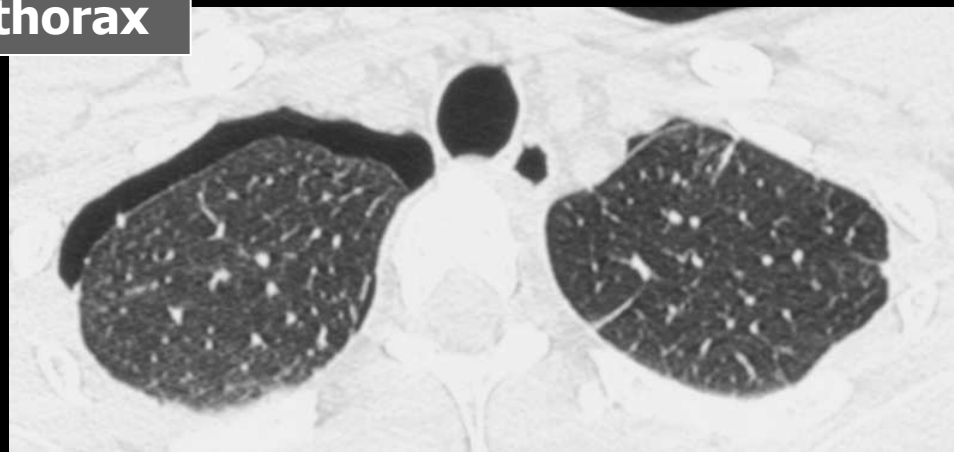
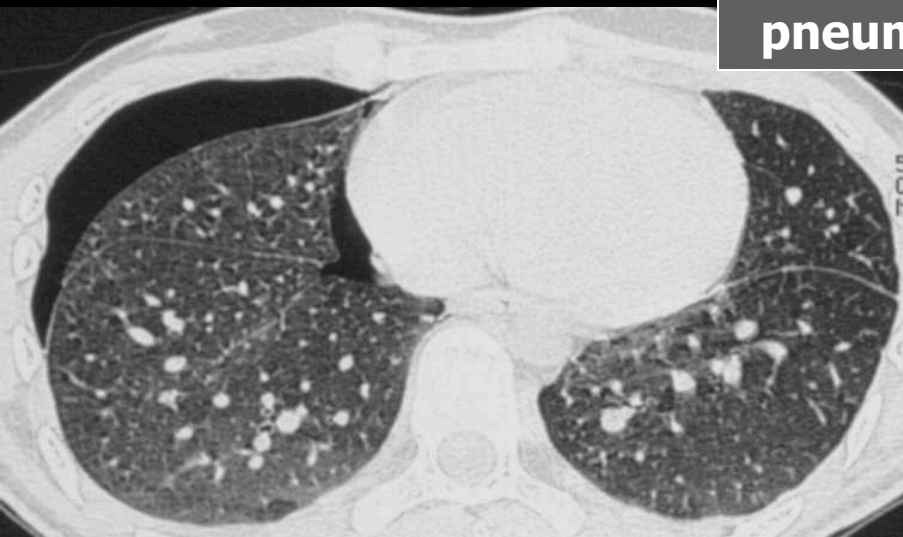
Lâcher de ballon
Métastases pulmonaires
Distribution hémotogènes



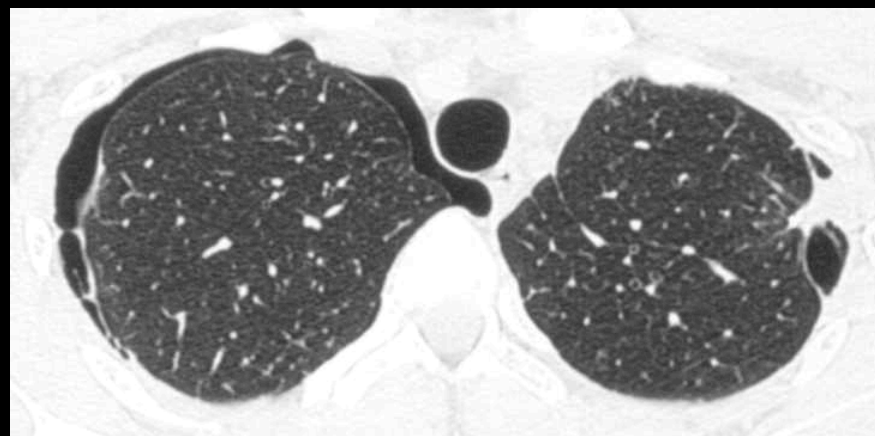
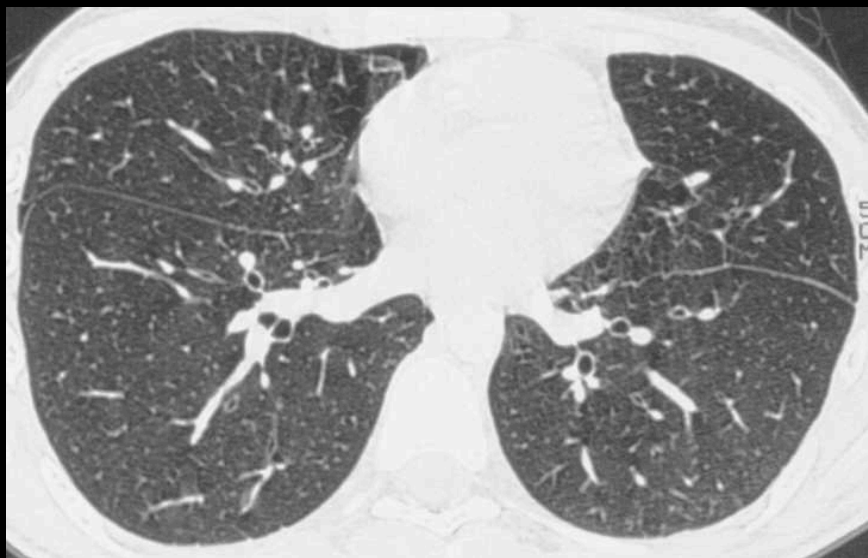

Hyperclartés
Bulles
d' emphysème

pneumothorax



coupes en expiration



coupes en inspiration

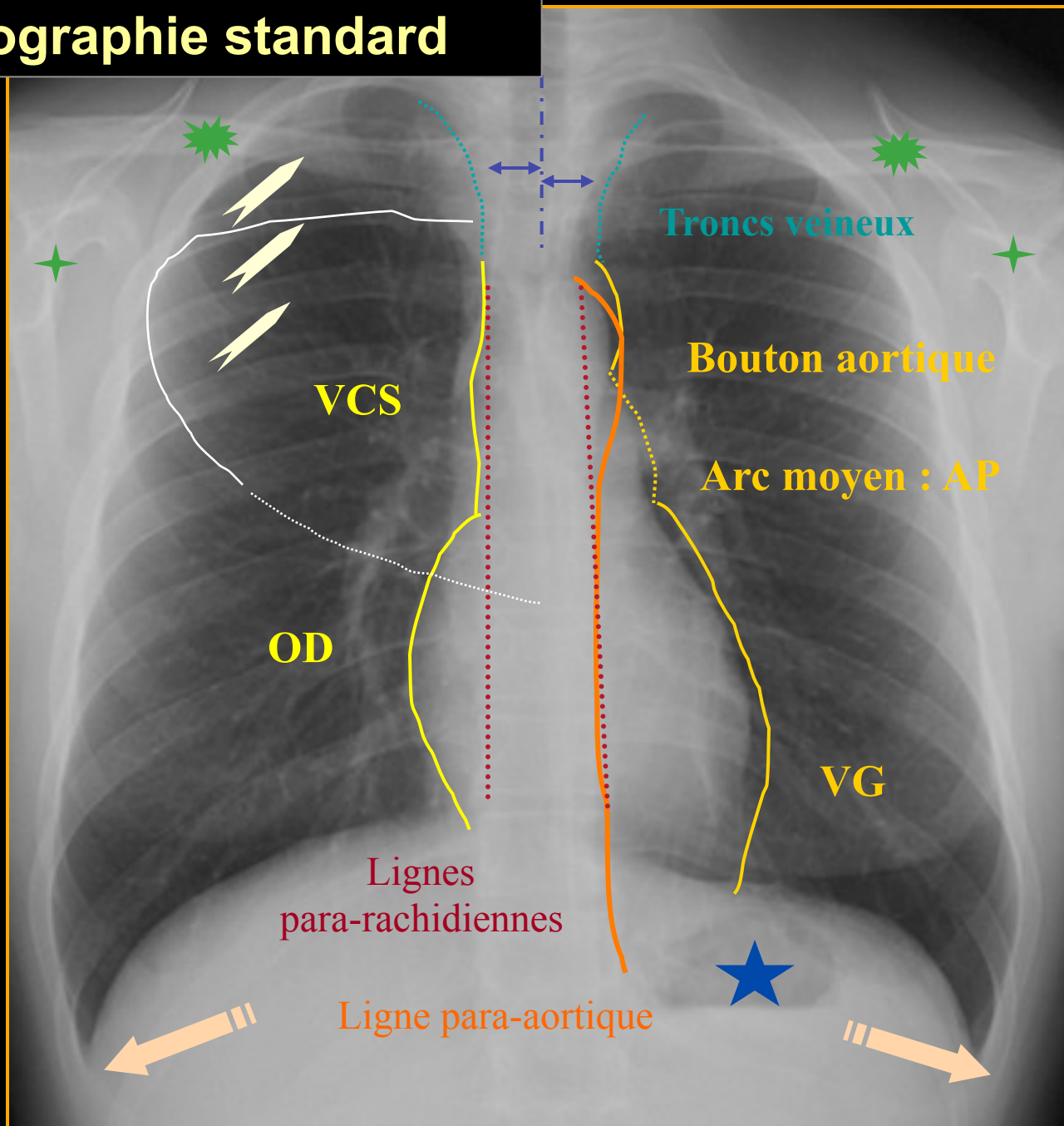


2/ RADIOANATOMIE DU MEDIASTIN

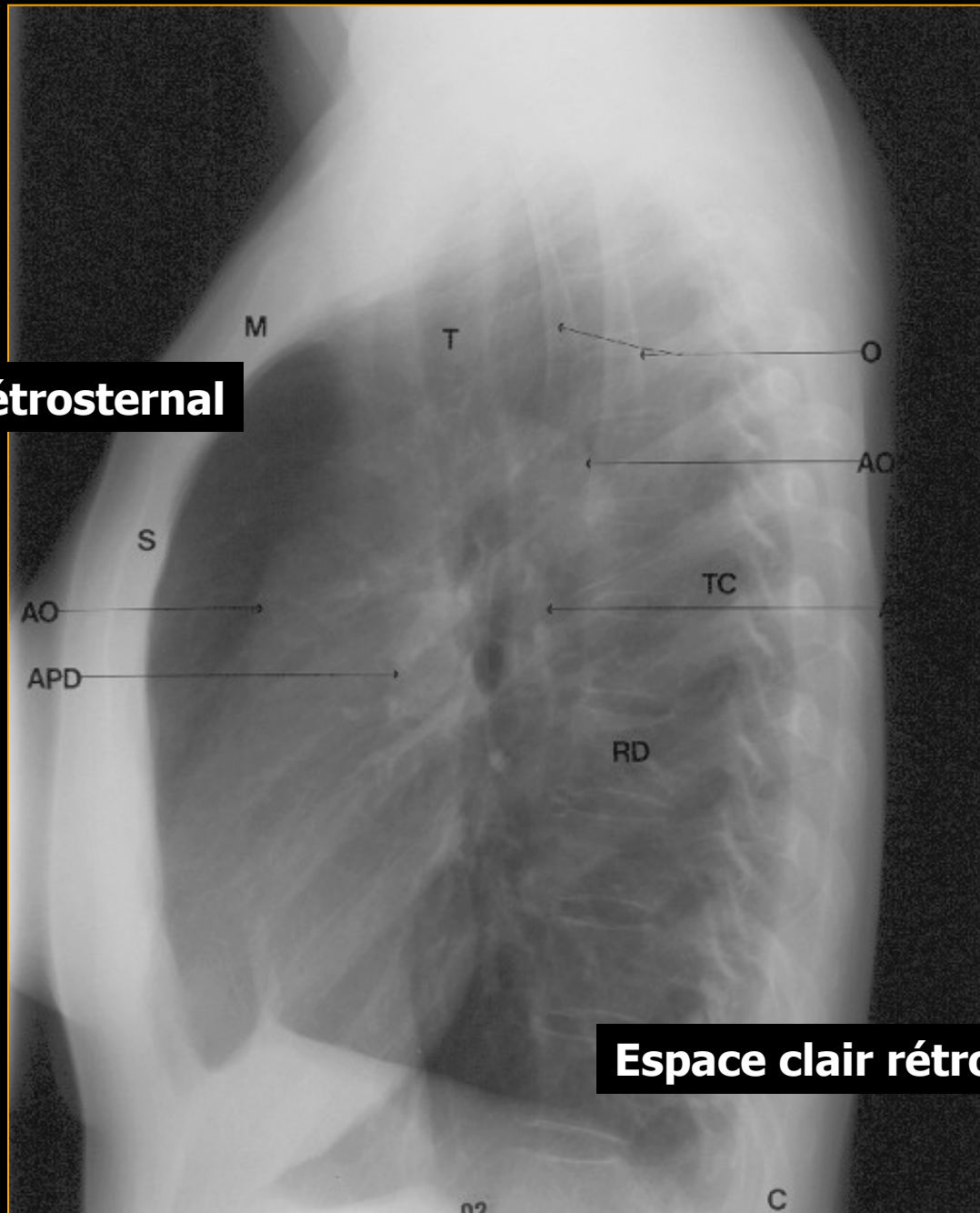
- **GENERALITES**
- **VAISSEAUX**
- **CŒUR**
- **ŒSOPHAGE**
- **CHAINES GANGLIONNAIRES**

Radiographie standard

DE FACE



Espace clair rétrosternal



Espace clair rétrocardiaque

Les 10 lignes du médiastin

RadioGraphics

The journal of continuing medical education in radiology

[HOME](#) | [CURRENT ISSUE](#) | [PAST ISSUES](#) | [COLLECTIONS](#) | [COVER GALLERY](#) | [RADIOLOGY](#)

Lines and Stripes: Where Did They Go? —From Conventional Radiography to CT

Jerry M. Gibbs, MD, Chitra A. Chandrasekhar, MBBS,
Emma C. Ferguson, MD and Sandra A. A. Oldham, MD

+ Author Affiliations

Address correspondence to

J.M.G. (e-mail: jerry.m.gibbs@uth.tmc.edu).

ABSTRACT

10

[« Previous | Next Article »](#)
[Table of Contents](#)

This Article

doi:
10.1148/rg.271065073
January 2007 RadioGraphics,
27, 33-48.

Abstract **Free**

Figures Only

» **Full Text**

Full Text (PDF)

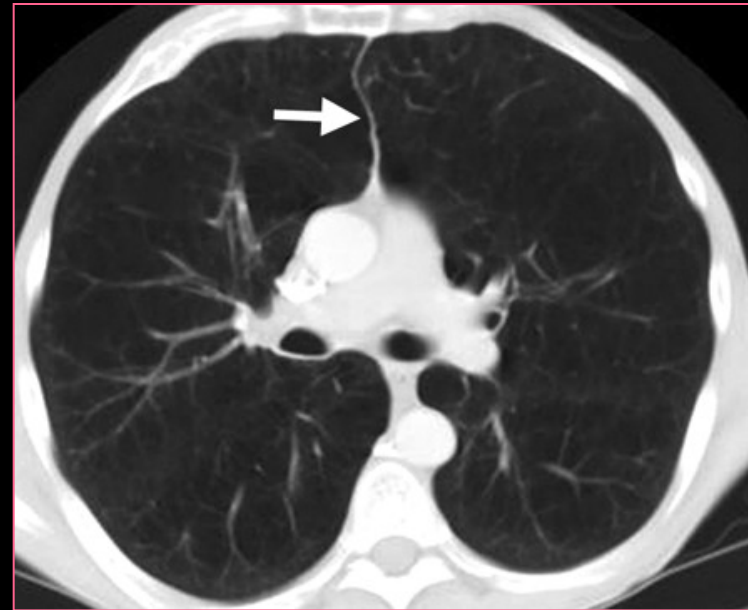
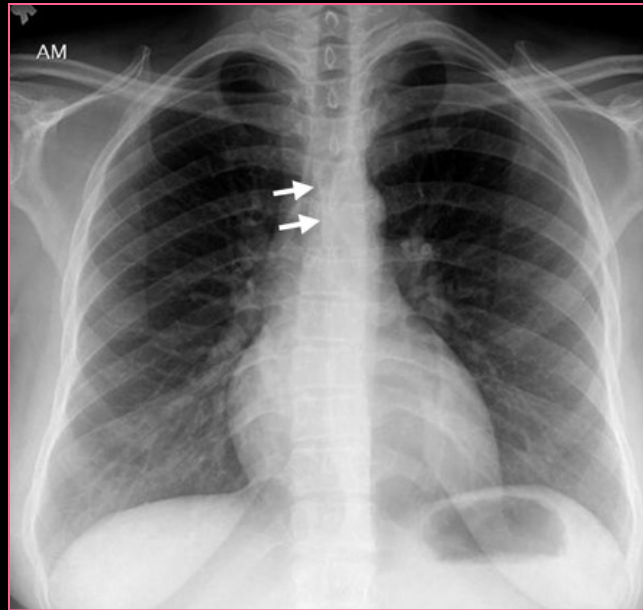
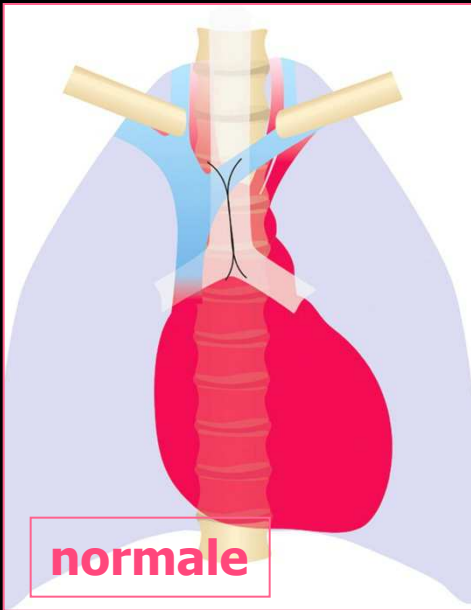
CME Test

- **Classifications**

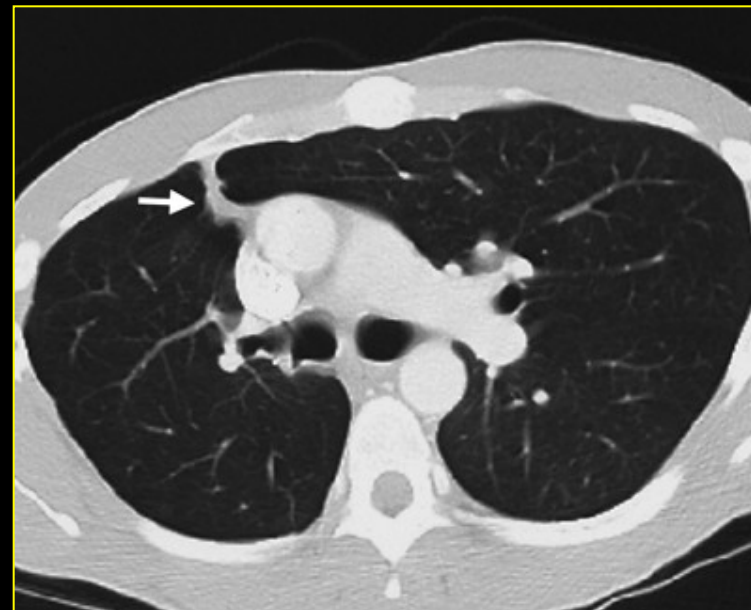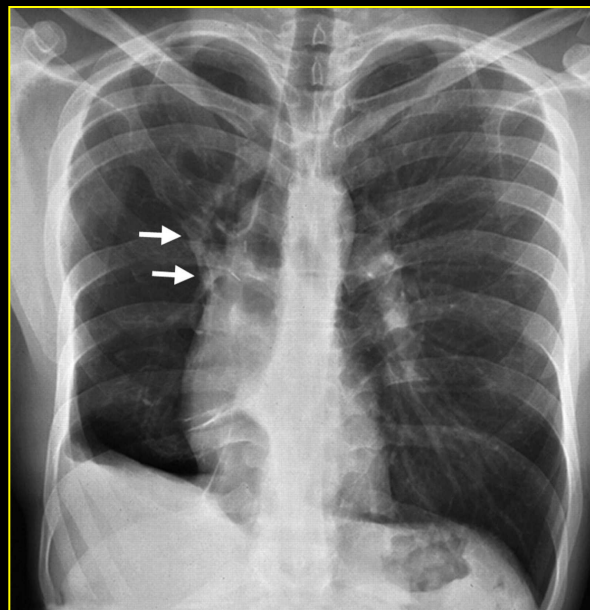
Series:

Continuing Medical
Education

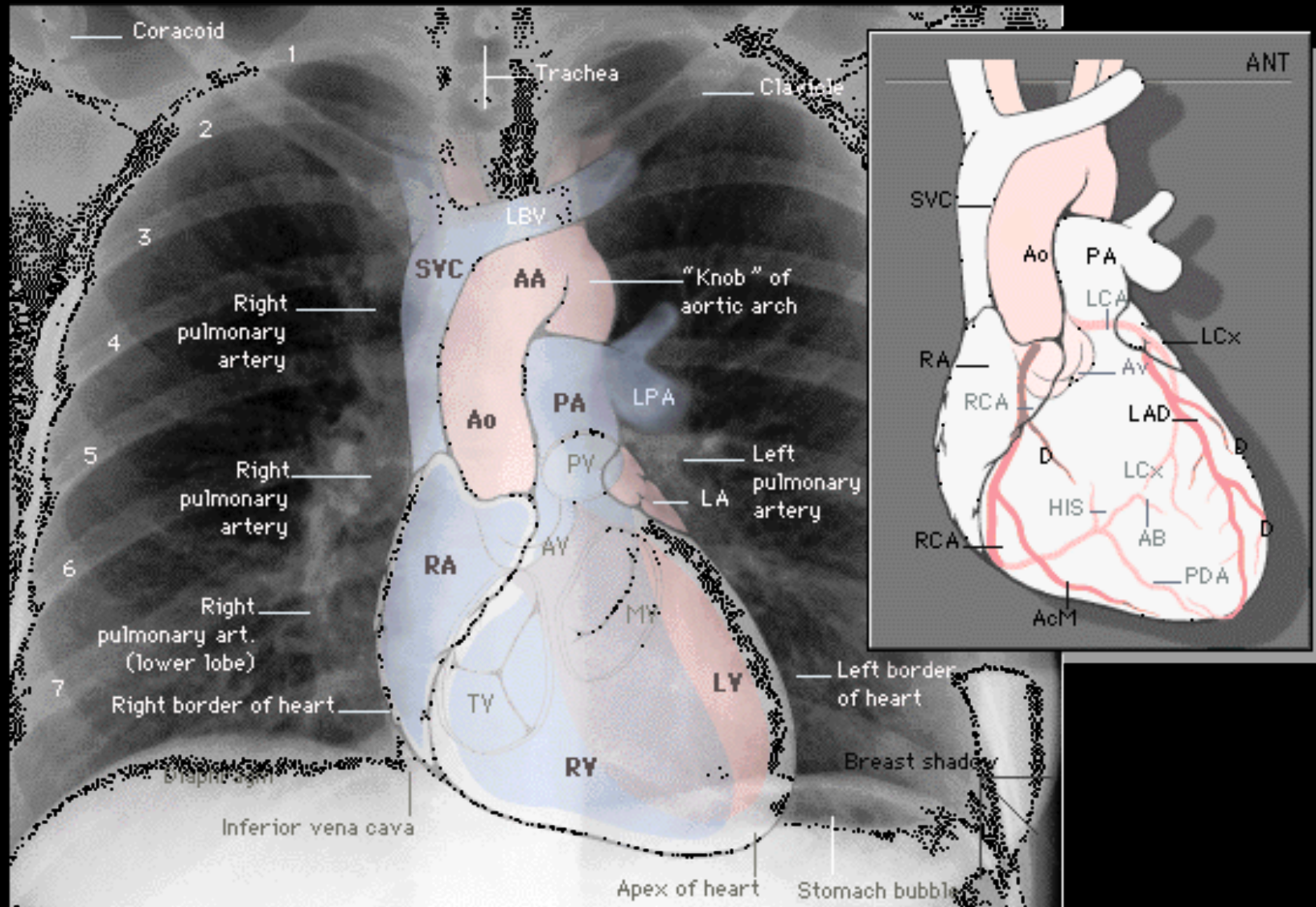
Ligne de jonction médiastinale antérieure



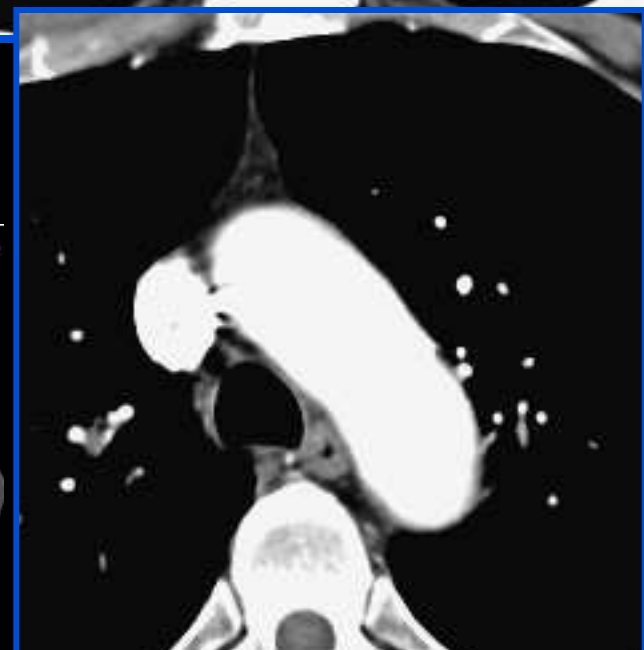
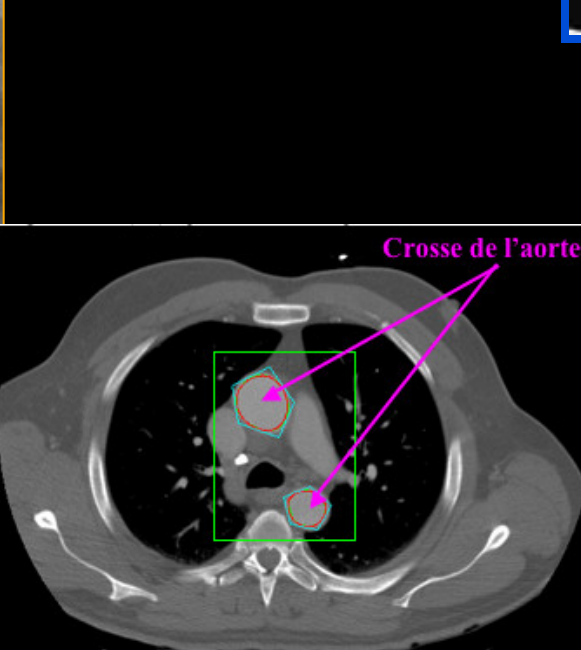
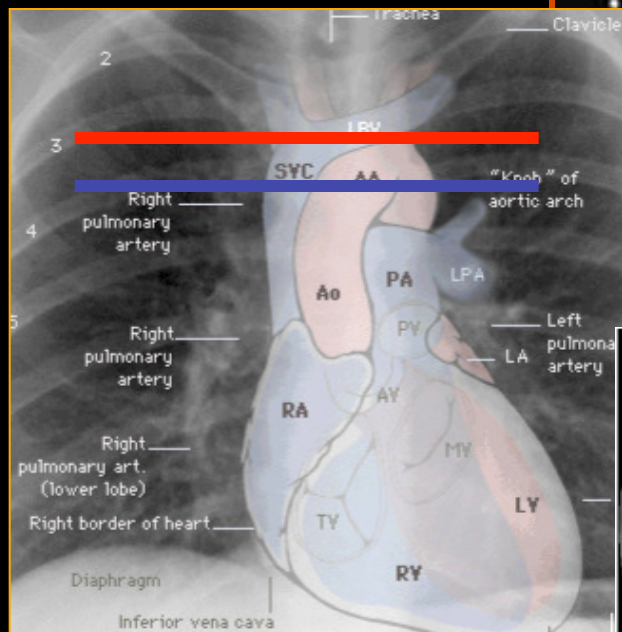
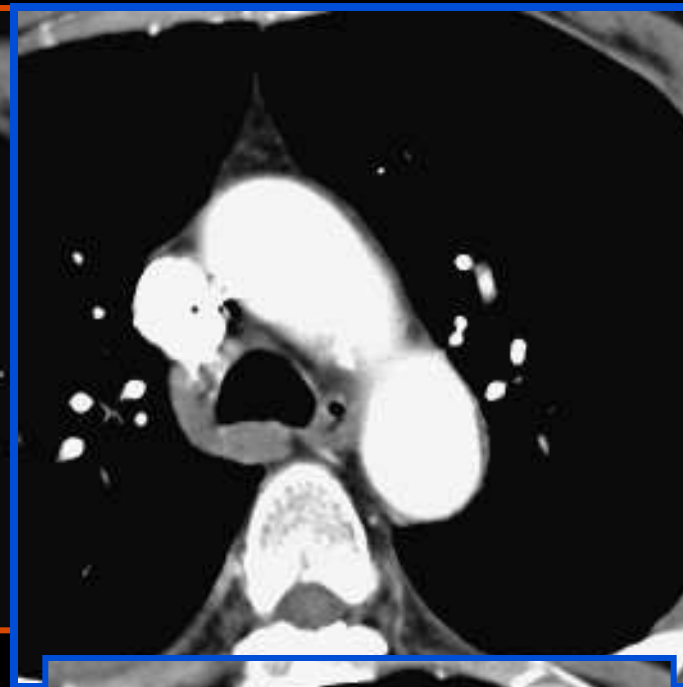
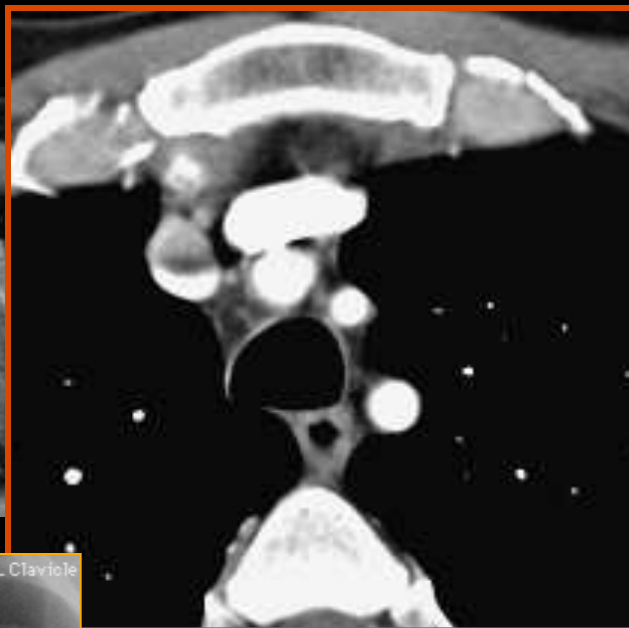
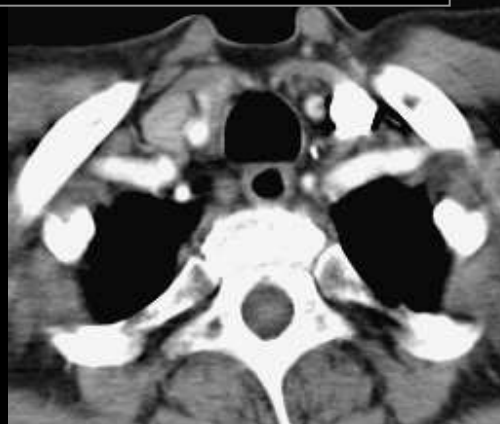**Déplacement
après lobectomie
moyenne droite**

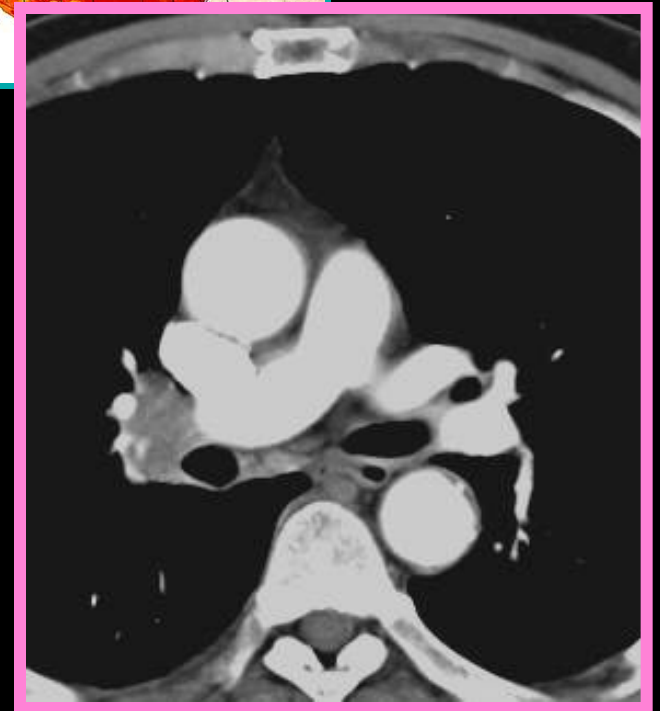
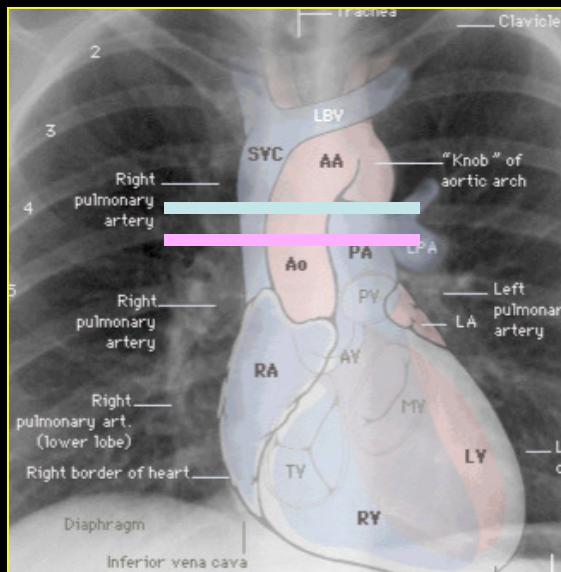
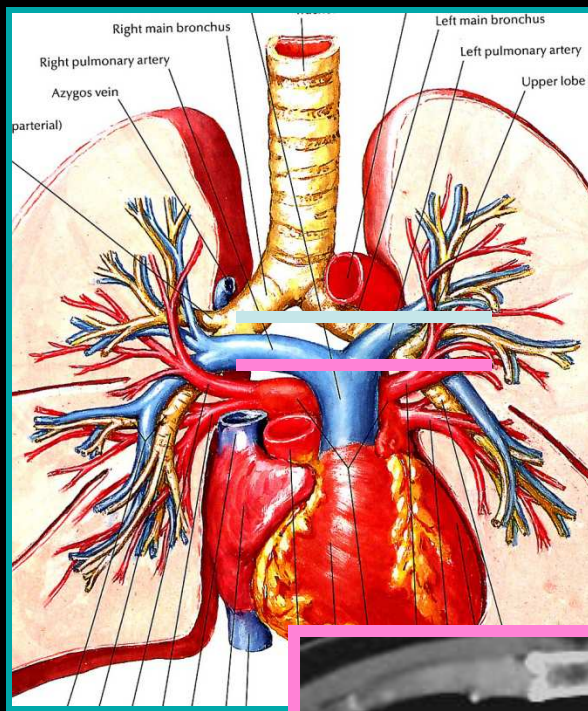
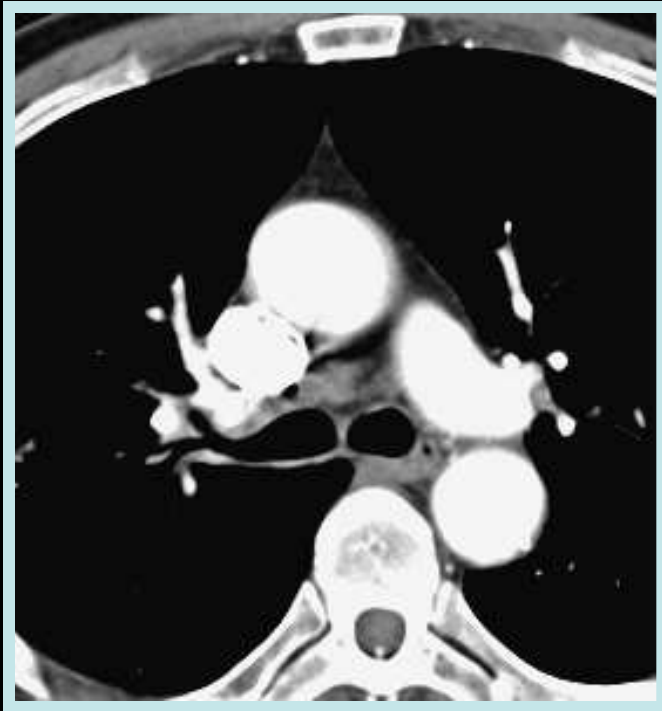


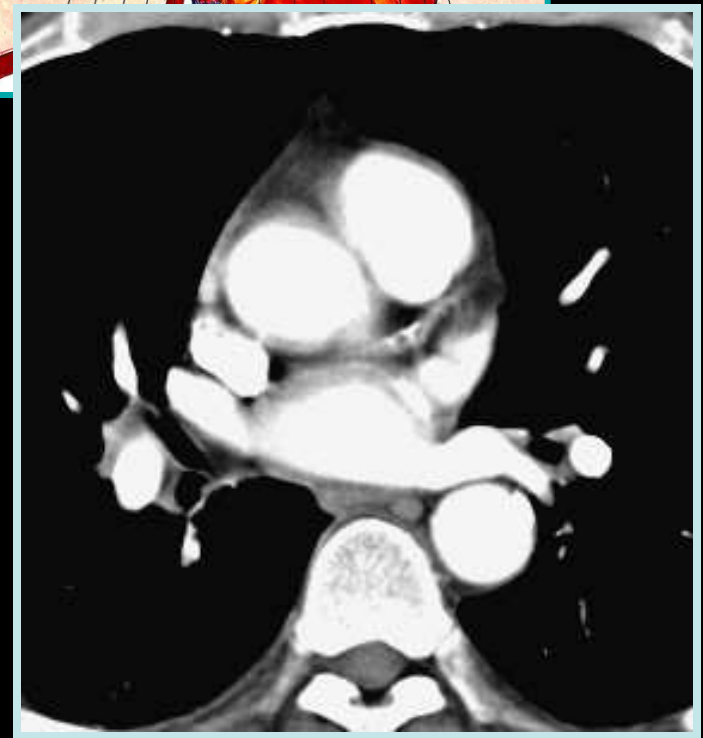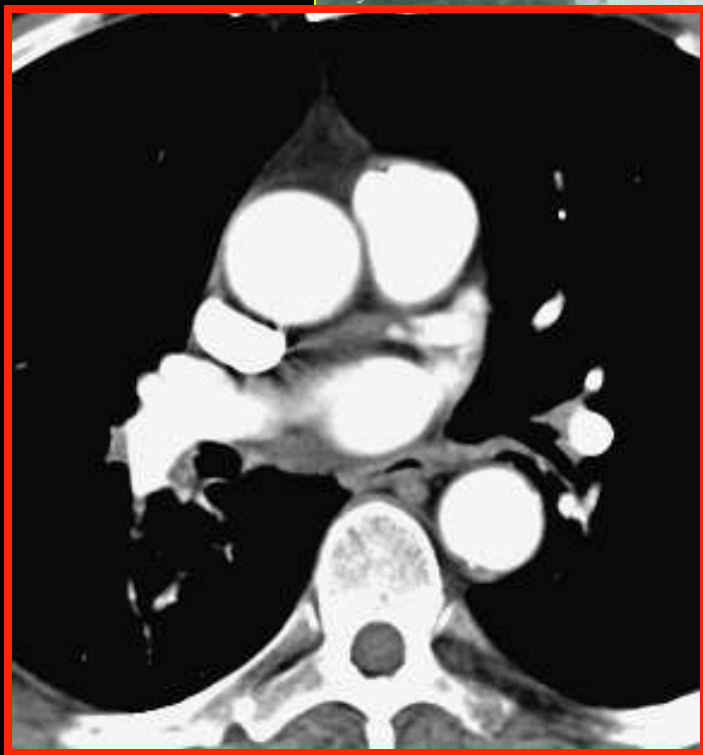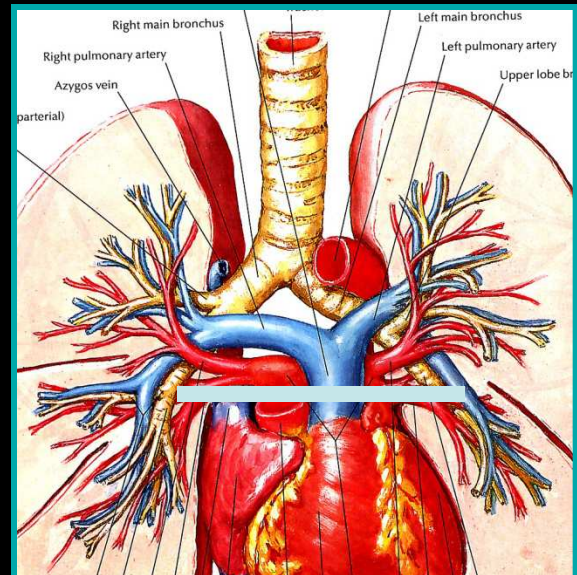
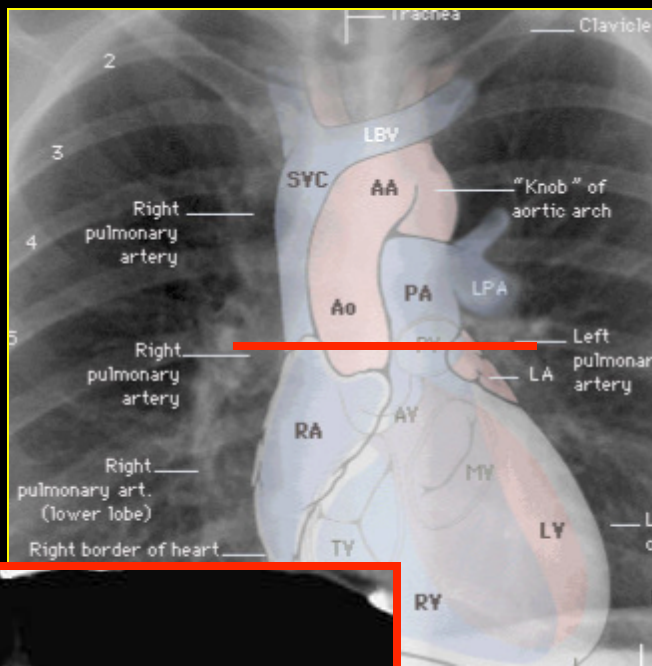
Reconnaître les structures vasculaires

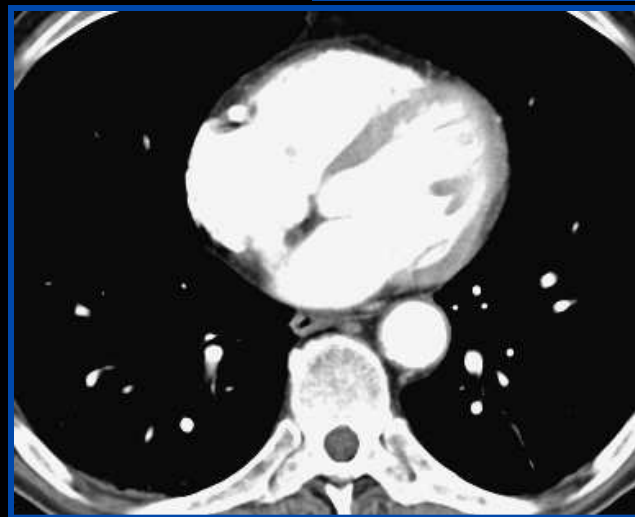
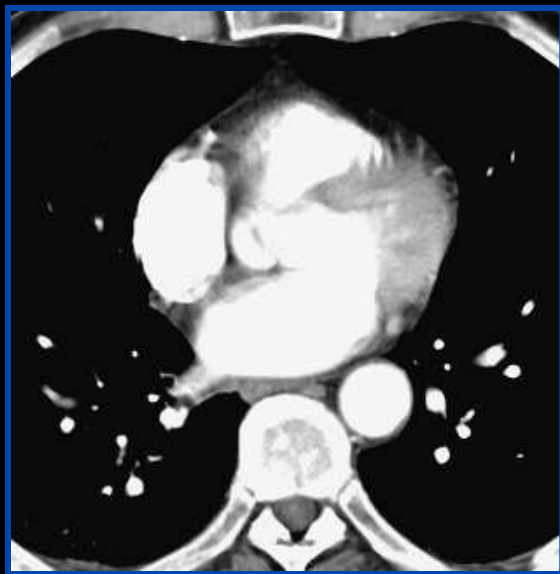
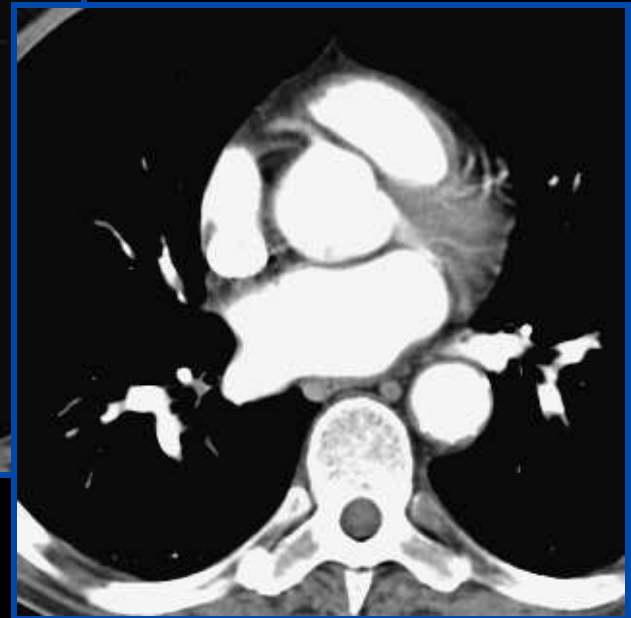
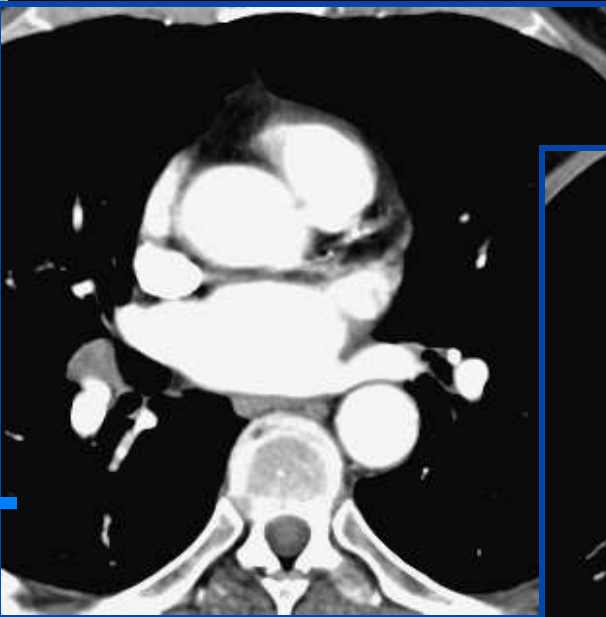
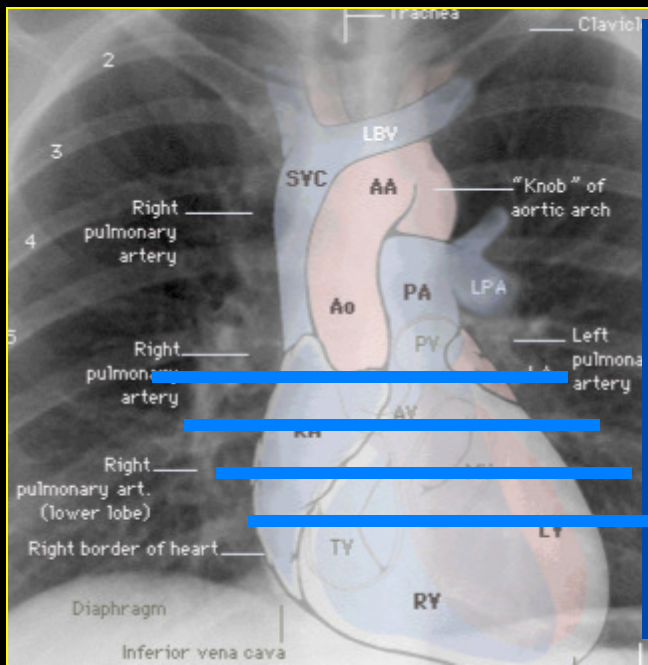


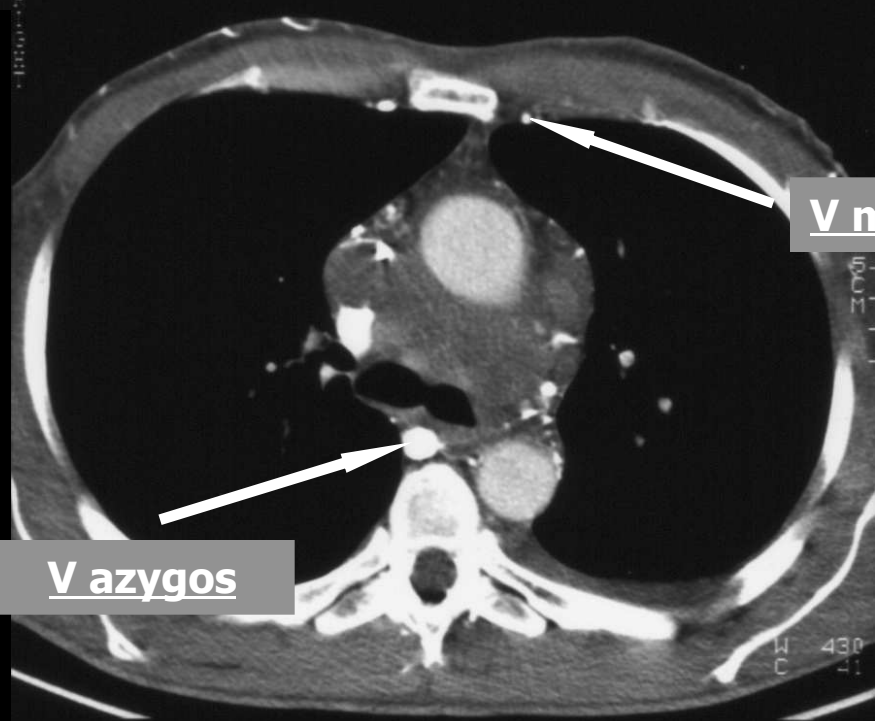
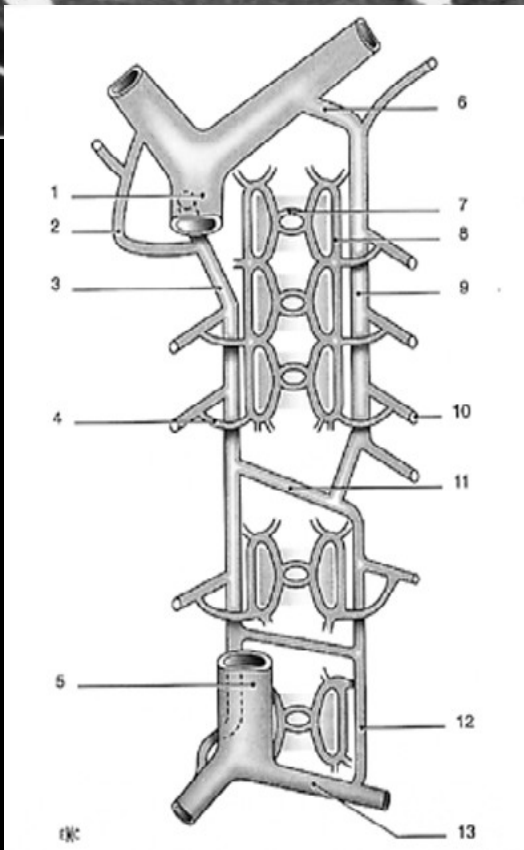
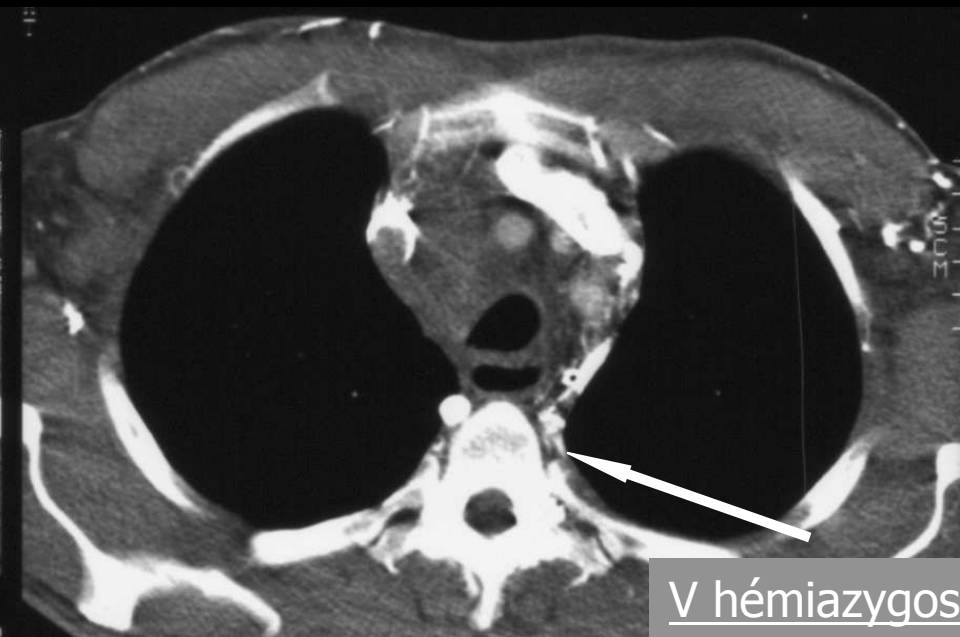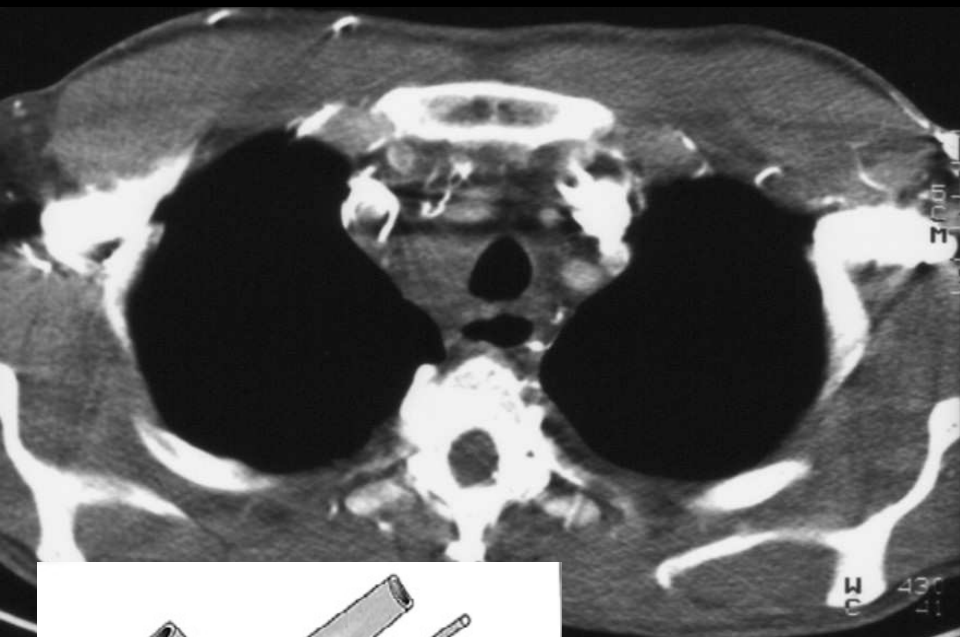
Scanner







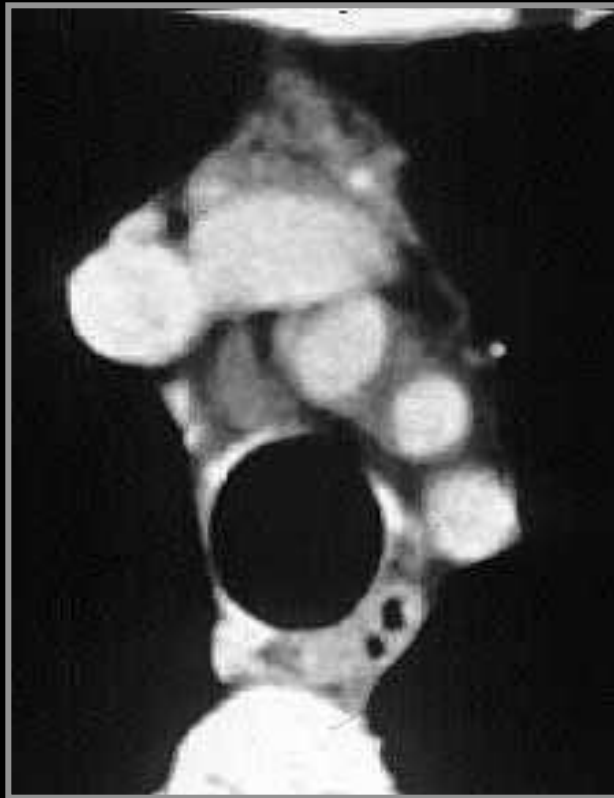




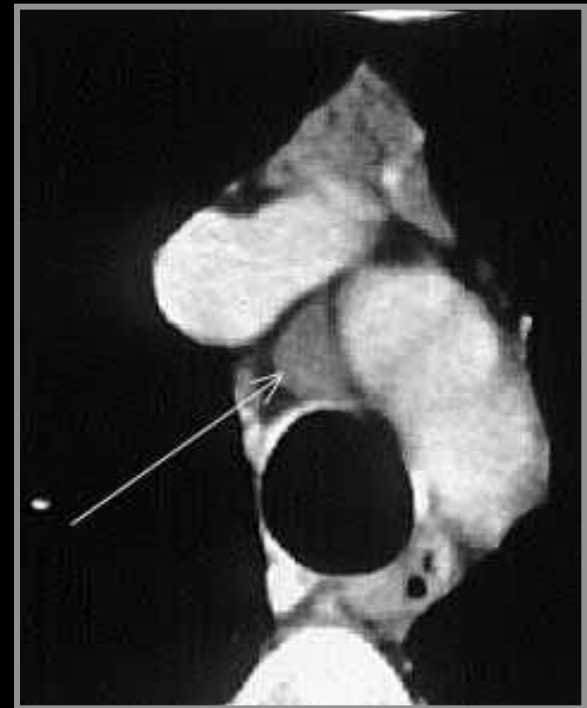
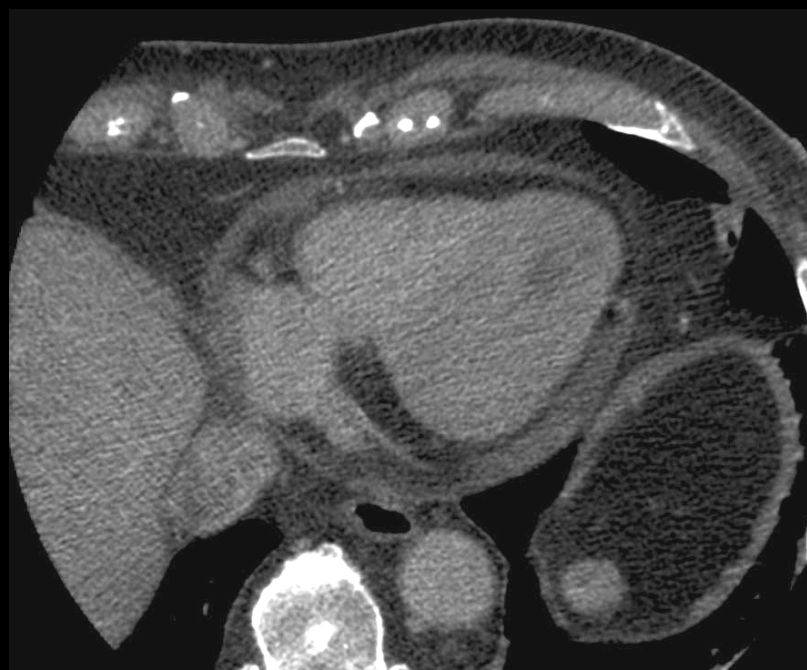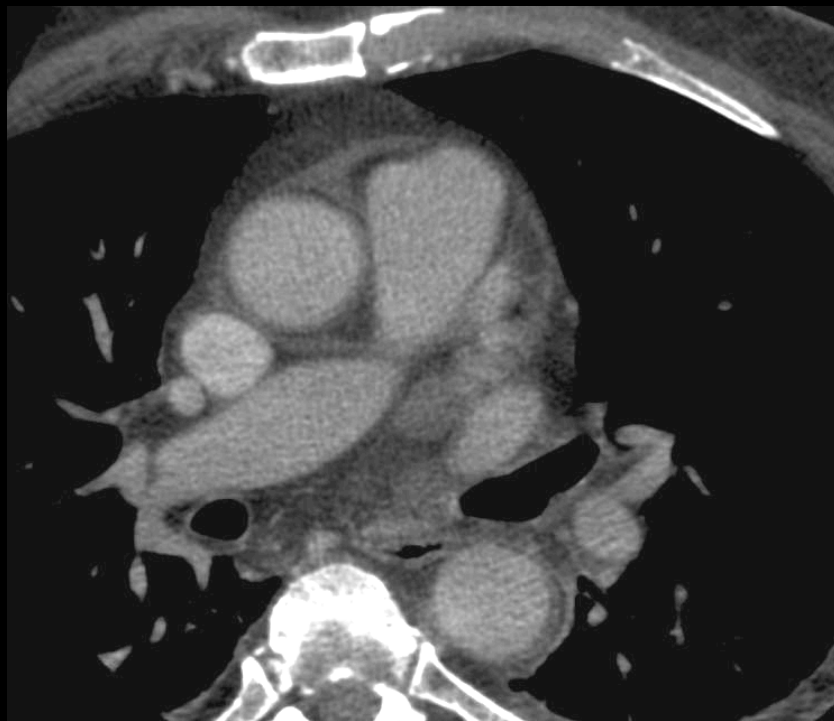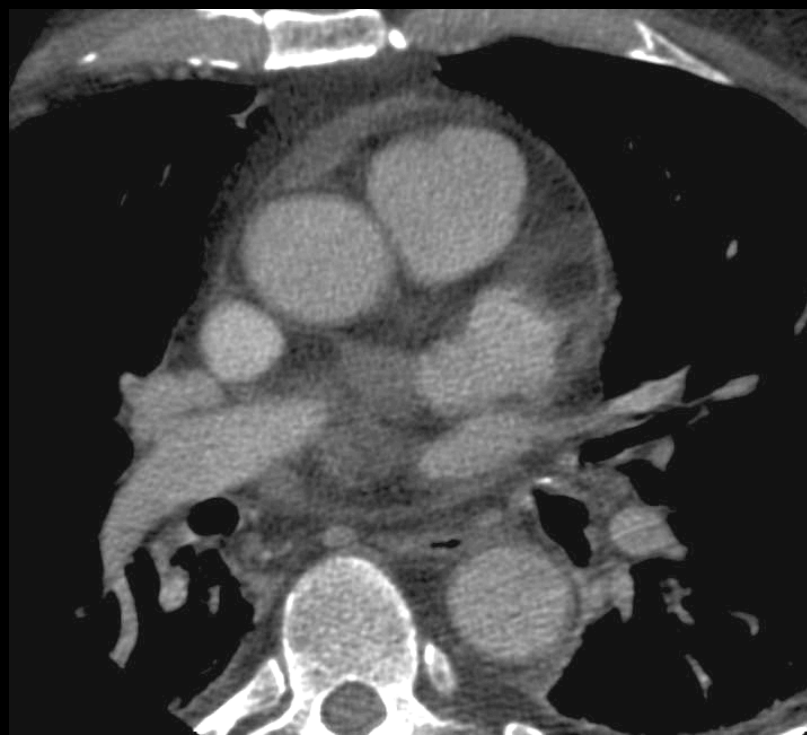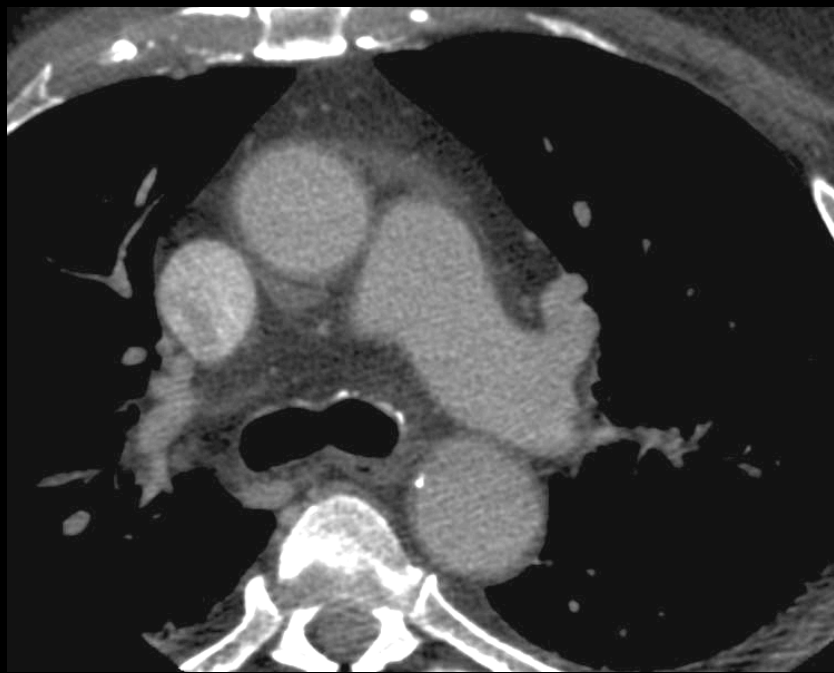
**UN PEU DE PATHOLOGIE ET
VARIATIONS ANATOMIQUES...**

Pièges et erreurs

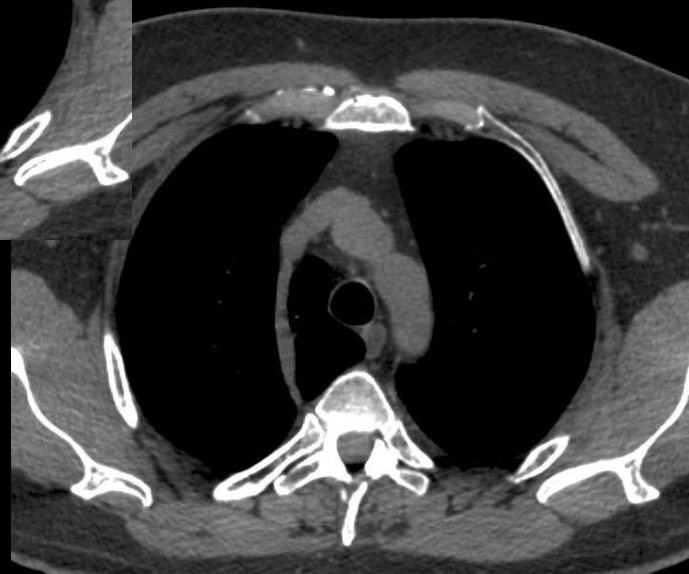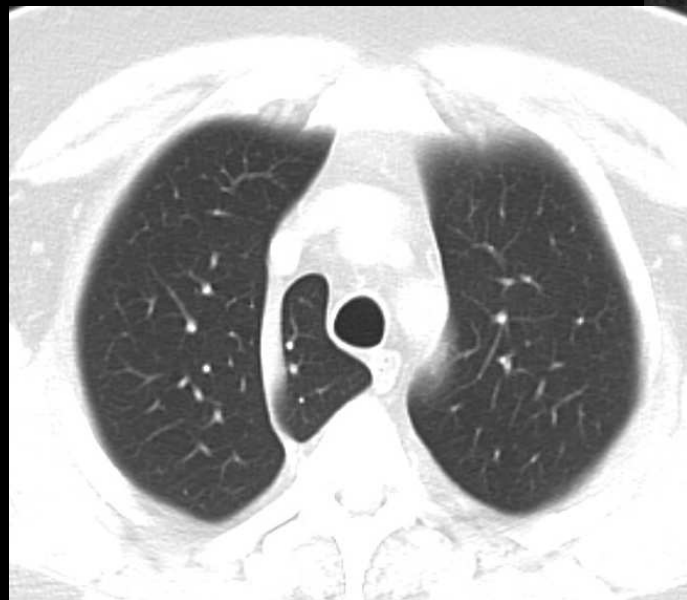
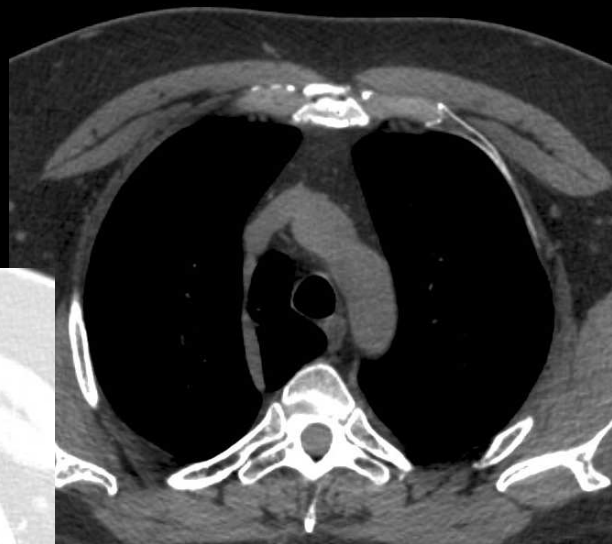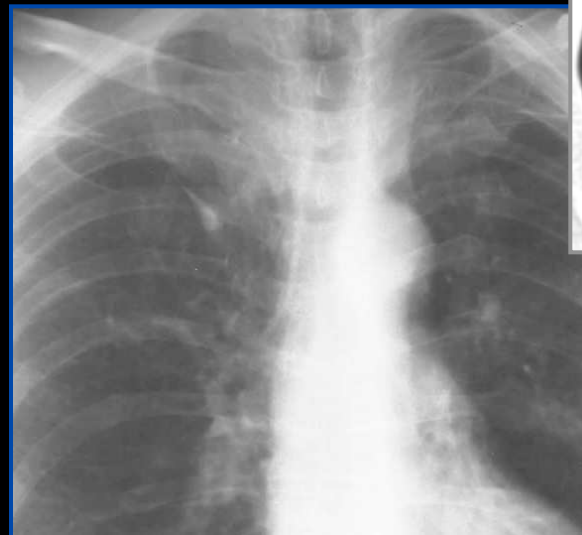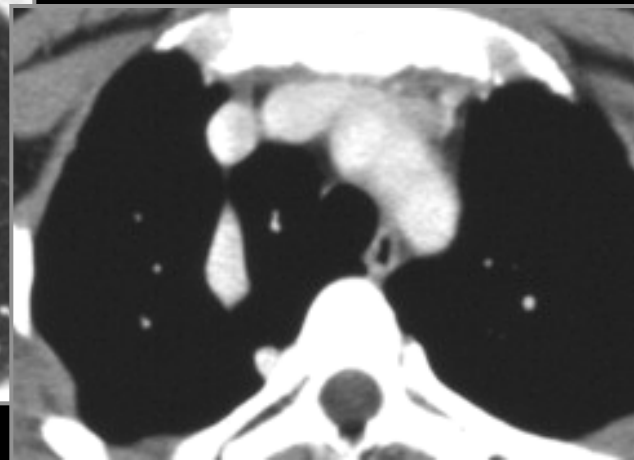


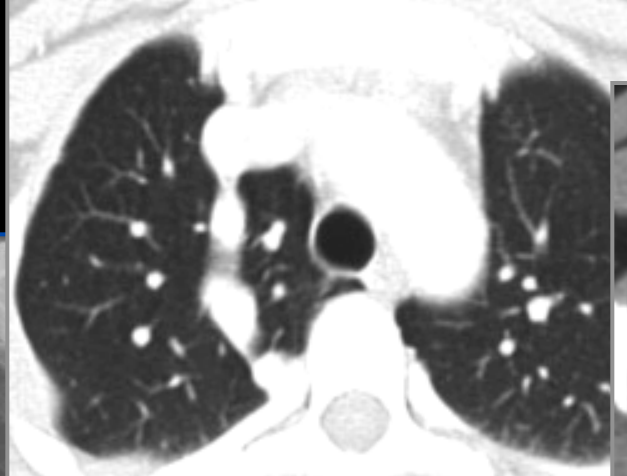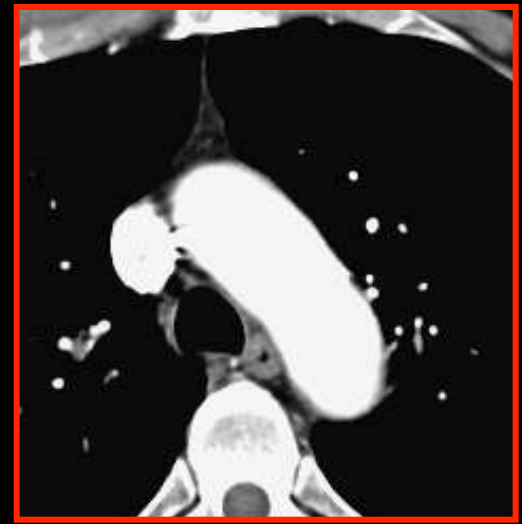
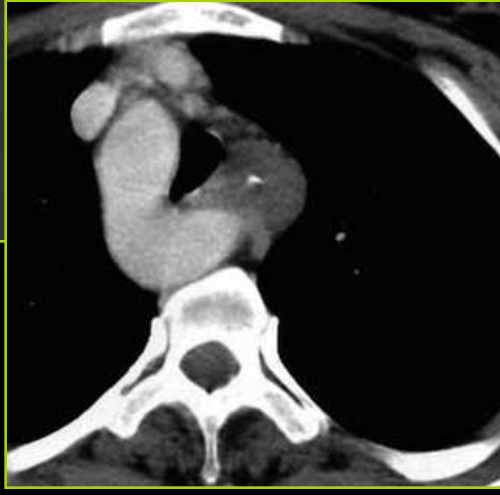
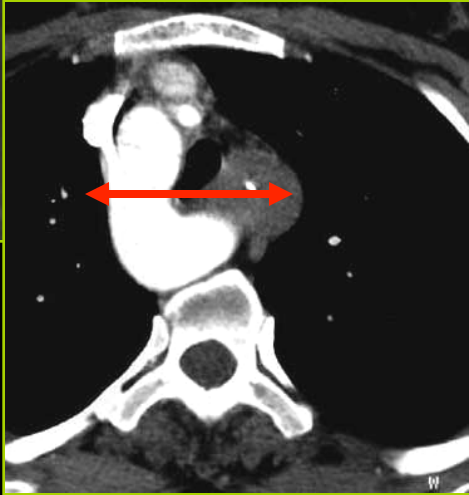
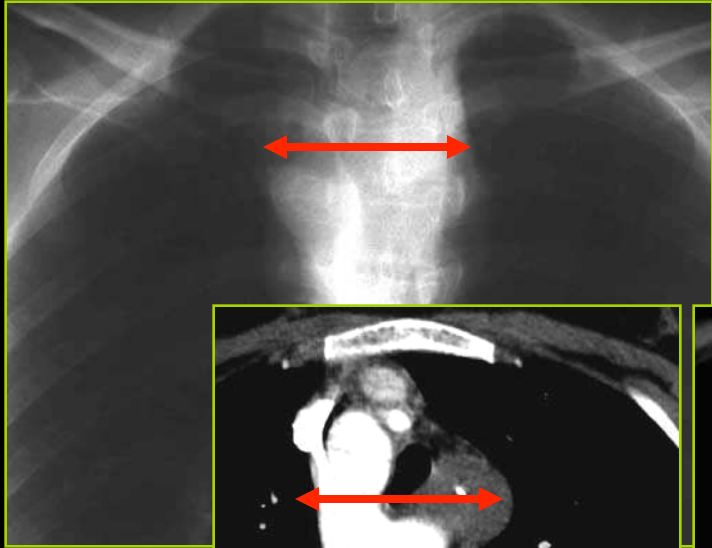
Récessus péricardique



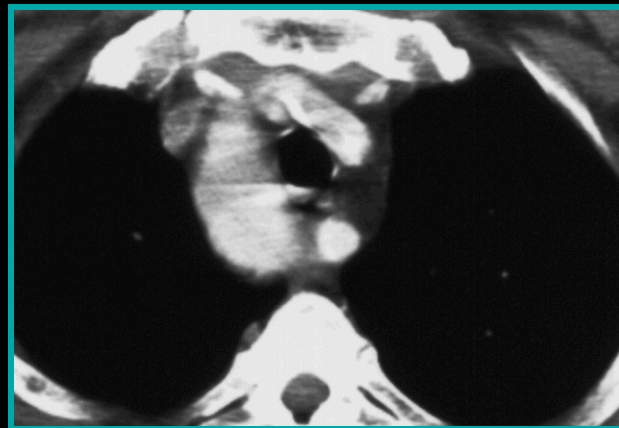
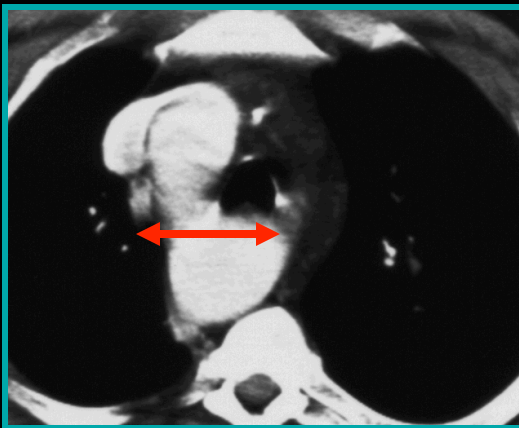


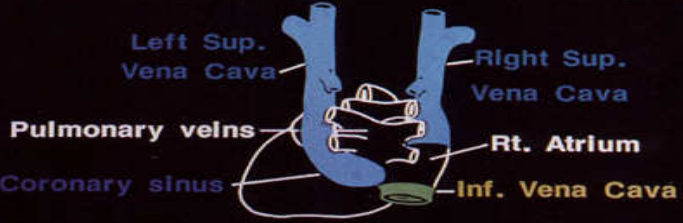Scissure azygos





Arche aortique à droite

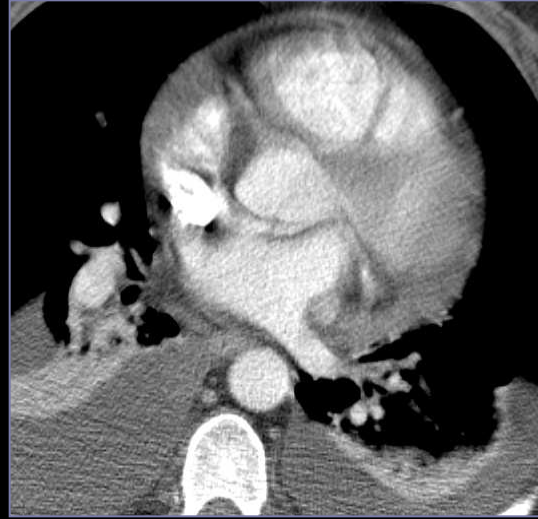
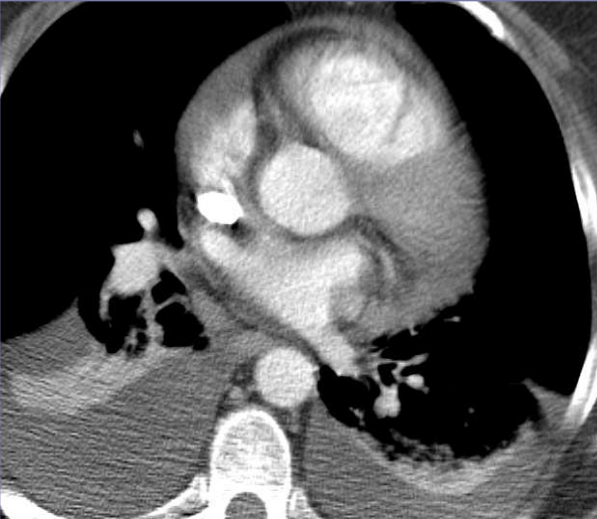
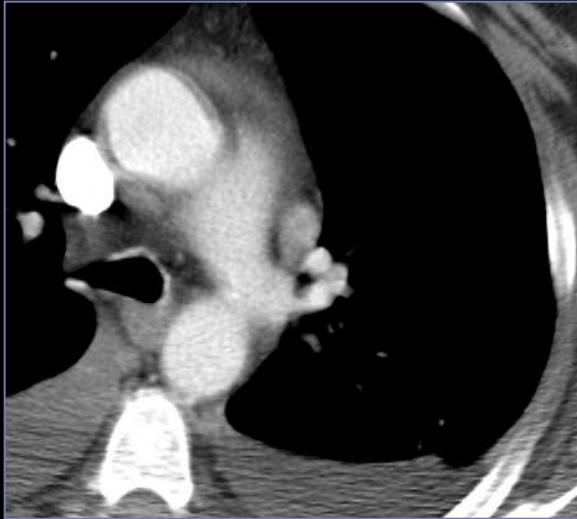
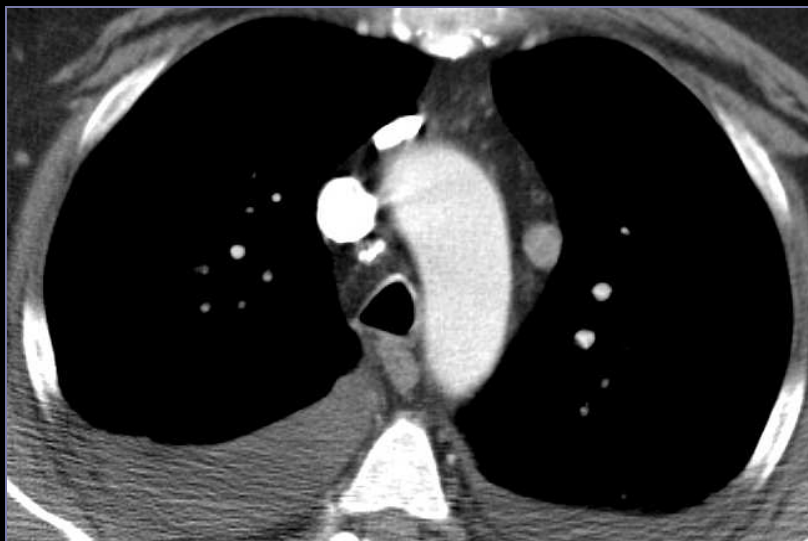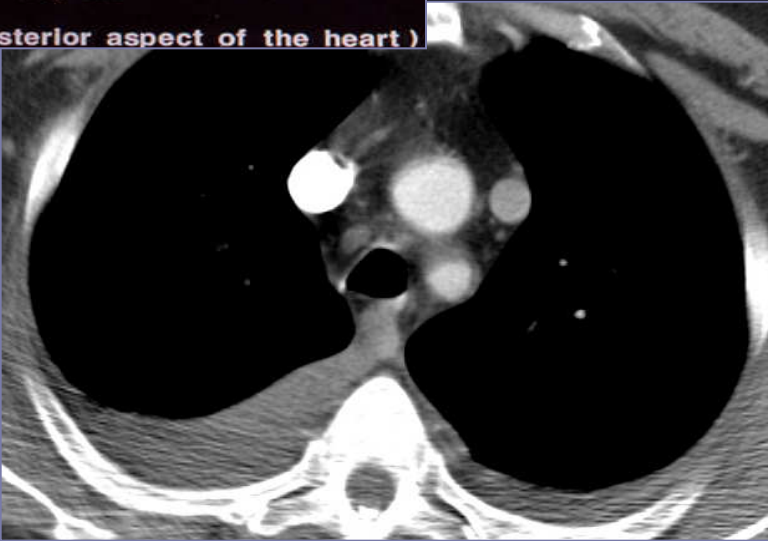


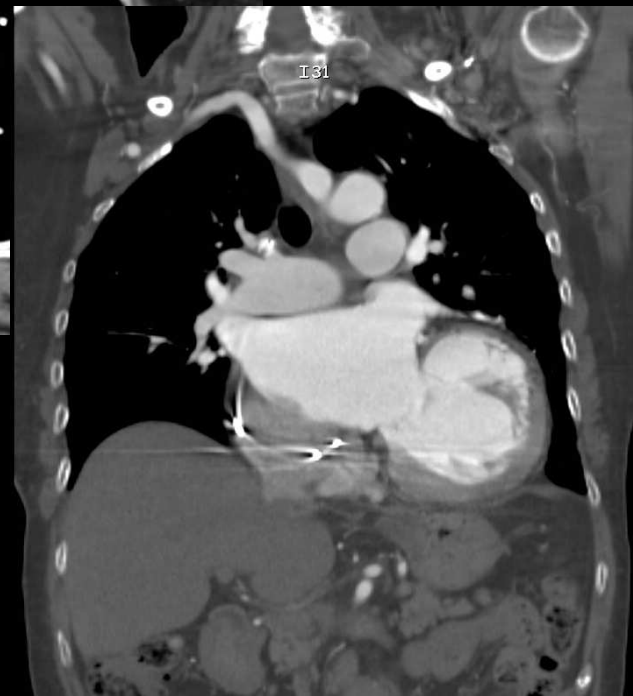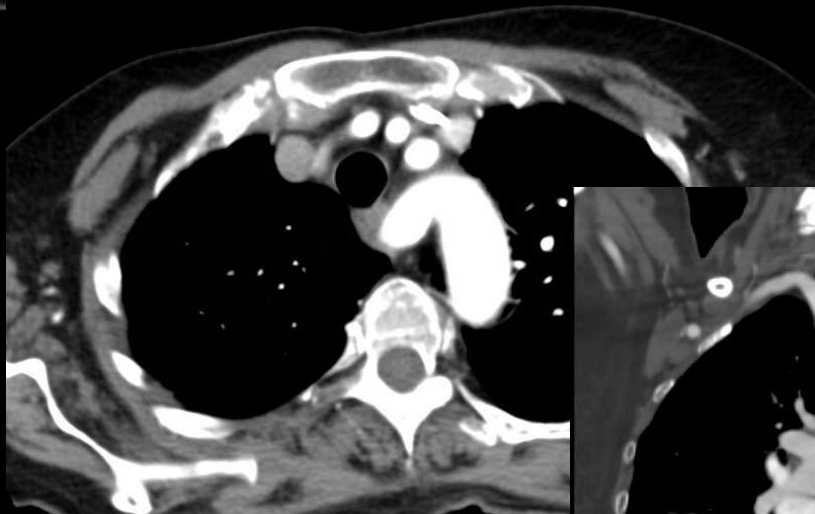


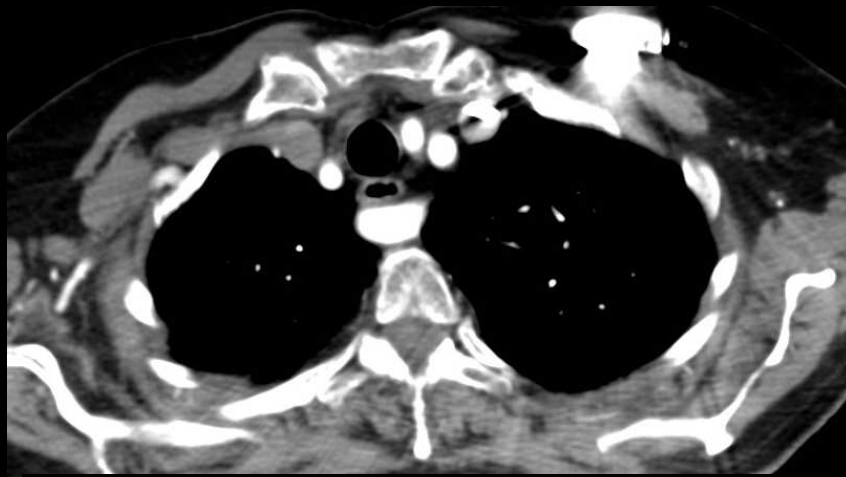Double Veine cave sup

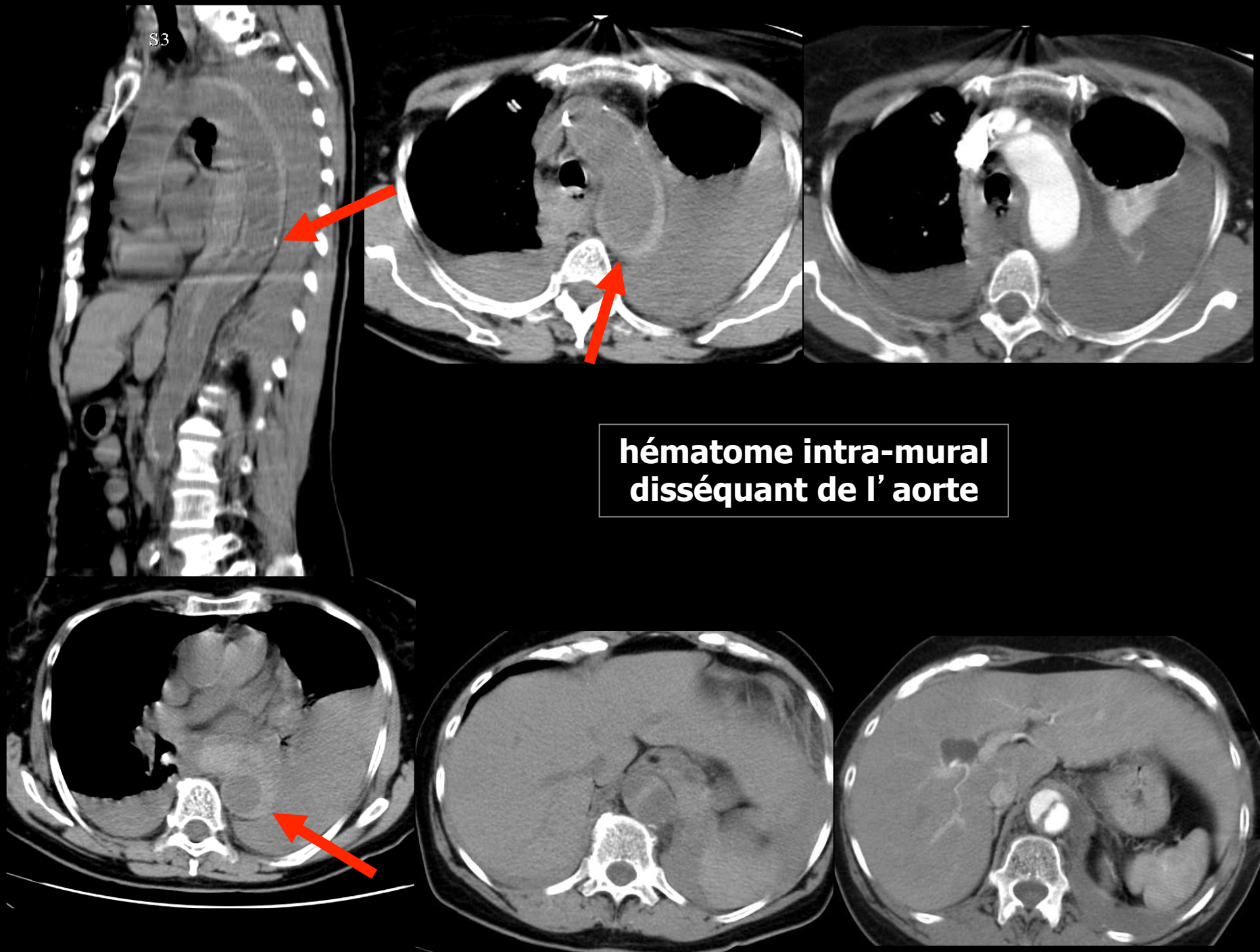
Fig 8B

(Viewed from posterior aspect)

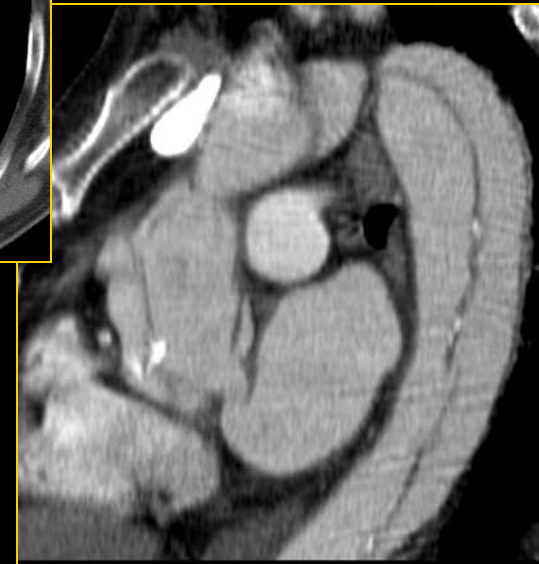
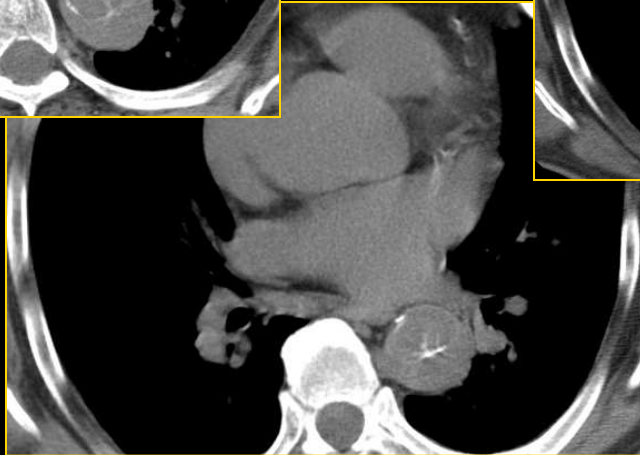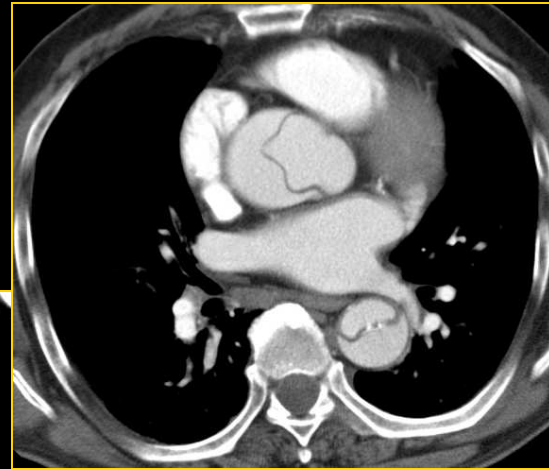
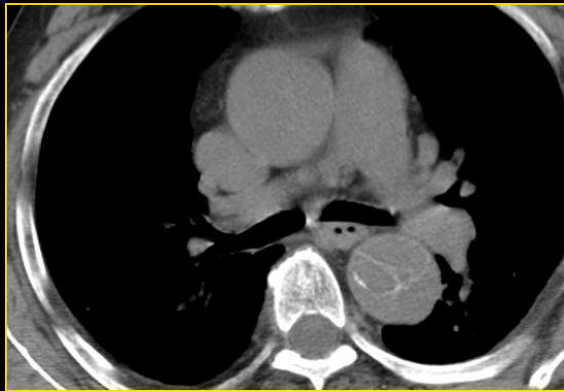
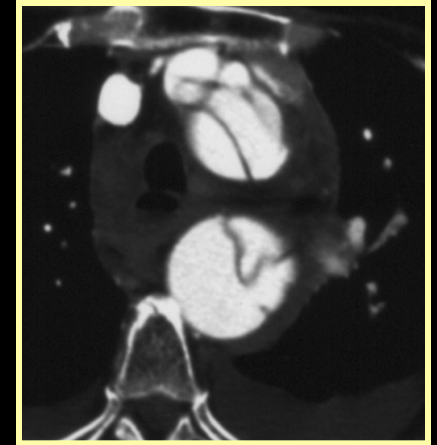
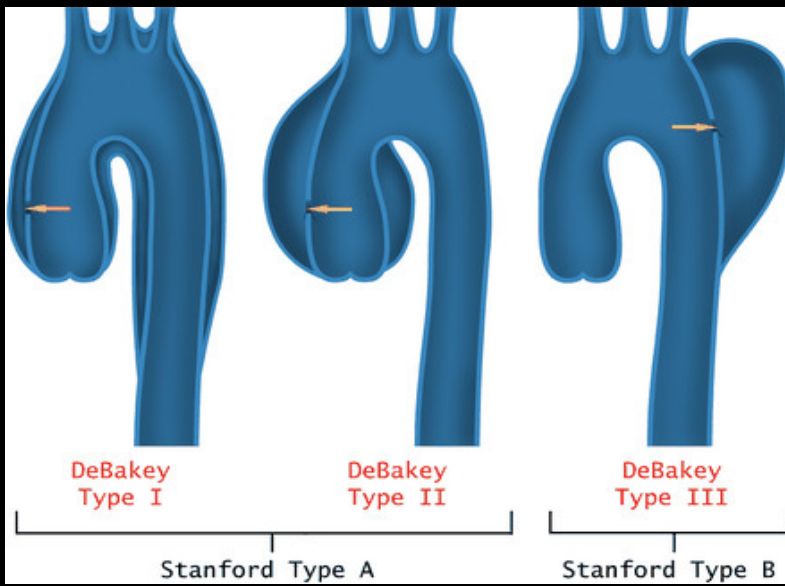


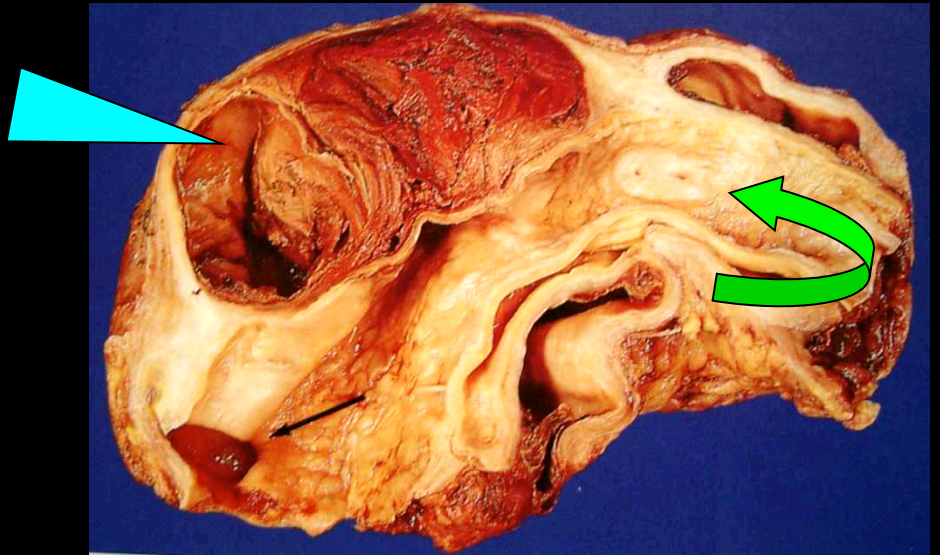
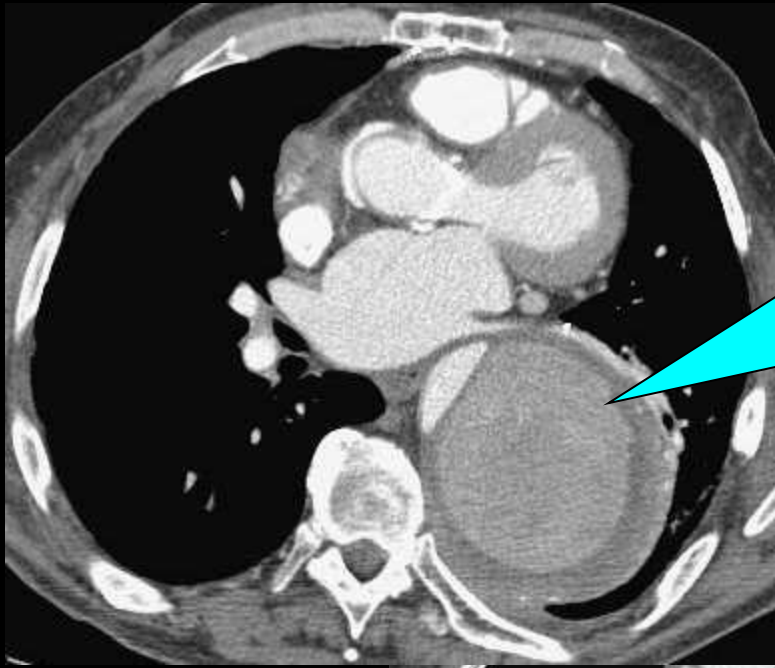


**Artère sous clavière droite
rétrooesophagienne: arteria lusoria**

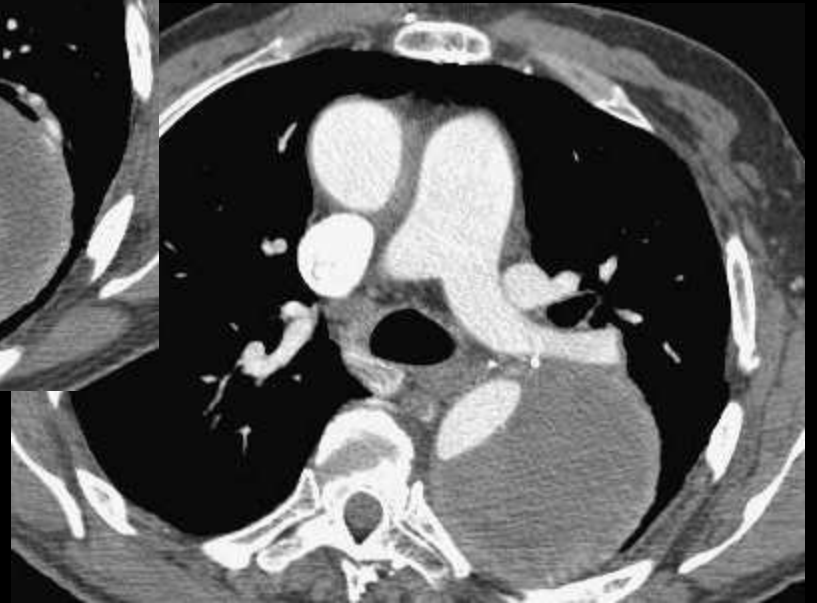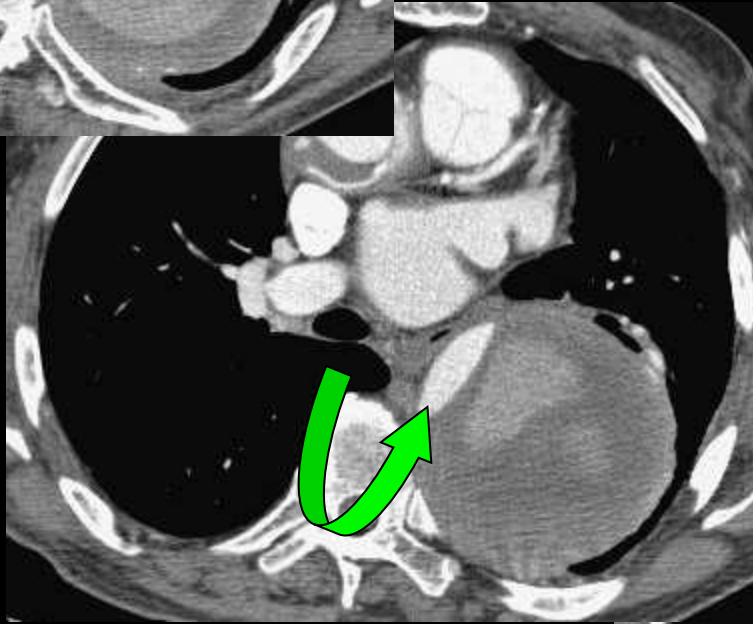


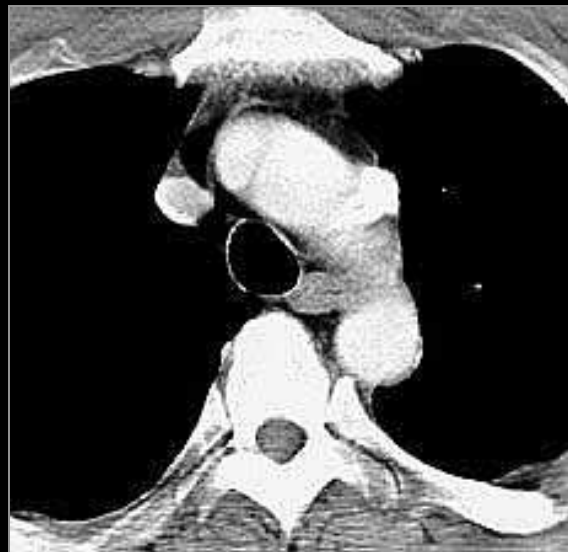
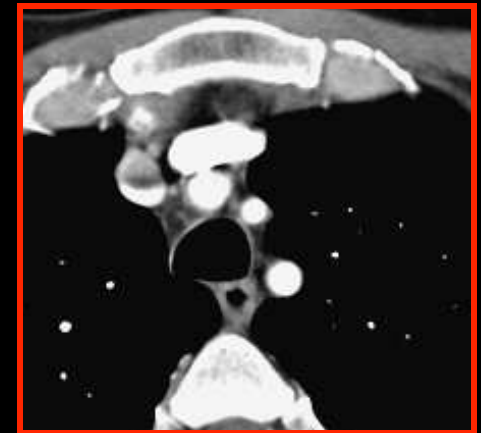
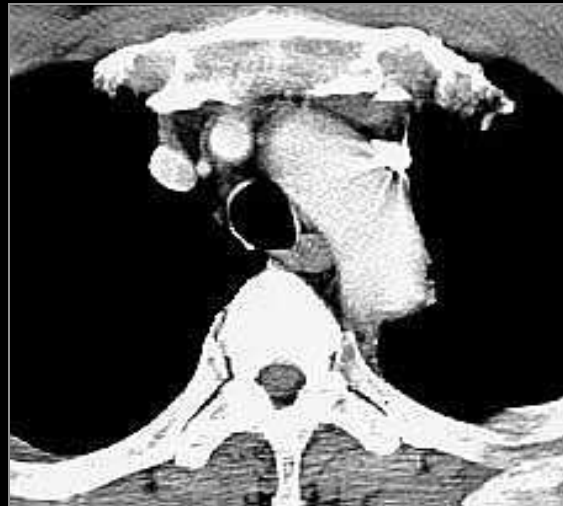
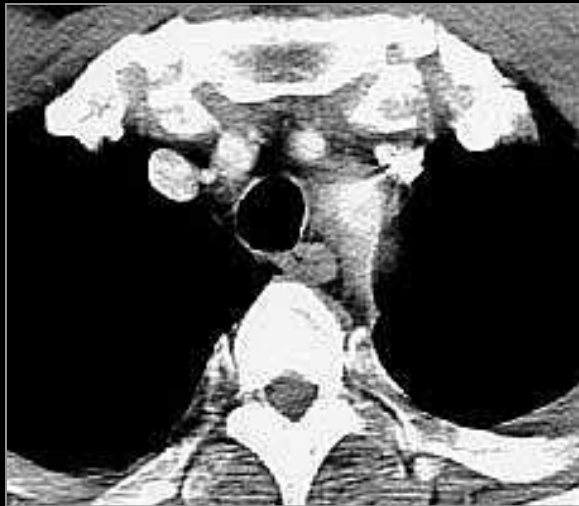Dissection aortique aiguë



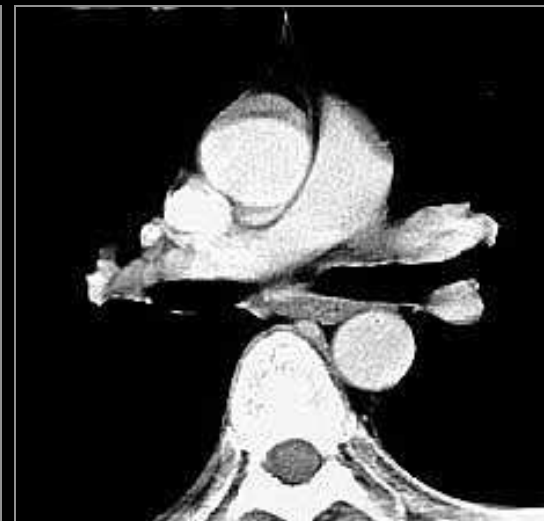
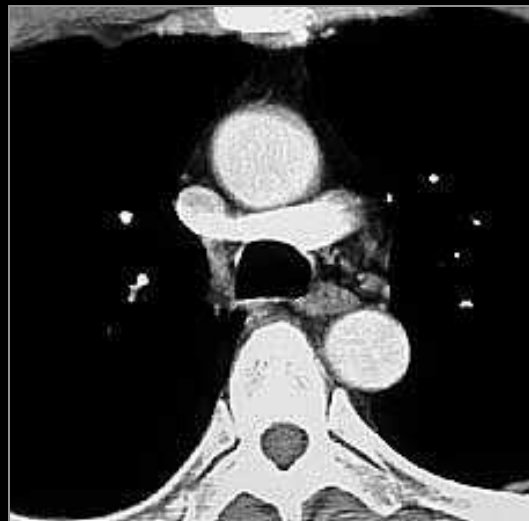

**Dissection aortique et
dilatation anévrysmale
du faux chenal**





**Veine brachiocéphalique G
aberrante**



Artères pulmonaires
Embolie pulmonaire

