

# **Fundamentals of Gonioscopy**

Denise Goodwin, OD, FAAO

## **Introduction:**

Evaluating the anterior chamber angle with gonioscopy is an essential part of evaluating patients at risk for glaucoma and neovascularization. It is also useful for patients with iris abnormalities or a history of trauma or ocular inflammation. Unfortunately, gonioscopy is underutilized by both optometrists and ophthalmologists.<sup>1,2</sup> Coleman, et al. found that less than half of Medicare beneficiaries underwent gonioscopy during a 4-5 year period prior to glaucoma surgery.<sup>3</sup> It is critical to our patient's ocular health that this change.

This article discusses the indications and contraindications to performing gonioscopy. Anterior chamber angle anatomy, types of gonioscopy lenses, a review of the procedure, and proper recording and insurance coding will also be covered. Finally, we will describe common variations of normal anterior chamber angles and angle abnormalities that are commonly seen in an eye care setting.

## **Indications for Performing Gonioscopy:**

There are many indications for performing gonioscopy. One of the most common reasons to do gonioscopy is if you suspect a patient is at risk for angle closure with pupil dilation.

The Van Herrick procedure is routinely used to estimate the depth of the anterior chamber and is a useful way to determine if gonioscopy is necessary prior to dilating the patient's pupils. Van Herrick angle estimation is performed in the biomicroscope by creating a 60° separation between the illumination and the magnification arms. A narrow beam of light is placed at the peripheral edge of the cornea. The size of the shadow between the posterior cornea and the iris is then compared to the size of the optic section (See Figure 1). A shadow that is greater than  $\frac{1}{2}$  the width of the optic section is considered a grade 4. A shadow  $\frac{1}{4}$  to  $\frac{1}{2}$  the size of the optic section is a grade 3. A shadow equal to  $\frac{1}{4}$  of the optic section is a grade 2, and a shadow less than  $\frac{1}{4}$  the size of the optic section is a grade 1. A grade of 3 or 4 with Van Herrick is considered safe for dilation. All patients with a Van Herrick grade 2 or less should have gonioscopy performed prior to dilation.

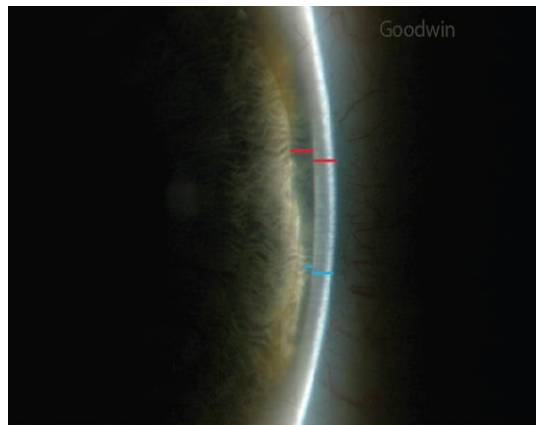


Figure 1: Van Herrick angle estimation compares the width of the shadow from the posterior cornea to the iris and the width of the optic section. This image was taken of a patient with an iris cyst. Therefore, the size of the shadow varies. The area with the red lines demonstrates a grade 4 anterior chamber angle depth (the shadow is greater than  $\frac{1}{2}$  the width of the optic section). The angle is narrower in the area of the blue lines. This area shows a grade 2 anterior chamber angle depth (the shadow is approximately  $\frac{1}{4}$  the width of the optic section).

Another important indication for gonioscopy is to determine the cause of intraocular pressure (IOP) elevation. Gonioscopy should be performed on all patients that are suspected or known to have glaucoma. Gonioscopy is not only used to differentiate between open and closed angle glaucoma by determining the accessibility of the trabecular meshwork, it aids in determining the cause of open angle glaucoma.

Patients with pigment dispersion syndrome (PDS) are likely to have a posterior insertion of the iris root and a concave iris configuration causing increased contact between the posterior iris and the anterior zonules.<sup>4</sup> Contact with the zonules causes release of pigment from the posterior iris. The pigment is then deposited throughout the anterior segment. Transillumination in the midperipheral area of the iris, pigment on the posterior surface of the cornea (Krukenberg spindle), and increased pigment in the trabecular meshwork are hallmark sign of PDS (See Figure 2). Pigment in the trabecular meshwork causes a rise in IOP (pigmentary glaucoma) in as high as 25% of patients with PDS.<sup>5</sup> It is, therefore, critical that gonioscopy is performed in all patients with iris transillumination, pigment on the posterior cornea, or pigment on the anterior lens.



Figure 2: Krukenberg Spindle (A), pigment on the anterior surface of the lens (B), and iris transillumination (C) in a patient with pigment dispersion syndrome.

Exfoliation syndrome can result in severe chronic open angle glaucoma. Here, abnormal fibrillar deposits are seen on anterior segment structures including the anterior lens capsule, pupillary margin, and trabecular meshwork (See Figure 3). It is important to perform gonioscopy in patients suspected of having exfoliation syndrome looking for evidence of the exfoliative material in the trabecular meshwork and along the pupil border.

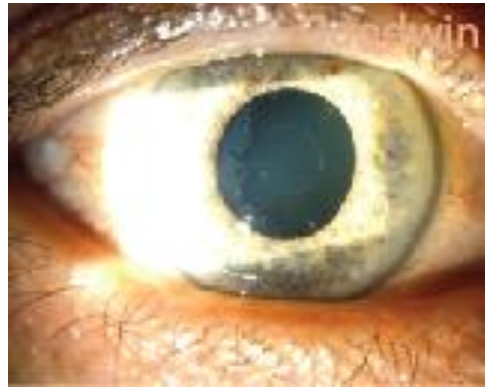

Figure 3 shows exfoliative material on the lens capsule in a patient with exfoliation syndrome.

Patients with a history of blunt ocular trauma should be evaluated for evidence of angle recession, tears between the longitudinal and circular muscles of the ciliary body. It is also common to see pigmentation of the trabecular meshwork and foreign bodies in the anterior chamber while performing gonioscopy on patients with a history of ocular trauma.

Gonioscopy is a good way to examine abnormalities of the iris. The view with gonioscopy is as if you are looking at the iris while you are standing on the crystalline lens and sticking your head up through the pupil. Therefore, gonioscopy makes it very easy to see elevation of an iris lesion (See Figure 4).




Figure 4 demonstrates the ability with gonioscopy to appreciate elevation of iris abnormalities such as this iris cyst.

Patients with a history of ocular inflammation should have gonioscopy performed.

Anterior synechiae and inflammatory debris in the trabecular meshwork can cause a rise in IOP.

Gonioscopy should be performed on all patients with a compromised vascular system.

This includes conditions such as diabetes (See Figure 5), carotid artery disease, and a history of central retinal artery occlusion or central retinal vein occlusion.

Neovascularization of the angle can cause severe glaucoma. It is critical that this is recognized and treated early.

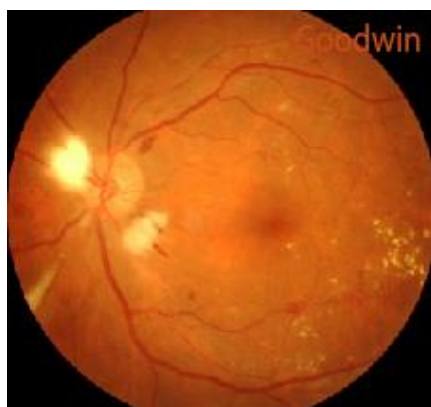

Figure 5 shows a patient with diabetic retinopathy. Due to the retinal ischemia this person is at risk for neovascularization in the anterior chamber angle.

### **Contraindications and Relative Contraindication to Performing Gonioscopy:**

There are many conditions that require that gonioscopy be performed. There are not many situations when gonioscopy should not be performed. However, if there is a worry that the patient may have lacerated or perforated the globe, gonioscopy should not be performed (See Figure 6). Putting pressure on the eye in this situation will cause aqueous to drain from the eye.

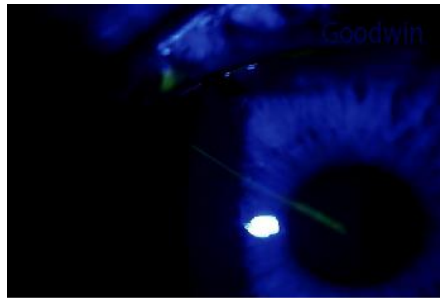


Figure 6 shows a patient with a recent corneal laceration.

Performing gonioscopy on a patient with a fresh hyphema can cause a rebleed (See Figure 7). If possible, wait a couple weeks after the hyphema has cleared to perform gonioscopy. It is important to perform gonioscopy on these patients once the eye has healed because it is common for these patients to have angle recession or other damage to the anterior chamber angle.

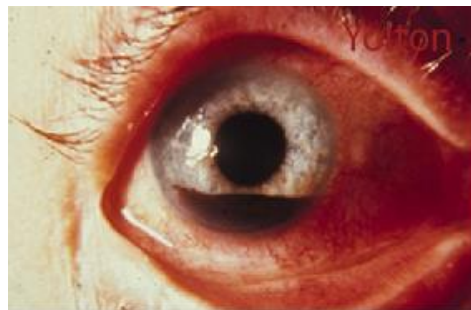

Figure 7 shows a patient with a hyphema. (Image credit Dr. Diane Yolton)

For patients with corneal or conjunctival surface disease such as herpes simplex keratitis or epidemic keratoconjunctivitis it is important to determine whether obtaining a view of the anterior chamber angle warrants the risk of damaging the already weakened corneal epithelium (See Figure 8). Epithelial basement membrane dystrophy also weakens the corneal epithelial attachment. It is, therefore, important to be aware of the amount of movement made with the gonioscopy lens on the cornea. Also, minimize the number of anesthetic drops you use in these patients since topical anesthetic tends to further soften the corneal epithelium.

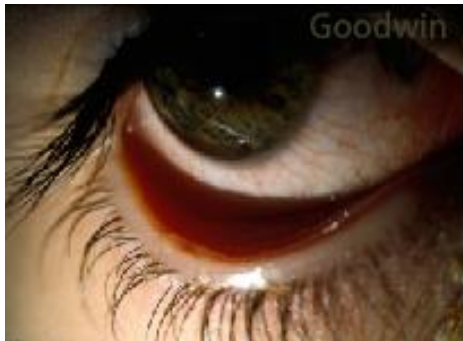

Figure 8 shows a patient with a viral conjunctivitis.

### **Anterior Chamber Anatomy:**

An understanding of what a normal anterior chamber angle looks like is essential to differentiating normal angle structures from abnormalities of the angle. When you first look at the anterior chamber angle it may be difficult to determine what you are seeing. Orient yourself by finding the pupil. Then follow the iris out to the ciliary body (See Figure 9A). Although the color of the ciliary body will vary depending on the color of

the iris, the ciliary body will be darker in color than the iris. People with brown irises will have a dark brown ciliary body. The ciliary body may be a light brown or gray color in patients with lighter irises.

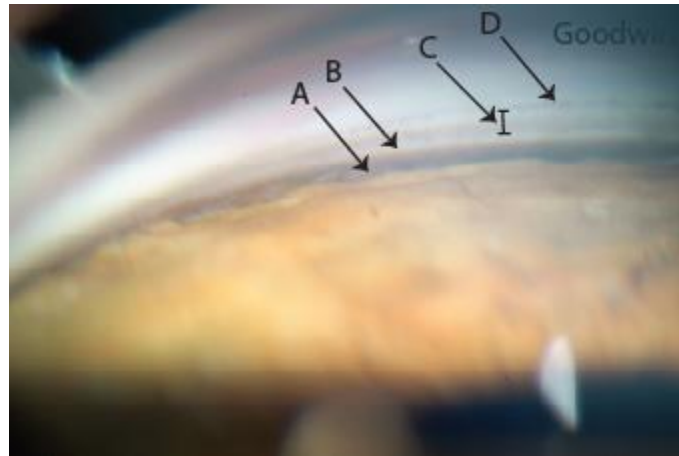


Figure 9 shows the anatomical structures of a normal anterior chamber angle: ciliary body (A), scleral spur (B), trabecular meshwork (C), and Schwalbe's line (D).

Moving anteriorly, the next structure seen is the scleral spur (See Figure 9B). The scleral spur will be bright white because it is a projection of scleral tissue. There is little variation in the coloration of the scleral spur making this a good landmark to determine which structures are visible.

The trabecular meshwork is adjacent to the scleral spur (See Figure 9C). The trabecular meshwork can also be whitish-gray color; however, the coloration is not as bright white as the scleral spur. The trabecular meshwork will often appear gray or pink and has a meshy appearance. If there is pigment in the trabecular meshwork, the trabecular meshwork will appear to have two distinct layers as seen in Figure 9. Because the majority of aqueous is filtered through the posterior portion of the trabecular meshwork,



the more posterior layer, closer to the iris, will be more pigmented. The anterior trabecular meshwork will often remain a gray or light brown color because it does not filter as much aqueous and, therefore, as much pigment or other elements in the aqueous.

Schwalbe's line is the termination of Descemet's membrane. It indicates the anterior border of the angle (See Figure 9D). In some patients it is not easy to identify, but you may see a white ridge in other patients. Occasionally pigment will deposit on this ridge and Schwalbe's line will appear pigmented as seen in Figure 9. The area anterior to Schwalbe's line is reflections off the cornea.

Figure 10 shows another normal anterior chamber angle. Again, begin by orienting yourself by finding the pupil. In this case, the iris has a concave appearance producing a very deep angle. The scleral spur is very prominent. This patient does not have much pigment in the trabecular meshwork so it does not appear to have two distinct layers. It is difficult to identify Schwalbe's line in this patient, but it is assumed to be where the trabecular meshwork ends.

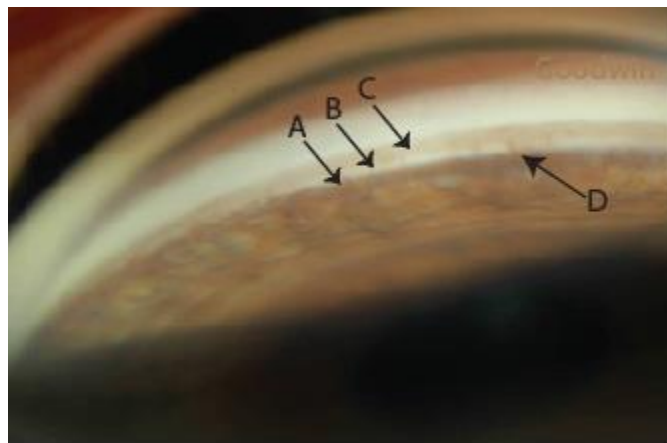


Figure 10 shows the anatomical structures of a normal anterior chamber angle: ciliary body (A), scleral spur (B), and trabecular meshwork (C). Schwalbe's line is difficult to identify in this patient. Iris processes are also present (D).

Iris processes are visible in the angle shown in Figure 10. Iris processes are found in 35% of normal eyes.<sup>6</sup> They typically extend from the peripheral iris to the ciliary body or scleral spur. Occasionally the iris processes extend to the posterior aspect of the trabecular meshwork or Schwalbe's line.

Figure 11 is an image of an angle in a patient with a dark iris. The ciliary body has a very dark appearance. The scleral spur is prominent, and the trabecular meshwork appears grayish-brown. Iris processes are prominent in this patient. The image in Figure 11 appears inverted compared to Figures 9 and 10 because it is the superior angle whereas the previous angles were views of the inferior angle.

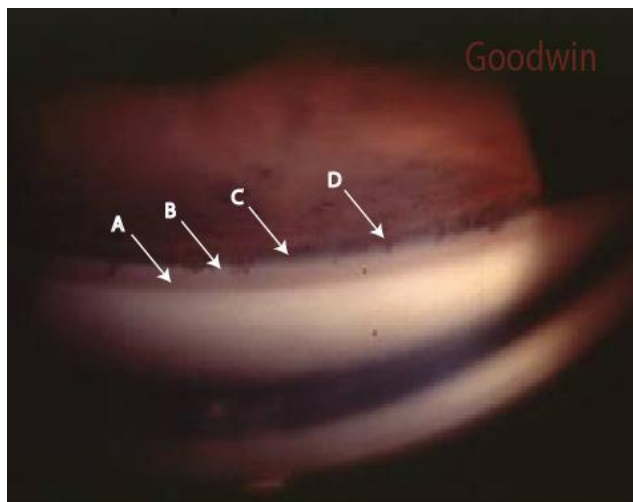


Figure 11 is an image of a superior anterior chamber angle: Ciliary body (C), scleral spur (B), trabecular meshwork (A), and iris process (D). Schwalbe's line is difficult to identify in this patient.

Figure 12 is a gonioscopy image of a patient with a lighter iris. The ciliary body is a light brown color followed by a bright white scleral spur. There are two distinct areas of the trabecular meshwork. Schwalbe's line is pigmented.




Figure 12 is an inferior gonioscopy view of a patient with a light iris: Ciliary body (A), scleral spur (B), trabecular meshwork (C), and Schwalbe's line (D).

### Gonioscopy Lenses:

Indirect gonioscopy lenses (Figure 13) do not view the angle structures directly. A mirror is used to view the anterior chamber angle. Because a mirror is used to view a reflection of the angle, the structures being evaluated are 180° from the mirror you are viewing. For example, if you are looking at the superior mirror, you are viewing the inferior angle. If you are looking at the temporal mirror, you are viewing the nasal angle.

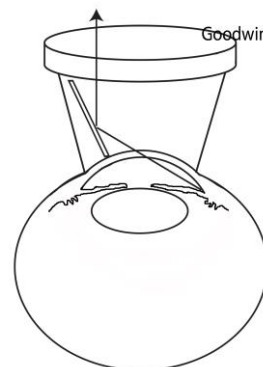


Figure 13 demonstrates how an indirect gonioscopy lens gives a view 180° away from the mirror.

There are many indirect gonioscopy lenses to choose from. The biggest differentiation between indirect gonioscopy lenses is whether they are suction lenses (require a viscous fluid such as Celluvisc between the eye and lens) or non-suction lenses (do not require a viscous fluid between the eye and the lens). Figure 14 shows the difference in the patient contact surface between a suction and non-suction lens.



Figure 14 shows the difference in size between a suction and non-suction lens.

Suction gonioscopy lenses provide better image quality. They are also easier to use since you do not have to be as aware of the amount of pressure you are putting on the eye with the lens. However, it takes more time and is sometimes inconvenient to use a cushioning solution.

Non-suction gonioscopy lenses are good for doing a rapid evaluation, but the quality of the image is not as good as that with suction lenses. Non-suction lenses are more difficult to learn on because you do have to be aware of the pressure you are putting on

the eye with the lens. If you are pushing too hard you will cause wrinkling of the cornea which will not allow a quality view of the angle. If you don't have enough pressure on the lens you will get air beneath the lens. If air is between the lens and the eye, a view of the angle is not possible. Non-suction lenses enable indentation gonioscopy to differentiate between appositional and synechial angle closure.

I recommend that people who are just starting out with gonioscopy start with a suction lens. Once they get good at identifying the structures with a suction lens, they can move to a non-suction lens. However, some people can perform gonioscopy easily by going directly to a non-suction gonioscopy lens.

In addition to the patient contact surface, gonioscopy lenses vary based on the number of mirrors that are available to view ocular structures. Both suction and non-suction gonioscopy lenses are manufactured with 4 mirrors, 3 mirrors, 2 mirrors, or 1 mirror.

The gonioscopy lenses with 4 mirrors (See Figure 15A) are good because they allow a quick examination of all 4 quadrants of the anterior chamber angle. There is no need to rotate the lenses during the examination. However, gonioscopy lenses with 4 mirrors do not have the ability to view the peripheral area of the retina as do 3-mirror gonioscopy lenses.




Figure 15 shows different gonioscopy lens types: 4 mirror gonioscopy lenses (A), 3 mirror gonioscopy lens (B), and 1 and 2 mirror gonioscopy lenses (C).

The advantage of a 3 mirror lens (See Figure 15B) is that in addition to 1 mirror (the D-shaped mirror) that allows views of the anterior chamber angle, you have 2 other mirrors that allow examination of the anterior retina (See Figure 16). Because only one of the three mirrors can be used to view the anterior chamber angle, the lens must be rotated three times in order to look at all four quadrants of the anterior chamber angle.

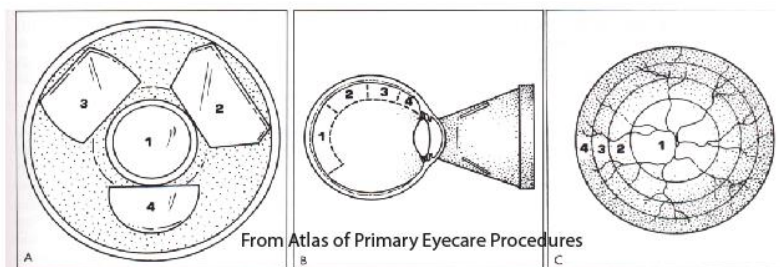


Figure 16 shows a 3-mirror gonioscopy lens with mirrors that are used to view various areas of the retina. Mirror 4 is used to view the anterior chamber angle.<sup>7</sup>

Because gonioscopy lenses with only 1 or 2 mirrors (See Figure 15C) are small, they are good for patients with small interpalpebral fissures. The lenses are light so they are easy to maintain correct positioning. The mirrors are also smaller producing a more minified view of the anterior chamber. A gonioscopy lens with 2 mirrors would only need to be rotated once to observe all quadrants. A one mirror, similar to the three mirror gonioscopy lenses, would need to be rotated three times in order to view all four areas of the anterior chamber angle.

## **Gonioscopy Procedure:**

Prior to performing gonioscopy, it is essential that you clean and disinfect the gonioscopy lens. The gonioscopy lens should be soaked in a solution of 1:10 bleach or a commercially available disinfectant for 5 minutes followed by thoroughly rinsing the lens with saline.

Click on the following link to view a 4-5 minute video demonstrating how to perform gonioscopy with both a suction and non-suction gonioscopy lens.

[Insert streaming video of gonioscopy procedure here.](#)

When first performing the gonioscopy procedure you should start with cooperative patients. Contact lens wearers are usually easier to perform the procedure on because they are used to having something on their eye. Anytime you put a drop of anesthetic in the eye, practice gonioscopy. The more normal angles you look at, the better you will be at recognizing abnormalities when they are present.

Start by looking at the inferior angle; that is with the mirror in the superior position. This is typically the widest angle so it is easier to identify the visible anatomy. Also, due to gravity causing the pigment to drop to the lower area of the aqueous, there tends to be more pigment present in the inferior trabecular meshwork.

### **Common Errors While Performing Gonioscopy:**

It is common to get air bubbles between the gonioscopy lens and the cornea (See Figure 17). This occurs when the gonioscopy lens is not flat on the patient's cornea. If a bubble occurs, try tilting the gonioscopy lens toward the bubble and push lightly on the eye to try to squish the bubble out. Occasionally you can still obtain an adequate view despite the presence of a small air bubble underneath the gonioscopy lens. If the bubble is large and you can't squish it out, you will need to remove and reinsert the gonioscopy lens.

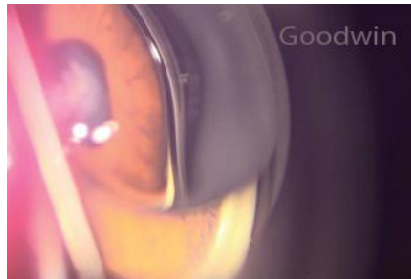

Figure 17: An air bubble between the cornea and gonioscopy lens.

If no anterior chamber angle structures are visible after inserting the gonioscopy lens, check to assure the lens is centered over the corneal apex. There should be an equal width of visible sclera 360° when the lens is in the appropriate position.

Especially when first performing gonioscopy, the arm can get tired causing the lens to become decentered. Resting the elbow on a small box placed on the table of the biomicroscope can help stabilize the arm.



If you are using a 3-mirror gonioscopy lens, make sure the slit lamp is focused correctly on the D-shaped mirror. The other mirrors are used for viewing the retina and will not direct the light into the anterior chamber angle.

Finally, if you are unable to obtain a view of the anterior chamber angle, check to make sure the oculars of the biomicroscope are not being obstructed by another part of the slit lamp or by fingers.

### **Recording and Coding for Gonioscopy:**

There are several methods of recording gonioscopy findings. The following is a clinically useful way of recording information from the gonioscopy examination. Because it is descriptive, other practitioners that read your chart notes will be able to easily interpret the findings. See Figure 18 for an example of recording gonioscopy findings.

Each quadrant of an “X” represents one quadrant of the anterior chamber angle. For each quadrant a minimum of three features should be recorded. First, record the abbreviation of the most posterior structure that is visible: ciliary body (CB), scleral spur (SS), trabecular meshwork (TM), or Schwalbe’s line (SL). All structures that are anterior to that recorded can be assumed to be present. For example, if scleral spur is the most posterior structure seen in the superior quadrant, record SS in the superior quadrant. It is assumed that trabecular meshwork and Schwalbe’s line are also visible.

Second, it is important to make note of the pigment in the trabecular meshwork. The pigment is typically graded on a scale of 0 (no pigment in the trabecular meshwork) to 4 (extremely dense pigment in the trabecular meshwork).

Finally, the third item that needs to be recorded is the topography of the iris. It should be documented whether the iris has a flat, convex, or concave appearance. In addition to these three features, it is also important to record any abnormalities seen within the anterior chamber angle.

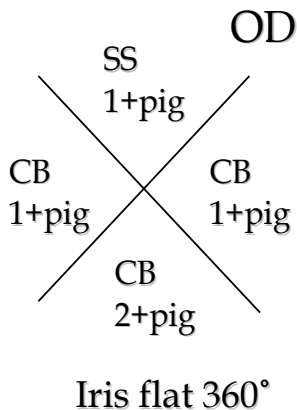


Figure 18 shows an example of how to record gonioscopy results.

Gonioscopy is not bundled with the office visit. This bilateral procedure should be billed with the 92020 CPT code. Common billable diagnoses include all types of glaucoma except steroid induced glaucoma, potential angle-closure, pigment dispersion syndrome, central retinal artery occlusion, central retinal vein occlusion, uveitis, angle recession, rubeosis, anterior or posterior synechiae, diabetic retinopathy, neoplasm, retinal vasculitis, retinal detachment, and iris lesions. Proper documentation includes a diagram

including angle structures, pigment in the trabecular meshwork, and other angle abnormalities.

### **Anterior Chamber Angle Grading Considerations:**

The position of the gonioscopy lens, as well as the type of gonioscopy lens being used, can affect the appearance of the angle. In a patient with a convex iris, the angle may appear deeper when using a gonioscopy lens with a higher vantage point or angling the gonioscopy lens so light is reflected over the obstruction of the iris (See Figure 19).

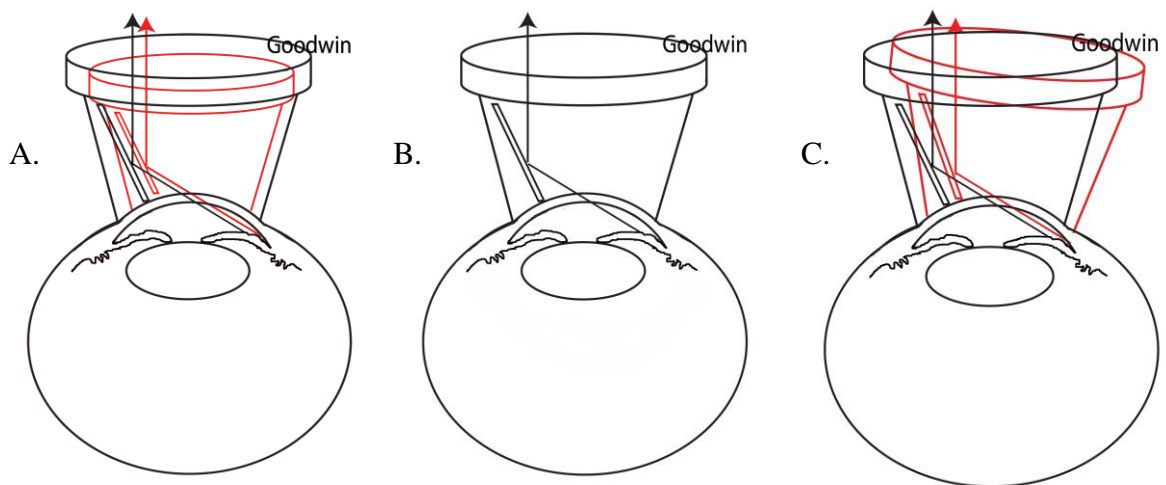


Figure 19 demonstrates how the use of a smaller gonioscopy lens (A) or tilting the gonioscopy lens (C) will aid in seeing over a convex iris.

The mirrors of the smaller 1 or 2-mirror gonioscopy lenses are closer to the apex of the cornea than the larger 3-mirror gonioscopy lenses. This causes the light to be reflected differently (See Figure 19A). A view with a bigger gonioscopy lens may be obstructed by a convex iris, whereas the angle may be visible when viewing through a more centrally placed mirror.

If a patient appears to have a closed angle, have the patient move their fixation to look in the direction of the mirror being observed. Alternatively, tilt the gonioscopy lens away from the observation mirror. This will permit the examiner to look over the convex iris into the anterior chamber angle (See Figure 19B). If anterior angle structures are visible following refixation, this indicates that the patient has a convex iris configuration rather than an appositionally closed angle. If additional structures are not visible after the patient refixates, the iris is in contact with the angle structures. Indentation gonioscopy should then be performed to determine if the iridotrabecular contact is appositional in nature or caused by anterior synechiae.

Pushing too hard with a non-suction gonioscopy lens will cause aqueous to move to the peripheral portion of the angle. This pushes the iris back causing the angle to appear wider than under normal conditions. This technique, indentation gonioscopy, can be useful if attempting to differentiate between appositional angle closure and synechiae in the anterior chamber.

When examining potentially narrow angles, the patients should be examined in a dark room with a narrow beam of light to minimize pupillary constriction and corresponding widening of the angle. The anterior chamber angle is significantly narrower in dark versus light due to peripheral iris thickening and the iris assuming a more convex configuration.<sup>8,9,10</sup> Angle closure is also more likely to occur when a patient is in a dim environment such as watching a movie at the theater. Dim illumination while performing

gonioscopy increases the likelihood of correctly diagnosing a patient that is at risk for angle closure. In addition to angle closure, it is important to look for pigment in the trabecular meshwork, neovascularization of the angle, anterior synechiae, angle recession, and peripheral iris and ciliary abnormalities. These may be more easily seen if the pupil is smaller creating a wider view of the anterior chamber angle.

### **Anterior segment OCT:**

Anterior segment OCT can non-invasively and quantitatively assess for narrow angles.

However, it is not as sensitive or specific for angle closure as gonioscopy.<sup>11-14</sup>

Additionally, you are unable to evaluate other angle characteristics, such as pigmentation in the angle, with an anterior segment OCT.

The scleral spur is used as the main landmark to measure the angle size with anterior segment OCT (Figure 20). However, the scleral spur cannot be identified in up to 25% of patients.<sup>11,15,16</sup> Localization may be especially difficult in those with narrow or closed angles. The ability to visualize the angle anatomy may be improved with high resolution OCT technology.<sup>17,18</sup> With the anterior segment OCT, apposition between the iris and anterior chamber angle beyond the scleral spur is considered angle closure.<sup>18</sup>

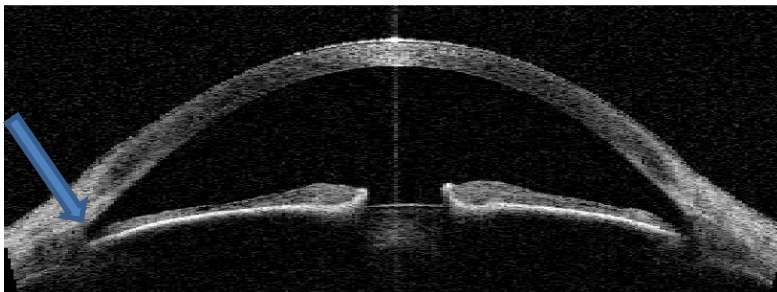

Figure 20X: Anterior segment OCT image showing the position of the scleral spur (blue arrow).

### **Common Gonioscopy Findings:**

Watch the beam of the slit lamp as it traverses across the iris toward the anterior chamber angle to determine the contour of the iris as it approaches the angle. Figure 21 shows a patient with a concave iris. This is more commonly found in myopic patients. Having a concave iris configuration puts the patients at an increased risk for pigment dispersion syndrome because the posterior iris is more likely to come in contact with the zonules.

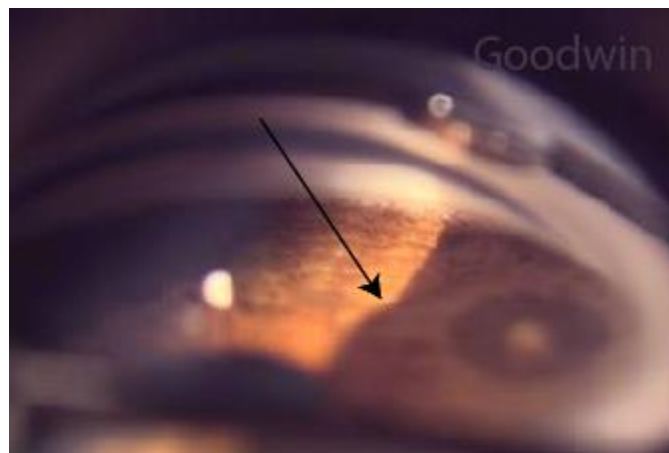


Figure 21 shows a concave iris. Note how the iris can be seen to bow posteriorly evidenced by the bending of the edge of the light (arrow).

Hyperopic patients are more likely to have a convex iris putting the patient at increased risk for angle closure glaucoma. On first glance, the image in Figure 22 may appear to have ciliary body present. If the image was being viewed in depth, it would be evident

that the dark structure that is first encountered as you follow the iris toward the angle is not ciliary body. Notice that scleral spur is not visible next to the dark area and that the trabecular meshwork appears narrower than in other angles. The dark area is actually a shadow created by the convex iris. Only  $\frac{1}{2}$  of the trabecular meshwork is present.

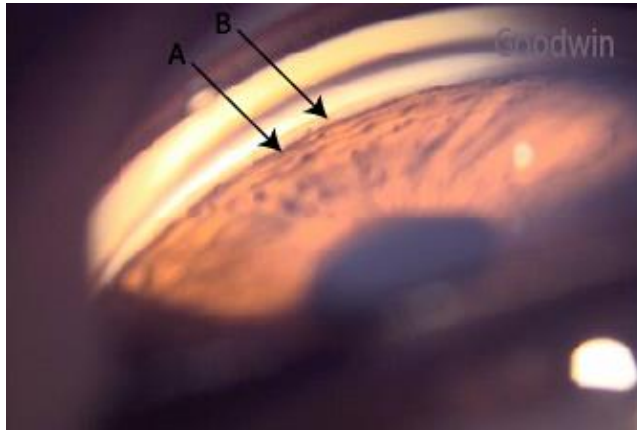


Figure 22 shows a convex iris. Note the shadow caused by the iris (A) and the narrow area of trabecular meshwork (B).

Figure 23 shows a patient with posterior embryotoxon, a prominent Schwalbe's line. In patients with posterior embryotoxon, Schwalbe's line is often visible during a routine slit lamp examination as a white line in the peripheral cornea which is more visible nasally and temporally. It is also common in patients with posterior embryotoxon to find iris processes that extend beyond the scleral spur. As seen in Figure 23, iris processes can extend all the way to Schwalbe's line.

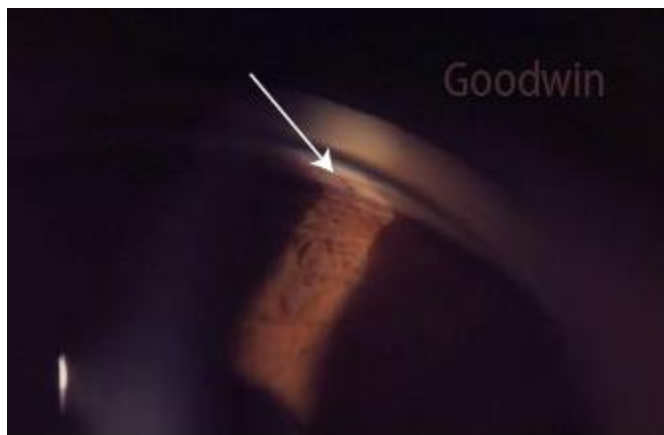

Figure 23 shows a patient with posterior embryotoxon. Note that the iris process extends to Schwalbe's line.

Because Schwalbe's line is a ridge, it is not uncommon to find pigment along Schwalbe's line (Figure 24). This pigment deposition is called Sampaolesi's line.




Figure 24 shows a patient with pigment along Schwalbe's line (Sampaolesi's line).

Sampaolesi's line is especially prominent in cases of exfoliation syndrome. In addition to pigment along Schwalbe's line, exfoliation syndrome is associated with increased pigmentation in the trabecular meshwork and exfoliative material in the trabecular meshwork and along the pupil border (Figure 25).

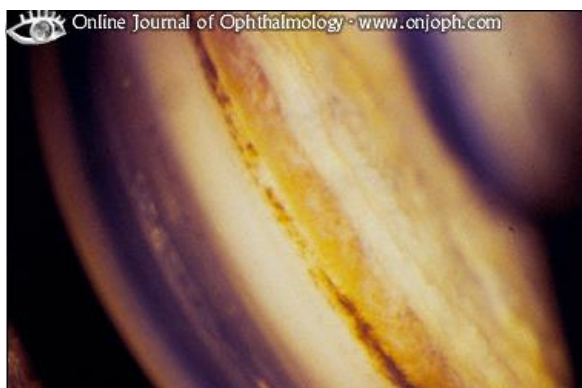




Figure 25 shows a patient with exfoliation syndrome. Note the increased pigment and exfoliative material in the trabecular meshwork. (Image from <http://www.atlasophthalmology.com>)

The amount of pigment in the trabecular meshwork should be evaluated in patients with pigment dispersion syndrome. Figure 26 shows the angle of a young female with pigment dispersion syndrome. Without careful inspection, some may mistake this heavily pigmented trabecular meshwork for ciliary body. The ciliary body is lighter brown than the trabecular meshwork and is obscured by many iris processes. Scleral spur is evident between the ciliary body and trabecular meshwork. Although the posterior area of the trabecular meshwork is heavily pigmented, the anterior trabecular meshwork remains relatively unaffected in some areas. Despite the extensive pigmentation of the trabecular meshwork, this patient demonstrated no evidence of glaucoma. She did, however, have prominent Krukenberg spindle and iris transillumination defects.

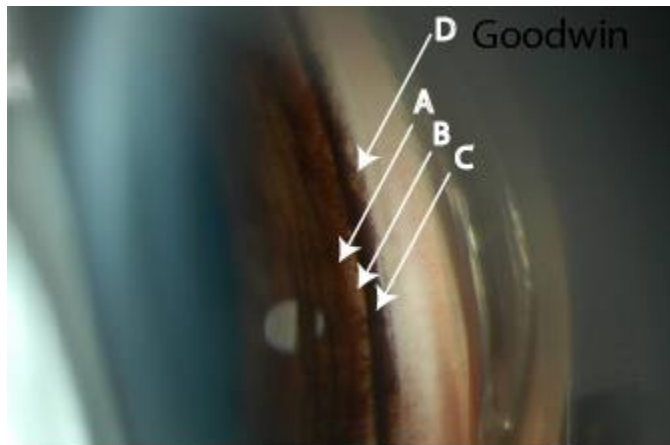


Figure 26 shows a patient with pigment dispersion syndrome. Note the dense pigment in the trabecular meshwork (C). Also note the pigment obscuring the ciliary body (A) and scleral spur (B). Schwalbe's line is to the right of arrow (D).

Normal blood vessels are found in the anterior chamber angle in 62% of blue eyes and 9% of brown eyes.<sup>19</sup> The major circle of the iris runs circumferentially. Radial branches may also be seen in the iris stroma. It is rare to see a blood vessel run the entire quadrant length of the angle as shown in Figure 27. More commonly a small segment of the blood vessel will be seen (See Figure 28).

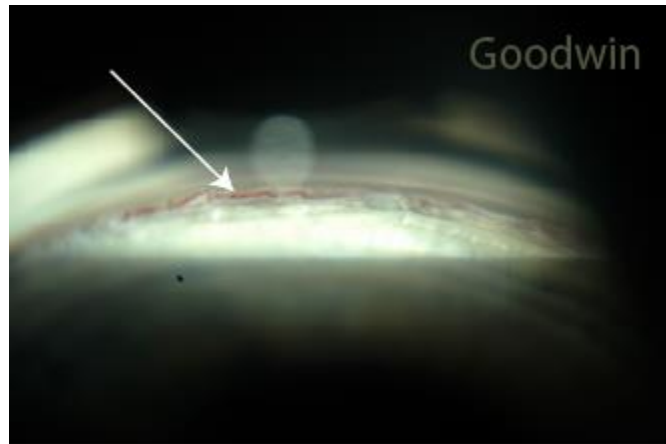


Figure 27 shows a large branch of the major circle of the iris.




Figure 28 shows a small area of the major circle of the iris visible with gonioscopy.

It is important to differentiate normal blood vessels from neovascularization of the angle. Normal iris blood vessels are never attached to structures anterior to the scleral spur. Normal blood vessels also are thick and have a definite pattern (circumferential or radial). Neovascular vessels are more feathery and have an erratic pattern. The neovascular blood vessels in Figure 29 are seen to extend past the scleral spur into the trabecular meshwork. They also are thinner and do not follow the typical radial or circumferential pattern of iris blood vessels.

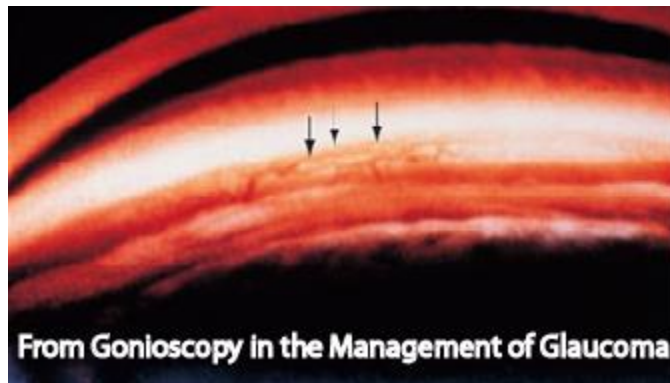


Figure 29 demonstrates neovascularization in the anterior chamber angle in a eye with diabetic retinopathy (Image from Gonioscopy in the Management of Glaucoma).<sup>20</sup>

Looking at the anterior chamber angle you can determine the accessibility of the aqueous to the trabecular meshwork. With Van Herrick method, a patient is at risk for angle closure with pupil dilation when the width of the shadow is  $\frac{1}{4}$  or less the width of the corneal optic section (grade 2 or less). Gonioscopy should be performed on these patients. If the posterior trabecular meshwork is present in at least  $180^\circ$  of the anterior chamber angle, the person is typically considered safe for pupil dilation.

Figures 30A and 30B shows the nasal and temporal angles as measured with Van Herrick in a 35 year old hyperopic, Caucasian female with a past diagnosis of migraines. Only a trace to  $\frac{1}{4}$  of trabecular meshwork is present with gonioscopy in the nasal angle (See Figure 30C) and a trace of trabecular meshwork was present in the inferior angle (See Figure 30D).




Figure 30 show a patient with subacute angle closure glaucoma. The angles are narrow with Van Herrick estimation (A and B). Only a portion of the trabecular meshwork is visible with gonioscopy (C and D).

In patients with narrow angles, the ciliary body and scleral spur are no longer observable landmarks, and it is difficult to determine if trabecular meshwork or Schwalbe's line is visible. In these cases, Schwalbe's line is most easily found using a narrow beam of light

and observing the cornea through the gonioscopy lens. Move the illumination arm of the biomicroscope to approximately 20° from the oculars. The slit of light will then appear to split into 2 beams, one from the posterior cornea and one from the anterior cornea. The position in which the anterior and posterior corneal light bands appear to converge is the position of Schwalbe's line (See Figure 31A). If the corneal light band are not seen coming together prior to being obscured by the iris, no anterior chamber angle structures are visible (See Figure 31B).

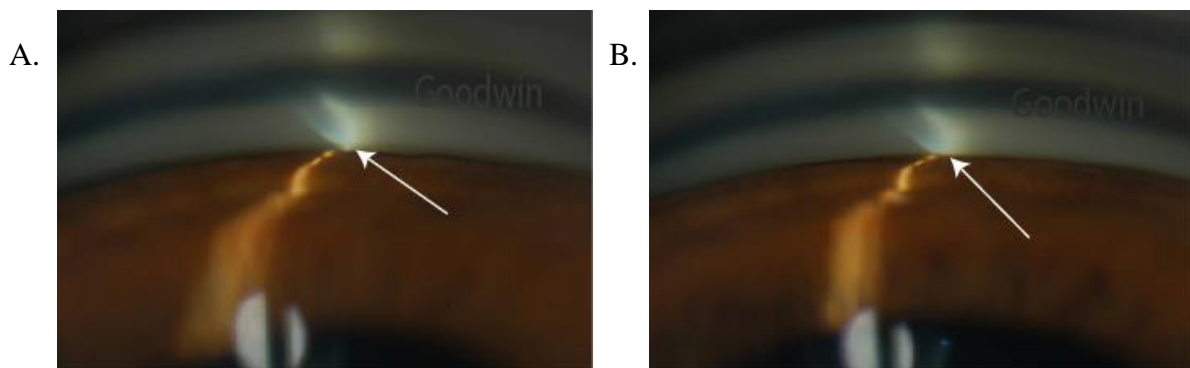


Figure 31 demonstrates the corneal wedge that can be used to determine the position of Schwalbe's line. Schwalbe's line is located where the two light beams come together (A). Note that in the right image (B), you cannot see the position that the beams join; therefore, no angle structures are visible.

People of Alaskan or Asian decent, hyperopic patients, and females are at higher risk for angle closure glaucoma.<sup>21</sup> Also, increased age and changes to the crystalline lens, such as increased lens thickness and cataracts, put the patient at increased risk for developing angle closure glaucoma. Laser iridotomy is appropriate for patients with extremely narrow angles (Figure 32).

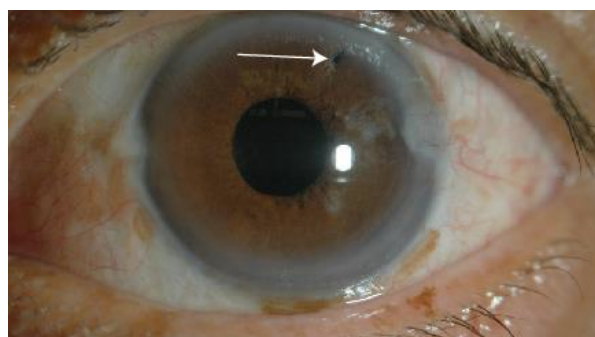


Figure 32 shows a patient following an iridotomy procedure (arrow).

As in the patient presented above, symptoms of migraines can be very similar to that of subacute angle closure glaucoma and are, therefore, often misdiagnosed.<sup>22</sup> Both conditions will cause unilateral headaches around the eye and can be associated nausea and visual symptoms. These patients have often seen a primary care physician or neurologist prior to reporting the symptoms at an eye examination. A delay in diagnosis may lead to irreversible vision loss so it is critical that the correct diagnosis is made in a timely manner.

Angle recession occurs when the ciliary muscle has been torn due to blunt trauma (See Figure 33). The ciliary body is typically the same size as the scleral spur and trabecular meshwork combined. If the ciliary body is wider than normal, suspect an angle recession. Also, a cobwebby appearance or visualization of the sclera posterior to the ciliary body may be present in patients with angle recession. Iridodialysis, where the iris is completely torn from the ciliary body, may also be present after severe trauma to the eye.

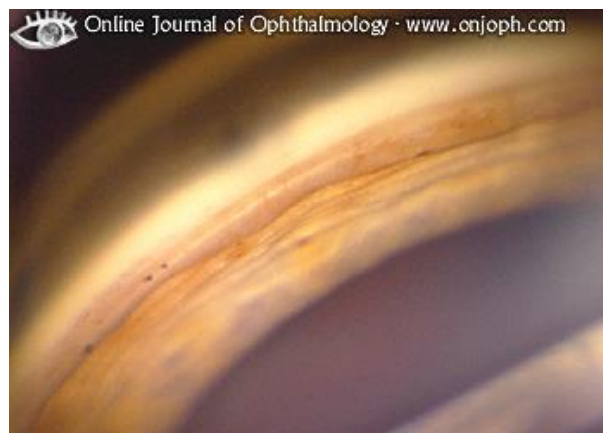

Figure 33 shows a patient with an angle recession. (Image from <http://www.atlasophthalmology.com>)

Anterior synechiae, adhesions of the iris to the trabecular meshwork, may form following uveitis or an angle closure attack (See Figure 34). Synechiae that are caused from angle closure are most often found in the superior quadrant since the superior angle is the narrowest. Synechiae associated with inflammation are more commonly found in the inferior angle due to increased inflammatory debris gravitationally moving downward. It is important to differentiate between synechiae and a closed angle. Pushing on the eye with a non-suction gonioscopy lens will push the aqueous to the peripheral area of the anterior chamber. This will cause the iris to bow posteriorly and widen the anterior chamber. If synechiae are present, the iris will remain permanently opposed to the trabecular meshwork. An anatomically narrow angle will appear wider.

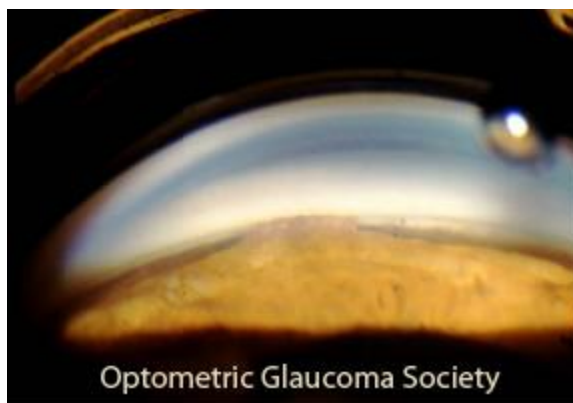


Figure 34 shows a patient with anterior synechiae. (Image from Optometric Glaucoma Society E-Journal)<sup>22</sup>

Gonioscopy is an excellent way to evaluate elevated areas of the iris. The iris cyst shown in Figure 35 was found on routine slit lamp examination. As shown in Figure 35A, there is a focal shallowing of the anterior chamber where the iris is raised in the inferior of the view. Figure 35B shows the same area with gonioscopy. It is easy to distinguish the area of elevation with gonioscopy. It is critical to differentiate iris cysts from a neoplasia. Note that there is no distortion of the iris architecture or aberrant blood vessels. Iris cysts can be monitored for progression or collapsed by penetrating the cyst with a YAG laser. It is also important to watch for angle closure in these patients.




Figure 35 shows a patient with an iris cyst as shown with slit lamp examination (A) and gonioscopy (B).

In cases of malignant melanoma of the ciliary body, the ciliary body will appear abnormally dark (See Figure 36). Compare to the size and coloration of the ciliary body to that in the other eye looking for symmetry.

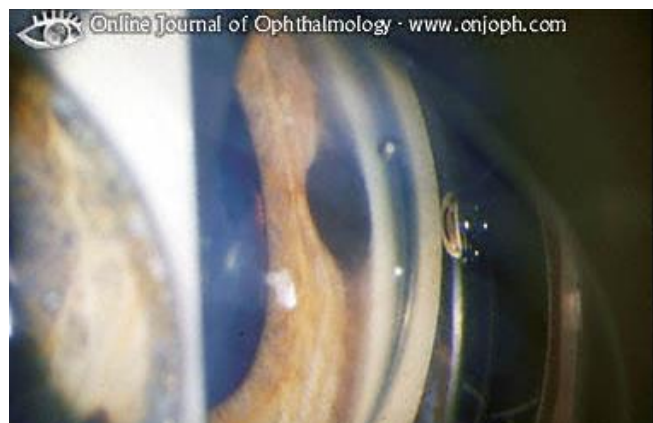




Figure 36 shows a patient with a melanocytoma of the iris. (Image from <http://www.atlasophthalmology.com>)

Wilson's disease is a genetic disorder affecting copper metabolism. Copper excretion is reduced, and excess copper accumulates in the liver. If untreated, the condition can be fatal. Copper also accumulates in the peripheral cornea (Kayser-Fleisher rings) and the lens (See Figure 37).

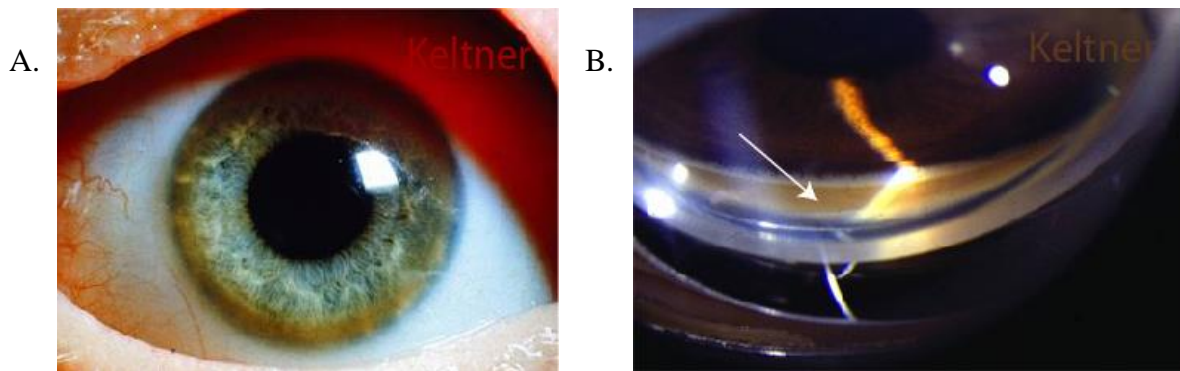


Figure 37 shows a patient with copper deposits in the cornea secondary to Wilson's disease. The copper deposits can be seen with slit lamp examination (A) and gonioscopy (B).

When there is a suspicion of an intraocular foreign body, gonioscopy should be performed to look for debris that may not be visible with biomicroscopy alone. Figures 38 and 39 show patients with material in the anterior chamber.

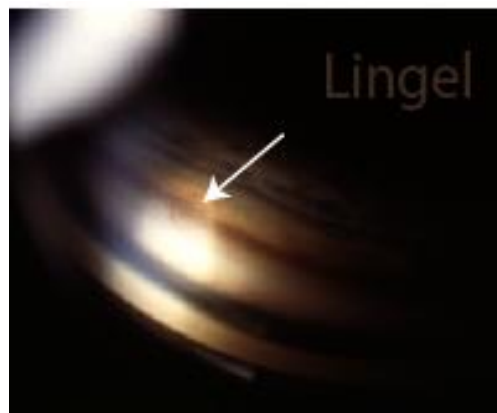


Figure 38 shows a detached iris cyst in the anterior chamber (arrow).

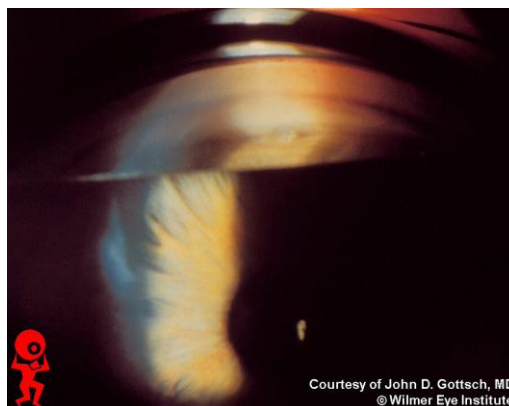


Figure 39 shows a patient with a piece of glass in the anterior chamber. (Image from <http://www.redatlas.com>)

### **Conclusion:**

Gonioscopy is often neglected, especially if the patient does not appear to have a narrow angle with slit lamp examination. However, it is an essential diagnostic tool that aids in diagnosis of many condition including glaucoma, ocular trauma and inflammation, iris abnormalities, intraocular foreign bodies, and conditions that cause ocular ischemia, including diabetes.

## References:

1. Fremont AM, Lee PP, Mangione CM, Kapur K, Adams JL, Wickstrom SL, Escarce JJ. Patterns of care for open-angle glaucoma in managed care. *Archives of Ophthalmology* 2003;121:777-83.
2. Choong YF, Devarajan N, Pickering A, Pickering S, Austin MW. Initial management of ocular hypertension and primary open-angle glaucoma: an evaluation of the royal college of ophthalmologists' guidelines. *Eye* 2003;17:685-90.
3. Coleman AL, Yu F, Evans SJ. Use of gonioscopy in medicare beneficiaries before glaucoma surgery. *Journal of Glaucoma* 2006;15:486-93.
4. Kanadani FN, Dorairaj S, Langlieb AM, et al. Ultrasound biomicroscopy in asymmetric pigment dispersion syndrome and pigmentary glaucoma. *Archives of Ophthalmology* 2006;124:1573-6.
5. Scheie HG, Cameron JD. Pigment dispersion syndrome: a clinical study. *British Journal of Ophthalmology* 1981;65:264-9.
6. Lichter PR. Iris processes in 340 eyes. *American Journal of Ophthalmology* 1969;68:872-8.

7. Casser L, Fingeret M, Woodcome HT. Atlas of primary eyecare procedures 2<sup>nd</sup> ed. Stamford: Appleton & Lange, 1997:239.
8. Kunimatsu S, Tomidokoro A, Mishima K, Takamoto H, Tomita G, Iwase A, Araie M. Prevalence of appositional angle closure determined by ultrasonic biomicroscopy in eyes with shallow anterior chambers. *Ophthalmology* 2005;112:407-12.
9. Leung CK, Cheung CY, Li H, Dorairaj S, Yiu CK, Wong AL, Liebmann J, Ritch R, Weinreb R, Lam DS. Dynamic analysis of dark-light changes of the anterior chamber angle with anterior segment OCT. *Investigative Ophthalmology & Visual Science* 2007;48:4116-22.
10. Barkana Y, Dorairaj SK, Gerber Y, Liebmann JM, Ritch R. Agreement between gonioscopy and ultrasound biomicroscopy in detecting iridotrabecular apposition. *Archives of Ophthalmology* 2007;125:1331-5.
11. Chang DS, Sakata LM, Aung T, et al. Single versus sequential testing with scanning peripheral anterior chamber depth analyser, IOLMaster and anterior segment optical coherence tomography for the detection of narrow angles. *Br J Ophthalmol* 2011;95(10):1410-4.

12. Khor WB, Sakata LM, Friedman DS, et al. Evaluation of scanning protocols for imaging the anterior chamber angle with anterior segment-optical coherence tomography. *J Glaucoma* 2010;19(6):365-8.
13. Lavanya R, Foster PJ, Sakata LM, et al. Screening for narrow angles in the singapore population: Evaluation of new noncontact screening methods. *Ophthalmology* 2008;115(10):1720-7.
14. Park SB, Sung KR, Kang SY, et al. Assessment of narrow angles by gonioscopy, van herick method and anterior segment optical coherence tomography. *Jpn J Ophthalmol* 2011;55(4):343-50.
15. Cheon MH, Sung KR, Choi EH, et al. Effect of age on anterior chamber angle configuration in asians determined by anterior segment optical coherence tomography; clinic-based study. *Acta Ophthalmologica* 2010;88(6):e205-10.
16. Narayanaswamy A, Sakata LM, He MG, et al. Diagnostic performance of anterior chamber angle measurements for detecting eyes with narrow angles: An anterior segment OCT study. *Arch Ophthalmol* 2010;128(10):1321-7.
17. Wang D, Pekmezci M, Basham RP, et al. Comparison of different modes in optical coherence tomography and ultrasound biomicroscopy in anterior chamber angle assessment. *J Glaucoma* 2009;18(6):472-8.

18. Wong HT, Lim MC, Sakata LM, et al. High-definition optical coherence tomography imaging of the iridocorneal angle of the eye. *Arch Ophthalmol* 2009;127(3):256-60.
19. Henkind P. Angle vessels in normal eyes. A gonioscopic evaluation and anatomic correlation. *British Journal of Ophthalmology* 1964;48:551-7.
20. Savage JA. Gonioscopy in the management of glaucoma. *American Academy of Ophthalmology Focal Points: Clinical Modules for Ophthalmologists*; 2006;24:1-14.
21. He M, Foster PJ, Ge J, Huang W, Wang D, Friedman DS, Khaw PT. Gonioscopy in adult Chinese: the Liwan Eye Study. *Investigative Ophthalmology & Visual Science* 2006;47:4772-9.
22. Neshet R, Hering-Hanit R, Neshet G. Subacute glaucoma masquerading as migraine. How to avoid the pitfall and make the diagnosis. *Postgraduate Medicine* 2006;119:70-3.
22. McSoley J. Optometric Glaucoma Society E-Journal. Available at <http://www.optometricglaucomasociety.org/EJSupp/Gonio.html>. Accessed 29 January 2012.