

# Classification of pediatric urinary tract dilation: the new language

Jeanne S. Chow<sup>1,2</sup> · Jeffrey L. Koning<sup>2</sup> · Susan J. Back<sup>3</sup> · Hiep T. Nguyen<sup>4</sup> · Andrew Phelps<sup>5</sup> · Kassa Darge<sup>3</sup>

Received: 10 January 2017 / Revised: 27 February 2017 / Accepted: 28 April 2017 / Published online: 2 August 2017  
© Springer-Verlag Berlin Heidelberg 2017

**Abstract** The multidisciplinary consensus on the classification of prenatal and postnatal urinary tract dilation (UTD classification system) was created to unify the language used to describe urinary tract dilation on antenatal and postnatal ultrasound examinations and thereby facilitate communication among providers and improve outcomes research. The background and new classification system are described in this review, with imaging examples.

**Keywords** Bladder · Children · Hydronephrosis · Kidney · Ultrasound · Ureter · Urinary tract

## Introduction

Urinary tract dilation (UTD) is present on 1–2% of obstetrical ultrasound (US) examinations [1]. The presence and description of fetal urinary tract dilation are variably conveyed to those caring for the newborn. This lack of optimal communication is multifactorial: fetal health care professionals might not know which pediatricians and specialists ultimately assume care of the baby, postnatal providers might not have access to the reports or images from prenatal US examination, and imaging specialists' terminology to describe the urinary tract varies considerably.

A recent survey showed that pediatric radiologists do not have a standard method to describe urinary tract dilation. For example, many antenatal imagers use the term “pyelectasis” to describe the dilation of the renal pelvis, whereas postnatal imagers use terms such as “pelviectasis” and “hydronephrosis” to describe the same finding [2]. Antenatal imagers often do not describe calyceal dilation, partially because this anatomy can be too small to resolve by fetal US. The anterior-posterior renal pelvic diameter (APRPD) is frequently measured and recorded on obstetrical US exams and therefore normal fetal values are well established [3–5]. Because renal and bladder US exams are performed for clinical indications, reported normal anterior-posterior renal pelvic diameter values are based on smaller sample sizes and are less widely used [6–8]. Postnatal imagers rarely measure and report anterior-posterior renal pelvic diameter and inconsistently describe calyceal dilation [2].

The intended meaning of the terminology used to describe antenatal and postnatal urinary tract imaging can be unclear to pediatricians and specialists, which further confounds patient care. Does pelviectasis require follow-up and additional imaging? Is pelvicaliectasis the same as hydronephrosis? Does hydronephrosis mean obstruction? These are only a few of the questions that arise. In an attempt to better describe the urinary

✉ Jeanne S. Chow  
Jeanne.chow@childrens.harvard.edu

<sup>1</sup> Department of Urology,  
Boston Children's Hospital,  
300 Longwood Ave., Boston, MA 02115, USA

<sup>2</sup> Department of Radiology,  
Boston Children's Hospital,  
Boston, MA, USA

<sup>3</sup> Department of Radiology, The Children's Hospital of Philadelphia,  
Perelman School of Medicine,  
University of Pennsylvania,  
Philadelphia, PA, USA

<sup>4</sup> Banner Children's Specialists,  
Cardon Children's Medical Center,  
Mesa, AZ, USA

<sup>5</sup> Department of Radiology,  
UCSF Benioff Children's Hospital,  
San Francisco, CA, USA

**Table 1** Prenatal urinary tract dilation (UTD) classification<sup>a</sup> for UTD A1 and UTD A2–3

	UTD A1		UTD A2–3
APRPD 16–27 weeks	<4 mm	4–7 mm	≥7 mm
APRPD ≥28 weeks	<7 mm	7–10 mm	≥10 mm
Calyceal dilation	None	Central or none	Peripheral <sup>b</sup>
Parenchymal thickness	Normal	Normal	Abnormal
Parenchymal appearance	Normal	Normal	Abnormal
Ureters	Normal	Normal	Abnormal
Bladder	Normal	Normal	Abnormal
Oligohydramnios	None	None	Unexplained <sup>c</sup>

<sup>a</sup> Classification is based on the presence of the most concerning feature. For example, a fetus with an anterior posterior renal pelvic diameter (APRPD) within the UTD A1 range but with ureteral dilation would be classified as UTD A2–3

<sup>b</sup> Central versus peripheral calyceal dilation can be difficult to assess early in gestation

<sup>c</sup> Oligohydramnios thought to be the result of a genitourinary cause

tract, various classification systems had been developed, but none created a common language between antenatal and postnatal findings [9–13].

As pediatric radiologists, we evaluate both fetuses and children and would like to provide a clear assessment of the urinary tract to help guide patient management. The new multidisciplinary consensus on the classification of prenatal and postnatal urinary tract dilation (UTD classification system) described here facilitates that goal [14] because it unifies the terminology for urinary tract dilation in the fetus and infant.

## The UTD classification system

The UTD classification system was created by representatives from eight societies who participate in the diagnosis and

management of fetuses and children with urinary tract dilation, including the following: American College of Radiology (ACR), American Institute of Ultrasound in Medicine (AIUM), American Society of Pediatric Nephrology (ASPN), Society for Fetal Urology (SFU), Society for Maternal-Fetal Medicine (SMFM), Society for Pediatric Urology (SPU), Society for Pediatric Radiology (SPR) and Society of Radiologists in Ultrasound (SRU). These representatives made recommendations based on combining the current literature on imaging and best practices of antenatal and postnatal urinary tract dilation.

The UTD classification system uses six US findings to describe the antenatal and postnatal urinary tract: (1) anterior-posterior renal pelvic diameter (APRPD), (2) calyceal dilation with distinction between central and peripheral calyces postnatally, (3) renal parenchymal thickness, (4) renal parenchymal appearance, (5) bladder abnormalities and (6) ureteral abnormalities (Tables 1 and 2). In the fetus, the quantity of amniotic fluid is also evaluated. To avoid the confusion associated with the implied meanings of various terms for urinary dilation, the consensus panel recommended using the term “dilation” and avoiding nonspecific terms such as hydronephrosis, pyelectasis, pelviectasis and pelvic fullness.

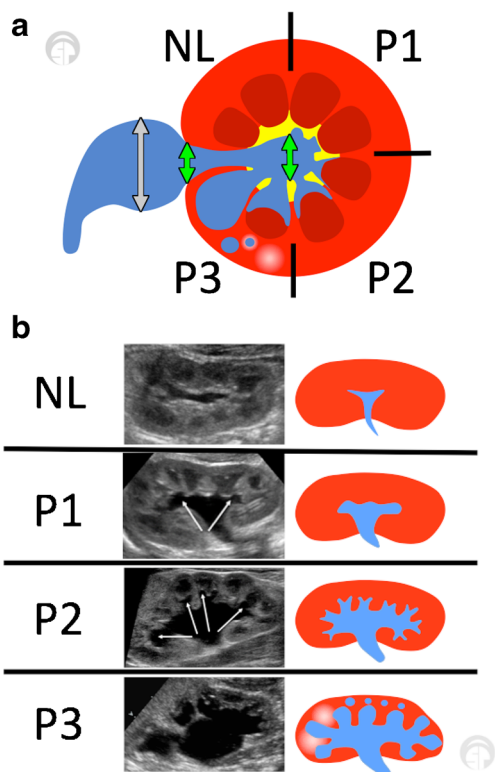
The anterior-posterior renal pelvic diameter is the maximal intrarenal diameter of the renal pelvis taken in the transverse plane (Fig. 1). The measurement is made at the diameter of greatest distension of the renal pelvis, which is not necessarily at the parenchymal tip on the transverse scan. The largest measurement of the renal pelvis should be the one used for the purpose of UTD classification, and this measurement can be made anywhere within the renal pelvis bordered by renal parenchyma in the transverse plane. Measurement of the extrarenal pelvis is not regarded as anterior-posterior renal pelvic diameter. In the fetus, this is classically performed with the “spine up” — or closest to the transducer. In the infant, we recommend that this measurement be made in the prone

**Table 2** Postnatal urinary tract dilation (UTD) classification<sup>a</sup> for UTD P1, UTD P2 and UTD P3

	Normal	UTD P1	UTD P2	UTD P3
APRPD	<10 mm	≥10–15 mm	≥15 mm	≥10 mm
Calyceal dilation	None	Central only	Peripheral	– <sup>b</sup>
Parenchymal thickness	Normal	Normal	Normal	Abnormal
Parenchymal appearance	Normal	Normal	Normal	Abnormal
Ureters	Normal	Normal	Abnormal	– <sup>b</sup>
Bladder	Normal	Normal	Normal	Abnormal

<sup>a</sup> Classification is based on the most concerning ultrasound finding. For example, if the anterior posterior renal pelvic diameter (APRPD) is in the UTD P1 range but there is peripheral calyceal dilation, the classification is UTD P2. The presence of parenchymal abnormalities denotes UTD P3 classification as long as there is urinary tract dilation

<sup>b</sup> Calyceal dilation and ureteral dilation, although frequently present in patients with UTD P3, are not necessarily needed to qualify for UTD P3 if there is urinary tract dilation with either abnormal parenchymal thickness, abnormal parenchymal appearance or abnormal bladder



**Fig. 1** Schematic illustration of urinary tract dilation (UTD) classification shows a transverse view of mid/interpolar kidney. **a** The green arrows indicate acceptable locations for measuring the anterior-posterior renal pelvic diameter, which can be measured anywhere within the renal pelvis bordered by renal parenchyma visualized during prone imaging. Measurements of the extrarenal pelvis should not be included. The largest measurement should be the one used for the purpose of UTD classification. The gray arrow indicates the anterior-posterior diameter of the extrarenal pelvis, which should not be used for UTD classification. The different degrees of calyceal dilation are shown in clockwise fashion. The upper left corner shows normal (NL), where fluid is confined to the pelvis. The upper right corner shows UTD P1 (P1), where there are varying degrees of central calyceal dilation. The lower right corner shows UTD P2 (P2), where there are varying degrees of peripheral calyceal dilation, with fluid cupping around the medullary pyramid. The lower left corner shows UTD P3 (P3), where the renal parenchyma is hyperechoic, cystic and thinned. Although this schematic illustration shows progressive increases in calyceal dilation, note that the definition of UTD P3 is based on abnormal parenchyma or bladder appearance in addition to UTD. **b** The longitudinal appearances of the UTD classifications are shown in tabular format, with side-by-side US and schematic images. Note that the renal pelvic diameter is not measured in the longitudinal plane. The P1 category demonstrates central calyceal dilation and the P2 category demonstrates peripheral calyceal dilation (arrows). The P3 category shows abnormal parenchymal thickness with cystic changes in the parenchyma

position because the prone position tends to exaggerate the distension of the renal pelvis. However if measurements are more accurate in the supine position, that should be used.

Central and peripheral calyces are terms that the UTD consensus committee created to avoid the potentially confusing interpretation of “major” and “minor”

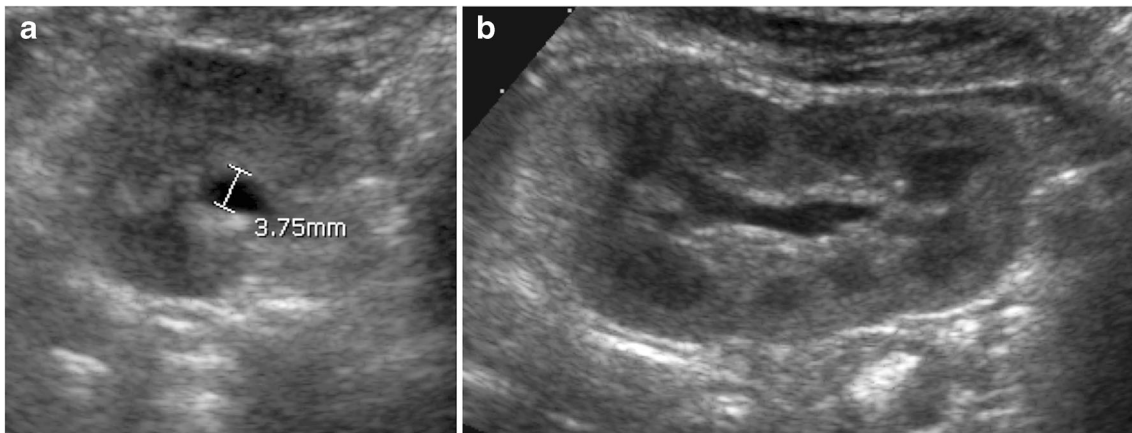
calyceal dilation (Fig. 1). If one were to communicate that there is “major calyceal dilation,” this might be misinterpreted as severe calyceal dilation. Minor calyces are peripheral and cup the tips of the medullary pyramids. Two or three minor calyces converge to form a major calyx. Major calyces are more centrally located and equivalent to the infundibula. The consensus panel used the anatomical location to newly describe the major calyces as central calyces and minor calyces as peripheral calyces. Of course, dilation is in a continuum and it is not always possible to exactly distinguish central from peripheral calyceal dilation, and in different positions the degree of distension might change. Thus it is appropriate to use the description of the most severe finding.

When describing ureteral dilation, either all or part of the ureter should be consistently dilated. A transient mild dilation of the ureter from peristalsis is not regarded as pathological ureteral dilation. An extrarenal pelvis should not be confused with proximal ureteral dilation. Unfortunately there are no standard cut-off measurements for defining ureteral dilation. A normal ureter is not constantly dilated, thus the label “ureteral dilation” is subjective without actual measurement of ureteral diameter. A ureteral dilation in the absence of pelvicalyceal dilation — i.e. anterior-posterior renal pelvic diameter <10 mm and no calyceal dilation — is not included in this classification system, which has as its primary premise the dilation of the renal pelvis or renal calyx.

The UTD classification system distinguishes antenatal from postnatal findings, where the higher numbers (UTD 1–3) indicate greater risk of underlying or developing uropathy. Because urinary tract abnormalities are more subtle and difficult to visualize on fetal versus pediatric US examination (e.g., distinguishing peripheral versus central calyces), there are only three antenatal categories (normal, UTD A1, UTD A2–3), compared to four postnatal categories (normal, UTD P1, UTD P2 and UTD P3; Figs. 2, 3, 4, 5).

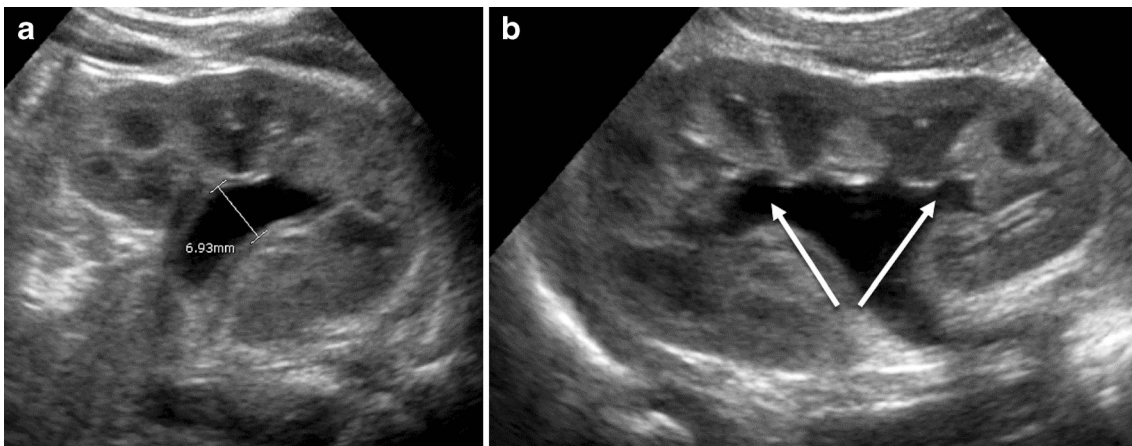
Concluding that a kidney appears normal is as important as describing an abnormality. The UTD classification system encourages the use of the word “normal” in the impression to prevent unnecessary follow-up, imaging or familial anxiety. However, describing the appearance of a normal urinary tract does not preclude the existence of underlying urological abnormalities, specifically reflux. It is well known that a normal renal and bladder US does not exclude vesicoureteral reflux [15]. Conversely, prenatal urinary tract dilation even of varied degrees does not increase the risk of reflux [16].

The antenatal classification was based on the common current practice of obstetrical imagers where findings are interpreted based on whether they occur earlier



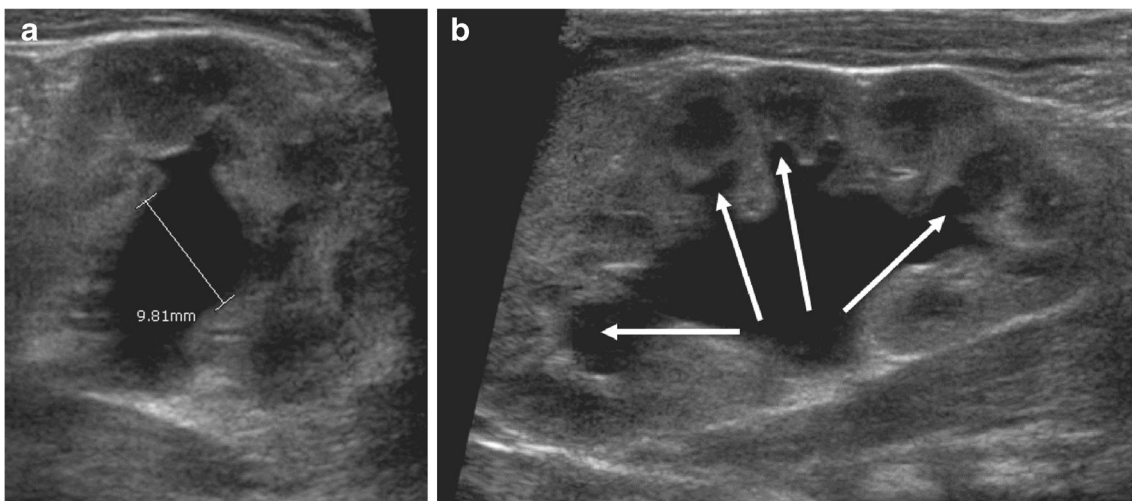
**Fig. 2** Postnatal US examination in a 6-week-old boy with normal kidneys. **a** Transverse US demonstrates an anterior posterior renal pelvic diameter <10 mm, which is normal. The anterior-posterior renal pelvic diameter is measured at the maximal diameter of intrarenal pelvis,

which in this case is at the mid-intrarenal pelvis. **b** Sagittal US demonstrates normal renal parenchyma without any calyceal dilation. The bladder was normal (not shown) and the ureters were not dilated



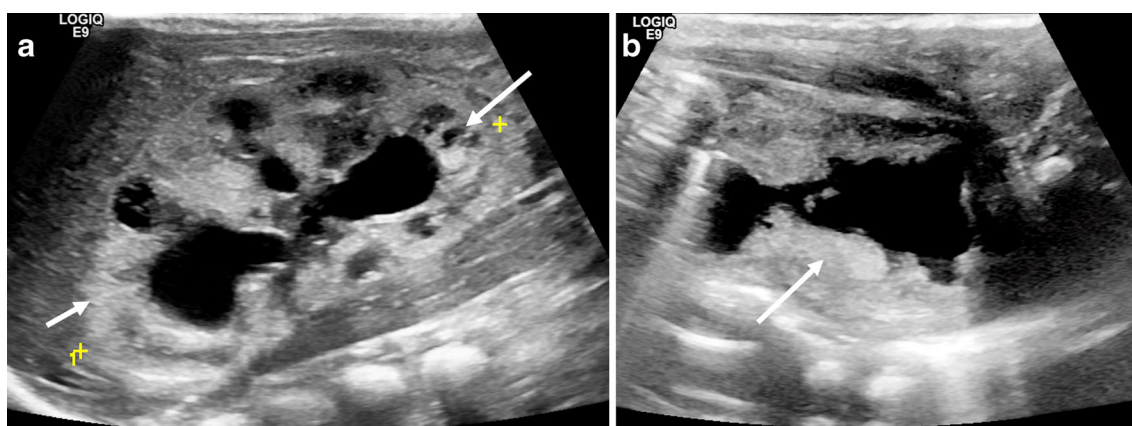
**Fig. 3** Postnatal US examination in a 4-week-old girl with urinary tract dilation (UTD) P1. **a** Transverse US demonstrates an APRPD <10 mm. **b** Sagittal US demonstrates central calyceal dilation (*arrows*). The renal

parenchyma is otherwise normal. The bladder was normal and the ureters were not dilated (not shown). APRPD anterior posterior renal pelvic diameter



**Fig. 4** Postnatal US examination in a 5-week-old girl with urinary tract dilation (UTD) P2. **a** Transverse US demonstrates an APRPD <10 mm. **b** Sagittal US demonstrates peripheral (*arrows*) and central calyceal

dilation. The renal parenchymal thickness and appearance are normal. In addition, there were no bladder abnormalities and the ureters were not dilated (not shown). APRPD anterior-posterior renal pelvic diameter



**Fig. 5** Postnatal US examination in a 6-day-old boy with urinary tract dilation (UTD) P3. **a** Sagittal US of the right kidney demonstrates pelvic, central and peripheral calyceal dilation. The renal parenchyma is echogenic (*short arrow*) with small cortical

cysts (*long arrow*). **b** The bladder (seen in the sagittal plane) has a thick and trabeculated wall (*arrow*). The boy was later diagnosed with posterior urethral valves

(16–27 weeks) or later (>28 weeks) in gestation. The system was predicated on the anterior-posterior renal pelvic diameter and calyceal dilation. Normal anterior-posterior renal pelvic diameter values are less than 4 mm before 28 weeks and less than 7 mm after 28 weeks of gestation. If the only abnormal finding of the urinary tract is increased anterior-posterior renal pelvic diameter (4 to <7 mm early in gestation; 7 to <10 mm later in gestation) or central calyceal dilation, then the urinary tract is classified as UTD A1. If the anterior-posterior renal pelvic diameter is >7 mm early or >10 mm later in gestation or there is peripheral calyceal dilation, then the kidney is upgraded to UTD A2–3. Any abnormal pelvic dilation combined with renal parenchymal abnormality (in thickness and appearance) or bladder abnormality and oligohydramnios secondary to poor renal function upgrade the kidney to a UTD A2–3. Ureteral dilation, even without pelvic dilation, is automatically a UTD A2–3 (Table 1).

With the exception of severe antenatal findings, the first postnatal US examination should occur at least 48 hours or more after birth to avoid underestimating the degree of urinary tract dilation during a time of normal physiological oliguria. The criteria of the postnatal classification are applied regardless of the child’s age. A normal kidney has an anterior-posterior renal pelvic diameter less than 10 mm measured in the transverse plane and there should be no calyceal or ureteral dilation. Normal renal echotexture depends on gestational age, although it should be iso- to hypoechoic to the adjacent solid organ at term or within the first few months of age. The classification system distinguishes dilation of central (major) calyces from peripheral (minor) calyces (Fig. 3 and Fig. 4). Again the system

was predicated on the anterior-posterior renal pelvic diameter and calyceal dilation. Stratification is based on the most concerning US finding. If the renal pelvis measures between 10 mm and 15 mm or there is central calyceal dilation, then the urinary tract is graded UTD P1. If the anterior-posterior renal pelvic diameter >15 mm or peripheral calyces are dilated then it is categorized as UTD P2. Because stratification is based on the most concerning US finding, ureteral dilation with pelvic dilation greater than 10 mm is UTD P2. If the renal parenchyma is of abnormal echogenicity or thickness or bladder is abnormal when there is urinary tract dilation, the urinary tract is upgraded to UTD P3 (Fig. 5, Table 2). If the parenchyma is abnormal and there is no pelvic or calyceal dilation (e.g., autosomal-recessive polycystic kidney disease or multicystic dysplastic kidney), then the kidney does not meet criteria to be classified by this system.

When reporting urinary tract dilation, a description of the six US imaging parameters should be included in the body of the report. The specific UTD category (normal, UTD A1, UTD A2–3, UTD P1, UTD P2 or UTD P3) should be in the impression. We recommend that the UTD nomenclature not replace the descriptions of the abnormality in the impression of the report. For example, the impression might be “UTD P2 based on pelvic, calyceal and ureteral dilation, which raises the concern for ureterovesical junction obstruction or reflux.” Ideally, US images should accompany the report.

The consensus statement also proposed a management algorithm based on the antenatal and postnatal classifications (Tables 3 and 4). Because the consensus was based on current but limited literature there was not enough evidence to assess the risk of uropathy based on

**Table 3** Management schema based on urinary tract dilation (UTD) classification system's risk stratification of UTD A1 and UTD A2-3

	UTD A1 (low risk)	UTD A2-3 (increased risk)
Prenatal period	One additional US examination at $\geq 32$ weeks	Initial US exam in 4–6 weeks
After birth	Two additional US examinations: 1. >48 h to 1 month 2. 1–6 months later	US exam at >48 h to 1 month*
Other	Aneuploidy risk modification if indicated	Specialist consultation, e.g., nephrology, urology

\*Certain situations such as posterior urethral valves or bilateral severe hydronephrosis, for example, might require more expedient management

gender or laterality. This system and the management recommendations are expected to be validated and modified with experience.

### Current literature using the UTD classification system

The UTD grading system correlates with the risk of postnatal uropathy [14]. Since the original consensus paper in 2014, Hodhod et al. [17] were the first to assess the reliability of the UTD system in predicting outcomes. They concluded that the grade of urinary tract dilation can be used to predict the resolution rate of hydronephrosis. Additionally, when compared to the Society for Fetal Urology system, the UTD system more accurately predicted those who developed urinary tract infections or needed surgery because of the inclusion of ureteral dilation in the classification system [17]. However this is an important point that requires further research and discussion. When the appearance of the kidney was normal according to the UTD system, the rate of urinary tract infection was no greater than in the general population [18–20].

Although the UTD classification system was not intended to be used with the postsurgical kidney,

Rickard et al. [21] used it to evaluate the success of pyeloplasty in children with ureteropelvic junction obstruction. In this study a UTD <P1 defined success. In addition to the UTD classification system, the authors reported a percentage improvement of the anteroposterior renal pelvic diameter (PI-APD). A PI-APD cutoff of 38% at the first postoperative US was previously shown to predict success of pyeloplasty [22]. In Rickard et al.'s [21] series 89/138 patients (64%) had a UTD <P1 and 81 of these (91%) had >40% PI-APD.

### Conclusion

The UTD classification system and the recommendations of the consensus panel were published in the *Journal of Pediatric Urology* in 2014 [14] and disseminated through letters to the editor in multiple journals [23]. This classification system standardized terminology to improve communication and care of fetuses and infants with urinary tract dilation. The unified system is expected to facilitate future research and understanding of urinary tract disease. Several researchers have used this system to assess reliability and clinical outcomes. Future research will build on this literature and help refine the classification and management set forth in this guideline.

**Table 4** Management schema based on urinary tract dilation (UTD) classification system risk stratification of UTD P1, UTD P2 and UTD P3

	UTD P1 (low risk)	UTD P2 (intermediate risk)	UTD P3
Follow-up US	1–6 months	1–3 months	1 month
VCUG*	Discretion of clinician	Discretion of clinician	Recommended
Antibiotics*	Discretion of clinician	Discretion of clinician	Recommended
Functional scan	Not recommended	Discretion of clinician	Discretion of clinician

\*The choice to use antibiotics or recommend voiding cystourethrogram (VCUG) depends on the suspected underlying pathology

**Acknowledgments** Dr. J. S. Chow and Dr. K. Darge are pediatric radiologists and Dr. H. Nguyen a pediatric urologist who took part in the multidisciplinary consensus on the classification of prenatal and postnatal urinary tract dilation.

#### Compliance with ethical standards

**Conflicts of interest** The authors have no financial interests, investigational or off-label uses to disclose.

#### References

- Hamilton BE, Martin JA, Ventura SJ (2013) Births: preliminary data for 2012. U.S. Department of Health and Human Services, Centers for Disease Control and Prevention, National Center for Health Statistics, National Vital Statistics System. *Natl Vital Stat Rep* 62:1–20
- Swenson DW, Darge K, Ziniel SI et al (2015) Characterizing upper urinary tract dilation on ultrasound: a survey of north American pediatric radiologists' practices. *Pediatr Radiol* 45:686–694
- Odibo AO, Marchiano D, Quinones JN et al (2003) Mild pyelectasis: evaluating the relationship between gestational age and renal pelvic anterior-posterior diameter. *Prenat Diagn* 23: 824–827
- Chitty LS, Altman DG (2003) Charts of fetal size: kidney and renal pelvis measurements. *Prenat Diagn* 23:891–897
- van Vuuren SH, Damen-Elias HA, Stigter RH et al (2012) Size and volume charts of fetal kidney, renal pelvis and adrenal gland. *Ultrasound Obstet Gynecol* 40:659–664
- Blane CE, DiPietro MA, Strouse PJ et al (2003) Pediatric renal pelvic fullness: an ultrasonographic dilemma. *J Urol* 170:201–203
- Tsai TC, Lee HC, Huang FY (1989) The size of the renal pelvis on ultrasonography in children. *J Clin Ultrasound* 17:647–651
- Schaeffer AJ, Kurtz MP, Logvinenko T et al (2016) MRI-based reference range for the renal pelvis anterior-posterior diameter in children ages 0-19 years. *Br J Radiol* 89:20160211
- Grignon A, Filion R, Filiatrault D et al (1986) Urinary tract dilatation in utero: classification and clinical applications. *Radiology* 160:645–647
- Fernbach SK, Maizels M, Conway JJ (1993) Ultrasound grading of hydronephrosis: introduction to the system used by the society for fetal urology. *Pediatr Radiol* 23:478–480
- Riccabona M, Avni FE, Blickman JG et al (2009) Imaging recommendations in paediatric urology. *Minutes of the ESPR urology task force session on childhood obstructive uropathy, high-grade fetal hydronephrosis, childhood haematuria, and urolithiasis in childhood.* ESPR annual congress, Edinburgh, UK, June 2008. *Pediatr Radiol* 39:891–898
- Onen A (2007) An alternative grading system to refine the criteria for severity of hydronephrosis and optimal treatment guidelines in neonates with primary UPJ-type hydronephrosis. *J Pediatr Urol* 3: 200–205
- Ellenbogen PH, Scheible FW, Talner LB et al (1978) Sensitivity of gray scale ultrasound in detecting urinary tract obstruction. *AJR Am J Roentgenol* 130:731–733
- Nguyen HT, Benson CB, Bromley B et al (2014) Multidisciplinary consensus on the classification of prenatal and postnatal urinary tract dilation (UTD classification system). *J Pediatr Urol* 10:982–998
- Nelson CP, Johnson EK, Logvinenko T et al (2014) Ultrasound as a screening test for genitourinary anomalies in children with UTI. *Pediatrics* 133:e394–e403
- Lee RS, Cendron M, Kinnamon DD et al (2006) Antenatal hydronephrosis as a predictor of postnatal outcome: a meta-analysis. *Pediatrics* 118:586–593
- Hodhod A, Capolicchio JP, Jednak R et al (2016) Evaluation of urinary tract dilation classification system for grading postnatal hydronephrosis. *J Urol* 195:725–730
- Oliveira EA, Diniz JS, Rabelo EA et al (2000) Primary megaureter detected by prenatal ultrasonography: conservative management and prolonged follow-up. *Int Urol Nephrol* 32:13–18
- Winberg J, Andersen HJ, Bergstrom T et al (1974) Epidemiology of symptomatic urinary tract infection in childhood. *Acta Paediatr Scand Suppl* 1974:1–20
- Marild S, Jodal U (1998) Incidence rate of first-time symptomatic urinary tract infection in children under 6 years of age. *Acta Paediatr* 87:549–552
- Rickard M, Braga LH, Oliveria JP et al (2016) Percent improvement in renal pelvis antero-posterior diameter (PI-APD): prospective validation and further exploration of cut-off values that predict success after pediatric pyeloplasty supporting safe monitoring with ultrasound alone. *J Pediatr Urol* 12:228.e1–6
- Romao RL, Farhat WA, Pippi Salle JL et al (2012) Early postoperative ultrasound after open pyeloplasty in children with prenatal hydronephrosis helps identify low risk of recurrent obstruction. *J Urol* 188:2347–2353
- Chow JS, Darge K (2015) Multidisciplinary consensus on the classification of antenatal and postnatal urinary tract dilation (UTD classification system). *Pediatr Radiol* 45:787–789