

MAJALAH KEDOKTERAN **UKI**

Medical Journal of the Christian University of Indonesia

DAFTAR ISI

Editorial

Forman Erwin Siagian, Retno Wahyuningsih.....	159
Cryptococcal Meningitis among AIDS Patients in Jakarta Ridhawati Sjam, Mulyati, Robiatul Adawiyah, Darma Imran, Retno Wahyuningsih.....	160-166
Value of Tygerberg Scoring for the Diagnosis and Management of Tuberculous Pericarditis Achnes Pangaribuan, Kurniyanto, Donnie Lumban Gaol, Yunus Tanggo.....	167-171
Kandung Kemih Neurogenik pada Anak: Etiologi, Diagnosis dan Tata Laksana Rhyno Febriyanto, Bernadetha Nadeak, Sudung O. Pardede.....	172-181
Neurogenesis pada Perdarahan Intraserebral Spontan Robert Sinurat.....	182-187
Diabetes Melitus Tipe 1 pada Orang Dewasa Kurniyanto, Yunus Tanggo.....	188-193
Diagnosis Oklusi Pembuluh Darah Retina Reinne N. Christinc, Angela N. Agni.....	194-199
Ucapan Terima Kasih	200-201
Indeks Penulis	202
Daftar Isi Volume XXVIII 2012	203-204
Indeks Kata Kunci	205-206
Indeks Key Words	207-208

Penerbit :
Fakultas Kedokteran
Universitas Kristen Indonesia

ISSN No 0216-4752 No.
Tahun XXVIII
Oktober-Desember 2012

4

**Susunan Pengurus Majalah Kedokteran
Fakultas Kedokteran Universitas Kristen Indonesia
Medical Journal of the Christian University of Indonesia**

Penasehat :

Rektor UKI
Dekan FK. UKI
Direktur RSU FK. UKI

Pimpinan Umum :

Dr. Med. dr. Abraham Simatupang, M.Kes

Pimpinan Redaksi :

Prof. Dr. dr. Retno Wahyuningsih, MS, Sp.ParK

Anggota Dewan Redaksi :

Dr. dr. Carmen M. Siagian, MS, Sp.GK
dr. Tigor P. Simanjuntak, Sp.OG, M.Kes
Dra. Endang Darniati, MSc
dr. Forman Erwin Siagian, M.Biomed
dr. Gilbert W. S. Simanjuntak, Sp.M (K)
Eva Suarthana, MD.,MSc, Ph.D
(Université de Montréal, Kanada)

Sekretariat :

Lamria Sianturi
Tarmini

Alamat Redaksi :

Fakultas Kedokteran UKI
Jl. Mayjen Sutoyo Cawang No. 2
Jakarta Timur 13630
Telepon : (021) 8092425, Faks. (021) 8093133
E-mail : majalahfk@uki.ac.id
majalah_fkuki@yahoo.com

DAFTAR ISI

Editorial

Forman Erwin Siagian, Retno Wahyuningsih	159
Cryptococcal Meningitis among AIDS Patients in Jakarta Ridhawati Sjam, Mulyati, Robiatul Adawiyah, Darma Imran, Retno Wahyuningsih.....	160-166
Value of Tygerberg Scoring for the Diagnosis and Management of Tuberculous Pericarditis Achnes Pangaribuan, Kurniyanto, Donnie Lumban Gaol, Yunus Tanggo.....	167-171
Kandung Kemih Neurogenik pada Anak: Etiologi, Diagnosis dan Tata Laksana Rhyno Febriyanto, Bernadetha Nadeak, Sudung O. Pardede.....	172-181
Neurogenesis pada Perdarahan Intracerebral Spontan Robert Sinurat.....	182-187
Diabetes Melitus Tipe 1 pada Orang Dewasa Kurniyanto, Yunus Tanggo.....	188-193
Diagnosis Oklusi Pembuluh Darah Retina Reinne N. Christine, Angela N. Agni.....	194-199
Ucapan Terima Kasih	200-201
Indeks Penulis	202
Daftar Isi Volume XXVIII 2012	203-204
Indeks Kata Kunci	205-206
Indeks Key Words	207-208

Value of Tygerberg Scoring for the Diagnosis and Management of Tuberculous Pericarditis

Achnes Pangaribuan,¹ Kurniyanto,² Donnie Lumban Gaol,² Yunus Tanggo²

¹Department of Internal Medicine General Hospital,
²Department of Internal Medicine Faculty of Medicine
Christian University of Indonesia

Abstract

Extra pulmonary tuberculosis occurs in 20% of patients with tuberculosis. Tuberculosis pericarditis is seen in 1-8% of these patients. Tuberculosis has been reported to be the cause of acute pericarditis in 60-80% of the patients in the developing world. We reported a case of 19 years old male who presented with right chest pain, cough, breathlessness, night sweat, fever, fatigue, and weight loss. From the physical examination, jugular venous pressure was high and on auscultation, the heart sounds were muffled and associated with a pericardial rub. The chest x-ray revealed enlargement of cardiac silhouette. Transthoracic echocardiography showed pericardial effusion, and mantoux tuberculin skin test were positive. Since the pericardiocentesis is not feasible in our hospital, the tygerberg tuberculous pericarditis score was applied. Furthermore, patients were given anti-TB treatment, and showed a good response to treatment.

Key words: extra pulmonary tuberculosis, tuberculous pericarditis, tygerberg score

Penggunaan Skor Tygerberg untuk Diagnosis dan Tatalaksana Perikarditis Tuberkulosis

Abstrak

Tuberkulosis dapat menyebabkan kelainan di luar paru. Prevalensinya berkisar sekitar 20% dan dapat menyebabkan kelainan diberbagai organ seperti perikarditis pada jantung. Tuberkulosis telah dilaporkan menjadi penyebab perikarditis akut pada 60-80% pasien di negara berkembang. Pada tulisan ini dilaporkan seorang laki-laki berusia 19 tahun dengan keluhan nyeri dada kanan disertai batuk, sesak nafas, keringat malam, lemas, dan penurunan berat badan. Pada pemeriksaan fisik ditemukan peningkatan tekanan vena jugularis, dan pada auskultasi ditemukan bising jantung sesuai dengan gesekan perikardium. Pada pemeriksaan foto polos dada ditemukan pembesaran ruang jantung. Pada ekokardiografi ditemukan efusi perikardial. Karena perikardial drainase tidak dapat dilakukan, diterapkan skor tygerberg untuk diagnosis perikarditis tuberkolosis. Selanjutnya pasien diberi pengobatan anti TB, dan menunjukkan respons yang baik terhadap pengobatan.

Kata kunci: tuberkulosis ekstra pulmoner, perikarditis tuberkulosis, skor tygerberg

Introduction

Tuberculosis (TB) can involve any organ system in the human body. Pulmonary TB is the most common presentation, but extrapulmonary tuberculosis (EPTB) is also an important clinical problem. It has been observed that EPTB constituted about 15-20% of all cases of TB. Tuberculosis pericarditis has been estimated to occur in 1-8% patients with pulmonary tuberculosis. Tuberculosis has been reported to be the cause of acute pericarditis in 4% of patients in the developed world and 60-80% of the patients in the developing countries.¹⁻⁵ Pericardial involvement usually develops by retrograde lymphatic spreading of the organism, *Mycobacterium tuberculosis*, from peritracheal, peribronchial, or mediastinal lymph nodes or by hematogenous spread from primary tuberculous infection. The pericardium is infrequently involved by breakdown and contiguous spread from a tuberculous lesion in the lung or by hematogenous dissemination from distant secondary skeletal or genitourinary infection. The immune response to the viable acid-fast bacilli penetrating the pericardium is responsible for the morbidity associated with tuberculous pericarditis. Protein antigens of the bacillus induce delayed hypersensitivity responses, stimulating lymphocytes to release lymphokines that activate macrophages and influence granuloma formation. The cytokine profile suggests that tuberculous pericardial effusions arise as a result of a hypersensitivity reaction orchestrated by the Th-1 lymphocytes. Tuberculous pericarditis presents clinically in three forms, namely, pericardial effusion, constrictive pericarditis, and a combination of effusion and constriction.⁶ Tuberculous pericardial effusion usually develops insidiously, presenting with nonspecific systemic symptoms such as fever, night sweats, fatigue, and weight loss. Chest pain, cough, and breathlessness are common.

Right upper abdominal aching due to liver congestion is also common. The patients may manifest pericardial rub, vague chest pain, cardiomegaly on a chest radiograph, and echocardiography reveal pericardial effusion. Cardiac tamponade and constrictive pericarditis are major lethal complications of TB pericarditis. According to Reuter *et al.*,⁷ definite tuberculous pericarditis was diagnosed by one or more of the following criterias: (i) "demonstration and isolation of *M. tuberculosis* from the drained pericardial effusion or pericardial biopsy specimen; (ii) demonstration of granulomatous inflammation on histological examination of the pericardial biopsy sample; and/or (iii) isolation of *M. tuberculosis* from sputum or non-pericardial exudates in the presence of clinical and/ or radiological evidence of TB, associated with a positive response to anti-tuberculous therapy."

Tuberculin skin test (mantoux test) has little value of diagnostic, especially in highly endemic area such as Indonesia. It is due to the mass Bacille Calmette Guerin (BCG) immunization, but large induration more than 10 mm in diameter is suspicious for TB. Tygerberg TB pericarditis diagnosis score is applicable when pericardiocentesis is not feasible. For proper treatment, accurate diagnosis of tuberculous pericarditis is very important. Without specific treatment, the mean survival rate is 3.7 months, with a mortality rate approaching 85% at six months. Effective treatment requires a rapid and accurate diagnosis, but this is often difficult. It is important to identify which clinical and basic laboratory features should be used.

Case Presentation

A case of 19 years old male presented with right chest pain, cough, breathlessness, night sweat, fever, fatigue, and weight loss. On physical examination, jugular venous

pressure was high and on auscultation, the heart sounds were muffled and associated with a pericardial rub. There was no peripheral edema, cyanosis, pallor, icterus or hepatosplenomegaly. Laboratory investigation revealed anemia, increased erythrocyte sedimentation rate (ESR) 85 mm, haemoglobin (Hb) was 10.7 gr/dl, white blood cells (WBC) was 9000/mm³, platelet count was 615 000/mm³. The result of WBC differential was: -/1/10/58/26/5 (%), serum globulin 4.6 mg/dL, albumin 3.32 mg/dL and anti-streptolysin O (ASTO) titer was negative. The chest x-ray revealed enlargement of cardiac silhouette. Transthoracic echocardiography showed pericardial effusion, and mantoux tuberculin skin test were highly positive. Electrocardiography showed low voltage complexes with sinus tachycardia. A working diagnosis of tuberculous pericarditis

was diagnosed without active pulmonary tuberculosis finding. Definitive diagnosis of tuberculosis etiology was challenging because we did not do the pericardiocentesis due to limitation of tools and diagnostic approach. Because pericardiocentesis is not feasible in our hospital, we applied tygerberg TB pericarditis diagnostic score and showed total score ≥ 6 , which indicated tuberculosis pericarditis. The patient was given empiric antituberculosis chemotherapy with isoniazid (5 mg/kg per day), rifampicine (10 mg/kg per day), ethambutol (20 mg/kg per day), pyrazinamide (20 mg/kg per day), and in addition, the patients received corticosteroid at initial dose of prednisone 1 mg/kg per day, then tapered down. The patient was responding well to the treatment, with no recurrence of symptoms or any signs of deterioration after one month followed up.

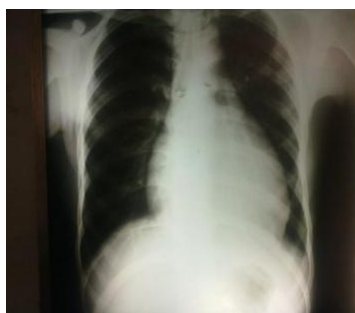


Figure 1

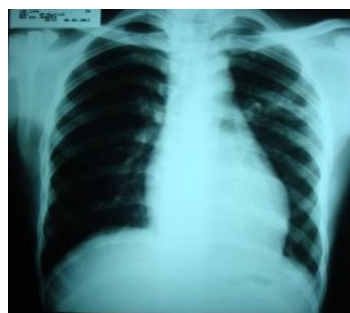

Figure 2

Chest x-ray, before treatment, showed enlargement of cardiac silhouette, interstitial pulmonary infiltrations notably in the left hilum of the lungs (Figure 1); chest x-ray one month after treatment showed improvement compared to previous x-ray (the heart reached normal size), but pulmonary interstitial infiltrate is evidenced in left hilum (Figure 2).

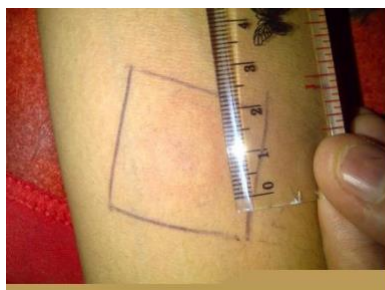

Figure 3

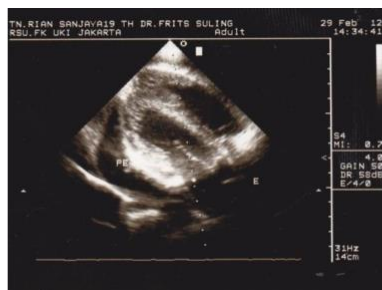

Figure 4

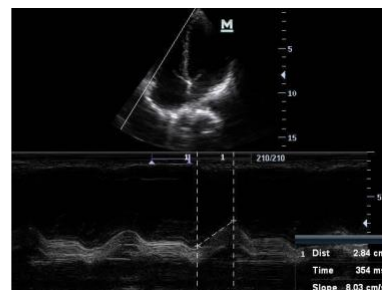


Figure 5

Mantoux tuberculin skin test, 22 mm in diameter, indicating size of induration is positive (Figure 3); Echocardiography showed pericardial effusion $\pm 200-300$ cc (Figure 4); six month echocardiography follow up shows no pericardial effusion (Figure 5)

Discussion

Echocardiography is an accurate and noninvasive method for the diagnosis of pericardial effusion. The chest radiograph shows an enlargement of cardiac shadow. In Indonesia and other developing countries in which TB is endemic, tuberculin skin test has a little value of diagnostic because of mass BCG immunization, but highly positive skin induration more than 10 mm has 89% sensitivity and 56% specificity.⁷ Direct methods for the diagnosis of a tuberculous pathogenesis must be established as far as possible by a diligent search for acid-fast bacilli in pericardial fluid. Pericardiocentesis is recommended in all patients in whom tuberculosis pericarditis is suspected. In this case due to limitation of tools and diagnostic approach we did not do perform the pericardiocentesis, we applied tygerberg TB pericarditis diagnostic score to establish the diagnosis of tuberculous pericarditis. Tygerberg TB pericarditis diagnostic score is applicable when pericardiocentesis is not feasible and has 86% sensitivity and 85% specificity.

Table 1. Tygerberg TB pericarditis scoring⁷

Criteria	Score
Weight loss (>10%)	1
Night sweats	1
Fever > 38 °C	2
Serum globulin >40 g/L	3
White cell count < 10 X10 ⁹ /L	3
Total Score ≥ 6 = TB pericarditis	

We applied tygerberg TB pericarditis diagnostic score resulted total score of 10, which was highly indicated for tuberculous pericarditis. Therefore, the diagnosis was made without serologic and or microbiology confirmation of pericardial fluid; the patient received antituberculous chemotherapy.

Tuberculin skin test has a little value of diagnostic, but large diameter of skin

induration more than 10 mm is highly suspicious for TB. In this patient we find large diameter of skin induration 22 mm, that highly suspicious for TB infection.

Without specific contraindication, corticosteroid should be prescribed in addition to antituberculosis chemotherapy to prevent constrictive pericarditis.⁸⁻¹² Using Tygerberg TB pericarditis diagnostic tool and tuberculin skin test, we made a accurate diagnosis, which proved by good respond of the treatment. The patient was discharged from the hospital in a good condition and one month followed up using chest x ray revealed no enlargement of cardiac silhouette and echocardiography showed normal heart without effusion.

Conclusion

Where the diagnostic tools and resources are available, suspected cases of tuberculous pericarditis may be diagnosed using isolation of *M. tuberculosis* from the drained pericardial effusion or pericardial biopsy, but it is often difficult in the resource with limited setting, where the paucity of evidence to support clinical decisions is emphasized and the need for well designed diagnostic and therapeutic studies is highlighted. In the absence of sufficient tools and diagnostic approach and pericardiocentesis is not feasible, it is appropriate in high prevalence areas to initiate empiric antituberculosis therapy in the presence of pericardial effusion and tygerberg TB pericarditis diagnostic score ≥ 6.

References

1. Mayosi B, Wiysonge C, Ntsekhe M, Volmink J, Gumedze F, Maartens G, *et al.* Clinical characteristics and initial management of patients with tuberculous pericarditis in the HIV era: the investigation of the management of pericarditis in Africa (IMPI Africa) registry. *BMC Infect Dis* 2006; 6: 2.
2. Sharma SK, Mohan A. Extrapulmonary tuberculosis. *Indian J Med Res.* 2004; 120 (4): 316-53.

3. Syed FF, Mayosi BM. A modern approach to tuberculous pericarditis. *Prog Cardiovasc Dis.* 2007; 50 (3): 218-36.
4. Wanjari K, Baradkar V, Mathur M, Kumar S. A case of tuberculous pericardial effusion. *Indian J Med Microbiol.* 2009; 27 (1): 75-7.
5. Gibbs CR, Watson RD, Singh SP, Lip GY. Management of pericardial effusion by drainage: a survey of 10 years' experience in a city centre general hospital serving a multiracial population. *Postgrad Med J.* 2000; 76 (902): 809-13.
6. Mayosi BM, Burgess LJ, Doubell AF. Tuberculous pericarditis. *Circulation.* 2005; 112: 3608-16.
7. Reuter H, Burgess L, van Vuuren W, Doubell A. Diagnosing tuberculous pericarditis. *QJM.* 2006; 99 (12): 827-39.
8. Strang JI, Nunn AJ, Johnson DA, Casbard A, Gibson DG, Girling DJ. Management of tuberculous constrictive pericarditis and tuberculous pericardial effusion in Transkei: results at 10 years follow-up. *QJM.* 2004; 97 (8) : 525-35.
9. Ntsekhe M, Wiysonge C, Volmink JA, Commerford PJ, Mayosi BM. Adjuvant corticosteroids for tuberculous pericarditis: promising, but not proven. *QJM.* 2003; 96 (8): 593-9.
10. Liu YW, Tsai HR, Li WH, Lin LJ, Chen JH. Tuberculous constrictive pericarditis with concurrent active pulmonary tuberculous infection: a case report. *Cases J.* 2009; 2: 7010.
11. Lou E, Adams GL. A case of tuberculous pericarditis: a rare but deadly disease. *Am J Med.* 2006; 119 (8): e1-2.
12. Hsien-Kuo Chin, Yee-Phoung Chang, Chia-Shen Chao. Acute primary tuberculous pericarditis. *Acta Cardiol Sin.* [Case Report]. 2007; 23: 56 - 61.

