

## Primary Tuberculosis of the Parotid Gland

Dr. Natraj M, Dr. Irfan Ismail Ayub, Dr Dhanasekar T, Dr. Rajagopalan B

Department of Chest and TB, Sri Ramachandra University, Porur, Chennai, India

### Case Report

\*Corresponding author

Dr. Natraj M

### Article History

Received: 22.11.2017

Accepted: 27.11.2017

Published: 30.11.2017

### DOI:

10.21276/sjmeps.2017.3.11.20



**Abstract:** Eventhough Tuberculosis is widespread in India; parotid gland involvement is very rare. TB primarily affects the lung, but in about 15 – 20% of the cases extra pulmonary involvement can be seen. Here we present a case of TB parotid abscess in a 45 year old diabetic male patient.

**Keywords:** *Cinnamomum verum*, toxicity, aqueous, stem bark, extract

### INTRODUCTION

Although tuberculosis infection is widespread in India, infection of the parotid gland is very rare [1]. Tuberculosis of the parotid gland is an infectious disease, which causes the gland to increase in volume making it lobulated, and causes lymphadenitis [2]. Less than 200 cases have been reported. It can be present as acute parotitis, an abscess resistant to most of the antibiotics, a fistula or by a slow growing mass within the gland often mimicking neoplasm [3,4]. Majority of the cases can be diagnosed with ultrasound or fine needle aspiration cytology. But few cases need surgery when neoplasm is suspected [5].

### CASE PRESENTATION

45-year-old male patient who is a known diabetic came to our hospital with complaints of right-sided neck swelling with pain for 15 days. He also complained of fever for the last 15 days with loss of weight of about 3 kgs along with loss of apatite. He had no complaints of dysphagia (both liquids and solids), cough, expectoration, hemoptysis, chest pain and difficulty in breathing. He had no previous history of tuberculosis infection. He is not a smoker nor alcoholic.

His total counts were elevated, while his LFT, RFT, Serum electrolytes and urine routine examination were normal. His chest X ray is normal. Sputum AFB showed no AFB. CT neck showed right-sided parotid abscess and was planned for incision and drainage of the parotid abscess under general anesthesia. The drained pus was sent for analysis. GeneXpert from

aspirated pus showed mycobacterium tuberculosis with rifampicin being sensitive.

Thus the diagnosis of primary tuberculosis parotid gland was made and patient was started on anti tuberculosis treatment containing rifampicin, ethambutol, isoniazid and pyrazinamide.

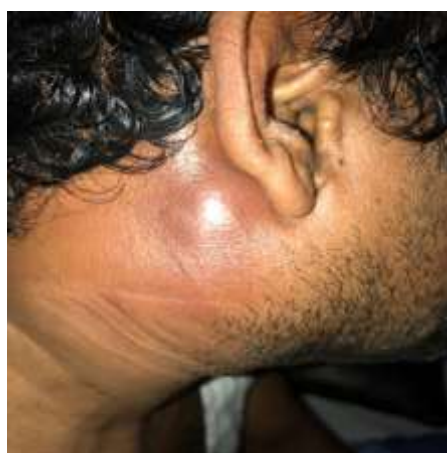

Fig-1: Showing right side neck swelling

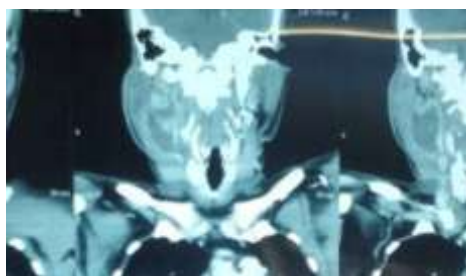


Fig-2: Ct neck showing right sided swelling

## DISCUSSION

Tuberculosis is a chronic granulomatous infection primarily affecting the lungs caused by mycobacterium tuberculosis. Only 15 – 20% of the cases are extra pulmonary – affecting lymph nodes, bones, kidney and meninges. Involvement of the parotid gland is very rare even in the countries where tuberculosis infection is rampant [3]. The source of infection of the parotid gland is controversial. There are different postulations on the source of infection. Some of them are spread from primary focus in the body or through wounded oral mucosa or through extension of infection from stenson's duct [1]. Most common presentation of parotid tb is a slowly growing painless mass, which often mimics neoplasm. But occasionally it can be present as an abscess requiring surgical interventions. Other forms of involvement include fistula and facial nerve palsy. Patients who are immunocompromised are at more risk of developing tuberculosis infection [3]. Imaging (ultrasound, CT) and fine needle aspiration cytology is useful in diagnosis of tb parotid. Methods like conventional cultures and GeneXpert significantly increases the yield of diagnosis [6]. Treatment of TB parotid gland with standard regimen yields good results; however, frequent monitoring is required to see the response to treatment.

## CONCLUSION

Though it is a rare possibility tuberculous infection of the parotid gland must be considered as one of the differential diagnosis for all parotid gland lesions.

## REFERENCES

1. Alex, L., Balakrishnan, M., & Ittyvirah, A. K. (2006). Tuberculosis of parotid gland: A case report. *Ind Radiol Imag*, 16, 689-90.
2. Caldart, A. U., Adriano, C. F., Caldart, A. U., & Mocellin, M. (2007). Primary tuberculosis of the parotid gland. *Revista Brasileira de Otorrinolaringologia*, 73(5), 720-720.
3. Bhat, V., Kolathingal, B., Aroor, R., & Gowda, M. M. (2014). Tuberculosis of parotid gland masquerading as Pleomorphic adenoma. *Medical Journal of Dr. DY Patil University*, 7(1), 56.
4. Birkent, H., Karahatay, S., Akcam, T., Durmaz, A., & Ongoru, O. (2008). Primary parotid tuberculosis

mimicking parotid neoplasm: a case report. *Journal of medical case reports*, 2(1), 62.

5. Sharma, K., Mehdiratta, N. K., & Gupta, A. K. (1996). Tuberculosis of the parotid gland. *Canadian Journal of Surgery*, 39(3), 253.
6. Weiner, G. M., & Pahor, A. L. (1996). Tuberculous parotitis: limiting the role of surgery. *The Journal of Laryngology & Otology*, 110(1), 96-97.