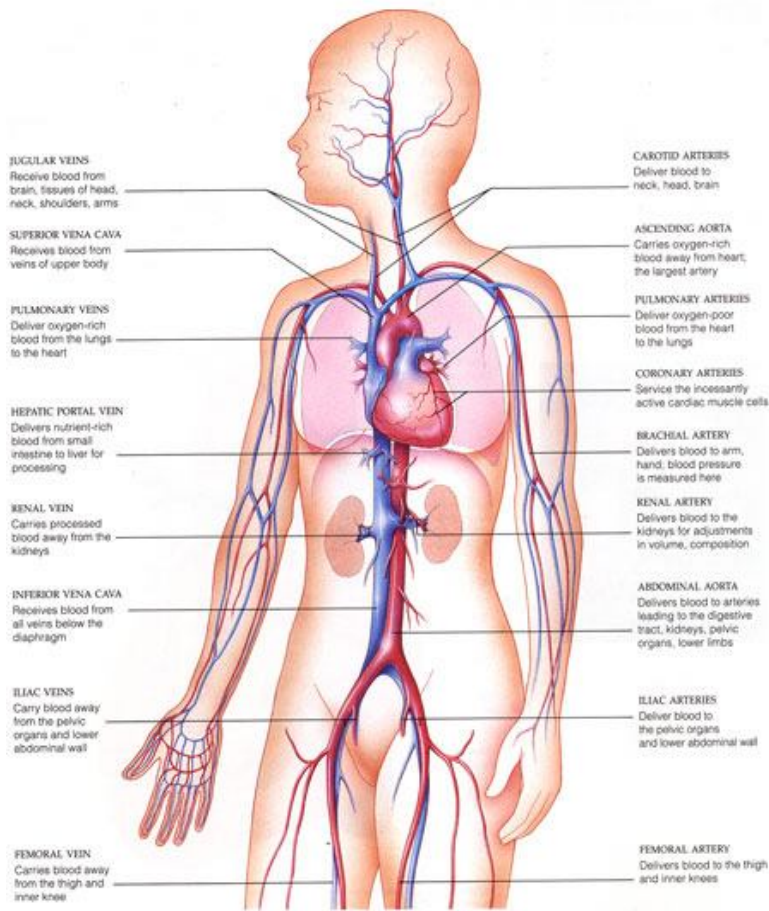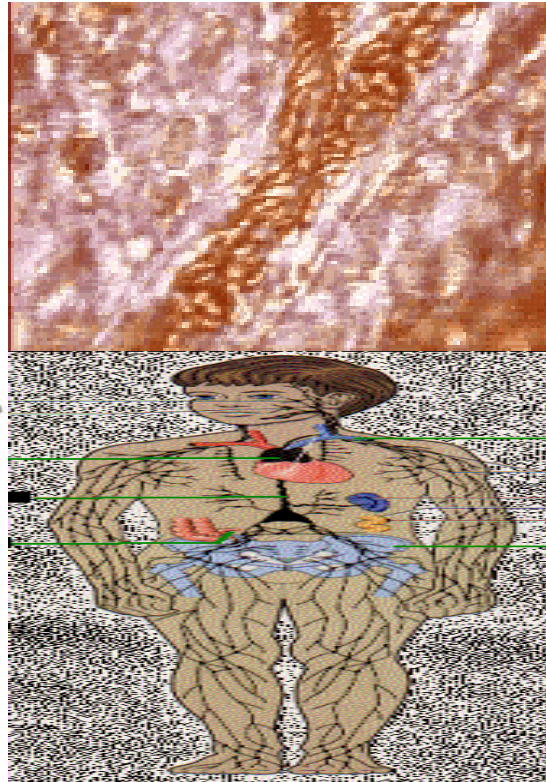
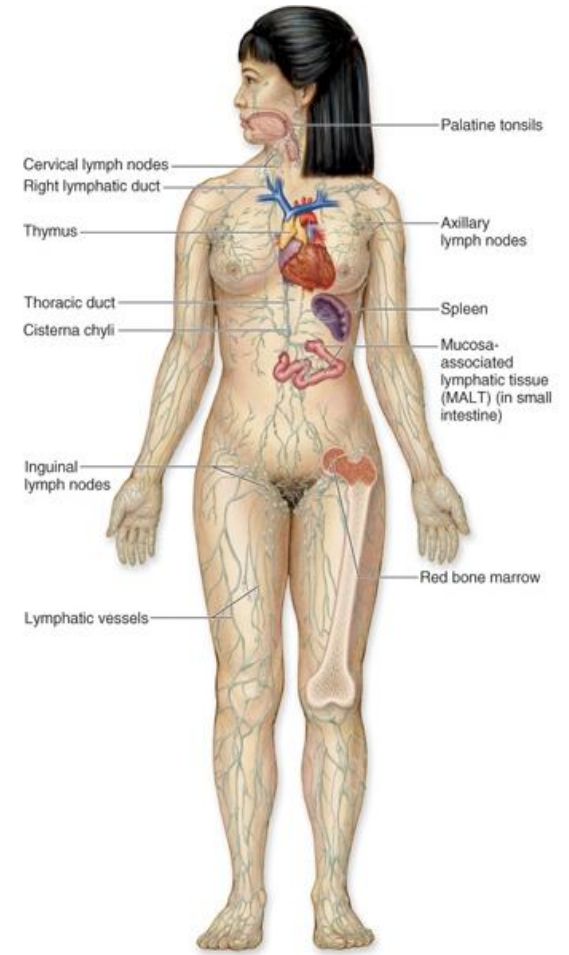


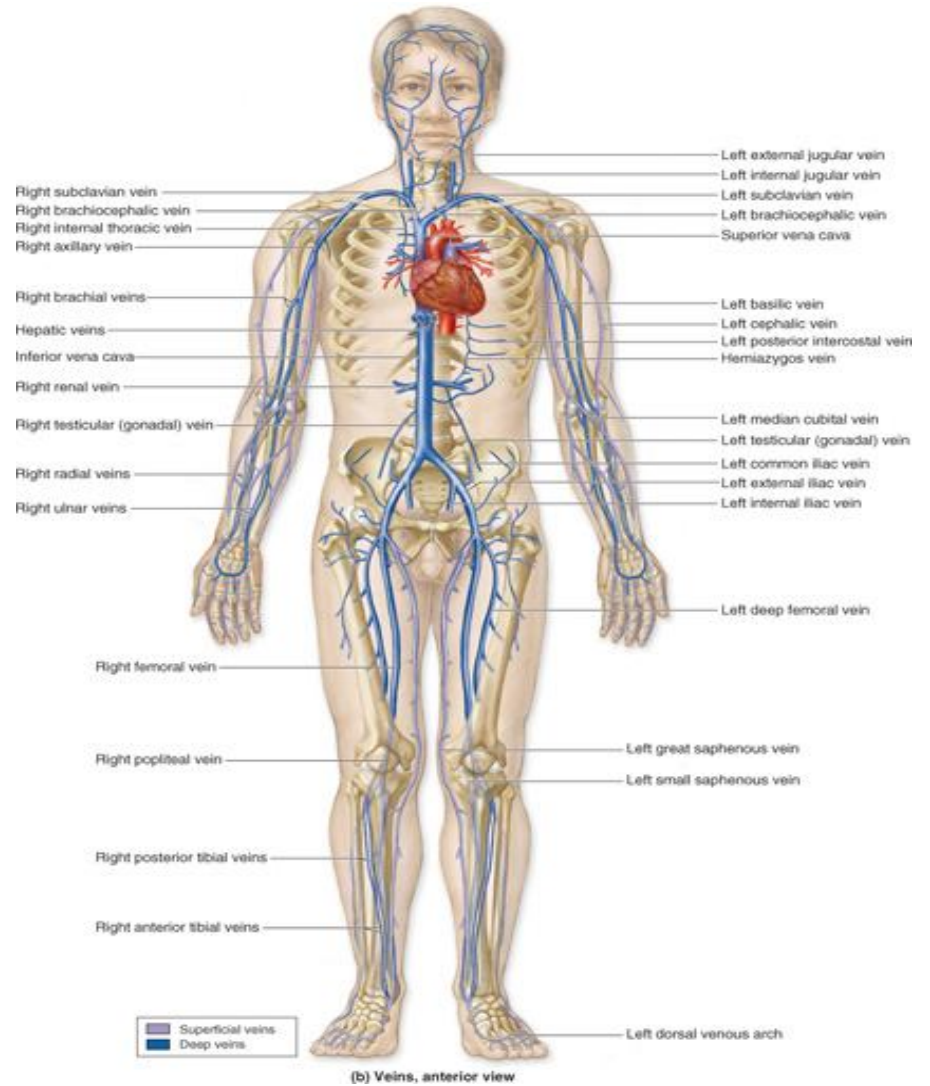
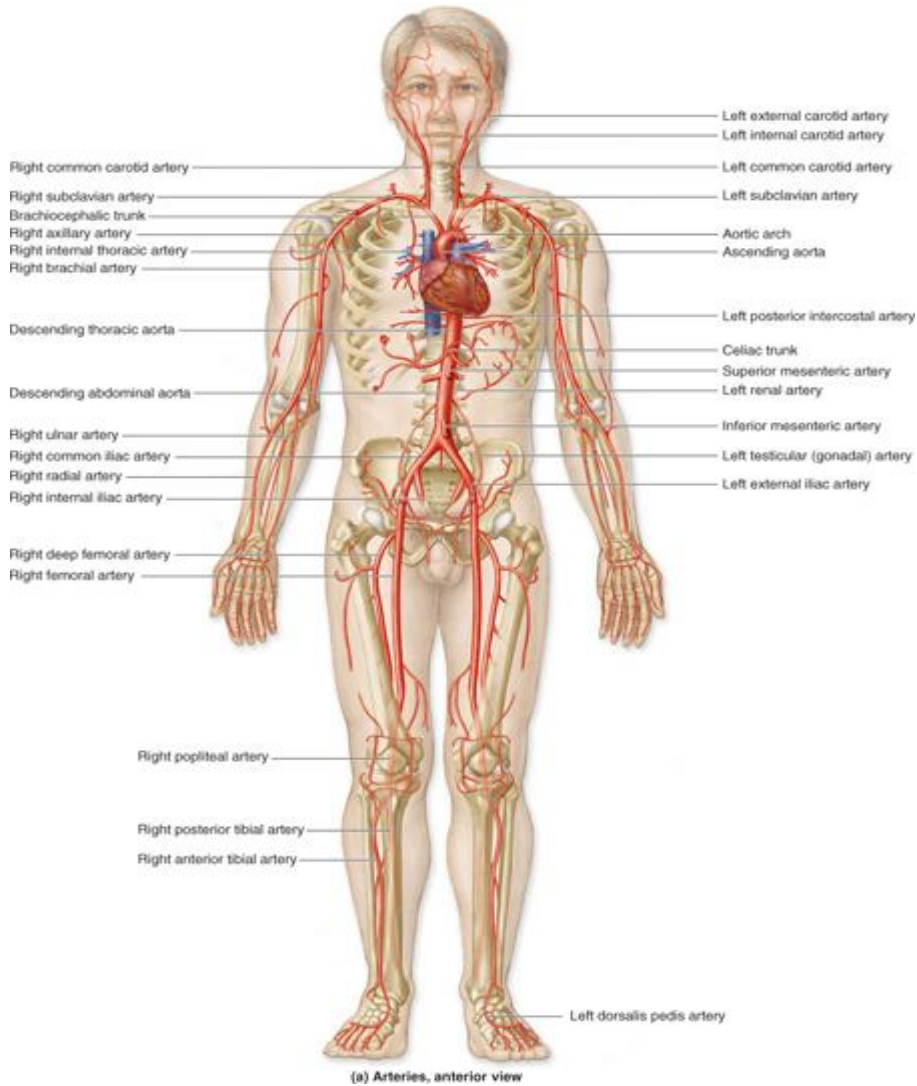
Human circulatory system, showing some of the major blood vessels. Arteries are color-coded red; veins are blue.



VASCULAR

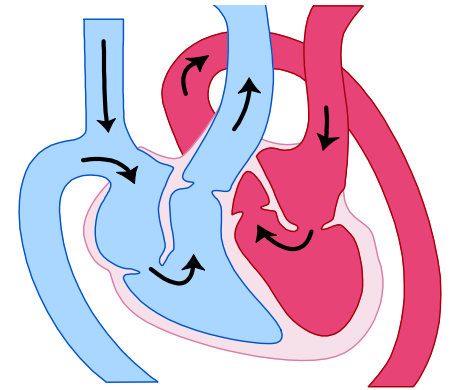
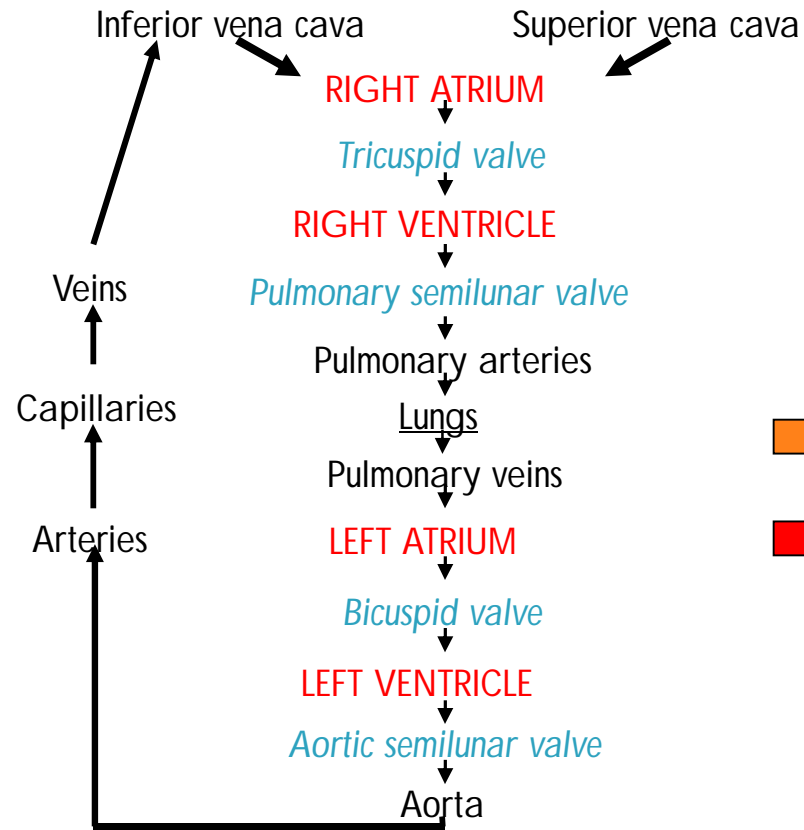


D.HAMMOUDI. MD



The Heart

Pathway of blood flow:

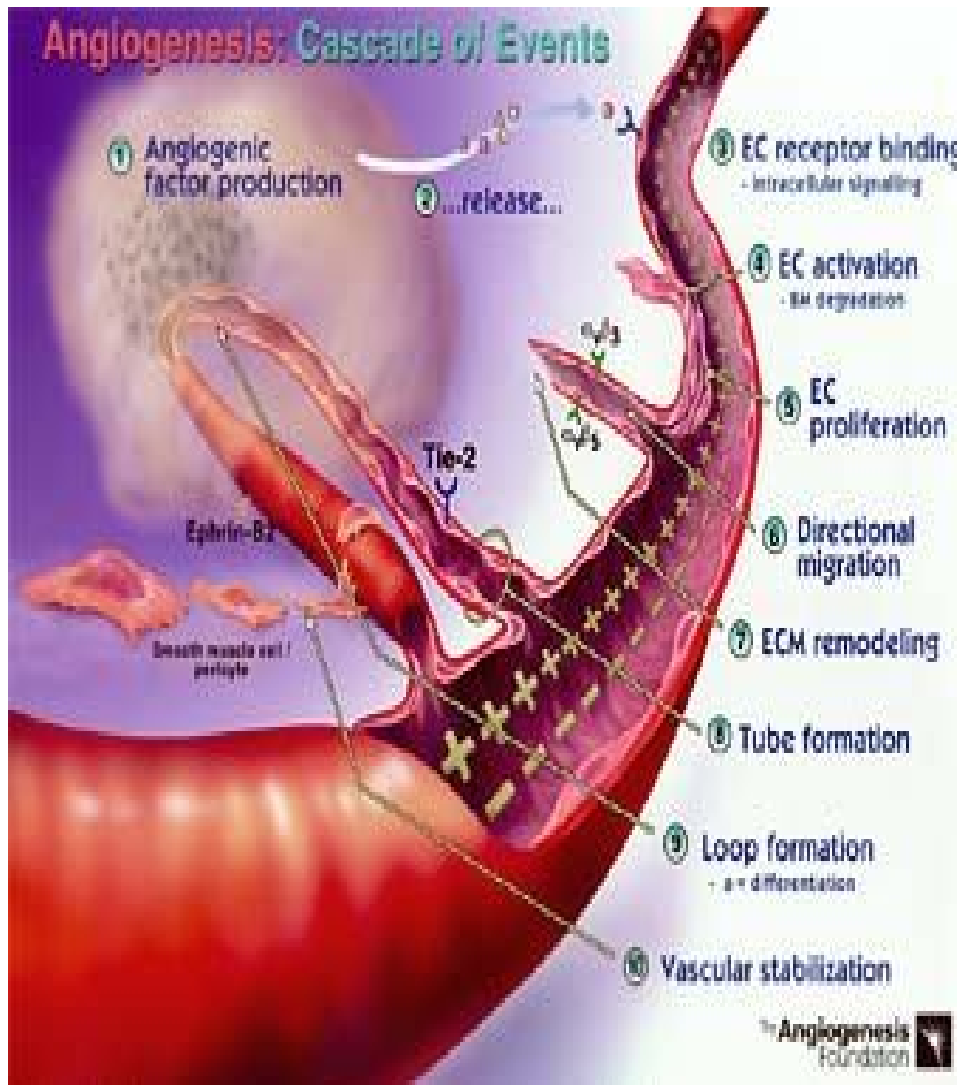


Deoxygenated

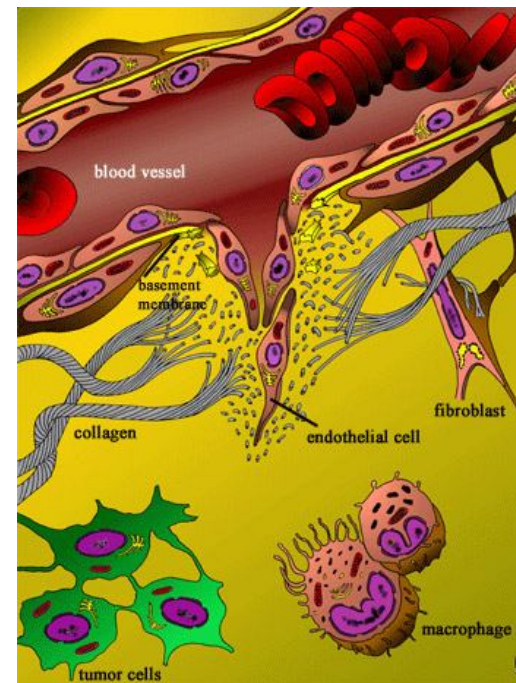
Oxygenated

Angiogenesis is the physiological process involving the growth of new blood vessels from pre-existing vessels

- Angiogenesis takes place:
 - ▣ As the number of vessels to a region increases
 - ▣ When existing vessels enlarge
 - ▣ When a heart vessel becomes partly occluded
 - ▣ Routinely in people in high altitudes, where oxygen content of the air is low
 - ▣ New tissue or extended tissue [abnormal as cancer]
 - ▣ wound healing and in granulation tissue



The healthy body controls angiogenesis through a series of "on" and "off" switches: The main "on switches" are known as angiogenesis-stimulating growth factors. The main "off switches" are known as angiogenesis inhibitors.



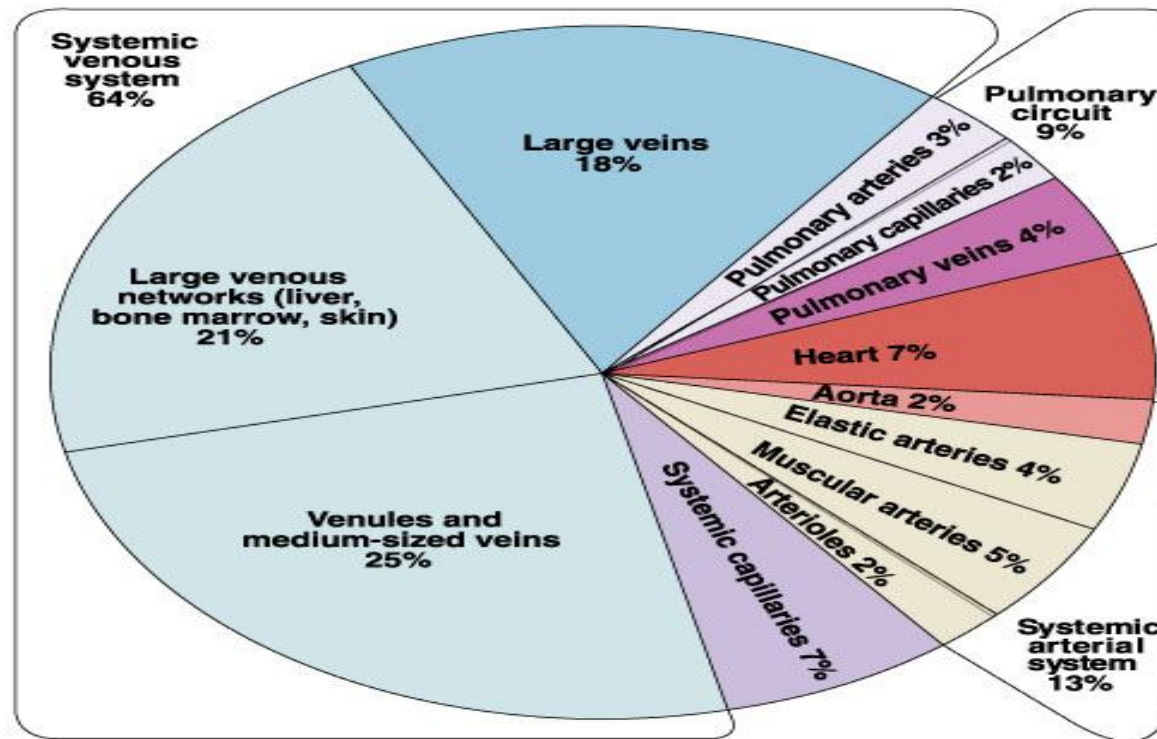
The Angiogenesis Process: How Do New Blood Vessels Grow?for your information only

The process of angiogenesis occurs as an orderly series of events:

1. Diseased or injured tissues produce and release angiogenic growth factors (proteins) that diffuse into the nearby tissues
2. The angiogenic growth factors bind to specific receptors located on the endothelial cells (EC) of nearby preexisting blood vessels
3. Once growth factors bind to their receptors, the endothelial cells become activated. Signals are sent from the cell's surface to the nucleus. The endothelial cell's machinery begins to produce new molecules including enzymes
4. Enzymes dissolve tiny holes in the sheath-like covering (basement membrane) surrounding all existing blood vessels
5. The endothelial cells begin to divide (proliferate), and they migrate out through the dissolved holes of the existing vessel towards the diseased tissue (tumor)
6. Specialized molecules called adhesion molecules, or integrins ($\alpha\beta3$, $\alpha\beta5$) serve as grappling hooks to help pull the sprouting new blood vessel sprout forward
7. Additional enzymes (matrix metalloproteinases, or MMP) are produced to dissolve the tissue in front of the sprouting vessel tip in order to accommodate it. As the vessel extends, the tissue is remolded around the vessel
8. Sprouting endothelial cells roll up to form a blood vessel tube
9. Individual blood vessel tubes connect to form blood vessel loops that can circulate blood
10. Finally, newly formed blood vessel tubes are stabilized by specialized muscle cells (smooth muscle cells, pericytes) that provide structural support. Blood flow then begins

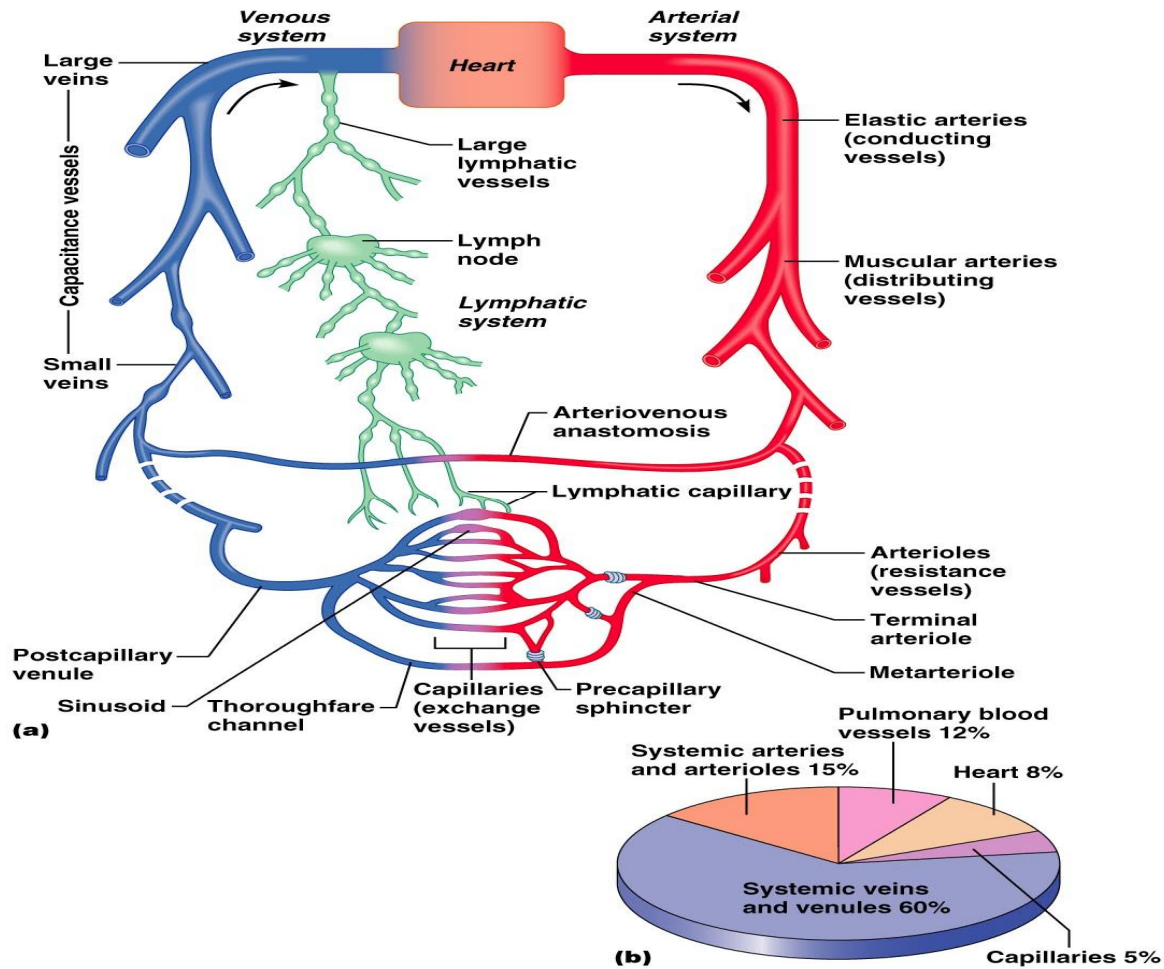
http://www.angio.org/patients/cancer/understanding_angiogenesis.html

The Distribution of Blood



Blood Vessels

- Blood is carried in a closed system of vessels that begins and ends at the heart
- Arteries carry blood away from the heart, veins carry blood toward the heart
- Capillaries contact tissue cells and directly serve cellular needs

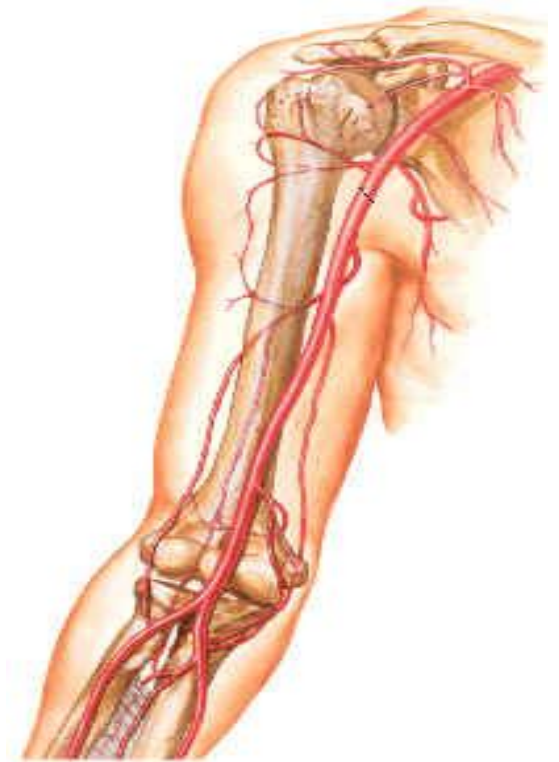

Type of blood vessels

- Arteries [small[arterioles], medium, large]
- Veins [small[veinules], medium, large]
- Capillaries
- Lymphatics

The Vascular Anastomosis

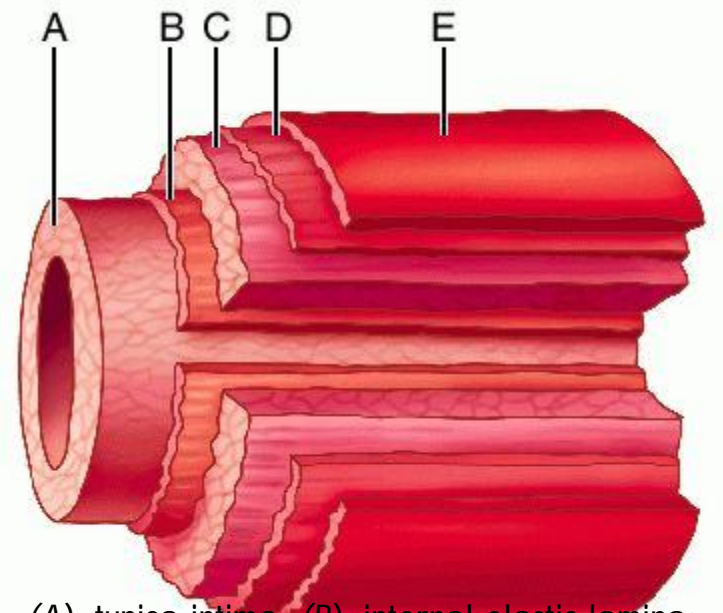
- 1. Arterial anastomosis arterial arch**
- 2. Venous anastomosis venous arch**
- 3. Arteriovenous anastomosis :
arteriolo-venular anastomosis**
- 4. Venous plexus**
- 5. Collateral anastomosis collateral
vessel collateral circulation**



Systematic Anatomy

Generalized Structure of Blood Vessels

- **Arteries and veins are composed of three tunics –**
 - ▣ **tunica interna,**
 - ▣ **tunica media,**
 - ▣ **tunica externa**
- Lumen – central blood-containing space surrounded by tunics
- Capillaries are composed of endothelium with sparse basal lamina



(A), tunica intima; (B), internal elastic lamina; (C), tunica media; (D), external elastic lamina; (E), tunica externa.

The arterial wall is composed of three main layers or tunics.

- **Tunica intima** (internal tunic) consisting of :
 - **endothelium** (single lining layer of endothelial cells) **sub-endothelial** connective tissue basement membrane **layer inner elastic limiting membrane** (elastic lamina, which after fixation appears undulating).

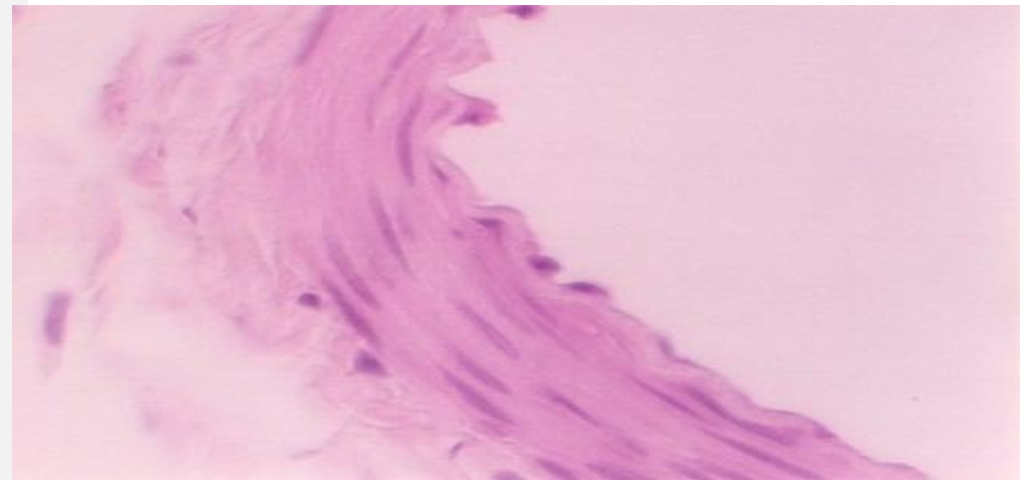
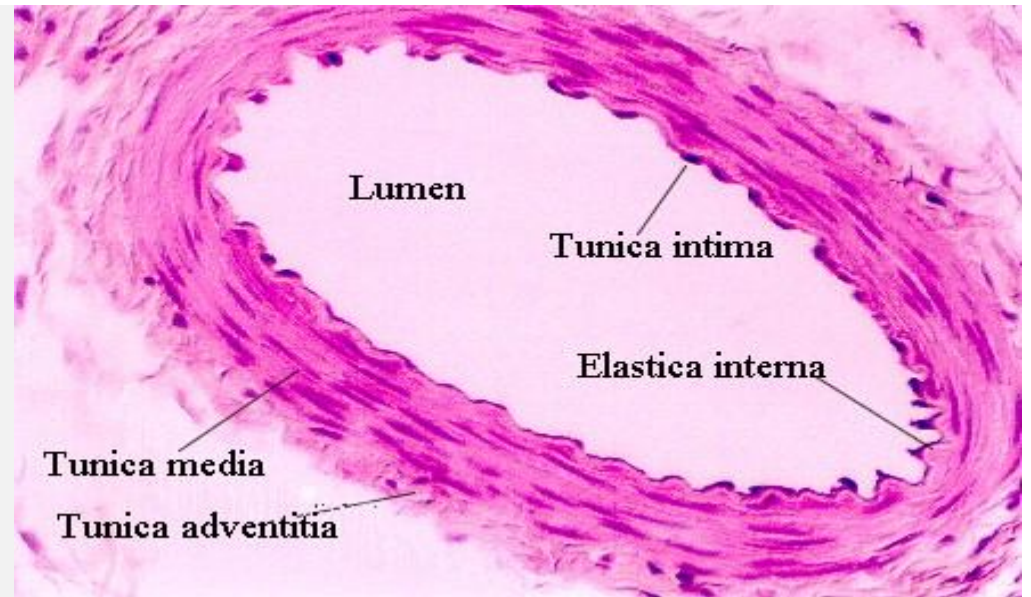
- **Tunica media** (middle tunic) consisting of :
 - **circular smooth muscle** (or spiral)
 - **concentric elastic lamina** (formed by the smooth muscle cells).
 - Smooth muscle and elastic fiber layer, regulated by sympathetic nervous system
 - Controls vasoconstriction/vasodilation of vessels

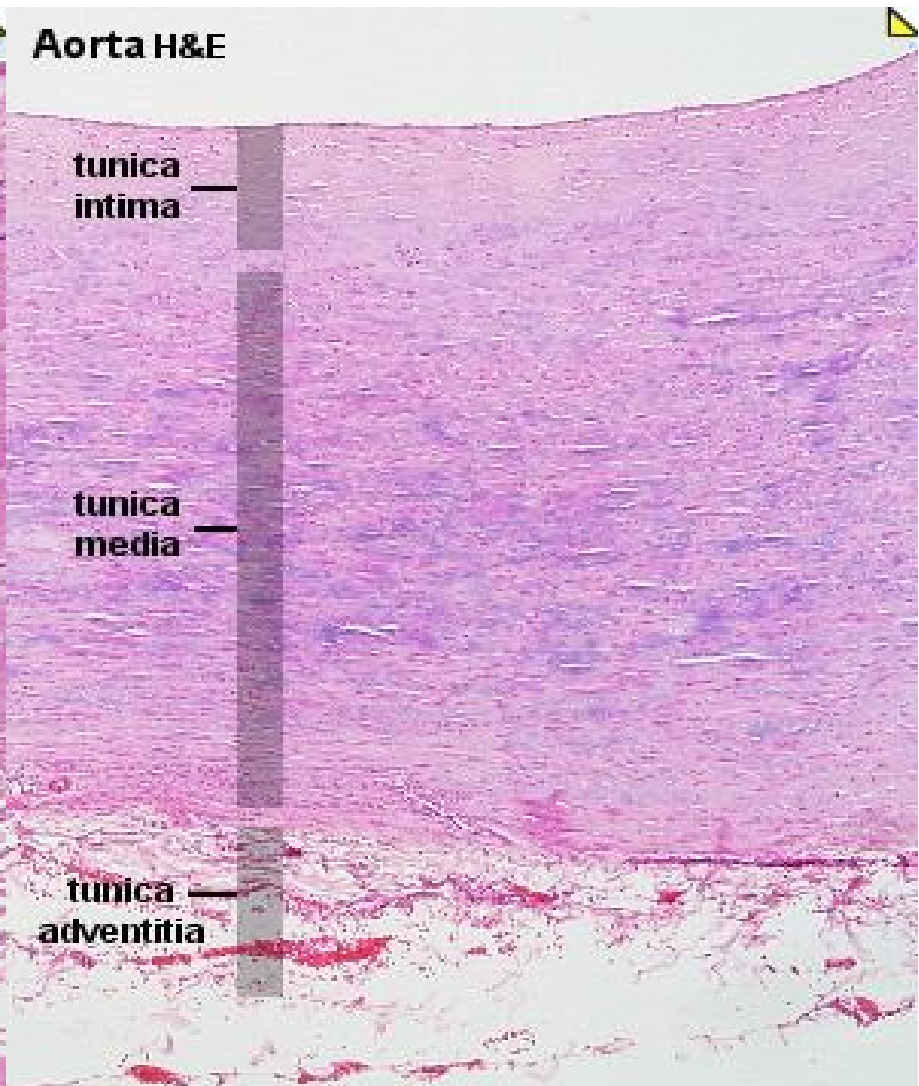
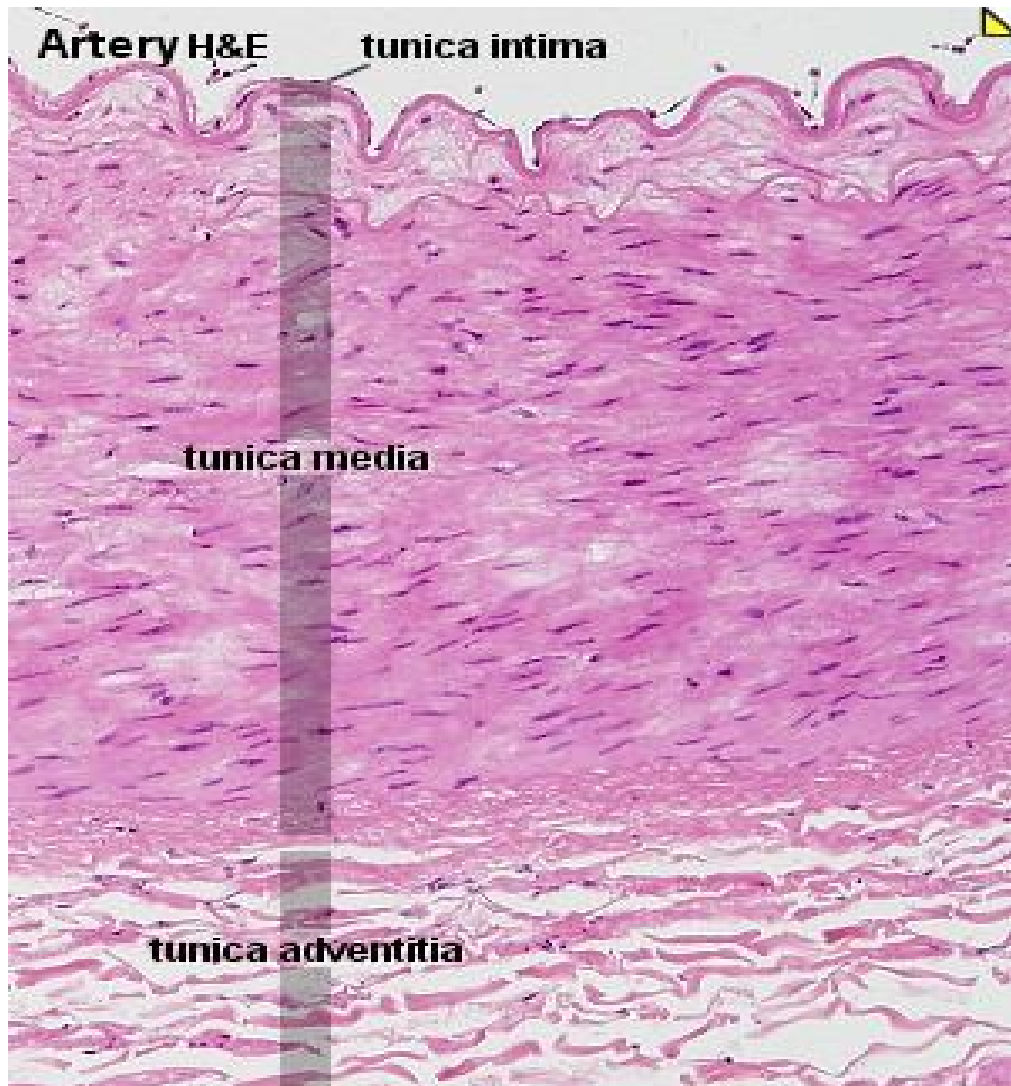
- **Adventitia = tunica externa** (outer layer) composed of :
 - Collagen fibers that protect and reinforce vessels
 - Larger vessels contain vasa vasorum

 - **connective tissue** surrounding the vessel **outer elastic limiting membrane** (on the border between the *Tunica media* and the *Adventitia* **Vasa vasorum**. These are small blood vessels supplying oxygen and nutrients to the wall of the artery. The blood flow in the arterial lumen is too great for exchange of oxygen or nutrients.

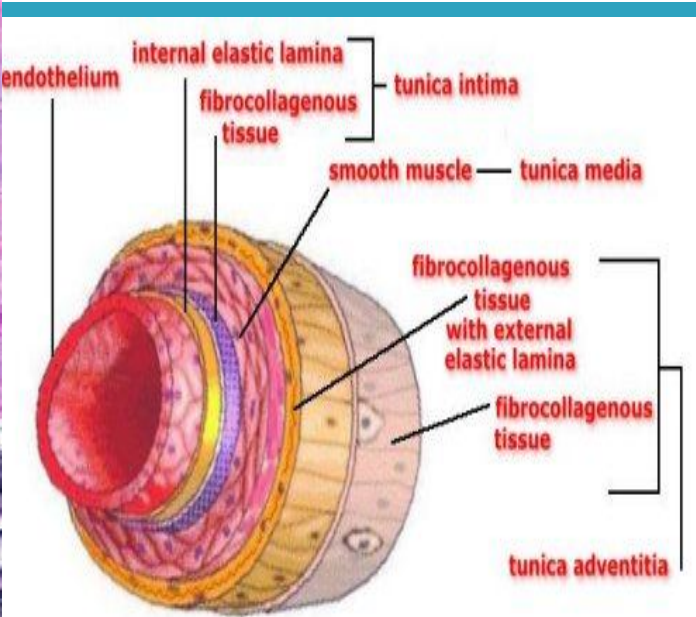
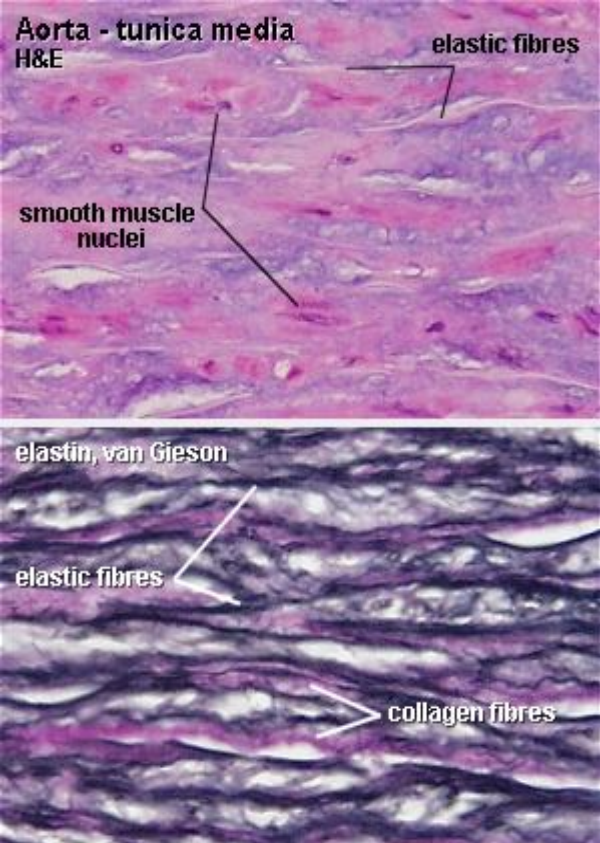
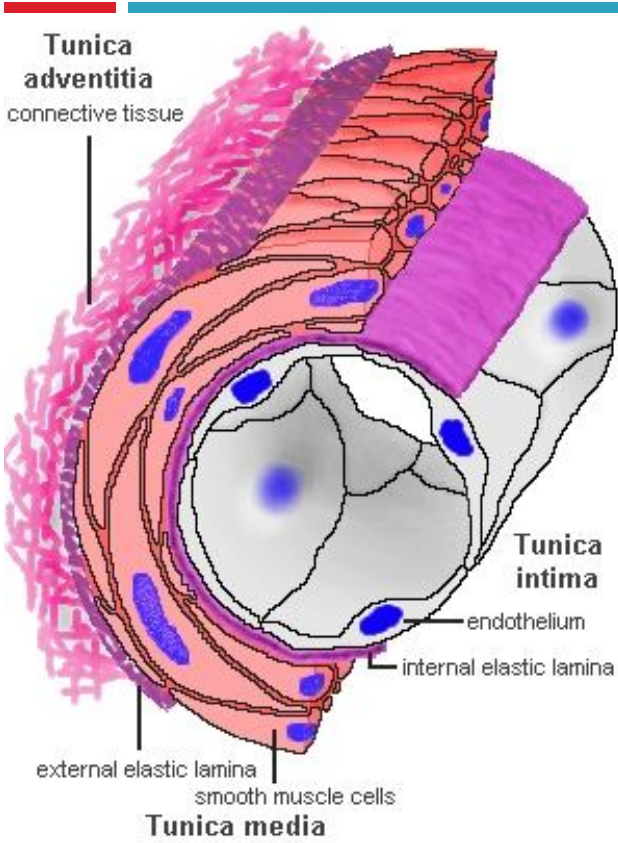
□ Muscular Arteries

- 1) Blood vessels contain each of the major tissue types: epithelia (called endothelia), connective tissue, muscle, and nerve fibers.
- The **Tunica intima** is a simple endothelial layer, made of simple squamous cells.
- Underneath is an internal elastic membrane, the **elastica interna.**
- Then, there is a smooth muscle layer, **the tunica media.**
- This is followed by a poorly defined outer elastic layer.
- Finally, the Adventia is connective tissue (loose) that blends into the surrounding connective tissue.



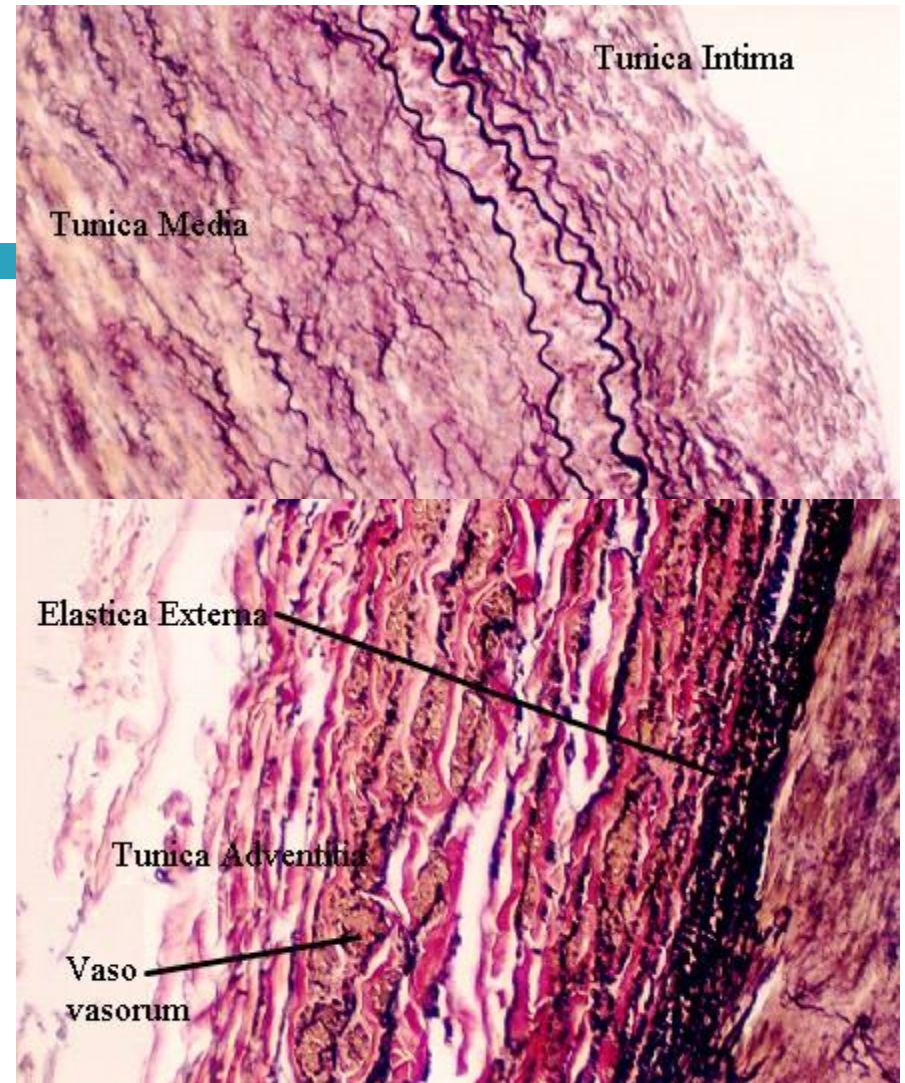


Muscular artery

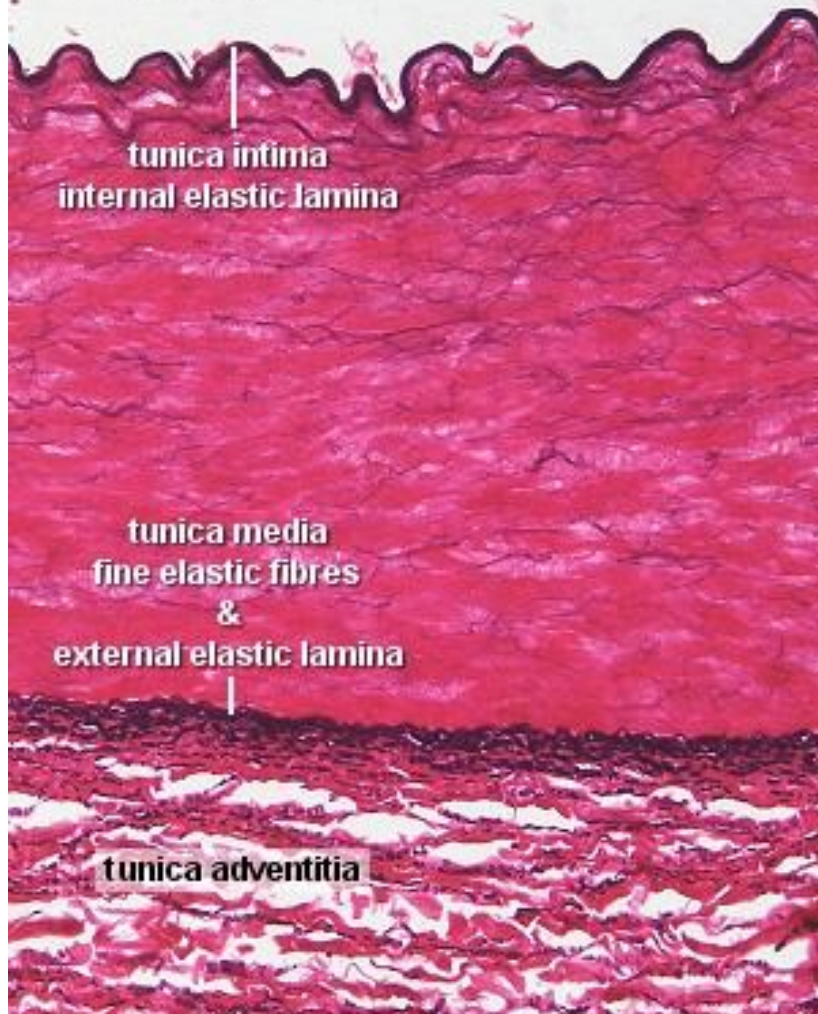


Elastic Artery

- The elastic artery is a specialized type of artery designed for distension and elasticity.
- The largest of these also have connective tissue underneath the endothelium.
- A good example of an elastic artery is the aorta.

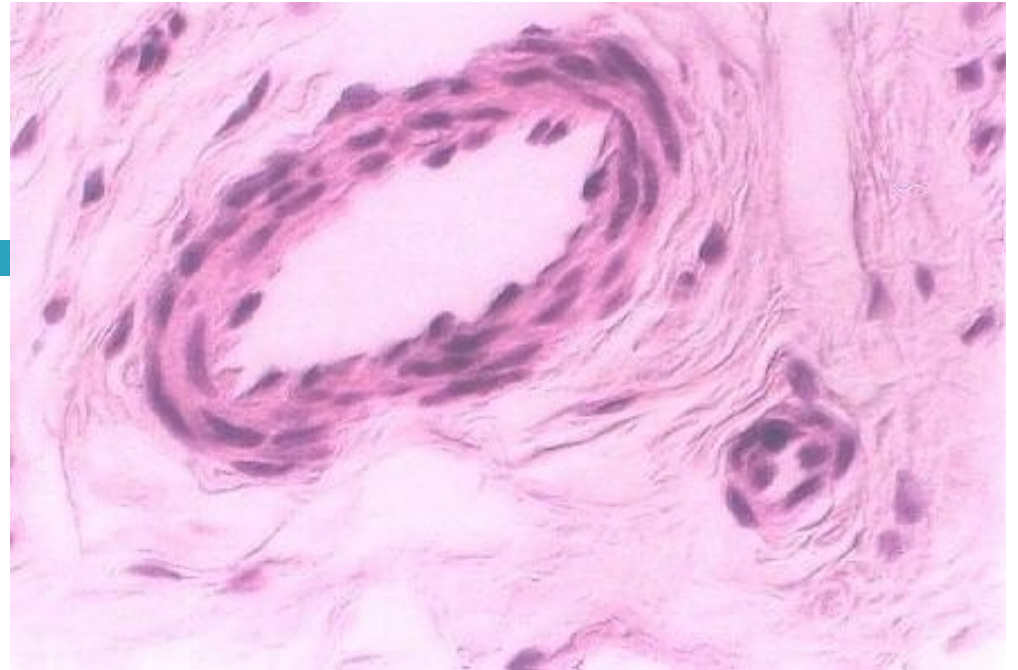


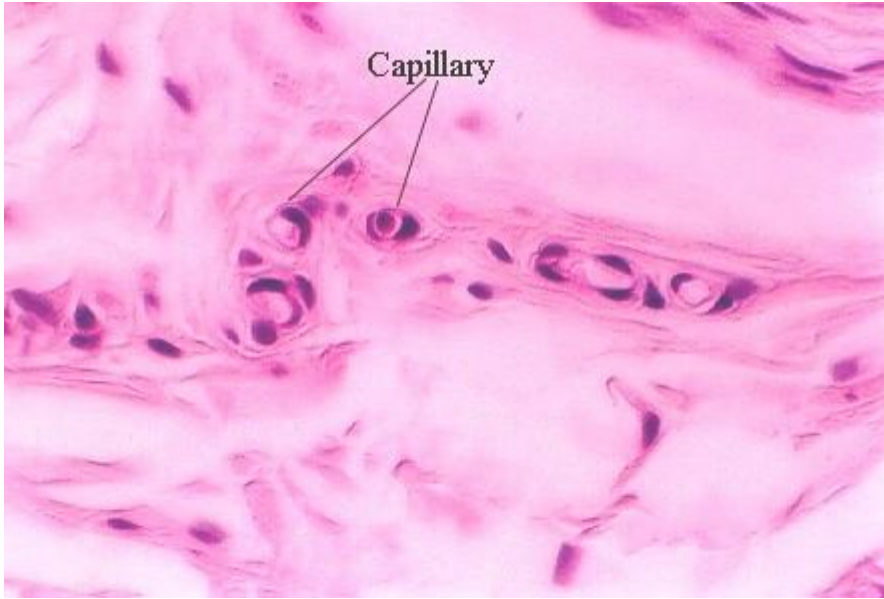
Artery elastin & eosin



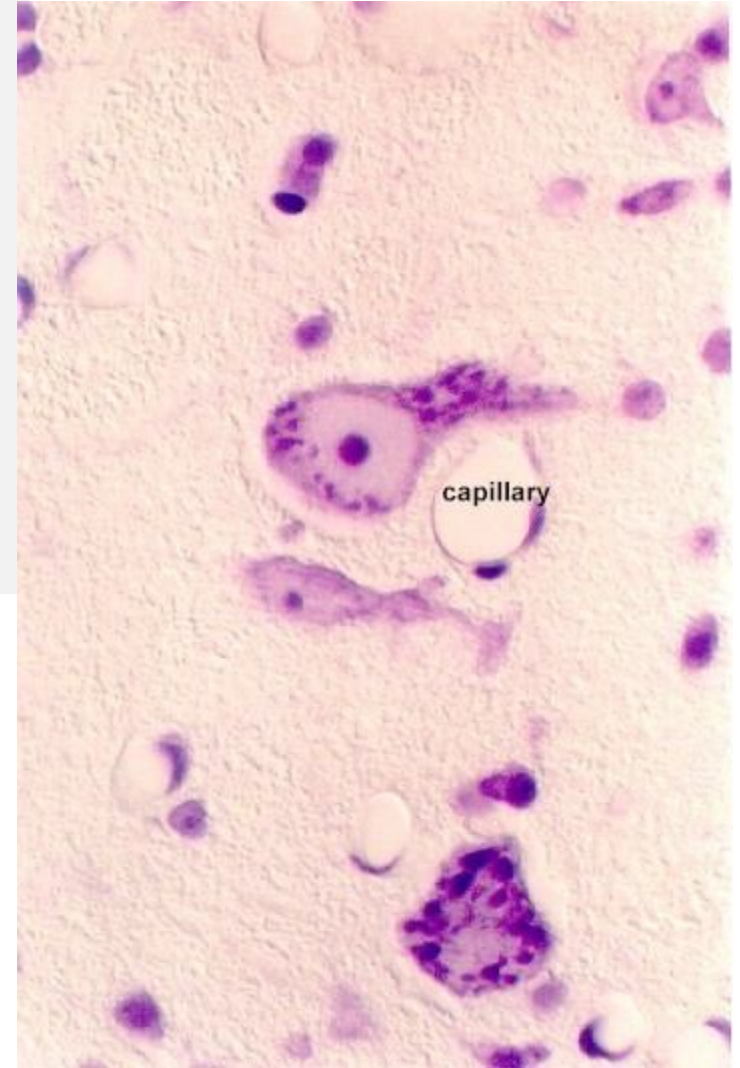
Arterioles

- Arterioles can be differentiated from arteries by the numbers of layers of smooth muscle.
- Usually there are no more than 6 layers.
- The smaller of the two vessels is often called a "precapillary arteriole" because of the number of smooth muscle layers.

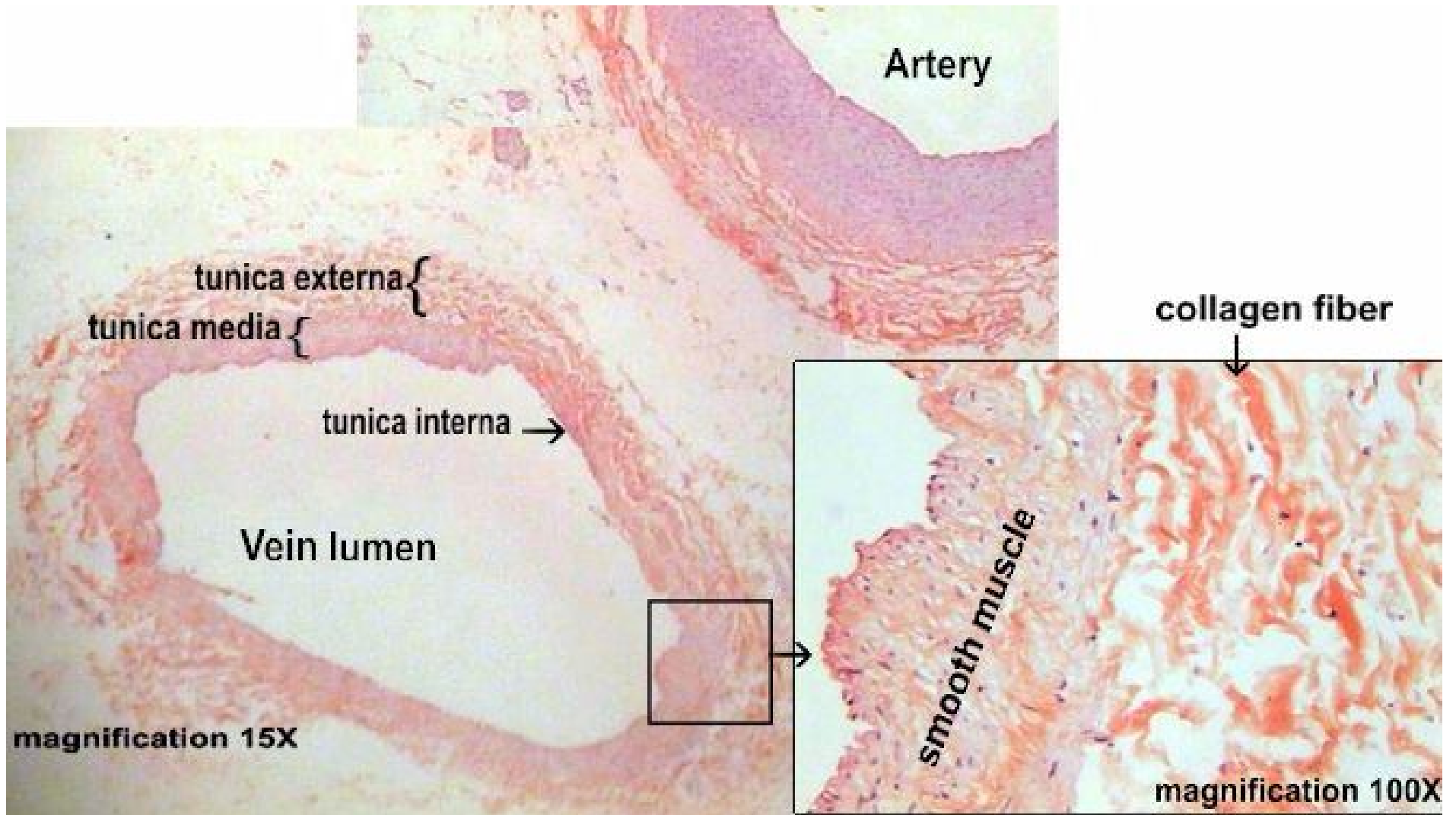


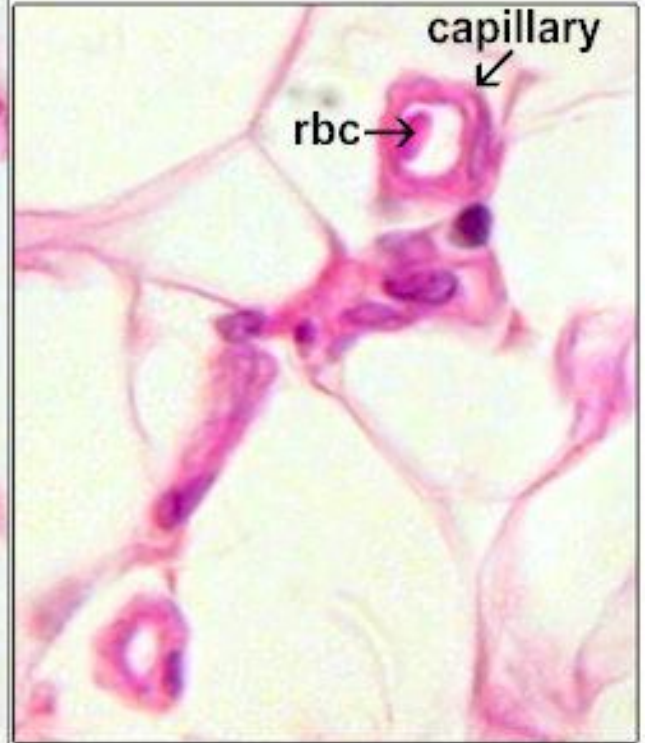
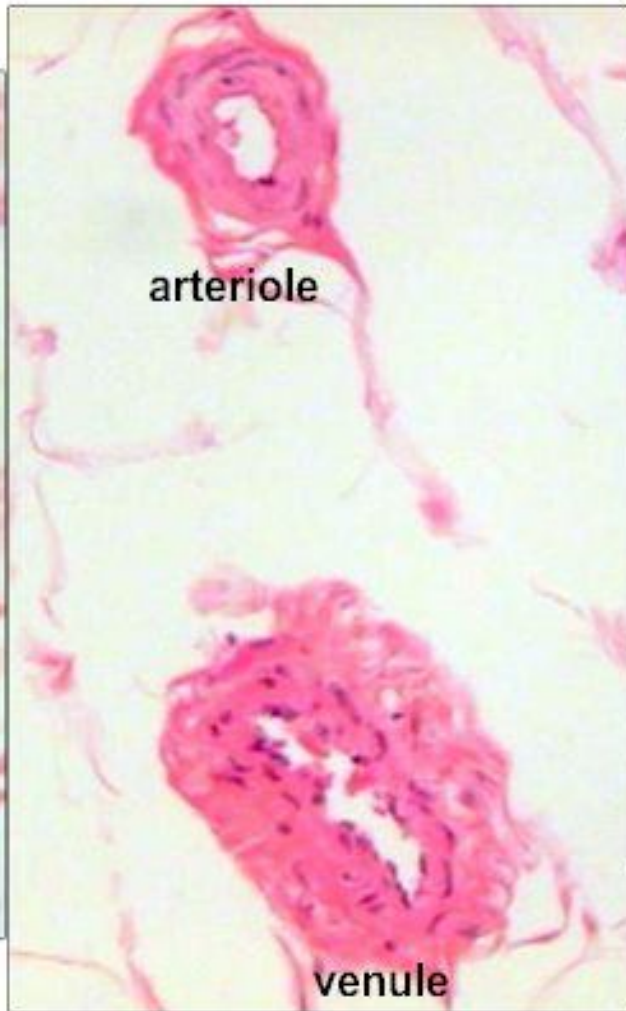
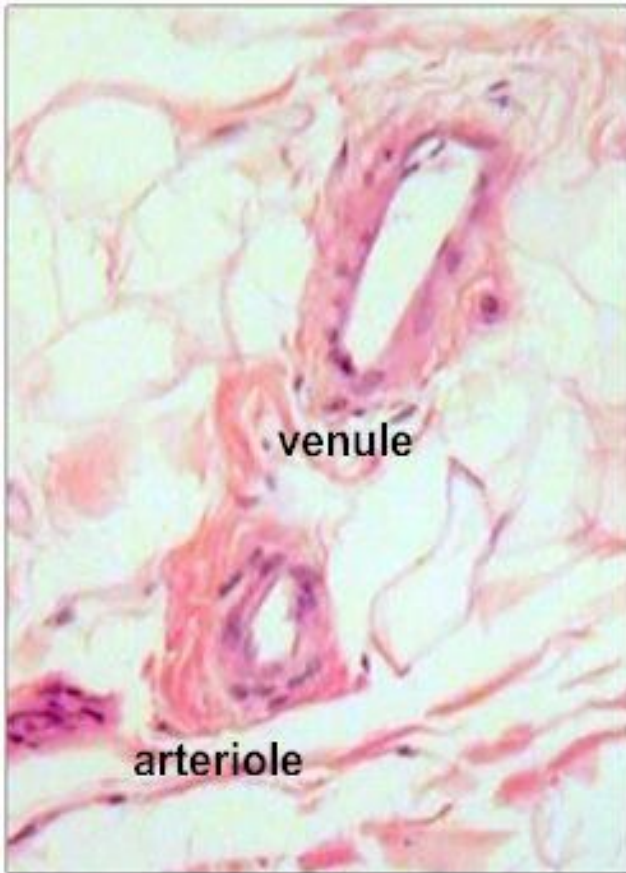


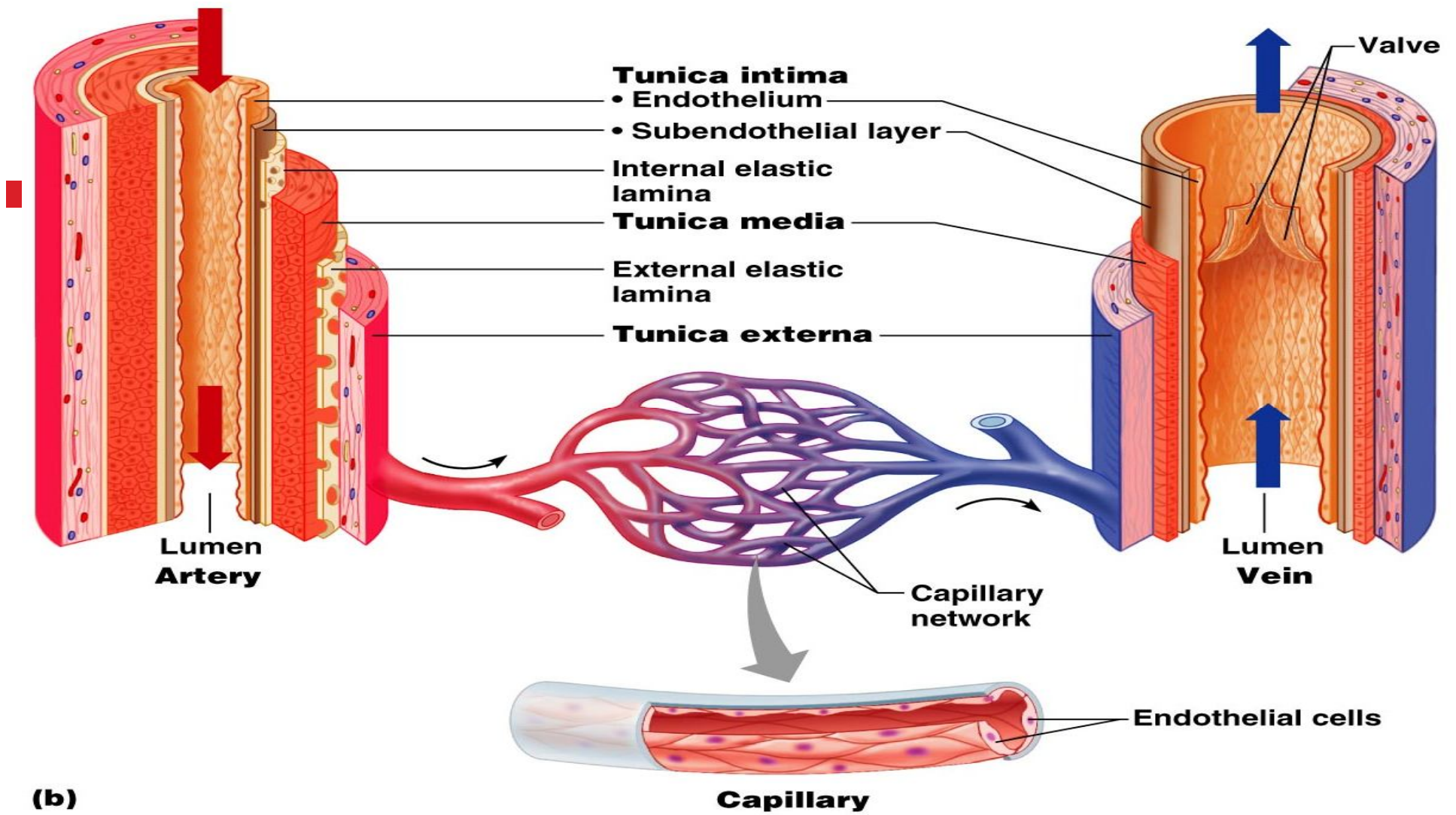
Capillaries

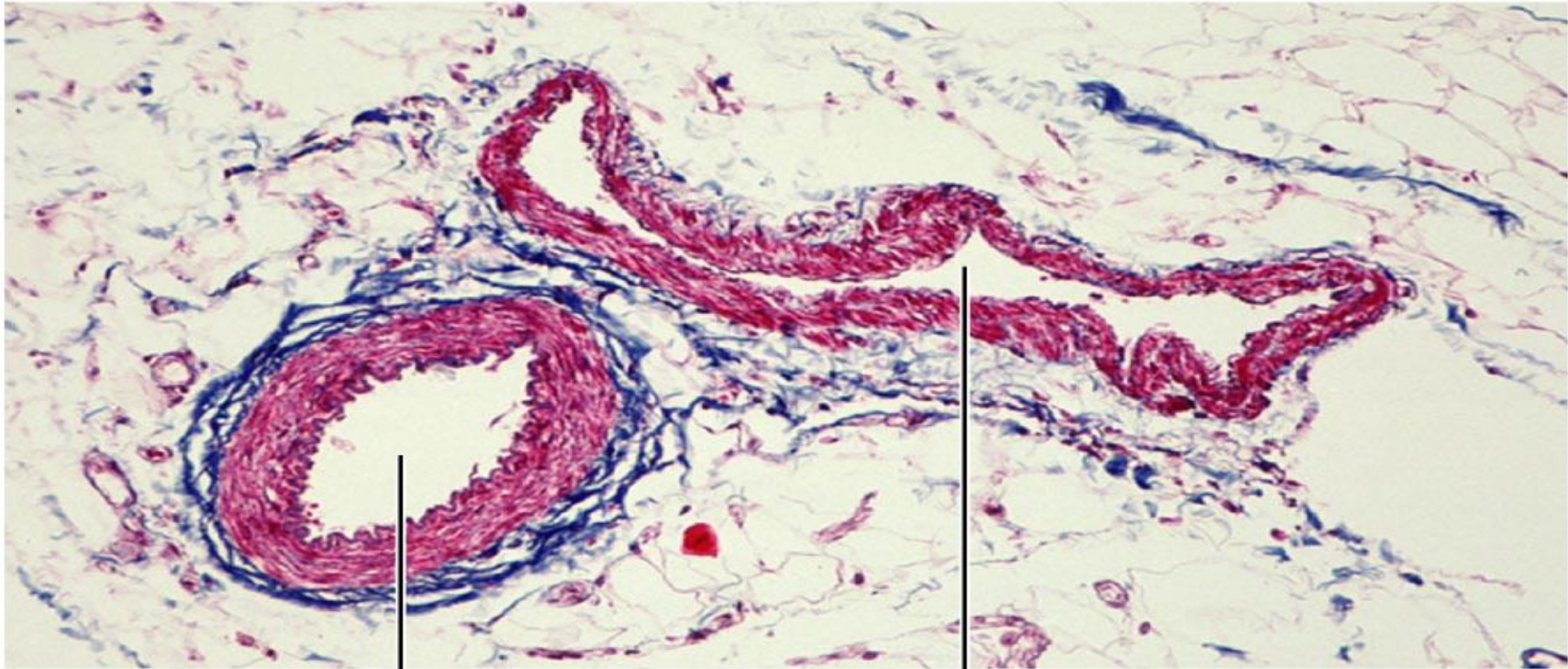


- Capillaries are tiny vessels lined by a single layer of endothelial cells.
- Capillary accomodates only one blood cell.









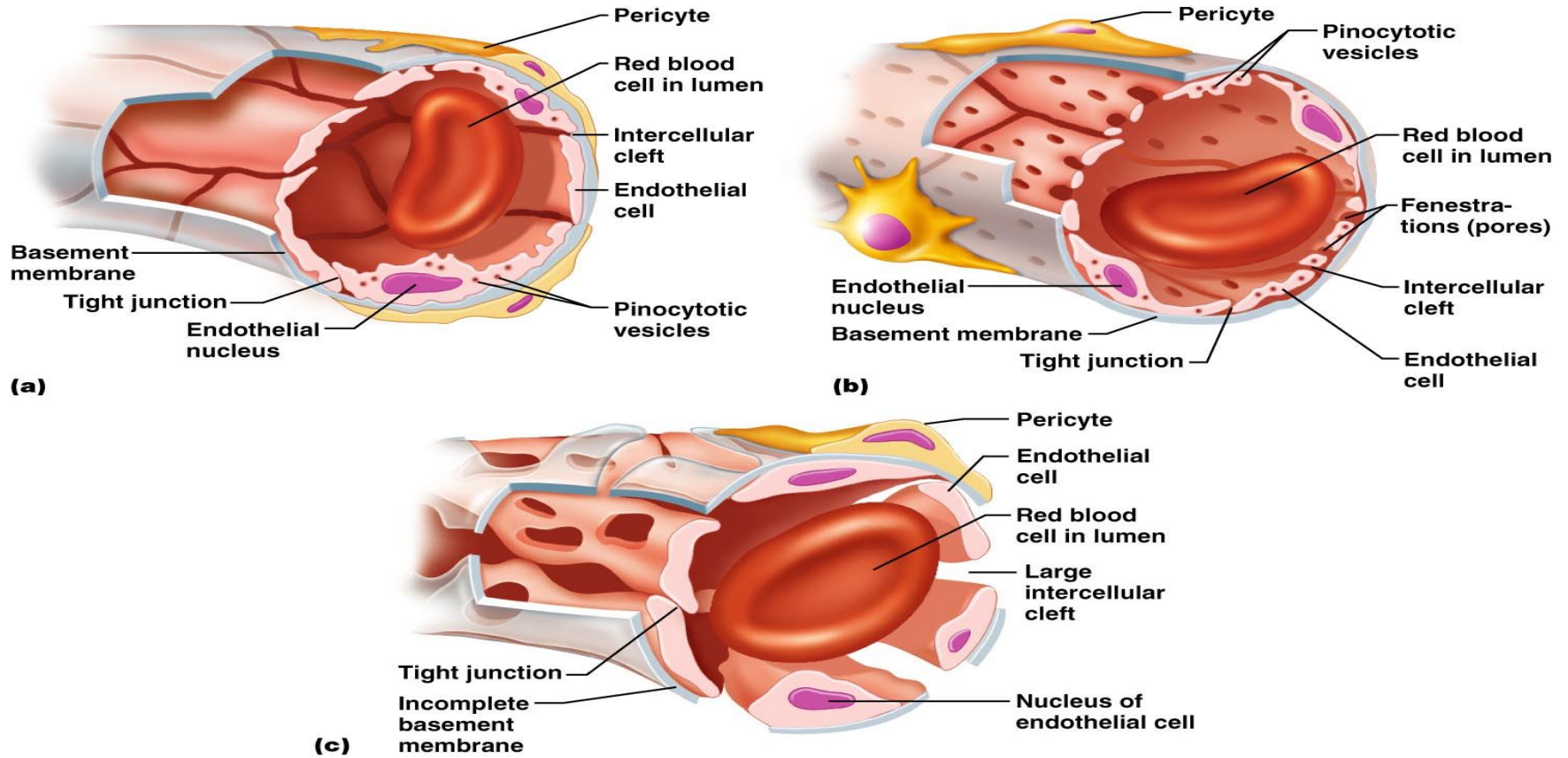
Artery

Vein

(a)

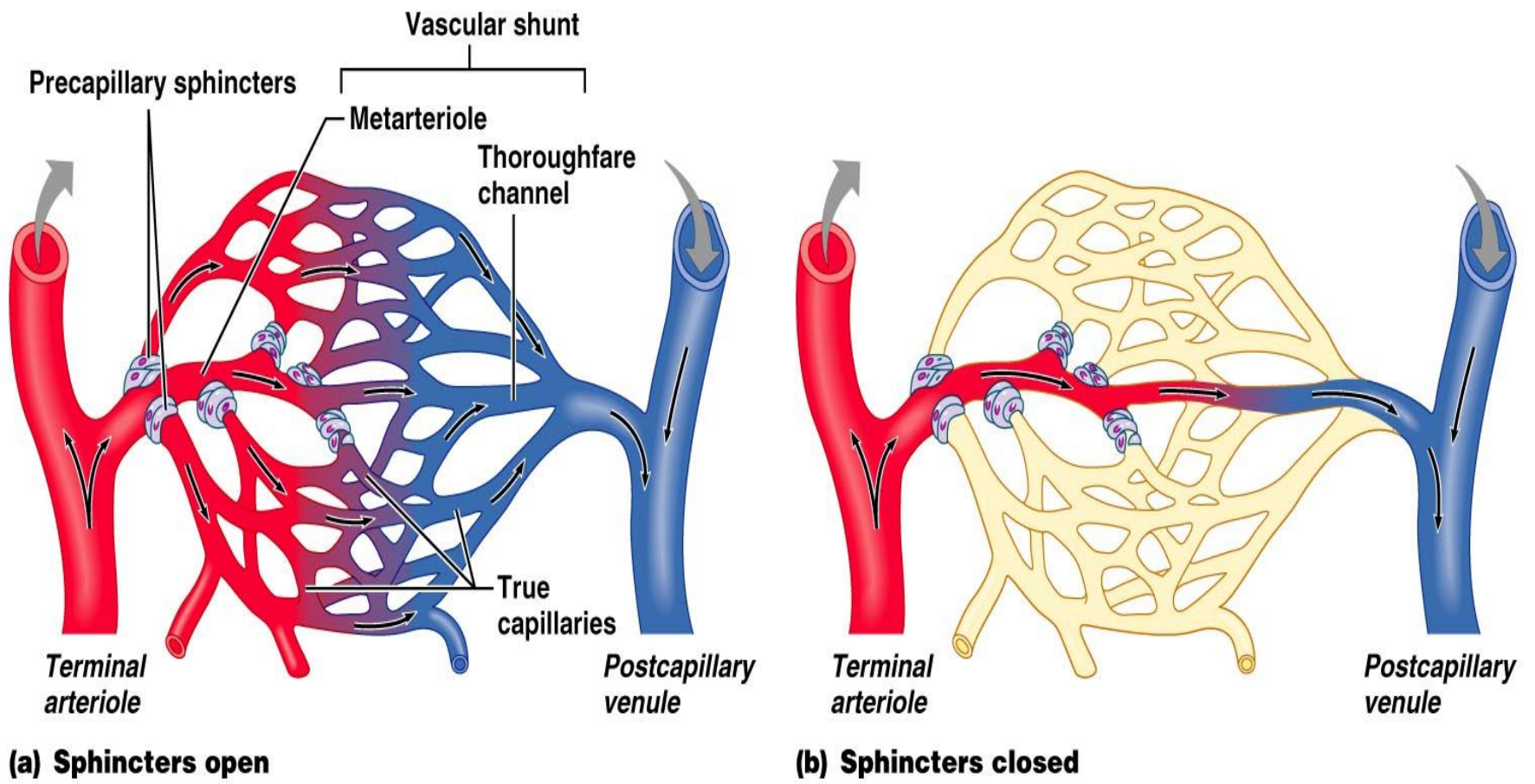
Copyright © 2006 Pearson Education, Inc., publishing as Benjamin Cummings.

Figure 19.1a



Copyright © 2006 Pearson Education, Inc., publishing as Benjamin Cummings.

Figure 19.3



Copyright © 2006 Pearson Education, Inc., publishing as Benjamin Cummings.

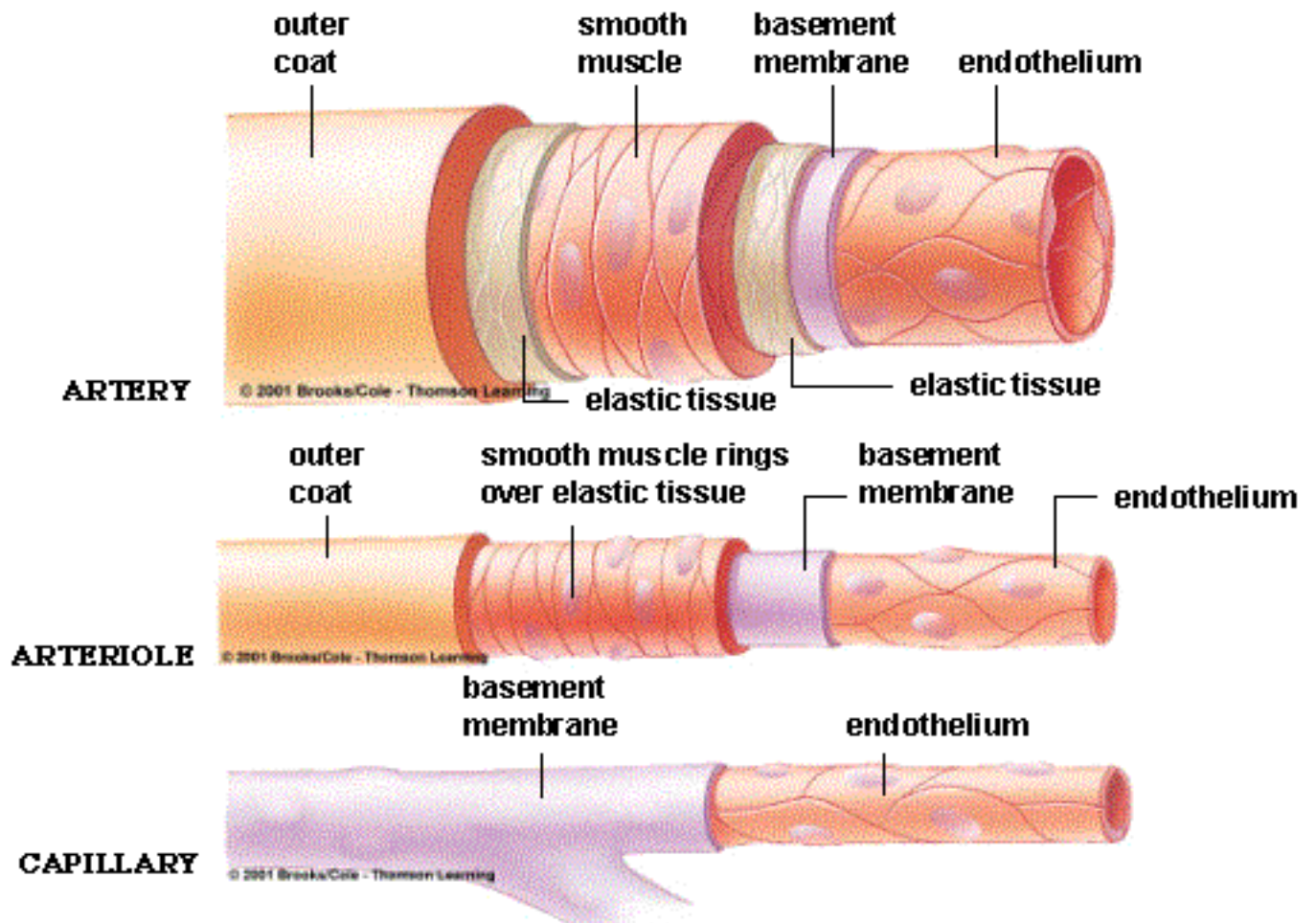
Figure 19.4

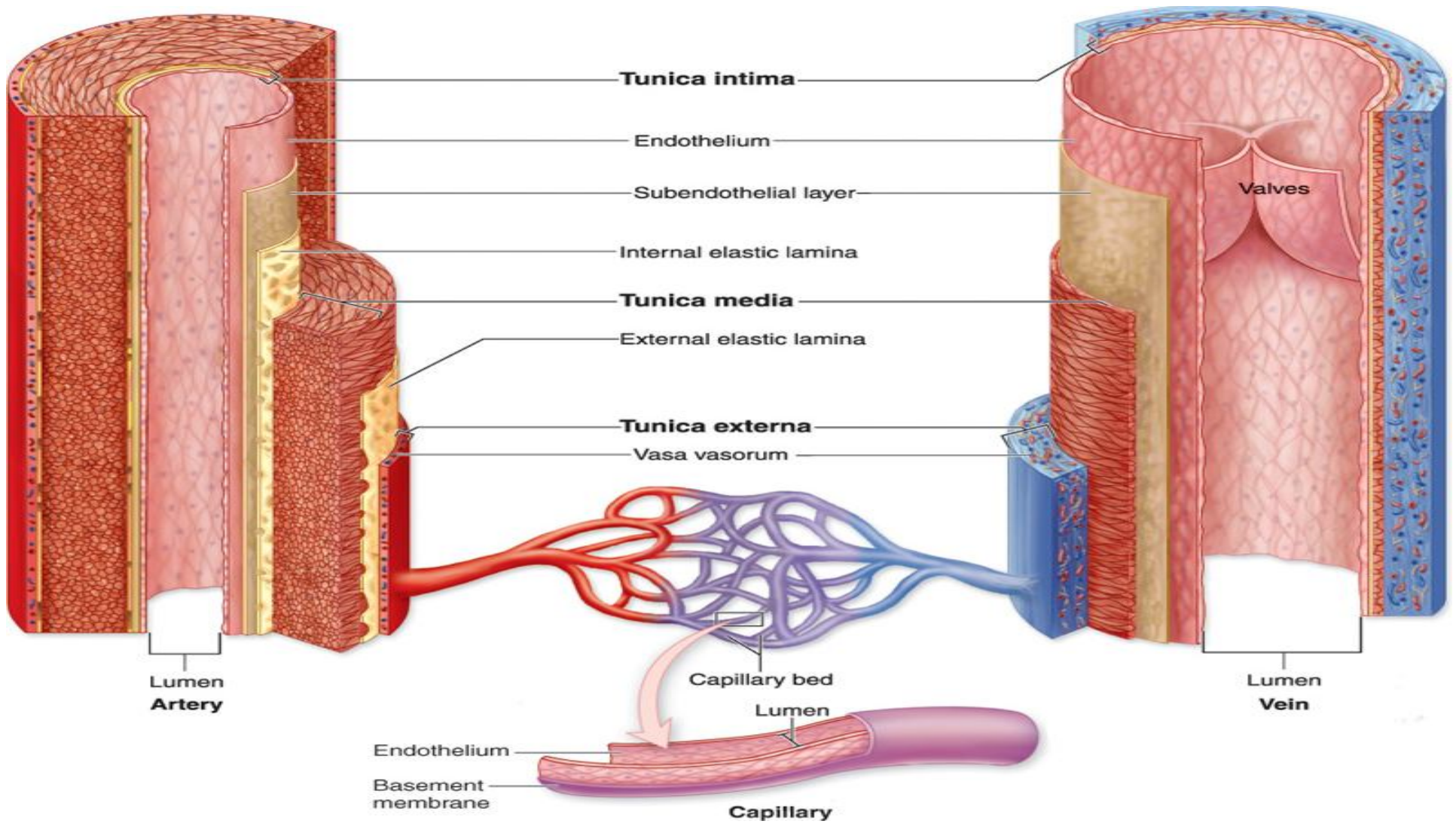
Blood Vessels

Arteries: main transporters of oxygenated blood

Arterioles: diameter is adjusted to regulate blood flow

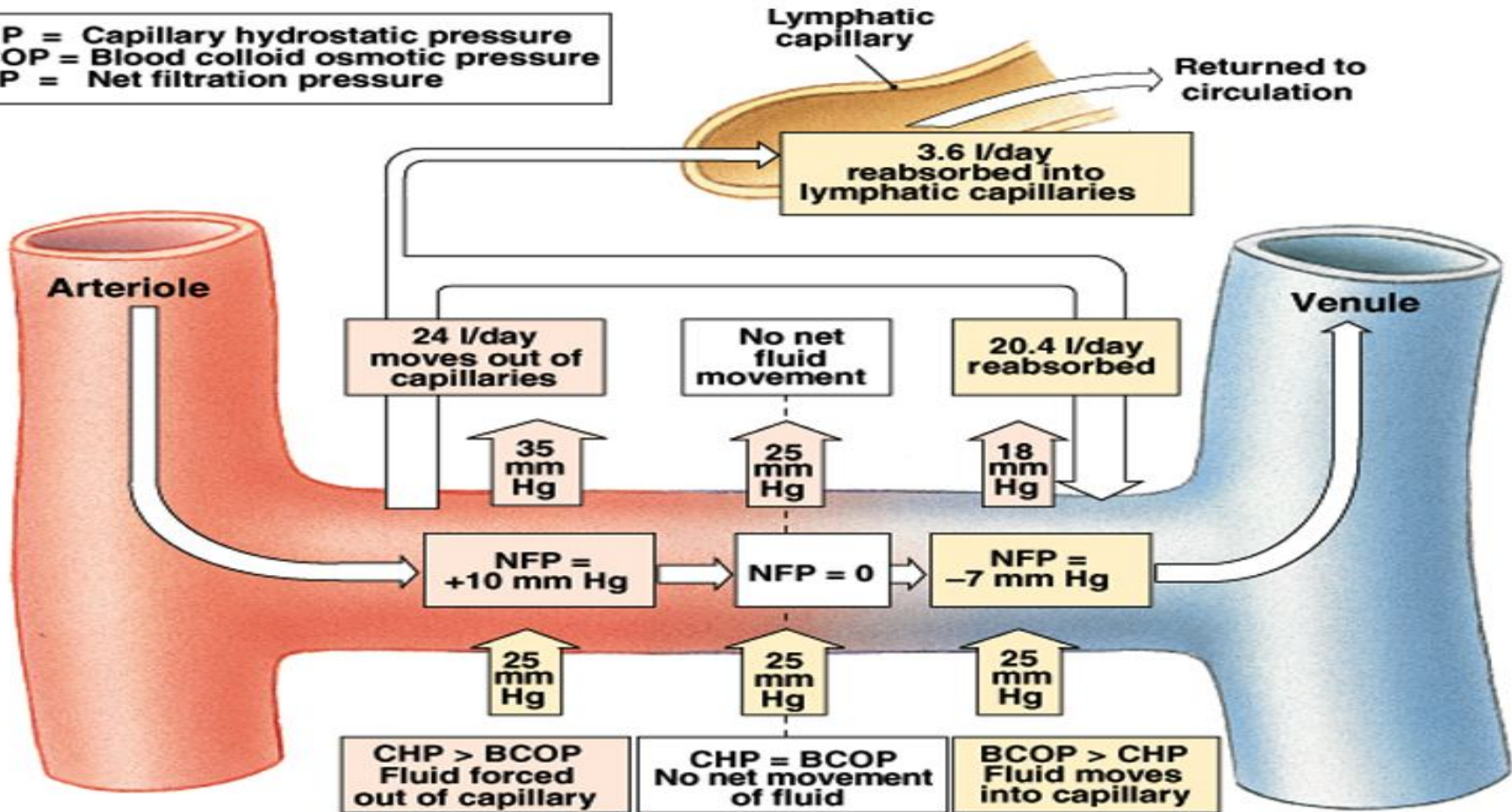
Capillaries: diffusion occurs across thin walls

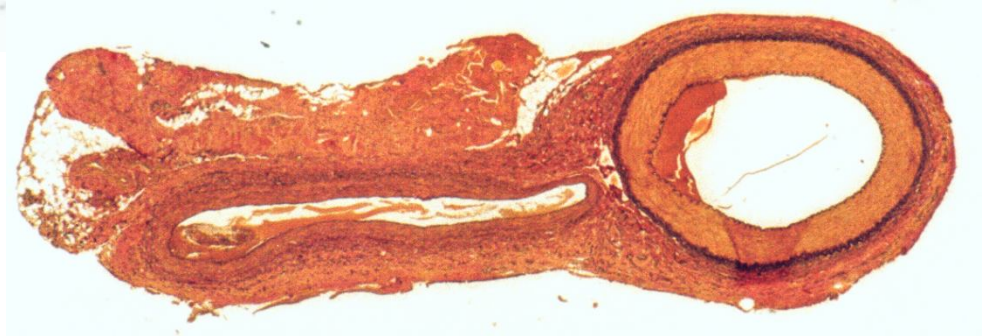
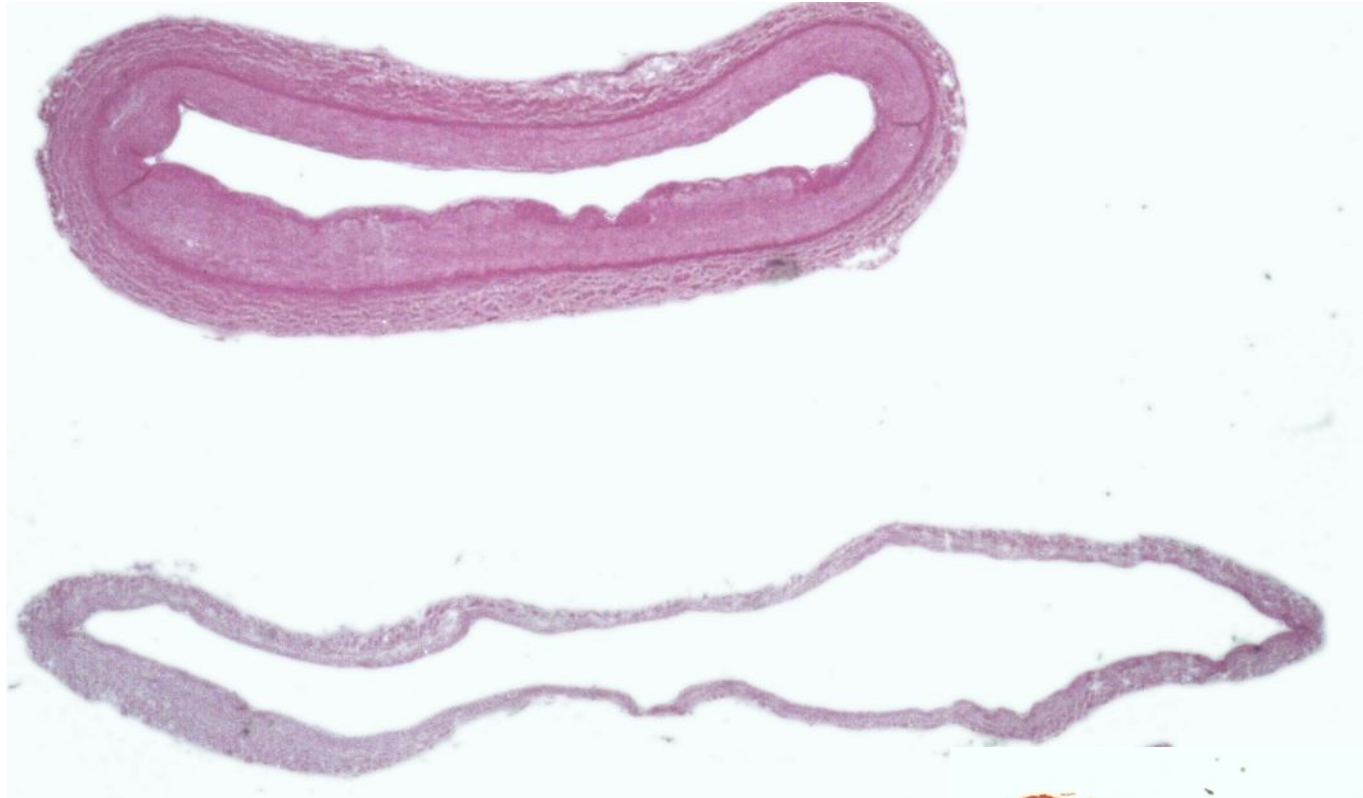


Capillary Exchange

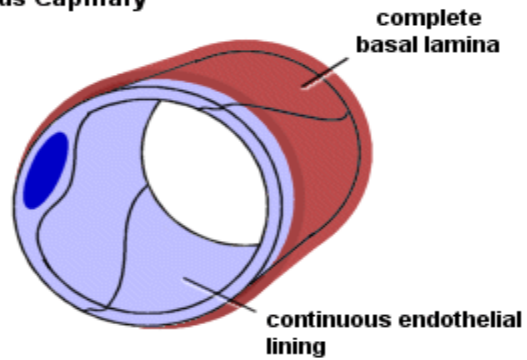
CHP = Capillary hydrostatic pressure
BCOP = Blood colloid osmotic pressure
NFP = Net filtration pressure



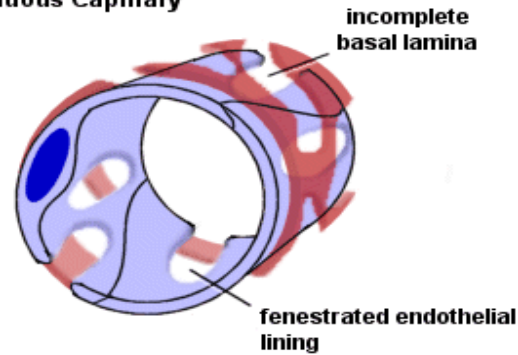


Blood Vessel Anatomy

Continuous Capillary



Discontinuous Capillary



Fenestrated Capillary

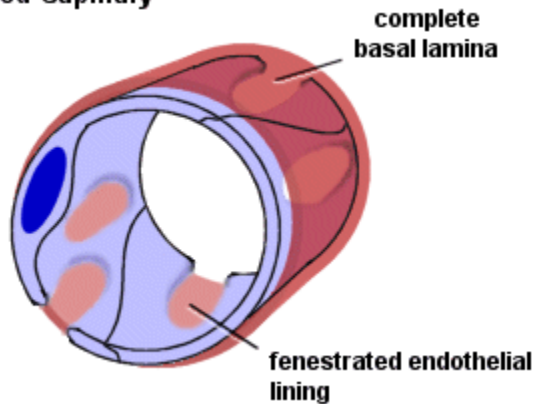


TABLE 19.1 Summary of Blood Vessel Anatomy

VESSEL TYPE/ ILLUSTRATION*	AVERAGE LUMEN DIAMETER (D) AND WALL THICKNESS (T)	RELATIVE TISSUE MAKEUP			
		Endothelium	Elastic Tissues	Smooth Muscles	Fibrous (Collagenous) Tissues
Elastic artery	D : 1.5 cm T : 1.0 mm	Low	High	High	Low
Muscular artery	D : 6.0 mm T : 1.0 mm	Low	Low	High	High
Arteriole	D : 37.0 μ m T : 6.0 μ m	Low	Low	High	High
Capillary	D : 9.0 μ m T : 0.5 μ m	High	Low	Low	Low
Venule	D : 20.0 μ m T : 1.0 μ m	High	Low	Low	Low
Vein	D : 5.0 mm T : 0.5 mm	Low	Low	Low	High

*Size relationships are not proportional. Smaller vessels are drawn relatively larger so detail can be seen. See column 2 for actual dimensions.

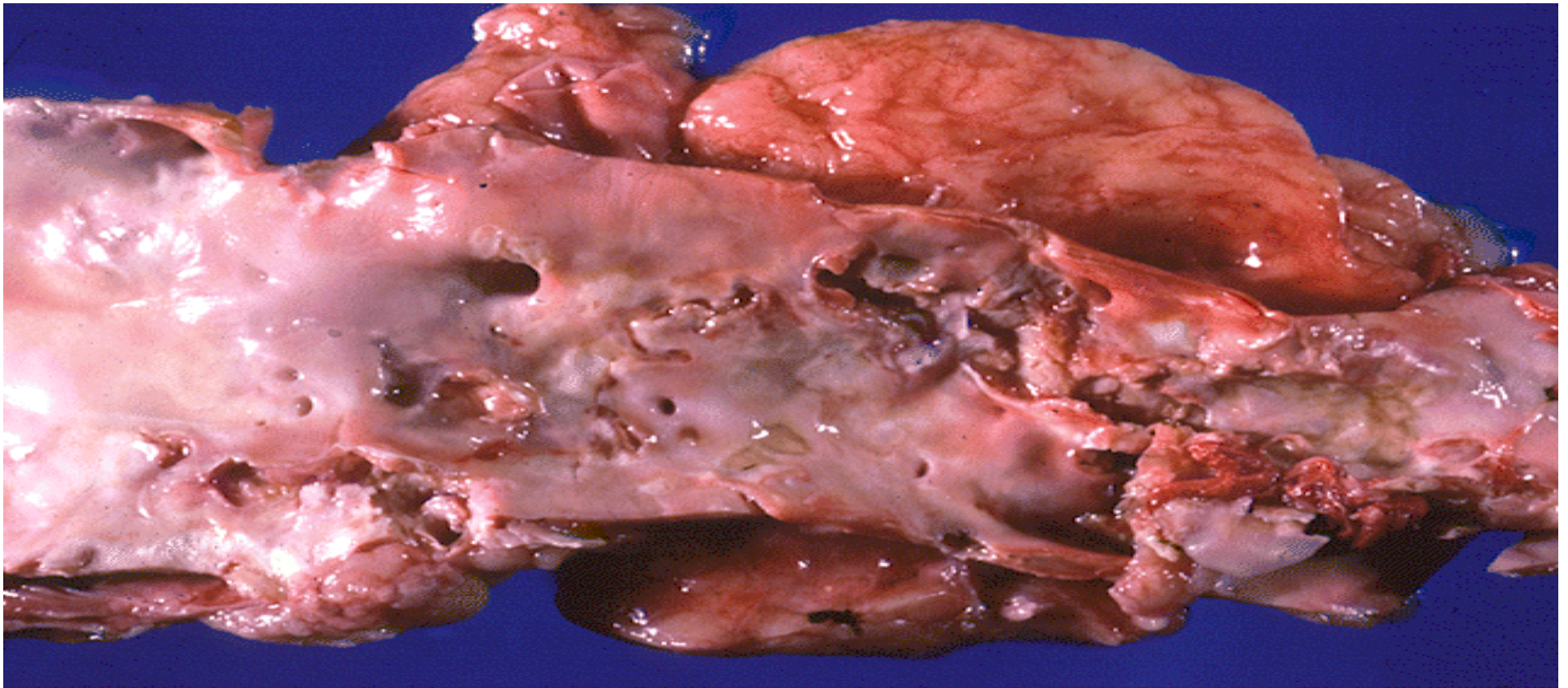
Elastic (Conducting) Arteries

- Thick-walled arteries near the heart; the aorta and its major branches
 - ▣ Large lumen allow low-resistance conduction of blood
 - ▣ Contain elastin in all three tunics
 - ▣ Withstand and smooth out large blood pressure fluctuations
 - ▣ Serve as pressure reservoirs

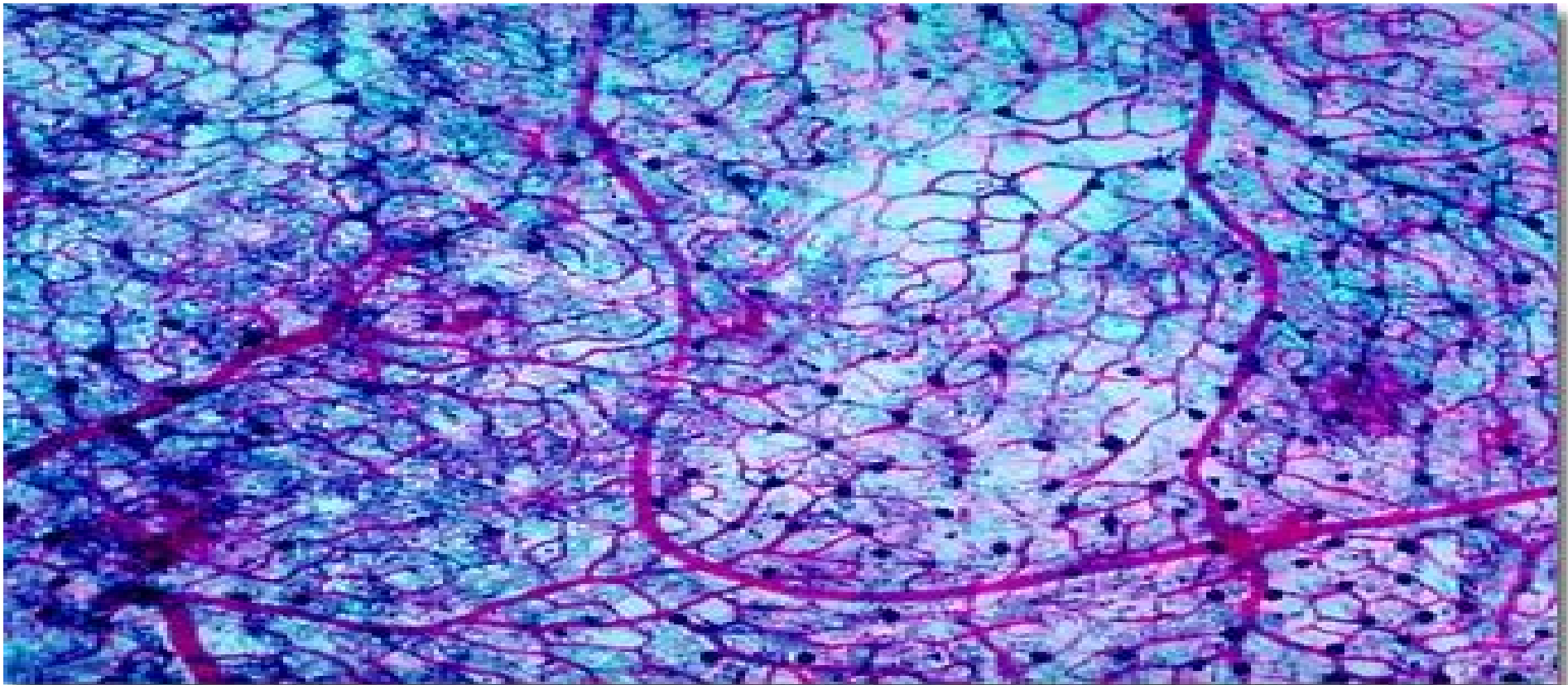
Muscular (Distributing) Arteries and Arterioles

- Muscular arteries – distal to elastic arteries; deliver blood to body organs
 - ▣ Have thick tunica media with more smooth muscle
 - ▣ Active in vasoconstriction
- Arterioles – smallest arteries; lead to capillary beds
 - ▣ Control flow into capillary beds via vasodilation and constriction

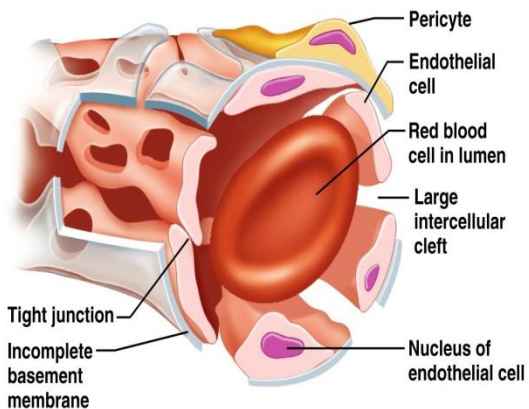
Atherosclerosis



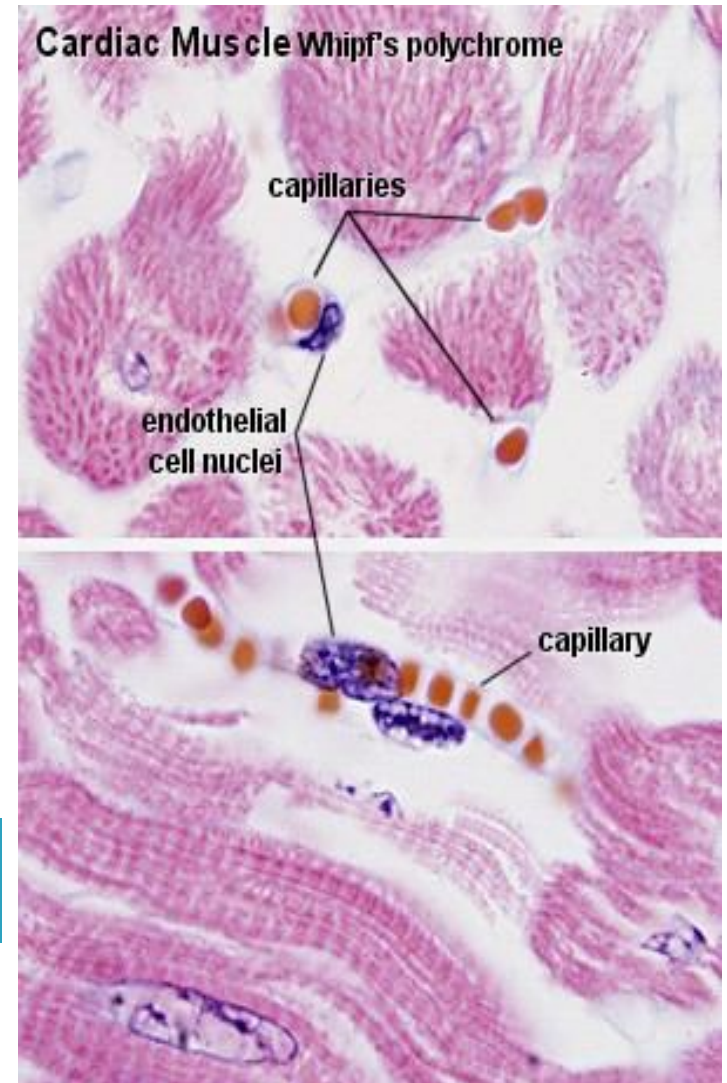
capillaries



- Capillaries are the smallest blood vessels
 - ▣ Walls consisting of a thin tunica interna, one cell thick
 - ▣ Allow only a single RBC to pass at a time
 - ▣ **Pericyte** on the outer surface stabilize their walls
- There are three structural types of capillaries: **continuous, fenestrated, and sinusoids**



Capillaries



Continuous capillaries

are formed by "**continuous" endothelial cells and basal lamina.**

The endothelial cell and the basal lamina do not form openings, which would allow substances to pass the capillary wall without passing through both the endothelial cell and the basal lamina.

Both endothelial cells and the basal lamina can act as selective filters in continuous capillaries.

Fenestrated capillaries

The endothelial cell body forms **small openings called fenestrations,** which allow components of the blood and interstitial fluid to bypass the endothelial cells on their way to or from the tissue surrounding the capillary.

The fenestrations may represent or arise from **pinocytotic vesicles which open onto both the luminal and basal surfaces of the cell.**

The extent of the fenestration may depend on the physiological state of the surrounding tissue, i.e. fenestration may increase or decrease as a function of the need to absorb or secrete.

The endothelial cells are surrounded by a continuous basal lamina, which can act as a selective filter.

Discontinuous capillaries

are formed by fenestrated endothelial cells, which may not even form a complete layer of cells.

The basal lamina is also incomplete.

Discontinuous capillaries form large irregularly shaped vessels, sinusoids or sinusoid capillaries.

They are found where a very free exchange of substances or even cells between bloodstream and organ is **advantageous (e.g. in the liver, spleen, and red bone marrow).**

Pericytes (Perivascular cells)

Many capillaries have inconspicuous, elongated cells, similar in appearance to embryonic mesenchymal cells, associated with them.

These cells, known as **pericytes**, or **perivascular cells**, are quite difficult to see in most histological preparations.

These pericytes appear to have important roles in repair of blood vessels and connective tissue after injury.

They have the potential to develop into fibroblasts, smooth musccells and may even be phagocytic.

Endothelial cells are known to produce a variety of local factors that are important in the functioning of the cardiovascular system. These include nitric oxide.

A **pericyte**, also known as **Rouget cell** or mural cell, is a mesenchymal-like cell, associated with the walls of small blood vessels.

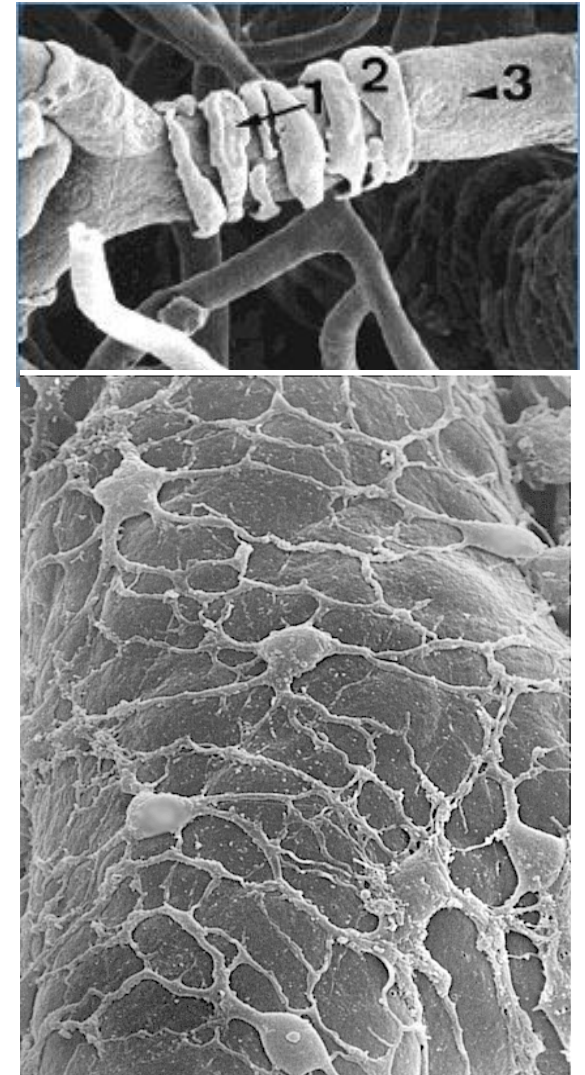
it serves to **support these vessels**, it can differentiate into a **fibroblast, smooth muscle cell, or macrophage** if required.


In order to migrate into the interstitium, the pericyte has to break the barrier, formed by the basement membrane, which can be accomplished by **fusion with the membrane**.

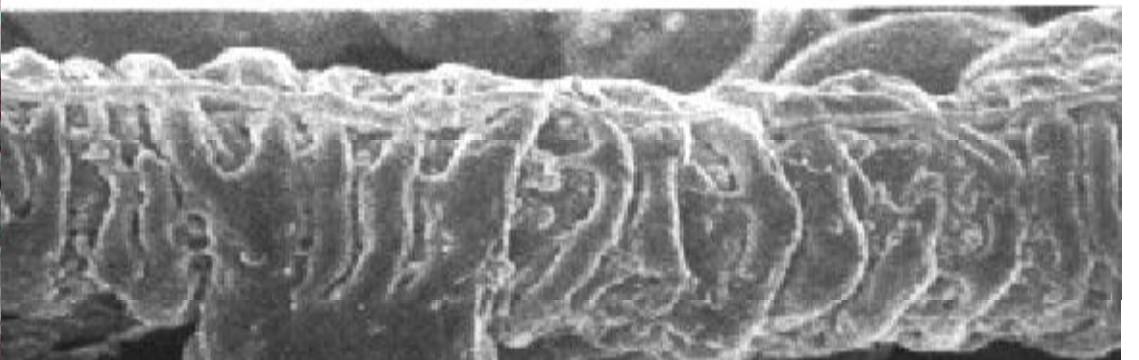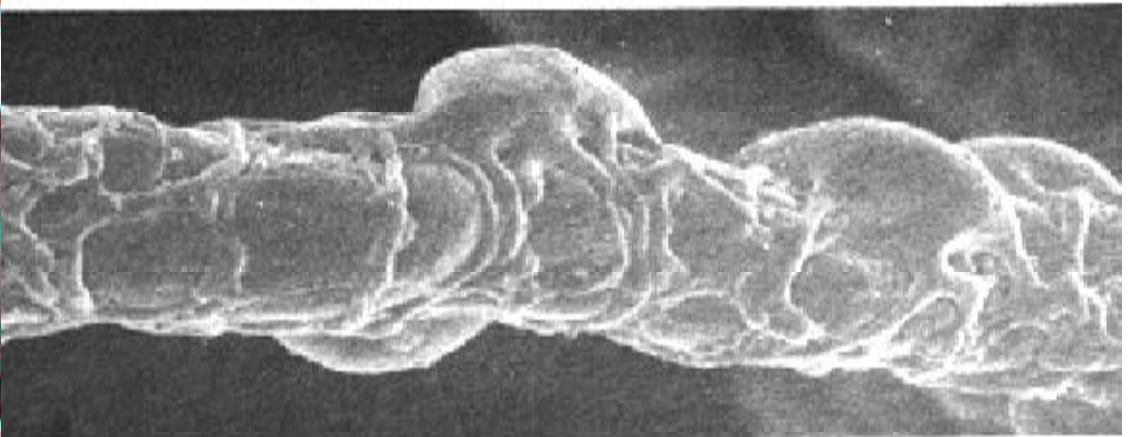
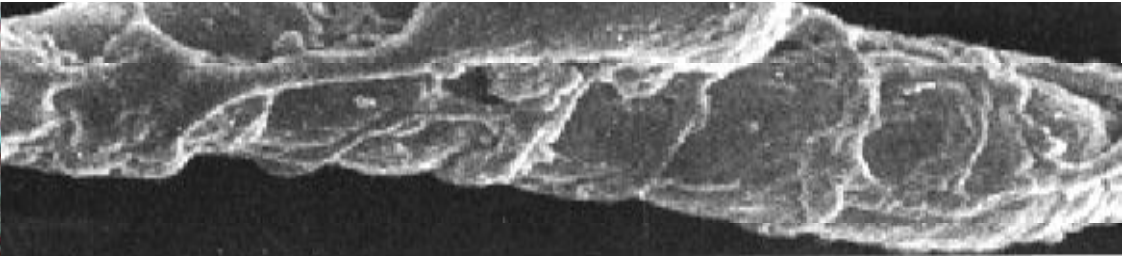
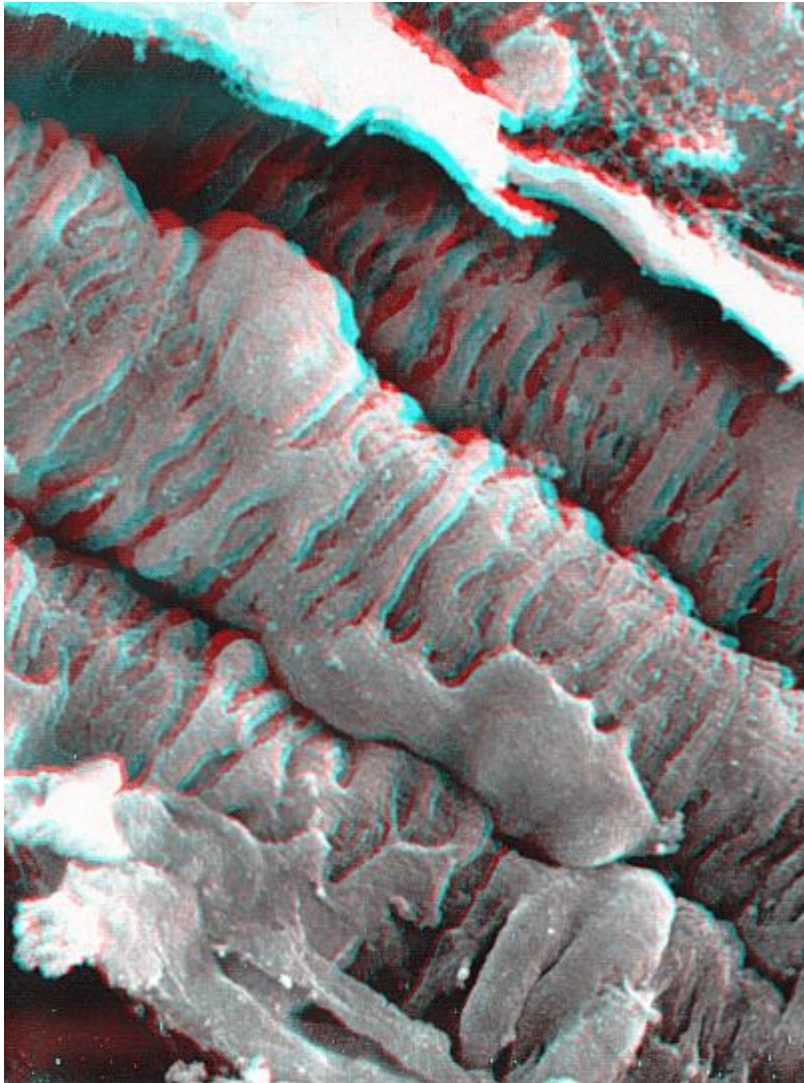
They are important in blood-brain barrier stability as well as angiogenesis.

They have been implicated in **blood flow regulation at the capillary level**.

Their expression of smooth muscle actin (SMA) and desmin, two proteins found in smooth muscle cells, and their adherence to the endovascular cells makes them very strong candidates for **blood flow regulators in the microvasculature**.







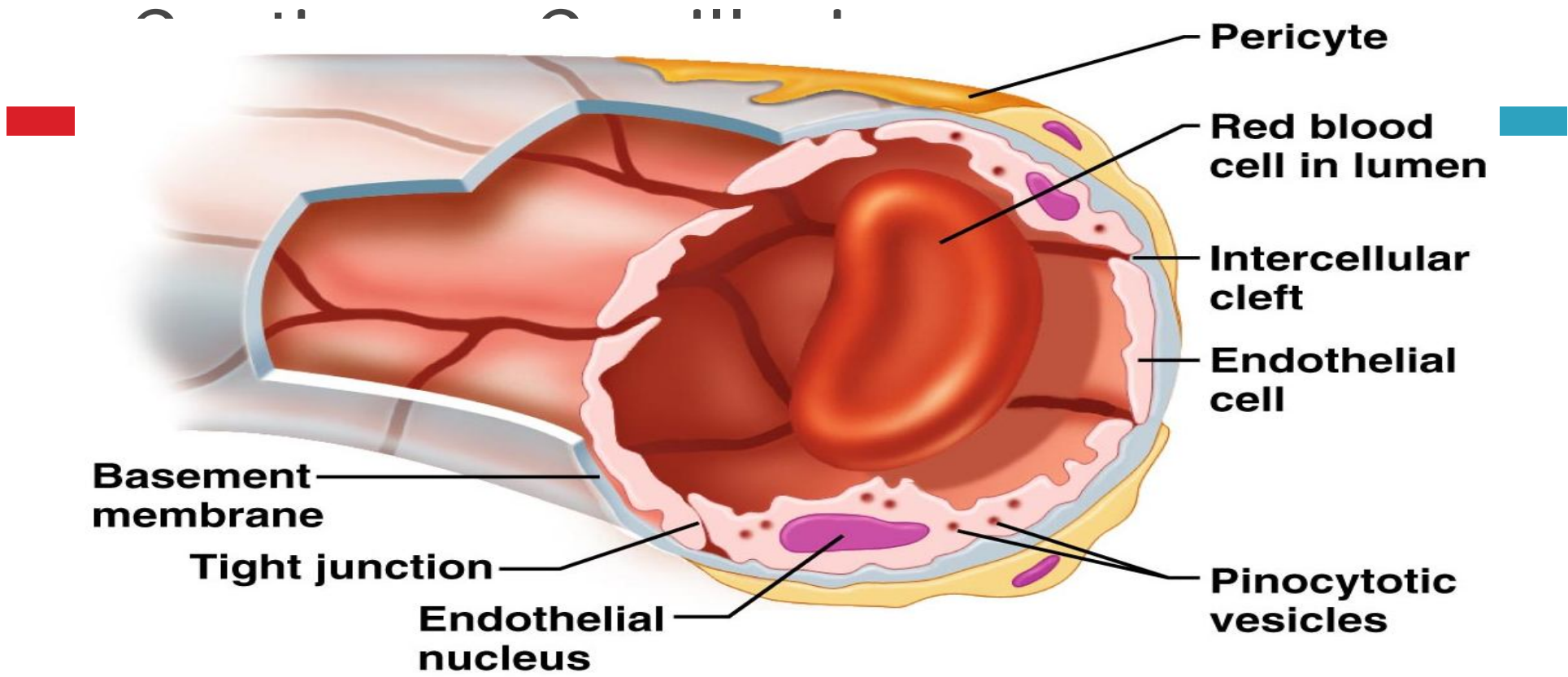
Continuous Capillaries

- Continuous capillaries are abundant in the skin and muscles
 - ▣ Endothelial cells provide an uninterrupted lining
 - ▣ Adjacent cells are connected with tight junctions
 - ▣ Intercellular clefts allow the passage of fluids

Continuous capillaries of the brain:

Have tight junctions completely around the endothelium

Constitute the blood-brain barrier

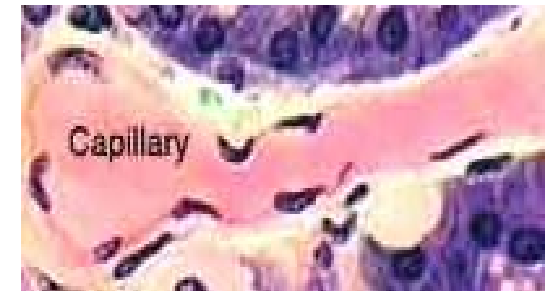

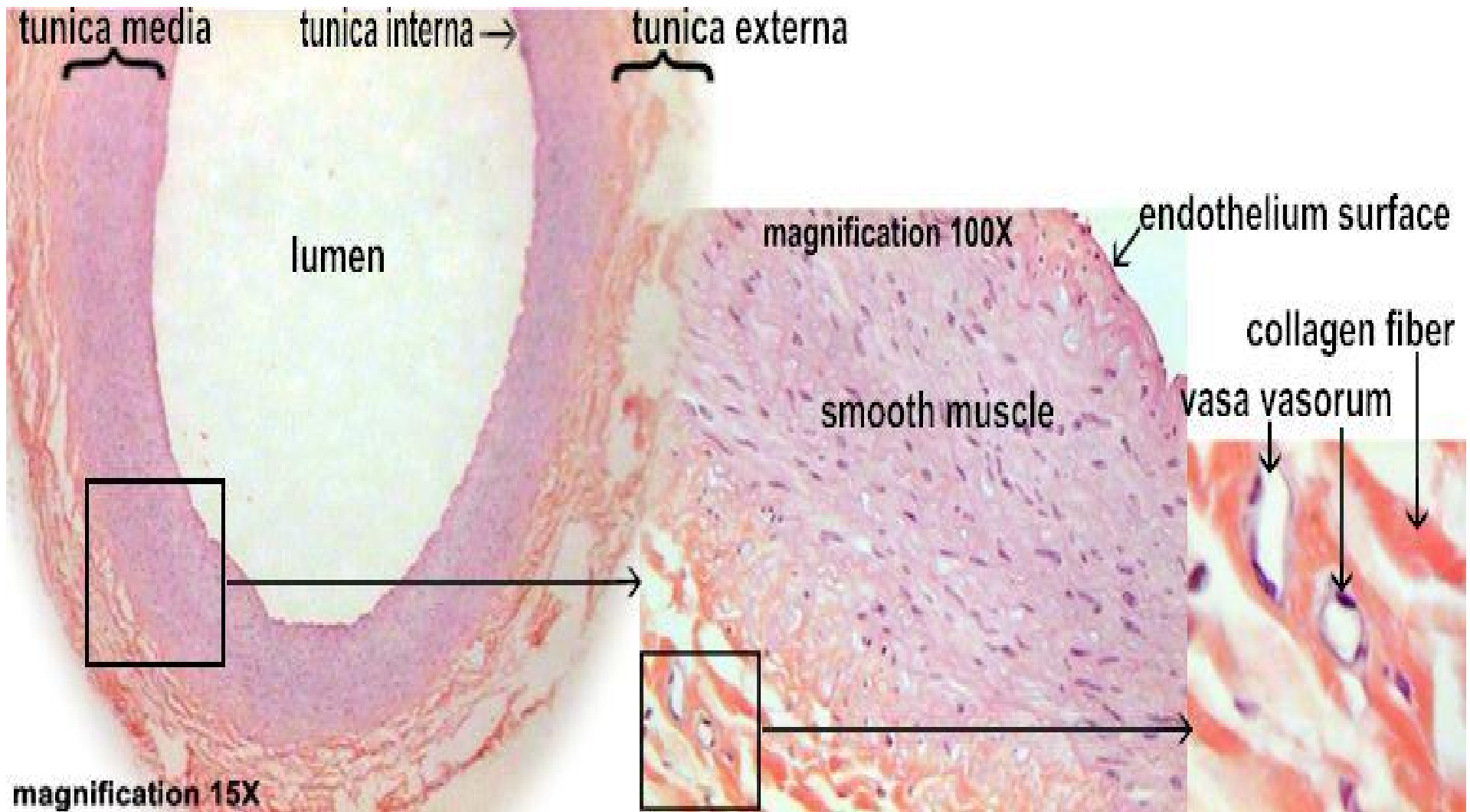
(a)

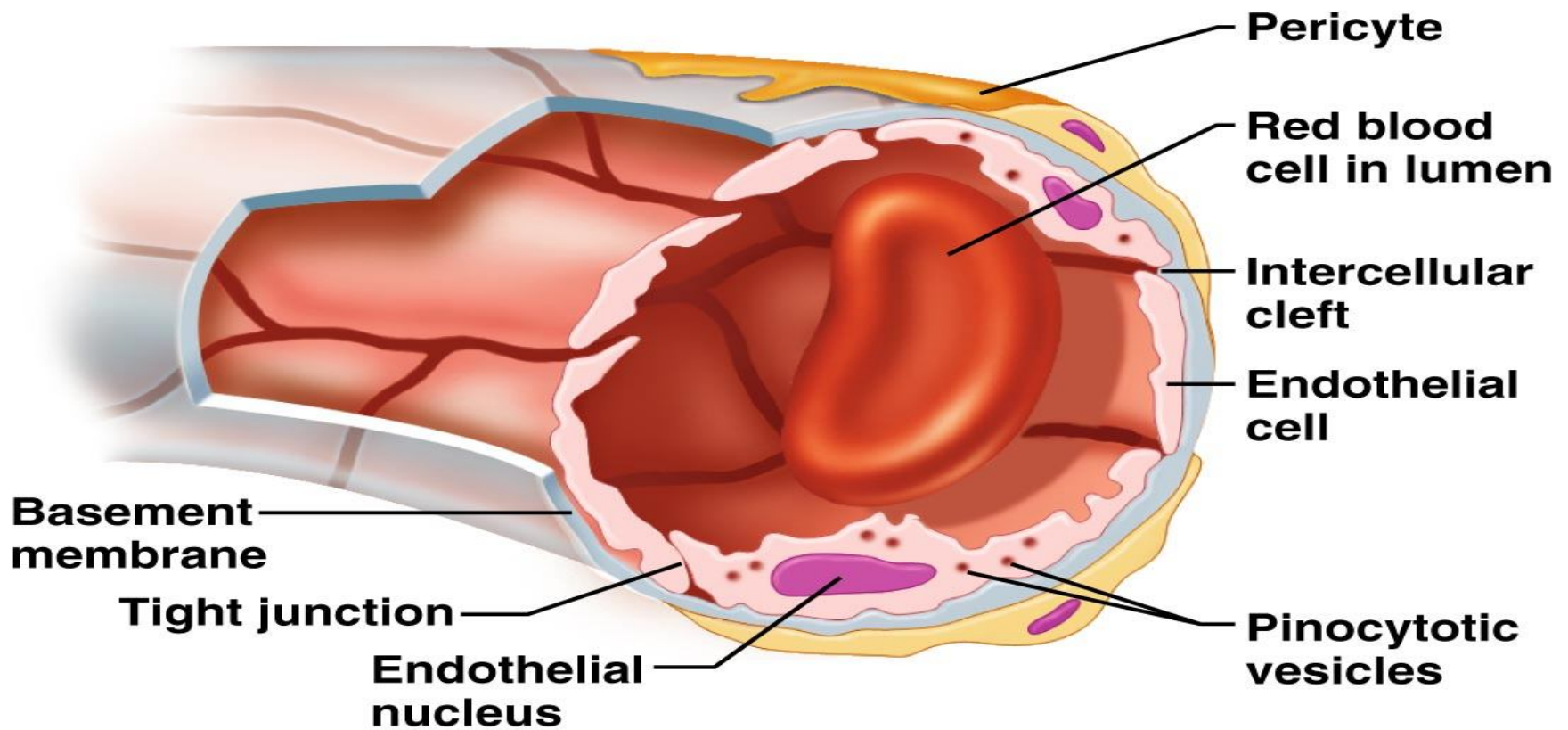
Figure 19.3a

Fenestrated Capillaries

- Found wherever active capillary absorption or filtrate formation occurs (e.g., small intestines, endocrine glands, and kidneys)
- Characterized by:
 - ▣ An endothelium riddled with pores (fenestrations)
 - ▣ Greater permeability than other capillaries



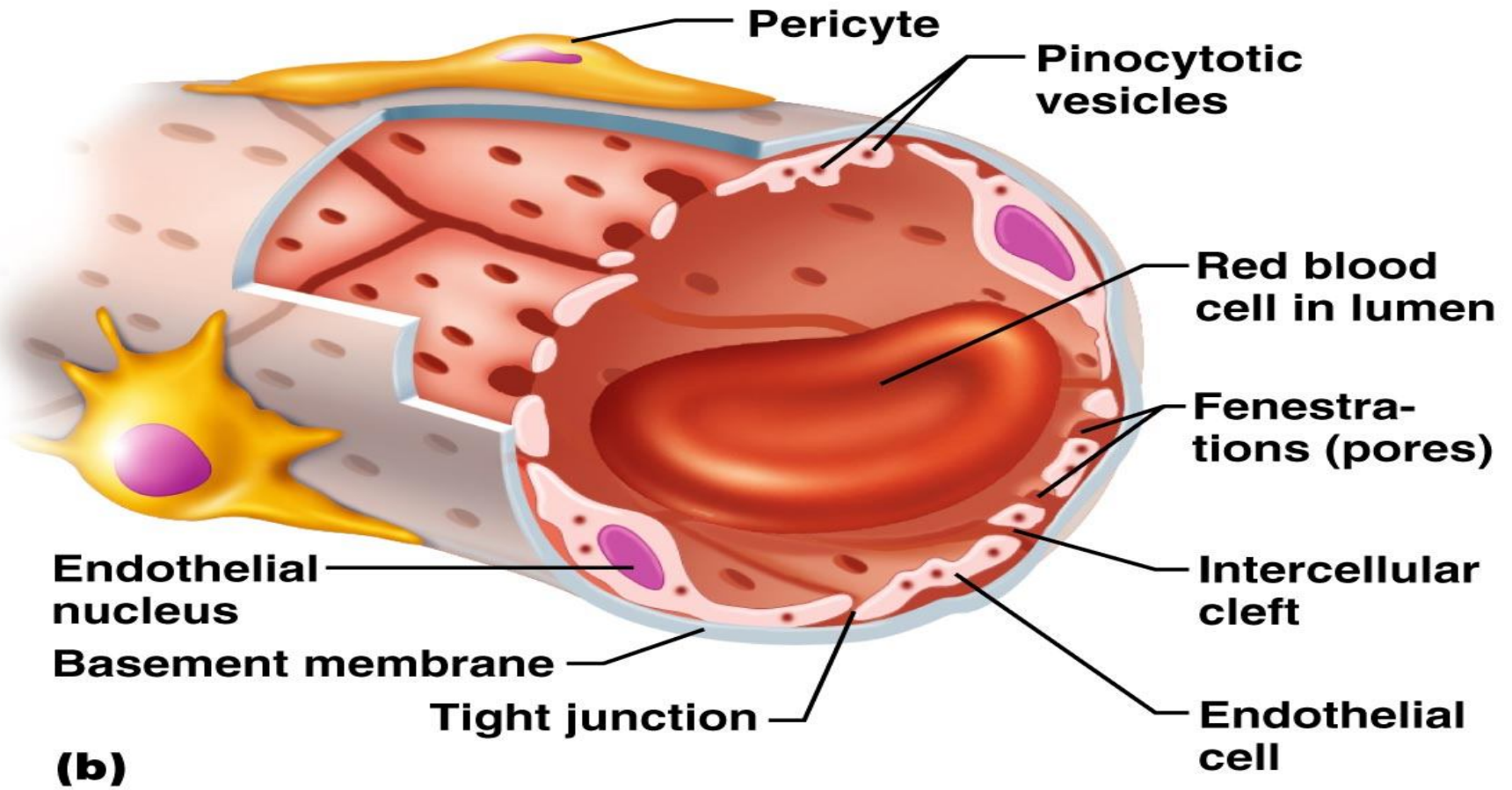




(a)

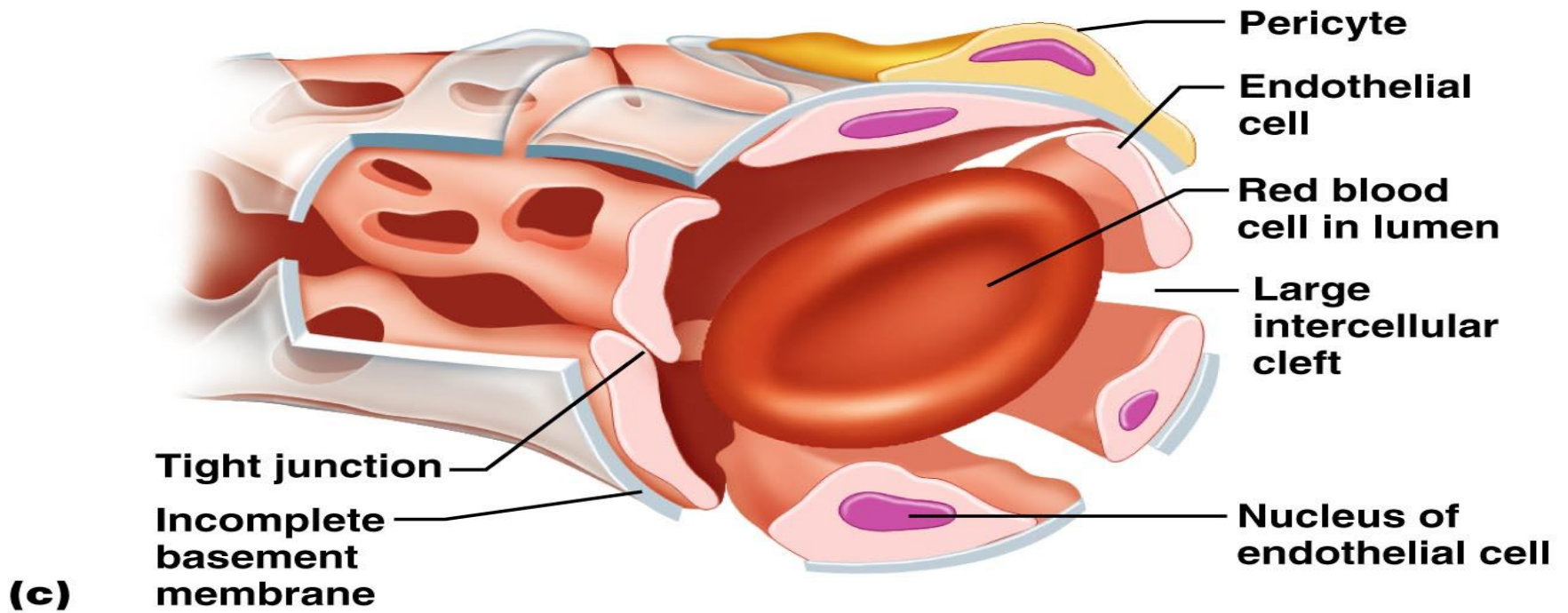
Copyright © 2006 Pearson Education, Inc., publishing as Benjamin Cummings.

Figure 19.3a



Copyright © 2006 Pearson Education, Inc., publishing as Benjamin Cummings.

Figure 19.3b



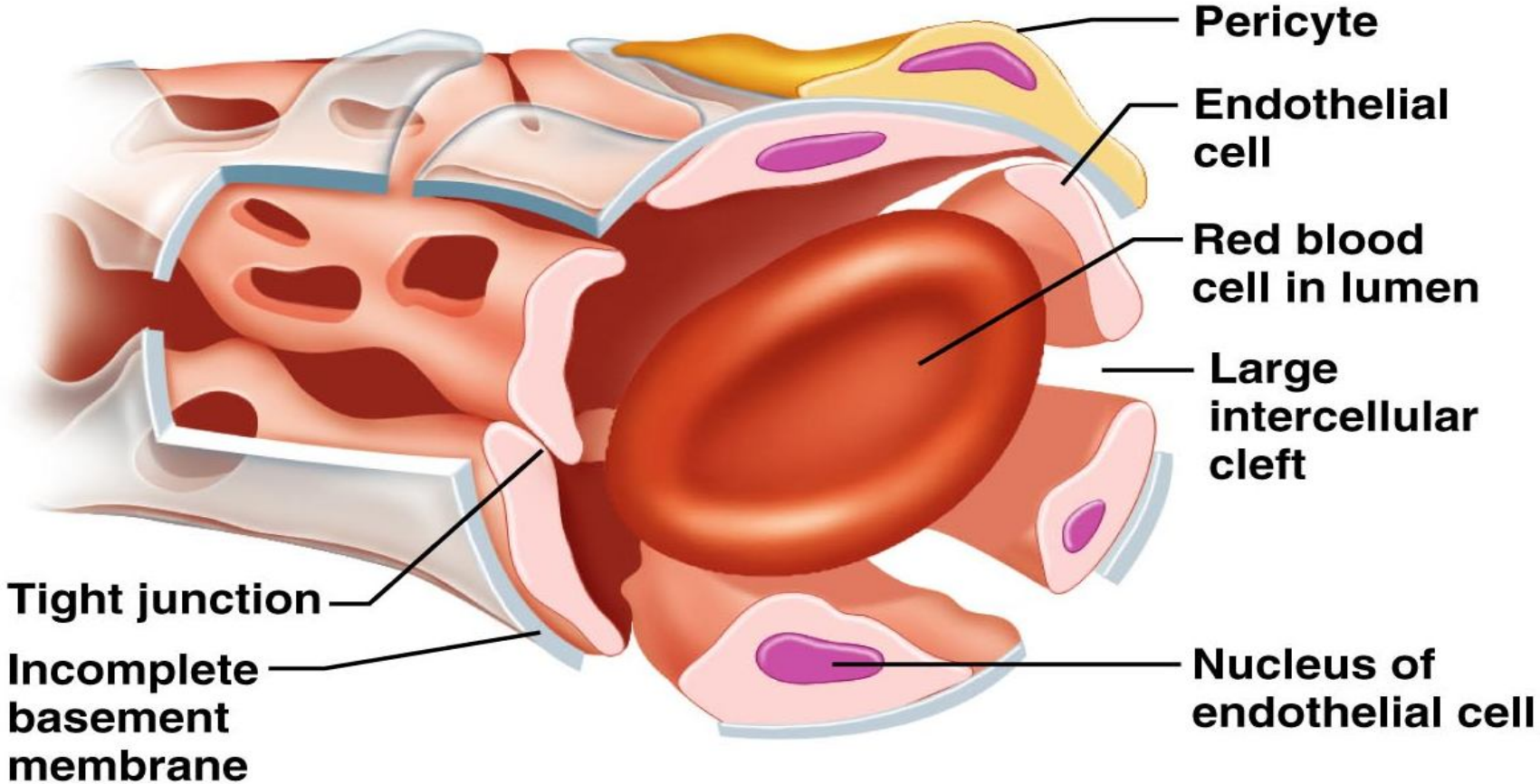
Copyright © 2006 Pearson Education, Inc., publishing as Benjamin Cummings.

Figure 19.3c

Sinusoids

- Highly modified, leaky, fenestrated capillaries with large lumens
- Found in the liver, bone marrow, lymphoid tissue, and in some endocrine organs
- Allow large molecules (proteins and blood cells) to pass between the blood and surrounding tissues
- Blood flows sluggishly, allowing for modification in various ways

Sinusoids

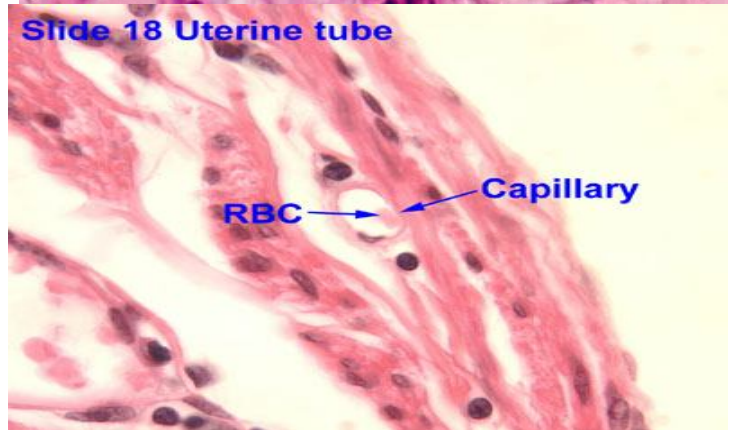
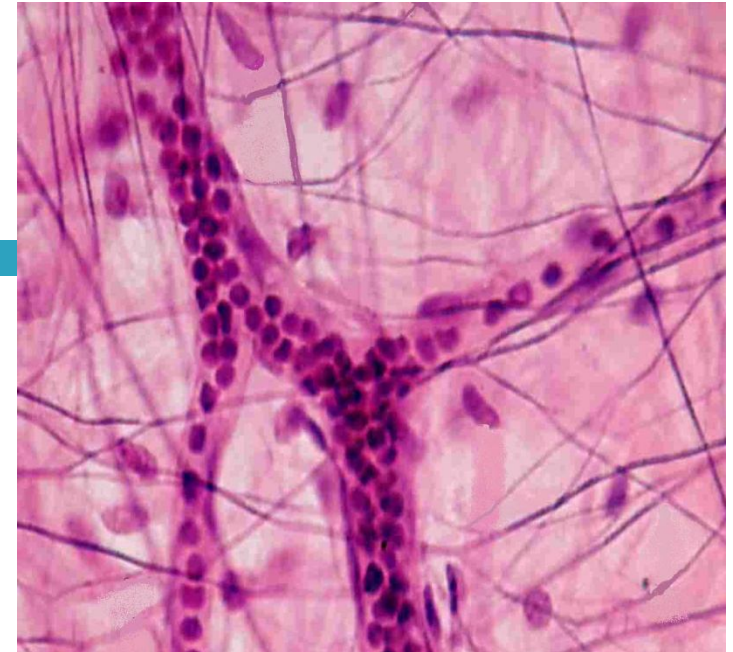


(c)

Figure 19.36

Capillary Beds

- A microcirculation of interwoven networks of capillaries, consisting of:
 - ▣ Vascular shunts – metarteriole–thoroughfare channel connecting an arteriole directly with a postcapillary venule
 - ▣ True capillaries – 10 to 100 per capillary bed, capillaries branch off the metarteriole and return to the thoroughfare channel at the distal end of the bed

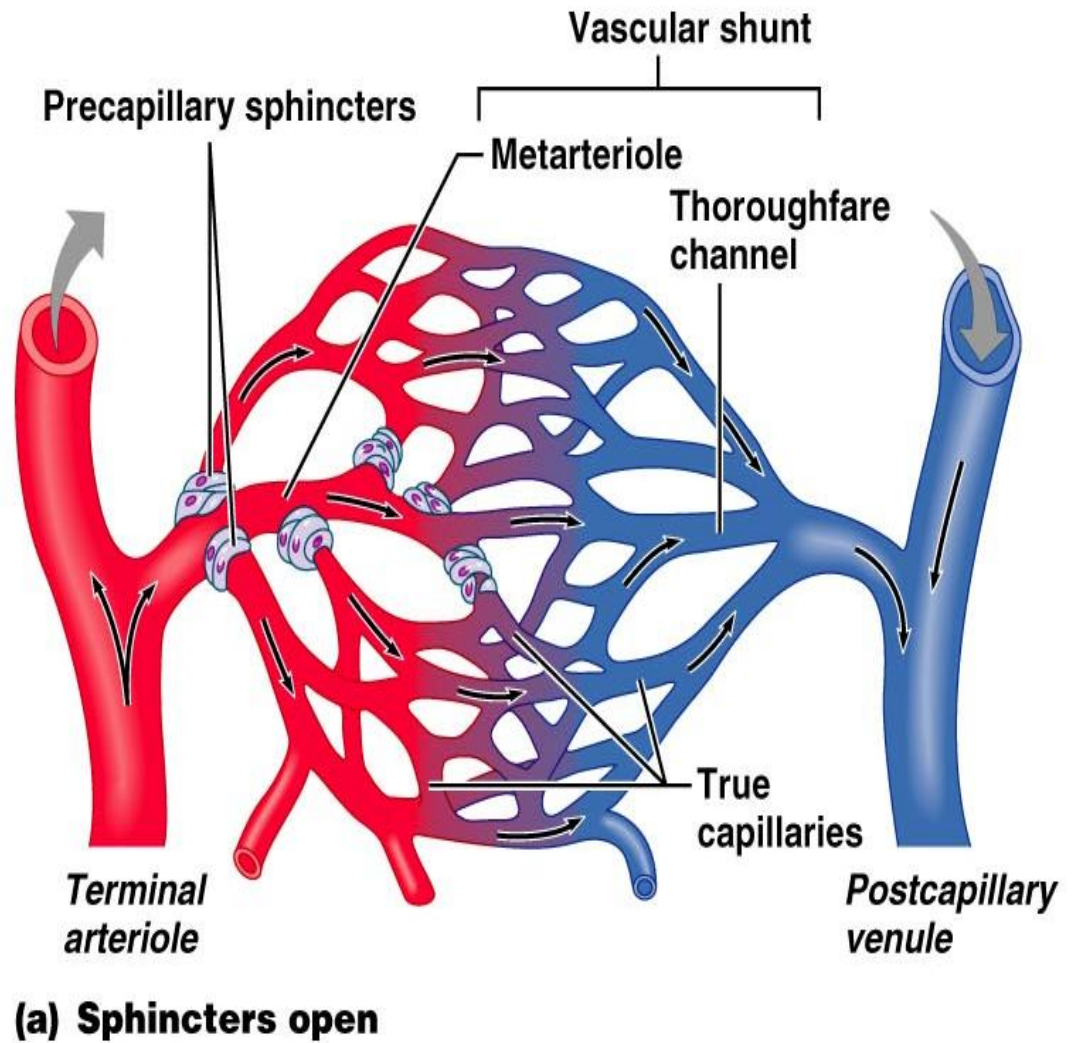
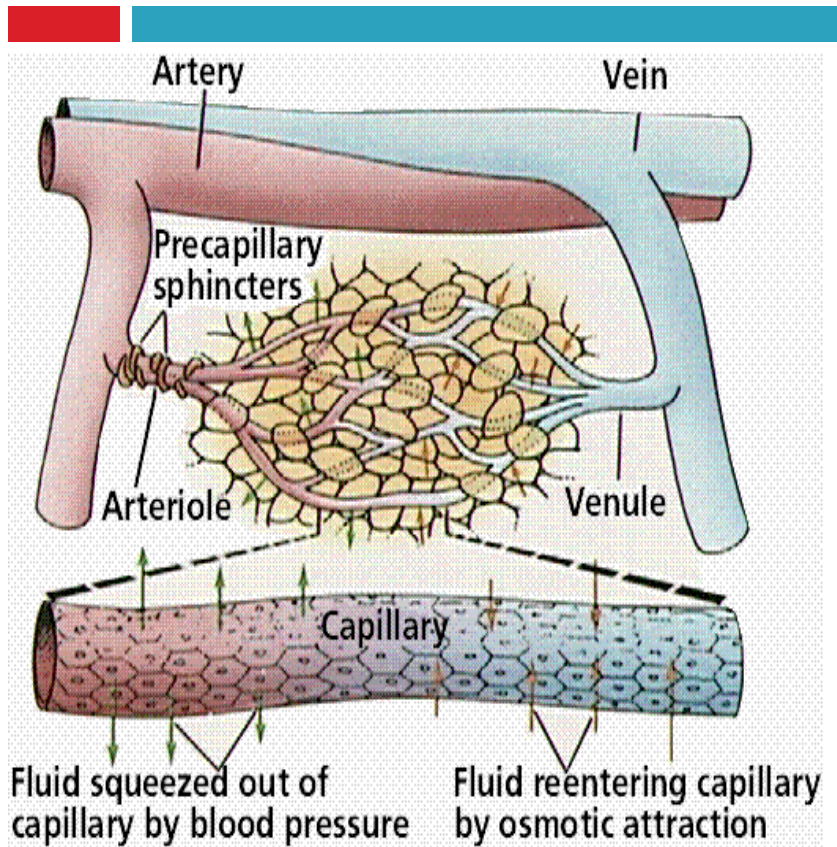


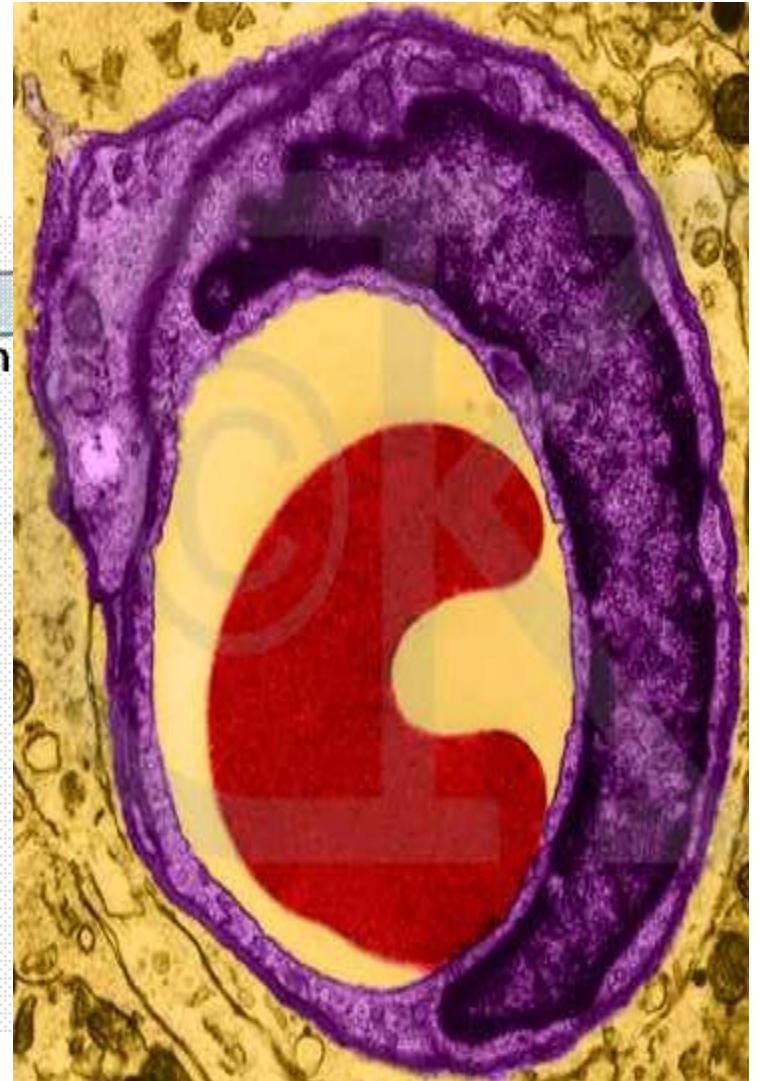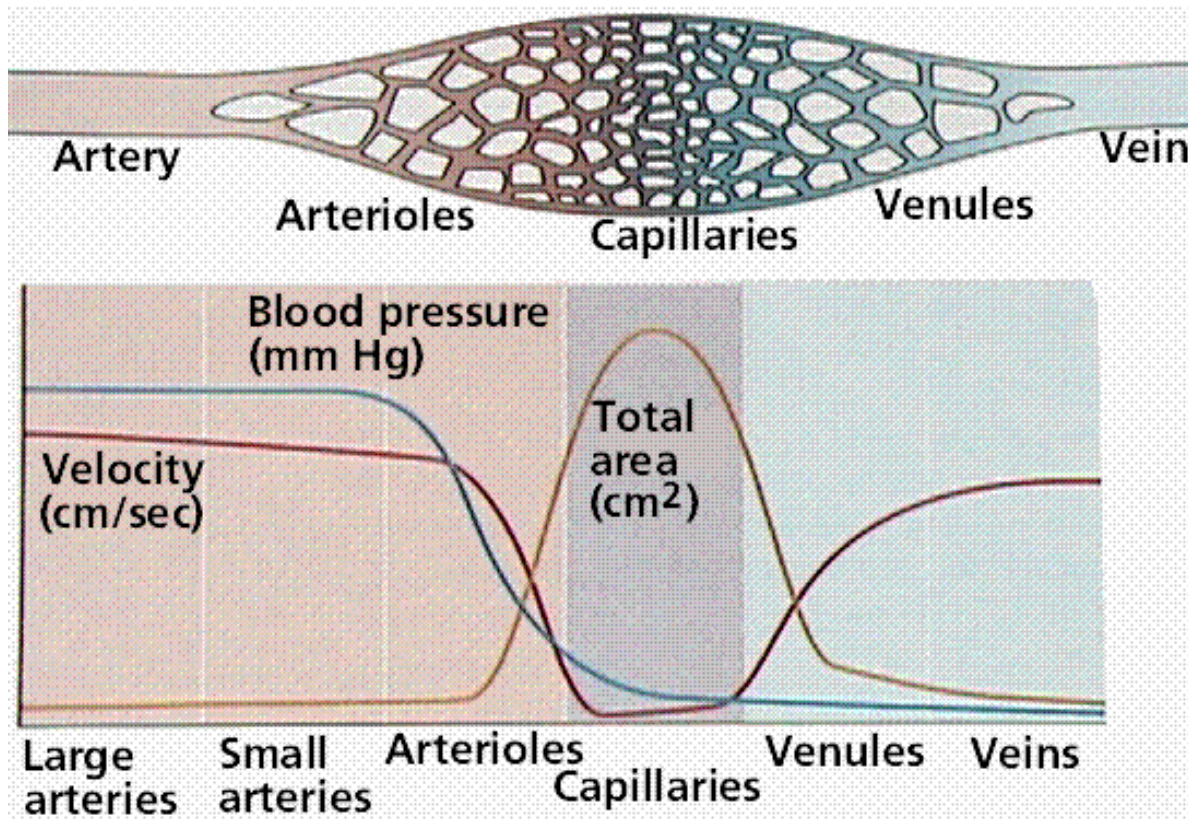
Blood Flow Through Capillary Beds

- **Precapillary sphincter**
 - ▣ Cuff of smooth muscle that surrounds each true capillary
 - ▣ Regulates blood flow into the capillary
- **Blood flow is regulated by vasomotor nerves and local chemical conditions**

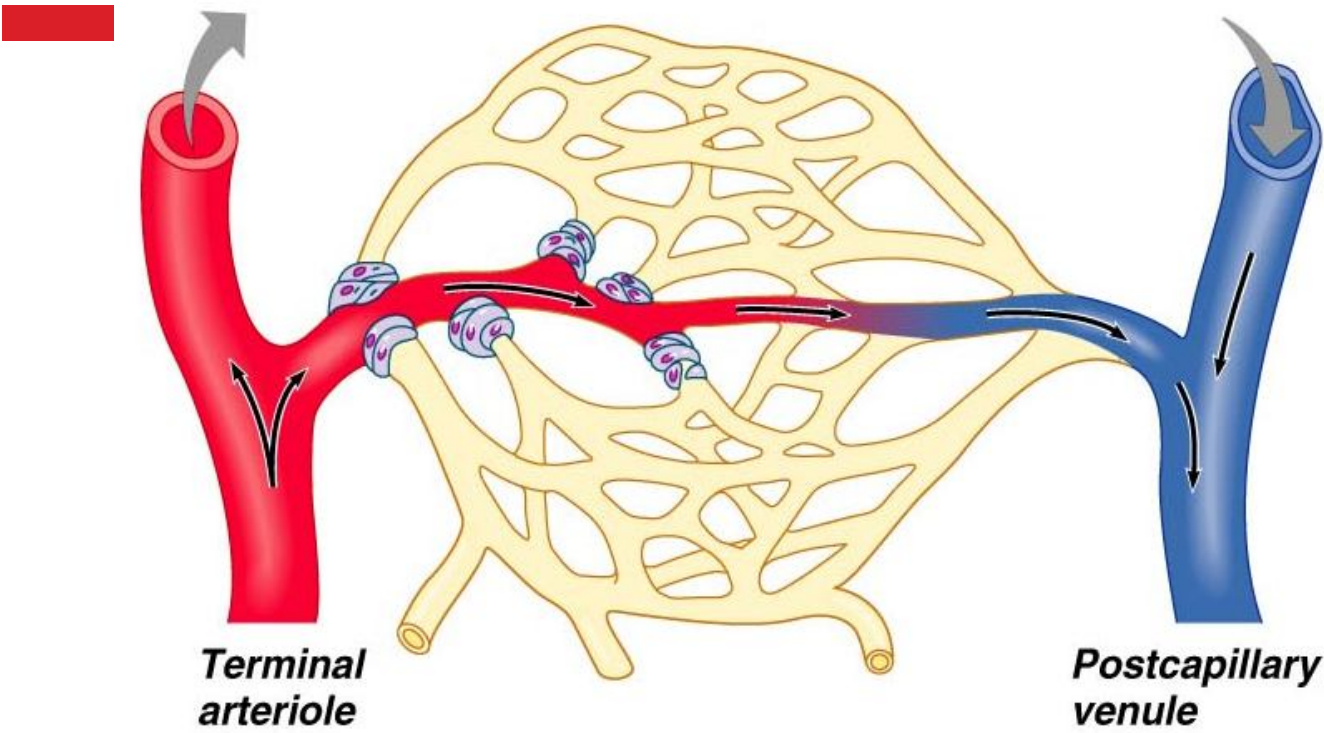


Capillary Beds





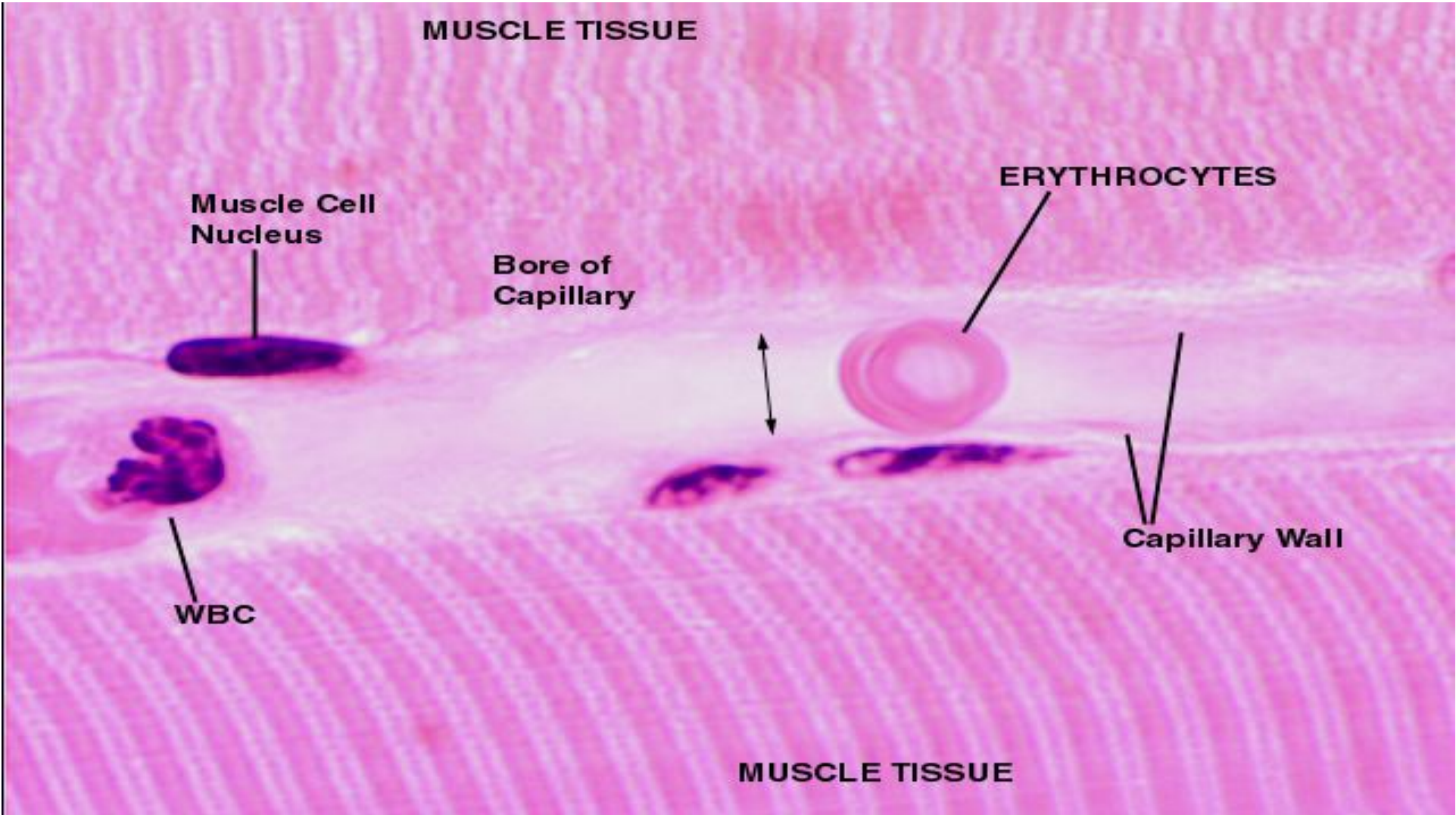
Capillary Beds

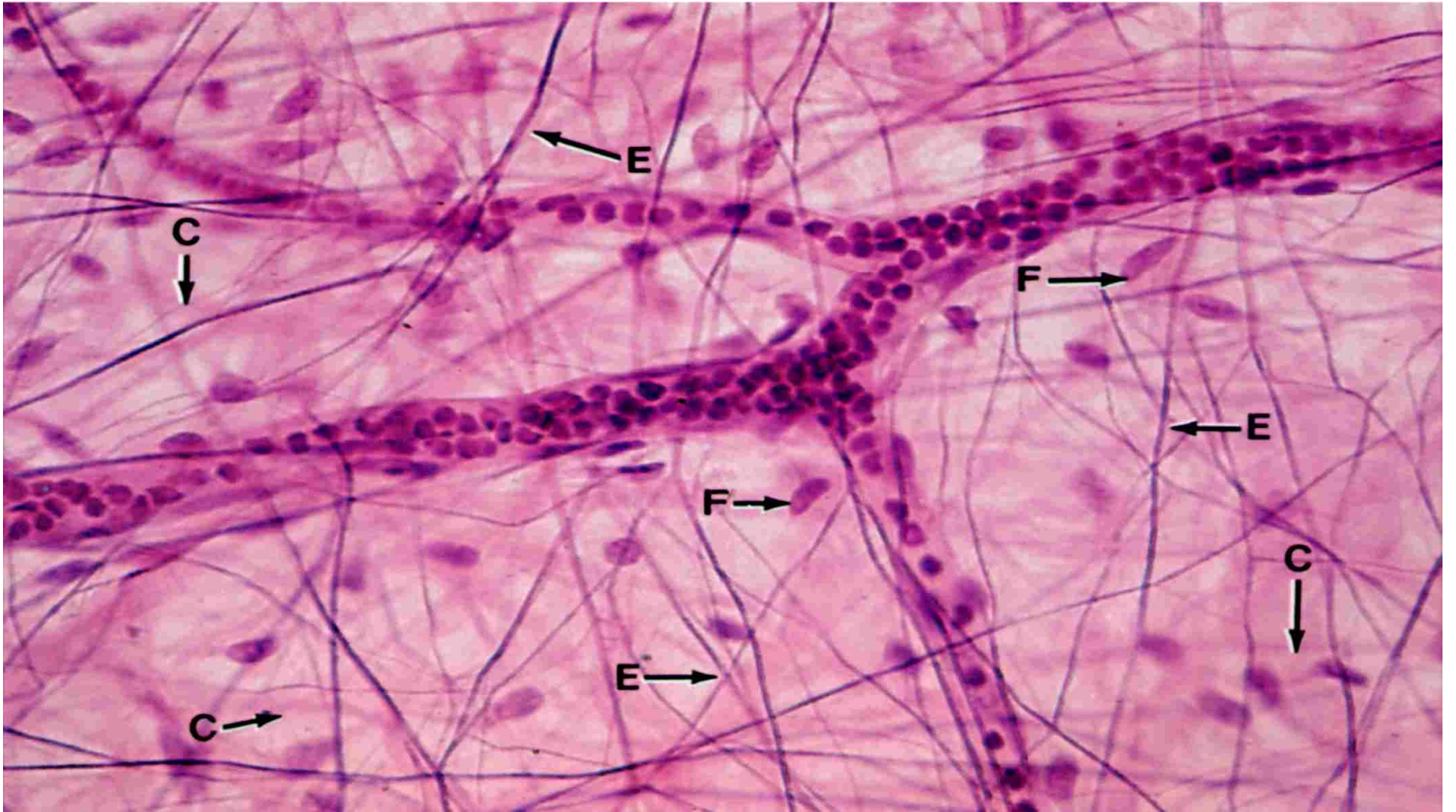


(b) Sphincters closed

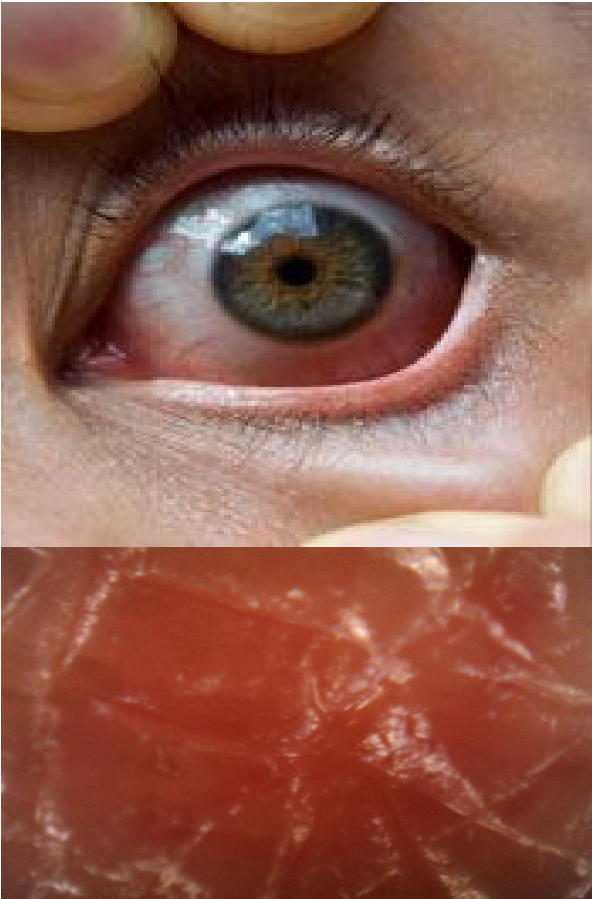

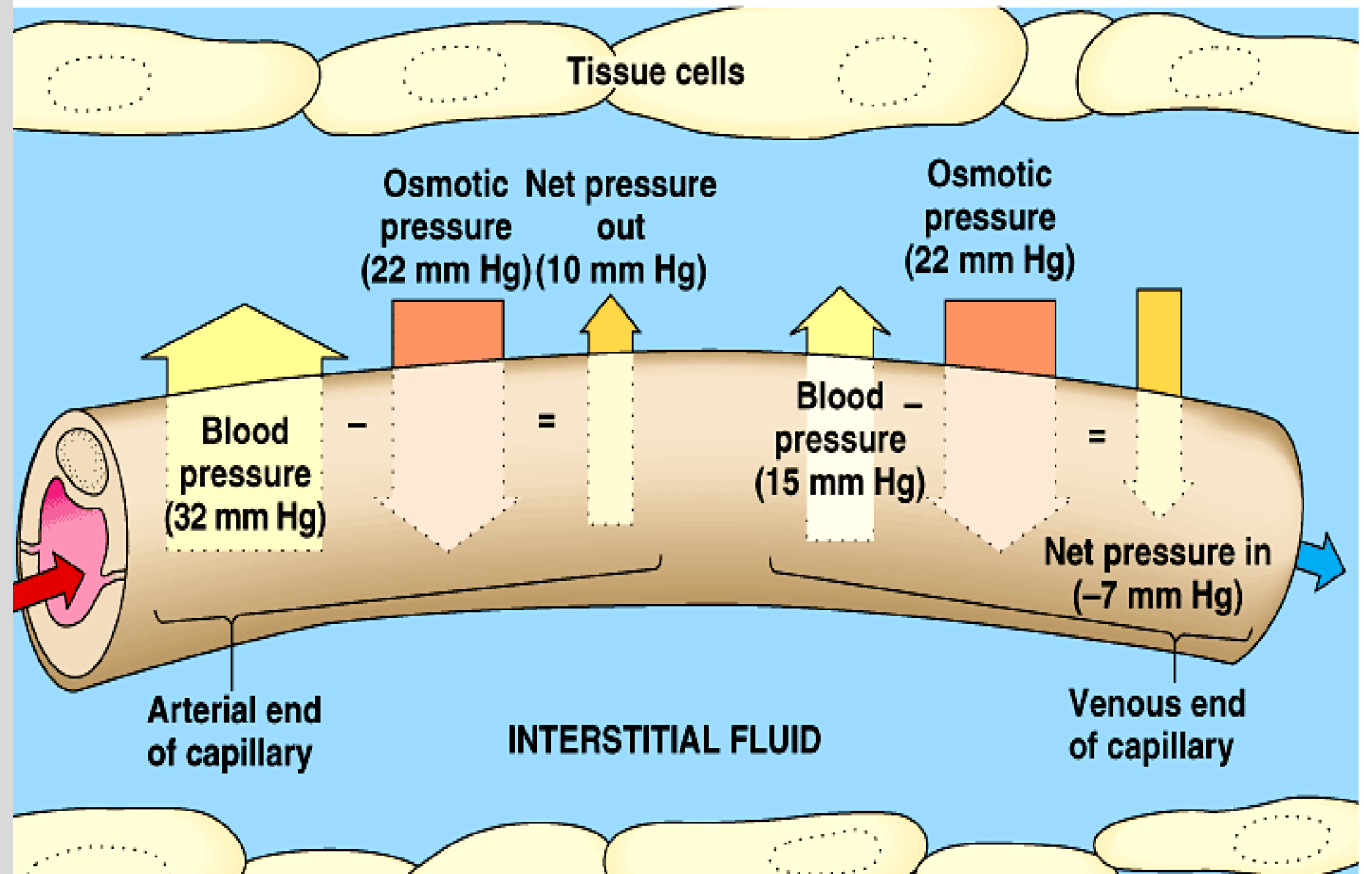
Figure 19.4b





The movement of fluid between capillaries and the interstitial fluid. Fluids flow out of a capillary at the upstream end near an arteriole and reenters a capillary downstream near a venule.

The direction of fluid movement across the capillary wall at any point depends on the difference between two opposing forces: blood pressure and osmotic pressure.

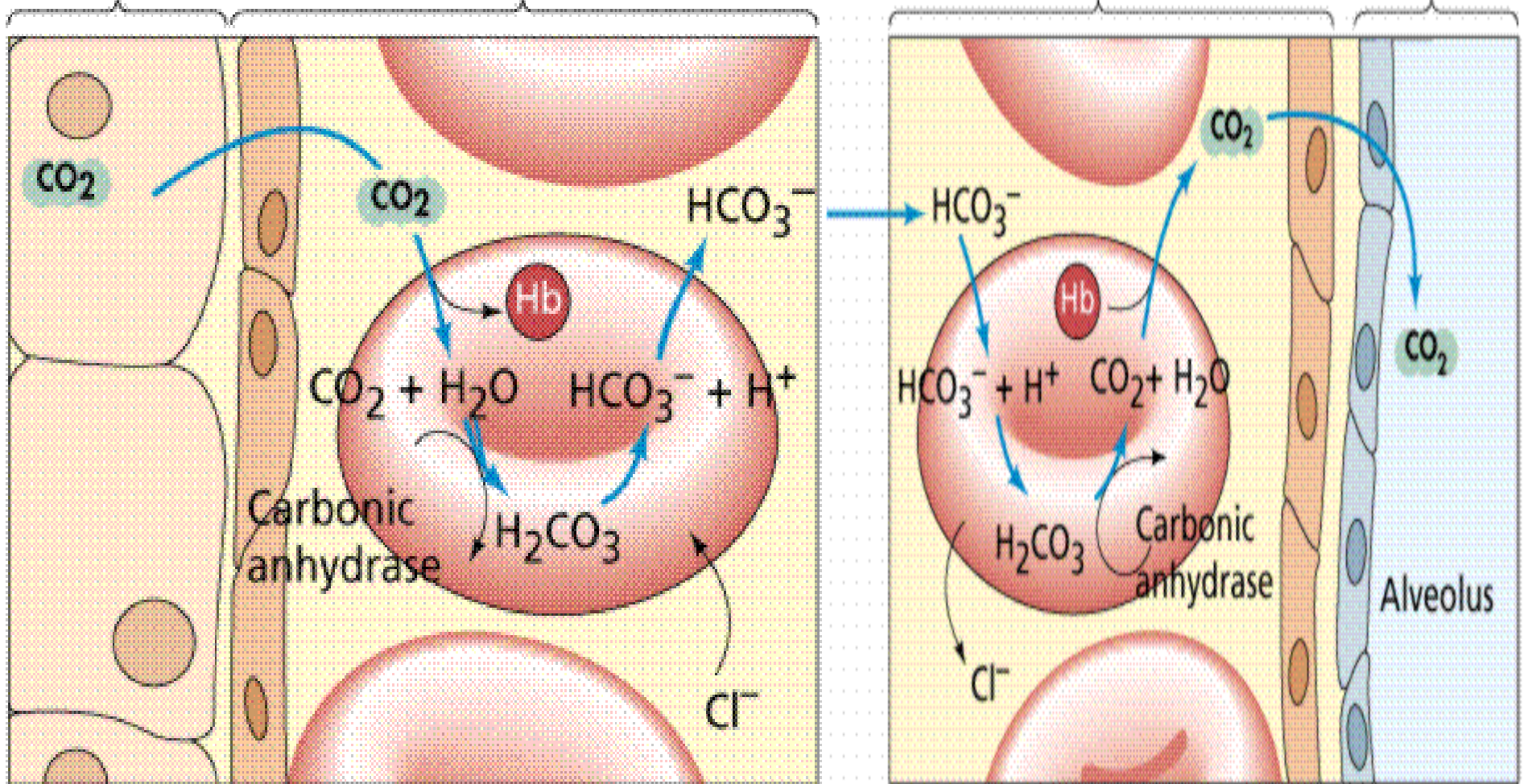


Body tissue

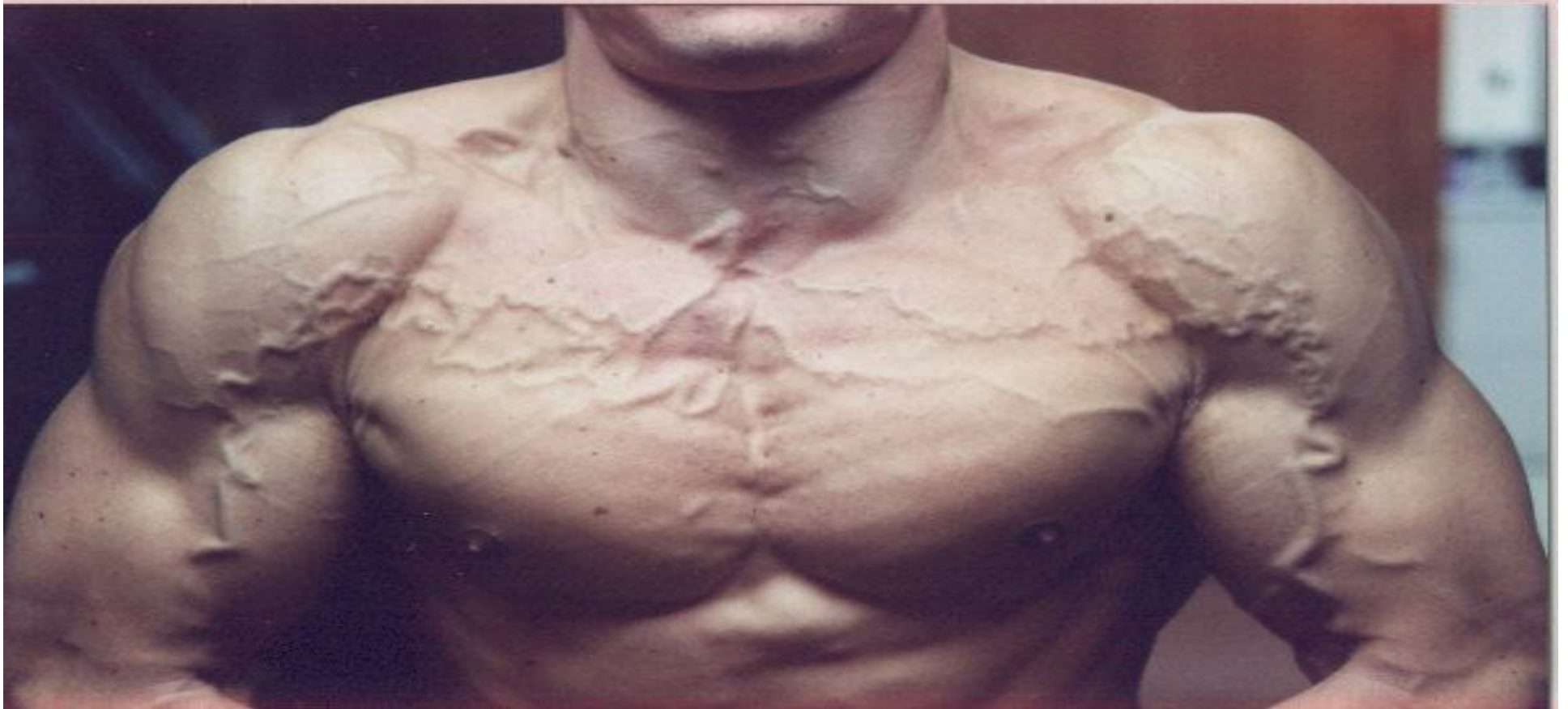Blood capillary

Blood capillary

Lung



VEINS

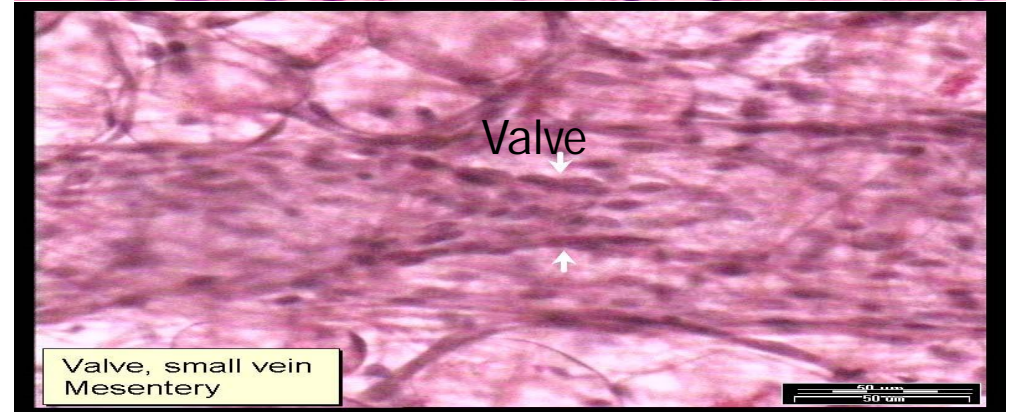
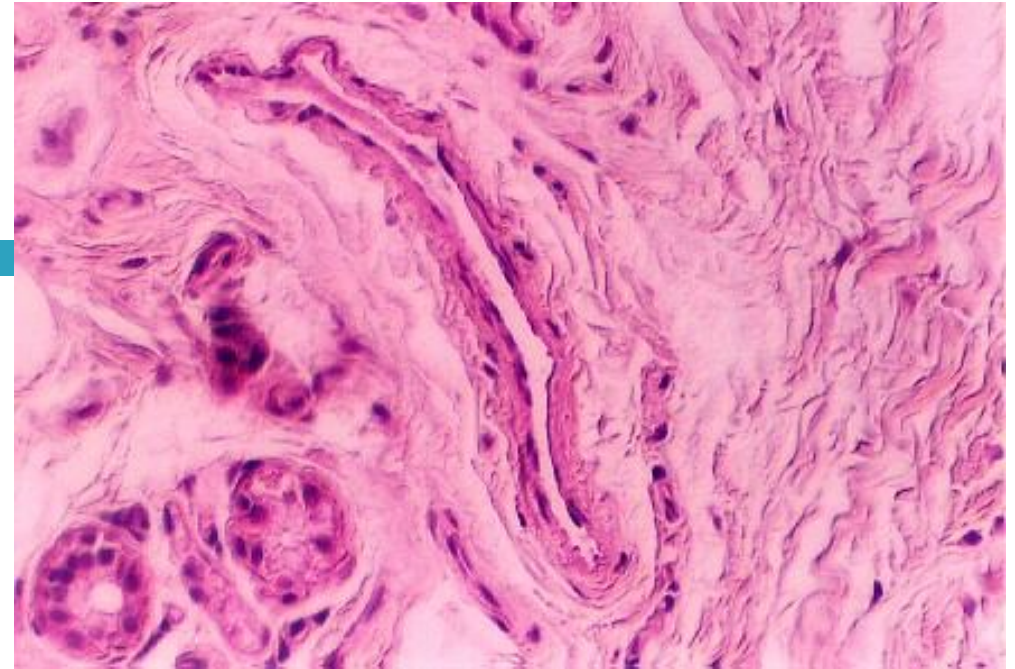


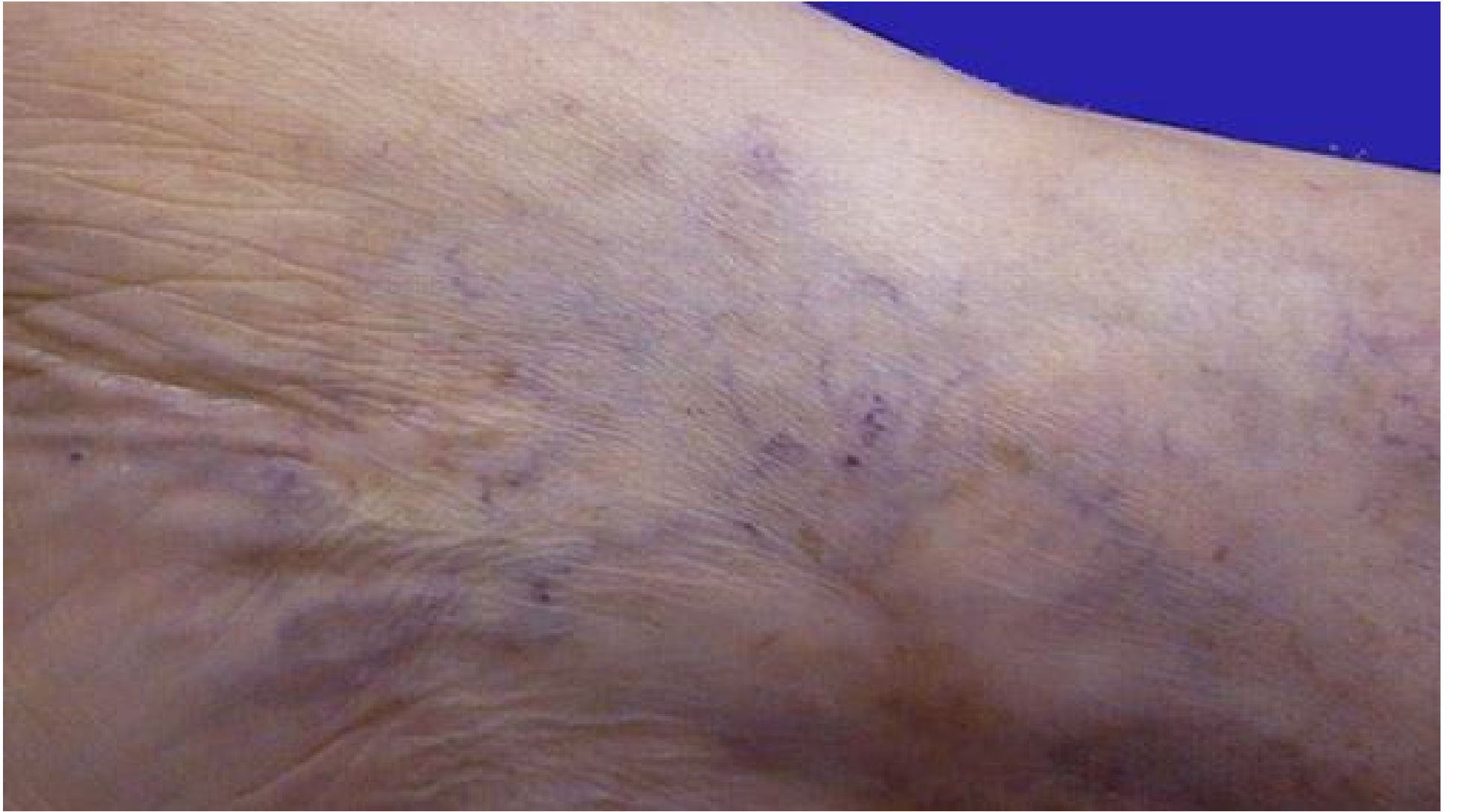
Venous System: Venules

- Venules are formed when capillary beds unite
 - ▣ Allow fluids and WBCs to pass from the bloodstream to tissues
- Postcapillary venules – smallest venules, composed of endothelium and a few pericytes
- Large venules have one or two layers of smooth muscle (tunica media)

Veins

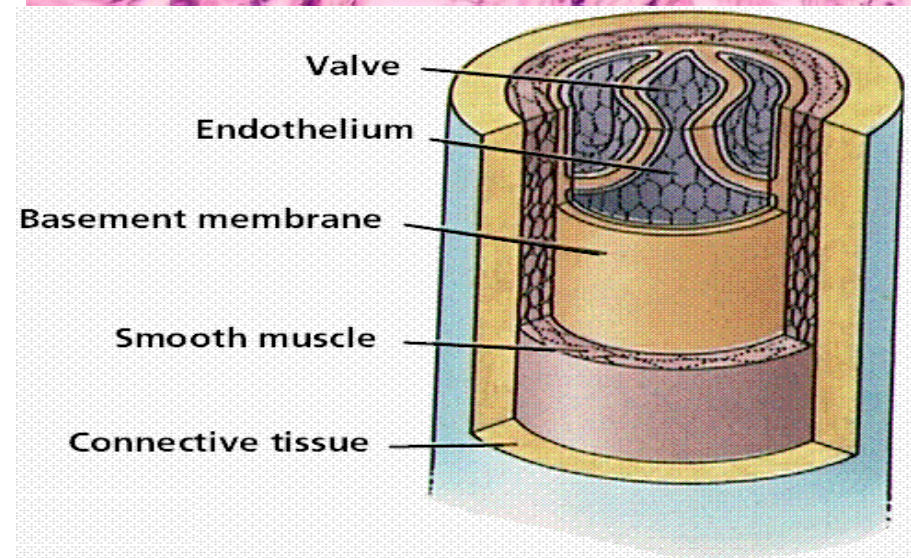
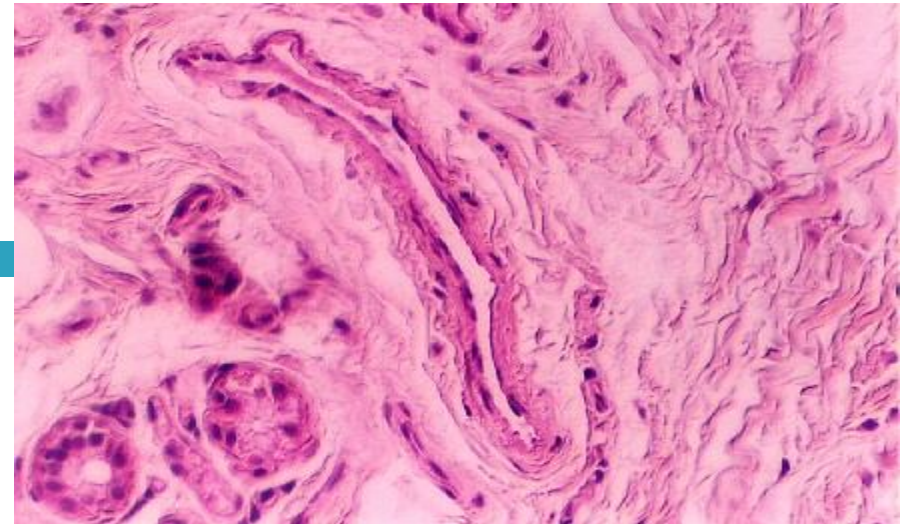
- Veins are distinguished by their thinner wall, valves, collapsed state.
- The tunica media does not look as well organized as that in the artery or arteriole.

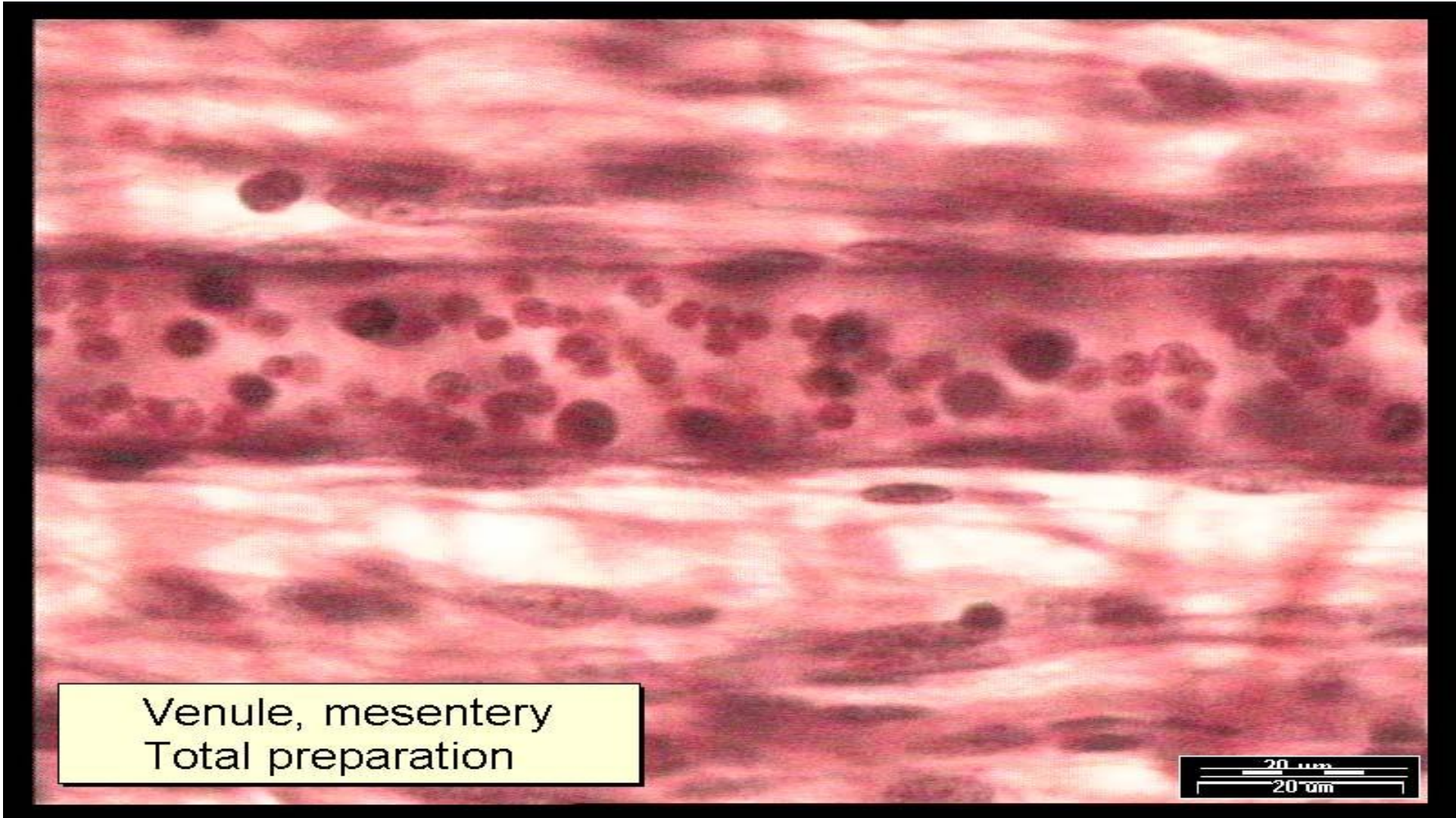




Venous System: Veins

- Veins are:
 - ▣ Formed when venules converge
 - ▣ Composed of three tunics, with a thin tunica media and a thick tunica externa consisting of collagen fibers and elastic networks
 - ▣ Capacitance vessels (blood reservoirs) that contain 65% of the blood supply



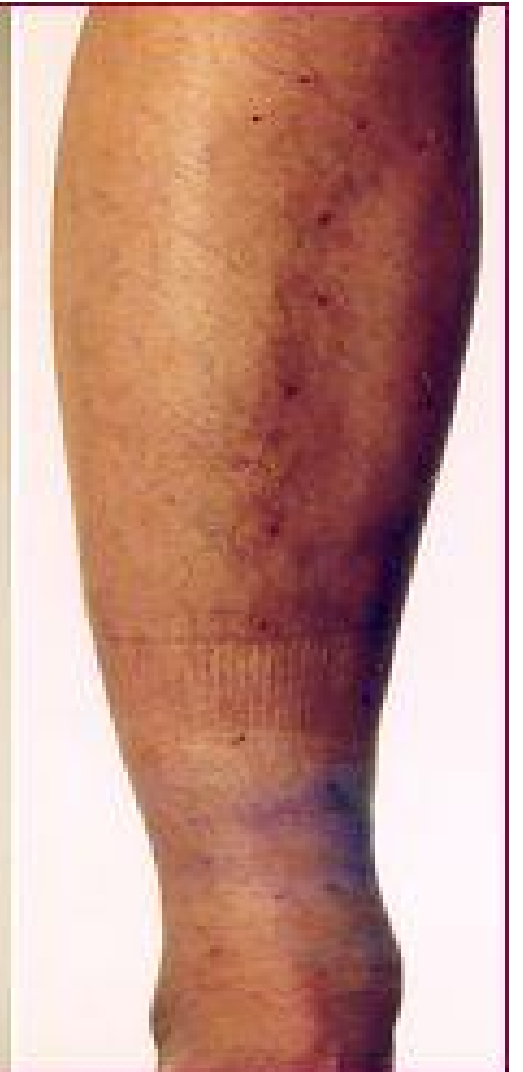
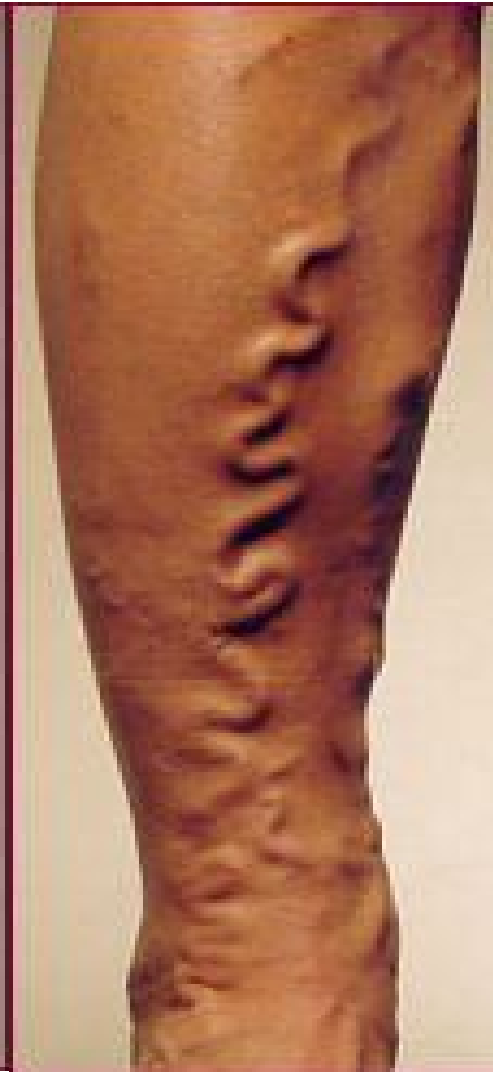
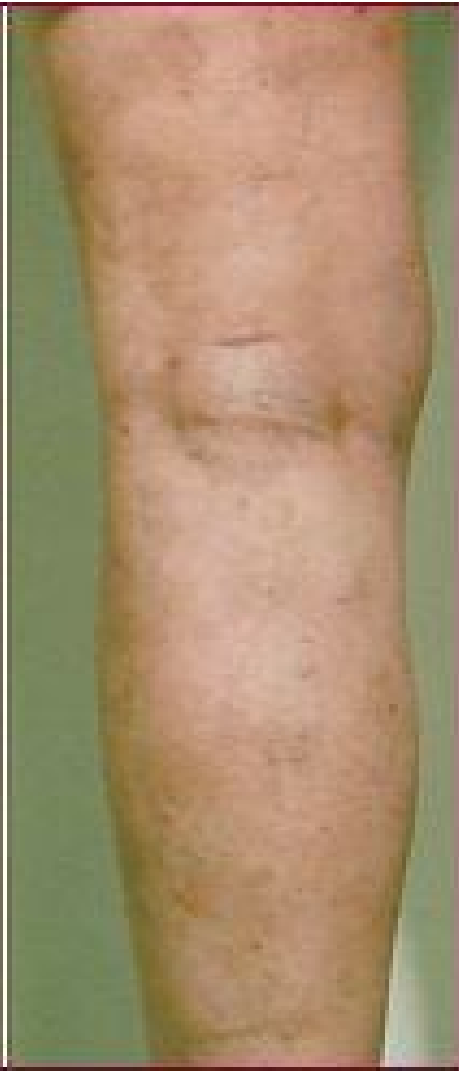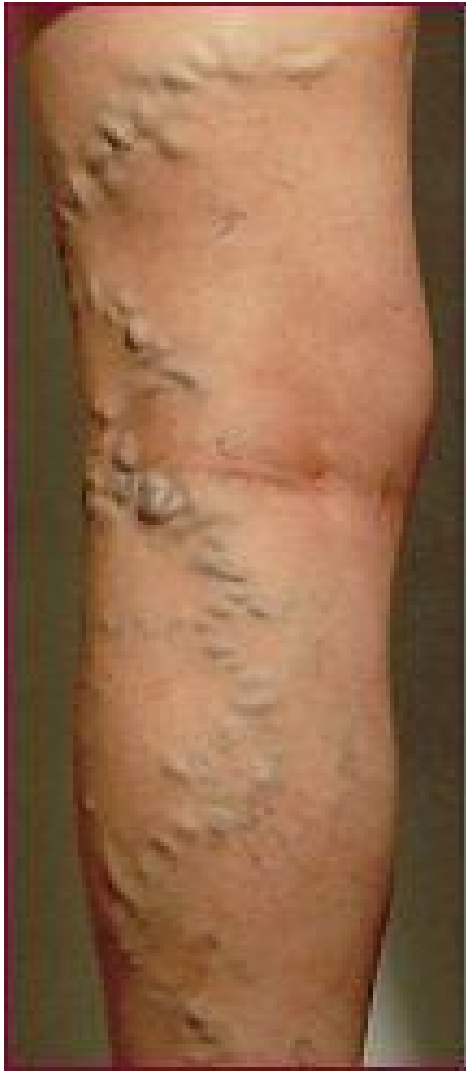Venule, mesentery
Total preparation

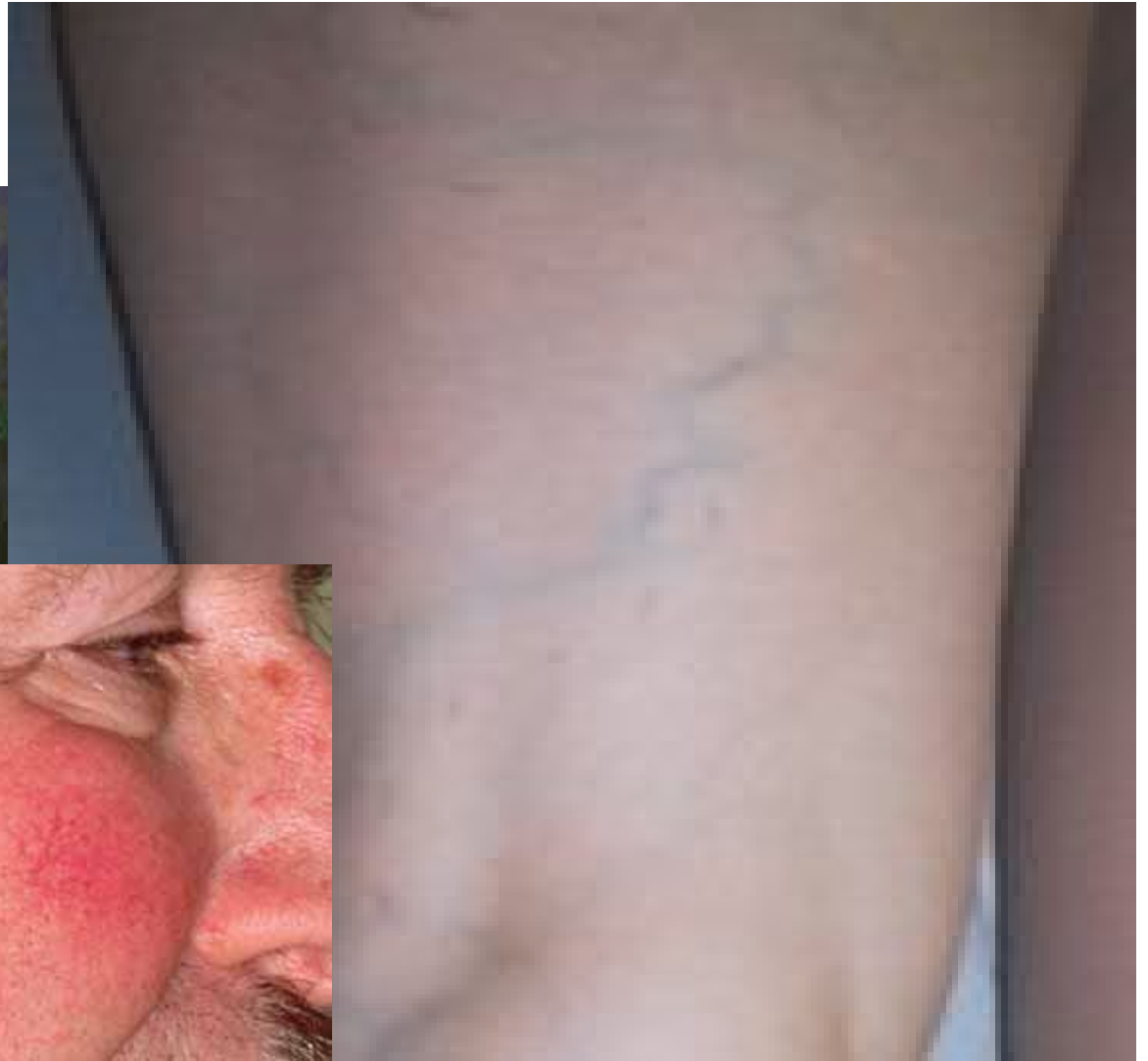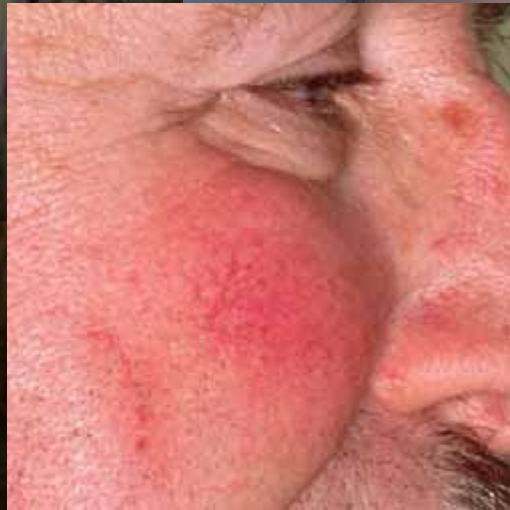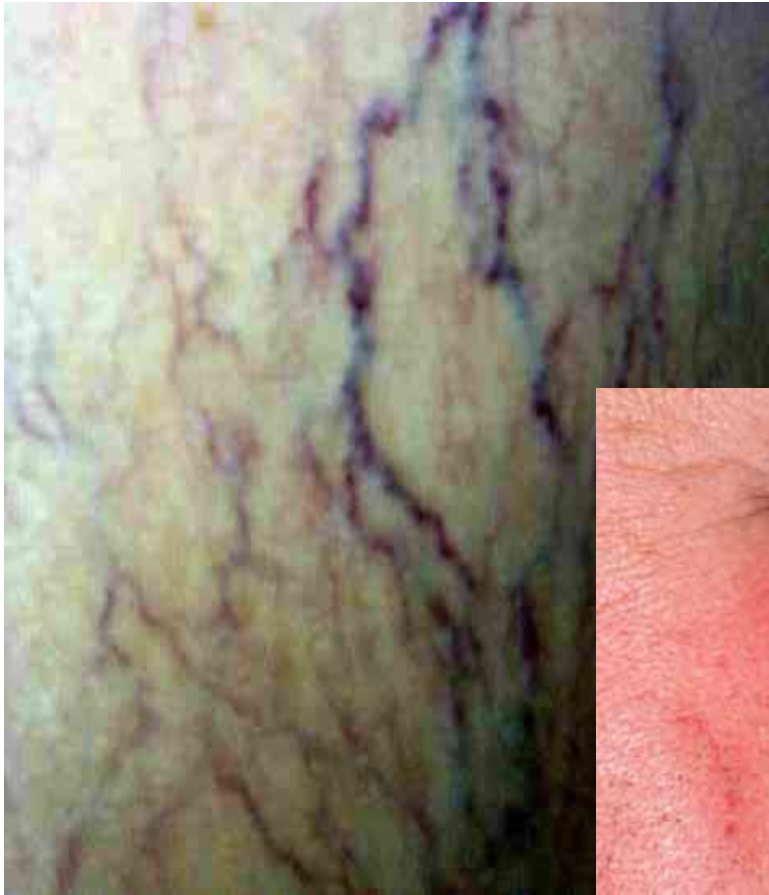20 μ m
20 μ m

Venous System: Veins

- Veins have much lower blood pressure and thinner walls than arteries
- To return blood to the heart, veins have special adaptations
 - ▣ Large-diameter lumens, which offer little resistance to flow
 - ▣ Valves (resembling semilunar heart valves), which prevent backflow of blood
- Venous sinuses – specialized, flattened veins with extremely thin walls (e.g., coronary sinus of the heart and dural sinuses of the brain)

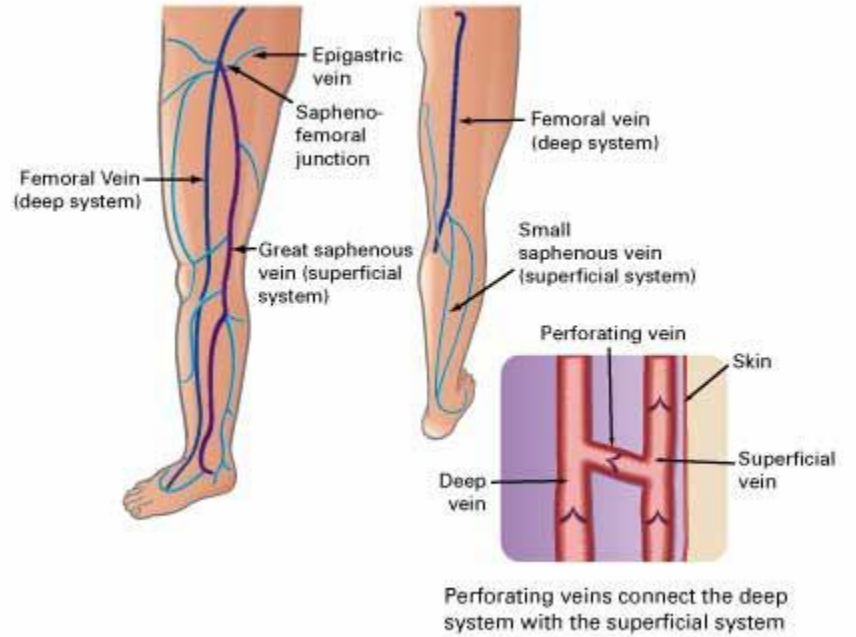
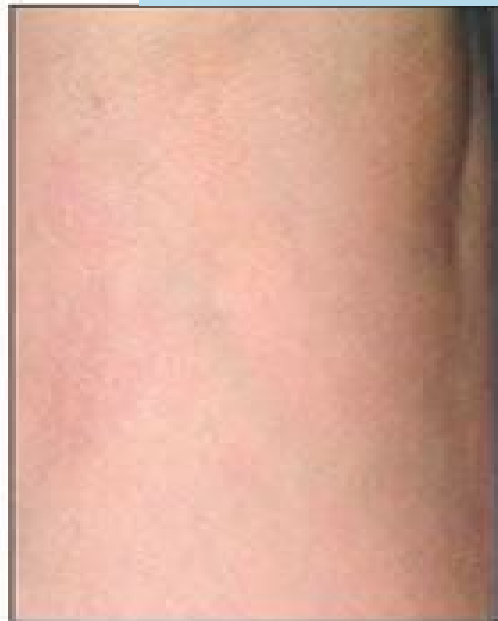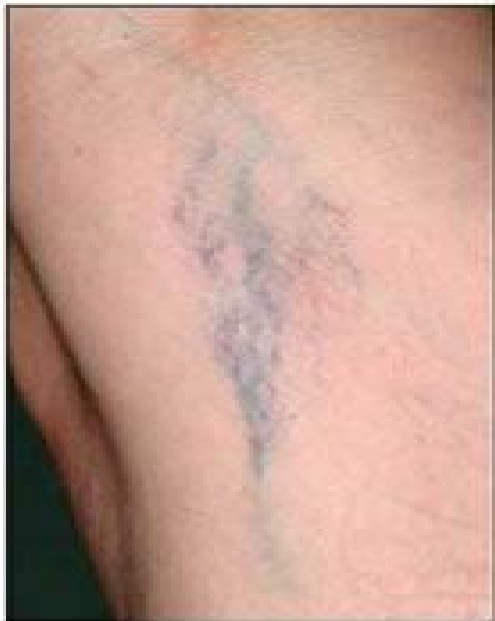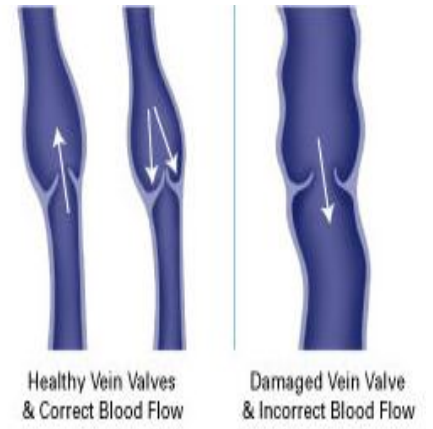


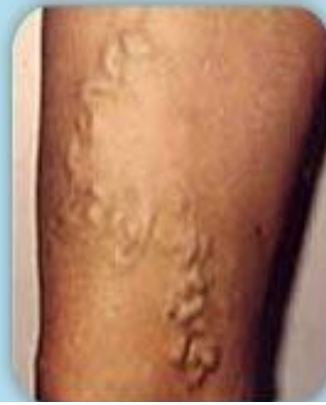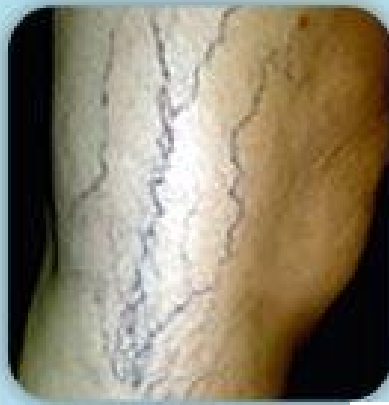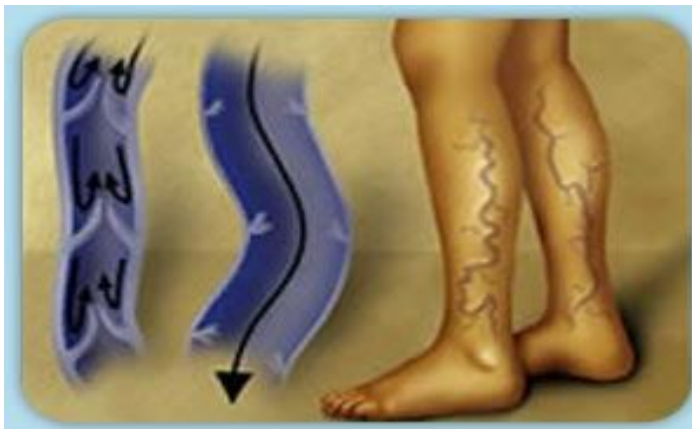SPIDER VEINS

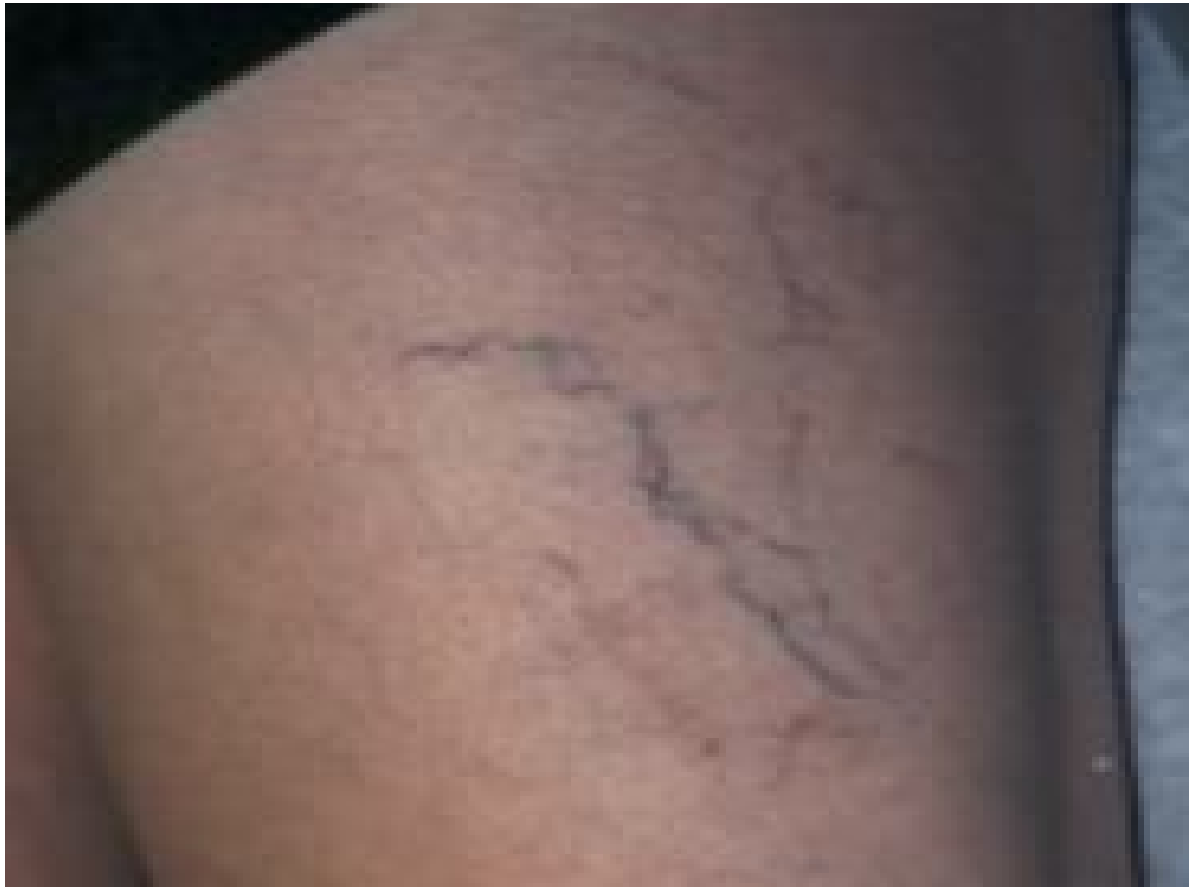

Vascular Anastomoses

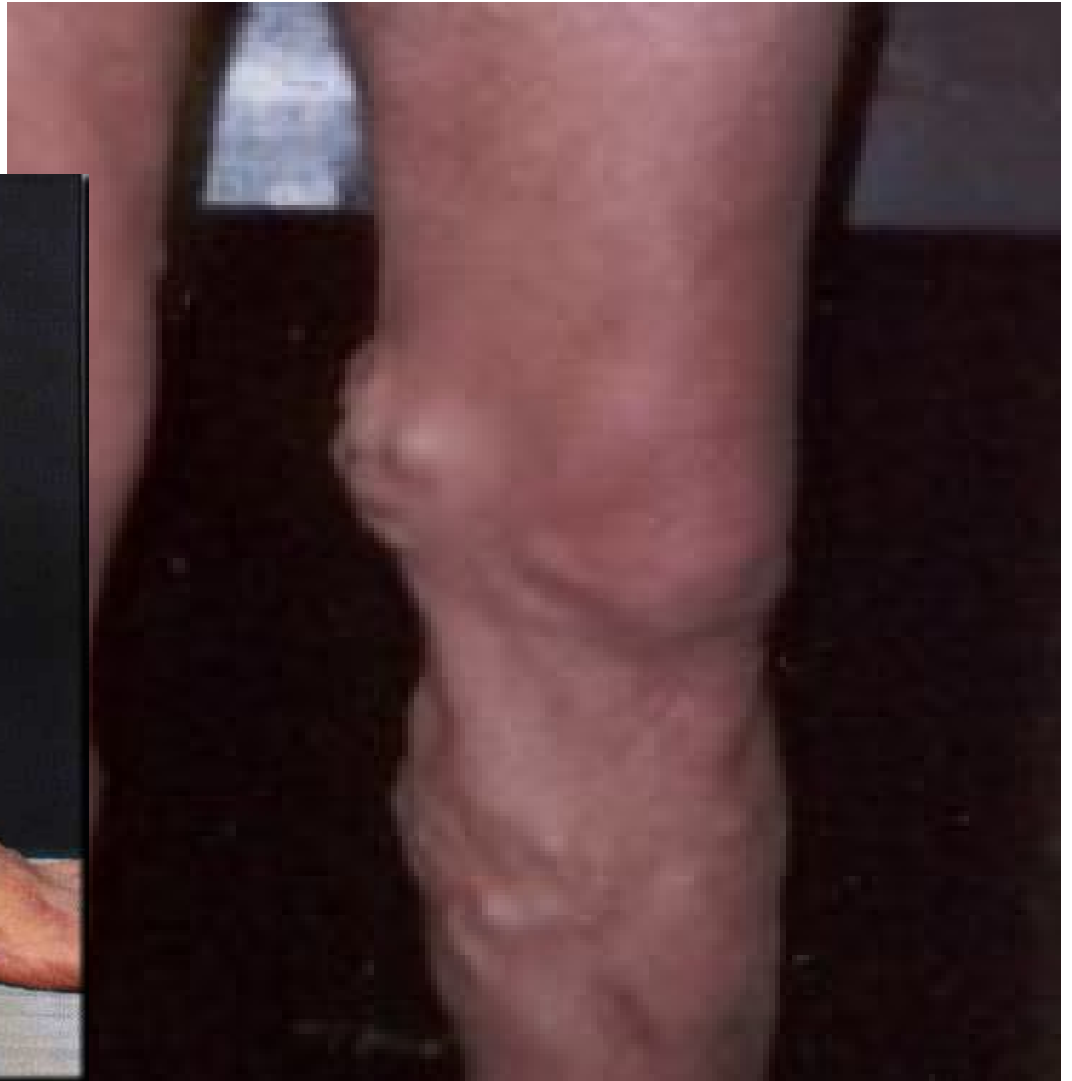
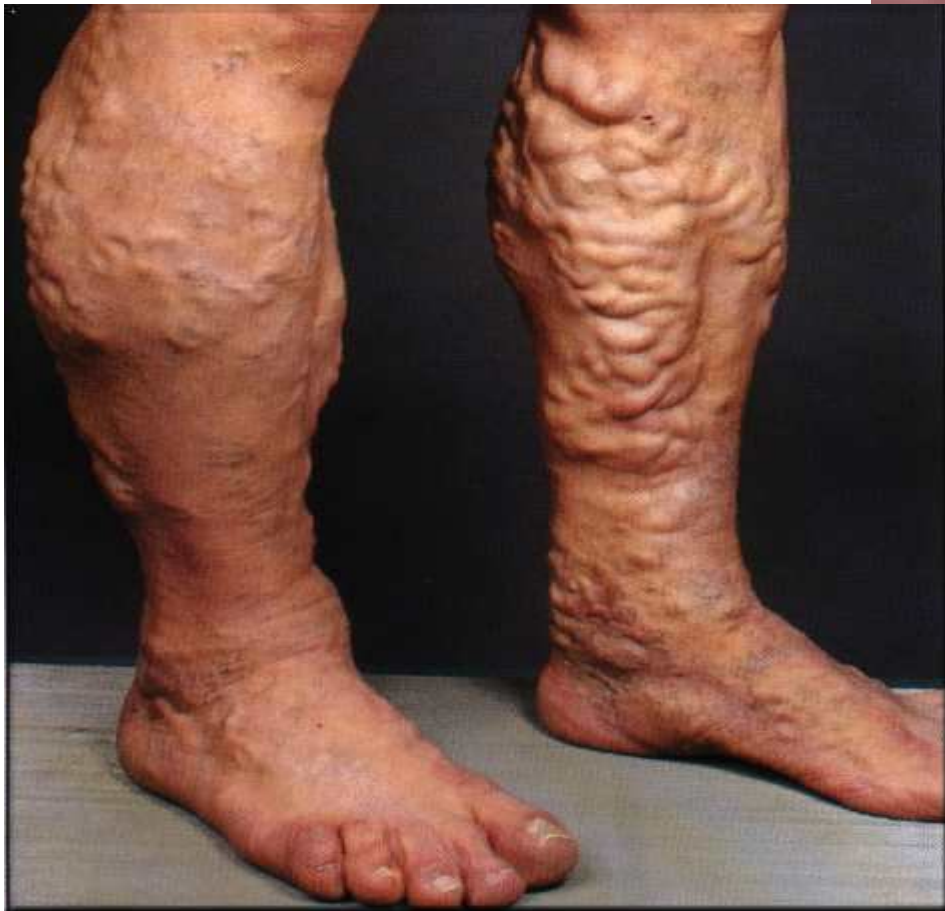- Merging blood vessels, more common in veins than arteries
- Arterial anastomoses provide alternate pathways (collateral channels) for blood to reach a given body region
 - ▣ If one branch is blocked, the collateral channel can supply the area with adequate blood supply
- Thoroughfare channels are examples of arteriovenous anastomoses

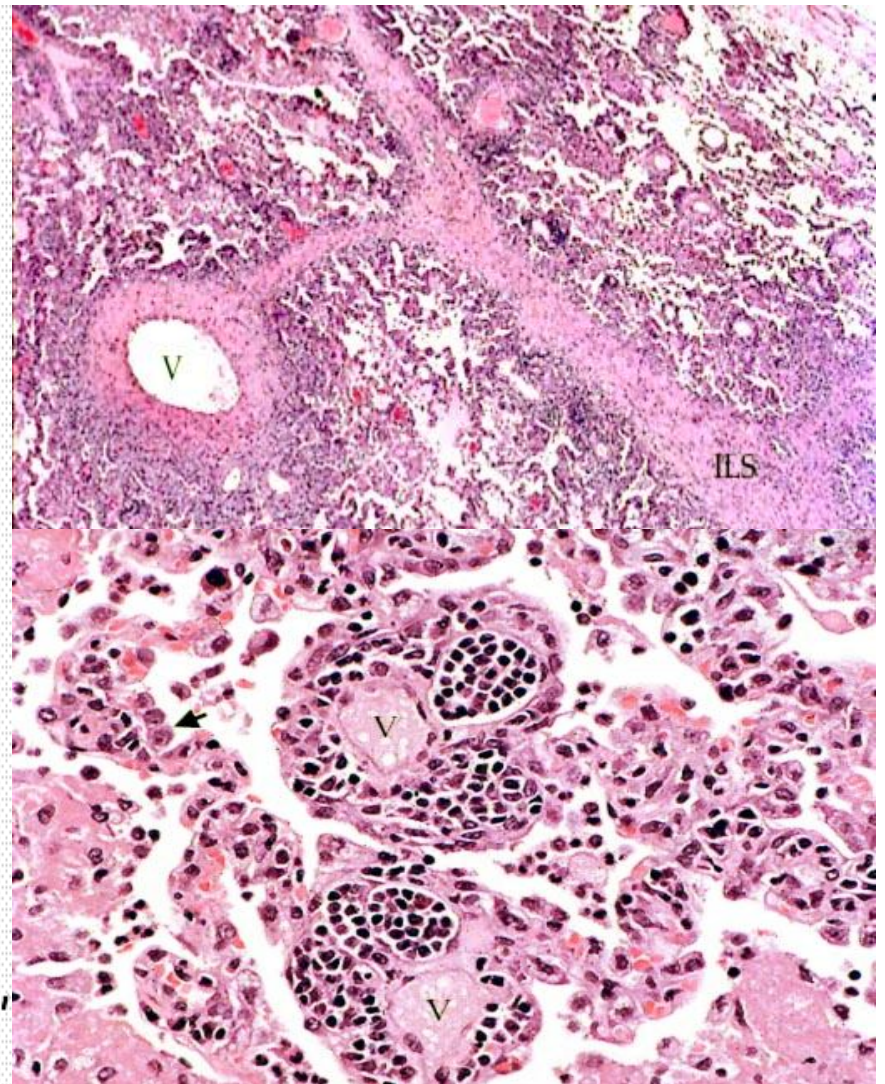
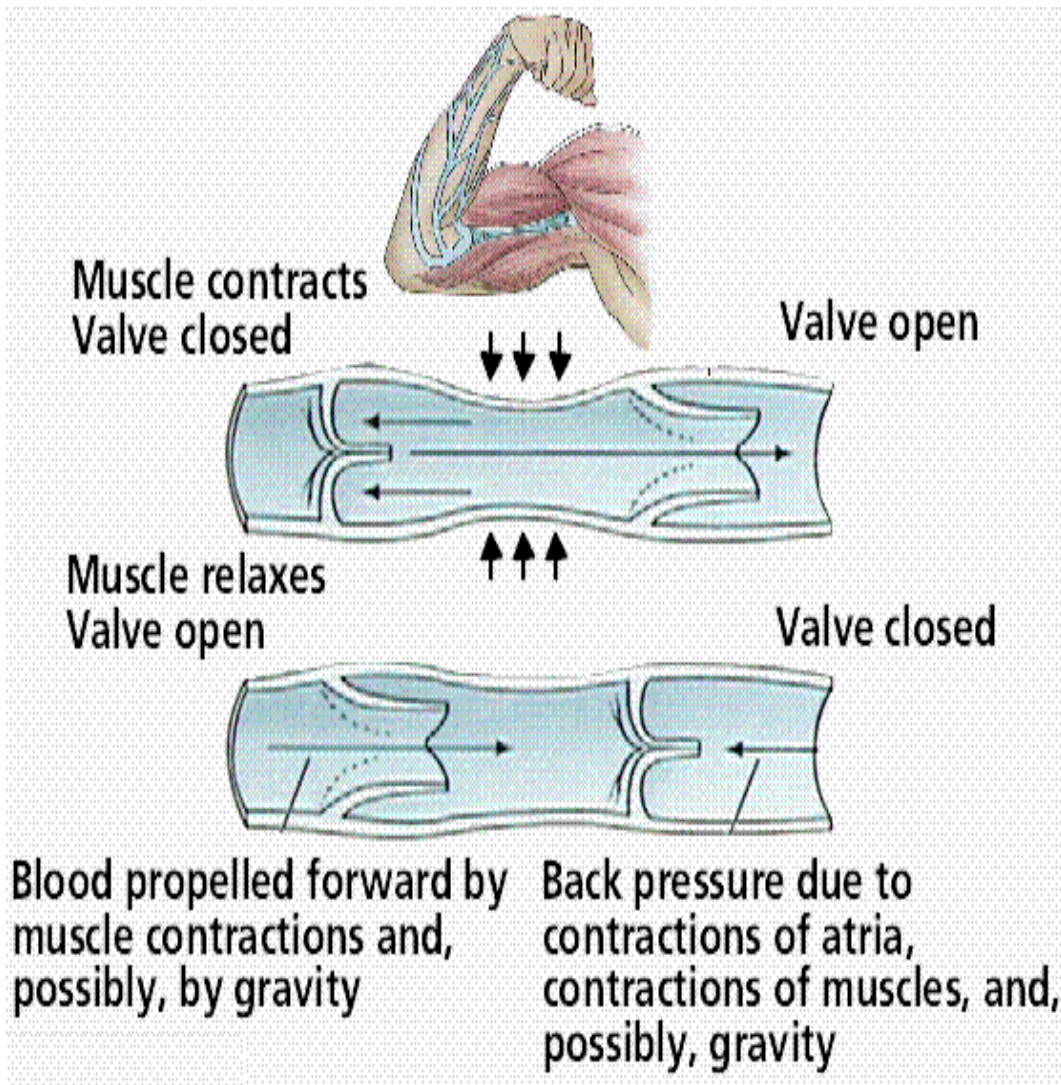


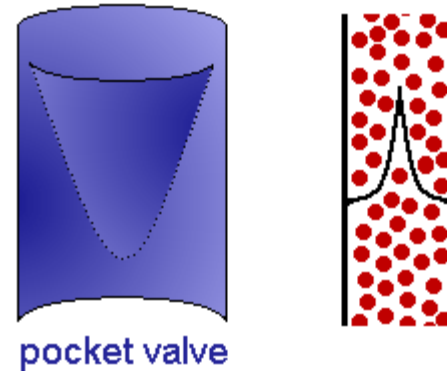
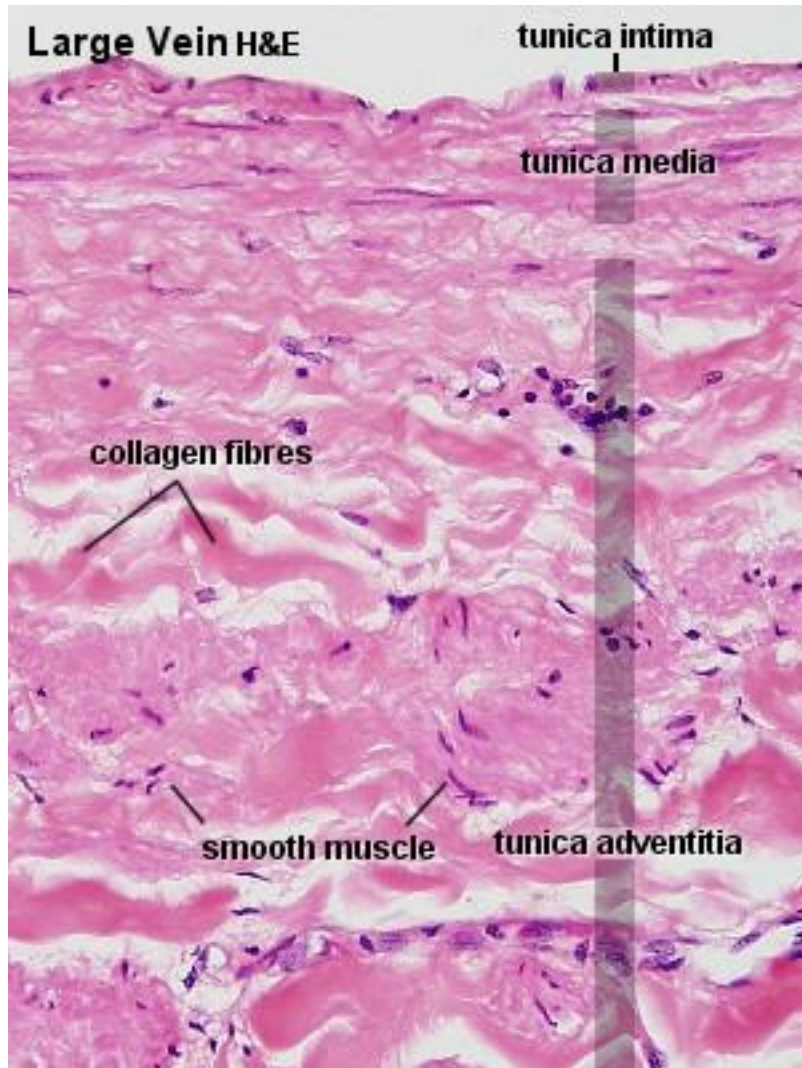
RETICULAR VEINS



VERICLOSE VEINS







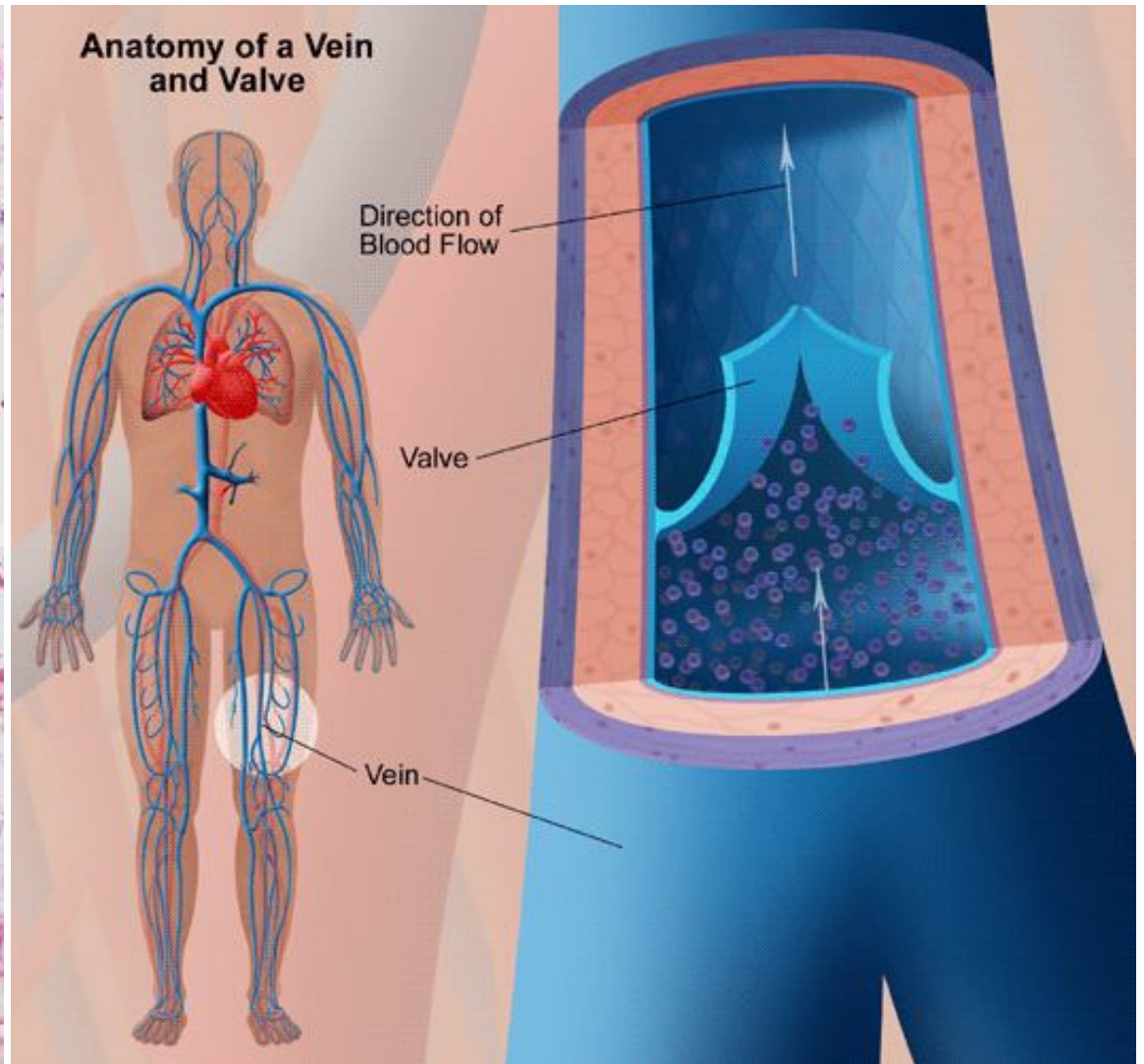
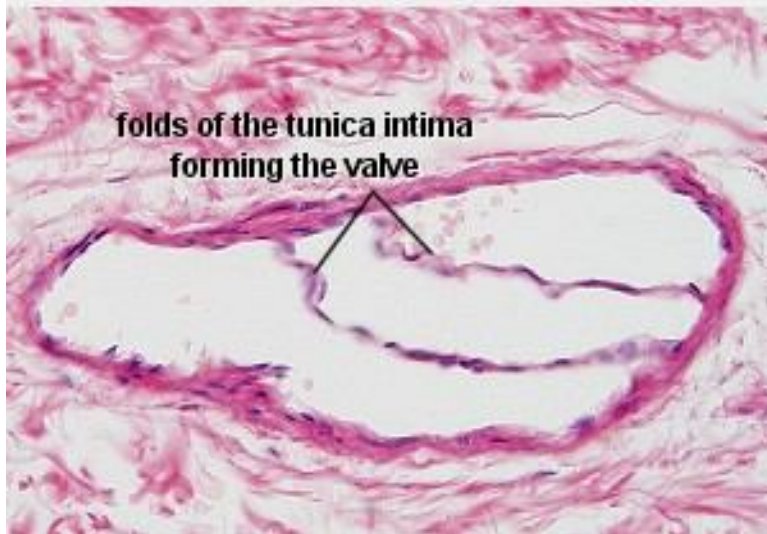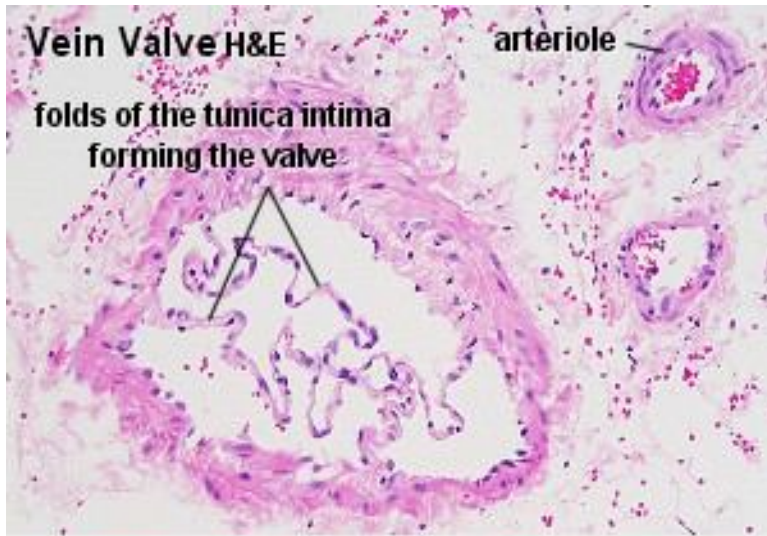The largest veins of the abdomen and thorax do contain some subendothelial connective tissue in the tunica intima, but both it and the tunica media are still comparatively thin.

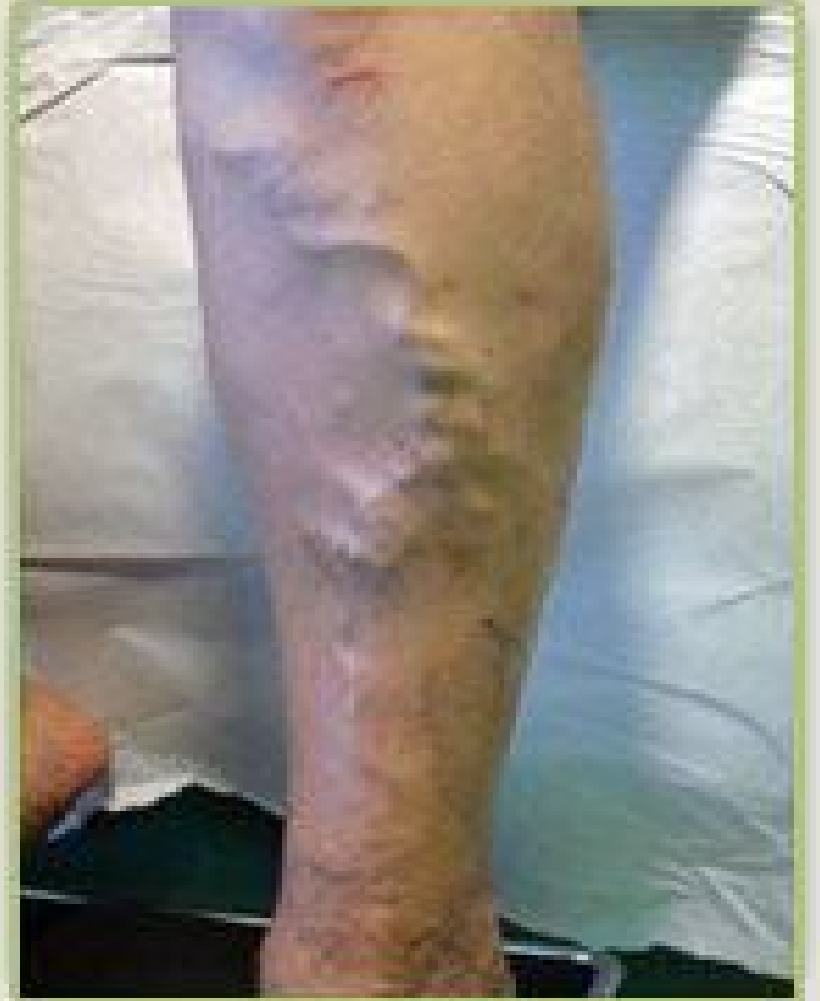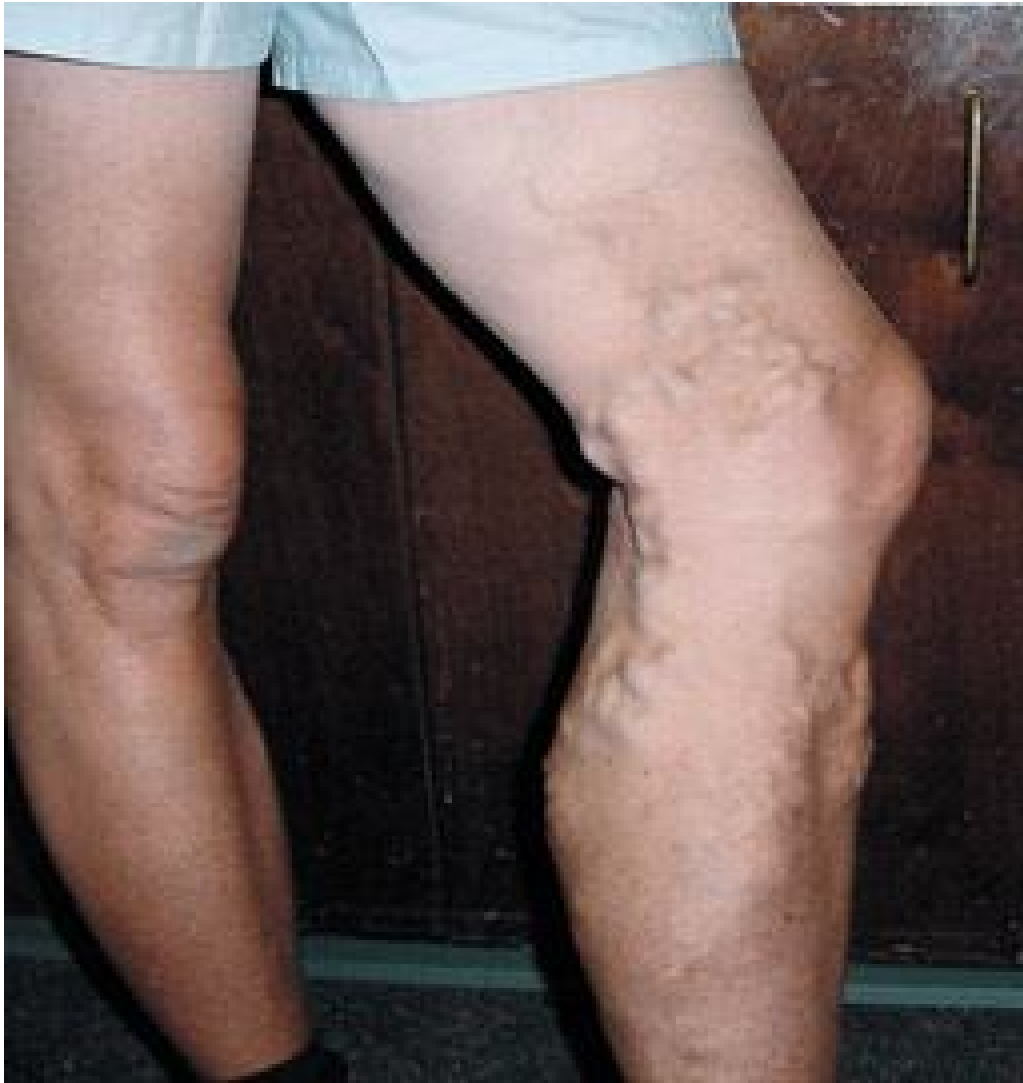Collagen and elastic fibres are present in the tunica media. The tunica adventitia is very wide, and it usually contains bundles of longitudinal smooth muscle.

The transition from the tunica adventitia to the surrounding connective tissue is gradual. Valves are absent.

Valves are absent.

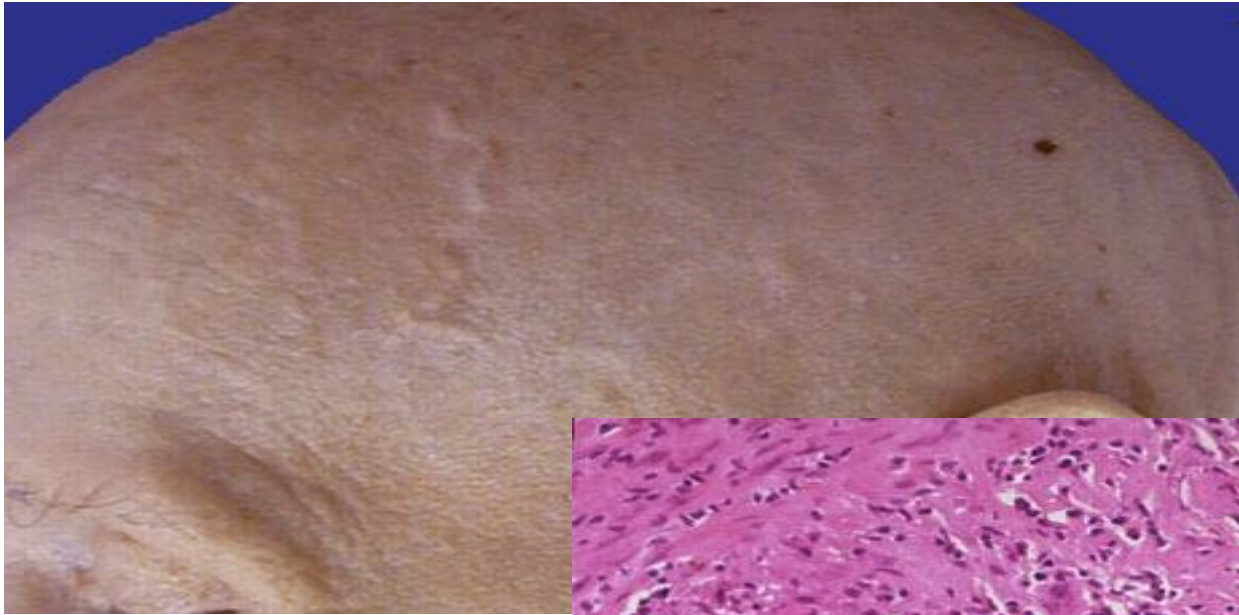
Vasa vasorum are more frequent in the walls of large veins than in that of the corresponding arteries - probably because of the lower oxygen tension in the blood contained within them.





Differences Between Arteries and Veins

	Arteries	Veins
Delivery	Blood pumped into single systemic artery – the aorta	Blood returns via superior and inferior venae cavae and the coronary sinus
Location	Deep, and protected by tissue	Both deep and superficial
Pathways	Fair, clear, and defined	Convergent interconnections
Supply/drainage	Predictable supply	Dural sinuses and hepatic portal circulation



**Temporal (Giant Cell)
Arteritis**
Horton'S disease

