

Abdominal wall hernias: types, features, diagnosis & complications

Dr. Muhammad Shamim

FCPS (Pak), FACS (USA), FICS (USA), MHPE (NI & Eg)

Assistant Professor, Dept. of Surgery

College of Medicine, Salman bin Abdulaziz University

Email: surgeon.shamim@gmail.com

Web: surgeonshamim.com



DEFINITION

- A hernia is a protrusion of a viscus or part of a viscus through an abnormal opening in the walls of its containing cavity.
 - Abdominal wall hernia is the commonest form.
 - Most frequent varieties are inguinal, umbilical & femoral, respectively (75, 15 & 8.5%).

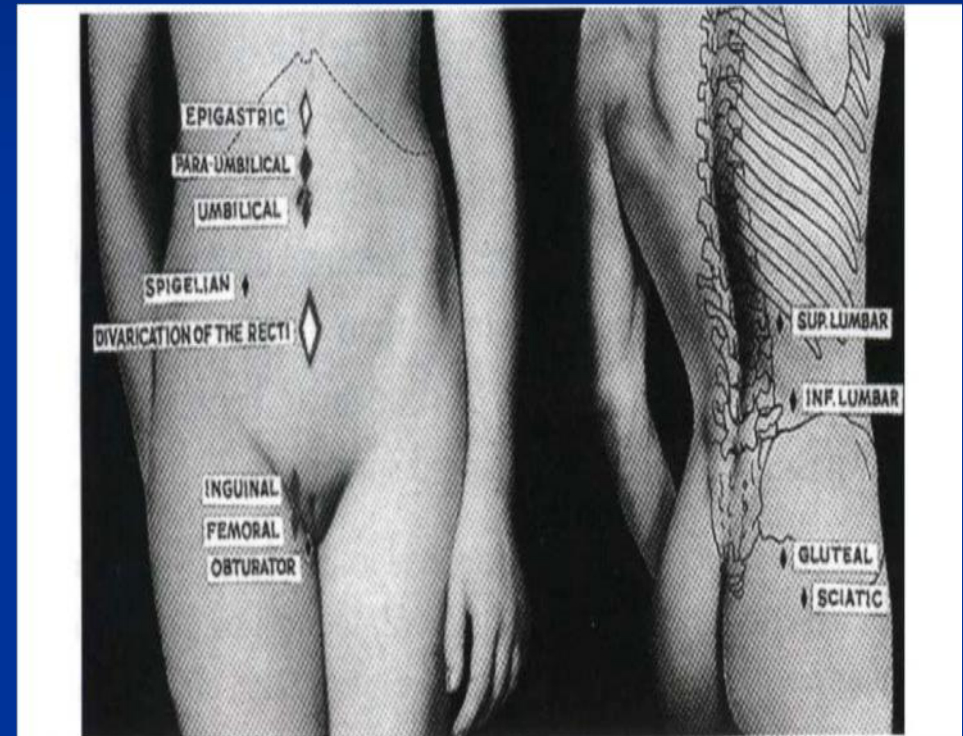


Fig. 62.1 External hernias. Red = common; white = not unusual; black = rare.

ETIOLOGY

- 1. High intra-abdominal pressure from;**
 1. Powerful muscular effort eg lifting a heavy weight.
 2. Chronic cough.
 3. Straining on micturition, or on defecation.
 4. Obesity.
 5. Pregnancy.
- 2. Intra-abdominal malignancy.**
- 3. An acquired weakness following trauma.**
- 4. An anatomical weakness where;**
 1. Structures pass thru abdominal wall.
 2. Muscles fail to develop.
 3. No muscles, only scar tissue eg umbilicus.
- 5. Smoking.**
- 6. Peritoneal dialysis.**

COMPOSITION OF A HERNIA

- **Sac**
 - It is a diverticulum of peritoneum consisting of mouth, neck, body, & fundus.
- **Coverings of sac**
 - Derived from the layers of abdominal wall thru which sac passes.

■ Contents of sac

- Fluid.
- Omentum (**omentocele, epiplocele**).
- Intestine (**enterocele**): Usually small intestine, but in some cases large intestine or vermiform appendix.
- A portion of circumference of intestine (**Richter's hernia**).
- A portion of bladder, or a diverticulum of bladder.
- Ovary with or without its fallopian tube.
- A Meckel's diverticulum (**Littre's hernia**).

CLINICAL CLASSIFICATION

1. Reducible hernia
2. Irreducible hernia
3. Obstructed hernia
4. Strangulated hernia
5. Inflamed hernia

Reducible hernia

- Hernia either **reduces** itself when the patient lies down, or can be reduced by the patient or surgeon:
 - **Intestine** gurgles on reduction, & first portion is more difficult to reduce than last.
 - **Omentum** is doughy, & last portion is more difficult to reduce than first.
- It imparts an **expansile impulse** on coughing.

Irreducible hernia

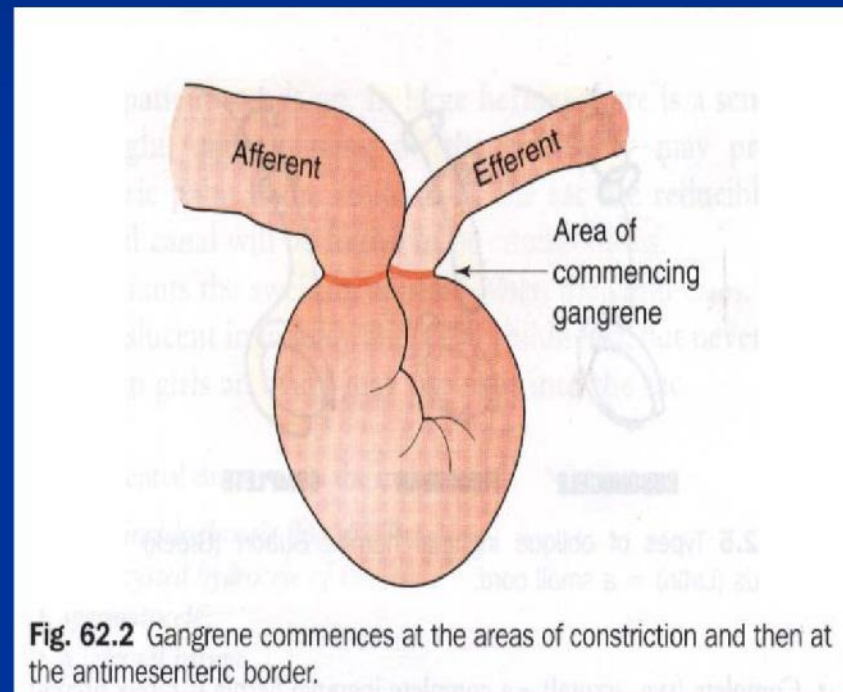
- Contents cannot be returned to abdomen, & there is no evidence of other complications.
- **Etiology**
 - Adhesion of its contents to each other.
 - Adhesion of its contents with sac.
 - Adhesion of one part of sac to other part.
 - Sliding hernia.
 - Very large scrotal hernia.

Obstructed hernia

- This is an irreducible hernia
 - containing intestine which is obstructed from without or from within; &
 - there is no interference to blood supply of bowel.

Strangulated hernia

- Here the contents are so constricted as to interfere with their blood supply.
- **On examination**
 - Hernia is tense, & extremely tender.
 - It is irreducible.
 - There is no expansile impulse on coughing.



Inflamed hernia

■ Causes

- irritation or sepsis of contents within sac, eg acute appendicitis or salpingitis,
- external causes, eg from a sore caused by an ill-fitting truss.

■ On examination

- Hernia is tender but not tense.
- Overlying skin becomes red & edematous.

INGUINAL HERNIA

- 2 types
 - Direct inguinal hernia
 - Indirect inguinal hernia

Indirect (oblique) inguinal hernia

- It comes out of abdominal cavity thru deep inguinal ring, traverses inguinal canal & becomes superficial thru superficial inguinal ring.
- **Types**
 - **Bubonocoele**
 - Hernia is limited to inguinal canal.
 - **Funicular**
 - Sac is closed just above the epididymis, & contents can be felt separately from testis, which lies below the hernia.
 - **Complete (scrotal)**
 - Hernia reaches the bottom of scrotum, & testis appears to lie within the lower part of hernia.

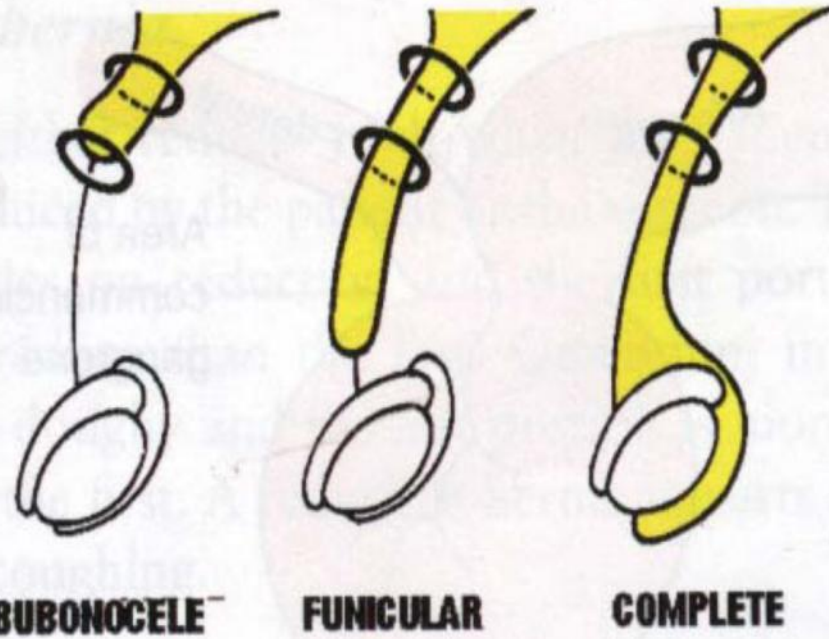


Fig. 62.5 Types of oblique inguinal hernia. *Bubon* (Greek) = groin; *funiculus* (Latin) = a small cord.

Direct inguinal hernia

- It enters the inguinal canal thru a weakness or defect of transversalis fascia, & becomes superficial thru the superficial inguinal ring.
- **Types**
 - **Incomplete**
 - Hernia fails to reach the bottom of scrotum.
 - **Complete**
 - Hernia reaches the bottom of scrotum (rare).
 - **Funicular direct inguinal hernia**
 - It occurs thru a small oval defect in medial part of conjoined tendon just above the pubic tubercle.
 - **Dual (Saddle bag, pantaloons) hernia**
 - Here there are 2 sacs which straddle the inferior epigastric artery.

Clinical features

■ Age

- Indirect hernia is most common in young.
- Direct hernia is most common in middle life or after.

■ Sex

- Males are 20 time more commonly affected than females.

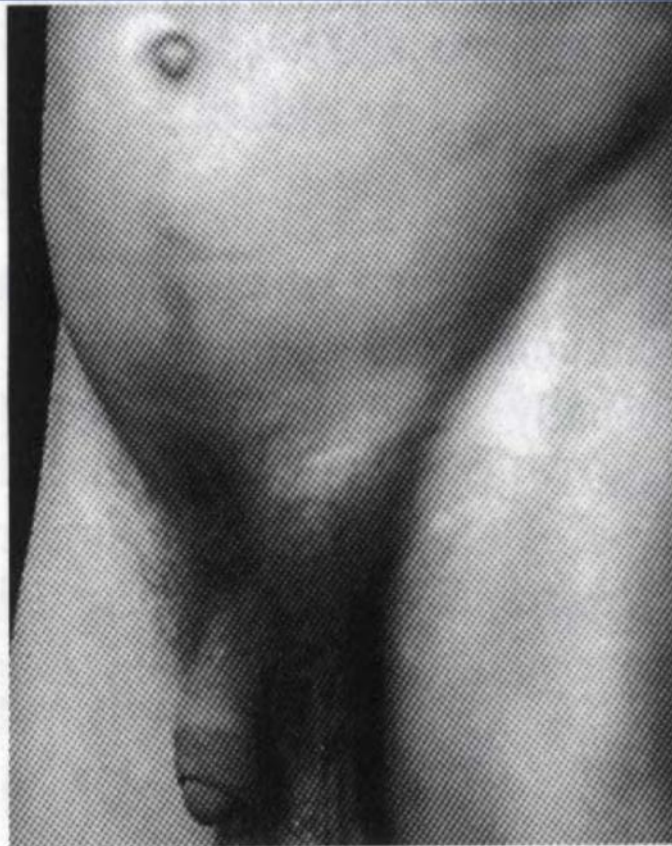
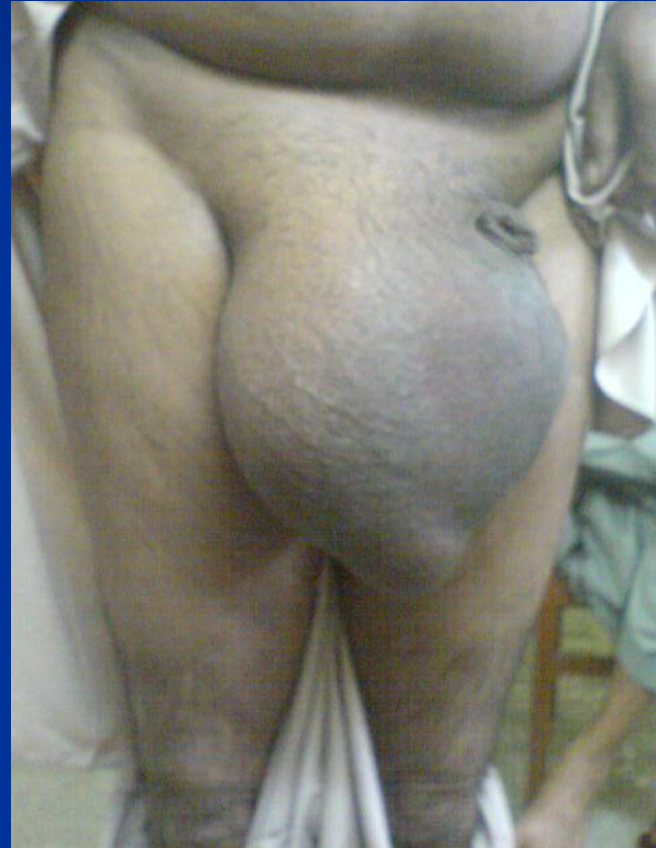
Fig. 62.6 Oblique left inguinal hernia which became apparent when the patient coughed, and persisted until it was reduced when he lay down.



Symptoms

- Pain
- Lump
- **Systemic symptoms**
 - In obstructed hernia, cardinal symptoms of intestinal obstruction are present
 1. Colicky abdominal pain,
 2. vomiting,
 3. abdominal distension, &
 4. absolute constipation.
 - Persistent coughing (of chronic bronchitis).
 - Constipation.
 - Frequency of micturition or urgency (BPH).

Signs

■ Local signs — Lump

- Position.
- Shape.
- Size.
- Color.
- Temperature.
- Cough impulse.
- Reducibility.
- Direct or indirect.

■ Composition

■ If it contains gut:

- Consistency: Soft.
- Percussion note: Resonant.
- Gut sounds: Audible.

■ If it contains omentum;

- Consistency: Rubbery, or doughy.
- Percussion note: Dull.
- Gut sounds: Nil.

■ General signs

- signs which reveals a cause of hernia, eg
 - chronic bronchitis,
 - ascites,
 - intra-abdominal masses, &
 - enlarged prostate.
- Signs of intestinal obstruction in obstructed hernia
 - Distension,
 - increased bowel sounds,
 - visible peristalsis.

D/D of inguinal hernia

■ In male

- Femoral hernia.
- Vaginal hydrocele.
- Encysted hydrocele of cord.
- Spermatocele.
- Undescended testis.
- Lipoma of cord.

■ In female

- Femoral hernia.
- Hydrocele of canal of Nuck.



Treatment

- **Herniotomy**
- **Herniorrhaphy**
 - Lytle method.
 - Shouldice method.
 - Bassini repair.
 - Darning repair.
- **Hernioplasty**
 - Lichtenstein tension-free hernioplasty.

Strangulated Inguinal Hernia

■ Predisposing Factors

- Oblique inguinal hernia.
- Partially reducible or irreducible hernia.
- Large hernia in elderly patients.

■ Constricting Agents

- Neck of sac.
- Superficial inguinal ring in children.
- Adhesions within sac.

■ Contents

- Small intestine (usually).
- Omentum.
- Large intestine (rarely).

Pathology

- Intestine is obstructed, & its blood supply is constricted.
- Initially venous return is impeded, with congestion of intestinal wall, & out pouring of serous fluid into sac.
- Strangulated loop becomes distended & purple, & arterial supply becomes more & more impaired.
- Blood is extravasated under serosa & into lumen.
- Serosa becomes dull, & intestine flabby & very friable.
- Lowered vitality of intestine favors migration of bacteria thru the wall into sac.
- Gangrene appears first at rings of constriction, & then it appears in antimesenteric border & spreads upwards.
- If strangulation is unrelieved, perforation of intestinal wall occurs, & peritonitis spreads from the sac to peritoneal cavity.

Clinical features

Symptoms

■ Pain

- Sudden onset.
- At first over the hernia, followed by generalized abdominal pain.

■ Vomiting

- Forcible, & usually oft-repeated.

■ Lump

- Recent increase in the size of lump.

Signs

■ Local signs — Lump

- Position, shape & size
- **Color:** Skin is reddened.
- **Temperature:** Raised.
- **Tenderness**
 - Hernia is tense & extremely tender.
 - In Maydl's hernia (hernia-en-W, the strangulated loop of the W lies within the abdomen, thus local tenderness over the hernia is not marked).
- **Cough impulse:** Absent.
- **Reducibility:** Hernia is irreducible.

■ General signs

- As in case of unstrangulated hernia.
- Features of paralytic ileus, peritonitis, & endotoxic shock, in late cases.

Treatment

- **Preoperative treatment**
 - Intravenous fluid replacement.
 - NG tube & gastric aspiration.
 - Bladder catheterization.
 - Suitable broad-spectrum antimicrobials, IV.
- **Operation — inguinal herniotomy**
 - Incision.
 - Delivering, & opening up of sac
 - Division of constricting agent
 - Excision of strangulated content
 - Excision of sac

FEMORAL HERNIA

Pathology

- Hernia passing down the femoral canal descends vertically as far as saphenous opening.
- Once escapes thru saphenous opening it expands, sometimes considerably.
- A fully distended hernia assumes the shape of a retort, & its bulbous extremity may be above the inguinal ligament.
- By the time the contents have pursued so tortuous a path, they are usually irreducible & apt to strangulate.

Clinical features

- Sex: Female to male ratio is 2:1.
- Age: Rare before puberty;
 - prevalence increases between 20 & 40 years, & continues to old age.

Symptoms

■ Local

- Lump in groin.
- Pain & discomfort.

■ General

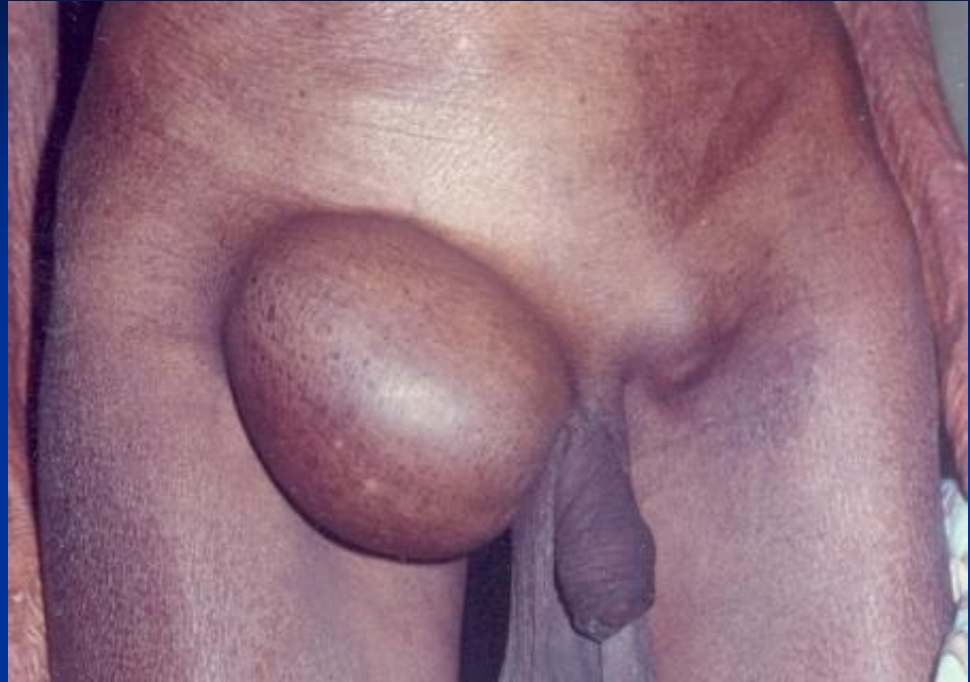- If causing obstruction:
Colic, distension,
vomiting, &
constipation.



Signs

Local signs — Lump

- Position.
- Shape & size.
- Color.
- Temperature.
- Tenderness.
- Cough impulse.
- Reducibility.
- Composition
 - Usually contain omentum, or the sac is empty surrounded by a lot of extra-peritoneal fat.
 - A large hernia may contain bowel.



Systemic signs

- Same as mentioned above in inguinal hernia.

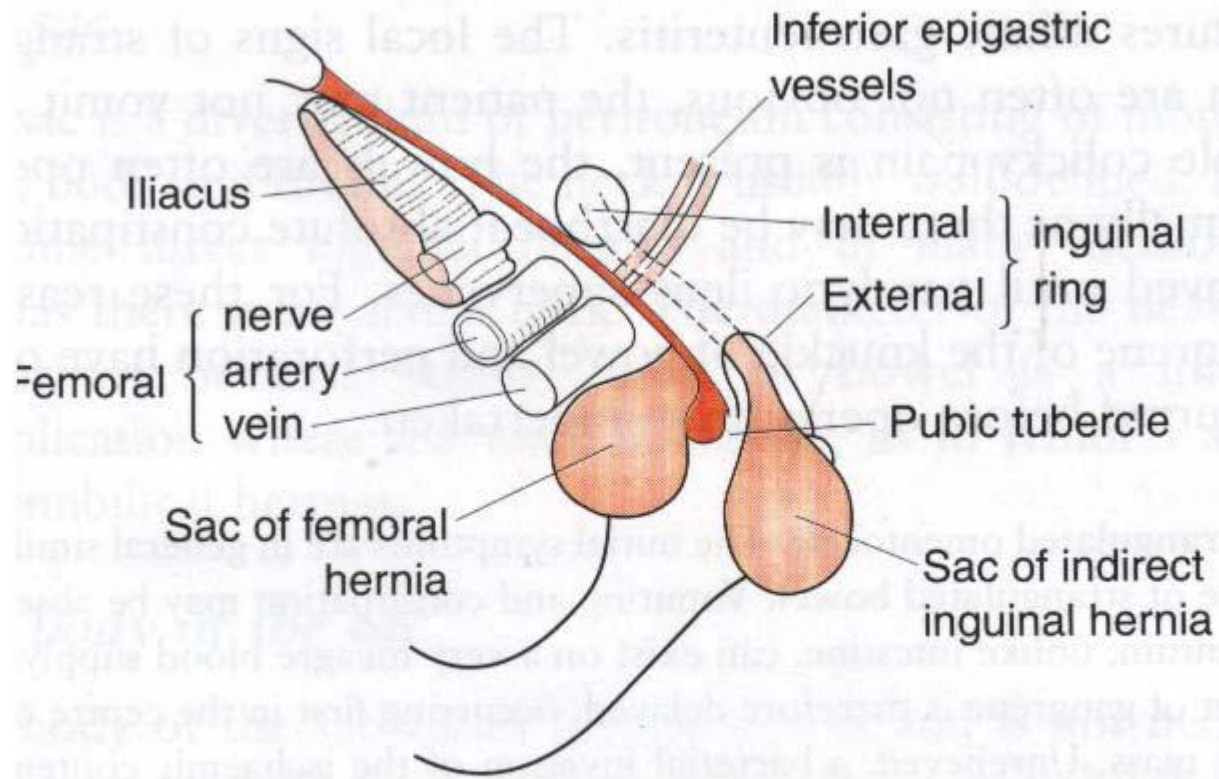


Fig. 62.4 The relationship of an indirect inguinal and a femoral hernia to the pubic tubercle; the inguinal hernia emerges above and medial to the tubercle, the femoral hernia lies below and lateral to it.

D/D of femoral hernia

1. Inguinal hernia
2. Saphena varix
3. Enlarged femoral lymph node
4. Lipoma
5. Femoral aneurysm
6. Psoas abscess
7. Distended psoas bursa
8. Rupture of adductor longus with hematoma

Treatment

■ Operative choices

- Low (Lockwood) operation
- High (McEvedy) operation
- Lotheissen's operation
- Modified Lotheissen operation (for strangulated femoral hernia)

UMBILICAL HERNIA

Exomphalos (Omphalocele)

- Abdominal contents are protruded thru a defect in all layers of abdominal wall at the centre of abdomen, being covered by a thin transparent membrane.
- **Etiology**
 - Failure of all or part of midgut to return to coelom during early fetal life.

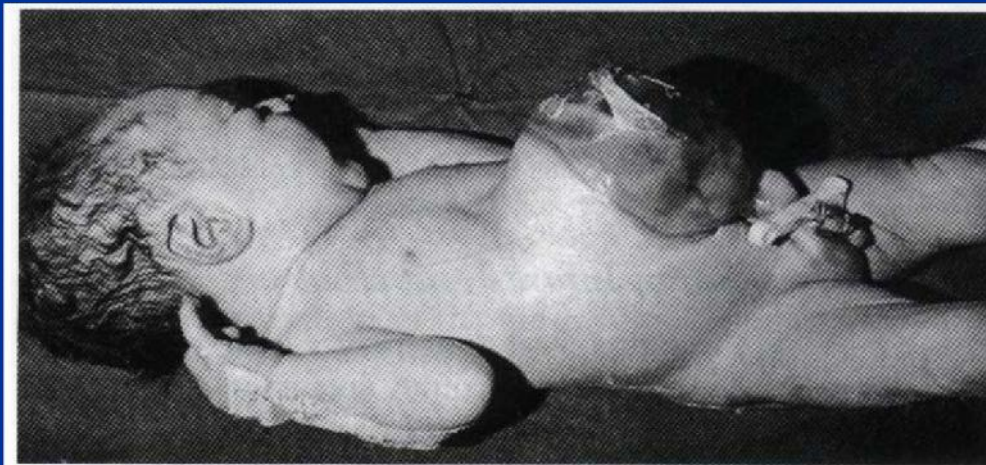


Fig. 62.15 Exomphalos. The delicate sac ruptured soon afterwards.

Types

■ Exomphalos minor

- Fascial defect is less than 4 cm;
- the sac is relatively small, contains a loop of small intestine or a Meckel's diverticulum, & to its summit is attached the umbilical cord.

■ Exomphalos major

- Fascial defect is greater than 4 cm.
- Umbilical cord is attached to the inferior aspect of swelling, which contains small & large intestine, & nearly always a portion of liver; spleen, stomach, pancreas, or bladder may also be seen thru the membrane.
- Here the sac may rupture, & peritonitis supervene.

Treatment

■ In exomphalos minor

- Twist the cord, so as to reduce the contents of sac thru narrow umbilical opening into peritoneal cavity, & retain them by firm strapping.

■ In exomphalos major

- Nonoperative therapy
 - Intact sac is painted daily with a desiccating antiseptic solution &, if successful, an eschar forms over the sac. Eventually granulations grows in from the periphery & the subsequent ventral hernia can be repaired later.
- Skin flap closure
- Staged closure
- Primary closure

Congenital umbilical hernia

- This is a hernia thru a weak umbilical scar, usually the result of neonatal sepsis.
- About 90% herniae disappears spontaneously during first 5 years of life as the umbilical scar thickens & contracts.

Clinical Features

■ Symptoms

- Swelling at umbilical scar, which increases in size on crying.
- Aching abdominal pain (occasionally).

■ Signs — lump

- Position
- Shape
- Size
- Cough impulse
- Reducibility
- Composition

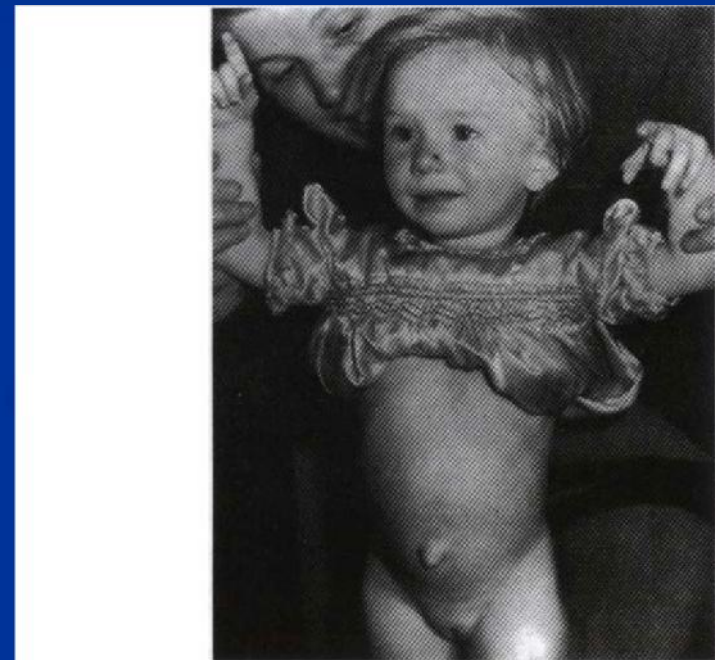


Fig. 62.16 Infantile umbilical hernia.

Treatment

- Conservative treatment
 - Masterly inactivity.
 - Pulling the skin & abdominal musculature together by adhesive strapping placed across the abdomen.
- Herniorrhaphy

Acquired umbilical hernia

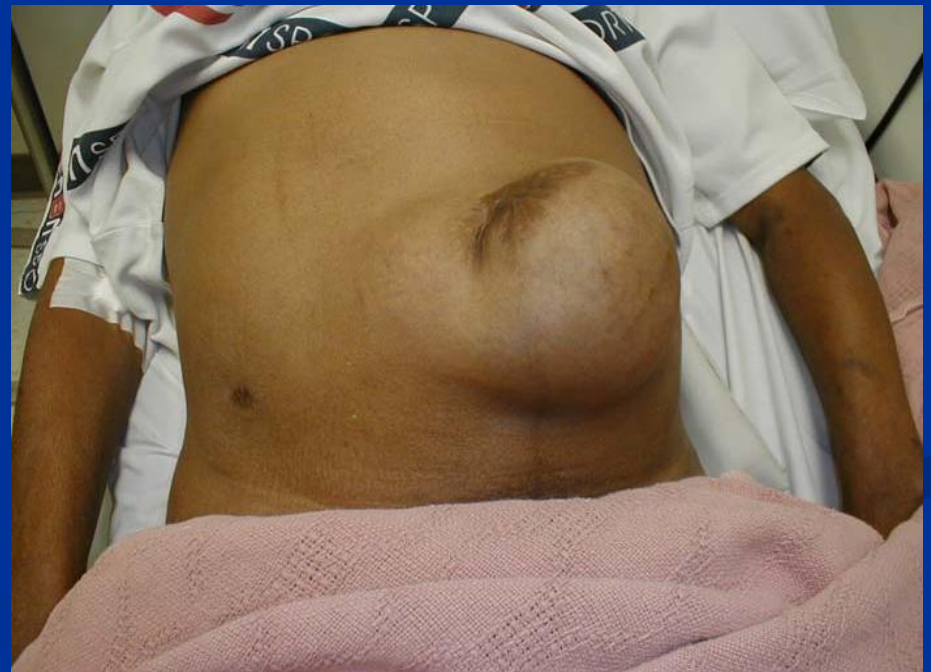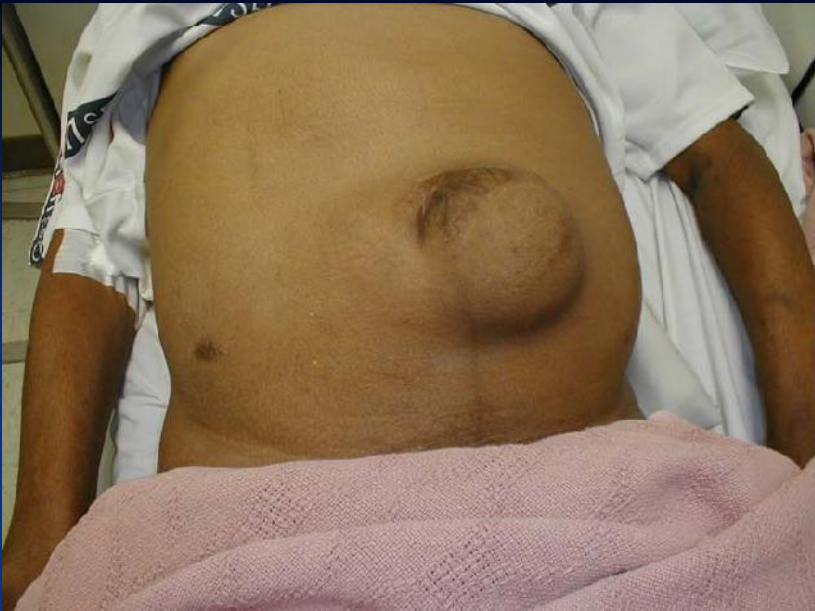- This hernia occurs in adult life & protrudes thru the umbilical scar, & is usually secondary to a raised intra-abdominal pressure.

Paraumbilical hernia

- It is a protrusion thru the linea alba just above or sometimes just below the umbilicus.
 - Supraumbilical or infraumbilical hernia
- Owing to the narrow neck of sac & fibrous edge of linea alba, strangulation is likely to occur.

Clinical Features

- Age: Middle & old age.
- Sex: Five times more common in women esp. in obese & multiparous women.
- **Symptoms**
 - A swelling, just above or below the umbilicus.
 - Dragging pain, in case of large hernia.
 - Gastrointestinal symptoms (due to traction on stomach or transverse colon).
 - Transient attack of intestinal colic (due to subacute intestinal obstruction).
 - Intertrigo (superficial dermatitis) of adjacent surfaces of skin, in long-standing cases.
- **Signs — lump**



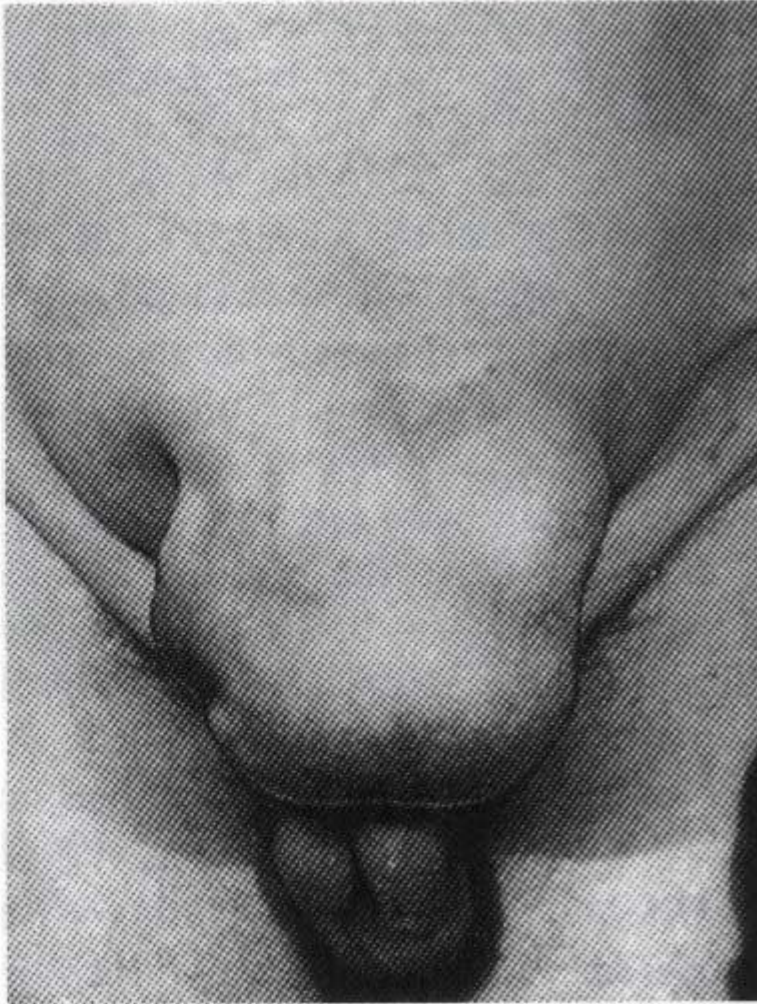


Fig. 62.17 A large paraumbilical hernia.

Treatment

■ Herniorrhaphy

- In small hernia, deficiency can be closed by a simple repair using interrupted unabsorbable sutures.
- For larger hernia — Mayo's repair

■ Hernioplasty

- In very large paraumbilical hernias (fascial defect > 4 cm) or for recurrent paraumbilical hernias.

■ For strangulated hernia

- In early cases: Mayo's technique.
- Devitalized omentum: Excision.
- Gangrenous small intestine: Excision & end-to-end anastomosis.
- Gangrenous transverse colon: It should be exteriorized by Paul-Mikulicz method, & the gangrenous portion is excised.

EPIGASTRIC HERNIA

- It occurs thru the linea alba anywhere between xiphoid process & umbilicus, usually midway between these structures.
- It commences as a protrusion of extraperitoneal fat, & when enlarges, it drags a pouch of peritoneum after it.

Clinical Features

■ Symptomless

- Hernia discovered during routine abdominal palpation.

■ Lump

- In the midline between xiphoid process & umbilicus, firm, unreducible, & with no cough impulse.

■ Pain

- Attacks of local pain, which is worse on physical exertion & after eating, & tenderness to touch & tight clothing.

Treatment

■ Operation

- Herniorrhaphy
- Hernioplasty, if the hernia is large (defect greater than 4 cm in diameter).

INCISIONAL HERNIA

- This is a hernia thru an acquired scar in abdominal wall, usually caused by previous surgical operation or accidental trauma.
- **Predisposing factors**
 - Persistent postoperative cough.
 - Postoperative abdominal distension.
 - Obesity.
 - Operation for peritonitis without drainage tubes.

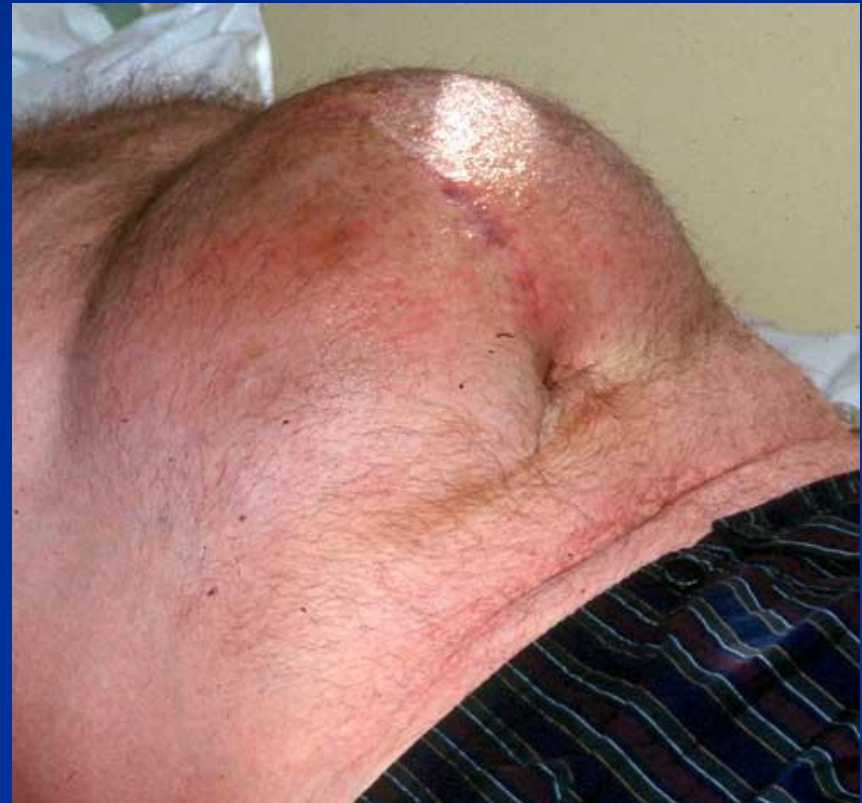Clinical Features

■ Symptoms

- Lump, thru a small portion of scar, often the lower end, or a diffuse bulge of whole length of incision.
- Pain
- Symptoms of intestinal obstruction

■ Signs

- Lump
- Abdominal distension



Treatment

■ Palliative treatment

- An abdominal belt, esp. in cases of a hernia thru an upper abdominal incision.

■ Surgical treatment

- Anatomical repair
- Plastic fibre mesh or net closures.

The End!