

# Non epileptiform abnormality

---

SUDA JIRASAKULDEJ, MD.

CHULALONGKORN COMPREHENSIVE EPILEPSY CENTER

JULY 27, 2016



# Outline

---

- Slow pattern
  - Focal slowing
  - Generalized or regional slowing
  - Triphasic waves
- Fast frequency pattern
  - Abnormal beta activity
  - Breach rhythm
- Patterns in coma
  - Alpha coma
  - Alpha-theta coma
  - Beta coma
  - Spindle coma
- Amplitude asymmetry
- Focal attenuation
- Generalized change of amplitude
  - Low voltage and suppressed patterns
    - Generalized suppression
    - Burst suppression
    - Electro-cerebral inactivity
  - High voltage pattern
- Abnormal frequency or reactivity of alpha
- Abnormal sleep potentials

# Abnormal EEG pattern

---

- Interictal epileptiform activity
- Ictal patterns
- **Non-epileptiform abnormality**

# Slow pattern

Focal slowing

Generalized slowing

Triphasic waves

---




# Focal slowing

---

- Frequency less than 8 Hz and limited distribution
  - Delta 0.5-3.9 Hz, theta 4-7.9 Hz
- Indicate focal cerebral dysfunction
- Result of cortex deafferentation from subcortical structure
- Suggests underlying abnormality but nonspecific etiology
  - Structural (tumor, infarction, trauma, abscess)
  - Functional (postictal, migraine)
  - Rarely: toxic-metabolic: hypoglycemia, hyperglycemia

# Focal slowing: assessment

---

- Arrhythmic polymorphic or rhythmic monomorphic
  - Persistence: intermittent or continuous
  - Reactivity
  - Amplitude
  - Frequency
- 

# Focal slowing: clinical correlation

---

- Continuous focal **arrhythmic polymorphic** delta activity
    - Highly correlated with localized structural lesion in subcortical white matter
    - Tumor, stroke, abscess, intra parenchymal hematoma or contusion
  - Continuous focal **rhythmic monomorphic** slowing
    - More commonly associated with grey matter lesions
  - **Persistence**
  - **Reactivity**
- } Indicators of damage degree
- Frequency
    - Slow growing tumor usually associated with focal slow more frequently in theta range +/- epileptiform discharges
    - Fast-growing tumor → focal slow in delta range

Generalized or regional slow

---





# Generalized or regional slow

---

- Intermittent or continuous
- Arrhythmic polymorphic or rhythmic monomorphic
- Synchronous or asynchronous
  - Synchronous → disordered circuits between cortex and thalamus
  - Asynchronous → interfere with structural or function of both hemispheres, and involve subcortical white matter or thalamocortical or corticothalamic pathway

## Intermittent rhythmic delta activity (IRDA)

---

- Runs of high voltage rhythmic 2-3 Hz recurring at irregular interval
- Bisynchronous, monomorphic, may be asymmetric or unilateral, reactive/attenuate to eye opening or alerting
- Considered a projected rhythm from deep structure, may reflect diffuse grey dysfunction either cortical or subcortical
- Possible sources in reticular activating system or dorsomedial nucleus of thalamus

## Rhythmic delta activity

---

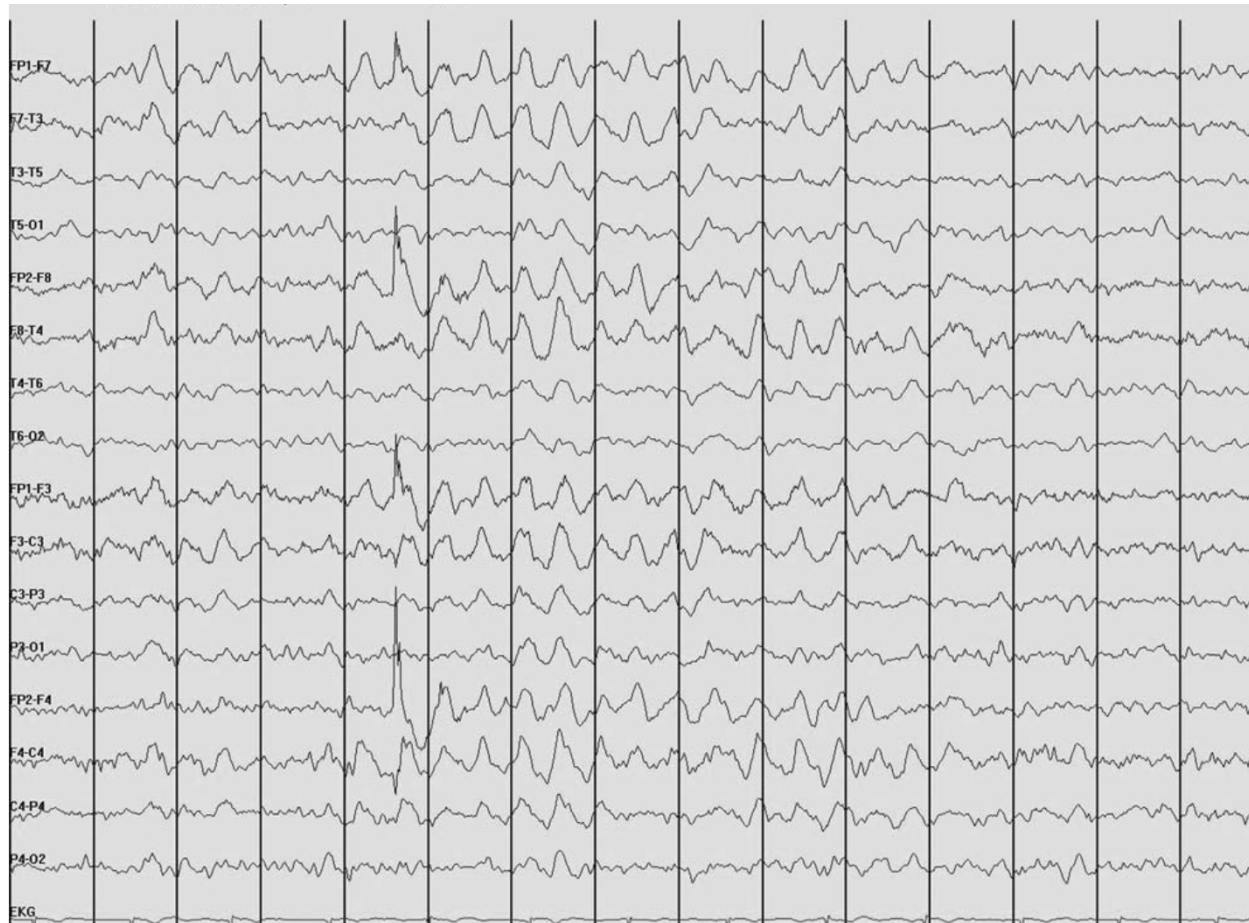- Frontal intermittent rhythmic delta activity (FIRDA)
- Occipital intermittent rhythmic delta activity (OIRDA)
- Temporal intermittent delta activity (TIRDA)

# FIRDA

---

- Bilateral synchronous 2-3 Hz delta activity with frontal predominance
- Early study
  - Tumor of posterior fossa and third ventricle, deep midline lesion, hydrocephalus
- More recent study
  - Focal structural lesion: asymmetric FIRDA
  - Diffuse brain injury in combination with metabolic disturbances
- Prospective controlled study
  - Identified FIRDA in 6% of EEG
  - Should initiate work up for toxic, metabolic or structural lesion
- Must be differentiated from vertical eye blinks, normal HV, hypnagogic hypersynchrony

# FIRDA



# Temporal intermittent delta activity (TIRDA)

---

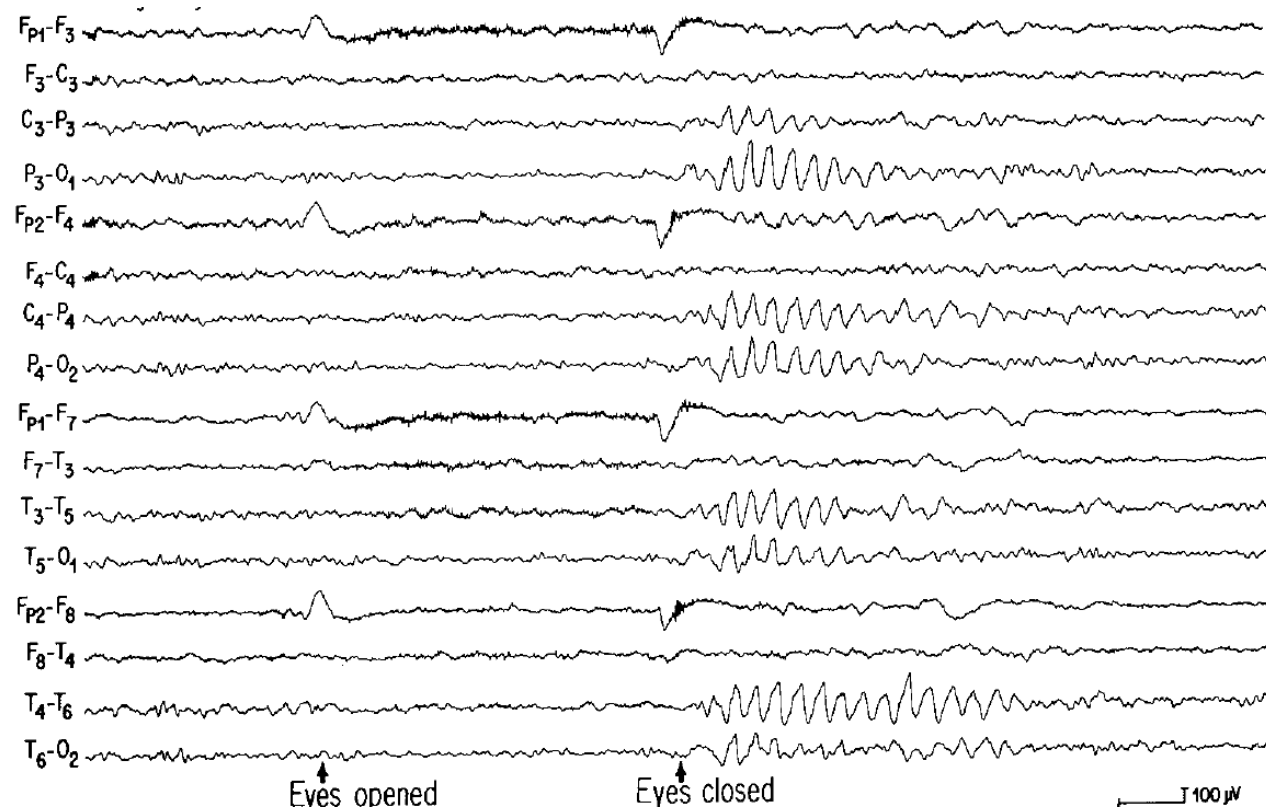
- Bursts or train of 3 seconds or more of repetitive, rhythmic, saw-toothed or sinusoidal 1-4 Hz, 50-100 microvolts
- Predominant over anterior temporal region
- Associated with temporal lobe epilepsy

## Occipital intermittent rhythmic delta activity

---

- Bi-posterior predominant rhythmic delta activity in children
- Occurred primarily in children with absence epilepsy
- Lesion in occipital lobe with involvement of posterior lateral ventricle: unilateral OIRDA

# Rhythmic delta slow over posterior head region in absence epilepsy





# Generalized theta activity

---

- Metabolic or drug induced encephalopathy
- Reactive in mild encephalopathy
- Non reactive in theta coma
  - Similar prognosis with alpha coma
  - Majority die or remain vegetative, some recover

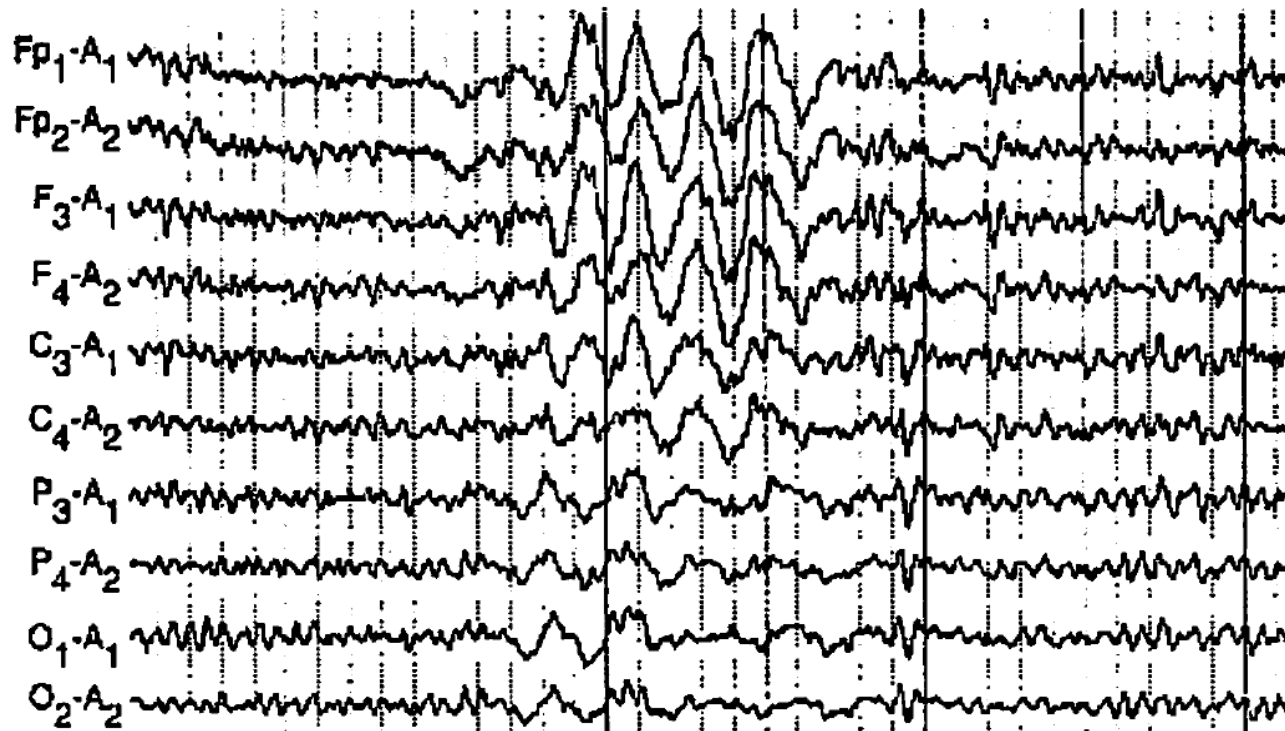# Continuous generalized slow

---

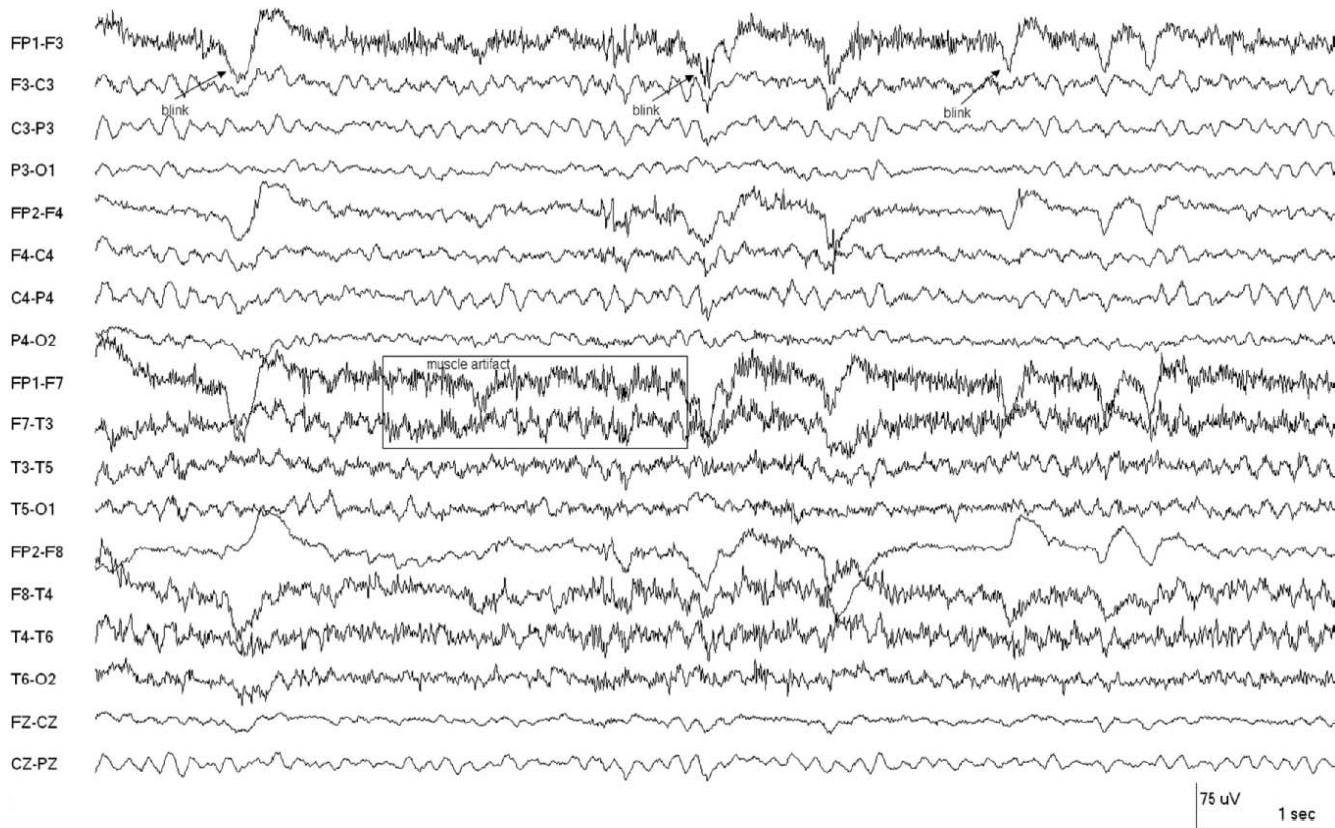
- Normal feature or drowsy or sleep EEG
- Earliest sign of mild encephalopathy → slowing of posterior waking background
- Encephalopathy deepens → slow of anterior rhythm → predominant polymorphic delta slowing → less reactivity or organization
- Deep coma → burst suppression, generalized suppression → isoelectric

# Drowsy burst in older patient

---




# Mild diffuse slowing

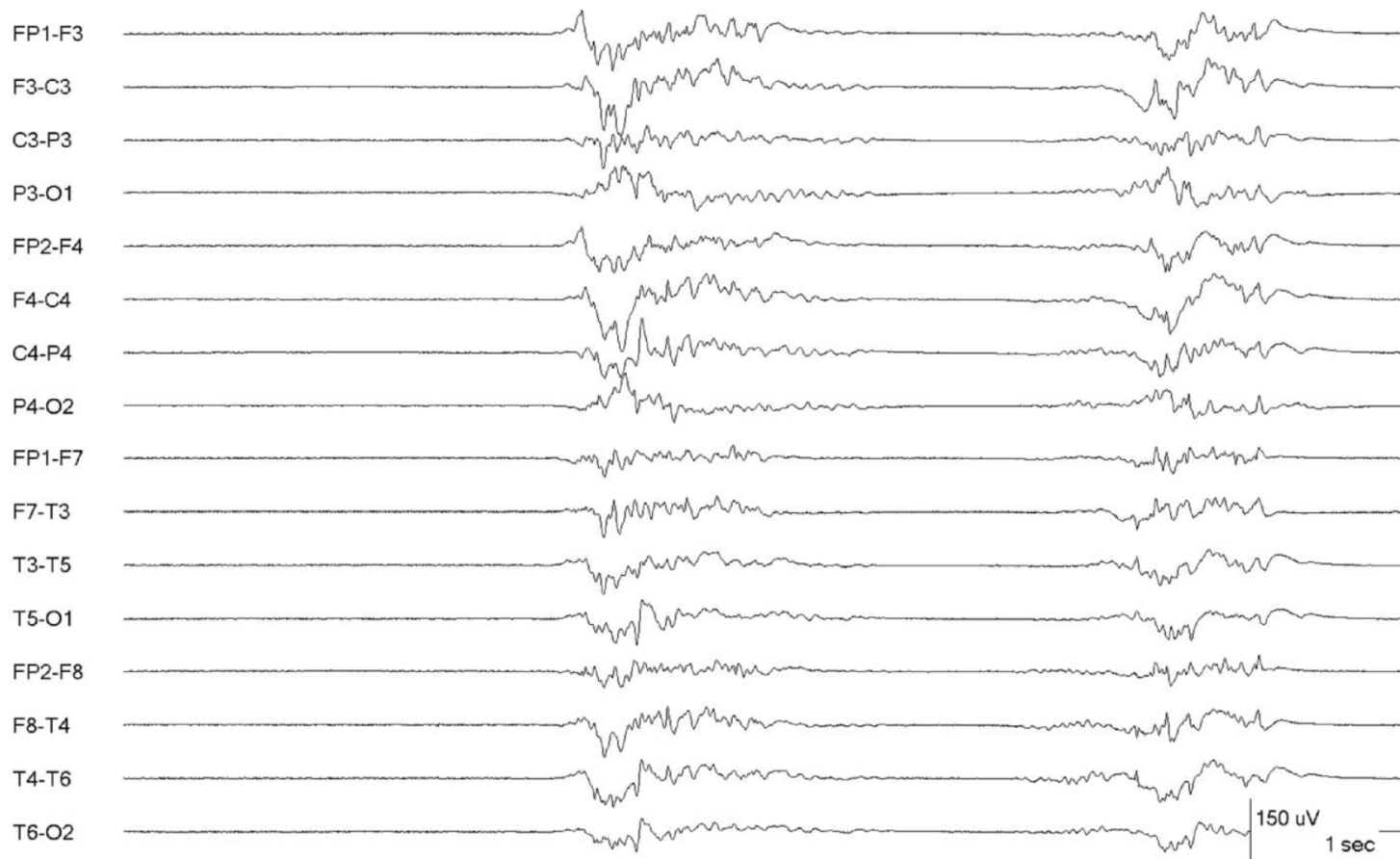


# Marked diffuse slowing and attenuation

---



# Suppression burst pattern



# Triphasic wave

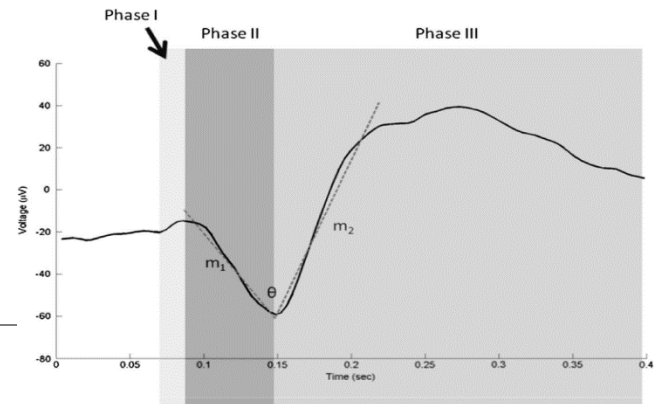
Special type of generalized slow waves

---



# Triphasic waves

---



- First description: Blunt spike and slow waves pattern in hepatic coma
- Bilaterally synchronous and symmetrical waves
- **Three phases**: initiate and terminate with small upward deflection (negative wave) surrounding a **prominent downward deflection** on bipolar montage
- Typically bi-frontal predominant, 1.5-2.5 Hz, 70-300  $\mu\text{V}$
- May have 25-140 ms anterior–posterior or posterior-anterior lags
- May increase or attenuate with stimulation
- Occur intermittently in brief runs or continuous pattern

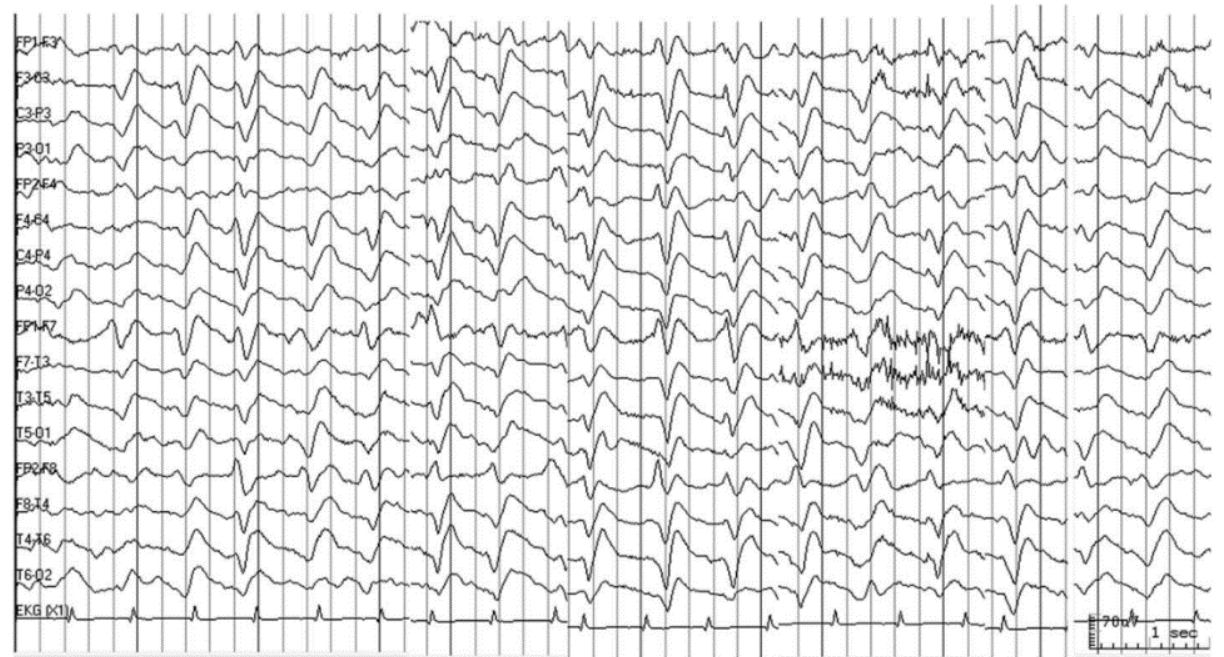

## Triphasic waves: clinical correlation

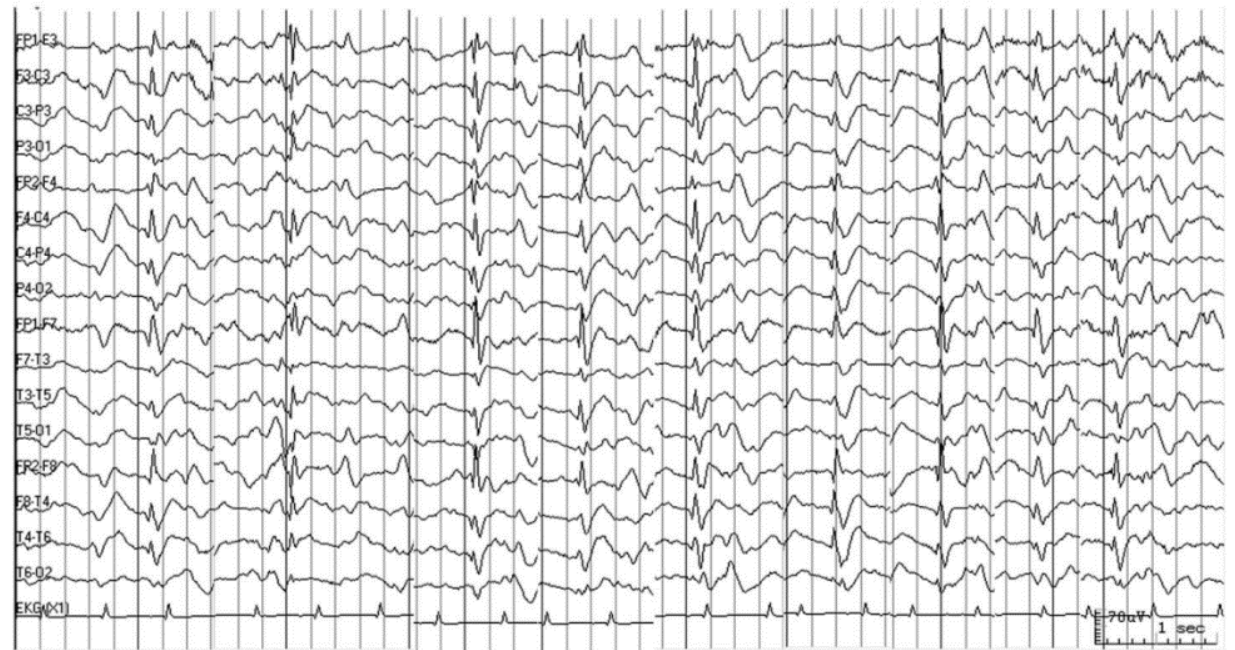
---

- Etiology: wide variety
  - Renal failure, hyponatremia, metabolic encephalopathy
  - Hepatic encephalopathy
  - Hypothyroidism
  - Encephalitis
  - Post-anoxic encephalopathy
  - Sepsis
  - Dementia: in rapidly progressive dementia → CJD
  - Drug intoxication
  - Structural lesion: subdural hematoma, stroke
- Correlate closely with severity of encephalopathy
  - Longer in duration and more widespread when patient became less responsive
  - Usually absent in alert or deeply comatose patient

Triphasic wave



GNCSE



## NCSE


- Response to benzodiazepine
- Higher frequency 2.4 Hz average
- Morphology
  - Shorter duration > 0.3 sec
  - Extra spike component
  - Maximum fronto-polar
  - First phase: absent
  - Second phase: sharply downgoing
  - Third phase: acutely rising, sharply descending, then return to baseline
- Less severe generalized BG slowing

## Triphasic wave

- Response to benzodiazepine
- Slower frequency 1.5-2.5 Hz
- Morphology
  - Longer duration < 0.3 sec
  - Prominent amplitude of phase 2
  - Maximum fronto-central
  - Phase lag
  - First phase: blunt upward spike
  - Second phase: blunted descent
  - Third phase: large amplitude, blunted ascend, gradually fall to baseline
- Increase with painful or auditory stimulation

Fast frequency pattern  
Abnormal beta activity  
Breach rhythm

---



## Generalized increased beta rhythm: causes


---

- Normal subjects, but persistence of increased beta activity throughout recording is abnormal
- Un-medicated children with chronic encephalopathy may have prominent beta especially when a/w dysgenetic lesion of the brain
- Barbiturates, benzodiazepines, sedative, tranquilizers
- Hyperthyroidism: central or wide distribution
- Acute and chronic anxiety

# 2 year-old boy with lissencephaly


## Continuous generalized moderate amplitude beta

---



# Generalized beta due to drugs

---



# Asymmetric beta activity

---

- Asymmetrical beta activity should be considered abnormal if persistent voltage difference of 35% or more
- Beta activity is attenuated by subdural, epidural or subgaleal fluid collections
- Barbiturates → bring out a beta asymmetry

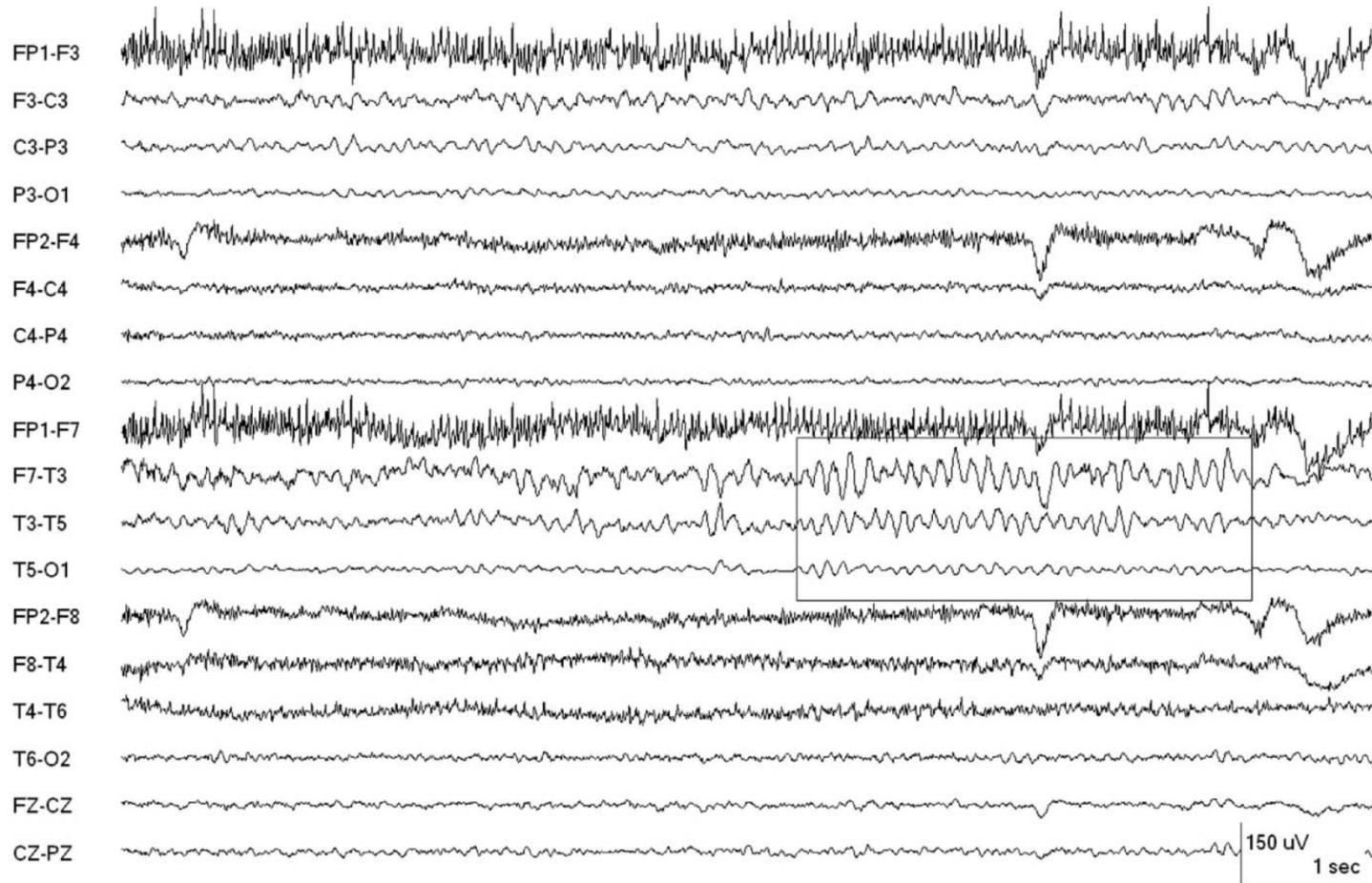


# Breach rhythm

---

- Consequence of intracranial surgery requiring craniotomy or burr hole, less often from skull fracture
- Attenuate high frequency filter function of the skull
- Enhanced voltage of fast frequency on the side of the defect
- Sharply contoured morphology

# Breach rhythm



# Patterns in coma

---



# Patterns in coma

---

- Alpha coma
- Theta coma
- Beta coma
- Spindle coma

# Alpha, theta, beta coma

---

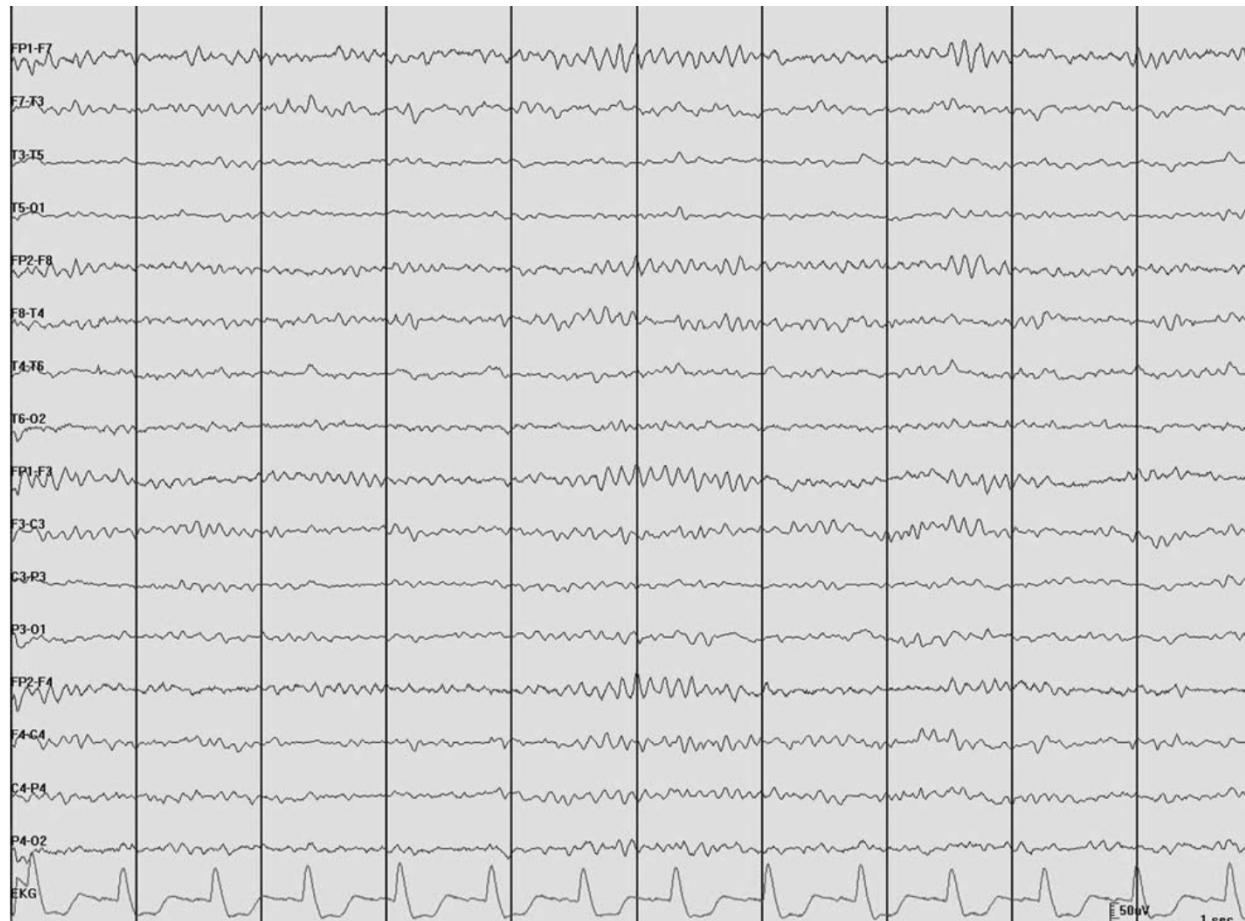- Patterns of rhythmical waves which have theta, alpha, beta frequency but occurs in isolation without other accompanying waves form in comatose patients
- No spontaneous variability or reactivity to sensory stimulation

# Alpha coma

---

- Generalized or predominantly frontal alpha activity, 8-12 Hz, unreactive to stimuli in comatose patient
  - Widespread cerebral damage, HIE, prolonged hypoglycemia, bilateral destruction of thalamic nuclei
- Posterior dominant alpha coma shows no reaction or variable attenuation or increase in amplitude following alerting maneuvers
  - Brainstem lesion, pontine infarction
- Imply very poor prognosis

# Alpha coma



# Theta coma

---

- Generalized monorhythmic activity in theta frequency range
- Little or no spontaneous variability or reactivity to noxious stimuli
- Theta coma or mixed alpha-theta coma are not as reliable to predict a poor outcome as absence of reactivity and spontaneous variability




# Beta coma

---

- Generalized, sometimes frontal dominant, pattern of mainly rhythmic beta waveforms
- Barbiturate or benzodiazepine intoxication
- Usually indicate likelihood of recovery from coma

# Spindle coma

---

- Sleep spindles in unconscious or comatose patients
  - Sleep spindle in 9-14 Hz diffuse distribution, often with vertex and K complex
  - No cycles of wakefulness and sleep
  - Preservation of intact pontine raphe nucleus and thalamocortical circuits, impairment of ARAS at midbrain level that maintains consciousness
  - Indicate better prognosis in coma patient than its absence
- 

# Amplitude asymmetry

---



# Amplitude asymmetry

---

- Characterized by differences in amplitude from two sides of the head
- Should be evaluated on referential montage
- Considered abnormal
  - Consistent asymmetry of beta > 35%
  - Consistent asymmetry of alpha > 50%
- Causes of asymmetry
  - Unilateral lesion
  - Change in conducting medium between cortex and recording electrode (SDH, skull defect, local scalp edema)

# Clinical significance of asymmetry

---

- Normal asymmetry
  - Asymmetry of photic driving, POSTs, mu rhythm in the absence of other abnormalities
- Abnormal asymmetry
  - Usually due to decrease of amplitude on the side of cerebral abnormality

# Abnormal amplitude asymmetry

---

- Asymmetry of all background activity
- Decrease amplitude of all type of activities
  - Reduction of cortical EEG production
    - Long lasting: Structural lesion
    - Transient: focal seizure, TIA, migraine
  - Increased of all media separating cortex from recording electrodes
- Increased amplitude of all type of activities: local skull defect

# Focal attenuation

---



# Focal attenuation

---

- Focal cortical lesion, tumor, cerebral ischemia
- Reversible cortical dysfunction (e.g. post ictal)
- Collection between cortex and recording electrode: swelling of scalp, subdural collection



Generalized change of amplitude

---



# Patterns of generalized change of amplitude

---

- Bilateral symmetrical decrease or increase of amplitude of all types of normal frequency
- Abnormal low amplitude
  - Cerebral activity < 20 microvolts during relaxed wakefulness with eye closed
  - Low amplitude must be sustained
  - Attenuation, suppression, burst suppression
- Abnormal high amplitude
  - Not well defined, > 200 microvolts
  - Amplitude > 100 microvolts is uncommon in wakeful adults, only considered abnormal on basis of frequency, morphology, or distribution rather than amplitude alone

# Clinical significant

---

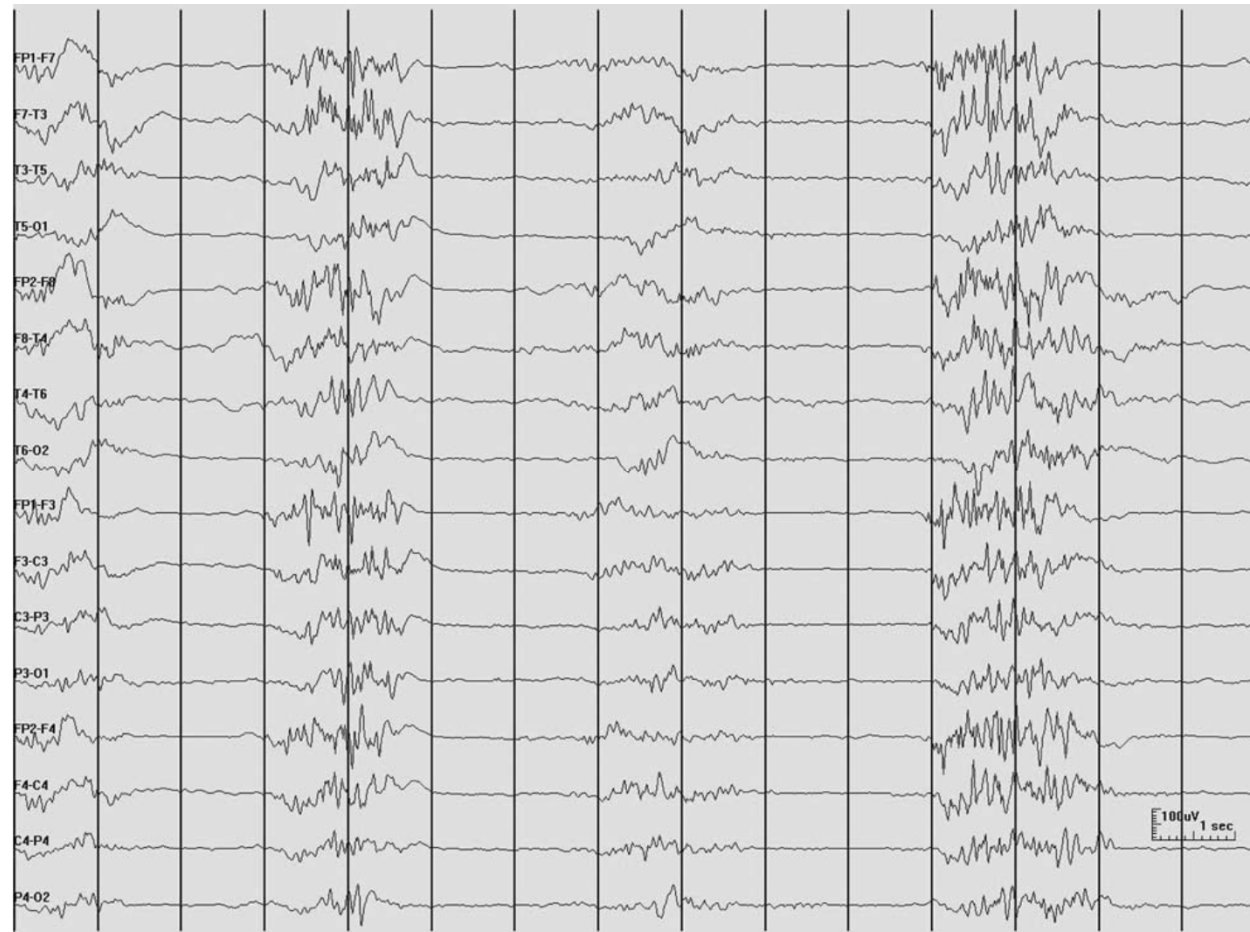
- Normal high amplitude occurs in waking record of children and deep stage of sleep at any age
- Normal low amplitude < 20 microvolts occurs transiently as a result of eye opening, mental effort, anxiety, alerting or drowsiness
- Abnormal low amplitude of all activity
  - Low amplitude in normal subjects can be seen in about 5-10% of adults but is not acceptable as normal in younger persons
  - Moderate or marked reduction if overall amplitude <10 microvolts → abnormal at any age
  - Transients and due to acute anoxic, toxic and metabolic, head injury, postictal
  - Permanent: lasting damage or from other disease significant involve cortex

# Burst suppression

---

- Presence of brain activity bursts of variable amplitude, duration and form, usually with sharp and spike waves lasted at least 0.5 sec, followed by marked depression of activity, occur on cyclical basis
- Severe cerebral damage in post anoxic encephalopathy
- Effect of anesthetic drug or drug induced coma

# Burst suppression



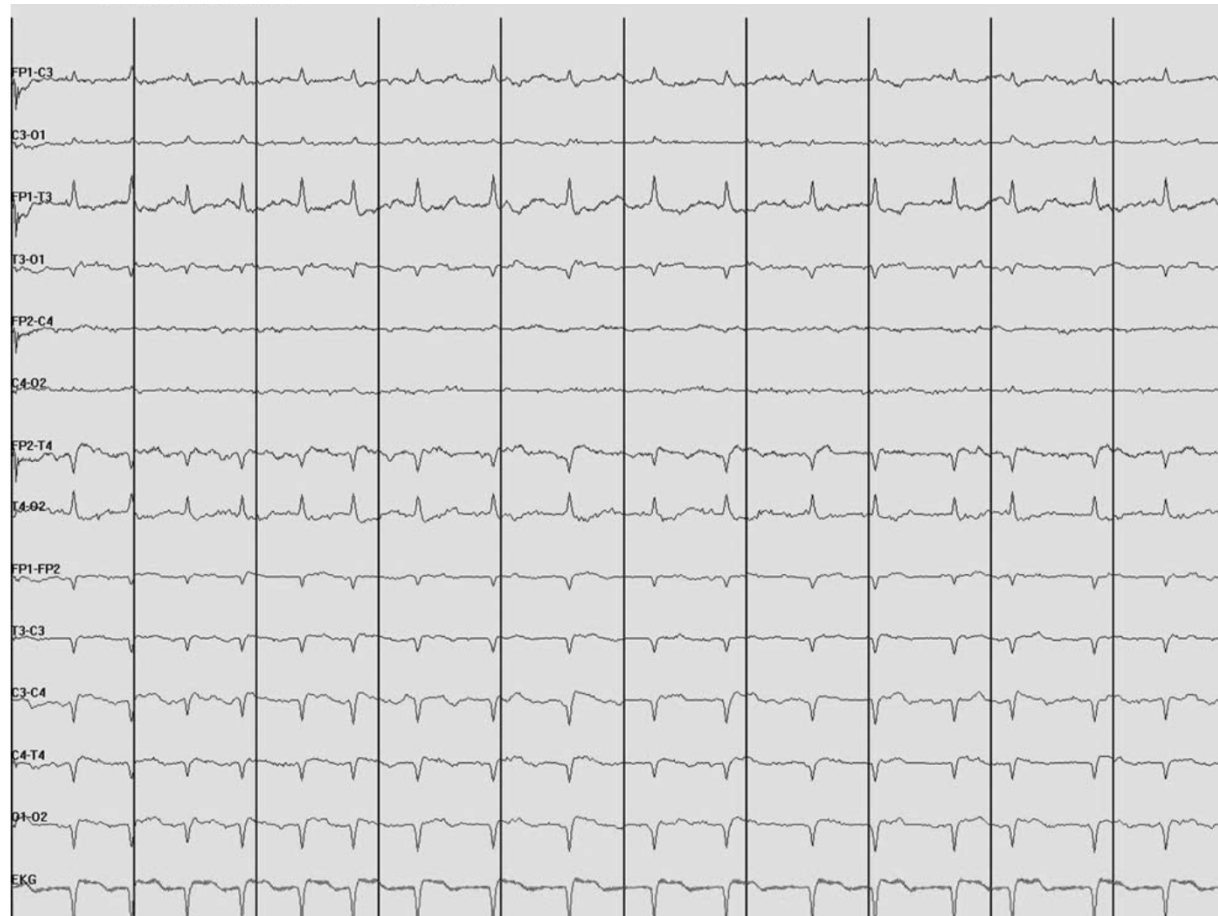# Electro-cerebral inactivity

---

- Isoelectric, nonreactive EEG, flat EEG or electro-cerebral silence
- Expression of severe and widespread cerebral dysfunction in which EEG activity is undetectable (**amplitudes of  $< 2 \mu\text{V}$** )
- Conventional scalp electrodes placed at double routine international 10-20 electrode distances
- Body core temperature above 34 degrees centigrade
- At least 30 minutes of continuous recording

# Electrocerebral activity

---



# Abnormal alpha rhythms

---





# Posterior/alpha rhythm

---

- Normal attenuation of alpha rhythm occurs with eye opening, alerting, mental effort, anxiety, decreased alerting to level of drowsiness
- **Abnormal frequency of alpha rhythm**
- **Voltage asymmetry >50% in amplitude**
  - Rarely an indication of focal abnormality
  - Skull defect result in higher voltage alpha rhythm
- Symmetry of **frequency and reactivity** are abnormal and reliably indicate the side of lesion

# Abnormal frequency of alpha rhythm

---

- Unilateral decrease in alpha frequency is abnormal
  - Abnormal <8-8.5 Hz
  - Mild asymmetry (consistent asymmetry in frequency of 0.5 - 1 Hz)
  - Marked asymmetry (>1 Hz frequency asymmetry)
- Bilateral decrease of alpha frequency
  - Generalized disturbance of cerebral function
  - Bilateral structural damage to occipital cortex or its thalamic input
- Unilateral decrease of alpha frequency
  - Unilateral disturbance of function of occipital cortex or its thalamic input
  - Unilateral structural damage to occipital cortex or its thalamic input
- Bilateral increase of alpha frequency
  - Metabolic disorder: fever, hyperthyroid

# Abnormal reactivity of alpha rhythm

---

- Unilateral failure of alpha blocking (attenuation with eye opening): Bancaud's phenomenon
  - Posterior subcortical lesion
  - Parietal or temporal lesions
- Bilateral failure of alpha blocking in monocular input
  - Disorder of one eye or optic nerve
- Absence of alpha rhythm, presence of occipital spikes
  - Long standing diseases of both eyes or central visual pathway
- Alpha frequency coma
  - Central pontine lesion
  - Widespread cerebral damage

# Abnormal alpha rhythm

---

- Focal cerebral lesion can alter alpha rhythm even though they do not involve occipital lobe or adjacent brain regions
  - Unilateral slowing of frequency
  - Loss of reactivity
  - Loss of modulation
  - Voltage attenuation

# Asymmetry response to photic stimulation

---

- May result from lesions on the side of lower voltage
- Can consistently lateralized in some normal individual
- Should not be interpreted as abnormal in the absence of corroborative findings such as focal slow or localized attenuation of background rhythms on the same side
- Rarely epileptogenic lesions result in responses to photic stimulation that are of higher voltage on the side of lesion

# Abnormal sleep potential

---



# Abnormal sleep potentials

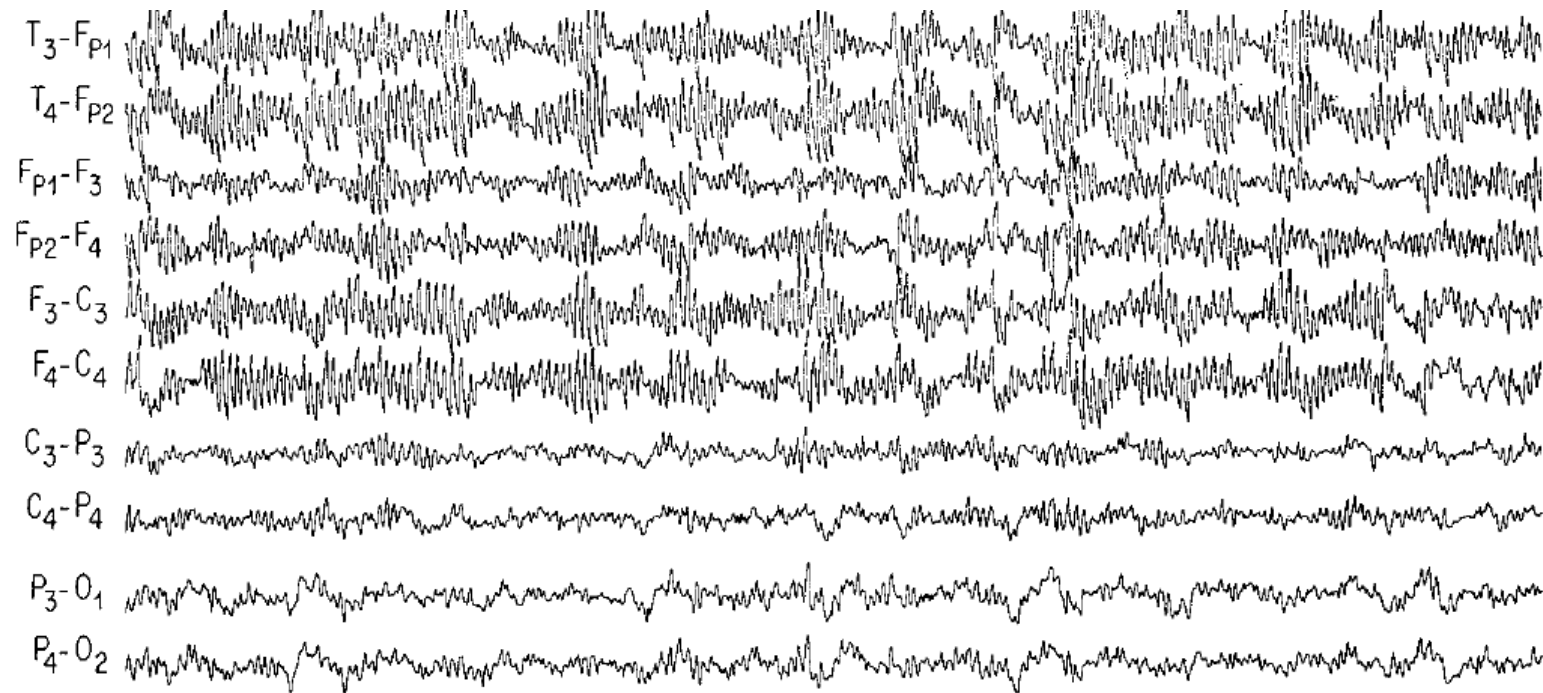
---

- Normal sleep patterns, sleep spindle and vertex can be affected by cerebral lesion
- Decrease potential, spindles, especially if involved cortex or thalamus
  - Lesion of parietal lobe or thalamus can attenuate sleep spindles
  - Thalamic lesion can result in interhemispheric asynchrony of spindles, affect regulation spindle frequency
- Skull defects enhance scalp-recorded voltage of sleep spindles and vertex

# Extreme spindles

---

- Wide spread and persistent than normal spindles
- Diffuse encephalopathy of childhood



6 y/o with MR and seizure, persistent high voltage spindle activity during sleep