



FIRST REPORT OF *LINOGNATHUS AFRICANUS* (PHTHIRAPTERA: ANOPLURA) ON GOATS IN BULGARIA

N. S. NIZAMOV & P. N. PRELEZOV

Department of Veterinary Microbiology, Infectious and Parasitic Diseases,
Faculty of Veterinary Medicine, Trakia University, Stara Zagora, Bulgaria

Summary

Nizamov, N. S. & P. N. Prelezov, 2020. First report of *Linognathus africanus* (Phthiraptera: Anoplura) on goats in Bulgaria. *Bulg. J. Vet. Med.* (online first).

The current study was conducted in 28 farms from 11 administrative districts in Bulgaria and included 4132 goats from six breeds, naturally infested with ectoparasitic insects. The visit to the farms was paid after the owners alarmed for signs of strong discomfort and itching among the animals. From the 28 studied herds, 14 (50%) turned out to be infested with the African sucking louse of goats: *Linognathus africanus* (Kellog & Paine, 1911) belonging to the family *Linognathidae*, suborder Anoplura, order Phthiraptera. All documented cases were of mixed infestation with other ectoparasitic species. The ectoparasites were collected and preserved in 70° ethanol for laboratory identification, morphological observation and for preparing photographic material. The full morphological description of the species showed that the total body length (TBL) of the male individuals varied between 0.912–1.556 mm, and that of the females: from 1.159 to 1.784 mm. A morphological identification of the phylogenetically close species *Linognathus africanus* (Kellog & Paine, 1911) and *Linognathus stenopsis* (Burmeister, 1838) was conducted in laboratory conditions. The population structure of the species was presented through the sex identification of *Linognathus africanus* which demonstrated a numerical ratio of F:M = 2.2:1.

Key words: Bulgaria, ectoparasites, first record, goats, lice, *Linognathus africanus*

INTRODUCTION

The infestation with lice is very common in goat (*Capra hircus*) herds around the world. The sucking lice (Phthiraptera: Anoplura) are permanent, strictly host specific ectoparasites in mammals. They cause economical losses from weight loss, skin damage, moderate to severe anaemia, hypoproteinaemia, insufficient absorption of food and reduced vitality (Otter *et al.*, 2003; Paul *et al.*, 2012). As vectors they

can transmit viruses, bacteria, fungi and protozoa like *Anaplasma ovis* and *Rickettsia spp.* (Hornok *et al.*, 2010). Poor hygiene and high density of the animals in the barn contribute to the spreading of the lice.

The *Linognathus africanus* species has been found in a few regions of the planet. Earlier reports showed its prevalence in Africa (Kellogg & Paine, 1911), Middle

East: Turkey (Topcu *et al.*, 2000) and Israel (Yeruham *et al.*, 1999), Mongolia (Tsedev *et al.*, 1975), China (Yi *et al.*, 2003), India (Mishra *et al.*, 1974), The Philippines (Tongson *et al.*, 1981) and Australia (O'Callaghan *et al.*, 1989). Mexico (Lozoya-Saldana *et al.*, 1986), Chile (Gonzalez-Acuna *et al.*, 2005) and Brazil (dos Santos *et al.*, 2006) are among American countries where the parasite was reported from. In the USA the species was spread in more than 8 states (Kim *et al.*, 1986). Infestation with *L. africanus* in goats has been reported in Europe as well: Spain (Portus *et al.*, 1977), Greece (Himonas & Liakos, 1989) and only recently in continental Italy (Calzolari *et al.*, 2006; 2013). In The Sardinies (Fois *et al.*, 2012) the species was found and described in goats from nine areas in four different provinces of the island.

The purpose of the present study was to detect the presence of the *L. africanus* species in Bulgaria, and to perform a complete morphological description with regard to its identification and distinction from the species *Linognathus stenopsis* (Burmeister, 1838).

MATERIALS AND METHODS

Animals

The current study included 4,132 goats belonging to six breeds (Bulgarian Dairy White, Boer, Alp, Anglo-Nubian, Toggenburg and a local breed) naturally infested with ectoparasitic insects. The herds were bred in 11 regions of the country. The visit to the farms was paid upon request from the owners who complained that the animals were scratching and suffered from discomfort. Twenty eight herds were examined. During the pasture season most of the herds shared pastures with cattle herds.

Examination

The goats were inspected with a magnifying glass for signs of skin disorders like alopecia, dandruff, crusts, nodules as well as eggs and adult ectoparasites. The found lice (preimaginal and imaginal stages) were collected individually with tweezers and were preserved in 70° ethanol. All the insects found were transported to the laboratory. For clearing and dehydration the insects were placed in a dish with xylene for 5 minutes after which they were fixed on slides with Canadian balm and were covered with coverslip. The species and sex differentiation was done by morphological features described by Blagoveshtchensky (1964) and Ferris & Stojanovich (1951). A DMi1 S/M 424790 Leica® microscope (Leica Microsystems CMS GmbH) equipped with a Leica MC120 HD camera was used for the microscopic exams and the photographic materials.

Seven morphological features of 100 male and 100 female individuals were measured following the biometric criteria guidelines of Perez-Jimenez *et al.* (1988). They included: head length (HL), head width (HW), thorax length (TL), thorax width (TW), abdomen length (AL), abdomen width (AW), total body length (TBL). The index of the head ($IH=HL/HL$) and index of the body ($IB=TBL/AW$) were calculated. Also, the last segment length (LSL), last segment width (LSW), their ratio e.g. the index of the last segment ($ILS=LSL/LSW$) as well as the ratio between the total body length to the body to head length (TBL/HL) were measured.

Statistical analysis

The data were presented as mean values \pm SEM, and comparisons were made using the t-test (STATISTICA 7 software). The significance level (P) was set at 0.05.

RESULTS

From all 28 examined herds, the goats in 14 (50%) were found to be infested with the African sucking louse of goats *L. africanus* (Kellog & Paine, 1911), Family *Linognathidae*, Suborder Anoplura of Order Phthiraptera (Fig. 1 and 2). A mixed infestation with *L. stenopsis* was found in all herds infested with *L. africanus*. The sex identification of *L. africanus* revealed the population structure of the species as F:M-2.2:1.



Fig. 1. *Linognathus africanus* (Kellog & Paine, 1911) – male (dorsal). Bar = 0.5 mm.



Fig. 2. *Linognathus africanus* (Kellog & Paine, 1911) – female (dorsal). Bar = 0.5 mm.

The structure of the last abdominal segment was an important morphological characteristics with taxonomical value, serving as a sign of sexual dimorphism. In the male individuals it was with a wide base, had a pair of terminal tubercles with two long setae on both sides of the

medial line (Fig. 3). In females it was rounded and had a vertical groove (Fig. 5).




Fig. 3. Male *Linognathus africanus* (Kellog & Paine, 1911) – last abdominal segment. Bar = 0.1 mm.

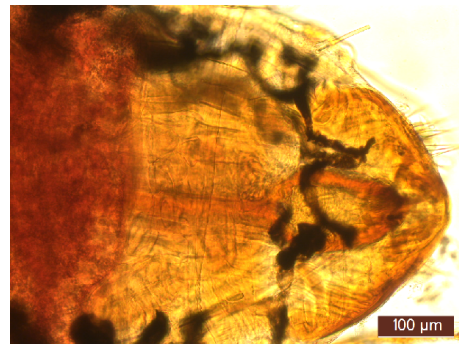


Fig. 4. Male *Linognathus stenopsis* (Burmeister, 1838) – last abdominal segment. Bar = 0.1 mm.

For easier comparison and distinction, pictures of the last abdominal segment of male (Fig. 4) and female (Fig. 6) specimens from the *L. stenopsis* are presented. The head shape (Fig. 7) is another key morphometric trait.

The values of biometric parameters for the *L. africanus* species are presented in Table 1. The total body length (TBL) in male individuals varied between 0.912-1.556 mm and in females – from 1.159 to 1.784 mm. The values showed that TBL

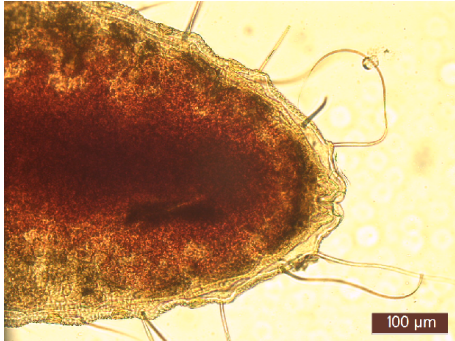


Fig. 5. Female *Linognathus africanus* (Kellog & Paine, 1911): last abdominal segment. Bar =0.1 mm.

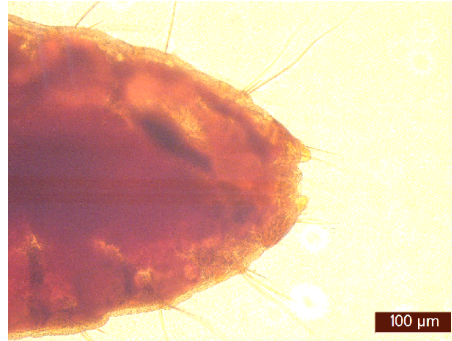

Fig. 6. Female *Linognathus stenopsis* (Burmeister, 1838): last abdominal segment. Bar=0.1 mm.



Fig. 7. *Linognathus africanus* (Kellog & Paine, 1911) showing prominent ocular processes on head. Bar =0.2 mm.

of females (1.498 ± 0.01 mm) was significantly higher than that of males (1.230 ± 0.02 mm; $P < 0.001$).

The ratio of TBL to HL exceeded 5, which defined the head of the species as relatively small. The average values of HW/TW in both sexes were around 0.7 ($P < 0.01$). The data for AW in Table 1 showed that the abdomen of males was statistically significantly narrower than that of females ($P < 0.001$). The last abdominal segment in males and females, differed both in shape, and in terms of metric parameters. The values of LSL, LSW and ILS demonstrated statistically significant differences between the male and female individuals ($P < 0.001$).

DISCUSSION

It is known that in sucking lice (Anoplura) the head is narrower than the prothorax. In the biting lice (Amblycera and Ischnocera) it is wider. The systematic position of *L. africanus* in the group of sucking lice emphasised on the ratio between head width (HW) and thorax width at the prothorax (TW). According to our data, the average HW/TW in both sexes was about 0.7. The metric parameters of the head show that in both sexes it is definitely longer than wider. The morphological differences between the *L. africanus* and *L. stenopsis* according to O'Callaghan *et al.* (1989) are in the shape of the head which in *L. africanus* is with

Table 1. Basic biometrical indicators of the species *Linognathus africanus* (Kellog & Paine, 1911)

Parameters	Male (n = 100)		Female (n = 100)	
	Min–max (mm)	Mean ± SEM (mm)	Min–max (mm)	Mean ± SEM (mm)
Total body length	0.912–1.556	1.230±0.02***	1.159–1.784	1.498±0.01
Head length	0.134–0.303	0.228±0.005***	0.187–0.334	0.269±0.001
Thorax length	0.140–0.314	0.218±0.004**	0.153–0.352	0.238±0.003
Abdomen length	1.077–0.120	0.772±0.01***	0.705–1.252	0.991±0.01
Head width	0.135–0.240	0.188±0.003***	0.166–0.236	0.207±0.001
Thorax width	0.172–0.340	0.246±0.004***	0.210–0.383	0.283±0.002
Abdomen width	0.308–0.562	0.427±0.008***	0.436–0.722	0.574±0.006
Index of the body	2.371–3.674	2.909±0.03***	2.30–3.02	2.61±0.01
Index of the head	0.735–1.520	1.214±0.02***	0.90–1.5	1.30±0.01
Total body length/head length	4.052–7.959	5.485±0.10	4.28–7.84	5.58±0.06
Head width/thorax length	0.588–0.960	0.772±0.01**	0.60–0.97	0.73±0.006
Last segment length	0.029–0.140	0.081±0.003***	0.066–0.157	0.098±0.001
Last segment width	0.100–0.260	0.185±0.005***	0.197–0.364	0.272±0.003
Index of the last segment	0.206–0.664	0.436±0.01***	0.264–0.578	0.365±0.005

IB – index of the body (IB=total body length/abdomen width); IH – index of the head (IH=head length/head width); ILS – index of the last segment (ILS= last segment length / last segment width); *** - $p < 0.001$; ** - $p < 0.01$; * $P < 0.05$; ** $P < 0.01$; *** $P < 0.001$ between both sexes.

prominent eye bulges located behind the antennae, while in *L. stenopsis* the head is elongated (Fig. 7).

Our data for TBL (1.498 ± 0.01 mm for females and 1.230 ± 0.02 for male *L. africanus* specimens) are lower, compared to those presented by Blagoveshtchensky (1964) 1.5–1.6 mm for males and 1.8–2.3 mm for females and they varied within a broader range. We assume that the possible reason is the difference in the climate and the geographical conditions in our country compared to the African continent where the species originated from.

Concerning the population structure of *L. africanus*, our results showed a ratio of 1.0:2.2 between males and females. Santos *et al.* (2006) reported that this ratio

was 1.0:4.6. Other authors like Rashmi *et al.* (2017) examined about 1000 goats in Rampur and also discovered that in the natural populations the female *L. africanus* individuals were more numerous than the males without reporting a specific ratio and on the other side, the nymphs were more numerous than the adults.

The morphology of both Anopluran lice species infesting goats (*L. stenopsis* and *L. africanus*) is pretty similar. The differences consisted in the shape of the head and the morphology of last abdominal segment (Fig. 3 and 4) (Ferris & Stojanovich, 1951). The female gonopods of *L. africanus* are rounded and without a “tooth like” appendix which has been described in *L. stenopsis* (Fig. 6) (Kim *et al.*,

1986). In male *L. africanus*, the gonopods have a pair of terminal tubercles with setae (Fig. 3) (Price & Graham, 1997). It is possible that the species has emerged recently in our country because of the import of all kinds of animals in the country during the recent years, including goats.

In a study on the phthirapterids of ruminants, Nedelchev (1985) discovered two species of Phthiraptera on goats: *L. stenopsis* and *Bovicola caprae*. The absence of *L. africanus* at that time suggested that the species may have been introduced later in Bulgaria.

CONCLUSION

The current study confirmed that the infestation with lice from the *L. africanus* species in goats is widely spread in our country. The full morphological description will make the recognition of the species easier and will eliminate the possibility of mistakes.

The detection of the species is essential for veterinary specialists and goat farmers, as it could be associated with the transfer of new vector-borne diseases on goats from countries with warmer climate.

REFERENCES

- Blagoveshtchensky, D. I., 1964. Mallophaga – chewing lice. In: Manual of Insects in the European part of the USSR. Vol. 1. Collembola, Palaeoptera, with hemimetabolous metamorphosis. Nauka, Moscow-Leningrad, pp. 309–323 (RU).
- Calzolari, M., P. D’Altri, L. Calisesi, F. Giombetti, M. Dottori & G. Vecchi, 2006 – Prima segnalazione in Italia del pidocchio *Linognathus africanus* Kellogg & Paine, 1911. *Atti XVII Congresso SIPAOC*, **17**, 142.
- Calzolari, M., M. Dottori, F. Fois & P. Mereu Piras, 2013. Segnalazioni Faunistiche Italiane. *Linognathus africanus* Kellogg and Paine, 1911 (Phthiraptera Anoplura). *Quaderno di Studi e Notizie di Storia Naturale della Romagna*, **39**, 133–139.
- Durden, L. A., T. M., Kollars, S. Patton & R. R. Gerhardt, 1997. Sucking lice (Anoplura) of mammals of Tennessee. *Journal of Vector Ecology*, **22**, 71–76.
- Ferris, G. F. & C. J. Stojanovich, 1951. The Suckling Lice, Pacific Coast Entomological Society Memorandum.
- Fois, F., P. Mereu Piras, C. Pilo, C. Cozzolino, M. Calzolari, P. A. Cabras & M. Liciardi, 2012. Segnalazioni Faunistiche Italiane 555 *Linognathus africanus* Kellogg & Paine, 1911 (Phthiraptera Anoplura). *Bollettino della Società Entomologica Italiana*, **144**, 138.
- Gonzalez-Acuna D., D. Castro, E. Mey & L. Moreno-Salas, 2005. New records of Phthiraptera in domestic mammals in Chile. *Archivos de Medicina Veterinaria*, **37**, 77–78.
- Himonas, C. A. & V. D. Liakos, 1989. Field trial of cypermethrin against lice infestation in goats. *The Veterinary Record*, **125**, 420–421.
- Hornok, S., R. Hofmann-Lehmann, I.G. Fernandez de Mera, M. L. Meli, V. Elek, I. Hajtos, A. Repasi, E. Gönczi, B. Tanczos, R. Farkas, H. Lutz & J. De La Fuente, 2010. Survey on blood-sucking lice (Phthiraptera: Anoplura) of ruminants and pigs with molecular detection of *Anaplasma* and *Rickettsia* spp. *Veterinary Parasitology*, **174**, 355–358.
- Kellogg V. L. & J. H. Paine, 1911. Anoplura and Mallophaga from African hosts. *Bulletin of Entomological Research*, **2**, 145–152.
- Kim, K. C., H. D. Pratt & C. J. Stojanovich, 1986. The sucking Lice of North America. An Illustrated Manual for Identification. Pennsylvania State University Press, University Park.
- Lozoya-Saldana, A., S. Quinones-Luna, L. A. Aguirre-Uribe & E. Guerrero-Rodriguez, 1987. Distribution and abundance of the

- mallophagan and anopluran lice of sheep and goats in the region of Saltillo, Coahuila, Mexico. *Folia Entomologica Mexicana*, **69**, 117–125.
- Mishra, A. C., H. R. Bhat & S. M. Kulkarni, 1974. A survey of haematophagous arthropods in western Himalayas, Sikkim and hill districts of West Bengal – Anoplura. *Indian Journal of Medical Research*, **62**, 1268–1287.
- Nedelchev, N. K., 1985. A study on the phthirapterosis of domestic ruminants. PhD Thesis, Sofia (BG).
- O’Callaghan, M. G., I. Beveridge, M. A. Barton & D. R. McEwan, 1989. Recognition of the sucking louse *Linognathus africanus* on goats. *Australian Veterinary Journal*, **66**, 228–229.
- Otter, A., D. F. Twomey, T. R. Crawshaw & P. Bates, 2003. Anaemia and mortality in calves infested with the long-nosed sucking louse (*Linognathus vituli*). *The Veterinary Record*, **153**, 176–179.
- Paul, A., M. Tanjim, S. Akter, M. Rahman & M. Talukder, 2012. Prevalence of ectoparasites in black Bengal goat at the gaidbandha district of Bangladesh. *Bangladesh Journal of Progressive Science and Technology*, **10**, 005–008.
- Pérez-Jiménez, J. M., M. D. Soler-Cruz, R. Benítez-Rodríguez, M. Díaz-López & I. Ruiz-Martínez, 1988. Mallophaga of *Buteo b. buteo* in Southern Spain. *Angewandte Parasitologie*, **29**, 189–200.
- Portus, M., J. Gallego & J. Aguirre, 1977. On Anoplura parasitising domestic and wild Spanish mammals. *Revista Iberica de Parasitologia*, **37**, 345–354.
- Rashmi, A. & A. K. Saxena, 2017. Population levels of phthirapteran ectoparasites on the goats in Rampur (U.P.). *Journal of Parasitic Diseases*, **41**, 778–781.
- Santos, S. B., P. H. Cancado, E. M. Piranda & J. L. Faccini, 2006. Infestation for *Linognathus africanus* (Kellogg e Paine, 1911) (Linognathidae) and *Bovicola caprae* (Ewing, 1936) (Trichodectidae) in goat flock of the State of Rio de Janeiro, Brazil. *Revista Brasileira de Parasitologia Veterinária*, **15**, 41–43.
- Tongson, M. S., M. F. Manuel & S. L. Eduardo, 1981. Parasitic fauna of goats in the Philippines. *Philippine Journal of Veterinary Medicine*, **20**, 1–37.
- Topcu, A., 2000. Lice (Phthiraptera) species in sheep of Nigde region. *Ankara Universitesi Veteriner Fakultesi Dergisi*, **47**, 197–200.
- Tsedev, B. & R. V. Grebenyuk, 1977. Ectoparasites of sheep and goats and certain feral animals of Mongolia. *Entomological investigations in Kirgizia*, **10**, 126–127.
- Yeruham, I., S. Rosen, A. Hadani & Y. Braverman, 1999. Arthropod parasites of Nubian ibexes (*Capra ibex nubiana*) and gazelles (*Gazella gazella*) in Israel. *Veterinary Parasitology*, **83**, 167–173.
- Yi, Z., C. Hongjian, J. XiZheng, N. Gang & W. YouWen, 2003. The first report a list of sucking lice (Anoplura) in Qinghai Province. *Entomotaxonomia*, **25**, 292–294.

Paper received 24.10.2019; accepted for publication 12.12.2019

Correspondence:

Nikola Nizamov DVM
Department of Veterinary Microbiology,
Infectious and Parasitic Diseases,
Faculty of Veterinary Medicine,
Trakia University,
6015 Stara Zagora, Bulgaria,
email: nikola_nizamov@abv.bg