



Clinical Management of Mast Cell Tumors in Dogs

Tracy Gieger, DVM, DACVIM
Nicole Northrup, DVM, DACVIM
Michelle Wall, DVM, DACVIM
The University of Georgia

ABSTRACT:

Mast cell tumors are one of the most commonly encountered neoplasms in veterinary medicine. They vary in appearance, location, and biologic behavior. The biologic behavior of canine mast cell tumors is best predicted by evaluating factors such as histologic grade, stage of disease, location, and proliferative markers. Treatment options include surgery, radiation therapy, chemotherapy, or combinations of these modalities. Recent studies suggest that some dogs with advanced mast cell disease can experience long-term survival with aggressive therapy. This article reviews the clinical presentation, diagnosis, grading, staging, prognostic indicators, and current treatment recommendations for mast cell tumors in dogs.

Mast cell tumors are one of the most commonly encountered neoplasms in veterinary medicine. This article reviews the clinical presentation, diagnosis, grading, staging, prognostic indicators, and current treatment recommendations for mast cell tumors in dogs.

MAST CELLS

Mast cells are the major effector cells of acute hypersensitivity reactions and allergic disease.¹ They originate in bone marrow and migrate to peripheral tissues, where they mature. They are not normally found in the circulation but are concentrated in lymphoid organs and highly vascularized tissues such as the lungs, liver, skin, and gastrointestinal (GI) tract. Mast cells constitutively express receptors for IgE, which is bound to the cell surface.

When IgE is bound by antigens, the receptors crosslink and mast cells are activated. This results in release of pre-

formed cytoplasmic granules (i.e., degranulation) as well as synthesis and secretion of prostaglandins, leukotrienes, and cytokines (e.g., tumor necrosis factor- α , interleukins). Mast cell granules contain histamine, heparin, and proteases. Histamine is a vasoactive protein that results in vasodilation, vascular leakage, and constriction of smooth muscle in the intestine and bronchi. Clinically, histamine release can result in localized swelling, pruritus, and erythema; hypotension during surgery or vigorous palpation of mast cell tumors; and GI ulceration resulting from histamine-stimulated gastric acid release from parietal cells. Coagulopathies and bruising secondary to heparin release and delayed wound healing due to the presence of proteolytic enzymes may also occur as sequelae of mast cell degranulation.¹

CLINICAL PRESENTATION

Mast cell tumors are the most common cutaneous tumors in dogs, accounting for 7% to 21% of all skin tumors.² Mast cell tumors have

Send comments/questions via email
compendium@medimedia.com,
fax 800-556-3288, or web
CompendiumVet.com

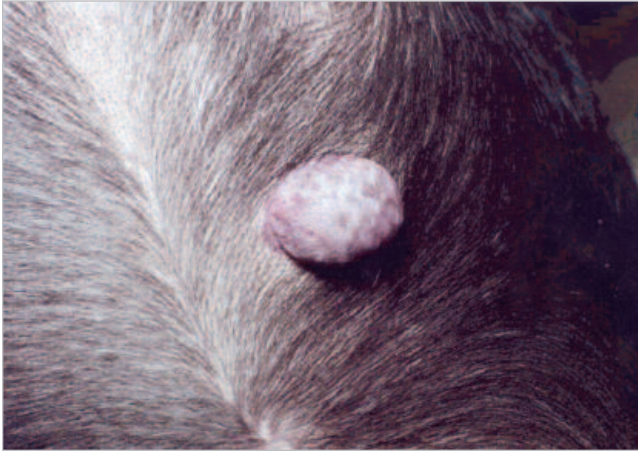


Figure 1. Mast cell tumor on the ventral abdomen of a Boston terrier.

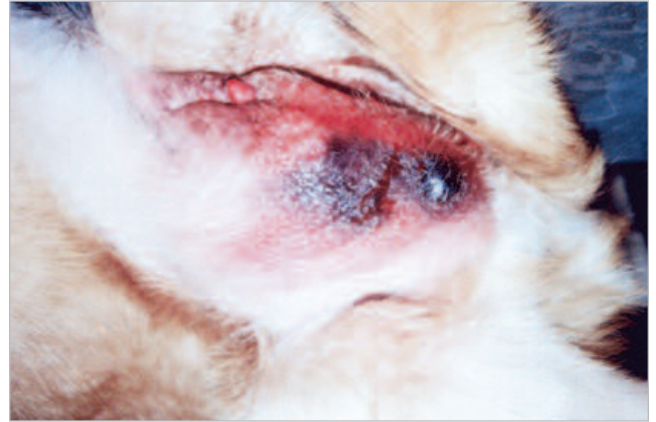


Figure 2. Preputial mast cell tumor. Note the peritumoral edema, bruising, and erythema related to histamine and heparin in the mast cell granules (Darier's sign).

been reported in dogs of all ages and breeds, although boxers, Labrador and golden retrievers, shar-peis, and terriers (especially Boston terriers) are overrepresented.³⁻⁸ Reports indicate that boxers with mast cell tumors might have a better prognosis because they have a higher incidence of well-differentiated tumors⁶ and shar-peis have a worse prognosis because they develop more aggressive tumors at a younger age than do other breeds.³ There is no apparent sex predisposition.

Mast cell tumors vary greatly in appearance, location, biologic behavior, and treatment response. Most mast cell

tumors, peritumoral edema, bruising, and erythema often occur (i.e., Darier's sign; Figure 2). If a skin or subcutaneous tumor is thought to be a mast cell tumor based on its clinical appearance, administering diphenhydramine (1 to 2 mg/kg SC) 30 to 60 minutes before aspirating the mass may minimize further mast cell degranulation after aspiration. The cause of mast cell tumors remains largely unknown, although some researchers believe that chronic skin irritation or viruses can lead to tumor formation.⁷

Approximately 10% of dogs have multiple cutaneous mast cell tumors at diagnosis or develop additional mast

Mast cell tumors have a variable appearance that may include intermittent shrinking and swelling of the tumor, peritumoral erythema, edema, and bruising related to the presence of histamine and heparin within mast cell granules.

tumors originate in the skin and subcutaneous tissue, but tumors arising primarily from other sites have been reported. Most patients are evaluated for a skin mass and are asymptomatic. Mast cell tumors most often appear as raised alopecic masses (Figure 1). Because some mast cell tumors may look and feel more like lipomas, obtaining aspirates of all skin and subcutaneous masses is recommended so that a diagnosis of mast cell tumor is not missed. Some mast cell tumors have a history of shrinking and swelling related to intermittent mast cell degranulation with histamine release. In large, poorly differentiated

cell tumors after therapy.⁹ This form of mast cell disease presents a challenge to practitioners because repeated surgical excision is not feasible in all cases and metastasis occurs in some dogs. Clients must be educated that future skin masses should be addressed as soon as possible in dogs with mast cell tumors.

DIAGNOSIS AND GRADING

In most cases, the diagnosis of mast cell tumors is based on visualizing small to medium round cells with cytoplasmic metachromatic granules via cytology. Tolui-

Table 1. The Patnaik Grading System for Canine Cutaneous Mast Cell Tumors¹⁰

Patnaik System Grade	Microscopic Description
III (High; anaplastic, undifferentiated)	Highly pleomorphic cells Binucleated cells are common Frequent mitosis Low number of cytoplasmic granules Tumor has replaced subcutaneous tissues Edema, hemorrhage, and necrosis are common in and around tumor
II (Intermediate)	Moderately pleomorphic cells Mitotic figures are infrequent Tumors in dermal and subcutaneous tissues Tumors extended to skeletal muscle or surrounding tissues Edema is present in some tissues
I (Low; well-differentiated)	Round nuclei with condensed chromatin Mitotic figures are absent Large, well-staining cytoplasmic granules Tumors are confined to the dermis

dine blue stain may be needed to identify granules in some poorly differentiated tumors in which granules may not be cytologically or histologically evident.

Although multiple grading systems for mast cell tumors exist, the Patnaik system is currently the most widely used.¹⁰ This system of histologic grading was developed to assist clinicians in determining the outcome of dogs with cutaneous mast cell tumors. Mast cell tumor grading is based on a histologic classification scheme and cannot be determined via cytology. The Patnaik grading system divides mast cell tumors into three categories based on their histologic appearance and invasiveness (Table 1)¹⁰:

- **Grade I**—Well-differentiated tumors
- **Grade II**—Intermediately differentiated tumors
- **Grade III**—Poorly differentiated tumors

After these tumors were categorized based on histologic appearance, clinical follow-up information was obtained to determine whether grade affected prognosis. The percentages of dogs surviving 1,500 days after diagnosis were 83%, 44%, and 6% for grades I, II, and III tumors, respectively. In another published study evaluating this grading system, the percentages of dogs that died as a result of incurable tumors were 9%, 29%, and 58% for grades I, II, and III tumors, respectively.¹¹ Although this grading sys-

tem has been well studied and shown to be the most consistent prognostic indicator of disease-free interval, metastasis, and survival time in dogs with mast cell tumors,^{5,6,10-14} interpathologist variation can occur.¹⁵ In a recent unpublished study, 10 pathologists at the same institution were independently asked to grade 60 canine cutaneous mast cell tumors.¹⁵ These pathologists agreed on the same grade for only four tumors, and six of 60 tumors were assigned three different grades. In individual patients, the tumor grade should be evaluated with other clinical findings, such as the size and invasiveness of the tumor, presence of local and distant metastasis, tumor location, and other findings (see Staging).

STAGING

The clinical stage is a determination of the degree of local and systemic involvement (metastasis) of a tumor. The World Health Organization (WHO) has determined clinical staging systems for many canine tumors, including mast cell tumors (Table 2).¹⁶ For mast cell tumors, occurrence of metastasis increases with tumor grade. Well-differentiated (i.e., Patnaik grade I) tumors have a low metastatic rate (<5%).^{7,17} Intermediately differentiated (i.e., Patnaik grade II) tumors and poorly differentiated (i.e., Patnaik grade III) tumors have metastatic rates of 12% and 55%, respectively, 1 year following radiation therapy.¹² Metastatic rates for dogs

with grade II mast cell tumors treated with surgery alone were 5% and 22% in two different studies.^{9,18}

Mast cell tumors generally metastasize to regional lymph nodes first, followed by the spleen, liver, mesenteric lymph nodes, other cutaneous sites, and bone marrow.^{5,7,17} The lungs are a rare site for metastasis, although in some cases of advanced metastatic mast cell tumors, pleural and/or peritoneal effusion can occur. Before surgical excision, routine blood work (i.e., complete blood count, biochemical profile) and a urinalysis should be conducted and regional lymph node aspiration performed. Aspiration should be performed regardless of lymph node size because a recent study documented that of 11 dogs with cytologically confirmed regional lymph node metastasis, only seven had palpably enlarged lymph nodes.⁵

Additional systemic staging for mast cell tumor metastasis should be considered before surgery in patients that have evidence of regional lymph node metastasis if tumors are highly infiltrative or nonresectable, peritumoral edema or bruising is present, or tumors are recurrent or are present in unfavorable locations. After surgery, systemic staging should be conducted in patients with poorly differentiated tumors and those with incompletely excised tumors before radiation therapy is initiated. Further staging should include thoracic radiography (to screen patients for concurrent diseases before aggressive therapy for mast cell tumors), abdominal radiography, ultrasonography (to examine echotexture of the spleen and liver and look for nodal metastasis), a buffy coat smear (to detect circulating mast cells), and bone marrow aspiration (to detect increased numbers of mast cells in marrow).^{5,7,17} Obtaining aspirates of the liver and spleen is indicated if these organs appear ultrasonographically abnormal. Although mast cells can normally be found in the spleen and liver, large numbers of mast cells or poorly granulated mast cells in these organs likely indicate metastasis. Computed tomography or magnetic resonance imaging may be indicated for treatment planning of large tumors or body wall mast cell tumors.

The WHO staging scheme for canine mast cell tumors has been evaluated, and its influence on survival time is inconsistent.^{5,12} Regional and distant metastases should be determined with caution because of lack of a standardized definition of metastasis. For example, in dogs with mast cell tumors, uncertainty exists on how to differentiate true nodal metastasis versus migration of nonneoplastic mast cells through the node secondary to chemotactic factors and drainage of the tumor. Lymph node biopsy may be more likely than fine-needle aspira-

Table 2. World Health Organization Clinical Staging System for Mast Cell Tumors in Dogs¹⁶

Stage ^a	Description
0	Incompletely excised solitary tumors without regional node involvement
1	Solitary tumors confined to the dermis and without regional lymph node involvement
2	Solitary tumors confined to the dermis and with regional lymph node involvement
3	Multiple dermal tumors or large infiltrating tumors with or without regional lymph node involvement
4	Tumors with distant metastasis

^aSubstage a: no clinical signs are present; substage b: clinical signs are present.

tion to confirm true metastasis versus “draining” mast cells, but this procedure adds morbidity and cost to staging procedures. Interpreting positive buffy coat smears is also challenging. Mast cells in a buffy coat smear are not specific for mast cell disease and may be seen in many other systemic inflammatory conditions, such as pancreatitis, parvovirus, and heartworm disease.¹⁷ It has been documented that dogs with buffy coat smears positive for mast cells can survive long-term and that dogs with disseminated mast cell tumors can have buffy coat smears negative for mast cells.⁵ Buffy coat smears can provide evidence to support systemic mastocytosis in dogs with mast cell tumors and clinical signs related to mast cell disease (e.g., GI bleeding, peritumoral edema), but this test should be regarded as non-specific and insensitive.¹⁹ Despite the limited usefulness of systemic staging tests in many cases, these tests are still recommended in the types of patients already mentioned until further studies clarify the usefulness of staging tests in large numbers of patients.

PROGNOSTIC INDICATORS

Many prognostic factors have been evaluated for canine cutaneous mast cell tumors. Histologic grade is the most consistent prognostic indicator of survival, metastasis, and disease-free interval.^{5,7,8,12,17} Tumor location affects the outcome of dogs with mast cell tumors in some studies, although this finding has not been consistent.^{5,8,12,20,21} Patients with mast cell tumors of the oral cavity and muzzle, inguinal areas, and digits are thought

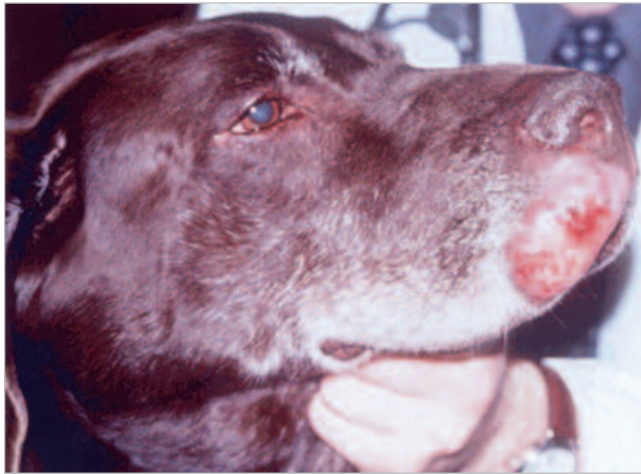


Figure 3. Muzzle mast cell tumor. The ipsilateral mandibular lymph node is enlarged, and metastasis was detected cytologically. (Courtesy of Dr. M. C. McEntee, Cornell University, Ithaca, NY)

to have higher metastatic rates and shorter survival times than do patients with mast cell tumors in other areas.^{5,7,12,17,22,23} It has been documented that patients with mast cell tumors of the extremities (except digital tumors) have longer disease-free intervals, lower metastatic rates, and longer survival times than do patients with mast cell tumors of the trunk.¹² A report of 24 dogs with mast cell tumors of the muzzle revealed a regional lymph node metastatic rate of 58%,⁵ which is higher than what is reported for mast cell tumors of the limbs^{24,25} (Figure 3).

vidual laboratory's normal counts because there can be interpathologic variation. The AgNOR count should be interpreted only in conjunction with other findings, such as tumor grade and other clinically important features of mast cell tumors.¹¹ Ki-67 is another measure of cell proliferation that has been correlated with both mast cell tumor grade and survival time.²⁷

Researchers have investigated the influence of p53 tumor suppressor protein on the outcome of canine cutaneous mast cell tumors.^{28,29} In one study, mast cell tumors were evaluated for the presence of both normal and mutant p53.²⁸ Positive reactivity for p53 was found in 50%, 47%, and 20% of grade I, II, and III tumors, respectively. There was no statistically significant difference between p53 staining and tumor grade or size or dog breed.²⁸ In another study, p53 staining was higher in grade III tumors than in other grades, but it did not predict tumor recurrence or clinical outcome.²⁹ Other investigators are examining the role of mutations in the proto-oncogene *c-kit* in the outcome of canine cutaneous mast cell tumors.^{30,31} The *c-kit* gene encodes for stem cell factor, a cytokine responsible for mast cell growth and differentiation. Mutations in this gene could theoretically promote development and progression of mast cell tumors. One study documented a significantly higher incidence of *kit* mutations in grade III than in grade I or II mast cell tumors.³⁰ Another study found that grade II and III mast cell tumors were five times more likely than grade I tumors to have *kit* mutations, but the difference between these groups was not statisti-

Treatment options for mast cell tumors include surgery, radiation therapy, chemotherapy, or a combination of these modalities.

Nucleolar sites of RNA transcription stain with silver (silver-staining nucleolar organizer regions [AgNOR]), which indirectly determines the rate of cell proliferation.^{11,26} The AgNOR count is obtained by counting the number of silver-stained regions in the nuclei of 100 cells and then calculating the average number per nucleus. The AgNOR count has been correlated with the tumor grade: Higher AgNOR counts are seen with higher-grade tumors. A higher AgNOR count has also been associated with a shorter survival time.^{11,26} An AgNOR count must be interpreted relative to an indi-

cally significant.³¹ Mast cell tumors containing *kit* mutations were twice as likely to recur and metastasize as those that did not undergo mutation, but the difference was also not statistically significant. One goal of this ongoing research is to examine the efficacy of an inhibitor of mutated *kit* on the outcome of canine mast cell disease.²⁶

TREATMENT

Treatment options for mast cell tumors include surgery, radiation therapy, chemotherapy, or a combination

of these modalities. If a cutaneous mast cell tumor in a location amenable to surgery is diagnosed via cytology and no negative prognostic indicators are present (i.e., peritumoral edema and bruising), wide surgical excision is indicated. The tumor should be submitted for histopathologic grading and evaluation of margins to determine whether further staging or treatment is indicated. If the tumor is not amenable to surgical resection or has metastasized, chemotherapy and/or radiation therapy may be indicated before or instead of surgery (Figure 4). In dogs presenting with locoregional or distant metastasis at diagnosis, current therapeutic options should be reviewed and consultation with an oncologist is indicated when available. In a recent study, five of 11 dogs with documented regional lymph node metastasis did not have local progression of their disease following treatment with radiation therapy and/or chemotherapy, indicating that aggressive local and systemic therapy may result in long-term survival for dogs presenting with local mast cell tumor metastasis.⁵ Unfortunately, treatment options are limited and generally unsuccessful in long-term management of dogs with evidence of disseminated mast cell tumors.

Surgery

Surgery is the primary treatment modality for most mast cell tumors. Potential complications of surgery are usually seen only with large, poorly differentiated mast cell tumors and include hypotension, tissue swelling, and excessive hemorrhage during surgery related to histamine and heparin in mast cell granules. Preoperative administration of a histamine blocker (e.g., diphenhydramine [1 to 2 mg/kg SC 30 to 60 minutes before surgery]) may help reduce intraoperative mast cell degranulation. Blood pressure should be monitored during anesthesia because both histamine and diphenhydramine can result in hypotension. Postoperative complications include incision dehiscence, delayed wound healing, and hemorrhage secondary to the presence of proteases, fibroblast suppressor factors, and heparin¹ (Figure 5). In a study of dogs treated with surgery for mast cell tumors, 10% had wound dehiscence after surgery.⁹

Because of the invasive growth pattern of mast cell tumors and potential for “skip metastasis” (i.e., clusters of mast cells surrounding but not directly adjacent to a tumor), surgeons should consider that every mast cell tumor could be incompletely resected. Client education before surgery is essential because incompletely excised tumors require a second surgery or radiation therapy. If

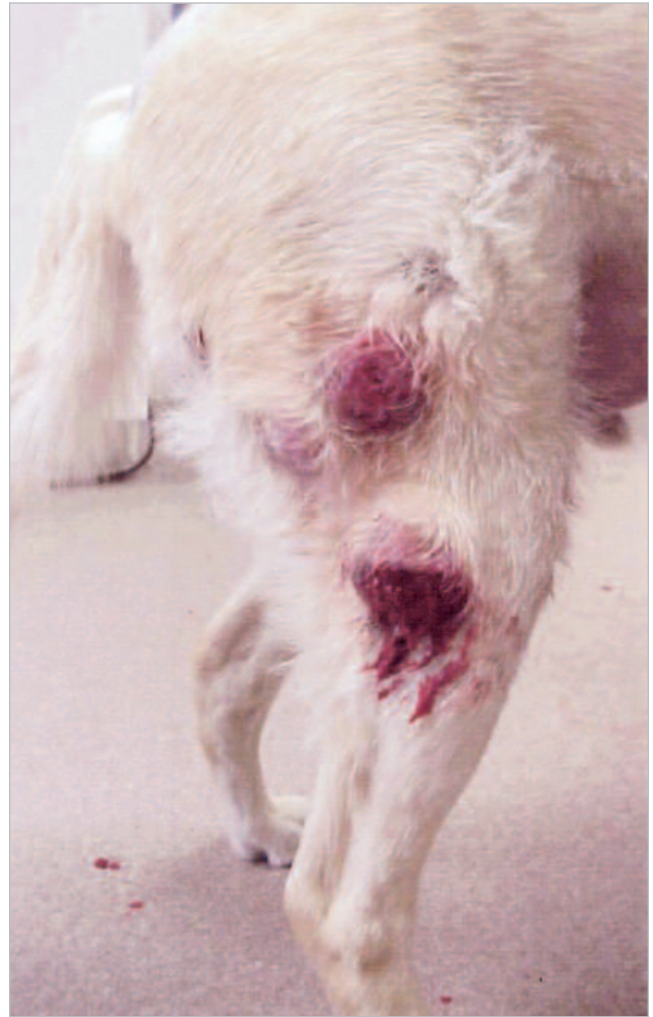

Figure 4. Multiple cutaneous mast cell tumors with peritumoral edema and bleeding. Before formulating a treatment plan, systemic staging tests are indicated in this patient to detect local and distant metastasis. (Courtesy of Dr. K. M. Rassnick, Cornell University, Ithaca, NY)

incomplete excision is likely (e.g., in the case of a large tumor on an extremity) or the tumor is over a body wall, marking the surgical site intraoperatively with hemoclips or stainless-steel suture is advocated. If radiation therapy is indicated postoperatively, these radiographically visible markers can assist a radiation therapist in setting up a treatment plan. Drain placement is rarely indicated when tumors are being resected because all tissues surrounding the drain are considered contaminated with tumor cells. This can make additional surgeries or radiation therapy planning more difficult.

All excised tissue should be submitted to a pathologist for evaluation. If the amount of removed tissue is large

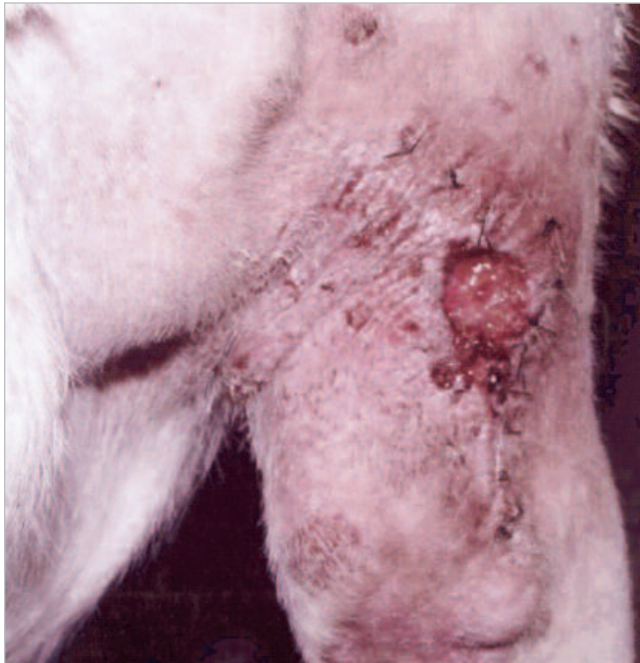

Figure 5. Wound dehiscence following incomplete excision of a mast cell tumor. (Courtesy of Dr. K. M. Rassnick, Cornell University, Ithaca, NY)

and involves several tissue planes, sutures to attach the skin and subcutaneous tissue should be placed to eliminate sliding of layers before placing the tissue in formalin. Tissue should be marked with India ink or the multicolor Davidson Marking System to help the pathologist visualize the margins and determine whether they are complete (Figures 6 and 7). The pathologist should report the tumor grade, invasiveness into surrounding tissues, and measurement of the margins in millimeters.

The extent of surgical margins necessary to remove mast cell tumors has been an ongoing debate, with most surgeons advocating a 3-cm margin in all directions surrounding the tumor.^{7,17} A recent prospective study examined tissue margins when mast cell tumors were excised with 3-cm lateral margins and one fascial plane deep to the tumor.³² Tissue sections were examined at 1, 2, and 3 cm around and deep to the tumors in 17 dogs. No neoplastic mast cells were present at 2- or 3-cm lateral margins. Not surprisingly, tumors on the limbs of dogs were more likely to be incompletely excised than were tumors in other locations. This study suggests that for most mast cell tumors, a 2-cm lateral margin with one fascial plane deep to the tumor is sufficient for excision.

In general, the outcome of dogs with mast cell tumors treated with surgery is excellent. In one study of 55 dogs

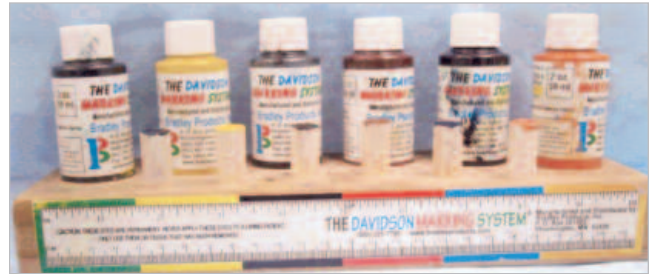

Figure 6. The Davidson Marking System can help pathologists identify tumor margins.

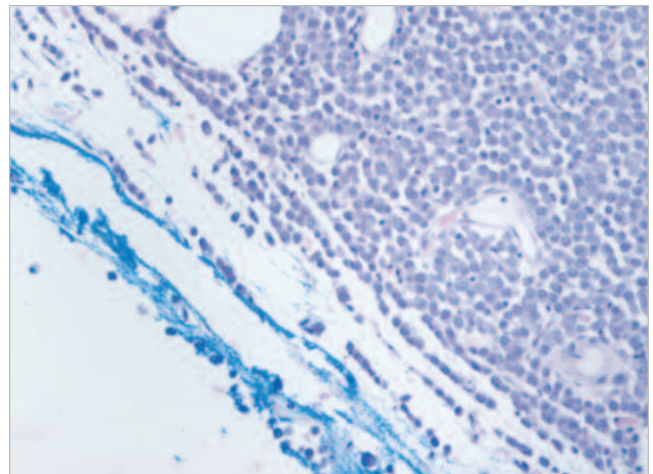


Figure 7. Histopathologic image of a mast cell tumor extending to the cut margin (marked with blue dye from the Davidson Marking System).

with grade II mast cell tumors treated with surgery alone, 90% had complete surgical margins after an attempt to excise 2 to 3 cm of tissue lateral to and deep to the tumor.⁹ During a median follow-up time of 540 days, 5% of dogs had local recurrence, 5% developed metastasis, and 11% developed additional cutaneous mast cell tumors. Three of the 55 dogs died of mast cell tumors.⁹ Another study reported 31 dogs with grade II mast cell tumors treated with surgery alone.¹⁸ Surgical margins were determined to be free of tumor cells by at least 1 to 2 mm. The dogs were not routinely staged before surgery. Eleven percent experienced local recurrence and 22% developed distant tumor recurrence (systemic metastasis or additional cutaneous mast cell tumors at other sites) during a median follow-up time of 510 days.¹⁸ In a 2003 Australian study, tumor grade was predictive of surgical margins: Grade III tumors were more likely than grade I or II tumors to be incompletely excised.⁸ Interestingly, surgeons could not predict

histologic margins based on extent of surgery, and some dogs with “radical” surgical excisions had incomplete surgical margins. Although only 4.2% of dogs developed local recurrence, this study reported a heterogeneous population of dogs, many of which had complete surgical margins or were treated postoperatively with chemotherapy, second surgeries, and deionized water injections into the tumor bed.⁸

Conflicting information exists regarding regrowth of incompletely excised mast cell tumors. Historically, recurrence rates of incompletely excised mast cell tumors range from 30% to 64%.^{7,17,33,34} In a report of 31 dogs comparing tumor recurrence between dogs with tumor-free versus non-tumor-free surgical margins, only two of 11 dogs with incomplete surgical margins developed local tumor recurrence.⁴ This information must be interpreted with caution because of a small sample size and limited follow-up information (only six of 11 dogs were followed up for longer than 1 year).⁴ It is possible that some mast cell tumors may not recur after incomplete excision; unfortunately, there is currently no way to predict which ones will regrow. Because mast cell tumor recurrence is associated with a shorter survival time versus dogs with no recurrence,³⁵ adjunctive therapies are recommended to improve local control of incompletely excised mast cell tumors. There is no evidence that using corticosteroids after surgery delays tumor regrowth.

After surgery, further treatment options are based on biopsy results, including evaluation of margins and tumor grade. If the surgical margins are “dirty” (i.e.,

controversy exists among oncologists regarding the definition of “clean” versus “close” margins for mast cell tumors. One report defines “clean” margins as a 1- to 2-mm distance between tumor and normal tissue,¹⁸ but other references are scarce. For mast cell tumors, we generally define “clean” margins as 10 mm or more between the tumor and normal tissue and “close” margins as 1 to 9 mm between the tumor and normal tissue. Chemotherapy is indicated in dogs with poorly differentiated or metastatic mast cell tumors.

Radiation Therapy

Radiation therapy is the standard of care for incompletely excised low- and intermediate-grade mast cell tumors and provides long-term tumor control in most cases (Table 3).^{12,20,24,25} Although radiation therapy is most effective when mast cell tumors are microscopic, reports of tumor control despite gross disease exist.²⁵ It is essential that clients be informed that radiation therapy is a localized form of treatment and does not prevent tumor metastasis or distant tumor formation. Acute local side effects within the radiation field, such as moist desquamation and mucositis, are common and resolve following therapy and supportive care. Late side effects are uncommon and usually occur 1 year or longer after completing radiation therapy. These side effects can include secondary tumor formation in the radiation therapy field, bone necrosis, and fibrosis of muscle in the treatment field. Although these complications are uncommon, they are difficult to treat. Because many patients with mast cell tumors live for years after com-

Recent reports indicate that long-term tumor control can be obtained in some cases of advanced or metastatic mast cell cancer.

tumor cells extend to the margins of excision), further treatment options include radiation therapy or a second surgery if the site is amenable. If the surgical margins are “close,” options include a second excision with scar revision; close monitoring of the site every 2 months for 6 months, then every 3 months for 2 years or longer; or radiation therapy. If the surgical margins are “clear,” frequent follow-up visits and diligent examination of the dog by the owner is indicated because some dogs develop recurrent or additional mast cell tumors. Con-

pleting radiation therapy, regularly scheduled rechecks of the site for tumor recurrence and late effects of radiation are indicated for the remainder of the patient’s life.

Although the role of radiation therapy in dogs with metastatic or poorly differentiated tumors is not as well defined, recent reports suggest a significant benefit to using radiation therapy in managing such cases.^{21,36} In a report of 19 dogs with cutaneous mast cell tumors with regional lymph node metastasis treated with surgery, definitive radiation therapy at the primary tumor site

Table 3. Radiation Therapy Studies for Incompletely Excised Canine Cutaneous Mast Cell Tumors

Radiation Source (total dose)	No. of Dogs Treated	Median Tumor-Free Interval ^a (days)	1-Yr Tumor-Free Rate	2-Yr Tumor-Free Rate	Median Survival Time ^b (days)	1-Yr Survival Rate	2-Yr Survival Rate	Additional Information
Orthovoltage unit cobalt-60 unit (36–48 Gy ¹²)	85	510	79%	77%	570	76%	73%	Patients with extremity tumors have a longer disease-free interval, lower rate of metastasis, and longer median survival time than do patients with truncal tumors. Grade predicts survival and metastasis. WHO stage predicts survival and DFI.
Cobalt-60 unit (54 Gy ²⁰)	32	—	94%	86%	—	100%	96%	5-y DFI: 86% 5-y survival: 96% Intermediate-grade-tumors only
Orthovoltage unit linear accelerator (46–48 Gy ²⁴)	37	—	96%	—	—	—	—	3-y DFI: 93% Intermediate-grade tumors only
Cobalt-60 unit (45–57 Gy ²⁵)	56	1,620 if there was microscopic disease 365 with measurable (macroscopic) disease	—	—	—	—	—	There was a higher recurrence in dogs treated Monday, Wednesday, and Friday than in those treated daily (i.e., Monday through Friday). Dogs <7½ years of age had a longer DFI than did those >7½ years of age.

^aTime between the start of therapy and recurrence or metastasis of the tumor.
^bTime between the start of therapy and death.
DFI = disease-free interval.

and lymph node, and prednisone, the median disease-free interval was 1,240 days.³⁶ In another recent study, 31 dogs with incompletely excised, poorly differentiated mast cell tumors with no evidence of nodal or systemic

metastasis (WHO stage 0) treated with a definitive course of radiation therapy alone had a 71% 1-year and 39% 2-year survival rate.²¹

In some cases, bulky nonresectable mast cell tumors are

irradiated to attempt to shrink tumors and palliate clinical signs. Large volumes of mast cell tumors should be irradiated with extreme caution because rapid degranulation with subsequent hypotension, GI ulceration, and anaphylactic shock may occur after treatment. Histamine blockers and steroids are indicated in these patients to minimize side effects.

Interstitial brachytherapy with iridium (Ir) 192 has also been used as an adjuvant to incomplete surgical excision for canine cutaneous mast cell tumors.³⁷ The advantage of this type of therapy is that radiation is localized in the skin and surrounding subcutaneous tissue, sparing underlying vital organs. Case selection is limited to small, incompletely excised, superficial tumors. In one study of 11 dogs treated with surgery and Ir192 interstitial brachytherapy, five dogs developed tumor recurrence with a progression-free interval of 1,391 days and six dogs had no recurrence at a median follow-up time of 942 days.³⁷

Chemotherapy

The role of chemotherapy in managing mast cell tumors has not been well defined. Chemotherapy has been used as an adjunct to other treatment modalities for high-grade mast cell tumors and in place of radiation therapy for incompletely excised tumors.^{5,13,14,38,39} As part of a larger study of dogs with mast cell tumors treated with prednisone and vinblastine, seven dogs with incompletely excised cutaneous mast cell tumors had a 57% 1- and 2-year disease-free interval.¹³ Also in this study, a group of dogs with grade III tumors treated with prednisone and vinblastine had a median survival time of 330 days and 45% survival at 1 and 2 years after diagnosis; however, there was no control population, and those dogs were treated heterogeneously with surgery and radiation therapy before chemotherapy.¹³

Chemotherapy should be considered if there is any evidence of metastasis, a poorly differentiated tumor is present, or an intermediate-grade tumor with negative prognostic indicators is present (i.e., peritumoral edema and bruising, a tumor in a location associated with a worse prognosis). This treatment may improve quality of life and survival time and may make nonresectable tumors amenable to surgery and/or radiation therapy (neoadjuvant chemotherapy). Various chemotherapy drugs have been used in dogs with mast cell tumors (Table 4).^{13,39-42} Unfortunately, few studies have examined the efficacy of individual chemotherapeutic agents in dogs with measurable mast cell tumors, so it is diffi-

cult to document which drugs work best against neoplastic mast cells. In general, combination therapy is thought to be most effective. Lomustine, vinblastine, and prednisone are considered the most active agents against mast cell tumors, and clinical studies involving combinations of these drugs are underway.

Adjunctive Therapy

It has been documented that dogs with mast cell tumors have plasma histamine concentrations four times higher than those in normal dogs.⁴³ In a study of 17 dogs with cutaneous mast cell tumors, there was no correlation between plasma histamine concentration and tumor grade, tumor size, or stage of disease. Six of 17 dogs had signs of GI ulceration (i.e., anorexia, vomiting, diarrhea, and/or melena), and there was no difference in plasma histamine concentrations between these dogs and dogs without clinical signs.⁴³ A recent study examined plasma histamine concentrations in 11 dogs with mast cell tumors.⁴⁴ Eight dogs had macroscopic disease, and three had microscopic disease. Tumors were of various grades and were treated with various combinations of surgery, radiation therapy, and chemotherapy. Dogs with macroscopic disease had significantly higher plasma histamine concentrations than those in normal dogs. Seven dogs that died from mast cell tumors had progressively higher plasma histamine concentrations over time. In dogs that lived, plasma histamine concentrations did not increase over time. Initially, four of 11 dogs had signs of GI ulceration, but there was no difference between plasma histamine concentrations in those dogs versus dogs with no clinical signs and all responded to H₂-blocker therapy (cimetidine [10 mg/kg IV or PO q12h]). Seven dogs developed GI signs that were refractory to therapy, and their plasma histamine concentration was 64 times higher than that in normal dogs. In this study, plasma histamine concentrations were not measured in relation to dosing of H₂-blockers, and proton pump inhibitors were not used.

Treatment with histamine-receptor blockers (i.e., diphenhydramine, cyproheptadine [H₁-blockers]; famotidine, cimetidine, ranitidine [H₂-blockers]) and/or proton pump inhibitors (e.g., omeprazole) is indicated in patients that have nonresectable mast cell tumors, in patients that have large tumors or peritumoral edema or bruising prior to surgery, before radiation therapy in dogs with bulky disease, or in any dog with local or systemic metastasis of mast cell tumors. The goal of these therapies is to decrease clinical signs related to GI ulceration and peritumoral inflammation.

Table 4. Efficacy of Chemotherapy Drugs Against Measurable Mast Cell Disease (i.e., gross disease) in Dogs

Drug(s)	No. of Dogs Treated	Overall Response Rate	Median Response Duration (days)	Additional Information
Prednisone ⁴¹	25	20%	—	Four of five dogs that responded had a partial response ^a ; one of five had a complete response. ^b Grade and location did not affect response.
Vincristine ⁴⁰	27	7%	—	The two dogs that responded had a partial response. ^b
Lomustine ³⁹	23	42%	77	Seven of eight dogs that responded had a partial response ^a ; one of eight had a complete response. ^b Grade, previous treatment, and tumor location did not affect response.
Prednisone, vinblastine ¹³	18	47%	154	Five of seven dogs that responded had a complete response ^b ; two of seven had a partial response. ^a Dogs that responded to therapy had longer survival times than those that did not.
Vinblastine, cyclophosphamide, prednisone ³⁸	14	78%	—	Eleven of 14 had a partial response ^a ; none had a complete response. ^b Median survival time was 5 mo.
Cyclophosphamide, vincristine, prednisone, hydroxyurea ¹⁴	15	60%	53	Four of 15 had a complete response ^b ; five of 15 had a partial response. ^a Three dogs had a complete response ^b for >2 y. Dogs that failed the protocol were treated with doxorubicin; no responses were noted.
Vinblastine, prednisone, lomustine ⁴²	11	63%	58	Three of seven had a complete response ^b ; four of seven had a partial response. ^a

^aGreater than 50% reduction in tumor volume.
^bNo evidence of a tumor.

Resource

The Davidson Marking System (Bradley Products, Inc.)
A tissue marking system for a variety of laboratory applications requiring orientation of tissue specimens.
www.bradleyproducts.com

Deionized water injections into the tumor bed as an adjunct to surgery have been performed by investigators but are not recommended because of conflicting results of efficacy.^{34,35} One study showed a shorter disease-free interval in dogs that had deionized water injections into the tumor bed versus those that did not, but survival times between the groups were similar.³⁵

REFERENCES

- Abbas AK, Lichtman AH, Pober JS: Immediate hypersensitivity, in Abbas AK, Lichtman AH, Pober JS (eds): *Cellular and Molecular Immunology*. Philadelphia, WB Saunders, 2000, pp 424-438.
- Dorn ER, Taylor D, Schneider R, et al: Survey of animal neoplasms in Alameda and Contra Costa counties, California. *J Natl Cancer Inst* 40:307-318, 1968.
- Miller DM: The occurrence of mast cell tumors in young shar peis. *J Vet Diagn Invest* 7:360-363, 1995.
- Michels GM, Knapp DW, DeNicola DB, et al: Prognosis following surgical excision of canine cutaneous mast cell tumors with histologically tumor-free versus nontumor-free margins: A retrospective study of 31 cases. *JAAHA* 38:458-466, 2002.
- Gieger TL, Theon AP, Werner JA, et al: Biologic behavior and prognostic factors for mast cell tumors of the canine muzzle: 24 dogs (1990-2001). *J Vet Intern Med* 17:687-692, 2003.
- Bostock DE: The prognosis following surgical removal of mastocytomas in dogs. *J Small Anim Pract* 14:27-40, 1973.
- Thamm DH, Vail DM: Mast cell tumors, in Withrow SJ, MacEwen EG (eds): *Small Animal Clinical Oncology*. Philadelphia, WB Saunders, 2001, pp 261-279.
- Baker-Gabb M, Hunt GB, France MP: Soft tissue sarcomas and mast cell tumours in dogs: Clinical behaviour and response to surgery. *Aust Vet J* 81(12):732-738, 2003.
- Seguin B, Leibman NF, Bregazzi VS, et al: Clinical outcome of dogs with grade-II mast cell tumors treated with surgery alone: 55 cases (1996-1999). *JAVMA* 218(7):1120-1123, 2001.
- Patnaik AK, Ehler WJ, MacEwen EG: Canine cutaneous mast cell tumor: Morphologic grading and survival time in 83 dogs. *Vet Pathol* 21:469-474, 1984.
- Simoes JPC, Schoning P, Butine M: Prognosis of canine mast cell tumors: A comparison of three methods. *Vet Pathol* 31:637-647, 1994.
- Turrel JM, Kitchell BE, Miller LM, et al: Prognostic factors for radiation treatment of mast cell tumors in 85 dogs. *JAVMA* 193:936-940, 1988.
- Thamm DH, Mauldin EA, Vail DM: Prednisone and vinblastine chemotherapy for canine mast cell tumor: 41 cases (1992-1997). *J Vet Intern Med* 13:491-497, 1999.
- Gerritsen RJ, Teske E, Kraus JS, et al: Multi-agent chemotherapy for mast cell tumors in the dog. *Vet Q* 20:28-31, 1998.
- Northrup NC, Howerth EW, Harmon B, et al: Variation among pathologists in histopathologic grading of canine cutaneous mast cell tumors. *Proc 23rd Vet Cancer Society*:73, 2003.
- Consultation on the biological behavior and therapy of tumors of domestic animals. Geneva, World Health Organization, 1978.
- Macy DW: Canine and feline mast cell tumors: Biologic behavior, diagnosis, and therapy. *Semin Vet Med Surg Small Anim* 1:72-83, 1986.
- Weisse C, Shofer FS, Sorenmo K: Recurrence rates and sites for Grade II canine cutaneous tumors following complete surgical excision. *JAAHA* 38:71-73, 2002.
- McManus PM: Frequency and severity of mastocytosis in dogs with and without mast cell tumors: 120 cases (1995-1997). *JAVMA* 215:355-357, 1999.
- Al-Sarraf R, Mauldin GN, Patnaik AK, et al: A prospective study of radiation therapy for the treatment of grade 2 mast cell tumors in 32 dogs. *J Vet Intern Med* 10:376-378, 1996.
- Hahn KA, King GK, Carreras JK: Efficacy of radiation therapy for incompletely resected grade III mast cell tumors in dogs: 31 cases. *JAVMA* 224(1):79-82, 2004.
- Fan TM, Kitchell BE: Retrospective analysis of oral mast cell tumors in dogs. *Proc 19th Annu Vet Cancer Soc Conf*:40, 1999.
- Marino DJ, Matthiesin DT, Stefanacci JD, et al: Evaluation of dogs with digit masses: 117 cases. *JAVMA* 207(6):726-728, 1995.
- Frimberger AE, Moore AS, LaRue SM, et al: Radiotherapy of incompletely resected, moderately differentiated mast cell tumors in the dog: 37 cases (1989-1993). *JAAHA* 320-324, 1997.
- LaDue T, Price GS, Dodge R, et al: Radiation therapy for incompletely resected canine mast cell tumors. *Vet Radiol Ultrasound* 39(1):57-62, 1998.
- Bostock DE, Crocker J, Harris K, et al: Nucleolar organiser regions as indicators of post-surgical prognosis in canine spontaneous mast cell tumors. *Br J Cancer* 59:915-918, 1989.
- Abadie JJ, Amardeilh MA, Delverdiere ME: Immunohistochemical detection of proliferating cell nuclear antigen and Ki-67 in mast cell tumors from dogs. *JAVMA* 215(11):1629-1634, 1999.
- Ginn PE, Fox LE, Brower JC, et al: Immunohistochemical detection of p53 tumor-suppressor protein is a poor indicator of prognosis for canine cutaneous mast cell tumors. *Vet Pathol* 37:33-39, 2000.
- Jaffe MH, Hosgood G, Taylor HW, et al: Immunohistochemical and clinical evaluation of p53 in canine cutaneous mast cell tumors. *Vet Pathol* 37:40-46, 2000.
- Zemke D, Yamini B, Yuzbasiyan-Gurkan V: Mutations in the juxtamembrane domain of c-KIT are associated with higher grade mast cell tumors in dogs. *Vet Pathol* 39:529-535, 2002.
- Downing S, Chien MB, Kass PH, et al: Prevalence and importance of internal tandem duplications in exons 11 and 12 of c-kit in mast cell tumors in dogs. *Am J Vet Res* 63:1718-1723, 2002.
- Simpson AM, Ludwig LL, Newman SJ, et al: Canine cutaneous mast cell tumors: A prospective study of surgical margins. *JAVMA* 224(2):236-240, 2004.
- Misdorp W: Incomplete surgery, local immunostimulation, and recurrence of some tumour types in dogs and cats. *Vet Q* 9(3):279-286, 1987.
- Grier RL, DiGuardo G, Myers R: Mast cell tumour destruction in dogs by hypotonic solution. *J Small Anim Pract* 36:385-388, 1995.
- Jaffe MH, Hosgood G, Kerwin SC, et al: Deionised water as an adjunct to surgery for the treatment of canine cutaneous mast cell tumors. *J Small Anim Pract* 41:7-11, 2000.
- Chaffin K, Thrall DE: Results of radiation therapy in 19 dogs with cutaneous mast cell tumors and regional lymph node metastasis. *Vet Radiol Ultrasound* 43(4):392-395, 2002.
- Northrup NC, Roberts RE, Harrell TW, et al: Iridium-192 interstitial brachytherapy as adjuvant treatment for canine cutaneous mast cell tumors. *JAAHA* 40:309-315, 2004.
- Elmslie R: *Vet Cancer Society Newsletter* 6-7, 1996.
- Rassnick KM, Moore AS, Williams LE, et al: Treatment of canine mast cell tumors with CCNU (lomustine). *J Vet Intern Med* 13:601-605, 1999.
- McCaw DL, Miller MA, Bergman PJ, et al: Vincristine therapy for mast cell tumors in dogs. *J Vet Intern Med* 11(6):375-378, 1997.
- McCaw DL, Miller MA, Ogilvie GK, et al: Response of canine mast cell tumors to treatment with oral prednisone. *J Vet Intern Med* 8(6):406-408, 1994.
- Hershey AE, Jones PD, Klein MK: Evaluation of combination vinblastine, lomustine, and prednisone for the treatment of canine mast cell tumors. *Proc 23rd Annu Conf Vet Cancer Soc*:71, 2003.
- Fox LE, Rosenthal RC, Twedt DC, et al: Plasma histamine and gastrin concentrations in 17 dogs with mast cell tumors. *J Vet Intern Med* 4:242-246, 1990.
- Ishiguro T, Kadosawa T, Takagi S, et al: Relationship of disease progression and plasma histamine concentrations in 11 dogs with mast cell tumors. *J Vet Intern Med* 17:194-198, 2003.

ARTICLE #4 CE TEST

This article qualifies for 2 contact hours of continuing education credit from the Auburn University College of Veterinary Medicine. Subscribers may purchase individual CE tests or sign up for our annual CE program. Those who wish to apply this credit to fulfill state relicensure requirements should consult their respective state authorities regarding the applicability of this program. To participate, fill out the test form inserted at the end of this issue or take CE tests online and get real-time scores at www.CompendiumVet.com.

1. **Which of the following staging tests would be recommended before surgery for a 10-year-old female mixed-breed dog with a 3 × 4-cm cutaneous mast cell tumor on the right perineum (diagnosed by fine-needle aspiration and a cytologic examination), peritumoral edema and bruising, and an enlarged right inguinal lymph node?**
 - a. aspiration of the right inguinal lymph node
 - b. bone marrow aspiration
 - c. buffy coat smear
 - d. abdominal ultrasonography with aspiration of the spleen and liver if they appear abnormal
 - e. all of the above

2. **A 2 × 2-cm grade II mast cell tumor is resected from the left hock of a 6-year-old neutered Labrador retriever. The biopsy reveals tumor cells extending to the margins of the submitted tissue. More underlying tissue cannot be resected. Which of the following describes the ideal treatment and prognosis?**
 - a. deionized water injection into the tumor bed; the median disease-free interval is 2 years
 - b. radiation therapy; more than 75% of patients have no evidence of a tumor at the site 2 years after the therapy
 - c. prednisone only; it is likely to be curative
 - d. monitoring the site for recurrence; the tumor is unlikely to recur
 - e. chemotherapy with vinblastine and lomustine; the median survival time is approximately 6 months

3. **Which statement regarding canine mast cell tumors is not true?**
 - a. Because boxers have a higher incidence of grade I tumors than other breeds, they may have a better prognosis.
 - b. More than 50% of grade III mast cell tumors metastasize and are often accompanied by peritumoral edema and inflammation.
 - c. Grade II mast cell tumors are the most common type and have a wide range of biologic behavior.
 - d. Shar-peis tend to have very malignant mast cell tumors that develop at a young age.
 - e. Buffy coat smears should be conducted on all animals with cutaneous mast cell tumors because a positive result is diagnostic of mast cell tumor metastasis.

4. **Which chemotherapy drug is least likely to shrink a mast cell tumor?**
 - a. vincristine
 - b. vinblastine
 - c. prednisone
 - d. lomustine
 - e. none of the above

5. **Which of the following has not been demonstrated as a prognostic indicator of canine mast cell tumors?**
 - a. p53 tumor suppressor protein
 - b. Ki-67 proliferation index
 - c. AgNOR proliferation index
 - d. tumor grade
 - e. tumor location

6. **Which statement regarding mast cell tumor grade is not true?**
 - a. Tumor grade can be easily determined via cytology or histopathology of a specimen.
 - b. Although other grading schemes exist, the most commonly accepted one is the Patnaik system in which grade I indicates well-differentiated mast cell tumors and grade III poorly differentiated mast cell tumors.
 - c. Histopathologic grade has been shown to be prognostic for survival time, local tumor recurrence, and mast cell tumor metastasis.
 - d. Poorly differentiated mast cell tumors have a reported metastatic rate of greater than 50%.
 - e. Tumor grade is the most consistent prognostic indicator among studies of canine cutaneous mast cell tumors.

7. **Which staging test is indicated in every patient before surgical excision of cutaneous mast cell tumors?**
 - a. buffy coat smear
 - b. regional lymph node aspiration
 - c. punch biopsy to determine the tumor grade before definitive surgery
 - d. abdominal ultrasonography
 - e. bone marrow aspiration

(CE test continues on p. 75)

Mast Cell Tumors in Dogs *(continued from page 68)*

8. A 1 × 1-cm cutaneous mast cell tumor is removed from the right side of the neck of a 2-year-old neutered Labrador retriever. The pathologist determines that the tumor is grade II and there is more than 2 cm of tissue between the tumor and normal tissue. What type of follow-up is recommended?

- a. radiation therapy to the tumor bed because the tumor will likely recur
- b. vinblastine and cyclophosphamide chemotherapy for 6 mo
- c. prednisone therapy (1 mg/kg PO sid for 6 mo)
- d. a second surgery to achieve better margins
- e. at least two follow-up visits per year because 10% of dogs that have had cutaneous mast cell tumors develop additional mast cell tumors; the client should be instructed to diligently examine the dog for new masses and to bring it to the clinic as soon as possible if any are discovered

9. Which statement regarding radiation therapy for cutaneous mast cell tumors in dogs is not true?

- a. Dogs with incompletely resected but microscopic

mast cell tumors during radiation therapy have a better prognosis than do dogs with measurable tumors during treatment.

- b. Radiation therapy can provide palliation for large non-resectable mast cell tumors; however, clinicians must monitor patients carefully for posttreatment complications such as GI ulceration, hypotension, and collapse related to release of histamine and other substances.
- c. Radiographically visible markers such as hemoclips should be used during surgery if incomplete tumor excision is probable and radiation therapy will likely be indicated after surgery.
- d. Radiation therapy for dogs with incompletely resected, well- to intermediately differentiated tumors provides long-term local tumor control in most cases.
- e. All of the above are true.

10. Which drug is a proton pump inhibitor that decreases gastric acid secretion related to hyper-histaminemia in dogs with mast cell tumors?

- a. cimetidine
- b. omeprazole
- c. ranitidine
- d. cyproheptadine
- e. famotidine