

Differential Diagnosis of Endometrial Hyperplasia and Carcinoma by Computerized Image Cytometry of Cell Proliferation, Apoptosis and Bcl-2 Expression*

LINDA B. MORA, M.D., JOSE I. DIAZ, M.D.,
ALAN B. CANTOR, Ph.D.,* and SANTO V. NICOSIA, M.D.

Department of Pathology and Biostatistics Core Program,
University of South Florida,
College of Medicine
and H. Lee Moffit Cancer Center and Research Institute,
Tampa, FL*

ABSTRACT

Background: The differential diagnosis between atypical endometrial hyperplasia and endometrial carcinoma is often difficult and based on controversial criteria. Cell kinetic parameters may be helpful.

Design: Cell proliferation, apoptosis and Bcl-2 expression were evaluated in benign endometrium, non atypical and atypical endometrial hyperplasia and endometrial carcinoma. The results were compared by one way analysis of variance and Bonferoni T tests.

Results: Cell proliferation was significantly higher ($p < 0.01$) in endometrial adenocarcinoma (25.6 percent) than in atypical hyperplasia (17.1 percent) and non-atypical hyperplasia (7.5 percent) of the endometrium. Apoptosis was observed in 12.3 percent of endometrial adenocarcinomas and less frequently in atypical hyperplasia (7.4 percent) and non-atypical hyperplasia of the endometrium (5.8 percent). Bcl-2 expression was significantly lower ($p < 0.002$) in endometrial adenocarcinoma (1.7 percent) than in atypical hyperplasia (4.2 percent) and non-atypical hyperplasia (5.3 percent) of the endometrium. In benign endometrium, cell proliferation and Bcl-2 expression were significantly higher during the proliferative phase while the rate of apoptosis was significantly higher during the secretory phase.

Conclusions: Our data suggests that cell proliferation, apoptosis and Bcl-2 expression could be helpful when distinguishing endometrial carcinoma from non-atypical or atypical endometrial hyperplasia.

Introduction

It is now well established that endometrial hyperplasia is a precursor lesion of well-

differentiated endometrial carcinoma.¹ A continuing spectrum of histological changes occurs during endometrial malignant transformation. This includes simple endometrial hyperplasia and complex endometrial hyperplasia without cytologic atypia, (which can be grouped as non-atypical endometrial hyperplasia), endometrial hyperplasia with cytologic atypia (also called atypical endometrial hyper-

* Address correspondence to Jose I. Diaz, M.D., Department of Pathology, MDC 11, University of South Florida College of Medicine, 12901 Bruce B Downs Blvd., Tampa, Florida 33612.

plasia), and endometrial carcinoma. The differential diagnosis of these lesions, particularly the distinction between atypical endometrial hyperplasia and endometrial carcinoma, is often difficult because it is based on subtle histological differences and controversial criteria.²

Endometrial carcinogenesis is a multistep process, triggered by the progressive loss of the control mechanisms that regulate cell growth and cell death. In normal endometrium, cell proliferation and programmed cell death or apoptosis are hormone-dependent. Estrogens increase cell proliferation and unopposed estrogens may lead to endometrial hyperplasia.³ The rate of apoptosis is very low in proliferative endometrium, increases in secretory endometrium and peaks prior to menstruation.⁴ Thus, kinetic parameters such as cell proliferation and apoptosis could be expected to change significantly during malignant transformation. These parameters can be objectively quantitated in diagnostic surgical specimens and might be helpful in establishing a correct diagnosis. The cell growth cycle consists of G_1 (presynthetic), S (DNA synthesis), M (mitosis), and G_2 (post-mitosis) proliferative phases, and a physiologic state G_0 in which cells are quiescent. The cycle lasts approximately 24 hours. Mitosis lasts less than 30 minutes and therefore is not considered an accurate assessment of cell proliferation.⁵ The cell proliferation-associated nuclear antigen Ki-67 is expressed throughout the proliferative phases of the cycle (late G_1 phase, S, G_2 and M phases) in all cycling human cells.⁶ The expression of this protein can be detected with the MIB-1 mAb in a variety of formalin fixed tissues, providing an excellent measurement of cell proliferation.⁷⁻⁸

During apoptosis, the DNA is fragmented in segments of 180 base pairs.⁹ This results in characteristic morphological features,¹⁰ which can be identified under the light microscope. Apoptosis can be also identified in tissue sections by the technique of terminal deoxynucleotidyl transferase (TdT)-mediated deoxyuridine (dUTP)-biotin nick end labeling (TUNEL).¹¹ However, previous studies have

shown that the morphological identification of apoptotic cells under the light microscope is more accurate than the TUNEL technique.¹²

The Bcl-2 protein is a powerful suppressor of apoptosis,¹³ and over-expression can be detected by immunohistochemistry.

In this study, we have evaluated cell proliferation and Bcl-2 expression by computerized image cytometry and the rate of apoptosis by light microscopy to determine if these parameters can discriminate between normal, hyperplastic and carcinomatous endometrium.

Material and Methods

Histopathological Materials: Formalin-fixed, paraffin-embedded archival specimens from 71 patients who underwent hysterectomy for uterine leiomyomas, cervical pathology, abnormal uterine bleeding or a previous diagnosis of endometrial hyperplasia or carcinoma were retrieved from the files of the Department of Pathology at the H. Lee Moffitt Cancer Center and Research Institute. Four μm thick, hematoxylin-eosin stained tissue sections were reviewed and the endometrial tissues were classified in the following groups: atrophic endometrium ($n = 10$), proliferative endometrium ($n = 10$), secretory endometrium ($n = 10$), simple or complex non-atypical endometrial hyperplasia ($n = 19$), atypical endometrial hyperplasia ($n = 9$) and endometrial carcinoma ($n = 13$).

Atypical endometrial hyperplasia and endometrial carcinoma were diagnosed according to published criteria.¹⁴ All endometrial carcinomas were well differentiated (FIGO grade I of III). The mean age of patients with benign atrophic, proliferative or secretory endometrium was 41 (range 32 to 54). The mean age of patients with non-atypical or atypical endometrial hyperplasia and endometrial carcinoma was 52, 59, and 63, respectively (range 31 to 79).

MIB-1 and Bcl-2 Immunohistochemistry: Deparaffinized four μm thick tissue sections were placed in methanol containing 0.3% H_2O_2 for 30 minutes at room temperature (RT) to block endogenous peroxidase activity.

Immunohistochemical staining was performed by the biotin-streptavidin amplified (BSA) peroxidase method¹⁵ using the anti-Ki-67 mAb MIB-1 (Immunotech, West Brook, ME) and the anti-Bcl-2 mAb (Dako, Carpinteria, CA). Briefly, antigen retrieval¹⁶ was performed by incubating the slides in citric acid buffered solution (pH 6.0) in a microwave for 5 minutes, and repeating this procedure 3 times. Slides were then incubated with the appropriate mAb for 60 minutes at RT. Visualization was achieved with the biotin-IgG/streptavidin-horseradish peroxidase immunodetection kit (Biogenics, San Ramon, CA) using diaminobenzidine (DAB) as a chromogen. Slides were incubated with a universal biotinylated IgG secondary Ab for 30 minutes at RT, with peroxidase-conjugated streptavidin for 30 minutes at RT and with sequential application of 3,3'DAB/H₂O₂ for 5 to 10 minutes at RT. Slides were washed with phosphate buffered saline pH 7.4 before the primary and secondary Abs, peroxidase-conjugated streptavidin and DAB were applied. Slides were counterstained with Meyer's hematoxylin regressively, dehydrated and mounted. Negative and positive immunostaining controls were established by omitting MIB-1 and anti-Bcl-2 mAbs and by using archival tonsillar tissue displaying reactive germinal centers, respectively.

MIB-1 and Bcl-2 Image Cytometric Analysis: A CAS-200 Image Analysis System (Cell Analysis Systems) with "Cell Proliferation Index" and "Oncogene" software programs were used to quantitate cell proliferation and Bcl-2 expression (MIB-1 nuclear

positive or Bcl-2 cytoplasmic positive cells/total number of cells \times 100). A minimum of 150 non-overlapping and well-preserved cells was measured within at least 10 adjacent 400 \times magnification fields in each sample.¹⁷ The digital image of an endometrial gland immunostained with MIB-1 mAb for evaluation of cell proliferation is shown in figure 1. The system operator was unaware of the histopathological diagnosis at the time of cytometric evaluation.

Apoptosis: The rate of apoptosis was determined by quantitating the percent of endometrial epithelial cells exhibiting the characteristic morphological features of apoptosis under the light microscope, according to previously published criteria.¹⁰ Characteristic apoptotic endometrial epithelial cells are shown in figure 2.

Statistical analysis: The mean percentages of apoptotic, Ki-67 and Bcl-2 positive endometrial epithelial cells were compared between atrophic endometrium, proliferative endometrium, secretory endometrium, non-atypical endometrial hyperplasia, atypical endometrial hyperplasia and endometrial carcinoma. The comparisons were analyzed by a one way ANOVA test using the general linear models procedure (Proc GLM of the SAS software system).¹⁸ Bonferroni testing to control the Type I error rate at 0.05 was then performed for each pair of histological sub-groups.

Results

The mean percentages of Ki-67, apoptotic and Bcl-2 positive endometrial epithelial cells

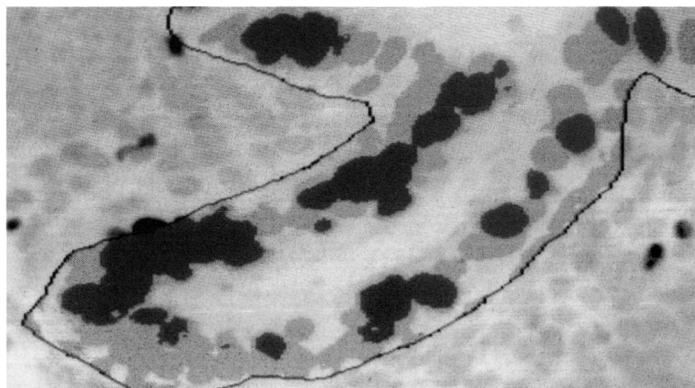
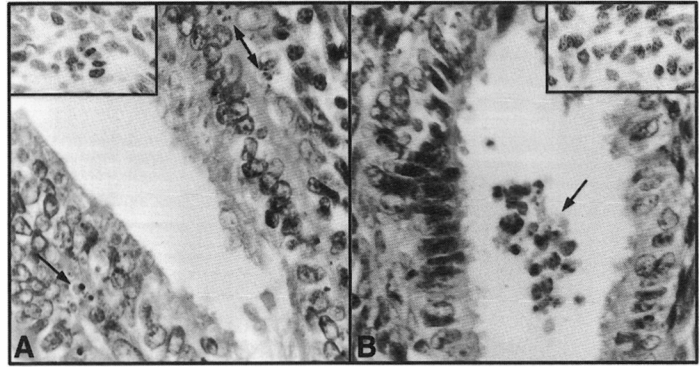


FIGURE 1. CAS-200 digital image of an endometrial gland after MIB-1 immunostaining, with a line drawn around the contour of the gland. The proliferating cells (MIB-1 positive nuclei) demonstrate dark nuclei.

FIGURE 2. Apoptosis (600 \times) and cell proliferation (insets, 400 \times) in atypical endometrial hyperplasia (A) and well-differentiated endometrial carcinoma (B). Endometrial epithelial apoptotic cells (labeled with arrows). The inset demonstrates proliferating endometrial epithelial cells labeled with MIB-1 mAb (dark nuclei) in these same cases.



are shown in figure 3. Ki-67 positive cells were significantly higher in endometrial carcinoma than in non-atypical or atypical endometrial hyperplasia ($p < 0.0001$ and $p = 0.002$, respectively). There was no significant difference between either type of endometrial hyperplasia ($p > 0.05$). As expected, the percent of Ki-67 positive cells was significantly higher in proliferative endometrium than in atrophic or

secretory endometrium ($p < 0.05$). Also, there was no significant difference in cell proliferation between benign proliferative endometrium and endometrial carcinoma.

Similarly, the percent of apoptotic cells was significantly higher in endometrial carcinoma than in non-atypical or atypical endometrial hyperplasia ($p < 0.0001$ and $p = 0.01$, respectively). There was no significant difference

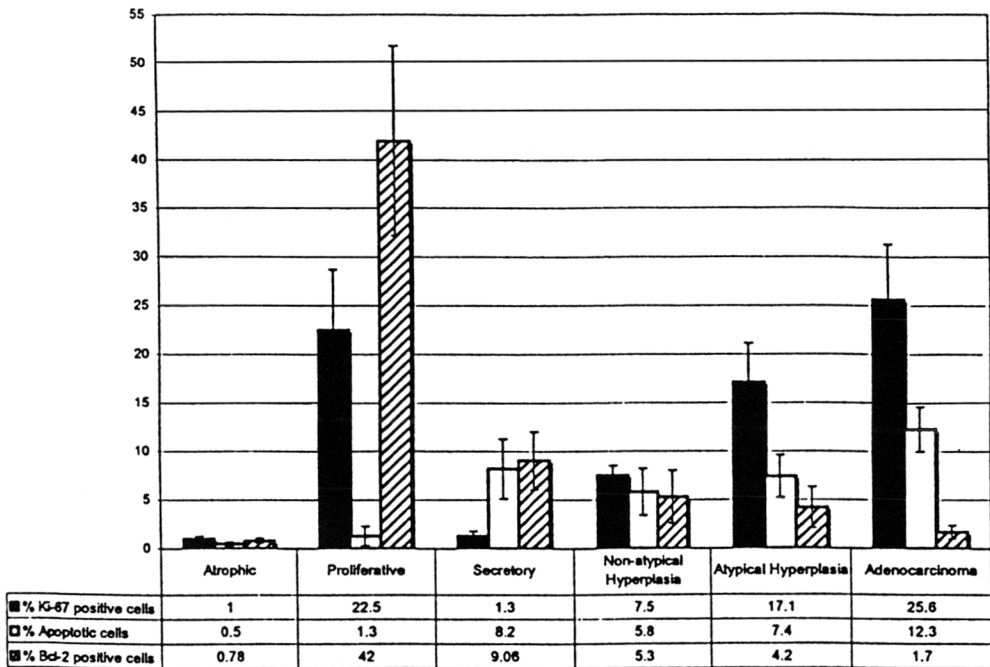


FIGURE 3. Histogram with the mean percentages of cell proliferation (black bars), apoptosis (white bars) and Bcl-2 protein expression (hatched bars) in non-atypical and atypical endometrial hyperplasia and endometrial carcinoma. The standard deviations are represented in vertical lines over the bars.

between either type of endometrial hyperplasia. The percent of apoptotic cells was significantly higher ($p < 0.05$) in secretory endometrium than in atrophic or proliferative endometrium. Proliferating endometrial cells labeled with the MIB-1 mAb and apoptotic endometrial cells recognized by their characteristic appearance under the light microscope, are shown in figure 2.

The percent of Bcl-2 positive cells was significantly lower in endometrial carcinoma than in non-atypical and atypical endometrial hyperplasia ($p < 0.0001$ and $p = 0.001$, respectively). There was no significant difference between either type of endometrial hyperplasia. Also, this percent was significantly higher in proliferative endometrium than in atrophic or secretory endometrium ($p < 0.05$). Endometrial cells immunolabeled with the Bcl-2 mAb are shown in figure 4.

The differences in the means described above suggest that it might be feasible to use the percent of Ki-67, Bcl-2, and apoptotic epithelial endometrial cells to distinguish between non-atypical/atypical endometrial hyperplasia and endometrial carcinoma. Figure 5 is a scatter plot that shows the separation of these groups based on empirical cutoffs in the percent of Ki-67 positive cells. As can be observed, all of the endometrial carcinomas and none of the non-atypical endometrial hyperplasia had greater than 14% Ki-67 posi-

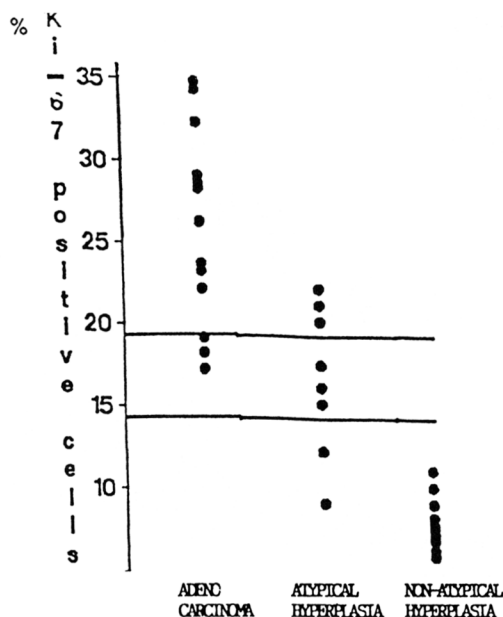


FIGURE 5. Scatter plot showing the separation of non-atypical and atypical endometrial hyperplasias and endometrial carcinomas based on the percent of Ki-67 positive cells. Empirical cutoffs of 14 and 19 percent will have identified correctly all non-atypical endometrial hyperplasias, 77 percent of the endometrial carcinomas and 55 percent of the atypical endometrial hyperplasias.

tive cells. Thus this value would have distinguished the carcinomas without error. However, the separation between endometrial carcinomas and atypical endometrial hyperplasias was not as perfect. Ten of the thirteen carcinomas (77%) had values above 19% while

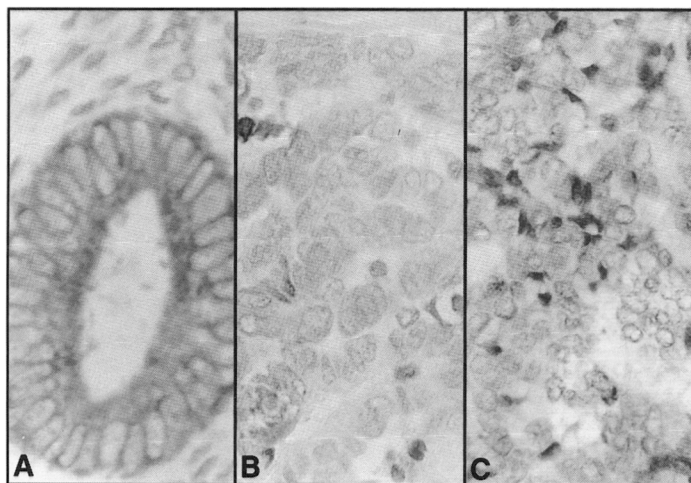


FIGURE 4. Bcl-2 protein expression after immunostaining with Bcl-2 mAb (600 \times). In normal endometrium, Bcl-2 expression peaks in mid-proliferative phase (A). There is low to negative Bcl-2 expression in atypical endometrial hyperplasia (B) and well-differentiated endometrial carcinoma (C), respectively.

five of the nine atypical endometrial hyperplasias (55%) were below this value (one of the dots represents the overlap of two atypical hyperplasias, each with 22% of Ki-67 positive cells). Figure 6 is a scatter plot that shows the separation of these groups based on empirical cutoffs in the percent of apoptotic and Bcl-2 positive cells. As can be observed, eleven of the thirteen endometrial carcinomas (85%) in our sample had more than 8% apoptotic cells, while six of nine atypical endometrial hyperplasias (67%) and eighteen of nineteen non-atypical endometrial hyperplasias (95%) had less than 8% apoptotic cells. Eleven of thirteen endometrial carcinomas (85%) had less than 2.5% Bcl-2 positive cells. All of the non-atypical endometrial hyperplasias and seven of the nine atypical endometrial hyperplasias (78%) had more than 2.5% Bcl-2 positive cells. Thus the percent of Bcl-2 positive cells can also make this distinction. Note that 7 of our 41 cases (17%) would be classified inconsistently when using these two parameters.

Discussion

Endometrial hyperplasia embraces a group of lesions with differing biologic potential, and may be a precursor of well differentiated endometrial carcinoma. The carcinomas that arise in this context are relatively benign in behavior. The overlap in histologic changes that occurs during this process accounts for the difficulties encountered by surgical pathologists when evaluating endometrial specimens. Attempts to subclassify what indeed is a continuing spectrum have resulted in controversies.

Endometrial hyperplasia is a disordered proliferation of endometrial glands resulting in glandular crowding and decreased intervening stroma. The term atypical endometrial hyperplasia was introduced to describe glandular proliferations with extreme glandular crowding and very little intervening stroma and therefore, closely resembling carcinoma.¹⁹ A later definition proposed the restriction of this

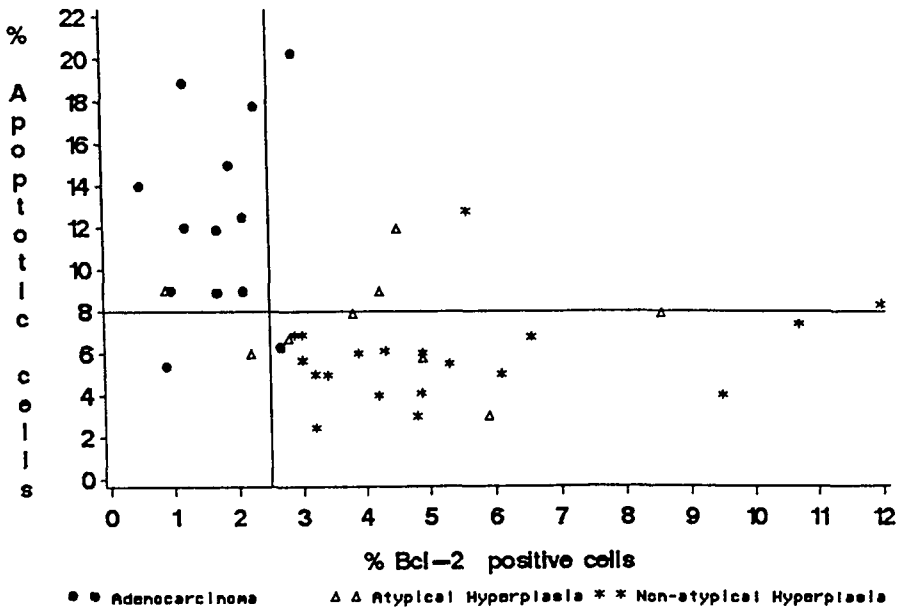


FIGURE 6. Scatter plot showing the separation of non-atypical and atypical endometrial hyperplasias and endometrial carcinomas based on the percent of apoptotic and Bcl-2 positive cells. An empirical cutoff of 8 percent apoptotic cells will have identified correctly 95 percent of the non-atypical endometrial hyperplasias, 85 percent of the endometrial carcinomas and 67 percent of the atypical endometrial hyperplasias. A cutoff of 2.5 percent Bcl-2 positive cells will have identified correctly all non-atypical endometrial hyperplasias, 85 percent of endometrial carcinomas and 78 percent of the atypical endometrial hyperplasias.

term to lesions with cytological atypia regardless of the degree of glandular crowding.²⁰ Other authors have required both extreme glandular crowding and atypia to designate atypical endometrial hyperplasia.²¹ The even more controversial term of carcinoma in situ was introduced to describe lesions at the end of the spectrum of endometrial proliferation in which the cytological and the architectural features were consistent with carcinoma although there was no stromal invasion.²⁰ The International Society of Gynecological Pathologists (ISGP) subdivides endometrial hyperplasia into two categories: non-atypical endometrial hyperplasia (without cytological atypia) and atypical endometrial hyperplasia (with cytological atypia). Since it appears that the rate of progression to carcinoma is very low in non-atypical endometrial hyperplasia regardless of glandular complexity and crowding, we have used in our study the presence of cytological atypia to differentiate non-atypical from atypical endometrial hyperplasia. Although many well differentiated endometrial carcinomas are diagnosed without difficulty, it might be very difficult to differentiate endometrial carcinoma from atypical endometrial hyperplasia.²² Stromal invasion excludes atypical endometrial hyperplasia, but this might be difficult to identify in endometrial biopsies.

Cell kinetic parameters such as cell proliferation,²³⁻²⁵ and more recently apoptosis,²⁶ have been investigated in an attempt to better understand the pathogenesis of these lesions. The results of measurement of cell proliferation have been controversial. We have investigated the potential use of these parameters to differentiate endometrial hyperplasia from carcinoma. As others,²⁶ we found that the rates of apoptosis and cell proliferation are lower in non-atypical and atypical endometrial hyperplasia than in endometrial carcinoma. As could be expected from previous reports,²⁷ we found that in benign endometrium, Bcl-2 expression peaks during the proliferative phase, when cell proliferation is high and apoptosis is low. In addition, we found that Bcl-2 expression is significantly lower in endometrial carcinoma than in non-atypical or atypical endometrial hyperplasia.

In summary, our data suggests that cell proliferation, apoptosis and Bcl-2 expression may provide useful information when attempting to distinguish between endometrial carcinoma and non-atypical or atypical endometrial hyperplasia. We realize a classification rule may perform better on the data used to create that rule than on other data. It is, therefore important that our observations be confirmed, and perhaps fine-tuned, in a prospective fashion by other investigators. We postulate that determination of the percentages of apoptotic, Ki-67 and Bcl-2 positive cells may be a useful ancillary tool.

References

1. Bokhman J. Two pathogenetic types of Endometrial Carcinoma. *Gynecol Oncol* 1983;15:10-17.
2. Kurman R, Norris H. Evaluation of the Criteria for Distinguishing Atypical Endometrial Hyperplasia from Well-differentiated Carcinoma. *Cancer* 1982;49:2547-59.
3. Ferenczy A, Gelfand M and Tzipris F. The Cytodynamics of Endometrial Hyperplasia and Carcinoma. *Ann Pathol* 1983;3:189-202.
4. Tabibzadeh S, Zupi E, Babaknia A, Liu R, Marconi D and Romanini C. Site and Menstrual Cycle-Dependent Expression of Proteins of the Tumour Necrosis Factor (TNF) Receptor Family, and BCL-2 Oncoprotein and Phase-Specific Production of TNF alpha in Human Endometrium. *Hum Reprod* 1995; 10(2):277-86.
5. Cordon-Cardo C. Mutation of Cell Cycle Regulators: Biological and clinical implications for human neoplasias. *Am J Path* 1995;147(3):545-560.
6. Gerdes J, Schwab U, Lemke H and Stein H. Production of a mouse monoclonal antibody reactive with a human nuclear antigen associated with cell proliferation. *Int J Cancer* 1983;31(1):13-20.
7. Hepburn PJ, Glynn-Jones E, Goddard L, Gee JM, and Harper ME. Cell Proliferation in Prostatic Carcinoma: Comparative Analysis of Ki-67, MIB-1 and PCNA. *Histochem J* 1995;27:196-203.
8. Noordzij MA, Van der Kwast TH, Van Steenbrugge GJ, van Weerden WM, Oomen MH, and Schroder FH: Determination of Ki-67 defined growth fraction by monoclonal antibody MIB-1 in formalin-fixed, paraffin-embedded prostatic cancer tissues. *Prostate* 1995; 27:154-159.
9. Lockshin R and Zakeri Z. Programmed Cell Death and Apoptosis. In: Tomei L and Cope F, editors. *Current Communications in Cell and Molecular Biology. Apoptosis: The Molecular Basis of Cell Death*, New York: Cold Spring Harbor Laboratory Press, 1991;3: 47-60.
10. Nicosia SV, Diaz J, Nicosia RF, Saunders BO, Muro-Cacho C. Cell Proliferation and Apoptosis during Development and Aging of the Rabbit Corpus Luteum. *Ann Clin Lab Sci* 1995;25(2):143-157.

11. Gavrieli Y, Sherman Y and Ben-Sasson S. Identification of Programmed Cell Death In Situ via Specific Labeling of Nuclear DNA Fragmentation. *J Cell Biol* 1992;119:493-501.
12. Drachenberg C, Ioffe O and Papadimitriou J. Progressive Increase of Apoptosis in Prostatic Intraepithelial Neoplasia and Carcinoma. Comparison between In Situ and End-labeling of Fragmentation of DNA and Detection by Routine Hematoxylin-Eosin Staining. *Arch Pathol Lab Med* 1997;121:54-58.
13. Bakhshi A, Jensen J, Goldman J, Wright O, McBride A, Epstein A and Korsmeyer S. Cloning the Chromosomal Break-point of the t(14;18) Human Lymphomas; Clustering Around JH on Chromosome 14 and near a Transcriptional Unit of 18. *Cell* 1985;41:889-906.
14. Kurman R and Mazur M. *Diagnosis of Endometrial Biopsies and Curettages: A Practical Approach*. New York, Springer Verlag, 1995.
15. Hsu SM, Raine L and Fanger H: Use of the avidin-biotin-peroxidase complex (ABC) in immunoperoxidase techniques: A comparison between ABC and unlabeled antibody (PAP) procedures. *J Histochem Cytochem* 1981;29(4):577-580.
16. Shi S, Key M and Kalra K. Antigen retrieval in formalin-fixed, paraffin-embedded tissues: an enhancement method for immunohistochemical staining based on microwave oven heating of tissue sections. *J Histochem Cytochem* 1991;39:741-748.
17. Mora L, Nicosia S, Pow-Sang J, Ku N, Diaz J, Lockhart J and Einstein A: Ancillary techniques in the follow-up of transitional cell carcinoma: A comparison of cytology, histology and deoxyribonucleic acid image analysis cytometry in 91 patients. *J Urol* 1996;156:49-55.
18. SAS Institute Inc, *SAS/STAT User's Guide*, Version 6, Fourth Edition, Vol 1, Cary, NC: SAS Institute Inc 1989.
19. Novak E and Rutledge F. Atypical Endometrial Hyperplasia Simulating Adenocarcinoma. *Am J Obstet Gynecol* 1948;55:46-54.
20. Vellios F. Endometrial Hyperplasia and Carcinoma In Situ. *Gynecol Oncol* 1974;2:152-61.
21. Kraus F. High Risk and Premalignant Lesions of the Endometrium. *Am J Surg Pathol* 1985;9(3):31-41.
22. Buehl I, Vellios F, Carter J and Huber C. Carcinoma In Situ of the Endometrium. *Am J Clin Pathol* 1964; 42:594-602.
23. Yu C, Wilkinson N and Brito M. Patterns of Immunohistochemical staining for Proliferating Cell Nuclear Antigen and P53 in Benign and Neoplastic Human Endometrium. *Histopathol* 1993;23:367-371.
24. Politschuk Z, Buchinskaja G and Vinnichenko V. Differences in Mitotic Regime in Various Gynecologic Conditions and Endometrial Carcinoma. *Akush Gynecol* 1984;11:26-30.
25. Punnonen R and Mazur J. DNA Ploidy, Cell Proliferation and Steroid Hormone Receptors in Endometrial Hyperplasia and Early adenocarcinoma. *J Cancer Res Clin Oncol* 1993;119:426-429.
26. Ioffe O, Papadimitriou J and Drachenberg C. Correlation of Proliferation Indices, Apoptosis and Related Oncogene Expression (Bcl-2 and c-erb-2) and p53 in Proliferative, Hyperplastic and Malignant Endometrium. *Human Pathol* 1998;29(10):1150-1159.
27. Gompel A, Sabourin J and Martin A. Bcl-2 Expression in Normal Endometrium during the Menstrual Cycle. *Am J Pathol* 1994;144:1195-1202.