


# GUIDELINES

for the  
Prevention and Clinical Management  
of Snakebite in Africa



# **GUIDELINES**

## **for the Prevention and Clinical Management of Snakebite in Africa**

**WORLD HEALTH ORGANIZATION  
Regional Office for Africa  
Brazzaville • 2010**

© WHO Regional Office for Africa 2010  
All rights reserved

The designations employed and the presentation of the material in this publication do not imply the expression of any opinion whatsoever on the part of the World Health Organization concerning the legal status of any country, territory, city or area or of its authorities, or concerning the delimitation of its frontiers or boundaries. Dotted lines on maps represent approximate border lines for which there may not yet be full agreement.

The mention of specific companies or of certain manufacturers' products does not imply that they are endorsed or recommended by the World Health Organization in preference to others of a similar nature that are not mentioned. Errors and omissions excepted, the names of proprietary products are distinguished by initial capital letters.

All reasonable precautions have been taken by the World Health Organization to verify the information contained in this publication. However, the published material is being distributed without warranty of any kind, either expressed or implied. The responsibility for the interpretation and use of the material lies with the reader. In no event shall the World Health Organization be liable for damages arising from its use.

# Contents

	<b>Page</b>	
Foreword		x
Preface		xi
Acknowledgements		xii
Abbreviations		xiv
1. Introduction		1
2. Morphological characteristics of African venomous snakes		3
2.1 Snakes that bite frequently, and are associated with serious or life-threatening envenoming		3
2.2 Snakes that bite frequently, but rarely cause serious or life-threatening envenoming		10
2.3 Snakes that bite rarely, but are capable of causing severe or life-threatening envenoming		14
2.4 Snakes that bite rarely, and have not caused significant envenoming		22
2.5 Other potentially venomous snakes which have not caused documented bites		24
3. Distribution of African Venomous Snakes and Epidemiological Data on Snakebite		29
3.1 Distribution of African venous snakes		29
3.2 Epidemiological data on snakebite in African countries		30
4. Prevention of Snakebite		33
4.1 Introduction		33
4.2 In the house		33
4.3 In the farmyard, compound, or garden		33
4.4 In the bush or countryside		34
5. Snake Venoms		35
5.1 Introduction		35
5.2 Snake venom composition		35
5.3 Classification of clinical patterns of snakebite envenoming		36
6. Clinical Features of Envenoming		39
6.1 Introduction		39
6.2 Local symptoms and signs in the bitten part		39
6.3 Generalized (systemic) symptoms and signs		39

7.	Clinical Profiles of Envenoming by Some Snakes of Medical Importance	41
7.1	Back-fanged snakes ( <i>Colubridae</i> )	41
7.2	Burrowing asps or stiletto snakes ( <i>Atractaspididae</i> , Genus <i>Atractaspis</i> )	42
7.3	African spitting cobras (Genus <i>Naja</i> )	43
7.4	Mambas (Genus <i>Dendroaspis</i> )	44
7.5	Neurotoxic non-spitting cobras ( <i>Naja haje</i> , <i>N. annulifera</i> , <i>N. anchietae</i> , <i>N. melanoleuca</i> and <i>N. nivea</i> )	45
7.6	Sea snakes	45
7.7	Spitting elapids: snake venom ophthalmia	45
7.8	Saw-scaled or carpet vipers (Genus <i>Echis</i> )	46
7.9	Puff adders ( <i>Bitis arietans</i> )	49
7.10	Gaboon vipers ( <i>Bitis gabonica</i> and <i>B. rhinoceros</i> )	50
7.11	Berg adder ( <i>Bitis atropos</i> ) and other small <i>Bitis</i> species	51
7.12	Desert horned-vipers (Genus <i>Cerastes</i> )	51
7.13	Night adders (Genus <i>Causus</i> )	52
7.14	Old World vipers (Genus <i>Macrovipera</i> )	52
8.	Main Clinical Syndromes of Envenoming in Africa	53
8.1	SYNDROME 1: Marked local swelling with coagulable blood	54
8.2	SYNDROME 2: Marked local swelling with incoagulable blood and/or spontaneous bleeding	54
8.3	SYNDROME 3: Progressive paralysis (neurotoxicity)	54
8.4	SYNDROME 4: Mild swelling alone	54
8.5	SYNDROME 5: Mild or negligible local swelling with incoagulable blood	55
8.6	SYNDROME 6: Moderate to marked local swelling associated with neurotoxicity	55
9.	Detailed Clinical Assessment and Species Diagnosis	57
9.1	History	57
9.2	Examination	58
9.3	Monitoring of snake-bitten patients	59
9.4	Investigations	60
9.5	Diagnosis	62
10.	First aid and Transport to Medical Care (Including what not to do)	63
10.1	Essential first-aid procedures	63
10.2	Pressure-pad method	64
10.3	Treatment of early symptoms	64
11.	Emergency Clinical Management of Snakebite	67
11.1	Introduction	67
11.2	Rapid clinical assessment and resuscitation	67
11.3	Cardio-pulmonary resuscitation	67
11.4	Urgent intervention	68

12.	Management of Snakebite at Community Level and Different Health Care Facilities	71
12.1	At community level	71
12.2	At rural clinic, dispensary, or health post	71
12.3	At the District Hospital	72
12.4	Referral (Higher Level) Hospital	72
13.	Antivenoms	73
13.1	Introduction	73
13.2	Antivenom production	73
13.3	Antivenom use	74
13.4	Precautions	74
13.5	Producers and suppliers	74
14.	Antivenom Treatment	77
14.1	Appropriate use of antivenoms	77
14.2	Indications for antivenoms.	78
14.3	Contraindications to antivenom	78
14.4	Hypersensitivity testing	78
14.5	Timing of antivenom treatment	78
14.6	Antivenom specificity	79
14.7	Antivenom administration	79
14.8	Antivenom dosage	79
14.9	Response to antivenom treatment	80
14.10	Antivenom reactions	80
14.11	Specific issues about antivenoms	82
14.12	Snakebite and traditional practices	82
15.	Ancillary Treatment	85
15.1	Treatment of local envenoming	85
15.2	Haemostatic abnormalities	87
15.3	Neurotoxic envenoming	87
15.4	Anticholinesterases	87
15.5	Hypotension and shock	88
15.6	Renal failure	88
15.7	Snake venom ophthalmia	89
15.8	Snakebite in pregnancy	89
15.9	Snakebite in children	90
15.10	Snakebite in the elderly	90



<b>References/Further reading</b>	<b>91</b>
<b>Tables</b>	
8.1 Six syndromes of envenoming	65
14.1 Indications for antivenom treatment after bites by African snakes	88
14.2 Guide to initial dosage of some important antivenoms for bites by African snakes	89
<b>Figures</b>	
1. Puff adder <i>Bitis arietans</i> Abuja, Nigeria	1
2. Burton's carpet viper <i>Echis coloratus</i> Saudi Arabia	3
3. Joger's carpet viper <i>Echis jogeri</i> Bandafassi, Senegal	4
4. White-bellied carpet viper <i>Echis leucogaster</i>	4
5. White-bellied carpet viper <i>Echis leucogaster</i> Sokoto, Nigeria	4
6. West African or ocellated carpet viper <i>Echis ocellatus</i> Kaltungo, Nigeria	4
7. Egyptian carpet viper <i>Echis pyramidum leakeyi</i> Archer's Post, Kenya	5
8. Egyptian carpet viper <i>Echis pyramidum leakeyi</i> Baringo, Kenya	5
9. Puff adder <i>Bitis arietans</i> Nigeria	5
10. Puff adder <i>Bitis arietans</i> Garki, Nigeria	5
11. Mozambique spitting cobra <i>Naja mossambica</i>	6
12. Red spitting cobra <i>Naja pallida</i> Watamu, Kenya	6
13. Black-necked spitting cobra <i>Naja nigricollis</i> Abuja, Nigeria	7
14. Zebra spitting cobra <i>Naja nigricincta</i> Namibia	7
15. Wood's black spitting cobra <i>Naja nigricincta</i> woodi Springbok, Northern Cape, South Africa	7
16. Ashe's spitting cobra <i>Naja ashei</i> Watamu, Kenya	7
17. Nubian spitting cobra <i>Naja nubiae</i>	8
18. Snouted ("banded") cobra <i>Naja annulifera</i> Limpopo, South Africa	8
19. Egyptian cobra <i>Naja haje</i> Zaria, Nigeria	8
20. Senegalese cobra <i>Naja senegalensis</i> Dielmo, Senegal	8
21. Cape cobra <i>Naja nivea</i> De Hoop, Western Cape, South Africa	9
22. Cape cobra	9
23. Eastern green mamba <i>Dendroaspis angusticeps</i> Gede, Kenya	9
24. Eastern green mamba <i>Dendroaspis angusticeps</i> Richard's Bay, South Africa	9
25. Traill's mamba <i>Dendroaspis jamesoni</i> kaimosi Kakamega, Kenya	9
26. Black mamba <i>Dendroaspis polylepis</i> Gede, Kenya	10
27. Black mamba <i>Dendroaspis polylepis</i>	10
28. Slender burrowing asp <i>Atractaspis aterrima</i> Nigeria	11
29. Small-scaled burrowing asp <i>Atractaspis (microlepidota) fallax</i> Watamu, Kenya	11
30. Snouted night adder <i>Causus defilipii</i> Matopos, Zimbabwe	11
31. Snouted night adder <i>Causus defilipii</i> Matopos, Zimbabwe	12
32. Western rhombic night adder <i>Causus maculatus</i> Zaria, Nigeria	12
33. Eastern rhombic night adder <i>Causus rhombeatus</i> Durban, KwaZulu Natal, South Africa	12

34.	Eastern rhombic night adder <i>Causus rhombeatus</i> Richard's Bay, South Africa	12
35.	Saharan horned-viper <i>Cerastes cerastes</i>	13
36.	Saharan horned-viper <i>Cerastes cerastes</i>	13
37.	Saharan horned-viper <i>Cerastes cerastes</i> Algeria	13
38.	Saharan sand viper <i>Cerastes vipera</i>	13
39.	Boomslang <i>Dispholidus typus</i> male Western Cape, South Africa	14
40.	Boomslang <i>Dispholidus typus</i> South Africa	14
41.	Boomslang <i>Dispholidus typus</i> showing rear fang	14
42.	Vine snake <i>Thelotornis capensis</i> Johannesburg, South Africa	15
43.	Vine snake <i>Thelotornis capensis</i> Johannesburg, South Africa	15
44.	Vine snake <i>Thelotornis capensis</i> oatesii northern Zimbabwe	15
45.	Forest cobra <i>Naja melanoleuca</i> .	16
46.	West African forest cobra <i>Naja melanoleuca</i> Sokoto, Nigeria	16
47.	Rinkhal <i>Hemachatus haemachatus</i> Johannesburg, South Africa	16
48.	Desert black snake <i>Walterinnesia aegyptia</i>	17
49.	Yellow-bellied sea snake <i>Pelamis platurus</i> South Africa	17
50.	Horned forest viper <i>Atheris ceratophora</i>	17
51.	West African tree viper <i>Atheris chlorechis</i> Côte d'Ivoire	17
52.	Hallowell's bush viper <i>Atheris squamigera</i> Kenya	18
53.	Mount Kenya bush viper <i>Atheris desaixi</i>	18
54.	Lowland viper <i>Proatheris superciliaris</i>	18
55.	Gaboon viper <i>Bitis gabonica</i>	18
56.	Gaboon viper <i>Bitis gabonica</i> St Lucia, KwaZulu Natal, South Africa	19
57.	Rhinoceros viper <i>Bitis rhinoceros</i> Ghana	19
58.	Nose-horned viper <i>Bitis nasicornis</i>	19
59.	Nose-horned viper <i>Bitis nasicornis</i> Kumba, Cameroon	19
60.	Berg adder <i>Bitis atropos</i> Betty's Bay, Western Cape, South Africa	20
61.	Péringuey's desert adder <i>Bitis peringueyi</i>	20
62.	Desert mountain adder <i>Bitis xeropaga</i>	20
63.	South African coral snake <i>Aspidelaps lubricus lubricus</i> South Africa	20
64.	South African coral snake <i>Aspidelaps lubricus infuscatus</i> South Africa	21
65.	Shield-nosed snake <i>Aspidelaps scutatus scutatus</i> West Nicholson, Zimbabwe	21
66.	Levantine viper <i>Macrovipera lebetina</i>	21
67.	Moorish viper <i>Macrovipera mauritanica</i>	21
68.	Horned adder <i>Bitis caudalis</i> Northern Cape, South Africa	22
69.	Namaqua dwarf adder <i>Bitis schneideri</i> .	22
70.	Kenyan horned viper <i>Bitis worthingtonii</i> Lake Naivasha, Kenya	22
71.	East African garter snake <i>Elapsoidea loveridgei</i> Kenya	23
72.	Half-banded garter snake <i>Elapsoidea semiannulata moebiusi</i> Gambia	23
73.	Half-banded garter snake <i>Elapsoidea semiannulata moebiusii</i> Zaria, Nigeria	23
74.	Sunderwall's garter snake <i>Elapsoidea sundevalli longicauda</i> Northern Transvaal, South Africa	23
75.	Ethiopian mountain adder <i>Bitis parviocula</i> Bedelle Ethiopia	24
76.	Rough-scaled bush viper <i>Atheris hispida</i> Kakamega, Kenya	24
77.	Southern adder <i>Bitis armata</i>	25



78.	Many-horned adder <i>Bitis cornuta</i> Springbok, Northern Cape, South Africa	25
79.	Red adder <i>Bitis rubida</i> Cederberg, Western Cape, South Africa	25
80.	Green night adder <i>Causus resimus</i> Watamu, Kenya	25
81.	Blanding's tree snake <i>Boiga (Toxicodryas) blandingii</i> Watamu, Kenya	26
82.	Blanding's tree snake <i>Boiga blandingii</i> Kakamega, Kenya	26
83.	Desert adder <i>Macrovipera (Daboia) deserti</i>	26
84.	Banded water cobra <i>Naja (Boulengerina) annulata stormsi</i> Lake Tanganyika	27
85.	Burrowing cobra <i>Naja (Paranaja) semifasciata duttoni</i>	27
86.	Gold's tree cobra <i>Pseudohaje goldii</i>	27
87.	Rinkhal <i>Hemachatus haemachatus</i> Johannesburg, South Africa	34
88.	Boomslang <i>Dispholidus typus</i> bite Harare, Zimbabwe	41
89.	Dahomey burrowing asp <i>Atractaspis dahomeyensis</i> bite	42
90.	Small-scaled burrowing asp <i>Atractaspis microlepidota</i> bite, Diani Beach, Kenya	42
91.	Small-scaled burrowing asp <i>Atractaspis microlepidota</i> bite, Diani Beach, Kenya	42
92.	Black-necked spitting cobra <i>Naja nigricollis</i> bite	43
93.	Black-necked spitting cobra <i>Naja nigricollis</i> bite	43
94.	Black-necked spitting cobra <i>Naja nigricollis</i> bite	43
95.	Black-necked spitting cobra <i>Naja nigricollis</i> bite	43
96.	Black mamba bite <i>Dendroaspis polylepis</i> Ngwelazana, South Africa	44
97.	Black-necked spitting cobra <i>Naja nigricollis spit</i> Zaria, Nigeria	46
98.	Black-necked spitting cobra <i>Naja nigricollis spit</i> Wusasa, Nigeria	46
99.	Black-necked spitting cobra <i>Naja nigricollis spit</i> resulting in blindness	46
100.	Saw-scaled viper <i>Echis ocellatus</i> bite on dorsum of foot in a 12-year-old boy, Kaltungo, Nigeria	47
101.	Saw-scaled viper <i>Echis ocellatus</i> bite on dorsum of foot in a 12-year-old boy, Kaltungo, Nigeria	47
102.	Saw-scaled viper <i>Echis ocellatus</i> bite on dorsum of foot in a 12-year-old boy, Kaltungo, Nigeria	47
103.	Saw-scaled viper <i>Echis ocellatus</i> bite, Kaltungo, Nigeria	47
104.	Saw-scaled viper <i>Echis ocellatus</i> bite, Kaltungo, Nigeria	47
105.	Saw-scaled viper <i>Echis ocellatus</i> bite, Kaltungo, Nigeria	47
106.	Saw-scaled viper <i>Echis ocellatus</i> bite, Zaria, Nigeria	48
107.	Saw-scaled viper <i>Echis ocellatus</i> bite, Kaltungo, Nigeria	48
108.	Puff adder <i>Bitis arietans</i> bite, Zaria, Nigeria	49
109.	Puff adder <i>Bitis arietans</i> bite, Zaria, Nigeria	49
110.	Untreated puff adder <i>Bitis arietans</i> bite Zaria, Nigeria	50
111.	Puff adder <i>Bitis arietans</i> bite, Zaria, Nigeria	50
112.	Rhinoceros viper <i>Bitis gabonica</i> bite	50
113.	Rhinoceros viper <i>Bitis rhinoceros</i> bite, Côte d'Ivoire	50
114.	Berg adder <i>Bitis atropos</i> bite, Drakensbergs, South Africa	51
115.	Berg adder <i>Bitis atropos</i> bite, South Africa	51
116.	Neurotoxicity from Berg adder <i>Bitis atropos</i> bite	60
117.	Formal clinical testing for ptosis	60
118.	20WBCT	61

119.	Saw-scaled viper <i>Echis ocellatus</i> bite	64
120.	Early antivenom reaction: generalized urticaria	81
121.	Angioedema	81
122.	Black-necked spitting cobra <i>Naja nigricollis</i> bite	87
123.	Management of venom ophthalmia	90

## **Annexes**

1	Venomous Snakes of Africa: Classification, Distribution, Habitat, ClinicalToxinology	102
2	Venomous Snakes of Africa: Geographical Distribution Composite Maps	110
3	Measurement of Central Venous Pressure	123
4	Femoral Venous Access	125
5	Setting Up an Intraosseous Infusion in Children	126
6	Pressure Immobilization Method	127
7	Essential Medicines and Supplies for Managing Snakebite at a District Hospital	129

# Foreword

In November 2000, the Federal Ministry of Health of Nigeria requested the WHO Regional Office for Africa to develop guidelines for the management of snakebite due to increasing cases of snakebite in many parts of that country as well as the difficulties in obtaining sufficient quantities of effective antivenom.


In response to this request, the WHO Regional Office for Africa developed the first guidelines in 2004 with the assistance of Professor Charles Nhachi (Zimbabwe): *Guidelines for the management of snakebite in the WHO African Region (AFRO/EDP/04.1)*. Following their release, comments on the guidelines were received from various experts and this set the scene for their revision. The revision process started with a technical review meeting with various experts in Nairobi, Kenya, in November 2005.

Snakebite is a neglected public health problem mainly affecting rural populations where medical resources are sparse. Health workers in both rural and urban settings are ill prepared to deal with snakebite cases and effective antivenom is often not available. Communities need to be educated about what to do and what not to do in case of snakebite, and prior to transferring a patient to professional medical care.

The exact extent and impact of the problem is still to be determined due to lack of reliable epidemiological data in most countries. Much research is still required into various aspects of snakes and snakebite management in Africa if case fatality rates are to be reduced. It is hoped that these guidelines will provide the target audiences, health-care providers and the general public with the necessary practical information for dealing with snakes and snakebite within and outside health-care facilities.

The World Health Organization wishes to build up a coalition of partners interested in putting the problem of snakebite on the public health agenda, and in particular stimulating further collaboration and research in the following areas:

- Manufacture of sufficient quantities of effective, safe and affordable antivenoms;
- Development of effective treatment protocols and training of medical personnel;
- Development and distribution of materials for effective community education;
- Improving knowledge of the epidemiology of snakebite;
- Assessing the true safety and efficacy of traditional methods of treatment.



Dr Luis G. Sambo  
Regional Director  
WHO Regional Office for Africa

# Preface

Snakebite is a neglected public health problem. Rural populations are frequent victims as they go about their daily food production and animal rearing activities and as they reside in the comfort of their homes. Unfortunately, many of these snakebite cases go unreported and thus do not appear in official epidemiological statistics. Health workers often have little or no formal training in the management of snakebite, and appropriate antivenom is rarely available.

The *Guidelines for the prevention and clinical management of snakebite in Africa* have been developed by the World Health Organization Regional Office for Africa with contributions from technical experts. They are meant to assist health workers to improve medical care for snakebite victims; they also serve as a source of information for the general public on issues related to snakes and snakebite.

The guidelines discuss snakes, snake venoms and snakebites and their consequences with emphasis on the medically important snakes i.e. those causing serious envenoming. The volume contains over a hundred snake photographs, clinical signs of envenoming and the consequences. The guidelines also feature various annexes and in particular the geographical distribution of African venomous snakes, as well as their classification, habitats and clinical toxicology.

The document is divided into fifteen chapters. Chapters 1, 2 and 3 introduce the subject, outline the morphological characteristics of African venomous snakes, present the distribution of African venomous snakes and provide epidemiological data on snakebite. Chapter 4 is specifically devoted to prevention of snakebite. Chapters 5, 6 and 7 discuss snake venoms as well as clinical features and profiles of envenoming by some snakes of medical importance. Chapters 8 and 9 outline the main clinical syndromes of envenoming in Africa and provide guidance to clinical assessment and diagnosis. Chapter 10 provides information on antivenoms and major suppliers of antivenoms. Chapters 11 and 12 discuss first aid and emergency clinical management of snakebite. Chapters 13, 14 and 15 discuss procedures for antivenom treatment and management of snakebite at community level and different health-care facilities as well as ancillary treatments.

The guidelines are designed to provide useful information and guide the work of various levels of health workers in dealing with snakes and snakebite. Some sections provide useful and easily understood information for the general public on topics such as snake characteristics and distribution, prevention of snakebite, first aid in case of snakebite, easily observable venom effects in a snakebite victim, and what not to do in case of snakebite.

The guidelines also mention traditional practices and beliefs in relation to snakes and snakebite. They emphasize the fact that there are no scientifically proven traditional antidotes to snake venoms. However, in many rural settings, traditional healers may have a good knowledge of snakes within their environment and they can be useful resource persons in the conduct of community education programmes about snakes and snakebite.

For any further information, comments and suggestions concerning the guidelines, please contact:

WHO Regional Office for Africa  
P.O. Box 6 Brazzaville, Republic of Congo  
Tel: + 47 241 39258; Fax: + 47 241 39511  
E-mail: [regafro@afro.who.int](mailto:regafro@afro.who.int)

# Acknowledgements

The development of these guidelines has been ongoing since November 2005 under the initiative of the Essential Medicines Programme, Division of Health Services and Systems Development, WHO Regional Office for Africa. The first complete working draft was produced in December 2007 with contributions from the following experts and to whom the World Health Organization is very grateful:

Mrs Sanda Ashe, Bioken Snake farm, Watamu, Kenya;  
Dr Roger Blaylock, South African Vaccine Producers, Sandringham, South Africa;  
Dr Moses G.P. Chisale, WHO Regional Office for Africa, Intercountry Support Team, Central Africa, Libreville, Republic of Gabon;  
Dr Gert J. Müller, University of Stellenbosch, Tygerberg, South Africa;  
Prof Charles F.B. Nhachi, University of Zimbabwe Medical School, Harare, Zimbabwe;  
Dr Joanna H. Tempowski, WHO Headquarters, Geneva, Switzerland;  
Prof David A. Warrell, University of Oxford, United Kingdom.

The above experts tirelessly reviewed the initial and subsequent drafts leading to the present version of the guidelines. WHO is also grateful for inputs from the following people who have taken part in the revision process: Prof Willy Anokbongo (Uganda); Dr Abdulsalami Nasidi (Nigeria); Mrs Damaris Rotich (Kenya) and Mr Rashid M. Kaka (Kenya).

This document has been produced with the financial assistance of the European Community and the Department for International Development (DFID), UK. The views expressed herein are those of the authors and can therefore in no way be taken to reflect the official opinion of the European Community or DFID.



# Abbreviations

20WBCT	20 minute whole blood clotting test
ACE	Angiotensin converting enzyme
aPTT	Activated partial thromboplastin time
CPR	Cardio-pulmonary resuscitation
D-dimer	Cross-linked fibrin degradation fragment (D for domain)
DNA	Deoxyribonucleic acid
ECG	Electrocardiogram
F(ab') <sub>2</sub>	Pepsin digestion product of immunoglobulin G lacking Fc
FDP	Fibrin (ogen) degradation products
HIV	Human immunodeficiency virus
HTLV1	Human T-lymphotropic virus Type I
IgE	Immunoglobulin E
IgG	Immunoglobulin G
INR	International normalized ratio (prothrombin time)
kDA	Kilodalton NAD Nicotinamide adenine dinucleotide
PO <sub>2</sub>	Partial pressure of oxygen
pH	Cologarithm of activity of dissolved hydrogen ions
PI	Pressure-immobilization
PLA <sub>2</sub>	Phospholipase A <sub>2</sub>
PCO <sub>2</sub>	Partial pressure of carbon dioxide
PR ECG	Interval between P and R waves of the electrocardiograph
PT	Prothrombin time
RAST	Radio allergo sorbent test
SAVP	South African Vaccine Producers
ST-T ECG	Segment between the S and T waves of the electrocardiograph
WHO	World Health Organization

# Chapter 1

## Introduction

Despite urbanization and destruction of their habitat, venomous snakes remain plentiful in most parts of Africa. Throughout the continent, snakes are feared and misunderstood even though most are harmless. Venomous snakes bite humans only when they feel threatened, are trodden on or picked up inadvertently. Snakes are creatures that inspire awe, reverence and even worship in some areas, and they are exhibited as performing animals by traditional snake charmers.

Despite this, they are usually loathed and killed on sight. Their survival depends on their remaining undetected. Snakes co-exist with humans in homes, gardens and outhouses but their presence usually goes unnoticed.

Fear of snakes is understandable since they are responsible for an untold number of bites and numerous deaths as well as cases of permanent physical handicap. No country is free from the risk of snakebite, and in

some rural areas, such as the Benue Valley of northern Nigeria, snakebite is a leading cause of morbidity and mortality among farmers, pastoralists, hunters and children. Snakes such as puff adders (*Bitis arietans*) (Figure 1) also kill and injure many domestic dogs and grazing animals.

The exact burden of human suffering attributable to snakebite is difficult to determine because bites occur most commonly in rural areas where the first impulse of many bite victims is to seek the help of a trusted traditional healer rather than go to a Western-style hospital where their attendance may be recorded and reported to a national authority (Warrell, 1992).

The inadequacy of official snakebite statistics is well illustrated by Swaroop and Grab's survey of global snakebite mortality (Swaroop and Grab, 1954). During a six-year period 1947–52, an annual average of 27.7 snakebites with 1.5 deaths per 100 000 population was reported in the whole of the northern region of Nigeria. However, in the six-year period 1964–69, an annual average of 158.8 bites with 8.3 deaths per 100 000 population was reported from one district

(Muri) with a population of some 250 000 people (Warrell and Arnett, 1976). Some epidemiological data on snakebite in African countries are presented in Chapter 3 but the figures are likely to underestimate the true magnitude of the problem.

© David A. Warrell



Figure 1: Puff adder *Bitis arietans* Abuja, Nigeria

A possible way to obtain reliable figures is by completing questionnaires in randomly selected households as part of a properly designed community-based study. Only a few such studies have been published from Africa. In Bandafassi, Senegal (Trape et al, 2001); Muri Division, Nigeria (Warrell and Arnett, 1976); Kilifi, Kenya (Snow et al, 1994); and Malumfashi, Nigeria (Pugh et al, 1980); 14, 8, 7 and 4 adult snakebite fatalities per 100 000 population per year, respectively, were reported.

These studies revealed an unexpectedly high rate of snakebite mortality and confirmed the low rate of hospital attendance (8.5% in Malumfashi, 27% in Kilifi), the preference for traditional treatments (36% of Kilifi patients visited the traditional therapist) and high incidence of persisting symptoms among survivors (19% in Malumfashi, 36% in Kilifi) including some amputations and deformities. Snakebite is an important public health problem in these areas and deserves far more attention from health ministries and other authorities.

African populations are not equally affected by snakebite. Children account for 20%–40% of cases in most published studies. Farmers and other agricultural workers are the most common victims. The occupational aspect of snakebite must be better appreciated as the targeted workers, which include farmers, plantation workers, herdsmen and hunters, are prime food producers and therefore particularly valuable members of the community.

Although snakes are almost universally feared and even hated, their essential role in the balance of nature must not be forgotten. They protect crops and food stores by preying on large numbers of rodents. Without this control, burgeoning numbers of rodents might cause epidemics of plague, typhus, leptospirosis, Lassa fever and other potentially lethal diseases that are transmitted from rodents to humans. Larger snakes such as pythons and *Bitis* species are frequently eaten as delicacies and valuable protein supplements, and also as part of various *ju-ju* rituals in West Africa. Humans can become infected with *Armillifer armillatus* (pentastomid), a parasite of the respiratory tract of snakes, by eating uncooked snakes. Calcified nymphs of this pentastomid were found in 1.4% of abdominal radiographs in Ibadan, Nigeria and in 22.5% of autopsies in Democratic Republic of Congo, 8% in Cameroon and 5% in West Africa (Palmer and Reeder, 2001). These observations show how commonly snakes are eaten in Africa.

Goats, sheep, domestic fowl and pets should be protected from pythons, but these snakes are valuable in controlling the numbers of feral cats and dogs. Elimination or eradication of snakes, even if it were possible, is therefore undesirable. Snake predators such as storks, hornbills, small carnivorous mammals and monitor lizards control their numbers. It is clear that, despite the very real risk of snakebite, humans must learn to co-exist peacefully with snakes, respecting their place in nature while minimizing the danger they pose by avoiding them as far as possible.

# Chapter 2

## Morphological characteristics of African venomous snakes

From a medical perspective, the venomous snakes of Africa can be divided into five categories:

Category 1: Snakes that bite frequently, and are associated with serious or life-threatening envenoming

Category 2: Snakes that bite frequently, but rarely cause serious or lifethreatening envenoming

Category 3: Snakes that bite rarely, but are capable of causing severe or lifethreatening envenoming

Category 4: Snakes that bite rarely, and have not caused significant envenoming

Category 5: Other potentially venomous snakes which have not caused documented bites

**2.1 Category 1: Snakes that bite frequently, and are associated with serious or lifethreatening envenoming (see Annex 1 for distribution and habitat and Annex 2 for geographical maps)**

### **2.1.1 Saw-scaled or carpet vipers (Genus *Echis*) (Annex 2, Map 1)**

A recent revision of the genus *Echis* recognizes five species that occur in Africa (Pook et al, 2009). *Echis* are relatively small slender-bodied snakes with overlapping keeled scales. The scales on the flanks have serrated keels. When the snake rubs its coils together in fear or irritation, a rasping sound is produced which is easily recognized and forms the basis of many onomatopoeic local names (e.g. *kububuwa* in Hausa; *kurot* in Tangale, *fufukr* in Bura, *for'doyre* in Fulani) (Warrell and Arnett, 1976). There are five species complexes currently recognised.

**2.1.1.1** Burton's carpet viper (*Echis coloratus*) (Figure 2). Average length 30–60 cm (maximum length 80 cm). The colouring is variable; ground colour grey, brown, blue or pink with a series of large, pale, oval patches along the dorsum with dark edges connected to a row of dark spots on each flank.

© David A. Warrell



**Figure 2: Burton's carpet viper *Echis coloratus* Saudi Arabia**



2.1.1.2 Joger's carpet viper (*Echis jogerii*). (Figure 3). Length about 30 cm. Colouring resembles *E. ocellatus*. Distinguished by lower ventral scale counts. Reported from Mali and Senegal.

© Wolfgang Wüster



**Figure 3: Joger's carpet viper *Echis jogerii* Bandafassi, Senegal**

2.1.1.3 White-bellied carpet viper (*Echis leucogaster*). (Figures 4 and 5). Average length 30–70 cm (maximum length 87 cm). The colour and dorsal pattern resemble *E. pyramidum* (Figures 6 and 7). The undulating pale line on the flanks is usually incomplete, producing a series of inverted Ushaped or crescentic marks either side of the dorsal series of pale patches, which sometimes form a zigzag pattern. The belly is pure white (Figure 5).

© Mark O'Shea



**Figure 4: White-bellied carpet viper *Echis leucogaster***



© D.A. Warrell

**Figure 5: White-bellied carpet viper *Echis leucogaster* Sokoto, Nigeria showing completely white ventral scales**

2.1.1.4 West African or ocellated carpet viper (*Echis ocellatus*) (Figure 6). Average length 30-50 cm (maximum length 70 cm). A reddish-brown or greyish snake with pale oval or rhomboidal dorsal markings connected by a dark median band and flanked by white spots ("eyes") bordered with black scales. The belly is white, heavily spotted with black.



© David A. Warrell

**Figure 6: West African or ocellated carpet viper *Echis ocellatus* Kaltungo, Nigeria**

2.1.1.5 Egyptian carpet viper (*Echis pyramidum*). (Figures 7 and 8) Average length 30-60 cm (maximum length 85 cm). The colour is greyish, brownish or reddish brown, with white dorsal oval markings connected by a dark band and flanked by a more or less complete pale undulating line. The belly is pale.

© Tomas Mazuch Warrell



**Figure 7: Egyptian carpet viper *Echis pyramidum leakeyi* Archer's Post, Kenya**

© David A. Warrell



**Figure 8: Egyptian carpet viper *Echis pyramidum leakeyi* Baringo, Kenya**

### 2.1.2 Large African adders or vipers (Genus *Bitis*) (Map 2)

All have relatively thick bodies with flattened heads and upward-pointing nostrils, keeled scales and very short tails.

2.1.2.1 Puff adder (*Bitis arietans arietans*) (Figures 1, 9 and 10). (*Bitis arietans* is most probably a species complex.). This is a very large, heavy bodied snake, maximum total length exceeding 190 cm. Its colour is almost black, brown, reddish or even orange

above, with distinctive pale, black edged U or V marks along the dorsum becoming annular rings around the tail. The belly is pale with blackish marks. It inflates its body and hisses loudly by expelling air through its dorsally placed nostrils (Figure 10) when threatened.

2.1.2.2 Somali puff adder (*Bitis arietans somalica*). It differs from *Bitis arietans arietans* only in that it has keeled sub caudals, which may be an aid to side winding.



© David A. Warrell

**Figure 9: Puff adder *Bitis arietans* Nigeria**



© David A. Warrell

**Figure 10: Puff adder *Bitis arietans* Garki, Nigeria, dorsal view of head nostrils**



**2.1.3 Spitting or cytotoxic cobras (Genus *Naja*) (Map 3)**

The spitting or cytotoxic cobras include the following six species (Wüster et al, 2007).

**2.1.3.1** West African brown spitting cobra (*Naja katiensis*). Average total length 50–80 cm (maximum 100 cm). Chestnut brown, maroon, paler on the ventral surface, with one or two reddish, brownish or black bands below the neck. A broad dark band on the underside of the neck may form a ring, which may fade in large specimens.

**2.1.3.2** Mozambique spitting cobra or m'Fezi (*Naja mossambica*) (Figure 11). Average total length 80–130 cm (maximum 150 cm). The colour is grey, olive or brown. Scales are dark-edged. The belly is pale or salmon pink, with black crossbars, half-bars, blotches and spots on the neck, throat and anterior third of the belly.



**Figure 11: Mozambique spitting cobra *Naja mossambica***

**2.1.3.3** Red spitting cobra (*Naja pallida*) (Figure 12). Average total length 70–120 cm (maximum 150 cm). Orange or red with a broad black throat band. Other specimens may be pale red, pinkish, yellow or steel grey.



© David A. Warrell

**Figure 12: Red spitting cobra *Naja pallida* Watamu, Kenya**

**2.1.3.4** Black-necked spitting cobra (*Naja nigricollis*) (Figure 13). Average total length 100–150 cm (maximum 220 cm). In West Africa it is dark grey, black or brown above and below with pinkish red throat bands, this colour being replaced by yellowish or pale brown in East Africa. The barred or zebra spitting cobra (*Naja nigricincta*) (Figure 14), average total length 80–120 cm (maximum 150 cm), is distinctly barred in black and white or red. The black spitting cobra (*Naja nigricincta woodi*) (Figure 15) (maximum total length 180 cm) is uniformly black.

**2.1.3.5** Ashe's spitting cobra (*Naja ashei*) (Figure 16) a newly recognized species is largely sympatric with *N. pallida* in East Africa. Maximum total length 215 cm (probably 270 cm). They are olive brown with a pale



© David A. Warrell

**Figure 13: Black-necked spitting cobra**



© Mark O'Shea

**14: Zebra spitting cobra  
cobra *Naja nigricollis* Abuja, Nigeria  
*Naja nigricincta* Namibia**



© David A. Warrell

**Figure 15: Wood's black spitting cobra *Naja nigricincta woodi* Springbok, Northern Cape, South Africa**

2.1.3.6 *Naja nubiae* (Figure 17), a new recognized species, can be differentiated from *Naja pallida*, with which it was until recently confused, by its throat and neck pattern. *N. nubiae* has two bands instead of one (*N. pallida*) across the neck. There is also a distinct light throat area before the main



© David A. Warrell

**Figure 16: Ashe's spitting cobra *Naja ashei* Watamu, Kenya**

belly and no red, orange or pink markings on the throat. Ventral and dorsal scale row counts are consistently higher than other East African spitting cobras (herp-Wüster and Broadley, 2007).



© David A. Warrell



**Figure 17: Nubian spitting cobra *Naja nubiae***

throat band, and practically all specimens feature a small dark spot on each side of the throat (herp-Wüster and Broadley, 2003).

#### 2.1.4 Neurotoxic cobras (Genus *Naja*) (Map 4)

The neurotoxic cobras include the following four snakes.

**2.1.4.1 Snouted ("banded") cobra (*Naja annulifera*)** (Figure 18). This is one of Africa's largest cobras, average total length 120-180 cm (maximum exceeding 250 cm). Dorsally they are yellowish to greyish brown, dark brown or blue-black. Below, yellow with darker mottles. A banded phase occurs throughout the range which is blue-black with 7-11 yellow to yellow-brown crossbars.

© Tony Phelps



**Figure 18: Snouted ("banded") cobra *Naja annulifera* Limpopo, South Africa**

**2.1.4.2 Egyptian cobra (*Naja haje*)** (Figure 19). Average total length 150-200 cm (maximum 220 cm). The colour is extremely variable: black, brown, grey, reddish or

yellow on the dorsal surface, with a paler grey, brownish or yellowish ventral surface, with bands or blotches of darker colour and commonly a dark band below the neck. Unlike in spitting cobras, the supralabial (upper lip) scales of *N. annulifera* and *N. haje* are separated from the orbit by small subocular scales.



© David A. Warrell.

**Figure 19: Egyptian cobra *Naja haje* Zaria, Nigeria**

**2.1.4.3 Senegalese cobra *Naja senegalensis*** (Figure 20). Length up to 2.3 m, average just over 1 m. Uniformly dark grey or brown above, sometimes with a pale blotch on the dorsum of the hood. Throat dark with pale cross bands. Ventral surface yellowish. Reported from savanna of Senegal east to south-west Niger and Western Nigeria.



© David A. Warrell.

**Figure 20: Senegalese cobra *Naja senegalensis* Dielmo, Senegal**

2.1.4.4 Cape cobra (*Naja nivea*) (Figures 21 and 22). Average total length 120–140 cm (maximum 170 cm). The colour is extremely variable, ranging from bright yellow, brown, reddish brown to black. Lighter colour variations often have brown speckles.



© Tony Phelps

**Figure 21: Cape cobra *Naja nivea* De Hoop, Western Cape, South Africa, male basking**



© John Visser

**Figure 22: Cape cobra**

## 2.1.5 Mambas (Genus *Dendroaspis*) (Map 5)

Mambas are very long, thin, alert, nervous, fast moving and agile, arboreal or terrestrial, highly dangerous venomous snakes.

2.1.5.1 Common or eastern green mamba (*Dendroaspis angusticeps*) (Figures 23 and Figure 24). The total length rarely exceeds 2.5 m. This species is coloured uniformly bright green and is strictly arboreal.



© David A. Warrell

**Figure 23: Eastern green mamba *Dendroaspis angusticeps* Gede, Kenya, showing fangs**



© David A. Warrell

**Figure 24: Eastern green mamba *Dendroaspis angusticeps* Richard's Bay, South Africa**

2.1.5.2 Traill's, Jameson's, green forest or western green mamba (*D. jamesoni*) (Figure 25). Average total length exceeds 120 cm (maximum 366 cm). The colour is bright green to yellowish green. The scales are edged with black. This species is mainly arboreal and, in defence, it spreads a hood or inflates its throat.



© David A. Warrell

**Figure 25: Traill's mamba *Dendroaspis jamesoni kaimosi* Kakamega, Kenya**



2.1.5.3 Black or black-mouthed mamba (*Dendroaspis polylepis*) (Title Page and Figures 26 and 27). The average total length is 220–270 cm (maximum 420 cm). It is more heavily built than other mambas and coloured greyish brown or olive brown with a black buccal lining. In defence, it rears up, distending a small hood, opening its mouth and hissing.



© David A. Warrell.

**Figure 26: Black mamba *Dendroaspis polylepis* Gede, Kenya showing fangs and black buccal lining**



© David A. Warrell.

**Figure 27: Black mamba *Dendroaspis polylepis***

2.1.5.4 Hallowell's or western green mamba (*Dendroaspis viridis*). The maximum total length is 210 cm. Its colouring is similar to that of *D. jamesoni*. It inflates its throat and spreads a small hood in defence.

## 2.2 Category 2: Snakes that bite frequently, but rarely cause serious or life-threatening envenoming

### 2.2.1 African burrowing asps (*Genus Atractaspis*) (Map 6).

Burrowing asps are found in a wide variety of habitats, including desert, semi-desert and lowland forests. They are fossorial (burrowing), living mostly underground in deserted termite mounds, under stones or logs, or in soft soil or sand. They are coloured predominantly grey, black or brown. Most are relatively small (30–70 cm in length). They are glossy, with a head indistinct from the neck. A very short tail ends abruptly, giving the snake a “two-headed” appearance reflected in local names such as *bida-bida* (Hausa, Nigeria). These snakes are easily confused with several species of non-venomous black snakes. The head is short with tiny dark looking eyes. These snakes are nocturnal and usually emerge on warm, wet summer evenings, especially after heavy rains. When the snake bites (strikes), one fang is protruded out of the side of the mouth and is then hooked or jabbed into the victim with a backward jerk of the head (“side swipe”) (Figure 28). They are extremely irritable, striking in sideways swings and sweeps (multiple bites), and showing annoyance by flattening the body. Accidental bites usually occur at night when the victim treads on the snake in a gutter or water-logged path after heavy rain.

The burrowing asps, for which bites have been reported, include:

- 2.2.1.1 Slender burrowing asp (*Atractaspis aterrima*), (Figure 28);
- 2.2.1.2 Southern or Bibron's burrowing asp (*A. bibronii*);

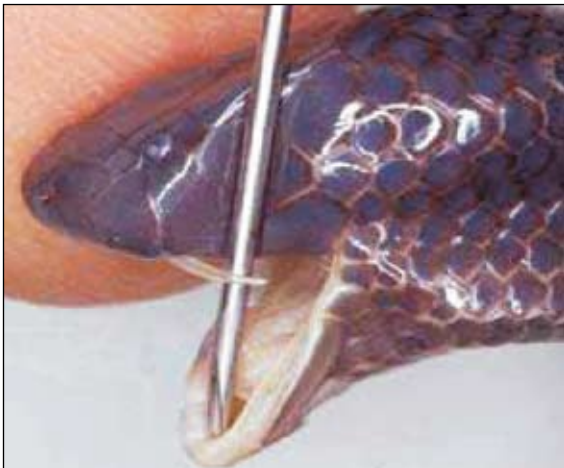- 2.2.1.3 Hallowell's burrowing or fat burrowing asp (*A. corpulenta*);
- 2.2.1.4 Brown or Dahomey burrowing asp (*A. dahomeyensis*);
- 2.2.1.5 Ein Geddi, Israeli burrowing asp (*A. engaddensis*);
- 2.2.1.6 Variable or Reinhardt's burrowing asp (*A. irregularis*);
- 2.2.1.7 Small-scaled burrowing asp [*Atractaspis (microlepidota) fallax*] (Figure 29);
- 2.2.1.8 Natal black snake (*Macrelaps microlepidotus*).

## 2.2.2 African night adders (Genus *Causus*) (Map 7)

The night adders are small (less than 100 cm) and, despite their name, are active by day and by night. They are not adder-like, and are fairly stout with the head being only slightly distinct from the neck. The venom fangs are short compared to those of genus *Bitis*. They have round pupils (most adders have vertical slit eye pupils) and large symmetrical scales on top of the head (most vipers have small scales). When threatened, they hiss and puff ferociously, inflating the body to a great extent. They may also raise the forepart of the body off the ground and slide forward with the neck flattened, looking quite cobra-like.

2.2.2.1 Snouted night adder (*Causus defilippii*) (Figures 30 and 31). Average total length 20-35 cm (maximum 42 cm). It has a relatively thick body, with pointed upturned snout. The colour is brownish, greenish or greyish, with a dorsal series of dark rhomboidal or V-shaped markings, extending to dark stripes on the flanks. It has a prominent dark V-shaped mark on the top of the head, the apex of which extends to between the eyes.

© David A. Warrell.



**Figure 28: Slender burrowing asp *Atractaspis aterra* Nigeria**

© David A. Warrell.



**Figure 29: Small-scaled burrowing asp *Atractaspis (microlepidota) fallax* Watamu, Kenya**



**Figure 30: Snouted night adder *Causus defilippii* Matopos, Zimbabwe**

© David A. Warrell.



© David A. Warrell.



**Figure 31: Snouted night adder *Causus defelipii* head Matopos, Zimbabwe**

**2.2.2.2** Forest, small, Lichtenstein's or olive green night adder (*C. lichtensteini*). Average total length 30–55 cm (maximum 70 cm). The colour is green, olive, yellowish or grey, without a marking on the head. There is a V-marking on the neck and dorsal black chevrons, facing forwards or backwards.

**2.2.2.3** Western rhombic night adder (*C. maculatus*) (Figure 32). Average total length 30–60 cm (maximum 70 cm). The colour is greyish, brownish or olive green, with large dark edged V-markings on its head and neck. There are a number of dark brown or blackish patches all along the back and a sprinkling of black scales on the flanks. The belly may be white, cream or pinkish grey.

**2.2.2.4** Eastern rhombic night adder (*C. rhombeatus*) (Figures 33 and 34). Average total length 30– 60 cm (maximum 100 cm). The head has a distinct dark brown or black forward pointing V-shaped marking, the apex of which extends to between the eyes. There are 20–30 dark, pale-edged rhombic blotches all along the back. The belly is pearly white to yellowish or light grey, with or without dark mottling.



**Figure 32: Western rhombic night adder *Causus maculatus* Zaria, Nigeria**

© David A. Warrell.



**Figure 33: Eastern rhombic night adder *Causus rhombeatus* Durban, KwaZulu Natal, South Africa**

© David A. Warrell.



**Figure 34: Eastern rhombic night adder *Causus rhombeatus* Richard's Bay, South Africa**

© David A. Warrell.

### 2.2.3 North African sand or desert horned-vipers (*Genus Cerastes*) (Map 8)

These are relatively small, thick-bodied, side-winding desert snakes, with markedly keeled and serrated scales. They live in desert and semi-desert and can sidewind. They are nocturnal and terrestrial, often hiding by burying themselves in sand. When threatened, they form S-shaped coils which are rubbed together, producing a rasping or crackling sound.

**2.2.3.1** Saharan horned-viper (*Cerastes cerastes*) (Figures 35, 36 and 37). Average total length 30–60 cm (maximum 85 cm). A whitish, greyish, yellow or brown snake with a dorsal series of paired or confluent darkish blobs and three dark spots on the cheeks. The distinctive supra-orbital “horns”, up to 5-6 mm long, are sometimes absent. Gasperetti’s or Arabian horned-viper (*C. gasperettii*) occurs in the Middle East but not in Africa as defined for these guidelines (herp-Werner et al, 1991).



© David A. Warrell.

**Figure 35: Saharan horned-viper *Cerastes cerastes***



© David A. Warrell.

**Figure 36: Saharan horned-viper *Cerastes cerastes***



© David A. Warrell.

**Figure 37: Saharan horned-viper *Cerastes cerastes***

**2.2.3.2** Saharan sand viper (*Cerastes vipera*) (Figure 38). Average total length 20–35 cm (maximum 48 cm). The colour is yellowish or pinkish, with dorsal pairs of alternating brownish spots. There are no supra-ocular “horns”.



© Mark O'Shea

**Figure 38: Saharan sand viper *Cerastes vipera***



## 2.3. Category 3: Snakes that bite rarely, but are capable of causing severe or life-threatening envenoming

### 2.3.1 Boomslang (*genus Dyspholidus*) (Map 9)

**2.3.1.1 Boomslang (*Dyspholidus typus*)** (Figures 39 and 40) is widely distributed in sub-Saharan Africa and is the only species in this genus. Average total length is 120–150 cm. It has a short chunky head with very large emerald green eyes. The colour may vary from green, brown, black to reddish, with a lighter ventrum. Females have whitish to brown bellies. Boomslangs are diurnal, arboreal, unobtrusive and non-aggressive. If cornered or restrained, they inflate the anterior part of the body to an impressive extent and strike. However, most require great provocation before biting and engaging its rear fangs (Figure 41). The boomslang is often confused with the green mamba and the harmless green bush snakes (*genus Philothamnus*).



© Tony Phelps

**Figure 39: Boomslang *Dyspholidus typus* male Western Cape, South Africa**



© David A. Warrell

**Figure 40: Boomslang *Dyspholidus typus* South Africa**



© John Visser

**Figure 41: Boomslang *Dyspholidus typus* showing rear fang**

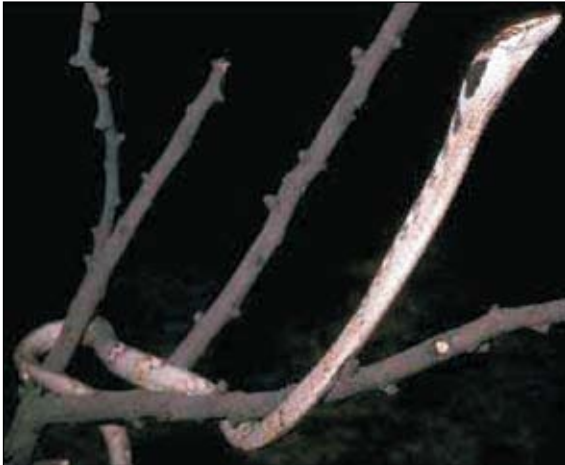### 2.3.2 Vine, bird, twig or tree snakes (*Thelotornis* spp.) (Map 9)

These very slender tree snakes occur throughout the forest and savanna regions of sub-Saharan Africa. Average total length is 80–120 cm. They are cryptically coloured and difficult to detect, favouring low bush, shrubs and dead tree-stumps and resembling branches or twigs. The head is lance-shaped with a keyhole-shaped pupil. If threatened, it will inflate the first half to two-thirds of its body like the boomslang. Bites are rare; snake keepers and catchers are most at risk.

**2.3.2.1 South-eastern savanna vine snake (*Thelotornis capensis*)** (Figures 42, 43 and 44).

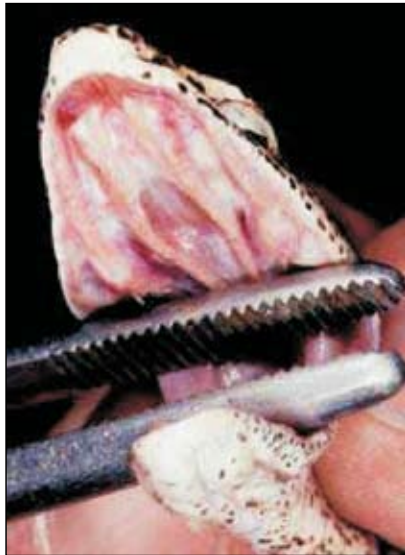**2.3.2.2 Forest vine, twig snake (*Thelotornis kirtlandii*).**

© David A. Warrell.



**Figure 42: Vine snake *Thelotornis capensis* Johannesburg, South Africa**

© David A. Warrell.



**Figure 43: Vine snake *Thelotornis capensis* Johannesburg, South Africa, showing fang**

© David A. Warrell.



**Figure 44: Vine snake *Thelotornis capensis oatesii* northern Zimbabwe**

**2.3.2.3** Montpellier snake (*Malpolon monspessulanus*). Maximum total length 250 cm and weight 3 kilograms. The colouring is very variable from uniform greyish, brownish-red, olive to blackish. The eyes are very large with prominent brow ridges. Diurnal, agile and aggressive, hissing, inflating the front of the body and flattening the neck and striking if provoked. It occurs in North Africa.

### **2.3.3 Other neurotoxic cobras (*Naja anchietae* *N. melanoleuca*) (Map 4)**


**2.3.3.1** Anchieta's Egyptian cobra (*Naja anchietae*). Average total length is 100 cm. Both plain and banded phases exist. Dorsally the colour varies from brown, through purple to almost black. Lighter ventrally. The banded phase has seven yellowish bands on the body and two on the tail.

**2.3.3.2** Forest, black-and-white-lipped cobra (*Naja melanoleuca*) (Figure 45). This is the largest African cobra. Average total length is 150–200 cm (maximum 270 cm). The head, neck and forepart of the body are usually yellowish brown, heavily flecked with black speckles. The sides of the head are strikingly marked with black and white bars (from there the name black-and-white-lipped cobra).



© David A. Warrell.

**Figure 45: Forest cobra *Naja melanoleuca***



© David A. Warrell.

**Figure 46: West African forest cobra *Naja melanoleuca* Sokoto, Nigeria**

In the West African savanna region this species is banded black and yellow (Figure 46). Those from the forests of Sierra Leone to Kenya and Angola are glossy black, having a cream or white throat, and the anterior part of the belly has broad crossbar markings. Specimens from the East African coast have an olive forebody and may lack black-and-white barring on the sides of the head.

**2.3.4 Rinkhals (*Hemachatus haemachatus*) (Map 3)**

2.3.4.1 The Rinkhal (Figure 47) is a diurnal, cobra-like elapid snake. It rears its head and

spreads a wide hood, and when threatened spits venom up to two metres towards the eyes of an aggressor. In the fangs the venom canal bends sharply upwards before its exit orifice so that the venom can be squeezed out in a fine stream under pressure. The body is relatively thick set and flattened compared with cobras, and is speckled black/brown and white with dark and light bands (see Figure 87). If severely threatened or cornered it will “play possum” (sham death) very convincingly, rolling over onto its back and lying motionless, with head twisted and mouth agape.



© David A. Warrell.

**Figure 47: Rinkhal *Hemachatus haemachatus* Johannesburg, South Africa**



### 2.3.5. Desert black snakes/cobras or Walter Innes's snakes (*Walterinnesia aegyptia*)

2.3.5.1 This species is uniformly glossy jet black, with bluish-black underparts (Figure 48). Average total length 80–120 cm (maximum 130 cm). It lives underground in rodent burrows. It is said to be aggressive, rearing its head without spreading a hood and hissing in defence. It is easily mistaken for a large burrowing asp (*Atractaspis*).



Figure 48: Desert black snake *Walterinnesia aegyptia*

### 2.3.6. Yellow-bellied sea snakes (*Pelamis platurus*)

2.3.6.1 The yellow-bellied sea snake has an average total length of 60–70 cm. The head is narrow and flattened, with an elongated snout (Figure 49). The colour is usually black above and yellow to yellow brown below, but the coloration may be extremely variable. The oar-shaped tail has distinct black and yellow reticulated markings. A second species of sea snake (beaked sea snake, *Enhydrina schistosa*) has been reported from Madagascan shores.



Figure 49: Yellow-bellied sea snake *Pelamis platurus* South Africa

### 2.3.7 Bush or tree vipers (Genera *Atheris*, *Proatheris*, *Montatheris* and *Adenorhinos*)

Bush vipers are relatively small (maximum total length 78 cm), mainly arboreal snakes inhabiting forests of tropical Africa. Two species (*Proatheris superciliaris* and *Montatheris hindii*) are terrestrial. They have a broad head, narrow neck and a slender tapering body. Most species have small, rough overlapping scales and prehensile tails. The eyes are relatively large with vertical pupils.

2.3.7.1 Horned or Usambara forest viper (*Atheris ceratophora*) (Figure 50). Maximum total length 54 cm. This arboreal snake has three hornlike scales above each eye. The colour is dark olive green above, with black spots forming crossed bands. The belly is pale olive, and speckled with black.

2.3.7.2 West African or Schlegel's green tree viper (*A. chlorechis*) (Figure 51). Maximum total length 72 cm. The colour is pale green, darker on the sides and towards the tail and paler below with paired yellow spots along the dorsal surface.



Figure 50: Horned forest viper *Atheris ceratophora*



Figure 51: West African tree viper *Atheris chlorechis*, Côte d'Ivoire



**2.3.7.3** Hallowell's green tree or bush viper (*Atheris squamigera*) (Figure 52). Maximum total length 78 cm. The colour is very variable, ranging from greenish-brown to red.

**2.3.7.4** Mount Kenya bush viper (*A. desaixi*) (Figure 53). Average total length 40–60 cm. Thick-bodied with green-black to charcoal-black body. The belly is yellow in front, becoming purplish-black to the rear.



**Figure 52: Hallowell's bush viper *Atheris squamigera* Kenya**



**Figure 53: Mount Kenya bush viper *Atheris desaixi***


**2.3.7.5** Lowland, swamp or flood plain viper (*Proatheris superciliaris*) (Figure 54). Maximum total length exceeds 60 cm. Most are coloured shades of green, varying from yellowish-green to almost blue. The belly may vary from yellowish to dark green.



**Figure 54: Lowland viper *Proatheris superciliaris***

**2.3.8 Gaboon adders (*B. gabonica*, *B. rhinoceros*, *B. nasicornis*) (Map 2)**

**2.3.8.1** Eastern Gabon/Gaboon viper or forest puff adder (*Bitis gabonica*) (Figures 55 and 56). Maximum total length may exceed 200 cm with a girth of 470 mm, a weight exceeding 12 kg and fangs 55 mm long. This snake is one of the heaviest venomous snakes in the world. It has small "nose horn" scales and two distinctive black triangles beneath each eye. The colouring is brilliant, like an oriental carpet. There is a dorsal series of pale brownish or yellowish elongated rectangles, having rounded or pointed ends, with dark triangles at their anterior and posterior ends. The flanks bear a complicated series of triangular-shaped yellow or pale brownish areas, edged with dark scales and separated by brown, purple and yellow areas. The belly is yellowish, blotched with brown or black. The dorsum of the head is pale, apart from a narrow, dark median line.



**Figure 55: Gaboon viper *Bitis gabonica***

© David A. Warrell.

© David A. Warrell.

© David A. Warrell.

© Tony Phelps



**Figure 56: Gaboon viper *Bitis gabonica* St Lucia, KwaZulu Natal, South Africa**

**2.3.8.2** Western Gaboon/Gabon or rhinoceros adder or viper (*Bitis rhinoceros*) (Figure 57). Maximum total length 12 cm. The snake is named for its large nasal horns. Morphologically similar to that of *Bitis gabonica* except that there is only one distinctive sub-ocular black triangle beneath each eye.

© David A. Warrell.



**Figure 57: Rhinoceros viper *Bitis rhinoceros* Ghana**

**2.3.8.3** Nose-horned or rhinoceros-horned viper or riverjack (*Bitis nasicornis*) (Figure 58). Average total length 60–90 cm (maximum 120 cm). A heavily built, semi-arboreal snake, with long “nose-horn” scales). On the end of the nose is a cluster of two to three pairs of horn-like scales, the front pair may be quite long (Figure 59). Its overall geometric colour pattern is similar to that of *Bitis gabonica*. However, it has brighter and more vivid colours. The top of the head is blue or green, the belly is dirty white to dull green,

with numerous black and grey blotches. The scales are very sharply keeled. Unlike *B. gabonica* and *B. rhinoceros*, the dorsum of the head bears a large dark arrow-shaped marking.



© David A. Warrell.

**Figure 58: Nose-horned viper *Bitis nasicornis***



© David A. Warrell.

**Figure 59: Nose-horned viper *Bitis Nasicornis* Kumba, Cameroon, showing long nasal horns**

### **2.3.9 Small (dwarf) adders (Genus *Bitis*) (Map 11)**

**2.3.9.1** Berg adder or Cape mountain adder (*Bitis atropos*) (Figure 60). Average total length 30–40 cm (maximum 60 cm). This small, stoutly built viper is greyish-olive to dark brown with two rows of triangular black dorsal markings and lateral rows of square markings. The chin and throat are usually



flesh pink or yellowish, while the belly is off-white with grey infusions. It lacks raised ridges above the eyes.

**2.3.9.2** Péringuey's desert or side-winding adder (*Bitis peringueyi*) (Figure 61). Average total length 20–25 cm (maximum 33 cm). A very small, orangey brown snake with three longitudinal often ill-defined rows of dark dorsal spots. The spots on the sides are often pale centred. The belly is uniformly white or white with dark reddish spots on the sides. It lacks horns and the eyes are placed on top of the head. It is the only small adder that inhabits the true Namib Desert. It is well known for its ability to side-wind leaving S-shaped tracks in the sand.



© Tony Phelps

**Figure 60: Berg adder *Bitis atropos* Betty's Bay, Western Cape, South Africa**



© Marco Beugel

**Figure 61: Péringuey's desert adder *Bitis peringueyi***

**2.3.9.3** Desert mountain adder (*Bitis xeropaga*) (Figure 62). Average total length 30–40 cm (maximum 61 cm). It is ash to dark grey, with 16–4 dark crossbars. Each crossbar

consists of a median dark brown to blackish rectangle flanked on either side by a whitish spot and a light brown area. The belly is greyish to dirty cream, with darker spots and speckles.



© Marco Beugel

**Figure 62: Desert mountain adder *Bitis xeropaga***

**2.3.10 Coral/Shield-nosed snakes (Genus *Aspidelaps*) (Map 10)**

**2.3.10.1** South African coral snake (*Aspidelaps lubricus*) (Figure 63). Maximum total length is 80 cm. A relatively thick-bodied elapid snake coloured black and orange or greyish with blackish bands. It rears up, spreads a narrow hood and hisses in defence. Three subspecies (races) are recognized (Figure 64).



© David A. Warrell

**Figure 63: South African coral snake *Aspidelaps lubricus lubricus* South Africa**



© David A. Warrell

**Figure 64: South African coral snake *Aspidelaps lubricus infuscatus* South Africa**

**2.3.10.2** Shield-nosed snake (*Aspidelaps scutatus*) (Figure 65). Average total length is 60–70 cm (maximum 80 cm). A relatively thick set snake with a broad head and a very large rostral shield, coloured greyish or reddish-brown with dark dorsal saddle markings, a pale throat and dark neck. It rears up, flattens its neck and hisses in defence and will feign death. Three shield-nosed snake subspecies (races) are recognized (see Annex 1).



© David A. Warrell

**Figure 65: Shield-Nosed Snake *Aspidelaps scutatus scutatus* West Nicholson, Zimbabwe**

**2.3.11 Old World vipers (*Macrovipera* species) (Map 8)**

**2.3.11.1** Levantine, Levant, Lebetine or blunt-nosed viper (*Macrovipera lebetina*) (Figure 66). Maximum total length (*M. l. transmediterranea*) 100 cm. This viper is greyish or reddish, with two rows of black or

brown dorsal spots which may alternate or coalesce to produce a zigzag stripe. A series of smaller, darkish spots is distributed along the flanks. There is a V marking on the head. In desert areas the markings may be absent or indistinct and the general colour is palish brown.

© David A. Warrell



**Figure 66: Levantine viper *Macrovipera lebetina***

In Africa, the sub species *M. l. transmediterranea* is restricted to Algeria and Tunisia where it seems to be very rare. It is known by only five preserved museum specimens and may represent a separate species (herp-Schleich et al, 1996).

**2.3.11.2** Moorish viper (*Macrovipera mauritanica*) (Figure 67). Maximum total length 180 cm. A large fat-bodied adder, with the head distinct from the body and a narrow snout. The tail is relatively long and the body is brownish-grey, usually with a conspicuous pattern of 23 to 33 blotches or windings that form a zigzag pattern down the back. A pale reddish or brown phase,



© Peter Stafford

**Figure 67: Moorish viper *Macrovipera mauritanica***



with a weakly developed pattern, may also be found. The desert viper (*M. deserti*) from Tunisia has been variously described as a full species or as a subspecies of *M. lebetina* or *M. mauritanica*.

## 2.4 Category 4: Snakes that bite rarely and have not caused significant envenoming

(see table in Annex 1 for distribution and habitat and Annex 2 for geographical maps).

### 2.4.1 Other minor adders (*Bitis caudalis*, *B. schneideri*, *B. worthingtonii*) (Map 11)

**2.4.1.1** Horned adder (*Bitis caudalis*) (Figure 68). Average total length 30–40 cm (maximum 50 cm). There is a prominent single horn above each eye. The colour pattern is very varied. The primary colour is grey to brown, with varying shades of orange-red or sandy to dark brown, with a dorsal row of dark square/oval markings. A dark V-shaped marking occurs on the top of the head. It is a sidewinder that buries itself in the sand.



Figure 68: Horned adder *Bitis caudalis* Northern Cape, South Africa

**2.4.1.2** Namaqua dwarf adder (*Bitis schneideri*) (Figure 69). Average total length 20 cm (maximum 28 cm). This is the smallest

venomous adder. Dorsally, it is pale greyish or brown, with a series of dark brown to black pale-centred blotches centred down the back. Where it inhabits red sand, the body may be orange-red. The eyes are placed on the sides of the head and have small raised ridges above them.



Figure 69: Namaqua dwarf adder *Bitis schneideri*

**2.4.1.3** Kenyan horned viper (*Bitis worthingtonii*) (Figure 70). Average total length 20–35 cm (maximum 50 cm). A small, stoutly-built snake with prominent supra-orbital “horns”. Its colour is usually darkish-brown or olive, with two lighter undulating lines along each flank. There is a dorsal series of dark triangular blobs and a dark arrow-shaped marking on the back of the head. The belly is off-white and heavily mottled with small black patches.



Figure 70: Kenyan horned viper *Bitis worthingtonii* Lake Naivasha, Kenya

## 2.4.2 African garter snakes (genus *Elapsoidea*) (Map 12)

These snakes have an average total length of 25–50 cm. They are small fossorial (burrowing), nocturnal elapid snakes, with very short tails, cylindrical bodies, no distinct neck and a bluntly rounded rostral scale as in other burrowing species. The young are brightly banded, but the bands fade as they mature. They are sluggish and not aggressive. Taxonomy is under revision, several subspecies are described. The garter snakes include:

- 2.4.2.1 East African, Loveridge's garter snake (*Elapsoidea loveridgei*) (Figure 71);
- 2.4.2.2 Angolan or half-banded garter snake (*E. semiannulata*) (Figures 72 and 73);
- 2.4.2.3 Sundewall's garter snake (*E. sundevalli*) (Figure 74).



Figure 71: East African garter snake *Elapsoidea loveridgei* Kenya



Figure 72: Half-banded garter snake *Elapsoidea semiannulata moebiusi* Gambia



Figure 73: Half-banded garter snake *Elapsoidea semiannulata moebiusi* Zaria, Nigeria



Figure 74: Sunderwall's garter snake *Elapsoidea sundevalli longicauda* Northern Transvaal, South Africa



## 2.5 Category 5: Other potentially venomous snakes which have not caused documented bites

(See table in Annex 1 and geographical maps in Annex 2 for distribution and habitat.)

**2.5.1 Ethiopian mountain adder (*Bitis parviocula*)** (Figure 75). Maximum total length 100 cm. A big, broad-headed viper, with prominent geometric markings likely to be capable of causing severe envenoming.



Figure 75: Ethiopian mountain adder *Bitis parviocula* Bedelle Ethiopia

### 2.5.2 Other bush vipers (genus *Atheris*)

- 2.5.2.1 *Atheris anisolepis* (common name not known);
- 2.5.2.2 Rough-scaled, spiny or prickly bush viper (*A. hispida*) (Figure 76);
- 2.5.2.3 Shaba bush viper (*A. katangensis*);
- 2.5.2.4 Great Lakes bush viper or Nitsche's bush viper (*A. nitschei*);
- 2.5.2.5 *Atheris rungweensis*;
- 2.5.2.6 *Atheris hirsuta* (Taï National Park, Ivory Coast);
- 2.5.2.7 Kenya montane viper (*Montatheris hindii*);
- 2.5.2.8 Uzungwe viper or Barbour's viper (*Adenorhinos barbouri*).



Figure 76: Rough-scaled bush viper *Atheris hispida* Kakamega, Kenya

### 2.5.3 Other burrowing asps (Genus *Atractaspis*)

- 2.5.3.1 Battersby's burrowing asp (*Atractaspis battersbyi*);
- 2.5.3.2 Central African burrowing asp (*A. boulengeri*);
- 2.5.3.3 Black burrowing asp (*A. coalescens*);
- 2.5.3.4 Congo burrowing asp (*A. congica*);
- 2.5.3.5 Duerden's burrowing asp (*A. duerdeni*);
- 2.5.3.6 Engdahl's burrowing asp (*Atractaspis engdahli*);
- 2.5.3.7 *Atractaspis fallax* (subspecies of *Atractaspis microlepidota*);
- 2.5.3.8 Ogaden burrowing asp (*A. leucomelas*);
- 2.5.3.9 *Atractaspis micropholis* (subspecies of *A. microlepidota*);
- 2.5.3.10 Reticulate burrowing asp (*A. reticulata*);
- 2.5.3.11 Somali burrowing asp (*A. scortecchii*).

### 2.5.4 Other dwarf adders (Genus *Bitis*) (Map 11)

- 2.5.4.1 Albany adder (*Bitis albanica*);
- 2.5.4.2 Southern adder (*B. armata*) (Figure 77);
- 2.5.4.3 Many-horned adder, hornsman (*B. cornuta*) (Figure 78);

© Steve Spawls

© David A. Warrell

- 2.5.4.4 Angolan adder (*B. heraldica*);
- 2.5.4.5 Plain mountain adder (*B. inornata*);
- 2.5.4.6 Red adder (*B. rubida*) (Figure 79).




© Tony Phelps

Figure 77: Southern adder *Bitis armata*



© Tony Phelps

Figure 78: Many-horned adder *Bitis cornuta*  
Springbok, Northern Cape, South Africa, female



© Tony Phelps

Figure 78: Many-horned adder *Bitis cornuta*  
Springbok, Northern Cape, South Africa, female

### 2.5.5 Other night adders (Genus *Causus*) (Map 7)

- 2.5.5.1 Two-striped night adder (*Causus bilineatus*);
- 2.5.5.2 Green night adder (*Causus resimus*) (Figure 80).



© David A. Warrell

Figure 80: Green night adder *Causus resimus*  
Watamu, Kenya

### 2.5.6 Other vine snakes (Genus *Thelotornis*) (Map 9)

- 2.5.6.1 Oates' savanna vine snake (*Thelotornis capensis oatesi*);
- 2.5.6.2 Eastern vine snake (*T. mossambicanus*);
- 2.5.6.3 Usambara vine snake (*T. usambaricus*).

### 2.5.7 Other Colubridae

- 2.5.7.1 Many-spotted snake (*Amplorhinus multimaculatus*);
- 2.5.7.2 Blanding's tree snake [*Boiga (Toxicodryas) blandingii*] (Figures 81 and 82);
- 2.5.7.3 Jan's desert racer (*Coluber rhodorachis*);
- 2.5.7.4 Herald, red- or white-lipped snake (*Crotaphopeltis hotamboeia*);
- 2.5.7.5 Hooded malpolon (*Malpolon moilensis*);
- 2.5.7.6 Kenyan link-marked sand snake (*Psammophis biseriatus*);
- 2.5.7.7 Hissing or olive sand snake (*Psammophis mossambicus*);
- 2.5.7.8 Spotted skaapsteker (*Psammophylax rhombeatus*);
- 2.5.7.9 Striped skaapsteker (*Psammophylax tritaeniatus*);

2.5.7.10 Tiger snake (*Telescopus semiannulatus*)

2.5.7.11 Large-eyed snake (*Telescopus dhara*).



© David A. Warrell

**Figure 81: Blanding's tree snake *Boiga blandingii* Watamu, Kenya**



© David A. Warrell

**Figure 82: Blanding's tree snake *Boiga blandingii* Kakamega, Kenya**

**2.5.8 Other Old World vipers (Genus *Macrovipera* and *Vipera*) (Map 8)**

2.5.8.1 Desert adder [*Macrovipera (Daboia) deserti*] (Figure 83);

2.5.8.2 Lataste's viper or Iberian viper (*Vipera latastei*);

2.5.8.3 Atlas mountain viper (*Vipera monticola*).



© Tomas Mazuch

**Figure 83: Desert adder *Macrovipera (Daboia) deserti***

**2.5.9 Other garter snakes (Genus *Elapsoidea*) (Map 12)**

2.5.9.1 Zambezi garter snake (*Elapsoidea semiannulata boulengeri*);

2.5.9.2 Southern Somali garter snake (*E. chelazzii*);

2.5.9.3 Gunther's garter snake (*E. guentherii*);

2.5.9.4 Central African garter snake (*E. laticincta*);

2.5.9.5 Usambara garter snake (*E. nigra*);

2.5.9.6 *Elapsoidea broadleyi*, *E. trapei*.

**2.5.10 Water cobras (Genus *Naja* [*Boulengerina*])**

These are medium to large elapid snakes, with short broad heads, and medium-sized eyes with round pupils; they are both nocturnal and diurnal, aquatic or semi-aquatic. Water cobras can inflate their bodies but do not spread hoods.

2.5.10.1 Banded water cobra (*Naja [Boulengerina] annulata*) (Figure 84) has an average total length of 140–220 cm. Colour variable; warm-brown, with dark bands on the neck and anterior part or along the body.



**2.5.10.2** Congo water cobra (*Naja [Boulengerina] chrystyi*) has an average total length of 70–130 cm. Brown or speckled brown, with 3–6 yellow cross bars on the neck and front top third of the body.



© David A. Warrell

**Figure 84: Banded water cobra *Naja (Boulengerina) annulata stormsi* Lake Tanganyika**

**2.5.11 Burrowing cobra (*Naja [Paranaja] multifasciata*)**

The burrowing cobra (Figure 85) is a small ground dwelling rainforest species of southern Cameroon and adjacent territories. Total length 50-70 cm (maximum 80 cm).

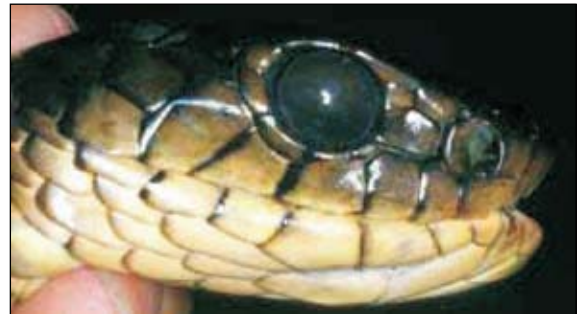

© David A. Warrell

**Figure 85: Burrowing cobra *Naja (Paranaja) semifasciata duttoni***

**2.5.12 Tree cobras (Genus *Pseudohaje*)**

The two species *Pseudohaje goldii* (West-Central Africa) (Figure 86) and *P. nigra* (West Africa) are long, thin, fast moving, very agile, predominantly black, arboreal, rainforest snakes with large eyes and spiked tail tips. Average total length is 150–220 cm (maximum 270 cm). In the laboratory, the venom has high lethal potency, but no cases of bites or envenoming are recorded.



© Chris Wild

**Figure 86: Gold's tree cobra *Pseudohaje goldii***





# Chapter 3

## Distribution of African Venomous Snakes and Epidemiological Data on Snakebite

### 3.1 Distribution of African Venomous Snakes

**3.1.1** The geographical area covered by this publication includes the whole continent of Africa, its adjacent islands and Madagascar. Although almost 400 snake species occur on the African continent, most are relatively harmless. Approximately 100 species are medically important, of which 30 are known to have caused human deaths. The venomous species of medical importance are members of the following four families: **Atractaspididae, Colubridae, Elapidae and Viperidae.**

**3.1.2** There are three major vegetation types or zones in Africa, namely forest, savannah (grasslands) and desert. In addition there are two transitional zones: woodland, where savannah becomes heavily wooded, and semi-desert, where savannah becomes dry and sparsely vegetated. Although these terms are very general for describing botanical regions of Africa, they are useful for the purpose of delineating snake habitats.

**3.1.3** Apart from the zones described above, other habitats include the Mediterranean coast of North Africa, the hills and mountains of eastern and south-eastern Africa, and the temperate regions, hills, and small deserts of Southern Africa. Particular snake species are usually found in only one of the above three vegetation zones (forest, savannah

or desert). Some species, however, may be found in both intermediate zones (woodland or semi-desert) (Spawles and Branch, 1985).

**3.1.4** There are no medically important snakes (i.e. venomous) in Mauritius, Réunion, Rodrigues, the Comoros, Canary Islands, Cape Verde islands, Mafia and Seychelles. The islands that have venomous snakes include Coïama (Koyaama), the Lamu archipelago, Zanzibar and Pemba, Ilhas Quirimbas (Kerimbás), the Bazaruto Archipelago and Inhaca Island, São Tomé, Príncipe, islands of the Bight of Benin, Bioko (Fernando Po), Dahlak Islands and Socotra. The venomous snakes on these islands tend to be similar to those on the adjacent mainland. A colubrid, *Madagascarophis meridionalis*, and perhaps other species of the same genus, are the only terrestrial snakes of possible medical importance found in Madagascar (Domergue, 1989).

**3.1.5** The highest incidence of snakebite in Africa occurs in the West African savanna region. In this region, saw-scaled or carpet vipers (*E. ocellatus*, *E. leucogaster*, *E. jageri*), spitting cobras (*Naja nigricollis* and *N. katiensis*) and puff adders (*Bitis arietans*) are common causes of serious envenoming. Egyptian cobras (*N. haje*) and Senegalese cobras (*N. senegalensis*) cause some cases of neurotoxic envenoming but forest cobras (*N. melanoleuca*) are far less commonly implicated.

**3.1.6** In North Africa (the Magreb), desert horned vipers (*Cerastes cerastes*) and saw-scaled vipers (*Echis leucogaster* and *E. pyramidum*) cause most envenomings. In East Africa, most serious bites are attributed to the puff adders, spitting cobras (e.g. *N. nigricollis*, *N. pallida*, *N. ashei*, *N. nubiae*), and in a few instances, to mambas. As in West Africa, the incidence of snakebite increases in parallel with agricultural activity at the start of the rainy season.

**3.1.7** Throughout eastern and southern Africa, the puff adder is thought to be responsible for most cases of serious envenoming, followed by the cytotoxic spitting cobras (*Naja mossambica*, *N. nigricincta* and *N. nigricollis*). The mambas (*D. polylepis* and *D. angusticeps*) and Cape cobra (*N. nivea*) (south-western regions), which are neurotoxic, cause few bites but with a high case fatality (Warrell, 1995; Warrell, 1999).

**3.1.8** The taxonomic status, habitats, geographical distribution and clinical toxicology of medically important African snakes are summarized in Annex 1. The geographical distributions are illustrated in composite colour maps in Annex 2 (Maps 1-13). These maps have been compiled with modifications with reference to the locations published in Spawls and Branch, 1995 (Müller, 2005). Distribution and habitat of venomous snakes of Africa are dealt with separately in Annex 1.

## 3.2 Epidemiological Data on Snakebite in African Countries

**3.2.1** Epidemiological data on snakebite in Africa are hard to obtain. There are probably more than 100 000 envenomings and 5000 deaths in Africa each year.

However, Chippaux (1998, 2005) has estimated five-fold higher figures of one million bites, 500 000 envenomings and 20 000 deaths (10 000 of which are reported) each year. Important species involved in these envenomings include *Echis ocellatus*, *E. leucogaster*, *E. pyramidum*, *Bitis arietans*, spitting cobras (*Naja nigricollis*, *N. katiensis*, *N. pallida*, *N. mossambica* etc), *N. haje*, *N. annulifera*, *N. nivea*, *Dendroaspis polylepis* and *D. angusticeps*.

**3.2.2** No epidemiological data on snakebite are available from Algeria, Libya, Morocco, Tunisia or Western Sahara. Throughout the Magreb region, scorpion stings are a much more common cause of morbidity and mortality than snake bites. Several bites by *Cerastes cerastes* have been reported from Algeria. Other medically important species include *Naja haje*, *Echis* spp., *Macrovipera/Daboia* spp. and *Bitis arietans* (Morocco only).

**3.2.3** In Egypt, the Poison Control Centre in Cairo received 156 cases (one fatality) in 2002, 160 in 2003 and 215 in 2005. Most victims were Bedu farmers at Wahat Bahareya oasis near Fayoum. *Cerastes cerastes* was the only snake identified but paralytic cases (about 10% of all cases) from the Nile Valley were attributed to *Naja haje* and a case of venom ophthalmia to the spitting cobra *N. nubiae*.

In summary, there may be about 5000 bites and several hundred deaths each year. The most important species are *Naja haje*, *Cerastes cerastes*, *Echis leucogaster*, *E. pyramidum* and *Macrovipera* spp.

**3.2.4** For most parts of Africa, the only available epidemiological data are from small areas, often chosen because of their notoriously high rate of snakebite (e.g. Pugh and Theakston, 1980). Chippaux has used

these data to estimate national totals of bites and mortality (Chippaux 1998; Chippaux 2005). For many countries, there are no epidemiological data (e.g. Central African Republic, Chad, Democratic Republic of Congo, Eritrea, Ethiopia, Mozambique, Niger, Somalia and Tanzania).

**3.2.5 Benin:** 4500 envenomings and 650 fatalities each year are claimed by the public health authorities, mainly attributed to *Echis ocellatus*.

**3.2.6 Burkina Faso:** snake bites (*Echis leucogaster*) are said to be common, even in the suburbs of Ougadougou (7.5 envenomings per 100 000 population per year). In rural areas, the incidence is 35–120 per 100 000 population per year with a case fatality of 3%. Health services claim 7000–10 000 envenomings and 200 fatalities. Few patients are admitted to hospitals and there is virtually no antivenom available.

**3.2.7 Cameroon:** in the Benue valley in the north there are 200–300 envenomings/100 000/year. *Echis ocellatus* is responsible for more than 85% of bites.

**3.2.8 Republic of Congo:** in rural areas, there were 120–450 bites/100 000 population/year and in Brazzaville 11.5/100 000/year.

**3.2.9 Côte d'Ivoire:** incidence of envenomings varies from 200–400/100 000/year in rural areas (especially high in plantation workers) and is 10/100 000/year in Abidjan.

**3.2.10 Ghana:** in northern Ghana there are 86 envenomings and 24 deaths/100 000/year caused mainly by *Echis ocellatus*.

**3.2.11 Guinea:** in Kindia, there are 100–150 envenomings/100 000/year, with a case fatality of 18% and amputations in 2% of

cases. Neurotoxic cobra bites, probably attributable to *Naja melanoleuca*, are common in the forests. In Friguilagbe, there were 375 bites with 19.2 deaths /100 000/year.

**3.2.12 Kenya:** a preliminary survey based on Ministry of Health, hospital, clinic and dispensary records in Kakamega and western Kenya, Lake Baringo and Laikipia, Kilifi and Malindi and northern Kenya suggested an overall average frequency of snakebite of 14 (range 2–68) per 100 000 population per year with a minimum death rate of 0.45 per 100 000 per year. Puff adders, black mambas and spitting cobras (*Naja nigricollis*, *N. pallida*) were responsible for the fatalities (Coombs et al, 1997). However, a community-based study on the coast in Kilifi District discovered 15 adult snakebite fatalities per 100 000 population per year (Snow et al, 1994). Egyptian cobras (*N. haje*), eastern green mambas (*Dendroaspis angusticeps*) and the colubrid boomslang (*Dispholidus typus*) cause a few bites and fatalities.

**3.2.13 Liberia:** in one rubber plantation there were 420 bites and 170 envenomings/100 000/year but no deaths. The western rhombic night adder (*Causus maculatus*) was chiefly responsible (Stahel, 1980).

**3.2.14 Mali:** case fatality varies from less than 4% to more than 15%. *Echis leucogaster* is the most important species.

**3.2.15 Nigeria:** 174 snakebites/100 000 population/year are reported (Nasidi, 2007). The saw-scaled or carpet viper (*Echis ocellatus*) is responsible for 90% of bites and 60% of deaths (Nasidi, 2007). In the Benue Valley of north-eastern Nigeria, the incidence of snakebite was found to be 497 per 100 000 population per year with a mortality of 12.2% (Warrell and Arnett, 1976). Most bites



and deaths were attributed to saw-scaled vipers (*Echis ocellatus*). A community survey of snakebite by the black-necked spitting cobra (*Naja nigricollis*) in Malumfashi, northern Nigeria, found that in a population of 43 500 there were 15–20 bites/100 000/year. Only 8.5% of the victims had visited a hospital. The case fatality was 5%, and 19% of survivors had persistent physical disability from the locally necrotic effects of the venom (Pugh et al, 1980).

**3.2.16 Senegal:** in the south-east, in Bandafassi, there are 700–900 bites and 14 deaths/100 000/year caused mainly by saw-scaled vipers (*E. ocellatus*), puff adders (*Bitis arietans*) and spitting cobras (*N. katiensis*) (Trape et al, 2001). In the Sahel region the incidence is 30–300/100 000/year.

**3.2.17 South Africa:** three hospital-based studies in KwaZulu Natal reported incidences of bites of 31–89/100 000/year and a study from Transvaal an incidence of 34/100 000/year. There were few deaths. The species responsible included *Bitis arietans*, *Naja nivea*, *N. mossambica*, *Dendroaspis polylepis*, *Causus rhombeatus* and *Atractaspis bibronii*.

**3.2.18 Togo:** there are 130 +/- 27 envenomings and 3-4 deaths/100 000/year. *Echis ocellatus* is the dominant species responsible for an epidemic of lethal bites in the 1950s.

**3.2.19 Zimbabwe:** incidence of bites admitted to hospitals is 3.5/100 000/year with case fatalities of 1.8-5%; 19 deaths were reported in 1980.

#### Medically important snakes of Africa (most important\*)

North

***Naja haje*, *Cerastes cerastes*\* , *Echis leucogaster*, *Echis pyramidum*\* and *Macrovipera spp.***

West

***Echis ocellatus*\* , *E. leucogaster*\* , *E. jageri*\* , *Bitis arietans*\* ,** spitting cobras (***Naja nigricollis*\* , *N. katiensis***), *N. haje*, *N. senegalensis*, *N. melanoleuca*, *Dendroaspis polylepis*, *D. viridis*, *D. jamesoni*

East

***Echis pyramidum*\* , *Bitis arietans*\* ,** spitting cobras (***N. nigricollis*\* , *N. pallida*\* , *N. ashei*\* , *N. nubiae***), *N. haje*, *Dendroaspis polylepis*, *D. angusticeps*

Central

***Bitis arietans*\* ,** spitting cobras (***N. mossambica*\***), *N. haje*

South

***Bitis arietans*\* ,** spitting cobras (***N. mossambica*\* , *N. nigricincta*\***), ***N. nivea*\* , *N. annulifera*, *D. polylepis*\* , *D. angusticeps*\***

# Chapter 4

## Prevention of Snakebite

### 4.1 Introduction

Snakes have adapted to a wide range of habitats and prey species. All snakes are predatory carnivores; none are vegetarians although some eat eggs. Since snakes are preyed upon by other animals, they tend to be secretive and have evolved many survival strategies. By understanding something about snakes' habits, simple precautions can be adopted to reduce the chance of encounters and subsequent bites. Some truths apply to all snakes: they prefer not to confront large animals (such as humans); thus, it is best so give them the chance or time to slither away. Some species are mainly nocturnal hunters, and other species are mainly diurnal hunters. Many snakes are non-venomous, while others are only mildly venomous and not particularly dangerous to humans. However, a few are highly venomous and their bites are potentially lethal. Snakes are necessary for maintaining a healthy balance in nature; they should not be killed unnecessarily. It is important that everyone learn which dangerous snakes occur in the local community or area.

4.2 In the house, where snakes may enter in search of food or to find a hiding place for a short time.

**4.2.1** Do not keep livestock, especially chickens, in the house, as some snakes will come to hunt them.

**4.2.2** Store food in rat-proof containers.

**4.2.3** Raise beds above floor level and use an insecticide-impregnated mosquito net, completely tucked in under the sleeping mat. This guards against centipedes, scorpions, and snakes as well as malaria mosquitoes and many ectoparasites (fleas, lice, bed bugs etc) (Chappuis et al, 2007).

**4.3** In the farmyard, compound, or garden, try not to provide hiding places for snakes.

**4.3.1** Use a light and wear proper shoes when walking outside at night.

**4.3.2** Clear heaps of rubbish, building materials and other refuse from near the house.

**4.3.3** Do not have tree branches touching the house.

**4.3.4** Keep grass short or ground clear around your house and clear underneath low bushes so that snakes cannot hide close to the house.

**4.3.5** Keep your granary away from the house (it may attract animals that snakes will hunt). Water sources, reservoirs and ponds may also attract animals of prey.

**4.3.6** Listen to wild and domestic animals: they often warn of a snake nearby.

**4.4** In the bush or countryside, firewood collection at night is a real danger.

**4.4.1** Watch where you walk. Step on to rocks or logs rather than straight over them as snakes may be sunning themselves on the other side.

**4.4.2** Do not put hands into holes, nests or any hiding places where snakes might be resting.

**4.4.3** Wild animals, especially birds, may warn of snakes nearby.

**4.4.4** Be careful when handling dead or apparently dead snakes: even an accidental scratch from the fang of a snake's severed head may inject venom. Some species such as the rinkhal (*Hemachatus haemachatus*) (Figure 87) may sham death as a defensive tactic.

**4.4.5** Many snakebites occur during ploughing, planting and harvesting and in the rainy season. Rain may wash snakes and debris to the edges of roads, and flush some species such as burrowing asps (*Atractaspis*)

out of their burrows. Pedestrians should be careful when walking on roads after heavy rain especially after dark.

**4.4.6** Drivers or cyclists should never intentionally run snakes over on the road. The snake may not be instantly killed and may lie injured and pose a risk to pedestrians and other cyclists. The snake may also be injured and trapped under the vehicle, from where it will crawl out once the vehicle has stopped or has been parked in a compound or garage.



© David A. Warrell

**Figure 87: Rinkhal *Hemachatus haemachatus* Johannesburg, South Africa**

# Chapter 5

## Snake Venoms

### 5.1 Introduction

The primary function of snake venom is to help the snake immobilize and eventually digest its prey. Snake venoms are complex mixtures of numerous toxic and non-toxic components. More than 90% of the dry weight is protein. The most important venom components that lead to significant clinical effects after a bite are enzymes and polypeptide toxins.

The amount of venom injected during a bite depends on various factors: species and size of the snake, mechanical efficiency of the bite, whether one or two fangs penetrated the skin, and whether there were repeated bites. Not all bites by venomous snakes lead to venom injection. On an average of 50% of occasions, no venom is injected; this is referred to as a "dry bite". Even after several bites or after eating their prey, snakes do not exhaust their venom, and they remain just as venomous.

Within the same species, larger snakes also tend to inject more venom than smaller ones, but the venom of the latter may be richer in some very dangerous components. Bites by small snakes should therefore not be neglected but should receive the same attention as those by larger snakes.

### 5.2 Snake venom composition

The most important venom components that cause serious clinical effects are

pro-coagulant enzymes, cytolytic or necrotic toxins, haemolytic and myolytic phospholipases A<sub>2</sub>, pre- and post-synaptic neurotoxins, and haemorrhagins.

Snake venoms vary in their composition from species to species but also within a single species:

- (i) throughout the geographical distribution of that species, (ii) at different seasons of the year,
- (iii) as the snake grows older (ontogenic variation). This contributes to the enormous and fascinating clinical diversity of snakebite (Warrell, 1997).

#### 5.2.1 Pro-coagulant enzymes

These are found mainly in vipers. They activate different steps of the blood-clotting cascade. Ultimately, this leads to the formation of fibrin in the blood. Most of the fibrin is broken down by the body's fibrinolytic system. This process depletes the body's own levels of clotting factors, and eventually the blood does not clot. This is also called *consumption coagulopathy*.

Haemostatic disturbances are an important feature of envenoming by vipers and dangerous venomous colubrids. Snake venoms can cause bleeding in a number of different ways. Venom procoagulants can activate intravascular coagulation and produce consumption coagulopathy leading to incoagulable blood (Edgar et al,



1980; Hutton and Warrell, 1993). For example, procoagulants in the venom of Colubridae and Echis species activate prothrombin, Echis venoms activate factor X, and *Bitis arietans* venom has a direct thrombin-like action on fibrinogen.

### 5.2.2 Cytolytic or necrotic toxins

These are digestive hydrolases (proteolytic enzymes and phospholipases) and polypeptides that may destroy cell membranes and tissues and therefore increase the permeability of the vascular endothelium. This leads to local swelling, blistering and oedema.

### 5.2.3 Haemolytic and myolytic phospholipases A<sub>2</sub>

These damage cell membranes, endothelium, skeletal muscle nerves and red blood cells. Phospholipases A<sub>2</sub> are the most widespread and extensively studied of all venom enzymes. Under experimental conditions, they damage mitochondria, red blood cells, leucocytes, platelets, peripheral nerve endings, skeletal muscle, vascular endothelium and other membranes. They produce presynaptic neurotoxic activity, opiate-like sedative effects and the autopharmacological release of histamine.

### 5.2.4 Pre-synaptic neurotoxins

These are mainly found in elapid venoms and in some vipers. They are phospholipases A<sub>2</sub> that damage nerve endings, initially releasing acetylcholine followed by interfering with its release.

### 5.2.5 Post-synaptic neurotoxins

These are mainly found in elapid venoms. They are polypeptides that compete with

acetylcholine for binding at neuromuscular junction receptors and lead to curare-like paralysis.

### 5.2.6 Haemorrhagins

Spontaneous systemic bleeding is attributable to haemorrhagins which damage vascular endothelium. These are zinc metallo-endopeptidases (reprolysins), some of which have disintegrin-like, cysteine-rich and lectin domains. The combination of incoagulable blood, thrombocytopenia and vessel wall damage results in massive bleeding.

### 5.2.7 Biogenic amines

Biogenic amines such as histamine and serotonin (5-hydroxytryptamine) are found particularly in viper venoms. They may contribute to the local pain and permeability changes at the site of snakebite.

## 5.3 Classification of clinical patterns of snakebite envenoming

Very broadly, the above described venom components can lead to four main types of envenoming.

### 5.3.1 Cytotoxic envenoming

This is characterized by painful and progressive swelling with blood-stained tissue fluid leaking from the bite wound, hypovolaemic shock, blistering and bruising. The victim will complain of severe pain at the bite site and throughout the affected limb and painful and tender enlargement of lymph glands draining the bite site. Irreversible death of tissue may occur (necrosis/gangrene).

Species that cause this type of envenoming include saw-scaled/carpet vipers, puff adders, Gaboon and rhinoceros vipers, and spitting cobras.

### 5.3.2 Haemorrhagic envenoming

This is characterized by bleeding from the gums; gastro-intestinal and genito-urinary tracts; and recent and partly healed wounds. Species involved include saw-scaled/carpet vipers, Gaboon and rhinoceros vipers, boomslang, and vine snakes.

### 5.3.3 Neurotoxic envenoming

This is characterized by moderate or absent local swelling, progressive descending paralysis starting with drooping eyelids (ptosis) and paralysis of eye movements causing double vision. There may be painful and tender enlargement of lymph glands draining the bite site. The patient may vomit, the saliva may become profuse and stringy, and eventually there may be difficulties with swallowing and breathing. Species involved include black and green mambas, non-spitting cobras and Berg adder.

### 5.3.4 Myotoxic envenoming

This is characterized by negligible local swelling, increasing generalized muscle pain and tenderness (myalgia) associated with features of neurotoxic envenoming and progressive descending paralysis culminating in paralysis of breathing. The species involved is the yellow-bellied sea snake.

Mixed types of envenoming may occur. **Mixed cytotoxic and neurotoxic** bites occur in the case of the rinkhals but not with other spitting cobras. There can be **mixed haemorrhagic and cytotoxic** bites from saw-scaled/carpet vipers, North African desert vipers and puff adders.



# Chapter 6

## Clinical Features of Envenoming

### 6.1 Introduction

Bites by venomous snakes, even the deadliest ones, do not always cause envenoming. The proportion of "dry bites" ranges from more than 50% in the case of night adders (*genus Causus*) to less than 10% following saw-scaled viper bites. In someone bitten by a snake, symptoms and signs may result from the effects or complications of any or all of the following: fear, treatment (first aid, medical or traditional), envenoming.

### 6.2 Local symptoms and signs in the bitten part

There is immediate pain. Local bruising and persistent bleeding from the fang punctures suggests a haemostatic disturbance (viper and certain colubrid bites). Swelling usually begins within 10-20 minutes. It may become extensive after viper and spitting cobra bites, involving the entire limb, adjacent areas of the trunk and the whole body in children. Regional lymph nodes draining the bitten part may become enlarged, painful and tender on palpation within 30-60 minutes.

Blisters, blood- or fluid-filled, may appear, first near the fang marks within 12-24 hours. Demarcated pigmentation or depigmentation with anaesthesia and a distinctive smell of putrefaction are signs of necrosis. This progresses to frank necrosis with spontaneous sloughing of dead tissue or the need for surgical debridement.

### 6.3 Generalized (systemic) symptoms and signs

#### 6.3.1 Bleeding and clotting disorders (viper and certain colubrid bites)

There is bleeding from wounds, the fang punctures and venepuncture sites because the blood is defibrinogenated and will not clot and platelet function is impaired. Venom haemorrhagins cause spontaneous systemic bleeding from gingival sulci and nose, haematemesis, rectal bleeding, melaena, haemoptysis, haematuria, retroperitoneal, extrapleural or intracranial haemorrhage, and, in pregnant women, ante-partum haemorrhage.

#### 6.3.2 Shock (hypotension) (viper bites)

There is blurred vision, dizziness, syncope and collapse sometimes occurring very soon after the bite; these symptoms may be transient, recurrent, persistent, progressive, delayed and life-threatening.

#### 6.3.3 Neurotoxic symptoms (neurotoxic cobras, mambas, other elapids, some small *Bitis* vipers)

Transient paraesthesiae of the tongue and lips, abnormalities of taste and smell, heaviness of the eyelids, increased salivation or a dry mouth, nausea and vomiting are followed by progressive, descending paralysis: bilateral ptosis, pupillary abnormalities, external and



internal ophthalmoplegia, paralysis of the facial muscles, jaw, tongue, neck flexors (causing the “broken neck” sign) and other muscles innervated by the cranial nerves, dysphonia, difficulty in swallowing secretions and finally respiratory and generalized flaccid paralysis.

Mamba bite envenoming causes paraesthesiae, sweating, gooseflesh, salivation, viscous respiratory tract secretions, diarrhoea, fasciculations and other involuntary muscle spasms and rapidly progressive paralysis.

#### **6.3.4 Acute renal failure**

This is uncommon after bites by any of the terrestrial African snakes, but renal failure may develop if there has been profound hypotension or rhabdomyolysis (in neglected adder bites).

# Chapter 7

## Clinical Profiles of Envenoming by Some Snakes of Medical Importance

### 7.1 Back-fanged snakes (Colubridae)

**7.1.1** Species that have proved capable of causing fatal envenoming in Africa are the boomslang (*Dispholidus typus*) and two of the four species of vine, twig, tree or bird snake (*Thelotornis kirtlandii* and *T. capensis*) including among their victims the famous herpetologists Karl P. Schmidt (*Dispholidus typus*) and Robert Mertens (*Thelotornis kirtlandii*). If these snakes are able to engage their rear fangs for 15 seconds or longer, severe envenoming may result. Symptoms resulting from envenoming by *D. typus* and *Thelotornis* sp. may be delayed for many hours or even days after the bite.

**7.1.2** There is nausea, vomiting, colicky abdominal pain and headache. Bleeding develops from old and recent wounds such as venepunctures, and there is spontaneous gingival bleeding, epistaxis, haematemesis, melaena, subarachnoid or intracerebral haemorrhage, haematuria and extensive ecchymoses. Intravascular haemolysis and microangiopathic haemolysis have been described.

**7.1.3** Most of the fatal cases died of renal failure from acute tubular necrosis, many days after the bite. Local effects of the venom are usually trivial but several patients

showed some local swelling and one bitten by *Dispholidus typus* had massive swelling with blood-filled bullae (Figure 88). Investigations reveal incoagulable blood, defibrination, elevated fibrinogen degradation products (FDPs), severe thrombocytopenia and anaemia. These clinical features are explained by disseminated intravascular coagulation triggered by venom prothrombin activators.

**7.1.4** Montpellier snake (*Malpolon monspessulanus*) bites can cause local swelling, inflammation, stiffness and numbness of the bitten limb and, in rare cases, mild systemic neurotoxic envenoming (ptosis, external ophthalmoplegia) (González, 1991; Pommier and de Haro, 2007).

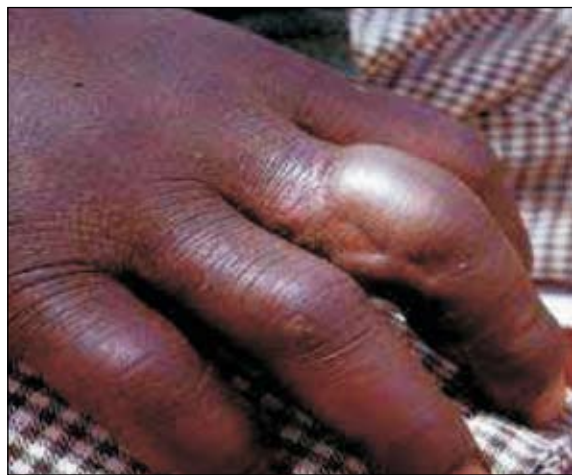

© Jimmy Thomas

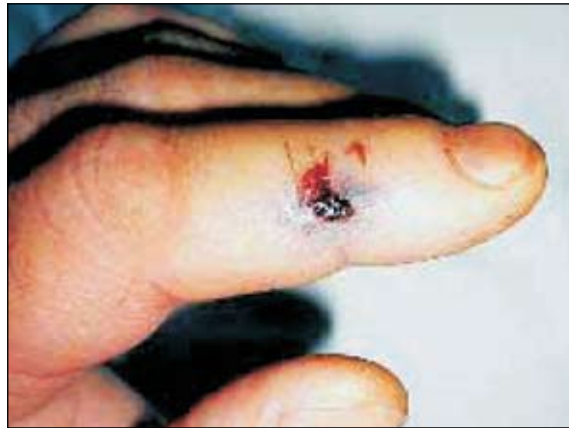**Figure 88: Boomslang *Dispholidus typus* bite Harare, Zimbabwe, healing site of the bite**

## 7.2 Burrowing asps or stiletto snakes (*Atractaspididae*, Genus *Atractaspis*)

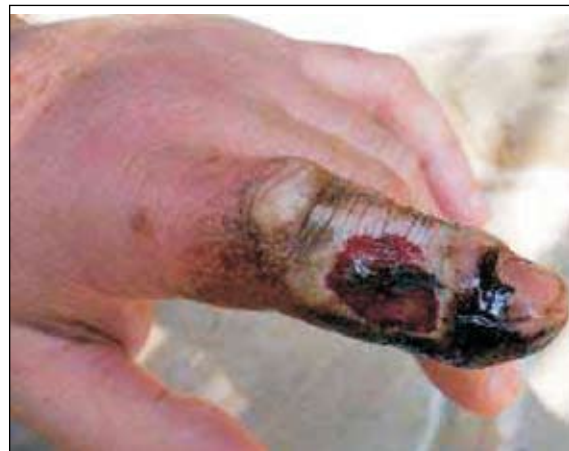**7.2.1** Only three (*Atractaspis microlepidota*, *A. irregularis* and *A. engaddensis*) of the 17 species in this genus have proved capable of killing humans (Warrell and Ormerod, 1976; Warrell, 1993; Warrell, 1995). Local effects include pain, swelling, blistering, necrosis (Figures 89, 90, 91) (requiring amputation in several published cases), tender enlargement of local lymph nodes, local numbness or paraesthesiae. The most common systemic symptom is fever. Most of the fatal cases died within 45 minutes of the bite after vomiting, producing profuse saliva and lapsing into coma. Severe envenoming by *A. engaddensis* in Israel may produce violent autonomic symptoms (nausea, vomiting, abdominal pain, diarrhoea, sweating and profuse salivation) within minutes of the bite. One patient developed severe dyspnoea with acute respiratory failure, one had weakness, impaired consciousness and transient hypertension and in three there were electrocardiographic changes (ST-T changes and prolonged PR interval) (Kurnik et al, 1999).



**Figure 89: Dahomey burrowing asp *Atractaspis dahomeyensis* bite, local blistering and swelling**



**Figure 90: Small-scaled burrowing asp *Atractaspis microlepidota* bite, Diani Beach, Kenya: early swelling**



**Figure 91: Small-scaled burrowing asp *Atractaspis microlepidota***

**7.2.2** Mild abnormalities of blood coagulation and liver function have been described. *Atractaspis* venoms contain endothelin-like peptides such as sarafotoxins (*A. engaddensis*) that can have marked cardiovascular effects (see Chapter 5 on snake venoms). Venoms also contain haemorrhagic and necrotic factors but no true neurotoxins. In South Africa, bites by the Natal black snake (*Macrelaps microlepidotus*) are said to have resulted in collapse and loss of consciousness for up to 30 minutes in two cases (Visser and Chapman, 1978).

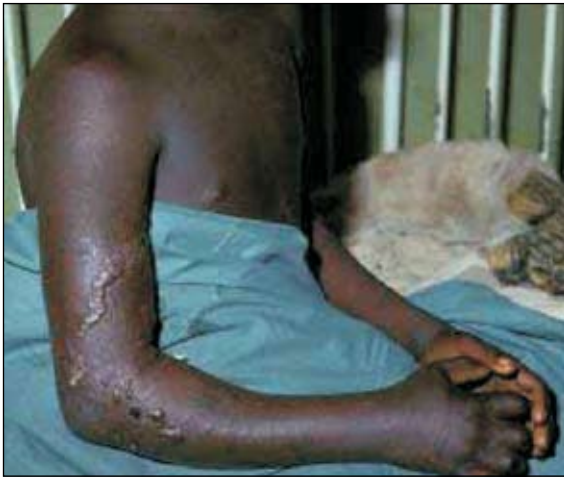## 7.3 African spitting cobras (Genus *Naja*)

**7.3.1** Bites by spitting cobras (*Naja nigricollis*, *N. katiensis*, *N. pallida*, *N. mossambica*, *N. nigricincta*, *N. nubiae*, *N. ashei*) produce a distinctive clinical syndrome unlike that caused by other elapid snakes: local necrosis without neurotoxicity (Davidson, 1970; Strover, 1973; Warrell et al, 1976b; Warrell, 1979; Pugh et al, 1980; Tilbury, 1982). Most bites occur at night inside homes while the victims are asleep. There is immediate pain followed by vomiting within six hours and extensive local swelling, local blistering in 60% of cases and local tissue necrosis in 70% of envenomed cases (Figures 92, 93, 94). Necrosis usually involves only the skin and subcutaneous connective tissues.

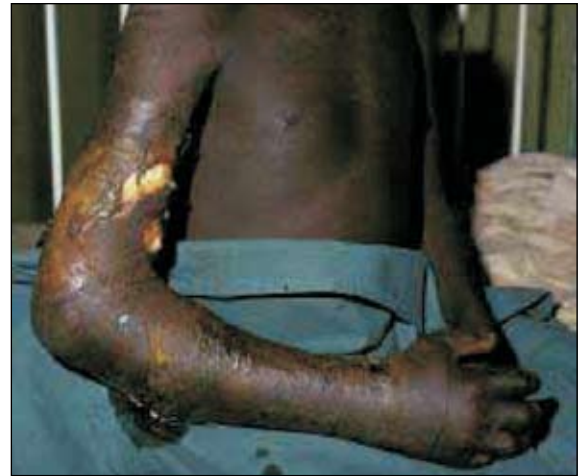**7.3.2** There may be "skip lesions", areas of necrosis separated by strips of apparently-normal skin caused by proximal spread of venom in lymphatic vessels. There is neutrophil leucocytosis with evidence of complement activation, principally via the alternative pathway. Complications of necrotic lesions include loss of function due to

chronic ulceration, osteomyelitis, arthrodesis, hypertrophic scars, keloid formation and, after several years, malignant transformation ("Marjolin's ulcer") (Figure 95).

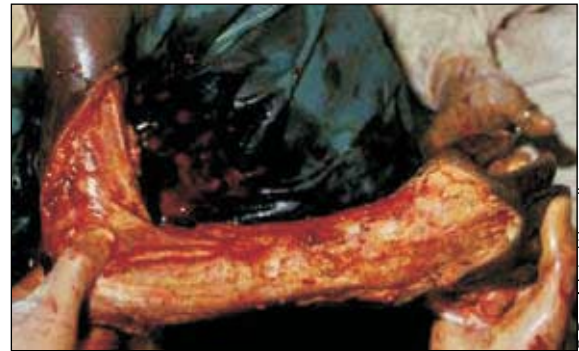© David A. Warrell (Warrell et al, 1976)



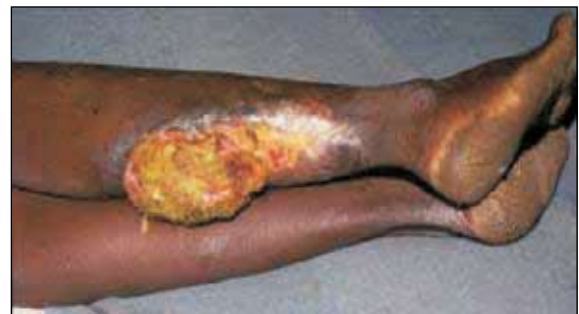**Figure 92:** Black-necked spitting cobra *Naja nigricollis* bite on the upper forearm in a 9-year-old girl, Kaltungo, Nigeria, swelling of entire arm and adjacent trunk with blistering and early signs of necrosis on 4th day after the bite



**Figure 93:** Black-necked spitting cobra *Naja nigricollis* bite, same patient as Figure 92, frank necrosis on 9th day after the bite



**Figure 94:** Black-necked spitting cobra *Naja nigricollis* bite, same patient as Figures 92 and 93, surgical debridement of necrotic skin and subcutaneous tissues on 9th day after bite

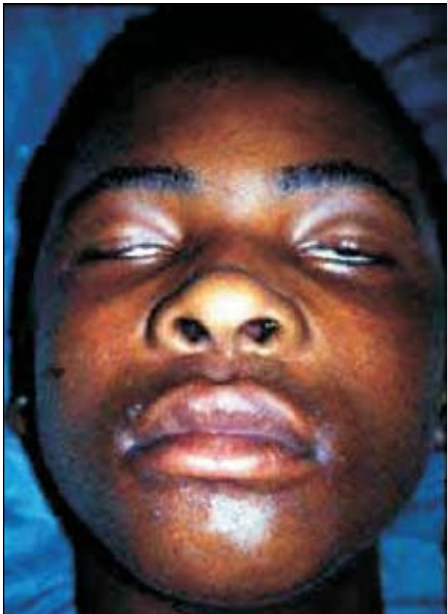

**Figure 95:** Black-necked spitting cobra *Naja nigricollis* bite, malignant transformation to squamous



## 7.4 Mambas (Genus *Dendroaspis*)

**7.4.1** These are justifiably the most feared snakes of Africa. Mamba venoms contain unusual neurotoxins called *dendrotoxins*. They are 59 amino acid proteins that bind to voltage-gated potassium channels at nerve endings, causing acetylcholine release. These toxins are responsible for a distinctive clinical syndrome of envenoming: paraesthesiae, signs of autonomic nervous system stimulation and muscular fasciculations (contractions of groups of muscle fibres innervation by single motor neurones producing a rippling contraction under the skin that can be confused with shivering). All four species (*D. polylepis*, *D. angusticeps*, *D. jamesoni* and *D. viridis*) are capable of causing rapidly-progressive descending paralysis, appearing as soon as 15 minutes after the bite and progressing to fatal respiratory paralysis (Figure 96).



© Iain Thirsk

**Figure 96: Black mamba bite *Dendroaspis polylepis* Ngwelazana, South Africa: showing ptosis, external ophthalmoplegia and facial**

**7.4.2** The speed of evolution of envenoming and its distinctive features are well-illustrated by a patient seen in Harare, Zimbabwe. Within one minute of being bitten by a 3-metre-long black mamba (*D. polylepis*) (illustrated on the Title Page), a 41-year-old man noticed tingling of the tongue and lips, followed by generalized tingling, abdominal pain and light-headedness. Within 20 minutes he was sweating profusely, had dilated pupils and was too weak to stand up. He became nauseated and vomited 30 minutes after the bite, by which time he was unable to pass urine and had detectable ptosis. He became breathless and found it difficult to clear his throat of thick secretions; 40 minutes after the bite he felt cold all over and noticed gooseflesh, his conjunctivae were congested and he was unable to open his mouth or protrude his tongue. There was then a rapid deterioration in his breathing and level of consciousness. Generalized fasciculations were noticed. He was treated with antivenom after 75 minutes, and 4½ hours after the bite he was intubated and mechanically ventilated for 40 hours, after which he made a complete recovery (Warrell, 1995).

**7.4.3** Other features described in the literature include severe local pain, a strange taste in the mouth, diarrhoea, excessive salivation, involuntary muscular contractions and recurrent episodes of paralysis despite antivenom treatment (Strover, 1967; Chapman, 1968; Blaylock, 1982). Local swelling is variable and sometimes absent after mamba bites. However, patients bitten by eastern green mambas (*D. angusticeps*) can develop swelling of the entire bitten limb and also show mild haemostatic disturbances (Warrell DA unpublished; Mackay et al, 1966). The rare cases of local tissue damage usually resulted from bites on the fingers or the use of a tight tourniquet.

## 7.5 Neurotoxic non-spitting cobras (*Naja haje*, *N. annulifera*, *N. anchietae*, *N. melanoleuca* and *N. nivea*)

**7.5.1** Bites by these species may cause some local swelling but necrosis does not develop. Classical neurotoxic symptoms appear as early as 30 minutes after the bite and can evolve to the point of fatal respiratory paralysis within 2-16 hours of the bite (Strover, 1961; Warrell et al, 1976a; Blaylock et al, 1985; McNally and Reitz, 1987).

**7.5.2** There are signs of progressive descending paralysis, starting with ptosis (drooping eyelids), external ophthalmoplegia (causing diplopia, i.e. double vision) and weakness of the muscles innervated by the cranial nerves so that the victim cannot open the mouth, clench the jaws, protrude the tongue, swallow, protect the airway from secretions, speak, flex the neck and eventually cannot breathe. When the respiratory muscles become affected, the pattern of breathing is initially abdominal or "paradoxical": the abdomen expands during inspiration due to contraction of the diaphragm. Respiratory distress increases, the patient becomes anxious, sweaty and cyanosed and will die unless ventilated artificially.

## 7.6 Sea snakes

**7.6.1** Bites by *Pelamis platurus* (East coast of Africa) and *Enhydrina schistosa* (Madagascar) are usually painless and may not be noticed by the wader or swimmer (Reid, 1979; Warrell, 1994). Fangs may be left in the wound. There is minimal or no local swelling and involvement of

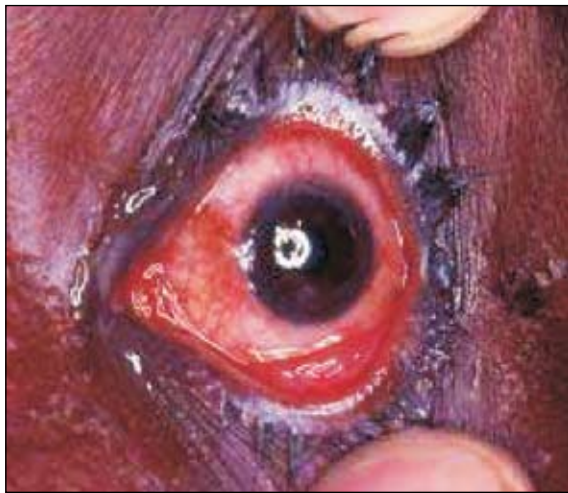local lymph nodes is unusual. Generalized rhabdomyolysis, paralysis and renal failure are the dominant effects of envenoming.

**7.6.2** Early symptoms include headache, a thick feeling of the tongue, thirst, sweating and vomiting. Generalized aching, stiffness and tenderness of the muscles become noticeable between 30 minutes and 3 ½ hours after the bite. Trismus (like tetanus, i.e. "lock jaw") is common. Passive stretching of the muscles is painful. Later, there is progressive flaccid paralysis starting with ptosis, as in other neurotoxic envenomings. The patient remains conscious until the respiratory muscles are sufficiently affected to cause respiratory failure. Myoglobinaemia and myoglobinuria develop 3-8 hours after the bite. These are suspected when the serum/plasma appears brownish and the urine dark reddish brown ("coca-cola coloured"). Bedside "stix" tests will appear positive for haemoglobin/blood in urine containing myoglobin. Myoglobin and potassium released from damaged skeletal muscles may cause renal failure, while hyperkalaemia developing within 6-12 hours of the bite may precipitate cardiac arrest.

## 7.7 Spitting elapids: snake venom ophthalmia

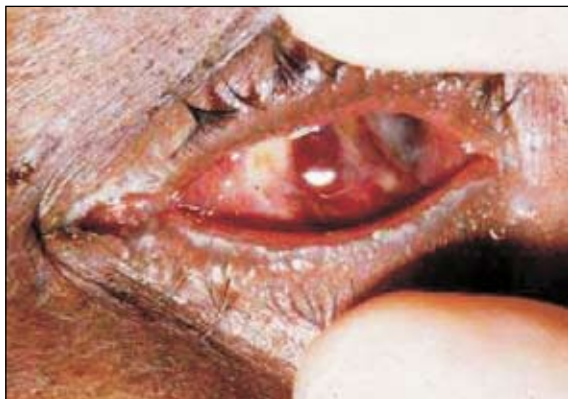**7.7.1** When venoms of the spitting elapids (African spitting cobras, genus *Naja*; southern African rinkhals *Hemachatus haemachatus*) enter the eye, there is intense local pain, blepharospasm, palpebral oedema, epiphora and leucorrhoea (Figure 97) (Warrell and Ormerod, 1976; Pugh et al, 1980; Lath and Patel, 1984). In Nigeria, slit-lamp or fluorescein examination revealed corneal erosions in more than half the patients spat at by *N. nigricollis*.

**7.7.2** Secondary infection of the corneal lesions may result in permanent opacities causing blindness or panophthalmitis with destruction of the eye (Figures 97, 98 and 99). Rarely, venom is absorbed into the anterior chamber causing hypopyon and anterior uveitis. Seventh (facial) cranial nerve paralysis is a rare complication which results from tracking of venom from the conjunctival sac through lymphatics posteriorly to the superficially situated VIIth cranial nerve.



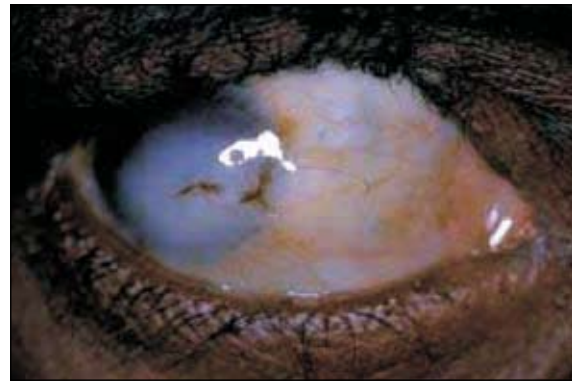© David A. Warrell

**Figure 97: Black-necked spitting cobra *Naja nigricollis* spit Zaria, Nigeria: showing intense conjunctivitis and leucorrhoea**



© David A. Warrell

**Figure 98: Black-necked spitting cobra *Naja nigricollis* spit Wusasa, Nigeria: endophthalmitis complicating corneal erosion in a neglected case first presenting to hospital 2 weeks after the accident; enucleation was required to prevent sympathetic ophthalmia**



© David A. Warrell

**Figure 99: Black-necked spitting cobra *Naja nigricollis* spit resulting in blindness from dense corneal opacity, untreated 5 years earlier**

## 7.8 Saw-scaled or carpet vipers (*Genus Echis*)

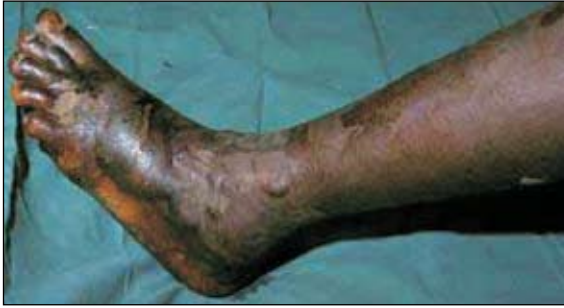**7.8.1** This genus of vipers is of enormous medical importance. It is widely distributed in the northern third of Africa from Senegal in the west, to Egypt and the horn of Africa in the east, north to the countries bordering the Mediterranean and south to the Tana River in Kenya. Throughout this range, it is usually the most important cause of human snakebite morbidity and mortality. In Africa, bites are most common in West Africa, where *Echis ocellatus* is the most important species.

**7.8.2** In northern Nigeria, only 4% of patients admitted to the hospital with proven *Echis ocellatus* bite lacked signs of envenoming, the lowest rate of “dry bites” reported in any large case series of snake bites (Warrell and Arnett, 1976; Warrell et al, 1977; Warrell, 1979). The remainder had both local and systemic envenoming. Some 12% developed local blistering (Figures 100 and 101) and 9% developed necrosis (Figure 102), sometimes requiring amputation or skin grafting. Local swelling (Figure 103) and bruising (Figure 104) may be extensive. Coagulopathy (attributable to venom prothrombin- and Factor X- activators) was universal, resulting in persistent local bleeding and bleeding



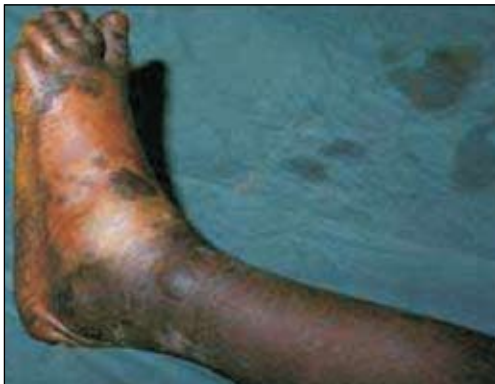from recent wounds (Figure 105). In 55% of patients there was spontaneous systemic bleeding, usually from the gingival sulci (Figure 106). Thrombocytopenia ( $<103 \times 109/l$ ) was present in only 7%.

© David A. Warrell



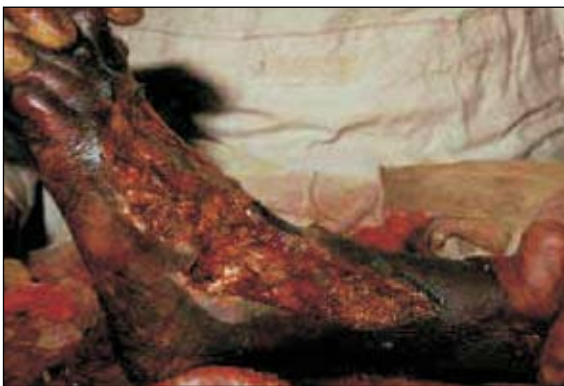**Figure 100:** Saw-scaled viper *Echis ocellatus* bite on dorsum of foot in a 12-year-old boy, Kaltungo, Nigeria: local swelling and blistering on 1st day after bite

© David A. Warrell (Warrell et al, 1977)

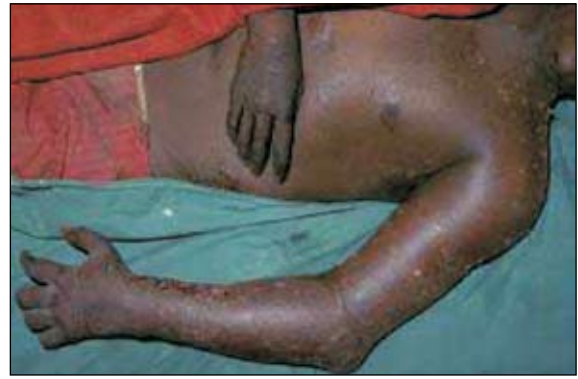

**Figure 101:** Saw-scaled viper *Echis ocellatus* bite, same patient as Figure 100: demarcated, depigmented area of necrotic tissue on 12th day after bite

© David A. Warrell

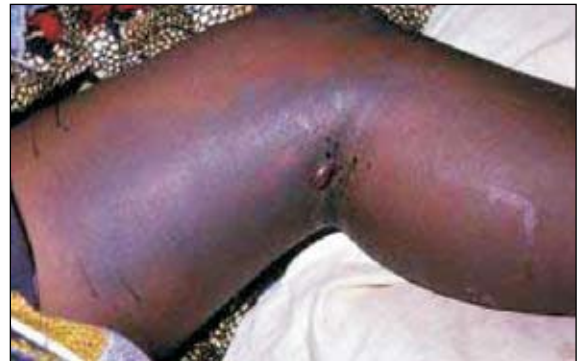

**Figure 102:** Saw-scaled viper *Echis ocellatus* bite, same patient as Figure 100, after debridement of necrotic tissue on 14th day after bite



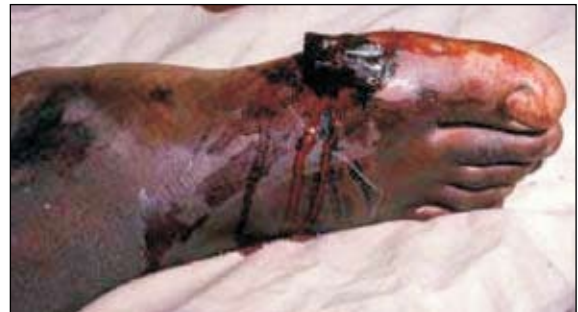© David A. Warrell

**Figure 103:** Saw-scaled viper *Echis ocellatus* bite on wrist 4 days previously, treated with topical application of *Crinum yuccaeiflorum* (Amaryllidaceae) (*gadali* in Hausa) root by a traditional doctor, Kaltungo, Nigeria: showing swelling of entire arm and trunk



© David A. Warrell

**Figure 104:** Saw-scaled viper bite *Echis ocellatus* bite behind knee 36 hours previously, Kaltungo, Nigeria: showing massive swelling and bruising

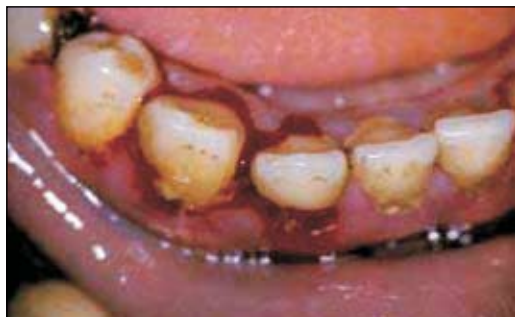

© David A. Warrell

**Figure 105:** Saw-scaled viper *Echis ocellatus* bite on foot 36 hours previously, Kaltungo, Nigeria: persistent bleeding from incision made to attach black "snake stone"



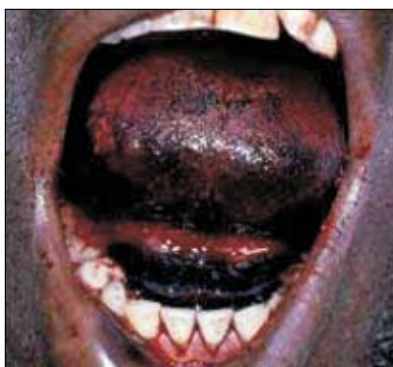© David A. Warrell



**Figure 106: Saw-scaled viper *Echis ocellatus* bite, Zaria, Nigeria: showing bleeding from gingival sulci**

**7.8.3** Other common sites of spontaneous systemic bleeding are nose, floor of the mouth (Figure 107), sub-conjunctival, gut, retroperitoneal, extrapleural, genito-urinary tract (haematuria), uterus in pregnant women (ante- and post-partum haemorrhage), subarachnoid and intracerebral. Renal failure is very uncommon unless the patient has suffered profound shock which may result in bilateral renal cortical necrosis which has been reported from Kenya (*Echis pyramidum*) and Saudi Arabia (*E. coloratus*). In Nigerian studies, the case fatality of 3.6% was attributable to haemorrhagic shock (3 cases) and intracerebral haemorrhage (2 cases) (Warrell et al, 1977).

© David A. Warrell



**Figure 107: Saw-scaled viper *Echis ocellatus* bite, Kaltungo, Nigeria: showing bleeding from gingival sulci and into floor of mouth**

**7.8.4** Envenoming by the eastern and north African species *Echis pyramidum* is generally less severe than in *E. ocellatus*

bites, but fatalities are reported in Turkana (*E. p. leakeyi*) and Wajir (*E. p. aliaborri*) in northern Kenya and in Somalia, Somaliland, Egypt and northern Sudan where it is the commonest cause of snakebite with a case fatality of 20%. Clinical features include local pain, swelling, blistering, abdominal pain, vomiting, bleeding from injection sites and recent injuries, haematuria, bleeding from the gums, haematemesis, melaena, menorrhagia, generalized bruising, periorbital bleeding, shock, fever, anaemia and leucocytosis. In Lokitaung area close to Lake Turkana in northern Kenya, *E. pyramidum* is responsible for most deaths and morbidity resulting from snakebite. A woman bitten at Loarengak collapsed unconscious soon after the bite and died of cerebral haemorrhage. Another patient, who had been given only symptomatic treatment at a dispensary, died 36 hours after the bite (Rev. Father Dr. R.J. MacCabe, personal communication). A patient bitten in Ferguson Gulf, Lake Turkana, Kenya, developed chronic renal failure from bilateral renal cortical necrosis following protracted hypotension (Oram et al, 1963). One patient bitten by a Tunisian specimen developed transient ptosis (Gillissen et al, 1994). There are no published data on *E. leucogaster* bites.

**7.8.5** There are reports of some 80 cases of *Echis coloratus* bites from Israel and a few from elsewhere (Benbassat and Shakev, 1993; Warrell and Arnett, 1976). Local pain and swelling are common and, in severe cases, swelling may involve the whole limb and is associated with bruising, haemorrhagic blisters and necrosis in 9% of cases in Israel. Systemic symptoms appear 15-120 minutes after the bite: nausea, vomiting, headache, spontaneous bleeding from gums, nose, gastrointestinal and urinary tracts and recent wounds. Most patients have incoagulable blood, hypofibrinogenaemia and elevated fibrin(ogen) degradation products by

the time they are admitted to hospital. About 20% have thrombocytopenia less than  $100 \times 10^9/l$ . A few patients, including one of the reported fatal cases, develop acute renal failure. Anaemia is attributable to microangiopathic haemolysis or haemorrhage. Haemostatic dysfunction persists for up to 9 days unless antivenom is given. Other abnormalities include hypotension, shock, loss of consciousness, ECG changes, neutrophil leucocytosis, proteinuria and microscopic haematuria with casts. In two cases, histopathological changes suggested "acute haematogenous interstitial nephritis", focal mesangial proliferation and tubular necrosis. Only four fatalities have been reported. Compared to envenoming by other *Echis* species, *E. coloratus* seems to be more likely to cause thrombocytopenia and renal failure but the case fatality is lower.

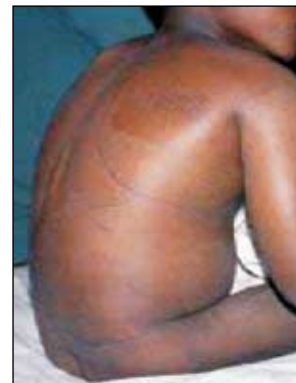## 7.9 Puff adders (*Bitis arietans*)

**7.9.1** This species, almost certainly a species complex, is thought to be responsible for the majority of serious venomous snake bites throughout Africa as a whole. Local swelling is often very extensive, commonly extending to involve the entire bitten limb and spreading to the trunk (Figure 108) (Strover, 1961; Chapman, 1968; Warrell et al, 1975). This extravasation of plasma causes hypovolaemic shock, a common presenting feature (Chapman, 1968).

**7.9.2** Local blistering (Figure 109) and necrosis (Figure 110) may be extensive requiring the amputation of the bitten digit or even part or all of the bitten limb. Major arteries may become thrombosed or entrapped by swollen tissue (Blaylock, 2003) in the bitten limb (and, rarely elsewhere), increasing the local tissue damage. Compartmental syndromes may develop, especially involving the anterior tibial compartment

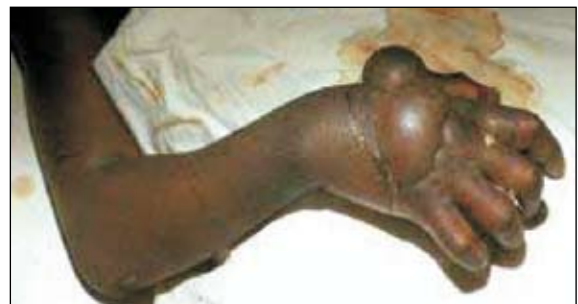after bites on the feet and ankles (Figure 111). These may lead to ischaemic necrosis of the compartmental muscles as in Volkmann's ischaemic contracture of the forearm. Direct myocardial effects and arrhythmias, commonly sinus bradycardia, may contribute to hypotension.

**7.9.3** In West Africa, envenoming by *B. arietans* causes spontaneous bleeding, bruising and petechial haemorrhages on serosal surfaces attributable to thrombocytopenia but there is no coagulopathy (Warrell et al, 1975). However, in East and South Africa, coagulopathy leading to incoagulable blood has been reported (Sezi et al, 1972) and rarely even cerebral thrombosis (Rollinson P unpublished). This regional variation in the pattern of envenoming is consistent with the concept of there being different species of puff adder.



© David A. Warrell

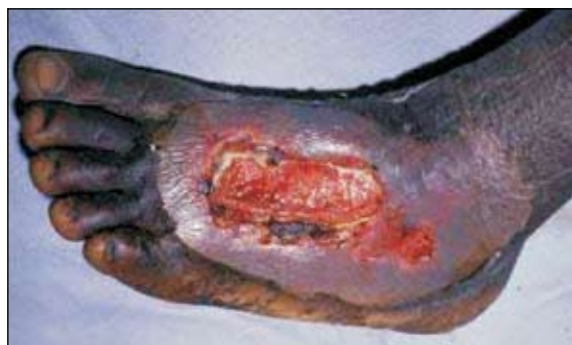**Figure 108: Puff adder *Bitis arietans* bite on hand in a 7-year-old boy, Zaria, Nigeria, massive swelling of arm and trunk 22 hours after bite**



© David A. Warrell

**Figure 109: Puff adder *Bitis arietans* bite Zaria, Nigeria, same patient as Figure 108, blistering of bitten hand**

© David A. Warrell



**Figure 110: Untreated puff adder *Bitis arietans* bite Zaria, Nigeria, local necrosis at the site of the bite 20 days after bite**

© David A. Warrell

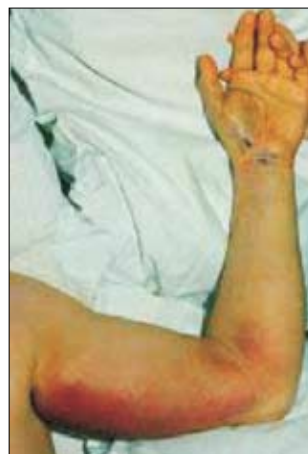

**Figure 111: Puff adder *Bitis arietans* bite, Zaria, Nigeria, results of neglected anterior tibial compartment syndrome; patient absconded from hospital after initial treatment**

## 7.10 Gaboon vipers (*Bitis gabonica* and *B. rhinoceros*)

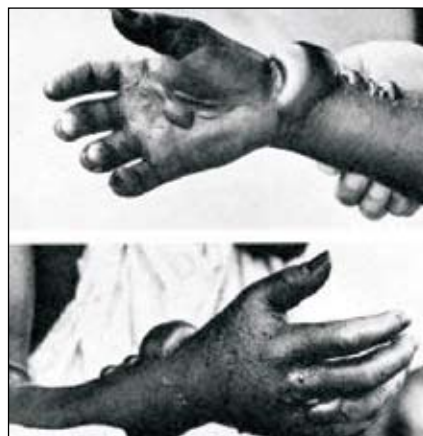**7.10.1** These giant vipers, now believed to be two separate species western (*B. rhinoceros*) and eastern (*B. gabonica*), are the commonest causes of snakebite in some focal areas of the rainforest, for example in southern Nigeria. It is surprising that so few cases of envenoming have been reported in view of their wide distribution, prodigious size, enormous fangs and massive yield of highly potent venom.

**7.10.2** Local effects of envenoming may be less severe than those produced by puff adder bites, but swelling, bruising (Figure 112), blistering and necrosis (Figure 113) are common. Systemic symptoms may be early and dramatic. Cardiovascular abnormalities, including hypotension and shock, arrhythmias and ECG changes, are reported (Marsh and Whaler, 1984). Spontaneous systemic bleeding is a common feature, while haemostatic abnormalities include thrombocytopenia and evidence of thrombin-like and fibrinolytic activities (McNally et al, 1993).



© David A. Warrell

**Figure 112: Rhinoceros viper *Bitis gabonica* bite on wrist, swelling, bruising and early necrosis at site of fang punctures**



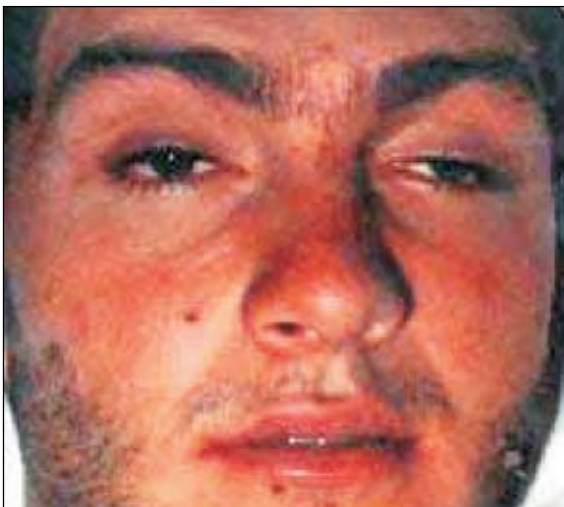© Jean Doucet (Doucet, 1963)

**Figure 113: Rhinoceros viper *Bitis rhinoceros* bite on back of the hand of a 15-year-old in Côte d'Ivoire 24 hours previously: blood still oozes from a fang puncture and there is massive swelling and blistering up to the elbow**



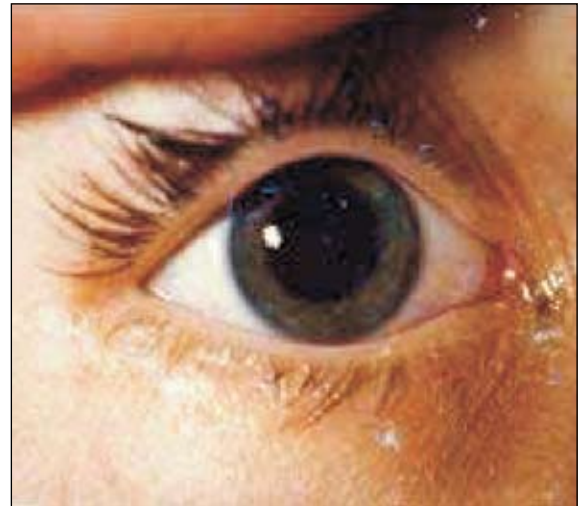## 7.11 Berg adder (*Bitis atropos*) and other smaller *Bitis* species

**7.11.1** The Berg adder (*B. atropos*) is mainly a mountain species that has been responsible for envenoming rock climbers in Zimbabwe and South Africa. It causes unusual symptoms. After initial pain and local swelling, paraesthesiae of the tongue and lips, blurring of vision, loss of the sense of taste and smell, nausea and vomiting may develop. Ptosis, external/internal ophthalmoplegia (Figure 114), dilated pupils (Figure 115), loss of visual accommodation and anosmia were reported in 93% of cases in one series. There is respiratory paralysis in 72%, hyponatraemia (attributed to a natriuretic hormone-like toxin) and dysphagia in 64%, and convulsions in 29% (Müller GJ and van Zyl JM, unpublished). Only one fatal case has been reported. Envenoming by other smaller *Bitis* species may also result in neurotoxic envenoming. For example, a child bitten by *B. peringueyi* in Namibia was left with cycloplegia (mydriasis) temporarily responsive to pilocarpine.



© Craig Smith

**Figure 114:** Berg adder *Bitis atropos* bite, Drakensbergs, South Africa, ptosis, external ophthalmoplegia and facial paralysis



© Craig Smith

**Figure 115:** Berg adder *Bitis atropos* bite, South Africa, dilated pupil (mydriasis)

## 7.12 Desert horned-vipers (*Genus Cerastes*)

*Cerastes cerastes* and *C. vipera* inhabit the vast arid deserts of North Africa where they are the commonest causes of snakebite.

**7.12.1** A few fatal cases of *Cerastes cerastes* bites were reported in 19th century French colonial military literature but none more recently. Usually envenoming results in local pain and swelling, complicated by necrosis in some cases. Nausea, vomiting, coagulopathy and spontaneous bleeding, including cerebral haemorrhage, have been observed in some cases. Recently, disseminated intravascular coagulation, microangiopathic haemolysis and acute renal failure were described in two proven cases of envenoming by *C. cerastes* (Schneemann et al, 2004).

**7.12.2** About a dozen cases of bites by *Cerastes vipera* have been reported. It is capable of causing mild local and systemic envenoming including coagulopathy, but local necrosis, renal failure and systemic bleeding have not been observed (Ben-Baruch et al, 1986).



### 7.13 Night adders (*Genus Causus*)

**7.13.1** Night adders are a common cause of snakebite in many parts of sub-Saharan Africa. Local envenoming (pain, swelling and lymphadenopathy) is usually the only effect. No antivenoms are available, nor is antivenom treatment necessary.

**7.13.2** With *Causus defilippi* (snouted night adder) bites there is local swelling, lymphadenopathy and mild fever without local necrosis.

**7.13.3** *Causus lichtensteini* (Lichtenstein's or forest night adder) is responsible for most bites in Makokou, Gabon, but the results are never serious.

**7.13.4** One of two people bitten by *Causus resimus* (green night adder) in the Sudan developed fever. A child bitten in Kilifi, Kenya, developed mild local swelling and transient dizziness.

**7.13.5** *Causus maculatus* (Western rhombic night adder) is responsible for many bites in the West African savannah region.

Most patients suffer no more than pain, limited local swelling and painful regional lymphadenopathy. Of 13 cases reported from northern Nigeria, three had fever and one, a five-year-old boy bitten by a 60-cm-long specimen, became hypotensive and drowsy but recovered rapidly. Mild neutrophil leucocytosis but no evidence of haemostatic disturbances was found. There are no reliable reports of local necrosis or fatalities (Warrell et al, 1976c).

**7.13.6** *Causus rhombeatus* (Eastern rhombic night adder) bites cause pain, local swelling and fever. Local necrosis and fatalities have not, reliably, been attributed to this species.

### 7.14 Old World vipers (*Genus Macrovipera*)

7.14.1 Most of the 63 snakebite cases reported from Morocco (Vidal, 1962) are attributable to *Macrovipera mauritanica*. There was local swelling, bruising and haematological disturbances with three fatalities. Interpretation is complicated by the ill-advised treatment with heparin.

# Chapter 8

## Main Clinical Syndromes of Envenoming in Africa

Except in those rare cases when a dead snake is brought to hospital with its victim and can be reliably identified by medical staff, the identification of the snake responsible for the bite is usually difficult or impossible. It is, however, important to try to diagnose which particular snake (species, genus or even family) was responsible for the bite so that the likely course of envenoming and potential complications can be promptly anticipated, prevented or treated. Descriptions of the snake and the circumstances of the bite may suggest a species diagnosis but this is not a satisfactory basis for treatment. What is needed for appropriate clinical management is the reliable identification of a distinctive clinical syndrome based on epidemiological, clinical and laboratory data.

South of the Sahara and north of the equator (Map 1), a simple bed-side test, the 20-minute-whole-blood-clotting test (20WBCT), usefully identifies patients systemically envenomed by saw-scaled vipers (*Echis* spp.) (see below). It requires no more than a new, clean, dry glass tube or vessel. In

this geographical area, the only other species whose venoms are likely to cause incoagulable blood very rarely bite (e.g. *Dispholidus typus* and *Atheris* spp.) and so the diagnosis of *Echis* envenoming and the use of a monospecific *Echis* antivenom is appropriate.

However, a syndromic approach is recommended in the majority of cases in which the cause of the bite is not certain. This has been developed and used effectively to guide algorithmic treatment with polyspecific antivenoms in southern Africa (Blaylock, 2005); sub-Saharan Africa as a whole (Warrell, 1999) and in south-east Asia (WHO, 1999). The following scheme is based on published material and aims to provide a sound method for syndromic treatment in any part of Africa.

Those working in southern Africa are recommended to consult Blaylock (2005) for algorithms specifically tailored for snakebite envenoming in that region. Equivalence between the scheme below and Blaylock's scheme is indicated in Table 8.1.

**Table 8.1 Six syndromes of envenoming**

Syndrome	Description	Blaylock scheme
SYNDROME 1	Marked local swelling with coagulable blood	Equivalent to "painful progressive swelling"
SYNDROME 2	Marked local swelling with incoagulable blood and/or spontaneous systemic bleeding	Partly equivalent to "bleeding syndrome"
SYNDROME 3	Progressive paralysis (neurotoxicity) weakness syndrome"	Equivalent to "progressive
SYNDROME 4	Mild swelling alone	
SYNDROME 5	Mild or negligible local swelling with incoagulable blood	Partly equivalent to "bleeding syndrome"
SYNDROME 6	Moderate to marked local swelling associated with neurotoxicity	

### 8.1 SYNDROME 1: Marked local swelling with coagulable blood

There is painful, rapidly progressive or extensive local swelling, sometimes with blistering and necrosis, with coagulable blood (detected by the 20WBCT) and absence of spontaneous systemic or persistent local bleeding.

It is suggestive of bites by spitting cobras (*Naja* spp.) especially if the patient was bitten indoors at night, or puff adders (*Bitis arietans*) especially if the patient is shocked. A rare cause is Berg adder (*B. atropos*) (southern Africa only) especially if the patient has paralysis.

Treatment: polyspecific antivenom and circulating volume repletion or supportive only if Berg adder is proven.

### 8.2 SYNDROME 2: Marked local swelling with incoagulable blood and/or spontaneous systemic bleeding

There is painful, rapidly progressive or extensive local swelling, sometimes with blistering and necrosis, with incoagulable blood (detected by the 20WBCT) and often spontaneous systemic bleeding (gums, nose, and gastrointestinal/urino-genital tracts) or persistent local bleeding at the bite site.

The syndrome is strongly suggestive of bites by saw-scaled or carpet vipers (*Echis* spp.)

(northern third of Africa only, north of the equator) or desert horned-vipers (*Cerastes cerastes*) (Sahara desert only). It may also be caused by some populations of puff adders (*Bitis arietans*) (east and southern African savannah region but not West Africa). Rare causes may be Gaboon vipers (*B. gabonica*, *B. rhinoceros*) (rainforests) and bush vipers (*Atheris* spp.).

**Treatment:** south of the Sahara and north of the equator, use monospecific *Echis* antivenom; anywhere in Africa, use polyspecific antivenom.

### 8.3 SYNDROME 3: Progressive paralysis (neurotoxicity)

There is negligible, mild or only moderate local swelling with progressive, usually descending, paralysis. It is strongly suggestive of bites by neurotoxic cobras or mambas.

*Treatment:* polyspecific antivenom; consider trial of anticholinesterase therapy; monitor respiratory function carefully, and intubate and assist ventilation if/when necessary.

### 8.4 SYNDROME 4: MILD SWELLING ALONE

There is mild local swelling alone, rarely involving more than half of the bitten limb with negligible or absent systemic symptoms. It is suggestive of bites by night adders (*Causus* spp.) or burrowing asps (*Atractaspis* spp.), and some dwarf, bush and desert vipers.

**Treatment:** no antivenom; palliative treatment only.

## 8.5 SYNDROME 5: MILD OR NEGLIGIBLE LOCAL SWELLING WITH INCOAGULABLE BLOOD

This is a rare syndrome. There is mild or absent local swelling with incoagulable blood (detected by the 20WBCT) and often spontaneous systemic bleeding. It is suggestive of bites by boomslangs (*Dispholidus typus*) or even more rarely by vine snakes *Thelotornis* spp.

**Treatment:** monospecific antivenom for boomslang; supportive treatment for vine snake.

## 8.6 SYNDROME 6: Moderate to marked local swelling associated with neurotoxicity

This syndrome is characterized by moderate to marked local swelling associated with neurotoxicity. Although a rare clinical entity, it is characteristic of Berg adder (*Bitis atropos*) bite. This syndrome has also been observed in other dwarf adder bites, eg. Péringuey's desert or side-winding adder (*Bitis peringueyi*) and the desert mountain adder (*B. xeropaga*).

**Treatment:** no antivenom available; palliative treatment only.





# Chapter 9

## Detailed Clinical Assessment and Species Diagnosis

### 9.1 History

A precise history of the time and circumstances of the bite and the progression of local and systemic symptoms and signs is of the utmost importance. Four initial questions should be asked as below.

#### 9.1.1 “In which part of your body have you been bitten?”

Look where the patient points. There may be evidence that the patient has been bitten by a snake (for example: fang marks), with signs of local envenoming (for example: local swelling, bruising or continuing bleeding from the fang punctures), but also evidence of pre-hospital treatment (for example: impressions made by a tourniquet or incision marks that may be bleeding, suggesting that the blood is incoagulable). Exceptionally, the snakebite may not have been recognized by the victim, if it occurs at night during sleep, or in the dark, or in water. In such cases, suspicion of the diagnosis will depend on typical signs such as fang puncture marks, progressive swelling, bleeding gums or descending paralysis.

#### 9.1.2 “When were you bitten?”

Assessment of the severity of envenoming depends on the length of time between the actual bite and when the patient seeks treatment. The patient seek treatment so soon after the bite that symptoms and signs of envenoming have not yet developed. Or, the patient may arrive so late after the bite that the only signs are of late complications

of envenoming (for example: gangrene, pneumonia or renal failure).

#### 9.1.3 “Where is the snake that bit you?” or “What did the snake look like?”

In some parts of Africa, such as the Benue and Niger valleys of Nigeria, the snake responsible for a bite is often killed and brought to hospital with the victim. If the snake is available, its identification can be extremely helpful but only if there is someone competent who can identify the snake. If it is obviously a harmless species (or not a snake at all), the patient can be quickly reassured, given an injection of tetanus toxoid and discharged from hospital immediately.

Descriptions of the snake by bite victims or onlookers are often unreliable and misleading but it is worth asking about the snake's size, colouring, markings and behaviour. The surroundings where the bite occurred and the time when it happened can also suggest a particular species:

- Cobras may rear up and spread a characteristic hood and hiss; puff adders make a loud blowing sound; saw-scaled vipers produce a rasping sound.
- Dangerous tree snakes include black and green mambas, forest cobras (*Naja melanoleuca*), boomslangs (*Dispholidus typus*) and vine snakes (*Thelotornis* spp.).
- Any green tree snake longer than about 1 m is likely to be a venomous green mamba or boomslang.

- Bites inflicted on sleeping persons in their huts at night are likely to have been caused by spitting cobras (*Naja nigricollis* or *N. mossambica*) (Warrell et al, 1976b; Tilbury, 1982).
- Bites in and near rivers, lakes and marshy areas are also most likely to be caused by cobras.

#### 9.1.4 “How are you feeling now?”

The patient's current symptoms can point to what is likely to be the most important effect of envenoming (for example: faintness or dizziness indicating hypotension or shock; breathlessness indicating incipient respiratory failure).

Patients should be asked to describe their symptoms and should then be questioned directly about the extent of local pain, swelling, tenderness, tender painful enlarged lymph nodes draining the bite area, bleeding from the bite wounds, at sites of other recent injuries and at sites distant from the bite (gums, nose etc), motor and sensory symptoms, vomiting, fainting and abdominal pain. The time after the bite when these symptoms appeared and their progression should be noted. Details of pre-hospital treatment (tourniquets, ingested and applied herbal remedies etc) should also be recorded as these may, themselves, be responsible for some of the symptoms.

## 9.2 Examination

### 9.2.1 Tooth marks

The absence of discernible fang marks does not exclude snakebite, but the discovery of two or more discrete, separate puncture marks suggests a bite by a venomous snake.

The pattern of fang punctures is rarely helpful as marks made by accessory fangs, palatine maxillary and mandibular teeth may complicate the pattern and there may have been multiple strikes/bites. The greater the distance between the fang marks, the larger the snake.

### 9.2.2 Local signs

Local swelling and enlargement and tenderness of regional lymph nodes are often the earliest signs of envenoming, but factitious swelling may be caused by a venous tourniquet. Most cases of significant envenoming by African vipers and spitting cobras are associated with the development of local swelling within two hours of the bite but there have been exceptions to this rule. Symptoms and signs of severe systemic envenoming from colubrids (*Dispholidus typus*, *Thelotornis* spp.) have been delayed for 15 hours or more after the bite. These species, like sea snakes, cause negligible local swelling. However, systemic envenoming by most African venomous snakes is associated with local swelling, although this may be negligible in the case of some bites by colubrids, mambas and neurotoxic cobras.

### 9.2.3 Bleeding

Persistent bleeding from the fang marks, other recent wounds and venepuncture sites suggest that the blood is incoagulable. The gums (gingival sulci) should be examined thoroughly as these are usually the first sites of spontaneous systemic bleeding.

### 9.2.4 Shock

The signs of shock are fall in blood pressure; collapse; cold, cyanosed and sweaty skin;

and impaired consciousness. The foot of the bed should be raised and an intravenous infusion of isotonic saline or a plasma expander such as haemaccel, gelofuse, dextran or fresh frozen plasma should be started immediately.

### **9.2.5 Neurotoxicity/paralysis**

The earliest symptoms of neurotoxicity after elapid bites are often blurred vision, a feeling of heaviness of the eyelids and apparent drowsiness. Whether snake venom toxins can exert any direct central effect on the level of consciousness is controversial but it is unlikely that they cross the blood-brain barrier. The frontalis muscle is contracted, raising the eyebrows and puckering the forehead, even before ptosis can be demonstrated (Figure 116). Respiratory muscle paralysis with imminent respiratory failure is suggested by dyspnoea, distress, restlessness, sweating, exaggerated abdominal respiration, central cyanosis and coma. If there is any suggestion of respiratory muscle weakness, objective monitoring should be attempted by measuring peak expiratory flow, forced expiratory volume in one second (FEV<sup>1</sup>), vital capacity or forced expiratory pressure using the mercury manometer of a sphygmomanometer. Coma is usually the result of respiratory or circulatory failure.

## **9.3 Monitoring of snake-bitten patients**

Patients bitten by snakes should, ideally, be observed in hospital for at least 24 hours after the bite. The intensive care unit or a high dependency bed is appropriate but rarely possible. In an open ward, the patient should be placed close to the nursing station and in full view of the medical staff. The following should be checked at least once every hour and action taken if there is any deterioration:

**9.3.1** Level of consciousness.

**9.3.2** Presence or absence of ptosis, the earliest sign of neurotoxicity. Seeing droopy eyelids is not diagnostic! Ask the patient to look upwards and check that the upper eyelids are fully retracted so that the pupils are fully exposed (Figure 117).

**9.3.3** Pulse rate and rhythm.

**9.3.4** Blood pressure. Measure while lying supine and after sitting up or being propped up in bed to assess any postural drop in pressure, suggesting hypovolaemia.

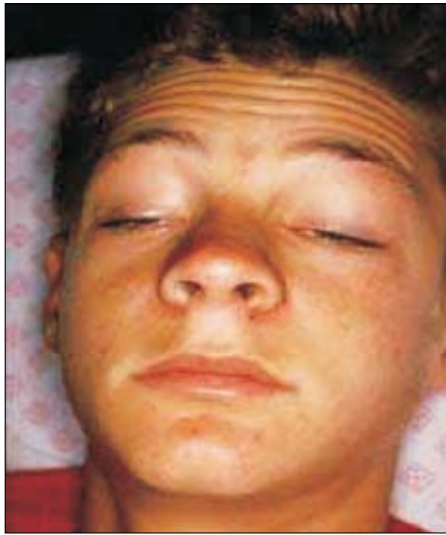**9.3.5** Respiratory rate.

**9.3.6** Extent of local swelling and tenderness (best marked gently on the skin with black marker pen with time and date).

**9.3.7** New symptoms or signs.

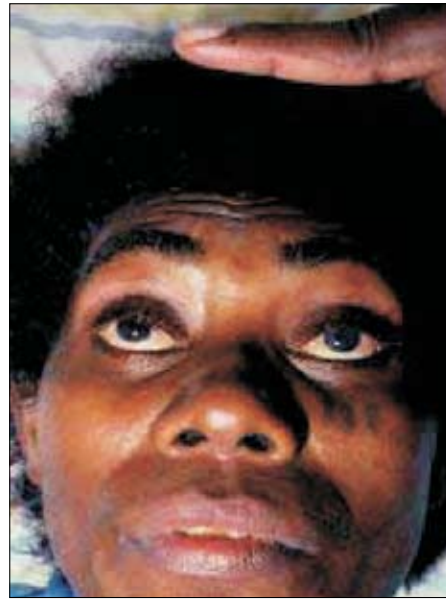

© Gert Müller and John Visser



**Figure 116: Neurotoxicity from Berg adder *Bitis atropos* bite: the patient is contracting the (forehead) frontalis muscle in an attempt to open his eyes despite bilateral ptosis**

© David A. Warrell



**Figure 117: Formal clinical testing for ptosis in a patient with early elapid neurotoxicity**

## 9.4 Investigations

### 9.4.1 Haematology

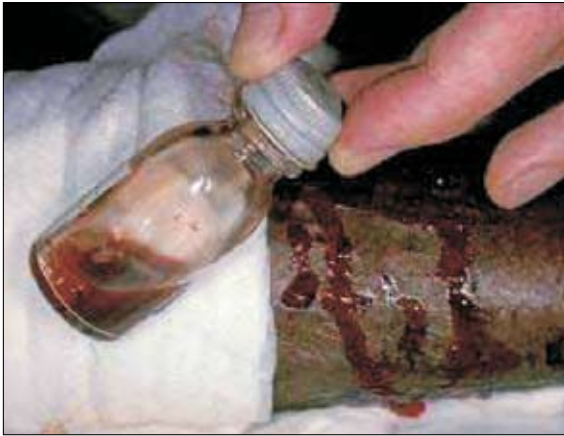Total blood count systemic envenoming is usually associated with a neutrophil leucocytosis: counts above  $20 \times 10^9/l$  indicate severe envenoming. Initially, there may be haemoconcentration (increased haemoglobin concentration or haematocrit), but later haemoglobin concentration and haematocrit may fall because of bleeding into the bitten limb and elsewhere, and from intravascular haemolysis or microangiopathic haemolysis in patients with disseminated intravascular coagulation. Thrombocytopenia is common after viper (e.g. *Bitis arietans*) and colubrid bites. The platelet count may fall to its lowest level after 1-2 days. The blood film may show evidence of microangiopathic haemolysis (fragmented erythrocytes also known as “helmet cells” or schistocytes) (Schneemann et al, 2004).

### 9.4.2 Test of haemostasis: 20-minute whole blood clotting test

Incoagulable blood is a cardinal sign of consumption coagulopathy from envenoming by most Viperidae (in Africa, especially saw-scaled vipers and desert horned-vipers; puff adders in south and central Africa) and the medically important Colubridae. For clinical purposes, the 20WBCT has proved reliable. This is a simple, rapid, “all-or-nothing” test of blood coagulability which can be done at the bedside and correlates well with fibrinogen concentration (Warrell et al, 1977; Sano-Martins et al, 1994).

A few millilitres of blood taken by venepuncture is placed in a new, clean, dry, glass vessel left undisturbed at room temperature for 20 minutes; then tipped once to see if the blood has clotted or not (Figure 118). The vessel must be glass rather than plastic in order to activate blood coagulation via Hageman factor (FXII).

Glass vessels may not activate coagulation if they have been cleaned with detergent or are wet.



© David A. Warrell

**Figure 118: 20WBCT: the patient is bleeding profusely from incisions made at the site of the bite 7 hours previously, further evidence of consumption coagulopathy**

#### 9.4.2 Other tests of haemostasis

More sensitive laboratory tests include prothrombin time (PT), thrombin and activated partial thromboplastin (aPTT) times and measurement of FDP and D-dimer concentrations. PT is often reported as international normalized ratio (INR).

#### 9.4.3 Biochemistry

Biochemistry can reveal evidence of muscle damage. Serum concentrations of creatine kinase, aspartate aminotransferase and blood urea are commonly raised in patients with severe envenoming because of local muscle damage at the site of the bite. Generalized rhabdomyolysis caused by sea snakes as well as neglected large adder bites causes a steep rise in serum creatine kinase and other muscle-derived enzymes, myoglobin and potassium concentrations. Plasma is stained brownish by myoglobin and urine will be black, darkish brown or

“coca-cola coloured” and positive for blood/haemoglobin on testing with reagent sticks.

#### 9.4.5 Plasma bilirubin increases following breakdown of extravasated blood.

#### 9.4.6 Evidence of intravascular haemolysis

Pink plasma (haemoglobinaemia) suggests haemolysis, but centrifugation or storage of blood samples may cause in vitro disruption of erythrocytes. Urine may be black (as in malarial “blackwater fever”) or reddish-brown and positive for blood/haemoglobin on testing with reagent sticks. Haematuria is excluded by microscopy. Distinguishing myoglobinuria from haemoglobinuria is difficult, requiring immunoassay.

#### 9.4.7 Evidence of renal dysfunction and acid-base imbalance

Blood urea or serum creatinine and potassium concentrations should be measured in patients who become oliguric, especially in cases with a high risk of renal failure (e.g. sea snakes and Colubridae). A snake-bitten patient should be encouraged to empty his/her bladder on admission. Urine should be examined for blood/haemoglobin and protein (by reagent sticks, stix test) and for microscopic haematuria and red cell casts. Severely sick, hypotensive and shocked patients may develop lactic acidosis (suggested by an increased anion gap), those with renal failure will also develop a metabolic acidosis (decreased plasma pH and bicarbonate concentration, reduced arterial PCO<sub>2</sub>), and patients with respiratory paralysis will develop respiratory acidosis (low pH, high arterial PCO<sub>2</sub>, decreased arterial PO<sub>2</sub>) or respiratory alkalosis if they are mechanically overventilated.

#### 9.4.8 Evidence of hypoxaemia/respiratory failure

Arterial oxygen saturation will fall. Arterial blood gas analysis will confirm low PO<sub>2</sub>, high PCO<sub>2</sub> and low pH. However, arterial puncture is contraindicated when there are haemostatic abnormalities! Arterial oxygen saturation can be monitored non-invasively by finger oximeter.

#### 9.4.9 Electrocardiographic abnormalities

Electrocardiographic abnormalities include sinus bradycardia, ST-T wave changes, and various degrees of atrioventricular block and evidence of hyperkalaemia. Shock may induce myocardial ischaemia or infarction in patients with diseased coronary arteries.

**9.4.10 Chest radiography** is important in artificially-ventilated patients who are desaturated or when there is doubt about the position of the endotracheal tube. Lung collapse, consolidation or pneumothorax may be revealed.

## 9.5 Diagnosis

In most patients, the history of snakebite will be clear-cut and the clinician will have to decide which species was likely to have been responsible and whether there are signs of envenoming. However, some patients may only suspect that they have been bitten by a snake because they experienced a sharp pricking pain while walking in the dark or in undergrowth, collecting firewood or even while asleep on the floor in their hut (see above).

#### 9.5.1 Differential diagnosis of snakebite in Africa

The differential diagnosis of **immediate local pain and one or more puncture marks** include thorn pricks, rodent bites, and bites and stings by arthropods; and in the water, fish bites and spine pricks.

The differential diagnosis of **immediate local pain and one or more puncture marks with mild local swelling and severe systemic symptoms** includes bites and stings by venomous African arthropods (for example, scorpions, spiders, centipedes).

The differential diagnosis of **local swelling and inflammation, sometimes resulting in a hot, red, swollen limb with enlarged regional nodes** includes secondary infection (cellulitis) following cytotoxic bites (necrotic arachnidism), penetrating wounds from thorns or rodent or other mammal bites. The interval between the accident and the development of inflammatory swelling is usually more than 24 hours, but in the case of *Pasteurella multocida* infection following mammal (especially dog and cat) bites, this interval may be as short as 6-12 hours.

#### 9.5.2 Species diagnosis

Unless the snake has been brought for identification or the circumstances of the bite are helpful, the clinician will have to rely on the clinical picture and the results of bedside and laboratory tests to make a species diagnosis. Clinical features are rarely diagnostic and so a syndromic approach is recommended to guide antivenom treatment (see above).

# Chapter 10

## First Aid and Transport to Medical Care (Including what not to do)

### 10.1 Essential first-aid procedures

It is essential that first aid is carried out by bite victims themselves or bystanders, using materials that are immediately available. While instituting the following first aid procedures, organize transport to get the patient to a medical facility as soon as possible (e.g. use cellular phone and other forms of communication to call for help).

**10.1.1** Move the victim to safety from the area where they might be bitten again and remove the snake if it is still attached but not with your bare hands. Sea snake victims should be removed from the water to prevent drowning.

**10.1.2** Reassure the victim, who may be terrified. Reassurance is justified as most bites result in negligible or no envenoming and, even if the patient is envenomed, there is usually ample time to transport them to medical care. Deaths occur in hours after elapid bites, in days after viper bites.

**10.1.3** Remove constricting clothing, rings, bracelets, bands, shoe etc from the bitten limb.

**10.1.4** Immobilize the whole patient, especially the bitten limb, using a splint or sling. Muscular contractions anywhere in the body, but especially in the bitten limb, will promote the absorption and spread of venom from the site of the bite via veins

and lymphatics; all movements should be avoided as far as possible.

**10.1.5** The pressure-immobilization technique (Sutherland et al, 1979) demands special equipment and training and is not considered practicable for general use in Africa. However, it might be feasible in certain specific settings such as institutions, zoos, fieldwork programmes or expeditions where the necessary equipment and highly trained staff could be made available or in highly motivated communities (see Annex 6). It is a safer alternative to the use of the highly dangerous tight (arterial) tourniquets that cause many gangrenous limbs throughout Africa (see below).

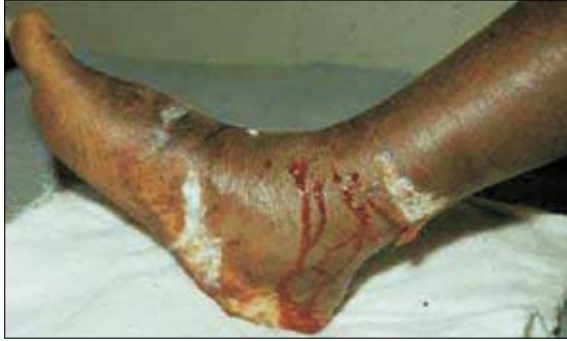**10.1.6** Transport the patient as quickly and as passively as possible to the nearest facility available for medical care (health clinic, dispensary or hospital). Ideally, patients should be transported by stretcher, in a motor vehicle, on a bicycle (as a passenger), or by boat, or the patient can be carried using the "fireman's lift".

**10.1.7** Avoid the many harmful and time-wasting traditional first-aid treatments. Rejected or controversial first aid methods are discussed below.

Cauterization, incision (Figure 119) or excision, tattooing, immediate prophylactic amputation of the bitten digit, suction by mouth, vacuum pumps (Bush, 2004) or "venom-ex" apparatus, instillation of



chemical compounds such as potassium permanganate, application of ice packs (cryotherapy), "snake stones" or electric shocks are absolutely contraindicated as they are all potentially harmful and none has any proven benefit (Hardy, 1992).



© David A. Warrell

**Figure 119: Saw-scaled viper *Echis ocellatus* bite, persistent profuse bleeding from multiple incisions at the site of bite inflicted 18 hours earlier**

Incisions provoke uncontrolled bleeding if the blood is incoagulable; may damage nerves, blood vessels or tendons; and introduce infection. Suction, chemicals and cryotherapy increase the risk of tissue necrosis.

**A tight (arterial) tourniquet should NEVER be used!** Tourniquet is one of the most popular first-aid methods in Africa and continues to cause terrible morbidity and even mortality in snakebite victims: tourniquet should not be used. The dangers of tourniquets are ischaemia and gangrene, if they are applied for more than about 2 hours; damage to peripheral nerves (especially the lateral popliteal nerve at the neck of the fibula); increased fibrinolytic activity; congestion and swelling; increased bleeding; increased local effects of venom; and, immediately after release, shock, pulmonary embolism or rapidly-evolving life-threatening systemic envenoming.

Do not wash, rub, massage or tamper with the bite wound in any way. These interventions may encourage systemic absorption of venom from the site, or they may introduce infection.

**10.1.8** Since species diagnosis is important, the snake should be taken along to hospital if it happens to have been killed. However, if the snake is still at large, do not risk further bites and waste time by searching for it. Even snakes which appear to be dead should not be touched with the bare hands but carried in a bag or dangling across a stick. Some species (e.g. rinkhals *Hemachatus haemachatus*) pretend to be dead (sham death), and even the fangs of a severed snake's head can inject venom!

## 10.2 Pressure-pad method

Scientists at Monash University first suggested this alternative to pressure immobilization. It is a simpler method for attempting to delay venom absorption, using local compression at the bite site (Anker et al, 1982; 1983). It has been studied by Tun-Pe et al, in victims of Russell's viper bites in Myanmar (Tun-Pe et al, 1995). Application of a foam rubber pad directly over the bite wound delayed systemic envenoming, as assessed by measurements of venom antigenaemia. This method appeared safe and effective in a preliminary field trial (Tun-Pe et al, 2000).

## 10.3 Treatment of early symptoms

**10.3.1** Distressing and dangerous effects of envenoming may appear before the patient reaches a health facility. Local pain may be intense. Oral paracetamol is preferable to aspirin or non-steroidal anti-inflammatory

agents, which carry the risk of gastric bleeding in patients with incoagulable blood. Severe pain should be treated with opiates but there is danger of respiratory depression.

**10.3.2** Vomiting is a common early symptom of systemic envenoming. Lay the patient in the recovery position (on the left side), head down to avoid aspiration. Persistent vomiting can be treated with chlorpromazine by intramuscular injection (25-50 mg in adults,

1 mg/kg in children) or prochlorperazine intramuscular dose in adults is 12.5 mg. Note that in patients with incoagulable blood, injections can cause haematomas. Pressure dressings should be applied to all injection sites to prevent oozing.

Suppositories are more appropriate in children. Avoid if <10 kg or < than 1 year. Rectally give in 2-3 divided doses: 10-13 kg, up to 7.5 mg/day; 14-17 kg, up to 10 mg/day; 18-40 kg, up to 15 mg/day) by intrarectal suppositories.



# Chapter 11

## Emergency Clinical Management of Snakebite

### 11.1 Introduction

**Snakebite is a medical emergency.** Ideally, all patients bitten by snakes should be assessed by medically-trained staff. Uncertainties, such as the species responsible, the amount of venom injected and the variable time course for development of signs, demand that patients be kept under observation for at least 24 hours. Medical staff must decide quickly whether the patient has been bitten by a snake, whether there are signs of envenoming and whether antivenom or ancillary treatment is needed.

### 11.2 Rapid clinical assessment and resuscitation

**Rapid clinical assessment and resuscitation are essential.** In Africa, patients may arrive in hospital between hours and many days, after being bitten. They may, therefore, show early or late signs of envenoming or its complications. It is essential that all patients with a history of snakebite be assessed rapidly; they may be moribund but still salvageable by appropriate resuscitation.

### 11.3 Cardio-pulmonary resuscitation

Cardio-pulmonary resuscitation may be needed. This includes clearance of the airway, oxygen administration by face mask or nasal catheters, and establishment of

intravenous access to allow treatment of hypovolaemic shock with intravenous fluids and medicines.

**11.3.1** Airway, respiratory movements (Breathing) and arterial pulse (Circulation) must be checked immediately. Vital signs must be recorded: blood pressure, pulse rate and respiratory rate.

**11.3.2** If the patient is unresponsive and no pulse or respiratory movement is detectable, start cardio-pulmonary resuscitation (CPR) immediately (external cardiac compression: mouth-to-mask respiration in the ratio 30:20, check electrocardiogram for arrhythmia, defibrillate if appropriate).

**11.3.3** In case of respiratory distress/failure: clear the airway (tongue, foreign bodies etc), lift the chin, give oxygen by face mask or nasal catheters with or without assisted ventilation and consider the need for endotracheal intubation.

**11.3.4** In case of circulatory failure/shock (impaired consciousness, cold cyanosed extremities)/hypotension (systolic pressure less than 80-90 mmHg with rapid pulse): raise the foot of the bed on blocks, establish intravenous access with one or two wide-bore cannulae and start infusing normal (0.9%) saline or other available crystalloid or colloid as soon as possible. If intravenous access seems impossible, consider femoral venous or intraosseous access (annexes 4 and 5). However, avoid excessive fluid



replacement as this may result in fluid overload/pulmonary oedema. Consider the need for a vasopressor medicine such as phenylephrine or noradrenalin or adrenalin. Techniques for achieving venous access in difficult cases and for monitoring intravenous fluid therapy by measuring jugular venous or central venous pressures are given in annexes 3 and 4.

11.3.5 Level of consciousness should be recorded and monitored if possible using the semi-quantitative Glasgow Coma Scale, but in patients with advanced neurotoxicity from snakebite it is difficult to assess. These patients appear unconscious because their eyes may be closed (eyelids are paralyzed, i.e. ptosis) and they may be unable to speak or move their limbs because of the descending flaccid paralysis typical of venom-induced neurotoxicity.

11.3.6 In patients with generalized flaccid paralysis whose ventilation is adequately supported, full consciousness can often be confirmed by asking them to signal, in response to spoken questions or commands, by flexing a finger or toe. These movements may remain possible even when paralysis is virtually complete. In patients with complete ptosis, raising the upper eyelids manually, so that they can see their surroundings, is very reassuring and helps to rouse them and establish communication.

## 11.4 Urgent intervention

Patients bitten by venomous snakes in Africa may present with any of the following problems requiring urgent intervention:

**11.4.1** Profound hypotension and shock, resulting from:

- hypovolaemia secondary to extravasation of plasma volume into the bitten limb, external or concealed blood loss, persistent vomiting and failure of adequate oral fluid intake;
- direct cardiovascular effects of the venom (for example, after viper/adder and *Atractaspis* bites);
- autopharmacological effects of the venom (activation/inhibition of physiological vasomotor systems, such as the angiotensin-renin-bradykinin system, by venom toxins); and, rarely,
- Anaphylaxis provoked by antivenom given outside hospital or, rarely, provoked by venom in those who have been sensitized by previous exposure.

**11.4.2** Sudden deterioration after release of a tourniquet or compression bandage, resulting in shock, bleeding or respiratory paralysis. These bands, bandages or ligatures are often removed too hastily by hospital staff before antivenom treatment has been initiated and appropriate staff and equipment are on hand in case resuscitation is needed.

**11.4.3** Airway obstruction resulting from aspirated vomit or the tongue blocking the upper airway, especially in patients with evolving bulbar paralysis who have not been transported to hospital in the left lateral (recovery) position. Vomiting can be the result of systemic envenoming or ingestion of emetic traditional herbal remedies.

**11.4.4** Terminal respiratory failure from progressive neurotoxic envenoming that has led to paralysis of the respiratory muscles.

**11.4.5** Intracranial haemorrhage after envenoming by saw-scaled vipers (*Echis*), desert horned-vipers (*Cerastes*), some other vipers and boomslang. There will be characteristic lateralizing signs, dysphasia, impaired consciousness (haemorrhagic stroke) or neck rigidity (subarachnoid haemorrhage).

**11.4.6** Hours after the bite: Cardiac arrest resulting from hyperkalaemia in patients with massive generalized skeletal muscle breakdown (rhabdomyolysis) after sea snake bites and neglected cytotoxic bites.

**11.4.7** Days after the bite: Acute renal failure due to shock and rhabdomyolysis.

**11.4.8** Days after the bite: Septicaemia from secondary infection of necrotic bite wounds or of incisions made at the site of the bite or from complicating aspiration pneumonia (see above).



# Chapter 12

## Management of Snakebite at Community Level and Different Health-care Facilities

In rural areas where snakebite is most frequent, transfer to a hospital may not be feasible within a reasonable time frame of a few hours. In that case, a lower level health facility service must cope with the emergency as suggested below.

### 12.1 At community level

**12.1.1** Check history of snakebite and look for obvious evidence of a bite (fang puncture marks, swelling of the bitten part).

**12.1.2** Immobilize the whole patient as far as possible and especially the bitten limb; give reassurance.

**12.1.3** Arrange transport of the patient to medical care as quickly, safely and passively as possible by motor vehicle, boat, bicycle, stretcher etc. Ideally the patient should lie in the recovery position (prone, on the left side) with the airway protected to minimize the risk of shock and inhalation of vomit.

**12.1.4** Discourage time-wasting and potentially dangerous traditional treatments such as tight ligatures (tourniquets), incisions, suction and application of herbs, ice, chemicals, snake stones.

**12.1.5** If the snake responsible has already been caught or killed, take it with patient but ensure safety and avoid direct contact.

### 12.2 At rural clinic, dispensary or health post

Different levels of health care can contribute to the management of a patient with suspected snakebite. Since the treatment of severe envenoming is a medical emergency that may require a range of medical skills, equipment, antivenom and other medicines, referral should be to the highest level of care that is readily available.

**12.2.1** Simple medical assessment: history and simple physical examination – local swelling, painful tender enlarged local lymph glands, persistent bleeding from the bite wound, blood pressure, pulse rate, bleeding (gums, nose, vomit, stool or urine), level of consciousness, drooping eyelids (ptosis) and other signs of paralysis, 20MWBCT, urine examination (appearance, sticks testing for blood etc). Identify the snake (if brought).

**12.2.2** Assess need and feasibility of transporting the patient to a higher level of the health service (see 12.1.3 above).

**12.2.3** Give analgesia by mouth if required: paracetamol (acetaminophen) (adult dose 1 g maximum 4 g in 24 hours; children 15–20 mg/kg, maximum 100mg/kg/day) or codeine phosphate (adult dose 30–60 mg maximum 240 mg in 24 hours; children more than 2 years old, 0.5 mg/kg, maximum 2 mg/kg/day) can be given every 4–6 hours by mouth as required (not aspirin or non-steroidal anti-inflammatory medicines which can cause bleeding).



**12.2.4** If the necessary skills, equipment, antivenom and other medicines are available give intravenous fluid to correct hypovolaemic shock and if the patient fulfils criteria for antivenom treatment, give antivenom. These skills include ability to diagnose local and systemic envenoming, set up intravenous infusion or intravenous injection, identify the early signs of anaphylaxis and treat it with intramuscular adrenaline/epinephrine. If no antivenom is available, transfer to a hospital.

**12.2.5** If the patient has evidence of respiratory paralysis, give oxygen by mask and transfer to a hospital. It is assumed that assisted ventilation other than by a tight-fitting face mask connected to an anaesthetic (Ambu) bag will not be possible at this level.

**12.2.6** Discourage the use of ineffective and potentially harmful medicines (e.g. corticosteroids, antihistamines, and heparin).

## 12.3 At the District Hospital

Proceed as in 12.2 above plus:

**12.3.1** More detailed clinical and laboratory assessment including biochemical and haematological measurements, ECG or radiography as indicated.

**12.3.2** If no antivenom is available, transfer to a hospital that has antivenom or treat conservatively; this may require transfusion of blood or fresh frozen plasma (see below).  
**12.3.3** Reassess analgesia (see 12.2.3 above) and, if required, consider stronger parenteral opioid medicines as required all with great caution (e.g. subcutaneous, intramuscular or even intravenous pethidine, initial adult dose 50-100 mg; children 0.5–1 mg/kg; or

morphine, initial adult dose 5-10 mg; children 0.03-0.05 mg/kg). Facilities must be available to provide ventilatory support if necessary.

**12.3.4** If the patient has evidence of local necrosis (gangrene), give tetanus toxoid booster, antibiotics and consider surgical debridement of dead tissue.

**12.3.5** If the patient has evidence of bulbar or respiratory paralysis, insert endotracheal tube or laryngeal mask airway. If there is evidence of respiratory failure, assist ventilation manually by anaesthetic (Ambu) bag or mechanical ventilator.

**12.3.6** If the patient has evidence of acute renal failure, treat with peritoneal dialysis. If this is not available, transfer to a specialized hospital.

**12.3.7** If the patient is bleeding severely or is already seriously anaemic, consider blood transfusion.

**12.3.8** Simple rehabilitation (exercising of bitten limb).

## 12.4 Referral (Higher Level) Hospital

Proceed as in 12.2.and 12.3 above plus:

**12.4.1** More advanced surgical management of local necrosis (e.g. split skin grafting).

**12.4.2** More advanced investigations including bacterial cultures and imaging (CT scans) as indicated.

**12.4.3** If the patient has evidence of acute renal failure peritoneal or haemodialysis or haemofiltration.

**12.4.4** Rehabilitation by physiotherapists.

# Chapter 13

## Antivenoms

### 13.1 Introduction

Antivenoms are the only effective specific treatments or antidotes for snakebite. They are raised in large domestic animals (usually horses, donkeys or sheep) by hyperimmunizing them against a single snake venom (producing a monovalent/monospecific antivenom) or against venoms of several species of snakes whose bites are common and frequently lead to severe envenoming in the geographical area where the particular antivenom is intended to be used (producing a polyvalent/polyspecific antivenom).

### 13.2 Antivenom production

The venom of a single species of snake may vary in composition and antigenicity (see above) (Warrell, 1997). As a result, pooled venom from many (20-50) individual specimens of each snake species should be used for antivenom production. These individuals should come from different parts of the geographical range and should include some younger (smaller) specimens to take these factors into account.

After animals have completed the immunization schedule, plasma is collected, preferably by plasmapheresis (so that the red blood cells can be returned to the donor animal) and is passed through several processes designed to produce either refined whole IgG antibodies or IgG antibody fragments such as F(ab')<sub>2</sub> or Fab, which are free of other plasma proteins such as albumin, fragments such as Fc,

aggregates (a major cause of antivenom reactions), pyrogens and microbes. It is then either lyophilized or stored as a liquid.

Lyophilized antivenom has a longer shelf life but is more expensive and must be redissolved in liquid before use. Liquid antivenom in glass ampoules should be stored at 2-8 °C (not frozen).

Polyspecific (polyvalent) antivenom is derived from animals hyperimmunized against the venoms of several snake species (those known to be of the greatest medical importance in the area where the antivenom is intended to be used), while monospecific (monovalent) antivenom is derived from animals immunized against the venom of a single snake species. Polyspecific antivenom allows syndromic management of snakebite where the identity of the snake responsible for the bite is uncertain while monospecific antivenom requires precise knowledge of the snake species responsible. Larger doses of polyvalent than of monovalent antivenom, and hence a larger protein load, may be required to treat a particular case of snakebite, but this is not always certain.

### 13.3 Antivenom use

Antivenom neutralizes a fixed amount of venom. Since snakes inject the same amount of venom into adults and children, the same dose/volume of antivenom must be administered to children as to adults. Antivenom can be effective as long as

venom is still active in the patient's body causing symptoms of systemic envenoming. These may persist for several days or even weeks after the bite (e.g. incoagulable blood and bleeding after saw-scaled viper bites).

### 13.4 Precautions

As antivenom is scarce, expensive and might have potentially serious side effects, it should be administered only if there is threat to life or limb. Administration may be associated with acute life-threatening adverse reactions (anaphylaxis), pyrogenic (feverish) reactions, or later immune complex disease (serum sickness). The former may be treated (and perhaps prevented) with epinephrine (adrenaline) and the latter with antihistamines and corticosteroids.

### 13.5 Producers and suppliers

There is great concern about the supply of antivenom for Africa. Some of the large traditional manufacturers have either stopped or have reduced production. The only antivenom producers based in Africa are SAVP (Pty) Ltd. in South Africa, Vacsera (EgyVac) in Egypt and one or two Pasteur Institutes in North Africa. Some antivenoms made in India have been marketed in Africa despite the fact that non-African snake venoms have nearly always been used in their production. In some cases, the results have been disastrous (Warrell, 2008; Visser et al, 2008).

Below are details of some known antivenom producers and the antivenoms they produce. The information was correct at the time of preparing the present guidelines. For more information, the following web sites can be visited:

<http://www.toxinfo.org/antivenoms/synopsis.html> <http://globalcrisis.info/latestantivenom.htm> [http://www.who.int/bloodproducts/animal\\_sera/en/](http://www.who.int/bloodproducts/animal_sera/en/) <http://www.toxinology.com/>

#### 13.5.1 Egyptian Organization for Biological Products and Vaccines (VACSERA) (now EgyVac)

51 Wezaret El Zeraa St. Agouza, Giza, Egypt 22311 <http://www.vacsera.com>  
phone (20 2) 761-1111 ext. 1633  
fax (20 2) 336-9872/748-3187/760-9177  
ceo@vacsera.com m.abadi@vacsera.com

Polyvalent snake venom antiserum: *Bitis arietans*, *Bitis gabonica*, *Cerastes cerastes*, *Cerastes vipera*, *Echis carinatus multisquamatus*, *Macrovipera lebetina*, *Naja haje*, *Naja melanoleuca*, *Naja mossambica*, *Naja nigricollis*, *Naja oxiana*, *Naja pallida*, *Pseudocerastes fieldi*, *Vipera ammodytes*, *Vipera palaestinae*, *Vipera xanthina*.

#### 13.5.2 Felsenstein Medical Research Center (formerly Rogoff-Wellcome Medical Research Institute)

Rabin Medical Center Petah-Tikva 49100  
Tel Aviv University Sackler School of  
Medicine Tel Aviv, Israel <http://www.tau.ac.il/medicine/felsenstein> phone 972-3-937-6741, fax 972-3-924-7019 [hmoroz@post.tau.ac.il](mailto:hmoroz@post.tau.ac.il)

Anti-Echis coloratus: *Echis coloratus*.

#### 13.5.3 Institut Pasteur de Tunis

13 Rue Place Pasteur Tunis Belvédère,  
Tunisia BP 74, 1002 Phone 216 (7)1 840 716,  
fax 216 (7)1 841 203

Antiviperin sera: *Cerastes cerastes*, *Cerastes vipera*, *Macrovipera lebetina*, *Macrovipera mauritanica*.

#### 13.5.4 Instituto Clodomiro Picado

San Jose, Costa Rica Phone +506-229-0344,  
Fax:+506-292-0485 Email: josemorama@  
gmail.com URI: <http://www.icp.urc.ac.cr>  
EchiTAb-Plus-ICP: *Echis ocellatus*, *Bitis*  
*arietans*, *Naja nigricollis* (Abubakar et al,  
2009).

#### 13.5.5 MicroPharm Ltd

Unit F/G, Station Road, Industrial Estate,  
Newcastle Emlyn Carmarthenshire, Wales,  
United Kingdom SA38 9BX  
<http://www.micropharm.co.uk>  
Phone 44 (0) 1239 710529,  
Fax 44 (0) 1239 710529  
[enquiries@micropharm.co.uk](mailto:enquiries@micropharm.co.uk)

EchiTAb-Plus-ICP: *Echis ocellatus*, *Bitis*  
*arietans*, *Naja nigricollis* (Abubakar et al,  
2009).

#### 13.5.6 National Antivenom and Vaccine Production Center (NAVPC)

The National Guard King Abdulaziz Medical  
City  
P.O. Box 22490, Riyadh, Saudi Arabia 11426  
<http://www.ngha.med.sa>  
phone 966-1- 252 0252, ext. 5626/5637/5655  
fax 966-1- 252 0188  
[info@antivenom-center.com](mailto:info@antivenom-center.com) or [navpc@  
ngha.med.sa](mailto:navpc@ngha.med.sa)

Polyvalent snake antivenom-equine: *Bitis*  
*arietans*, *Cerastes cerastes*, *Echis carinatus*  
*multisquamatus*, *Echis coloratus*, *Naja haje*,  
*Walterinnesia aegyptia*.

Bivalent *Naja/Walterinnesia* snake  
antivenom-equine: *Naja haje arabica*  
*Walterinnesia aegyptia* (also *Naja haje*  
*haje*, *N. melanoleuca*, *N. naja*, *N.nigricollis*,  
and *N. nivea*).

Experimental bivalent "black snake"  
antivenom: *Walterinnesia aegyptia*,  
*Atractaspis microlepidota andersoni* (Ismail  
et al, 2007).

#### 13.5.7 Sanofi-Pasteur (formerly Pasteur- Merieux-Connaught)

2, Avenue Pont Pasteur, CEDEX 07 Lyon,  
France 69367.  
Phone 33 (0)4 37 37 01 00, Fax 33 (0)4 37 37  
77 37 <http://www.sanofipasteur.com>

Fav-Afrique: *Bitis arietans*, *Bitis gabonica*,  
*Dendroaspis jamesoni*, *Dendroaspis*  
*polylepis*, *Dendroaspis viridis*, *Echis*  
*leucogaster*, *Naja haje*, *Naja melanoleuca*,  
*Naja nigricollis*.

Favirept: *Bitis arietans*, *Cerastes cerastes*,  
*Echis leucogaster*, *Macrovipera deserti*,  
*Naja haje*, *Naja nigricollis*.

#### 13.5.8 South African Vaccine Producers (Pty) Ltd. (SAVP) (formerly SAIMR)

PO Box 28999 Sandringham 2131  
Johannesburg, South Africa  
<http://www.savp.co.za>  
Tel (011) 386 6052 [cillaf@savp.co.za](mailto:cillaf@savp.co.za)

SAVP Boomslang antivenin: *Dispholidus*  
*typus*.

SAVP Echis antivenom: *Echis carinatus*,  
*Echis ocellatus*.

SAVP polyvalent snake antivenom: *Bitis*  
*arietans*, *Bitis gabonica*, *Bitis heraldica*,  
*Dendroaspis angusticeps*, *Dendroaspis*  
*jamesoni*, *Dendroaspis polylepis*,  
*Hemachatus haemachatus*, *Naja*  
*annulifera*, *Naja melanoleuca*, *Naja*  
*mossambica*, *Naja nivea*.



**13.5.9 Instituto Bioclon also known as “Bioclon, S.A. de C.V.”**

Calzada de Tlalpan # 4687 Col. Toriello Guerra Mexico, D.F., Mexico C.P. 14050  
<http://www.bioclon.com.mx/> Leonides Suarez Rodriguez, Production Manager,  
Phone 52-5-488-3716,  
Fax 52-5-688-2074  
[jpaniagu@silanes.com.mx](mailto:jpaniagu@silanes.com.mx)

“Antivipmyn Africa”: *Bitis gabonica*, *B. arietans*, *Echis ocellatus*, *E. leucogaster*, *E. pyramidum*, *Naja haje*, *N. melanoleuca*, *N. nigricollis*, *N. pallida*, *Dendroaspis polylepis* (Stock et al, 2007; Chippaux et al, 2007; Abubakar et al, 2009).

**13.5.10 Indian antivenom manufacturers**

Several Indian producers, including Serum Institute of India (SII), Vins Bioproducts and Bharat Serum and Vaccines Ltd. (Asna Antivenom), export antivenoms to Africa. **The clinical efficacy and safety of these antivenoms needs to be established. Confirm that the venoms used for their production are from African and not Asian snake species. Beware of misleading labelling implying that they have activity against African rather than Asian cobra and saw-scaled viper venoms** (Warrell, 2008; Visser et al, 2008; Warrell and Williams, 2009; Visser et al, 2009).

# Chapter 14

## Antivenom Treatment

### 14.1 Appropriate use of antivenoms

The most important and urgent decision to be made concerning any patient bitten by a snake is whether or not to give antivenom, the only specific antidote to venom. There are various reasons why antivenom should never be used routinely, indiscriminately or carelessly, but only when indicated. The reasons are discussed below.

**14.1.1** All commercial antivenoms carry a risk of potentially dangerous early anaphylactic reactions.

**14.1.2** Antivenom is not always necessary: some patients are bitten by non-venomous snakes and 10%–50% of those bitten by venomous snakes are not envenomed.

**14.1.3** Antivenoms have a defined range of specific and paraspecific neutralizing activity but are useless for venoms outside that range. Currently (2010), specific antivenoms are not available for treatment of envenoming by the following species:

- *Thelotornis* species and other colubrids except the boomslang *Dispholidus typus*
- Atractaspis species (except for Arabian *A. microlepidota andersoni*)
- Elapid species which rarely bite: *Aspidelaps*, *Naja* (*Boulengerina*), *Elapsoidea*, *Pseudohaje*, *Naja* (*Paranaja*) etc.
- *Atheris* species
- *Bitis atropos* and other smaller *Bitis* species
- Night adders (Genus *Causus*) which bite commonly but cause only mild local effects
- Sea snakes (*Pelamis platurus*): although an antivenom is manufactured by Commonwealth Serum Laboratories in Australia, it is not available anywhere in Africa.

**14.1.4** Antivenom is very expensive, usually in short supply and has a limited shelf life. Scarce and valuable supplies must not be wasted.

**Table 14.1 Indications for antivenom treatment after bites by African snakes**

<b>Systemic envenoming</b>
1. Neurotoxicity
2. Spontaneous systemic bleeding
3. Incoagulable blood (20MWBCT)
4. Cardiovascular abnormality: hypotension, shock, arrhythmia, abnormal electrocardiogram
<b>Local envenoming by species known to cause local necrosis*</b>
1. Extensive swelling (involving more than half the bitten limb)
2. Rapidly progressive swelling
3. Bites on fingers and toes

\**Bitis*, *Echis*, *Cerastes*, *Macrovipera* spp. and spitting cobras

## 14.2 Indications for antivenom

Antivenom is indicated in all cases of systemic and severe local envenoming (Table 14:1).

## 14.3 Contraindications to antivenom

There is no absolute contraindication to antivenom when a patient has life-threatening systemic envenoming. However, patients with an atopic history (severe asthma, hay fever etc) and those with a history of previous reactions to equine antisera (e.g. anti-tetanus serum) have an increased risk of severe reactions. In these cases only, pretreatment with subcutaneous adrenaline and intravenous antihistamine and hydrocortisone is justified to prevent or diminish the reaction. There is no time for even rapid desensitization.

**Children should be given the same dose of antivenom as adults (see Chapter 15.9).**

## 14.4 Hypersensitivity testing

Intradermal, subcutaneous or intraconjunctival tests with diluted antivenom are not predictive of early anaphylactic or late serum sickness type antivenom reactions and should no longer be used (Malasit et al, 1986). The reason is that the large majority of these reactions are not IgE-based, Type I hypersensitivity reactions of the kind that might be predicted by prick skin tests or radioallergosorbent tests (RAST). Most early anaphylactic reactions to antivenom result from direct complement activation by aggregates of IgG or its fragments.

## 14.5 Timing of antivenom treatment

Antivenom should be given as soon as possible once signs of systemic or severe local envenoming are evident (Table 14:2). It is almost never too late to try

**Table 14.2 Guide to initial dosage of some important antivenoms for bites by African snakes**

Genus species	English Name	Manufacturer, Antivenom	Approximate Initial Dose
<i>Bifis arietans</i>	Puff adder	SAVP <sup>1</sup> Sanofi-Pasteur	50-100 ml
<i>B. gabonica/B. rhinoceros</i>	Gaboon viper	FavAfrique polyspecific	
<i>Dendroaspis spp.</i>	Mambas	SAVP, Dendroaspis	40-200 ml ( <i>D. polylepis</i> ) less for <i>D. angusticeps</i>
<i>Dispholidus typus</i>	Boomslang	SAVP, Boomslang	20 ml
<i>Echis coloratus</i>	Burton's carpet viper	SAVP, Echis monosp.	20 ml
<i>E. ocellatus</i>	West African/ocellated carpet viper	SAVP, Echis monosp. <sup>2</sup> Sanofi-Pasteur FavAfrique polysp. <sup>3</sup>	20 ml 40 ml
<i>Naja haje</i>	Egyptian cobra	SAVP, polysp.	50-120 ml
<i>N. mossambica</i>	Moçambique spitting cobra/ <i>m'Fezi</i>	SAVP, polysp. <sup>4</sup>	100 ml
<i>N. nigricollis</i>	Black-necked spitting cobra	SAVP, polysp. <sup>5</sup>	50-100 ml
<i>N. nivea</i>	Cape cobra	SAVP, polysp. <sup>6</sup>	80-120 ml

1 South African Vaccine Producers (formerly South African Institute for Medical Research).

2 Warrell et al, 1974.

3 Chippaux et al, 1998.

4 Tilbury, 1982.

5 Warrell et al, 1976b.

6 Blaylock et al, 1985.

antivenom treatment for persistent systemic envenoming; it has proved effective in reversing coagulopathy 10 days or more after *Echis* bites.

**WARNING: When patients arrive at hospital with a tourniquet or other constricting band in place, antivenom treatment, if it is thought necessary, should be started before these are loosened as there is a risk of severe envenoming when the venom in the occluded limb is released into general circulation.**

## 14.6 Antivenom specificity

If the species responsible for the bite is known for certain, monospecific antivenom is the optimal treatment. However, in areas where the venoms of a number of different species produce similar clinical effects, polyspecific antivenoms must be used in the majority of patients who do not bring the dead snake for identification. Polyspecific antivenoms can be just as effective as monospecific antivenoms for the prescribed range of venoms which they cover and may be less expensive. Depending on their method of production, a larger dose may be required to provide the same specific neutralizing power as monospecific antivenom (see above).

## 14.7 Antivenom administration

Antivenom is most effective when given intravenously. Freeze-dried (lyophilized) antivenom should redissolve quickly (less than 10 minutes) in sterile water. Difficulty redissolving suggests faulty manufacture. Antivenom can be given by intravenous injection at a rate of about 5 ml per minute, or diluted in isotonic fluid and infused over 30-60 minutes. The incidence and severity of antivenom reactions was the same with these two methods (Malasit et al, 1986).

The advantage of intravenous infusion is ease of control, but intravenous “push” injection requires less expensive equipment, is quicker to set up and ensures that someone remains at the patient's side during the crucial first 10-15 minutes after the start of treatment, when early reactions are most likely to occur.

When intravenous administration is impossible, antivenom can be given, as a last resort, by deep intramuscular injection at multiple sites in the anterior and lateral aspects of the thighs, followed by massage to promote absorption and application of pressure dressings to limit haematoma formation. **Intramuscular injection is not ideal and not generally recommended** as absorption is very slow. Absorption from intragluteal injection is very unreliable. There is a limit to the volume of antivenom that can be given by this route and there is a risk of haematoma formation in patients with incoagulable blood.

## 14.8 Antivenom dosage

Guidelines for initial dosage based on clinical studies are available for some important antivenom used in West Africa (Table 14.2). In most cases, manufacturers' recommendations given in the package insert are based on mouse assays which may not correlate with clinical findings. The initial dose of antivenom, however large, may not completely neutralize the depot of venom at the site of injection or prevent redistribution of venom from the tissues. Patients should therefore be observed for several days even if they show a good clinical response to the initial dose of antivenom.

Continuing absorption of venom from the bite-site depot and redistribution of venom from the tissues may cause recurrent neurotoxicity or haemostatic problems



after therapeutic antivenom has been eliminated. This process may be enhanced by resuscitation: correction of hypovolaemia and restoration of blood pressure may improve tissue perfusion at the bite site, resulting in further absorption of venom from the site of injection. The average initial dose of antivenom for treating bites by a particular species may vary throughout the geographical range. For example, in Kenya, it is believed that lower doses of antivenom may be effective in treating green mamba (*D. angusticeps*) envenoming.

### 14.9 Response to antivenom treatment

Neurotoxic signs often change slowly, after several hours, or unconvincingly. Cardiovascular effects such as hypotension and sinus bradycardia (for example after bites by *Bitis arietans*) may respond within 10-20 minutes. Spontaneous systemic bleeding usually stops within 15-30 minutes and blood coagulability is restored within about six hours if an adequate dose of antivenom has been given. The 20MWBCT (see Chapter 9) should be used to monitor the dose of antivenom in patients with coagulopathy. If the blood remains incoagulable 6 hours after the first dose, the dose should be repeated and so on, every 6 hours, until blood coagulability is restored.

It must be emphasized that the administration of polyvalent antivenom in the acute phase of neurotoxic snake envenoming will usually not prevent progression of neurotoxic effects, most notably respiratory paralysis, and consequently the patient will not survive without life support. Respiratory support is the only life-saving treatment modality in neurotoxic snake envenoming. However, intravenous administration of adequate dose of antivenom will decrease the time course

of muscle paralysis and recovery. Similarly, in cytotoxic envenoming, administration of polyvalent antivenom will not reverse but may limit further tissue damage. On the other hand, the haemostatic effects of boomslang and carpet viper envenomings are rapidly reversed by their specific antivenoms at any time after the bite.

Antivenom treatment has undoubtedly reduced snakebite mortality. In northern Nigeria, mortality was reduced from approximately 20% to less than 3% following bites by *Echis ocellatus* (Warrell et al, 1977). Some antivenoms are capable of rapidly eliminating venom antigenaemia and reversing haemostatic and cardiovascular abnormalities. Efficacy against neurotoxicity, even against the predominantly post-synaptic neurotoxins of African elapids, is less convincing. The efficacy of antivenoms in preventing local necrosis is controversial. Laboratory studies have shown that the antivenom must be given very early after envenoming to prevent these changes, but clinical observations suggest that antivenom may prevent local necrosis after bites by *Bitis arietans*, *Naja mossambica* and *N. nigricollis* if given in adequate doses within three to six hours of envenoming (Warrell et al, 1975; Tilbury, 1982; Warrell et al, 1976b).

## 14.10 Antivenom reactions

### 14.10.1 Early reactions

Early reactions begin 3-60 minutes after starting intravenous administration of antivenom. Cough, tachycardia, itching (especially of the scalp), urticaria (Figure 120), fever, nausea, vomiting and headache are common symptoms. More than 5% of patients with early reactions develop systemic anaphylaxis: hypotension, bronchospasm and angio-oedema (Figure 121). However, there are

few reports of deaths reliably attributed to these reactions. The incidence of these reactions varies from 3-54% depending on manufacturer, refinement, dose and route of administration. The vast majority of early anaphylactic antivenom reactions are not immediate type I hypersensitivity reactions but result from complement activation by aggregates of IgG or its fragments present in the antivenom.

Adrenaline (epinephrine) 0.1% (1 in 1000) should be given intramuscularly in a dose of 0.5-1.0 ml for adults, 0.01 mg/kg for children. This should be followed by an intravenous injection of an H1 antagonist (antihistamine) such as chlorphenamine maleate (10 mg for adults, 0.2 mg/kg for children) or promethazine (25 mg intramuscularly in adults; contraindicated in children <2 years of age; in children 5-10 years old 6.25-12.5 mg and in children 10-16 years old 12.5-25 mg intramuscularly).

#### 14.10.2 Pyrogenic reactions

Pyrogenic reactions result from pyrogen contamination of the antivenom during manufacture. They begin within 1-2 hours after treatment. There is an initial chill with cutaneous vasoconstriction, gooseflesh and shivering. Temperature rises sharply during the rigors and there is intense vasodilatation,

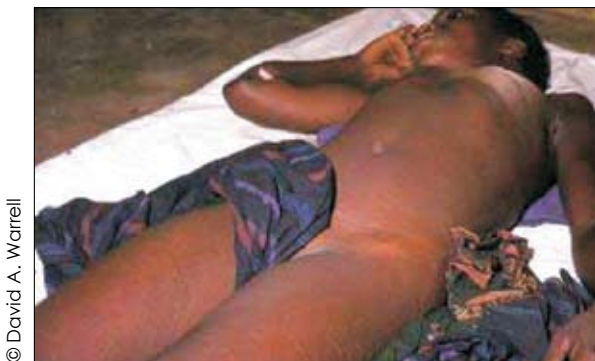widening of the pulse pressure and eventual fall in mean arterial pressure. In children, febrile convulsions may occur at the peak of the fever. Patients should be laid flat to prevent postural hypotension. Their temperature should be reduced by fanning, tepid sponging and antipyretic medicines such as paracetamol (15 mg/kg) given by mouth, suppository or via nasogastric tube.

#### 14.10.3 Late reactions

Late (serum sickness type) reactions occur 5-24 (average 7) days after treatment. There is itching, urticaria, fever, arthralgia, peri-articular swellings, proteinuria and sometimes neurological symptoms. Antihistamines are used for milder attacks, but in severe cases, including those with neurological symptoms, a short course of prednisolone should be given.

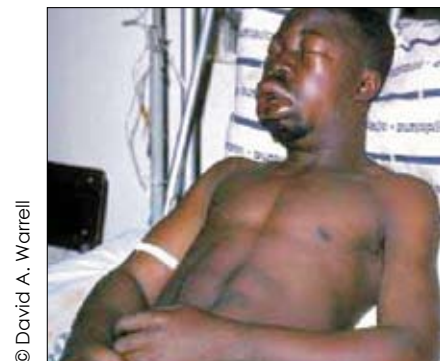#### 14.11 Specific issues about antivenoms

Antivenom, if available, should be administered only when there is a threat to life or limb, as determined clinically, because administration is not without risk and is expensive. If antivenom is used, it must be specific for the venom of the snake suspected or proved to be responsible for the particular snakebite. Otherwise, there will be risk without benefit.



© David A. Warrell

**Figure 120: Early antivenom reaction: generalized urticaria**



© David A. Warrell

**Figure 121: Angioedema**

### 14.11.1 Route of administration

Antivenoms should always be given intravenously for maximal therapeutic effect. Administration by other routes (intramuscular, subcutaneous) result in maximum blood levels after many hours which are lower than those achieved by intravenous administration. This is too little and too late in an emergency situation. A slow intravenous injection (over 5–10 minutes) is as safe as an infusion (antivenom in 200 ml or more of saline solution) and ensures that medical personnel are at the bedside should an acute adverse reaction occur. Should intravenous administration be impossible, then intramuscular injection in several places (adult) or intraosseous injection in a child is the second best choice (see Annex 5).

### 14.11.2 Antivenom in pregnancy

Pregnant patients may develop uterine vasoconstriction during compensated hypovolaemic shock even though maternal vital signs may appear normal. As a result, the fetus may become hypoxic while the mother has normal tissue oxygenation. Adequate fluid resuscitation and oxygenation of the mother are therefore essential. Uterine and fetal heart rate monitoring are recommended to detect asymptomatic premature labour and fetal distress. If there is coagulopathy, retroplacental haemorrhage may occur causing high maternal and fetal mortality. Early, adequate doses of antivenom are therefore essential if there is any suggestion of anti-haemostatic disorders. Labour (for example, induced by the snakebite) in a woman with snake

venom-induced haemostatic abnormalities may be complicated by massive post-partum haemorrhage.

### 14.11.3 Antivenom in children

Venous access may be a problem. The intraosseous route may be required. Due to high venom: mass ratio both morbidity and mortality are higher than in adults. Swelling travels further and faster up their bodies, coagulopathies occur sooner as does weakness and respiratory failure due to a faster evolution of envenomation. Frequent reassessment of snake bitten children is necessary. Should the indications for antivenom administration be followed, then children will receive antivenom sooner and more frequently than adults.

## 14.12 Snakebite and traditional practices

Traditional practices and healers are held in high esteem in most African communities and play a large role in the village-based treatment of many illnesses, including snakebite. There is need to educate traditional practitioners in evidence-based snakebite management and to make use of the trust and belief members of the community have in them.

It should be emphasized that in many cases of snakebite, traditional healing procedures have resulted in delayed transfer of victims to health-care facilities, thus increasing the risk of death and permanent sequelae. Traditional healers should, therefore, be encouraged not to delay the victim's transfer

to a health-care facility. They should also be discouraged from engaging in practices that may endanger lives, especially where efficacy has not been established. These include incisions applying the black (snake) stone and tight tourniquets, and administering unproven herbal remedies.

To date, no herbal or traditional remedy for snakebite has proved effective in a clinical trial. To validate efficacy of African traditional treatments, properly designed scientific research should be instigated.





# Chapter 15

## Ancillary Treatment

### 15.1 Treatment of local envenoming

**15.1.1 Tetanus toxoid:** It is appropriate to give a prophylactic booster dose of tetanus toxoid to all snakebite victims. This is also a safe and useful “placebo” for those who are not envenomed but need the reassurance of being given some sort of therapy.

**15.1.2 Wound infection:** Although most local effects of snakebite are attributable directly to cytolytic and other activities of the venom itself, the bite may introduce bacteria, and the risk of local infections greatly increases if the wound has been incised with an unsterile instrument, tampered with in some other way or if it contains necrotic tissue. The potential risk of tetanus must be addressed by boosting immunity (see above). The pattern of bacterial flora may vary in different countries (Theakston et al, 1990). Antibiotic treatment should be delayed until there are definite signs of infection, such as a hot reddened fluctuant local swelling resembling an abscess or if the wound is necrotic. Appropriate blind antibiotic treatment is with chloramphenicol or amoxicillin with clavulanic acid. Prophylactic antibiotics are not appropriate (Jorge et al, 2004) unless the wound has been grossly interfered with or is frankly necrotic.

**15.1.3 Care of the bitten limb:** the wound should be cleaned with an antiseptic. Blisters and bullae should be left intact. Snake-bitten limbs should be nursed in the most comfortable position but should not be

elevated excessively if there is tense swelling or suspicion of incipient intracompartmental syndrome as this increases the risk of ischaemia. The wound should be examined frequently for evidence of necrosis: blistering, blackening or depigmentation of the skin, loss of sensation and a characteristic smell of putrefaction.

**15.1.4 Debridement of necrotic tissue:** necrotic tissue should be debrided by a surgeon under general or local anaesthesia as soon as possible to reduce the risk of secondary infection and to promote eventual healing (Warrell and Rollinson, 2000). Skin appearances may be deceptive, for necrosis can undermine apparently normal skin. Large areas may be denuded of skin; recovery can be accelerated by applying split skin grafts immediately after debridement provided that the wound is not infected. Debrided tissue, serosanguinous discharge and pus should be cultured and the patient treated with appropriate antimicrobials. Fluctuant areas, suggestive of an underlying abscess, should be aspirated and opened for drainage. Inexperienced surgeons may mistake bruised for necrotic muscle. In some cases, muscle fibres damaged by snake venom myotoxins (phospholipases  $A_2$ ) may regenerate if the muscle sheath is left intact and so debridement should be restrained.

**15.1.5 Compartment syndromes:** these are uncommon and over-diagnosed but require urgent attention. The clinical appearance of snake-bitten limbs often suggests that there is a compartment syndrome. There may

be severe pain, tense tender swelling, cold cyanosed anaesthetic skin, pain on passive stretching of the muscles and apparently absent pulses. However, these appearances are usually misleading and when the intracompartmental (tissue) pressure is measured directly (for example with a Stryker monitor) pressures are found to be below the threshold of danger for ischaemic necrosis of the intracompartmental muscles.

**15.1.6 Compartment syndromes** of hands and feet tend to self decompress via the bite site. If a compartment syndrome in a limb is suspected, the pressure should be measured directly as this is the only reliable way of confirming raised intracompartmental pressure and justifying fasciotomy.

However, many surgeons seem reluctant to measure the pressure. The normal intracompartmental pressure is 0-10 mmHg. An intracompartmental pressure of more than 45 mmHg is usually associated with compartment syndrome, but there may be a risk of intracompartmental ischaemia at lower pressures if mean arterial pressure<sup>1</sup> (perfusion pressure; **mean arterial pressure = diastolic pressure + 1/3 [systolic – diastolic pressure]**) is reduced, for example, in an elevated limb (Matsen, 1980). If the pressure is raised but mean arterial pressure is more than 30 mmHg higher than intracompartmental pressure, the patient may be treated conservatively for one hour with the appropriate antivenom and intravenous mannitol 100 g (500 ml of 20% solution in adults, less for children) (Mars et al, 1991; Mars and Hadley, 1998).

Should conservative treatment fail, open full length fasciotomy should be performed providing there is no coagulopathy or gross thrombocytopenia. However, animal studies have shown that fasciotomy is ineffective in saving envenomed muscles (Garfin et al,

1994). Provided that adequate antivenom treatment is given as soon as possible after the bite, fasciotomy is rarely if ever needed (Warrell and Rollinson, 2000). However, bites involving the finger pulps are frequently complicated by necrosis. Expert surgical advice should be sought, especially if the thumb or index finger is involved.

**15.1.7 Vessel entrapment syndrome:** this is uncommon and is usually due to massive swelling compressing the femoral vessels beneath the inguinal ligament. It presents as a cool, blister-covered leg with absent distal pulses (Blaylock, 2003). Provided there is no coagulopathy and the leg is still viable, division of the inguinal ligament and multiple fasciotomies are required.

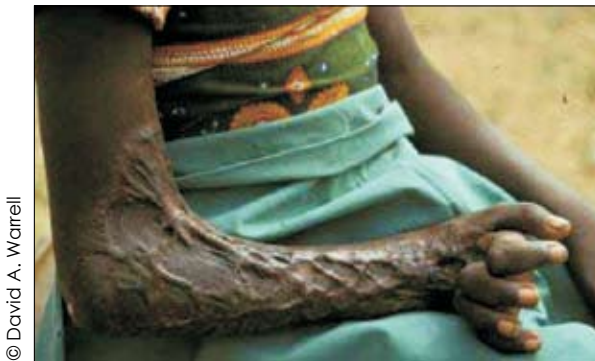**15.1.8 Nerve entrapments** (e.g. median carpal tunnel syndrome, femoral nerve i.e. meralgia paraesthetica) are treated conservatively.

**15.1.9 Muscle haematomas** (e.g. iliacus haemorrhage causing unilateral weakness of hip flexion as in patients with haemophilia) are treated conservatively after correction of the haemostatic disorder with antivenom and, in some cases, clotting factors.

**15.1.10 Vascular thromboses:** Deep vein thrombosis may be suspected when the swelling of a leg fails to subside after 2-3 weeks. Arterial and venous thromboses are rare complications reported after bites by vipers. Arterial thrombosis is suspected when agonizing pain develops rapidly in a limb, there is a sharply demarcated cold distal area and arterial pulses prove undetectable even by doppler. Once haemostatic abnormalities are corrected, the limb might be investigated by arteriography with the possibility of angioplasty, thrombectomy or reconstructive arterial surgery.

**15.1.11 Amputation** of doomed digits and limbs is the last resort but the decision must be made and agreed upon by the patient and family before life-threatening septicaemia, gas gangrene or tetanus supervenes.

**15.1.12 Late complications of local envenoming:** these include incapacitating and deforming hypertrophic and keloid scars (Figure 122), muscle and tendon contractures, equinus deformity, destroyed or arthrodesed joints, osteomyelitis, chronic ulceration with or without malignant change and consequences of intracompartmental syndromes (Figure 123) such as Volkmann's ischaemic contracture. These are treated according to standard guidelines.



© David A. Warrell

**Figure 122: Same patient as in Figures 92-95: black-necked spitting cobra *Naja nigricollis* bite, hypertrophic scar**

## 15.2. Haemostatic abnormalities

Once adequate doses of antivenom have been given to neutralize venom antihemostatic factors, recovery of normal haemostatic function may be accelerated by giving fresh whole blood, fresh frozen plasma, cryoprecipitates or platelet concentrates. However, this is unnecessary unless traumas such as imminent childbirth or emergency surgery are anticipated. The risk of contamination of blood and its products

with HIV, HTLV<sub>1</sub>, hepatitis viruses and other pathogens greatly restricts their use in many parts of Africa.

**NB: Heparin and antifibrinolytic agents should never be used in snake bitten patients.**

Heparin does not inhibit the abnormal thrombin generated by snake venoms and it exaggerates, some times fatally, the haemostatic disturbances (Warrell et al, 1976d).

## 15.3 Neurotoxic envenoming

The airway must be protected in patients developing bulbar and respiratory paralysis. Once secretions begin to pool in the pharynx, a cuffed endotracheal tube or laryngeal mask airway must be inserted. Non-invasive assisted ventilation by special face mask has proved difficult to use in snake bitten patients. Mechanical ventilation is usually required for only a few days but exceptionally patients have recovered after 10 weeks of mechanical ventilation and 30 days of manual ventilation by ambu bag or anaesthetic bag. Antivenoms cannot be relied upon to reverse neurotoxicity or prevent its progression to respiratory paralysis.

## 15.4 Anticholinesterases

Neuromuscular blockade by post-synaptic neurotoxins may be partly overcome by the use of anticholinesterase medicines. Neostigmine (prostigmine, Prostigmin™) has been used successfully to treat patients with severe neurotoxic envenoming following bites by *Naja melanoleuca* and *Dendroaspis viridis*, and in a patient envenomed by *Naja nivea* there was an improvement in motor response to command and electromyographic responses after administration of this medicine (Blaylock et al, 1985).

**All patients with neurotoxic symptoms except those thought to have been bitten by mambas should be given an anticholinesterase test. Ideally, edrophonium is used because it is short acting, as in the classic “Tensilon” (edrophonium) test in patients with suspected myasthenia gravis. However, edrophonium is rarely available but neostigmine and glycopyrronium are widely used by anaesthetists to reverse non-depolarising (competitive) neuromuscular blockade.**

Atropine sulphate (0.6 mg for adults, 50 µg/kg for children) is given by slow intravenous injection to block the unpleasant and potentially serious muscarinic effects of acetylcholine such as colic. This is followed by edrophonium chloride (10 mg in adults, 0.25 mg/kg in children) by slow intravenous injection. If edrophonium is not available, use neostigmine bromide or methylsulphate (Prostigmin) by intramuscular injection 0.02 mg/kg for adults, 0.04 mg/kg for children together with atropine as above.

Patients who respond convincingly, by demonstrating increased muscle power or improvement in ptosis, can be maintained on neostigmine, 0.5-2.5 mg every 1-3 hours up to 10 mg/24 hours maximum for adults or 0.01-0.04 mg/kg every 2-4 hours for children by intramuscular, intravenous or subcutaneous injection together with atropine as above. It is important to note that atropine must always be given concurrently with cholinesterase inhibitors (e.g. neostigmine) in order to prevent serious muscarinic effects.

Since mamba venoms contain an anticholinesterase (fasciculin), it is theoretically inappropriate to use the Tensilon test in suspected or proven victims of mamba bites.

## 15.5 Hypotension and shock

Specific antivenom can reverse the direct myocardial and vasodilating effects of some venoms, but in patients who have leaked large amounts of blood and plasma into the bitten limb and elsewhere, a plasma expander is needed to correct hypovolaemia. As an emergency, the foot of the bed can be raised to improve cardiac filling while an intravenous infusion is set up. Ideally, central venous pressure should be monitored to prevent fluid overload. Other causes of hypotension, such as a massive concealed haemorrhage or effects of venom toxins on the physiological mechanisms controlling blood pressure (e.g. ACE-inhibiting and bradykinin-potentiating peptides (see Chapter 5) should be considered.

## 15.6 Renal failure

Acute renal failure may be caused by haemorrhage, ischaemia resulting from hypotension, disseminated intravascular coagulation and renal vasoconstriction, pigment nephropathy caused by haemoglobinuria or myoglobinuria, direct nephrotoxicity and immune complex glomerulonephritis caused by serum sickness reactions to antivenom.

Renal failure is not a common complication of envenoming by any African snake but cases of renal failure have been reported after bites by *Echis coloratus*, *E. ocellatus*, *E. pyramidum*, *Bitis arietans*, *Thelotornis* species and *Dispholidus typus*. This complication can occur in any case of severe envenoming especially if there has been prolonged profound hypotension. If the urine output falls below 400 ml in 24 hours, central venous pressure should be monitored and a urethral catheter inserted. Cautious rehydration with isotonic fluid (to increase the central venous



pressure to +10 cmH<sub>2</sub>O) can be followed by high dose of frusemide (up to 100 mg intravenously) and finally dopamine (2.5 µg/kg/minute) by continuous infusion into a central vein. If these measures fail to increase urine output, patients should be managed conservatively until dialysis is indicated.

## 15.7 Snake venom ophthalmia

The eight spitting elapid species in the African region (*H. haemachatus*, *N. nigricollis*, *N. ashei*, *N. nubiae*, *N. pallida*, *N. katiensi*, *N. mossambica* and *N. nigricincta*) can cause intense conjunctivitis and bullous corneal erosions complicated by secondary infection, anterior uveitis, corneal opacities and permanent blindness.

First aid treatment (Figure 123) consists of irrigating the eye or other affected mucous membrane as soon as possible using large volumes of water or any other available bland fluid such as milk. To facilitate irrigation, a single application of local anaesthetic eye drops to overcome tightly closed eyelids may be used. Unless a corneal abrasion can be excluded by slit lamp examination or fluorescein staining, the patient should be treated as for a corneal injury with a topical antimicrobial agent (tetracycline and chloramphenicol).

Topical or systemic antivenom treatment is not indicated. It has been said that 1 in

1000 (0.1%) adrenaline eye drops or 10% phenylephrine eye drops relieve the burning sensation instantaneously. However, these eye drops can cause a rise in blood pressure and tachycardia and should be used with caution in older patients.

## 15.8 Snakebite in pregnancy

(See 14.11.2 above)

During the last trimester of pregnancy avoid the supine hypotensive syndrome by resuscitating the mother while she sits up, or place her in the left lateral decubitus position or raise the left hemipelvis.

Envenoming by saw-scaled or other vipers that cause a bleeding diathesis may cause ante-partum haemorrhage and precipitate miscarriage at any stage of pregnancy. Pregnant women should be questioned about and examined for evidence of vaginal bleeding and, in the third trimester, fetal heart rate and uterine contractions should be monitored. Fetal bradycardia may indicate fetal envenoming. Late deceleration of fetal heart rate in relation to uterine contractions indicates fetal distress. Envenomed pregnant women are at risk of ante- and post-partum haemorrhage, premature labour, fetal distress and stillbirth. Early adequate antivenom treatment is indicated, its benefits outweighing the risks to the mother and fetus e.g of anaphylactic antivenom reactions.



## References/Further reading

- Abubakar SB et al (2009). Pre-clinical and preliminary dose-finding and safety studies to identify candidate antivenoms for treatment of envenoming by saw-scaled or carpet vipers (*Echis ocellatus*) in northern Nigeria. *Toxicon*. [Epub ahead of print]
- Anker RL et al (1982). Retarding the uptake of "mock venom" in humans: comparison of three first-aid treatments. *Med J Aust*. 1(5):212–4.
- Anker RL et al (1983). Snakebite. Comparison of three methods designed to delay uptake of "mock venom". *Aust Fam Physician*. 12(5): 365–8.
- Ben-Baruch N et al (1986). *Cerastes vipera* envenoming—a report of seven cases. *Trans R Soc Trop Med Hyg*. 80(4):664.
- Benbassat J, Shalev O (1993). Envenomation by *Echis coloratus* (Mid-east saw-scaled viper): A review of the literature and indications for treatment. *Israel J Med Sci* 29:239–50.
- Blaylock RSM (1982). Snake bites at Triangle Hospital January 1975 to June 1981. *Cent Afr J Med* 28:1–11.
- Blaylock RS (1994). Pressure immobilisation for snakebite in southern Africa remains speculative. *S Afr Med J* 84 (12):826–27.
- Blaylock RSM (1999). Antibiotic use and infection in snakebite victims. *S Afr Med J* 89(8):874–76.
- Blaylock RSM (2000). Antibacterial properties of KwaZulu-Natal snake venoms. *Toxicon* 38 (11):1529–34.
- Blaylock RSM (2001). Normal oral flora from some Southern African snakes. *Onderstepoort Journal of Veterinary Research* 69:175–82. Blaylock RSM (2002).
- Acute adverse reactions to South African manufactured snakebite antivenom. *Current Allergy & Clinical Immunology* 15:107–13.
- Blaylock RSM (2003). Femoral vessel entrapment and compartment syndromes following snakebite. *S Afr J Surg* 41(3):72–3.
- Blaylock R (2004). Epidemiology of snakebite in Eshowe, KwaZulu-Natal, South Africa. *Toxicon* 43 (2):159–66.
- Blaylock RS (2004). Snakebites. In: Kamel R, Lumley J (eds). *Tropical Surgery*, Westminster Publishing Ltd, London, pp. 1149–52. Blaylock RS (2005). The identification and syndromic management of snakebite in South Africa, *SA Fam Pract* 47:48–53.
- Blaylock RS, Lichtman AR, Potgieter PD (1985). Clinical manifestations of Cape cobra (*Naja nivea*) bites. Two cases. *S Afr Med J* 68(5):342–344. Blaylock RSM, Tilbury CR, Branch WR (2002). Anaphylaxis following exposure to snake venoms in South Africa. *Current Allergy and Clinical Immunology* 15(2):65–8.
- Branch WR (1988). *Field Guide to Snakes and other Reptiles of Southern Africa*. Struik Publishers, Cape Town. Branch WR (1997). A new adder (*Bitis*; Viperidae) from the western Cape Province, South Africa. *S Afr J Zool* 32:37.
- Branch WR (1999) Dwarf adders of the *Bitis cornuta-inornata* complex (Serpentes: Viperidae) in South Africa. *Kaupia* 8:39–63. Broadley DG (1983). *FitzSimons' Snakes of Southern Africa*. Delta Books, Johannesburg. Broadley DG (1990). *The herpetofaunas of the islands off the coast of south Mozambique*, Arnoldia

Zimbabwe 9:469–93.

Broadley DG (1996). A review of the tribe Atherini (Serpentes: Viperidae), with the description of two new genera. *Afr J Herpetology* 45:40–8.

Broadley DG (2001). A review of the genus *Thelotornis* A. Smith in eastern Africa, with the description of a new species from the Usambara Mountains (Serpentes: Colubridae: Dispholidini), *Afr J Herpetology* 50:53–70.

Broadley DG, Wallach V (2002). Review of the Dispholidini, with the description of a new genus and species from Tanzania. *Bull Nat Hist Mus London (Zool.)* 68(2):57–74.

Broadley DG, Wüster W (2004). A review of the southern African “non-spitting” cobras (Serpentes: Elapidae: *Naja*). *Afr J Herpetology* 53:101–22.

Bush SP (2004). Snakebite suction devices don’t remove venom: they just suck. *Ann Emerg Med* 43(2):187-8.

Bush SP et al (2004). Pressure immobilization delays mortality and increases intracompartmental pressure after artificial intramuscular rattlesnake envenomation in a porcine model. *Ann Emerg Med.* 44(6):599-604.

Chapman DS (1968). The symptomatology, pathology, and treatment of the bites of venomous snakes of central and southern Africa. In Bücherl W, Buckley EE, Deulofeu V (eds), *Venomous animals and their venoms*, Academic Press, New York, Vol I: 463–527.

Chappuis F et al (2007). Protection against snake bites by sleeping under a bed net in south-eastern Nepal. *Am J Trop Med Hyg* 77(1):197–9.

Cheng AC, Currie BJ (2004). Venomous snakebites worldwide with a focus on the Australia-Pacific region: current management and controversies. *J Intensive Care Med.* 19(5):259–69.

Cherlin VA. (1990). Taxonomic review of the snake genus *Echis* (Viperidae) II. An analysis of taxonomy and descriptions of new forms, *Proc Zool Inst Leningrad* 287:193–223.

Chippaux J-P (1999). *Les Serpents d’Afrique occidentale et centrale*. IRD Éditions, Paris.

Chippaux J-P (1998). Snake-bites: appraisal of the global situation. *Bull of the WHO* 76:515–24.

Chippaux J-P (2005). Évaluation de la situation épidémiologique et des capacités de prise en charge des envenimations ophidiennes en Afrique subsaharienne francophone. *Bull Soc Path Exot* 98(4):263–8.

Chippaux JP et al (1998). Clinical safety of a polyvalent F(ab')<sub>2</sub> equine antivenom in 223 African snake envenomations: a field trial in Cameroon. *VAO (Venin Afrique de l’Ouest) Investigators. Trans R Soc Trop Med Hyg* 92(6):657-62.

Chippaux JP et al (2007). Clinical trial of an F(ab')<sub>2</sub> polyvalent equine antivenom for African snake bites in Benin. *Am J Trop Med Hyg* 77(3):538–46.

Coetzer PWW, Tilbury CR (1982). The epidemiology of snakebite in Northern Natal. *S Afr Med J* 62:206–212.

Coombs MD et al (1997). Occurrence of snake bites in Kenya: a preliminary survey of four selected areas. *Transactions Roy Soc Trop Med Hyg* 91:319–21.

David P, Ineich I (1999). *Les serpents venimeux du monde: systématique et repartition*. *Dumerilia* 3:3–499.

Davidson RA (1970). Case of African Cobra bite. *Brit Med J* 4:660.

Domergue CA (198) Un serpent venimeux de Madagascar observation de deux cas de morsure par *Madagascarophis* (Colubride opisthoglyphe), *Arch Inst Pasteur Madagascar* 56:299–311.

- Dobey M, Vogel G (2007). Venomous snakes of Africa. Frankfurt am Main, Edition Chimaira. (and review by DG Broadley. African Journal of Herpetology 56(2):179–81.
- Doucet J (1983). Les Serpents de la République de Côte d'Ivoire. Acta Tropica 20(3):201–59; (4):297–340.
- Edgar W et al (1980). The structure of soluble fibrin complexes and fibrin degradation products after *Echis carinatus* bite. Brit J Haematol 44:471–81.
- Garfin SR et al (1984). Rattlesnake bites and surgical decompression: results using a laboratory model. Toxicol 22:177-82.
- Gillissen A et al (1994). Neurotoxicity, haemostatic disturbances and haemolytic anaemia after a bite by a Tunisian saw-scaled or carpet viper (*Echis "pyramidum"*-complex): failure of antivenom treatment. Toxicol 32(8):937–44.
- Golay P et al (1993). Endoglyphs And Other Major Venomous Snakes Of The World, Azemiops, S.A. Herpetological Data Center.
- Gonzalez A (2009). Ethiopian mountain adder strikes in the Texas Hill country. Clinical Toxicology 47(7):758, abstract 276.
- Hakansson T, Madsen T (1983). On the distribution of the black mamba (*Dendroaspis polylepis*) in West Africa, Journal of Herpetology 17:186-89.
- Hardy DL (1992). A review of first aid measures for pit viper bite in North America with an appraisal of Extractor TM suction and stun gun electroshock. In Campbell JA, Brodie ED (eds), Biology of the pit vipers, Tyler, Texas, Selva: 405–14.
- Herrmann HW, Joger U, Nilson G (1992). Phylogeny and systematics of viperine snakes. III: Resurrection of the genus *Macrovipera* (Reuss, 1927) as suggested by biochemical evidence. Amphibia-Reptilia 13:375–92.
- Howarth DM, Southee AE, Whyte IM (1994). Lymphatic flow rates and first-aid in simulated peripheral snake or spider envenomation. Med J Australia 161:695–700.
- Hutton RA, Warrell DA. (1993) Action of snake venom components on the haemostatic system. Blood Rev 7:176–89.
- Ismail M et al (2006). Preparation of a novel antivenom against *Atractaspis* and *Walterinnesia* venoms. Toxicol. 49(1):8–18.
- Jakobsen A (1997) A review of some East African members of the genus *Elapsoidea* Bocage with the description of a new species from Somalia and a key for the genus (Reptilia, Serpentes, Elapidae), Steenstrupia 22:59–82.
- Jorge MT et al (2004). Failure of chloramphenicol prophylaxis to reduce the frequency of abscess formation as a complication of envenoming by *Bothrops* snakes in Brazil: a double-blind randomized controlled trial. Trans R Soc Trop Med Hyg 98(9):529-34.
- Kasilo OMJ, Nhachi CFB (1993). A retrospective study of poisoning due to snake venom in Zimbabwe. Hum Exp Tox 12:15–18.
- Kurnik D, Haviv Y, Kochva E (1999). A snake bite by the burrowing asp, *Atractaspis engaddensis*. Toxicol 37:223-7.
- Lath NK, Patel MM (1984). Treatment of snake venom ophthalmia. Centr Afr J Med. 30 (9):175-6.
- Link P et al (1999). Phylogeny and taxonomic subdivision of *Bitis* (Reptilia: Viperidae) based on molecular evidence. Kaupia 8:31-38.
- Link P et al (2001). Evolutionary relationships among the true vipers (Viperinae) suggested by mitochondrial DNA sequences. Molecular Phylogenetics and Evolution 19:94–104.



- McDiarmid RW, Campbell JA, Toure TA. (1999) Snake Species of the world, The Herpetologists' League, Washington, DC.
- Mackay N, Ferguson JC, McNicol GP (1966). The effects of the venom of the East African Green Mamba (*Dendroaspis angusticeps*) on blood coagulation and platelet aggregation. *E Afr Med J* 43(11):454-63.
- McNally SL, Reitz CJ (1987). Victims of snakebite: A five-year study at Shongwe Hospital, Kangwane, 1978–1982. *S Afr Med J* 72:855–60.
- McNally T et al (1993). Accidental envenoming by a Gaboon viper (*Bitis gabonica*): the haemostatic disturbances observed and investigation of in vitro haemostatic properties of whole venom. *Trans Roy Soc Trop Med Hyg* 87:66-70.
- Malasit P et al (1986). Prediction, prevention and mechanism of early (anaphylactic) antivenom reactions in victims of snake bites. *BMJ* 292:17-20.
- Mallow D, Ludwig D, Nilson G (2003). *True Vipers: Natural History and Toxinology of Old World Vipers*. Krieger Publishing Company, Malabar, Florida.
- Marais J (2004). *A Complete Guide to the Snakes of Southern Africa*. Hirt and Carter Cape (Pty) Ltd.
- Mars M, Hadley, GP (1998). Raised intracompartmental pressure and compartment syndromes. *Injury* 29(6):403–11.
- Mars M, Hadley GP, Aitchison JM (1991). Direct intracompartmental pressure measurement of snakebites in children. *S Afr Med J* 80:227-8.
- Marsh NA, Whaler BC (1984). The Gaboon viper (*Bitis gabonica*): its biology, venom components and toxinology. *Toxicon* 22(5):669-94.
- Matsen FA (1980). *Compartmental Syndromes*. Grune and Stratton, New York.
- Moreau RE, Pakenham RHW (1941). The land vertebrates of Pemba, Zanzibar and Mafia: A zoogeographical study. *Proc Zool Soc Lond A* 110:97–128.
- Muguti GI, Maramba A, Washaya CT (1994). Snake bites in Zimbabwe: A clinical study with emphasis on the need for antivenom. *Cent Afr J Med* 40(4):83-8.
- Müller GJ (2005). African Snakes In: Brent J et al, eds, *Critical Care Toxicology: The Diagnosis and Management of the Critically Poisoned Patient*. Elsevier Mosby, Philadelphia, pp. 1159–70.
- Nasidi A (2007). Snakebite as a serious public health problem for Nigeria and Africa. Paper presented at the WHO Consultative Meeting on Rabies and Envenomings: A Neglected Public Health Issue, Geneva, Switzerland, 10 January 2007. [http://www.who.int/bloodproducts/animal\\_sera/A.Nasidi.pdf](http://www.who.int/bloodproducts/animal_sera/A.Nasidi.pdf) [accessed 14 November 2007].
- Nhachi CF, Kasilo OM (1994). Snake poisoning in rural Zimbabwe: a prospective study. *J Appl Toxicol* 14(3):191-3.
- Norris RL et al (2005). Physicians and lay people are unable to apply pressure immobilization properly in a simulated snakebite scenario. *Wilderness Environ Med*. 16(1):16–21.
- Obst FJ (1983). Zur Kenntnis des Schlangengattung. *Vipera* (Reptilia, Serpentes, Viperidae). *Zool Abh* 38:229–35.
- Oram S et al (1963). Renal cortical calcification after snake bite. *Br Med J* 22;1(5346):1647–8.
- Pakenham RHW (1983). The reptiles and amphibians of Zanzibar and Pemba islands, *J East Afr Nat Hist Soc & Natn Mus* 177:1–40.
- Palmer PES, Reeder MM (eds) (2001). *The Imaging of Tropical Diseases with Epidemiological, Pathological and Clinical Correlations*. Springer, Berlin, vol 2:389–95.

- Parker HW (1949). Snakes of Somaliland and the Socotra Island. Zool. Berhand (Leiden) 6:12–115.
- Pook CE et al (2009). When continents collide: Phylogeny, historical biogeography and systematics of the medically important viper genus *Echis* (Squamata: Serpentes: Viperidae). Mol Phylogenet Evol Aug 8. [Epub ahead of print].
- Pugh RN, Theakston RD (1980). Incidence and mortality on snake bite in savanna Nigeria. Lancet 2(8205):1181–3.
- Pugh RNH et al (1980). Malumfashi endemic diseases research project. XIII. Epidemiology of human encounters with the spitting cobra, *Naja nigricollis*, in the Malumfashi area of northern Nigeria. Ann Trop Med Parasitol 74:523–530.
- Reid HA (1979). Symptomatology, pathology and treatment of the bites of sea snakes. In: Lee CY (ed), Snake Venoms. Handbook of Experimental Pharmacology. Springer, Berlin, pp. 922–55.
- Sano-Martins IS et al (1994). Reliability of the simple 20 minute whole blood clotting test as an indicator of low plasma fibrinogen concentration in patients envenomed by Bothrops snakes. Toxicon 32:1045–50.
- Schire L, Muller GJ, Pantanowitz L (1996). The Diagnosis and Treatment of Envenomation in South Africa. South African Institute for Medical Research, Johannesburg.
- Africa. South African Institute for Medical Research, Johannesburg. Schleich HH, Kästle W, Kabisch K (1996). Amphibians and Reptiles of North Africa. Koeltz Scientific Publishers, Koenigstein.
- Schneemann M et al (2004). Life-threatening envenoming by the Saharan horned viper (*Cerastes cerastes*) causing micro-angiopathic haemolysis, coagulopathy and acute renal failure: clinical cases and review. Quart J Med 97(11):717–27.
- Sezi CL, Alpidovsky VK, Reeve MI (1972). Defibrination syndrome after snakebite. East Afr Med J 49:589–596.
- Simpson ID et al (2008). The Ebbinghaus retention curve: training does not increase the ability to apply pressure immobilisation in simulated snake bite-implications for snakebite first aid in the developing world. Trans R Soc Trop Med Hyg [Epub ahead of print].
- Snow RW et al (1994). The prevalence and morbidity of snake bite and treatment-seeking behaviour among a rural Kenyan population, Annals of Tropical Medicine and Parasitology 88(6):665–71.
- Spawls S, Branch B (1995). The dangerous snakes of Africa, Southern Book Publishers, London.
- Spawls S et al (2002). A field guide to the reptiles of East Africa. Natural World, San Diego.
- Stahel E (1980). Epidemiological aspects of snake bites on a Liberian rubber plantation. Acta Tropica 37:367–74.
- Stock RP et al (2007). Bringing antivenoms to sub-Saharan Africa. Nat Biotechnol 25(2):173–7.
- Strover HM (1961). Snakebite and its treatment. Cent Afr J Med 7:84–7.
- Strover HM (1967). Report on a death from Black Mamba bite (*Dendroaspis polylepsis*). Cent Afr J Med 13(8):185–6.
- Strover HM (1973). Observations on two cases of snake bite by *Naja nigricollis* ss *mossambica*. Cent Afr J Med 19(1):12–13.
- Sutherland SK, Coulter AR, Harris RD (1979). Rationalisation of first-aid measures for elapid snakebite. Lancet i:183–186.
- Swaroop S, Grab B (1954). Snake bite mortality in the world. Bull of the WHO 10:35–76.

- Theakston RDG et al (1990). Bacteriological studies of the venom and mouth cavities of wild Malayan pit vipers (*Calloselasma rhodostoma*) in southern Thailand. *Trans R Soc Trop Med Hyg* 84:875-879.
- Tilbury CR (1982). Observations on the bite of the Mozambique spitting cobra (*Naja mossambica mossambica*). *S African Med J* 61(9):308-13.
- Tilbury CR, Branch WR (1989). Observations on the bite of the southern burrowing asp (*Atractaspis bibronii*) in Natal. *S Afr Med J*. 75:327-31.
- Trape J-P, Mané Y (2006). *Guide des serpents d'Afrique Occidentale. Savane et Désert*. IRD Éditions, Paris.
- Trape JF et al (2001). High mortality from snakebite in south-eastern Senegal. *Trans R Soc Trop Med Hyg* 95(4):420-3.
- Trape, J-P et al (2009). Phylogeography and systematic revision of the Egyptian cobra (Serpentes: Elapidae: *Naja haje*) species complex, with the description of a new species from West Africa. *Zootaxa* 2236:1-25.
- Trape J-F, Mané Y, Ineich I (2006). *Atractaspis microlepidota*, *A. micropholis* et *A. watsoni* en Afrique occidentale et centrale. *Bulletin de la Société Herpétologique de France*, 119:5-16.
- Tun-Pe et al (1995). Local compression pads as a first-aid measure for victims of bites by Russell's viper (*Daboia russelii siamensis*) in Myanmar. *Trans R Soc Trop Med Hyg* 89:293.
- Tun-Pe et al (2000). Field trial of efficacy of local compression immobilization first-aid technique in Russell's viper (*Daboia russelii siamensis*) bite patients. *Southeast Asian J Trop Med Public Health*. 31(2):346-8.
- Vidal L (1962). Les complications secondaires des morsures de serpents venimeux au Maroc. Leur traitement par l'hepannothérapie. *Resultats de 63 cas traités de 1954 a mai 1962*. *Maroc Med* 41:784-9.
- Visser J (1972). *What snake is that? A Purnell Pocket Book*. Southern African Series. The Rustica Press (Pty) Ltd, Cape.
- Visser J, Chapman DS (1978). *Snakes and snakebite. Venomous Snakes and Management of Snakebite in Southern Africa*. Purnell, Cape Town.
- Visser LE et al (2008). Failure of a new antivenom to treat *Echis ocellatus* snakebite in rural Ghana: the importance of quality surveillance. *Trans R Soc Trop Med Hyg* Jan 9; [Epub ahead of print].
- Visser LE et al (2009). Reply to comment on: Failure of a new antivenom to treat *Echis ocellatus* snake bite in rural Ghana: the importance of quality surveillance. *Trans R Soc trop Med Hyg* (in press).
- Wagner P et al (2009). First record of human envenomation by *Atractaspis congica* Peters, 1877 (Squamata: Atractaspididae). *Toxicon* 54(3):368-72.
- Warrell DA (1979). Clinical snakebite problems in the Nigerian savanna region. *Technische Hochschule Darmstadt. Schriftenreihe Wissenschaft u-Technik* 14:31-60.
- Warrell DA (1990). Treatment of snakebite in the Asia-Pacific Region: a personal view. In: Gopalakrishnakone P, Chou LM (eds), *Snakes of Medical Importance (Asia-Pacific Region)*, pp. 641-70, National University of Singapore.
- Warrell DA (1992). The global problem of snakebite: its prevention and treatment. In: Gopalakrishnakone P, Tan CK (eds), *Recent Advances in Toxinology Research*, vol. 1. National University of Singapore, pp. 121-53.

- Warrell DA (1993). Venomous bites and stings in Saudi Arabia. *Saudi Med J* 14(3): 196-220.
- Warrell DA (1994). Sea snake bites in the Asia-Pacific region. In: Gopalkrishnakone P (ed), *Sea Snake Toxinology*. Singapore University Press, pp. 1-36.
- Warrell DA (1995). Clinical Toxicology of Snakebite in Africa and the Middle East/Arabian Peninsula. In: Meier J, White J (eds), *Handbook of Clinical Toxicology of Animal Venoms and Poisons*. CRC Press, Inc, pp. 433-92.
- Warrell DA (1997). Geographical and intraspecies variation in the clinical manifestations of envenoming by snakes. In: Thorpe RS, Wüster W, Malhotra A (eds), *Venomous snakes. Ecology, evolution and snakebite*. Clarendon Press, Oxford, pp. 189-203.
- Warrell D (1999). Snakebite in sub-Saharan Africa, *African Health July*: 5-9.
- Warrell DA (2006). Australian toxinology in a global context. *Toxicon* 48(7):718-25.
- Warrell DA (2008). Unscrupulous marketing of snakebite antivenoms in Africa and Papua New Guinea: choosing the right product-"What's in a name?" *Trans R Soc Trop Med Hyg Mar* 20; [Epub ahead of print].
- Warrell DA, Arnett C (1976). The importance of bites by the saw-scaled or carpet viper (*Echis carinatus*). *Epidemiological studies in Nigeria and a review of the world literature. Acta Trop (Basel)* 33:307-341.
- Warrell DA, Barnes HJ, Piburn MF (1976a). Neurotoxic effects of bites by the Egyptian cobra (*Naja haje*) in Nigeria. *Trans Roy Soc Trop Med Hyg* 70:78-9.
- Warrell DA et al (1977). Poisoning by bites of the saw-scaled or carpet viper (*Echis coloratus*) in Nigeria. *Quart J Med New Series XLVI* 181:33-62.
- Warrell DA et al (1974). Bites by the saw-scaled or carpet viper (*Echis carinatus*): trial of two specific antivenoms. *Brit Med J* 4:437-440.
- Warrell DA et al (1977). Poisoning by bites of the saw-scaled or carpet viper (*Echis carinatus*) in Nigeria. *Q J Med* 46:33-62.
- Warrell DA et al (1976b). Necrosis, haemorrhage and complement depletion following bites by the spitting cobra (*Naja nigricollis*). *Quart J Med* 45:1-22.
- Warrell DA, Ormerod LD (1976). Snake venom ophthalmia and blindness caused by the spitting cobra (*Naja nigricollis*) in Nigeria. *Am J Trop Med Hyg* 25:525-29.
- Warrell DA, Ormerod LD, Davidson N McD (1975). Bites by the puff adder (*Bitis arietans*) in Nigeria, and value of antivenom. *Br Med J* 4:697-700.
- Warrell DA, Ormerod LD, Davidson N McD (1976c). Bites by the night adder (*Causus maculatus*) and burrowing vipers (genus *Atractaspis*) in Nigeria. *Am J Trop Med Hyg* 25:517-24.
- Warrell DA, Pope HM, Prentice CRM (1976d). Disseminated intravascular coagulation caused by the carpet viper (*Echis carinatus*): trial of heparin. *Brit J Haematol* 33:335-42.
- Warrell D, Rollinson P (2000) Attacks by animals: bites stings and other injuries. In: Hamilton Bailey's *Emergency Surgery*, 13th edition, Arnold, London, 787-97.
- Warrell DA et al (1980). Comparison of Pasteur and Behringwerke antivenoms in envenoming by the carpet viper (*Echis carinatus*). *Brit Med J* i: 607-609.
- Warrell DA, Williams DJ (2009). Reply to comment on: Failure of a new antivenom to treat *Echis ocellatus* snakebite in rural Ghana: the importance of quality surveillance. *Trans R Soc trop Med Hyg* (in press).

Werner YL et al (1991). Systematics and zoo geography of *Cerastes* (Ophidia: Viperidae) in the Levant: 1. Distinguishing Arabian from African "*Cerastes cerastes*". *The Snake* 23:90–100.

Wilkinson D (1994). Retrospective analysis of snakebite at a rural hospital in Zululand. *S Afr Med J* 84 (12):844–47.

World Health Organization (1981). Progress in the characterization of venoms and standardization of Antivenoms. WHO Offset Publication No 58. World Health Organization, Geneva.

World Health Organization (1999). WHO/SEARO Guidelines for the clinical management of snake bites in the South East Asian region. *South East Asian Journal of Tropical Medicine & Public Health* 30 (Supplement 1): 1–85.

<http://www.searo.who.int/en/Section10/Section17/Section53/Section1024.htm>

World Health Organization (2007). Rabies and envenoming. A neglected public health issue. Report of a consultative meeting WHO, Geneva, January 2007.

WHO (2009). Guidelines for the production, control and regulation of snake antivenom immunoglobulins. World Health Organization, Geneva.

Wüster W, Broadley DG (2003). A new species of spitting cobra (*Naja*) from north-eastern Africa (Serpentes: Elapidae), *J Zool, Lond* 259:345–9.

Wüster W, Broadley DG (2007). Get an eyeful of this: a new species of giant spitting cobra from eastern and north-eastern Africa (Squamata: Serpentes: Elapidae: *Naja*). *Zootaxa* 1532:51–68.

Wüster W, Golay P, Warrell DA (1997). Synopsis of recent developments in venomous snake systematics, *Toxicon* 35:319–40.

Wüster W, Golay P, Warrell DA (1998) Synopsis of recent developments in venomous snake systematics, No. 2, *Toxicon* 36:299–307.

Wüster W, Golay P, Warrell DA (1999) Synopsis of recent developments in venomous snake systematics, No. 3, *Toxicon* 37:1123-29.

Wüster W et al (2007). The phylogeny of cobras inferred from mitochondrial DNA sequences: evolution of venom spitting and the phylogeography of the African spitting cobras (Serpentes: Elapidae: *Naja nigricollis* complex). *Mol Phylogenet Evol* 45(2):437–53.

Wüster W et al (2008). A nesting of vipers: Phylogeny and historical biogeography of the Viperidae (Squamata: Serpentes). *Mol Phylogenet Evol* 49(2):445–59.

Yerzingatsian KL (1997). Snakebite – Rest and elevation in the management of a selected group of patients in an urban setting. *S Afr J Surg* 35(4):188–89.







# Annex 1

Venomous Snakes of Africa  
Classification, Distribution, Habitat, Clinical Toxinology

© Gert J. Muller 2010 (See Chapters 2, 3 and 7)

## Venomous Snakes of Africa: Classification, Distribution and Habitat; Clinical Toxinology

FAMILY AND SPECIES	FAMILY AND SPECIES	DISTRIBUTION (see figures)	CLINICAL TOXINOLOGY
<b>ATRACASPIDIDAE</b> (Genus Atractaspis):			
African burrowing adders or asps (burrowing or mole vipers or adders, side stabbing or stiletto snakes), Natal black snake			
<b>ATRACASPIDIDAE</b> (Genus Atractaspis):			
The burrowing asps are fossorial, living mostly underground in deserted termite mounds, under stones or logs, or in soft soil or sand. They are mostly grey, black or brown and most are relatively small (30 cm – 70 cm in length). Nocturnal and usually emerge on warm, wet summer evenings, especially after heavy rains. When the snake bites (strikes) the fangs are exposed out of the sides of the mouth and are then hooked or jabbed into the victim with a backward jerk of the head. They are extremely irritable, striking in sideways swings and sweeps, and showing annoyance by flattening the body. Accidental bites usually occur at night when the victim treads on the snake.			
<i>Atractaspis aterrima</i>	Slender burrowing asp	Rainforest and savanna – West Africa to north-west Uganda.	Local pain, swelling, lymphadenitis, necrosis.
<i>Atractaspis bibronii</i>	Southern, Bibron's burrowing asp	Semi-desert, savanna and woodland of southern Africa, from Kenya through to eastern Tanzania, Malawi, Zambia, Zimbabwe, Botswana, eastern parts South Africa.	Local pain, swelling, lymphadenitis.
<i>Atractaspis corpulenta</i>	Hallowell's burrowing, fat burrowing asp	Forests, from Cameroon eastwards to northern DRC	Local pain, swelling, lymphadenitis.
<i>Atractaspis dahomeyensis</i>	Brown, Dahomey burrowing asp	Savanna of West Africa	Life-threatening and fatal cases recorded. Dyspnoea, respiratory failure, ECG abn., collapse.
<i>Atractaspis engaddensis</i> (? Subspecies of <i>Atractaspis microlepidota</i> )	Ein Geddi, Israeli burrowing asp	Desert areas of Egypt	Life-threatening and fatal cases recorded.
<i>Atractaspis irregularis</i>	Variable, Reinhardt's burrowing asp	Forest regions of West and East Africa	See <i>A. engaddensis</i> .
<i>Atractaspis (microlepidota) fallax</i>	Smallscaled burrowing asp	Savanna, from Mauritania to Horn of Africa and Kenya.	Local pain, swelling, necrosis. Fatalities recorded. See <i>A. engaddensis</i> .
<i>Macrelaps microlepidotus</i>	Natal black snake	East coast of South Africa: riverine forest and urban gardens.	Local pain, swelling. Serious cases recorded.
<b>Atractaspidae considered potentially venomous but for which no bites have been recorded:</b> <i>A. baiffesbyi</i> (Baiffesby's burrowing asp); Bolobo, Congo River basin, <i>A. boulengeri</i> (Central African burrowing asp); western Congo river basin, <i>A. coalescens</i> (black burrowing asp); Congo River basin, Angola and Zambia, <i>A. congica</i> (Congo burrowing asp); Congo River mouth, Angola and Zambia, <i>A. duerdeni</i> (Duerden's burrowing asp); northern Namibia, south-eastern Botswana, north-western South Africa, <i>A. engdahli</i> (Engdahli's burrowing asp); southern Somalia, north-eastern Kenya, <i>A. fallax</i> (? Subspecies of <i>A. microlepidota</i> ); Ethiopia, Somalia and northern Kenya, <i>A. leucomelas</i> (Ogaden burrowing asp); eastern Ethiopia, northern Somalia and Djibouti, <i>A. micropholis</i> (? Subspecies of <i>A. microlepidota</i> ); West African Sahel, <i>A. reticulata</i> (reticulate burrowing asp); central West Africa, <i>A. scorreccii</i> (Somali burrowing asp); eastern Ethiopia and northern Somalia.			

FAMILY AND SPECIES		FAMILY AND SPECIES		DISTRIBUTION (see figures)		CLINICAL TOXINOLOGY	
<b>COLUBRIDAE</b>		Common snakes or rear-fanged snakes		Wide distribution throughout Africa.		Venom of some capable of inducing fatal haemostatic defects.	
The back-fanged snakes have fixed, grooved rear fangs that are situated quite far back in the mouth. Although only the boomslang and the vine snakes have caused fatal bites, all back-fanged colubrids should be regarded as potentially dangerous to man and must be handled with caution.							
<i>Diplolidius typus</i>	Boomslang ("tree snake")			Wide distribution throughout sub-Saharan open bushveld and savanna.		Venom contains enzymes which activate prothrombin and factor X, leading to a consumptive coagulopathy, severe hypofibrinogenaemia and fatal bleeding if untreated.	
<i>Thelotornis capensis capensis</i>	South eastern savanna vine snake			Trees and shrubs in lowland forest to moist savanna and arid savanna. South western Zimbabwe and south eastern Botswana, south through northern South Africa and Swaziland to southern Mozambique and KwaZulu-Natal.		Same as for boomslang (see above).	
<i>Thelotornis capensis oatesi</i>	South eastern savanna vine snake			Trees and shrubs in lowland forest to moist savanna and arid savanna. Southern Angola and northern Namibia, west through northern Botswana, Zambia and southeast Katanga to Zimbabwe, western Mozambique and Malawi.		Same as for boomslang (see above). No cases recorded.	
<i>Thelotornis kirilandii</i>	Oates' savanna vine snake			Rainforests of western Central Africa.		Same as for boomslang (see above). No cases recorded.	
<i>Thelotornis mossambicanus</i>	Forest vine, twig snake Eastern vine snake			Trees and shrubs in lowland forest to moist savanna. Southern Somalia, south to central Mozambique, west to the shores of Lake Tanganyika, Malawi and eastern Zimbabwe.		Same as for boomslang (see above). No cases recorded.	
<i>Thelotornis usambaricus</i>	Usambara vine snake			Coastal forests; eastern Usambara mountains – Kenyan/Tanzanian coast.		Same as for boomslang (see above). No cases recorded.	
<i>Malpolon monspessulanus</i>	Large Montpellier snake			Semi-desert, along Mediterranean coast and Atlas Mountains, North Africa.		Local pain, swelling, lymphangitis. Possibly neurotoxic.	
<b>Colubridae capable of mild envenoming causing local pain, mild swelling and lymphangitis only, but for which no bites have been recorded:</b> <i>Amplorhinus multimaculatus</i> (many-spotted snake); eastern regions of southern Africa and Zimbabwe. <i>Boiga blandingii</i> (Blanding's tree snake); rainforests of West, East and Central Africa. <i>Coluber rhodorhachis</i> (Jan's desert racer); North Africa and Middle East. <i>Crotaphopeltis hotamboeia</i> (Herald, red- or white-lipped snake); sub-Saharan Africa, except rainforest and western South Africa. <i>Malpolon moliensis</i> (hooded malpolon); North Africa. <i>Psammophis biseriatus</i> (Kenyan link-marked sand snake); North and East Africa. <i>Psammophis philipsii</i> (olive grass snake); sub-Saharan Africa. <i>Psammophis sibilans</i> ; throughout Africa outside rainforests. <i>Psammophis rhombiceps</i> (spotted skaapsteeker); southern African grasslands. <i>Psammophis tritaeniatus</i> (striped skaapsteeker); southern Africa up to southern Tanzania. <i>Telescopus semiannulatus</i> (tiger snake); East, Central and southern Africa.							
<b>ELAPIDAE</b>							
The majority of elapids are long and slender. The rinkhals and the cobras are easily identified, since they usually rear their heads and spread a hood. Some have the ability to spit venom. There is a relatively high incidence of serious spitting cobra bites in Africa. The black mamba may also spread a narrow hood when threatened. Compared to vipers, elapids possess relatively short (up to about 10mm long), fixed front (proteroglyphous) fangs. In the case of mambas, the fangs are mounted at the very front of the maxilla, and can rotate at their articulation with the pre-frontal bone.							
		Cobras, rinkhals, mambas, coral-, shield-of-fatal nose-, garfer- and sea snakes		Wide distribution throughout Africa.		Potently neurotoxic and cytotoxic. Common cause snakebite.	



FAMILY AND SPECIES Neurotoxic Cobras (Genus <i>Naja</i> ):	COMMON NAME	DISTRIBUTION (see figures)	CLINICAL TOXINOLOGY
<i>Naja anchietae</i>	Anchieta's Egyptian cobra	Arid savanna: Namibia, Angola, north-western Botswana, S.W. Zambia.	Potently neurotoxic. See above for <i>Naja haje haje</i> .
<i>Naja annulifera</i>	Banded cobra	Arid and moist savanna: northern South Africa, eastern	Potently neurotoxic. See above for <i>Naja haje haje</i> .
<i>Naja haje</i> and <i>N. senegalensis</i>	Egyptian cobra	Botswana and Zimbabwe. Savanna, woodland (never forest): North Africa (not Morocco), West (N. senegalensis) and East Africa.	Potently neurotoxic, causing flaccid paralysis and respiratory depression. Fatalities due to respiratory arrest.
<i>Naja melanoleuca</i>	Forest, black and white-lipped cobra	Forested areas of West and Central Africa, southern East Africa and eastern coast of South Africa.	Potently neurotoxic. See above for <i>Naja haje haje</i> .
<i>Naja nivea</i>	Cape cobra	Karoo scrub, arid savanna, Namib desert: western part of South Africa, southern Namibia and Botswana.	Potently neurotoxic. See above for <i>Naja haje haje</i> .
<i>Naja senegalensis</i>	Senegalese cobra	Savanna of Senegal east to SW Niger and western Nigeria	Potently neurotoxic. See above for <i>Naja Haje</i>
<b>Neurotoxic cobras considered potentially neurotoxic, but for which no bites have been recorded. These include 2 tree cobras: <i>Pseudohaje gollaji</i> (Gold's tree cobra); Forests of central Africa, from Kenya to Nigeria, and south to northern Angola; <i>Pseudohaje nigra</i> (Black tree cobra): Forests of west Africa, from Sierra Leone to Nigeria.</b>			

FAMILY AND SPECIES Spitting or cytotoxic Cobras (Genus <i>Naja</i> ):	COMMON NAME	DISTRIBUTION (see figures)	CLINICAL TOXINOLOGY
<i>Naja ashei</i>	Ashe's spitting cobra	Northern and eastern Kenya, the rift valley in Ethiopia, and southern Somalia.	Considered to be potentially cytotoxic.
<i>Naja katiensis</i>	West African, western brown spitting cobra	Savanna of West Africa, from Senegal and southern Mauritania, eastwards to Nigeria and Cameroon.	Considered to be cytotoxic. No documented cases.
<i>Naja mossambica</i>	Mozambique spitting cobra, M'fesi	Moist savanna and lowland forest: south-east Africa, from Pemba to northern South Africa and Namibia.	Potently cytotoxic. Spits and bites. Severe local pain, swelling, tissue necrosis, often extensive. Eye envenoming.
<i>Naja pallida</i>	Red spitting cobra	Semi-desert areas of northern Kenya, Somalia, Sudan, Ethiopia and upper Egypt.	Bites not well documented.
<i>Naja nigricollis</i>	Black-necked spitting cobra	Savanna, from West Africa to southern Sudan and southwards, through West Africa to Angola.	Potently cytotoxic. Spits and bites. As in <i>N. mossambica</i> .
<i>Naja nigricincta</i>	Barred, zebra spitting cobra	Namib desert and karoo scrub: southern coastal Angola and northern Namibia.	Potently cytotoxic. Spits and bites. As in <i>N. mossambica</i> .
<i>Naja nigricincta woodi</i>	Black spitting cobra	Dry savanna: southern Namibia, Northern Cape and down to Western Cape Province of South Africa.	Potently cytotoxic. Spits and bites. As in <i>N. mossambica</i> .
<i>Naja nubiae</i>	Red spitting cobra	South eastern part of the Saharan region: Egypt, Nile Valley of north-eastern Sudan and Eritrea.	Potently cytotoxic. Spits and bites. As in <i>N. mossambica</i> .
<b>Coral/Shield-nose Snakes (Genus <i>Aspideleaps</i>):</b>			
Relatively small, robust elapids easily recognized by the much enlarged, shield like rostral scale on the snout. 60 cm – 80 cm in size.			
Aspideleaps lubricus. Three coral snake sub-species recognized: <i>Aspideleaps lubricus lubricus</i> (southern race), <i>Aspideleaps lubricus infuscatus</i> (central race) and <i>Aspideleaps lubricus cowlesi</i> (northern race).			
<i>Aspideleaps scutatus</i> . Three shield-nose snake sub-species (races) recognized: <i>Aspideleaps scutatus scutatus</i> (western race), <i>Aspideleaps scutatus fulvifula</i> (eastern race) and <i>Aspideleaps scutatus intermedius</i> (central race).			
Desert and arid savanna: south-western South Africa, through Namibia to southern Angola.			
Sandy and stony regions in Namib desert, moist and arid savanna, across northern regions of southern Africa, from Namibia across to Mozambique.			
Local pain, swelling, lymphangitis. Mildly neurotoxic. Bites not well documented.			
Details contradictory. Local pain, swelling and lymphangitis in some of the bites. Neurotoxic in others, with one fatality.			

FAMILY AND SPECIES	COMMON NAME	DISTRIBUTION (see figures)	CLINICAL TOXINOLOGY
<p><b>Mambas (Genus Dendroaspis):</b></p> <p><i>Dendroaspis angusticeps</i></p> <p><i>Dendroaspis jamesoni</i></p> <p><i>Dendroaspis polylepsis</i></p> <p><i>Dendroaspis viridis</i></p>	<p>Common, eastern green, white mouthed mamba</p> <p>Trill's, Jameson's, western green mamba</p> <p>Black mamba</p> <p>Hallowell's, West African green mamba</p>	<p>Forests or bush on eastern coast of Africa, from Kenya to South Africa.</p> <p>Central African forests.</p> <p>Savanna of eastern and southern Africa.</p> <p>Coastal forests of West Africa.</p>	<p>Local pain, swelling, lymphangitis, peripheral gangrene. Mildly neurotoxic. One fatal case.</p> <p>Local and extended swelling. Neurotoxicity prominent leading to respiratory paralysis.</p> <p>Potently neurotoxic. Nausea, vomiting, sweating, diarrhoea, involuntary muscle contractions/fasciculations. Respiratory paralysis may develop within an hour. High incidence of fatal cases.</p> <p>Local swelling and neurotoxicity prominent. Same as for <i>D. jamesoni</i>.</p>
<p><b>Garter snakes (Genus Elapsoides):</b></p> <p>Taxonomy under revision. Several subspecies.</p> <p><i>Elapsoides loveridgei</i></p> <p><i>Elapsoides semiannulata</i></p> <p><i>Elapsoides sundevalli</i></p>	<p>They are small fossorial, nocturnal elapid snakes, with very short tails, cylindrical bodies, with no distinct neck and a bluntly rounded rostral scale as in other burrowing species. Most have (Genus Elapsoides): an average length of 25 cm – 50 cm. The young are brightly banded (except for one species), the bands fading as they grow. Sluggish when exposed and does not bite if handled gently.</p> <p>East African, Loveridge's garter snake</p> <p>Angolan or Half-banded garter snake</p> <p>Sundevall's garter snake</p>	<p>Woodland, savanna and grassland: Kenya, Ethiopia and northern Tanzania.</p> <p>Savanna: Senegal to northern Uganda and a separate southern population from Angola to Mozambique.</p> <p>Karoo scrub to arid savanna, moist savanna, grassland and lowland forest: southern Africa.</p>	<p>Local pain, mild swelling and lymphangitis.</p> <p>Local pain, swelling and lymphangitis.</p> <p>Local pain, swelling and lymphangitis. ? neurotoxic.</p>
<p><b>Other Elapidae:</b></p> <p><i>Enhyalina schistosa</i></p> <p><i>Hemachatus haemachatus</i></p> <p><i>Pelamis platurus</i></p> <p><i>Wallerinnesia aegyptia</i></p>	<p>Beaked seasnake</p> <p>Rinkhals</p> <p>Pelagic, yellow-bellied sea snake</p> <p>Walter Innes's, desert black snake</p>	<p>Coastal regions of Madagascar.</p> <p>Wide variety of habitats: grassland, moist savanna, lowland forest: eastern regions of South Africa. Isolated population in south-western Zimbabwe.</p> <p>East coast of Africa, from Djibouti to Cape Town.</p> <p>Rocky desert, desert-fringe settlements: North-eastern Egypt.</p>	<p>Neurotoxic and myotoxic.</p> <p>Bites and spits. Local swelling and bruising. Mildly neurotoxic?</p> <p>Neurotoxic and myotoxic. Myoglobinuria.</p> <p>Local pain and swelling. Possibly neurotoxic. Deaths have been reported.</p>
<p><b>Water cobras:</b> <i>Naja (Boulengerina) annulata</i></p> <p>Potentially neurotoxic, no recorded cases.</p> <p><b>Burrowing cobra</b> <i>Naja (Paranaja) multifasciata</i>: rainforest of Cameroon, Equatorial Guinea, Gabon, Congo and W DR Congo. No recorded cases.</p>	<p>(Banded water cobra): rivers and lakes of Central Africa: Cameroon, DRC and Gabon. Potentially neurotoxic, no recorded cases, <i>N. chrysis</i> (Congo water cobra): Lower Congo river.</p>		

FAMILY AND SPECIES VIPERIDAE	COMMON NAME	DISTRIBUTION (see figures)	CLINICAL TOXINOLOGY
	Adders and vipers	Approximately 45 species distributed throughout Africa.	Cytotoxic, haemostatic disorders, neurotoxic. Common cause of lifethreatening and fatal snake bite in Africa.
	Vipers or adders are relatively thick bodied, sluggish, mainly terrestrial snakes which have long, curved, camulated and fully erectile fangs which fold down against the upper jaw in a mucous membrane sheath when the snake is not striking.		
<b>Bush vipers (Genera <i>Atheris</i>, <i>Proatheris</i> and <i>Montatheris</i>):</b>	Bush vipers are relatively small (maximum size 78 cm), mainly arboreal snakes inhabiting forests of tropical Africa. Two species ( <i>Proatheris superciliosus</i> and <i>Montatheris hindii</i> ) are terrestrial. They have a very broad head, narrow neck and a slender tapering body. Most species have small, rough overlapping scales and prehensile tails. The eyes are relatively large and have vertical pupils.		
<i>Atheris ceratophora</i>	Usambara bush viper	Montane forest: Usambara, Uzungwe and Uluguru mountains, Tanzania.	Minor local pain and bruising.
<i>Atheris chlorenchis</i>	Western bush, Schlegel's green tree viper	West African rainforests, from Guinea to Cameroon.	Haemostatic disorders: incoagulable blood in several cases.
<i>Atheris desaxi</i>	Mount Kenya bush viper	Evergreen forest: central Kenya.	Local pain and prominent swelling.
<i>Atheris squamigera</i>	Green tree, Hallowell's, green bush viper	West and Central Africa rainforests, from Ghana to Cameroon to Uganda, West Kenya and northern Angola.	Prominent swelling, incoagulable blood, haemorrhagic shock in one fatal case.
<i>Proatheris superciliosus</i>	Lowland, swamp, flood plain viper	Terrestrial. Grassland bordering swamps and floodplains: southwestern Tanzania, Malawi and Mozambique.	Local pain, swelling and blistering.
<b>Bush vipers considered venomous, but for which no bites have been recorded:</b> <i>Atheris anisolepis</i> ; West central Africa; Gabon, Congo, western DRC and northern Angola; <i>Atheris hispida</i> (Rough-scaled, spiny or prickly bush viper); DRC, Uganda and western Kenya. <i>Atheris katangensis</i> (Shaba bush viper); Eastern DRC. <i>Atheris nitschei</i> (Great Lakes bush viper or Nitsche's bush viper); Uganda, N.W. Tanzania, Rwanda, Burundi, DRC. <i>Atheris rungwensis</i> : south western Tanzania to north eastern Zambia and northern Malawi. <i>Montatheris hindii</i> (Kenya montane viper); Kenya. <i>Adenorhinos barbouri</i> , <i>Uzungwe viper</i> or <i>Barbour's viper</i> is a small adder known only from western Tanzania.			
<b>African vipers (adders): Large adders (Genus <i>Bitis</i>):</b>	Wide head and narrow neck. The tail appears oddly short in females and only less so in males. The four larger species have a total length of 80 cm to 2m. The puff adder is the most widespread and unmistakable; body stout and massive; brown or grayish with well marked chevron markings. Medically, one of the most important snakes in Africa. The small adders of southern Africa have an average length of between 20 cm to 50 cm.		
<i>Bitis arietans arietans</i>	Puff adder	Wide variety of habitat, savanna and open grassland, except in high montane grasslands, true desert and rainforest; widespread throughout sub-Saharan Africa, absent in African rainforests.	Potently cytotoxic. Severe local pain, extensive swelling and blistering, compartmental syndrome, necrosis, hypovolaemia, shock. Blood coagulation abnormalities.
<i>Bitis arietans somalica</i>	Somali puff adder	Savanna and open grassland: western Ethiopia and Somalia	As in <i>Bitis arietans arietans</i> .
<i>Bitis gabonica</i>	Gaboon adder or viper, forest puff adder	Tropical forests of West, Central and East Africa, and eastern parts of southern Africa.	Local effects as above. Cardiovascular and haemostatic abnormalities may be prominent.
<i>Bitis rhinoceros</i>	Rhinoceros adder or viper	Forests of Guinea to Ghana and Togo.	As in <i>Bitis gabonica</i> .
<i>Bitis nasicornis</i>	Rhinoceros homed viper, nose-homed viper or riverjack.	Forests of West, Central and East Africa.	Not well documented. Massive local swelling and necrosis.
<i>Bitis parviocula</i>	Ethiopian mountain adder	Grassland and forest: southern Ethiopia.	No documented cases, but considered highly cytotoxic.

FAMILY AND SPECIES Small (dwarf) adders (Genus <i>Bitis</i> ):	COMMON NAME	DISTRIBUTION (see figures)	CLINICAL TOXINOLOGY
<i>Bitis atropos</i>	Berg adder	Montane fynbos and grasslands: mountains of eastern Zimbabwe, Drakensberg Mountains down to mountains of south-western Cape, South Africa.	Cytotoxic and neurotoxic. Local pain, swelling and lymphangitis, ophthalmoplegia, anosmia, hyponatraemia, life-threatening respiratory depression in some cases.
<i>Bitis caudalis</i>	Horned adder	Arid savanna and desert: arid regions of South-West Africa, extending eastwards through Botswana to northern South Africa and southern Zimbabwe.	Local pain and swelling (this may be extensive with necrosis) lymphangitis.
<i>Bitis peringueyi</i>	Peringuey's adder, side-winding adder	Namib desert, Namibia.	Local pain, swelling and lymphangitis. Ophthalmoplegia and other minor neurotoxic effects observed.
<i>Bitis schneideri</i>	Namaqua dwarf adder, Schneider's adder	Vegetated coastal sand: coastal regions of southern Namibia and northern Cape Province, South Africa.	Local pain, swelling and lymphangitis.
<i>Bitis worthingtoni</i>	Kenya horned viper	Kenya. Restricted to high altitude along the high central rift valley.	Local pain and swelling.
<i>Bitis xeropaga</i>	Desert mountain adder	Sparsely vegetated rocky hillides and mountain slopes: southern Namibia and adjacent small area across Orange River into South Africa.	Local pain and swelling. Ophthalmoplegia and other minor neurotoxic effects observed. Hyponatraemia.
<b>Other small adders (vipers) considered venomous, but for which no bites have been recorded:</b> <i>Bitis albanica</i> (Albany adder); isolated population in the Algoa Bay region, eastern Cape, South Africa; <i>Bitis armata</i> (Southern adder); two isolated populations on the coast of the Western Cape, South Africa; <i>Bitis cornuta</i> (many horned adder, hornsman); coastal regions of south-western and western South Africa to southern Namibia, <i>Bitis heraldica</i> (Angolan adder); high parts of central Angola, <i>Bitis inornata</i> (plain mountain adder); isolated populations in the Graaf Reinet region of the Eastern Cape, South Africa; <i>Bitis rubida</i> (Red adder); southern to south-western part of South Africa; Cederberg, through Little Karoo and foot hills of the Roggeveld and Komsberg.			
<b>Carpet or saw-scaled vipers</b> (Genus <i>Echis</i> ):			
<i>Echis coloratus</i>	Burton's carpet viper, painted carpet viper	In rocky, boulder-strewn sites on hard ground in the eastern part of Egypt.	Pain and severe local swelling, blistering and necrosis, with severe haemostatic disorders leading to systemic bleeding.
<i>Echis leucogaster</i>	White-bellied carpet viper	In semi-desert and savanna, from Mauritania, Senegal, Burkina Faso, north-eastern Nigeria, Niger and isolated areas in Algeria.	No reported cases. Presumed to cause same toxic effects as in other <i>Echis</i> species.
<i>Echis ocellatus</i> and <i>E. jogeri</i>	West African carpet viper	Savanna of West Africa, from Mauritania east to Nigeria, Chad and Cameroon and Central African Republic. ( <i>E. jogeri</i> Mali and Senegal)	Of major medical importance in West Africa. Toxic effects as described in <i>E. coloratus</i> .
<i>Echis pyramicum</i>	North-East African carpet viper, Egyptian carpet viper	Oases, semi-desert and dry savanna; sporadically distributed across north and north-east Africa. Isolated populations in Algeria, Tunisia, Libya and northern Egypt, central-eastern Sudan, Eritrea, northern Somalia. Another population occurs in north-west Kenya.	Commonest cause of serious snake bite in Sudan. Toxic effects as described for <i>E. coloratus</i> .



FAMILY AND SPECIES Small (dwarf) adders (Genus Bitis):	COMMON NAME	DISTRIBUTION (see figures)	CLINICAL TOXINOLOGY
<b>Night adders (Genus Causus):</b>	The night adders are small (< 1 meter) and despite their name they are active by day and by night. They are not adder-like, and are fairly stout with the head being only slightly distinct from the neck. The venom fangs are short with no hinge action compared to the genus Bitis. They have round pupils (most adders have vertical eye pupils) and they have large scales on top of the head (most vipers have small scales). They are not given to standing their ground, but when angry, they hiss and puff ferociously, inflating the body to great extent. They may also raise the forepart of the body off the ground and slide forward with the neck flattened, looking quite cobra-like.		
<i>Causus dellippii</i>	Snouted night adder	Moist and dry savanna and coastal thickets; eastern Africa, from Kenya and Tanzania, Malawi, Zambia, Zimbabwe and Mozambique to north-eastern South Africa.	Local pain, swelling, lymphangitis and local necrosis
<i>Causus maculatus</i>	West African or western rhombic night adder	Savanna and forest of West and western Central Africa; from Mauritania and Senegal to western Ethiopia, south to D. R. Congo and northern Angola.	Local pain, swelling, lymphangitis and local necrosis
<i>Causus rhombatus</i>	Eastern rhombic night adder	Savanna, from eastern Nigeria, through Central Africa, down to eastern half of South Africa.	Local pain, swelling, lymphangitis and local necrosis
<i>Causus fichtensteini</i>	Forest or olive green night adder	Rainforests of western Central Africa.	Pain and local swelling.
<b>Other night adders considered venomous, but for which no bites have been recorded:</b> <i>Causus bilineatus</i> (Two-striped night adder); South Central Africa, from southern DRC, West to northern Zambia and Angola, <i>Causus resimus</i> (Green night adder); Scattered populations in Angola, around Lake Victoria, coastal Kenya and Somalia, Sudan, eastern Cameroon – Chad border region.			
<b>North African sand or desert vipers (Genus Cerastes):</b>			
<i>Cerastes cerastes</i>	Horned, Sahara horned viper	Great deserts (Sahara), and semi-deserts of north Africa from Morocco and Mauritania east to Egypt and Sudan and into the Middle East.	Local pain, swelling and necrosis. Coagulopathy, thrombocytopenia, haemolytic anaemia and renal failure reported.
<i>Cerastes vipera</i>	Sahara desert or sand viper	Sahara desert from Morocco to Egypt.	Local pain, swelling.
<b>Old world (or Palaearctic) vipers (Genera Daboia, Macrovipera, Vipera):</b>			
<i>Daboia mauritanica</i>	Moonish viper	Wooded coast and rocky mountain slopes: Morocco and coastal areas of Algeria.	Local swelling and bruising. Haemostatic disorders.
<i>Macrovipera lebetina</i>	Levant or blunt-nosed viper	Algeria and Tunisia.	Local swelling and bruising. Haemostatic disorders mentioned.
<b>Other old world vipers for which no bites have been recorded in Africa:</b> <i>Daboia deserti</i> (desert adder); northern Tunisia and Libya; <i>Vipera latastei</i> (Lataste's viper or Iberian viper); North African coast, from Morocco to Algeria, <i>Vipera monticola</i> (Atlas mountain viper); Atlas mountains of Morocco.			
The above information is based on the attached references. See text for specific details. <b>G J Müller 2010</b>			

## Annex 2

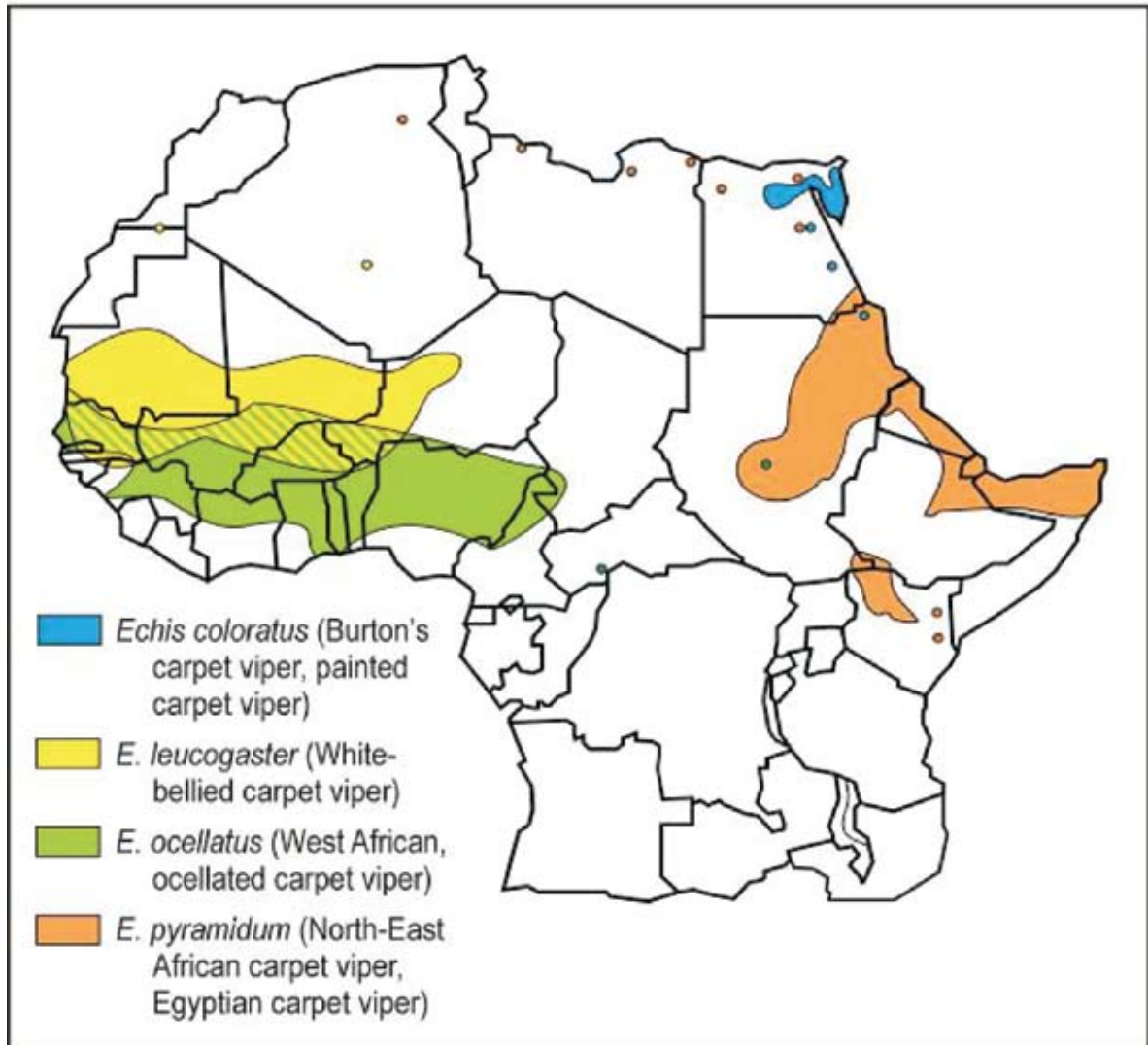
### Venomous Snakes of Africa Geographical Distribution Composite Maps

“The composite maps have been compiled with reference to the locations published in Spawls and Branch, 1995. Since the first publication of these composite maps in Brent et al 2005, they have been substantially modified”.

- Map 1 : Carpet or Saw-Scaled Vipers
- Map 2 : Large (Major) Adders
- Map 3 : Spitting Cobras and Rinkhals
- Map 4 : Neurotoxic Cobras and Sea Snakes
- Map 5 : Mambas
- Map 6 : African Burrowing Snakes or Asps and the Natal Black Snake
- Map 7 : Night Adders
- Map 8 : North African Desert and Palaeartic Vipers
- Map 9 : Common Snakes, Rear-Fanged Snakes (Colubridae)
- Map 10 : Coral/Shield-Nose Snakes and the Desert Black Snake
- Map 11 : Dwarf or Minor Adders
- Map 12 : Garter Snakes

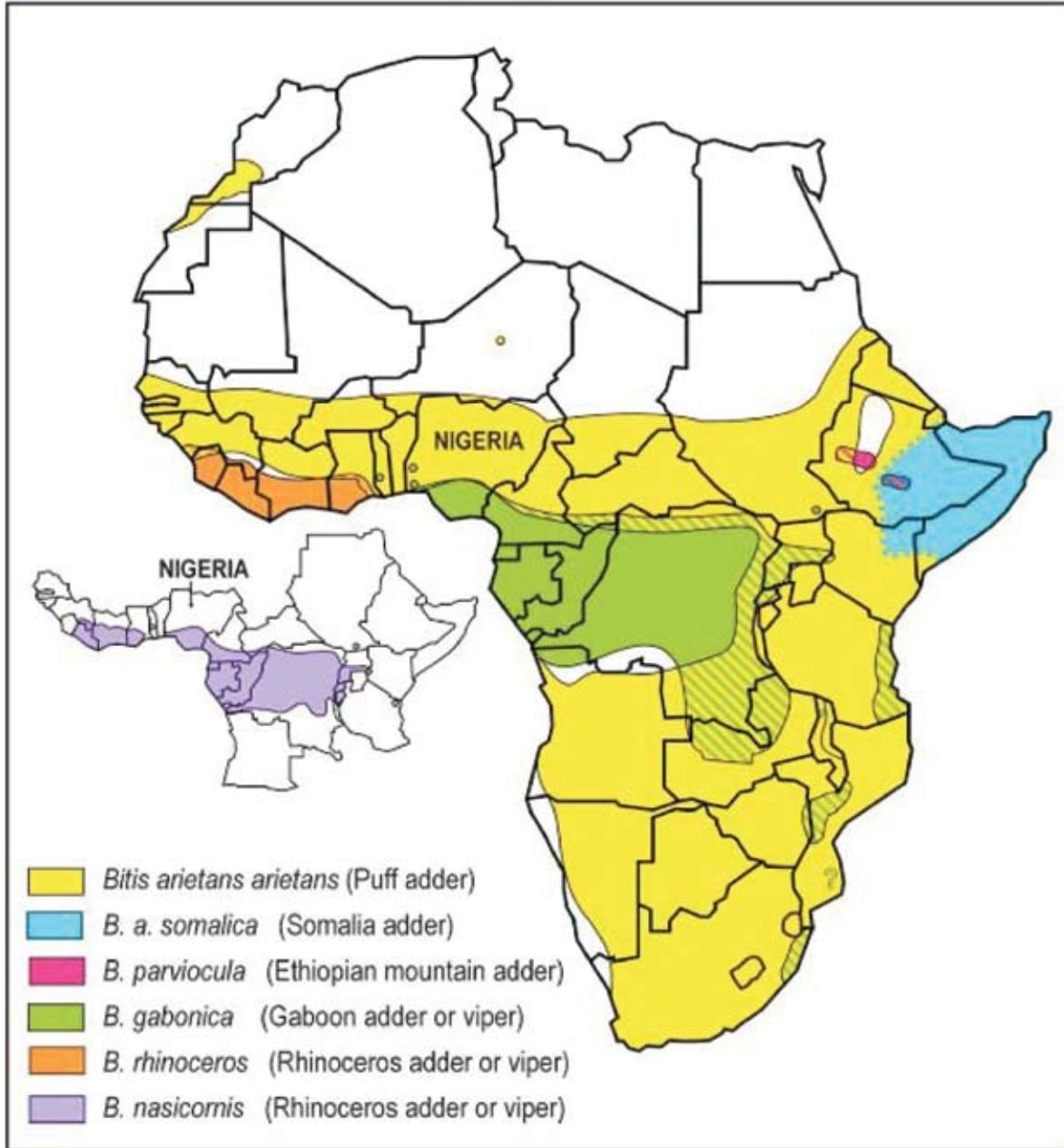
# Map 1

## CARPET OR SAW-SCALED VIPERS



# Map 2

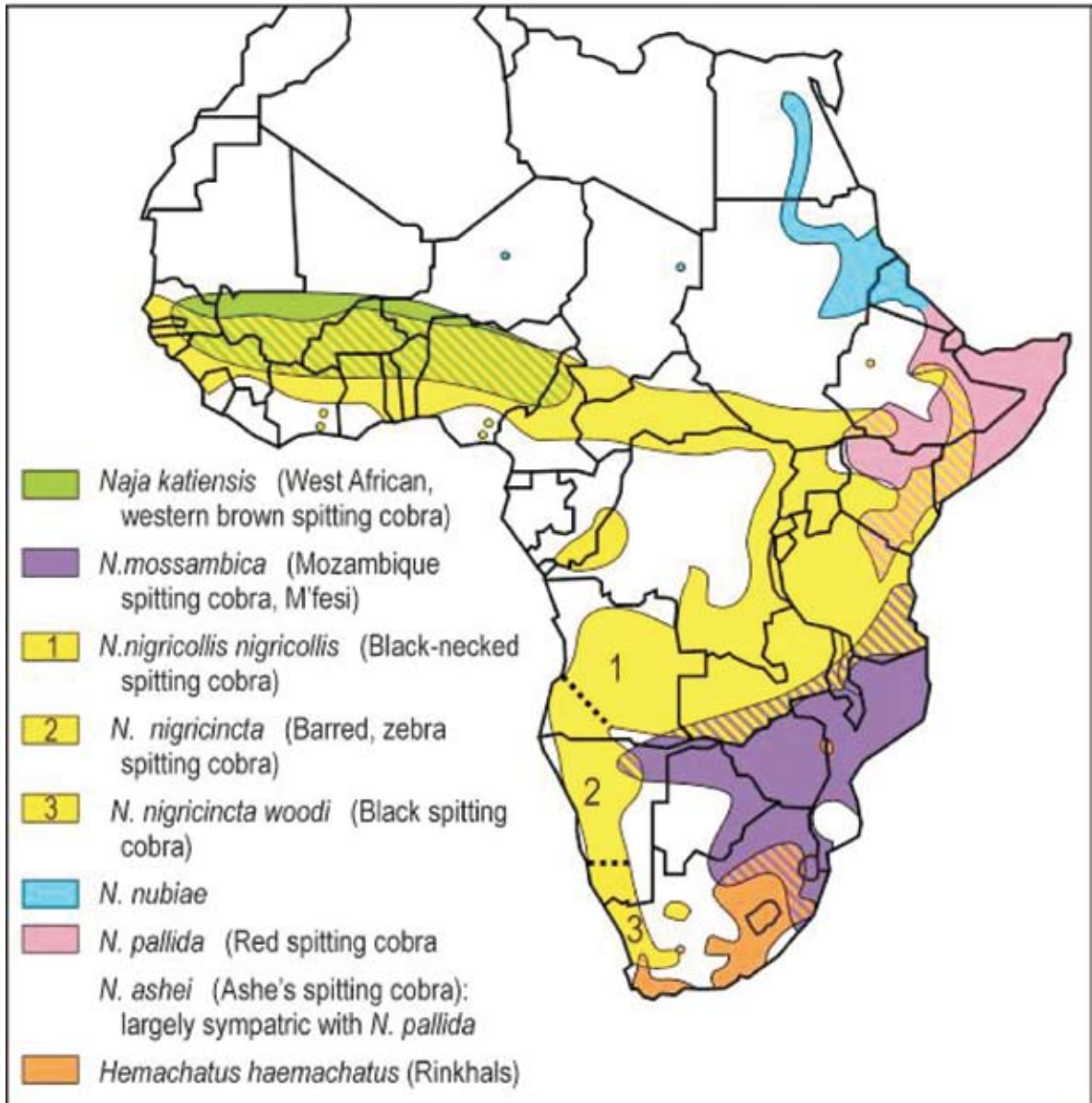
## LARGE (MAJOR) ADDERS



Country name indicated for orientation purposes

# Map 3

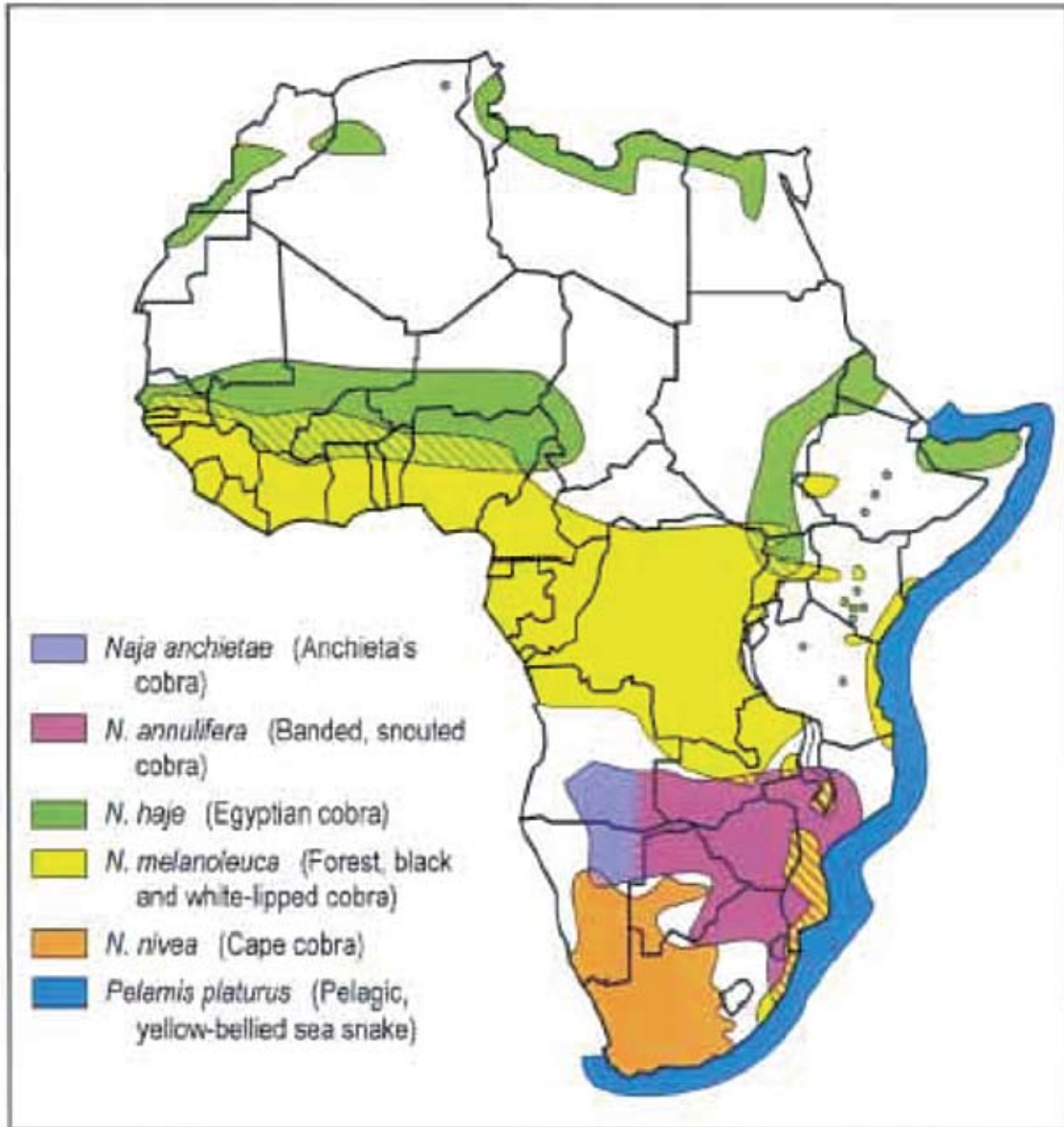
## SPITTING COBRAS AND RINKHALS





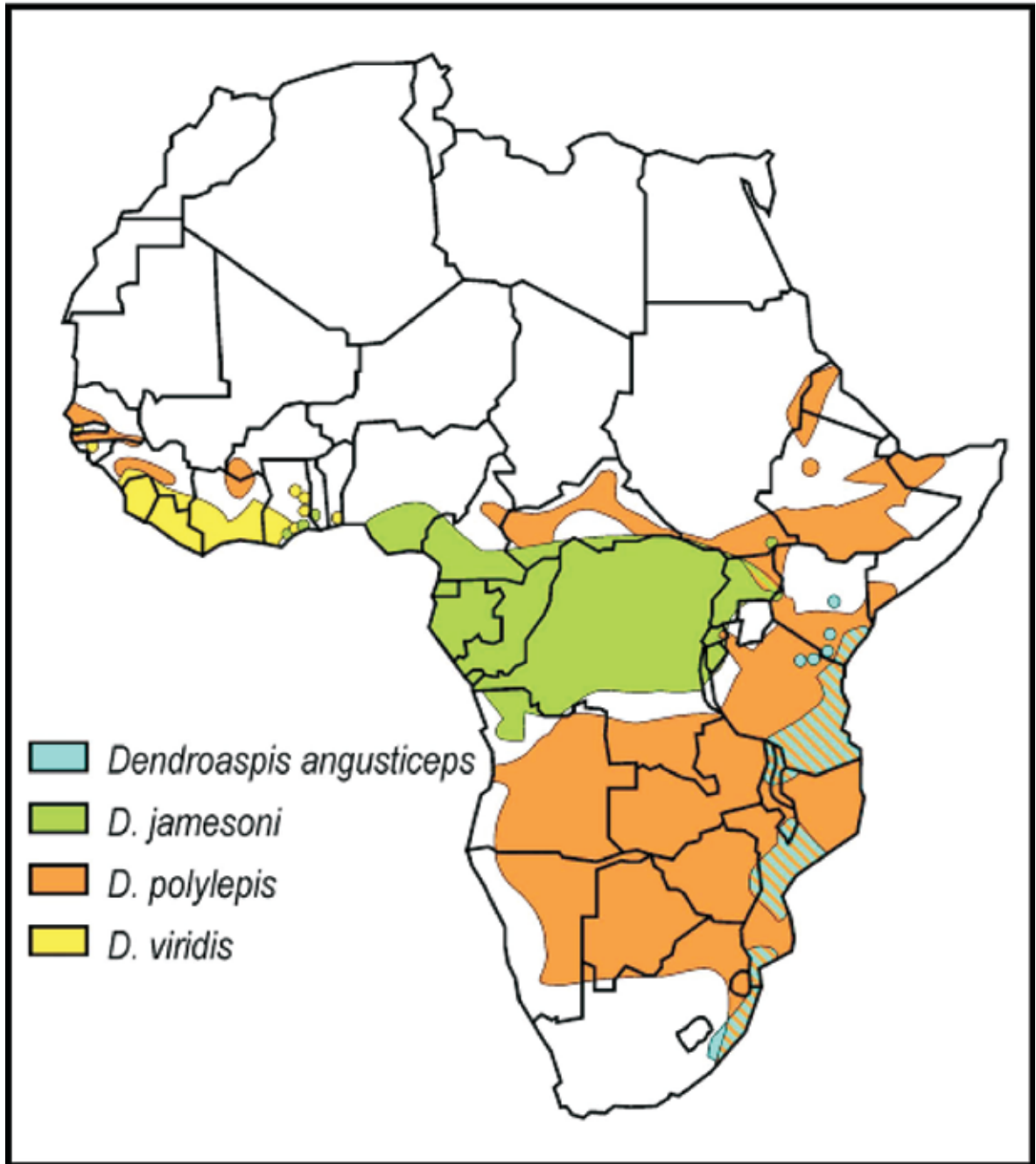
## Map 4

### NEUROTOXIC COBRAS AND SEA SNAKES



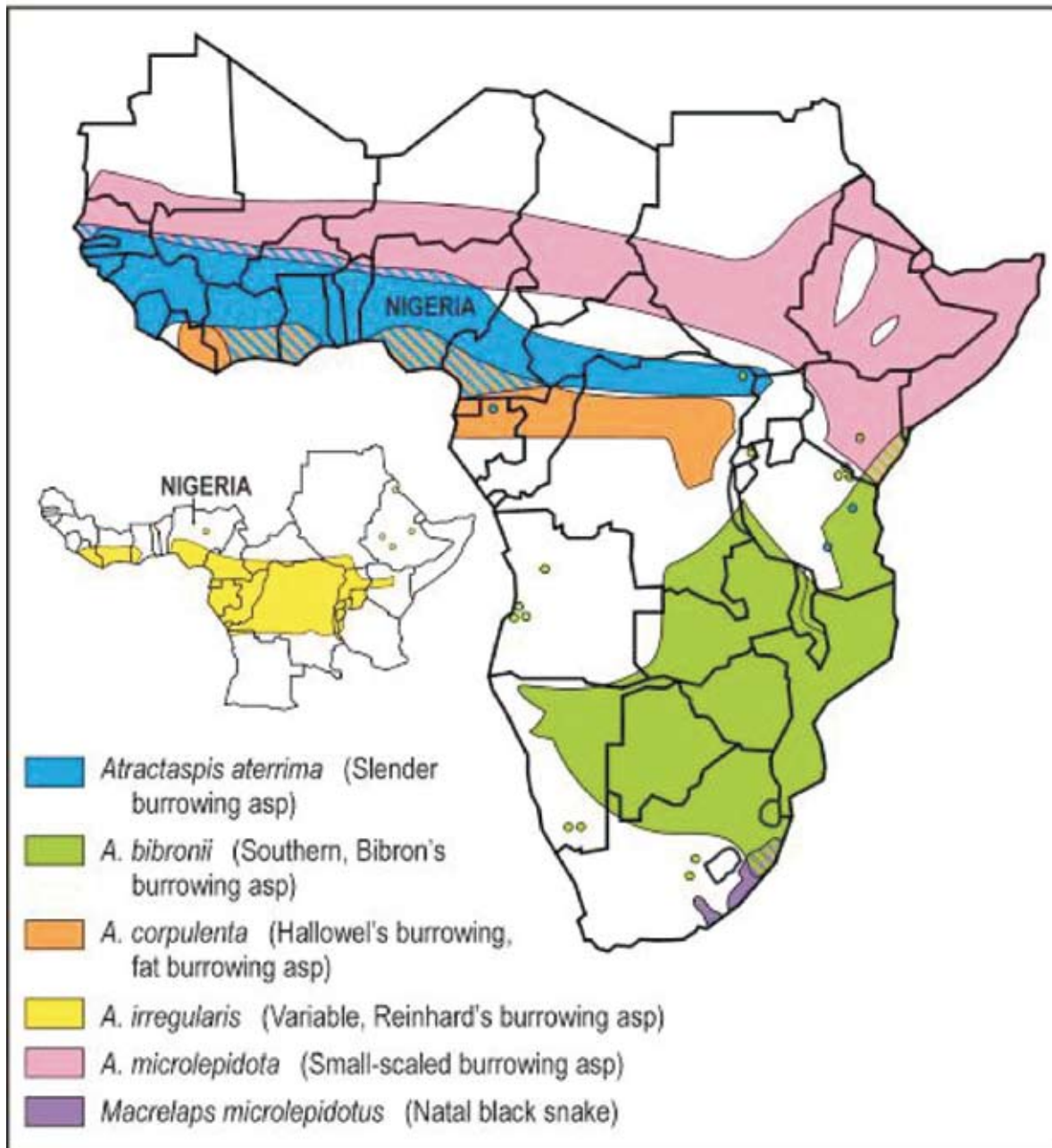
# Map 5

## MAMBAS



## Map 6

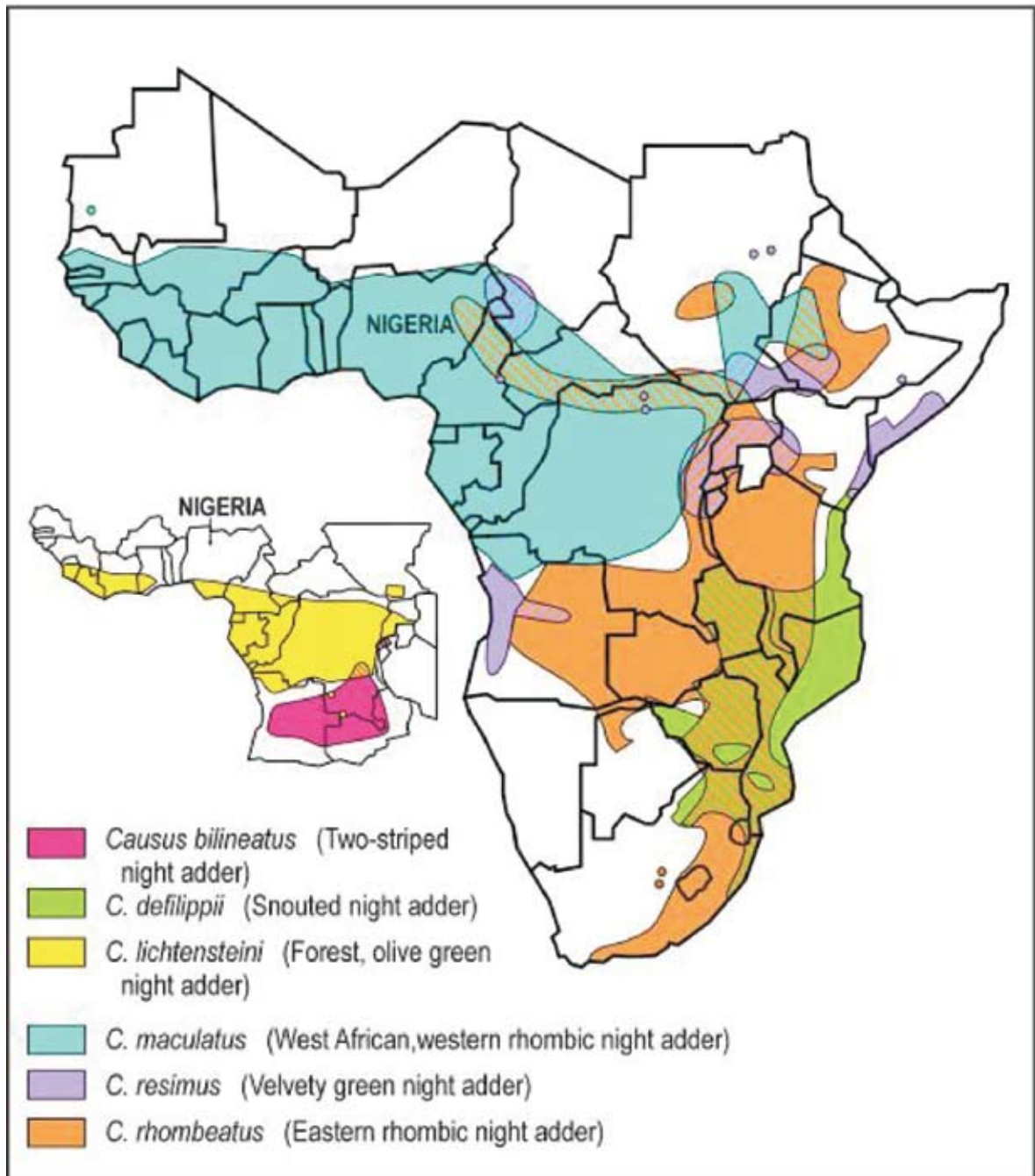
### AFRICAN BURROWING SNAKES OR ASPS AND THE NATAL BLACK SNAKE



Country name indicated for orientation purposes

# Map 7

## NIGHT ADDERS

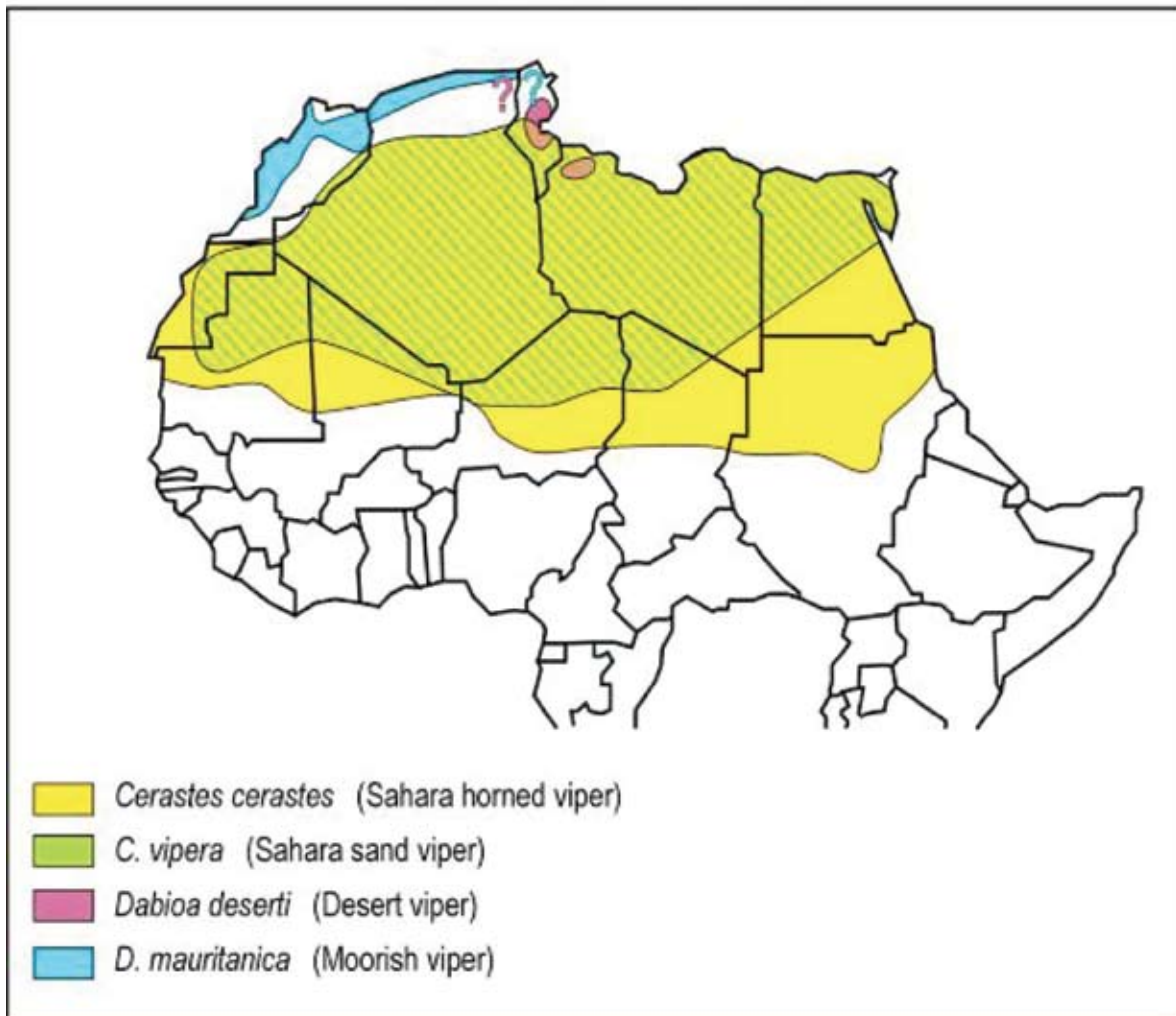


Country name indicated for orientation purposes



# Map 8

## NORTH AFRICAN DESERT AND PALAEARCTIC VIPERS

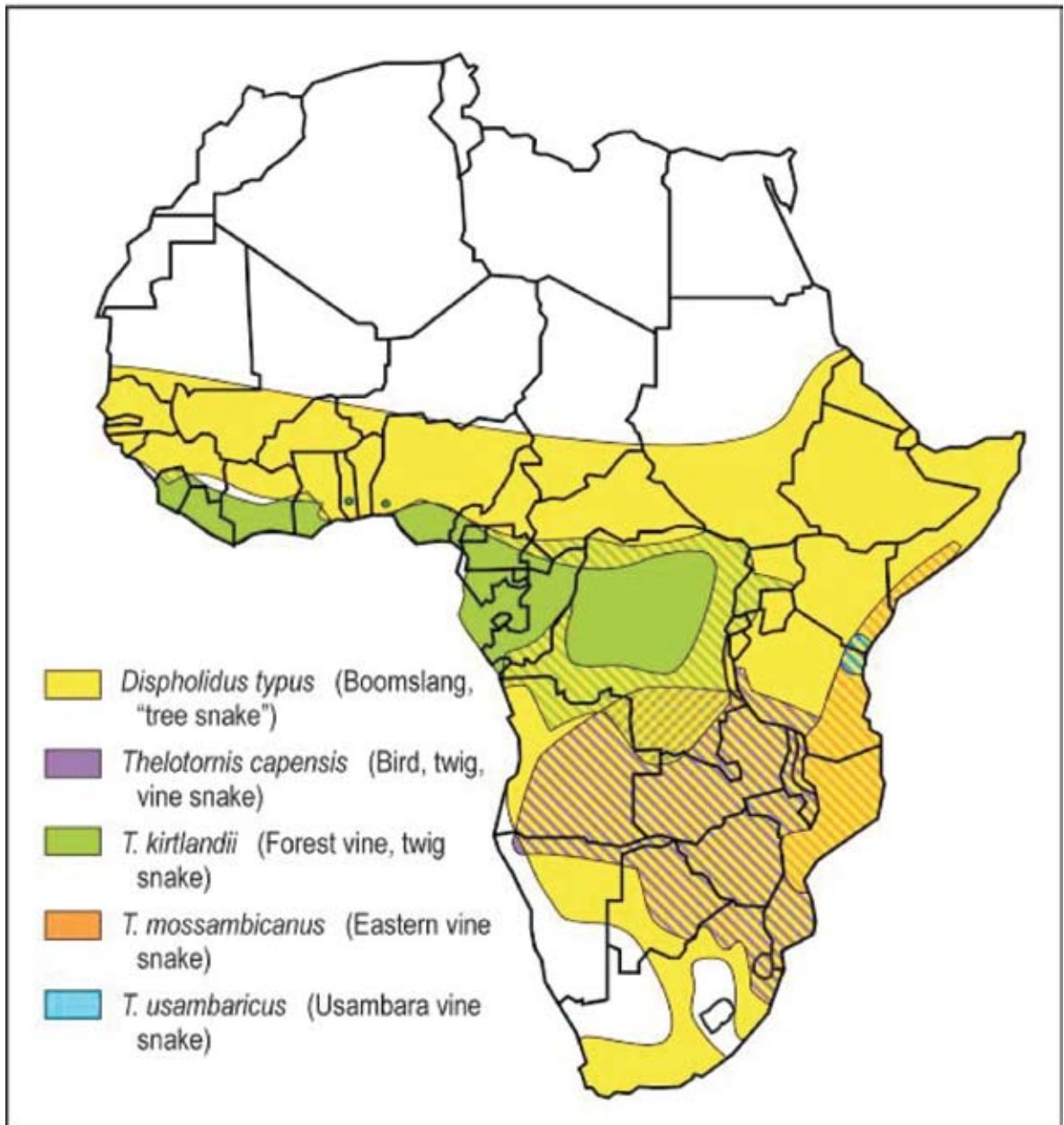


Question marks refer to unconfirmed/possible occurrences



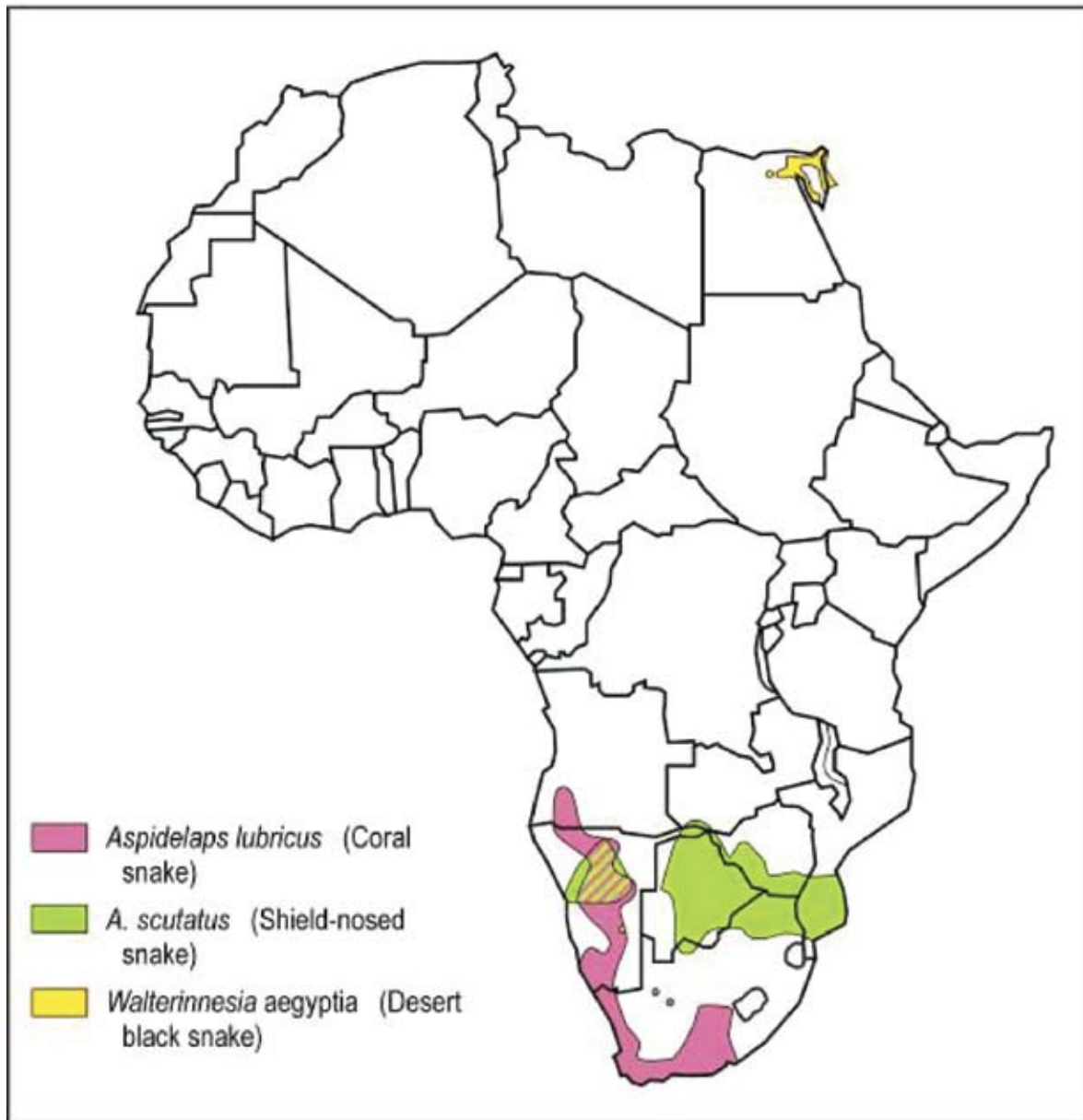
# Map 9

## COMMON SNAKES, REAR-FANGED SNAKES (COLUBRIDAE)



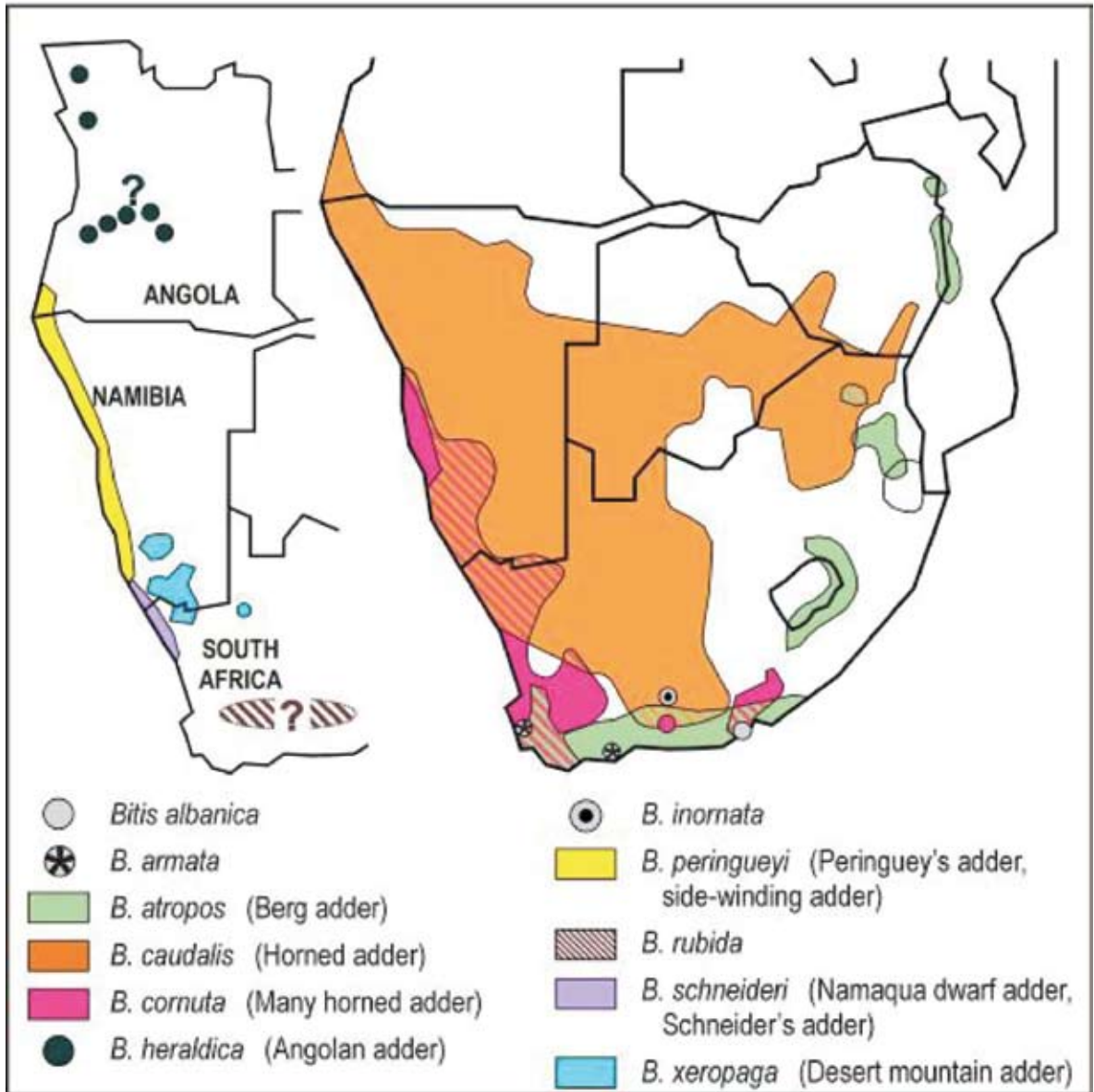
# Map 10

## CORAL / SHIELD-NOSE SNAKES AND THE DESERT BLACK SNAKE



# Map 11

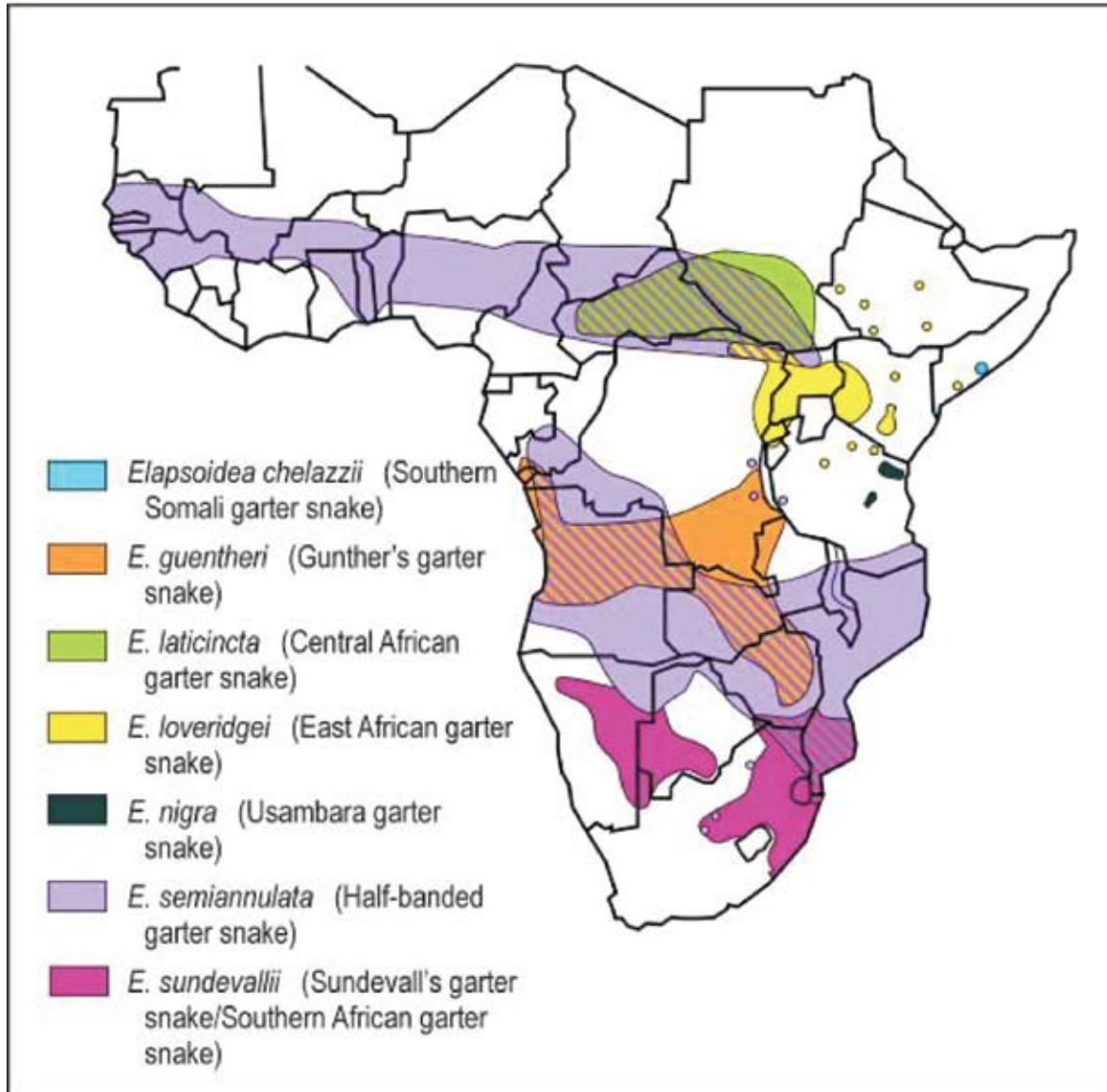
## DWARF OR MINOR ADDERS



Country names indicated for orientation purposes Question marks refer to unconfirmed/possible occurrences

# Map 12

## GARTER SNAKES

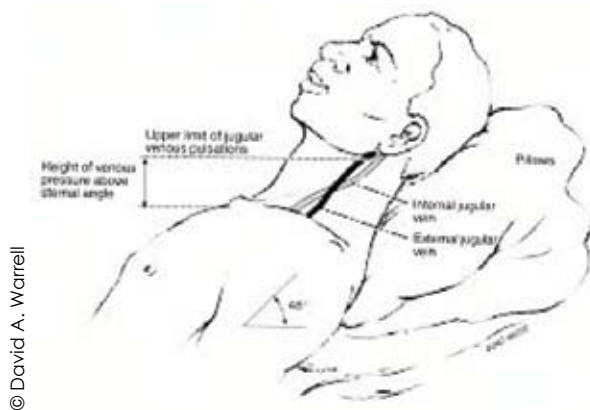




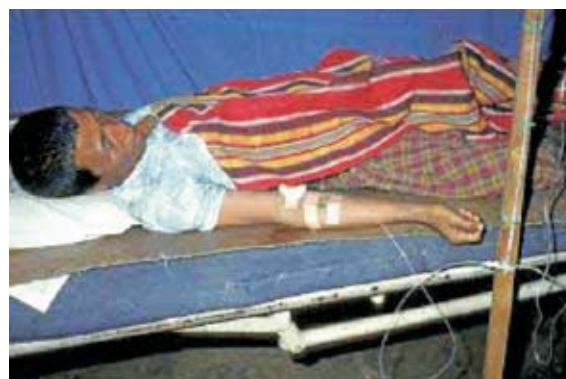# Annex 3

## Measurement of Central Venous Pressure

The jugular venous pressure is a clinical measure of central venous pressure (Figure A3.1). However, in seriously ill patients with shock or renal failure in whom clinical assessment of the jugular venous pressure is difficult or considered inaccurate, a central venous catheter should be inserted into the jugular or subclavian vein provided adequate facilities for a sterile procedure and subsequent nursing are available. Four approaches are possible: **antecubital** (Figure A3.2), subclavian (**infraclavicular**) (Figure A3.3), subclavian (**supraclavicular**) (Figure A3.4) and **internal jugular**. A long catheter (at least 50 cms for an adult) is required.



**Figure A3.1:** Measurement of jugular venous pressure in a patient lying in bed with head and shoulders propped up with pillows at an angle of 45°. Jugular venous pressure is the vertical distance between the level of the jugular venous pulsation (in the internal jugular vein) and the sternal angle (angle of Louis).



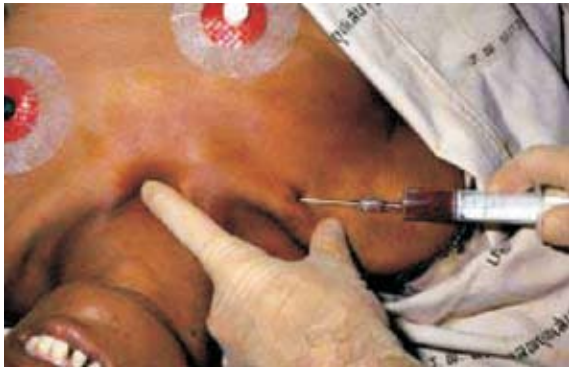© David A. Warrell

**Figure A3.2:** Central venous pressure monitoring in a township hospital in rural Myanmar. A catheter 70 cm long was inserted into an antecubital vein (Seldinger technique) and advanced until its tip was in the superior vena cava. An extension tube was connected to a simple saline manometer with its zero point at the level of the mid-axillary line.

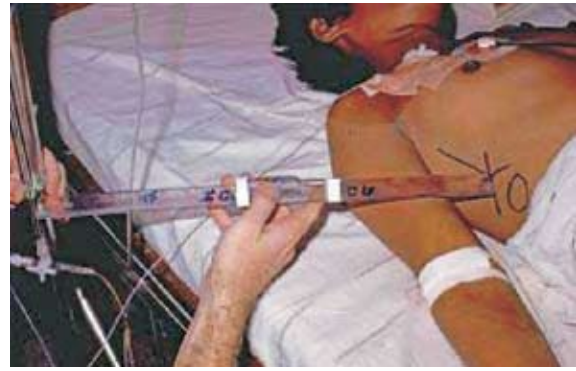The antecubital approach is the safest, and homeostasis is most easily achieved by local pressure on the site. Before readings can be taken, the zero on the manometer must be aligned as accurately as possible with the horizontal plane of the right atrium. A simple spirit level (e.g. a 20 ml glass ampoule, containing an air bubble in water or saline, taped to a ruler) can be used to locate the manometer zero at the same height as an appropriate chest-wall landmark, such as the mid-axillary line, in the supine patient (Figure A3.5). There should be strict attention to asepsis. Infection and thrombosis are potential complications, especially if the catheter remains in place for a long time (Kaye and Smith, 1988).



© David A. Warrell



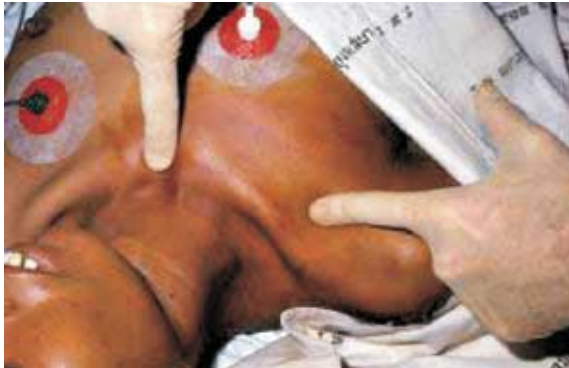**Figure A3.3:** Central venous pressure monitoring. Puncture of subclavian vein (infraclavicular approach) preparatory to inserting a guide wire and short catheter (Seldinger technique).



© David A. Warrell

**Figure A3.5:** Central venous pressure monitoring. Levelling the manometer at the mid-axillary line using a home-made ruler-plus-glass ampoule "spirit level", in a provincial hospital in Thailand.

© David A. Warrell



**Figure A3.4:** Central venous pressure monitoring. Surface marking of the subclavian vein for needle insertion by the supraclavicular approach.

There should be strict attention to asepsis. Infection and thrombosis are potential complications, especially if the catheter remains in place for a long time.

# Annex 4

## Femoral Venous Access

In a shocked adult or child with hypotension and collapsed peripheral veins, the femoral veins may provide the only possibility for venous access.

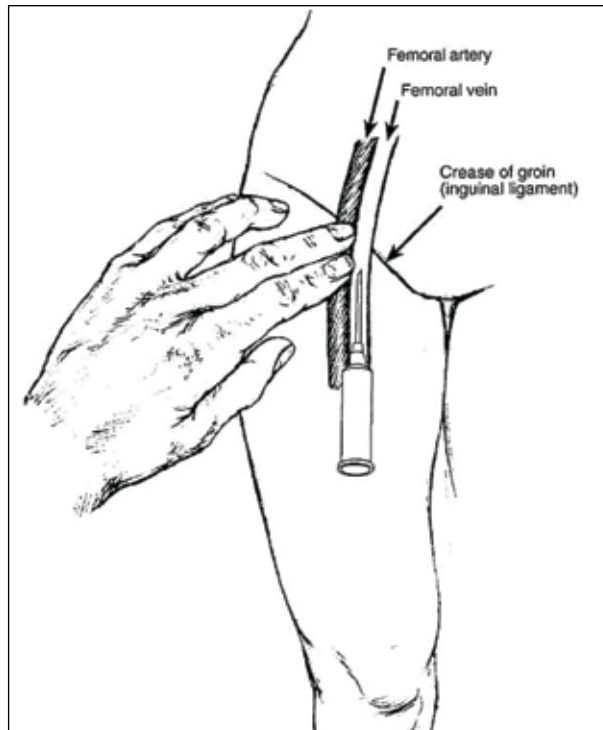
### Anatomy

The femoral vein lies immediately medial to the femoral artery at about the mid-point of the inguinal (Poupart's) ligament at the groin (Figure A4.1).

### Method

With the patient lying supine with right thigh slightly abducted and externally rotated, locate the femoral arterial pulse at the groin with the index and middle fingers of your left arm. Clean the skin thoroughly with alcohol or iodine and, with full sterile precautions, mount the cannula (e.g.

Abbocath, Venflon) with its introducing needle on a syringe. Puncture the skin just medial to the femoral artery, just below the groin crease, and, with the cannula assembly at an angle of 45 degrees, advance gently, aspirating repeatedly until the vein is entered and blood drawn back. If the needle meets firm resistance, withdraw, millimeter by millimeter, aspirating each time until blood can be drawn back freely with the syringe. Once you are confident that the needle tip is in the lumen of the vein, flatten the angle slightly and advance the cannula into the vein. Secure the cannula in place with a gauze pad and sticking plaster. Alternatively, the left femoral vein may be cannulated; this is more convenient if the operator is left-handed.



**Caution:** infection and thrombosis of the femoral vein are serious complications. Avoid leaving a femoral cannula for longer than is absolutely necessary.

**Figure A4.1:** Location of the femoral arterial pulse and site for insertion of a cannula in the femoral vein.

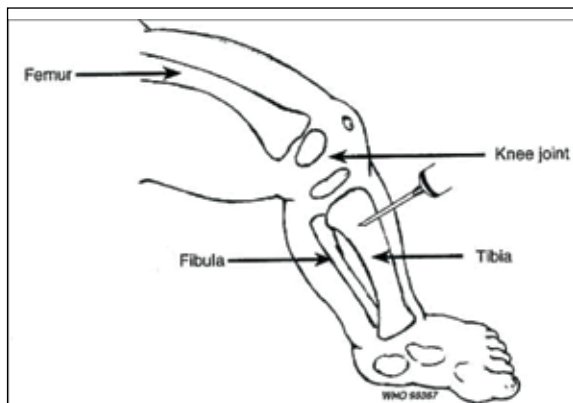
# Annex 5

## Setting Up an Intraosseous Infusion in Children

If intravenous access is impossible, an intraosseous infusion can be life saving. It can be used to administer anything that would normally be given intravenously, i.e. fluids, whole blood, packed cells, or medicines.

### Equipment

Alcohol swabs. A small syringe and fine needle for giving local anesthetic (unnecessary if patient is comatose). Local anesthetic, e.g. 1% lignocaine (= lidocaine). An 18-gauge needle with trochar (special needles are made for intraosseous infusion). Alternatively a bone-marrow aspiration needle can be used. Intravenous bottle and drip set, or 50 ml syringe containing fluid for infusion



**Figure A5.1: Site for insertion of an intraosseous infusion in the tibia**

### Procedure

Choose a point for insertion of the infusion needle in the middle of the wide flat part of the tibia, about 2 cm below the line of the knee joint (Figure A5.1). Do not use a site of trauma or skin sepsis. If the patient is conscious, infiltrate the skin and underlying periosteum with 1% lidocaine.

With the needle vertical to the skin, press firmly with a slight twisting motion until the needle enters the marrow cavity with a sudden "give".

Attach a 5-ml syringe and aspirate to confirm that the position is correct. The aspirate can be used for a blood film, blood culture and blood glucose measurement.

The infusion needle should be held in place with sticking plaster (a plaster of Paris cast can be used, as with a scalp vein needle), and the child's mother or minder can be asked to hold the leg.

### Notes

An infusion can be placed in each leg, either simultaneously or in sequence, if necessary. An alternative site for an intraosseous infusion is the antero-lateral surface of the femur, 2-3 cm above the lateral condyle.

An infusion allowed to drip through the needle in the usual way (by gravity) may go very slowly. For urgent administration a 50-ml syringe can be used to push in the required fluid in boluses.

### Possible complications

**Sepsis.** An intraosseous line must not be left in one site for more than 6-8 hours; after this time sepsis is increasingly likely to develop.

**Compartment syndrome:** If the needle is allowed to pass entirely through the tibia, fluid may be infused into the posterior compartment of the leg causing swelling and eventually impairing circulation. Circulation in the distal leg must be checked at regular intervals.

# Annex 6

## Pressure Immobilization Method

**Background:** The splinting and crepe bandaging method ("Pressure Immobilization Method," PI) developed in Australia proved effective in limiting the absorption of high molecular weight phospholipase A2 Australian elapid toxins in restrained monkeys (Sutherland et al, 1979). Soundly based on experimental studies in animals, the method was never subjected to formal clinical trials (Warrell, 2006). It has proved successful in some patients, as judged by anecdotal reports of delayed systemic envenoming and rapid deterioration after release of the bandage, supported in some cases by measurements of venom antigenaemia. However, there have been practical difficulties in implementing PI and, even in Australia, only 18-53% of the bandages in place when patients arrived in the hospital had been correctly and effectively applied. The method remains controversial, and its implementation is fraught with a number of difficulties (Cheng and Currie, 2004; Warrell, 2006).

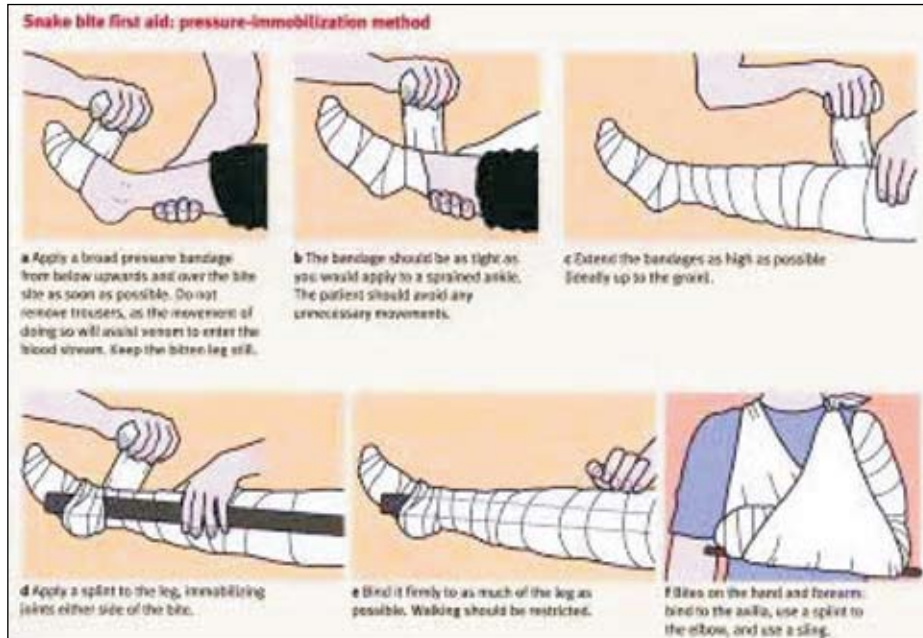
**Principles and practice:** The aim is to apply the crepe bandage sufficiently tightly to compress the lymphatic vessels and veins through which larger molecular weight toxins spread from the site of the bite. This requires a pressure of about 55 mmHg, that of a venous tourniquet. In practice, it is difficult to judge how tightly the bandage should be applied and difficult for the patient to put it on unaided. This is why so many are incorrectly applied, usually too loosely. External compression directly increases intra-compartmental pressure

and may accentuate the local effects of some necrotic snake venoms (Bush et al, 2004) and so, in Africa, the method is not appropriate if the bite is known to have been caused by a viperine snake or spitting cobra.

**Indications:** Unless a bite by a dangerously neurotoxic elapid (such as a mamba, neurotoxic cobra or sea snake) can be reliably and confidently excluded, there is a risk that respiratory paralysis might develop en route to the hospital perhaps, in exceptional circumstances, within 30-60 minutes of the bite. Therefore in cases where the cause of the bite is uncertain and those in which a dangerously neurotoxic elapid is implicated, it is recommended that PI be applied immediately.

**Technique (Figure A6.1):** Several long (preferably 4.5 m), wide (preferably 10 cm) stretchy/elasticated/crepe bandages and a splint are required. AS SOON AS POSSIBLE AFTER THE BITE, PREFERABLY IMMEDIATELY, the bandage is applied over any clothing starting distal to the bite site and progressing proximally to encase the whole of the bitten limb up to the groin or axilla and incorporating a splint. The bandage is applied "as firmly as for a sprained ankle" but not so tightly that it cuts off arterial blood flow to the limb. If the bandage has been applied too tightly the limb quickly becomes very painful and cyanosed and the peripheral pulses, radial or ulnar at the wrist or dorsalis pedis or posterior tibial at the ankle (exposed by separating the layers of bandage), become impalpable. Lymphoscintigraphy studies

showed that excessive pressure (>70 mmHg) or movement of the other limbs or the subject as a whole overcame the obstructive effect of PI on lymphatic flow (Howarth et al, 1994). The whole patient should therefore be immobilized, not just the bitten limb.



**Figure A6.1: Immobilization technique**

**Difficulties:** In some situations, it has proved difficult to teach the technique to volunteers, especially when the instructors were unenthusiastic (Norris et al, 2005; Simpson et al, 2008). The bandage is often applied too late, too loosely and not sufficiently extensively. The requirement for rigorous training and the need for special equipment make it impracticable for most rural settings in Africa. However, it might be feasible in certain specific settings such as institutions, zoos, fieldwork programmes or expeditions where the necessary equipment and highly trained staff could be made available, or in highly motivated communities.



# Annex 7

## Essential Medicines and Supplies for Managing Snakebite at a District Hospital

In order for health workers to deal effectively with cases of snakebite, it is important that certain essential supplies are available in their health facilities and that they are trained in the best methods for using them. Below is a list of recommended essential supplies for the management of snakebite. It can be modified to suit the needs of local health workers, depending on their specific training and aptitude in dealing with snakebite victims.

1. Antivenom (with sterile water for reconstituting lyophilized antivenom)
2. Tetanus toxoid
3. Epinephrine (adrenaline) injection 0.1% (1:1,000) (1 mg/ml)
4. Parenteral antihistamine and hydrocortisone
5. Pain killers e.g. paracetamol and codeine NOT aspirin or nonsteroidal anti-inflammatory agents
6. Antipyretics (paracetamol tablets, syrups and suppositories)
7. Local anaesthetic agents (1-2% lidocaine)
8. Intravenous (IV) fluids e.g. normal saline (0.9% NaCl)
9. Vasopressor drug e.g. phenylephrine, adrenaline and nonadrenalin
10. Atropine and edrophonium or neostigmine (Prostigmin) for "Tension Test"
11. Fresh frozen plasma or cryoprecipitates
12. Blood platelets
13. Oxygen cylinders with spanners, gauges, necessary connectors
14. Antibiotics (chloramphenicol, benzylpenicillin, flucloxacillin, metronidazole, gentamicin, amoxicillin-clavulanic acid)
15. Laryngoscope (adult and paediatric sizes) with spare batteries and bulbs
16. Cuffed endotracheal tubes (various sizes)
17. Ambu bag with connectors to endotracheal tube and face mask that fit
18. Face masks and oral airways
19. Suction apparatus and catheters
20. Urine dip sticks
21. New, clean, dry glass vessels for 20WBCT
22. Syringes, needles, intravenous cannulae
23. IV administration set
24. Sticking plaster
25. Scissors
26. Splints
27. Urethral catheters
28. Bathroom type weighing scales
29. Stretchy, elasticated crepe bandage and splint

