

Capsula Eburnea

# HEAD & NECK EXPERIMENTAL MEDICINE

*Guest Editors*

**Alessandro De Stefano • Francesco Dispenza**

*With the collaboration of*

Pamela Di Giovanni  
Giulio Filograna-Pignatelli  
Gautham Kulamarva  
Anna Grazia Petrucci

**Alessandro De Stefano**

School of Advanced Studies

Department of Surgical, Clinical and Experimental Sciences

“G. d’Annunzio” University of Chieti-Pescara, Italy

e-mail address: a.destefano@unich.it

**Francesco Dispenza**

ENT Institute

Department of Surgical and Oncological Sciences

University of Palermo, Italy

e-mail address: francesco.dispenza@gmail.com

*With the collaboration of*

**Pamela Di Giovanni**

Department of Drugs Sciences

“G. d’Annunzio” University of Chieti-Pescara, Italy

**Giulio Filograna-Pignatelli**

ENT Institute

Department of Surgical, Clinical and Experimental Sciences

“G. d’Annunzio” University of Chieti-Pescara, Italy

**Gautham Kulamarva**

ENT & Head Neck Clinic

Thekkil Complex, Kasaragod, Kerala State, India

**Anna Grazia Petrucci**

Public Health and Preventive Medicine Department

“G. d’Annunzio” University of Chieti-Pescara, Italy

# CONTENTS

5 Presentation

7 Preface

## Lectures

11 Anatomy of central and peripheral vestibular system

*Alfred Cuschieri*

25 Autoimmune Inner Ear Disease (AIED)

*Simon A. McKean and Musheer Hussain*

31 Diagnosis and management of psychogenic vertigo  
and psychiatric associated dizziness

*João Carlos Ribeiro, Rui Cerejeira, José Romão, António Paiva*

39 Pseudohypacusis in childhood: diagnostic approach

*Giorgos Kontorinis*

49 Malignant Sinonasal Tumors

*Carlos Celedon Lavin, Michel Royer Faundez, Costanza Valdez Perez*

51 Understanding Functional Neck Dissection

*Javier Gavilán, Jesús Herranz, Lourdes Martín*

## Review

67 Hearing outcomes in children with surgery for cholesteatoma

*Matthew J. Lin*

## Original researches

77 Acute otitis media in Saudi children:  
pathogens and their response to antibiotics

*R.M. Alsumm and D.M. Alfrage*

85 Minimal access endoscopic attic exploration made possible through  
the use of a Kwills filling tube: a novel approach to attic cholesteatoma

*Amir Farboud, Aaron Trindade, Rohit Pratap, Paul Leong*

- 91 Dissassembly-Modelling-Reassembly:  
a new technique in aesthetic and functional surgery of the nose  
Smontaggio-Modellamento-Rimontaggio:  
una nuova tecnica nella chirurgia estetica e funzionale del naso  
*Daniela Cerrone, Alessandro De Stefano, Alessandro Cerrone, Sante Cerrone*
- 99 The endoscopic stapling of pharyngeal pouches:  
long term patient outcomes  
*Floyd Gomes and Eduard Pudel*

### **Clinical reports**

- 109 Spontaneous haemotympanum:  
an uncommon presentation of otitis media with effusion  
*Aaron Trinidad, Amir Farboud, Claudine Horrock*
- 113 Bilateral pseudocysts of the auricle  
Pseudocisti auricolare bilaterale  
*Francesco Lorusso, Francesco Dispenza*
- 119 Mucopyocele of the middle turbinate: a case report  
*Abdul-latif Hamdan, Mohammad Natout, Khaled M. Musallam,  
Sami Tanbouzi Husseini*
- 123 Mucoepidermoid carcinoma in the larynx successfully treated  
by radiotherapy: a case report  
*Gökçe Şimşek, Erkan Vuralkan, İstemihan Akin, Ünsal Han*
- 130 Acknowledgments
- 131 Capsula Eburnea Guidelines for authors



## PRESENTATION

The Head and Neck region is a complex part of the human body that includes anatomical structures of a number of systems, as musculoskeletal, nervous, circulatory, respiratory, digestive and endocrine ones. Thus, this area is of great interest for specialists of several medical branches, firstly otorhinolaryngologists. The latter are actively involved in diagnosing and treating of frequent diseases by mean of complex investigative methods and variegated therapeutic tools.

Additionally, the rapid progresses of knowledge through experimental researches have led to a large number of sub-specialization addressing different fields of otolaryngologist sciences.

This Special Issue of *Capsula Eburnea* includes original contributes from otolaryngologists of different Schools in the World. The contents embrace articles of anatomy, physiology, physiopathology, oncology, pharmacology and surgery that concern pathologies of ear, nose, pharynx and larynx. In this way, we would allow an exchange of experiences and ideas among groups of researchers actively involved in this field, in accordance with the aim of our Journal to be a constructive platform for debates in Experimental Medicine. For this reason, we are grateful to all the colleagues that participated, with their worthy contribute, to this project.

*Francesco Cappello*  
*Walter Mazzucco*  
*Giuseppe Puccio*  
Editors in Chief



## PREFACE

When a Special Issue of “Capsula Eburnea” completely dedicated to Head and Neck fields was thought, we planned it as a open space, where the Aristotelian idea of the discovery and intuition could lead to a different form of knowledge able to amalgamate researcher and famous university lecturer.

To this end in the present issue we tried to enroll several Institution coming from all nations and continent. We tried also to variegate the fields of interest, keeping in mind the wholeness of the Head and Neck district that connect instead separate several medical disciplines.

From such project arise the “Head & Neck - Experimental Medicine” Issue. A supplement that hold inside the immediacy of a scientific journal, where scientist from all over the world can propose them Original Researches, Review and Clinical Reports.

As introduction of such exposition, a Lectures section was planned to collect the most experienced school's lections. The superb contribution of Prof. Cuschieri from University of Malta introduce the readers to the Anatomy and Physiology of the Cochlear-Vestibular system, allowing to better understand: the insidious Autoimmune Sensorineural Hearing Loss described by Prof. Musheer Hussain from the University of Dundee, the frequents Psicogenic Vertigo exposed by Prof. Paiva from University of Coimbra and the Pseudohypoacusis of childhood described by Dr. Kontorinis from Hannover. The nasal tumors reported by Prof. Celedon from Chile together with the rational that could lead all Head and Neck surgeons in the Neck Dissection as taught by Prof. Gavilán from University of Madrid complete and conclude not only the lectures but also the concept that this volume has regard to the Head and Neck's disciplines.

*Alessandro De Stefano  
Francesco Dispenza*

HEAD & NECK  
EXPERIMENTAL MEDICINE



# LECTURES



# ANATOMY OF THE PERIPHERAL AND CENTRAL VESTIBULAR SYSTEM



Alfred Cuschieri  
Department of Anatomy  
University of Malta,  
Msida, MALTA

## Abstract

The central and peripheral vestibular system, in conjunction with the ocular and somato-sensory systems, is responsible for the equilibrium, balance and orientation of the body in the space.

Balance and its disorders are intimately connected with the anatomy and physiology of the vestibular system and therefore knowledge of the gross and molecular mechanisms in the posterior labyrinth and its pathways is necessary for a correct diagnosis and an accurate management of the dizzy patient.

*Keywords:* Vestibular System, Utricule, Saccule, Semicircular canals, Inner ear, Vertigo.

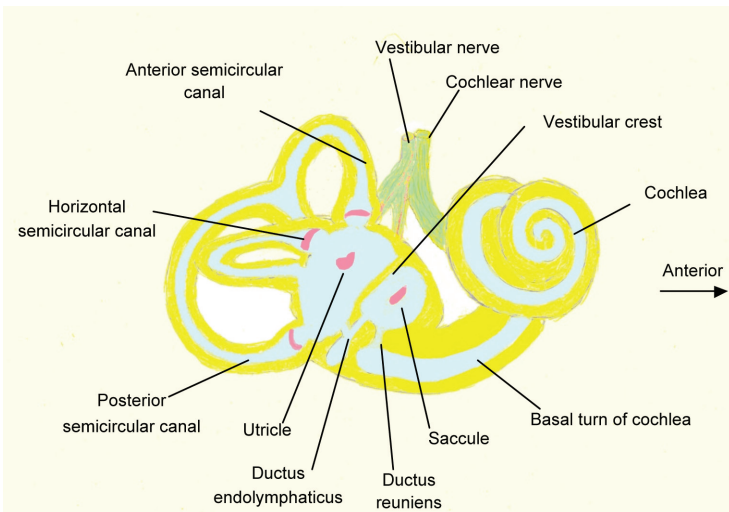
## Introduction

The vestibular system is the silent set of sensors that monitors the position and movements of the body in relation to gravity. It is silent because, unlike the olfactory, visual or auditory stimuli it does not evoke emotions and pleasant or unpleasant sensations and is generally taken for granted until the correct functioning of the system is lost evoking disease symptoms. It consists of five groups of mechanoreceptor hair cells that are sensitive to slight deflections of the stereocilia caused by gravity or motion, with high directional sensitivity.

## The Vestibule and Semicircular Canals

Situated in the membranous labyrinth, that is bounded by an epithelial-lined membrane, the receptor cells are bathed in endolymph that has an ionic composition that is distinct from that of the perilymph that bathes the outer surface of the membranous labyrinth. The bony labyrinth, hewn out of dense bone in the petrous temporal bone, provides a strong casing for the delicate membranous labyrinth and its enclosed hair cells.

The vestibule (figure 1) lies medial to the tympanic cavity, posterior to the cochlea and anterior to the semicircular canals and measures approximately 5 mm vertically, 5 mm horizontally and 3 mm in depth from medial to lateral. On the medial wall an oblique vestibular crest separates the vestibule into two parts. A small spherical recess anterior and inferior to the crest contains the saccule and a larger elliptical recess postero-superior to it contains the utricle, encroaching on the roof of the vestibule. At its inferior end the crest widens into a cochlear recess where the base of the cochlea is situated. The macula cribrosa media and the macula cribrosa superior are perforations in the spherical and elliptical recesses that transmit the branches of the vestibular nerve to the saccule and utricle respectively. Medially the maculae cribrosae correspond to the inferior and superior vestibular areas respectively of the internal auditory meatus. At the posterior end of the vestibule where the semicircular canals open into it, the macula cribrosa inferior transmits the nerves to the anterior and inferior semicircular canals. The foramen singulare that transmits the nerve to the posterior semicircular canal is prominent as a separate foramen in the internal auditory meatus.



**Figure 1** - The membranous labyrinth (blue) and the bony labyrinth (yellow). The maculae of the utricle and saccule and the crests of the ampullae of the semicircular canals are indicated in red.

In the posterior part of the vestibule are five openings of the semicircular canals, which are located posterior and superior to the vestibule. The anterior (superior) semicircular canal is oriented vertically at right angles to the long axis of the petrous temporal bone, and lies deep to the arcuate eminence on the superior surface of the petrous temporal. At its anterior end the anterior



semicircular canal widens into the ampulla which opens into the upper and lateral part of the vestibule. Its narrow posterior end joins the narrow end of the posterior semicircular canal to form the crus commune that opens into the vestibule. The posterior semicircular canal is also vertical but lies along the long axis of the petrous temporal bone. Its ampulla opens into the inferior part of the vestibule, just posterior to the macula cribrosa inferior that transmits the branches of the vestibular nerve to the semicircular canals. The lateral semicircular canal is horizontal, with its ampulla situated anteriorly and opening into the upper and lateral angle of the vestibule, just below the ampulla of the anterior semicircular canal. Its narrow end opens into the vestibule below the crus commune. The membranous labyrinth is a membrane lined cavity that contains endolymph. It is attached to the periosteum of the bony labyrinth at certain points but is largely separated from it by perilymph, a fluid with a different chemical composition to that of endolymph. The membranous labyrinth is a closet cavity that consists of the utricle, saccule, semicircular ducts and cochlea. The semicircular ducts communicate directly with the utricle, and are wider at one end to form the ampulla. The utricle communicates with the duct of the cochlea by means of the ductus reunions, and with the saccule by means of the Y-shaped ductus endolymphaticus that leads to a blind sac, the saccus endolymphaticus. Within the utricle and the saccule two small patches of neuroepithelium containing the receptors form the maculae. Similarly, a transverse strip of neuroepithelium containing receptors, forms the ampullary crest, which is located within the ampulla of each semicircular duct.

### **Structure of the Peripheral Receptor Cells**

The receptors are limited to five small discrete areas of the membranous labyrinth, two maculae in the utricle and saccule respectively, and three ampullary crests one in each of the three semicircular canals. The receptor cells are each equipped, on their apical surface, with a single kinocilium and a set of stereocilia. The kinocilium has the structure of a motile cilium with 9 peripheral doublet microtubules and two central microtubules, but is static. The stereocilia are long microvilli arranged in successive rows behind the kinocilium in descending order of length. The kinocilium sets the polarity of the receptors, while the stereocilia carry the sensory transducers. Deflections of the stereocilia in the direction of the kinocilium opens ion channels that allow potassium and calcium ions to enter the receptor cell and sodium ions to leave it, thus causing depolarisation of the receptor membrane. Deflection of the stereocilia in the opposite direction, away from the kinocilium, closes the channels and the receptor cell is hyperpolarised.

The distal ends of the stereocilia and the kinocilium are embedded in a stato-clonial membrane, more commonly known as the otolith membrane in the maculae of the utricle and saccule, and as the cupola in the cristae ampulla-

res of the semicircular canals. It consists of an extracellular gelatinous matrix of glycosaminoglycans and fibrous proteins in which are embedded the ends of the stereocilia. The otolith membrane of the utricle and saccule has, embedded in its distal part, cylindrical crystals of calcium carbonate, variably known as otoconia, otoliths or statoliths. The mass of the otoliths make the otolith membrane sensitive to linear acceleration movements, including gravity, in the planes of the maculae. The inertia of the otoconial membrane in relation to the membranous labyrinth results in movement of the membrane and deflection of the stereocilia. The cupola in the ampullae of the semicircular canals does not contain otoliths and does not respond to gravity but is responsive to the angular acceleration caused by movement of endolymph in the semicircular canals. Angular acceleration, as in rotation movements of the head, cause the cupola to lag behind the fluid in the semicircular canal. The movements thus caused, deflects the stereocilia resulting in depolarization or hyperpolarisation depending on the direction of the angular movement.

### **Molecular Structure of the Mechanoreceptors**

The stereocilia are the effective mechanoreceptors, having on their plasma membrane mechanically gated Na<sup>+</sup> and K<sup>+</sup> channels that cause an action potential when the stereocilia are deflected. The tips of the stereocilia are connected together by tip links, a series of micro filaments that connect the tips of stereocilia from the tallest to the shortest and to corresponding ion channels, and are thus instrumental in operating the gating mechanism.<sup>1,2</sup> Each tip-link acts as a sort of rope opening the lid of an ionic channel when the stereocilia are deflected.

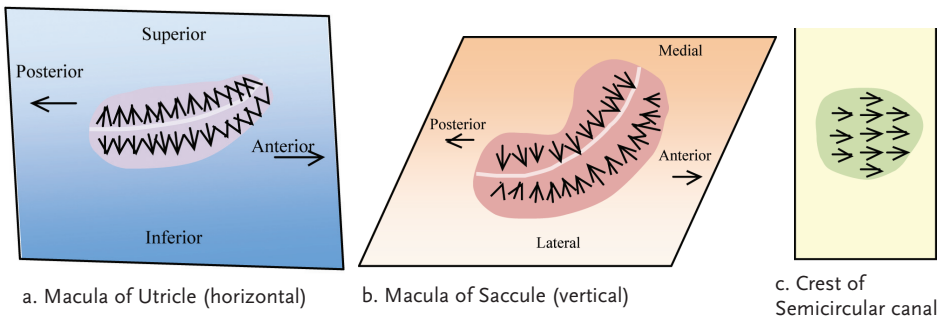
Evidence derived from the Usher syndrome that involves sensorineural hearing loss, vestibular dysfunction and visual impairment, as well as other inherited types of hearing loss, have brought to light various molecules involved in the tip-link structure and the mechanically-gated ionic mechanisms. Five molecules have been identified. The filamentous tip-link consists of two Ca<sup>2+</sup>-dependent cell adhesion molecules, namely hair cell-specific cadherin 23<sup>3</sup> and protocadherin 15 that localize to the upper and lower parts of the tip-links respectively.<sup>4</sup> Both these molecules belong to the large family of Cadherins or Ca<sup>2+</sup> ion dependent cell adhesion molecules that bind cells together. Cadherin 23 has been shown to form a complex with harmonin,<sup>5</sup> a protein that includes a PDZ domain that helps to anchor transmembrane proteins to the cytoskeleton of the stereocilia.<sup>6</sup> Harmonin binds with myosin VIIa, an unconventional myosin found in neurosensory receptors, that interacts with actin filaments in the core of the stereocilia.<sup>7</sup> MAGI-1, (a membrane-associated guanylate kinase-1), also has a PDZ domain and can bind to cadherin 23 and perform a function similar to that of harmonin.<sup>8</sup> These molecules form a chain, including actin in the cytoskeleton of stereocilia, myosin

VIIa, harmonin, MAG-1, Cadherin 23, and protocadherin 15 that are linked in tandem to form the mechanical link between the cytoskeleton of one stereocilium to that of the following, shorter, stereocilium.

However, how these molecules that link up to the mechanically gated channels is still poorly understood.

### Orientation of the Receptors in the Utricle and Sacculle

Apart from their extremely high directional sensitivity as determined by their kinocilium, the receptors in the maculae of the utricle and sacculle are sensitive to all possible positions of the head by virtue of their precise orientation in the skull and in relation to the position of the head in the erect position with the head and eyes facing forwards.



**Figure 2** - (a) and (b) show the orientation of the maculae of utricle and sacculle respectively relative to the vertical and horizontal planes. The striola is indicated as a pale line. The arrows indicate the directions of deflection of the stereocilia that cause depolarization. (c) The crest of a semicircular canal has no striola and all receptor stereocilia are oriented in one direction.

Each macula is traversed by the striola, a narrow crescentic line where the number of receptors and of the overlying otoconia are less than those in the rest of the macula. It divides the macula into two parts. The striola also corresponds approximately, but not perfectly, to the line of polarity reversal (LPR).<sup>9</sup> The kinocilia and receptor stereocilia are anatomically and functionally polarized in relation to the striola (figure 2) so that the kinocilia on either side of this line are facing the striola, and the directions of deflection of the stereocilia that causes depolarization also face this line. Thus, linear acceleration in one direction will cause depolarization of the receptors on one side of the striola and hyperpolarization of the receptors on the other side.

The macula of the utricle is parallel to the base of the skull, while that of the sacculle is in a vertical plane in the direction of the axis of the petrous temporal bone. By virtue of this arrangement the utricular macula is responsive to linear movements in any direction in the horizontal plane while the macula of the sacculle is responsive to antero-posterior head and lateral head tilt and

head tilt in any direction between these. The maculae occupy very small areas of the membranous labyrinth, having a mean area of  $4.30 \text{ mm}^2$  in the human utricle<sup>10</sup> and a mean area of  $2.35 \text{ mm}^2$  in the human saccule.<sup>11</sup>

The macula of the utricle is shaped like a boomerang with one end situated anteriorly, its convex border directed laterally, and a striola that follows a smooth, curved line in its middle. Being a curved line it is responsive to linear movement in all directions within the horizontal plane and to head tilt in any direction from the horizontal plane.

The macula of the saccule is a more elongated oval area that is situated mainly in the vertical plane on the lateral wall of the membranous labyrinth with its long axis directed antero-posteriorly and its striola follows a gentle curve along the antero-posterior axis. It is thus highly sensitive to linear acceleration in the vertical plane and the great gravity sensor e.g in an elevator or when falling.

The receptors in the semicircular canals are located in three small areas known as the ampullary crests situated one in each of the ampullae of the semicircular canals. They respond to angular acceleration. The semicircular canals are oriented in three planes at right angle (orthogonal) to one another. The anterior (superior) semicircular canal is in a vertical plane at right angles to the long axis of the petrous temporal bone. It raises an elevation visible on the superior surface of the petrous temporal bone. The posterior semicircular canal is also in a vertical plane but is situated approximately along the long axis of the petrous temporal bone. Both the anterior and the posterior semicircular canals arise from a common limb that opens on the medial part of the utricle. The lateral ends of these semicircular canals each have a dilated ampulla that opens into the lateral part of the utricle, and is traversed by a corresponding ampullary crest. The lateral semicircular canal is situated in a horizontal plane. Its ampulla opens into the upper and lateral part of the utricle just below the ampulla of the lateral semicircular canal. Its narrow end opens into the utricle just below the crus commune.

Unlike the maculae, in which the kinocilia are arranged in into two groups with the directions of kinocilia and the directions of depolarization being opposite to one another across the striola, the kinocilia and the directions of depolarization of the receptors of the cristae are all unidirectional. However the orientation of the semicircular canals of opposite sides are oriented in opposite directions to one another. The anterior semicircular canal of one side is parallel to the posterior semicircular canal of the opposite side, while the two lateral semicircular canals are in the same plane. Although one study based on 10 human skulls, and reported in two papers<sup>12,13</sup> had found that the canals are not orthogonal to one another recent evidence based on computerized tomography of the inner ears of 22 human subjects<sup>14</sup> indicates that the three canals are in fact quite closely orthogonal. Three pairs of semicircular canals, one from each side, act in concert with one another, being oriented in parallel planes but in opposite directions to one another. Thus the anterior

semicircular canal of one side and the posterior semicircular canal of the opposite side are parallel to one another, but the directions of their kinocilia and of depolarization are in opposite direction and thus act in unison, complementing one another. The corresponding pair of superior-posterior semicircular canals of the opposite sides is set at right angles to the first pair. Vectors from the two pairs cover all possible directions of angular acceleration in the vertical plane. The two horizontal semicircular canals are both in the same horizontal plane, but the direction of the kinocilia and the direction of deflection that causes depolarization are opposite to one another. Turning of the head toward one side, e.g. towards the right, will result in depolarization of the receptors of the lateral semicircular canal on the right side, and hyperpolarization of the receptors of the opposite side. Between them they cover all possible angular acceleration movements in the horizontal plane.

### Synaptic contacts with receptors

Receptor cells, also known as hair cells, make synaptic contacts with afferent and efferent nerve terminals in the basal two-thirds of the cell. The type and number of these synapses led to the distinction between type I and type II vestibular hair cells, which also show some morphological differences.

Afferent nerve endings are the proximal processes of the bipolar nerve cells in the vestibular ganglion (Scarpa's ganglion) interspersed among bundles of the vestibular nerve. Three types of afferent endings are distinguished. Calyx terminals are large axon terminals that envelope almost completely the lower two-thirds of the receptor cell. Bouton terminals occur in clusters of 15 to 80 fine arborisations. Dimorphic terminals end in both small calyces and boutons, which are highly variable in their relative proportions.

The most characteristic feature of type I receptor cells is that they have a single large calyx enveloping the lower two-thirds of their cell body. They are shaped like a round-bottomed flask, with their upper one third forming a thin narrow neck extending to the apical surface that bears the stereocilia.<sup>15</sup> The distended lower two-thirds is enveloped by the large synaptic calyx, which arises from a thick axon. Simple calyces contact only one receptor cell, while complex calyces contact two or more receptor cells. Type I receptors do not reach the basal lamina of the epithelium. They are concentrated in the region of the striola in the maculae of the utricle and saccule and the central zone of the crista in the ampullae of the semicircular canals.<sup>16,17</sup> Glutamate the main neurotransmitter at the synapses between Type I vestibular hair cell and its calyx.<sup>18-20</sup> Aspartate and glutamate have been localized not only in the vestibular hair cells, but also in the vestibular nerve fibres and vestibular ganglion cells.<sup>21</sup>

Type II hair cells are scattered throughout the extra-striolar parts of the maculae and the peripheral zone of the cristae. They are more cylindrical in shape, variable in their height and have bouton type and dimorphic endings

on their lower two-thirds. Dimorphic endings are the most common accounting for 70% of the endings in the cristae of the semicircular canals<sup>16</sup> and 92% of the endings in the maculae.<sup>17</sup>

Immunohistochemical investigations have shown that the large calyces on type I receptors contain calretinin, a vitamin D-dependent calcium binding protein that is present in some vestibular neurons and at several other extravestibular sites. It appears that calretinin localizes only in the large calyces and the large axons from which they arise, and are absent from bouton and dimorphic axons.<sup>22</sup>

A complicated pattern of synaptic contacts exists on the vestibular hair cells. Ribbon type synapses have been reported between the membranes of the receptor and the calyx, appearing early in development.<sup>23</sup> Ribbon synapses are specialized presynaptic structures anchored to the cytoplasmic surface of the plasma membrane, that have a layer of closely packed synaptic vesicles tethered to them, while huge numbers of other vesicles are present in the vicinity in the hair cell. They are also present in the cochlear hair cells, and in the retinal photoreceptor and bipolar cells, where they have been most extensively studied. They are thought to facilitate the fast release of neurotransmitters through cycles of synaptic exocytosis and endocytosis in response to graded short, phasic rapidly changing stimuli as well as to sustained, tonic stimuli<sup>24</sup>. Synaptic ribbons vary greatly in shape, size and number not only among different species and stages of development but also within a single hair cell at different stages of activity, as for example during weightlessness and during or after space flights.<sup>25</sup> In addition to synapses with afferents, the vestibular hair cells receive efferent nerve terminals from the neurons of the vestibular nuclei, which are cholinergic. They may form axo-dendritic synapses with the calyx surrounding type I hair cells, with other afferent terminals and directly with the cell bodies of type 2 receptors.<sup>26</sup> The efferent bouton terminals contain a variety of lucent vesicles, which are thought to be mainly inhibitory, while some contain scattered dense-cored vesicles in the endings of sympathetic nerves.<sup>27</sup>

### **The Vestibular Nerve and Ganglion**

The afferent fibres that terminate on the hair cells, constitute the majority of axons in the vestibular nerve that arise from the neurons of the vestibular ganglion. These are the first order neurons in the vestibular pathways. The vestibular nerve emerges from the bony labyrinth through two sets of foramina in the vestibular area of the internal auditory meatus, and join to form the vestibular nerve.

Afferent fibres from the lateral and anterior semicircular canals, known as the lateral and anterior ampullary nerves, pass through the superior vestibular area, a number of foramina in the internal auditory meatus. A small bundle of afferents from the utricle, and a small bundle of fibres from the saccule,

known as Voit's nerve, also pass through the superior vestibular area. Collectively the fibres passing through this area form the superior division of the vestibular nerve. The remaining fibres from the vestibular receptors in the saccule, and the posterior semicircular canal collectively form the inferior division of the vestibular nerve which passes through the inferior vestibular area, a number of small foramina in the inferior part of the internal auditory meatus. One of these is the foramen singulare that transmits the nerve from the posterior semicircular canal.

The afferent nerves that terminate on the receptors are the peripheral processes of the bipolar vestibular ganglion cells, commonly known as Scarpa's ganglion.

The ganglion cells are situated within the main vestibular nerve, and its superior and inferior divisions at the internal auditory meatus. The central processes of these ganglion cells enter the brain stem at the ponto-medullary junction, to terminate mainly in the vestibular nuclei, and partly in the vestibular part of the cerebellum. The axons and ganglion cells vary greatly in diameter, the largest ones being those that terminate as the calyces on the type I receptor cells. The smaller axons and bipolar cells are the ones that give rise to the afferent bouton and dimorphic endings on the type II receptors.

### **The Vestibular Nuclei**

The second neurons on the vestibular pathway constitute the vestibular nuclei, a collection of four nuclei situated in the floor of the lateral recess of the fourth ventricle. They are the superior, inferior, medial and lateral nuclei that occupy approximately the positions indicated by their names. The superior vestibular nucleus is located entirely within the pons, while the other three nuclei lie partly in the pons and partly in the medulla. There are also a few small accessory vestibular nuclei including the Y-group, the parasolitary nucleus, and the nucleus intercalatus. The connections of the vestibular nuclei are many and complex, and have been extensively reviewed by Barmack.<sup>28</sup> For the purpose of the present general review only a few salient points are given about the main connections of the individual vestibular nuclei, and their connections are summarized below as functional connections and pathways.

The superior and medial vestibular nuclei receive afferents from the primary vestibular nerves supplying the cristae ampullares of semicircular canals, whereas the lateral vestibular nucleus receives mainly primary afferents from the utricle and saccule and the inferior nucleus receives primary afferents from the semicircular canals and the utricle.<sup>29</sup>

However, these distinctions are not clear cut, and there is evidence of extensive interconnections among the vestibular nuclei of the same side and contralaterally.<sup>28,30,31</sup>

On entering the vestibular area, primary afferent fibres of the vestibular nerve bifurcate within the lateral vestibular nucleus into ascending and descending branches, and gives direct branches to the lateral vestibular nucleus. The ascending branches reach the superior vestibular nucleus, where they give off collaterals and form terminal boutons or en passant synapses, while the main axons proceed directly to the cerebellum without synapsing. The descending branch gives terminal boutons in approximately equal proportions to the neurons of the medial and inferior vestibular nuclei.<sup>32</sup>

The main projections of the superior vestibular nucleus are to the motor nuclei of the ocular muscles via the medial longitudinal fasciculus, direct connections with the flocculo nodular lobe of the cerebellum and accessory mid-brain nuclei and reciprocal and bilateral connections with the medial and inferior vestibular nuclei of the same and opposite sides.<sup>33</sup>

The lateral vestibular (Deiter's) nucleus is distinctive because it contains large (Deiter's) neurons, as well as small neurons,<sup>34</sup> and gives origin to the prominent lateral and medial vestibulo-spinal tracts to the spinal cord mediating vestibulo-spinal reflexes.

### **Functional Connections of the Central Vestibular System**

The vestibular nuclei have four main connections. Many of them are reciprocal connections, giving efferents to and receiving afferents from the nuclei to which they connect.

#### *1. Connections with the Ocular muscles.*

One pathway connects the vestibular nuclei to the motor nuclei of the oculomotor, trochlear and abducent nerves, via the medial longitudinal fasciculus. It mediates the important vestibulo-ocular reflex through which it exerts control over involuntary eye movements that are triggered by movements of the head. Apart from the motor nuclei of the III, IV and VI cranial nerves, accessory nuclei are also involved in this pathway and the control of eye movement. These include the interstitial nucleus of Cajal in the midbrain, an important centre for eliciting vertical and rotatory eye movements, the nucleus of Darkshewitsch, situated in the central gray matter ventral to the oculomotor nuclei and having connections with the medial longitudinal fasciculus and the nucleus prepositus hypoglossi in the medulla<sup>35</sup>. The main output to these nuclei is from the superior vestibular nucleus via the medial longitudinal fasciculus but the medial vestibular nucleus also contributes. There is predominant bilateral representation from the medial vestibular nucleus and unilateral representation from the superior vestibular nucleus, the latter being largely inhibitory.<sup>35</sup>



## 2. *Connections with the Postural Back muscles.*

The second pathway connects the vestibular system to the muscles of the neck and back via the lateral and medial vestibulo-spinal tracts thus contributing to the control of posture and adjusting reflexes of the body in response to changes in position and movement. Both these pathways arise from the large cells of the lateral vestibular nucleus. The lateral vestibulo-spinal tract descends the whole length of the spinal cord and is stimulatory to the anterior horn cells supplying the back muscles in the cervical, thoracic and lumbosacral regions through monosynaptic and polysynaptic connections.

## 3. *Cerebellar Connections.*

The third pathway is to the vestibular cerebellum, which is also known as the archicerebellum, the evolutionarily oldest part of the cerebellum, originally a neural cortex for integration of the vestibular input to the body movement. In higher organisms it comprises the flocculo-nodular lobe, consisting of the flocculus, nodulus and part of the uvula of the cerebellar vermis. The vestibulocerebellum regulates body balance and posture, and connects to the ocular motor neurons. It has reciprocal connections with both the maculae of the utricle and saccule, and the cristae of the semicircular canals. Most of the axons pass uninterruptedly through the superior vestibular nucleus without synapsing. They terminate in the granule layer of the nodule, uvula and the ventral part of the anterior lobe of the cerebellum as mossy fibres that form the centres of the cerebellar glomeruli. Here they form complex synapses with the dendrites of the granule cells, the Golgi type II cells, the basket cells and the stellate cells of the cerebellum. The connections of the primary vestibulo-cerebellar afferents are mainly ipsilateral.

Secondary vestibulo-cerebellar afferents that have synapsed in the superior, medial or inferior vestibular nuclei, also form mossy fibres, but these terminate bilaterally on the flocculus as well as the nodulus and uvula.

The nucleus fastigii is the main vestibular outflow from the vestibular cerebellum. It sends crossed efferent connections mainly to the lateral vestibular nucleus, and bilateral efferents to the superior, medial and inferior nuclei.

The vestibular efferents also connect through the nucleus fastigii with the oculomotor nuclei thus contributing to the regulation of compensatory eye movements through the vestibulo-ocular pathway. They also make connections with the reticular formation and midbrain nuclei, the Fields of Forel, situated in the subthalamus ventral to the red nucleus (and conveying information from the globus pallidus to the cerebellum and thalamus, thus exerting control over posture and movement.

## 4. *Connections with higher centres.*

The fourth pathway constitutes the ascending pathways to the thalamus and cerebral cortex, through which there is conscious perception of changes in

posture and movements, and the mediation of appropriate adjustments of voluntary actions. The location of a human vestibular cortex has been disputed and most evidence for its localization has been derived from primate experiments on stimulation of cortical areas. The vestibular cortical regions identified in primates have been indicated as vestibular area 2v situated at the base of the intraparietal sulcus just posterior to the hand and mouth region of the postcentral gyrus, area 3av in the dorsolateral part of the somatosensory area near the neck and trunk region,<sup>36</sup> Brodmann area 7, in the parietal cortex between the somatosensory and visual association areas and thought to mediate visual-motor coordination, and the parieto-insular vestibular cortex (PIVC) in the upper lip of the lateral sulcus near the posterior end of the insula. Tracer studies also demonstrated reciprocal connections between the posterior parietal cortex area 7 with three thalamic nuclei, the nucleus ventralis posterior inferior, the magnocellular part of the medial geniculate nucleus, and some intralaminar nuclei.<sup>37</sup> Data from Positron emission tomography and recordings of evoked potentials using brain electrical source imaging in humans are consistent with the findings in primates.<sup>38</sup>

## References

1. Pickles JO, Brix J, Comis SDet al. The organization of tip links and stereocilia on hair cells of bird and lizard basilar papillae. *Hear Res* 1989;41:31-41.
2. Tsuprun V, Goodyear RJ, Richardson GP. The Structure of Tip Links and Kinocilial Links in Avian Sensory Hair Bundles. *Biophys J* 2004;87:4106-4112.
3. Di Palma F, Holme R H, Bryda E C, Belyantseva I A, Pellegrino R, Kachar B, Steel K P, Noben-, K. T. Mutations in *Cdh23*, encoding a new type of cadherin, cause stereocilia disorganization in waltzer, the mouse model for Usher syndrome type 1D. *Nature Genet* 2001;27:103-107.
4. Kazmierczak P, Sakaguchi H, Tokita Jet al. Cadherin 23 and protocadherin 15 interact to form tip-link filaments in sensory hair cells. *Nature* 2007;449:87-91.
5. Siemens J, Kazmierczak P, Reynolds A, Sticker M, Littlewood-Evans A, Mueller U. The Usher syndrome proteins cadherin 23 and harmonin form a complex by means of PDZ-domain interactions. *Proc Nat Acad Sci* 2002;99:14946-14951.
6. Ranganathan R, Ross E. PDZ domain proteins: scaffolds for signaling complexes. *Curr Biol* 1997;12:770-773.
7. Boëda B, El-Amraoui A, Bahloul Aet al. Myosin VIIa, harmonin and cadherin 23, three Usher I gene products that cooperate to shape the sensory hair cell bundle. *EMBO Journal* 2002;21:6689-6699.
8. Xu Z, Peng AW, Oshima K, Heller S. MAGI-1, A Candidate Stereociliary Scaffolding Protein, Associates with the Tip-Link Component Cadherin. *J Neurosci* 2008;28:11269-11276.
9. Li A, Xue J, Peterson EH. Architecture of the Mouse Utricle: Macular Organization and Hair Bundle Heights. *J Neurophysiol* 2008;99:718-733.

10. Tribukait A, Rosenhall U. Directional Sensitivity of the Human Macula utriculi Based on Morphological Characteristics. *Audiol Neurootol* 2001;6:98-107.
11. Tribukait A, Rosenhall U, Österdahl B. Morphological Characteristics of the Human Macula saccule. *Audiol Neurootol* 2005;10:90-96.
12. Blanks RH, Curthoys IS, Markham CH. Planar relationships of the semicircular canals in man. *Acta Otolaryngol* 1975;80:185-196.
13. Curthoys IS, Blanks RHI, Markham CH. Semicircular canal functional anatomy in cat, guinea pig and man. *Acta Otolaryngol* 1977;83:258-265.
14. Della Santina CC, Potyagaylo V, Migliaccio AA, Minor LB, Carey JP. Orientation of Human Semicircular Canals Measured by Three-Dimensional Multiplanar CT Reconstruction. *J Assoc Res Otolaryngol* 2005;6:191-206.
15. Ricci AJ, Cochran SL, Rennie KJ, Correia MJ. Vestibular type I and type II hair cells. 2: Morphometric comparisons of dissociated pigeon hair cells. *J Vest Res* 1997;7:407-420.
16. Fernández C, Baird RA, Goldberg JM. The vestibular nerve of the chinchilla. Peripheral innervation patterns in the horizontal and superior semicircular canals. *J Neurophysiol* 1988;60:167-181.
17. Fernández C, Goldberg JM, Baird RA. The vestibular nerve of the chinchilla. III. Peripheral innervation patterns in the utricular macula. *J Neurophysiol* 1990;63:767-780.
18. Devau G, Lehouelleur J, Sans A. Glutamate receptors on type I vestibular hair cells of guineapig. *Eur J Neurosci* 1993;5:1210-1217.
19. Prigioni I, Russo G. Glutamate excitatory effects on ampullar receptors of the frog. *Amino Acids* 1995;9:265-273.
20. Bonsacquet J, Brugeaud A, Compan V, Desmadryl G, Chabbert C. AMPA type glutamate receptor mediates neurotransmission at turtle vestibular calyx synapse. *J Physiol* 2006; 576:63-71.
21. Harper A, Blythe WR, Grossman G, Petrusz P, Prazma J, Pillsbury HC. Immunocytochemical localization of aspartate and glutamate in the peripheral vestibular system. *Hear Res* 1995;86:171-182.
22. Desmadryl G, Dechesne CJ. Calretinin immunoreactivity in chinchilla and guinea pig vestibular end organs characterizes the calyx unit subpopulation. *Exp Brain Res* 1992;89:105-108.
23. Morales MM, Serrano EE. Synaptic ribbon formation during *Xenopus* inner ear organogenesis. *Dev Biol* 2006;295:457.
24. Nouvian R, Beutner D, Parsons TD, Moser T. Structure and Function of the Hair Cell Ribbon Synapse. *J Membr Biol* 2006;209:153-165.
25. Ross MD, Varelas J. Synaptic ribbon plasticity, ribbon size and potential regulatory mechanisms in utricular and saccular maculae. *J Vest Res* 2005;15:17-30.
26. Weijia K, Egg G, Hussl B, Schrott-Fischer A. Innervation of cholinergic vestibular efferent system in vestibular periphery of rats. *J Huazhong Univ Sci Technolog Med Sci* 1997;17:57-60.
27. Holstein G, Martinelli G, Boyle R, Rabbitt R, Highstein S. Ultrastructural observations of efferent terminals in the crista Ampullaris of the toadfish, *Opsanus tau*. *Exp Brain Res* 2004;155:265-227.
28. Barmack NH. Central vestibular system: vestibular nuclei and posterior cerebellum. *Brain Res Bull* 2003;60:511-541.

29. Patestas MA, Gartner LP. *A textbook of Neuroanatomy*. Blackwell Publishing, 2006:326.
30. Bacsikai T, Szekely G, Matesz C. Ascending and descending projections of the lateral vestibular nucleus in the rat. *Acta Biol Hung* 2002;53: 7-21.
31. Matesz C, Bácskai T, Nagy É, Halasi G, Kulik Á. Efferent connections of the vestibular nuclei in the rat: a neuromorphological study using PHA-L. *Brain Res Bull* 2002;57:313-315.
32. Sato F, Sasaki H, Ishizuka N, Sasaki S, Mannen H. Morphology of single primary vestibular afferents originating from the horizontal semicircular canal in the cat. *J Comp Neurol* 1990;290:423-439.
33. Carpenter MB, Cowie RJ. Connections and oculomotor projections of the superior vestibular nucleus and cell group 'y'. *Brain Res* 1985;336:265-287.
34. Suarez C, Diaz C, Tolivia J, Alvarez JC, Gonzalez del Rey C, Navarro A. Morphometric analysis of the human vestibular nuclei. *Anat Rec* 1997;247:271-288.
35. Wentzel PR, De Zeeuw CI, Holstege JC, Gerrits NM. Inhibitory synaptic inputs to the oculomotor nucleus from vestibulo-ocular-reflex-related nuclei in the rabbit. *Neuroscience* 1995;65:161-174.
36. Akbarian S, Grušser OJ, Guldin WO. Corticofugal connections between the cerebral cortex and brainstem vestibular nuclei in the macaque monkey. *J Comp Neurol* 1994;339:421-437.
37. Faugier-Grimaud S, Ventre J. Anatomic connections of inferior parietal cortex (area 7) with subcortical structures related to vestibulo-ocular function in a monkey (macaca fascicularis). *J Comp Neurol* 2004;280:1-14.
38. de Waele C, Baudonnière PM, Lepecq JC, Tran Ba Huy P, Vidal PP. Vestibular projections in the human cortex. *Exp Brain Res* 2001;141:541-551.

*Corresponding author:*

**Prof. Alfred Cuschieri**

Department of Anatomy

University of Malta

Msida, Malta

e-mail: [alfred.cuschieri@um.edu.mt](mailto:alfred.cuschieri@um.edu.mt)

# AUTOIMMUNE INNER EAR DISEASE



**Simon A. McKean and Musheer Hussain**

University Department of Otolaryngology  
Ninewells Hospital & Tayside Children's Hospital  
University of Dundee Medical School  
Dundee, Scotland, UK

*This paper was presented to the ENT Masterclass 2009*

## Abstract

Autoimmune Inner Ear Disease (AIED) is a rare disease that accounts for less than 1% of hearing loss or dizziness. Clinical course is of progressive, fluctuating, bilateral sensorineural hearing loss (SNHL) over a matter of weeks to months. Other symptoms may include vestibular effects (i.e. imbalance, ataxia and vertigo), tinnitus, and aural fullness. It is most common in females in their 3<sup>rd</sup> to 6<sup>th</sup> decade. Systemic autoimmune diseases coexist in 15-30% of patients. There is no specific test for diagnosis of AIED, but importantly, prompt treatment with steroids may reverse the hearing loss. Therefore, the diagnosis is made based on clinical criteria and response to steroids.

*Keywords:* Autoimmune, cochlear, vestibular, hearing loss.

## Introduction

AIED is a rare disease that accounts for less than 1% of hearing loss or dizziness. McCabe first described rapidly progressive, bilateral sensorineural hearing loss that improved with steroid treatment in 1979<sup>1</sup>. It is most common in females in their 3<sup>rd</sup> to 6<sup>th</sup> decade. Systemic autoimmune diseases coexist in 15-30% of patients and these patients may have a poorer prognosis.

## Clinical Features

The clinical course of AIED is a rapidly progressive, often fluctuating, frequently bilateral, sensorineural hearing loss over a period of weeks to months. This progression is too slow to be a sudden sensorineural hearing loss (within 72 hours) and too quick to be presbycusis (related to ageing). Up to 50% of patients thought to have AIED initially present with vestibular symptoms,<sup>2</sup> including imbalance, ataxia, true vertigo, or motion intolerance. Other symptoms can include tinnitus and aural fullness.

## Background

There are many hundreds of reported autoantibodies, broadly divided into organ-specific and organ-non-specific. Autoantibodies are either directly involved with the pathological process (primary antibodies) or are markers for the disease process (secondary antibodies). There are multiple techniques for testing, and comparison between different assays is difficult. There is often no “gold standard” and results may vary between different laboratories. Western Blot analysis, lymphocyte migration assay and indirect immuno-fluorescence, are the most common techniques for antibody detection.

AIED implies antibodies to an inner ear antigen. Viral infection, trauma and vascular damage may be triggers for AIED. Perhaps antibodies or T-cells cause accidental inner ear damage because inner ear tissue (possibly type II collagen in particular), shares common antigens with potentially harmful substances. The normal cochlea does not contain lymphocytes. The hypothesis that the endolymphatic sac is the key organ in the immune response of the inner ear was proposed in 1974.<sup>3</sup> Macrophages, B cells and T cells have been demonstrated in the endolymphatic sac and the peri-sacculus tissues<sup>iv</sup>, but it is not clear whether these are produced locally or are recruited from the systemic circulation.<sup>5</sup> Obliteration of the endolymphatic sac has been shown to reduce immune responses in the cochlea.<sup>6</sup> Immune mediated or autoimmune pathology of the endolymphatic sac may lead to endolymphatic hydrops.

## Differential diagnoses

Although there are many possible causes of a sensorineural hearing loss, many patients do not have a clear aetiology (i.e. idiopathic).

**Table 1** – Possible identifiable causes of sensorineural hearing loss<sup>7</sup>

|             |  |
|-------------|--|
| Autoimmune  | See Table 2  |
| Infectious  | Meningococcal meningitis, encephalitis, herpes virus, measles, mumps, rubella, HIV, syphilis, Lyme disease, toxoplasmosis    |
| Traumatic   | Temporal bone fracture, barotrauma, perilymph fistula, excess noise exposure, decompression sickness, surgery                |
| Neoplastic  | Acoustic schwannoma, meningioma, leukaemia, myeloma  |
| Toxic       | Aminoglycoside antibiotics, salicylates, loop diuretics, NSAIDs, platinum based chemotherapeutic agents, general anaesthesia |
| Circulatory | Micro-vascular disease, vertebrobasilar insufficiency, sickle cell disease, cardiopulmonary bypass                           |
| Neurologic  | Multiple sclerosis, migraine, focal point ischaemia  |
| Metabolic   | Thyrotoxicosis, hyperlipidaemia, diabetes  |
| Other       | Meniere's disease  |

**Table 2** - Autoimmune diseases

|  |   |
|--|---|
| Non-organ specific autoimmune diseases | Wegener's granulomatosis<br>Rheumatoid arthritis<br>Polyarteritis nodosa<br>Systemic Lupus Erythematosus<br>Cogan's syndrome<br>Sjorgen's<br>Relapsing polychondritis<br>Ulcerative colitis<br>Antiphospholipid syndrome<br>Sarcoidosis |
| Ear-specific autoimmune disease        | Autoimmune Inner Ear Disease  |

### Investigations

The pathophysiology of AIED is not well understood but the suggestion is that there are antibodies to an inner ear antigen. This hypothesis has stimulated research into organ-specific autoimmunity with the initial focus on the 68kD protein (previously thought to be heat shock protein-70).<sup>8</sup> However, this is now regarded as incorrect, not specific, not sensitive and unhelpful in diagnosis of AIED.<sup>9,10,11</sup>

A battery of non-specific antigen-screening tests may however, be useful as evidence of systemic autoimmune dysfunction, but this may not correlate with AIED.<sup>12</sup> Immunological laboratory tests suggested include; antinuclear, antineutrophil, cytoplasmic, antiendothelial cell, antiphospholipid/anticardiolipin, and antithyroid antibodies.<sup>13</sup> The more selective tests of ANA levels<sup>14</sup> and/or immuno-phenotype of peripheral blood lymphocytes<sup>15</sup> may be as helpful and far cheaper. The prognostic value of these tests is not clear and although they may help with diagnosis, it is likely that treatment will have been instigated before the results are available. There is no clear relation between these tests and steroid responsiveness.

### Treatment

The current therapy is empirically based on the fact that steroids improve hearing in about 60% of patients thought to have AIED. Immunosuppressive therapy, usually in the form of oral corticosteroids, is suggested. A 1 mg/kg course of daily Prednisolone, for a month, which is then slowly reduced to a maintenance dose, may be appropriate.

If there are adverse effects from the steroids or the hearing loss continues despite steroid use, then cytotoxic medications might be indicated. These

drugs, such as cyclophosphamide<sup>16</sup> and methotrexate<sup>17</sup> have less clear benefits with significant toxicity and side effects. Transtympanic injections of chemotherapy have also been suggested.

A small study showed improvement in hearing and the ability to discontinue immunosuppressive medication after plasmapheresis.<sup>18</sup> Plasmapheresis removes antibody, antigen, immune complexes and mediators from the blood by extracorporeal filtration.

Cochlear implants may be of benefit in the long term.

Genetic factors are thought to influence susceptibility to hearing disorders. However, there is conflicting evidence as to the precise location of these genetic differences. In the future there may be scope for cell<sup>19</sup> or gene<sup>20</sup> therapy to treat the inner ear cell damage.

## Conclusions

There is no specific test for diagnosis of AIED, but importantly, prompt treatment with steroids may reverse the hearing loss. Therefore, the diagnosis is made based on clinical criteria and response to steroids.

## References

1. McCabe BF. Autoimmune sensorineural hearing loss. *Annals of Otolaryngology, Rhinology and Laryngology*. 1979; **88**: 585-9
2. Rauch SD. Clinical management of immune-mediated inner ear disease. *Annals of the New York Academy of Sciences*. 1997; **830**: 203-10
3. Lim D, Silver P. The endolymphatic duct system. A light and electron microscopic investigation. *Barany Society Meeting, Los Angeles*; 1974. p.390
4. Rask-Andersen H, Stahle J. Immunodefence of the inner ear lymphocyte-macrophage interaction in the endolymphatic sac. *Acta Otolaryngol* 1980; **89**: 283-94
5. Harris J. Immunology of the inner ear: evidence of local antibody production. *Ann Otol Rhinol Laryngol* 1984; **93**: 157-62
6. Tomiyama S, Harris J. The role of the endolymphatic sac in inner ear immunity. *Acta Otolaryngol*. 1987; **103**: 182-8
7. Rennie C, Selvadurai D. Sudden sensorineural hearing loss – aetiology and management. *Journal of ENT Masterclass*. 2008; **1**: 45-50
8. Moscicki RA, San Martin JE, Quintero CH et al. Serum antibody to inner ear proteins with progressive hearing loss. Correlation with disease activity and response to corticosteroid treatment. *JAMA*. 1994; **272**: 611-6
9. Gottschlich S, Billings PB, Keithley EM et al. Assessment of serum antibodies in patients with rapidly progressive sensorineural hearing loss and Meniere's disease. *Laryngoscope* 1995; **105**: 1347-52



10. Yeom K, Gray J, Nair TS et al. Antibodies to HSP-70 in normal donors and autoimmune hearing loss patients. *Laryngoscope* 2003; **113**: 1770-6
11. Garcia-Berrocal JR, Ramirez-Camacho R, Vargas JA, Millan I. Does the serological testing really play a role in the diagnosis of immune-mediated inner ear disease? *Oto-Laryngologica* 2002; **122**: 243-8
12. Bovo R, Clorba A, Martini A. The diagnosis of autoimmune inner ear disease: evidence and critical pitfalls. *Eur Arch Otorhinolaryngol* 2009; **266**: 37-40
13. Agrup C, Luxon LM. Immune-mediated inner ear disorders in neuro-otology. *Curr Opin Neurol*. 2006; **19 (1)**: 26-32
14. Dayal VS, Ellman M, Sweiss N. Autoimmune inner ear disease: clinical and laboratory findings and treatment outcome. *J Otolaryngol Head Neck Surg*. 2008; **37 (4)**: 591-6
15. Garcia-Berrocal JR, Trinidad A, Ramirez-Camacho R et al. Immunologic work-up study for inner ear disorders: looking for a rational strategy. *Acta Otolaryngol*. 2005; **125 (8)**: 814-8
16. McCabe BF. Autoimmune inner ear disease: therapy. *Am J Otol*. 1989; **10 (3)**: 196-7.
17. Harris JP, Weisman MH, Derebery JM et al. Treatment of corticosteroid-responsive autoimmune inner ear disease with methotrexate: a randomized controlled trial. *JAMA*. 2003; **290(14)**: 1875-83
18. Luetje CM. Theoretical and practical implications for plasmapheresis in autoimmune inner ear disease. *Laryngoscope*. 1989; **99(11)**: 1137-46
19. Nakagawa T, Ito J. Application of cell therapy to inner ear disease. *Acta Otolaryngol Supplement*. 2004; **(551)**: 6-9
20. Pau H, Clarke RW. Advances in genetic manipulations in the treatment of hearing disorders. *Clin Otolaryngol & Al Sci*. 2004; **29**: 574-6

*Corresponding author:*

**Mr. S.S. Musheer Hussain**

University Department of Otolaryngology

University of Dundee

Dundee, Scotland, UK

e-mail: musheer.hussain@nhs.net



# DIAGNOSIS AND MANAGEMENT OF PSYCHOGENIC VERTIGO AND PSYCHIATRIC ASSOCIATED DIZZINESS



UNIVERSIDADE DE COIMBRA

João Carlos Ribeiro, Rui Cerejeira, José Romão, António Paiva  
Department of ORL  
University of Coimbra Medical School  
Coimbra, Portugal

## Abstract

Vertigo is an illusionary sensation of movement, which is frequently accompanied by great discomfort and distressing vegetative reactions. Dizziness caused by vestibular dysfunction involves psychological reactions. These reactions can vary considerably depending on whether or not psychiatric patients are involved. Vertigo may also be a symptom of a psychiatric disorder with no objective symptoms of a disorder of the vestibular system or of other neurological pathologies. This dichotomy in which psychological issues are the cause or the consequence of dizziness represents a possible incomplete view of the disorder, leading to sub-optimal care.

Typically, otoneurologic disorders and psychiatric disorders coexist and interact, probably as a result of central-neurologic links between the vestibular and the autonomic systems.

*Keywords:* Vertigo, psychogenic vertigo, psychiatric dizziness, inner ear.

## Introduction

Vertigo is an illusionary sensation of movement, which is frequently accompanied by great discomfort and distressing vegetative reactions.

It is a common symptom that often remains unexplained despite extensive medical evaluation. Psychiatric and psychosomatic disorders are usually considered after all somatic causes of vertigo have been ruled out. In up to 50% of all dizziness states, psychiatric disorders appear to exert an important influence on the course of the illness.<sup>1</sup>

As a symptom, vertigo characterizes several organic diseases of the peripheral and central vestibular systems. As a subjective complaint, it may be an integral part of several psychiatric syndromes, including anxiety, somatoform and depressive disorders. The anxiety disorders are the most relevant in patients with psychiatric dizziness.<sup>2</sup>

Dizziness caused by vestibular dysfunction involves psychological reactions.<sup>3</sup> These reactions can vary considerably depending on whether or not psychiatric patients are involved. Vertigo may also be a symptom of a psychiatric disorder with no objective symptoms of a disorder of the vestibular system or of other neurological pathologies. This dichotomy in which psychological issues are the cause or the consequence of dizziness represents a possible incomplete view of the disorder, leading to sub-optimal care. Typically, otoneurologic disorders and psychiatric disorders coexist and interact, probably as a result of central-neurologic links between the vestibular and the autonomic systems.<sup>4,5</sup>

## Discussion

It is a well-known clinical fact that vestibular dysfunction in some predisposed persons may induce psychiatric syndromes. Several psychiatric disorders have been most frequently described in patients with dizziness illnesses: anxiety disorders, depressive, and somatoform disorders. Besides that, vertigo is accompanied by depression, dysthymia, and significant impact in the quality of life.<sup>6</sup> The most prevalent are panic and depressive disorders.<sup>7</sup> Dizziness is often situation specific. Vestibular disease therefore favors avoidance responses in some situations, and these responses are sometimes confused with psychogenic vertigo. The mismatch between vestibular, visual and proprioceptive sensorial inputs can lead to dizziness even in healthy individuals (physiological vertigo). In vestibular disorders, the patient can develop unusual sensitivity to some stimuli or inadequate balance strategies.<sup>8</sup> Space and motion sensitivity is a finely tuned awareness of non-vestibular sensation, interfering with life relation activities and lead to psychological adjustments.

A vestibular disorder may develop reactive psychic disorders or not. In the majority of patients it is not induced by an organic vestibular disorder. The extent to which dizziness becomes a chronic clinical problem depends mainly on the patient's psychological reactions to symptoms, particularly affecting those having a delayed vestibular compensation following a vestibular lesion.<sup>9</sup>

Agoraphobia is defined as anxiety about being in places or situations in which escape might be difficult or help might not be available in the event of a panic attack or panic-like symptoms.<sup>10</sup> Most people with panic disorder develop at least some degree of agoraphobia.<sup>11</sup>

In extreme cases, an individual with panic disorder and agoraphobia may be completely unable to leave the house. More typically, people with agoraphobia experience some restrictions in what they are able to do but they are able to leave the house, especially if they are accompanied by someone they know. Agoraphobia may be both explained by panic disorders and as a functional dizziness. It may be a reaction to dizziness rather than a cause, a reasonable

adaptation to conditions that affect balance in an unpredictable way: open places have neither surfaces that can be used for support nor close visual references. The feeling of dizziness and subjective postural imbalance associated with anxiety felt in wide open spaces and public places may be initiated by the physiological impairment of visual control over body sway linked to the distance to stationary objects in the seen environment.<sup>11</sup>

Acrophobia results when physiological height vertigo induces a conditioned phobic reaction characterized by dissociation between the objective and the subjective risk of falling. It is likely to occur as a post-traumatic neurotic reaction, sometimes initiated by a traumatic lesion of the otoliths. It is seen as functional vertigo.

Phobic postural vertigo syndrome (table 1) is characterized by a combination of situational triggered panic attacks including vertigo. Patients complain of vertigo rather than anxiety and feel physically ill. An impairment of the space constancy mechanism leads to partial uncoupling of the efferent copy for active head movements which triggers phobic attacks. It is the third most common cause of vertigo in otoneurology consultations.<sup>12,13</sup>

**Table 1** - Phobic postural vertigo syndrome diagnostic criteria<sup>12</sup>

| <b>Phobic postural vertigo syndrome</b>  |
|--|
| Dizziness is experienced while upright and during gait, despite normal clinical balance and routine otoneurologic tests.   |
| Patients describe non rotational dizziness, with fluctuating unsteadiness, and postural and gait instability, often in the form of attacks (seconds to minutes), or the perception of transient illusory body perturbations for, at most, seconds. |
| Attacks occur spontaneously or with specific perceptual stimuli or social situations (ex, bridges, staircases, empty rooms, store aisles, streets, meetings, or when driving a car).   |
| Anxiety and distressing vegetative symptoms often (but not always) accompany the attacks of dizziness, and there is a tendency for generalization and dependent or avoidance behavior to develop.  |
| Patients often have psychiatric co morbidities, including obsessive-compulsive type personalities, hypochondriasis, generalized anxiety disorders, panic disorder with or without agoraphobia, and (reactive) depression.                          |
| Onset typically occurs following an illness (usually a vestibular disorder that has subsequently resolved) or an important psychosocial stress or conflict.  |

Panic attacks are by nature episodic and consist of a myriad of physical symptoms, among which may include dizziness, lightheadedness, unsteadiness, and faintness.<sup>7</sup>

In some cases, dizziness, lightheadedness, faintness, diaphoresis, paresthe-

sias, dyspnea or “smothering” sensation, and fear of dying may be components of a hyperventilation attack.<sup>8</sup>

Psychosomatic mechanisms involve an alteration in vestibular function as a result of psychiatric conditions. Somatization syndrome requires between four and six unexplained symptoms excluding dizziness. We should be aware that otherwise unexplained nausea, headache or fatigue might be caused by a vestibular imbalance. As awareness and somnolence affect the vestibular function (modifying the gain of the vestibulo-ocular reflex), anxiety and hyperventilation can affect vestibular responses. Some patients, after compensation of a peripheral vestibular disease, still complain of chronic vague dizziness and postural imbalance because of psychiatric disorders.<sup>14</sup> It is an exclusion criteria syndrome sometimes overlooked. The management is exclusively psychiatric.

An association with various central and peripheral vestibular disorders such as benign paroxysmal vertigo or vestibular neuritis may also increase the risk of psychogenic vertigo.<sup>15</sup>

The combination of acute psychiatric and somatic disorders can have an especially negative effect on the course of the illness, leading to chronification and greater handicap. Particularly in these cases a comorbid or reactive psychiatric disorder is often overlooked and consequently left untreated. Patients presenting with complex somatoform dizziness still show symptoms and are more impaired in their professional and daily activities than those with organic forms of dizziness.<sup>16</sup>

Attempts to distinguish between organic and “psychogenic” dizziness can prove unproductive, as these patients often present with a chronic syndrome of combined physical and psychiatric dysfunction resulting from various psychophysiological and somatopsychic processes. Very few patients have only psychogenic symptoms and overlooking it carries the risk of missing a clinically important underlying disorder.<sup>17,18</sup>

In addition to psychiatric dizziness and balance disorders without any psychiatric troubles, and the functional overlap between both types of troubles, vestibular disorders and psychiatric disorders in some individuals could be manifestations of a common underlying disorder of the central nervous system. This is called linkage and may apply to some patients with anxiety disorders.<sup>19</sup>

The psychological reactions associated with dizziness can be particularly important for different reasons. Vertigo induced somatopsychological consequences can result in limitations on everyday life (social contacts, professional abilities, and mobility), reducing self esteem and promote depression. Moreover vertigo often evolves unpredictably, frequently iteratively or with fluctuations in the intensity of imbalance. This unpredictable component of

vertigo increases anxiety and may lead to phobic avoidance responses in specific situations.<sup>1,9,19</sup>

Many dizzy patients present with psychological decompensation because of vertigo, but some personalities are more at risk: obsessive-compulsive personalities, perfectionist traits, pre-existing anxiety or depressive problems and somatisation.<sup>3,8</sup>

A controversial relationship between a specific psychological profile and Ménière's disease exists. Some state that patients with Ménière's disease present a psychopathological profile which significantly differs to that of a reference population, particularly in terms of level of anxiety, depressive tendency and phobia.<sup>20,21</sup>

The borderline between physiological vertigo induced by sensorial mismatches and true kinetosis, for example, is not always evident. Dizziness that occurs within a posttraumatic vertigo seems to be associated with a high risk of psychological decompensation.<sup>18</sup>

Vertigo can also be a symptom of mental disorder. In psychiatric dizziness, the dizziness is part of a recognized psychiatric syndrome<sup>10</sup> (ex. dizziness in panic attack and abnormal gait in conversion hysteria). In these cases, dizziness cannot be explained by vestibular dysfunction. We should be able to distinguish between psychological problems caused by vertigo and true psychiatric disorders.<sup>22</sup>

Questionnaires may be important as describing of a particular mental state, at a specific time. Although they evaluate subjective perceptions, they may evaluate the handicap caused by vertigo and patient levels of depression or anxiety. Repeating the questionnaire later is one way of assessing patient management.<sup>6</sup> Several frequently used questionnaires include: HAD (Hospital Anxiety and Depression scale)<sup>11</sup>, DHI (Dizziness Handicap Inventory)<sup>23</sup>, PHQ (Patient Health Questionnaire).<sup>24</sup>

At the moment there is no entirely reliable method of consistently distinguishing among patients with dizziness caused by a psychiatric condition or organic dizziness. So, the discussion about diagnosis of psychogenic dizziness is characterized by considerable opinion and a paucity of good relevant evidence. Regarding the high percentage of patients presenting with anxiety and depressive symptoms,<sup>1,5,13,25</sup> we recommend it to be routinely evaluated in all patients who present with persistent dizziness. There are several self report questionnaires available for anxiety and depression, which can be completed by patients in the waiting room and quickly scored by the clinician during evaluation of the patient (ex. Beck Depression Inventory,<sup>26</sup> Beck Anxiety Inventory).<sup>27</sup> Even in those cases a primary vestibular cause is suspected, such instruments should apply because many patients present with such comorbidities and better treatment options could apply.<sup>7,28</sup>

## Treatment and management

Management of dizziness should always include the treatment of treatable causes as well as motivating our patients to engage in vestibular training.

Regarding the management of psychogenic vertigo and psychiatric associated dizziness, there should be an adequate otoneurologic assessment. Unnecessary and prolonged examinations must be avoided, for obvious economic reasons, but more to avoid reinforcing patient belief in an organic illness.

Patients with psychiatric dizziness (the psychiatric disorder associated with the symptom dizziness) should be referred to the specialty.<sup>28</sup>

Dizziness patients with organic or associated psychiatric disorders should be offered a multidisciplinary treatment, including a basic psychological evaluation. This assumes a willingness to listen, which in turn implies providing enough time in our consultations. After a full and thorough examination, patients should receive the most complete information possible about their illness: symptoms, consequences, evolution, and proposed treatment.

The most important therapeutic measure consists in increasing the patient self-assessment while exposing them to an anxiety-exposition therapy that specifically takes into account the symptom of dizziness.<sup>25</sup> The patient should not avoid triggering situations but, on the contrary, seek them out in a controlled manner.<sup>29</sup>

The psycho educational explanation to the patient and relatives leads to a better understanding of the disorders, organic disorders and psychological reactions that will help them.<sup>5</sup> A good patient- doctor relationship gives patients a reassuring feeling and prevents the development or the aggravation of neurosis.

The treatment should include vestibular training and regular exercise. Similarly to other vestibular disorders, this helps to develop vestibular compensation and recover adequate balance strategies. In these disorders it also plays a role in the psychological support of the patient.<sup>29</sup>

In some cases, pharmacotherapy<sup>30</sup>, psychotherapy and behavioral therapy<sup>29</sup> should be considered. Patients with anxiety/panic and dizziness symptoms show a high sensitivity to lower doses of antidepressants, tendency to have initial worsening of anxiety or panic symptoms, good response to Selective serotonin reuptake inhibitors treatment (including the improvement of vestibular symptoms), and increased risk to have discontinuation symptoms.<sup>30</sup> We must remain aware that most of the medical treatments used for dizziness, anxiety and depression interfere with central vestibular compensation.<sup>12</sup>

## Conclusion

Psychogenic vertigo includes different forms that have a different implicit management: vertigo as a symptom (anxiety, depression, hysteria, psychosis, posttraumatic syndrome, stimulation...), vertigo in a defined syndrome (agoraphobia, acrophobia, phobic postural vertigo...) and the psychological overlay of organic vertigo syndromes in predisposed person-



alities and manifest psychiatric disorders.

Otoneurologic assessment of this pathology should integrate the psychological dimension of this pathology in a multidisciplinary team to avoid missing the opportunity to treat these patients. We recommend that anxiety and depressive symptoms should be routinely evaluated in all patients who present with persistent dizziness.

## References

1. McKenna L, Hallam R, Hinchcliffe R. The prevalence of psychological disturbance in neurotology outpatients. *Clinical Otolaryngology* 1991;16:452–56.
2. Furman J, Jacob R. A clinical taxonomy of dizziness and anxiety in the otoneurological setting. *Journal of Anxiety Disorders* 2001;15:9–26.
3. Brandt T. Psychogenic vertigo. In: *Vertigo its multisensory syndromes*. Swasch M, editor. London: Springer-Verlag; 1997. p. 291–306.
4. Jacob R, Furman J. Psychiatric consequences of vestibular dysfunction. *Current Opinion in Neurology* 2001;14:41–46.
5. Yardley L, Burgneay J, Nazareth I, et al. Neuro-otological and psychiatric abnormalities in a community sample of people with dizziness: a blind, controlled investigation. *J Neurol Neurosurg Psychiatry* 1998;65:679–84.
6. Savastino M, Marioni G, Aita M. Psychological characteristics of patients with Meniere's disease compared with patients with vertigo, tinnitus or hearing loss. *ENT journal* 2007;148:56.
7. Clark D, Hirsch E, Smith M, et al. Panic in otolaryngology patients presenting with dizziness or hearing loss. *Am J Psychiatry* 1994;151:223–25.
8. Hain T. Vertigo and psychological disturbances. In: <http://www.dizziness-and-balance.com/disorders/psych/psych.htm>; 2009-08-17.
9. Jacob R, Furman J. Psychiatric consequences of vestibular dysfunction. *Current Opinion in Neurology* 2001;14:41–46.
10. First M, Spitzer R, Gibbon M, et al. *Structured Clinical Interview for Axis I DSM-IV Disorders—Patient Edition*. Washington, DC; 1994.
11. Jacob R, Furman J, Durrant J, et al. Panic, agoraphobia, and vestibular dysfunction. *Am J Psychiatry* 1996;153:503–12.
12. Brandt T. Phobic postural vertigo. *Neurology* 1996;46:1515–19.
13. Strupp M, Glaser M, Karch C, et al. The most common form of dizziness in middle age: phobic postural vertigo. *Nervenarzt* 2003;74:911–14.
14. Garcia F, Coelho M, Figueira M. Psychological manifestations of vertigo: a pilot prospective observational study in a Portuguese population. *Int Tinnitus J* 2003;9:42–7.
15. Kapfhammer H, Mayer C, Hock U, et al. Course of illness in phobic postural vertigo. *Acta Neurol Scand* 1997;95:23–28.
16. Eckhardt-Henn A, Breuer P, Thomalske C, et al. Anxiety disorders and other psychiatric subgroups in patients complaining of dizziness. *J Anxiety Disord* 2003;43:1–20.

17. Clark M, Sullivan M, Fischl M, et al. Symptoms as a clue to otologic and psychiatric diagnosis in patients with dizziness. *J Psychosom Res* 1994;38:461-70.
18. Staab J, Ruckenstein M. Which comes first? Psychogenic dizziness versus otogenic anxiety. *Laryngoscope* 2003;113:1714-8.
19. Balaban C, Thayer J. Neurological bases for balance-anxiety links. *J Anxiety disord* 2001;15:53-79.
20. Martin C, Martin H, Carre J, et al. Psychologic factor in Menière's disease. *Ann Otolaryngol Chir Cervicofac* 1990;107:526-31.
21. Furman J, Cass S. Psychiatric aspects of vestibular disorders. In: *Vestibular disorders A case Study approach* Second ed. New York: Oxford University Press; 2003. p. 54-59.
22. Pollak L, Klein C, Rafael S, et al. Anxiety in the first attack of vertigo. *Otolaryngol Head Neck Surg* 2003;128:829-34.
23. Jacobson G, Newman C. The development of the Dizziness Handicap Inventory. *Arch Otolaryngol Head Neck Surg* 1990;116:424-27.
24. Kroenke K, Spitzer R. The PHQ-9: a new depression diagnostic and severity measure. *Psychiatr Ann* 2002;32:509-21.
25. Clark M, Swartz K. A conceptual structure and methodology for the systematic approach to the evaluation and treatment of patients with chronic dizziness. *Journal of Anxiety Disorders* 2001;15:95-106.
26. Beck A, Steer R, Garbin M. Psychometric properties of the Beck Depression Inventory: Twenty-five years of evaluation. *Clinical Psychology Review* 1988;8:77-100.
27. Beck A, Epstein N, Brown G, et al. An inventory for measuring clinical anxiety: psychometric properties. *J Consult Clin Psychol* 1988;56:893-97.
28. Huppert D, Strupp M, Rettinger N. Phobic postural vertigo: a long term follow up (5-15 Years) of 106 patients. *J Neurol* 2005;252:564-69.
29. Beidela D, Horak F. Behavior therapy for vestibular rehabilitation. *J Anxiety Disord* 2001;15:121-30.
30. Ramos R. Antidepressants and dizziness. *J Psychopharmacology* 2006;20:708-13.

*Corresponding author:*

**Prof. António Paiva**

HUC – ORL, Av. Bissaya Barreto

3000-075 Coimbra, Portugal

tel.: (00351) 239400450

e-mail: [otorrino@huc.min-saude.pt](mailto:otorrino@huc.min-saude.pt)

# PSEUDOHYPACUSIS IN CHILDHOOD: DIAGNOSTIC APPROACH



**Georgos Kontorinis**  
Otorhinolaryngology Department  
Medical University of Hanover  
Hanover, Germany

## Abstract

Pseudohypacusis is the discrepancy between hearing thresholds being obtained with subjective and objective audiological tests. Although more frequent in adults, pseudohypacusis should always be considered as a possible etiology of hearing loss in children. A specific protocol for the evaluation of children being suspected of feigning hearing impairment does not exist yet. The combination of history, otoscopy, impedance measurements, Pure/Play-Tone Audiometry/Speech Recognition Tests and Otoacoustic Emissions seems to be a practical and safe diagnostic approach. Auditory Brainstem Responses should be applied in cases with uncertain results. It is important for the audiologist to remember that pseudohypacusis in children is a diagnosis of exclusion that needs time. The treatment is usually simple, though in complex cases multidisciplinary intervention may be required.

*Keywords:* Pseudohypacusis, hearing loss, PTA, audiometry, Otoacoustic Emissions, ABR.

## Introduction

Pseudohypacusis is the discrepancy between the actual and the measured hearing thresholds of a patient.<sup>1</sup> The term was first proposed by Carhart in 1961.<sup>2</sup> Since then a variety of synonyms such as non-organic hearing loss and functional hearing loss has been used in the literature to illustrate the same 'pathological' findings; responses being obtained on hearing tests which are above the patient's true thresholds.<sup>3,4,5</sup> In simple words, if we consider all causes displaying an organic hearing loss, then the definition of non-organic or pseudohypacusis becomes instantly clear.

Non-organic hearing loss is most commonly encountered in between adult population, since feigning a hearing impairment or exaggerating about an existing one can lead to significant economical, insurance or other type of profits.<sup>6,7</sup> On the other hand, children may not be often involved into medicolegal cases but they can still find their own reasons to overreact and

pretend a hearing problem. Pseudohypacusis is reported to be the most frequent etiology of sudden hearing loss in children.<sup>7</sup> Therefore, it should not be ignored.

The great significance of hearing acuity in speech development and the fragile psychical entity of children are already well known. As a result every hearing complaint of a child should always be seriously taken into account, even if it is clear that the patient is feigning. The diagnosis of pseudohypacusis can only be set when every other organic etiology is excluded. Afterward a suitable therapy must be commenced. Despite the fact that the diagnosis of pseudohypacusis is simpler in children than in adults, as young patients are not mature enough to reproduce identical answers in repeated audiological tests, it can sometimes be a real challenge as well as its treatment.<sup>7</sup>

A combination of audiological tests, image studies and multi-specialist evaluation may be required, in order to reach a certain conclusion about a child's hearing problem's genesis and to propose a drastic solution. When suspecting a non-organic origin these diagnostic batteries may vary from repeated pure-tone and speech audiograms<sup>8</sup> to complete diagnostic assessment.<sup>6</sup> A spherical approach of pseudohypacusis in children is necessary so as underestimated and mistreated cases can be avoided.

### **Etiology**

The causes of non-organic hearing loss in children may be divided in two main groups. The first one includes all conscious motivations leading to malingering such as poor academic performance, family conflicts or the presence of a new family member, for example a new baby. Every change in the environment of the child that can 'thread' its everyday convenience or lead to punishment can be the cause of pretending a hearing disability.<sup>2,5</sup>

The second group involves unconscious factors which contribute to a psychological based pseudohypacusis. These cases may include traumatic events and distressing situations like a divorce or a death of a person with whom the child is closely related.<sup>2,5,6</sup> Conversional disorders in children presenting as hearing loss have already been described.<sup>9,10</sup> In these cases a psychological defense mechanism results in expression of subconscious conflicts as a physical disability. However, in a large study of neurological symptoms associated with conversion disorders in children pseudohypacusis was not reported.<sup>11</sup>

It has been proposed that the term pseudohypacusis should not be used in cases of psychogenic background because the patient is not feigning but actually is convinced that a real hearing disability exists.<sup>6</sup> On the other hand a psychological based deafness is not actually a hearing problem. The patient may think that the hearing acuity is diminished but he/she faces no communication difficulties.<sup>8</sup> Therefore the diagnosis pseudohypacusis can be applied in cases not only of conscious but also of unconscious motivation as they both describe a discrepancy between the real and the measured hearing thresholds.

## Clinical presentations

The mean age of children admitted with pseudohypacusis may vary slightly between studies but they all agree that girls outnumber boys.<sup>6,7</sup> In a large series of children with non organic hearing loss the middle age was 10,5 years.<sup>7</sup> The symptomatology of a malingering child is usually identical. In general the onset of such a hearing loss is sudden and only in extremely rare cases can be progressive. Lumio et al. presented in 1969 a case of three sisters whose hearing problem was developed over a period of few months and proved finally to be of non-organic etiology.<sup>12</sup>

Typically, the child with pseudohypacusis is exaggerating, especially in front of the parents. A usual clinical presentation involves a child who turns the head and demonstrates the 'healthy' ear in order to understand speech, asks often the speaker to repeat words, cannot sit still on the examination chair whenever we do test the "problematic" ear, denies co-operation while using earphones claiming pain and itching and complains because of dizziness and tiredness to interrupt the examination but without wanting to go home.<sup>13</sup>

In addition to the clinical presentation the history background is of great importance and in most cases typical. An insignificant event can trigger underlying pressure or disappointment due to conflicts in the family or friends' environment, poor academic performance or the presence of a new family member and result in pretending a hearing loss.<sup>7</sup> The case of an eleven-year-old boy who was presented with acute unilateral deafness after a mild ipsilateral head injury is characteristic. A background of conversion disorders because of marital troubles within his parents and withdrawn behavior in class was revealed and the child was proved finally of being feigning.<sup>10</sup> Apart from hearing loss the presence of further multisystematic symptomatology is possible. The combination of bilateral sudden hearing loss with headaches, episodic loss of consciousness and dizziness in a 14 year-old boy is only a typical example. In these cases a high index of suspicion is needed so as pseudohypacusis to be revealed and further expertise counseling may be required in order successful treatment to be applied.<sup>7</sup>

## Audiological evaluation

Lack of consistent audiometric results is the key in diagnosis of pseudohypacusis.<sup>3</sup> It is usually easier to set a diagnosis in children than in adults. Young patients are not mature enough to repeat similar answers on repetitive tests. Diagnostic procedure starts with history taking, otolaryngological clinical examination, speech detection tests and impedance measurements, so middle ear pathologies can be excluded. The next test to be applied on a child of suspected fake hearing loss is the repeated Pure/Play Tone Audiometry (PTA). The co-operation of the patient is required therefore some problems may occur with younger children.<sup>4</sup>

Several 'tricks' can be used while testing a child with PTA. The ascending-

descending method in a study involving adults with non-organic hearing loss revealed better hearing thresholds with the modified ascending method than with the initially used descending.<sup>6</sup> This discrepancy is typical for patients with pseudohypacusis and can be also used as a diagnostic criterion on children populations. A variety of the time intervals between the given tones can be an additional beneficial tool to confuse a child who pretends.<sup>4,7</sup>

Furthermore, false negative responses are characteristic of pseudohypacusis and can be easily documented in repeated PTA. False negative responses occur when the patient does not respond at tones above the true hearing threshold.<sup>4</sup> Typically, patients who really face hearing problems want to hear. As a result they are sometimes overreacting during PTA and give false positive responses because they think they might have heard a tone. On the contrary patients who pretend hearing problems give enough false negative answers in order to convince the audiologist that they have impaired ears.

In addition to PTA, Speech Recognition Test (SRT) is also a useful tool to diagnose non-organic hearing loss. A discrepancy between PTA and SRT hearing thresholds is typical for patients pretending hearing loss. SRT is easy to be performed and can be really confusing, especially for children. Patients are not able to synchronize their responses with the ones given during the PTA. Therefore the combination of SRT and PTA can reveal malingering in most of the cases.<sup>13</sup>

There are many other tests that can be used to detect pseudohypacusis but unfortunately they are not easily applicable on children. Such methods are Bone Conduction Audiometry, Lombard test, Doefler-Steward test and tuning forks tests like the very effective in adult population Stenger-test.<sup>13</sup> The results of all these tests cannot be reliably interpreted as they are difficult for children to understand and perform.

An easy and low cost method which has been proved to work in cases of young children is the 'Yes-No' test.<sup>7</sup> The child is simply asked to say 'yes' when a sound is heard and 'no' when it is not. While increasing the intensity of noise in 5dB steps, it may be observed that the child, in attempt to convince the audiologist of hearing impairment, says 'no' to sounds that are heard below the false given hearing threshold.<sup>14</sup>

In addition to all the subjective testing methods already been mentioned an objective confirmation of our findings is always necessary in cases of pseudohypacusis. For this reason Otoacoustic Emissions (OAEs) and Auditory Evoked Potentials (AEP) and especially Auditory Brainstem Responses (ABR) are applied in everyday basis.

Since the introduction of OAEs, they have become very popular as they have offered a fast, reliable and inexpensive objective evaluation of cochlear function and consequently of hearing ability of non co-operative patients. Such patients are children and for that reason the application of OAEs and especially Transient Evoked OAEs (TEOAEs) have become a routine in pediatric audi-

ology. The advantages of TEOAEs in comparison to Distortion Products OAEs (DPOAEs) in cases of pseudohypacusis have been already analytically described in the literature.<sup>4,6</sup> The usage of TEOAEs in children being suspected for feigning offers the first objective sign of normal hearing. The suspicion of pseudohypacusis, the presence of TEOAEs and the repeated PTA are adequate tests to reveal with safety a child's normal hearing acuity.<sup>7</sup>

On the other hand ABR are the 'golden standard' in pediatric audiology and the 'crucial test' in setting the diagnosis of pseudohypacusis.<sup>15</sup> However, ABR are an expensive, time consuming method which in most of the cases are not necessary to prove pseudohypacusis. Psarommatis et al examined 26 children with non-organic hearing loss and in only 7 patients ABR were performed, as the real, normal hearing threshold had been already revealed with the help of history, subjective hearing evaluation and the reassurance of TEOAEs.<sup>7</sup>

Finally, stapedious muscle reflex can also offer a further objective evaluation of the hearing threshold of a child. Unfortunately, the false negative results because of the well known physiological variations and recruitment in both, normal hearing and impaired ears limit the usage of stapedious muscle reflex in detecting pseudohypacusis.

### Therapy options

After setting the diagnosis of pseudohypacusis in a child the treatment is in most of the cases undemanding. There are simple steps that should be followed to make a child discharge and to avoid a negative attitude. The parents should be given the necessary explanations about the results of the audiological evaluation and be informed that a real hearing problem does not exist. Moreover, the child must be treated as having a true hearing impairment, without presenting it as serious or permanent. Young patients should be reassured that their hearing ability will soon return to normal. Every effort to blame a child for pretending hearing loss or to enforce a diagnosis against children's beliefs may be proved unsuccessful.<sup>7,13</sup>

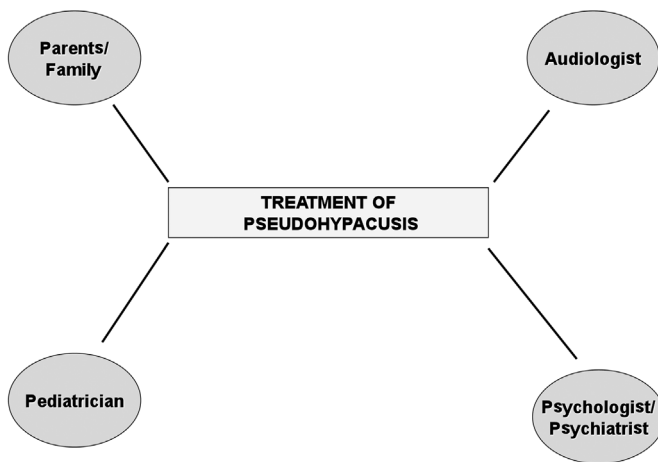
In a very few cases of conversional disorders or underlying psychogenic basis further psychological or psychiatric support may be needed. In these cases psychological tests which measure personality characteristics and psychodynamic processes in addition to psycho education can provide the desirable therapeutic outcomes.<sup>9</sup> Complex cases may require a multidisciplinary assessment (figure 1). In the majority of children with pseudohypacusis the treatment can be summarized in the words 'reassurance', 'counseling' and 'co-operation'.

### Discussion

Pseudohypacusis has an important prevalence in children with sudden hearing loss; therefore the otolaryngologist should be familiar with its diagnostic procedure and treatment.<sup>7</sup> The main motivation of a child to pretend hearing impairment includes rising concern and avoiding punishment. Therefore in

most of the cases the history reveals a background of family conflicts or poor academic performance. An analytical history usually sets a strong suspicion of malingering or overreaction.

**Figure 1** - The necessary co-operation in complex cases of pseudohypacusis.



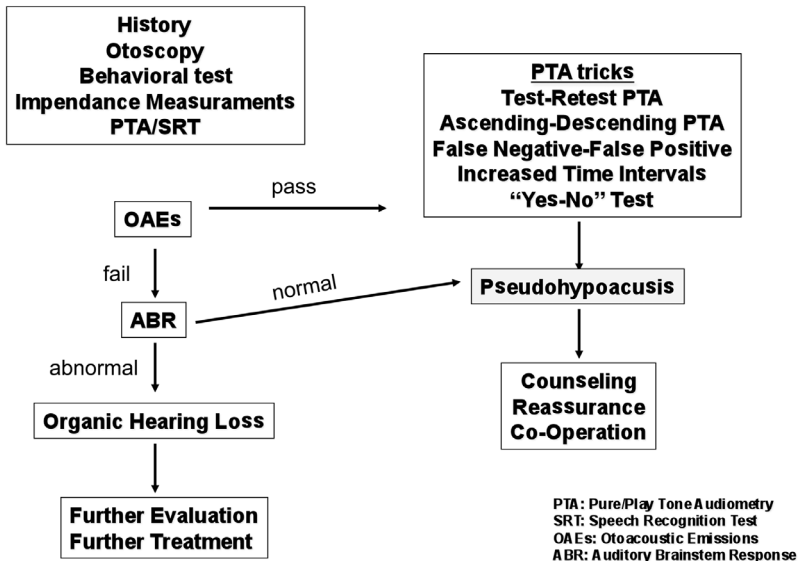
The main referral volume of children pseudohypacusis in the literature exists in form of case reports.<sup>9</sup> In these cases different batteries of diagnostic tools were used. Some children underwent diagnostic protocol based mainly on TEOAEs.<sup>6,7</sup> In other cases the comparison between the repeated PTA and SRT was adequate to set the diagnosis.<sup>8</sup> Additionally, every child being suspected for feigning hearing loss has different motives, family and academic background and psychological profile and requires a unique diagnostic approach. Due to these reasons a standard diagnostic protocol has not been utilized yet and it is difficult to be done.

Moreover, pseudohypacusis must be considered as a diagnosis of exclusion. There are diseases with similar audiological findings and clear organic basis such as auditory neuropathy and central nervous system disorders. Specific diagnostic methods and a different history background exist for these cases which can help the audiologist to perform a differential diagnosis. It is worth mentioning that the main responsibility of the audiologist is to determine the organic component rather than to find a cause of malingering hearing loss.<sup>4</sup> Despite the fact that a uniformly approach of pseudohypacusis is hard to be identified, there are some diagnostic steps which are common in most of the references. A case history is always of value. The family, school and friend environment of the child should always be analyzed and properly evaluated. In most of the cases the history background and the behavior of the child dur-



ing the examination are the first signs of feigning a hearing loss.<sup>4,7,13</sup> Furthermore, ENT clinical examination and especially otoscopy in addition to impedance measurements are of great importance so as a middle ear origin of hearing loss to be excluded. It is well known that the most frequent reason of conductive hearing loss in children is otitis media with effusion. Consequently, this possibility should always be examined.

**Figure 2** - A practical and safe diagnostic approach to children pseudohypacusis.



The next step involves PTA and SRT. This combination proved to be adequate to reveal pseudohypacusis in many cases.<sup>9</sup> The lack of consistency of responses to repeated PTA and a great difference between PTA and SRT results are characteristic for non-organic hearing loss. In children this seems to work much easier and in most of the cases repeated PTA, SRT combining with history and observation of behavior responses can set the diagnosis.

However, verification of our findings by an objective audiological test is necessary. TEOAEs are a time-saving, inexpensive and reliable in detecting non-organic hearing loss method.<sup>7</sup> On the other hand ABR represent the 'golden standard' in the pediatric audiology and should always be performed in cases with non-recordable TEOAEs or uncommon subjective test results. These cases seem to be rare; consequently a protocol consisting of history, otoscopy, impedance measurements, PTA/ SRT and TEOAEs seems to be the ideal diagnostic approach in the majority of the cases (figure 2).

As a conclusion, pseudohypacusis in children may be easier to diagnose and treat than in adults; though is a time-consuming situation. Despite the fact that it is a possible etiology in children presenting with sudden hearing loss it should always be considered a diagnosis of exclusion. Proper evaluation shall be performed to establish the diagnosis and patient-adjusted therapy shall be applied.

*Conflict of interest Statement*

The author declares that he has no conflict of interest.

## References

1. Rintelmann WF, Schwan SA, Blakley BW. Pseudohypacusis. *Otolaryngol Clin North Am* 1991;24:381-390
2. R. Carhart, Testing for malingering, *Trans. Am. Acad. Ophthalmol. Otolaryngol.* 65 (1961) 437. James Lin, Hinrich Staecker. Nonorganic Hearing Loss, *Seminars in Neurology*, Vol 26, Num 3, 2006
3. Katz J. *Handbook of Clinical Audiology*. In: Martin FN. Pseudohypacusis. USA: Lippincott Williams and Wilkins, 2002; 584-596
4. N. Saravanappa, G.A. Mephram, D.A. Bowdler, Diagnostic tools in pseudohypacusis in children, *Int J Pediatr Otorhinolaryngol* (2005) 69, 1235—1238
5. Balatsouras DG, Kaberos A, Korres S, Kandiloros D, Ferekidis E, Economou C. *Ear and Hearing.* 2003;24:518-527
6. Psarommatis I, Kontorinis G, Kontrogiannis A, Douniadakis D, Tsakanikos M. Pseudohypacusis: the most frequent etiology of sudden hearing loss in children. *Eur Arch Otorhinolaryngol.* 2009 Jun 30
7. J.P. Pracey, D.A. Bowdler, Pseudohypacusis in children, *Clin. Otolaryngol.* 21 (1996) 383—384.
8. Chawla JM, Handa KK, Tripathi BM. Unilateral pseudohypacusis in children. *Indian J Pediatr.* 2007 Mar;74(3):312-3
9. Rotenberg BW, Makhija M, Papsin BC Conversion disorder in a child presenting as sudden sensorineural hearing loss. *Int J Pediatr Otorhinolaryngol.* 2005 Sep;69(9):1261-4
10. Schneider S, Rice DR. Neurologic manifestations of childhood hysteria. *J Pediatr.* 1979 Jan; 94(1):153-6.
11. Lumio JS, Jauhiainen T, Gelhar K Three cases of functional deafness in the same family. *J Laryngol Otol.* 1969 Mar;83(3):299-304.
12. Lehnhardt E., Laszig R. *Praxis der Audiometrie*. In: Lehnhardt E. *Aggravation- Stimulation- psychogene Hörstörung*. Stuttgart; New York: Thieme, 2001; 239-250
13. Frank T. Yes-no test for non-organic hearing loss. *Arch Otolaryngol.* 1976 Mar; 102(3):162-5. 144. Knight J., Beagley H. Non-organic hearing loss in children. *Int. Audiol.* 9 (1970): 142-143.

### **Dr. Georgos Kontorinis**

Otorhinolaryngology Department  
 Medical University of Hanover  
 Dietterichstr. 25, 30159 Hanover, Germany  
 tel.: 004915778027080  
 e-mail: gkontorinis@gmail.com



# MALIGNANT SINONASAL TUMOURS



**Carlos Celedón Lavin, Michel Royer Faundez,  
Constanza Valdés Perez**  
Departments of Otolaryngology–Head and Neck Surgery,  
Hospital Clínico Universidad de Chile  
Santiago, Chile

## Abstract

Malignant sinonasal tumours have an incidence of 1/200 thousand inhabitants, being twice in male, concentrating in the fifth and seventh decade of life. These tumours represent 0,2 to 0,8% of all cancers and about 3% of all malignancies of the head and neck region.

Unfortunately the diagnosis is usually delayed, because the symptoms are initiated once the tumor extends through the sinus besides clinical presentation often imitate benign sinonsal diseases.

*Keywords:* sinonasal tumours, cancer, epistaxis orbit, rhinorrea, nasal obstruction.

## Introduction

Malignant sinonasal tumours have an incidence of 1/200 thousand inhabitants,<sup>1</sup> being twice in male, concentrating in the fifth and seventh decade of life.<sup>2</sup> These tumours represent 0,2 to 0,8% of all cancers and about 3% of all malignancies of the head and neck region.<sup>3</sup>

The groups of risk are: wood, leather, nickel and oil refiners workers, textiles, isopropyl alcohol and chrome pigments manufacturers. Of these, nickel is associated with an increased chance to develop squamous cell carcinoma, the bulk of wood dust is linked to an increased incidence of adenocarcinoma of the ethmoid sinus, while fine wood dust to squamous, anaplastic and adenocarcinoma.<sup>3,4,5</sup>

The diagnosis is usually delayed, because the symptoms are initiated once the tumor extends through the sinus. Sixty to 80% of all malignant sinonasal tumours are of the maxillary sinus, and only 25% are limited to it at the time of diagnosis, while 75% are in advanced stages (T<sub>3</sub> or T<sub>4</sub>).<sup>4</sup> About 10% occur

in the ethmoid and less than 1% in the frontal and sphenoid sinus. Between 20 to 30% of these tumors are located in the nasal cavity, but usually at diagnosis moment they undertake the sinunasal cavities.<sup>6</sup>

Regarding the histological types, approximately 80% are squamous cell carcinomas, between 10 to 14% are adenocarcinomas, 1% melanomas, 1% neurogenic tumors such as esthesioneuroblastoma and malignant schwannoma, and 5% are tumors of mesenchymal origin (chondrosarcoma, rhabdomyosarcoma, malignant ameloblastoma and lymphomas). One percent are metastases from primary tumors located in kidney, breast and prostate.<sup>7</sup>

There are several factors that make these tumors have poor prognosis: a) they grow in a closed cavity, so symptomatology is poor and are usually diagnosed when they arise from the cavities, b) they quickly spreads to the suprastructure through the diploic veins, that communicate the sinunasal cavities with the orbit and skull base, c) intrasinusal tumor infection, so they are treated as recurrent sinusitis.

### **Clinic**

The clinic presentation depends on where the tumor starts to grow and of its extension, for example:

- Nose
  - Epistaxis
  - Nasal obstruction
  - Rhinorrhea
- Orbit
  - Exophthalmos
  - Diplopia (depending on the speed of growth)
- Oral
  - Dental pain
  - increase of vestibular volume
  - Facial
  - Facial asymmetry
  - Skull-base
  - Intracranial hypertension
  - Personality disorders

### **Evaluation**

Given the importance of early diagnosis and low symptomatology that may occur in the initial stage, it is essential to have a high index of suspicion to make a proper approach.

## I - Clinical

Tumor in the nose, which is detected through the physical examination, nasofibroscope or rigid nasal endoscopy.

Evaluation of nasopharynx when conductive hearing loss is associated to otitis media with effusion (given the commitment eustachian tube)

Evaluation of nerve involvement, the presence of facial hypoesthesia indicates involvement of the infraorbital nerve. The evidence of perineural invasion on histological examination worsens the prognosis.

## II - Imaging

- Computed Tomography: it defines the tumor and bone destruction, but it does not differentiate adequately between the tumor and secretions, or the extent to soft tissue.
- Magnetic Resonance: it successfully distinguish tumor tissue from inflammatory secretions, also indicates adequately the extension into orbit, skull base and soft tissues. It can determine brain commitment, that in generally is considered to be out of reach of surgery.  
Both CT and MR do not differentiate a benign tumor from a malignant one.
- Pet-scan: mainly on suspicion of relapse, to differentiate tumor tissue from edema and fibrosis.
- Arteriography and/or Angioresonance: it is requested when there is evidence or suspicion of compromise of large vessels.

## III - Biopsy

Histopathological study is needed to establish the diagnosis, strategies for treatment (curative or palliative) and prognosis. It is recommended to do it after obtaining the image study to know the origin, size and vascularization of the tumor.

### *Staging*

Evolved from the original staging of maxillary sinus malignancies categorization based on Ohngren's line to a formal TNM tumor staging within the sinonasal compartment, first applied to tumors of the maxillary sinuses, and recently to cancerous of the ethmoid sinuses (8). This staging system provides an adequate stages-survival correlation.

### *Treatment*

The treatment strategy for these tumors is curative surgical resection and adjuvant postoperative radiation therapy. The surgical approach is dictated by the location and extent of disease and the functional anatomy at risk. Endoscopic surgery has made substantial progress in the management of benign tumors (fibroangioma, inverted papilloma) and there are reports of treatment of tumors of low malignancy in early stages. Probably in the future

there will be more experience in this type of approach, but for now there is not much evidence to make a general recommendation. Another point to consider is the management of tumor margins, a factor directly related to the prognosis, often achieved properly with surgery.

### **I - Craniofacial surgery**

Considers the orbit, skull base and sinuses as a single management structure. This is accomplished by working together with the neurosurgeon in the approach of these tumors with extension to anterior cranial base.

The results of craniofacial surgery are associated with the tumor aggressiveness, whereas in well-differentiated squamous cell carcinoma and esthesioneuroblastoma the survival rate is close to 100%, 60% for adenocarcinoma, 20% in undifferentiated carcinoma and only 20% in sarcomas. The meningeal invasion affect the prognosis (without commitment reaching 72 to 83% and with commitment 22-48%) and the extent of resection (assessed by the need for reconstruction).

### **Contraindications**

The contraindications of craniofacial surgery are based on the unresectability of the tumor and of the characteristics that give a poor prognosis (despite its surgical management):

- Frontal lobe invasion
- Cavernous sinus and/or internal carotid invasion
- Bilateral orbital-Invasion
- Metastasis
- High-grade malignant tumor
- Commitment of the middle fossa or pterygoid plate

### **Complications**

- Early: Mental impairment, diplopia, cerebrospinal fluid leak, epidural abscess
- Delayed: Cutaneous frontal flap loss, frontal osteitis

### **II - Radiotherapy**

Currently, radiotherapy is used after surgery as a strategy to reduce the risk of recurrence. Its use as an exclusive modality only in patients with palliative or with contraindication for surgery.

### **III - Management of the neck**

Neck metastatic disease has been reported to occur with low incident (less than 20% cases),<sup>9,10</sup> so this has Encouraged conservative management of the neck. Management of the neck is focused on the clinically positive neck, with a neck dissection indicated for diagnostic purposes as well as therapeutic.<sup>11</sup>



### Prognosis

Despite improvements in surgical techniques and radiation therapy delivery modalities, disease-free survival at 5 years remains less than 50%. In advanced stages disease-free survival is just 25% to 30%.<sup>12,13</sup>

The failure of treatment, resulting in death, is determined by local tumor persistence. The presence of positive tumor margins on surgical resection is a key point. Craniofacial surgery and postoperative radiotherapy have reduced local failures.

The presence of distant metastases is low, between 9 to 19%.

### Factors

- Location

Survival is related to the tumor site of origin, being 45% in the maxillary sinus, 51% in the ethmoid sinus and 66% in the nose.

- Stage

The survival rates decrease significantly with increasing of tumor extension, estimated at 90% in T<sub>1</sub>, 70% T<sub>2</sub>, 44% T<sub>3</sub>, and only 28% in T<sub>4</sub>.

- Tumor-margin

The persistence of tumor in surgical margins is related to reduced regional control measured at 5 years, with 65% in patients with negative margins and only 45% in patients with positive margins.

- Orbit compromise

It is arguably the effect of the compromise of the orbit in the local control and survival, while the need for orbital exenteration indicates a more advanced tumor, the realization of this procedure achieves a 79% disease control, compared to 14% when not using it. Indicating that orbital exenteration if compromise exists, gives a better prognostic. The definition of orbital commitment has varied over time, it is now accepted that it is when by histology the orbital fat is compromise.

### References

1. Speatt JS, Mercado R. Therapy and staging in advanced cancer of the maxillary antrum. *Amer J Surg* 1965; 110: 502-9.
2. Lee KL. *Essential Otolaryngology; Head and Neck Surgery* 6<sup>th</sup> ed. Appleton & Lange. Norwalk, Connecticut. 1995; 568-72.
3. Maniglia A, Phillips D. Midfacial degloving for the management of nasal sinus and skull-base neoplasms. *Otolaryngol Clin North Am* 1995; 28 (6): 1127-43.
4. Barton RT. Nickel carcinogenesis of the respiratory tract. *J Otolaryngol* 1977; 6: 412.
5. Herberg S, Westerholm P, Schultz Larsen et al. Nasal and sinonasal cancer: Connection with occupational exposures in Denmark, Finland, and Sweden. *Scand J Work Environ Health* 1983; 9: 315

6. Harrison DF. The management of malignant tumors of the nose and paranasal sinuses. *Otolaryngol Clin North Am* 1971; 4: 159.
7. Mc Guirt F. Maxillectomy. *Otolaryngol Clin North Am* 1995; 28: 1175-
8. Baker HW. Staging of head and neck cancer. *Semin Surg Oncol* 1992;8:73-7.
9. Myers LL, Nussenbaum B, Bradford CR, et al. Paranasal sinus malignancies: an 18-year single institution experience. *Laryngoscope* 2002;112:1964-9
10. Katz TS, Mendenhall WM, Morris CG, et al. Malignant tumors of the nasal cavity and paranasal sinuses. *Head Neck* 2002;24:821-9.
11. Rinaldo A, Ferlito A, Shaha AR, et al. Is elective neck treatment indicated in patients with squamous cell carcinoma of the maxillary sinus? *Acta Otolaryngol* 2002;122:443-7.
12. Samant S, Kumar P, Wan J, et al. Concomitant radiation therapy and targeted cisplatin chemotherapy for the treatment of advanced pyriform sinus carcinoma: disease control and preservation of organ function. *Head Neck* 1999;21:595-601.
13. Lee MM, Vokes EE, Rosen A, et al. Multimodality therapy in advanced paranasal sinus carcinoma: superior long-term results. *Cancer J Sci Am* 1999;5:219-23.

*Corresponding author:*

**Prof. Carlos Celedon Lavin**

ENT Department

Hospital Clinico, University of Chile

Av. Santos Dumont 999

Independencia, Santiago, Chile.

e-mail: celedonl@mi.cl

# UNDERSTANDING FUNCTIONAL NECK DISSECTION



Javier Gavilán, Jesús Herranz, Lourdes Martín  
Department of Otorhinolaryngology  
La Paz University Hospital  
Madrid, Spain

## Abstract

Functional neck dissection is based on specific anatomic concepts regarding the relationship between the lymphatic structures and the fascial system of the neck. During the second half of the 20<sup>th</sup> century, the road to “less-than-radical” neck dissection followed two different paths. The American evolution which is based on the idea of preserving important neck structures that may not be involved by the tumor, e.g. internal jugular vein, spinal accessory nerve, and sternocleidomastoid muscle; and the Latin approach to the problem which is based on the fascial concept developed by Osvaldo Suárez. The differences between both approaches may appear irrelevant from a practical standpoint but they are crucial to understand the rationale and surgical technique of functional neck dissection.<sup>3</sup>

*Keywords:* Functional neck dissection, spinal accessory nerve, internal jugular vein, sternocleidomastoid muscle, tumors, larynx.



**Figure 1**  
Prof. Osvaldo Suarez.

## Introduction

Functional neck dissection (FND) was first described by Suárez in the early 1960's.<sup>1</sup> Although the operation has been called “modified radical neck dissection”, FND is not a modification of the operation described by Crile in 1906<sup>2</sup> because its anatomic and surgical principles are not derived from those of the Crile operation. FND is based on specific anatomic concepts regarding the relationship between the lymphatic structures and the fascial system of the neck.

During the second half of the 20<sup>th</sup> century, the road to “less-than-radical” neck dissection followed two different paths. The American evolution which is based on the idea of preserving important neck structures that

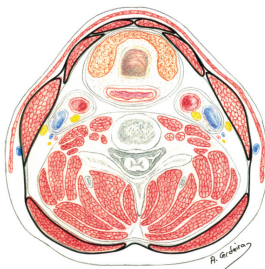
may not be involved by the tumor, e.g. internal jugular vein, spinal accessory nerve, and sternocleidomastoid muscle; and the Latin approach to the problem which is based on the fascial concept developed by Osvaldo Suárez.

The differences between both approaches may appear irrelevant from a practical standpoint but they are crucial to understand the rationale and surgical technique of functional neck dissection.<sup>3</sup>

### Historical approach to Neck Dissection

The American approach gave raise to the so-called “modified” radical neck dissections. After some years of debate, the oncologic safety of these “less-than-radical” operations was widely accepted. A step forward in this evolution resulted in the appearance of “selective” neck dissections in which some nodal regions are preserved according to the location of the primary tumor. This new approach to neck dissection carried a need for a comprehensive classification inclusive of all types of modifications to the radical operation. Since the potential number of modifications is rather large, the resulting classification is complex and difficult to handle on a daily basis.

The Latin approach is based on the anatomic compartmentalization of the neck. The fascial system creates spaces and barriers separating the lymphatic tissue from the remaining neck structures. The lymphatic system of the neck is contained within a fascial envelope which, under normal conditions, may be removed without taking out other neck structures such as the internal jugular vein, sternocleidomastoid muscle, or spinal accessory nerve. The surgical technique that made this possible was initially called “functional neck dissection” because it allowed a more functional approach to the neck in head and neck cancer patients.

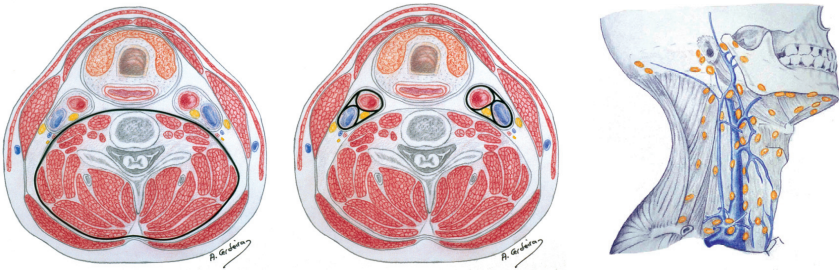


**Figure 2** - Schematic draw of axial section of the neck displaying the superficial fascial envelope of the neck.

However one of the most important, and less known fact about functional neck dissection, is that it represents a surgical concept with no implications regarding the extent of the surgery. Osvaldo Suárez never performed functional neck dissection as the comprehensive type of neck dissection that some have made of it. In fact, the operation he used for cancer of the larynx did not include the submandibular and submental lymph nodes (area I) in the resection, something that now will be considered a selective neck dissection.

### Rationale and anatomical basis for Functional Neck Dissection

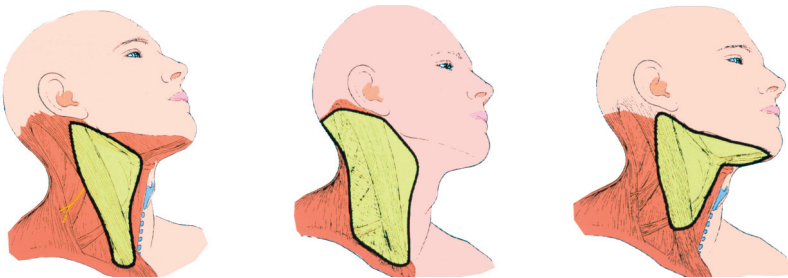
The anatomical description of the fascial layers of the neck has suffered a number of different descriptions. For practical reasons we will consider two distinct fascial layers in the neck, the superficial cervical fascia and the deep



**Figure 3** - a,b,c - Schematic draw of axial section of the neck showing the deep cervical fascia (a), the neurovascular sheath (b) and the lymphnode distribution of the neck (c).

cervical fascia. The superficial cervical fascia corresponds to the subcutaneous tissue. The deep cervical fascia is the key element for functional neck dissection since it surrounds the neck enveloping different structures. For teaching purposes two different layers are considered within the deep cervical fascia: a superficial, and a deep or prevertebral layer.

The *superficial* layer of the deep cervical fascia, also known as investing or anterior fascia, completely envelops the neck with the exception of the skin, platysma muscle, and superficial fascia. From posterior to anterior, the superficial layer splits to enclose the trapezius, the portion of the omohyoid muscle that crosses the posterior triangle of the neck, and the sternocleidomastoid muscle. In a similar way it envelops the strap muscles, before ending in the midline. The *deep* or *prevertebral* layer, like the superficial layer, attaches posteriorly at the spinous process of the cervical vertebrae and ligamentum nuchae. This fascial layer covers the splenius, levator scapulae and scalene muscles, reaching the transverse process of the vertebral bodies. From here it crosses the midline where it attaches to the transverse process of the cervical vertebrae of the opposite side, passing posterior to the esophagus and anterior to the spine. Is this prevertebral part which gives its name to this fascial layer.



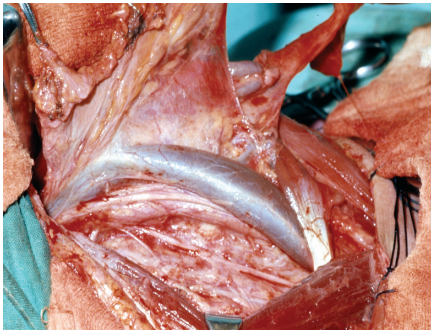
**Figure 4** - a,b,c - Schemes of the selective neck dissection: a. levels 2,3,4; b. levels 2,3,4,5; c. levels 1,2,3.

The space between the sternothyroid and the anterior scalene muscles is filled by the carotid sheath. This vascular sheath runs from the base of the skull to the root of the neck. It has independent compartments for the internal jugular vein, the carotid artery, the vagus nerve, and the ansa cervicalis. It attaches to the prevertebral layer at the level of the anterior scalene muscle. The cervical portion of the sympathetic trunk runs posterior to the carotid sheath.

Fascial compartmentalization allows the removal of cervical lymphatic tissue by separating and removing the fascial walls of these “containers” along with their contents from the underlying vascular, glandular, neural, and muscular structures.

### Functional as a concept

We are aware that the two approaches herein specified —American and Latin— may look similar to many. However, there is a great conceptual difference between them. In the first case the surgical technique is modified to preserve some neck structures, whereas in the second, a different approach is used to treat the neck with disease confined to the lymphatic system.



**Figure 5** - Surgical field after neck dissection.

This difference may appear terminological and irrelevant when it comes to compare “functional” versus “modified radical”. It may be said that although the rationale is different, the end result is the same: the lymphatic system is removed from the neck preserving the remaining neck structures. However, the situation becomes more complex when selective neck dissections appear in the surgical scenario.

Selective neck dissections are simple modifications of standard operations, would these be functional or radical. Selective neck dissections are just technical variations designed to fit the operation to the patient on a more individualized basis. Thus, their potential number is as high as modifications to the original procedure are possible. On the contrary, functional neck dissection as described here is a concept, allowing a different approach to the neck. The key factor for the misunderstanding of functional neck dissection was the mixture between concepts and techniques that took place in the literature. This situation was favored by a linguistic factor that played an important role in all this confusion.

The functional concept reached the American surgeons through the experience of third parties since Osvaldo Suárez never published his ideas in

English. Moreover, the few Spanish papers he published did not emphasize the importance of his approach —as often happens with important contributions, the author is the person less aware of the impact of the innovation—. The result of this indirect transmission of information was the partial distortion of the implicit message: *functional is a concept, not just another modification*.

The functional concept implies dissecting along fascial planes, regardless of the nodal regions that may be preserved or included in the resection. Functional means using fascial compartmentalization to remove the lymphatic tissue of the neck.

The final conclusion for this reasoning is that functional neck dissection should not be identified with a comprehensive type of non-radical neck dissection, but with a conceptual approach to the neck. Whether the surgeon decides to stop above or below the omohyoid muscle in oral cavity tumors, remove or preserve the lymph nodes in the posterior triangle of the neck (lower part of area V) in hypopharyngeal cancer, or resect or spare the submental lymph nodes in laryngeal cancer patients constitutes only minor considerations to the basic principle. Now let's address the relations between the basic functional principle and selective neck operations.

### **The role of selective neck dissections in the functional approach**

In the functional approach selective neck dissections are just technical modifications of the complete operation which includes all nodal regions in the resection. We do not question the usefulness of these operations. In fact, a large number of our non-radical operations are selective neck dissections. However, we do not share the need to establish a comprehensive classification that includes all possible types of modifications and technical variations. The number of combinations and permutations of 6 nodal regions and more than 10 primary sites, plus two preoperative N stages, is immense. Such classification is impractical for teaching purposes.

Some authors support the need to create extensive classifications as a tool to obtain proper information about the usefulness of different types of selective neck dissection. However, the validity of such reasoning is questionable. The ill-defined boundaries that delineate the separation of nodal regions at surgery stands as an important drawback for standardizing purposes. Although clearly marked in theory, the anatomic landmarks that separate the nodal groups are difficult to identify during the operation. The artificial lines that divide the neck into nodal regions are not easily visible and the anatomic landmarks that may be used to help the surgeon can be largely displaced during the operative maneuvers. This gives little consistency to the reports of selective neck dissections coming from different institutions, and even from different surgeons within the same institution. What somebody refers as anterolateral neck dissection may be completely different in extension,



number of removed lymph nodes, and true anatomic boundaries –in contrast to theoretic limits- to the anterolateral dissection performed by other surgeons. Extending this situation to all types of selective neck dissections gives an idea of the actual inconsistency of the current classification from a practical standpoint.

### **Neck dissection classifications: didactic vs. clinical intention**

For teaching purposes we prefer to use a more pragmatic approach that includes only two different types of neck dissection which represent the two main concepts: functional and radical. After the young surgeons have learned the basics for these two approaches, they will decide whether to enlarge their practice with technical modifications to the standard procedures, based on their personal experience. An additional group of modified procedures is included in our classification for special situations. We accept the criticism of those who consider this to be a very simplistic approach to neck dissection classification. Those supporting more detailed classifications consider our approach to be inadequate for comparison purposes between different surgeons and institutions. However, in our opinion exhaustive classifications do not allow either useful comparisons as a consequence of the multiple subjective variables that take part in every operation, especially when the surgical limits are diffuse and difficult to identify. In contrast, exhaustive systems are more difficult to learn and use in every day life than more simple methods. On the other hand, for clinical purposes we frequently use selective neck dissections, but only those that have been proved safe in our hands over the years (e.g., preserving level I in cancer of the larynx). However, we consider them simple modifications of the standard procedures and do not pay special attention to nomenclature and other terminological issues. Each one of these operations is selected on a personal basis according to factors relating to the primary tumor, the patient, and the treatment team. This selection process results in a polymorphous variety of procedures designed to fit the operation to the patient on a personal basis.

It must be emphasized that we never push the limits too far concerning the preservation of nodal regions. Two reasons stand for this. 1. The wish to avoid “staging” operations when therapeutic procedures are easily achievable. 2. The belief that the time and morbidity added with more extensive operations is not significant from the patient perspective. With this approach we try to increase the effectiveness of our surgery and limit the need for postoperative radiotherapy in early N stages, reducing the cost and morbidity of the treatment.

### **Indications and limitations of the functional approach**

In order to be safe, functional neck surgery requires all metastatic disease to be confined within the lymphatic tissue. Thus, this approach is ideal for No



patients with a high risk of occult metastasis. An additional advantage of functional neck dissection is that it may be performed simultaneously on both sides of the neck without increasing morbidity. In all midline head and neck lesions with high risk of cervical metastasis—floor of the mouth, base of tongue, supraglottic larynx—functional neck dissection is the best surgical option for No patients.

In patients with small palpable nodes functional neck dissection is still a valid option as long as some principles are carefully observed. The nodes should not be greater than 2.5-3 cm in greatest diameter. This is justified by the need to have all metastatic disease confined within the lymph node capsule. Although extracapsular spread is possible in lymph nodes of all sizes, it is well known that extracapsular spread increases with increasing lymph node size. Gross extracapsular extension results in lymph node fixation to contiguous structures. Therefore, lymph node mobility must be carefully assessed before surgery. This is even more important than the absolute size in centimeters because small nodes may be fixed, thus preventing a functional approach in these cases. In no instance functional neck dissection should be attempted in patients with fixed nodes. If at surgery there is any doubt about the feasibility of the functional operation, the suspicious structure must be removed with the specimen. Cancer cells cannot be pursued with a scalpel and surgical demonstrations of “technical expertise” are unacceptable in cancer patients and must be reserved to the dissection room.

The number of palpable nodes is not a contraindication for functional neck dissection as long as all nodes fulfill the previously mentioned criteria. The same can be said with respect to the location of the primary tumor. Functional neck dissection is as safe for supraglottic tumor as it is for piriform sinus cancer, as long as the indications are carefully followed in both situations. The fact that patients with cancer of the hypopharynx do poorer than those with laryngeal tumors cannot be modified by performing more aggressive operations than those required for the N stage of the patient.

By definition, functional neck dissection is not possible in patients previously treated with radiotherapy or other types of neck surgery. In these patients the fascial planes have disappeared as a consequence of the previous treatment. Thus, fascial dissection is not possible anymore. Is in these cases where the concept of “modified radical neck dissection” appears as an alternative to radical neck dissection in order to preserve structures not involved by the tumor. The dissection will be made according to the basic principles of radical neck dissection, but preservation of uninvolved neck structures will be accomplished according to the surgical scenario. This is a clear example that illustrates the difference between functional and modified radical neck dissection.

## References

1. Suárez O. El problema de las metástasis linfáticas y alejadas del cáncer de laringe e hipofaringe. *Revista de Otorrinolaringología* (Santiago de Chile) 1963;23:83-99.
2. Crile G. Excision of cancer of the head and neck with special reference to the plan of dissection based on 132 operations. *JAMA* 1906;47:1780-1785.
3. Gavilán J, Herranz J, DeSanto LW, Gavilán C. Functional and Selective Neck Dissection. New York: Thieme; 2002.

*Corresponding author:*

**Prof. Javier Gavilán**

Department of Otolaryngology

“La Paz” University Hospital

University of Madrid

Madrid, Spain

e-mail: [jgavilan.hulp@salud.madrid.org](mailto:jgavilan.hulp@salud.madrid.org)



**HEAD & NECK**  
EXPERIMENTAL MEDICINE



# REVIEW



# HEARING OUTCOMES IN CHILDREN WITH SURGERY FOR CHOLESTEATOMA



**Matthew J Lin**

Faculty of Medicine, Dentistry and Health Sciences  
University of Melbourne  
Victoria, Australia

## Abstract

*Objectives:* To review the literature on hearing outcomes in children with surgery for cholesteatoma.

*Methods:* A Medline database literature review in the English language of hearing outcomes following surgery for cholesteatoma in the paediatric population.

*Results:* Children with cholesteatoma had a mean pre-operative air bone gap in the order of 30-40 dB. Following mastoidectomy there was a mean air bone gap of 15-35.6 dB. Most children had a residual mild hearing loss (mean speech reception threshold < 30 dB in 43.5-68%). Sensorineural hearing was relatively stable however a mild sensorineural deterioration was not uncommon (7.6-14%). Hearing outcome is predicted by pre-operative level of hearing and the extent of disease in terms of ossicular chain destruction and erosion of the stapes superstructure.

*Conclusion:* Hearing outcomes after cholesteatoma surgery in children are important but the pursuit of hearing should not compromise the primary aim of disease eradication. The majority of children who undergo mastoidectomy will maintain or improve their hearing, however some degree of conductive hearing loss often remains.

*Keywords:* Paediatric cholesteatoma, surgery, mastoidectomy, treatment outcomes, hearing.

## Introduction

A cholesteatoma is a sac of keratinising squamous epithelium trapped within the middle ear or mastoid cavity. Extensive bone destruction and other complications may occur secondary to growth, enzymatic activity and infections. The incidence of cholesteatoma in children is estimated to be 3 to 6 per 100,000.<sup>1</sup> Approximately 70% are acquired while 30% are congenital<sup>2</sup>

Cholesteatoma in children is generally considered to behave more aggressively and destructively than in adults. Extensive disease is found more frequently in children and higher rates of residual and recurrent diseases have been documented.<sup>3-6</sup>

The main goal of cholesteatoma surgery is first and foremost complete eradication of disease. The secondary goal is preservation or restoration of hearing. Optimisation of hearing is important, but only after eradication of disease and establishing a safe ear. Several operations have been described to remove cholesteatoma. The most commonly employed are the canal wall up (CWU) mastoidectomy and canal wall down (CWD) mastoidectomy. Cholesteatoma management may also involve reconstruction of the hearing mechanism such as in an ossiculoplasty. The ideal surgical approach is controversial and there are many considerations in making the decision. Both canal wall up and canal wall down procedures have their advantages and disadvantages and there is literature supporting both techniques.<sup>7-11</sup> Canal wall up procedures preserve the posterior canal wall, allowing for quicker healing and avoiding cavity problems. However the rate of residual or recurrent cholesteatoma may be higher. Canal wall down procedures involves taking down the posterior canal wall and forming a mastoid cavity. This provides superior access to the middle ear and epitympanum but patients require periodic cleaning of their mastoid cavity and are predisposed to otorrhoea especially with swimming. Indications for the canal wall down mastoidectomy include sclerotic mastoid, labyrinthine fistula, only hearing ear and poor eustachian tube function. Customizing the approach to the individual child is the best practice.

## Method

A Medline database literature review was performed using the topic “cholesteatoma” and MeSH heading “otologic surgical procedures”. The search was refined to include only children 0 to 18 years of age and only articles published in the English language between 1980 and 2009. This search generated 301 articles. However, articles were included in the review only if the abstract indicated that they included results on post-operative level of hearing as an outcome measure (for instance air bone gap, bone conduction thresholds, speech recognition threshold or pure tone average). In total, 33 articles fulfilled this criteria and were included in the review.

## Review

The relevant literature comprises several retrospective analyses. Inevitably most studies used cholesteatoma recidivism as the primary basis for assessing outcomes. Hearing outcomes were secondary parameters. Comparing hearing outcomes between studies is difficult due to differences in terms of age range, patient selection criteria, surgical expertise, surgical procedures



and follow up times. Furthermore, there is variation in hearing documentation as there does not appear to be one recognized standardized presentation of hearing outcomes.

**Table 1** - Air bone gap (ABG) following canal wall up (CWU) mastoidectomy and canal wall down (CWD) mastoidectomy

|                        | Mean preoperative ABG (dB) | Mean postoperative ABG (dB) CWU mastoidectomy | Mean postoperative ABG (dB) CWD mastoidectomy |
|------------------------|----------------------------|---|---|
| Tos <sup>5</sup>       | 36-40                      | 15  | 25  |
| Dodson <sup>7</sup>    | —                          | 20.3  | 22.6  |
| Darrouzet <sup>8</sup> | 30                         | 21  | 31  |
| Chadha <sup>14</sup>   | 32-35.1                    | 25.8  | 35.6  |

Using the air bone gap categories defined by Darrouzet et al., “good” residual air bone gaps (< 20 dB) were achieved in 49-57% and “socially acceptable” air bone gaps (< 30dB) were achieved in 71-75% (Table 2).

**Table 2** - Mean postoperative air bone gap (ABG) following mastoidectomy  
Following cholesteatoma surgery most children had a mild degree of hearing loss. Mean postoperative pure tone averages (PTA) < 30dB occurred in 57-66% of children. Speech recognition thresholds (SRT) may be a better measure of the social value of hearing and SRTs < 30 dB were achieved in 43.5%-68% of children (Table 3).

|                          | ABG < 20 dB<br>“Good” | ABG < 30 dB<br>“Socially acceptable” |
|--------------------------|-----------------------|--------------------------------------|
| Tos <sup>5</sup>         | 57%                   | 78%                                  |
| Dodson <sup>7</sup>      | 56%                   | 78%                                  |
| Darrouzet <sup>8</sup>   | 54%                   | 75%                                  |
| Vertiainen <sup>15</sup> | 49%                   | 71%                                  |
| Schuring <sup>16</sup>   | 57%                   | 72%                                  |
| Soldati <sup>17</sup>    | 52%                   | —                                    |

In the literature, children with cholesteatoma had a mean pre-operative air bone gap (ABG) in the order of 30-40 dB. The majority of children who underwent mastoidectomy maintained or improved their pre-operative hear-

ing.<sup>8,12-14</sup> On average, some degree of conductive hearing loss remained. The mean postoperative air bone gap ranged from 15-25.8 dB for canal wall up mastoidectomy and 25-35.6 dB for canal wall down mastoidectomy (Table 1). Improvement of hearing can be attributed to disease eradication and where applicable reconstruction of the hearing mechanism with ossiculoplasty. A deterioration in conductive hearing may be due to disease recurrence or manipulation of the ossicles intraoperatively.

Sensorineural hearing appeared to be relatively stable following surgery for cholesteatoma. However a mild postoperative sensorineural hearing loss was not uncommon (Table 4). A sensorineural hearing loss in excess of 10dB was reported in 7.6% of all children by Darrouzet et al. Dodson et al reported sensorineural hearing loss in excess of 10 dB in 12-14% of mastoidectomies. Causes of sensorineural hearing loss following surgery for cholesteatoma may include acoustic trauma due to the noise or vibrations of drilling, continuous suction irrigation or more rarely inner ear injury due to perilymph fistula.

**Table 3** - Mean postoperative speech recognition threshold (SRT) and pure tone average (PTA) following mastoidectomy

|                          | SRT < 30 dB | PTA <30 dB |
|--------------------------|-------------|------------|
| Tos <sup>5</sup>         | 68%         | 62%        |
| Darrouzet <sup>8</sup>   | 63.7%       | 66%        |
| Vertiainen <sup>15</sup> | —           | 57%        |
| Fageeh <sup>12</sup>     | 59%         | —          |
| Edelstein <sup>18</sup>  | 45%         | —          |
| Schloss <sup>19</sup>    | 43.5%       | —          |

**Table 4** - Postoperative sensorineural hearing loss following canal wall up (CWU) and canal wall down (CWD) mastoidectomy

|                        | Deterioration in bone conduction threshold > 10 dB (CWU) | Deterioration in bone conduction threshold > 10 dB (CWD) | Deterioration in bone conduction threshold > 10 dB (Total) |
|------------------------|--|--|--|
| Darrouzet <sup>8</sup> | 6.5%   | 13.8%  | 7.6%   |
| Dodson <sup>7</sup>    | 12%  | 14%  | -  |

Although the data in Table 1 may suggest that the canal wall up approach is associated with slightly better hearing outcomes, this is controversial and it is difficult to make clear conclusions. There are selection biases and confounding variables. For instance, a more extensive disease may influence a surgeon's choice to operate with a canal wall down approach.<sup>14,20</sup> It is likely that the status of the canal wall has little effect on hearing outcome.<sup>7</sup> Hearing outcomes depend more on other factors rather than the surgical approach. These include pre-operative level of hearing and extent of disease in terms of ossicular chain destruction and erosion of the stapes superstructure.<sup>5,9,12,14</sup> The use of ossiculoplasty is variable and this would also influence hearing outcomes.

## Conclusion

Hearing outcomes after cholesteatoma surgery in children are important but the pursuit of hearing should not compromise the primary aim of disease eradication. Children with cholesteatoma have a mean pre-operative air bone gap in the order of 30-40 dB. The majority of children who undergo mastoidectomy will maintain or improve their hearing, however some degree of conductive hearing loss often remains (mean air bone gap 15-35.6 dB). Most children have a residual mild hearing loss (mean speech reception threshold < 30 dB in 43.5-68%). Sensorineural hearing is relatively stable, however a mild sensorineural deterioration is not uncommon. Hearing outcome is predicted by pre-operative level of hearing and the extent of disease in terms of the state of the ossicular chain and the presence of the stapes superstructure.

## References

1. Harker, L.A., *Cholesteatoma: an incidence study*. Otolaryngol Clin North Am, 2002. 35: p. 841-851
2. Friedberg, J., *Congenital cholesteatoma*. Laryngoscope, 1994. 104 (suppl): p. 1-24.
3. Stern, S.J. and M. Fazekas-May, *Cholesteatoma in the pediatric population: prognostic indicators for surgical decision making*. Laryngoscope, 1992. 102(12 Pt 1): p. 1349-52.
4. Glasscock, M.E., J. Dickens, and R.J. Wiet, *Cholesteatoma in children*. Laryngoscope, 1981. 91: p. 1743-53.
5. Tos, M., *Treatment of cholesteatoma in children: a long-term study of results*. Am J Otol, 1983. 4: p. 189-97.
6. De Corso, E., Marchese M.R., Scarano E., Paludetti, G., *Aural acquired cholesteatoma in children: surgical findings, recurrence and functional results*. Int J Pediatr Otorhinolaryngol, 2006. 70(7): p. 1269-73.
7. Dodson, E.E., Hashisaki, G.T., Hobgood, T.C., Lambert, P.R. *Intact canal wall mastoidectomy with tympanoplasty for cholesteatoma in children*. Laryngoscope, 1998. 108(7): p. 977-83.
8. Darrouzet, V., Duclos, J.Y., Portmann, D., Bebear, J.P., *Preference for the closed technique in the management of cholesteatoma of the middle ear in children: a retrospective study of 215 consecutive patients treated over 10 years*. Am J Otol, 2000. 21(4): p. 474-81.

9. Shirazi, M.A., Muzaffar, K., Leonetti, J.P., Marzo, S., *Surgical treatment of pediatric cholesteatomas*. Laryngoscope, 2006. 116(9): p. 1603-7.
10. Gocmen, H., Kilic, R., Ozdek, A., Kizilkava, Z., Safak M., Samim, E., *Surgical treatment of cholesteatoma in children*. Int J Pediatr Otorhinolaryngol, 2003. 67(8): p. 867-72.
11. Mishiro, Y., Sakagami, M., Okumura, S., Takeda, N., Kubu, T., *Postoperative results for cholesteatoma in children*. Auris Nasus Larynx, 2000. 27(3): p. 223-6.
12. Fageeh, N.A., Schloss, M.D., Elahi, M.M., Tewfik, T.L., Manoukian, J.J., *Surgical treatment of cholesteatoma in children*. J Otolaryngol, 1999. 28(6): p. 309-12.
13. Mutlu, C., Khashaba, A., Saleh, E., Karmarkar, S., Bhatia, S., DeDonato, G., Russo, A., Sanna, M., *Surgical treatment of cholesteatoma in children*. Otolaryngol Head Neck Surg, 1995. 113(1): p. 56-60.
14. Chadha, N.e.a., *A multivariate analysis of the factors predicting hearing outcome after surgery for cholesteatoma in children* J Laryngol Otol, 2006. 120: p. 908-913.
15. Vartiainen, E. and N. J., *Long term results of surgery for childhood cholesteatoma*. Int J Pediatr Otorhinolaryngol, 1992. 24: p. 201-8.
16. Schuring, A.G., Lippy, W.H., Rizer, F.M., Shuring, L.T., *Staging for cholesteatoma in the child, adolescent and adult*. Ann Otol Rhinol Laryngol, 1990. 99(4 Pt 1): p. 256-60.
17. Soldati, D. and A. Mudry, *Cholesteatoma in children: techniques and results*. Int J Pediatr Otorhinolaryngol, 2000. 52(3): p. 269-76.
18. Edelstein, D., S.C. Parisier, and G.S. Ahuja, *Cholesteatoma in the pediatric age group*. Ann Otol Rhinol Laryngol, 1988. 97(23-9).
19. Schloss, M.D. and Terraza. O., *Cholesteatoma in children*. J Otolaryngol, 1991. 20: p. 43-5.
20. Murphy, T.P. and D.L. Wallis, *Hearing results in pediatric patients after canal-wall-up and canal-wall-down mastoid surgery*. Otolaryngol Head Neck Surg, 1998. 119(5): p. 439-43.

*Corresponding author:*

**Dr. Matthew J Lin**

PO Box 2188, The Royal Melbourne Hospital

Victoria, 3050, Australia

e-mail: Matthew.Lin@alumni.unimelb.edu.au



**HEAD & NECK**  
EXPERIMENTAL MEDICINE



# **ORIGINAL RESEARCHES**





# ACUTE OTITIS MEDIA IN SAUDI CHILDREN: PATHOGENS AND THEIR RESPONSE TO ANTIBIOTICS



Alssum R.M., Alfrage D.M.

Department of Botany and Microbiology, Faculty of Science  
King Saud University  
Riyadh, Saudi Arabia

## Abstract

Acute otitis media is complicated by the emergence of common pathogens resistant to  $\beta$ -lactams and other antibiotics. The aim of the study reported here was to assess the distribution of pathogens by age, sex, disease groups and their resistance patterns on Saudi children. Swabs of middle ear were obtained from 142 assessable patients enrolled in the study during the winter of 2006-2007. Forty two swabs were found to be sterile or having uncultivable organisms, the rest one hundred contained isolates of which 40% displayed gram negative and 60 were gram positive. Most frequently isolates were Haemophilus Influenzae, (36.6%), Streptococcus pneumonia (25%), streptococcus pyogenes (20%), Staphylococcus aureus (15%) and Moraxella catarrhalis (3.4%). Antibiotic resistance patterns for the most commonly organisms that were repeatedly isolated during this study were H. influenza,  $\beta$ -lactamase producers, showed 35 (12.9) resistance against ampicillin, penicillin, erythromycin, bacitracin cephalosporin. For Streptococcus pneumoniae 20 (5) were resistance to penicillin, amoxicillin clavulanate, cephalosporin, tetracycline and less percentage to erythromycin 3 (0.75). For Streptococcus pyogenes 19 (0.2) showed resistance to amino glycosides, polymyxin and 4 (0.8) to tetracycline. For Streptococcus aureus 8 (1.2) were resistance to penicillin, polymyxin, and 4 (0.6) moderately resistance to erythromycin and tetracycline (table 1) The distribution of positive swab cultures and pathogens by disease, age, and sex groups indicated that male patients less than one year and five to ten years of age were more susceptible to acute otitis media infection than female.

**Keywords:** Pathogens, lactams, Resistan.

## Introduction

Acute otitis media (AOM) continue to be a universal problem with a debatable medical management and diagnostic criteria. The usefulness of antibiotics is threatened by antibiotic resistance amongst bacteria. In order to reduce this threat, sensible and rational antibiotic prescribing is required.<sup>1</sup> The controversy stems from the fact that six out of seven children with (AOM) improved with out antibiotic treatment operating on the principle that most (AOM) episodes resolve without antibiotics. Doctors in the Netherlands usually manage AOM in children with initial observation and Prescription of antibiotics is limited to children with a complicated course of AOM and those categorized as high risk.<sup>2</sup> Otitis media with effusion (OME) is the most common bacterial infection among children, accounting for as many as 30 million office visits annually. Proper treatment has become critical as offending pathogens become increasingly resistant to antibiotics and the cost of managing the disorder has exceeded 3 billion dollars per year, however, data suggest that many practitioners still struggle with the diagnosis of (OME) and often recommend medical and surgical intervention inappropriately.<sup>3</sup> Adherence with antibiotic therapies is generally poor among adults.<sup>4</sup>

Furthermore, experts have suggested that AOM treatment should be based on AOM severity, but there are no clinical trials using standardized methods for assessing AOM. Meta-analyses and systematic reviews of the literature have found a spontaneous resolution rate of 81% compared with a 93% resolution rate with antibiotic therapy, for an overall benefit of shortening the course of AOM by 1 day in 1 of 8 children treated.<sup>5</sup> There is a world wide consensus regarding the causative organisms of (AOM) with *St. pneumoniae*, *H. influenza* and frequently isolated other pathogens.<sup>2</sup> The prevalence of antibiotic resistance among OME and AOM pathogens have been the subject of multinational and multi-institutional studies.<sup>6</sup>

## Materials

Infants and children up to 2 and 13 years of age respectively, who met the criteria of acute otitis media (AOM) without tympanic perforation, AOM with tympanic perforation and otitis media with effusion (OME) fluid in the middle ear with out other symptoms and the fluid contained bacteria. Middle ear swabs, otoscope and small rubber bulb, blood and chocolate agar plates, penicillin, erythromycin, ampicillin, cephalosporin, tetracycline, aminoglycoside, calvulanate, polymyxine 1st generation, bacitracin.

## Methods

Criteria of AOM fluid in the middle ear accompanied by signs of an ear infection, such as: pain, redness or bulging eardrum; children with these symptoms and having fever were included in this study. The diagnosis of the (AOM) and (OME) had been based on otoscope findings of either middle ear

infusion or purulent otorrhea at the clinics of King Abdulaziz University Hospital, in Riyadh, Saudi Arabia. It was confirmed the presence or absence of fluid in the ear. Middle ear samples were collected on swabs in duplicates and this has been accomplished by looking carefully in the ear with an otoscopy using a small rubber bulb to push air against the eardrum by experienced observers. The swabbed samples were submitted to experts at the main investigation laboratory as reference. Soon after submission, initial isolation procedures were performed on blood and chocolate agar plates. The *in vitro* activities of ten antimicrobial agents against four clinical isolates of gram negative and gram positive bacteria were tested using broth micro dilution technique. Taking each strain, the MIC ( $\bar{I}g/l$ ) values 3 0.03, 0.06, 0.125, 0.25, 0.5, 1, 2 of penicillin, erythromycin, ampicillin, cephalosporin, tetracycline, aminoglycoside, calvulanate, polymyxine 1st generation and bacitracin were determined by the method proposed by.<sup>7</sup>

## Results

Swabs of middle ear were obtained from 142 assessable patients enrolled in the study during the winter of 2006-2007. Forty two swabs were found to be sterile or having uncultivable organisms, the rest one hundred contained isolates of which 40% displayed gram negative and 60 were gram positive strains. The distribution of positive swab cultures pathogens by disease groups, age groups and sex, indicated that male patients less than one year and five to ten years of age are more susceptible to AOM than female (figure 1) The most frequently isolated pathogens were *H. influenza* (36.6%) which was followed by *S. pneumoniae* (25%), *S. pyogenes* (20%), *St. aureus* (15%) and *M. catarrhalis* (3.4%). Antibiotic resistance patterns for the most commonly organisms that were repeatedly isolated during this study were *H. influenza*,  $\beta$ -lactamase producers, showed 35 (12.9) resistance against ampicillin, penicillin, erythromycin, bacitracin cephalosporin. For *Streptococcus pneumoniae* 20 (5) were resistance to penicillin, amoxicillin clavulanate, cephalosporin, tetracycline and less percentage to erythromycin 3 (0.75). For *Streptococcus pyogenes* 19 (0.2) showed resistance to amino glycosides, polymyxin and 4 (0.8) to tetracycline. For *Streptococcus aureus* 8 (1.2) were resistance to penicillin, polymyxin, and 4 (0.6) moderately resistance to erythromycin and tetracycline (table 1).

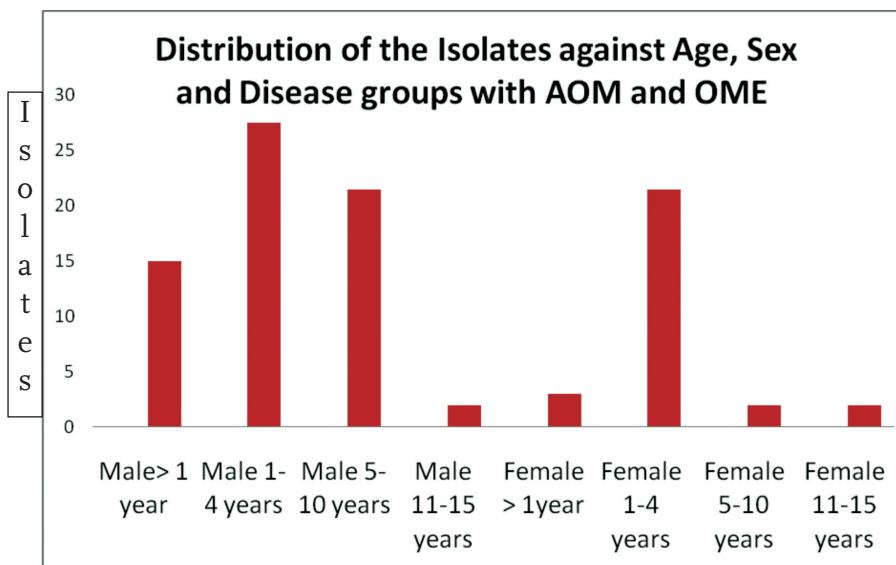
## Discussion

It is well known that (AOM) is a common childhood infection and if persisted may lead to various complications and serious illness, loss of hearing, speech impairment, haematogenous dissemination.<sup>8</sup> *Streptococcus pneumoniae* is the single most important cause of acute purulent meningitis, occurring in 47% of cases of acute bacterial meningitis.<sup>9</sup> There is a world wide consensus regarding the causative organisms of (AOM) with *St. pneumoniae*, *H. influenza* and frequently isolated other pathogens.<sup>2</sup>

**Table 1** - In vitro activity of 10 antibacterial agents against gram positive and gram negative bacteria isolates: distribution of MIC values.

|                          | Distribution of MIC (µg/ml)   |            |        |
|--------------------------|---|------------|--------|
|                          | ≥ 0.03, 0.06, 0.12, 0.25, 0.5, 1, 2, 3, 4   |            |        |
| Organism                 | Antimicrobial agent   | Resistance | %      |
| Haemophilus influenza    | Penicillin, Ampicillin<br>Cephalosporin, Erythromycin<br>and Bacitracin             | 35         | (12.9) |
| Streptococcus Pneumoniae | Penicillin, Amoxillin,<br>Calvulanate, cephalosporin,<br>Tetracycline, Erythromycin | 20         | (5)    |
|                          |   | 3          | (0,75) |
| Streptococcus pyogenes   | Aminoglycoside, Polymyxine,<br>tetracycline   | 19         | (0,2)  |
|                          |   | 4          | (0,8)  |
| Streptococcus aureus     | Penicillin, Polymyxine,<br>Erythromycin, Tetracycline                               | 8          | (1,2)  |
|                          |   | 4          | (0,6)  |

**Figure 1** - Distribution of the pathogens by diseases, age and sex groups.



The controversy stems from the fact that six out of seven children with acute otitis media improved with out antibiotic treatment operating on the principle that most acute otitis media (AOM) episodes resolve without antibiotics. Doctors in the Netherlands usually manage AOM in children with initial observation and Prescription of antibiotics is limited to children with a complicated course of AOM and those categorized as high risk.<sup>2</sup> The cost of managing the disorder has exceeded 3 billion dollars per year, however, data suggest that many practitioners still struggle with the diagnosis of (OME) and often recommend medical and surgical intervention inappropriately.<sup>3</sup> AOM should possess characteristics with therapy adherence to antibiotic therapy implications to the health plan as parental and caregiver attitudes indicate an increased desire for antibiotic adherence among their children.<sup>4</sup> The prevalence of antibiotic resistance among (OME) pathogen has been the subject of multinational and multi-institutional studies.<sup>6</sup>

The crisis of elevating resistance among the pathogens with *St. Pneumoniae* is taking the lead to address (OME) as global health problem and justifying the need for an annual evaluation of the clinical, microbiological and medical management.<sup>10</sup> To our knowledge, such assessment in Saudi Arabia goes back to the year 1984.<sup>11</sup> To counter the problem of intervention, infection, and antimicrobial resistance and to provide awareness of the situation, therefore, we conducted this investigation to clarify the recent situation concerning pathogens and their antibiotic patterns resistance. The most frequently reported etiological pathogens of otitis media are, in decreasing order, *S. pneumoniae*, *H. influenzae* and *M. catarrhalis* *S. pyogenes* and *St. aureus*.<sup>12</sup> In our studies the picture was vague due to the lack of local reference studies for the last ten years. However, a divergence from the international published data were noticed, bacterial cause of otitis media could be isolated from 71% of the patients, the higher was 61%.<sup>13</sup> Emergence of methicillin resistance, *S. aureus* and intracellular nature of non-typable *Haemophilus*. may be declaring the misfortune of the young generation due to the antibiotic resistance pattern to be within the range observed in recent studies.<sup>13</sup> However, owing to the new trends, the delay in the treatment of (OME) may be a result of low antibiotic concentration and short period of pathogen exposure at the site of infection. Therefore, the eradication of organisms causing AOM from the ear cavity with the use of antibiotics is greatly reduced.<sup>14</sup> Pharmacodynamic may help in the eradication of some organisms but, also there may be persistent ones, still waiting for more research. Since endo-toxins are lip polysaccharides complex present on the outer surface of most gram negative bacteria it may function as persistent factors contributing in the AOM and OME infections, which are associates with H. Influenza, It is possible that endo- toxin may be responsible for the inflammation and fluid accumulation in the middle ear. An increased isolation of H. influenzae resistance taking the lead, instead of S. pneumoniae and rare isolation of M. catarrhalis, dictates the necessity for

wider evaluation of OME and AOM infection impact, especially in the light of the high birth rate in Saudi Arabia.

The proper reporting of the outcomes of this study in OME and AOM infection will allow characterization of the patients who would potentially benefit from the pharmacological therapy. In conclusion, the most frequently isolated pathogens in this study approach were H. influenza (36.6%). Antibiotic resistance patterns for the most commonly organisms that were repeatedly isolated during this study were H. influenza, B-lactamase producers. The distribution of positive swab cultures pathogens by disease groups, age groups and sex groups indicated that male patients less than one year and five to ten year of age are more susceptible to AOM and OME infection than female. The success of the pharmacological therapy prior to surgery, in OME and AOM interventions necessitates critical proper treatment. We do agree antibiotic administration as first treatment but proper treatment has become critical, as offending pathogens become increasingly resistant to antibiotics.

## References

1. Tunger O, Karakaya Y, Cetin CB, Dinc G, Borand H. Rational antibiotic use. *J Infect Dev Ctries.* 2009;3:88-93.
2. Palma S, Fiumana E, Borgonzoni M, Bovo R, Rosignoli M, Martini A. Acute mastoiditis in children: "Ferrara" experience. *Int J Pediatr Otorhinolaringol.* 2009;71:1663-1669.
3. Darrow DH, Dash N, Derkay CS. Otitis media: concepts and controversies. *Curr Opin Otolaryngol Head Neck Surg.* Dec\ 2003;11(6):416-423\.
4. Brixner DI. Improving acute otitis media outcomes through proper antibiotic use and adherence. *Am J Manag Care.* Aug\ 2005;11(6 Suppl):S202-210\.
5. Coco AS. Cost-effectiveness analysis of treatment options for acute otitis media. *Ann Fam Med.* Jan-Feb\ 2007;5(1):29-38\.
6. McCormick DP, Chonmaitree T, Pittman C. Nonsevere acute otitis media: a clinical trial comparing outcomes of watchful waiting versus immediate antibiotic treatment. *Pediatrics.* 2005;115:1455-1465.
7. Schaumann R, Ackermann G, Pless B, Claros MC, Goldstein EJ, Rodloff AC. In vitro activities of fourteen antimicrobial agents against obligately anaerobic bacteria. *Int J Antimicrob Agents.* Nov\ 2000;16(3):225-232\.
8. Ochi K, Miyamoto Y, Ohashi T. Pediatric bilateral facial nerve palsy secondary to acute otitis media. *Auris Nasus Larynx.* 2003;30:s97-s98.
9. Erdem H, Pahsa A, Oncu S. Antimicrobial therapy in pneumococcal meningitis: an epidemiological assessment from Turkey. *Int J Infect Dis.* May\ 2006;10(3):262-263\.
10. Hsu PJ, Lee CH, Lee FY, Liu JW. Clinical and microbiological characteristics of mycotic aneurysms in a medical center in southern Taiwan. *J Microbiol Immunol Infect.* Aug\ 2008;41(4):318-324\.

11. Eiad A, Hamza A, Gulam J, Mukhdomi, Abdulmageed K, Hamad S, et al. Microbiology and Antimicrobial Sensitivity of Suppurative Otitis Media. *Saudi Med J*. 1984;19:417-422.
12. Oguz F, Unuvar E, Suoglu Y, Erdamar B, Dundar G, Katircioglu S, et al. Etiology of acute otitis media in childhood and evaluation of two different protocols of antibiotic therapy: 10 days cefaclor vs. 3 days azitromycin. *Int J Pediatr Otorhinolaryngol*. 2003;67:43-51.
13. Stone KC, Dagan R, Arguedas A, Leibovitz E, Wang E, Echols RM, et al. Activity of faropenem against middle ear fluid pathogens from children with acute otitis media in Costa Rica and Israel. *Antimicrob Agents Chemother*. Jun 2007;51(6):2230-2235.
14. Hickner J. A new look at an old problem: inappropriate antibiotics for acute respiratory infections. *Ann Fam Med*. Nov-Dec 2006;4(6):484-485.

*Corresponding Author:*

**Dr. Omar Shair**

Department of Botany and Microbiology, Faculty of Science

"King Saud" University

P.O. Box 2455

Riyadh 11451, Saudi Arabia

fax: 966146775833

e-mail: oshair@hotmail.com





# MINIMAL ACCESS ENDOSCOPIC ATTIC EXPLORATION MADE POSSIBLE THROUGH THE USE OF A KWILLS FILLING TUBE: A NOVEL APPROACH TO ATTIC CHOLESTEATOMA



Amir Farboud, Aaron Trinidad, Rohit Pratap, Paul Leong

Head and Neck Surgery Department

Edith Cavell Hospital

Peterborough

England, UK

## Abstract

Combined approach tympanoplasty (CAT) can be facilitated through the use of microscopy and endoscopy. For disease that is limited to the attic alone, re-look CAT can be successfully performed through an endoscopic minimal access approach that allows for both visualization of the attic and surgical removal of recurrent or residual disease as a day case procedure. In the presence of more extensive disease, endoscopic minimal access attic exploration aids in the effective planning of further open surgery. Endoscopic minimal access attic exploration allows for a quicker recovery time, and earlier return to work. It also negates the need to book large blocks of operating time on in-patient lists, as occurs in standard re-look CAT. We present a Short Scientific Communication outlining the results from the first 5 cases of patients to undergo minimal access Endoscopic attic exploration, through the use of Kwills filling tube.

*Keywords:* Kwills Filling Tube, Tympanoplasty, Cholesteatoma, Surgery


## Introduction

Combined approach tympanoplasty (CAT) is one of many techniques used in the management of acquired cholesteatoma of the middle ear, the main advantages being that it avoids the post-operative management of a mastoid cavity and results in a normal functioning ear canal. The very nature of CAT currently necessitates a staged procedure to rule out residual or recurrent disease.<sup>1</sup>

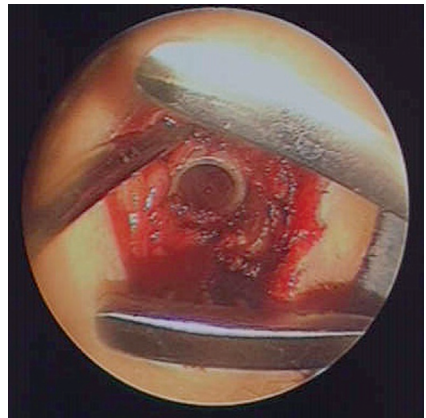
Following primary CAT (CAT-1), subsequent CAT is usually approached surgically in a similar fashion and is associated with a similar amount of post-operative morbidity. The morbidity has been shown to be less if a subsequent

CAT is performed through the combined use of an operating microscope and an endoscope.<sup>2</sup> Endoscopy has been shown to help in selecting the appropriate surgical technique to be undertaken in the event of residual or recurrent disease, and aids in the identification of those patients in whom cholesteatoma can be removed by a trans-canal approach alone.<sup>3,5</sup> Endoscopy may also aid in the better understanding of cholesteatoma and improved eradication of residual disease from hidden areas such as the anterior epitympanic recess, retrotympanum, and hypotympanum not yet controllable by the operating microscope.<sup>6</sup>

We describe a further modification of an endoscopic technique by the use of a minimal access approach through the use of a sterile, firm, plastic filling tube (Kwills, Universal Hospital Supplies [Uhs] Ltd, UK; Uhs reference: UN888; [www.uhs.co.uk/product.php?c=67](http://www.uhs.co.uk/product.php?c=67)) (figure 1), thereby further decreasing post-operative morbidity, the operating time needed and the amount of time needed for the patient to return to normal activities.



**Figure 1** - Kwills filling tube with lipped end, used to create a soft tissue tunnel through which endoscopy of the attic can occur.

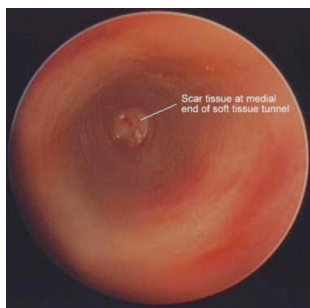

**Figure 2** - Lipped end of Kwills tube at edge of mastoid bowl exposed through a 1 cm post-auricular incision.

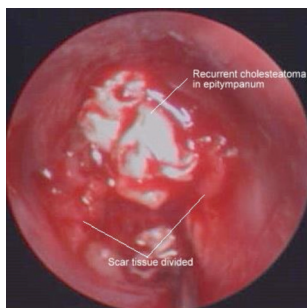
### **Surgical technique**

In a small pilot group of five patients who have previously had CAT-1 for attic disease we have performed a minimal access endoscopic attic exploration as a day-case procedure. During CAT-1, we meticulously remove all macroscopic

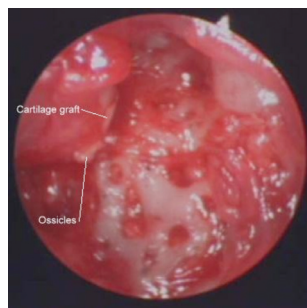
squamous epithelium and perform a primary ossiculoplasty if possible. Disease in the attic has been shown to be one of the commonest sites of recurrence at the second look procedure and is often the only site of recurrence.<sup>7,8</sup> We feel that, in a very select group of patients, this pattern of disease recurrence can be fairly confidently predicted. These are patients in whom the disease at CAT-1 is located only in the attic but not patients who have extensive mesotympanic, sinus tympani or antral disease. In our opinion this latter group of patients require a conventional CAT-2 approach. However in the former group (attic disease only), a Kwills filling tube is cut to fit within the mastoid bowl, the distal cut end being enlarged and placed such that an excellent view is made through to the attic and posterior tympanotomy. In our experience this gives excellent subsequent visualization of the epitympanic recess and integrity of the ossiculoplasty via an endoscope placed through the lumen of the soft tissue tunnel thus created once the Kwills tube is gently extracted. The lipped proximal end of the tube is left slightly protruding beyond the mastoid bowl edge and the skin edges closed over it.



**Figure 3** - Soft-tissue tunnel created 1 year after Kwills tube was inserted within mastoid bowl at time of original CAT.



**Figure 4** - Recurrent cholesteatoma visible in epitympanum following division of scar tissue at medial end of soft tissue tunnel.



**Figure 5** - View of attic after endoscopic removal of cholesteatoma.

This slight protrusion allows visual and tactile localization of the tube under the post-auricular skin during subsequent minimal access surgery in a year's time.

Once the end of the tube is located, a 1-cm minimal access stab incision is made directly over it and the surrounding soft tissue is retracted. (figure 2) The tube is then removed, leaving behind a soft tissue tunnel described above which links the edge of the mastoid bowl to the attic. (figure 3) Endoscopy is readily performed via this tunnel. Access to the middle ear is initially hindered by scar tissue that develops at the end of the tunnel. This is easily divided circumferentially with a sickle knife, with haemostasis being achieved by the use of cotton wool balls soaked in a 1:1000 adrenaline solution. Through

the use of 0, 30, 45 and 70 degree Hopkins rod telescopes, there is now a clear view of the attic, middle ear space and any previously inserted prosthesis and cartilage graft. The recurrence of a small recurrent pearl of keratin is also easily visualised if present. (figure 4) Complete endoscopic excision of recurrent or residual disease has been possible through this access, as in one of our cases shown here where residual cholesteatoma was found in only the epitympanum. (figure 5) This was possible through the soft tissue tunnel only without the need for creating a second portal. If recurrent disease is seen to be extending into areas where confident removal if not possible with this technique, the wound is closed and the patient is booked for a formal 2nd look CAT at a later date, although it must be stressed that in our experience this is very unusual (none of our cases) where patient selection has initially been good. The Kwills tube is then re-inserted to enable future endoscopy and the skin wound sutured. All patients make a full recovery, are discharged on the same day and are followed up at 3 and 12 months in the out-patient department. To date all five patients, with a minimum follow up of 6 months and maximum of 13 months, have remained free of residual or recurrent cholesteatoma or complications of surgery, have retained their pre-procedural levels of hearing and have returned to normal activities, including work, the following day.

## Discussion

The authors accept that the quoted follow-up times are relatively short for the natural history of chronic middle ear inflammatory disease, and that long-term data is not yet available. However, other similar endoscopic approaches quoted in the literature have not shown recurrence rates to be significantly higher than conventional approaches, thereby justifying the feasibility of this technique.<sup>4,5,9</sup>

In institutions where diffusion-weighted magnetic resonance imaging (MRI) is available and forms part of the standard practice of follow-up in cholesteatoma, the provisional diagnosis of recurrent or residual cholesteatoma can be made without the need for surgical intervention and future surgery planned accordingly.<sup>10,12</sup> The main limitation is that the lack of a hyperintense signal in diffusion-weighted MRI does not necessarily exclude a cholesteatoma.<sup>12</sup> Nonetheless, this imaging technique may eventually prove a useful screening tool for cholesteatoma as an alternative to re-look surgery.<sup>13</sup> However, in countries where otologists do not routinely use such imaging as part of their follow-up (many UK-based otologists do not), and in institutions where such facilities are not available, our technique may provide a useful alternative as a minimally-invasive 2<sup>nd</sup> and 3<sup>rd</sup> look procedure in low risk patients.

## Conclusion

Minimal access endoscopic attic exploration via a tube offers an alternative to CAT-2 in a select group of patients in whom CAT-1 has shown limited and predictable disease. In suitable patients, not only can limited disease be completely excised, it also allows discovery of disease extending beyond the attic on endoscopy, making the planning of future open surgery easier. Suitable patients can be operated as day-case procedures. All patients in our series returned to normal activity the following day with no short or long term sequelae from surgery. This has meant a more efficient use of theatre time when arranging operating lists. Further research is underway to investigate the impact of this novel approach on recurrent and residual disease rates and post-operative audiometric outcomes long-term.

## References

1. Sheehy JL, Brackmann DE, Graham MD. Cholesteatoma surgery: residual and recurrent disease. A review of 1024 cases. *Ann Otol Rhinol Laryngol.* 1977b;86:451.
2. Barakate M, Bottrill I. Combined approach tympanoplasty for cholesteatoma: impact of middle-ear endoscopy. *J Laryngol Otol.* 2008 Feb;122(2):120-4. Epub 2007 Jun 7.
3. Aoki K. Advantages of endoscopically assisted surgery for attic cholesteatoma. *Diagn Ther Endosc.* 2001;7(3-4):99-107.
4. Tarabichi M. Endoscopic management of limited attic cholesteatoma. *Laryngoscope.* 2004 Jul;114(7):1157-62.
5. El-Meselaty K, Badr-El-Dine M, Mandour M, Mourad M, Darweesh R. Endoscope affects decision making in cholesteatoma surgery. *Otolaryngol Head Neck Surg.* 2003Nov;129(5):490-6.
6. Presutti L, Marchioni D, Mattioli F, Villari D, Alicandri-Ciuffelli M. Endoscopic management of acquired cholesteatoma: our experience. *J Otolaryngol Head Neck Surg.* 2008 Aug;37(4):481-7.
7. Haginomori S, Takamaki A, Nonaka R, Takenaka H. Residual cholesteatoma: incidence and localization in canal wall down tympanoplasty with soft-wallreconstruction. *Arch Otolaryngol Head Neck Surg.* 2008 Jun;134(6):652-7.
8. Yung MW. The use of middle ear endoscopy: has residual cholesteatoma been eliminated? *J Laryngol Otol.* 2001 Dec;115(12):958-61.

9. Tarabichi M. Endoscopic management of cholesteatoma: long-term results. *Otolaryngol Head Neck Surg.* 2000 Jun;122(6):874-81.
10. De Foer B, Vercruyse JP, Bernaerts A, Deckers F, Pouillon M, Somers T, et al. Detection of postoperative residual cholesteatoma with non-echo-planar diffusionweighted magnetic resonance imaging. *Otol Neurotol.* 2008 Jun;29(4):513-7.
11. Fitzek C, Mewes T, Fitzek S, Mentzel HJ, Hunsche S, Stoeter P. Diffusion-weighted MRI of cholesteatomas of the petrous bone. *J Magn Reson Imaging.* 2002 Jun;15(6):636-41.
12. Teschner M, Hinz K, Stöver T, Lenarz T, Becker H. Diffusion-Weighted MRI in the Diagnosis of Cholesteatomas. *ORL J Otorhinolaryngol Relat Spec.* 2009 Jan 22;71(2):99-104. [Epub ahead of print]
13. Dhepnorrarat RC, Wood B, Rajan GP. Postoperative non-echo-planar diffusionweighted magnetic resonance imaging changes after cholesteatoma surgery: implications for cholesteatoma screening. *Otol Neurotol.* 2009 Jan;30(1):54-8.

*Corresponding Author:*

**Amir Farboud**

Head and Neck Surgery Department

Edith Cavell Hospital

Peterborough

England, UK

tel.: 01733 874000

e-mail: amirfarboud@doctors.net.uk

# DISSASSEMBLY - MODELLING - REASSEMBLY: A NEW TECHNIQUE IN AESTHETIC AND FUNCTIONAL SURGERY OF THE NOSE

SMONTAGGIO - MODELLAMENTO - RIMONTAGGIO: UNA NUOVA  
TECNICA NELLA CHIRURGIA ESTETICA E FUNZIONALE DEL NASO



Daniela Cerrone\*, Alessandro De Stefano\*\*,  
Alessandro Cerrone\*, Sante Cerrone\*

\* Clinica ORL, Ospedale "Casa Sollievo della Sofferenza"  
San Giovanni Rotondo, Foggia, Italy

\*\* Istituto di Otorinolaringoiatria, Dipartimento di Scienze Chirurgiche,  
Sperimentali e Cliniche, Università degli Studi "G. d'Annunzio"  
Chieti-Pescara, Italy

## Abstract

The rhinoplasty is considered one of the most challenging in the context of cosmetic surgery, especially when it is necessary to combine aesthetics and function.

The technique Disassembly-Reassembly-Modeling, which we developed from about 10 years, is indicated mainly in big noses, diverted and gibbous nasal pyramid.

It consists essentially in removing systematic quadrangular cartilage, according to modeling of the nose to be obtained and reintegration of the same, after performing the various respiratory any corrections, the median gibbotomy or osteotomy, the lateral osteotomies, and if necessary, the surgery of nasal tip.

Over the past 3 months were performed 33 rhino-septoplasties, including 26 primary and secondary 7 with the technique above.

In all it has achieved a good aesthetic result and a normalization of nasal patency.

*Keywords:* Rhinoplasty, Aesthetic Surgery, Nose, Quadrangular cartilage

## Italian Abstract

La rinoplastica è considerata uno degli interventi più impegnativi nell'ambito della chirurgia estetica, soprattutto laddove è necessario conciliare estetica e funzione.

La tecnica Smontaggio-Modellamento-Rimontaggio, da noi messa a punto da circa 10 anni, è indicata soprattutto nei nasi grandi, gibbosi e devianti.

Essa consiste essenzialmente nella rimozione sistematica della cartilagine quadrangolare, modellamento a seconda del naso che si vuole ottenere e reinserimento della stessa, dopo aver eseguito le varie eventuali correzioni respiratorie, la gibbotomia o osteotomia mediana, le osteotomie laterali e se necessario la chirurgia della punta nasale.

Negli ultimi 3 mesi sono state eseguite 33 rinosettoplastiche, di cui 26 primarie e 7 secondarie con la tecnica sopra citata.

In tutte si è ottenuto un buon risultato estetico ed una normalizzazione della pervietà nasale.

*Parole Chiave:* Rinoplastica, Chirurgia Estetica, Naso, Cartilagine Quadrangolare

## **Introduzione**

L'intervento di rinosettoplastica è una delle procedure più impegnative nel campo della chirurgia plastica. Essa necessita di una programmazione meticolosa e di una tecnica chirurgica senza compromessi, come nessun altro intervento chirurgico è in grado di fare.<sup>1,4</sup>

Il risultato di una rinoplastica può considerarsi buono quando il naso non sembra essere stato operato.<sup>1,2</sup>

Nel momento in cui si selezionano le alternative per correggere specifiche deformità, un chirurgo deve avere la conoscenza di tutte le tecniche e sapere che ognuna di esse ha un determinato grado di efficacia che dipende dal livello di conoscenza e dalle competenze tecniche del chirurgo.

Quando si selezionano le tecniche e si programma l'intervento, bisogna sapere che ogni tecnica possiede vantaggi ma anche svantaggi che devono essere ponderati a fronte di potenziali benefici.

Nessuna tecnica d'altronde è completamente esente da svantaggi e compromessi.<sup>3,6</sup>

Ogni chirurgo ha un preciso obiettivo: trattare principi e tecniche che offrono l'opportunità di garantire risultati prevedibili e controllati a qualunque livello di esperienza clinica.

In questo articolo ci proponiamo di illustrare una tecnica chirurgica, la Smontaggio-Modellamento-Rimontaggio (SMR) da noi messa in atto da diversi anni, che riteniamo essere di facile attuazione ed attuabile in qualsiasi tipo di naso.

## **La tecnica SMR**

La tecnica SMR fa riferimento al modo di utilizzo della cartilagine quadrangolare. Essa consiste nello scollamento sottomucoso del setto da entrambi i lati comprendente la cartilagine quadrangolare, la lamina perpendicolare dell'etmoide ed il vomere.

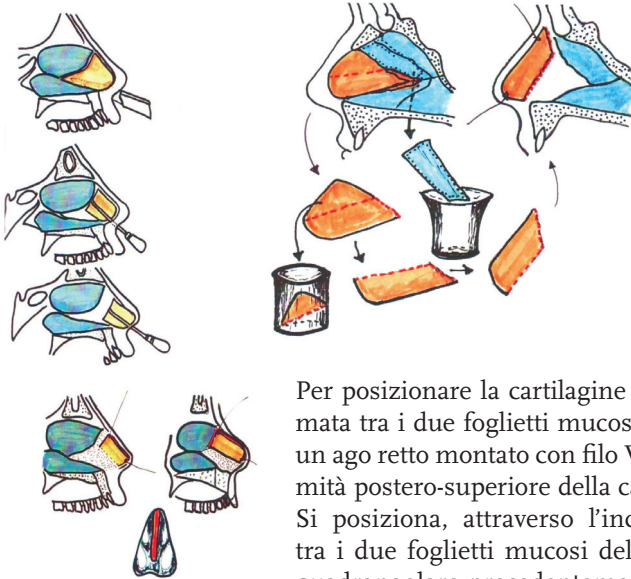
In seguito si esegue una condrotomia inferiore e posteriore ed infine si disloca la cartilagine quadrangolare a livello del dorso.



Una volta liberata la cartilagine quadrangolare da tutti e quattro i lati, la si estrae attraverso l'incisione emitrasfissa<sup>11</sup> (figura 1).

Risolti eventualmente i problemi respiratori, si esegue la chirurgia estetica con la classica gibbotomia o osteotomia mediana, le osteotomie laterali e se necessario la chirurgia della punta.<sup>5,8</sup>

A questo punto si prende la cartilagine quadrangolare, messa prima temporaneamente in fisiologica, si portano via le parti deviate e la si modella sul dorso, margine anteriore ed in altezza in modo che possa passare attraverso l'incisione emitrasfissa.



**Figura 1** - Asportazione per intero della cartilagine quadrangolare, suo modellamento e reinserimento attraverso l'incisione emitrasfissa.

**Figura 2**  
Fissazione del neosetto ai due foglietti mucosi settali.

Per posizionare la cartilagine quadrangolare sagomata tra i due foglietti mucosi del setto, si prende un ago retto montato con filo Vicryl e si lega l'estremità postero-superiore della cartilagine modellata. Si posiziona, attraverso l'incisione emitrasfissa, tra i due foglietti mucosi del setto, la cartilagine quadrangolare precedentemente sagomata e si fa passare l'ago con filo all'interno del naso verso l'esterno a livello della glabella, in modo da poter programmare l'altezza del naso.

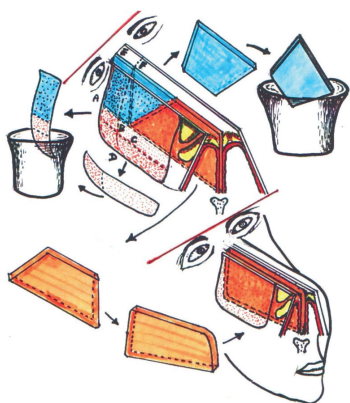
Con un altro ago retto si lega il lato anteriore corto della cartilagine modellata e si fa passare il filo attraverso la cute columellare.

Facendo leva su questi fili esterni, si posiziona la cartilagine dando la giusta altezza al dorso e la sporgenza voluta alla columella.

In seguito si fissa la cartilagine quadrangolare alla columella e ai due foglietti mucosi settali con tre punti trafissi.

Si pone il setto in asse con punti trafissi, il più lontano possibile dalla columella posteriormente.

Si fissa infine il neosetto ai due foglietti mucosi con delle placchette semirigide. A questo punto il neosetto diventa il fulcro su cui si adatterà il dorso del naso, la columella, l'angolo naso-labiale e l'angolo fronto-nasale (figura 2).



**Figura 3** - Il neosetto viene incastonato tra le lamine dei processi frontali del mascellare e tra le due crus medialis a livello della columella.

È ovvio aver eseguito dapprima, se necessario, la gibbotomia, le osteotomie laterali ed eventualmente la chirurgia della punta.

Il neosetto a questo punto viene ad essere incastonato nella parte dorsale tra le due lamine dei processi frontali del mascellare ed a livello della columella tra le due crus mediali.

Una leggera sporgenza della cartilagine quadrangolare rispetto alle due lamine dei processi frontali ci garantisce la linearità del dorso, una sagomatura della cartilagine quadrangolare ad angolo retto o leggermente ottuso sul margine caudale ci dà la possibilità di una variazione dell'angolo naso-labiale secondo necessità.

Lo stesso discorso vale anche per l'angolo naso-frontale (figura 3).

### Materiali e metodi e risultati

Utilizziamo questa tecnica da oltre dieci anni in maniera pressoché sistematica. Negli ultimi tre mesi (Marzo 2009-Maggio 2009) abbiamo eseguito 33 rinosettoplastiche, di cui 26 primarie e 7 secondarie con la tecnica SMR.

In tutte le rinosettoplastiche primarie il recupero della cartilagine quadrangolare rimossa è stata sufficiente per il reinserimento settale e per la ricostruzione dell'intero dorso e della columella.

Tutti i pazienti hanno avuto una normalizzazione della pervietà nasale.

Nelle rinosettoplastiche secondarie, in 4 pazienti il recupero della cartilagine quadrangolare è stato sufficiente per la ricostruzione dell'intero dorso.

In 3 pazienti, invece, abbiamo dovuto effettuare un assemblaggio di due o più pezzi di cartilagine residua recuperata utilizzando un supporto osseo prelevato dal naso dello stesso paziente.

Tra le rinoplastiche secondarie un paziente presentava una perforazione settale, epistassi recidivanti ed insufficienza respiratoria a causa della deviazione del setto.

Sfruttando la tecnica SMR e riducendo il volume dell'intera piramide nasale e dello stesso setto, abbiamo eliminato la perforazione ruotando la cartilagine quadrangolare in modo che la perforazione cartilaginea non coincidesse con la perforazione mucosa.

Con la riduzione volumetrica del setto in conseguenza della riduzione dell'intera piramide nasale, i margini mucosi della perforazione di concerto si sono avvicinati in modo centripeto ed in virtù del sostegno cartilagineo la perforazione si è chiusa senza bisogno di punti.

Il risultato è stato: la chiusura completa della perforazione, assenza di epistassi, normalizzazione della piramide nasale ed un buon profilo estetico.

### Discussione e conclusioni

La rinoplastica inventata da Joseph nel 1928, ha fatto dei progressi notevoli con la tecnica extramucosa di Andersen e quella fisiologica di Cottle.<sup>6,12</sup>

Negli anni poi si è evoluta allo scopo di conciliare l'estetica e la funzione respiratoria possibilmente nel corso dell'intervento.<sup>9,13,14</sup>

La tecnica SMR è indicata soprattutto nei pazienti che hanno un naso con deviazione di setto e piramide nasale, ovvero tutti quei nasi che necessitano di una chirurgia funzionale ed estetica ed in particolar modo i nasi lunghi, deviati e gibbosi (figura 4).

Essa presenta il vantaggio di poter essere eseguita in breve tempo, permette all'operatore di eseguire qualsiasi correzione della piramide e del setto poiché consente di arrivare sempre e facilmente sul vomere e sulla lamina perpendicolare dell'etmoide.

Essa presenta pochissime controindicazioni (figura 5).

Occorre una certa prudenza solo nelle rinoplastiche secondarie poiché non sappiamo quanta cartilagine è stata asportata dal chirurgo che ci ha preceduti. Inoltre la cartilagine quadrangolare residua deve essere in quantità sufficiente perché deve assolvere alla funzione di sostegno dell'intero dorso e della columella.

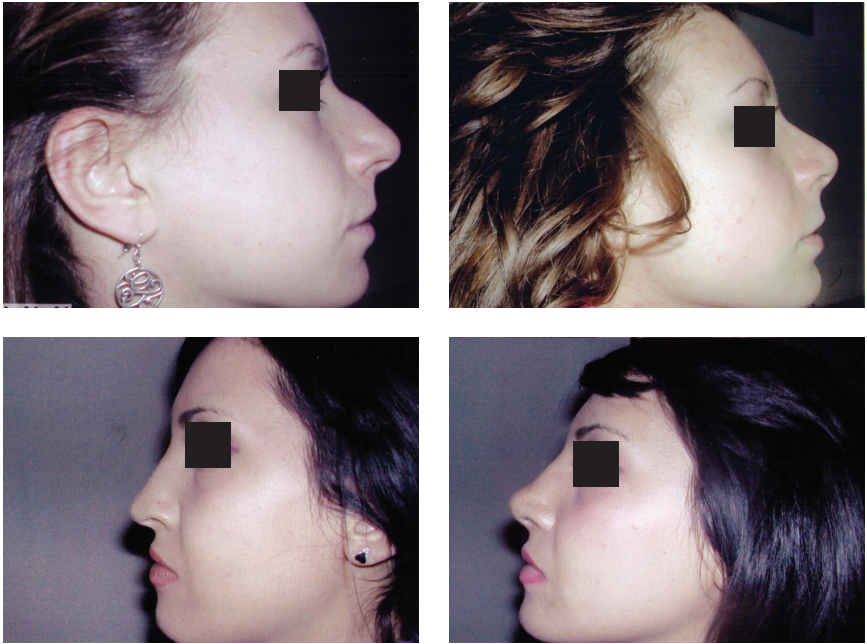
Qualora la cartilagine residua abbia delle curvature tali da non permettere un profilo rettilineo del dorso e della columella, si può utilizzare un pezzo di osso del setto sagomato a forma di asta e legato con punti transfissi alla cartilagine nel punto deviato in modo che faccia da sostegno per l'eliminazione della curvatura.<sup>10</sup>

Così pure se la cartilagine quadrangolare non bastasse, si può ricorrere al prelievo di materiale autologo come la cartilagine costale o quella auricolare.<sup>7</sup>

Nella nostra esperienza siamo sempre riusciti, anche nelle rinoplastiche secondarie, ad ottenere sufficiente cartilagine quadrangolare ricorrendo eventualmente ad assemblaggio di più pezzi tenuti assieme da supporti ossei o cartilaginei dello stesso paziente.

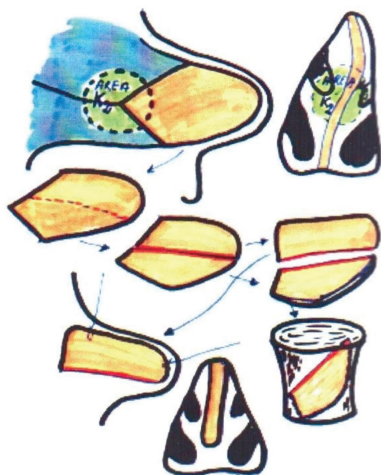

Figura 4 - Modifica dell'area K2 e risultato con l'attenzione della Tecnica SMR.



**Figura 5** - Immagini pre-operatorie (a sinistra) e post-operatorie dei nostri pazienti sottoposti a tecnica SMR.

## Bibliografia

1. Barman W.E. in "Dynamics of Nasal Surgery"; Rhinoplastic Surgery, Barman W.E.; The C.V. Mosby Company, St Louis 1989; 47-51.
2. Zaoli G. in "Considerazioni generali"; Rinoplastica Estetica, Zaoli G., Piccin Padova 1992; 115-119.
3. Meyer R. in "Rhinoplasty"; Aesthetic Plastic Surgery, III Vol, Gonzales -Ulloa M.- Mayer R.- Smith J.W. -Zaoli G.; Piccin, Padova 1988; 42.
4. Aiach G. in "Technique"; La Rhinoplastie Esthétique, Aiach G. - Levignac J.; Masson Paris 1989 ; 37 - 39.
5. Cerrone S. in "Chirurgia del Setto e della Piramide Nasale"; La Chirurgia Estetica e Funzionale del Naso, Cerrone S., Cerrone D.; Edizioni Le Nuove Muse 2007, San Marco in Lamis; 248-253.
6. Tercan M., Celik E.: The evaluation of transeptal transfixion incision of the nasal tip projection. Ann Plast Surg 2009 Jun; 62(6):609-12.
7. Maran A.G.D. - Lund V.J. in "Rinoplastica"; Rinologia Clinica, Maran A.G.D. - Lund V.J.; Maccarelli Editore, Roma 1991; 200-203.
8. Erisir F, Tahamiler R.: Lateral osteotomies in rhinoplasty: a safer and less traumatic method.

Aesthet Surg J. 2008 Sept-Oct; 28(5):518-20.

9. Anglana D. in "La Chirurgia della Valvola Nasale", La Chirurgia Funzionale ed Estetica del Naso, Villari G.– Pucci V.; ToGraf, Galatina 1998; 85.
10. Gentile P, Bottini DJ, Cervelli V. Rhinoplasty procedures: state of art in plastic surgery. J Craniofacial Surg. 2008 Nov;19(6):1491-6.
11. Ballert JA, Park SS: Functional consideration in revision rhinoplasty. Aesthet Surg J. 2008 Sep-Oct; 28(5):518-20.
12. T.D. Rees in "Considerazioni post-operatorie e complicanze", Chirurgia plastica estetica Vol I, T.D. Rees - La Trenta G.; Verducci Editore, Roma 2001; 328.
13. Sevhan A., Ozden S, Gungor M, Celik D. A double-layered, stepped spreader graft for the deviated nose. Ann Plast Surgery. 2009 Jun; 62(6):604-8.
14. Meyer R. in "Residual bony deformities"; Secondary and Functional Rhinoplasty. The Difficult Nose, Meyer R.; Grune and Stratton, Orlando 1988; 46-48.

*Corresponding Author:*

**Daniela Cerrone**

Clinica ORL, Ospedale "Casa Sollievo della Sofferenza"

Istituto di Ricovero e Cura a Carattere Scientifico

Viale Cappuccini, 1

71013 San Giovanni Rotondo (FG)

e-mail: danielacerrone@hotmail.it



# THE ENDOSCOPIC STAPLING OF PHARYNGEAL POUCHES: LONG TERM PATIENT OUTCOMES

Southern Health

MONASH  
UNIVERSITY



Floyd Gomes, Eduard Pudel

Department of Otolaryngology, Head & Neck Surgery  
Southern Health and Monash University  
Victoria, Australia

*This paper is based on previous presentations at the Marshall Prize, Monash Medical Centre 2008 and New Zealand Assoc of General Surgeons Annual Conference, Invercargill, New Zealand, 2009*

## Abstract

**Objective:** To determine<sup>1</sup> the quality of life<sup>2</sup> the complication rate and<sup>3</sup> the revision rate of patients post endoscopic stapling of pharyngeal pouches.

**Study Design:** Retrospective review

**Setting:** Southern Health is the largest healthcare network in Victoria catering to a diverse population. The Ear Nose and Throat, Head and Neck Surgery unit operates across four hospitals.

**Subjects & Methods:** ICD codes were used to search for all endoscopic and open pharyngeal pouch operations undertaken between 1 July 2002 and 30 June 2008 at Southern Health. Post operative quality of life was assessed via a telephone survey, the M.D. Anderson Dysphagia Inventory. Medical records were used to determine the rates of complication and revision operations.

**Results:** 19 patients underwent endoscopic stapling. The mean age was 76 years and mean follow up 31 months. The mean quality of life score was 79%, with a mean of 82% and 76% for those younger or equal to 76 years of age and those greater than 76 years of age respectively. The revision rate was 50% and complication rate was 21%. 4 patients had an open repair. The mean age was 57 years and mean quality of life was 97%. There was a 25% complication rate and zero revisions.

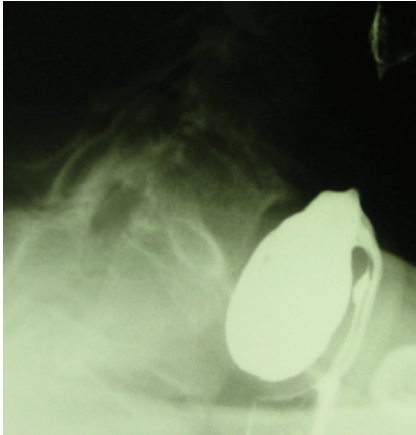
**Conclusion:** Patients have a good quality of life post endoscopic stapling of pharyngeal pouches. This effect is less pronounced in the elderly population. The higher recurrence and complication rates found in this study can be attributed to the learning curve and longer follow up.

**keywords:** Pharyngeal Pouches, Endoscopy, Zencker's diverticulum, Quality of Life




## Introduction

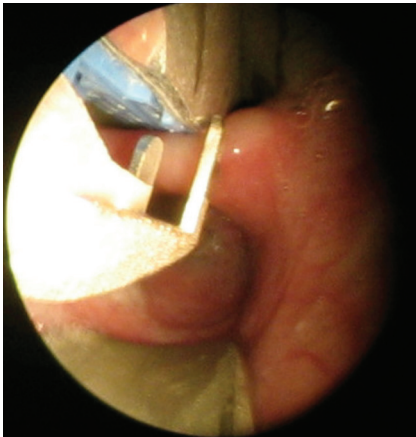
A pharyngeal pouch, or Zenker's diverticulum, occurs when the pharyngeal mucosa herniates through the muscles of the pharyngeal wall. This occurrence has been linked to gastro-oesophageal reflux and the subsequent cricopharyngeal spasm which it produces. The disease mainly occurs in the elderly since the pharyngeal musculature is generally weaker and the oesophagus has been exposed to prolonged pressure and reflux in this population.



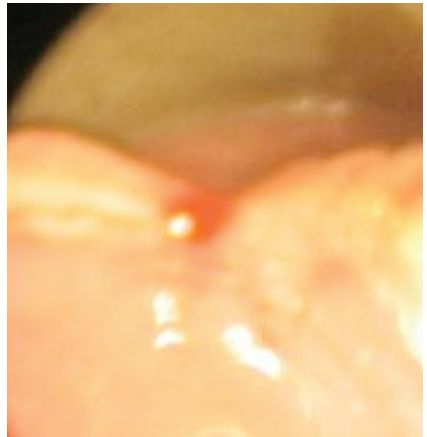**Figure 1** - Pharyngeal pouch as seen on barium swallow.



**Figure 2** - View of pharyngeal pouch (posterior) and oesophagus (anterior) as seen down the Weerda diverticuloscope.



**Figure 3** - Common wall between pouch and oesophagus about to be stapled, as viewed down Weerda diverticuloscope.



**Figure 4** - Common wall post stapling with oesophagus anterior and remnant pouch posterior.



It can cause troublesome regurgitation, dysphagia, weight loss, aspiration and even social isolation. A barium swallow is often used to initially assess for the presence of a pouch (figure 1).

Traditionally, an open procedure (OP), involving excision of the pouch, has been employed to correct the defect. However, this is a major operation and as such, may not be suitable for an elderly patient. Fortunately, an endoscopic approach has been pioneered. In 1960 Dohlman and Mattson advocated the use of diathermy to the common wall. Then in 1993 Martin – Hirsch et al commenced endoscopic stapling (ES)<sup>1</sup> and this approach has continued to gain worldwide popularity. ES involves the use of a bi-valved instrument with fibreoptic illumination, the Weerda diverticuloscope (Karl Storz, Tuttlingen, Germany), to achieve transoral division of the septum between oesophagus and pouch (the diverticulotomy) with a simultaneous cricopharyngeal myotomy (figure 2, 3, 4).

Due to the lower morbidity, shorter hospital stay, faster recovery and cost effectiveness, ES has in fact been hailed as something of a dream quick fix. However, fewer studies have been undertaken to investigate the longer term outcomes of ES. We decided to investigate the quality of life (QOL) post endoscopic stapling and open repair of pharyngeal pouches within Southern Health, Victoria, Australia which houses a busy Ear Nose and Throat unit operating over three separate hospitals. We also decided to analyse the rates of complication and pouch revision.

## Methods

We conducted a retrospective review of all pharyngeal pouch operations performed between 1 July 2002 and 30 June 2008 within the Southern Health network. The study design was initially submitted to the Southern Health Research Directorate. They considered the design consistent with a Quality Assurance activity and as such formal Ethics Committee approval was not required. The M.D. Anderson Dysphagia Inventory<sup>2</sup> survey was used to assess the quality of life outcome for patients identified as having ES or OP. This survey was originally designed to assess the impact of dysphagia for patients with head and neck cancer and includes four subscales – global, emotional, functional, and physical. The emotional, functional and physical subscales are summed and divided by 0.95 to give a score out of 100, where 100 indicates maximum QOL. The global subscale is rated separately out of five. The survey in detail is listed below in Table 1.

Patients were interviewed by telephone to generate their M.D. Anderson Dysphagia Inventory score. Complication rates and revision rates were ascertained from detailed examination of the medical records. A patient was classified as requiring a revision if their symptoms recurred post ES to an extent requiring further ES or OP.

**Table 1** – M.D. Anderson Dysphagia Inventory**Global subscale (5 points)**

My swallowing ability limits my day to day activities (strongly agree, agree, no opinion, disagree, strongly disagree)

**Emotional Subscale (30 points)**

I am embarrassed by my eating habits  
 I do not feel self-conscious when I eat  
 I am upset by my swallowing problem  
 I do not go out because of my swallowing problem  
 Other people are irritated by my swallowing problem  
 I have low self esteem because of my swallowing problem

**Physical subscale (40 points)**

Swallowing is more difficult at the end of the day  
 Swallowing takes great effort  
 It takes me longer to eat because of my swallowing problem  
 People ask me – “why can’t you eat that”  
 I cough when I try to drink liquids  
 I limit my food intake because of my swallowing difficulty  
 I cannot maintain my weight because of my swallowing problem  
 I feel that I am swallowing a huge amount of food

**Functional subscale (25 points)**

People have difficulty cooking for me  
 My swallowing difficulty has caused me to lose income  
 My swallowing problems limit my social and personal life  
 I feel free to go out to eat with my friends  
 I feel excluded because of my eating habits

**Results**

Our search identified 39 patients with pharyngeal pouches. 19 of these had ES only. 4 had an OP, 2 of which were done following ES. 7 patients were excluded as they did not have a pharyngeal pouch or they did not have a pharyngeal pouch operation. 3 were not contactable and 6 patients were deceased. The 19 ES and 4 OP patients were surveyed using the M.D. Anderson Dysphagia Inventory.

**All endoscopic procedures**

Of the 19 patients who underwent ES only, 14 were male and 5 were female. The stapler predominantly used was the Endo GIA 35, which creates a 35mm staple line. The mean age at time of the most recent procedure was 76, mean follow up 31 months and mean QOL score 79%. The complication rate was 21%, representing five patients of 23. 1 patient died day one post operatively from respiratory failure. His oesophageal biopsy showed poorly differentiated squamous cell carcinoma. Three patients had an oesophageal leak. 2 of these were treated conservatively. 1 progressed to requiring an emergency OP. 1 patient developed a haematoma during rigid oesophagoscopy and his procedure was aborted. He was treated conservatively. The revision rate was 50%,

representing 10 patients requiring revisions out of 20 patients, including 1 patient who went on to have OP.

### Subgroup analysis

#### *By Age*

Of the 19 patients who underwent ES, 9 were 76 years of age or younger (9 males and 0 females) and 10 were greater than 76 years (5 males and 5 females). For those 76 years or younger, mean follow up was 33 months, mean QOL was 82 (see Table 2) and mean revision rate was 60%. For those greater than 76 years, mean follow up was 35 months, mean QOL 76 (see Table 2) and mean revision rate was 40%.

**Table 2** - Mean QOL scores – Overall and by subscale

|                            | Overall | Global | Emotional | Functional | Physical |
|----------------------------|---------|--------|-----------|------------|----------|
| All ages                   | 79      | 71     | 79        | 87         | 73       |
| Less than or = to 76 years | 82      | 76     | 82        | 88         | 77       |
| > 76 years                 | 76      | 66     | 76        | 86         | 69       |

#### *By Revision*

Of the 19 patients, 10 did not require a revision procedure (7 male, 3 female) and 9 required an endoscopic revision procedure (7 male, 2 female). Those who did not require revision had a mean age of 76 years, mean follow up 30 months and mean QOL 79%. Those requiring revision also had a mean age of 76 years, mean follow up 40 months, mean QOL 78%.

### All open procedures

Four patients underwent an open procedure (4 males, 0 females). The mean age was 57, mean follow up 31 months and mean QOL score was 97%. The complication rate was 25% representing one patient who had an oesophageal leak which was treated conservatively.

### Discussion

ES continues to grow in popularity as the primary treatment modality for pharyngeal pouches. However, the stapling of pouches can be technically challenging. Essentially, staple too much and the risk of oesophageal perforation rises; staple too little and the effect of the procedure diminishes and risk of pouch recurrence rises. The balance is fine. Of note, in our department we

found that the reloading of the Endo-GIA 35mm (TYCO Health Care) stapler so as to achieve a longer staple line was linked to an increased rate of oesophageal leaks. A recent publication by Roth et al<sup>3</sup> supports this finding. Overall, ES is a delicate procedure and in reporting results the learning curve becomes crucial. Our department's results include our learning curve. We feel that this is the reason why both our revision rate of 50% and complication rate of 21% is higher than that published elsewhere.<sup>4,5,6</sup> In general, technically demanding procedures undertaken infrequently are likely to show results inferior to those widely published which tend to originate from highly specialised centres. To this end, there is merit to the view expressed by Mirza S et al.,<sup>7</sup> who suggests that surgeons should sub-specialise into ES. Our findings support this. Additionally, we feel our mean follow up of 31 months was adequate to capture a more accurate revision rate. Regarding the 1 death which occurred, this patient was palliated following the diagnosis of poorly differentiated squamous cell carcinoma. His early post operative death at day one, in part represents this.

Notwithstanding the high rate of revision, the actual QOL achieved post procedure of 79% demonstrates that patients enjoy a relatively high quality of life following ES. It is somewhat vexing to explain then the lower global subscale score of 71%. Perhaps this reflects the fact that swallowing is such a fundamental action, that once it is altered, that is, once dysphagia is present, it remains a conscious imposition regardless of severity.

The mean age of patients undergoing ES of 76 years is encouraging. Comparing this to the open procedure mean age of 57 years demonstrates that ES is indeed making pharyngeal pouch correction accessible to the elderly. The lower QOL scores for those greater than 76 years is conceivably because dysphagia is more likely to be multifactorial in an elderly population. This theme came through in survey respondents. Neurological disease, dementia, depression, malnutrition and polypharmacy, including the use of non steroidal anti-inflammatory drugs leading to higher rates of associated gastro-oesophageal reflux disease and immobility can all contribute to actual and perceived dysphagia, and thus have the potential to impact negatively on the QOL post ES. For this reason, even more attention to careful patient selection must be given to the elderly in whom such co-morbid conditions are common. Our study highlights this.

Our short series of four cases of OP demonstrated a very high QOL post OP with no revision required. However this occurred within a distinctly younger age group and there was a higher complication rate. Also, we did not analyse the length of hospital stay which is greater post OP. Nonetheless, the high QOL and zero revision rate post OP does suggest that this a more definite cure for pharyngeal pouches when compared to ES. It is worthwhile mentioning here that, given the strong causal relationship between GORD, cricopha-

ryngeal spasm and the subsequent pouch development, post either procedure, patients should be placed on lifelong anti-reflux therapy consisting of twice daily proton pump inhibitors. This will help to decrease the chance of recurrence.

Limitations to our study include the lack of blinding. The telephone interview was conducted after the medical records had been scanned. This leaves open the possibility of observer bias. Furthermore, for 2 patients with significant dementia, carers were asked to complete the survey, thus the results for these patients may not be entirely accurate. Lastly, since this study is retrospective, we do not know what change, or increase in QOL ES actually delivers. To determine this, a prospective study, including a preoperative QOL score is required. It would be worthwhile conducting such a study given the increasing use of ES, particularly in the elderly – a rapidly growing population. In the future, the results of ES, in terms of complication and recurrence rates may show improvement, as the procedure matures.

## References

1. Chang Y, Payyapilli R, Scher R. Endoscopic staple diverticulostomy for Zenker's Diverticulum: review of literature and experience in 159 consecutive cases. *Laryngoscope*. 2003; **113**: 957–65.
2. Chen Y, Frankowski R, Bishop-Leone J *et al*. The development and validation of a dysphagia-specific quality-of-life questionnaire for patients with head and neck cancer. *Arch Otolaryngol Head Neck Surg*. 2001; **77**: 870–6.
3. Roth J, Sigston E, Vallance N. Endoscopic stapling of pharyngeal pouch: A 10 year review of single versus multiple staple rows. *Otolaryngol Head Neck Surg*. 2009; **140**: 245–249.
4. Manni J, Kremer B, Rinkel R. The endoscopic stapler diverticulotomy for Zenker's diverticulum. *Eur Arch Otorhinolaryngol*. 2004; **261**: 68–70.
5. Van Eeden S, Lloyd V, Tranter R. Comparison of the endoscopic stapling technique with more established procedures for pharyngeal pouches: results and patient satisfaction survey. *Journal of Laryngology and Otology*. 1999; **113**: 237–40.
6. Aly A, Devitt P, Watson D *et al*. Endoscopic stapling for pharyngeal pouch: does it make the cut. *ANZ J Surg*. 2003; **74**: 116–21.
7. Mirza S, Dutt S, Minhas S *et al*. A retrospective review of pharyngeal pouch surgery in 56 patients. *Ann R Coll Surg Eng*. 2002; **84**: 247–51.

*Corresponding author:*

**Floyd Gomes**

18 Milverton Street, Camberwell, Vic 3124

phone/fax: +613 98091789

mob.: +61429992286

e-mail: fgomes2003@hotmail.com

**HEAD & NECK**  
EXPERIMENTAL MEDICINE



# **CLINICAL REPORTS**





# SPONTANEOUS HAEMOTYMPANUM: AN UNCOMMON PRESENTATION OF OTITIS MEDIA WITH EFFUSION



Aaron Trinidad, Amir Farboud, Claudine Horrocks  
Head and Neck Surgery Department  
Edith Cavell Hospital  
Peterborough, UK

## Abstract

*Objective:* We present the case of a gentleman with known otitis media with effusion presenting with a sudden drop in the hearing in his left ear.

*Method:* Case report.

*Results:* He was found to have a spontaneous left haemotympanum.

*Conclusion:* Spontaneous haemotympanum is an uncommon presentation of chronic otitis media. To our knowledge, this is only the second case present in the English-speaking literature. The case is presented, awareness of its presence is raised and the management discussed.

*Keywords:* spontaneous haemotympanum, chronic, otitis media.

## Introduction

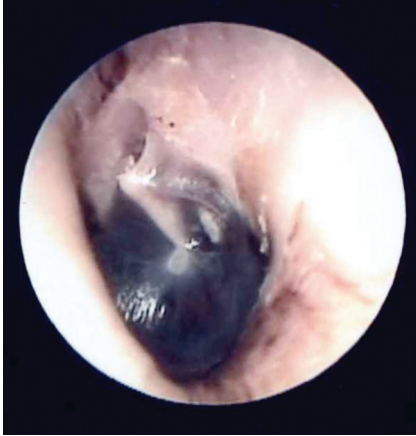Chronic otitis media with effusion presenting as a spontaneous haemotympanum is uncommon.<sup>1</sup> This case represents only the second of its kind reported in the English-language literature.

## Case Report

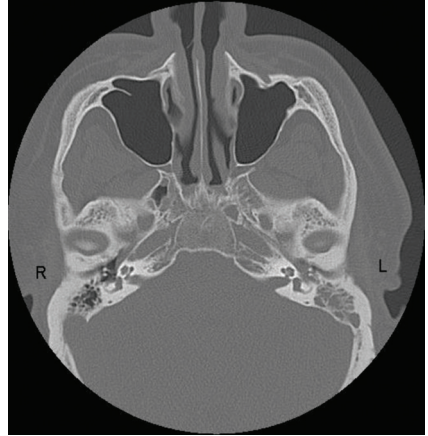
A 46-year old Caucasian gentleman with binaural digital hearing aids, known to our ENT Department for having a long history of bilateral conductive hearing loss secondary to chronic otitis media with effusion presented to the Audiology Department claiming that his left hearing aid had stopped working for one week. After examining his ears, the attending audiologist brought to our attention a blackish-bluish discolouration of his left tympanic membrane. (figure 1) There was evidence of drum retraction onto the incudostapedial joint. His hearing aids were found to be in good working order.

He did not give a recent history of head trauma, did not suffer from epistaxis and denied any history of bleeding disorders. Otherwise, he was fit and well, and was on no medications. He had three sets of grommets inserted in the

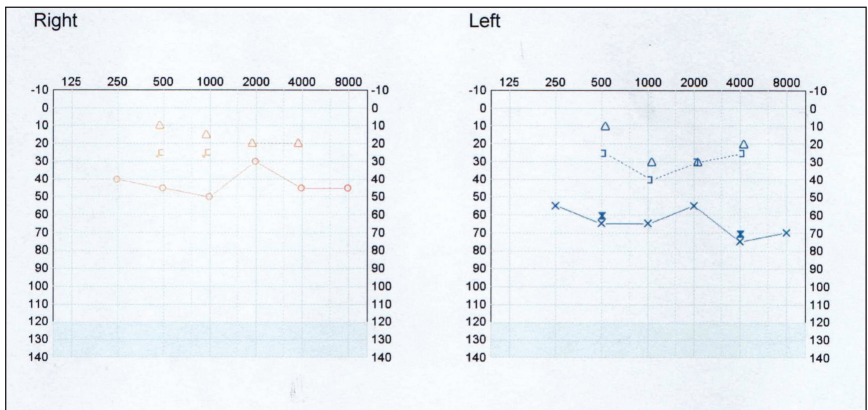
past, which did not resolve his middle ear effusions on extrusion, and eventually had one set of long-term tympanostomy tubes (Shah Permavent tubes) inserted at age 16. These needed to be removed 11 months later due to repeated infections in both ears. Following removal, the patient opted for hearing aids instead further surgical intervention.



**Figure 1** - Otoscopic view of left spontaneous haemotympanum.



**Figure 3** - Coronal CT scan of temporal bones showing left sided opacification of middle ear cavity and mastoid air cells as a result of the spontaneous haemotympanum. No bony erosion is noted.



**Figure 2** - Audiogram of patient following spontaneous left haemotympanum. A widened air-bone gap is seen on the left.

There was no tinnitus or vertigo associated with the new-onset reduction in his hearing. An audiogram was performed, which demonstrated a bilateral conductive hearing loss, worse on the left. (figure 2) The audiogram of the left ear represented a widening of the air-bone gap by 10 dB from his previous audiogram in keeping with the clinical picture. Tympanometry was also performed, and showed bilateral type B (flat) traces in keeping with his history of otitis media with effusion. A CT scan of his temporal bones showed complete opacification of the left mastoid air cells, extending into the supratympanic recess of the middle ear cavity, and surrounding the ossicles, which were intact. There was no evidence of bony erosion or retro-tympanic masses. The right middle and inner ear were found to be normal. (figure 3)

The patient was treated conservatively with observation only and went on to make a full recovery with complete resolution of the haemotympanum observed at four weeks' follow up. Repeat audiogram was performed at this time and revealed an return to pre-haemotympanum hearing thresholds, symmetrical to the right ear.

## Discussion

Haemotympanum is classically one of the signs of a skull base fracture.<sup>2</sup> Those occurring spontaneously are much more uncommon and may cause confusion in clinical diagnosis. The causes recorded in the literature include haemotympanum secondary to epistaxis, with resulting reflux of blood into the middle ear cleft via the Eustachian tube, occurring with or without nasal packing; secondary to idiopathic thrombocytopenia purpura, with resulting spontaneous bleeding of middle ear mucosa; secondary to warfarin use.<sup>3,6</sup>

In the setting of chronic secretory otitis media, it is thought that the spontaneous haemotympanum may be due to recurrent haemorrhages occurring in the chronically inflamed middle ear and mastoid air cells in the presence of Eustachian tube dysfunction. Indeed, a secretory chronic otitis media and spontaneous haemotympanum may both represent different phases of the same disease process.<sup>1</sup>

The diagnosis is, however, one of exclusion, and imaging is recommended to rule out the presence of congenital vascular malformation or bone erosion due to chronic otitis media or tumours.<sup>1</sup> Once made, the management is conservative, and the condition ultimately self-resolving.

## Conclusion

Spontaneous haemotympanum secondary to chronic otitis media with effusion is a rare, self resolving condition that probably represents a phase of the otitis media itself. A thorough history and relevant investigations are essential to rule out other causes of haemotympanum, and management is ultimately conservative.

## References

1. Lalwani AK, Jackler RK. Spontaneous hemotympanum associated with chronic middle ear effusion. *Am J Otol* 1991;12:455-8
2. Cannon CR, Jahrsdoerfer RA. Temporal bone fractures. Review of 90 cases. *Arch Otolaryngol* 1983;109:285-8
3. Evans TC, Hecker J, Zaiser DK. Hemotympanums secondary to spontaneous epistaxis. *J Emerg Med* 1988;6:387-9
4. Hurtado TR, Zeger WG. Hemotympanums secondary to spontaneous epistaxis in a 7-year-old. *J Emerg Med* 2004;26:61-3
5. B-Lajoie MR, El-Koussa L, Malaab S. Spontaneous bilateral hemotympanum in idiopathic thrombocytopenic purpura. *Paediatr Child Health* 2008;13:773-4
6. Balatsouras DG, Dimitropoulos P, Fassolis A, Kloutsos G, Economou NC, Korres S, et al. Bilateral spontaneous hemotympanum: case report. *Head Face Med.* 2006;2:31

*Corresponding author:*

**Aaron Trinidad**

ENT Department

Edith Cavell Hospital

Bretton Gate

Peterborough, UK

e-mail: aarontrinidad@gmail.com

fax: 01733875694

phone: 07834194047

# BILATERAL PSEUDOCYSTS OF THE AURICLE

PSEUDOCISTI AURICOLARE BILATERALE



**Francesco Lorusso, Francesco Dispenza**

U.O. Otorinolaringoiatria  
Dipartimento di Discipline Chirurgiche e Oncologiche  
Università degli Studi di Palermo  
Italy

## Abstract

The pseudocyst of the auricle is a rare disease of the ear and its etiology is still incompletely understood. Young adults seem to be the most affected and sometimes can occur bilaterally. There is no consensus regarding the treatment, in fact, in literature have been reported different management modalities with different results. The goal of any treatment should be the reduction of recurrence and the maintenance of normal architecture of the auricle. The proposed case is emblematic, as it has on one hand the natural course of disease, resulting in deformity of the elix, the other outcomes of treatment.

*Keywords:* Pseudocysts, Auricle, Elix, Management

## Italian abstract

La pseudocisti auricolare è una rara malattia del padiglione auricolare ad eziologia non completamente nota. I giovani adulti sembrano i più colpiti e talvolta può manifestarsi bilateralmente. Non esiste un consenso riguardo al trattamento, infatti in letteratura sono stati riportate diverse metodiche con alterni successi. L'obiettivo di ogni trattamento deve essere la riduzione delle recidive e la conservazione della normale architettura del padiglione auricolare. Il caso proposto è emblematico, poiché presenta da un lato il decorso naturale della patologia, con la conseguente deformità dell'elice, dall'altro gli esiti del trattamento.

*Parole Chiave:* Pseudocisti, Padiglione auricolare, Elice, Trattamento

## Introduzione

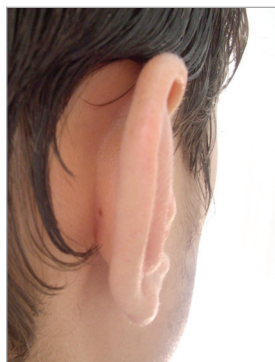La pseudocisti auricolare è una malattia rara che si manifesta con una raccolta di liquido sieroso a livello del padiglione auricolare. È stata descritta per la prima volta da Engel nel 1966 nella comunità cinese di Hong Kong<sup>1</sup> anche se

non sembra sia presente una predisposizione razziale per questa patologia<sup>2</sup>. Generalmente riscontrata prevalentemente nei giovani adulti di sesso maschile, è rara prima dei 20 e dopo i 60 anni, anche se può manifestarsi in entrambi i sessi, in tutte le razze ed età.<sup>3,4</sup>

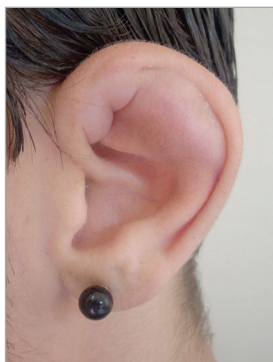Solitamente è unilaterale, e l'orecchio destro è affetto più del sinistro. Ma sono stati descritti anche casi bilaterali,<sup>4,5</sup> la maggior parte dei quali sviluppati in tempi diversi<sup>6</sup>.

Tale condizione è stata riportata in letteratura con vari nomi come pseudocisti endocondrale, condromalacia idiopatica cistica, cisti intracartilaginea.<sup>7,8</sup>

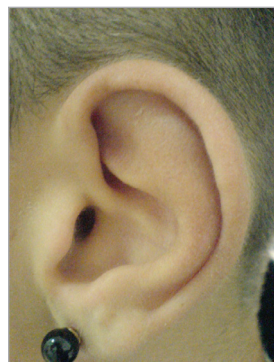L'insorgenza della pseudocisti interessa esclusivamente la faccia anteriore del padiglione auricolare, la maggior parte delle cisti sono localizzate a livello dello scafoide e della fossa triangolare, anche se Zhu e coll. hanno riscontrato il 71,1% delle cisti a livello della conca<sup>9</sup>.



**Figure 1** - Ispessimento localizzato dell'elice da preegressa tumefazione del padiglione auricolare.



**Figure 2** - Tumefazione del padiglione auricolare sinistro interessante elice, antelice e fossetta triangolare.



**Figure 3** - Il paziente è stato seguito con un follow-up a cadenza mensile e appare libero da recidive dopo 12 mesi.

L'eziologia ad oggi non è chiara ma ci sono due ipotesi principali. La prima associata a microtraumatismi cronici, come dormire su cuscini duri, uso di cuffie per ascoltare la musica o caschi per motociclette, o bambini con dermatite atopica che si sfregano e grattano le orecchie<sup>3,5</sup>. La seconda ipotesi prevede che una displasia embriologica congenita della cartilagine auricolare predisponga allo sviluppo della pseudocisti<sup>10</sup>.

Clinicamente compare spontaneamente come una tumefazione tipicamente asintomatica della superficie anteriore del padiglione auricolare, la cui cute conserva un aspetto normale.

Riportiamo un caso di pseudocisti auricolare bilaterale trattato con agoaspirazione e infiltrazione corticosteroidica.

## Case report

Paziente di 17 aa con un pregresso episodio di tumefazione dell'orecchio destro interessante elice e antelice che era andato incontro a evoluzione naturale residuando un ispessimento localizzato dell'elice (figure 1). Dopo alcuni mesi si presentava alla nostra attenzione per la comparsa di una tumefazione del padiglione auricolare sinistro interessando elice, antelice e fossetta triangolare (figure 2).

La cute di rivestimento era di aspetto normale, di consistenza tesa elastica, non dolente ma dolorabile al tocco. Il paziente non aveva storie di pregressi traumi o microtraumi occupazionali o legato a comportamenti.

Posta diagnosi di pseudocisti auricolare si è proceduto al trattamento con aspirazione e infiltrazione steroidea. Sono stati aspirati 2 ml di raccolta sierosa e dopo infiltrazione con Desametasone 4mg/1ml è stato applicato un bendaggio compressivo. Al successivo controllo (2 giorni), era evidente una nuova raccolta localizzata alla fossetta triangolare dalla quale è stato aspirato 1 ml di siero; è stata eseguita la seconda infiltrazione di 4mg/1ml di Desametasone ed è stato applicato un nuovo bendaggio compressivo. Dopo una settimana il paziente presentava una nuova raccolta a livello della fossetta triangolare, questa volta trattata con aspirazione e sutura trasfissa compressiva con bottone. Dopo una settimana, rimossa la sutura, si notava regressione del quadro clinico.

Il paziente è stato seguito con un follow-up a cadenza mensile e appare libero da recidive dopo 12 mesi (figure 3).

## Discussione e conclusioni

L'eziologia della pseudocisti rimane ancora oggi poco chiara. Engel aveva ipotizzato un anormale rilascio di enzimi lisosomiali da parte dei condrociti, causando la progressiva formazione di cavità intracartilaginee<sup>1</sup>. La ricerca della modificazione dell'attività lisosomiale nel fluido aspirato, così come la valutazione del numero dei lisosomi, ha però confutato tale teoria.

Altra teoria ipotizzava una displasia congenita della cartilagine auricolare come fattore necessario per lo sviluppo della malattia. L'orecchio si sviluppa dal primo e dal secondo arco branchiale. Residui di strati di tessuto possono rimanere all'interno del mesenchima durante il complesso processo di fusione e formazione dei tessuti auricolari. La riattivazione di questi piani tissutali potrebbe comportare la formazione delle pseudocisti<sup>6</sup>. Uno studio condotto su orecchi fetali ha mostrato che in circa il 30% dei casi è documentabile tessuto fibroso vascolarizzato intracartilagineo, questo ha confermato la presenza di spazi intracartilaginei che potrebbero evolvere in pseudocisti<sup>10</sup>.

I traumatismi cronici sono stati considerati da sempre come principali fattori di rischio per la formazione delle pseudocisti: dormire su supporti duri, trasporto di sacchi a spalla, caschi da motocicletta, cuffie. I ripetuti microtraumi possono innescare un processo infiammatorio con produzione di glicosaminoglicani, che ha inizio nella cartilagine, formando delle microcisti che confluiscono progressivamente formandone altre sempre più grandi<sup>11</sup>.

I traumi sono spesso assenti nella storia clinica di questi pazienti e le casistiche riportano la presenza di traumi in appena il 10% dei casi<sup>12</sup>. La bassa incidenza di traumi nella storia clinica però potrebbe dipendere dalla raccolta anamnestica non accurata e da domande poco orientate, traumi minori potrebbero rimanere misconosciuti. L'elevato tasso di LDH riscontrato nel fluido aspirato dalle pseudocisti potrebbe far propendere per la teoria traumatica della formazione delle pseudocisti<sup>13</sup>.

Lim e coll. hanno proposto una teoria infiammatoria alla base dello sviluppo delle pseudocisti, poiché hanno ritrovato la presenza di un infiltrato perivascularale composto prevalentemente da linfociti nello strato di connettivo della lesione<sup>14</sup>. Su queste basi gli autori ritengono il processo infiammatorio una condizione necessaria per lo sviluppo delle pseudocisti. Il *primum movens* della risposta infiammatoria localizzata potrebbe essere, secondo Lim, una reazione autoimmunitaria, il successivo rilascio di citochine alimenta un circolo vizioso che instaura una flogosi cronica e la conseguente formazione di essudato sieroso intracartilagineo.

Anche Chen e coll. hanno analizzato le basi autoimmunitarie della formazione delle pseudocisti riscontrando nel siero pseudocistico la presenza di anticorpi anti-nucleo e immunocomplessi<sup>15</sup>.

Cohen ha notato che nel 93% dei casi è colpito il sesso maschile, confermando le percentuali riportate da altri studi<sup>3</sup>. Questa prevalenza nel sesso maschile può essere spiegata sulla diversa azione di testosterone ed estrogeni sulla produzione di citochine.

Kanotra e coll. hanno elaborato una teoria basata sulla differente produzione di citochine legata all'azione ormonale. Secondo gli autori, gli ormoni modificano la risposta flogistica indotta da microtraumi cronici, in individui con una certa predisposizione alle patologie autoimmunitarie o displasia congenita della cartilagine auricolare, che invariabilmente conduce alla formazione delle pseudocisti<sup>16</sup>.

La diagnosi di pseudocisti è solitamente clinica. Le lesioni possono essere confuse con la policondrite recidivante, condrodermatite nodulare dell'elice, orecchio a cavolfiore e l'ematoma subpericondrale del padiglione. La differenza principale è che nella pseudocisti la lesione è intracartilaginea, nelle altre lesioni l'infiltrato è subpericondrale.

In letteratura sono riportate differenti metodiche per il trattamento della pseudocisti auricolare, ma tutti i trattamenti proposti presentano controversie e non esiste una modalità completamente accettata.

Il trattamento deve ottenere due risultati fondamentali: risoluzione della lesione riducendo la possibilità della recidiva e conservazione della normale struttura del padiglione auricolare.

Sia l'aspirazione che il drenaggio dopo incisione comportano un immediato accumulo di fluido nell'arco di poche ore.

L'aspirazione e l'incisione completate dalla compressione riducono l'inciden-



za delle recidive; la compressione può essere ottenuta tramite fasciatura classica, sutura transfissa e sutura con bottoni.

Il ruolo dei coricosteroidi sistemici o per infiltrazione intralesionale hanno avuto un tasso di successo variabile. Alcuni autori consigliano come primo approccio l'infiltrazione corticosteroidica dopo aspirazione del fluido pseudocistico<sup>3</sup>.

Il trattamento delle pseudocisti comprende anche approcci di tipo chirurgico, variamente proposti nel corso del tempo. L'incisione ed il drenaggio è stato il primo metodo impiegato e descritto, ma gravato da un elevato tasso di recidive ed insuccessi<sup>2</sup>. Per prevenire l'accumulo di fluido dopo l'aspirazione o il drenaggio chirurgico, è stata proposta l'applicazione di un piccolo tubo di drenaggio all'interno della cavità pseudocistica<sup>9</sup>.

L'escissione chirurgica della pseudocisti è stata introdotta da Choi che ha riportato un ottimo risultato nel 90% dei pazienti trattati<sup>11</sup> e, in seguito, riproposta con qualche modifica di tecnica da Lim<sup>2</sup> che ha suggerito la compressione con sutura trasfissa e bottone.

La rimozione chirurgica della cartilagine degenerata riduce considerevolmente la possibilità della successiva raccolta di fluido all'interno della pseudocisti e la compressione con bottone garantisce una compressione costante ed è facilmente applicabile<sup>16</sup>.

Nel caso presentato è interessante notare l'evoluzione naturale della pseudocisti nell'orecchio di destra, risultante in un ispessimento fibroso della cartilagine e conseguente deformazione del padiglione auricolare. Nell'orecchio trattato, invece, dopo il fallimento parziale della terapia con aspirazione ed infiltrazione, il risultato finale è stato ottenuto con l'aspirazione e la compressione con bottone. L'opzione conservativa (aspirazione e infiltrazione corticosteroidica) può essere utilizzata come primo approccio, in considerazione del non indifferente tasso di guarigione riportato da Miyamoto<sup>3</sup>. In caso di fallimento è sempre possibile ricorrere alla terapia più aggressiva con exeresi della pseudocisti e compressione.

## References

1. Engel D. Pseudocysts of the auricle in Chinese. *Arch Otolaryngol* 1966;83:197-202.
2. Lim CM, Goh YH, Chao SS, et al. Pseudocyst of the auricle. *Laryngoscope* 2002;112:2033-36.
3. Cohen PR, Grossman M. Pseudocyst of the auricle. Case report and world literature review. *Arch Otolaryngol Head Neck Surg* 1990;116:1202-04.
4. Laser RH, Heffner DK, Hughes G, et al. Pseudocyst of the auricle. *Otolaryngol Head Neck Surg* 1986;94.
5. Gramb R, Kim R. Pseudocyst of the auricle. *J Am Acad Dermatol* 1984;2:58-63.
6. Lee JA, Panarese A. Endochondral pseudocyst of the auricle. *J Clin Pathol* 1994;47:961-3.

7. Hansen JE. Pseudocyst of the auricle in caucasians. Arch Otolaryngol 1967;85:13-14.
8. Heffner DK, Hyams V. Cystic chondromalacia (endochondral pseudocyst) of the auricle. Arch Pathol Lab Med 1986;110:740-43.
9. Zhu L, Wang X. New technique for treating pseudocyst of the auricle. J Laryngol Otol 1990;104:31-32.
10. Zhu L, Wang H. Histological examination of the auricular cartilage and pseudocyst of the auricle. J Laryngol Otol 1992;106:103-4.
11. Choi S, Lam KH, Chan KW, et al. Endochondral pseudocyst of the auricle in Chinese. Arch Otolaryngol 1984;110.
12. Tan BY, Hsu PP. Auricular pseudocyst in the tropics: a multi-racial Singapore experience. J Laryngol Otol 2004;118:185-8.
13. Miyamoto H, Okajima M, Takahashi I. Lactate dehydrogenase isozymes in and intralesional steroid injection therapy for pseudocyst of the auricle. Int J Dermatol 2001;40:380-84.
14. Lim CM, Goh YH, Chao SS, et al. Pseudocyst of the auricle: a histological perspective. Laryngoscope 2004;114:1281-84.
15. Chen Q, Zhao T, Yang X. Immunological cause of auricle pseudocyst. Zhonghua Er Bi Yan Hou Ke Za Zhi 1999;34:236-37.
16. Kanotra SP, Lateef M. Pseudocyst of pinna: a recurrence-free disease. Am J Otolaryngol 2009;30:73-79.

*Corresponding Author:*

**Francesco Dispenza**

ENT Department

University of Palermo

via Paolo Emiliani Giudici 37

90127 Palermo, Italy

e-mail: francesco.dispenza@gmail.com

# MUCOPYOCELE OF THE MIDDLE TURBINATE: A CASE REPORT



**Abdul-latif Hamdan, Mohammad Natout,  
Khaled M. Musallam, Sami Tanbouzi Husseini**  
Department of Otolaryngology - Head & Neck Surgery  
American University of Beirut Medical Center  
Beirut, Lebanon

## Abstract

Mucopyoceles are mucosa lined lesion of the paranasal sinuses that harbor a bacterial infection. These space occupying lesions can significantly increase in size with exacerbation of active infection. The most common sites of involvement are the frontal and ethmoidal sinuses. We herein present a child with a unique presentation of a mucopyocle in the middle turbinate. Although this occurrence is rare, its inclusion in the differential diagnosis of nasal obstruction is justified. Radiologic imaging may aid in the diagnosis, however, pathological studies provide a definite one. Severe sequelae seem to be less frequent than the paranasal counterpart and surgical management consists of simple drainage and excision.

*Keywords:* mucopyocle, turbinate, nose, infection.

## Introduction

Mucocele refers to a mucosa lined lesion of the paranasal sinuses, which can eventually become infected forming a mucopyocle.<sup>1</sup> Its occurrence has been attributed to chronic inflammation, trauma, tumors or surgical manipulation of the sinuses.<sup>1</sup> Mucopyoceles can manifest at any age but are usually associated with cystic fibrosis in children.<sup>2</sup> These space occupying lesions can significantly increase in size with exacerbation of active infection. Bacterial infestation is usually polymicrobial.<sup>3,4</sup> The most dreaded complication remains erosion into the base of the cranium or the orbital compartment.<sup>1</sup> It is well established that the most common sites of involvement are the frontal and ethmoidal sinuses.<sup>1</sup> We herein present a child with a unique presentation of a mucopyocle in the middle turbinate.

## Case report

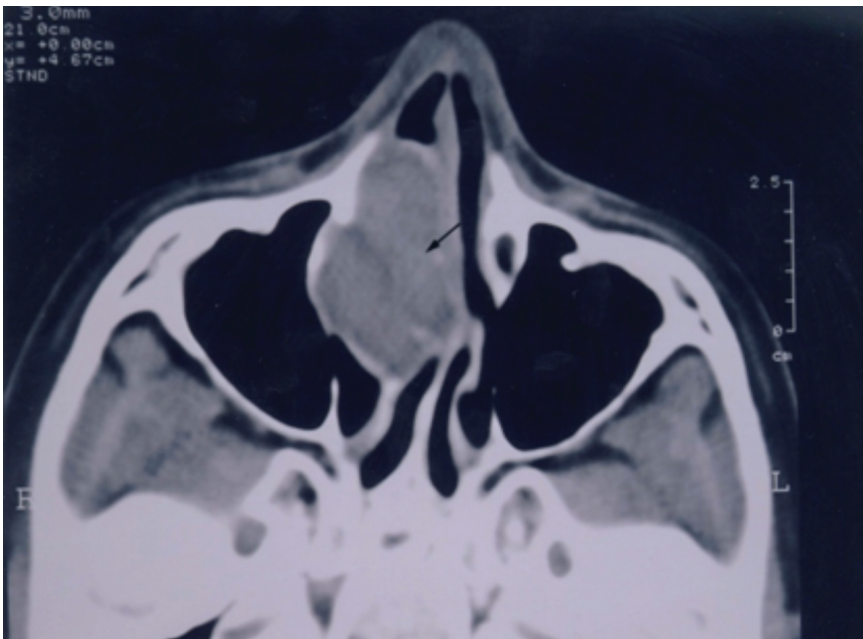
A 14-year-old girl presented to our care with a chief complaint of progressive right nasal obstruction, over the last six months, not responding to nasal decongestant treatment. The patient did not complain of any fever, allergy, nasal discharge or postnasal drip. She reported intermittent facial heaviness. Anterior rhinoscopy revealed a large middle turbinate almost filling the right nasal cavity that was impinging on the nasal septum and the lateral nasal wall. Computerized tomography (CT) scan of the paranasal sinuses revealed a large cystic middle turbinate abutting the lateral nasal wall, without any evidence of bony erosion (figure 1). Endoscopic excision of the middle turbinate after draining a thick purulent material was performed. The patient tolerated the procedure well, and reported marked improvement in her symptoms. Pathological examination of the excised tissue revealed a thin membranous cyst with a wall consisting of a monolayer of ciliated columnar epithelium with subepithelial edema, congestion and admixture of inflammatory cells. The diagnosis was consistent with a mucopyocele. Bacterial culture of the purulent material showed moderate growth of *Hemophilus aphrophilus*. The patient was prescribed antibiotic treatment (levofloxacin 500 mg/day for 10 days) and was discharged home in good condition. A follow-up visit after six months revealed no signs of recurrence or complications

## Discussion

Although mucopyoceles are most commonly encountered in the frontal and ethmoidal sinuses, reports on the involvement of the clivus, epidura, maxillary and sphenoid sinuses have been described.<sup>2,5,6</sup> To our knowledge, our report is the first in the English literature to highlight involvement of the nasal turbinates. The presentation, microbial involvement and management scheme differ from that of paranasal sinus involvement. Patients with sinus involvement may present with allergic diathesis; cranial neuropathies; or ocular complications such as proptosis, diplopia, decreased vision, echymosis, pain or optic neuritis.<sup>1,5,7,8</sup> The latter symptoms manifest as the expanding lesion erodes into the base of the cranium or orbital compartment. However, with nasal turbinate involvement the main complaint is nasal obstruction. Polymicrobial infestation of sinus mucopyoceles has been described. A retrospective review of the microbiological records of 36 patients revealed 106 bacterial isolates, 42 aerobes and 64 anaerobes.<sup>4</sup> The predominant aerobic isolates were *Staphylococcus aureus* and Alpha Hemolytic Streptococci. The main anaerobic isolates included *Peptostreptococcus*, *Prevotella*, *Fusobacterium*, and *Propionibacterium* species.<sup>4</sup> In our case, bacterial culture revealed moderate growth of a single organism, *Hemophilus aphrophilus*. Surgery remains the definite mode of treatment. Several approaches have been previously described, all aiming at preservation of the functionality of the paranasal sinuses while eradicating the diseased mucosa. External, endo-

scopic and endonasal microsurgical approaches have been described.<sup>9,10</sup> Obliteration of the affected sinus mucopyocele is usually achieved using either avascular autologous grafts (adipose tissue, muscle or cancellous bone) or vascular regional flaps (pericranial flaps).<sup>9,10</sup> In our case, there was no need for obliteration, as the treatment of choice was complete excision of the middle turbinate after draining the mucopurulent content.

In conclusion, we have described a novel presentation of mucopyoceles in the middle nasal turbinate. Although this occurrence is rare, its inclusion in the differential diagnosis of nasal obstruction is justified. Radiologic imaging may aid in the diagnosis, however, pathological studies provide a definite one. Severe sequelae seem to be less frequent and surgical management consists of simple drainage and excision.



**Figure 1** - Computerized tomography scan of the nose and paranasal sinuses (axial cut) showing an enlarged middle turbinate with a cystic component (arrow), displacing the nasal septum and medial wall of the maxillary sinuses.

## References

1. Palmer-Hall AM, Anderson SF. Paraocular sinus mucoceles. *J Am Optom Assoc.* 1997;68:725-733.
2. al-Dousary S, al-Kharashi S. Maxillary sinus mucopyocele in children: a case report and review of literature. *Int J Pediatr Otorhinolaryngol.* 1996;36:53-60.
3. Ito K, Ito Y, Mizuta K, et al. Bacteriology of chronic otitis media, chronic sinusitis, and paranasal mucopyocele in Japan. *Clin Infect Dis.* 1995;20:214-219.
4. Brook I, Frazier EH. The microbiology of mucopyocele. *Laryngoscope.* 2001; 111:1771-1773.
5. Chua R, Shapiro S. A mucopyocele of the clivus: case report. *Neurosurgery.* 1996;39:589-590.
6. el-Fiki ME, Abdel Fattah HM, el-Deeb AK. Sphenoid sinus mucopyocele with marked intracranial extension: a more common phenomenon in the Third World? *Surg Neurol.* 1993;39:115-119.
7. De Juan E Jr, Green WR, Iliff NT. Allergic periorbital mucopyocele in children. *Am J Ophthalmol.* 1983;96:299-303.
8. Weisberger EC, Dedo HH. Cranial neuropathies in sinus disease. *Laryngoscope.* 1977;87:357-363.
9. Dzhambazov KB, Traykova NI, Yovchev IP. Endonasal surgery in mucopyocele of the paranasal sinuses. *Folia Med (Plovdiv).* 2001;43:19-22.
10. Hosemann W, Leuwer A, Wigand ME. Intranasal endoscopy-controlled surgery of the frontal sinus in mucopyocele and empyema. *Laryngorhinootologie.* 1992;71:181-186.

*Corresponding author:*

**Sami Tanbouzi Hussein**

Department of Otolaryngology - Head & Neck Surgery

American University of Beirut Medical Center

P.O. Box: 11-0236

Riad El-Solh 1107 2020

Beirut, Lebanon

Phone: +961-3-771151, Fax: +961-1-370793

e-mail: drsam\_t@yahoo.com

# MUCOEPIDERMOID CARCINOMA IN THE LARYNX SUCCESSFULLY TREATED BY RADIOTHERAPY: A CASE REPORT



Gökçe Şimşek\*, Erkan Vuralkan\*, İstemihan Akin\*, Ünsal Han\*\*

\* Ear, Nose and Throat Clinic,

“Yildirim Beyazit” Training and Research Hospital

Faculty of Medicine, University of Ankara, Ankara, Turkey

\*\*Pathology Clinic, “Yildirim Beyazit” Training and Research Hospital

Faculty of Medicine, University of Ankara, Ankara, Turkey

## Abstract

Mucoepidermoid carcinoma is more commonly associated with the major and minor salivary glands. Mucoepidermoid carcinomas have been reported at atypical sites, including the larynx, breast, eustachian tube of the ear, bronchi of the lungs, and thyroid. Laryngeal mucoepidermoid carcinoma is an extremely rare laryngeal neoplasm with only a few individual cases or studies in small patient groups reported in the literature. Special histologic studies may be necessary to arrive at an accurate diagnosis of laryngeal mucoepidermoid carcinoma, due to errors in the pathologic diagnosis of this tumor are not uncommon. It is mostly seen in males aged between 60 and 70. The treatment of laryngeal mucoepidermoid carcinomas is still unclear. In this report, a case of mucoepidermoid carcinoma confined to the laryngeal surface of epiglottis has been presented and its treatment has been discussed along with the review of literature.

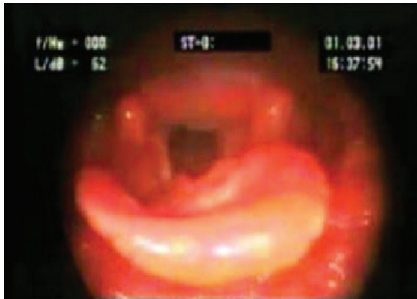*Key words:* Carcinoma, Mucoepidermoid; Laryngeal Neoplasms.

## Introduction

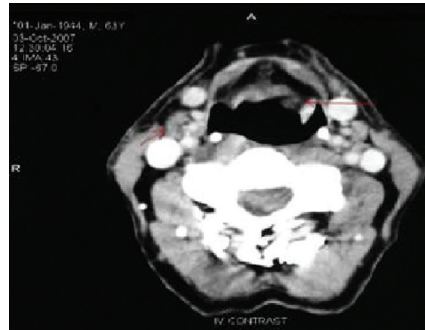
Mucoepidermoid carcinomas are composed of squamous cells, mucus expressing cells, and intermediate cells.<sup>1</sup> Massan and Berger<sup>2</sup> were the first to define these carcinomas in 1924 as a tumor located in the parotid gland. They constitute a group of well-defined salivary gland tumors, accounting for 30% of the malign tumors of the salivary gland.<sup>3</sup> Although mucoepidermoid carcinomas are considered a group of salivary gland tumors, they may also be located in the extremities, thyroid gland, and larynx.<sup>4-7</sup> They are extremely rare tumors of the larynx. To date, only 102 laryngeal mucoepidermoid carcinoma cases have been reported since 1963. No standard approach exists for the treatment of these rare tumors.

## Case report

A 64-year-old male patient applied to our otorhinolaryngology outpatient clinic with the complaints of hoarseness and loss of weight for the last 3 months. On the indirect laryngoscopic examination, a vegetative mass originating from the laryngeal surface of epiglottis and extending to the left laryngeal ventricle was determined (figure 1). No pathological lymph nodes were detected on palpation of the neck. On the computed tomography (CT) image of the larynx and neck, the epiglottis had an irregular contour and was slightly thicker. On the left of the midline of the epiglottis, a nodular appearance of 4mm in diameter and on the anterior left vocal cord, near the ariepiglottic fold, a nodular appearance of 4mm in diameter were observed. The left piriform sinus was obliterated and on the right side of the neck, a lymph node of 14x5mm was determined (figure 2). The tumor grade was determined as T<sub>2</sub>N<sub>1</sub>M<sub>0</sub> grade 2 according to grading of head and neck cancers as proposed by American Joint Committee on Cancer in 2002.



**Figure 1.** Endoscopic appearance of the larynx before radiotherapy.



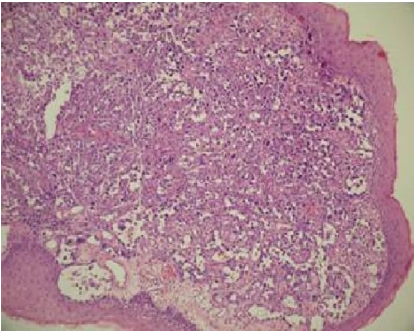
**Figure 2.** Computer tomography image of the larynx and neck before radiotherapy (marked area: the tumor and lymphadenopathy on the neck).

The biopsy material obtained through direct laryngoscopy was fixed in 10% formalin in neutral tampon form. All of the biopsy samples with a size of 8 mm and volume of nearly 1 cc were subjected to routine paraffin studies. The sections obtained from the paraffin blocks were stained with Hematoxylin and eosin (H&E) and evaluated under light microscopy. The evaluation revealed epidermoid and glandular tumor cells, below the mucosa. Epidermoid tumoral cells had aberrant nucleolus and wide eosinophilic cytoplasm and some of the glandular tumoral cells had clear cytoplasm. In staining with Alcian blue, intracytoplasmic and intracellular mucin were noteworthy. Immunohistochemically, MUC<sub>1</sub> and MUC 5AC antibodies were positively stained. Based on the morphological data, the tumor was defined as mucoepidermoid carcinoma. The dominance of epidermoid cells, presence of mito-

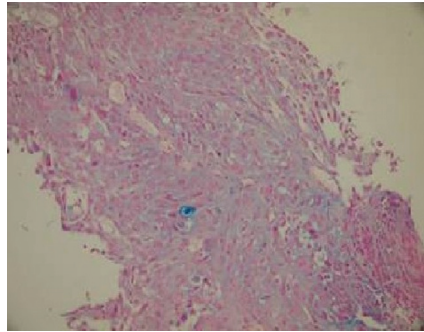


sis, and focal necrosis indicated a high grade for the tumor (figures 3 and 4). The patient had cardiovascular problems and did not consent to surgical treatment due to operational risks. Informed consent was obtained and, radiotherapy was applied considering the fact that no standard treatment approach has been defined for laryngeal mucoepidermoid carcinomas.

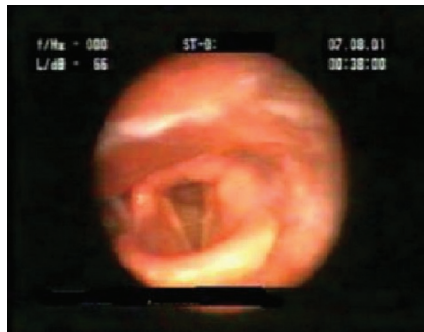The larynx and neck areas of the patient were exposed to 7000cGy (total) external radiotherapy at a fraction of 35, and the bilateral supraclavicular fossa, to 5000cGy (total) external radiotherapy at a fraction of 25. The patient has been under monthly follow-up by physical examination and indirect laryngoscopy for 1 year. In the 12th month of radiotherapy, videolaryngoscopic evaluation demonstrated that the mass had resolved (figure 5).



**Figure 3.** The image of acinar structures and solid epidermoid foci with presence of mitosis of the tumor cells located in the subepithelial area. (H&Ex200).



**Figure 4.** Intracytoplasmic mucin (Alcian blue x 400).



**Figure 5.** Endoscopic appearance of the larynx after radiotherapy.

## Discussion

Mucoepidermoid carcinoma of the larynx is a rare larynx malignancy. According to large series reported to date, it constitutes 0.5% of all larynx cancers.<sup>6,8,9</sup> In its pathogenesis, no definitive etiological factor has been defined.<sup>9</sup> It is more common in males and in the age group of 60-70 years.<sup>10</sup>

Mucoepidermoid carcinoma originates from the subepithelial mucus glands.<sup>11</sup> This accounts for its high incidence in the supraglottic area where the mucus glands abound. Cumberworth et al. reported the analysis of 41 cases of mucoepidermoid carcinoma of the larynx.<sup>10</sup> They have found supraglottic area as the most common site for the tumour location. In our case, the tumour was also supraglottic in location.

The tumor is classified as low, medium, and high grade according to cellular elements. Eversole has been reported that the mucoepidermoid carcinoma consists of three types of cells which are squamous epithelium, mucus-secreting and intermediate cells.<sup>1</sup> The low-grade tumors are composed of well-differentiated and frequently, mucus secreting cells. Tumors of high grade, however, are less differentiated and squamous cells have been defined as the dominant types in these tumors. Tumors of medium grade share some of the characteristics from each of these two other grades of tumors.<sup>12</sup> In our case, dominance of epidermoid cells, presence of mitosis and focal necrosis were seen in histopathologic evaluation which were indicated a high grade for the tumor (figures 3 and 4).

Histological tumor grade is a useful prognostic marker in mucoepidermoid carcinomas of the major and minor salivary glands. Pires et al<sup>12</sup> have determined a 5-year survival rate of 0-43% in high-grade mucoepidermoid carcinomas. This rate has been reported as 62-92% for mucoepidermoid carcinomas of medium grade and 92-100% for mucoepidermoid carcinomas of low grade. Accordingly, low-grade mucoepidermoid carcinomas have the best prognosis. Monin et al. has been reported 15 months disease free survival for a low grade mucoepidermoid carcinoma of the larynx. However, short term survival rates for high grade tumours are unknown.

No consensus has been reached on the best treatment protocol for mucoepidermoid carcinomas of the larynx. However, many authors have agreed on the presence of different treatment approaches depending on the anatomical location and histologic grade of the tumor. As in the treatment of high-grade mucoepidermoid carcinomas of the major and minor salivary glands, more aggressive treatment methods, such as total laryngectomy and cervical lymphadenectomy in particular, have been adopted.<sup>6-14</sup> Tandon et al. and Aygenç et al. have been suggested that in low-grade supraglottic tumors, partial laryngectomy, and in subglottic tumors, total laryngectomy are the primary treatment methods.<sup>14,15</sup> However, treatment methods preserving the laryngeal functions by ensuring safe surgical margins are also preferred.

Laryngeal squamous carcinoma is a well-known radiosensitive tumour,

mucoepidermoid carcinoma, on the other hand has limited radiosensitivity. Nevertheless, the efficiency of radiotherapy in the treatment of mucoepidermoid carcinomas of the larynx remains a controversial issue. Literature reveals reports of cases successfully treated with radiotherapy.<sup>15,16</sup> Shonai et al. reported the analysis of 14 cases of mucoepidermoid carcinoma of the larynx in which only 3 had the high grade tumours that was treated by primary radiotherapy between the year of 1978-1996.<sup>16</sup> According to the their report, 7 of cases (50%) has been cured, after radiotherapy. However, 2 of the cases of high grade tumour were dead, during the follow-up. On the other hand, Cumberworth et al. has been reported cases in whom radiotherapy has failed.<sup>10</sup>

In our patient, despite the diagnosis of high-grade mucoepidermoid carcinoma, the treatment consisted of primary radiotherapy, which is different from the treatment methods used in earlier cases with similar tumors. Furthermore, in the 1 year follow-up after the radiotherapy, the tumor of the patient had completely resolved.

In conclusion, although, according to the current knowledge, surgery is considered as primary treatment of high grade mucoepidermoid carcinoma of larynx, the success rates of different treatment approaches for mucoepidermoid carcinomas will be clarified with increasing numbers of reported cases. The most appropriate treatment modality should be personalized for each patient. Radiotherapy can be considered as an alternative method in patients with high grade mucoepidermoid carcinoma of the larynx who can not tolerate surgery or do not consent surgical treatment.

## References

1. Eversole LR. Mucoepidermoid carcinoma: Review of 815 reported cases. *J Oral Surg* 1970;28:490-4.
2. Monin DL, Sparano A, Litzky LA, Weinstein GS. Low-grade mucoepidermoid carcinoma of the subglottis treated with organ-preservation surgery. *Ear Nose Throat J*. 2006;85:332-6
3. Speight PM, Barren AW. Salivary gland tumours. *Oral Dis* 2002;8:229-40.
4. Hattori H. Goblet cell predominant high-grade mucoepidermoid carcinoma of the index finger. *Br J Dermatol* 2003;149:1091-2.
5. Sharma K, Nigam S, Khurana N, Chaturvedi KU. Sclerosing mucoepidermoid carcinoma with eosinophilia of the thyroid—A case report. *Indian J Pathol Microbiol* 2003;46:660-1.
6. Prgomet D, Bilić M, Bumber Z, Manojlović S, Katić V. Mucoepidermoid carcinoma of the larynx: report of three cases. *J Laryngol Otol* 2003;117:998-1000.
7. Arslan M, Eroğlu S, Akin I, Akçayöz N, Saka C. Mucoepidermoid carcinoma of the larynx: a case report. *Kulak Burun Bogaz İhtis Derg* 2004;12:48-50.
8. Ferlito A, Recher G, Bottin R. Mucoepidermoid carcinoma of the larynx. A clinicopathological study of 11 cases with review of the literature. *ORL J Otorhinolaryngol Relat Spec*

- 1981;43:280-99.
9. Alavi S, Namazie A, Calcaterra TC, Blackwell KE. Glandular carcinoma of the larynx: The UCLA experience. *Ann Otol Rhinol Laryngol* 1999; 108:485-9.
  10. Cumberworth VL, Narula A, MacLennan KA, Bradley PJ. Mucoepidermoid carcinoma of the larynx. *J Laryngol Otol* 1989; 103: 420-3.
  11. Spiro RH, Hajdu SI, Lewis JS, Strong EW. Mucus gland tumors of the larynx and laryngopharynx. *Ann Otol Rhinol Laryngol* 1976; 85:498-503.
  12. Pires FR, de Almeida OP, de Araujo VC, Kowalski LP. Prognostic factors in head and neck mucoepidermoid carcinoma. *Arch Otolaryngol Head Neck Surg* 2004;130:174-80.
  13. Snow RT, Fox AR. Mucoepidermoid carcinoma of the larynx. *J Am Osteopath Assoc* 1991;91 : 182-4, 187-9.
  14. Aygenç E, Okay E, Özbek E, Özdem C. Larinksin minör tükürük bezi karsinomları. *T Klin K B* 2003; 3:1-3.
  15. Tandon DA, Dekka RC, Chowdhury C. Mucoepidermoid carcinoma of the larynx. *Ear Nose Throat J* 1985;64:555-7.
  16. Shonai T, Hareyama M, Sakata K, Oouchi A, Nagakura H, Koito K, et al. Mucoepidermoid carcinoma of the larynx: A case which responded completely to radiotherapy and a review of the literature. *Jpn J Clin Oncol* 1998; 28:339-42.

*Corresponding author:*

**Gökçe Şimşek**

Ear Nose Throat Clinic, Yıldırım Beyazıt Training and Research Hospital  
Ankara, Turkey

daily phone: 00 90 312 596 21 14

fax number: 00 90 312 318 66 90

GSM: 00 90 506 241 75 02

e-mail: drgokceozelsimsek@yahoo.com



## ACKNOWLEDGMENTS

We thank the Editors in Chief of “Capsula Eburnea” for the support given to the development of this Special Issue.

A sincere gratitude to Dr. Mauro Menziotti for the trust given to us and without whose invaluable assistance this volume would not be born.

Thanks to Dr. Valentina Faricelli for the enthusiasm and perseverance with which worked on our project.

A dutiful gratitude to staff of Ikona Studio of Rome for the collaboration through the stage of drafting the Volume.

A priceless thanks to all the Authors and co-Authors of this special.

Finally we thanks the Lawyer Ilaria Persano and the Dr. Vittoria Mortillaro for the patience given us in these months.

*Alessandro De Stefano*  
*Francesco Dispenza*

# CAPSULA EBURNEA GUIDELINES FOR AUTHORS

Available at <http://www.capsulaeburnea.org>

**Capsula Eburnea** publishes original papers, reviews and clinical case reports on topics of medicine, biomedicine, biotechnology and pharmacology.

Manuscripts should conform to the “Uniform Requirements for Manuscripts Submitted to Biomedical Journals” (<http://www.icmje.org/index.htm>).

## **Manuscripts may be in Italian or in English.**

All manuscripts are peer-reviewed by an Editorial Committee or selected reviewers and must be prepared in agreement with the following rules.

## **Manuscripts have to be submitted by email to the following addresses:**

*francapp@hotmail.com*

Manuscripts should be in .rtf or .doc format, and pictures in .jpg or .tif format. Submission of a manuscript to Capsula Eburnea implies that the content has not been published previously and will not be submitted for publication elsewhere while the manuscript is under review. Capsula Eburnea considers research results (excluding abstracts and student dissertations) to have already been published if they are publicly available with a fixed content, i.e., content is in an unalterable form, and is citable in any language.

Authors that publish their papers on “Capsula Eburnea” have to declare, in the submitted manuscript, their Conflict(s) of interest, if any.

Previous publication of a particular figure may not prevent subsequent publication in Capsula Eburnea if that figure is essential to the submitted paper and does not constitute the major contribution. Previously published portions of a paper must be accompanied by a permission release from the copyright holder and must be cited.

Capsula Eburnea endorses the recommendations concerning human research that are contained in the Declaration of Helsinki. The Editors reserve the right to reject any manuscript containing studies that do not conform to these recommendations. All manuscripts reporting human research must contain a statement in the text that the institutional review board for human studies approved the protocols and written consent was obtained from the subjects or their surrogates if required by the institutional review board.

Use of animals in research should be compliant with all subsequent revisions of the International Guiding Principles for Biomedical Research Involving Animals (WHO). Animal experiments are to be undertaken only with the goal of advancing scientific knowledge.

Obtainment of informed consent has also to be indicated in the published article.

Following submission of a manuscript to Capsula Eburnea, the authors have to sign a declaration letter that certifies that (a) should the submitted manuscript be published the copyright will be transferred to the Editorial Board, (b) the material is original, has not been published except in abstract form, and is not being considered for publication elsewhere, including publicly accessible websites or e-print servers, (c) all authors have read the manuscript and approve its submission, (d) all clinical trials have been registered in a public trial registry, (e) all the research has been conducted adhering to the recommendations contain-

ned in the Declaration of Helsinki and it complies with the International Guiding Principle that regulate research on animals.

By submitting a manuscript to Capsula Eburnea, the authors agree to subject it to the confidential peer-review process. Editors and reviewers are informed that the manuscript must be considered confidential. The Editors reserve the right to modify the manuscript before publication with the consent of the Author(s). Should the Authors need to revise the manuscript, the revised version must be submitted to the Editors following the procedures outlined in these Guidelines.

## **Submission types**

### *Review*

is an authoritative, balanced and scholarly survey of recent developments in a research field. The requirement for balance need not prevent authors from proposing a specific viewpoint, but if there are controversies in the field, the authors must treat them in an even-handed way. Reviews can contain a maximum of 7500 words, and illustrations are strongly encouraged. References are limited to 60, with exceptions possible in special cases. Citations should be selective. The scope of a Review should be broad enough that it is not dominated by the work of a single laboratory, and particularly not by the authors' own work.

### *Article*

is a substantial novel research study, with a complex story often involving several techniques or approaches. The main text (excluding abstract, Methods, references and figure legends) is 5,000 words maximum. The abstract is 150 words maximum, unreferenced. Articles have a maximum of 6 display items (figures and/or tables). An introduction (without heading) is followed by sections headed Methods, Results and Discussion. The Methods and Results should be divided by topical subheadings; the Discussion does not contain subheadings. If statistical testing was used to analyze the data, the Methods section must contain a subsection on statistical analysis. References are limited to 30.

### *Clinical report*

Descrizione di uno o più casi clinici di particolare interesse (particolari presentazioni cliniche, difficoltà diagnostiche, novità terapeutiche). Sono ammesse fino a 2500 parole di testo e 15 citazioni bibliografiche. L'articolo deve essere suddiviso nelle sezioni: introduzione, caso clinico, conclusioni.

### *Brief communications*

only 1500 words and 10 references at maximum in the following formats are accepted.

- Technical reports
- Therapy reports
- Novel technologies
- Letters to the Editor or Correspondence
- Commentaries



## Manuscript preparation

Manuscripts should be typed in Times New Roman or Arial 12-point type with margins of 2.5 centimetres (1 inch). Double spacing should be used throughout. All papers should be organized to include: title page, abstract with keywords, text, acknowledgments, references, figure legends, footnotes, tables, and figures. Each of the preceding elements should begin on a separate page. While the Introduction should begin on a separate page, it is not necessary for the Methods, Results, and Discussion section to begin on a separate page; instead, they should follow after the Introduction, with two spaces separating each section. Pages should be numbered consecutively, beginning with the abstract.

### *Title Page*

1. Title, which should be limited to 100 characters (count letters and spaces, use no abbreviations).
2. First name, middle initial, and last name of each author.
3. Name of department(s) and institution(s) to which the work should be attributed linked to each author with a corresponding number.
4. Name and address of the author to whom requests for reprints should be addressed.
5. Corresponding Author's e-mail address, FAX number, and phone number.
6. All source(s) of support in the form of grants, gifts, equipment, and/or drugs.
7. Acknowledgements.

### *Abstract*

The second page (numbered page 1) should carry an abstract of not more than 150 words and labeled Abstract. A structured abstract must include the following headings: Rationale, Objectives, Methods, Measurements and Main Results, and Conclusions. Avoid a long introductory section. A clear conclusion is imperative, and all speculation should be avoided. The abstract should be written in a format that can be understood by both researchers and clinicians.

At the bottom of the page, state the number of words in the abstract and list 3 to 6 key words for use as indexing terms. These terms should not include words in the title of the manuscript. Key words are best expressed as MeSH (Medical Subject Headings) terms, the controlled vocabulary used by Pub Med.

Abstracts and Keywords must be in both Italian and English. A free translation service of Abstract and Keywords from English to Italian will be provided by Editors.

### *Text*

The text of articles should usually, but not necessarily, be divided into the following sections: Introduction, Methods, Results, and Discussion. Long articles may require subheadings within some sections to clarify the contents, especially the Results and Discussion sections. Generic names of drugs should be used instead of trade names. The location (city, state, country) of a manufacturer listed in the text should be provided after the first reference to the manufacturer.

Units of measurement should conform to current scientific usage and can be abbreviated when they follow a number (e.g., cm, nm, ml, g, mg, nmol) but not otherwise. Unusual units should be defined.

Statistical methods must be described and the program used for data analysis, and its source, should be stated. Summary statistics should define whether standard deviation ( $\pm$  SD),

variability of the sample, or standard error of the mean ( $\pm$  SEM), uncertainty about the average, is being used.

### *References*

Please ensure that your references include the most current articles and information. References should be typed double-spaced beginning on a separate sheet and numbered in the order that they appear in the text. All authors' names (do not use "et al."), complete article titles, and inclusive page numbers should be cited. The titles of journals should be abbreviated according to the style used in Index Medicus.

### **Example of references**

#### *Journal articles*

Gravante G, Pomara F, Russo G, Amato G, Cappello F, Ridola C: Plantar pressure distribution analysis in normal weight young women and men with normal and claw feet: a cross-sectional study. *Clin Anat* 2005;18:245-250.

#### *Books*

Cappello F, Bucchieri F, and Zummo G: Role of immunohistochemical expression of PCNA and p53 in prostate carcinoma. In: *Immunohistochemistry and in situ hybridization of human carcinomas*, Edited by M.A. Hayat, Vol. 2: *Molecular Pathology of Colorectal Carcinoma and Prostate Carcinoma*, Cap. 8, Elsevier, Life Sciences, 2004.

#### *Tables*

Each table should constitute a single unit of communication, completely informative in itself and be presented as a separate doc or rtf file. It should be possible to understand the information in a table without reading the text. The information in a very small table can be presented more economically as one or two sentences of text.

Do not submit tables as photographs or figures. Tables should be numbered consecutively, have a brief title, and be cited in text.

All non-standard abbreviations used in each table should be explained in footnotes.

#### *Illustrations*

Drawings, graphs, photographs etc. must be submitted in .jpeg format. Histological photographs must include magnification ratios, bars and staining method. Legends are to included in the text of the manuscript just before the references section.

#### *Icons*

For each manuscript, please include a small .jpeg file (50kb max) representing the manuscript.