

# Ultrasound of the Knee

Marc J. Lee, M.D.<sup>1</sup> and Kira Chow, M.D.<sup>2</sup>

## ABSTRACT

Ultrasound of the knee is best suited for the evaluation of tendons, fluid collections and effusion, synovitis, periarticular soft tissue masses, muscles, and the collateral ligaments. Advantages of sonographic evaluation include the lack of ionizing radiation, the noninvasive nature of the examination, focused evaluation correlated with the specific site of pain, multiplanar capability, and utility in patients for whom magnetic resonance imaging (MRI) is contraindicated. The ability to visualize the microanatomy of tendons, ligaments, nerves, and muscles is also an advantage over MRI. Moreover, ultrasound is generally readily accessible and of lower cost than MRI. Ultrasound is less suited for the evaluation of internal derangement. Certain structures that are exquisitely evaluated by MRI, including the menisci, cruciate ligaments, bone marrow, and articular cartilage, are suboptimally evaluated by sonography. This article reviews the structures and pathological processes for which ultrasound has been shown useful, emphasizing appropriate technique and normal anatomy, appearance of pathological processes, and advantages and limitations of sonographic evaluation.

**KEYWORDS:** Ultrasound, sonography, knee

Sonographic evaluation of the knee can be tailored to the history and clinical site of concern, correlating the point of maximal symptoms with the imaging findings. Comprehensive examination can be performed, and various protocols have been posited in the literature.<sup>1</sup> The examination should be performed with a high-resolution linear multifrequency transducer (7 to 10 MHz). Patient positioning and transducer orientation depend on the particular structure being imaged. Comparison with the asymptomatic contralateral knee is very useful and increases diagnostic confidence.

We discuss the ultrasound evaluation of tendon abnormalities, fluid collections including bursae and effusions, the menisci and parameniscal cysts, ligament tears, arthritis and synovitis, as well as the utility of ultrasound in the setting of total knee arthroplasty.

## EXTENSOR MECHANISM

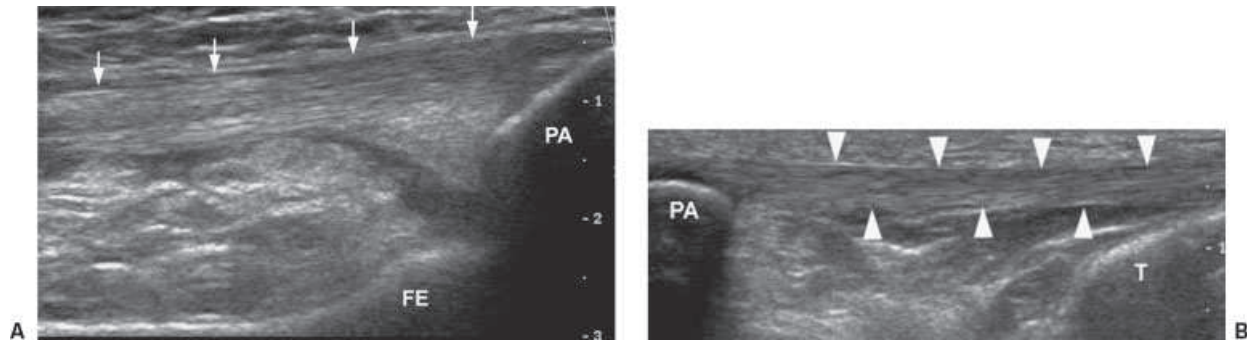
The extensor mechanism of the knee is poised for optimal sonographic evaluation given its superficial location. The patient can be positioned in a supine or sitting position with the knee flexed or semiflexed, thereby elongating the tendon. A support under the knee in the supine position can maximize patient comfort. Both longitudinal and transverse images should be obtained of the quadriceps and patellar tendons, both of which normally show a parallel fibrillar echogenic appearance (Fig. 1). The transducer should be parallel to the tendon to avoid creating artifactual hypoechoic areas that can simulate pathology. Extended field-of-view imaging is particularly useful to show the extensor mechanism along its length, delineating anatomical relationships.

<sup>1</sup>Department of Radiology, Saint Joseph Medical Center, Burbank, California; <sup>2</sup>Department of Radiology, Santa Monica-UCLA Medical Center and Orthopedic Hospital, Santa Monica, California.

Address for correspondence and reprint requests: Kira Chow, M.D., Department of Radiology, Santa Monica-UCLA Medical Center and Orthopedic Hospital, 1250 16th St., Ste. 275, 2nd Fl., Tower, Santa Monica, CA 90404 (e-mail: kchow@mednet.ucla.edu).

Musculoskeletal Ultrasound; Guest Editor, Kambiz Motamedi, M.D.

Semin Musculoskelet Radiol 2007;11:137-148. Copyright © 2007 by Thieme Medical Publishers, Inc., 333 Seventh Avenue, New York, NY 10001 USA. Tel: +1(212) 584-4662. DOI 10.1055/s-2007-1001879. ISSN 1089-7860.



**Figure 1** Normal quadriceps and patellar tendons. Normal fibrillar pattern with parallel echogenic lines can be well visualized in both superficially located tendons of the extensor mechanism. (A) Normal quadriceps tendon (arrows) anterior to the distal femur (FE) and attaching to the patella (PA). (B) Normal patellar tendon (arrowheads) extending from the patella (PA) to the proximal tibia (T).

The quadriceps and patellar tendons lack a synovial sheath. Tendinosis appears as focally or diffusely increased caliber of the tendon and decreased echogenicity. Peritendinous fluid also may be present. In more chronic phases, tendinopathy appears as heterogeneous echotexture and may show calcifications.<sup>1</sup> Application of power Doppler may be helpful to show the degree of hyperemia, indicating active inflammation.

Ultrasound can accurately determine the location and presence of tear. It also can differentiate complete tears from partial tears, an important distinction because the former requires surgery.<sup>2</sup> Partial tears are seen as a cleft or anechoic region with the tendon with interruption of its normal echogenic fibrillar pattern. Complete tears are seen as complete disruption of the tendon with separated ends.<sup>2</sup> The degree of tendon retraction can be assessed, and any interposed hematoma or fluid can be depicted. Note that the quadriceps tendon near the patellar insertion normally may appear hypoechoic due to anisotropy.<sup>1</sup> This potential pitfall should not be misconstrued as a tear, and comparison with the contralateral side may be helpful.

The distinction between partial and complete tears can be optimized by using graded compression and dynamic flexion and extension maneuvers. Because pain may limit attempts at active flexion, gentle distal traction on the patella is a useful maneuver to confirm the presence of a complete tear by showing an enlarged tendinous gap.<sup>2</sup>

### Jumper's Knee

Jumper's knee is a syndrome affecting adults, typically athletes prone to repetitive significant contraction of the quadriceps mechanism. Ultrasound will show focal swelling of the tendon with a hypoechoic area at the posterior aspect of the proximal patellar tendon<sup>3,4</sup> (Fig. 2). There also may be focally hypoechoic areas representing small tears. In chronic cases, inferior

patellar spurs and intratendinous calcifications or dystrophic ossification may be seen.<sup>3,4</sup>

### Osteochondroses

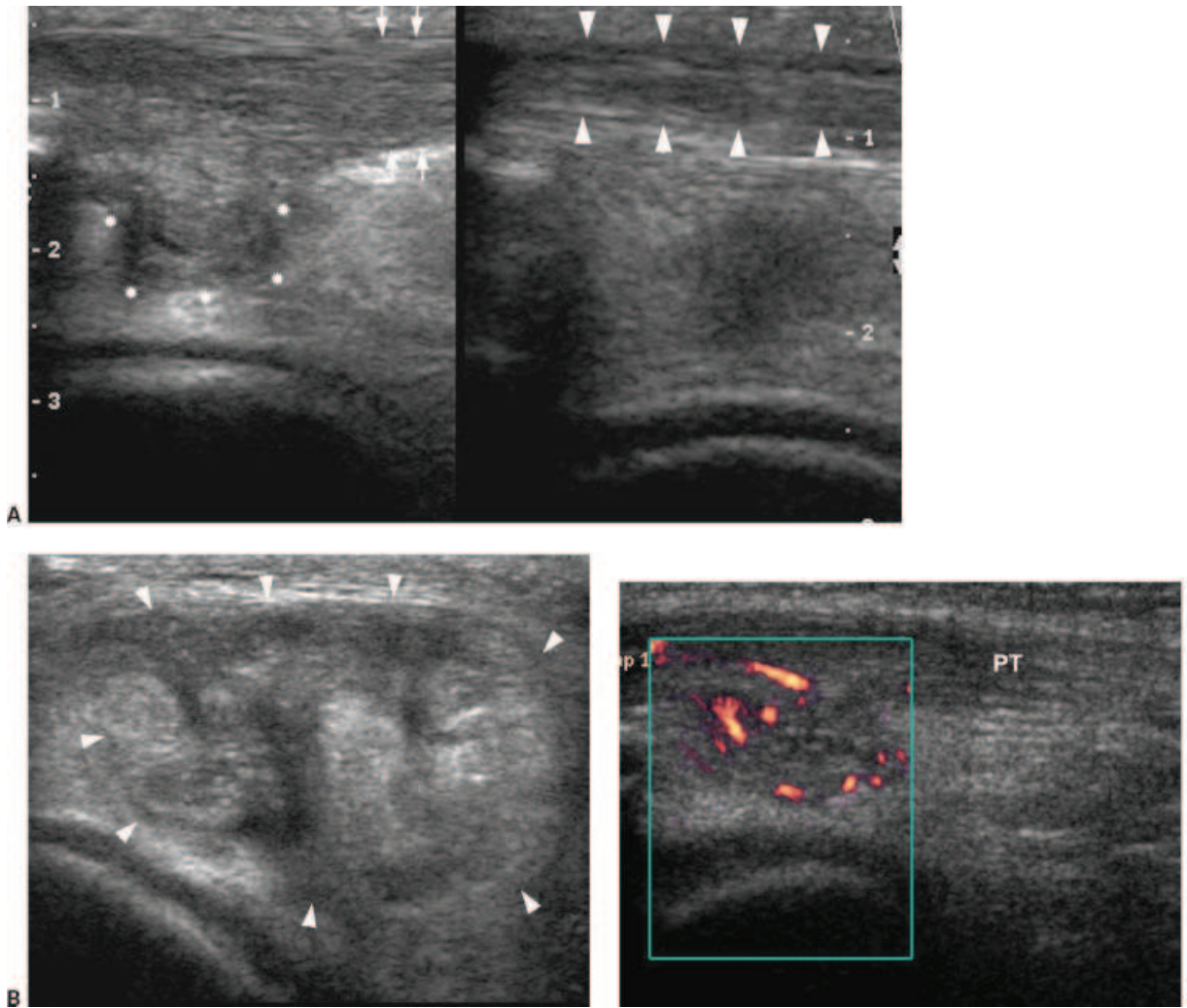
Osgood-Schlatter is a nonarticular osteochondrosis of the anterior tibial tuberosity frequently seen in active adolescents, believed to be due to chronic traction microtrauma at the patellar tendon insertion. Although the diagnosis is generally made clinically, ultrasound can be useful for diagnostic confirmation. Because a fragmented appearance of the tibial tuberosity can be seen normally, ultrasound can show the associated soft tissue changes that characterize this entity. Thickening of the distal patellar tendon, distention of the infrapatellar bursa, swelling of the unossified cartilage and overlying soft tissues, and fragmentation of the ossification center are well shown with ultrasound and better than on radiographs.<sup>3,5</sup>

Sinding-Larsen-Johansson disease is the analogous condition affecting the proximal patellar tendon at its attachment to the inferior patella, and similar changes are seen in this entity.<sup>3,5</sup> Note that the imaging appearances of jumper's knee and Sinding-Larsen-Johansson are similar.

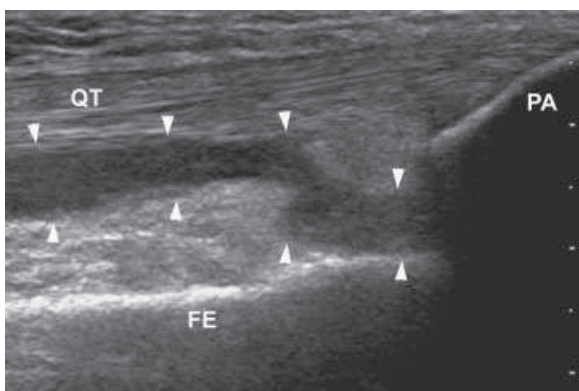
### FLUID COLLECTIONS

#### Joint Effusion

Knee effusion is optimally evaluated in the suprapatellar recess with the transducer oriented longitudinally<sup>6</sup> (Fig. 3). A small amount of physiological fluid can be seen, and abnormal effusion shows greater distention of the recess. The minimum amount of effusion to be detectable at sonography has been reported at 7 to 10 mL.<sup>7</sup> Ultrasound can be utilized to guide arthrocentesis, in which case the patella obstructs needle placement in the longitudinal plane. For aspiration, a transverse plane is recommended,



**Figure 2** Jumper's knee. (A) Longitudinal scans of the bilateral patellar tendons. On the right, the normal patellar tendon demonstrates regular caliber and normal fibrillar pattern (arrowheads). On the left, the abnormal patellar tendon is thickened (arrows) with a hypoechoic area at the posterior aspect of the proximal patellar tendon (asterisks). (B) Transverse image through the proximal patellar tendon demonstrates heterogeneous disorganized appearance with enlargement of the tendon (arrowheads). (C) Longitudinal scan through the abnormal patellar tendon (PT) shows hyperemia along the posterior proximal aspect on power Doppler image.



**Figure 3** Joint effusion. Longitudinal scan obtained anteriorly shows joint effusion in the suprapatellar recess (arrowheads) posterior to the quadriceps tendon (QT). Patella (PA) and distal femur (FE) are also seen.

either anteromedially or anterolaterally depending on the side of greater distention.<sup>6</sup>

In the setting of acute trauma, sonography can be used to evaluate for lipohemarthrosis. Lipohemarthrosis may appear as either a two-layered collection with inferior anechoic blood and nondependent hyperechoic fat or as a trilaminar collection with a superior hyperechoic fat layer, an intermediate anechoic serum layer, and a dependent hypoechoic layer of blood cells.<sup>8,9</sup> A prospective study comparing ultrasound with radiographs and using computed tomography (CT) as the gold standard showed that although ultrasound could not directly depict intra-articular knee fractures, ultrasound was significantly more sensitive (97%) than radiographs (55%) for depiction of lipohemarthrosis in the suprapatellar bursa

and could therefore potentially be used to evaluate for occult knee fracture in acute trauma.<sup>8</sup>

**Bursae**

Bursae about the anterior knee include the prepatellar bursa and the superficial and deep infrapatellar bursae. The prepatellar bursa is located in the subcutaneous tissues anterior to the lower patella. This bursa can become distended after prolonged kneeling (Fig. 4), and the entity is called “housemaid’s knee.” Superficial infrapatellar bursitis, “clergyman’s knee,” is seen anterior to the inferior patellar tendon. The deep infrapatellar bursa is located between the anterior tibia and the inferior patellar tendon. This last bursa is the only one commonly seen in the normal knee as a flattened 2- to 3-mm fluid structure.<sup>3</sup> Bursitis is seen as a fluid collection, which may be associated with wall thick-

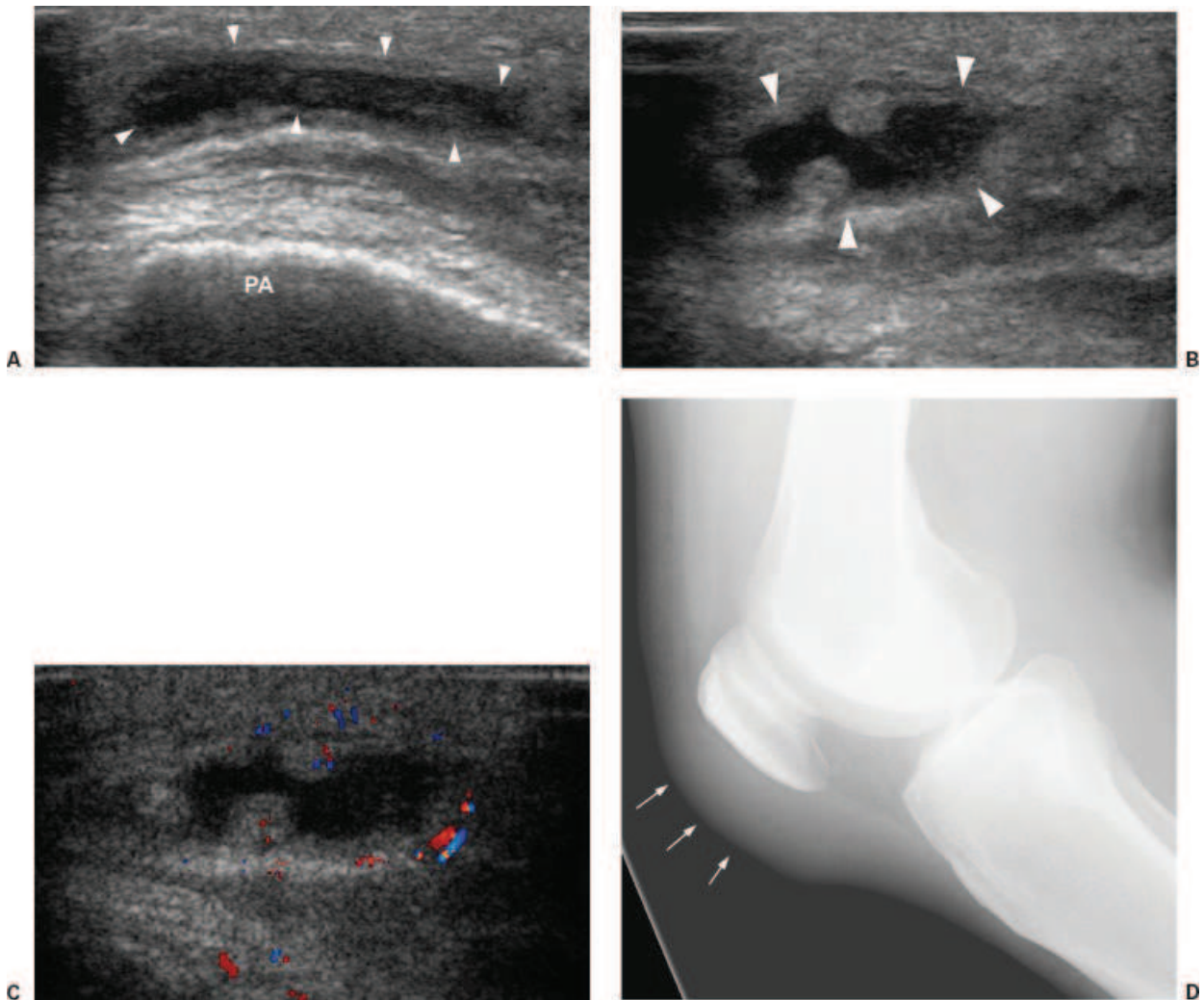
ening. Power Doppler may show associated inflammation.

Pes anserine bursitis is seen as a cystic mass just deep to the pes anserine tendon at the anteromedial aspect of the knee.

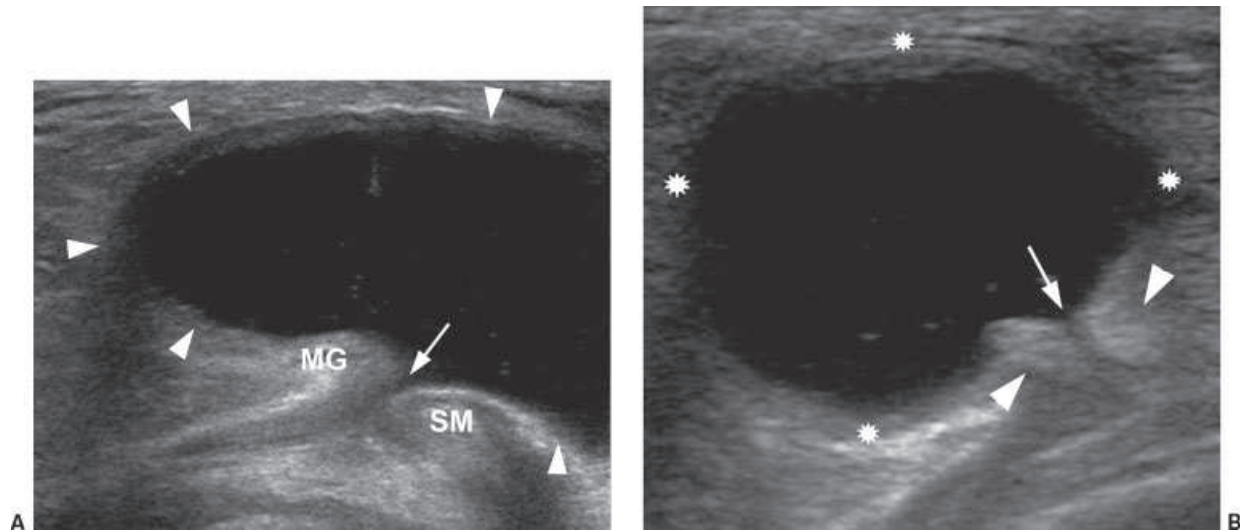
Bursae may contain echogenic material representing inflammatory or infectious debris or hemorrhage.<sup>1</sup>

**Baker Cyst**

Evaluation for Baker cyst is best performed from a posterior approach with the patient supine and the knee fully extended. Ultrasound is highly sensitive for the detection of Baker cysts, which are seen as thin-walled fluid collections (Fig. 5), sometimes containing debris. The fluid may be anechoic, hypoechoic, or of mixed echogenicity relative to skeletal muscle.<sup>10</sup> A Baker cyst typically communicates with the knee joint, extending



**Figure 4** Prepatellar bursitis. (A) Transverse image anterior to the patella (PA) demonstrates fluid in the prepatellar bursa (arrowheads). (B) Longitudinal scan shows nodularity and thickening of the periphery of the prepatellar bursa (arrowheads), secondary to inflammation. (C) Color Doppler longitudinal image shows hyperemia along the periphery of the prepatellar bursa. (D) Lateral radiograph of the knee shows focal prominence of the prepatellar soft tissues (arrows).



**Figure 5** Baker cyst. (A) Transverse scan obtained medially demonstrates anechoic fluid (arrowheads) in a Baker cyst. The neck of the Baker cyst (arrow) is between the medial gastrocnemius head tendon (MG) and the semimembranosus tendon (SM). (B) A second transverse image again demonstrates the Baker cyst (asterisks) with its neck (arrow) originating between the tendons just cited. The tendons (arrowheads) are well-defined hyperechoic ovals.

between the semimembranosus and medial gastrocnemius tendons. Demonstrating this connection is diagnostic for a Baker cyst with 100% accuracy and can eliminate false-positive diagnoses and misinterpretation of other cystic structures or masses as Baker cysts.<sup>10</sup> A leaking Baker cyst shows fluid tracking between the muscles and along the subcutaneous tissues. Doppler can be applied to differentiate a small Baker cyst from a popliteal aneurysm.

### Ganglion Cysts

Ganglion cysts about the knee are frequent findings but may be incidental. They are mucin-filled cystic structures that may be unilocular or septated and appear anechoic to hypoechoic (Fig. 6). Ultrasound is useful for guidance of aspiration for symptomatic cysts.

### MENISCI AND PARAMENISCAL CYSTS

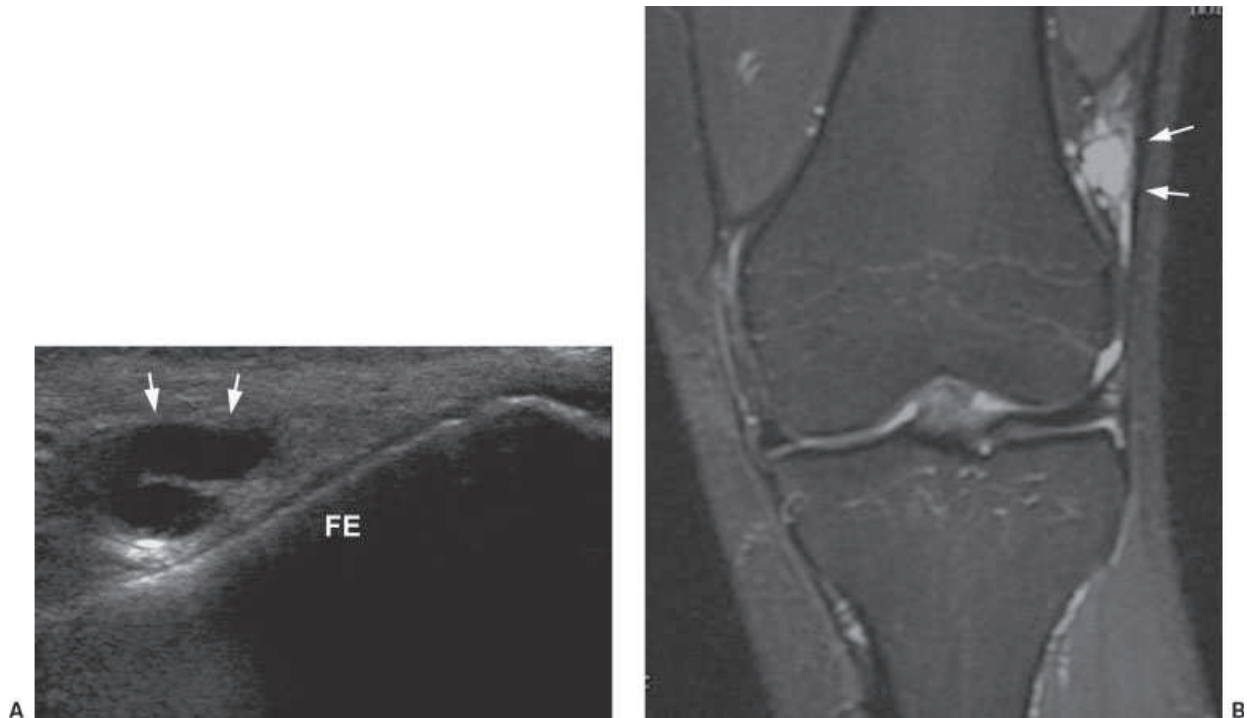
Although magnetic resonance imaging (MRI) remains the gold-standard imaging modality for evaluation of the menisci, some tears can be demonstrated sonographically with meticulous technique. The utility of sonography for meniscal tear is controversial. Earlier studies reported high sensitivities,<sup>11-13</sup> but experienced sonologists in a 2002 study comparing findings with MRI, CT, and arthroscopy results concluded that sonography is not accurate enough to be reliable as the sole modality for diagnosing or excluding tears.<sup>14</sup>

To examine the menisci, the transducer is placed longitudinally spanning the joint line and always oriented perpendicular to the meniscus. The anterior

horns and midzones can be imaged with the patient supine or in the lateral decubitus position with the knee extended; the posterior horns are imaged with the patient prone. Dynamic flexion and rotation can help open the joint line to improve visualization. Visualization may be improved by applying mild valgus or varus stress to image the medial and lateral meniscus, respectively. The entire meniscus cannot be routinely visualized due to its anatomical location. There may be limited conspicuity of the free edge of the meniscus; peripheral and posterior tears are the easiest to demonstrate.<sup>1,15,16</sup>

The normal meniscus appears as a triangular, uniformly hyperechoic structure sandwiched between the hypoechoic articular cartilage surfaces of the femoral condyle and tibial plateau. Tears appear as either hypoechoic or anechoic focal linear defects and less frequently as hyperechoic abnormalities.<sup>1,17</sup> In addition, tears can be obscured by an overlying parameniscal cyst. Meniscal degeneration appears as decreased echogenicity with a swollen appearance, sometimes with cystic regions or as heterogeneity.<sup>1,18</sup> In advanced degeneration, meniscal protrusion and fragmentation also may be seen.<sup>18</sup> The utility of ultrasound for evaluating meniscocapsular separation has not been well evaluated, with one study using arthroscopically created lesions in cadavers concluding that sonography is not accurate for the diagnosis.<sup>19</sup>

Sonography has an accuracy of > 90% for the evaluation of parameniscal cysts,<sup>18</sup> which may present as pain or a palpable mass or may be found incidentally. In 80 to 90% of cases, parameniscal cysts are associated with a meniscal lesion, generally horizontal tears, although some cysts may be due to degeneration.<sup>18,20</sup> Parameniscal



**Figure 6** Ganglion cyst. (A) Longitudinal scan demonstrates lobulated anechoic structure (arrows) adjacent to the femur (FE). (B) Coronal proton-density fat-saturated magnetic resonance imaging sequence demonstrates a lateral hyperintense lobulated mass (arrows) that corresponds to the ultrasound finding.

cysts appear as unilocular or multilocular formations adjacent to the joint line, with a range of appearances (Fig. 7), including uniformly anechoic, hypoechoic, hypoechoic with echogenic septa, and heterogeneously hyperechoic.<sup>18,21</sup>

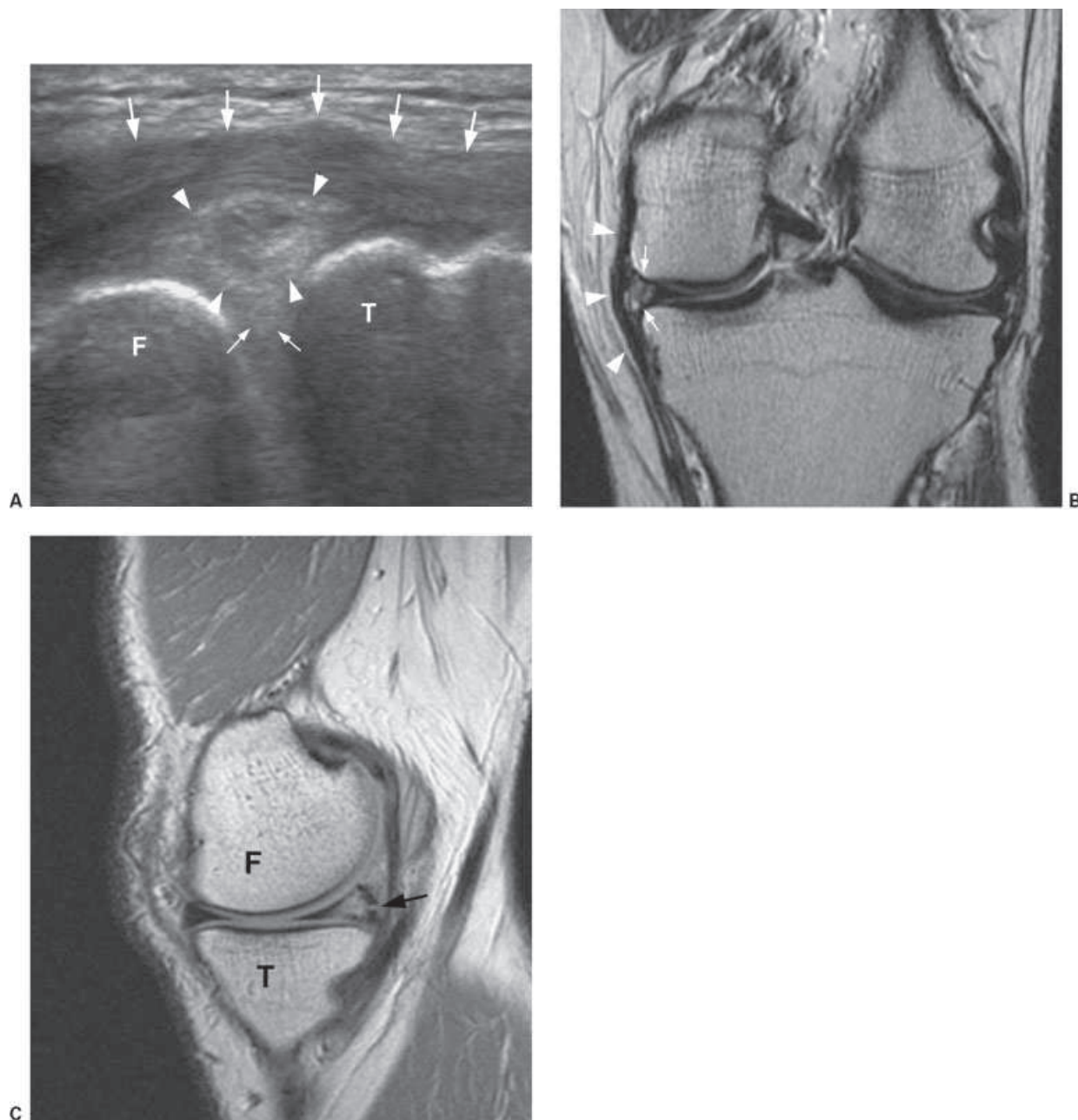
Because more complex cysts may be mistaken for a solid mass, the continuity with the adjacent meniscus rather than its echotexture is the most important feature to demonstrate.<sup>21</sup> Compressing the cyst with the transducer can empty the cyst and expand and better elucidate the connecting tract with the meniscus, thereby differentiating a parameniscal from a ganglion cyst.<sup>18</sup>

### CRUCIATE LIGAMENTS

MRI is the modality of choice for evaluating the anterior and posterior cruciate ligaments with sonography having a limited role. The anterior cruciate ligament (ACL) is difficult to visualize due to the lack of a good sonographic window, and studies to date have relied on indirect signs. A 91% sensitivity for diagnosing ACL rupture in the setting of recent traumatic hemarthrosis has been reported in a series of 37 patients.<sup>22</sup> The authors utilized a transverse posterior intercondylar view, on which the ACL appears as an oval hypoechoic structure within the notch along its lateral aspect proximally. Because the ligament cannot be seen along its length, evaluation of tear relies on an

indirect sign, a hypoechoic collection representing associated hematoma along the lateral wall of the notch near the proximal ACL attachment.<sup>22</sup> Using the same indirect finding and likewise reporting, another study reported high sensitivity and specificity using arthroscopic or clinical follow-up as reference standard.<sup>23</sup> Similarly, posterior subluxation of the tibial plateau, a secondary sign of injury, has been used to indicate ACL injury.<sup>12</sup> A study directly visualizing the ACL with hyperflexion of the knee was limited by the ability to see only a short segment of the ligament and evaluated only chronic cases.<sup>24</sup>

The posterior cruciate ligament (PCL) is visualized with the patient in the prone position with the knee extended in neutral position and the transducer in a sagittal oblique plane with its cephalad aspect directed ~30 degrees medially along the length of the ligament. The normal PCL appears as homogeneously hypoechoic. However, only the distal portion of the ligament can be seen, the proximal portion being too deep to visualize. Acute tear appears as thickening, loss of the sharp posterior border, and a heterogeneously hypoechoic appearance.<sup>25</sup> In 11 patients with PCL injury documented by MRI, ultrasound showed that the torn PCL was 36 to 100% thicker than the contralateral uninvolved PCL as measured at its mid-portion.<sup>26</sup> When torn, the PCL remains hypoechoic and diffusely enlarged, with focal disruption only seen occasionally.<sup>26</sup>



**Figure 7** Meniscal cyst. (A) Longitudinal scan along the medial joint line demonstrates a heterogeneous mass (arrowheads) with hypoechoic internal foci and echogenic periphery underneath the medial collateral ligament (large arrows). The hyperechoic triangle (small arrows) represents the meniscus, and the location of the mass adjacent to the meniscus is a helpful imaging characteristic in diagnosing meniscal cysts. The joint space is appreciated between the distal femur (F) and proximal tibia (T). (B) Coronal proton-density magnetic resonance imaging (MRI) sequence demonstrates heterogeneous signal in the meniscal cyst (arrows) underlying the medial collateral ligament (arrowheads). (C) Sagittal proton-density MRI sequence shows the knee joint, with distal femur (F) and proximal tibia (T). In the posterior horn medial meniscus, there is a horizontal meniscal tear (arrow), typically associated with meniscal cyst. Signal abnormality within the substance of the meniscus represents underlying degeneration.

### COLLATERAL LIGAMENTS

The collateral ligaments have an appearance similar to tendons, comprised of echogenic parallel bands. The medial collateral ligament (MCL) is visualized in the coronal plane, and axial images also can be obtained. The MCL extends from the medial femoral condyle to

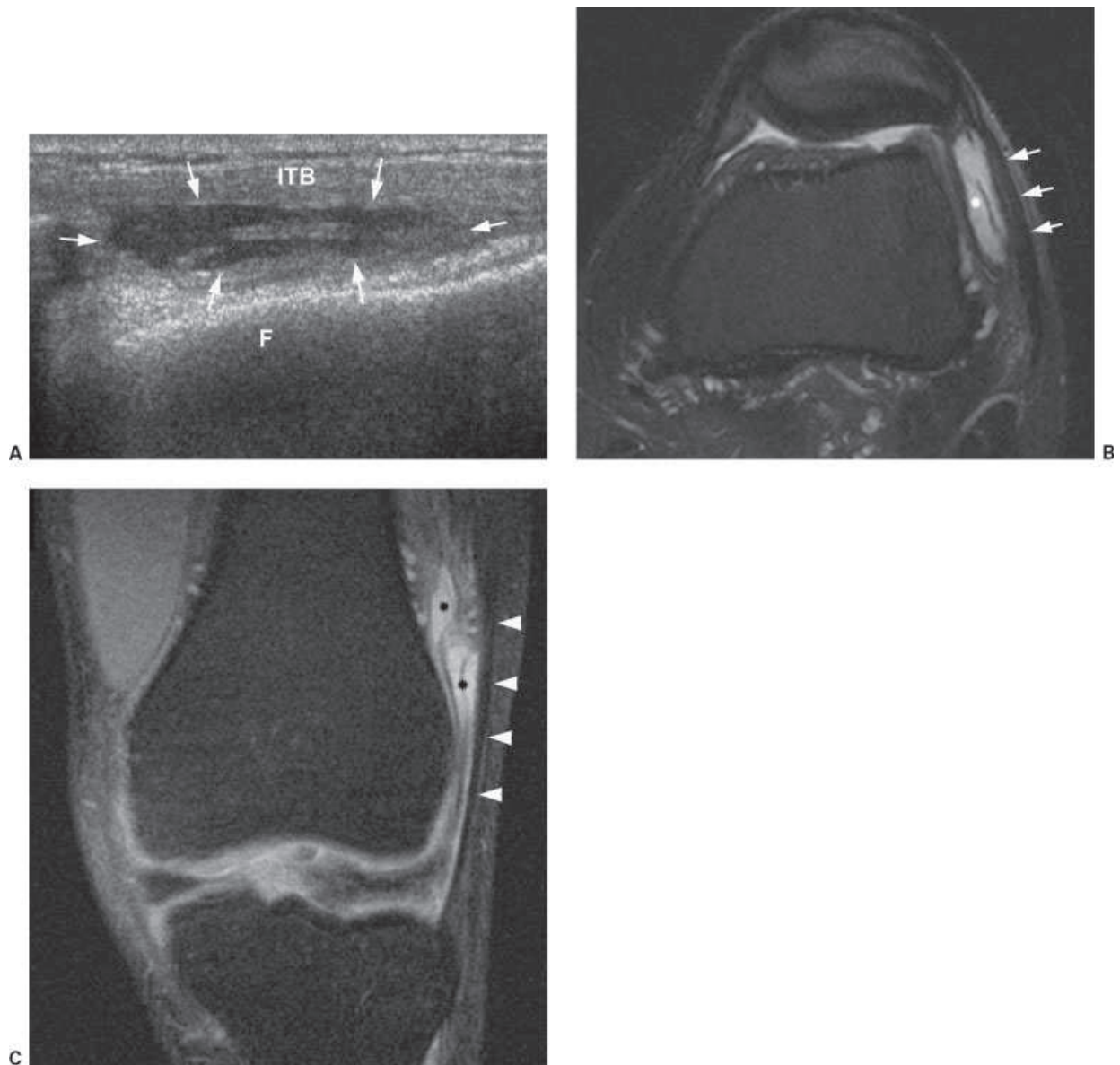
the medial tibial metaphysis, appearing as thin hyperechoic bands comprised of superficial and deep components separated by hypoechoic fibroadipose tissue. Low-grade injury with sprain is seen as hypoechoic fluid paralleling the MCL possibly with ligament thickening. In higher-grade injuries, there may be disruption

associated with bony avulsion at its attachments, or a partial- or full-thickness tear.<sup>19</sup> With complete rupture, hypoechoic fluid or hematoma may occupy the site of disruption. In chronic injury, the MCL may have a well-defined thickened appearance or contain calcification.<sup>1</sup> Gentle varus stress may help elucidate a tear.

The lateral collateral ligament complex is imaged with the patient supine and the leg in internal rotation or in the lateral decubitus position. The iliotibial (ITB) band is positioned somewhat anteriorly, and the fibular

collateral ligament and biceps femoris tendon are just posterior. The fibular collateral ligament is a thin band extending from the lateral femoral epicondyle to the fibular head and appears slightly hypoechoic.<sup>1</sup> A partial tear is seen as greater hypoechoogenicity and ill-defined thickening with surrounding fluid, whereas a full-thickness tear is seen as a disruption of the fibers often associated with hematoma.

The ITB friction syndrome, also called runner's knee, is commonly seen in athletes and readily evaluated



**Figure 8** Iliotibial bursitis. (A) Transverse scan along the lateral knee demonstrates fluid underlying the iliotibial band (ITB) with thickened periphery and internal septation (arrows), representing an acquired bursa. Lateral aspect of the femur (F) is appreciated deep to the bursa. (B) Axial T2-weighted fat-saturated magnetic resonance imaging (MRI) demonstrates fluid within the iliotibial bursa (asterisk) deep to a thickened ITB (arrows) and superficial to the lateral patellar retinaculum. The linear hypointense band within the bursa corresponds to the ultrasound finding. (C) Coronal proton-density fat-saturated MRI image shows the septated fluid collection (asterisk) deep to the ITB (arrowheads), which is coursing distally to insert onto the lateral tibial plateau.



with ultrasound. The normally hyperechoic ITB passes over the lateral femoral condyle, and repetitive motion may cause inflammation in the ITB and adjacent soft tissues. The ITB may be thickened and hypoechoic and may show surrounding fluid or an adventitial bursa deep to it over the condyle<sup>27</sup> (Fig. 8). The normal ITB on ultrasound in asymptomatic subjects measures ~2 mm in thickness at the level of the femoral condyle and 3 to 4 mm at the level of the tibial condyle.<sup>28</sup>

### LATERAL PATELLAR DISLOCATION

The medial soft tissue restraints of the patella, the medial patellar retinaculum and vastus medialis obliquus muscle, are important for patellofemoral instability. Several authors have evaluated the normal sonographic appearance of the retinaculum.<sup>29,30</sup> The medial patellar retinaculum appears as a bilaminar hypoechoic structure at the level of the patella, appearing thinner and not bilaminar superior and inferior to the patella.<sup>30</sup> It is normally thicker toward the patellar attachment. Ultrasound may show tear at either or both the patellar attachment, often associated with an avulsed bony fragment at the medial patella or at the femoral attachment at the adductor tubercle.<sup>31,32</sup>

### MUSCLES

Normal muscle appears hypoechoic with hyperechoic lines of fibroadipose septa interspersed throughout. Ultrasound is useful for the evaluation of muscle injury, including demonstration of partial- and full-thickness tears of the muscle and tendon. A partial tear will appear as an anechoic cleft or hypoechoic collection in the belly of the muscle.<sup>1</sup> As previously discussed, the quadriceps muscle and tendon are readily evaluated. Ultrasound can

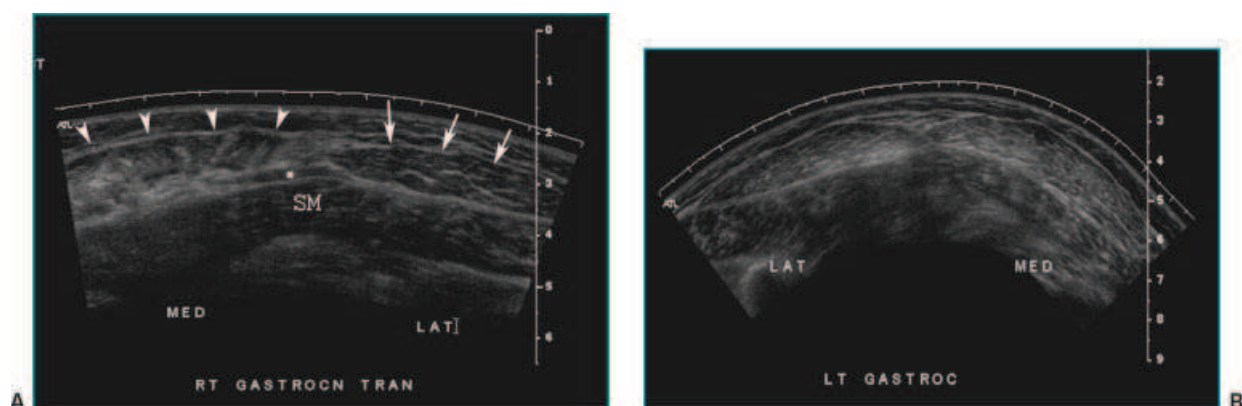
be used to evaluate for herniation of muscle through the fascia, a finding that is sometimes transient and therefore particularly amenable to real-time sonographic evaluation during which muscle flexion can evoke the abnormality.

Ultrasound is useful in the evaluation and follow-up of partial- and full-thickness tears of the medial head of the gastrocnemius ("tennis leg"), showing disruption at the origin and commonly associated with a hematoma or fluid collection between the gastrocnemius and the soleus muscles<sup>33</sup> (Fig. 9).

### ARTHRITIS AND SYNOVIAL PROCESSES

#### Rheumatoid Arthritis

Several authors have investigated ultrasound for its role in the evaluation of active inflammation in rheumatoid arthritis involving the knee and for its ability to detect subclinical synovitis. It is more sensitive than clinical examination by rheumatologists for the detection of effusion and synovitis, and in the literature, sonographic findings have correlated better with biological markers of inflammation, including the C-reactive protein and erythrocyte sedimentation rate, than did clinical measures.<sup>34</sup> Increased vascularity in the actively inflamed synovium of the knee has been shown with power Doppler by several studies.<sup>35-38</sup> Intermittently decreased perfusion has been demonstrated at serial ultrasound in symptomatic knees after knee aspiration and intra-articular steroid administration<sup>39</sup> and after therapy with the disease-modifying antirheumatic drug etanercept.<sup>40</sup> Thus ultrasound may be useful to assess active inflammation and response to treatment in the clinical and research settings. Likewise, ultrasound is sensitive and accurate to evaluate synovial thickening and effusion in the setting of juvenile rheumatoid arthritis.<sup>41,42</sup>



**Figure 9** Tennis leg. (A) An extended-view transverse scan of the calf demonstrates the distorted architecture of the medial gastrocnemius muscle (arrowheads) with a heterogeneous appearance due to edema. There is a small band of fluid (asterisk) between this muscle and the soleus muscle (SM). The lateral gastrocnemius muscle (arrows) appears normal. (B) The contralateral calf, which is normal, is readily available for comparison.

### Osteoarthritis

The specific etiology of pain in the setting of osteoarthritis has not been elucidated, and the severity of radiographic findings does not always correlate with symptoms. As such, ultrasound has been evaluated for its utility in painful episodes in osteoarthritis, with the authors of one study reporting a higher risk of a painful episode when there is suprapatellar effusion and Baker cyst.<sup>43</sup> However, ultrasound has a limited role in the evaluation of mechanical arthritis, with findings including meniscal pathology, osteophytes, and synovitis also evident.

### Calcium Pyrophosphate Dihydrate Deposition

Calcium pyrophosphate dihydrate deposition (CPPD) can affect the hyaline articular cartilage surfaces of the knee or the meniscal fibrocartilage. Within the normally uniformly hypoechoic band of articular cartilage along the articular surface, chondrocalcinosis appears as intrasubstance linear hyperechoic foci or a line.<sup>44,45</sup> Although this finding is generally readily detected radiographically, the appearance at sonography should suggest the diagnosis.

### Pigmented Villonodular Synovitis and Synovial Osteochondromatosis

Pigmented villonodular synovitis (PVNS) appears as a focal or diffuse mass or thickening within the joint or in the bursae, sometimes extending beyond the joint capsule. Because there are no specific sonographic appearances, MRI may provide a more definitive diagnosis by showing the characteristic hypointensity reflecting hemosiderin.<sup>46</sup> Synovial chondromatosis, due to synovial metaplasia, likewise has a nonspecific appearance. However, if the cartilage nodules have undergone ossification as frequently occurs, myriad ossific bodies with echogenic surfaces and posterior acoustic shadowing will be evident.

### EVALUATION AFTER TOTAL KNEE ARTHROPLASTY

Sonography is a useful adjunctive examination to radiographs in evaluating the knee after total arthroplasty, in which case MRI may be limited by artifact. The evaluation of anterior knee pain after total knee arthroplasty may be due to abnormalities of the extensor mechanism, whose pathology is the same as in the virgin knee. A rarer form of painful extensor mechanism dysfunction after arthroplasty is termed "patellar clunk syndrome," in which a fibrous nodule develops along the deep aspect of the distal quadriceps tendon. The nodule becomes entrapped in the anterior intercondylar notch, snapping free with extension.<sup>47</sup> Sonography shows an echogenic

area attached to the quadriceps tendon with vascularity by Doppler.<sup>48</sup>

Arthrofibrosis may cause chronic pain and stiffness after arthroplasty related to synovial hypertrophy and capsular thickening. In a study of patients with clinically established arthrofibrosis, ultrasound demonstrated a significantly greater thickness of the synovial membrane and neovascularity compared with asymptomatic controls.<sup>49</sup> Using a cutoff of 3.0 mm, sonography had a sensitivity of 84% and specificity of 82% for arthrofibrosis.<sup>49</sup>

The polyethylene liner of the arthroplasty is subject to abrasion and thinning and can be a significant source of debris predisposing to osteolysis. Although the liner is generally evaluated as a radiolucent band at radiography, ultrasound can demonstrate the liner as a strong linear echogenic interface with posterior acoustic shadowing and is accurate for measuring its thickness.<sup>50</sup>

### CONCLUSIONS

Ultrasound is a useful examination for evaluating the extensor mechanism, joint effusion and periarticular fluid collections, the collateral ligaments, muscle and tendon pathology, and synovitis. It may also be helpful for evaluation after total knee arthroplasty because MRI is limited by metallic artifact. Although sonography may demonstrate tears of the menisci and cruciate ligaments, MRI is generally preferred for evaluating internal derangement.

### REFERENCES

1. Friedman L, Finlay K, Jurriaans E. Ultrasound of the knee. *Skeletal Radiol* 2001;30(7):361-377
2. Bianchi S, Zwass A, Abdelwahab IF, Banderli A. Diagnosis of tears of the quadriceps tendon of the knee: value of sonography. *AJR Am J Roentgenol* 1994;162(5):1137-1140
3. Carr JC, Hanly S, Griffin J, Gibney R. Sonography of the patellar tendon and adjacent structures in pediatric and adult patients. *AJR Am J Roentgenol* 2001;176(6):1535-1539
4. Khan KM, Bonar F, Desmond PM, et al. Patellar tendinosis (jumper's knee): findings at histopathologic examination, US, and MR imaging. *Victorian Institute of Sport Tendon Study Group. Radiology* 1996;200(3):821-827
5. De Flaviis L, Scaglione P, Nesi R, Albisetti W. Ultrasound in degenerative cystic meniscal disease of the knee. *Skeletal Radiol* 1990;19(6):441-445
6. Fessell DP, Jacobson JA, Craig J, et al. Using sonography to reveal and aspirate joint effusions. *AJR Am J Roentgenol* 2000;174(5):1353-1362
7. Delaunoy I, Feipel V, Appelboom T, Hauzeur JP. Sonography detection threshold for knee effusion. *Clin Rheumatol* 2003;22(6):391-392
8. Bonnefoy O, Diris B, Moinard M, Aunoble S, Diard F, Hauger O. Acute knee trauma: role of ultrasound. *Eur Radiol* 2006;16(11):2542-2548

9. Costa DN, Cavalcanti CF, Sernik RA. Sonographic and CT findings in lipohemarthrosis. *AJR Am J Roentgenol* 2007;188(4):W389
10. Ward EE, Jacobson JA, Fessell DP, Hayes CW, van Holsbeeck M. Sonographic detection of Baker's cysts: comparison with MR imaging. *AJR Am J Roentgenol* 2001;176(2):373-380
11. Casser HR, Sohn C, Kiekenbeck A. Current evaluation of sonography of the meniscus. Results of a comparative study of sonographic and arthroscopic findings. *Arch Orthop Trauma Surg* 1990;109(3):150-154
12. Friedl W, Glaser F. Dynamic sonography in the diagnosis of ligament and meniscal injuries of the knee. *Arch Orthop Trauma Surg* 1991;110(3):132-138
13. Gerngross H, Sohn C. Ultrasound scanning for the diagnosis of meniscal lesions of the knee joint. *Arthroscopy* 1992;8(1):105-110
14. Azzoni R, Cabitza P. Is there a role for sonography in the diagnosis of tears of the knee menisci? *J Clin Ultrasound* 2002;30(8):472-476
15. Selby B, Richardson ML, Montana MA, Teitz CC, Larson RV, Mack LA. High resolution sonography of the menisci of the knee. *Invest Radiol* 1986;21(4):332-335
16. Selby B, Richardson ML, Nelson BD, Graney DO, Mack LA. Sonography in the detection of meniscal injuries of the knee: evaluation in cadavers. *AJR Am J Roentgenol* 1987;149(3):549-553
17. van Holsbeeck MIJ, Introcaso JH. *Musculoskeletal Ultrasound*. St. Louis: Mosby-Year Book; 2001
18. Rutten MJ, Collins JM, van Kampen A, Jager GJ. Meniscal cysts: detection with high-resolution sonography. *AJR Am J Roentgenol* 1998;171(2):491-496
19. De Maeseneer M, Lenchik L, Starok M, Pedowitz R, Trudell D, Resnick D. Normal and abnormal medial meniscocapsular structures: MR imaging and sonography in cadavers. *AJR Am J Roentgenol* 1998;171(4):969-976
20. Court-Payen M. Sonography of the knee: intra-articular pathology. *J Clin Ultrasound* 2004;32(9):481-490
21. Seymour R, Lloyd DC. Sonographic appearances of meniscal cysts. *J Clin Ultrasound* 1998;26(1):15-20
22. Ptasznik R, Feller J, Bartlett J, Fitt G, Mitchell A, Hennessy O. The value of sonography in the diagnosis of traumatic rupture of the anterior cruciate ligament of the knee. *AJR Am J Roentgenol* 1995;164(6):1461-1463
23. Skovgaard Larsen LP, Rasmussen OS. Diagnosis of acute rupture of the anterior cruciate ligament of the knee by sonography. *Eur J Ultrasound* 2000;12(2):163-167
24. Suzuki S, Kasahara K, Futami T, Iwasaki R, Ueo T, Yamamuro T. Ultrasound diagnosis of pathology of the anterior and posterior cruciate ligaments of the knee joint. *Arch Orthop Trauma Surg* 1991;110(4):200-203
25. Cho KH, Lee DC, Chhem RK, et al. Normal and acutely torn posterior cruciate ligament of the knee at US evaluation: preliminary experience. *Radiology* 2001;219(2):375-380
26. Miller TT. Sonography of injury of the posterior cruciate ligament of the knee. *Skeletal Radiol* 2002;31(3):149-154
27. Bonaldi VM, Chhem RK, Drolet R, Garcia P, Gallix B, Sarazin L. Iliotibial band friction syndrome: sonographic findings. *J Ultrasound Med* 1998;17(4):257-260
28. Goh LA, Chhem RK, Wang SC, Chee T. Iliotibial band thickness: sonographic measurements in asymptomatic volunteers. *J Clin Ultrasound* 2003;31(5):239-244
29. Phornphutkul C, Sekiya JK, Wojtys EM, Jacobson JA. Sonographic imaging of the patellofemoral medial joint stabilizing structures: findings in human cadavers. *Orthopedics* 2007;30(6):472-478
30. Starok M, Lenchik L, Trudell D, Resnick D. Normal patellar retinaculum: MR and sonographic imaging with cadaveric correlation. *AJR Am J Roentgenol* 1997;168(6):1493-1499
31. O'Reilly MA, O'Reilly PM, Bell J. Sonographic appearances of medial retinacular complex injury in transient patellar dislocation. *Clin Radiol* 2003;58(8):636-641
32. Trikha SP, Acton D, O'Reilly M, Curtis MJ, Bell J. Acute lateral dislocation of the patella: correlation of ultrasound scanning with operative findings. *Injury* 2003;34(8):568-571
33. Kwak HS, Han YM, Lee SY, Kim KN, Chung GH. Diagnosis and follow-up US evaluation of ruptures of the medial head of the gastrocnemius ("tennis leg"). *Korean J Radiol* 2006;7(3):193-198
34. Naredo E, Moller I, Moragues C, et al. Interobserver reliability in musculoskeletal ultrasonography: results from a "Teach the Teachers" rheumatologist course. *Ann Rheum Dis* 2006;65(1):14-19
35. Carotti M, Salaffi F, Manganeli P, Salera D, Simonetti B, Grassi W. Power Doppler sonography in the assessment of synovial tissue of the knee joint in rheumatoid arthritis: a preliminary experience. *Ann Rheum Dis* 2002;61(10):877-882
36. Kasukawa R, Yamadera Y, Takahashi A, Takeda I, Kanno T. Power Doppler sonography for detection of intraarticular vascularization in knee joints of patients with rheumatoid arthritis. *Mod Rheumatol* 2004;14(2):149-153
37. Qvistgaard E, Kristoffersen H, Terslev L, Danneskiold-Samsøe B, Torp-Pedersen S, Bliddal H. Guidance by ultrasound of intra-articular injections in the knee and hip joints. *Osteoarthritis Cartilage* 2001;9(6):512-517
38. Walther M, Harms H, Krenn V, Radke S, Faehndrich TP, Gohlke F. Correlation of power Doppler sonography with vascularity of the synovial tissue of the knee joint in patients with osteoarthritis and rheumatoid arthritis. *Arthritis Rheum* 2001;44(2):331-338
39. Newman JS, Laing TJ, McCarthy CJ, Adler RS. Power Doppler sonography of synovitis: assessment of therapeutic response—preliminary observations. *Radiology* 1996;198(2):582-584
40. Fiocco U, Cozzi L, Rubaltelli L, et al. Long-term sonographic follow-up of rheumatoid and psoriatic proliferative knee joint synovitis. *Br J Rheumatol* 1996;35(2):155-163
41. Cellerini M, Salti S, Trapani S, D'Elia G, Falcini F, Villari N. Correlation between clinical and ultrasound assessment of the knee in children with mono-articular or pauci-articular juvenile rheumatoid arthritis. *Pediatr Radiol* 1999;29(2):117-123
42. Sureda D, Quiroga S, Arnal C, Boronat M, Andreu J, Casas L. Juvenile rheumatoid arthritis of the knee: evaluation with US. *Radiology* 1994;190(2):403-406
43. de Miguel Mendieta E, Cobo Ibanez T, Uson Jaeger J, Bonilla Hernán G, Martín Mola E. Clinical and ultrasonographic findings related to knee pain in osteoarthritis. *Osteoarthritis Cartilage* 2006;14(6):540-544
44. Coari G, Iagnocco A, Zoppini A. Chondrocalcinosis: sonographic study of the knee. *Clin Rheumatol* 1995;14(5):511-514

45. Sofka CM, Adler RS, Cordasco FA. Ultrasound diagnosis of chondrocalcinosis in the knee. *Skeletal Radiol* 2002;31(1):43-45
46. Wakefield RJ, Brown A, O'Connor P, et al. Rheumatological ultrasound. *Rheumatology (Oxford)* 2003;42(8):1001
47. Miller TT. Sonography of joint replacements. *Semin Musculoskelet Radiol* 2006;10(1):79-85
48. Okamoto T, Futani H, Atsui K, Fukunishi S, Koezuka A, Maruo S. Sonographic appearance of fibrous nodules in patellar clunk syndrome: a case report. *J Orthop Sci* 2002;7(5):590-593
49. Boldt JG, Munzinger UK, Zanetti M, Hodler J. Arthrofibrosis associated with total knee arthroplasty: gray-scale and power Doppler sonographic findings. *AJR Am J Roentgenol* 2004;182(2):337-340
50. Sofka CM, Adler RS, Laskin R. Sonography of polyethylene liners used in total knee arthroplasty. *AJR Am J Roentgenol* 2003;180(5):1437-1441