



A Ruptured Retroperitoneal Germ Cell Tumor with Invasion into the Duodenum: A Case Report

W. Al Masri ¹, A. Alhendal ¹, M. Al Mishaan ¹

¹Department Of Surgery, Al- Sabah Hospital, Kuwait

Abstract

We report a rare case of a retroperitoneal germ cell tumor in a 31 years old male who presented with an acute abdomen. He gave a six-months history of back pain and significant weight loss.

Clinical examination and ultrasound of the testes didn't show any primary focus. Intra-operative findings showed a retroperitoneal midline mass that has ruptured into the

peritoneal cavity and has invaded into the duodenum. The final pathology revealed a yolk sac tumor.

We present this rare case of a primary para-aortic extragonadal yolk sac tumor and the differential diagnosis of a retroperitoneal mass.

Key Words

Retroperitoneal mass, extragonadal germ cell tumor, yolk sac tumor.

Introduction

The differential diagnosis of a retroperitoneal mass includes benign and malignant lesions. Benign masses include lymphangioma, lipoma, fibroma, leiomyoma, retroperitoneal fibrosis, dermoid cyst, nephrogenic cyst and adrenal adenoma. Examples of malignant masses include retroperitoneal sarcoma, (Extragonadal germ cell tumor), lymphoma, extension of a primary tumor, from renal, adrenal or colon. Enlarged para-aortic lymph nodes secondary to a testicular tumor can also present as a retroperitoneal mass. In fact the retroperitoneum is considered to be the most frequent site of late recurrences of testicular cancer. ⁽¹⁾

A tumor of germinal cells should be considered in the differential diagnosis of a retroperitoneal mass in a young patient. Although this kind of tumor is relatively uncommon, representing less than 1% of all tumors in males, very often they may present as a retro-peritoneal mass clinically characterised by lumbar pain that sometimes may simulate a renal colic.

Occasionally, physical examination of the testis may reveal a mass and there are a series of tumor markers very helpful for the diagnosis and follow up of the tumor. Moreover, even in advanced stages the prognosis of germ cell tumors is favourable ⁽²⁾.

Case Report

A 31 Years old male, admitted with a complaint of diffuse abdominal pain of one week duration. The patient was seen in a private clinic and a barium enema was ordered (Fig. 1). After the barium enema there was an aggravation of

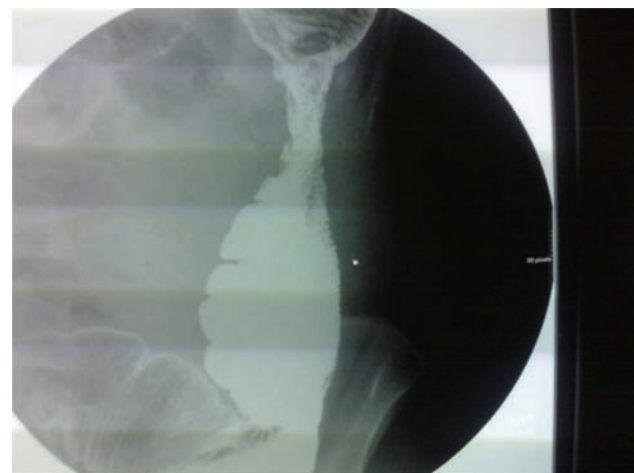

Fig. 1: Barium enema showing stenosed segment at the area of the sigmoid colon.

Address Correspondance To: Dr. Adnan Alhendal, Department Of Surgery, Al-sabah Hospital, Kuwait. Dradhend@hotmail.com.

his abdominal pain, which became very severe and diffuse. The patient gave a history of constipation and loss of appetite of few weeks duration. There was also a history of backpain six months earlier. MRI of the spine was done that was reported normal.

On Physical examination, the patient was in severe pain. The abdomen was diffusely tender and rigid. He was afebrile with normal haemoglobin and white cell count.

Chest X-ray showed air under the diaphragm. The patient was resuscitated and an urgent laparotomy was performed. The peritoneal cavity was full of pus, the greater omentum was necrotic and was stuck to loops of small bowel.

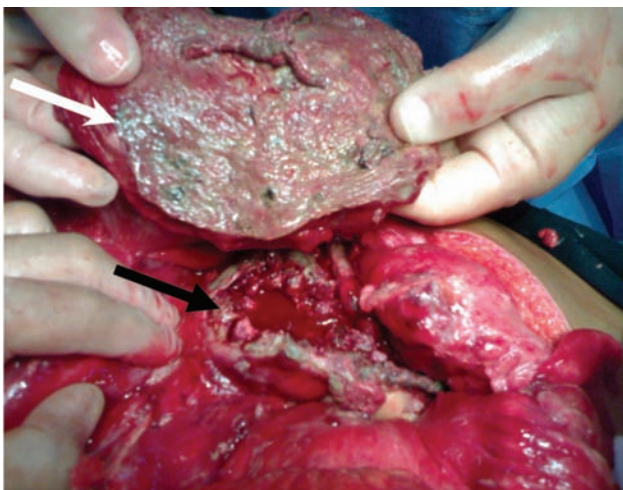


Fig. 2a: Necrotic Greater omentum adherent to loops of small bowel (white arrow). The black arrow points to the ruptured retroperitoneal mass.

The ruptured retroperitoneal mass was found stuck to the sigmoid mesentery, the root of small bowel mesentery, and penetrating through the duodenum. The small bowel loops were dilated and edematous (Fig. 2a - 2c).

Due to the hemodynamic instability of the patient and the gross contamination of the peritoneal cavity, incomplete resection of the mass was done due to its proximity to the major mesenteric blood vessels and the aorta. The perforation at the fourth part of the duodenum was converted into an external fistula using a depezar tube drain. The bed of the tumor was packed due to ongoing oozing.

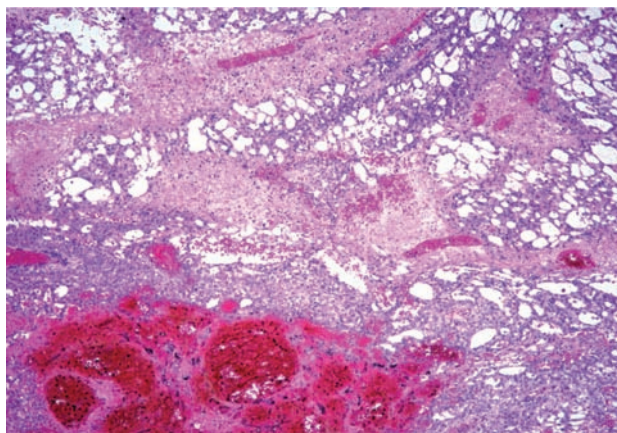


Fig. 2b: Primitive tumor with reticular pattern and areas of hemorrhage (Hematoxylin & eosin x40)

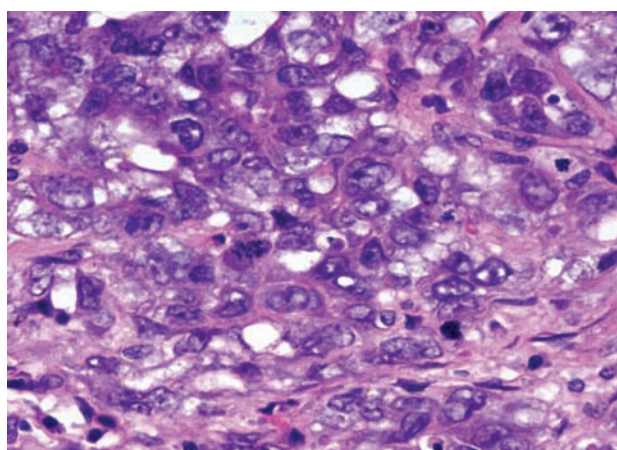


Fig. 2c: Primitive tumor cells with vesicular large nuclei and prominent nucleoli (Hematoxylin & eosin x400)

The abdominal wound was left open and the patient was shifted to the intensive care unit for correction of his acidosis and coagulation abnormalities.

A second look laparotomy was done. The packs were removed and the tumor bed was found dry with no more oozing. There was no more contamination of the peritoneal cavity and the small bowel loops looked much viable. The patient was shifted back to the intensive care unit and the same treatment was resumed with broad spectrum antibiotics, total parental nutrition and other supportive measures, including fistula care.

The patient showed dramatic improvement but the abdominal wound couldn't be closed primarily and a decision was taken to use a flap to close the wound.

So, a rotational flap using anterior thigh muscles with circumflex iliac artery as a feeding vessel was used. The flap eventually got necrotic and the patient expired secondary to sepsis and multi-organ failure.

Discussion

Retroperitoneal neoplasms are most commonly mesodermal, neurogenic or lymphatic in origin. Lymphoma, liposarcoma, leiomyosarcoma and malignant fibrous histiocytoma represent the vast majority of malignant primary retroperitoneal tumors.

Clinical diagnosis of a retroperitoneal lesion is difficult. Although modern diagnostic techniques such as computerized tomography (CT) permit accurate assessment of the retroperitoneum, many patients with retroperitoneal disease present with non specific symptoms, including abdominal pain, and back pain, and often have abdominal and spinal radiographs for work up. Although the radiographic features of re-troperitoneal neoplasms often overlap, certain CT characteristics, pattern of spread and specific tumor prevalence among different demographic groups can help to suggest the tumor type. CT is used to diagnose and assess the size and extent of retroperitoneal tumors, as well as to assess the involvement of organs and vasculature with resection in mind ⁽³⁾.

Retroperitoneal sarcomas are malignant tumors arising from mesenchymal cells usually located in the muscles, fat and connective tissue. They have varying clinical courses which depend on their histological subtype and grade.

The most commonly encountered subtypes are liposarcoma (41%) leiomyosarcoma (28%), malignant histiocytoma (7%), fibrosarcoma (6%) and malignant peripheral nerve sheath tumor (3%).

The evaluation and treatment of retroperitoneal soft tissue sarcomas remain challenging. The most important factor in the long term success in the treatment of primary tumors is complete surgical excision. The prognosis for patients with retroperitoneal sarcoma however

is poor with a 5-year survival rate ranging between 12% and 70%. Stage at presentation, high histological grade, unresectable primary tumour and incomplete resection are associated with a less favourable outcome. ⁽⁴⁾

Germ cell tumors occur mostly in the gonads. Extragonadal germ cell tumors are rare, and most occur in the retroperitoneum and mediastinum. Extragonadal germ cell tumors (EGGCT) are commonly found in the midline of the body. The most common site of EGGCTs is the mediastinum (50-70%) followed by the retroperitoneum (30-40%), the pineal gland (5%), and the sacrococcygeal area (less than 5%).

EGGCTs have been the source of much controversies and diagnostic difficulties in terms of determining their site of origin. However, throughout the last decades, there has been general agreement that germ cell tumors existing at extragonadal sites are EGGCT when the testes show no clinical signs of tumor on palpation. Occasionally, in patients with presumed EGGCTs, a fibrous scar is found in the testes at autopsy, or a gonadal primary tumor becomes evident during follow-up. Approximately 5 - 7 % of germ cell tumors are of extragonadal origin. Chemotherapy is the initial treatment of choice for extragonadal germ cell tumors. A primary testicular tumor must be ruled out by sonographic investigation and biopsy. The rate of metachronous testicular cancer in men with primary EGGCT is largely unknown ⁽⁵⁾. It appears that there are very few true extragonadal germ cell tumors, and that the possibility of primary testicular origin metastasizing from viable occult testicular tumor or burned-out testicular tumor with spontaneous regression is high in retroperitoneal germ cell tumors. ⁽⁶⁾

As part of the initial evaluation in young patients with undiagnosed abdominal or chest masses, tumors markers such as LDH, AFP and β -HCG levels should all be measured.

Extragonadal germinal tumors are frequently mixed tumors. ⁽⁷⁾

Yolk sac tumor is a rare, malignant tumor which arises from cells which line the yolk sac

of the embryo. These cells normally become ovaries or testes during development. However, the tumor can also occur in areas such as the brain or chest. Histological evaluation of these tumors demonstrates eosinophilic periodic acid-schiff [PAS]-positive inclusions bodies in the cytoplasm of clear cells that consist of AFP and schiller-duval bodies. A yolk-sac tumor could be judiciously demonstrated by either an elevated serum level of alpha foetoprotein (AFP), or by fine needle aspiration cytology. ⁽⁹⁾

Conclusion

Germ cell tumors should always be in the differential diagnosis of a retroperitoneal mass, especially in young patients. A primary source in the testes should always be searched for.

Acknowledgement

We would like to thank Dr Kenneth C. Katchy and Dr. Wael T. Abodie, Department of pathology, Al Sabah hospital for their contribution to this case report.

References

1. Sekine I, Sasaki Y, Hasebe T, et al. Recurrence of a germ cell tumor 12 years after initial treatment: a case report. *Jpn J Clin Oncol* 1998;28(1):50-3.
2. Solano RM, Velilla AJP, Alvarez FM. A retroperitoneal mass in a young patient. *An Med Interna* 2006;23(1):34-6.
3. Neville A, Herts BR. CT characteristics of primary retroperitoneal neoplasms. *Crit Rev Comput Tomogr* 2004;45(4):247-70.
4. Pirayesh A, Chee Y, Helliwell TR, et al. The management of retroperitoneal soft tissue sarcoma: a single institution experience with a review of the literature. *European Journal of Surgical Oncology* 1999;27(5):491-7.
5. Hatzinger M, Knoll T, Alken P, et al. Metachronous testicular tumor of an extragonadal germ cell tumor. *Aktuelle Urol* 2003;34(6):413-5.
6. Kitahara K, Hori J, Tokumitsu M, et al. Retroperitoneal germ cell tumor with testicular calcification indicating tiny testicular origin: consideration of the origin of retroperitoneal germ cell tumors: report of two cases. *Hinyokika Kyo* 2003;49(5):291-5.
7. Mrad K, Abid L, Oubiche F, et al. The value of cytology in the diagnosis of extragonadal germ cell tumors. *Ann Pathol* 2004;24(4):356-9.