

Hemophagocytic Lymphohistiocytosis: Advances in Pathophysiology, Diagnosis, and Treatment

Shanmuganathan Chandrakasan, MD, and Alexandra H. Filipovich, MD

Hemophagocytic lymphohistiocytosis (HLH) is a potentially life-threatening disorder characterized by immune dysregulation, overwhelming immune activation, and inflammation. HLH has been categorized as primary or familial HLH (FHLH), when there is a family history of HLH or known underlying genetic defects. Reactive or secondary HLH occurs in the setting of infection or underlying rheumatologic disorders or malignancy. HLH occurring in a setting of rheumatologic illness is commonly referred to as macrophage activation syndrome (MAS).¹

Most patients with FHLH have defects in lymphocyte cytotoxicity, leading to ineffective infection control and immune dysregulation resulting in massive activation and expansion of cytotoxic T cells and macrophages. This immune activation results in marked elevation of inflammatory cytokines, including interferon (IFN)- γ , interleukin (IL)-1, IL-6, and IL-10, and an ensuing extreme hyperinflammatory state. Clinically, patients with FHLH or secondary HLH typically present with high-grade fever, progressive cytopenias, liver dysfunction, coagulopathy, and variable degrees of neurologic symptoms.² Depending on the predominant organ system involved in HLH, patients may be seen by different clinical subspecialists. Initial manifestations of HLH may include fulminant hepatic failure³ or isolated neurologic involvement presenting with seizures and altered sensorium.⁴

Over the last decade, research on the genetics and pathophysiology of HLH has greatly improved our understanding of this condition. Importantly, increasing awareness and availability of better treatment options have improved the prognosis of HLH from a fatal disorder to a treatable condition with good long-term survival.⁵ In this review, we present recent advances in genetic and pathophysiological research, rapid diagnostic modalities, and clinical management of HLH.

Subtypes of HLH

Granule-mediated cytotoxic T lymphocyte (CTL) function is essential for the control of infection, as well as regulation and termination of the immune response. Mutations in genes that encode proteins critical to the lymphocyte granule-mediated cytotoxic pathway lead to FHLH.⁶ Based on genetic etiology, FHLH has been subcategorized into 5 subtypes, FHLH-1 to FHLH-5.⁷ The mutation in FHLH-1 remains unidentified, but the defect has been mapped to chromosome 9q21.3. FHLH-2 is due to mutations in the gene encoding perforin (*PRF-1*).⁸ Mutations in the genes encoding Munc-13-4 (*UNC13D*),⁹ syntaxin 11 (*STX11*),¹⁰ and syntaxin-binding protein 2 (*STXBP2*)¹¹ are associated with FHLH-3, -4, and -5, respectively. HLH is also described in 3 distinct disorders of intracellular granule trafficking resulting in both pigmentary abnormalities and defective cytotoxicity. They include Griscelli syndrome type II (*RAB27A*), Chediak-Higashi syndrome (*LYST*), and Hermansky-Pudlak syndrome type II (*AP3B1*). In these disorders, the defect in granule trafficking also affects neutrophil and platelet function. The degranulation pathway and the disorders associated with this pathway are illustrated in the **Figure** and listed in **Table I**.

Two unique X-linked disorders that do not affect the cytotoxic pathway directly but are associated with Epstein-Barr virus (EBV)-driven HLH are X-linked lymphoproliferative disease (XLP)¹² and X-linked inhibitor of apoptosis (XIAP).¹³ XLP is caused by mutations in the *SH2DIA* gene encoding signaling lymphocyte-activating molecule-associated protein. Recently, mutations in IL-2-inducible T cell kinase (*ITK*),¹⁴ *CD27*,¹⁵ and magnesium transporter gene (*MAGT1*)¹⁶ have been reported to be associated with EBV-associated lymphoproliferation, lymphoma, and HLH. The classification, genetic defects, and salient clinical features of HLH are summarized in **Table I**.

Infection and rheumatologic illness are the 2 most common settings of secondary HLH in children. Various infectious agents have been associated with HLH, with viral-associated HLH by far the most common form.¹⁷ Herpes family viruses, including EBV and cytomegalovirus, are frequent causes of infection-associated HLH.¹⁷ Systemic-onset juvenile idiopathic arthritis and systemic lupus

ATG	Antithymocyte globulin
CTL	Cytotoxic T lymphocyte
EBV	Epstein-Barr virus
FHLH	Familial hemophagocytic lymphohistiocytosis
HCT	Hematopoietic stem cell transplantation
HLH	Hemophagocytic lymphohistiocytosis
IFN	Interferon
IL	Interleukin
MAC	Myeloablative conditioning
MAS	Macrophage activation syndrome
NK	Natural killer
RIC	Reduced-intensity conditioning
XIAP	X-linked inhibitor of apoptosis
XLP	X-linked lymphoproliferative disease

From the Division of Bone Marrow Transplantation and Immune Deficiency Cincinnati Children's Hospital Medical Center, Cincinnati, OH

The authors declare no conflicts of interest.

0022-3476/\$ - see front matter. Copyright © 2013 Mosby Inc.
All rights reserved. <http://dx.doi.org/10.1016/j.jpeds.2013.06.053>

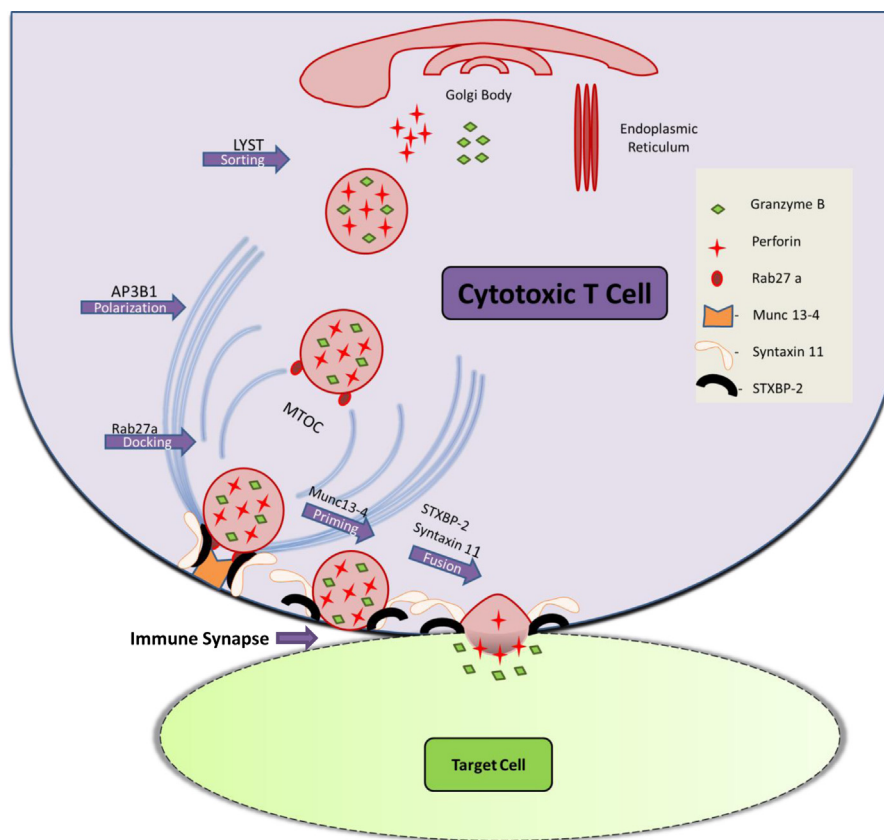


Figure. CTL activation results in microtubule organizing Centre (MTOC) polarization and transport of cytotoxic granules. LYST and AP3B1 are involved in sorting and transport of cytotoxic granules. The granules are then docked to the site of immune synapse by Rab27a. Granule priming is mediated by Munc13-4, and membrane fusion by STX11 and STXBP2. Granule fusion results in perforin mediated pore formation and release of lysosomal enzymes leading to target cell death. Genetic defects in highlighted proteins involved in granule-mediated cytotoxicity leads to HLH.

erythematosus are the rheumatologic conditions most commonly associated with MAS. Among malignancies, lymphoma and acute lymphoblastic leukemia have been reported in children with HLH.¹⁸ Of note, although infections alone can lead to secondary HLH, they are also the common trigger for overwhelming immune activation in FHLH. Thus, attempts should be made to identify an underlying genetic predisposition even if an obvious infectious trigger is identified.

Pathophysiology

In the normal physiological context, granule-mediated cytotoxic function of natural killer (NK) cells and CTLs is required for clearance of viral infection as well as regulation and termination of the inflammatory response.¹⁹ Thus, defects in NK cell and CTL granule-mediated cytotoxicity result in ineffective clearance of infection and defective suppression of antigen presentation, leading to persistent antigen exposure and prolonged cytotoxic T-cell activation.¹⁹ Until recently, the pathophysiology of secondary HLH was not well understood. However, the finding of an HLH/MAS-

like condition from repeated Toll-like receptor 9 stimulation in a murine model could explain the potential mechanism of HLH in inflammatory conditions with normal T-cell cytotoxicity.²⁰

Overwhelming T-cell and macrophage activation results in the “cytokine storm,” characterized by marked elevation of cytokines, such as IFN- γ , tumor necrosis factor α , IL-6, IL-8, IL-10, IL-12, IL-18, and macrophage colony-stimulating factor.²¹ IFN- γ has been shown to play a critical role in macrophage activation and hemophagocytosis.²² Elevated tumor necrosis factor levels lead to hypofibrinogenemia²¹ and hypertriglyceridemia.²³ Gene expression studies on peripheral blood mononuclear cells in patients with active HLH have revealed down-regulation of genes involved in innate and adaptive immune systems, including Toll-like receptor expression and B-cell and T-cell function. This finding suggests that patients with active HLH experience an immunodeficient state that may lead to increased susceptibility to infections.²⁴

HLH is a defect in immune regulation, apart from classical defects in granule-mediated cytotoxicity in FHLH, and

Table I. Classification of primary HLH, notable clinical findings, and rapid diagnostic results

HLH type	Defective gene	Function	Notable clinical findings	Rapid diagnosis by flow cytometry
FHLH-2	<i>PRF1</i>	Pore formation		Decreased/absent perforin expression
FHLH-3	<i>UNC13D</i>	Vesicle priming	Increased incidence of CNS HLH	Decreased CD107a expression
FHLH-4	<i>STX11</i>	Vesicle fusion	Mild, recurrent HLH, and colitis	Decreased CD107a expression
FHLH-5	<i>STXBP2</i>	Vesicle fusion	Colitis and hypogammaglobulinemia	Decreased CD107a expression
Syndromes				
Griscelli syndrome type II	<i>RAB27A</i>	Vesicle docking	Partial albinism and silvery-gray hair	Decreased CD107a expression, abnormal hair shaft examination*
Chediak-Higashi syndrome	<i>LYST</i>	Vesicle trafficking	Partial albinism, bleeding tendency, and recurrent pyogenic infection	Decreased CD107a expression, abnormal neutrophil granules†
Hermansky-Pudlak syndrome type II	<i>AP3B1</i>	Vesicle trafficking	Partial albinism, bleeding tendency, and immunodeficiency	Decreased CD107a expression
EBV-driven				
XLP-1	<i>SH2D1A</i>	Signaling in T, NK, and NK T-cells	Hypogammaglobulinemia and lymphoma	Decreased/absent SAP expression
XLP-2/XIAP‡	<i>BIRC4</i>	Signaling pathways involving NF-κB	Mild, recurrent HLH and colitis	Decreased/absent XIAP expression
IL-2–inducible T-cell kinase deficiency	<i>ITK</i>	Signaling in T-cell	AR, Hodgkin lymphoma	NA (gene sequencing required)
CD27 deficiency	<i>CD27</i>	Lymphocyte costimulatory molecule	AR, combined immunodeficiency	Absent CD27 expression on B cells
XMEN	<i>MAGT1</i>	T-cell activation via T-cell receptor	Combined immunodeficiency, chronic viral infections, and lymphoma	Decreased CD4 cells and defects in T-cell receptor signaling

CNS, central nervous system; AR, autosomal recessive; NF-κB, nuclear factor kappa light chain enhancer of activated B cells; SAP, signaling lymphocyte-activating molecule–associated protein; XMEN, X-linked immunodeficiency with Mg²⁺ defect, EBV infection, and neoplasia; NA, not available.

*Light microscopy examination of a hair shaft shows a characteristic abnormal clumping of pigment.

†Light microscopy examination of peripheral blood smear shows giant granules in neutrophils and other leukocytes.

‡Defect is present in all tissues.

the alternate pathway of direct macrophage activation could play a significant role in secondary HLH.

Clinical Presentation

FHLH was once thought to affect predominantly infants and young children. However, recent reports suggest that it can affect all age groups, from preterm neonates²⁵ to elderly adults.²⁶ With increasing awareness, HLH is likely to be diagnosed more often in infants. However, its occurrence in neonates and adults is still underrecognized.^{25,27} HLH in neonates merits special mention because the disorder can be easily missed and mismanaged as sepsis. Fever, a frequent symptom in children with HLH, is uncommon in neonates, especially those born preterm. Herpes simplex virus and enterovirus are common triggers of severe HLH in the neonatal period.^{25,28}

Classical manifestations of HLH include high-grade fever, progressive cytopenias, liver dysfunction, coagulopathy, and variable neurologic symptoms²⁹ (Table II). Untreated HLH is potentially fatal. Interestingly, patients with defects in *STX11* and *XIAP* have been reported to have milder recurrent episodes of HLH compared with patients with other forms of FHLH.¹⁰ Neurologic involvement is seen in approximately 30%–50% of patients with HLH^{4,30,31}; symptoms at presentation include seizures, altered mental status, brain stem symptoms, and ataxia. HLH also may be associated with atypical manifestations, such as colitis, bleeding disorder, and hypogammaglobulinemia. Colitis has been reported in a significant proportion of patients with defects of *STXBP2* (38%)³² and *XIAP* (17%).³³ Hypogammaglobulinemia is reported in two-thirds of patients with defects of *XLP-1*³³

and *STXBP2*.³² Based on the findings of colitis and hypogammaglobulinemia, some of these patients were initially diagnosed with common variable immunodeficiency.^{32,34}

Genetics

With the identification of defects in *PRF1*, *UNC13D*, *STX11*, and *STXBP2* genes in FHLH, a genetic diagnosis can be made in up to 40%–80% of patients with HLH.^{35,36} Defects in *UNC13D* are the predominant defects identified in Caucasians in the US.³⁶ In African-American patients, *PRF1* defects are by far the most common.³⁶ Studies in patients with defects in *PRF1*,³⁷ *UNC13D*,³⁸ and *STXBP2*³² have shown broad phenotype–genotype correlations based on the functionality of the protein expressed. Generally, the complete absence of protein resulting from frameshift and nonsense mutations

Table II. Diagnostic criteria for HLH

Diagnosis of HLH is based on the presence of 5 or more of the following:

- Fever
- Splenomegaly
- Cytopenias (affecting 2 of 3 lineages in the peripheral blood)
 - Hemoglobin <90 g/L (<100 g/L in infants aged <4 weeks)
 - Platelets <100 × 10⁹/L
 - Neutrophils <1.0 × 10⁹/L
- Hypertriglyceridemia and/or hypofibrinogenemia
 - Fasting triglycerides >3.0 mmol/L
 - Fibrinogen <1.5 g/L
- Hemophagocytosis in bone marrow, spleen, or lymph nodes
- Low or absent NK-cell activity
- Ferritin >500 μg/L
- sIL-2R >2400 U/mL

sIL-2R, soluble IL-2 receptor.

Adapted from the Histiocyte Society HLH-2004 protocol.²⁹

results in HLH at an early age and with more severe manifestations compared with HLH associated with hypomorphic (ie, missense and splice-site sequence variants) mutations. Interestingly, hypomorphic mutations in *PRF1*, *UNC13D*, and *STXBP2* have been reported in 14% of adults with HLH.³⁹

For a long time, only exons of disease causing genes were screened for genetic defects in HLH. Recently, deep intronic and inversion mutations in *UNC13D* were identified in patients with HLH. These mutations are the leading cause of FHLH in many European countries.⁴⁰ Multiple genetic predispositions also have been identified in patients with secondary HLH. However, unlike the genetic defects identified in patients with FHLH, those in secondary HLH involve sequence variants or single-nucleotide polymorphisms.⁴¹

Currently, the genetic basis for HLH can be identified in a significant proportion of patients. The genetic predisposition to HLH varies from classical frameshift and nonsense mutations in children with FHLH to sequence variants and single-nucleotide polymorphisms in patients with secondary HLH.

Diagnosis

The Histiocyte Society HLH 2004 protocol establishes both clinical and laboratory diagnostic criteria for the diagnosis of HLH²⁹ (Table II). These published criteria pertain especially to the diagnosis of FHLH. For early diagnosis of secondary HLH (especially MAS), decreasing leukocyte and platelets counts may be more relevant than absolute cytopenias. Although analysis of bone marrow aspirate is commonly used for diagnosing HLH, it has a sensitivity of only ~60%.⁴² Undue emphasis on a lack of hemophagocytosis could result in either missed or delayed diagnosis. Thus, a negative bone marrow analysis result should not preclude initiation of therapy if there is high clinical suspicion and laboratory evidence of HLH. On the other hand, the sensitivity of bone marrow analysis potentially could be improved by the addition of CD163 immunohistochemistry,⁴³ a marker of activated histiocytes.

Sometimes, differentiating a normal infection or rheumatologic illness-associated inflammatory state from hyperinflammatory HLH can be challenging. Fortunately, an array of rapid diagnostic tests is available to aid the diagnosis of HLH. Ferritin, an acute-phase reactant secreted by activated macrophages, has been widely used as a screening tool for HLH. A level >500 $\mu\text{g/L}$ is supportive of HLH,²⁹ but is nonspecific and can be seen in other febrile illnesses; however, a value >10 000 $\mu\text{g/L}$ has been reported to be highly specific and diagnostic of HLH (90% sensitivity and 96% specificity).⁴⁴ Soluble IL-2 receptor α , a marker of activated T lymphocytes, is increasingly used in the diagnosis and monitoring of patients with HLH. Soluble CD163, a marker of monocyte/macrophage activation, also has been reported to be useful in diagnosing HLH.⁴⁵ Elevations of multiple proinflammatory cytokines are seen in patients with HLH, and markedly elevated levels of IFN- γ and IL-10 have been identified as helpful markers in diagnosing HLH.⁴⁶

Several reliable flow cytometry-based rapid screening tests are available to help identify patients with FHLH.⁴⁷ Surface expression of CD107a on NK cells and CTLs is used to measure the integrity of the lymphocyte granule-mediated cytotoxicity pathway.⁴⁸ Patients with defects in genes of the cytotoxic degranulation pathway, such as *UNC13D*, *STX11*, *STXBP2*, and *RAB27A*, demonstrate decreased CD107a expression.^{48,49}

In contrast, patients with a *PRF-1* defect, XLP, XIAP, or secondary HLH generally show normal degranulation.⁴⁸ However, HLH due to defects in *PRF-1*, XLP-1, and XIAP can be identified by flow cytometry-based assays to detect the intracellular expression of perforin,⁴⁷ signaling lymphocyte-activating molecule-associated protein,⁵⁰ and XIAP.⁵¹ NK cell cytotoxicity assay is another commonly ordered test in the workup for HLH; however, this assay is more time-consuming, and NK cell cytotoxicity might not be depressed in all patients with HLH. Furthermore, this assay is insensitive in infants under 3 months of age. Thus, an abnormal NK function assay may be supportive of, but not diagnostic of, HLH.

In conjunction with the basic laboratory and clinical features, ferritin and soluble IL-2 receptor are the most useful widely available and validated markers for diagnosing HLH. Once a diagnosis of HLH is made, flow cytometry-based screening tests and a confirmatory genetic workup will guide long-term management, including hematopoietic stem cell transplantation (HCT).

Treatment

Significant advances have been made in the management of HLH over the last 2 decades. Current management of HLH involves a 2-pronged approach comprising a short-term strategy aimed at controlling the hyperinflammatory state and a long-term strategy aimed at definitively correcting the underlying genetic defect by allogeneic HCT. Management of the hyperinflammatory state focuses on 3 main areas: controlling or eliminating the infectious trigger, stopping T-cell proliferation and activation, and stopping or controlling the inflammatory process by blocking excessive cytokine production and function.

To control T-cell proliferation and activation, the Histiocyte Society HLH-94 protocol specified an 8-week course of combination dexamethasone-etoposide therapy.⁵ With this protocol, the remission induction rate was 71%, and 5-year post-HCT survival probability was 54% \pm 6%.⁵ Transplantation outcomes were better in patients with adequately controlled HLH activity before HCT.⁵ In an effort to improve the remission rate and to achieve better control of HLH activity, intensification of initial therapy with the addition of cyclosporine and intrathecal steroids was proposed in the Histiocyte Society HLH-2004 protocol.²⁹ Another HLH induction protocol consisting of antithymocyte globulin (ATG) in combination with steroids reported 82% short-term complete response in HLH.⁵² Based on this promising result, ATG has been incorporated into a novel hybrid therapy with chemotherapy. Hybrid Immunotherapy-HLH, a phase II clinical trial based on this principle, is now open and enrolling patients in the US.

Until recently, there was no good second-line therapy for pretransplantation treatment of HLH refractory to etoposide-based therapy. Alemtuzumab, a monoclonal antibody to CD52, reportedly induced partial response in 64% of treated patients.⁵³ As noted earlier, the status of HLH activity before HCT predicts ultimate outcome. Thus, in patients refractory to HLH-2004–based induction therapy, alemtuzumab might be useful bridge therapy for better disease control before proceeding to HCT.

HCT with myeloablative conditioning (MAC) using busulfan, cyclophosphamide, and etoposide with or without ATG has long been the standard of care for patients with HLH.²⁹ However, MAC HCT is associated with high transplantation-related mortality (30%–50%).⁵ In addition, patients with XIAP deficiency were found to have poor tolerance to MAC.⁵⁴ Reduced-intensity conditioning (RIC) with alemtuzumab, fludarabine, and melphalan has demonstrated better outcomes in HCT, and its use is increasing.^{55,56} Marsh et al⁵⁶ reported a 3-year survival rate of 92% in their RIC cohort, compared with 43% in their MAC cohort. However, a higher incidence of mixed donor chimerism was noted with RIC HCT. Although the RIC approach appears promising, more follow-up is needed to ascertain the long-term outcome. Novel treatment modalities, such as gene therapy for correction of perforin defects, are currently under evaluation. Preliminary data using a HLH mouse model have shown encouraging results.

Unlike with FHLH, there is no broad consensus on management of secondary HLH. The identification of genetic polymorphisms and heterozygosity for known HLH mutations has made long-term treatment decision making more complicated. In MAS, therapy with pulsed steroids and/or cyclosporine has demonstrated a good response.^{57,58} Various other targeted therapies, including alemtuzumab, infliximab, etanercept, and daclizumab, have been identified to be useful in anecdotal reports. There is no specific management guidelines for any infection-associated forms of HLH apart from EBV-driven HLH. EBV-associated HLH has historically been associated with poor outcome; however, outcomes have improved significantly with the use of rituximab, etoposide, and HCT for refractory EBV-associated HLH.⁵⁹ In both primary and secondary HLH, management of associated infection is essential for resolving HLH. Moreover, in infection-associated HLH, management of infection alone is often insufficient for clinical improvement. Some form of immunosuppressive/immunomodulatory therapy might be necessary to manage the hyperinflammatory state.¹⁷ Interestingly, in tropical infections associated with HLH, such as leishmaniasis,⁶⁰ definitive management of infection alone appears to be sufficient to control the associated HLH symptoms.

Summary

HLH is a potentially fatal disorder of immune regulation. Depending on the severity of the underlying genetic defect, it can present across all age groups. Both pediatricians and subspecialists need to be aware of the atypical presentations of

HLH. Colitis, bleeding tendency, and hypogammaglobulinemia are not uncommon in HLH. When evaluating patients with HLH, secondary HLH/MAS from underlying infections, rheumatologic disease, or malignant neoplasms should be considered as well. Many rapid diagnostic tests are available for diagnosing HLH. Increased awareness, early identification, and definitive management have improved outcomes. ■

Submitted for publication Oct 20, 2012; last revision received Jun 10, 2013; accepted Jun 24, 2013.

Reprint requests: Shanmuganathan Chandrakasan, MD, Division of Bone Marrow Transplantation and Immune Deficiency, Cincinnati Children's Hospital Medical Center, 3333 Burnet Ave, Cincinnati, OH 45229. E-mail: Shanmuganathan.Chandrakasan@cchmc.org

References

- Stephan JL, Zeller J, Hubert P, Herbelin C, Dayer JM, Prieur AM. Macrophage activation syndrome and rheumatic disease in childhood: a report of four new cases. *Clin Exp Rheum* 1993;11:451-6.
- Janka GE. Familial hemophagocytic lymphohistiocytosis. *Eur J Pediatr* 1983;140:221-30.
- Danhaive O, Caniglia M, Devito R, Piersigilli F, Corchia C, Auriti C. Neonatal liver failure and haemophagocytic lymphohistiocytosis caused by a new perforin mutation. *Acta Paediatr* 2010;99:778-80.
- Haddad E, Sulis ML, Jabado N, Blanche S, Fischer A, Tardieu M. Frequency and severity of central nervous system lesions in hemophagocytic lymphohistiocytosis. *Blood* 1997;89:794-800.
- Trotttestam H, Horne A, Arico M, Egeler RM, Filipovich AH, Gadner H, et al. Chemotherapy for hemophagocytic lymphohistiocytosis: long-term results of the HLH-94 treatment protocol. *Blood* 2011;118:4577-84.
- Ladisch S, Poplack DG, Holiman B, Blaese RM. Immunodeficiency in familial erythrophagocytic lymphohistiocytosis. *Lancet* 1978;1:581-3.
- Janka GE, Schneider EM. Modern management of children with haemophagocytic lymphohistiocytosis. *Br J Haematol* 2004;124:4-14.
- Dufourcq-Lagelouse R, Jabado N, Le Deist F, Stephan JL, Souillet G, Bruin M, et al. Linkage of familial hemophagocytic lymphohistiocytosis to 10q21-22 and evidence for heterogeneity. *Am J Hum Genet* 1999;64:172-9.
- Feldmann J, Callebaut I, Raposo G, Certain S, Bacq D, Dumont C, et al. Munc13-4 is essential for cytolytic granules fusion and is mutated in a form of familial hemophagocytic lymphohistiocytosis (FHL3). *Cell* 2003;115:461-73.
- Zur Stadt U, Schmidt S, Kasper B, Beutel K, Diler AS, Henter JJ, et al. Linkage of familial hemophagocytic lymphohistiocytosis (FHL) type-4 to chromosome 6q24 and identification of mutations in syntaxin 11. *Hum Mol Genet* 2005;14:827-34.
- Zur Stadt U, Rohr J, Seifert W, Koch F, Grieve S, Pagel J, et al. Familial hemophagocytic lymphohistiocytosis type 5 (FHL-5) is caused by mutations in Munc18-2 and impaired binding to syntaxin 11. *Am J Hum Genet* 2009;85:482-92.
- Nichols KE, Harkin DP, Levitz S, Krainer M, Kolquist KA, Genovese C, et al. Inactivating mutations in an SH2 domain-encoding gene in X-linked lymphoproliferative syndrome. *Proc Natl Acad Sci USA* 1998;95:13765-70.
- Rigaud S, Fondaneche MC, Lambert N, Pasquier B, Mateo V, Soulas P, et al. XIAP deficiency in humans causes an X-linked lymphoproliferative syndrome. *Nature* 2006;444:110-4.
- Stepensky P, Weintraub M, Yanir A, Revel-Vilk S, Krux F, Huck K, et al. IL-2–inducible T-cell kinase deficiency: clinical presentation and therapeutic approach. *Haematologica* 2011;96:472-6.
- van Montfrans JM, Hoepelman AI, Otto S, van Gijn M, van de Corput L, de Weger RA, et al. CD27 deficiency is associated with combined immunodeficiency and persistent symptomatic EBV viremia. *J Allergy Clin Immunol* 2012;129:787-93.

16. Li FY, Chaigne-Delalande B, Kanellopoulou C, Davis JC, Matthews HF, Douek DC, et al. Second messenger role for Mg²⁺ revealed by human T-cell immunodeficiency. *Nature* 2011;475:471-6.
17. Roupheal NG, Talati NJ, Vaughan C, Cunningham K, Moreira R, Gould C. Infections associated with haemophagocytic syndrome. *Lancet Infect Dis* 2007;7:814-22.
18. O'Brien MM, Lee-Kim Y, George TI, McClain KL, Twist CJ, Jeng M. Precursor B-cell acute lymphoblastic leukemia presenting with hemophagocytic lymphohistiocytosis. *Pediatr Blood Cancer* 2008;50:381-3.
19. Lykens JE, Terrell CE, Zoller EE, Risma K, Jordan MB. Perforin is a critical physiologic regulator of T-cell activation. *Blood* 2011;118:618-26.
20. Behrens EM, Canna SW, Slade K, Rao S, Kreiger PA, Paessler M, et al. Repeated TLR9 stimulation results in macrophage activation syndrome-like disease in mice. *J Clin Invest* 2011;121:2264-77.
21. Henter JI, Elinder G, Soder O, Hansson M, Andersson B, Andersson U. Hypercytokinemia in familial hemophagocytic lymphohistiocytosis. *Blood* 1991;78:2918-22.
22. Zoller EE, Lykens JE, Terrell CE, Aliberti J, Filipovich AH, Henson PM, et al. Hemophagocytosis causes a consumptive anemia of inflammation. *J Exp Med* 2011;208:1203-14.
23. Henter JI, Carlson LA, Soder O, Nilsson-Ehle P, Elinder G. Lipoprotein alterations and plasma lipoprotein lipase reduction in familial hemophagocytic lymphohistiocytosis. *Acta Paediatr Scand* 1991;80:675-81.
24. Sumegi J, Barnes MG, Nestheide SV, Molleran-Lee S, Villanueva J, Zhang K, et al. Gene expression profiling of peripheral blood mononuclear cells from children with active hemophagocytic lymphohistiocytosis. *Blood* 2011;117:e151-60.
25. Suzuki N, Morimoto A, Ohga S, Kudo K, Ishida Y, Ishii E. Characteristics of hemophagocytic lymphohistiocytosis in neonates: a nationwide survey in Japan. *J Pediatr* 2009;155:235-8.
26. Tabata R, Tabata C, Terada M, Nagai T. Hemophagocytic syndrome in elderly patients with underlying autoimmune diseases. *Clin Rheumatol* 2009;28:461-4.
27. Raschke RA, Garcia-Orr R. Hemophagocytic lymphohistiocytosis: a potentially underrecognized association with systemic inflammatory response syndrome, severe sepsis, and septic shock in adults. *Chest* 2011;140:933-8.
28. Whaley BF. Familial hemophagocytic lymphohistiocytosis in the neonate. *Adv Neonatal Care* 2011;11:101-7.
29. Henter JI, Horne A, Arico M, Egeler RM, Filipovich AH, Imashuku S, et al. HLH-2004: Diagnostic and therapeutic guidelines for hemophagocytic lymphohistiocytosis. *Pediatr Blood Cancer* 2007;48:124-31.
30. Henter JI, Samuelsson-Horne A, Arico M, Egeler RM, Elinder G, Filipovich AH, et al. Treatment of hemophagocytic lymphohistiocytosis with HLH-94 immunochemotherapy and bone marrow transplantation. *Blood* 2002;100:2367-73.
31. Horne A, Trottestam H, Arico M, Egeler RM, Filipovich AH, Gadner H, et al. Frequency and spectrum of central nervous system involvement in 193 children with haemophagocytic lymphohistiocytosis. *Br J Haematol* 2008;140:327-35.
32. Pagel J, Beutel K, Lehmborg K, Koch F, Maul-Pavicic A, Rohlf AK, et al. Distinct mutations in *STXBP2* are associated with variable clinical presentations in patients with familial hemophagocytic lymphohistiocytosis type 5 (FHL5). *Blood* 2012;119:6016-24.
33. Pachlopnik Schmid J, Canioni D, Moshous D, Touzot F, Mahlaoui N, Hauck F, et al. Clinical similarities and differences of patients with X-linked lymphoproliferative syndrome type 1 (XLP-1/SAP deficiency) versus type 2 (XLP-2/XIAP deficiency). *Blood* 2011;117:1522-9.
34. Rohr J, Beutel K, Maul-Pavicic A, Vraetz T, Thiel J, Warnatz K, et al. Atypical familial hemophagocytic lymphohistiocytosis due to mutations in *UNC13D* and *STXBP2* overlaps with primary immunodeficiency diseases. *Haematologica* 2010;95:2080-7.
35. Zur Stadt U, Beutel K, Kolberg S, Schneppenheim R, Kabisch H, Janka G, et al. Mutation spectrum in children with primary hemophagocytic lymphohistiocytosis: molecular and functional analyses of *PRF1*, *UNC13D*, *STX11*, and *RAB27A*. *Hum Mutat* 2006;27:62-8.
36. Jordan MB, Allen CE, Weitzman S, Filipovich AH, McClain KL. How I treat hemophagocytic lymphohistiocytosis. *Blood* 2011;118:4041-52.
37. Trizzino A, Zur Stadt U, Ueda I, Risma K, Janka G, Ishii E, et al. Genotype-phenotype study of familial haemophagocytic lymphohistiocytosis due to perforin mutations. *J Med Genet* 2008;45:15-21.
38. Sieni E, Cetica V, Santoro A, Beutel K, Mastrodicasa E, Meeths M, et al. Genotype-phenotype study of familial haemophagocytic lymphohistiocytosis type 3. *J Med Genet* 2011;48:343-52.
39. Zhang K, Jordan MB, Marsh RA, Johnson JA, Kissell D, Meller J, et al. Hypomorphic mutations in *PRF1*, *MUNC13-4*, and *STXBP2* are associated with adult-onset familial HLH. *Blood* 2011;118:5794-8.
40. Meeths M, Chiang SC, Wood SM, Entesarian M, Schlums H, Bang B, et al. Familial hemophagocytic lymphohistiocytosis type 3 (FHL3) caused by deep intronic mutation and inversion in *UNC13D*. *Blood* 2011;118:5783-93.
41. Zhang K, Biroshchak J, Glass DN, Thompson SD, Finkel T, Passo MH, et al. Macrophage activation syndrome in patients with systemic juvenile idiopathic arthritis is associated with *MUNC13-4* polymorphisms. *Arthritis Rheum* 2008;58:2892-6.
42. Gupta A, Weitzman S, Abdelhaleem M. The role of hemophagocytosis in bone marrow aspirates in the diagnosis of hemophagocytic lymphohistiocytosis. *Pediatr Blood Cancer* 2008;50:192-4.
43. Behrens EM, Beukelman T, Paessler M, Cron RQ. Occult macrophage activation syndrome in patients with systemic juvenile idiopathic arthritis. *J Rheumatol* 2007;34:1133-8.
44. Allen CE, Yu X, Kozinetz CA, McClain KL. Highly elevated ferritin levels and the diagnosis of hemophagocytic lymphohistiocytosis. *Pediatr Blood Cancer* 2008;50:1227-35.
45. Bleesing J, Prada A, Siegel DM, Villanueva J, Olson J, Ilowite NT, et al. The diagnostic significance of soluble CD163 and soluble interleukin-2 receptor alpha-chain in macrophage activation syndrome and untreated new-onset systemic juvenile idiopathic arthritis. *Arthritis Rheum* 2007;56:965-71.
46. Xu XJ, Tang YM, Song H, Yang SL, Xu WQ, Zhao N, et al. Diagnostic accuracy of a specific cytokine pattern in hemophagocytic lymphohistiocytosis in children. *J Pediatr* 2012;160:984-90.
47. Johnson TS, Villanueva J, Filipovich AH, Marsh RA, Bleesing JJ. Contemporary diagnostic methods for hemophagocytic lymphohistiocytosis disorders. *J Immunol Methods* 2011;364:1-13.
48. Bryceson YT, Pende D, Maul-Pavicic A, Gilmour KC, Ufheil H, Vraetz T, et al. A prospective evaluation of degranulation assays in the rapid diagnosis of familial hemophagocytic syndromes. *Blood* 2012;119:2754-63.
49. Wheeler RD, Cale CM, Cetica V, Arico M, Gilmour KC. A novel assay for investigation of suspected familial haemophagocytic lymphohistiocytosis. *Br J Haematol* 2010;150:727-30.
50. Tabata Y, Villanueva J, Lee SM, Zhang K, Kanegane H, Miyawaki T, et al. Rapid detection of intracellular SH2D1A protein in cytotoxic lymphocytes from patients with X-linked lymphoproliferative disease and their family members. *Blood* 2005;105:3066-71.
51. Marsh RA, Villanueva J, Zhang K, Snow AL, Su HC, Madden L, et al. A rapid flow cytometric screening test for X-linked lymphoproliferative disease due to XIAP deficiency. *Cytometry B Clin Cytom* 2009;76:334-44.
52. Mahlaoui N, Ouachee-Chardin M, de Saint Basile G, Neven B, Picard C, Blanche S, et al. Immunotherapy of familial hemophagocytic lymphohistiocytosis with antithymocyte globulins: a single-center retrospective report of 38 patients. *Pediatrics* 2007;120:e622-8.
53. Marsh RA, Allen CE, McClain KL, Weinstein JL, Kanter J, Skiles J, et al. Salvage therapy of refractory hemophagocytic lymphohistiocytosis with alemtuzumab. *Pediatr Blood Cancer* 2013;60:101-9.
54. Marsh RA, Rao K, Satwani P, Lehmborg K, Muller I, Li D, et al. Allogeneic hematopoietic cell transplantation for XIAP deficiency: an international survey reveals poor outcomes. *Blood* 2013;121:877-83.
55. Cooper N, Rao K, Gilmour K, Hadad L, Adams S, Cale C, et al. Stem cell transplantation with reduced-intensity conditioning for hemophagocytic lymphohistiocytosis. *Blood* 2006;107:1233-6.
56. Marsh RA, Vaughn G, Kim MO, Li D, Jodele S, Joshi S, et al. Reduced-intensity conditioning significantly improves survival of patients with hemophagocytic lymphohistiocytosis undergoing allogeneic hematopoietic cell transplantation. *Blood* 2010;116:5824-31.

57. Stephan JL, Kone-Paut I, Galambrun C, Mouy R, Bader-Meunier B, Prieur AM. Reactive haemophagocytic syndrome in children with inflammatory disorders: a retrospective study of 24 patients. *Rheumatology (Oxford)* 2001;40:1285-92.
58. Singh S, Chandrakasan S, Ahluwalia J, Suri D, Rawat A, Ahmed N, et al. Macrophage activation syndrome in children with systemic onset juvenile idiopathic arthritis: clinical experience from northwest India. *Rheumatol Int* 2012;32:881-6.
59. Ohga S, Kudo K, Ishii E, Honjo S, Morimoto A, Osugi Y, et al. Hematopoietic stem cell transplantation for familial hemophagocytic lymphohistiocytosis and Epstein-Barr virus-associated hemophagocytic lymphohistiocytosis in Japan. *Pediatr Blood Cancer* 2010;54:299-306.
60. Rajagopala S, Dutta U, Chandra KS, Bhatia P, Varma N, Kochhar R. Visceral leishmaniasis associated hemophagocytic lymphohistiocytosis: case report and systematic review. *J Infect* 2008;56:381-8.