



## Anti-Inflammatory Effect of *Neuracanthus Sphaerostachyus* Dalz. Leaves on Experimental Colitis in Rats

Dangar DK <sup>1</sup>, Patel NJ <sup>\*2</sup>

<sup>1</sup> Ganpat University, Ganpat Vidyanagar, Gujarat-384012, India

<sup>2</sup> Department of Pharmacology, S. K. Patel College of Pharmaceutical Education & Research, Ganpat University, Ganpat Vidyanagar, Gujarat-384012, India

Address for Correspondence: Patel NJ, [nilesh.patel@ganpatuniversity.ac.in](mailto:nilesh.patel@ganpatuniversity.ac.in) ;

[nileshcology127@yahoo.co.in](mailto:nileshcology127@yahoo.co.in)

### Received:

11.07.2019

### Accepted:

04.01.2020

### Published:

30.03.2021

### Keywords

*Neuracanthus sphaerostachyus*, Inflammatory Bowel Disease, Ulcerative colitis, tri-nitro benzene sulphonic acid, Myeloperoxidase Tumor necrosis factor-  $\alpha$ .

**ABSTRACT:** Inflammatory bowel disease (IBD) is a chronic idiopathic inflammatory disorder with unknown etiology affecting the GI tract. *Neuracanthus sphaerostachyus* has been traditionally used for the treatment of skin diseases, cough, and asthma in various forms orally. Lack of sufficient scientific evidence indicating the utility of this plant in the treatment of ulcerative colitis prompted us to investigate the anti-inflammatory activity of the plant on experimental colitis in rats. In-vivo pharmacological screening method for evaluation of anti-inflammatory activity of the methanolic and aqueous extract of *Neuracanthus sphaerostachyus* leaves at doses of 125, 250, and 500 mg/kg was assessed by TNBS-induced ulcerative colitis in Wistar rats. Colitis was induced by intra-rectal instillation of 10 mg of tri-nitro benzene sulphonic acid (TNBS) in 0.25 ml of 50% ethanol (v/v) followed by treatments with 7 d for various extracts and then animals were sacrificed to remove colon for histopathology, macroscopic scoring, and biochemical assays. The 7 d treatment with a methanolic and aqueous extract of *Neuracanthus sphaerostachyus* significantly improved feed intake and body weight with a decrease in macroscopic score, colonic MPO, LPO and, TNF- $\alpha$ . The findings from the histopathological study support the above results by its potential to protect the colonic mucosal damage. The present study exhibits anti-inflammatory potential of methanolic and aqueous extracts of *Neuracanthus sphaerostachyus* leaves in TNBS induced experimental colitis and it can be beneficial for patients suffering from ulcerative colitis. © 2020 iGlobal Research and Publishing Foundation. All rights reserved.

**Cite this article as:** Dangar, D.K.; Patel, N.J. Anti-inflammatory effect of *Neuracanthus Sphaerostachyus* Dalz. leaves on experimental colitis in rats. Indo Global J. Pharm. Sci., 2021; 11(1): 7-14. DOI: <http://doi.org/10.35652/IGJPS.2021.111002> .

## INTRODUCTION

Inflammatory bowel disease (IBD) is a chronic, idiopathic inflammatory disorder of intestine. Inflammatory bowel disease comprises of the crohn's disease (CD) and ulcerative colitis (UC) with their unique features. Ulcerative colitis mainly confined to colonic inflammation whereas Crohn's disease may involve any part of the gastrointestinal tract from the mouth to the anus [1]. Etiology of IBD is still not known, but current literature survey revealed that it may involve multiple factors like gene modulation, oxidative stress, infectious agents, immune reactions and microorganism. CD

and UC may be seen in different socioeconomic stages with western lifestyle and incidences can be seen at a higher rate in developed countries than developing countries. These factors may represent inflammation in mucosa, hemorrhage and, ulcers in a colon. Initiation and progression of IBD depend on the generation of the free radicals during the progression of the disease and may contribute to the development of cancer. Current therapeutics approaches involve treatment with immunosuppressants and 5-aminosalicylic acid for symptomatic or temporary relief with toxic side effects associated with their use. Therefore, it is essential to develop

alternative therapeutic agents with higher efficacy and safety for the treatment of IBD [2 -4].

*Neuracanthus sphaerostachyus* Dalz is commonly known as Ghoswel(Hindi), Golgonda(Marathi) and Ganthera - Gandharo(Gujarati). Plant belongs to Indian regions and widely distributed in Western Ghats, Deccan and Gujarat [5]. This plant is traditionally used in different areas of Western Ghats. Root extract is used to treat rheumatoid arthritis. Fruits, flowers and seeds are given for the treatment of diabetes. The mixture of ash of the whole plant with jaggery or honey is used 2 to 3 times a day orally to cure cough and asthma [6]. It is also administered in paste form in the cases of indigestion. Previous studies with *Neuracanthus sphaerostachyus* shows the presence of vanillic acid, syringic acid, melilotic acid and 6-OH luteolin [7].

## **MATERIALS AND METHODS**

### **Collection and Authentication of plant**

*Neuracanthus sphaerostachyus* Dalz. leaves were collected from Girnar forest region of Junagadh, Gujarat. Plant material was authenticated by NISCAIR-CSIR (National Institute of Science Communication and Information Resources), New Delhi. (NISCAIR/RHMD/Consult/2016/2987-14)

### **Extraction of plant material**

Extractive values of crude drugs were used to determine the number of active constituents extracted with solvents from a given amount of medicinal plant material. The successive extraction was carried out in Soxhlet apparatus with a known quantity of powder in different organic solvents like Hexane, chloroform, methanol and then water. After exhaustive extraction, the solvent was filtered and concentrated under reduced pressure at 50-55 ° C [8].

### **Chemicals**

Prednisolone and tri-nitro benzene sulphonic acid were procured from Merck, India. All the chemicals and reagents used were of analytical grade.

### **Animals**

Female Wistar rats (150-200 g) were used for the study. The animals were kept in polypropylene cages and maintained at a temperature of 26 ± 2°C. Animals were fed with diet provided by Pranav agro-industries Ltd., Sangli. Feed was composed of crude proteins (18.05%), crude fat (3%), crude fiber (4.25%), calcium (1.15%), phosphorus (0.52%), total ash (5.75%) and carbohydrates (63%). All the animal experiments were conducted in accordance with the guidelines of the CPCSEA (Reg. No. 1846/PO/RE/s/16/CPCSEA), a guide for the care and use of laboratory animals. The animals were acclimatized

for 10 days under standard husbandry conditions as Relative humidity 45 - 55%, and 12 h light and dark cycle [9].

### **Acute toxicity study**

Female Wistar rats of 150 - 200g body weight were selected to find out the acute toxicity study of a methanolic and aqueous extract of *Neuracanthus sphaerostachyus* leaves. The dose of 2000 mg/kg was selected on the basis of Up and Down Procedure (UDP) as per OECD Guideline No.425. All animals were observed for 24 h to detect autonomic or behavioral changes in responses to the extracts. Then the Mortality in each group was observed for 14 d [10]. The methanolic and aqueous extracts of leaves of *Neuracanthus sphaerostachyus* were found to be nontoxic at a dose of 1500 mg/kg, orally. Hence, LD cut off value of methanolic and aqueous extract were fixed as 1500 mg/kg. Therefore 1/10<sup>th</sup>, 1/6<sup>th</sup>, 1/3<sup>rd</sup> of the LD<sub>50</sub> cut off value that was approximately 150, 250 and 500 mg/kg were selected as screening dose for anti-inflammatory activity.

### **Animal grouping**

Animals were randomly divided into nine groups as normal control, positive control, reference control and test groups of 6 rats as follows:

Group I: normal control received vehicle (normal saline) (1 ml/kg) orally (PO) without colitis induction. Group II: positive control received TNBS in 0.25 ml of 50% ethanol (v/v). Group III: reference control received prednisolone (10 mg/kg, PO) 2 h after colitis induction and continued for 7 d thereafter. Group IV, V, and VI: received 3 increasing doses of MENS (methanolic extract of leaves of *Neuracanthus sphaerostachyus*) at 150, 250, and 500 mg/kg PO, 2 h after colitis induction and continued for 7 d thereafter. Group VII, VIII, and IX: received 3 increasing doses of AENS (aqueous extract of leaves of *Neuracanthus sphaerostachyus*) at 150, 250, and 500 mg/kg PO, 2 h after colitis induction and continued for 7 d thereafter.

### **Experimental protocol**

All samples, solutions of drugs, and plant extracts were freshly prepared. The extracts were used as a suspension in 0.5% v/v Tween 80 in normal saline (0.9%) and administered orally. Animals were fasted overnight and kept under anesthesia prior to the induction of colitis. 10 mg of tri-nitro benzene sulphonic acid (TNBS) dissolved in 0.25 ml of 50% ethanol (v/v) and administered through a Teflon cannula inserted 8 cm into the anus. During and after TNBS administration, rats remained in a head down position until they recover from the anesthesia. Rats from the normal control group will receive 0.25 ml of saline instead of TNBS. Treatments started after 2 h of TNBS administration and continued daily for 7 days. Animals were

sacrificed to remove colon for histopathology, macroscopic scoring and biochemical assay [11, 12].

#### Assessment parameters

##### Animal body weight and feed intake

Animal body weight was recorded for 7 d. For the evaluation of the intake of food, a fixed amount of feed was given to the rat every day. The intake of food was calculated by subtracting the remaining feed with the given feed weight.

##### Macroscopic Scoring

The animals were sacrificed and the small intestine was removed and opened longitudinally. Gross findings were ranked using the following criteria, 0 - No change mucosa, 1- Hyperemia, 2-Single mucosal erosion, 3-Single mucosal erosion, 4-Multiple ulcerations with less than 10 cm, 5-Multiple ulcerations with more than 10 cm.

#### Biochemical Assays

##### Colonic lipid peroxides concentration (LPO)

Lipid peroxidation involves the release of reactive oxygen species leading to mucosal injury. The mucosal injury was measured as thiobarbituric acid reactive substance. 0.5 ml of colonic tissue homogenate was collected and allowed to react with 2 ml of TBA reagent, containing 0.375% TBA, 15% trichloroacetic acid and 0.25 N HCl. Samples were heated for 15 min followed by centrifugation with cooling. The absorbance of the supernatants was measured by spectrophotometer measured at 532 nm.

$$\text{Concentration}(\mu\text{M}) = \frac{\text{Absorbance}}{\text{Molar extinction coefficient}} \times 10^2$$

##### Myeloperoxidase (MPO) activity

2 cm of inflamed tissues of rat colon was removed and the tissue was then rinsed with saline (ice cold) followed by blotted drying. Tissue was homogenized with 10 volumes of potassium phosphate buffer (pH 7.4, ice cold) using tissue homogenizer. The tissue homogenate was centrifuged at 3500 r/min for 3 cycles of 10 min each. The supernatant solution was discarded. 10 ml of cold 50 mM potassium phosphate buffer containing 0.5% hexadecyl trimethyl ammonium bromide (HETAB) and 10 mM EDTA was then added to the solution. It was subjected to freezing and thawing followed by sonication. Further, the solution was centrifuged at 15,000 r/min for 20 min. Myeloperoxidase (MPO) activity was measured spectrophotometrically as follows: Supernatant solution (0.1 ml) was added in 2.9 ml of 50mM phosphate buffer containing 0.167 mg/ml O-dianisidine hydrochloride and 0.0005% H<sub>2</sub>O<sub>2</sub>. The change in absorbance was measured spectrophotometrically at 460 nm.

$$\text{MPO Activity} = \frac{X}{\text{Weight of tissue piece taken}}$$

$$\text{Where } X = 10 \times \frac{\text{Change in absorbance per minute}}{\text{Vol of supernatant taken in final reading}}$$

##### Estimation of TNF- $\alpha$

TNF- $\alpha$  (a proinflammatory cytokine) in pg per ml was estimated with the help of ELISA Reader. The supernatant solution collected previously was used to quantify TNF- $\alpha$ . TNF- $\alpha$  (Cayman Chemical, USA) ELISA kit was used. The assay was performed according to the manufacturer's recommendations [11, 13].

##### Histopathological evaluation

Portions of the inflamed colon were fixed in phosphate buffered formaldehyde formalin solution and embedded in paraffin followed by thin sections with 5 $\mu$ m were prepared (Rotary microtome). Tissues were stained with hematoxylin and eosin and further evaluated by microscopy (Olympus DP74 – 400X) [14].

##### Statistical analysis

All values are presented as mean  $\pm$  SEM of six animals. Differences between means were assessed by one-way analysis of variance (ANOVA) followed by Dunnett's test. Results were considered as significant at P<0.05.

## RESULTS AND DISCUSSION

##### Animal body weight and feed intake

TNBS treated group (Positive control) exhibits severe anorexia with a decrease in animal body weight and average feed intake as shown in (Table 1). In contrast, groups treated with prednisolone (standard control), MENS and AENS significantly improved body weight and feed intake in dose-dependent manner.

##### Macroscopic Scoring

The macroscopic study revealed the extensive colonic mucosal injury to colon with the positive control group. During study it was observed that the normal control group showed no lesions of mucosal injury due to the insertion of saline. Treatment with reference drug (prednisolone) as corticosteroid reduced the ulcer score (p<0.001) (Table 1). Oral treatment with MENS and AENS reduced the macroscopic score significantly (p<0.01) as compared to the positive control group.

##### Biochemical Assays

Effect of MENS and AENS (150, 250, 500 mg/kg, PO) on Colonic Lipid Peroxides concentration (LPO),

Myeloperoxidase (MPO) and TNF- $\alpha$  is shown in **Table.2**. The biochemical assay shows that treatment of TNBS leads to extensive damage to colonic mucosa with an increase in colonic LPO, MPO activity, and TNF- $\alpha$  along with the decrease in animal body weight and feed intake. Prednisolone treatment was effective ( $p<0.001$ ) in reversing these parameters whereas MENS was found to be more effective than AENS ( $p<0.01$ ).

**Histopathological evaluation**

The Histopathological changes observed in the normal and treated rat colon are shown in **figure 1 - 9**. Fig. 1 - Normal colon of rat showed intact mucosa with no change in epithelial surface. Fig. 2 - TNBS treated group exhibits extensively inflamed colonic damage with edema. Fig. 3 - TNBS

treatment was followed by standard reference drug prednisolone, with no change in the normal architecture of mucosa. Fig. 4, 5, and 6 - Colon of MENS treated (150, 250, and 500 mg/kg respectively) rats showing recovered mucosal and submucosal damage with the presence of edema & few inflammatory cells due to treatment with TNBS administration. Treatment with 500 mg/kg of MENS test drug shows normal appearance, without no signs of ulceration or bleeding (Fig. 5). Fig. 7, 8, and 9 - Colon of AENS treated (150, 250, and 500 mg/kg respectively) rat showing recovered edema and reduced severity of cell damage. Histopathological studies showed the anti-inflammatory potential of MENS and AENS on inflamed colonic mucosal tissues.

**Table 1 – Effect of methanolic and aqueous extract of leaves of *Neuracanthus sphaerostachyus* on animal body weight, feed intake, and macroscopic score.**

Treatment	% Decrease in body weight	Food intake	Macroscopic score (points)
Normal control	-	162.3±5.26	0
Positive control	8.76±0.54	56.23±4.48	4.0±0.10
Standard control 10 mg/kg	1.56±0.26***	148±3.26***	0.56±0.02***
MENS 150 mg/kg	5.26±0.45	68.23±5.63	2.41±0.18*
MENS 250 mg/kg	2.46±0.62**	96.26±3.50**	1.95±0.14**
MENS 500 mg/kg	1.98±0.25***	140.20±4.30***	0.96±0.02***
AENS 150 mg/kg	5.38±0.46	64.06±4.09	2.89±0.14
AENS 250 mg/kg	3.41±0.42*	90.50±4.68*	2.18±0.16*
AENS 500 mg/kg	2.12±0.64**	132.21±3.89**	1.64±0.09**

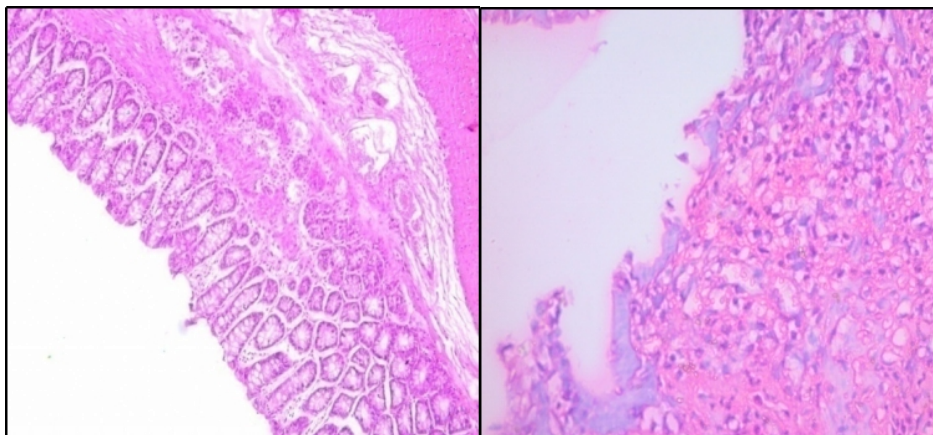
Values were expressed as mean ± SEM. N=6 in a group; \* $p<0.05$ , \*\* $p<0.01$ , \*\*\* $p<0.001$  vs Positive control (TNBS). Data are analysed by using one way ANOVA followed by Dunnet's test.

**Table 2 - Effect of methanolic and aqueous extract of leaves of *Neuracanthus sphaerostachyus* on colonic LPO, MPO activity and TNF- $\alpha$  level.**

Treatment	Colonic LPO concentration ( $\mu\text{g/g}$ of wet tissue)	MPO(U/gm)	TNF- $\alpha$ ( $\mu\text{g/ml}$ )
Normal control	54.21±2.12	0.195±0.023	214.92 ± 0.348
Positive control	92.41±0.47	1.048±0.132	357.22 ± 0.586
Standard control 10 mg/kg	58.56±0.23***	0.236±0.021***	216.79 ± 1.24***
MENS 150 mg/kg	86.62±1.32	0.925±0.054	351.56 ± 0.79 <sup>ns</sup>
MENS 250 mg/kg	78.24±0.56*	0.756±0.087*	311.01 ± 0.765**
MENS 500 mg/kg	64.58±0.45**	0.376±0.058**	248.20 ± 0.181***
AENS 150 mg/kg	89.41±0.21	0.988±0.087	349.52 ± 0.85 <sup>ns</sup>
AENS 250 mg/kg	81.23±1.56	0.790±0.084	318.20 ± 0.171**
AENS 500 mg/kg	70.54±0.23*	0.398±0.064**	261.64 ± 0.355***

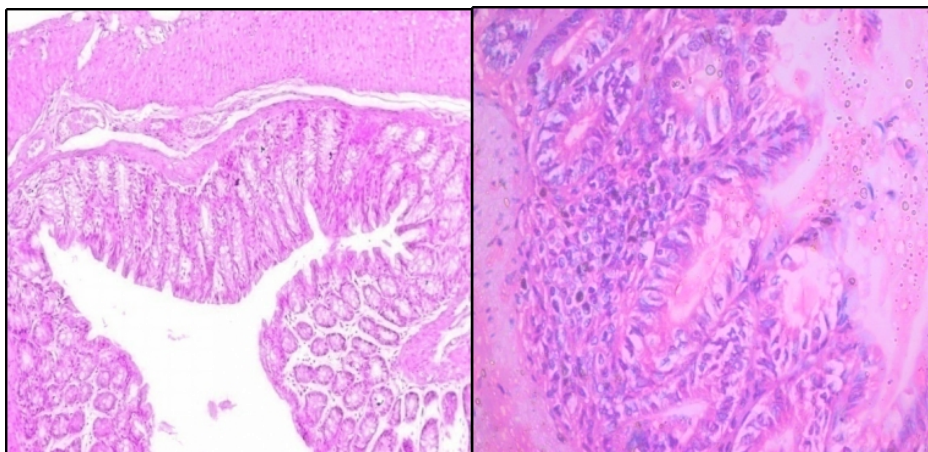
Values were expressed as mean ± SEM. N=6 in a group; \* $p<0.05$ , \*\* $p<0.01$ , \*\*\* $p<0.001$  vs Positive control (TNBS). Data are analysed by using one way ANOVA followed by Dunnet's test.

- Histopathological evaluation



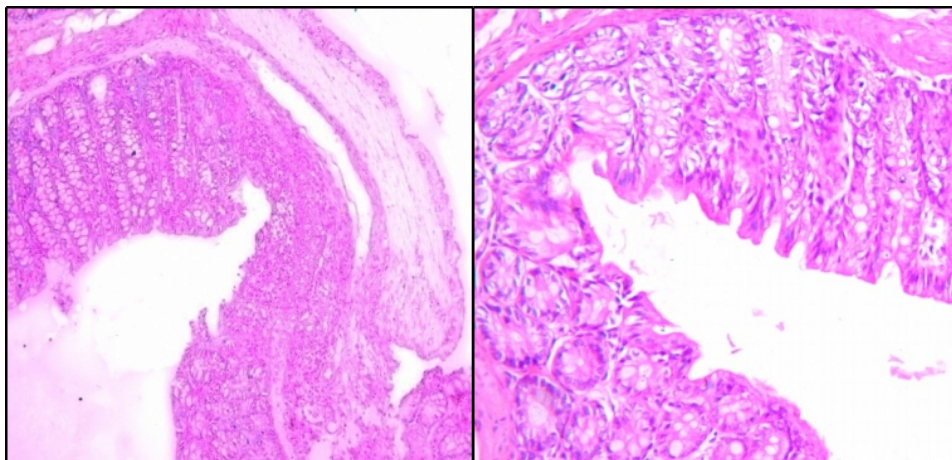
**Fig (1) Histopathological slide of normal control group**

**Fig (2) Histopathological slide of Positive control (TNBS) group**



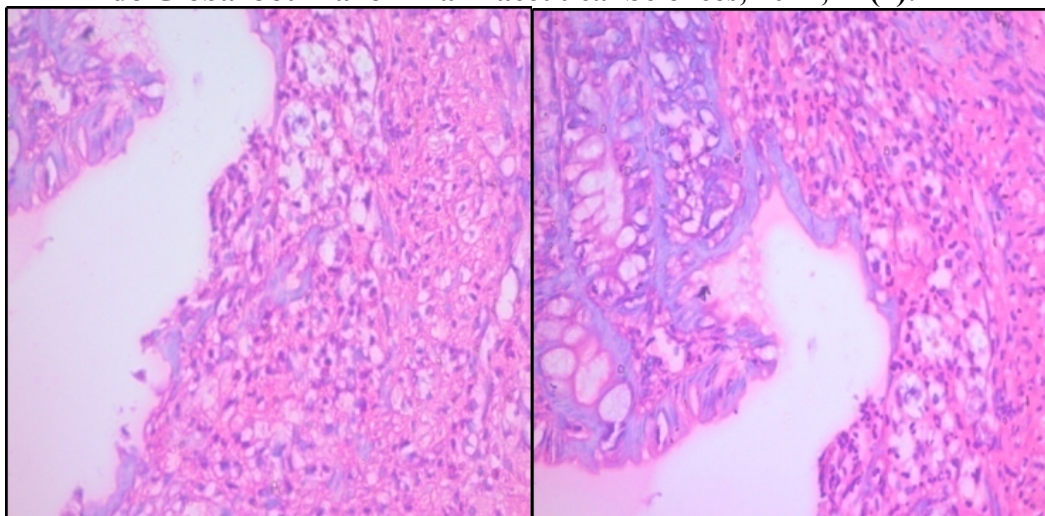
**Fig (3) Histopathological slide of standard Control (Prednisolone) group**

**Fig (4) Histopathological slide of group receiving methanolic extract of 150 mg/kg**



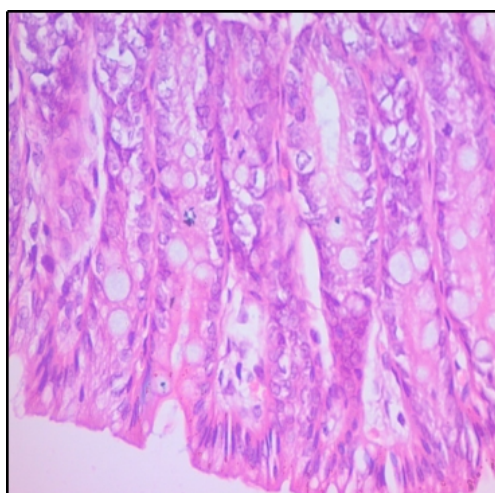
**Fig (5) Histopathological slide of group receiving methanolic extract of 250 mg/kg**

**Fig (6) Histopathological slide of group receiving methanolic extract of 500 mg/kg**



**Fig (7) Histopathological slide of group receiving aqueous extract of 150 mg/kg**

**Fig (8) Histopathological slide of group receiving aqueous extract of 250 mg/kg**



**Fig (9) Histopathological slide of group receiving aqueous extract of 500 mg/kg**

TNBS induced colitis mimics the condition associated with human IBD and considered as the best model to check the anti-ulcerogenic potential of crude extract [15]. Administration of TNBS in the colon leads to sustained chronic inflammation and ulceration. Tissue damage may result into increased no. of polymorphonuclear leukocytes, colonic wall thickening and formation of granuloma followed by increased vascular permeability making disturbances in intestinal immune defense mechanism. TNBS involves specific characteristics like one-time administration, the damage is reproducible, inexpensive, sustained inflammation with cellular infiltration and ulcer, makes TNBS most prominent for ulcerogenic activity. Inflammation for longer duration permits a specified time interval for the evaluation of

herbal extracts for their beneficial potential. Positive control group demonstrated the extensive damage to the mucosal architecture with cellular infiltration. Cellular infiltration allows movement of neutrophils and monocytes into colonic tissues. Locally produced cytokines are responsible for the migration of neutrophils and monocytes leading to the generation of reactive oxygen species or metabolites, responsible for the mucosal damage. Histological study exhibits a change in mucosal pattern allows assessing various parameters with different doses of crude extract.

Inflammation involves the release of MPO, and it represents ongoing neutrophilic activity. Measurement of MPO activity directly correlated with the activity of neutrophils in

inflammation. TNF- $\alpha$  is a pro-inflammatory cytokine secreted by T & B lymphocytes as well as from mast cells and plays a crucial role in the development of IBD [16]. The mucosal injury may be a result of lipid peroxidation and involves the release of ROS (reactive oxygen species).

*Neuracanthus sphaerostachyus* is traditionally used in western ghat and it shows the presence of vanillic acid, syringic acid, melilotic acid and, 6-OH luteolin [7]. In another study it shows the presence of luteolin and quercetin and it will be reported under the phytochemical profile in future. Various studies are reported with luteolin and quercetin for its potential to inhibit lipid peroxidation, myeloperoxidase activity and, TNF- $\alpha$ , a proinflammatory mediator.

Luteolin is a potent inhibitor of lipid peroxidation and arachidonic acid release from cell membrane inhibits release of various prostaglandins, leukotrienes and, interleukins. Luteolin inhibits mast cell degranulation through its mast cell stabilizing property. Luteolin and quercetin have been reported as an anti-inflammatory agent [17-22]. Major cases of IBD may involve the inflammation with mucosal damage due to the release of various free radicals and accumulation of lymphocytes and monocytes being a target for luteolin and quercetin with its beneficial application in current allopathic medicine system.

## CONCLUSION

With these pre-clinical results, it can be concluded that methanolic and aqueous extracts of *Neuracanthus sphaerostachyus* Dalz. leaves are significantly effective in the treatment of colonic mucosal damage caused by TNBS and can be used in the treatment of IBD due to the presence of flavonoids like luteolin and quercetin. However, these findings should be extrapolated through human trials before its application in clinical cases.

## CONFLICTS OF INTEREST

The authors declare that there is no conflict of interest regarding the publication of this paper.

## ACKNOWLEDGEMENT

None

## DATA AVAILABILITY

Not declared.

## FUNDING SOURCE

Not declared

## REFERENCES

- Patil, M.V., Kandhar, A.D., Bhise S.D. anti-inflammatory effect of *daucus carota* root on experimental colitis in rats. Int. Journal of Pharmacy and Pharma. Sciences., 2012; 4(1): 18-25.
- Biradar, S.M., et al. Protective effects of ethanolic extract of *Ageratum conyzoides* on experimental induced inflammatory bowel disease. J. of pharmacol. and toxic., 2011; 6(8): 664-678.
- Katzung, B.G. Basic and clinical pharmacology, 10<sup>th</sup> Edn., McGraw Hill Companies Inc., New Delhi, India, 2007.
- Shanahan, F., Inflammatory bowel disease: immunodiagnostics, immunotherapeutics and ecotherapeutics. Gastroenterology, 2001; 120: 622-635.
- Khare, C.P. Indian medicinal plants, An illustrated dictionary, Springer publication. 2007.
- Punjani, B.L., Kumar, V., Traditional medicinal plant remedies to treat cough and asthmatic disorders in the Aravalli ranges in North Gujarat, India, J. of Nat. Reme., 2002; 2(2): 173-178.
- Daniel, M., Sabnis, S.D., Chemosystematics of some Indian members of the Acanthaceae. Proe. Indian Acad. Sci. (Plant Sci.), 1987; 97(4): 315-332.
- Indian Pharmacopoeia. Government of India, 2<sup>nd</sup> ed., New Delhi, 1966; 33-4.
- Committee for the Purpose of Control and Supervision on Experiments on Animals. CPCSEA guidelines for laboratory animal facility, Indian J of Pharmacol. 2003; 35: 257-274.
- <http://www.oecd.org/chemicalsafety/risk-assessment/1948378.pdf>
- Costa, C.A. et al. Anti-inflammatory effects of Brazilian ginseng on TNBS-induced intestinal inflammation: Experimental evidence. Inter Immunopharmacology 2015; 28: 459-69.
- Patil, N.R. et al., Screening of Mandarin Oil on Indomethacin Induced Inflammatory Bowel Disease in Wistar Rats. I J Pharma Edu and Re, 2014; 48.
- <https://www.caymanchem.com/pdfs/500850.pdf/21/7/2018>
- Jagtap, A.G., Shrike, S.S., Phadke, A.S. Effect of polyherbal formulation on experimental models of inflammatory bowel diseases. J Ethnopharmacol. 2004; 90(2): 195-204.
- Morris, G.P., Rebeiro, L., Herride, M.M., Szewczuk, M., Depew, W. An animal model of chronic granulomatous inflammation of stomach and colon, Gastroenterology, 1985; 86: 1188.
- Prakash, O. et al. Effect of combination of thalidomide and sulfasalazine in experimentally induced inflammatory bowel disease in rats. Indian journal of Experimental Biology. 2011; 49: 672-78.
- Elliott, M., Chithan K., Theoharis C. The Effects of Plant Flavonoids on Mammalian Cells: Implications for Inflammation, Heart Disease, and Cancer. The American Society for Pharmacology and Experimental Therapeutics. Pharmacol Rev, 2000 ; 52: 673-751.
- Ufuk, O et al. Relationship Between Chemical Structure and Antioxidant Activity of Luteolin and Its Glycosides Isolated from *Thymus sipyleus* subsp. *sipyleus* var. *Sipyleus*. Rec. Nat. Prod. 2011; 5(1):12-21.
- Theoharis, C. Luteolin as a therapeutic option for multiple sclerosis. J Neuroinfl, 2009; 6(29): 1-3.
- Cai, Q., Rahn, R.O., Zhang, R. Dietary flavonoids, quercetin, luteolin and genistein, reduce oxidative DNA damage and lipid peroxidation and quench free radicals. *Cancer Letters*, 1997; 119(1): 99-107.
- Patel, N.G., Patel, K.G., Patel K.V., Gandhi T.R. Validated HPTLC Method for Quantification of Luteolin and Apigenin in *Premna mucronata* Roxb., Verbenaceae. Adv in Pharmacol Sci, 2015: 1-7.

22. Dong, H. et. al. Enhanced antioxidant activity, antibacterial activity and hypoglycemic effect of luteolin by complexation with manganese(II) and its inhibition kinetics on xanthine oxidase. The Royal Society of Chemistry, 2017; 7: 53385–53395.

*Indo Global Journal of Pharmaceutical Sciences( ISSN 2249 1023; CODEN- IGJPAI; NLM ID: 101610675) indexed and abstracted in CrossRef (DOI Enabling), CNKI, EMBASE (Elsevier), National Library of Medicine (NLM) Catalog (NCBI), ResearchGate, Publons (Clarivate Analytics), CAS (ACS), Index Copernicus, Google Scholar and many more. For further details, visit <http://iglobaljournal.com>*