

## Morphology of Hyoid Bone with its Forensic Implication

[Prashant Kumar](#)<sup>1</sup>, [Tambe SV](#)<sup>2</sup>, [Rahule AS](#)<sup>3</sup>, [Kamdi NY](#)<sup>4</sup>

Assistant Professor<sup>1</sup> of Anatomy, ITS CDSR, Gaziabad, UP, Assistant Professor<sup>2</sup>, Associate Professor<sup>3,4</sup>, Department of Anatomy, Government Medical College Nagpur, Maharashtra

<http://dx.doi.org/10.18049/jcmad/221>

### Abstract

**Background:** The hyoid bone is of considerable forensic interest owing to its susceptibility to fracture during manual strangulation, hanging and other forms of neck compression. The hyoid bone is also not infrequently injured in road traffic accidents and may cause significant airway concerns. A hyoid bone's shape may influence its susceptibility to fracture and hyoid fractures are frequently confused with normal variation in both clinical and forensic settings. Current literature regarding the shape and size of the hyoid bone is mostly from European studies. Scarcity of data on Indian subjects led us to undertake this study. **Objectives:** To anatomically classify the hyoid bone according to Shape & Dimensions and to note if any gender variation exist. **Methods:** The study was conducted on fifty hyoid bone specimens obtained from medico-legal postmortems conducted in the Department of FMT, Maulana Azad Medical College, New Delhi. **Results:** It is observed that the most common pattern of hyoid is of the Hyperbola type in either sex and the boat type being the least common. The second leading form is the Parabola type in males and the Horseshoe type in females. Of the 50 hyoid bones studied 33 were symmetrical and 17 were asymmetrical. **Conclusion:** The presence of a fractured hyoid bone is often of great importance in cases involving badly decomposed bodies and skeletal remains lacking soft tissue evidence of neck injury. Our study is an attempt to provide preliminary data regarding variation in shape of hyoid bones obtained from autopsy of Indian subjects.

**Keywords:** Hyoid bone, Skeleton, Strangulation.

**Address for correspondence:** Dr. Shivpal V Tambe, Assistant Professor, Department of Anatomy, Government Medical College, Nagpur (M.S.) 440003. India. Mob: +918888707352, +918888954813, E-mail: [shivtambe@gmail.com](mailto:shivtambe@gmail.com) and Dr. Prashant Kumar, Assistant Professor, Department of Anatomy, ITS CDSR, Meeruth Road, Murad Nagar, Gaziabad( U.P.) Mob: 9422153880, E-mail: [rahuleanil@yahoo.co.in](mailto:rahuleanil@yahoo.co.in)

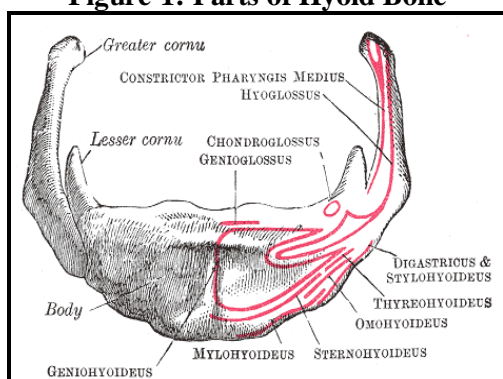
### Introduction

The hyoid bone is a part of the viscerocranium placed between the tongue and the thyroid cartilage to which it is connected by the thyrohyoid membrane. It is part of the both digestive and respiratory tracts. The hyoid bone is an integral component of the hyoid apparatus. Its name is derived from the Greek word *hyoeides* meaning "shaped like the letter epsilon" ( $\upsilon$ ).<sup>1,2,3</sup> The hyoid bone is the bony origin of the root of the tongue and the site of attachment of the muscles of the hyoid apparatus which regulate mastication, deglutition, and phonation. The bone consists of a body and two paired processes, the lesser and the greater cornua<sup>1</sup>.

It is not present in any of our closest living relatives, but it did exist in virtually identical form in Neanderthal man. That suggests, along with other anthropological clues of communication, that the Neanderthal employed some form of spoken language. The hyoid bone is of considerable forensic interest owing to its susceptibility to fracture during manual strangulation, hanging and other forms of neck compression<sup>4, 5, 6</sup>. Relationships between hyoid bone shape and fracture pattern figure prominently in forensic investigations of strangulation. The hyoid bone is also not infrequently injured in road traffic accidents and may cause significant airway concerns. A hyoid bone's shape may influence its susceptibility to fracture and hyoid fractures are frequently confused with normal variation in both clinical

and forensic settings. It is considered that the incidence of fractures directly depend on the shape and the status of calcification of the bone. This assumption is the consequence of significantly larger number of fractures in aged people due to ossification of the joints and calcification which leads to loss of elasticity and inability to shape adaptation on one hand and on the other hand of specific morphological characteristics of the fractured bone<sup>7,8</sup>. The shape of the hyoid bone is frequently described as hyperbolic or parabolic but such a bimodal distribution of shape has not been conclusively established. A widely accepted morphological classification does not exist. In most cases the shape of the hyoid bone does not belong to any of the shapes that are conventionally described<sup>9,10</sup>. Existence of large number of asymmetrical bones as well as the assumptions of sexual dimorphisms makes universal morphological classification evens more difficult<sup>5</sup>. The principle objective of the study was to anatomically classify the hyoid bone according to shape and dimensions. Current literature regarding the shape and size of the hyoid bone is mostly from European studies. Scarcity of data on Indian subjects led us to undertake this study.

**Figure-1: Parts of Hyoid Bone**



## Materials and Methods

The purpose of the study was to define the morphology of the hyoid bone and to formulate a working classification based on its morphologic measurements. The study was conducted on 50 hyoid bones in the Department of Anatomy, Maulana Azad Medical College & associated L.N J.P. Hospital, New Delhi. of the hyoid bones studied, twenty nine (29) specimens were obtained from male cadavers and twenty

one (21) from female cadavers. The age group ranged from 21 to 60 years. Hyoid bones of only Indian subjects (autopsy material) were included in the study. Hyoid bones displaying comminuted fracture were excluded from the study. Hyoid bones of children and persons who died of hanging or any other neck trauma were excluded.

Routine dissection room material was used to remove soft issue attached to hyoid bone and permanent markers were used for numbering the bones after defatting them with acetone. The bones were weighed on an electronic weighing balance and morphologic analysis was done on an image analyzer. Anterior aspect of neck was made prominent by extending the neck and elevating the shoulder region. Wooden blocks were placed under the shoulder region so that the midline of neck became more prominent.

A mid line incision extending from the chin to the sternal notch was made. The two skin flaps were separated out on the two sides up to the anterior border of sternocleidomastoid. Trachea was identified in the midline and followed upward; thyroid cartilage was identified as a shield attached to superior end of trachea. Hyoid bone was palpable just above the thyroid cartilage and it was cut from surrounding attached muscles and soft tissue attached to greater and lesser cornu. Care was taken not to break the fragile greater cornua.

After the bone was dissected out:-

1. The hyoid bone was kept in jar containing water for 2 days
2. Defatting was done by keeping in acetone for 3-4 days.
3. Shape and symmetry of bone was noted after numbering the hyoids
4. Bones were dried and numbered.
5. Weight of each bone was taken on electronic weighing balance.

## Results

The data was recorded in the form of distribution tables. The hyoids, on the basis of their shapes, are classified into four major types.

1. **Hyperbola:** It is triangular in shape and resembles 'U'. The greater transverse

diameter of the bone is the base of the triangle.

**Figure-1: Hyperbola shaped Hyoid Bone**



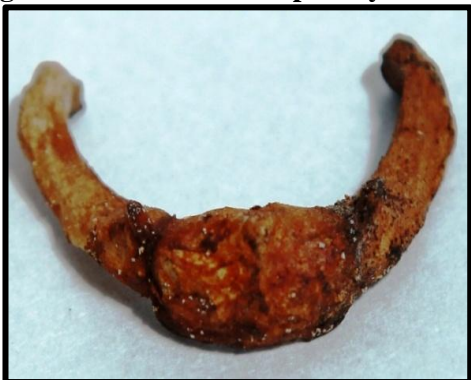- 2. Parabola:** It is a half circle anteriorly and the greater cornua are almost V type straight. The diameter of the half circle and the transverse diameters posterior to it, being approximately the same.

**Figure-2: Parabola Shaped Hyoid Bone**



- 3. Horse-shoe:** It is half circle anteriorly and greater cornu face each other and are converging. The diameter of half circle is more than the distance between the tips of greater cornua.

**Figure-3: Horse-shoe Shaped Hyoid Bone**



- 4. Boat- Shaped:** It resembles transverse section of a Boat. The two greater cornua

deviate from each other. As compared to 'V' shaped, in this type the greater cornua have opened out. This is almost a half circle or part of it, the diameter of which coincides with the major transverse axis.

**Figure- 4: Boat shaped Hyoid Bone**



All the above mentioned four types are further sub classified as symmetrical and asymmetrical. The frequency of types of shape is shown in Table 1.

It is observed that the most common pattern is of the Hyperbola type in either sex and the boat type being the least common as shown in Table 1 above. The second leading form is the Parabola type in males and the Horseshoe type in females. Of the fifty hyoid bones studied 33 were symmetrical and 17 were asymmetrical. It is further seen that most of the hyperbola types are symmetrical in nature as shown in Table 2 below. The Horse-shoe type of hyoid is the most commonly seen symmetrical type in females followed by the hyperbola type. In both the sexes the boat shaped type is most commonly asymmetrical.

**Table- 1: Frequency distribution**

Sex	Shapes			
	Parabola	Hyperbola	Horse-shoe	Boat Shaped
Male	8	9	6	5
Female	3	10	6	3
Total	11	19	12	8

The hyoid bones were weighed on an electronic weighing machine. The average weight of male hyoids is found to be greater than that of female hyoids. In males, the weight is found to range from 2.1 to 3.1 grams with an average weight of 2.9 grams. In females the weight is found to range from 1.9 to 2.9 grams with an average weight of 2.4 grams.

**Table 2: Frequency distribution table for symmetry in relation to shape and gender**

Symmetry	Shapes							
	Parabola		Hyperbola		Horse-shoe shaped		Boat Shaped	
	M	F	M	F	M	F	M	F
Symmetrical	6	2	8	4	5	5	1	2
Asymmetrical	2	1	1	6	1	1	4	1
Total	8	3	9	10	6	6	5	3

## Discussion

The hyoid bone is a key bone in the neck because it connects the floor of the oral cavity in front with the pharynx behind and the larynx below. It is supported by the muscles of the neck and in turn supports the root of the tongue. It is neither free-floating nor contiguous to any bone. If the neck is hyper-extended, the protection afforded by the mandible is diminished and direct trauma can cause isolated hyoid fracture.<sup>11</sup>

Anatomic variations in hyoid shape have been related to fracture patterns in forensic literature. By using the dissection technique and doing Subjective qualitative analysis of the shape or by reontgenologic studies of the bone, investigators have variously classified the shape of hyoid<sup>2,3,6</sup>. It is now well established that the shape of hyoid bone that displays a polymorphism and is a continuous spectrum between parabolic type on one hand and hyperbolic on the other with the horse shoe shape, boat shape and deviated shape scattered in between. The parabolic type (V) showing converging greater cornua is seen to be the leading shape in males, followed by the parabolic type and the hyperbolic type (u) with straight greater cornua is the commonest form observed in females<sup>5</sup>. Our results are in consonance with previous workers in so far that hyperbola was the predominant shape found in females; in males parabolic and hyperbolic forms were present in equal numbers. Horse-

shoe shaped and boat shaped hyoids were less frequent than the parabolic and hyperbolic forms but did not demonstrate any gender dimorphism.

Discussion of the morphological features regarding shape of hyoid bone have been discussed with following authors which has been shown in table 3.

The two dimensional size of the hyoid bone, which is of importance to the vital space of the superior opening of the lower respiratory tract, varies greatly and to a certain degree, it is related to the hyoid bone. Most hyoid bone dimensions are significantly higher in males than in females. Some measurements are much more gender dimorphic than others.

So far, mention has been made of various morphological studies on hyoid bone taken out of the body and various parameters studies in isolation. Undoubtedly the qualitative and quantitative assessment of the bone will act as a base line reference in Indian Subjects. Newer investigative modalities have brought into light the role of spatial inter-relationships of the hyoid to its neighboring structures. Thus highlighting the anatomic basis of various clinical procedures. hyoid suspension is a procedure designed to stabilize the airway behind the back of the tongue to correct obstructive sleep apnea<sup>10</sup>. The hyoid bone is pulled forward in front of the voice-box either in conjunction with genioglossus for tongue advancement or isolated procedures.

**Table-3: Comparison between studies**

Investigator	Year	Predominant shape of hyoid	
Koebke Saturnus	1979	Males	Females
Papadopoulos et al	1989	Parabola	Hyperbola
Dewan I & Jit	1996	Deviated parabola	Hyperbola
Pollanen et al	1997	Parabola and Hyperbola	Hyperbola
Miller et al	1998	Parabola and Hyperbola	Hyperbola
Current study	2008	Parabola and Hyperbola	Hyperbola

Quantitative assessment of hyoid bone displacement from video images during swallowing to determine the anterior and superior hyoid trajectories is found to be a useful method for identification of reduced hyoid displacement in cases of aspiration.<sup>12</sup>

## Conclusion

A hyoid bone's shape may influence its susceptibility to fracture and hyoid fracture is frequently confused with normal variation in both clinical and forensic settings. In spite of the importance of understanding normal age and sex variation in these contexts, few systematic studies of hyoid morphology have been conducted. The present study was undertaken to analyze variation in morphological parameters of hyoid bones taken at autopsy. Scarcity of literature on this bone and revival of interest in light of various clinical procedures performed with the hyoid as a key bone led us to undertake the present study.

---

**Source(s) of support:** Nil

**Conflict of Interest:** None declared

---

## References

1. Standring S, Ellis H, Healy C J, Johnson D, Williams A, Collins P, Wigely C. Neck and Upper Aero digestive Tract. Gray's Anatomy 39th Edition, 2005; Elsevier Churchill Living Stone: 541-42.
2. Papadopoulos N, Lykaki-Astopoulou G, Aluanidou EL. The shape and size of the human hyoid bone and a proposal for an alternative classification. J Anat 1989;69:249-60. [Pubmed]
3. Koebke J, Saternus k S. Morphology of the adult human hyoid bone. Folia Morphologica 1979; 84:7-18.
4. Pollanen MS, Bulger B, Chiasson DA. The Location of hyoid fracture in strangulation revealed by Xeroradiography. J Forensic Sci. 1995;40:303-05. [Pubmed]
5. Miller KWP, Walker PL, O'Halloran RL. Age and sex related variation in hyoid bone morphology. J Forensic Sci 1998;43(6):1138-43. [Pubmed]
6. Pollanen MS, Ubelaker DH. Forensic significance of the polymorphism of hyoid bone shape. J Forensic Sci 1997;92(5):890-92. [Pubmed]
7. Ubelaker DH. Hyoid fracture and strangulation. J Forensic Sci 1992;37:1216-22. [Pubmed]
8. Pollanen MS, Chiasson DA. Fracture of the hyoid bone in strangulation; Comparison of fractured and unfractured hyoids from victims of strangulation. J Forensic Sci 1996;41(1):110-113.
9. Dewan I. Jit. Shape, size and sexual dimorphism of the hyoid bone in north-west Indians. Journal of Anatomical Society of India 1996;45(1):4-22.
10. Peters G, Hast MH. Hyoid structure, laryngeal anatomy and vocalization in felids (Mammalia: Carnivora: Felidae). Z Saugetierk 1994;59:87-104.
11. Vieira DN, Printo AE, Sa FO. Homicidal hanging. Am J Forensic Med pathol 1988;9:287-9.
12. Yin SK, Yi HL, Lu WY, Guan J, Wu HM, Cao ZY. Genioglossus advancement and hyoid suspension plus uvulopalatopharyngoplasty for severe SAHS. Otolaryngol Head Neck Surg 2007;136(4):626-31. [Pubmed]