

Otologic Examination

Last updated: June 3, 2019

HISTORY 1
 Complaints 1
 PMH 1
AURICLE..... 2
 Pediatric aspects 2
AUDITORY ACUITY 2
 Pediatric aspects 3
TUNING FORK TESTS 3
OTOSCOPY 5
 Pediatric aspects 6
VESTIBULAR FUNCTION 7
 Alert patient 7
 Impaired consciousness 8
 Pediatric aspects 8
INSTRUMENTAL TESTS (incl. audiometry, otoacoustic emissions) → see p. Ear30 >>

HISTORY

COMPLAINTS

I. Inflammation - earache (otalgia), sensation of ear fullness / pressure, discharge (otorrhea) - pus, blood, CSF.

II. Hearing loss (hypoacusis):

- 1) current and in past
- 2) one or both sides is affected (symmetric or asymmetric?)
- 3) what types of sounds are poorly perceived (low-pitched, high-pitched, speech only, speech with background noise)
- 4) actual handicap (social withdrawal, occupational demands)

III. Tinnitus

IV. Dizziness / Vertigo:

1. Meaning of “dizziness” - TRUE VERTIGO or LIGHTHEADEDNESS (FAINTNESS, PRESYNCOPE)

“Do you ever feel dizzy?” “Tell me exactly what you mean by dizziness”
 “Could you clarify the meaning of the dizziness” “Did you feel the room spinning around you, or did you feel lightheaded as if you were going to pass out?”

Subjective vertigo – patient feels as if he is moving in relation to environment.
Objective vertigo – patient feels as if environment is moving in relation to him.

2. Acute or chronic

3. Constant or episodic - how long lasts:

- benign paroxysmal positional vertigo - lasts < 30 seconds;
- Ménière’s disease - attacks last hours;
- vestibular neuritis, labyrinthitis - persists for days;
- central vertigo - may persist for years.

4. Triggering factors (esp. positional triggers!!!)

5. Alleviating factors (esp. lying still)

6. Associated symptoms:

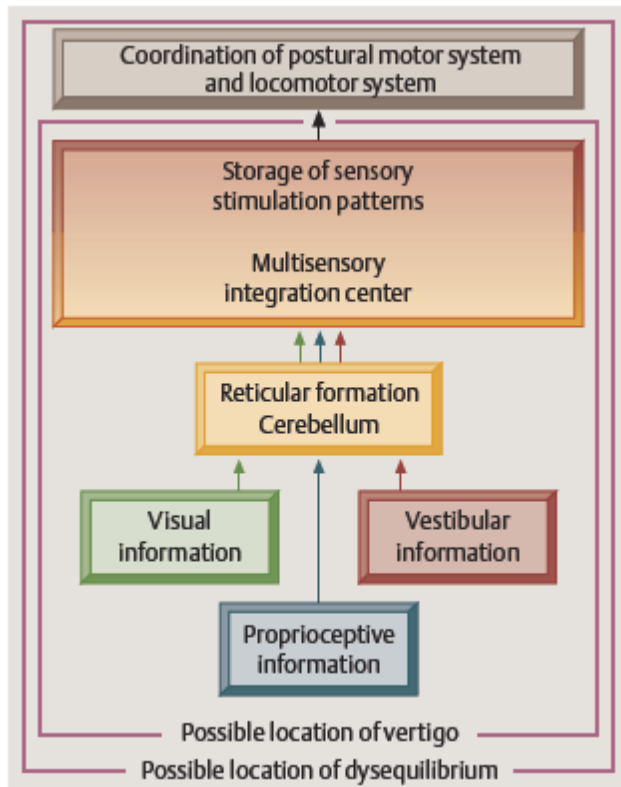
- 1) changes in hearing (loss, tinnitus), earache
- 2) nystagmus - ask patient's family if they have noted any unusual eye movements during dizzy spells (esp. important in children - unable to offer concise history).
- 3) oscillopsia - inability to recognize objects when head is moving (normalizes when head is stationary)
- 4) dysequilibrium (loss of balance)
- 5) nausea-vomiting
- 6) sweating, hypotension, bradycardia, fainting (black outs)
- 7) headaches (migraine is frequent source of vertigo)
- 8) dysarthria, diplopia

7. Etiology: head trauma, URI, medications, neck pain / trauma, hx of atherosclerosis & hypertension & palpitations.

V. Dysequilibrium (loss of balance)

Associated symptoms: vertigo, gait disturbances, falling

N.B. dysequilibrium may occur without vertigo!



PMH

History of noise exposure!!!

Medication history!!! - numerous medications can induce vertigo or impair hearing (esp. aminoglycosides, furosemide, salicylates, quinine, cisplatin / cyclophosphamide)

Toxins (esp. lead / mercury / arsenic, alcohol / tobacco / heroin / cocaine)

Head trauma

Ear disorders: TM perforations, ear inflammations, ear surgeries, ear traumas

Neurologic disorders

Cardiovascular disorders

FAMILY HISTORY of hearing disorders

AURICLE

1. Inspection:

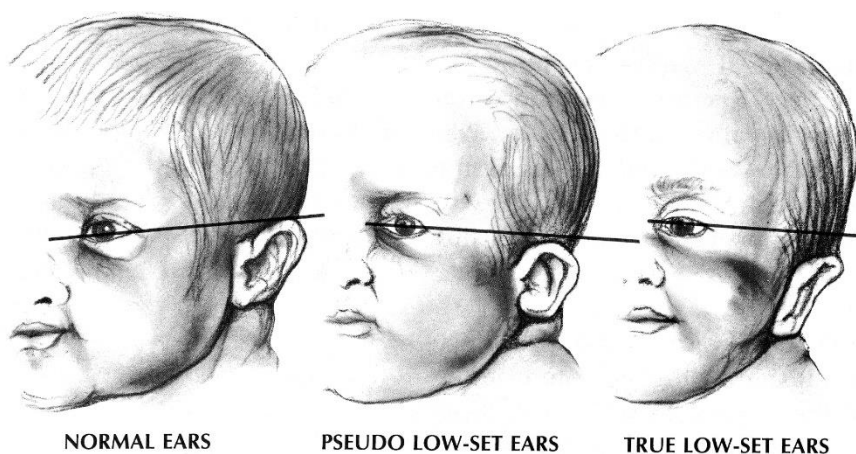
- 1) shape (of auricle & ear canal)
- 2) scars
- 3) redness & swelling
- 4) discharge & crusting

2. Palpation:

- 1) move **auricle** up & down, then press **tragus** – painful in **otitis externa** (but not in otitis media).
- 2) press firmly just **behind ear** – tenderness in **otitis media**.
- 3) palpate **temporomandibular joint** for tenderness and crepitus.

PEDIATRIC ASPECTS

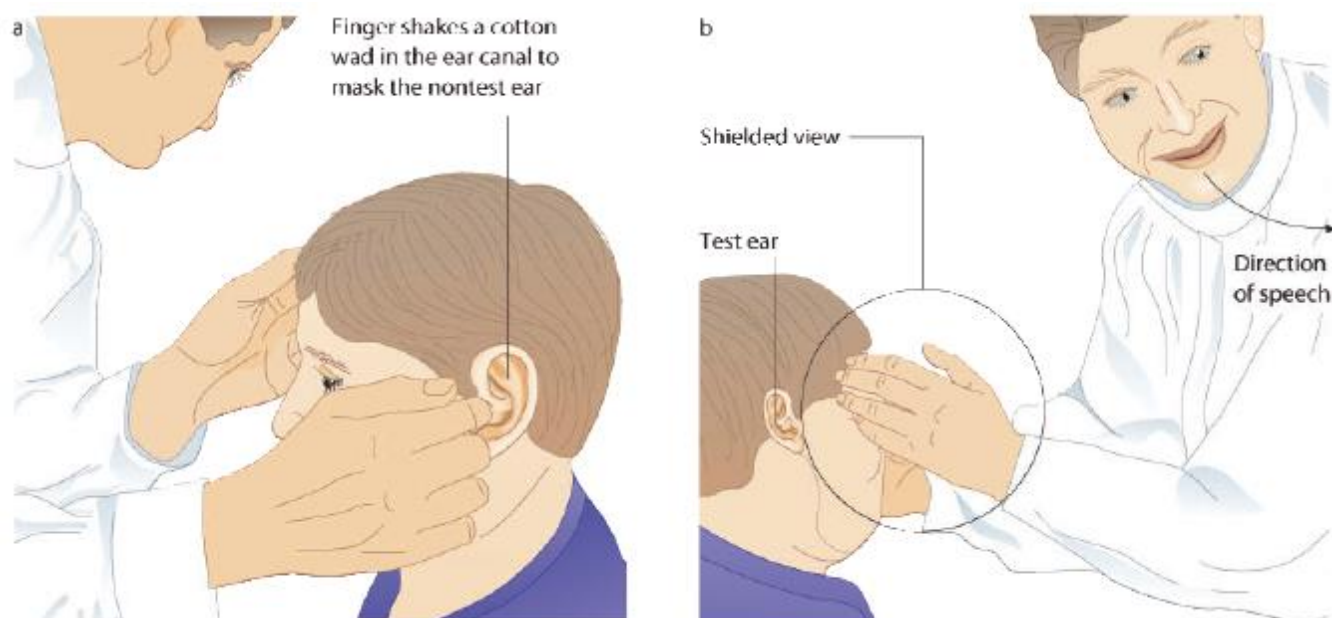
- note **EAR POSITION** in infants - normally ear joins scalp on or above extension of line drawn across inner and outer canthi:
small, deformed, low-set auricles may indicate associated **congenital defects** (esp. renal).
small skin tags, clefts, pits just forward of tragus represent **remnants of 1st branchial cleft**.



AUDITORY ACUITY

- detects only **difference** between left and right ears (quantitative degree of hearing loss is determined only by audiometry!!!)

- test one ear at time (occlude another ear at least with patient's finger);
 - **if auditory acuity on two sides is quite different**, simple occlusion of better ear is inadequate, instead move your finger rapidly but gently in patient's ear canal (noise so produced will prevent occluded ear from doing work of ear you wish to test).
 - the best masking of nontest ear – insert moist cotton wad into ear canal and gently wiggle it with finger (or rub tragus).
- make sure patient is **not reading your lips** – cover your mouth (or obstruct patient's vision).



Source of picture: Rudolf Probst, Gerhard Grevers, Heinrich Iro "Basic Otorhinolaryngology" (2006); Publisher: Georg Thieme Verlag; ISBN-10: 1588903370; ISBN-13: 978-1588903372 >>

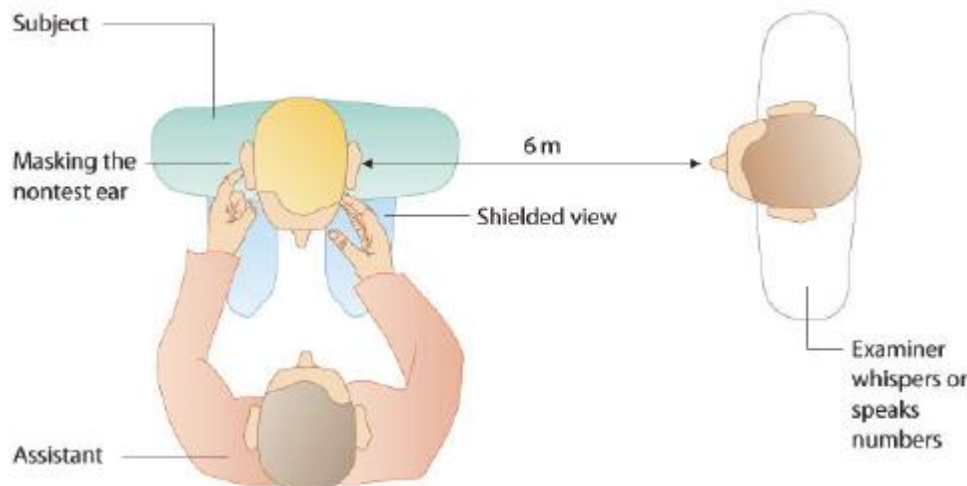
- instruct patient to repeat your words aloud.
- stand **≈ 60 cm (arms length) away**, exhale fully (so as to minimize intensity of your voice) and **whisper** softly away from unoccluded ear:
 - N.B. you may start with normal voice, to make sure that patient understands task!
 - use numbers with two equally accented syllables (e.g. "9-4", "5-2");
 - if patient does not hear → move closer to ear canal (up until just outside canal); if patient still does not hear → repeat test with number spoken at normal voice loudness.

If patient can hear whispered voice at 60 cm, hearing is better than 30 dB, i.e. **normal**.

Severe hearing loss – hears only when whispered just outside ear canal.

Functional deafness for speech – does not hear when spoken close to ear with normal / loud voice.

If assistant is available: test whisper at 6 meters with test ear facing examiner – normally must hear; if necessary → move closer → repeat test at normal voice loudness.



Source of picture: Rudolf Probst, Gerhard Grevers, Heinrich Iro "Basic Otorhinolaryngology" (2006); Publisher: Georg Thieme Verlag; ISBN-10: 1588903370; ISBN-13: 978-1588903372 >>

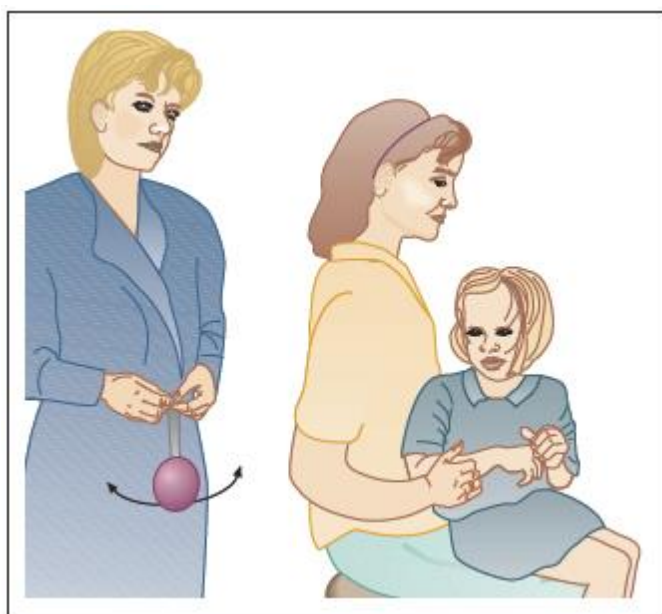
- acuity to **high-pitched sounds** is roughly tested with **watch tick** or by **rubbing patient's hair between examiner's fingers** (noise is brought closer and closer until it is heard, and distance is recorded).
- SPECIFIC CIRCUMSTANCES:
 - **unilateral auditory inattention** to bilateral simultaneous stimuli using finger rustling.
 - in unconscious / uncooperative patients, **audiopalpebral reflex** is crude screening test.
- if hearing loss is suspected, use INSTRUMENTAL TESTS: see p. Ear30 >>
 - 1) tuning fork tests
 - 2) audiometry
 - 3) otoacoustic emissions
 - 4) BAER, etc

PEDIATRIC ASPECTS

N.B. *parents' impression of baby's auditory acuity is usually correct* – if parents believe that their baby cannot hear, it should be assumed that he cannot hear until proven otherwise!!!

Crude screening tests (for infants):

- 1) normal *newborn* will **pause** briefly during sucking when bell is presented, but after several stimuli pauses will cease (habituation).
- 2) normal *infant* will **turn its head** toward bell, rattle, or crumpled paper and by 3 mo of age will **look** in sound source direction.



Testing the distraction response. A tester at the front attracts the child's attention with a toy. Then the audiometrist, standing at the rear, presents a standardized auditory stimulus (e.g., a rattle, bell, or drum) outside the child's visual field. Hearing the sound, the child will turn its head toward the sound in order to locate the source.

- 3) **acoustic blink (cochleopalpebral, audiopalpebral) reflex** – *eyelids blink in response to sharp loud noise* (e.g. snapping fingers, clapping hands, bell ringing); be sure that in generating sound you do not produce airstream that could evoke blink reflex!; it is one of INFANTILE AUTOMATISMS (PRIMITIVE REFLEXES):
 - difficult to elicit during first 2-3 days.
 - may disappear temporarily after it is elicited (habituation).
 - *disappearance time* variable.
 - absence may indicate **decreased hearing** but it is crude test and does not indicate deafness!

Child cooperation is adequate for **OBJECTIVE audiometry** since 3-4 years of age (perform *audiometric screening* at 5, 10, 12 years; *full-scale audiometry* at school entry). see p. Ear30 >>

- Any child suspected of hearing loss* → **INSTRUMENTAL TESTS:** see p. Ear30 >>
- 1) noncooperative child → *brain stem-evoked potential testing, otoacoustic emissions*
 - 2) cooperative child → *audiometry*

Age-specific testing:

- automated ABR:** up to 9 months
- visual reinforced audiometry:** 9 months to 2.5 years
- play audiometry:** 2-4 years
- conventional audiometry:** ≥ 4 years.

TUNING FORK TESTS

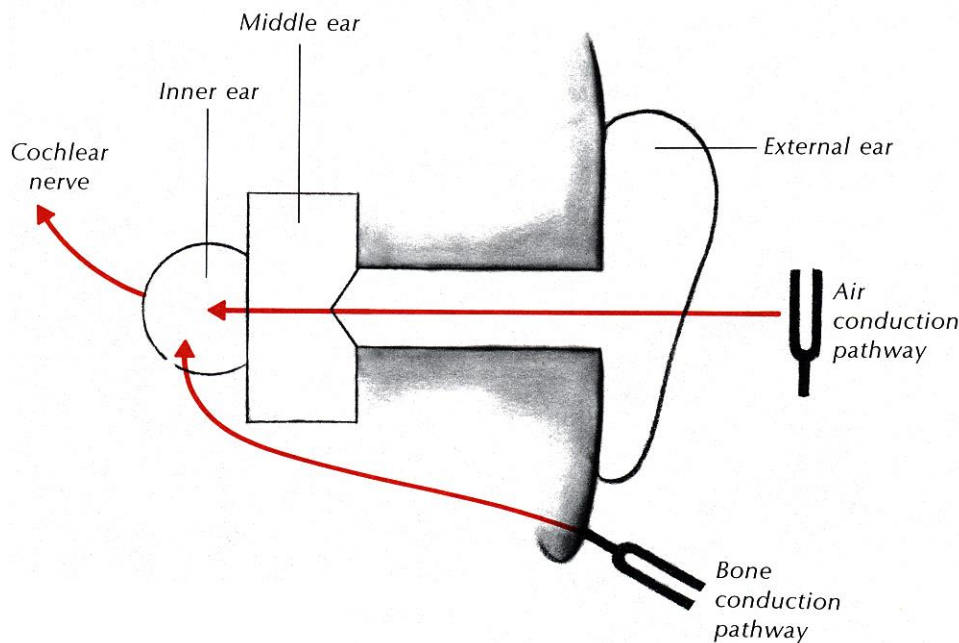
- aim to **differentiate between conductive and sensorineural hearing loss.**
- use 250-800 Hz tuning fork (functionally most important range is human speech – i.e. 300-3000 Hz); forks with lower pitches overestimate bone conduction + also felt as vibration.
- fork must have broad base (large surface area).
- set fork into light vibration by stroking it between thumb and index finger (or by tapping it on your knuckles).
- to test bone conduction – press fork base firmly against bone (to overcome sound dampening by skin).
- about sound conduction types → see p. Ear25 >>

AC – air conduction

BC – bone conduction

normally	AC > BC
CONDUCTION deafness	BC↑ - masking effect of background noise is blocked (bone conduction becomes better than in norm)
NERVE deafness	both BC & AC↓

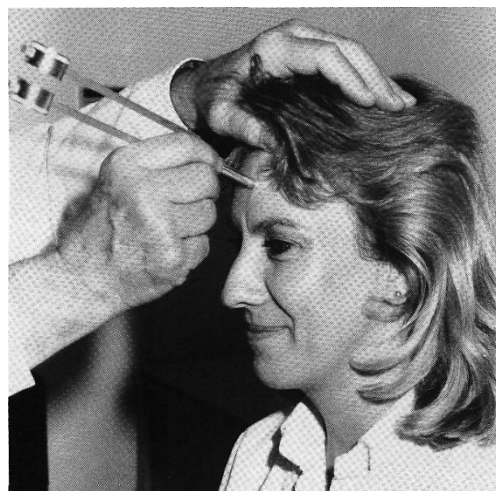Think that **middle ear acts as AMPLIFIER FOR SOUND TRAVELLING IN AIR:**



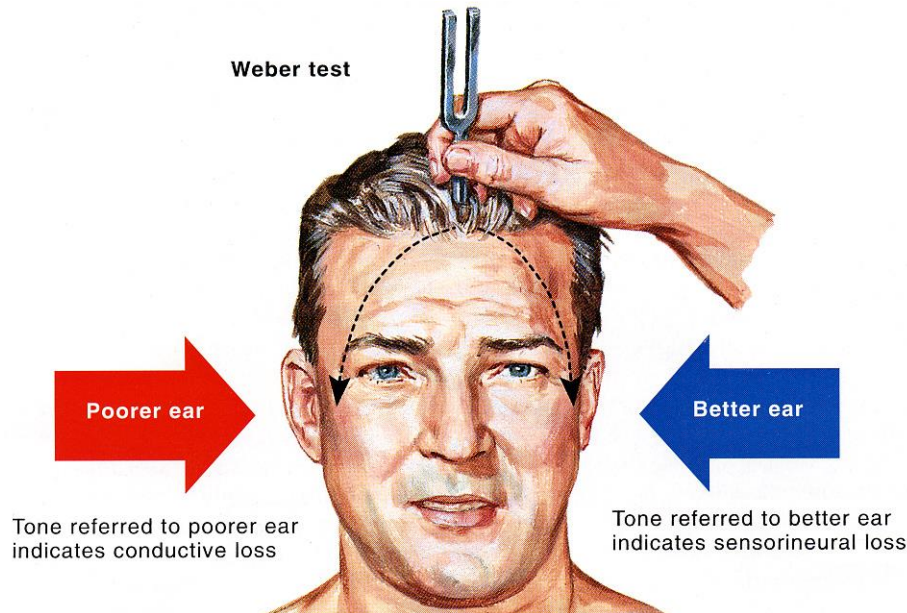
I. Lateralizing test of WEBER – base of active tuning fork is firmly placed on midline of *forehead* (or *vertex*) – ask patient where he hears (if he cannot hear, press fork more firmly on head)

- **normally** hears equally on both side.
- sound↑ on **conductive** loss side (bone conduction relatively↑*); can be reproduced by blocking normal ear canal (artificial conductive loss).

*due to blocked background room noise (so this lateralization disappears in absolutely quiet room!!!)



- sound ↓ on **neurosensory** loss side (bone & air conduction ↓).



Įsivaizduok, kad kamertonas kaip rodyklė rodo, kur yra **conductive** loss (bet nusiuka nuo **neurosensory** loss).

Lateralization can also be detected by having **patient to hum** (loud hum also induces vibration of cranium)!

II. Air-bone conduction test of RINNE:

Standard conditions:

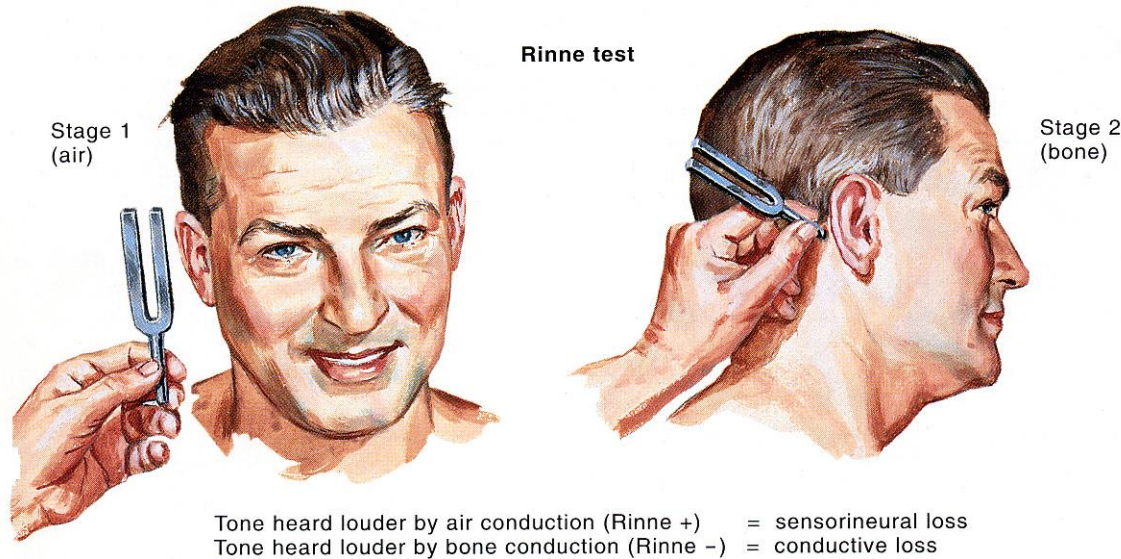
BC – base of vibrating tuning fork is firmly placed on **mastoid process**

AC – hold fork just outside ear canal without touching it with one side of fork toward ear.

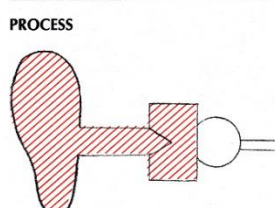
Screening: let patient to hear AC then BC – ask which is louder? If patient is not sure → threshold test.

Threshold test: test BC until subject no longer hears it → quickly move fork (not struck again!) to test AC.

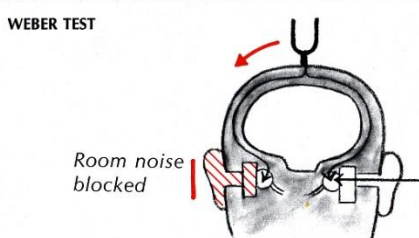
- **normally** after bone conduction is over, vibration in air is still heard at least 15 secs longer (because of sound amplification by middle ear structures) – AC > BC (**positive Rinne**).
- on **conductive** loss side air vibration is not heard (i.e. BC > AC – **negative Rinne**).
- on **neurosensory** loss side pattern is normal – i.e. air vibration is heard as long as nerve deafness is partial (because middle ear structures are intact) - AC > BC (**positive Rinne**).
N.B. when testing BC in ear with severe **neurosensory** loss, it is advisable to mask normal ear because it may feel skull vibrations (pacientui atrodis, kad BC > AC – **pseudonegative Rinne**). But this is rarely done routinely!



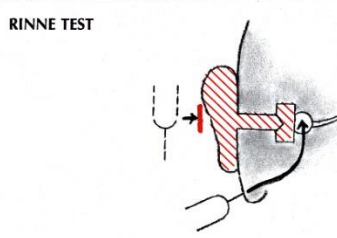
CONDUCTION LOSS



Problem in the external or middle ear

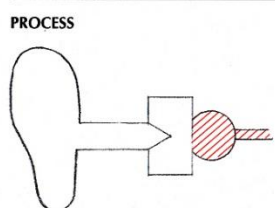


Lateralizes to the poor ear. Because the poor ear is not distracted by room noise, it can detect bone vibrations better than normal. Test this on yourself by doing a Weber test while occluding one ear with your finger. This lateralization disappears in an absolutely quiet room.

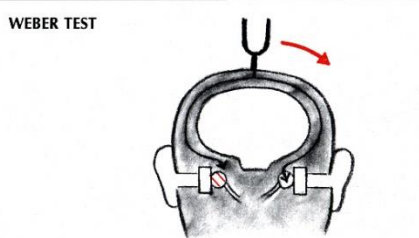


Bone conduction lasts longer than air conduction (BC > AC). Pathways of normal conduction through the external or middle ear are blocked. Vibrations through bone bypass the obstruction.

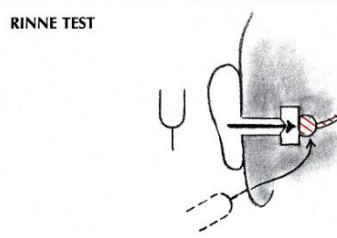
SENSORINEURAL LOSS



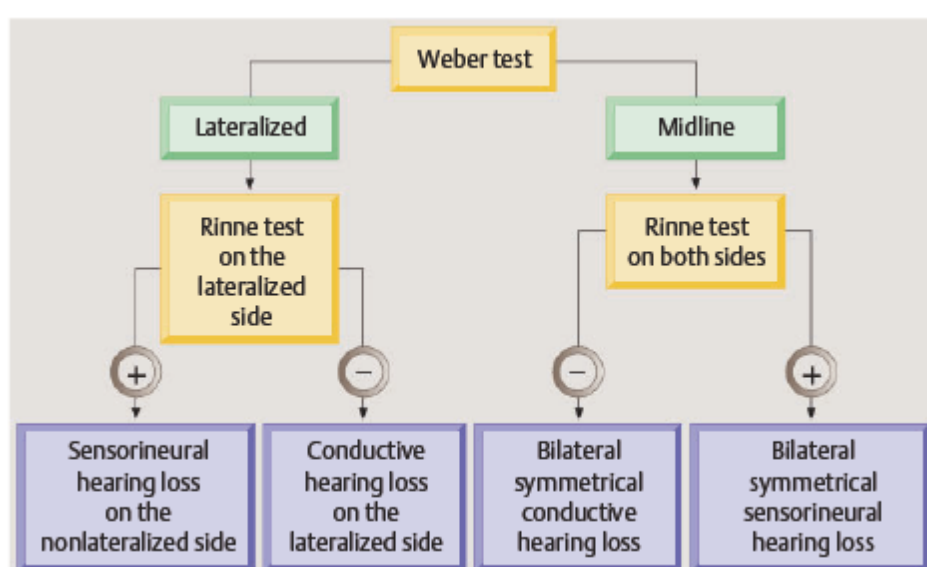
Problem in the inner ear or nerve



Lateralizes to the good ear. The inner ear or nerve is less able to receive vibrations arriving by any route, including bone. The sound is therefore heard in the better ear.



Air conduction lasts longer than bone conduction (AC > BC). The inner ear or nerve is less able to perceive vibrations arriving by either route. The normal pattern prevails.



III. SCHWABACH test – bone conduction is compared with that of examiner (i.e. normal individual).

- normally conduction is the same;
- on **conductive** loss side bone conduction is better than normal;
- on **neurosensory** loss side bone conduction is worse than normal.

IV. BING test - fork is struck and placed on mastoid tip; examiner alternately occludes patient's ipsilateral external meatus.

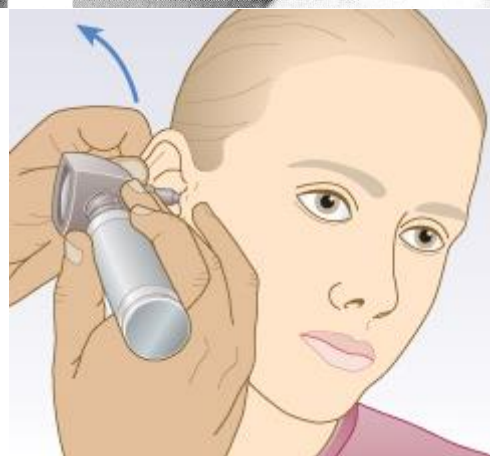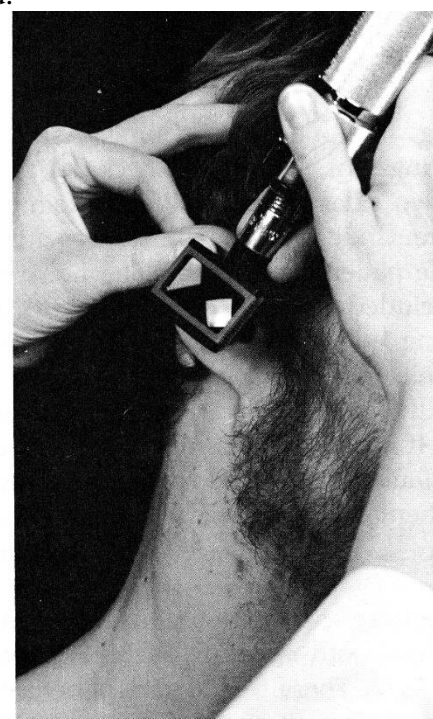
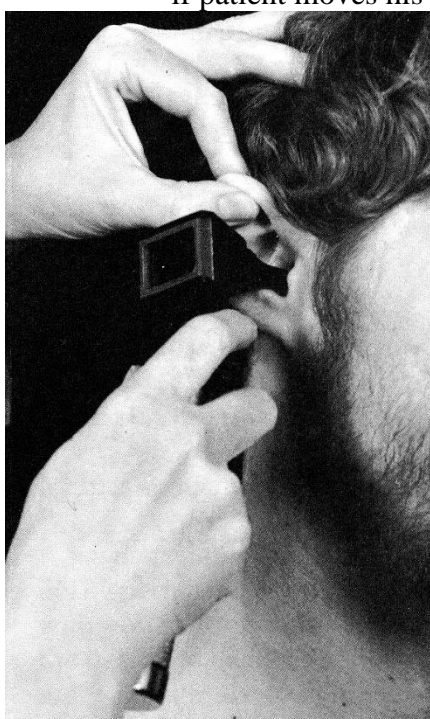
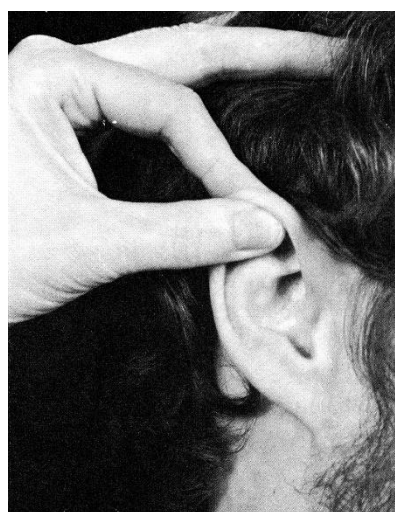
- in **normal** hearing (or **sensorineural** loss), patient notices change in intensity with occlusion.
- in **conductive** loss, patient notices no change.

OTOSCOPY

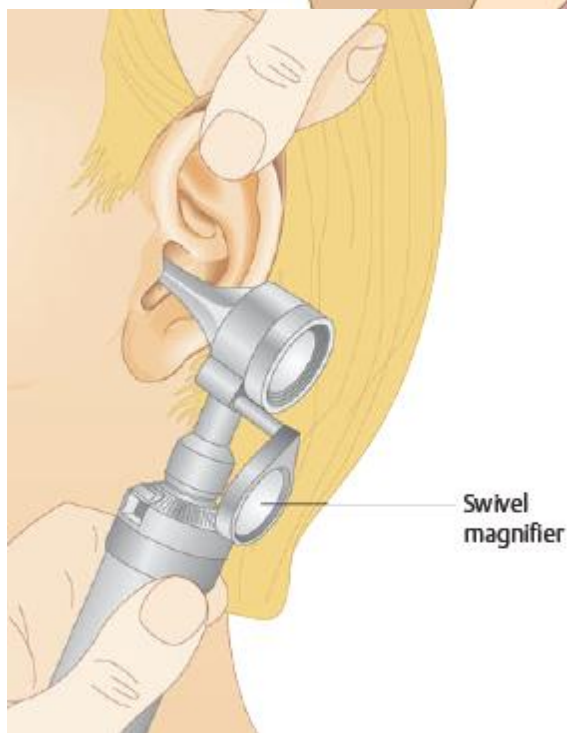
Before otoscopy – check by palpation for otitis externa (pull auricle + tragal tenderness) → particularly careful otoscopic technique!

- hand-held otoscope**
- otomicroscope** (in ENT office)

- patient's head should be tipped slightly to opposite side.
- grasp auricle (firmly but gently) pulling it **upward, back, and slightly out** (avoid excessive traction!)
- use *largest speculum ear canal can accommodate* – best visualization, no risk of inserting too far.
- two possible grips are possible:
 - first** – firm & natural
 - second** (otoscope held as pen; ulnar border of hand lightly braced against patient's cheek) – more gentle method - helpful for active patients (esp. children) – avoids trauma if patient moves his head.



- insert slowly (!) into canal slightly down and forward.
- insert under visual guidance past vibrissae but do not touch (!) bony and pain-sensitive **medial portion of canal**.
- after speculum has been introduced, it is held securely in alignment with bony ear canal, and auricle can be released.



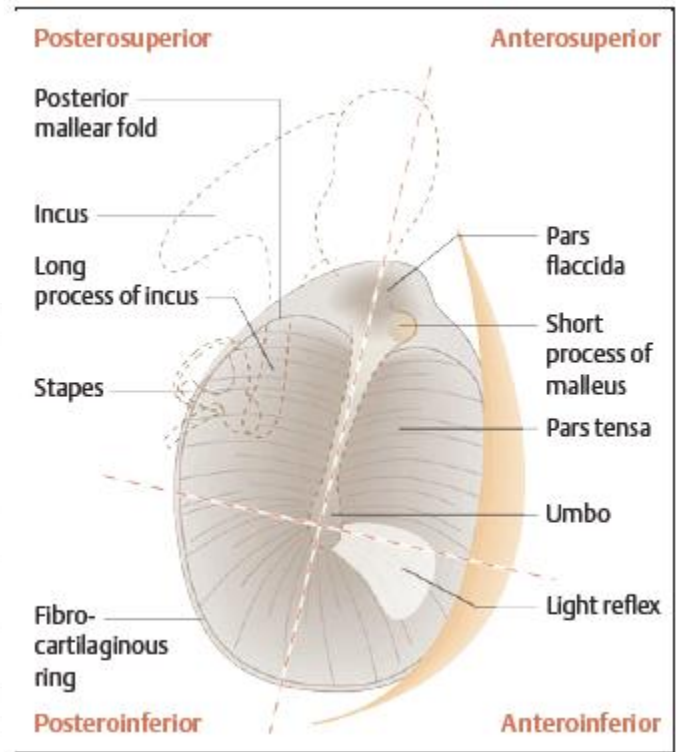
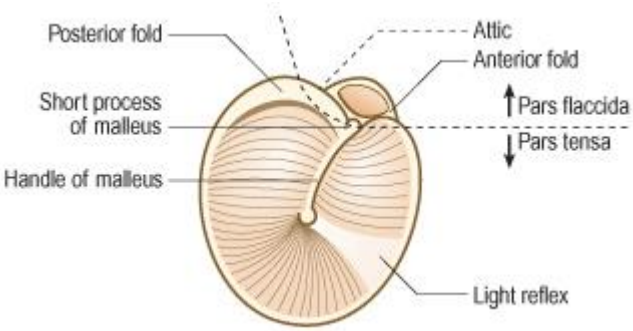
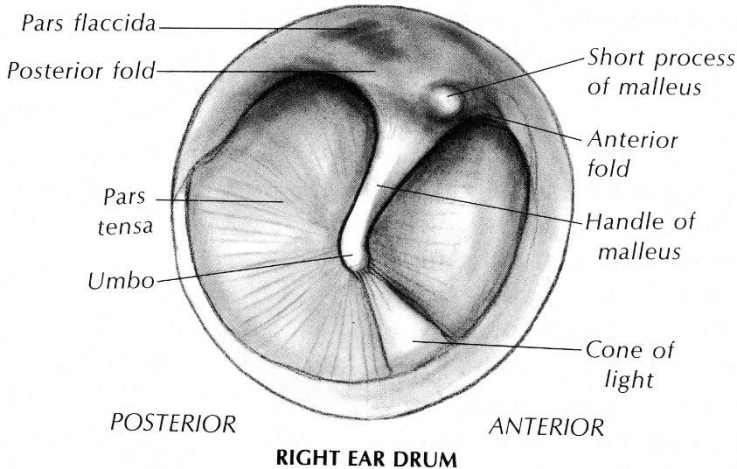
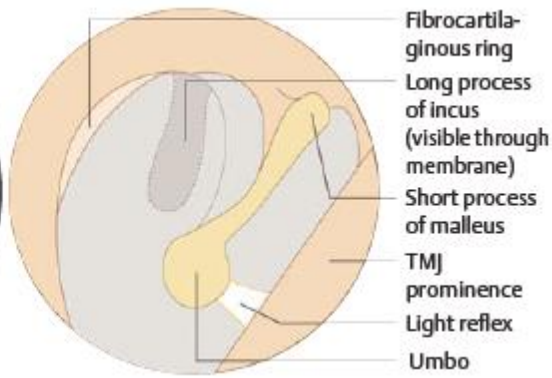
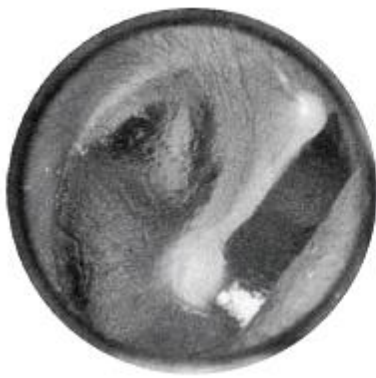Inspect EAR CANAL:

- nontender nodular swellings covered by normal skin deep in ear canal suggest **osteomas**.
- redness, pain, narrowing suggest **acute otitis externa**.

N.B. **purulent material in ear canal** (**otitis externa** or **otitis media with perforation**) must not be washed – painful and may introduce m/o into middle ear (in case of drum perforation).

Inspect EAR DRUM:

- 1) **color** (normally, grayish)
- 2) **thickness** (normally, variable transparency – may be possible to see inner structures – long process of incus, chorda tympani)
- 3) **light reflex** (normally, light reflex “points to toes”, i.e. anteroinferiorly) – indicates smooth surface of TM;
 - if **epithelium becomes swollen (inflammation)** – light reflex is lost!
- 4) **differentiation** – fibrocartilaginous ring and malleus handle must be identifiable!;
 - in **inflammation** – these structures can no longer be seen (TM has undifferentiated appearance).
- 5) **mobility** (*see below >>*); most obvious in posterior superior TM quadrant; mobility is restricted in **middle ear effusions, TM scars**.
- 6) **abnormalities:**
 - a) **perforations**
 - b) **white patches** - tympanosclerosis (scarring from perforation).
 - c) **vascular hyperemia**
 - d) **fluid in middle ear** (→ pneumatic otoscopy).



TM mobility assessment:

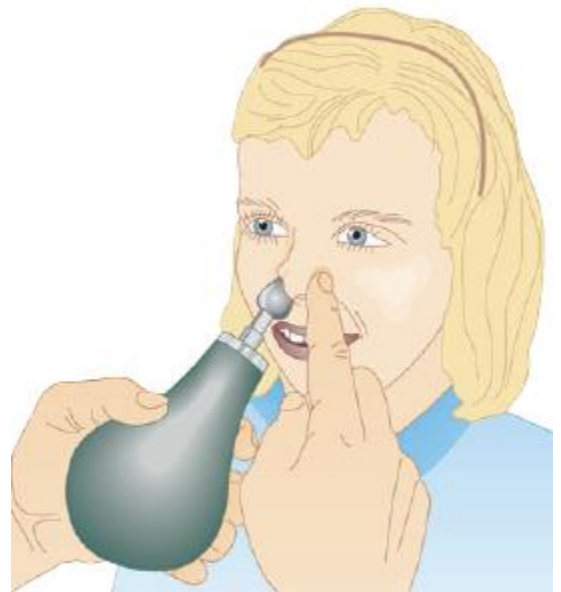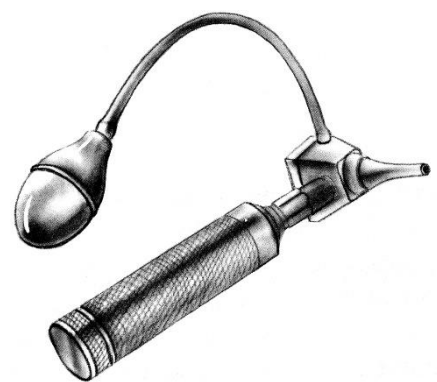A. Pneumatic otoscopy: increase / decrease pressure in ear canal → simultaneously observe drum (and its light reflex) movements.
 - drum movements are absent / diminished in **otitis media**.

B. Patent eustachian tube is indicated by drum movement during **Valsalva maneuver**: patient is told to swallow → pinch nostrils → “bear down” (patient must hear “popping”).

C. Politzer maneuver – air is forced into one side of nose by squeezing air bag while other nostril is occluded and soft palate is closed off (patient says “cuckoo” or “Coca-Cola”):

D. Toynbee maneuver – negative pressure is created in pharynx by having patient swallow with nostrils pinched shut.

N.B. **B-D maneuvers** should not be used in acute otitis media / acute pharyngitis!

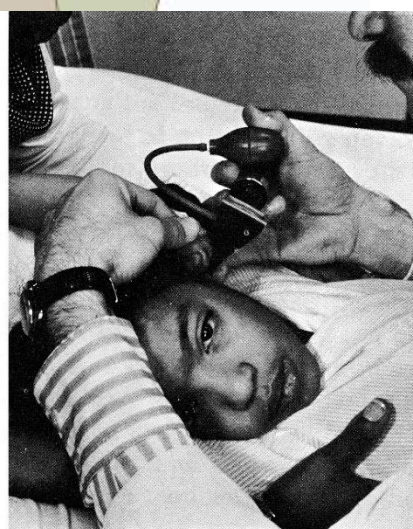
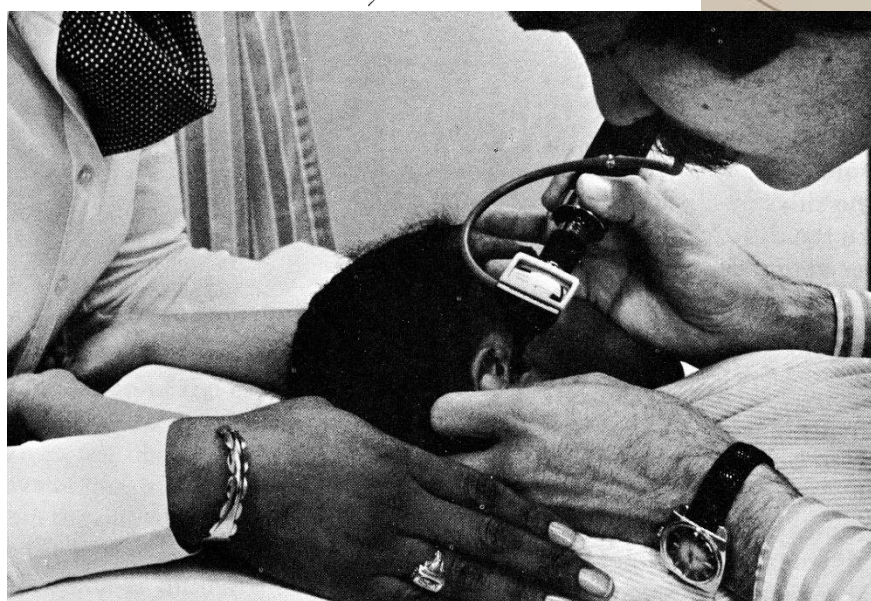
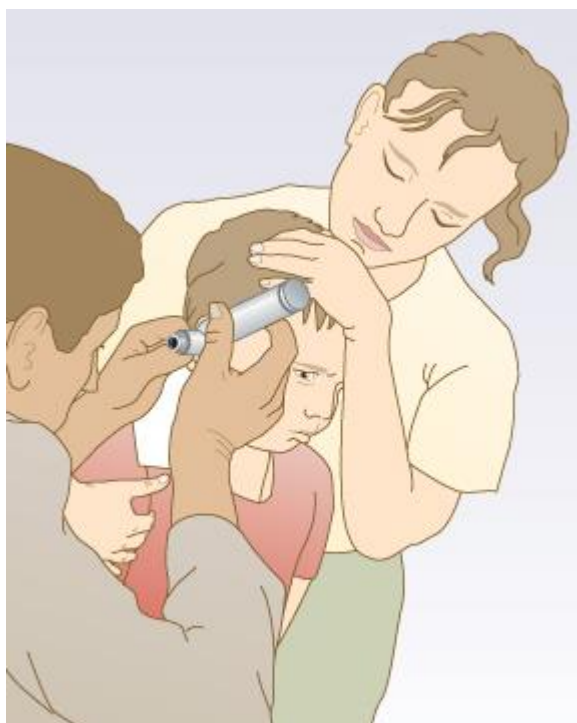

PEDIATRIC ASPECTS

- in neonates examine **patency of ear canal** only (drum is obscured by accumulated vernix caseosa for first 2-3 days).
- in infancy, *ear canal is directed downward from outside* – pinna should be pulled gently downward & backward for drum visualization; *tympanic light reflex is diffuse* (no cone shape for several months).

High incidence of **otitis media** mandates middle ear examination in all infants! (best sensitivity - **pneumatic otoscopy** results combined with **tympanometry** results)

- in early childhood examination becomes difficult – ear canal is sensitive + child cannot observe procedure;
 H: restrain child (vaikas laikomas mamos glėbyje – kojos suspaustos tarp mamos kojų; mamos viena ranka apglėbia vaiko krūtinę ir rankas, kita ranka laiko prispaustą galvą prie krūtinės) + manipulate ear and otoscope gently (geriausiai įkišti speculum į vieną ausį nieko nedarant, po to į kitą ausį, po to vėl atgal – taip vaikas nusiramins).



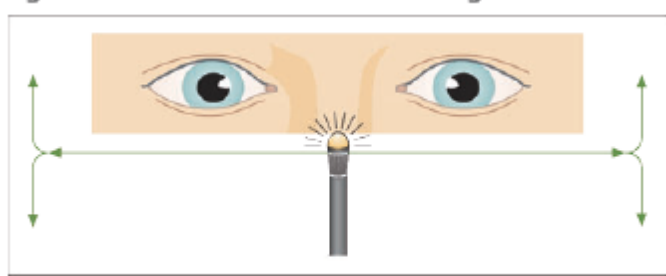
VESTIBULAR FUNCTION

ASK FOR VERTIGO / DYSEQUILIBRIUM *see above >>*

EYE MOVEMENTS:

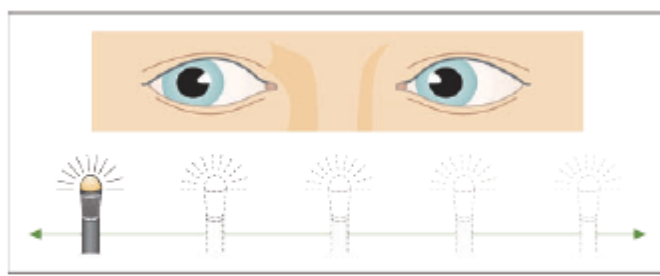
Pacientas seka gydytojo pirštą vedamą H-formos figūrą (ekstraokulinių raumenų paralyžius?), po to 12, 6, 3, 9 valandomis (nistagmas?). *see p. D1eye >>*

Fig. Horizontal and vertical tracking test



Normally, both eyes can track the moving target in all directions in a coordinated fashion.

Fig. Testing slow tracking eye movements



With normal oculomotor function, both eyes can track the target smoothly without catch-up saccades.

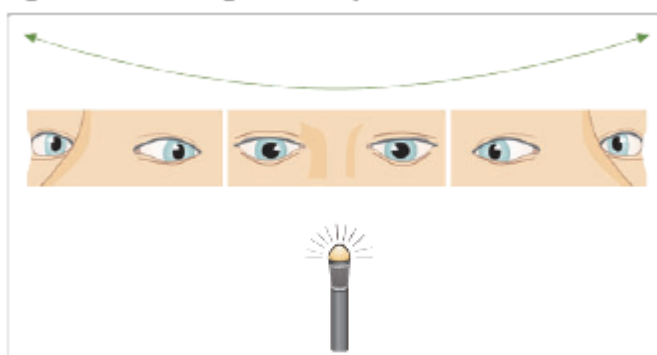
NYSTAGMUS: spontaneous, gaze-evoked, positional, suppressible by visual fixation? (peripheral vestibular nystagmus is suppressible by visual fixation)

CATCH-UP SACCADES during smooth pursuit (**oculomotor system disorder**)

Pacientas fiksuoja žvilgsnį į gydytojo, sėdinčio už 1 metro, nosį* o gydytojas greitai sukinėja paciento galvą horizontaliai 30° ribose (**HALMAGYI test**):

*or ask to read Snellen chart. *see p. Eye64 >>*

Fig. Screening for oscillopsia



Inability to fix the gaze on a stationary object during active head movements is a sign of bilateral vestibular hypofunction.

OSCILLOPSIA (**bilateral vestibular disorder**) – inability to fix gaze, accompanied by refixating saccade. *see p. Eye64 >>*

COORDINATION TESTS (atsimerkus, užsimerkus): *see p. D1 >>*

- 1) rapidly alternating movement, finger-to-nose, heel-to-shin tests
- 2) simple gait, vaikščioti tiesia linija "tip-top"
- 3) **eyes-closed tandem (s. sharpened) ROMBERG test**;
 - no patient with **bilateral vestibular loss** can stand for 6 seconds.
 - patients with **chronic unilateral vestibular loss** show very little ataxia - can perform eyes-closed tandem Romberg test.

VESTIBULAR FUNCTION LABORATORY TESTS:

- perform if patient has failed eyes-closed tandem Romberg test.
- easily observable end result is **NYSTAGMUS** (documented by **nystagmography**).
- because **patient can visually suppress peripheral vestibular nystagmus**, many tests are performed with **+20 D lenses (cataract glasses)**, which prevent patient from focusing on objects in visual surround.

Vestibular disorders lead to **directional** instability toward side of affected vestibular organ (vs. **other neurologic disorders** – lead to **nondirectional** instability / ataxia).

ALERT PATIENT

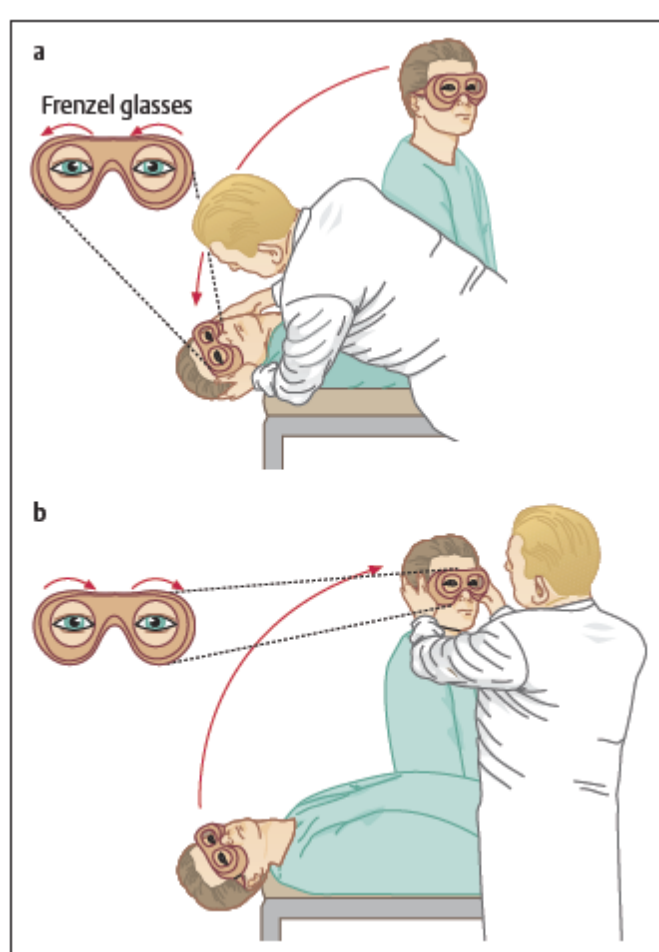
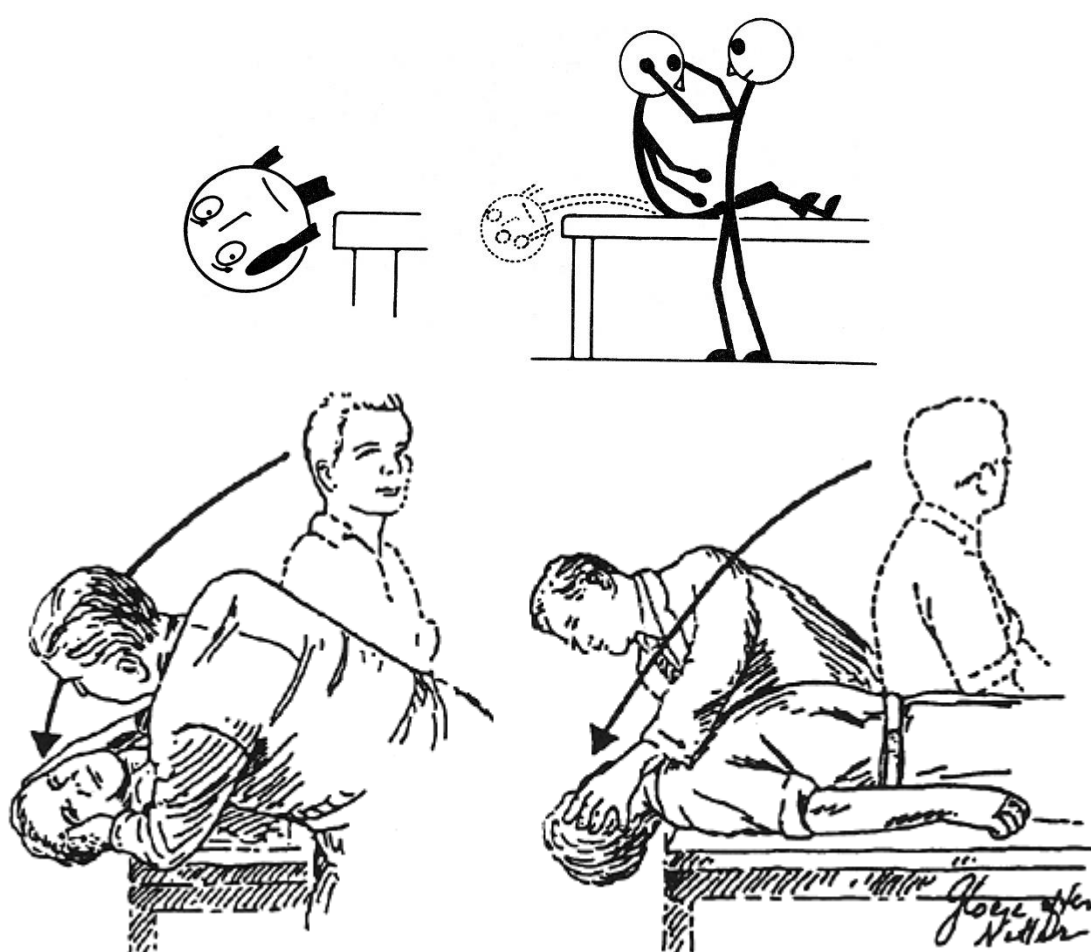
- 1) **vestibulo-ocular tests**, incl. rotating chair test. *see p. Eye64. >>*
past-pointing test; *see p. D1 >>*

- 2) **caloric irrigation test**; goal is to determine asymmetry - peripheral vestibular disease.

see p. S30 >>

- 3) **UNTERBERGER stepping (s. FUKUDA) test** - patient is asked to step in place 50 steps (eyes closed), bringing thighs up to horizontal position with each step; rotation of patient to one side $> 45^\circ$ indicates **ipsilateral loss of vestibular tone**.
- 4) tests for **benign paroxysmal positional vertigo** (warn patient to expect dizziness!!!):
- a) **DIX-HALLPIKE maneuver** (one of most important tests for patients complaining of true vertigo) – patient is first seated on examining table (best if wears Frenzel glasses); then with his **head turned 45° to side** (not 90° !), he quickly assumes supine position with his head dependent over end of table (30° below horizontal); positive (abnormal) if patient reports ¹severe **vertigo** and exhibits characteristic ²rotational **nystagmus**;
- starts 1-20 seconds after patient lies back (**latency**) [wait minimum 20 seconds!]
 - lasts 15-60 seconds (**adaptation**).
 - **specific direction**: if left ear is affected, nystagmus is clockwise (ageotropic)* when head is turned to left; if right ear is affected, nystagmus is counterclockwise (geotropic)*; when patient slowly sits up (with head still turned 45°), response recurs, but nystagmus is rotary in opposite direction and is milder.
 - **fatigability** (i.e. if test is repeated immediately, response is diminished).
 - test is repeated with head **turned to other side**; finally in **neutral position**; affected side can be determined from side of greater response (“down” ear is affected).

*for definitions see p. D1eye >>



EPLEY modification: from behind patient, performing maneuver is easier, since one can pull outer canthus superolaterally to visualize eyeball rotation.

- b) **NYLEN-BÁRÁNY maneuver** – hyperextend patient's neck and rotate head laterally as patient is rapidly moved from seated to supine position; response as in Dix-Hallpike maneuver.
- 5) **apply pressure to tragus** - if vertigo appears / worsens – consider **perilymphatic fistula**.
- 6) **hyperventilation test** - patient breathes deeply and forcefully for 30 breaths at rate 1 breath per second; immediately after hyperventilation, eyes are inspected for nystagmus with Frenzel goggles, and patient is asked if procedure reproduced symptoms:
- *subjectively positive test result without nystagmus* suggests diagnosis of **hyperventilation syndrome** (anxiety disorder).
 - *nystagmus* can occur in **tumors / irritation of CN8** or in **multiple sclerosis**.
- 7) **COMPUTERIZED PLATFORM POSTUROGRAPHY** assesses equilibrium as whole (as vestibular, visual, somatosensory interaction); instrumented variant of Romberg test; sole diagnostic indication for posturography is *to document MALINGERING*.

IMPAIRED CONSCIOUSNESS

- 1) **"doll's eye" test** see p. S30 >>
- 2) **caloric irrigation test** see p. S30 >>

PEDIATRIC ASPECTS

- vestibular function is evaluated by **caloric irrigation test**. see p. S30 >>

BIBLIOGRAPHY for ch. "Diagnostics" → follow this [LINK >>](#)

Viktor's NotesSM for the Neurosurgery Resident
Please visit website at www.NeurosurgeryResident.net