

# Spinal Muscular Atrophies (SMA)

Synonyms: **PROGRESSIVE SPINAL MUSCULAR ATROPHY, PROGRESSIVE SPINAL ATROPHY**

Last updated: August 8, 2020

ETIOPATHOPHYSIOLOGY ..... 1  
 EPIDEMIOLOGY ..... 1  
 CLINICAL FEATURES ..... 1  
 DIAGNOSIS ..... 2  
 TREATMENT ..... 3  
 PROGNOSIS ..... 3  
**OTHER FORMS OF LMN DEGENERATION..... 3**

SMA - progressive degeneration and loss of **LMN** (midbrain ÷ spinal cord).

- replacement of lost cells by gliosis (e.g. atrophic spinal cord at autopsy).
- UMN is not affected! (vs. in ALS)

Type	Inheritance	Age of Onset	Presenting Symptoms	Prognosis
<b>SMA type I</b> (infantile / acute / fatal SMA, <b>Werdnig-Hoffman</b> disease)	AR	In utero ÷ 6 months	Hypotonia and <b>generalized</b> weakness, problems with sucking, swallowing, and breathing; never able to sit	Average life expectancy - 8 months; 95% dead before age of 18 months
<b>SMA type II</b> (intermediate between type I and type III)	AR	6 ÷ 15 months	< 25% learn to sit; never able to stand, facial muscles spared	Depends on respiratory complications
<b>SMA type III</b> (chronic SMA, <b>Kugelberg-Welander</b> disease)	AR, AD	15 months ÷ teen years	<b>Proximal</b> leg weakness, delayed motor milestones	
<b>Kennedy's disease</b> (bulbosplinal muscular atrophy)	X-linked recessive	After age 40 yrs	<b>Bulbar</b> → <b>distal</b> limb weakness; endocrine dysfunction	Normal lifespan
<b>Fazio-Londe disease</b> (progressive bulbar palsy of childhood)		Late childhood ÷ adolescence	<b>Bulbar</b> weakness	
<b>SMA type IV</b> (adult-onset SMA)	AD, AR, X-recessive (very rare)	median ≈ 37 years	<b>Proximal</b> weakness, variable within families, more severe in AD	Life expectancy not markedly reduced
<b>Distal SMA</b> ( <b>Charcot-Marie-Tooth</b> type-SMA)	AR, AD	AR: birth ÷ infancy; AD: adulthood	<b>Distal</b> weakness	Very slow clinical progression; does not alter lifespan

## ETIOPATHOPHYSIOLOGY

Autosomal recessive **SMA types I, II, III** (allelic heterogeneity) have been linked to **5q11.3-13.1 - gene for survival of motor neurons (SMN)**:

Defect in neuronal apoptosis!

- contains multiple copies of genes and pseudogenes;
- characterized by instability: deletions (98%), truncations, point mutations.
- protein product has no known homolog, and its function is not yet known.
- no correlation between genotype and phenotype! - but most affected siblings exhibit same phenotype - may be additional modifying factors, e.g. another gene tightly linked to pathogenic gene:
  - a) contiguous deletion of nearby **neuronal apoptosis inhibitory protein gene (NAIP)** is associated with most severe phenotype (occurs in 45-65% **SMA type I** and in 20-40% **SMA type II and III** cases).
  - b) homozygous deletions in exons 7 and 8 in **SMNt (telomeric copy of SMN)** → **SMA type I**; mutations that convert SMNt to centromeric copy (**SMNc**) → **SMA type II and III**.
- SMN protein is implicated in the trafficking of RNA in and out of the nucleus and in the formation of complexes that are important in RNA splicing.
- SMN locus on chromosome 5 has two almost identical copies of the SMN gene - one produces a full length SMN protein, whereas the second expresses a small amount of full-length SMN and a shortened SMN; loss of full-length SMN from mutations at the main locus can be mitigated to some degree by the shortened SMN protein expressed at the second locus.

## EPIDEMIOLOGY

**SMA type I** (most common SMA) INCIDENCE ≈ 4-10 in 100,000 (2<sup>nd</sup> most common neuromuscular disease, following Duchenne muscular dystrophy).

- similar numbers are affected with milder forms and forms with later onset.
- *carrier frequency* of **SMNt mutation** - 1 in 50.

## CLINICAL FEATURES

Clinical hallmarks:

1. Insidious onset of symmetrical **WEAKNESS**.
  - proximal muscles > distal muscles.
  - legs > arms.
  - *greatest decline in muscular power occurs at onset\** and then slows (i.e. great loss of motoneurons initially, followed by stabilization in any remaining neurons) - difference between SMAs and other neurodegenerative disorders.
 

\*results in **large number of complications**: scoliosis, contractures (e.g. arthrogryposis multiplex congenita), disuse atrophy, respiratory / nutritional / sleep problems.
2. **HYPOTONIA, ATROPHY, LOSS OF TENDON REFLEXES**  
 After immediate neonatal period, spinal muscular atrophy is *most common cause of infantile hypotonia* ("floppy infant")!
3. **CRANIAL NERVE PALSIES** (CN3, 4, 6 are typically spared!).

No sensory symptoms or loss, no myalgias!  
 No heart involvement!  
 Intelligence normal! (children often appear brighter than their normal peers!)

**SMA type 1 (Werdnig-Hoffmann)** - evident at birth or soon thereafter, always *before age 6 months*.

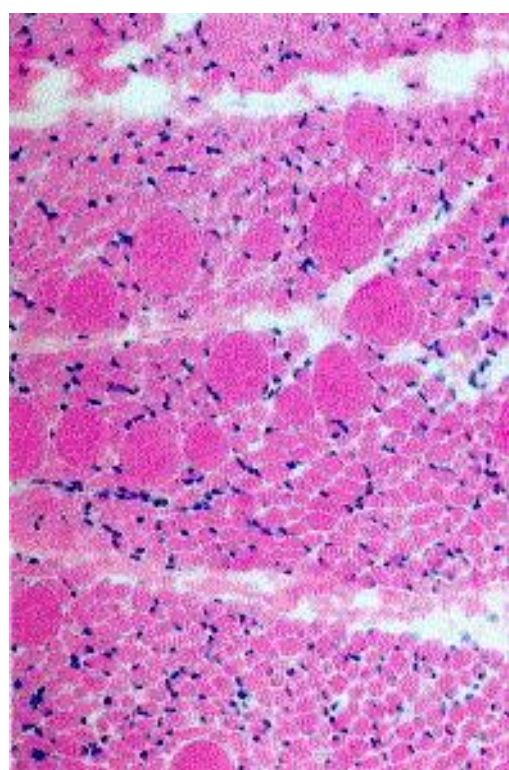
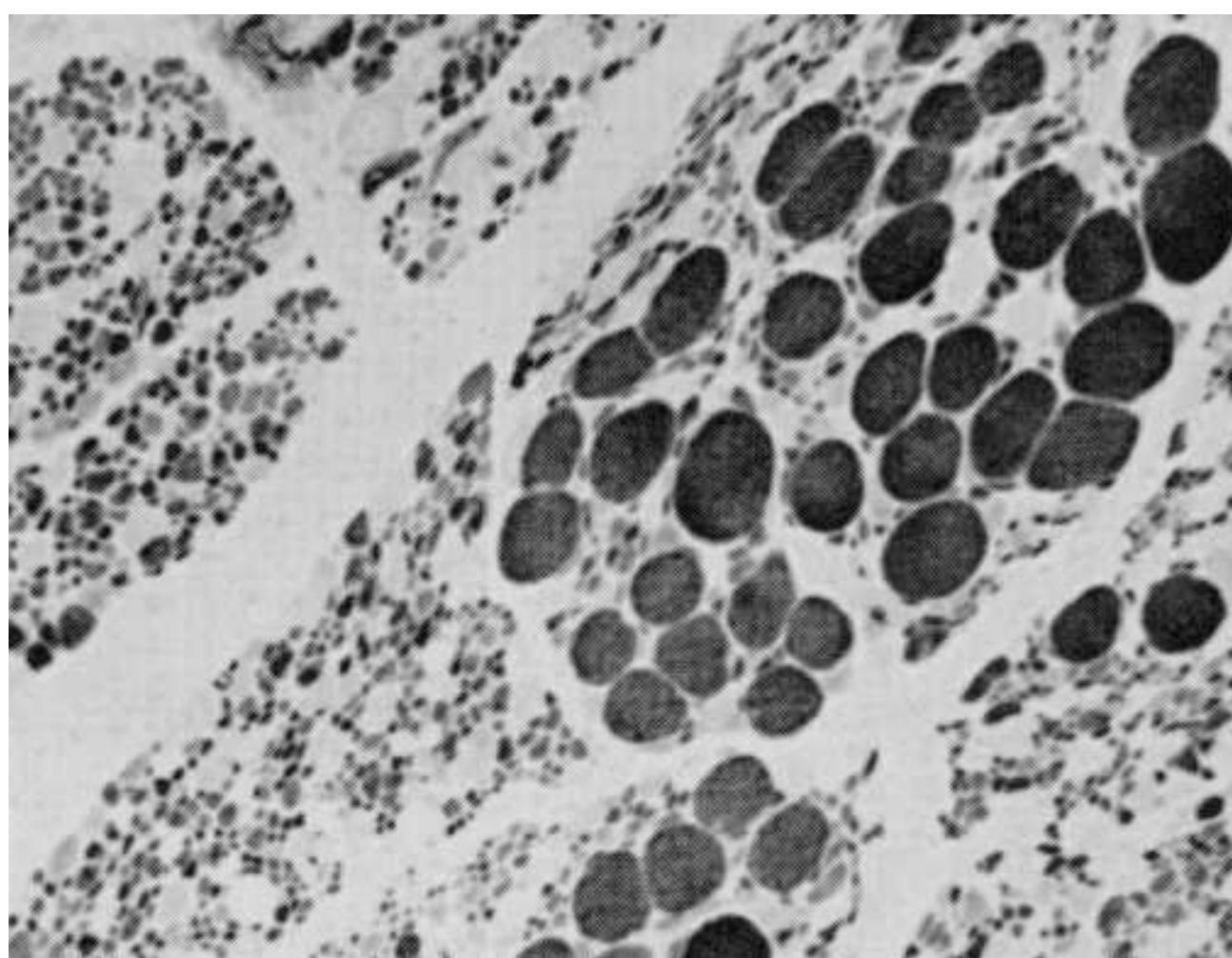
- mothers notice decreased intrauterine movements.
- one of most common forms of *floppy infant syndrome* (infants lie flaccid with little movement, unable to overcome gravity).
- tongue is often seen to fasciculate (rarely in limb muscles - because of ample subcutaneous fat).
- ultimately, **complete flaccid quadriplegia** results with **compromised respiration**.
- all dead by age 4 yrs.

**SMA type 3 (Kugelberg-Welander)** – slowly progressive gait disorder in *late childhood or adolescence*.

- **proximal** limb muscle weakness and wasting (simulates muscular dystrophy!); tendon reflexes are lost.
- relative sparing of bulbar muscles.
- *course relatively benign* - many continue to function socially with normal life span (others may be handicapped); many children are highly intelligent.

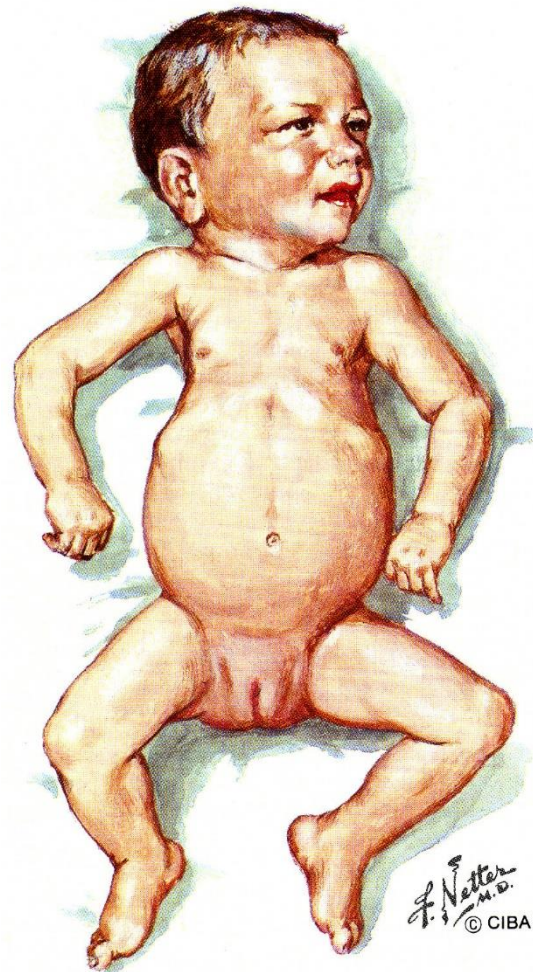
## DIAGNOSIS

- **genetic test** – **homozygous SMN deletion** (sensitive test in 95% cases!).
  - prenatal testing is available only on research basis.
- **serum CK** can be elevated (correlates with illness duration);
  - in **SMA 3**, may be 20 times normal (in range of many myopathies!).
- **ECG** – normal.
- without DNA diagnosis, it is essential to verify neurogenic process via:
  - 1) **EMG** – denervation.
  - 2) **nerve conduction studies** – normal.
  - 3) **muscle biopsy** (with histochemistry) – **denervation & reinnervation**: large numbers of atrophic fibers, often only few micrometers in diameter; atrophic fibers often involve entire fascicle (**panfascicular atrophy!!!**); scattered groups of large fibers that are 2-4 times normal size.      also see p. D30 >>

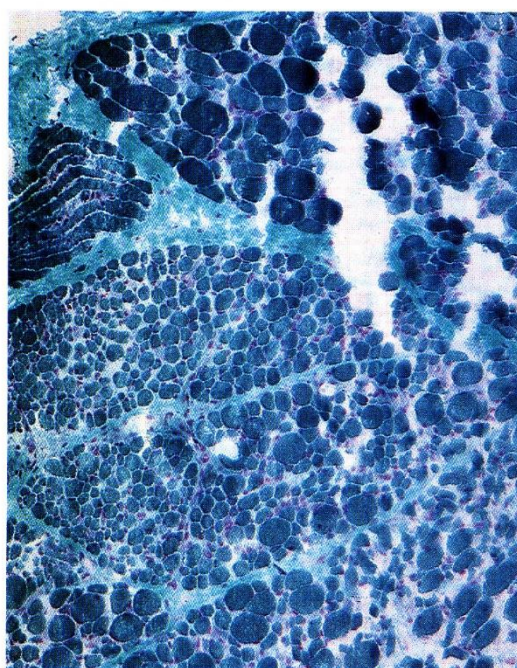


Source of picture: Ramzi S. Cotran "Robbins Pathologic Basis of Disease", 6<sup>th</sup> ed. (1999); W. B. Saunders Company; ISBN-13: 978-0721673356 >>

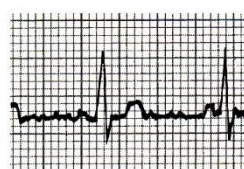Werdnig-Hoffmann Disease



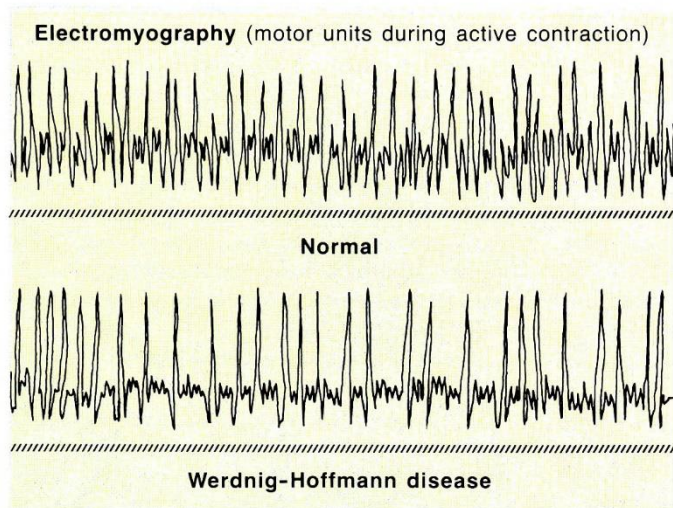
Infant with typical bell-shaped thorax, frog-leg posture, and "jug-handle" position of upper limbs



Muscle biopsy specimen showing groups of small atrophic muscle cells and areas of normal or enlarged cells (group atrophy). (Toluidine blue O stain)



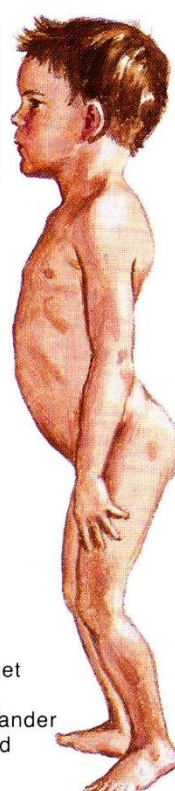
Baseline tremor in otherwise normal electrocardiogram



Electromyography (motor units during active contraction)

Normal

Werdnig-Hoffmann disease



Boy with much milder, late-onset form of disease (Kugelberg-Welander disease). Marked lordosis and eversion of feet

TREATMENT

- multidisciplinary approach aimed at preventing contractures, skeletal deformities, respiratory complications, and social isolation.

**NUSINERSEN** (Spinraza®) intrathecal injection - antisense therapy - the first FDA approved drug to treat children and adults with spinal muscular atrophy.

- sham-controlled study in 78 children with infantile SMA showed that treatment with nusinersin leads to a 50% reduction in deaths or early ventilation.

Finkel RS, Mercuri E, Darras BT, et al; ENDEAR Study Group. Nusinersen versus sham control in infantile-onset spinal muscular atrophy. *N Engl J Med.* 2017;377:1723-1732.

**RISDIPLAM** (Evrysdi®) taken by mouth or via a feeding tube – gene-splicing modulator that increases production of survival of motor neuron protein (SMN), needed for survival of motor neurons - FDA approved for treatment of SMA in adults and children age 2 months or more.

PROGNOSIS

Earlier onset – more rapid decline.

Other Forms of LMN degeneration

**Poliomyelitis** – viral disease of LMN – see p. 259 (1) >>

- do not map to 5q11.
- most are *autosomal recessive*.

**Fazio-Londe disease (progressive bulbar palsy of childhood)** - **brainstem** LMN degeneration of all brainstem nuclei (vs. most juvenile SMAs).

- presents in late childhood or adolescence with stridor → ptosis, dysarthria, facial palsy, dysphagia.
- weakness of arms & legs may occur later, and respiration may be affected.
- death in early childhood?

**Scapuloperoneal and facioscapulohumeral SMA forms**

- distinction from *muscular dystrophy* depends on **DNA analysis**.

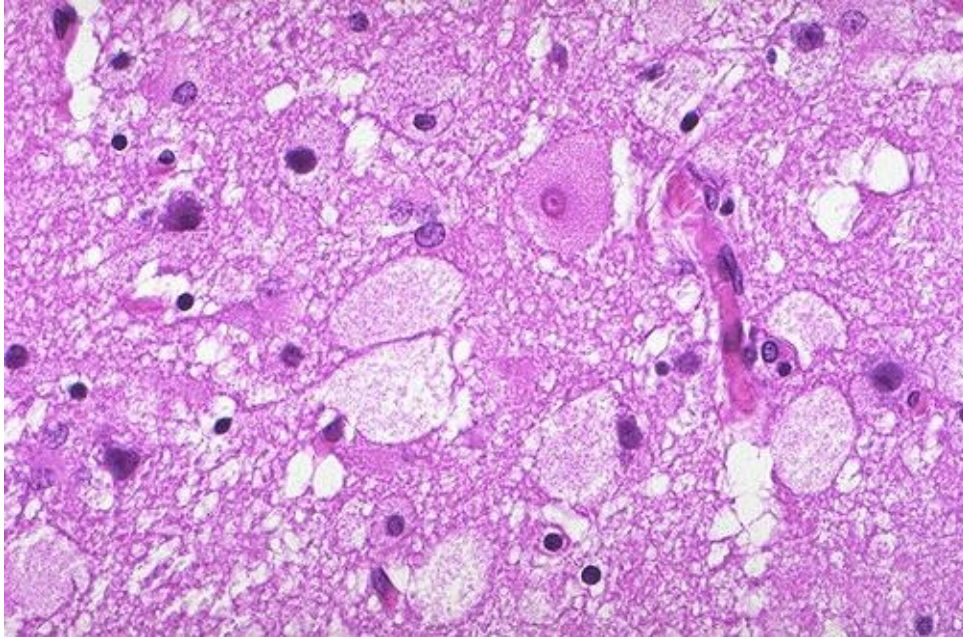
**Kennedy's disease** - X-linked recessive disorder (**expansion of CAG trinucleotide repeats** in first exon of **androgen receptor gene** Xq11-12) - affects males:

- 1) **progressive bulbospinal muscular atrophy** (preferentially **bulbar\*** → **distal** limb muscles) \*incl. ocular!
  - 2) **endocrine dysfunction** – androgen insensitivity (testicular atrophy, gynecomastia, oligospermia), diabetes mellitus.
  - 3) subtle **sensory sign** in some patients. (e.g. abnormal sensory-evoked potentials, affected spinal sensory tracts, distal degeneration of sensory axons).
- midlife onset, after age 40 yrs. (direct correlation between number of -CAG- repeats and disease severity).
  - most common form of adult-onset SMA!
  - may be readily screened from blood **DNA analysis**.
  - slowly progressive, normal lifespan.

**Adult Tay-Sachs disease** (hexosaminidase A deficiency)

- primarily in Ashkenazi Jewish families.
- adult-onset (vs. classical Tay-Sachs disease), very slowly progressive.
- dysarthria and cerebellar atrophy.

Baby with Tay-Sachs disease - enlarged, pale neurons:



Source of picture: "WebPath - The Internet Pathology Laboratory for Medical Education" (by Edward C. Klatt, MD) >>

BIBLIOGRAPHY for ch. "Spinal Disorders" → follow this [LINK](#) >>