

MANAGEMENT OF ACOUSTIC NEUROMA

Mr Nigel Mendoza

Consultant Neurosurgeon

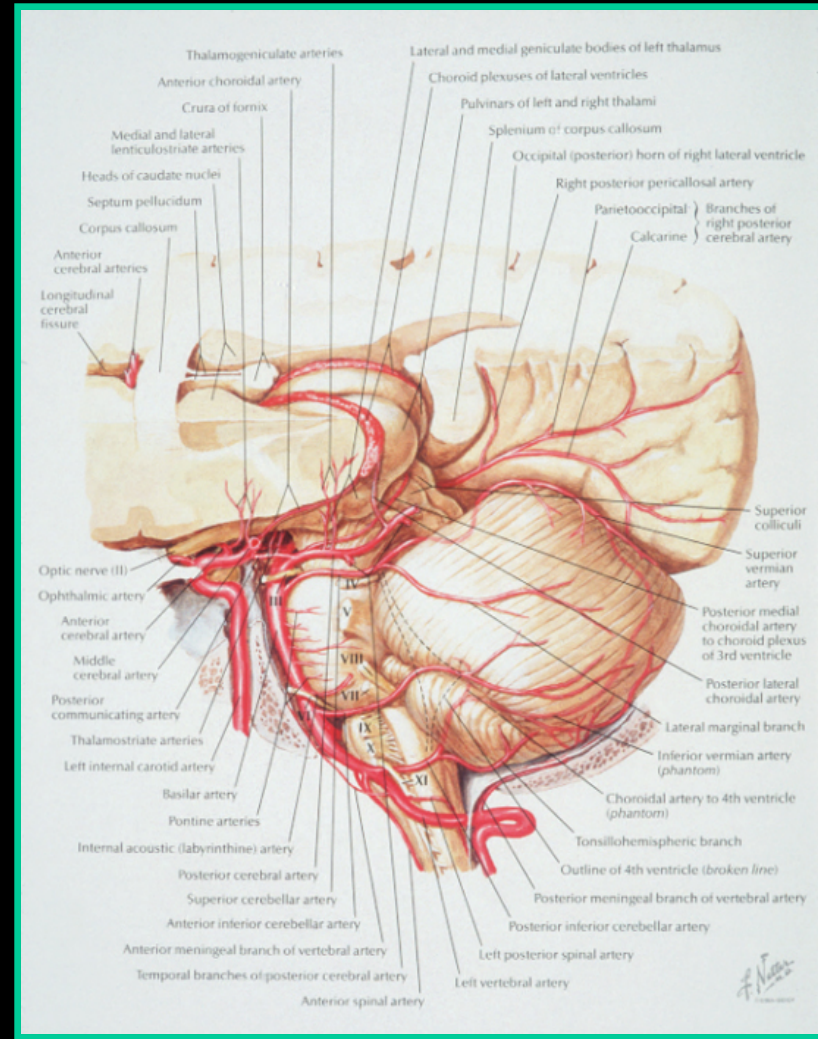
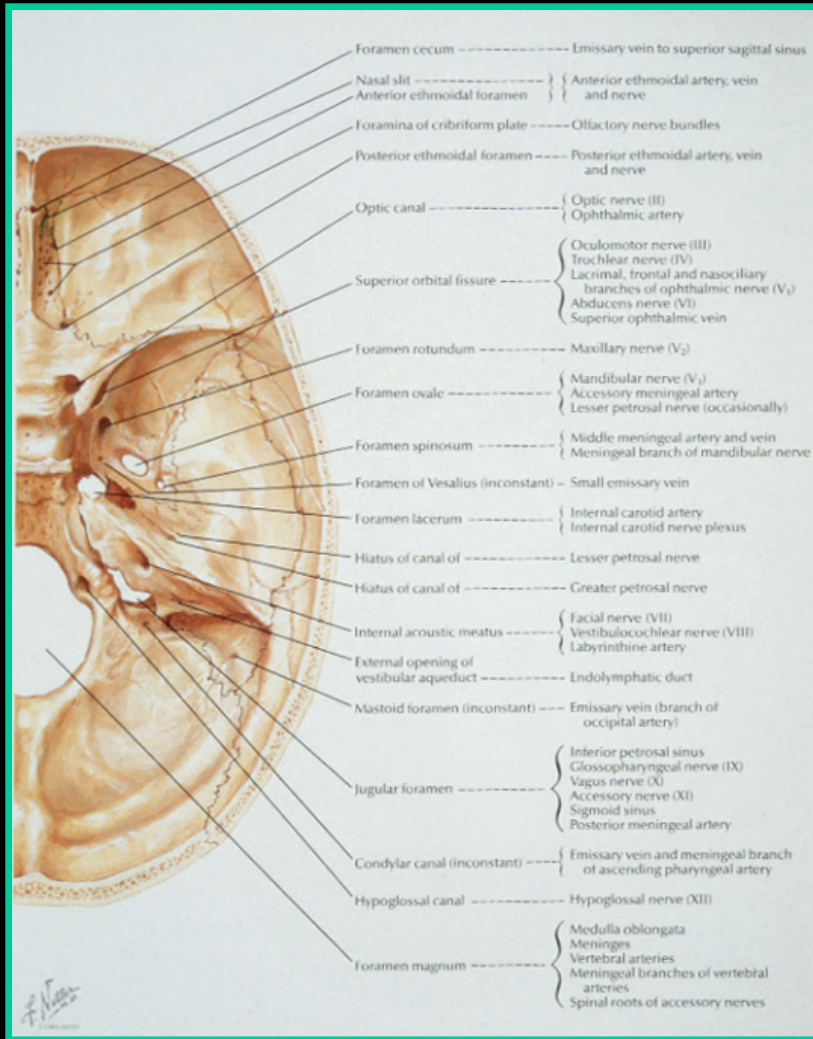
West London Neurosciences Centre

Charing Cross Hospital

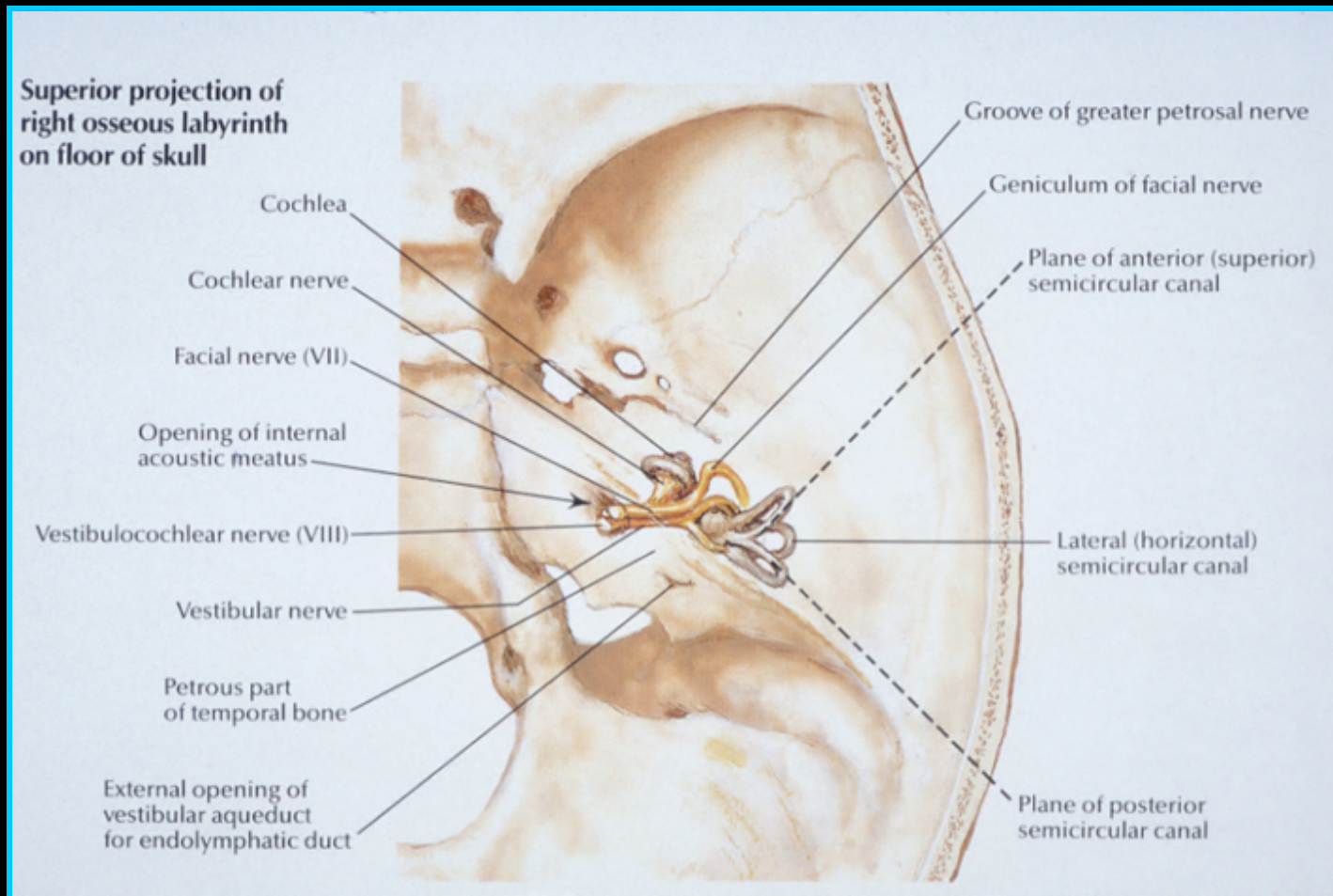
Acoustic Neuroma Vestibular Schwannoma

- Benign tumour that arises from the Superior Vestibular nerve ,part of the eight cranial nerve : the Vestibular cochlear nerve

Anatomy : Skull Base



Vestibulocohlear nerve



'The Bloody Angle'

Harvey Cushing

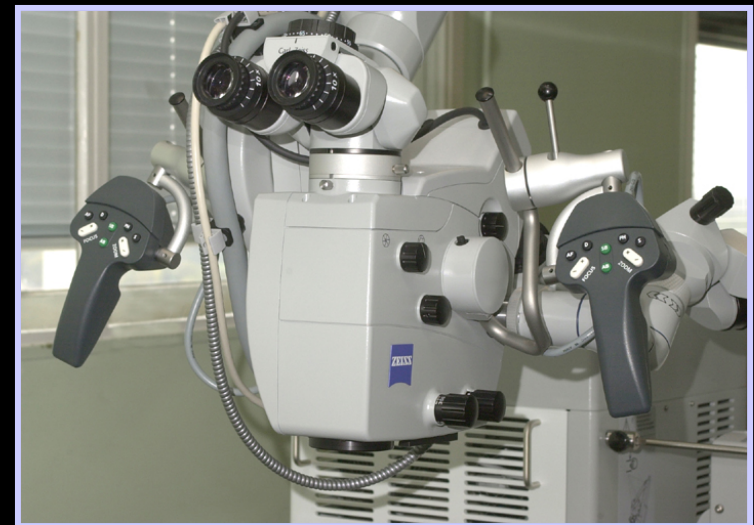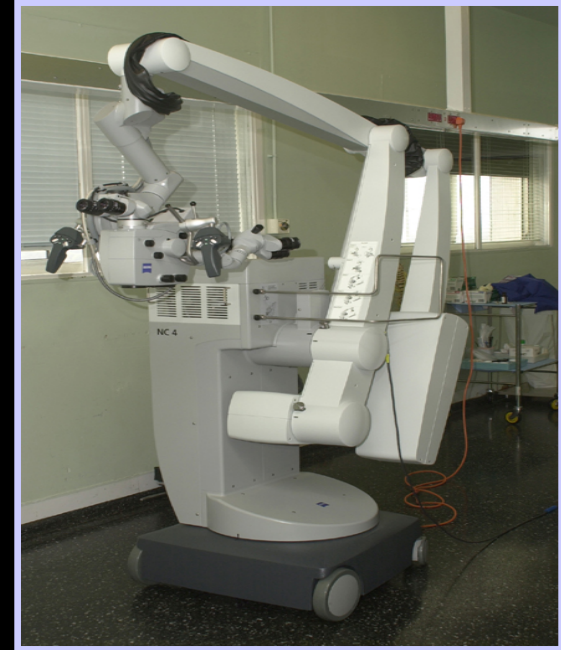- 2500 BC Archeological evidence in Austria of a child's temporal bone
- 1777 Sandifort : Post mortem description of A.N.
- 1810 Lasource : Case report of antemortem Sx in France
- 1830 Bell : Case report of antemortem Sx in England
- 1895 Annandale : 'a brilliant surgical result'
(Charles Ballances' case was probably a meningioma)
- 1904 Krause : 84% Mortality
- 1904 Panse : Translabyrinthine approach
- 1917 Cushing : Neurosurgical techniques : intracapsular debulking reducing mortality from 35 – 10%

Historical perspectives


- 1925 Dandy : Total excision
- 1950 Pennybacker and Cairns : 20% mortality
- 1950 Northfield : 38% mortality
- 1961 House : Facial nerve preservation,
combined neuro- and otological teams
- 1970's Leksell : Stereotactic radiosurgery
- 1990's MRI Detection of A.N.of 2 mm diam
- 2000 Samii : Mortality 1%

Advances

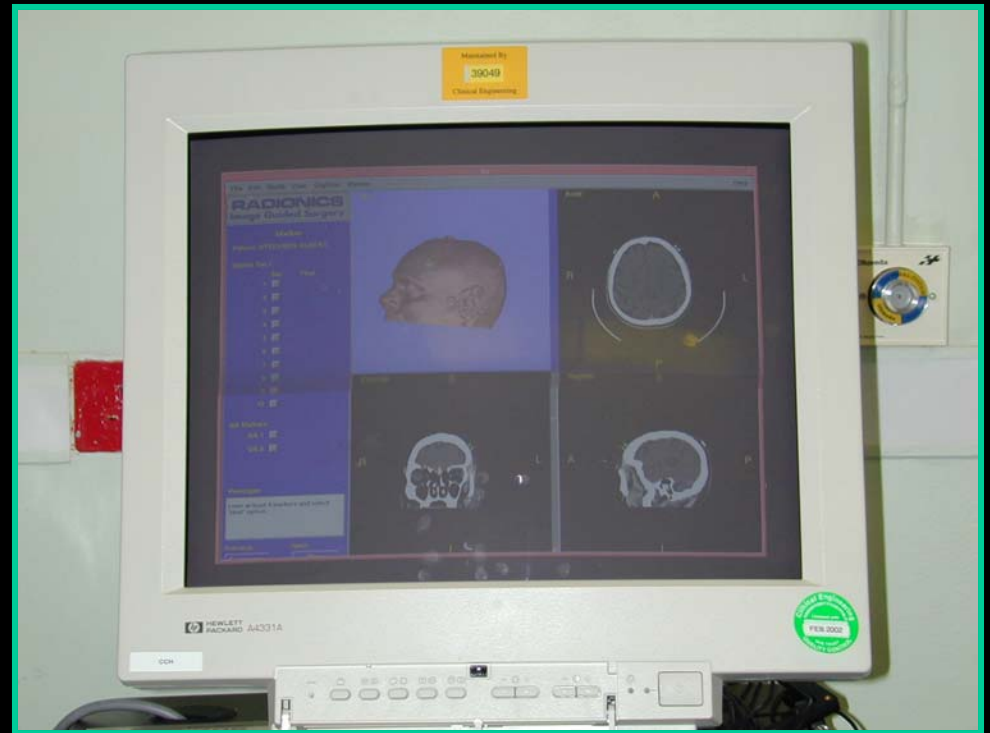
- General anaesthesia
- Monitoring
 - BP, ECG
 - Cranial nerve monitoring
- Diathermy
- Microscope
- Microneurosurgical instruments
 - Ultrasonic aspirator
- Combined procedures
- Radiosurgery
- Imaging :MRI
 - Allows identification of small tumours
 - Intra – operative neuronavigation
 - Intra – operative MRI



Facial Nerve Monitor



Neuronavigation



Epidemiology of Acoustic Neuroma

- Incidence (number of newly diagnosed cases / year) : **13 cases/million/year**

Moffat et al. J. Laryngol Otol 1989 : 109 ; 51 - 59. Davis A. Proc. Acoustic Neuroma meeting 1995

- Prevalance :
 - *Leonard and Talbot 1970 - autopsy study* : About 0.8% (8000 / 1,000,000)
 - *Anderson et al 2000* : MRI study found an incidental 7 AN / 10,000 MRI studies
 - equivalent to 700 cases / 1,000,000 population
i.e large number asymptomatic / undiagnosed
- Number of patients attending ENT clinic with unilateral hearing loss due to AN : 3 - 7.5%

Ferguson et al 1996, Hollingworth et al 1998

Clinical Presentation

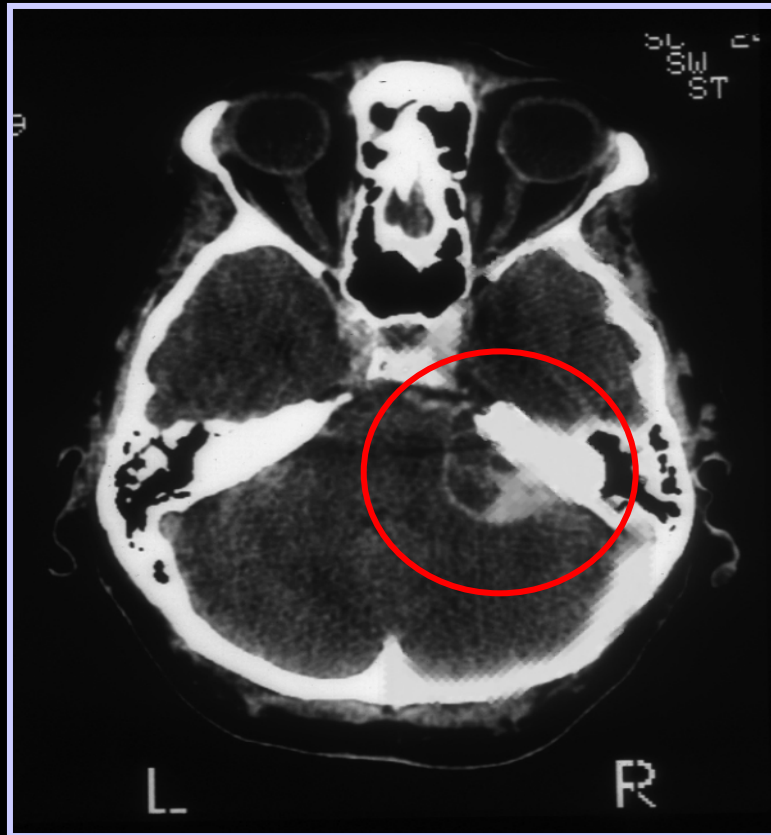
- Hearing loss : 90%
 - usually progressive , 5% sudden onset
 - 3% have normal hearing
- Tinnitus : 70%
- Vestibular dysfunction :59%
- Facial paresis : 17%
- Trigeminal neuropathy :19%
- Headache : 32%

Investigations

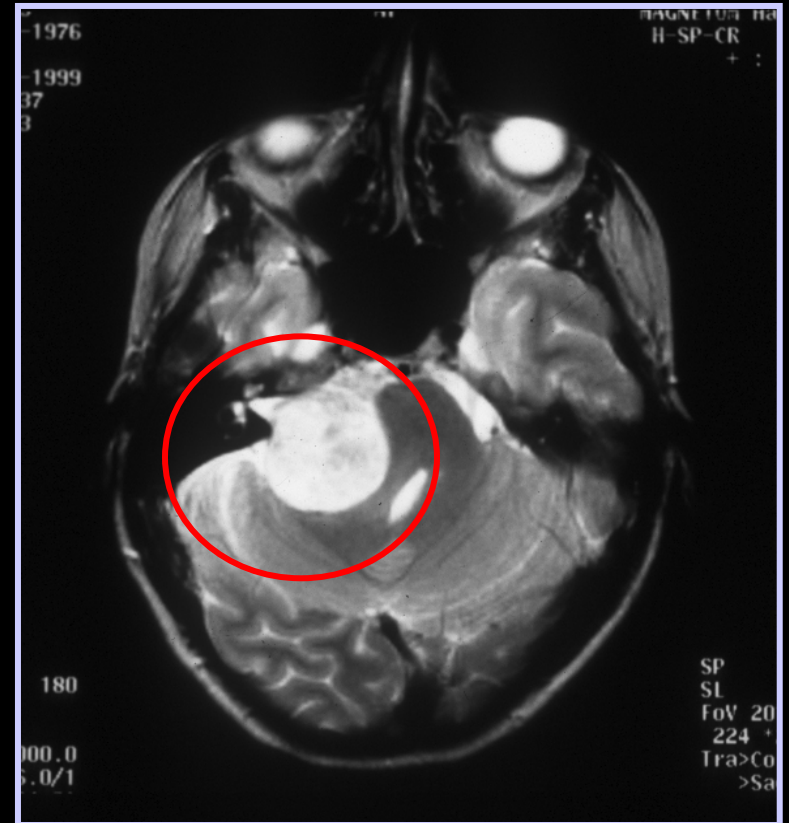- **Audiology**
 - Pure tone threshold and pure tone average (PTA)
 - Speech discrimination score
 - Brain stem evoked auditory potentials
- **MRI** (any patient with unilateral sensori-neural hearing loss should have MRI)
- **CT Bone windows**
 - Position of jugular bulb

Imaging

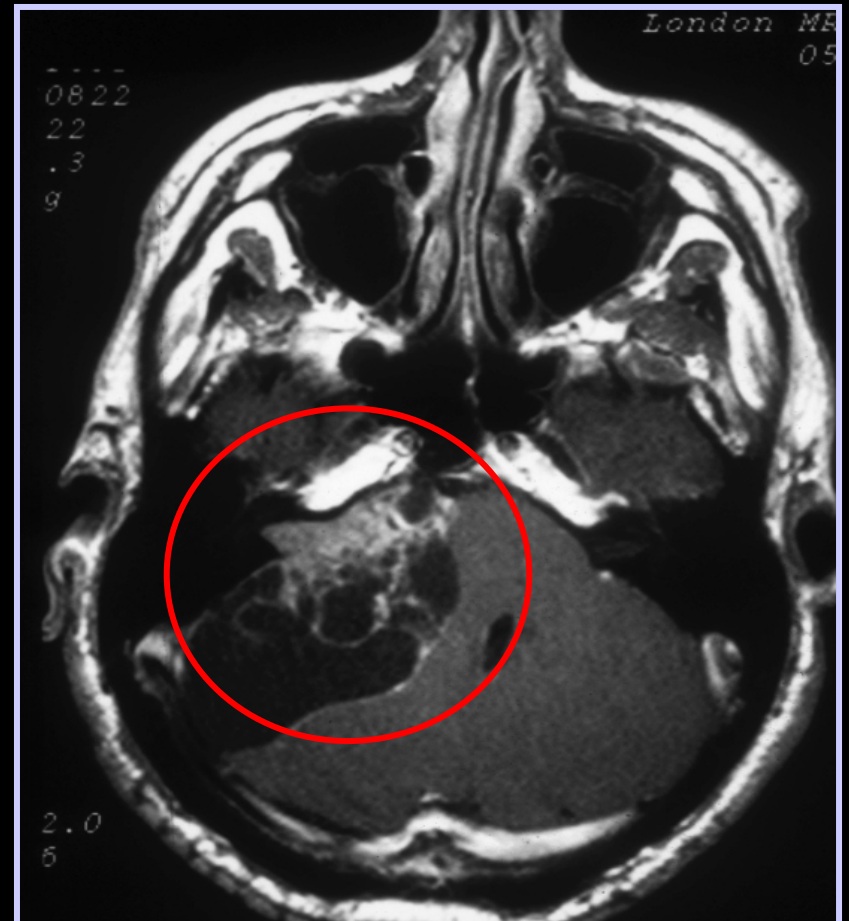
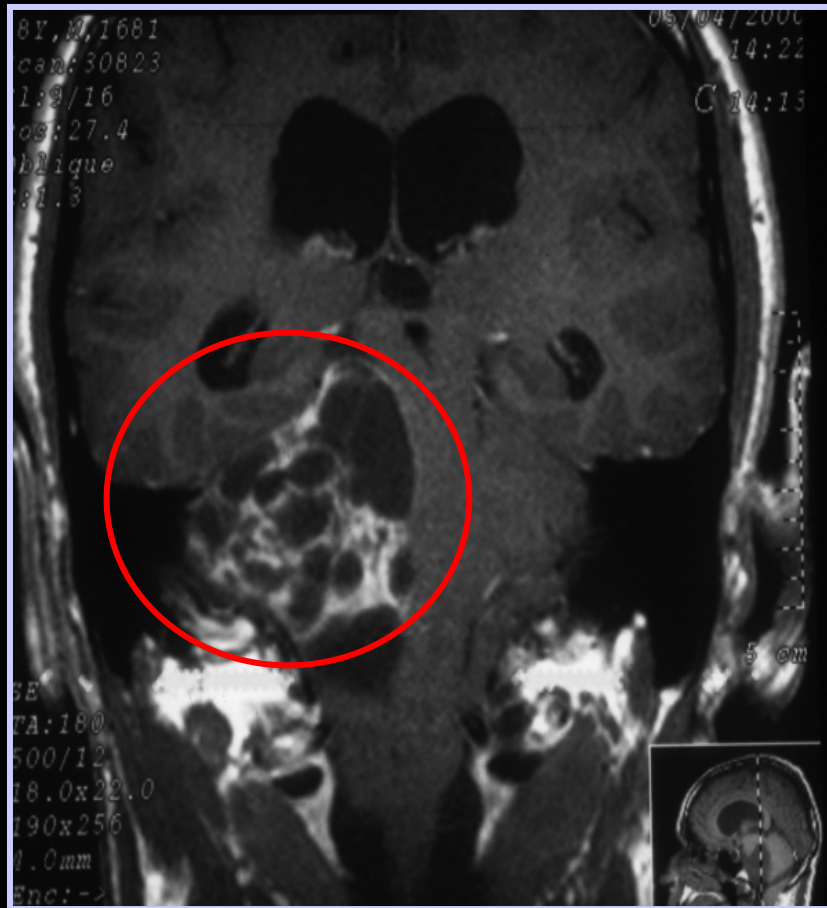
CT



MRI



Cystic acoustic neuroma



Current issues and controversies

- Management of small incidental tumours
- Prediction of tumour growth
- Hearing preservation surgery
- Role of Stereotactic radiosurgery

Management Options : Acoustic Neuroma

- Conservative management
 - Surveillance imaging
 - ? How frequent
- Microneurosurgical resection
 - Total resection
 - Subtotal resection
- Radiotherapy
 - Stereotactic radiosurgery
 - Fractionated external beam radiotherapy
- Combined modality intervention

Levels of Evidence

Level	Type of evidence
1a	Meta-analysis of randomised controlled trials
1b	At least one randomised controlled trial
2a	At least one non randomised controlled trial
2b	At least one type of quasi-experimental trial
3	Non - experimental descriptive study, such as comparative, correlation and case-control studies
4	Expert committee reports/opinions and / or clinical experience of respected authorities

US Agency for Health Care Policy and Research

Acoustic neuroma management : an evidence - based approach

Nikolopoulos T, O'Donoghue GM. Otol Neurotol 2002 ; 23 : 534 - 541

- English language literature search over past 23 years for papers relating to outcome and AN management
- Papers assessed for levels of evidence (Levels 1 - 4)
- 111 papers identified
 - 70.3% related to surgery
 - 18% to radiosurgery
 - 8.1% to imaging surveillance
 - 3.6% compared different management strategies
- Results
 - 85.6% : Type 3 evidence
 - 5.4% : Type 4 evidence
 - No study type 1 - 2

'Well designed randomised comparative studies required to determine optimum management modality and outcomes'

NATURAL HISTORY

Incidence and growth pattern of vestibular schwannomas in a Danish county, 1977 - 1988

Mirz F, Pedersen, Fitzgerald B, Lundorf E. Acta Otolaryngol 2000; 543 : 30 - 33

- Over 21 years 162 Acoustic neuromas diagnosed in county of Aarhus
- Incidence increased over the years related to access to CT / MRI
- 98 patients underwent surgery
- 64 patients pursued Conservative Mx and surveillance imaging
 - 6 patients : surgical excision because increase in size
 - 14 patients (22%) regressed
 - 35 patients (55%) did not grow / marginal growth (< 1mm / yr)
 - 15 patients (23 %) increased in size : growth rate > 1mm / yr

The natural history of untreated vestibular schwannomas. Is there a role for conservative management?

Walsh RM, Bath A, Bance M, Keller A, Tator C, Rutka J. *Rev Laryngol Otol* 2000 ;121:21 - 26

- 72 Patients managed Cx because poor health, age, pt choice, tumour size, tumour in hearing ear
- Follow up : 37.8 months (12 - 194 months)
- Mean tumour growth rate : 1.16mm / year (0.75 to 9.65mm / year)
- 83% of tumours grew at < 2mm / year
 - 36.4% : > 1mm / year
 - 50% : 0 - 1mm /year
 - 13% : regressed
- Growth rate CPA (1.4mm/year) : IAC (0.2mm/year) $p = 0.001$
- 15% underwent treatment : Growth rate in failed Cx Mx : 4.2mm/year (Cx Mx : 0.55mm / yr)
 - No difference in outcome of patient undergoing non Cx Mx
- No predictive factors for growth identified
- Deterioration in PTA and speech discrimination occurred regardless of whether radiological growth was demonstrated or not

Conservative Management of Acoustic Neuroma :An Outcome Study

Dean et al. Neurosurgery 1996. 39 : 39; 260 - 266

- 68 patients, mean age 67.1years, mean f/u 3.4 years
- Conservative Management
 - ‘advanced’ age 55%, pt choice 21%, asymptomatic 13%, severe co-morbidity 7%, tumour in only hearing ear 4%
- Results
 - 85% (58pt) Cx Mx
 - 15% (10pt) Rt : 9 Surgical, 1 Gamma knife : Mean time interval from diagnosis to treatment : 4 years
- Growth Rate
 - 71% No growth
 - 29% Increase in size :
 - Tumour growth rate at one year significantly higher in group with surgery : 3.00mm / 0.36mm $p < 0.0001$
 - *‘ Growth rate at 1 year follow up was a strong predictor for eventual need for treatment’*

Conservative management : Indications

- Small tumours on only hearing ear
- ‘Elderly’ patients with longstanding, stable Sx
- Incidental asymptomatic finding
- Patients who refuse treatment

SURGICAL TREATMENT

Surgical Aims

- No mortality
- Complete tumour excision
 - No recurrence
- Preservation of facial nerve function
- Preservation of hearing
- No neurological morbidity
 - CN 5,6,7,9,10
- No operative morbidity

Surgical management

Aims and indications

- **Small tumours** (<1.5cm)
 - Preserve hearing
 - Facial nerve preservation
 - Prevent future growth
- **Medium** (1.5 – 3.5 cm) / **Large tumours** (> 3.5 cm)
 - Symptomatic : Brain stem compression
 - Enlarging on serial MRI
 - Recurrence after previous treatment
 - Patient preference

Surgical Approaches

- Retrosigmoid Transmeatal
- Translabyrinthine
- Middle Fossa
- Stereotactic Radiosurgery
 - Gamma knife
 - Linear accelerator

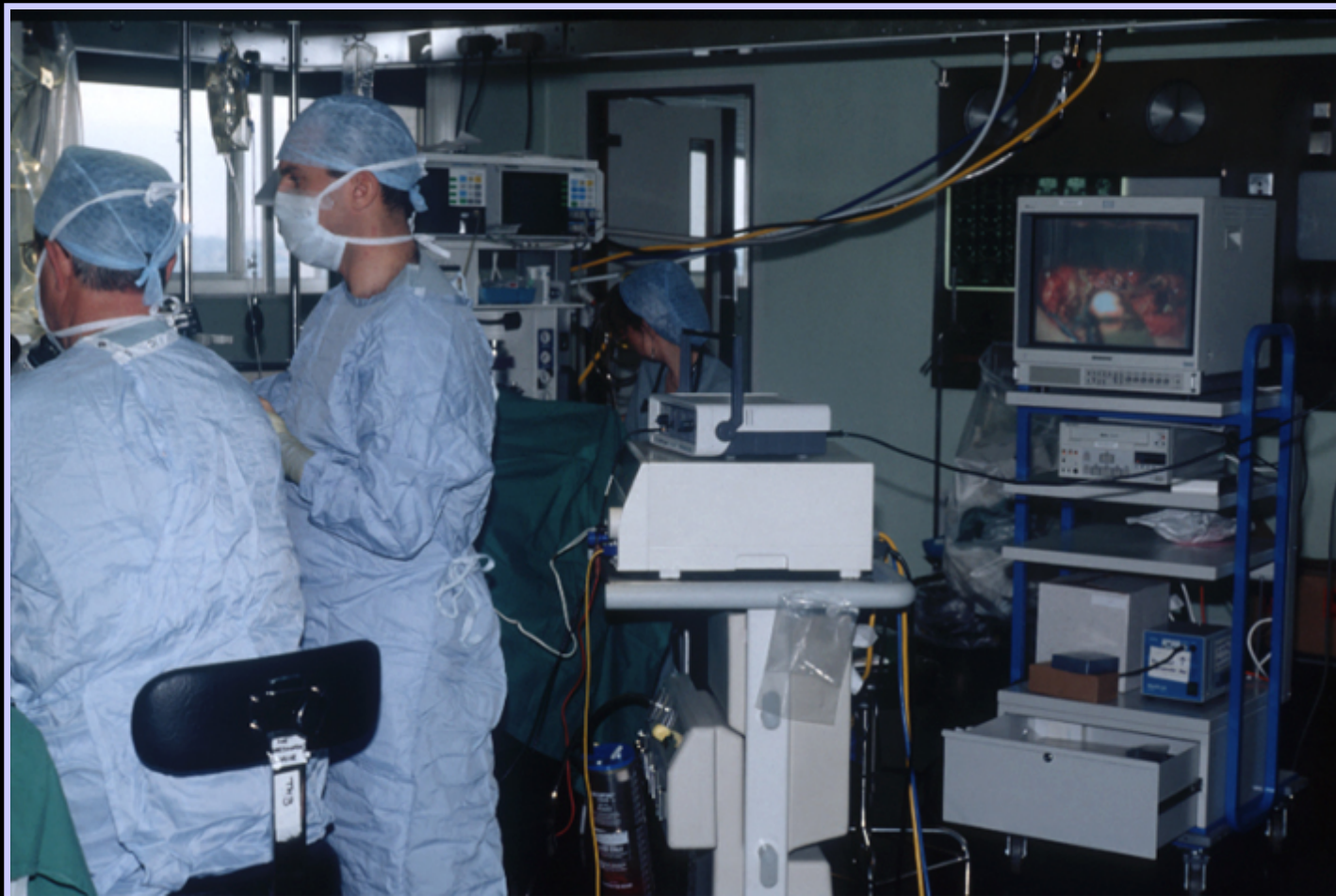
Retrosigmoid transmeatal approach

- Advantages
 - Versatile
 - All tumours
 - Hearing preservation
- Disadvantages
 - Intracranial procedure
 - Cerebellar retraction

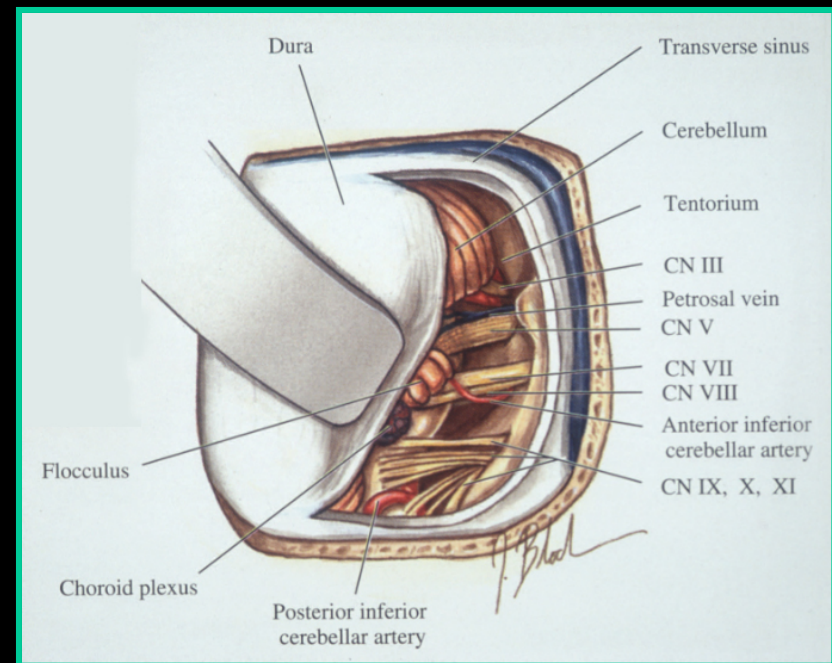
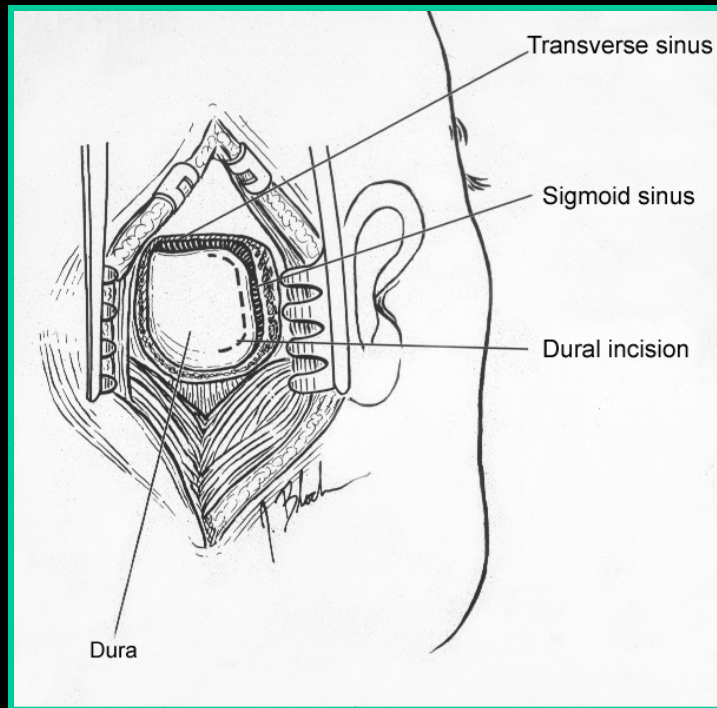
Retrosigmoid Transmeatal Approach

- Position
 - Park bench : attention to pressure areas
 - Semisitting (Risk of air emboli)
 - Supine
 - Prone
- Facial nerve monitoring
 - 2 channel, 3 – 30 Hz continuous monitoring
- Lumbar drainage / EVD
- Brain stem evoked auditory potentials
- Antibiotic and steroid cover

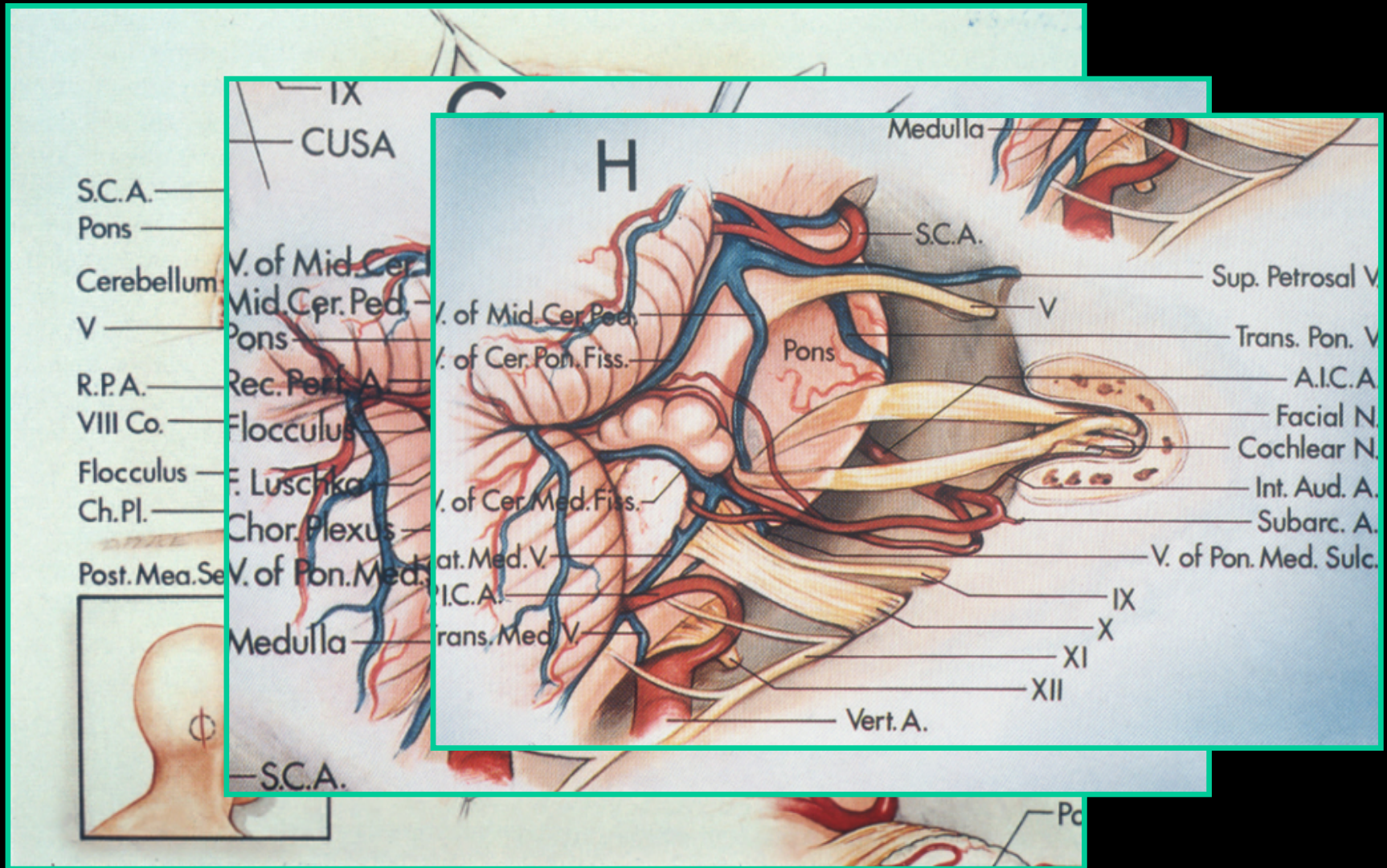
Theatre setup



Retrosigmoid Transmeatal Approach

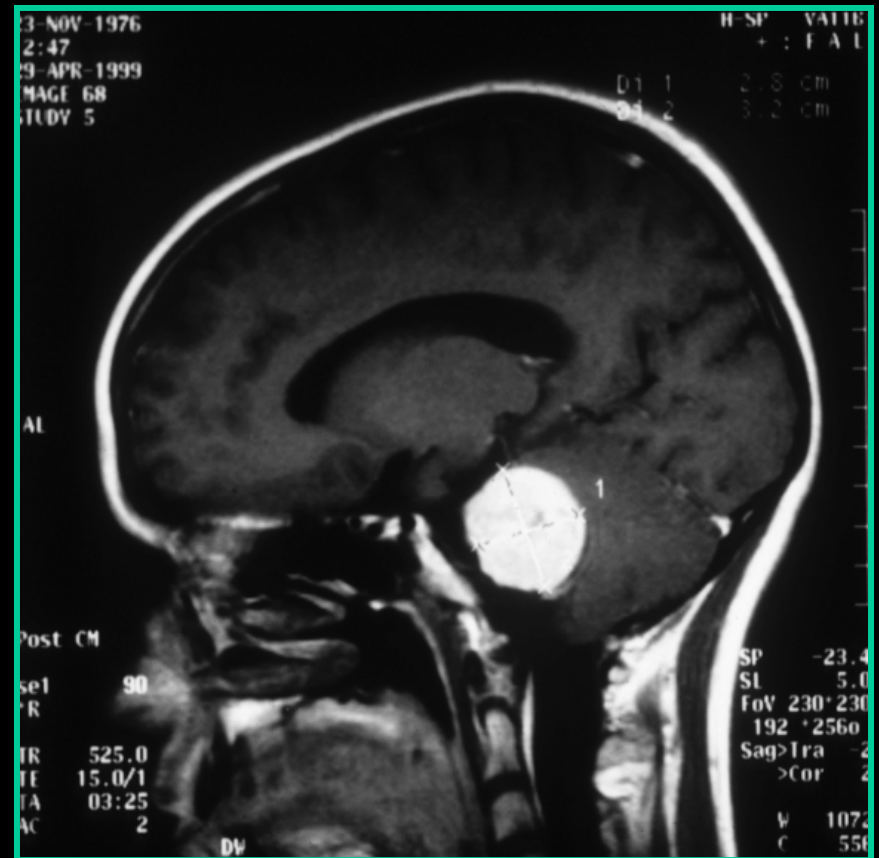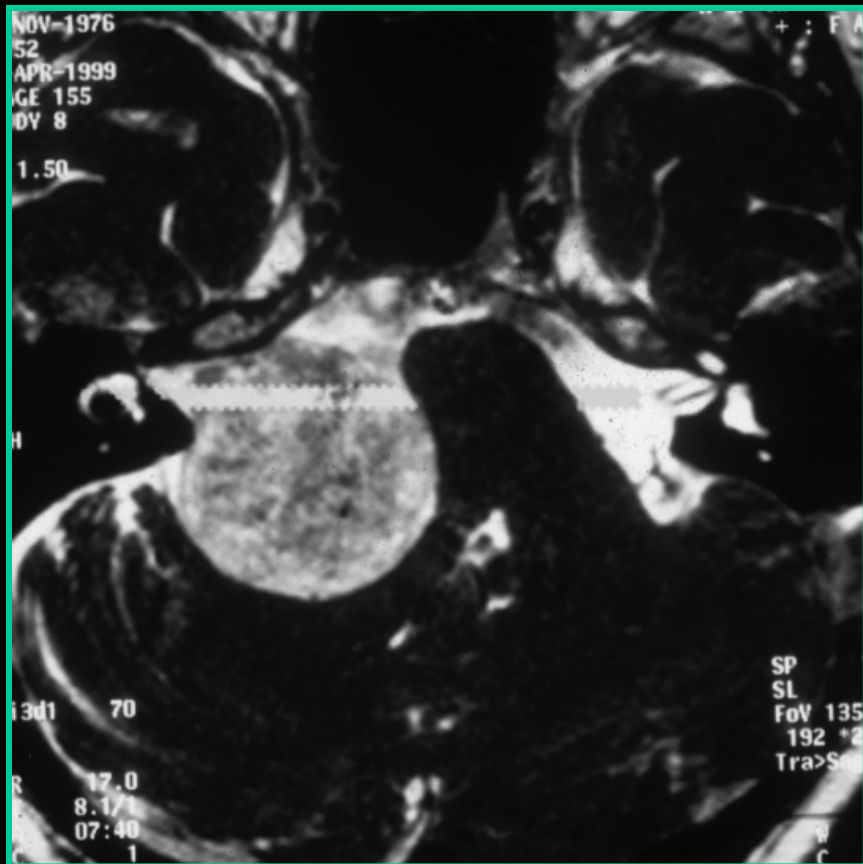


Retrosigmoid Transmeatal Approach



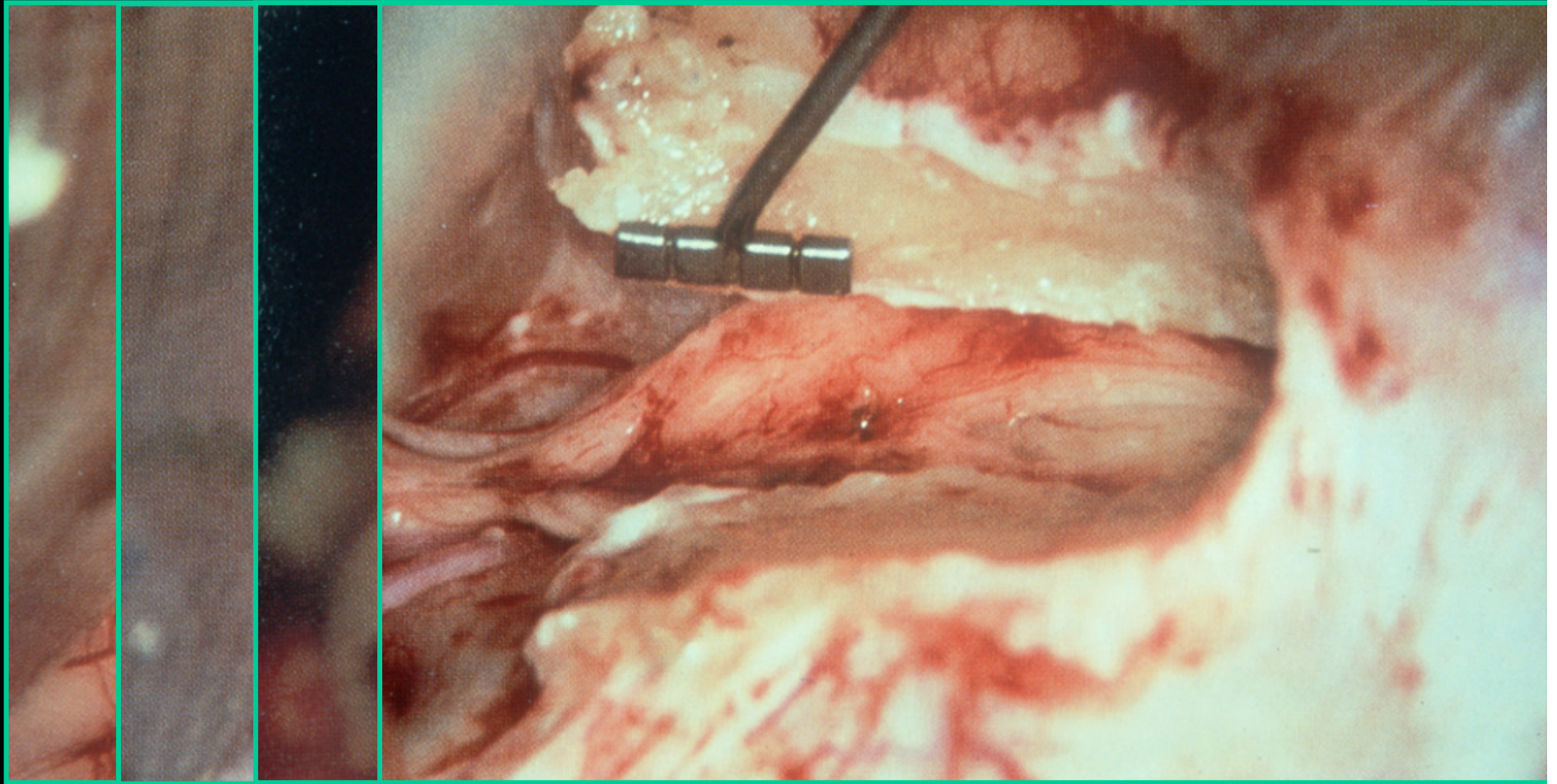
Large Acoustic Neuroma : preop MRI

22 yr female 3/12 post delivery

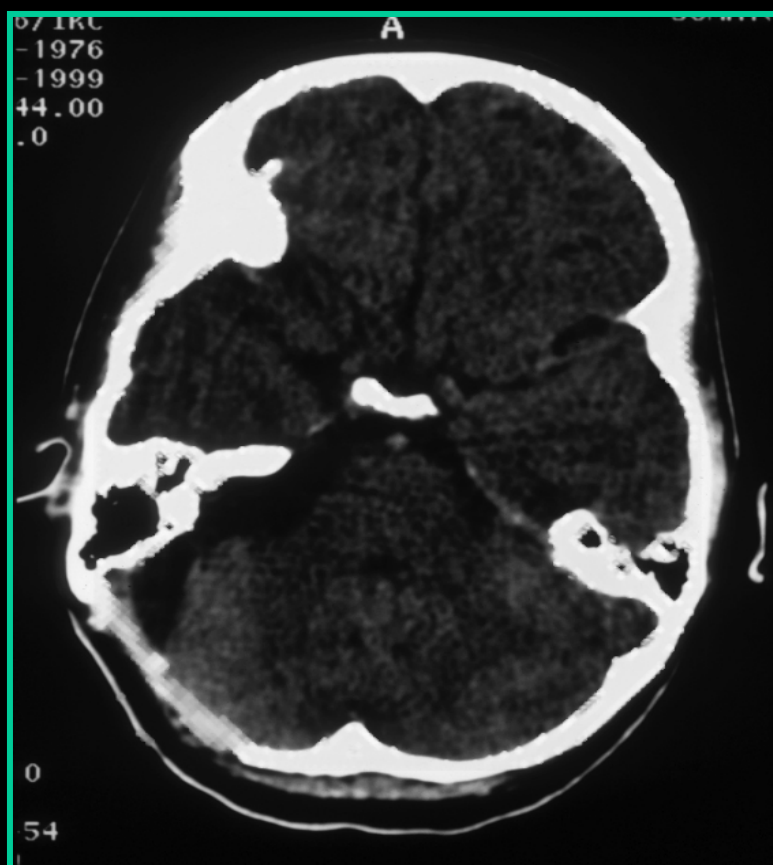

Acoustic neuroma : Intraoperative exposure

Tumour debulking
Meatal dissection



Large Acoustic Neuroma : post op CT scan



Acoustic Neuromas : Results of Current Surgical Management

*Gormley W. Sekhar L et al. Neurosurgery 1997;41;50 - 60
Pittsburgh, Pennsylvania*

- 179 Patients
 - 84% Retromastoid
 - 4% Translabyrinthine
 - Small tumours < 2cm, Medium 2-3.9 cm, Large > 4cm
- Mean f/u 70 months, median 65 months (3 - 171 months)
- Complete excision 99%
 - No evidence of recurrence
- Facial Nerve Function
 - Grade 1-2 House and Brackmann
 - Small tumours : 96%, Medium : 74%, Large 38%
 - Grade 3 - 4 House and Brackmann
 - Small tumours : 4%, Medium : 26 %, Large 58%

Acoustic Neuromas : Results of Current Surgical Management

*Gormley W. Sekhar L et al. Neurosurgery 1997;41;50 - 60
Pittsburgh, Pennsylvania*

- Hearing preservation
 - Gardner - Robertson 1 - 2
 - Small tumours : 48%
 - Medium : 25%
 - Large : 0%
- Complications
 - CSF Leak : 15%
 - 2% re - explored
 - Death : 1% (2 patients)
 - Severe neurological disability: 1 pt
- Conclusion
 - ‘microsurgery by an experienced team of surgeons is preferred over radiosurgery’*

Management of 1000 Vestibular schwannomas: Surgical Management and results with an emphasis on complications and how to avoid them.

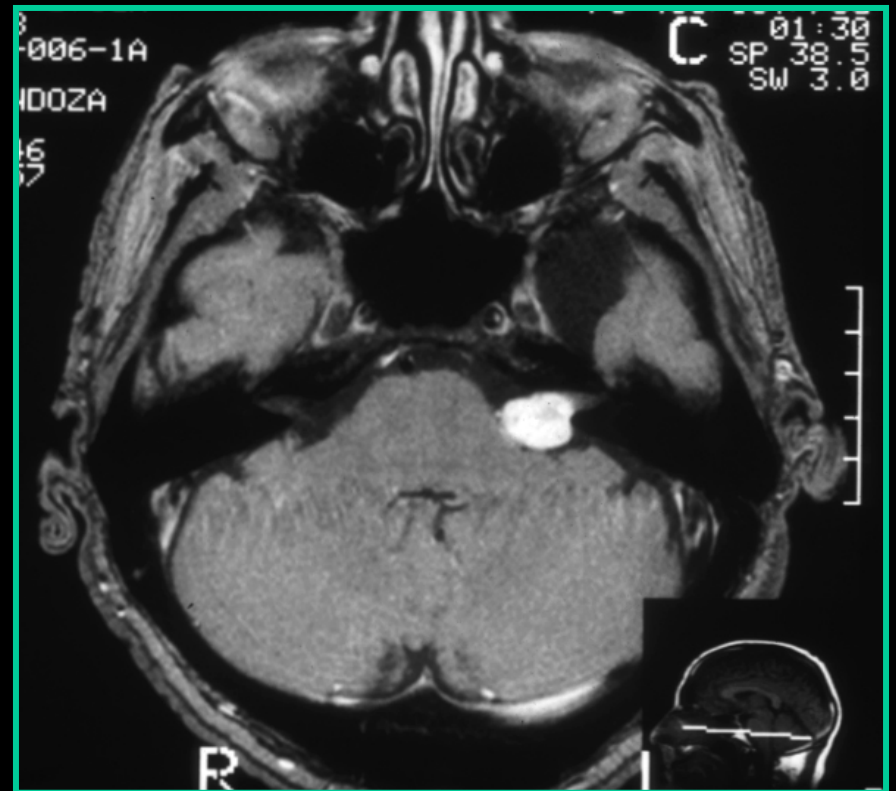
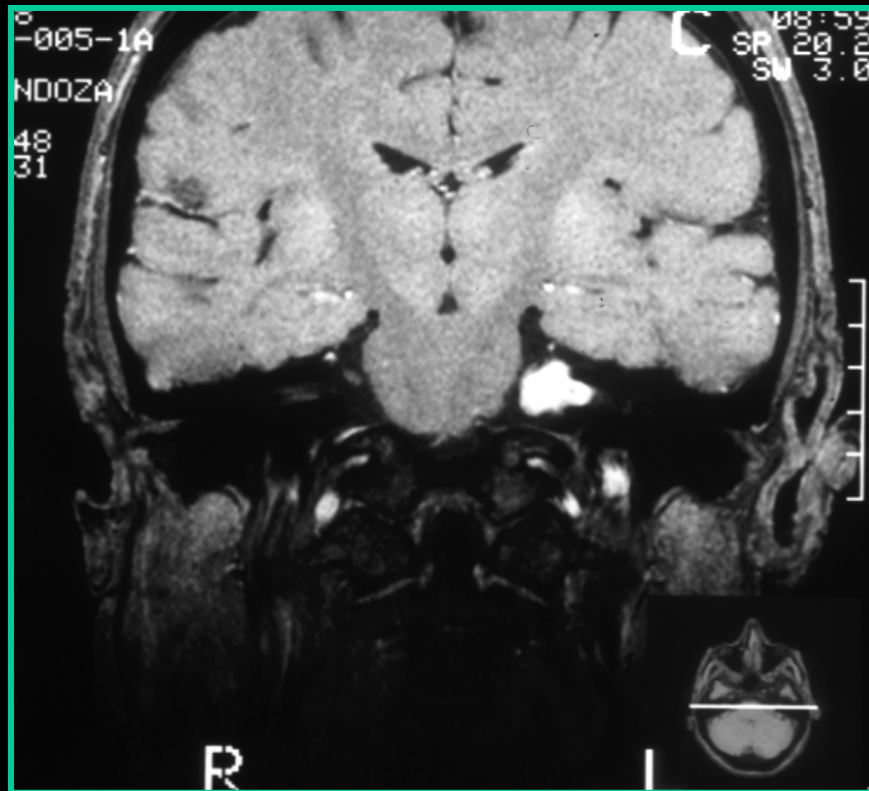
Samii M, Matthies C. Neurosurgery 1997;40 ; 11 - 23

- 962 patients (1000 VS) between 1978 - 1993
- Suboccipital transmeatal approach
 - 979 tumours : complete excision
 - 21 patients underwent subtotal excision
- Anatomical CN preservation
 - Facial nerve : 93%
 - Cochlear nerve : 68%
- Complications
 - Death : 1.1% (11 patients)
 - Haematoma : 2.2%
 - CSF leak : 9.2%
 - Lower CN palsy : 5.5%
 - Hydrocephalus : 2.3%
 - Meningitis : 1.2%
- Risk factors
 - Medical comorbidity
 - Neurological comorbidity
 - Brain stem compression
 - Lower CN palsy
 - Cystic tumour

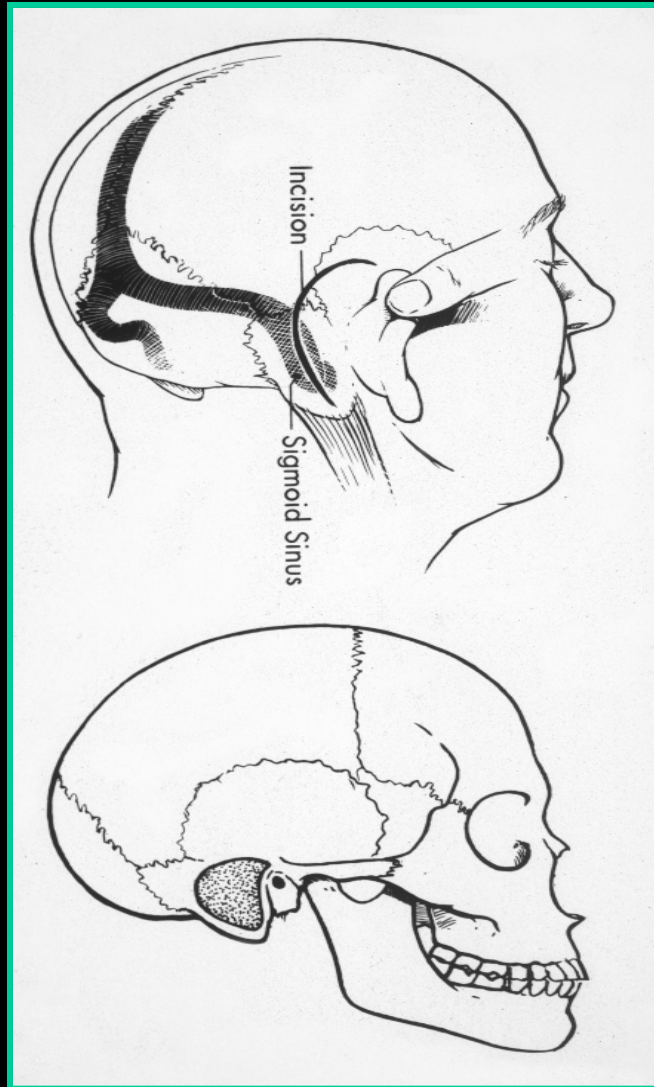
Translabyrinthine approach

- Advantages
 - Consistent anatomy
 - CN 7, 8 Sigmoid and Sup. petrosal sinus, Carotid artery and Jugular bulb
 - Avoids Cerebellar retraction
 - Direct and short route to I.A.C. and C.P.A
- Disadvantages
 - Destruction of Labyrinth
 - Hearing and Balance loss
 - Limited access to medial side of large tumours
 - CSF fistula

Small Acoustic Neuroma

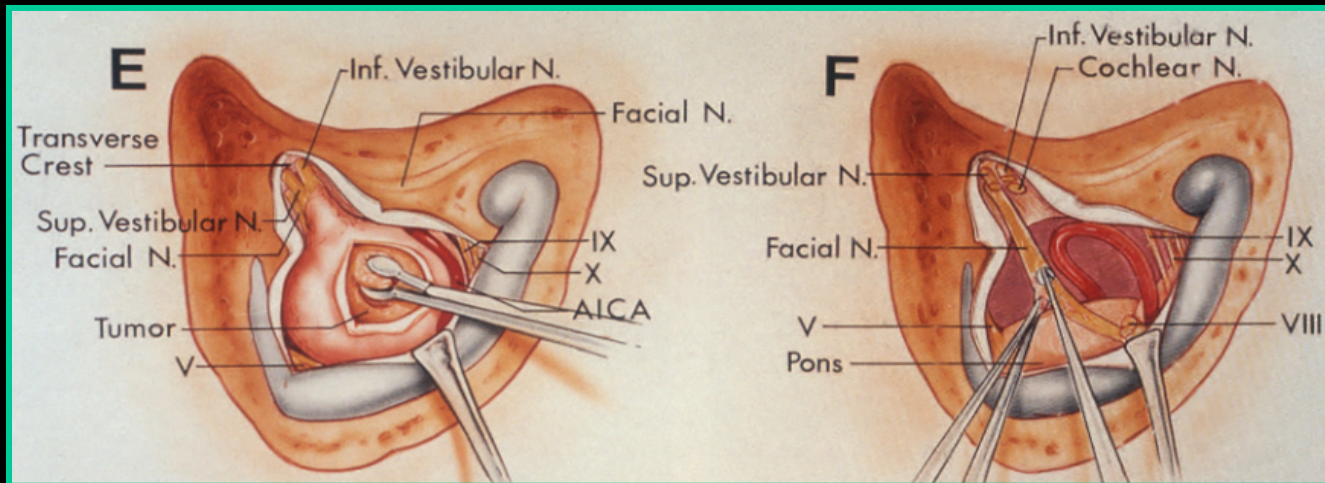
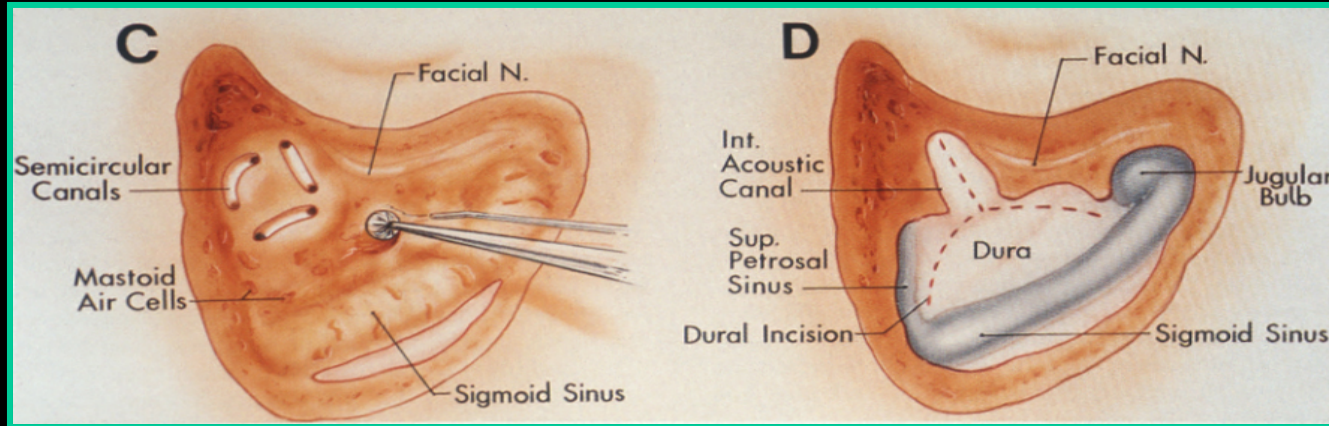


Translabyrinthine approach



- Mastoidectomy
 - Expose
 - Lateral : Sigmoid sinus
 - Superior : Middle fossa dura
 - Anterior : Facial nerve in facial canal, anterior and inferior to lateral semicircular canal
- Labyrinthectomy
 - Remove semicircular canals
 - Vestibule opened
 - Remove posterior wall of I.A.C to porous
- Dural opening

Translabyrinthine approach



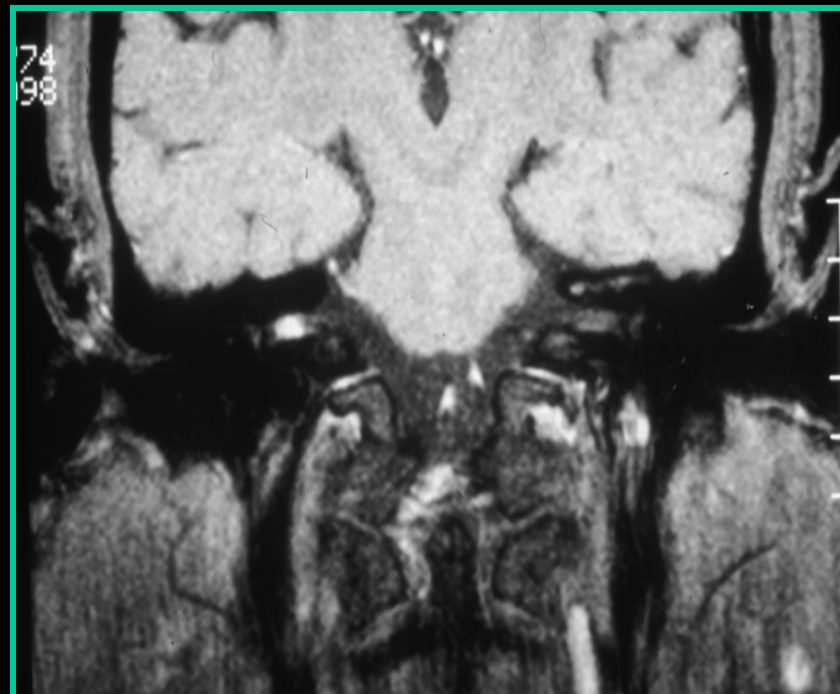
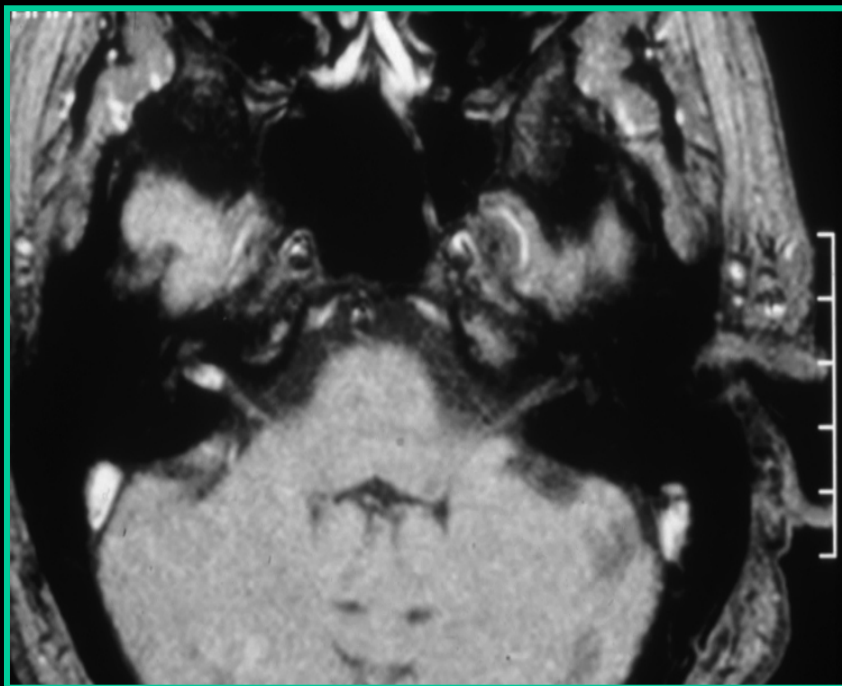
Translabrynthine approach : Results

	Sterkers	Lueje	King
Total excision	91%	93.3%	75%
Mortality	0.1%	2.6%	2.5%
Recurrence	6%		
Facial nerve preservation	89%	96.6%	54%
Good function	65% 45% > 3.0cm		
Paralysis		13%	

Middle fossa approach

- Small intracanalicular tumour with preserved hearing
- Subtemporal extradural approach
 - Described by William House in 1961
 - Exposes lateral end of I.A.C
 - » Early identification of Facial nerve
 - Low Mortality / Morbidity
 - Total tumour removal

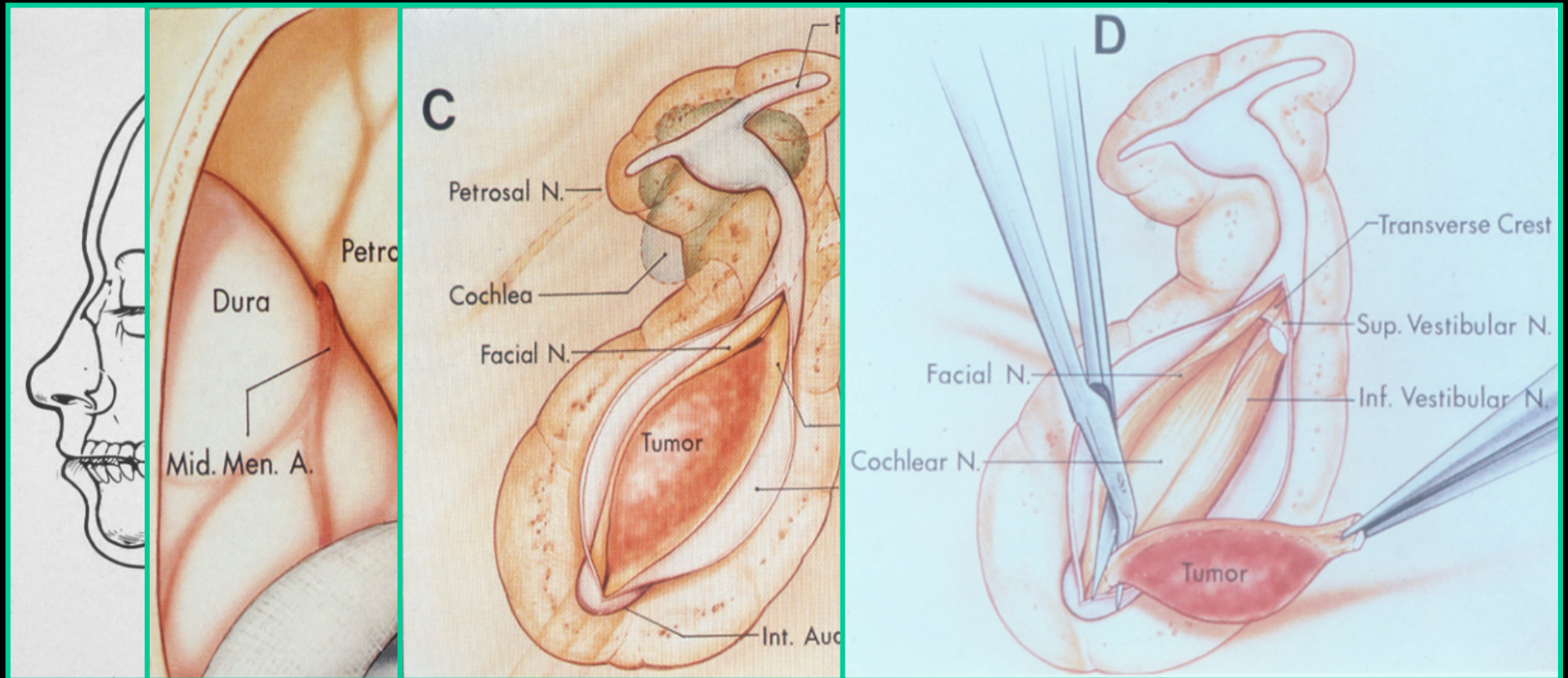
Intracanalicular acoustic neuroma



Middle fossa approach

- Position
 - Supine : head turned to opposite side
 - Lateral
- Incision
 - Straight anterior to tragus
 - Temporal flap : 2/3 ant + 1/3/ post to E.A.M
- Craniotomy
 - Temporal (4 cm diam) to base of middle fossa

Middle fossa approach



Middle fossa approach : Results

- Brackman and House 1991
 - Nos : 106
 - Size : 0.4 – 2.0 cm
 - No deaths
 - Facial nerve preservation : 80 %
 - Hearing preservation : 59 %

Complication rates of surgical treatment for acoustic neuromas

- Death < 1%
- Hemiparesis < 1%
- Ataxia 10 %
- CSF Fistula 9%
- Facial palsy 10% - 50%
- Inability to work 15%
- Poor quality of life > 15%

Postoperative care

- Immediate
 - BP, Pulse, RR, prevent infection, eye care,
 - Feeding
- Post discharge
 - 3/12 op visit
 - 1 yr MRI, 5 yr MRI
 - Facial nerve reconstruction / re - animation
 - manage residual / recurrent tumour


RADIOTHERAPY

Stereotactic Radiosurgery

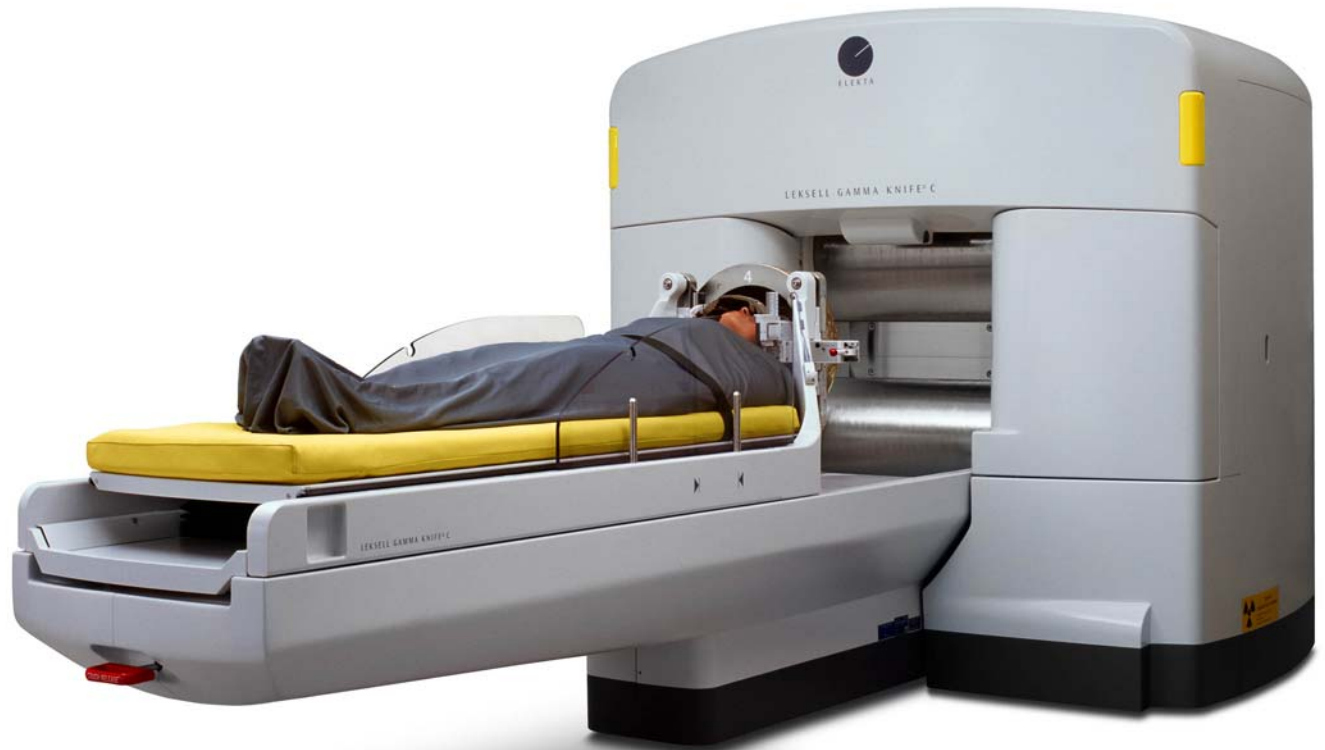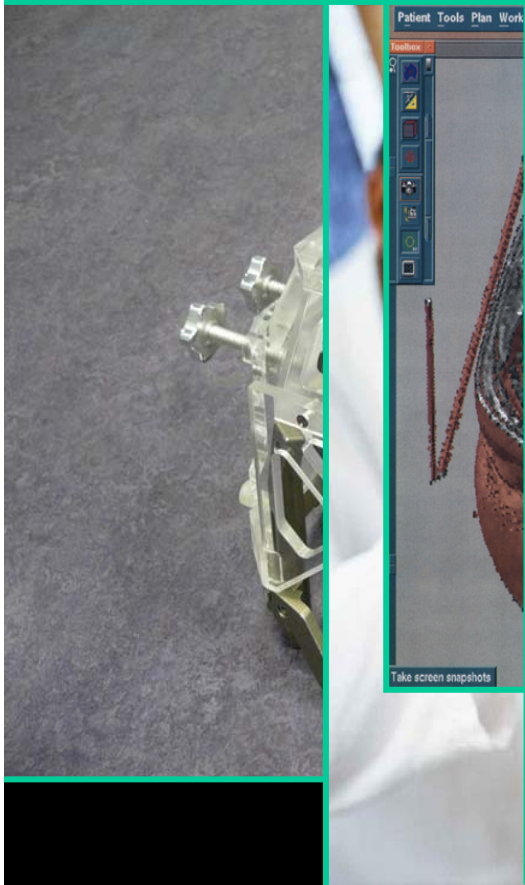volume of tissue from a Cobalt source emitting photon irradiation Stereotactic system that delivers a focused beam of radiotherapy to a target

Developed by Lars Leksell

*‘ the history of surgery is
the history of its tools’*



Stereotactic radiosurgery



Stereotactic radiosurgery : Indications

- Enlarging small / medium tumour in elderly / unfit patient
- Recurrence after subtotal excision
- Patient preference
- Chronic severe medical illness precluding surgery
 - e.g Haemophilia, COAD
- Bilateral tumours in NF 2

Long - term outcomes after radiosurgery for acoustic neuromas

Kondziolka D, Lunsford L, McLaughlin M, Flickinger J. N Engl J Med 1998;339:1426 - 33

- Aim of radiosurgery
 - Long term prevention of tumour growth
 - Maintenance of neurological function, Prevention of new neurological deficit
- 162 patients treated 1987 - 1992
 - Mean dose to tumour margin 16Gy, Mean transverse tumour diameter 22mm (8 - 39)
 - Previous surgery in 42 pt (26%) : 13 pt recurrence after ‘ total’ resection
 - Facial function was normal in 76% preRt, 20% had useful hearing
- Tumour control: 98 %
 - 62% became smaller, 33% ISQ, 6% ‘slightly’ bigger
 - 6 patients (2%) had surgery 4 years post Rt
- Facial function
 - 79% normal at 5 years, Trigeminal nerve function was normal in 73%
- Hearing
 - 51% had no change in hearing
- No new deficits
- Conclusion : *‘radiosurgery can provide long - term control of acoustic neuromas while preserving neurologic function’*

Fractionated stereotactic radiotherapy for acoustic neuromas

Williams J. Acta Neurochir. 2002 : 144 ; 1249 - 1454

- Compared to radiosurgery, FSR offers escalation of dose of tumour dose and potential sparing of auditory and facial function
- 287 patients with AN treated with FSR from 1995 - 2002
- 150 pt f/u > 1 yr
- FRS schedules:
 - AN < 3.0 cm : 25Gy total (5 doses) - 131 pt
 - 3.0 - 3.9 cm : 30 Gy total (10 doses) - 18 pt
 - > 4.0 cm : 40 Gy total (2 doses) - 2 pt
- No tumour increased in size
- No patient developed facial weakness
- 2 pt transient trigeminal sensory disturbance
- Hearing preservation the same for small and large tumours
- Tumour regression : 14 % (25Gy regimen), 15% (30 Gy), 8% (40 Gy)
- *‘FSR may preserve normal function and control both small and large acoustic neuromas’*

Radiosurgery : Results

- Tumour control (No growth) 92 – 98%
- Volume reduction 23 – 55%
- Hearing preservation 30 – 46%
 - Hearing loss related to tumour size
 - No loss if tumour < 1.0cm
- Facial nerve palsy 1.3 – 4.2%
 - Usually transient with 66% improving in 1 year
- Trigeminal neuropathy 4 – 30%
- Hydrocephalus 4%

Functional outcome after gamma knife surgery or microsurgery for vestibular schwannomas

*Regis et al. J. Neurosurg.2002: 97; 1091 - 1100
Marseille, France*

- 500 patients followed prospectively, 104 pt f/u > 4 yrs
- Data used from 97 pt Rt with GKS, 110 pt Rt with MS
- Facial Nerve Function (normal)
 - GKS 100%, MS 63%
- Functional deterioration
 - GKS 91% had no functional deterioration, MS 61% had no functional deterioration
- Mean Hospital Stay
 - GKS : 3 days, MS : 23 days
- Occupation
 - GKS : 99% returned to preRt occupation, MS : 56% returned to preRt occupation
 - GKS : 7/7 away from work, MS : 130/7 away from work
- Hearing preservation
 - GKS : 70 % preserved (Grade 1-2), MS : 37.5% preserved hearing

‘ Functional side effects occur during 1st 2 years afer GKS. Findings after 4 years of follow up indicated that GKS provide better functional outcomes than MS in this patient series’

A Meta-analysis comparing outcomes of microsurgery and gamma knife radiosurgery

Kaylie D. et al. Laryngoscope 2000 : 110 ; 1850 - 1856

- Retrospective MEDLINE search for all studies re GKS and MS from 1990-1998

- Results

- Tumours < 4cm no difference in hearing preservation or facial nerve outcome
- Surgery on all sizes has a significantly lower complication rate than radiosurgery undertaken on tumours small than 4 cm
- Surgery has superior tumour growth control (because resected!)

- Conclusion :

‘Data from these studies dates back to late 1960’s and do not completely reflect outcomes using current imaging and procedures. A major difficulty encountered is inconsistent data reporting. Future surgical and radiation reports should use standardized outcome scales to allow valid comparison. Surgery should remain the therapy of choice for AN until tumour growth rates can be established’

Evidence Base : Conclusions

- A number of neuromas involute or do not exhibit growth.
- Surgery can achieve total tumour removal in about 97% of patients with mortality of 1%
- Facial paralysis is common, and a major cause of disability
- Radiotherapy can 'control' tumour growth in the short term.
- Hearing preservation may be better with radiotherapy
- Lack of class 1 and 2 evidence
- No systematic study compares different modalities of treatment

What does this all mean?

Conclusions

The patient has a choice :

- Small tumours ($<1.5\text{cm}$)
 - Cx Mx, Surgery, Radiosurgery
- Medium tumours ($1.5 - 3.5 \text{ cm}$)
 - Cx Mx, Surgery, Radiosurgery
- Large tumour ($> 3.5\text{cm}$)
 - Surgery
 - Total Excision
 - Subtotal + DXT
 - ? Cx Mx in asymptomatic incidental tumour

Conclusions



What would I do ?

I would probably have radiosurgery

Or find a very experienced surgical team !