

*April 1961*

# Artificial Limbs

*A Review of  
Current Developments*

COMMITTEE ON PROSTHETICS  
RESEARCH AND DEVELOPMENT

**National Academy of Sciences  
National Research Council**

**COMMITTEE ON PROSTHETICS RESEARCH AND DEVELOPMENT**

**Division of Engineering and Industrial Research**

**NATIONAL ACADEMY OF SCIENCES-NATIONAL RESEARCH COUNCIL**

Howard D. Eberhart, *Chairman*] Professor of Civil Engineering,  
University of California (Berkeley)

C. Leslie Mitchell, M.D., *Vice-Chairman*; Surgeon-in-Charge, Division  
of Orthopaedic Surgery, Henry Ford Hospital

George T. Aitken, M.D., Orthopedic Surgeon, Mary Free Bed Guild  
Children's Hospital

Charles O. Bechtol, M.D., Chief, Division of Orthopedic Surgery,  
University of California Medical Center (Los Angeles)

R. C. Doolittle, Capt., MC, USN, Director, Navy Prosthetics Research  
Laboratory

Herbert Elftman, Associate Professor of Anatomy, College of Physicians  
and Surgeons, Columbia University

Sidney Fishman, Project Director, Prosthetic Devices Study, New  
York University College of Engineering

Chester C. Haddan, President, Gaines Orthopedic Appliances, Inc.

Verne T. Inman, M.D., Professor of Orthopedic Surgery, University  
of California Medical Center (San Francisco)

Fred Leonard, Chief, Plastics Development Branch, Army Prosthetics  
Research Laboratory

Anthony Staros, Chief, Veterans Administration Prosthetics Center

Augustus Thorndike, M.D., Chief Surgeon, Department of Hygiene,  
Harvard University

Howard R. Thranhardt, Partner, J. E. Hanger, Inc. (Atlanta)

Tonnes Dennison, Executive Director

Earl J. Murphy, Executive Secretary

A. Bennett Wilson, Jr., Staff Engineer

# Artificial Limbs

VOL. 6

APRIL 1 1961

NO. 1

## CONTENTS

SYME'S AMPUTATION	
Walter Mercer . . . . .	1
THE HISTORY AND DEVELOPMENT OF SYME'S AMPUTATION	
R. I. Harris . . . . .	4
SYME'S AMPUTATION FOR GANGRENE FROM PERIPHERAL VASCULAR DISEASE	
Gordon M. Dale . . . . .	44
PROSTHESES FOR SYME'S AMPUTATION	
A. Bennett Wilson, Jr. . . . .	52
THE BIOMECHANICS OF THE SYME PROSTHESIS	
Charles W. Radcliffe . . . . .	76
THE PLASTIC SYME PROSTHESIS IN CANADA	
C S. Boccia . . . . .	86
SOME AMERICAN EXPERIENCE WITH SYME PROSTHESES	
Herman Gladstone and Louis Iulucci . . . . .	90
TECHNICAL NOTES FROM THE ARTIFICIAL LIMB PROGRAM . . . . .	102

COMMITTEE ON PROSTHETICS RESEARCH AND DEVELOPMENT

NATIONAL ACADEMY OF SCIENCES—NATIONAL RESEARCH COUNCIL

2101 Constitution Ave.

Washington 25, D. C.

*Artificial Limbs* is a publication of the Committee on Prosthetics Research and Development, National Academy of Sciences—National Research Council, issued randomly two numbers to the volume, in partial fulfillment of Veterans Administration Contract V1005M-1914, Office of Vocational Rehabilitation Contract SAV-1000, and National Institutes of Health Grant RG-5057 Copyright 1961 by the National Academy of Sciences—National Research Council. Quoting and reprinting are freely permitted, providing appropriate credit is given. The opinions expressed by contributors are their own and are not necessarily those of the Committee on Prosthetics Research and Development. Library of Congress Catalog Card No. 55-7710.

Editorial Board: Eugene F. Murphy, Prosthetic and Sensory Aids Service, Veterans Administration, New York City; Herbert Elftman, College of Physicians and Surgeons, Columbia University, New York City.

# Syme's Amputation

WALTER MERCER<sup>1</sup>

This issue of ARTIFICIAL LIMBS is, and always will be, a classical contribution to everything pertaining to Syme's amputation, including, as it does, the most detailed and accurate description extant of the proper method of doing the amputation.

It has to be remembered that Syme was the greatest of the pre-Listerian surgeons and, indeed, his operation was developed to combat the disastrous septic complications that so often beset the surgeon who dealt with compound fractures, especially where the bone was divided, in contrast to cases that were disarticulated. The fear of sepsis was no longer a real one after Lister's discovery, but that there were other and great advantages in this operation is proved by the fact that Syme's operation is still recognised by competent surgeons as a method of choice in the suitable case. But there have been criticisms of the operation. Harris has stated the reasons for this difference of opinion. He believes that these lie in the method of the operation and in the after-treatment. Various imperfections of the end-results and the methods of their avoidance are described. Most of these can be avoided by a careful technique, and if this were generally practised there would be fewer complications about this excellent operation.

Harris reminds us of an important feature of anatomy not generally recognised. This is the specialised form of elastic adipose tissue developed between the calcaneum and the plantar aponeurosis which is resistant to pressure. There are here pockets of fat enclosed by dense septa of fibrous tissue. These fibrous tissue strands are in the form of the letter "U," with the open end of the "U" pointing towards the calcaneum. If this concept is true, it is obvious why the dissection of the heel flap should be close to the calcaneum, because if these little loculi are opened, as will happen if the dissection is through the subcutaneous layer, the fat content is extruded and an important weight-bearing mechanism rendered useless.

All modifications, apart from Syme's own one, have detracted from the good qualities of the Syme stump and, indeed, have often ruined its weight-bearing qualities and brought the modified Syme's operation into disrepute. Kelham

<sup>1</sup>"Bidston," 7 Easter Belmont Road, Edinburgh 12, Scotland.

and Perkins, of the British Ministry of Pensions, are often quoted for their strong objection to this operation, and they concluded their article by expressing the hope that the modified operations would soon be as dead as the original Syme. But their remarks were not based on the original Syme, and so it is not remarkable that they hoped that their modified operation would become obsolete.

Modifications like that of Elmslie only lead to failure by reducing the weight-bearing area and making the positioning and fixation of the heel flap more difficult. The plane of transection of the tibia should be so placed that the minimum of bone is removed and the largest possible cross-section of the tibia remains, and that, of course, should be parallel to the ground.

It is good to know that the opinions of the British Ministry of Pensions at Roehampton are now very different. The Chief Medical Officer there believes that a Syme amputation is the operation of choice and he adds that "nobody would persuade me to have a below-knee amputation if I could have a Syme."

Opinion on durability, too, seems to have changed. Many of the cases seen at Roehampton have had little or no trouble over 30 and 40 years. Shellswell quotes a case who had no trouble in 74 years of limbwearing and in his investigation of 305 Syme's amputations with an average follow-up of 29.6 years he found that 66 percent had satisfactory stumps.

Harris points out that an imperfection that is commonly overlooked is the misplaced heel flap. So often after the operation the patient is sent out of the theatre to have the bandaging and the dressing completed. A little too much pull inwards or outwards produces—and permanently—a flap which is not exactly beneath the centre of the cut lower end of the tibia. Harris secured this correct position by strips of adhesive plaster. A plaster-of-Paris support has also been suggested, and a very secure method is to fix the stump by a nail or pin driven up through the lower end of the tibia.

Gordon Dale, who has had an immense experience when in charge of all amputations for the Canadian Department of Veterans Affairs, discusses the use of the Syme amputation in peripheral vascular disease. This is an interesting review of the subject with a detailed description of typical cases. The first Syme amputation for thromboangiitis obliterans was done as far back as 1925, and since then it has been used in such cases whenever it seemed warranted. By 1940 this amputation had been used successfully for a wide variety of conditions, including perforating ulcers, in unrecovered sciatic lesions, cauda-equina lesions, frostbite, arterial occlusion, and gangrene from peripheral arterial disease. Dale showed by demonstration of actual cases the great value and durability of these amputations in active life, and in so doing was able to refute the views on durability expressed by the British Ministry of Pensions.

The biomechanics of the Syme prosthesis are reviewed by Radcliffe and particularly the locomotion pattern and the manner of weight-bearing for a Syme amputee. In an analysis of the process of human locomotion, the walking cycle is divided into two phases—the stance phase and the swing phase—and these are reviewed. The energy curves are most interesting and give some

insight into the complexity of knee-ankle interaction in normal human locomotion. Because of the inherent limitations in available space in the Syme prosthesis, attempts to introduce ankle action have been for the most part unsuccessful. Because in this limited space the Syme amputee cannot achieve the same degree of function as the above-knee or below-knee amputee wearing a SACH foot, the function will in general represent an improvement over the result to be had with the usual articulated joint. This is perhaps an understatement, for when the knee joint on the prosthetic side assumes a greater proportion of the shock-absorption function as evidenced by increased knee flexion under load just after heel contact there is much less deviation from the normal gait.

The actual prosthesis is described in a further article. In a review of the history it is apparent that there has been a gradual improvement since the beginning of the century, though even in 1940 the device was bulky, uncomfortable, and generally subject to mechanical failure. With the introduction of plastic laminates into the practise of prosthetics, research workers have been able to alleviate to a great extent the shortcomings of the designs then currently in use, and now excellent and enduring results have been obtained in a large number of Syme amputations observed in Canada. There seems to be little doubt but that the results in Canada, superior apparently to those in Great Britain, have been due chiefly to adherence to the classical procedure of Syme. In this connection, it is said that "Syme was seldom if ever meticulous as to detail," which is hardly consistent with the views of a famous assistant of Syme's, Joseph Bell, in expressing the special character of Syme's method of operating, nor indeed with his reputation in Edinburgh.

The present prosthesis is the result of research undertaken by the National Research Council of Canada, an activity initiated by Dr. Harris in 1944, though it was not till ten years later that the device had sufficient merit to warrant its general adoption. This is known as the "Canadian-Type Syme Prosthesis," or more simply, in Canada, as the "Plastic Syme." Among the essential features is a socket made of laminations of Fiberglas applied to a plastic mould of the stump and bonded with a rigid epoxy resin. It is lined with foam rubber, and the stump is inserted posteriorly. There is no ankle joint, and the foot is of the SACH type. This prosthesis is stronger, lighter, and much neater than anything produced before and is now in general use, and we have in the last two articles the considered opinion on it from Canada and America. It is stated in the first of these that its chief advantages lie in its improved appearance with reduced weight, its improved durability by virtue of a stronger structure, its freedom from mechanical troubles, and its reduced cost.

This issue of ARTIFICIAL LIMBS leads one to the conclusion that the Syme's amputation is a very good one when properly carried out and properly cared for afterwards. The limb, too, that is in common use as described is a vast improvement on the older *types* and permits a gait that is not much short of normal.

# The History and Development of Syme's Amputation

R. I. HARRIS<sup>1</sup>

JAMES SYME (1799-1870), the last and greatest of the pre-Listerian surgeons (Fig. 1), was renowned in his day as the most eminent surgeon in the English-speaking world. Well informed and well trained by study and travel, he developed in practice the experience, courage, sagacity, and dexterity that enabled him to obtain improved results in the surgical treatment of disease at a time when anaesthesia and antisepsis were unknown. During his occupancy of the Chair of Clinical Surgery at the University of Edinburgh (1833-1869), he developed and perfected many new surgical procedures. Time has outmoded them all save one—his disarticulation amputation through the ankle joint with preservation of the heel flap to permit weight-bearing on the end of the stump.

In the days before antisepsis, the surgeon's efforts to cure his patients frequently ended in disaster. Compound fractures and operation wounds were almost invariably complicated by one or other of the "hospital diseases" (14): erysipelas, septicaemia, pyaemia, hospital gangrene. The patient was fortunate if he escaped death. On rare occasions his wound might heal by "first intention" or "under a scab." Otherwise the wound became "inflamed." If it discharged "laudable pus," it might heal by "second intention," and if so the outlook was reasonably good. But if the discharge was "thin, watery, sanious, acrid," the future for the patient was ominous. Death too frequently supervened. We know now that these complications were the manifestation of virulent infections. But in 1843, when Syme wrote his first paper *On Amputation at*

*the Ankle Joint* (30), Pasteur's work on fermentation (41), which first revealed to us the world of microorganisms, was still more than a decade in the future (1856), and Lister, the founder of antiseptic surgery, was at age 16 finishing his preliminary education with a view toward entering University College, London. Twenty-four years were to elapse before Lister first wrote on his success in treating compound fractures with carbolic acid (1867). Till then the surgeon resigned himself, as had his predecessors from the dawn of history, to the possibility that his most skillful efforts and even the most simple of his operations would be followed too often by dangerous or even fatal reactions. Writing of this period, Volkmann (14,44) said in flowery simile:

The surgeon is like the husbandman, who having sown his field, waits with resignation for what the harvest may bring, and reaps it, fully conscious of his own impotence against the elemental powers, which may pour down on him rain, hurricane and hail storm.

There is a vivid and moving picture of the surgery of the preanaesthetic and preantiseptic era in the story *Rab and His Friends* (6). The author, John Brown, was Syme's pupil and later his colleague and friend, and he admired him profoundly. In the memorial he wrote after Syme's death, he stated (7):

He was my master—my apprentice fee bought him his first carriage; a gig, and I got the first ride in it, and he was my friend. He was I believe the greatest surgeon Scotland ever produced; and I cannot conceive of a greater clinical teacher.

In the account of Ailie's operation, in *Rab and His Friends*, Syme is the surgeon, and John Brown is the house surgeon who tells the story. In spite of Syme's skill in removing Ailie's breast for cancer, she develops sep-

<sup>1</sup> M.C., M.B., F.R.C.S. Can., F.R.C.S. Eng. (Hon.), F.R.A.C.S. (Hon.), F.R.C.S. Edin. (Hon.), Lecturer in Surgery, University of Toronto, Toronto, Canada.





Fig. 1. James Syme (1799-1870), Professor of Clinical Surgery, University of Edinburgh, 1833-1869. Holl's engraving from George Richmond's drawing of him "in the prime of life." Probably this was Syme's likeness at age 43 when he performed his first amputation at the ankle. From Paterson (25).

ticaemia and dies. The agony of her death from this frequent complication of the surgery of those days is so graphically depicted that it brings home to us with dramatic force the immense risks which beset the individual who sustained a compound fracture or was compelled to submit to surgical treatment—all the more impressive because it is told to us by a participant in the tragedy.

In the case of open fractures, the complications were so likely to be fatal that the most radical measures were deemed necessary to forestall the spread of "putrefaction." Immediate amputation through the thigh was the standard procedure for compound fractures of

the tibia and fibula, amputation at the site of election (a hand's breadth below the tibial tubercle) for caries and compound injuries of the foot (30,31,32,33,35,36). Though the mortality from these amputations was 25 percent in the hands of the best surgeons and 50 percent in hospitals less carefully managed (14), the results were better than those to be had from any other form of treatment. The result of conservative treatment was much worse. Mortality from compound fractures of the femur so treated was 80 percent (14), from compound fractures of the tibia 50 percent (14), and from compound dislocation of the astragalus 87 percent (32,36). Whether patients

were treated conservatively or by amputation, the mortality from compound injuries of the foot was shockingly great. Of those who survived compound dislocation of the astragalus without amputation, Syme said (32,36):

... the foot generally remains in such a state of stiffness, weakness and sensibility to external impressions as to be rather an encumbrance than a support to the patient.

For those who survived after amputation of the leg, the disability from loss of the limb also was great. In the words of Syme (32,36):

So long as the only alternatives were an attempt to preserve the limb and amputation of the leg, there was a strong inducement to abstain from operating. But if the patient's safety and speedy recovery may be ensured by taking away merely that part of the limb, which in the circumstances can be of little value either to use or ornament, while at the same time a stump is produced in all respects preferable to a shattered, stiff, irritable foot, I think there should be little hesitation in resorting to amputation at the ankle joint under the circumstances in question.

During a period of study in Europe (probably in 1822 in Paris, where he attended Lisfranc's course of surgical operations on human cadavers and Dupuytren's lectures and clinical demonstrations), Syme learned the technique of Chopart's amputation for removal of part of a foot damaged or diseased. He introduced the procedure in Edinburgh in 1829, and the results he obtained convinced him of its merit.

Chopart's amputation (disarticulation at the mid-tarsal joint, long plantar flap) was seldom complicated by the hospital diseases that made amputations through the leg so dangerous, and it left the patient with a partial foot capable of weight-bearing and with a movable ankle joint above it. We now know that the success of Chopart's amputation was a demonstration of the principle that, in the presence of sepsis, disarticulation is a much safer procedure than is amputation through muscle masses and the open medullary cavities of long bones. Articular cartilage left on the end of a bone, or the subarticular cortical plate and the network of cancellous bone deep to it, serve as barriers to the spread of infection, whereas the intermuscular and interfascial planes of an amputation stump

provide easy pathways for invasion by microorganisms. Syme could not know the true reason for the life-saving merit of Chopart's amputation because knowledge of bacteria and of wound infections was still in the future. His conviction of its value was founded on empirical experience.

Syme commented upon the merits of Chopart's amputation as follows:

The operation of Chopart, which leaves only the astragalus and os calcis, is the most valuable of all partial amputations as it commands the largest portion of the foot requiring removal for disease or injury, and at the same time preserves a support for the patient not less useful than that which is afforded by the whole of the tarsus. Its introduction was long opposed on the ground that the extensor muscles of the ankle, acting through the tendo achillis, when no longer antagonized, would draw up the heel and point the cicatrix to the ground. I performed this operation in 1829, so far as I know for the first time in Edinburgh (Great Britain?) and have frequently done so since with the most satisfactory result, no inconvenience having been experienced from the source just mentioned, as the cut ends of the tendons on the forepart of the joint speedily acquired new attachments enabling them to counteract the extensive power.

Syme's favourable impression of the merit of Chopart's disarticulation at the mid-tarsal joint led him to apply the same principle to the ankle joint when caries or compound injury involved the astragalus or calcaneus, problems for which Chopart's amputation was inadequate. He performed his first disarticulation at the ankle joint in 1842, thirteen years after his first Chopart amputation. The long delay in applying to the ankle joint the principle which was so successful at the mid-tarsal joint arose from the problem of how to make the long stump bear weight satisfactorily. Disarticulation at the ankle joint might prove as effective as Chopart's amputation in saving the patient's life, but the long stump would prove an intolerable nuisance unless the patient could walk upon it. In Chopart's amputation, walking upon the stump presented no problem since the whole of the posterior half of the sole of the foot remained intact, and upon this the patient walked almost as easily as upon a normal foot. Amputation at a higher level (a hand's breadth below the tibial tubercle) permitted weight-bearing by applying the flexed knee to the

padded cleft in the upper end of a crude prosthesis. This was "amputation at the site of election," a useful operation if the patient survived, but the mortality rate was 50 percent.

To make disarticulation at the ankle joint a functional success, some procedure was needed which would permit all the body weight to be borne upon the end of the stump in a manner similar to Chopart's stump. Other surgeons had attempted to solve this problem without success. Syme's solution was to detach from the underlying tarsal bones the whole thickness of the posterior half of the sole of the foot, disarticulate the astragalus from the mortise of the ankle joint, remove the malleoli, and then reapply the heel flap to the lower ends of the tibia and fibula. This proved to be the technique necessary for a satisfactory end-bearing stump at the level of the ankle joint for it provided a thick and bulky covering for the end of the stump composed of tissue adapted to weight-bearing.

Syme's account of the development of his new operation is interesting (32,36):

The idea of amputating at the ankle joint is not new, the operation having been performed on the Continent by different surgeons before I thought of it; and it would probably ere now have become generally adopted but for the doubt that was entertained as to the ends of the bones being sufficiently covered to afford the patient a comfortable and useful support for the limb. For my own part when I read of dissecting flaps of skin from the instep, or sides of the foot, I felt so much distrust in the protection that could thus be effected against the injurious effects of pressure on a part so exposed to it, that I had no desire to try the experiment. But it occurred to me, that by performing the operation in a different way all such objections might be obviated. This was to save a flap from the sole of the foot and the thick integuments of the heel, by making a transverse incision, and dissecting these parts from the os calcis, so that the dense structures provided by nature for supporting the weight of the body, might still be employed for the same purpose. Two trials of this operation having proved satisfactory, I communicated them to the profession, and am glad to find that not only my colleagues in the hospital here, but also practitioners in other planes have already acted upon this recommendation. The additional experience of my own practice now enables me to suggest some improvements in the mode of procedure—point out an error to be avoided [this was cutting the posterior tibial artery before division into the median and lateral plantar branches]—and verify the expectation formerly expressed as to amputation of the leg being hardly ever required.

Since Syme does not say why it took him so long to evolve this successful technique, we can only speculate upon the reasons. It may be that the principle of raising a skin flap and then replacing it in a new position was sufficiently radical to make him hesitate. This is a possibility for it was known that amputations with flaps were more prone to postoperative troubles than circular amputations. Or it may be that he was so immersed in the many other new surgical procedures he introduced that time elapsed before he gave thought to disarticulation at the ankle joint. Or it may be that it required thirteen years of experience with Chopart's amputation to convince him that disarticulation was so much more safe than amputation that he would be justified in applying the principle to the ankle joint. Probably this last supposition is important. In the era of "hospital diseases" it was of immense value to know that disarticulations could with certainty be relied upon to heal without the complications which after amputations endangered life and marred the healing of the stump.

Syme's first patient (30,36,37) was a 16-year-old boy who suffered from caries of the tarsal bones, almost certainly tuberculosis. Syme described the problem, the operation, and the result in his first published paper on the subject (30):

John Wood, aged 16, was admitted to the Royal Infirmary on the 8th of September, 1842, suffering from disease of the foot which had suppurated and ulcerated in consequence of a twist he had given to it in walking about twelve months before. The instep was swollen and there were two openings discharging pus. A probe entered the sinuses freely into the substance of the tarsal bones, more particularly the astragalus and os calcis. ... As the disease had extended beyond the limits of Chopart's amputation it would have been necessary in accordance with ordinary practice to remove the leg below the knee, but as the ankle joint seemed sound I resolved to perform a disarticulation there. With this in view, I cut across the instep in a curved direction with the convexity towards the toes, and then across the sole of the foot so that the incisions were nearly opposite one another. The flaps thus formed were next separated from their subjacent connexions which was easily effected except at the heel where the firmness of texture caused a little difficulty. The disarticulation being readily completed, the malleolar projections were removed by means of cutting pliers.

Although a small slough separated from the

edge of the lower flap, in which a counter-opening had to be made for the drainage of matter, the patient recovered with little reaction and left the hospital in three months. Five months after the operation:

. . . the wounds were soundly healed, and any degree of pressure can be born by the stump which has a round form, well suited for the adaptation of a boot or artificial foot, and is strongly protected from external injury by its thick integument.

The success of his first case led Syme to the following conclusion:

It thus appears that compound dislocation of the astragalus and caries of this bone and the surrounding articular surfaces are the principal cases for amputation of the leg. This amputation can usually be superseded by amputation at the ankle joint. . . . The advantages promised by amputation at the ankle joint instead of operation near the knee are: 1st, That the risk to life will be smaller: 2nd, That a more comfortable stump will be afforded and 3rd, That the limb will be more seemly and useful for progressive motion. . . . On these grounds I think amputation at the ankle joint may be advantageously introduced into the practice of surgery. I regret having cut off many limbs that might have been saved by it, and shall be glad if what has been said in its favour encourages others to its performance.

Between 1843 and 1846 Syme wrote four more papers on amputation at the ankle joint (31,32,33,35), and he reprinted them with a summary in *Contributions to the Pathology and Practice of Surgery* (36). Therein he states:

I have operated in more nearly two than one dozen of cases with perfect success.

Years later (1857) he wrote again to attest to the satisfactory results obtained by his amputation at the ankle joint (37). He had been aroused by a review in *Lancet* (13) of the then new (4th) edition of Fergusson's *System of Practical Surgery*, in which appeared the following sentence: "Mr. Fergusson states, in relation to removal of the foot at the ankle joint in the manner recommended by Mr. Syme; that he had formed from experience a most unfavourable impression against it." Syme wrote to the editor of *Lancet* to refute Fergusson's statement. He said:

Sir,

Fifteen years ago I proposed a mode of affording relief from diseases that had been held to require amputa-

tion of the leg, by removal of the foot at the ankle-joint. This proposal was favourably received, and has long since been adopted by intelligent surgeons at home and abroad as the established procedure in cases proper for its performance. It is easily executed, and proves in the highest degree satisfactory, if done in accordance with certain principles which have been carefully explained, but is difficult and disastrous if performed incorrectly.

He then included letters from three patients upon whom he had performed his amputation at the ankle joint, respectively 10, 14, and 15 years earlier. One of them was his first case. All were well—with useful, painless stumps on which they could walk without difficulty and without a prosthesis if necessary.

Before Syme died in 1870, the problem of hospital diseases was in the process of solution as the result of the clinical studies of his son-in-law, Joseph Lister. Today, more than a century since Syme first wrote on amputation at the ankle joint, we have accumulated an immense fund of knowledge on the problem of infection in surgery, and we have at our command effective measures for its control. The technique of aseptic surgery and the rigid standards of cleanliness and hygiene in operating rooms and hospitals have to a large degree enabled us to eliminate infection from our surgical procedures. When infection does occur, we can now do more to control it with antiseptic and bacteriostatic and antibiotic agents than has ever before been possible. Today, therefore, the merit of Syme's amputation lies not chiefly in the circumstance that "the risk to life will be smaller." On the other hand, it still remains the most useful of all amputations of the lower extremity "because a more comfortable stump is provided, and the limb is more seemly and useful for support and progressive motion."

Of historical interest in demonstrating Syme's conviction of the merit of end-bearing stumps in the lower extremity is the record of his attempt to devise, at the level of the knee, an end-bearing stump embodying the principles which had proved so successful at the ankle. Two years after his first account on amputation at the ankle joint he reported the results of his attempt on two patients to remove the lower extremity at the knee and to close the wound with a skin flap so that weight could be borne on the end of the stump

(34). Both patients seem to have been suffering from tuberculosis of the knee joint. In both, the femur was transected through the condyles just above the carious articular surface, and the end of the stump was covered with a long posterior flap of skin derived from the calf. Both wounds healed without complication, though they took a long time to do so.

It seems evident from Syme's presentation of these two cases that he was concerned chiefly with devising an operation safer than amputation through the shaft of the femur and that he believed that transection through cancellous bone just above the articular surface would involve less risk from hospital diseases than would amputation at a higher level. Since he did not cover the end of the stump with skin accustomed to weight-bearing, he evidently believed that the achievement of a healed stump without sepsis and without serious risk to the life of the patient was the prime objective and that good function and even end-bearing would follow good healing.

Twenty-one years later (38) he wrote again

about transcondylar amputation of the femur. His interest had been renewed by Carden's report (8) of a method of amputating through the knee or through any part of the lower end of the femur using to cover the end of the bone a single, long, anterior flap composed of skin and subcutaneous tissue only. The muscles were divided at the level of transection of the bone and thus were excluded from the flap as was also the patella. Carden's purpose was to avoid the thin, sensitive, adherent cicatrix ("retreating muscles and obtrusive bone"), which so frequently resulted when equal flaps were used, and to cover the end of the femur with a broad cap of skin and subcutaneous tissue accustomed to bearing the weight of the body in kneeling (Fig. 2). Syme warmly commended Carden's amputation, which he said could be performed with little risk to the patient and had the additional advantage (38) that:

... the stump proved eminently serviceable since the skin over the bone, instead of becoming thinner, acquired additional thickness so that patients could

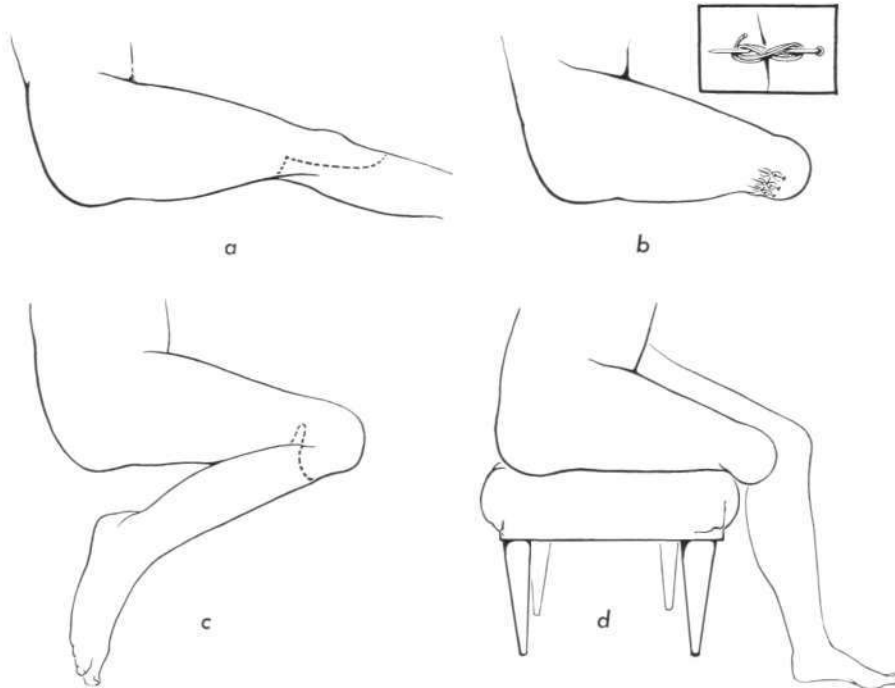


Fig. 2. Carden's operation by single flap, *a*, The line of the skin incision; *b*, closure of the wound; *c*, ankylosis of the knee in extreme flexion deformity following fractured patella; *d*, the end-bearing stump obtained by Carden's operation on the limb illustrated in *c*. From Carden (8).

rest upon it just as they do after amputation at the ankle.

In the same publication, Syme acknowledged that his earlier attempt to perfect the technique of transcondylar amputation had failed and that the method had fallen into disuse because the skin flap derived from the calf of the leg "proved very inconvenient." Syme, therefore, nearly achieved success in devising an end-bearing stump at the transcondylar level. He failed because his attention was focused upon the avoidance of sepsis and because he did not appreciate the importance of covering the end of the stump with skin naturally adapted to weight-bearing—a strange circumstance since he seems to have been well aware of the value of "the thick integuments of the heel" in the ankle-joint cases.

#### DEVELOPMENT OF SYME'S AMPUTATION

Shortly after Syme's first publication on amputation at the ankle joint (30), the operation began to be adopted in England and Scotland, generally with satisfactory results. In subsequent publications Syme stressed details of technique he had found essential for success (*i.e.*, avoidance of damage to the posterior tibial artery, separation of the heel flap by dissection close to the calcaneus, drainage of the dead space, etc.). By 1846 he had perfected the technique of the operation, and from then on he accumulated experience in the application of the procedure to various problems. But he wrote nothing more on the operation except the letter to the editor of *Lancet* in 1857 (37).

#### BAUDENS' TIBIOTARSAL AMPUTATION

On the Continent, and especially in France, there was less ready acceptance of Syme's amputation, partly because a somewhat similar amputation (2) had been reported by Baudens (Fig. 3) in 1842, a year before Syme's first publication. Described as a "tibiotarsal amputation," it involved a procedure in which the foot was removed by disarticulation at the ankle joint accompanied by removal of the malleoli and the posterior half of the

inferior articular surface of the tibia by a single saw cut. The end of the stump was covered with a flap from the dorsum of the foot which included in its thickness all the structures from the skin to the tarsal bones and intertarsal ligaments (skin, subcutaneous tissue, tendons, nerves, and blood vessels). Baudens' concern was to secure good healing by a flap which would drape itself over the end of the stump as the patient lay supine in bed and when healed would provide a long stump on the end of which the patient could walk (Figs. 4, 5, and 6). When reports of Syme's operation reached France, there was renewed appraisal of Baudens' cases, and the columns of *Les Annales de Therapeutique* for 1845-1847 contain several references to the problem. The following editorial comment (2) is typical:

Our readers already know the tibiotarsal amputation of the foot which Doctor Baudens performed several years ago on a young soldier at the Gros-Caillou Hospital. We followed the patient in this hospital and then at the Val-de-Grace to which he had been transferred and we were happy one year later to see him walk well with the aid of an ordinary dancing shoe supported by two small metallic splints. This soldier took long walks without fatigue, went upstairs and went down slowly, danced and jumped with agility. His peg leg made him an excellent support and all without even a limp. We were extremely satisfied with this result in spite of the fact that one or two other patients who had had this operation performed upon them by Doctor Baudens had succumbed from gangrene of the flaps. Doctor Baudens' patient was admitted subsequently to l'Hotel des Invalides. Soon we found him again admitted to the Infirmary of the Hotel and for several months he has continued there. His stump has become excessively painful. The cicatrix has re-opened and has ulcerated at several points. Doctor Hutin, the surgeon-in-chief, has been obliged to open two small new abscesses which had formed in the tissue of the scar and it is probable that the underlying bones are affected. The patient complains of acute suffering and he demands with earnest insistence an amputation near the knee. M. Hutin will probably be obliged to come to that. This fact raises questions which demand an explanation. Let us first remark that the indifference with which our surgeons, civil and military, have received the remarkable memoir of M. Baudens is not a proof that the operation is without value for it has been practised in Edinburgh by M. Syme half a score of times with complete success. (We say indifference for the reason that no French surgeon to this day has himself performed or even recommended M. Baudens' valuable operation.) It is true, however, that M. Syme had generally operated only upon children and that he had pub-

lished only the immediate results of the operation. Now the question is what are the remote effects (of the operation) since the scar in M. Baudens' patient was not inflamed or ulcerated and did not re-open for more than a year after the operation. It is all the more important, therefore, to know the actual state of M. Syme's patients for this knowledge could decide whether in the patient at Les Invalides, the evil in the scar derives from morbid constitutional conditions as we have presumed or to inherent conditions in the form of the flaps or in the stump. We should recall that in M. Baudens' operation the top of the ankle is sawed off after the disarticulation, while M. Syme preserved the ankle intact. Let us say finally that until new facts come to enlighten the above questions and in spite of the very great aversion the civil and military surgeons show to adopting the tibiotarsal amputation, we persist in believing it beneficial in most cases which we have from time to time indicated. Amputation at the wrist is satisfactory; why then hesitate to operate at the same level in the inferior member? We know the reasons of those who oppose. Time and new facts will be the best judges.

We should not terminate this article without stating that there prevails in military practice a sort of aversion for all those operations which one could perhaps call *de luxe* such as partial amputation of the foot, supramalleolar amputation, etc. For several reasons orders have been to adopt the same treatment for all cases. It is otherwise in civil hospitals. We have already discussed the diverse questions connected with these declarations.

This editorial was reproduced in the *Monthly Journal of Medical Science*, where it came to Syme's attention (36). Certain inaccuracies demanded correction, and there was the implication that perhaps Syme's results were not as good as they were said to be or that, if they were, the reason should be found so that Baudens' operation could be modified and made acceptable on its merits.

Syme therefore wrote to the editor of the *Monthly Journal of Medical Science* (35) to clarify the points in confusion. The gist of his reply was as follows:



Fig. 3. J. B. L. Baudens, the French military surgeon who published in 1842 the account of his tibiotarsal disarticulation. Courtesy National Library of Medicine, Washington, D. C.

1. He had operated upon a considerable number of patients (more nearly two than one dozen of cases) with complete success.

2. Most of his patients were adults (not children as stated by the editor of *Les Annales de Therapeutique*).

3. In one case only did he leave the malleoli intact and that was the case of an infant five months of age with an erectile tumour of the foot.

4. His results were satisfactory, in evidence of which he quoted from letters received from his first three patients, each of whom stated that the stump was satisfactory and was scarcely any handicap.

5. His mode of performing the operation was to obtain a heel flap of sufficient length by cutting from the tip of one malleolus to the tip of the other. By this the risk of sloughing was lessened if not entirely prevented.

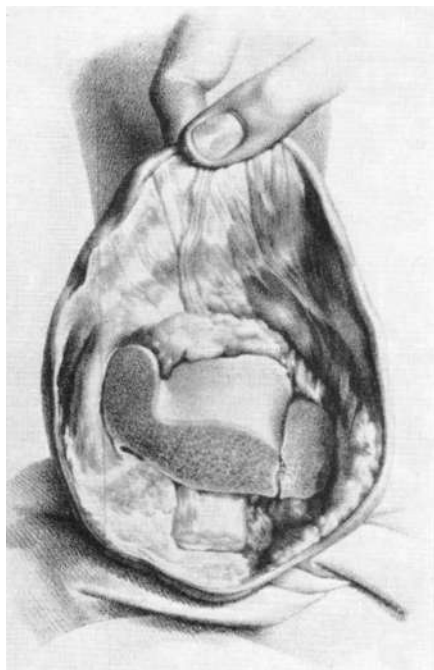


Fig. 4. Baudens' tibiotarsal amputation. Appearance of the stump after removal of the foot. The malleoli have been removed with the posterior margin of the articular surface of the tibia. The long dorsal flap is held up. Left to itself, it fell naturally over the cut ends of the bones and required the minimum amount of fixation. From Baudens (2).

The fact is that there was an essential difference between Baudens' tibiotarsal amputation and Syme's amputation at the ankle joint. Both surgeons were striving to devise, for treatment of disease of the foot beyond the scope of Chopart's amputation, an operation which would replace amputation below the knee. They desired to diminish the risks to the patient's life and to leave him with a long, well-covered, unscarred stump capable of total end-bearing. Both surgeons disarticulated the foot at the ankle and removed the malleoli, with or without a thin flake from the lower end of the tibia. The essential difference lay in the nature of the flap used to cover the end of the stump. Baudens used a long flap from the dorsum of the foot because it would drape itself naturally over the end of the stump while the patient lay supine in bed. It required the minimum of fixation and permitted free

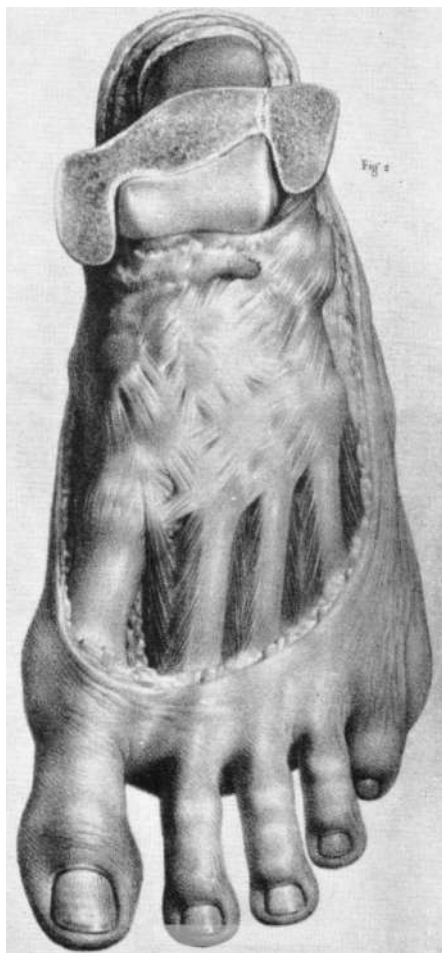

Fig. 5. Baudens' tibiotarsal amputation. Appearance of the foot after its amputation. The denuded area on the dorsum of the foot indicates the extent of the flap and shows that it included in its thickness all the tissues from the skin to the tarsal bones and intertarsal ligaments. From Baudens (2).

drainage in the immediate postoperative period. Syme used a plantar flap in order that he might cover the end of the stump with the thick integument of the heel.

Syme's amputation at the ankle joint proved superior to Baudens' tibiotarsal amputation even in the days before antisepsis. Today, with infection eliminated as an operative risk, Syme's operation has even more to recommend it as the best operation of the lower extremity.



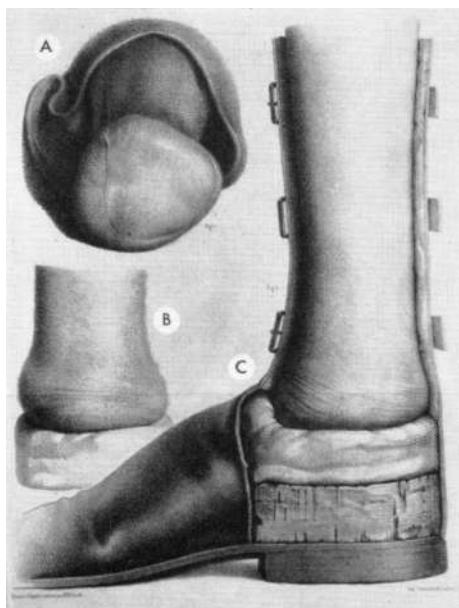


Fig. 6. Baudens' tibiotarsal amputation, *a*, End of the stump when completely healed; *b*, appearance of the stump when bearing weight; *c*, simple prosthesis fitted into a boot with a high, laced top. From Baudens

In addition to Baudens' tibiotarsal amputation and Syme's amputation at the ankle joint, several other amputations of the foot in the region of the ankle were devised in the latter half of the nineteenth century with the purpose of avoiding the grave complications of amputation through the leg and to provide an end-bearing stump. Though none of these proved to have the value of Syme's amputation, they are of historic interest.

#### ROUX'S AMPUTATION

Roux's amputation (1845) was a supramalleolar amputation (19,27) with a medial flap to cover the ends of the tibia and fibula (Fig. 7). The tibia and fibula were divided transversely above the articular cartilage, and the medial flap included all the skin on the medial side of the foot as far forward as the talonavicular joint and as far inferior as the inner margin of the sole of the foot. The advantages claimed were that the flap had an assured blood supply from the posterior tibial artery and that a weight-bearing stump could be salvaged from a foot with a heel flap damaged too extensively to permit a formal Syme's amputation. The disadvantage proved to be the inadequacy of the flap, which was too thin to withstand the stresses of weight-bearing.

It is interesting to record that Roux came to recognize the superiority of Syme's amputation. In 1846, after performing his first disarticulation of the ankle joint by Syme's method, he said (16):

It appears to me that by this operation art modifies without changing the language of nature; in fact, the malleoli being removed, the lower extremity of the leg affords a base of support which transversely exceeds that of the os calcis.

#### GUYON'S AMPUTATION

Guyon's elliptical supramalleolar amputation with posterior flap (1868) was performed (15) by a single elliptical incision which encircled the heel and the front of the ankle joint (Fig. 8). Only a finger's breadth of skin from the plantar surface of the foot in front of the heel was retained. A flake of the os

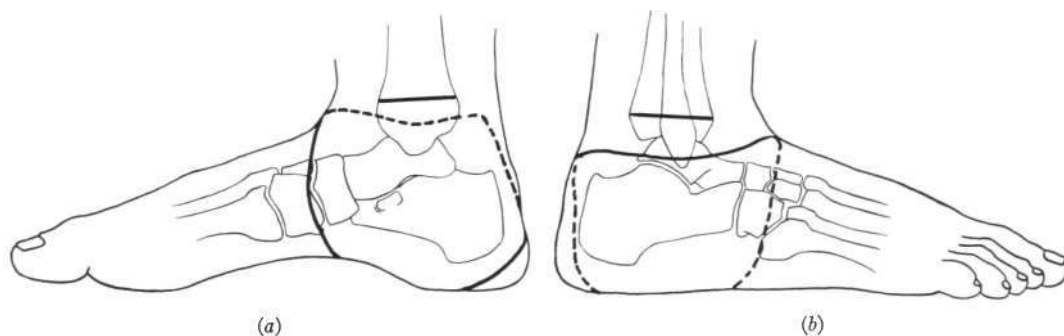


Fig. 7. Roux's supramalleolar amputation with medial flap, *a*, Medial view; *b*, lateral view. Redrawn from Jacobson (19).

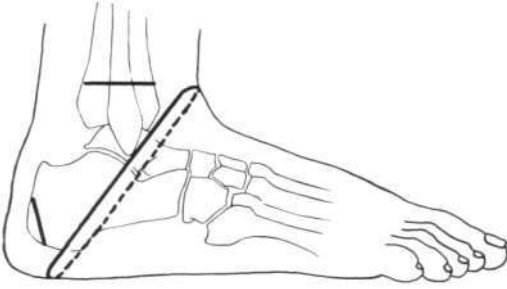


Fig. 8. Guyon's elliptical supramalleolar amputation with posterior flap. Redrawn from Farabeuf (12).

calcis was removed at the insertion of the tendo achillis and retained with the heel flap, and the tibia and fibula were transected above the articular surface of the tibia. The heel flap, with its flake from the posterior end of the os calcis, was applied to the cut surfaces of the tibia and fibula, and the skin margins were sutured. The weakness of Guyon's amputation lay in the inadequate heel flap, which did not stand up under the stress of weight-bearing, and the small tapered end of the stump, which provided too small an area of support.



Fig. 9. Nicolai Ivanovitch Pirogoff (1810-1881), who devised his amputation at the ankle to overcome certain features of Syme's amputation that he regarded as detrimental. From *Pirogoff: Collected Works*, Vol. 1, State Publications Medical Literature, Moscow-Leningrad, U.S.S.R., 1959. Print obtained through the courtesy of Dr. W. G. Bigelow and the Russian Ambassador to Canada, His Excellency A. A. Aroutunian.

#### PIROGOFF'S AMPUTATION

In 1854, Pirogoff (Fig. 9), the greatest Russian surgeon of his day, published the account of his new operation at the ankle joint (26), which he intended as an improvement upon Syme's amputation. In 1847, at the Clinic of Professor Chelius at Heidelberg, Pirogoff had seen two patients upon whom Syme's amputation had been performed, and he was impressed with the results. In 1848 and 1849 he performed Syme's amputation on four patients, all of whom died (one of pulmonary tuberculosis, one of scurvy, and two of sepsis, one of whom had gangrene of the heel flap). In a fifth case, an attempt to perform Syme's amputation failed because of gross damage to the heel flap incurred in separating it from the calcaneus. Nevertheless, Pirogoff, in his attempt to deal with compound injuries and caries of the astragalus and calcaneus by some method better than amputation below the knee, continued to use Syme's amputation at the ankle joint as well as Baudens' tibiotarsal amputation and Roux's supramalleolar amputation with a medial flap. From his experience he came to the following conclusions:

1. The most difficult part of Syme's amputation is the separation of the heel bone from the skin. Only with

great care can the tightly adherent skin be separated without injuring the flap or making it too thin.

2. In Syme's operation, the skin over the tendo achillis forms the base of the flap and is much thinner than the apex of the flap. If care is not taken, it may be cut too thin and the flap may become gangrenous.

3. A considerable depression remains in the heel flap of Syme's amputation after the os calcis is shelled out. It may form a pocket for the collection of pus.

4. In the method of Baudens, the skin over the lower surface of the os calcis is removed. In this operation the creation of a foundation for the stump is not accomplished as it is in Syme's method, where the thick skin of the sole of the heel forms a sturdy covering.

5. In Roux's method, the formation of the posteromedial flap is certainly easier than in Syme's method. The base is wider, and necrosis occurs less often because the posterior tibial artery is cut below its division. However, the base of the flap is thinner than the summit. The depression in the flap is just as deep as in Syme's method, and, finally, the Achilles tendon is completely cut at its attachment to the os calcis as in the two previous cases.

In order to avoid these inconveniences, Pirogoff devised a new procedure (Figs. 10, 11, 12, and 13). The skin incisions resembled those of Syme. The skin, soft tissues, and tendons were divided down to the bone, and

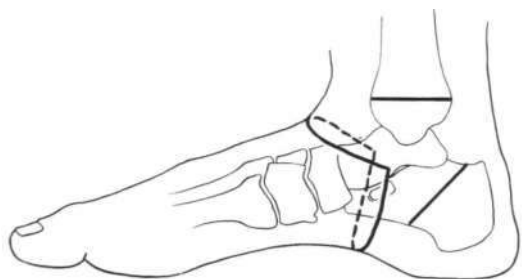


Fig. 10. Pirogoff's amputation. Redrawn from Pirogoff (26) and Elmslie (11).

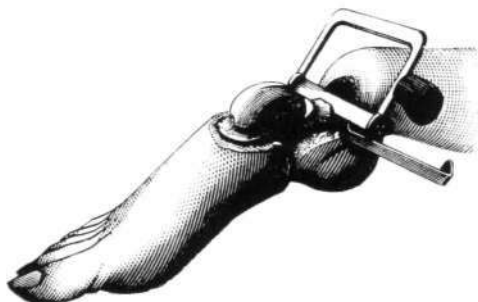

Fig. 11. Pirogoff's amputation. Dividing the calcaneus. From Farabeuf (12).

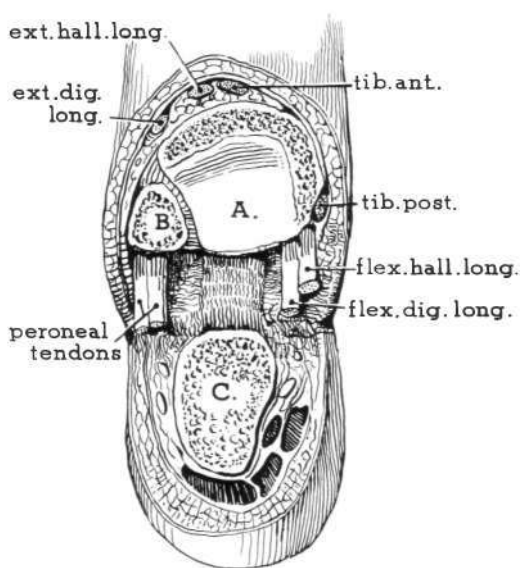


Fig. 12. Pirogoff's amputation. Appearance of the stump after removal of the foot by disarticulation at the ankle. A, Tibia; B, fibula, C, os calcis "sawn behind *lig. sustentaculæ*" Redrawn from Pirogoff (26).

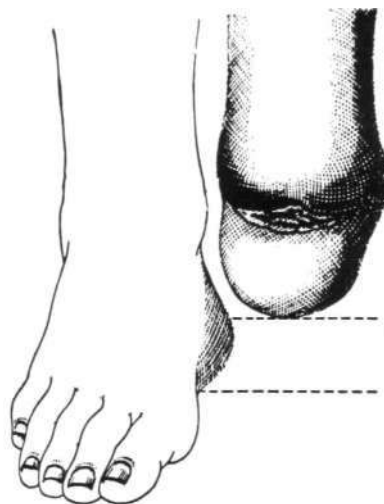


Fig. 13. Pirogoff's amputation. Appearance of the healed stump. Redrawn from Pirogoff (26).

the ankle joint was entered from in front by dividing the capsule anteriorly. The lateral ligaments were detached from the malleoli and the astragalus displaced downwards. The capsule was then opened posteriorly and the superior surface of the calcaneus exposed. A saw placed through the two vertical limbs of

the plantar incision and across the superior surface of the calcaneus behind the body of the astragalus and in front of the tendo achillis divided the calcaneus obliquely from above downwards at the junction of the middle with the posterior third of that bone. The posterior third of the calcaneus and the tendo achillis retained their normal attachments and formed an integral part of the heel flap. The malleoli were divided at their base and removed level with the articular surface of the lower end of the tibia. The inferior articular surface of the tibia was not removed unless it was diseased. When the vessels had been ligated, the heel flap was turned up and secured to the margin of the anterior flap by two or three sutures.

The operation was ingenious and had certain merits. If the wound healed satisfactorily and the calcaneal fragment fused to the tibia, an end-bearing stump resulted, longer than a Syme's stump, so that no prosthesis was necessary to compensate for the shortening. The patient walked without much "dipping" (limp). Also the heel flap was firmly fixed in place by fusion of the calcaneal fragment to the tibia. But there were risks which could mar the success of the operation. If the calcaneal fragment failed to unite to the tibia, an unstable and painful stump end resulted. If the wound became infected, chronic osteomyelitis with persistently discharging sinuses was prone to establish itself in the calcaneal fragment or in the lower end of the tibia. Weight was borne ultimately upon the skin over the back of the heel, an area not as well suited to weight-bearing as is the plantar surface of the foot. For success, the calcaneus had to be free of disease and the heel flap not seriously damaged by trauma. In an age when the nature and management of infection was unknown, it was an operation technically difficult and uncertain in its results. Pirogoff's first three cases were all complicated by serious sepsis, and many months elapsed before they could walk on their stumps. Even then they still had discharging sinuses. Syme's operation was easier to perform and more certain of a good result, and these advantages still prevail.

#### SUBASTRAGALAR AMPUTATION

Subastragalar disarticulation was first mentioned by Velpeau in a single small paragraph in his *New Elements of Operative Surgery* (43). He stated that it had been proposed to him by des Lingerolles, who seems not to have been a surgeon. At the time Velpeau had not performed the operation. He merely mentioned it as a promising procedure in selected cases of disease or injury of the foot. Farabeuf (12) perfected the operative technique and described it with excellent engravings in his *Precis de Manuel Operatoire* (12). He also discussed its merits and limitations. There is also a paper by Hutchinson (18), which contains a good description of the operation as well as a report upon the end result obtained in six cases. Five of his cases, operated upon by the technique described by Farabeuf, were gratifyingly successful, while the sixth, in which the flap was formed by a technique similar to that of Syme, was imperfect because the heel flap could not cover the head of the astragalus without undue tension.

Subastragalar amputation is of value in a limited number of cases, the best technique being that described by Farabeuf (12). A large internal and plantar flap extends to the outer margin of the heel and as far forward as the base of the fifth metatarsal (Fig. 14). The subastragalar and astragaloscaphoid joints are opened from the lateral side, and the heel is inverted until the medial side of the os calcis can be reached. The os calcis is then freed from the heel flap beginning at the medial surface and is removed with the foot. Care must be

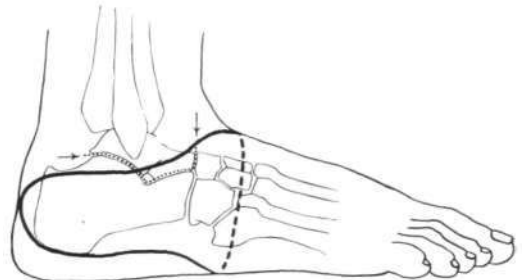


Fig. 14. Subastragalar amputation of de Lingerolles and Velpeau giving large plantar flap. Redrawn from Farabeuf (12). Dotted line is the plane of subastragalar disarticulation.

taken to avoid injury to the posterior tibial artery. The advantages over Syme's amputation, as stated by Hutchinson, are:

1. The stump is some 2 in. longer than a Syme's stump.
2. It gives a broader base of support.
3. The elasticity due to ankle movement is of marked advantage in walking.
4. The pad at the end of the stump is much thicker.
5. The arterial supply is better and runs less risk during the operation.
6. The artificial foot can be better fitted to the stump.

Hutchinson states that between 1891 and 1900 Syme's amputation was performed under antiseptic surgery on 27 patients at the London Hospital. The outcome: complete failure, 3 (one died); suppuration and sloughing of flap, 12; good result, 12. Several factors other than imperfection in technique (*e.g.*, difficulty in sterilizing the skin of the heel flap, delay in operating because of patient's "obstinacy," operation in unpromising cases) contributed to the poor results. Even with the advantages of anaesthesia and antisepsis, the results at the London Hospital were inferior to those of Syme. In his meagre accounts of long-term results, Syme makes no mention of a fatality, and the functional results were good. For best results from Syme's amputation, the cases must be selected carefully, and the operation has to be timed wisely and performed skillfully.

In Hutchinson's paper also is an informative note, quoted from Clinton Dent (10), on the amputations in the South African War. The following is a summary:

Syme's amputation was performed in a small number of cases, but the resulting stumps were not entirely satisfactory. Damage of the foot from trauma is perhaps not as good an indication for Syme's amputation as is tuberculosis, because of damage to the skin. Sloughing of the flap sometimes occurred. Syme's amputation depends more than any other upon very careful attention to the details of the technique.... In Syme's amputation it is really impossible to depart from the lines laid down by Syme in the fashioning of the flaps. [It will be remembered that Syme emphasized this in almost the same words in his letter to the editor of *Lancet* (37) already quoted.] There may be merit in the subtragalar amputation. English surgeons are too limited in their methods of operating upon the foot and have a good deal to learn from their French colleagues.

The variety of ankle amputations introduced in the latter half of the nineteenth

century is an indication of a common purpose on the part of the surgeons of that era. They were attempting to replace the dangerous operation through the upper end of the tibia with the safer disarticulation at the ankle and at the same time to provide for the end of the stump a covering which would withstand the period of postoperative sepsis without undue damage and which could ultimately permit weight to be borne upon the end of the stump. When we recall that, in its early years, Syme's amputation was performed without the benefit of anaesthesia, it is not surprising that sometimes it was executed imperfectly. Time has proved that success in Syme's amputation is dependent upon precise adherence to a particular technique. Even in today's era of advanced surgery, it still is necessary, if we are to avoid imperfect results, to use a technique which differs in no essential detail from that used by Syme.

In Syme's day, the chief difficulty that hampered the general acceptance of his procedure was the frequent occurrence of necrosis of the heel flap, and we can appreciate from Hutchinson's account that it was still a problem even in 1900 with benefit of antiseptic surgery. According to Dent also (10), necrosis of the heel flap was a complication of Syme's amputation performed on soldiers in the South African War. The chief cause of necrosis of the heel flap was injury to the posterior tibial artery. Syme himself learned, in the hard school of experience, the necessity for preserving this vessel (32,36). His account is as follows:

In describing the operation, I have said that care must be taken to avoid cutting the posterior tibial artery before it divides into the plantar branches and I may now explain more particularly the ground on which this advice is founded.

Elizabeth Wilson, aged seven, was admitted on the 19th of February on account of disease in her left ankle. . . . The foot was much enlarged, stiff and shapeless; and two sinuses allowed a probe to pass into carious bone.

On the 21st I proceeded to amputate at the ankle joint, but finding that ankylosis had taken place between the articular surfaces, I exposed the extremities of the tibia and fibula, and sawed them through without previously removing the foot as usual. In tying the vessels, it appeared that the posterior tibial artery had been divided before its division into the plantar branches, so that one ligature sufficed in place of two.

The stump looked remarkably well and the result of the operation was expected to prove very favourable. It was, therefore, with much surprise, and no small disappointment, that in the course of a few days I saw the flap had sloughed through fully half its extent. Recovery was consequently delayed much beyond the ordinary period. . . .

I attributed the sloughing in this case to the undue pressure of the bandage; and having occasion soon afterwards to perform the operation on a patient in Minto House, intentionally divided the posterior tibial before its division, in order to obtain the same facility in tying the vessel as on the last occasion. To my surprise and concern, the flap again sloughed to the same extent as in the case just related, and as great attention had been paid to the dressing of the stump, I could not refer this effect to the cause formerly supposed. But as on both occasions the artery had been cut before its division, while in all other cases it had been left entire, and as the flap, being deprived of nourishment from most of its ordinary sources, must be supplied with blood only through the successive anastomoses of small vessels, I concluded that this deviation from usual practice had led to the mischief in question, and I resolved to avoid it for the future.

A further cause of poor result from Syme's amputation was damage inflicted on the skin over the heel while the flap was being separated from the calcaneus or while the tendo achillis was being detached from its insertion. Unless the plane of dissection hugged the calcaneus, and unless the dissection was performed with precision and delicacy, the skin was apt to be buttonholed. It was this problem especially that led Pirogoff to introduce his operation and Guyon to devise his elliptical supramalleolar amputation at the ankle joint. Syme's amputation, then and now, is an operation which must conform rigidly to an exact technique. If it is not performed properly when first attempted, many of its advantages will be lost irretrievably. It is interesting that the technique necessary for success is almost exactly that which Syme himself ultimately evolved. As we shall see later in the section on technique, the only addition of proven value is subperiosteal separation of the calcaneus from the heel flap. All other attempts at improvement have failed to achieve the success which follows the use of Syme's original technique.

The 1914-1918 war, with its innumerable casualties, renewed interest in amputations. One outcome was the publication of an English translation of the small volume, *Artificial Limbs* (4), written by the French

surgeons Broca and Ducroquet. In discussing end-bearing stumps, this monograph makes no mention of Syme's amputation. It lists only supramalleolar amputation, disarticulation at the ankle joint, subastragaloid amputation, and osteoplastic amputation through the ankle joint. An editor's footnote with respect to supramalleolar amputation states, "In England, of course, this is always called a Syme's amputation." This statement is not strictly accurate since an important detail of Syme's amputation contributory to its success is the large area of support provided for the heel pad when the lower end of the tibia is left intact or virtually so. Syme's operation is not a supramalleolar amputation; it is a slightly modified disarticulation. French surgeons, particularly Farabeuf (12), were meticulous in distinguishing between disarticulations (in which group Syme's amputation was included) and amputations (*e.g.*, the supramalleolar operations of Roux and Guyon). It is true that Syme himself always referred to his operation as "amputation at the ankle joint," but in doing so he evidently used the term "amputation" in a general sense and not in the exact sense of Farabeuf. It is certain from Syme's description of his operations, and from the derivation of his operation from the disarticulation of Chopart, that Syme's operation was in fact disarticulation of the foot at the ankle joint with removal of the malleoli. Had Syme emphasized this as precisely as did Farabeuf, he might have prevented the innumerable supramalleolar Syme amputations which have been performed because of imperfect knowledge of Syme's technique or in the hope of obtaining an improved stump. These are the cases which have cast doubt on the value of Syme's operation, for the resulting stumps are functionally imperfect and may be complete failures.

E. C. Elmslie, who translated and edited the English edition of Broca and Ducroquet (4), formed a high opinion of Syme's amputation. In a footnote to the paragraph on low leg amputations allowing walking with end-bearing only, he says, after brief discussion of Pirogoff's amputation, subastragaloid amputation, and disarticulation at the ankle joint: "In fact, in this region there is Syme's amputa-

tion and a number of other far inferior amputations which should never be considered when a Syme amputation is possible." In 1924, in the section on amputations which he contributed to Carson's *Modern Operative Surgery* (11), Elmslie states with reference to Syme's amputation:

When successful it yields an excellent stump which is capable of complete end bearing. It can be fitted with a simple and cheap stump boot known as an elephant boot. Upon such a boot a patient with a Syme's amputation can often walk ten or twelve miles. In fact, Syme's amputation is so satisfactory that it may be said that all other amputations of the foot at a lower level are obsolete except amputation of the toes or parts of the toes.

Despite the high regard in which he held Syme's amputation, Elmslie does not appear to have understood how essential for success is exact adherence to the precise details of Syme's technique. For reasons which probably were related to limbfitting problems, Elmslie felt it necessary to secure an improved Syme stump, and for that purpose he devised a modified Syme amputation which is described in his chapter on amputations in Carson's *Modern Operative Surgery* (11). It is the only procedure for Syme's amputation that is described and illustrated there. Syme's original technique is not mentioned. Elmslie does not state clearly why he felt it necessary to revise Syme's technique. However, he does state that the Syme stump was too long and the end too bulky. Almost certainly these represent criticisms by the limbfitters of Elmslie's day, who certainly had difficulties in designing, manufacturing, and fitting a satisfactory prosthesis for a Syme stump.

#### ELMSLIE'S MODIFIED SYME'S AMPUTATION

Elmslie's modified Syme's amputation (11) differed from the classical Syme's amputation in three essential particulars:

1. The heel flap was smaller.
2. The dissection was carried out from the dorsal to the plantar surface.
3. The tibia and fibula were transected at a level well above the ankle joint.

Apparently the purpose of these changes was twofold: to provide a small, neat, tapered end to the stump and thus avoid the bulge in

the prosthesis necessary to accommodate a bulbous-ended stump; and to accommodate more easily the ankle-joint mechanism by high transection of the tibia and fibula.

Elmslie was not the first person to advocate high transection of the tibia and fibula to facilitate the introduction of an ankle joint mechanism in the artificial limb for a Syme amputation in the space between the end of the stump and the level of the ground. Henry Thompson (39), at a meeting of the Pathological Society of London on April 21, 1863, shared in the presentation of seven patients with Syme's amputation and two patients with Pirogoff's amputation. As reported in *Lancet*, Thompson's remarks were as follows:

He [Thompson] would not enter upon the various points of comparison between Syme's amputation and that modification of it in which a portion of the os calcis is left in the flap, but would only refer to the different results which remained after the two operations [*i.e.*, Syme and Pirogoff] as regards the kind of artificial limb which is applicable afterwards. He thought it very important for the surgeon and the mechanic to act in concert in most amputations of the lower extremity and he therefore showed also two artificial limbs to illustrate the advantage in relation to this matter which the proceeding of Syme offered over that of Pirogoff. In the former the patient enjoyed the advantage of complete ankle joint movement of the limb; while in the other, the stump being so close to the ground, there was no room for it and the best substitute that could be applied was by iron hinges outside of the limb. . . . Mr. Thompson wished to point out the necessity of taking off a sufficient slice of bone, including the two malleoli instead of merely removing the lower portion of the latter, so as to avoid extreme width and a bulbous stump which was more difficult to fit with a well made artificial limb than a stump which tapered gradually from the calf downwards. . . . Mr. Thompson said that the objection to the bulbous form of the stump did not materially apply if the common circular shoe which is laced around the lower part of the leg was worn [elephant boot], but it did to the artificial leg.

In Elmslie's operation the skin incision was an ellipse (Fig. 15) which commenced on the plantar surface of the foot 3/4 in. in front of the point of the heel. Therefrom it extended obliquely upward and forward over either malleolus to a point on the anterior surface of the ankle 1 in. above the joint line. The ankle joint was entered, the foot depressed, and the medial and lateral ligaments of the joint divided from within the joint. The astragalus was then dislocated from the mortise

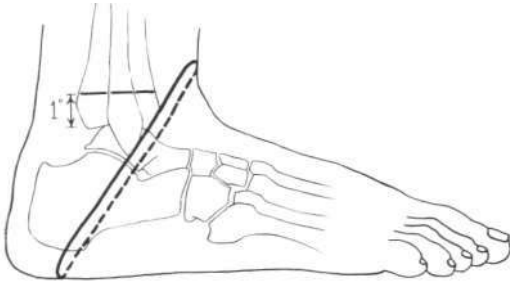


Fig. 15. Elmslie's modified Syme's amputation. Redrawn from Elmslie (11).

of the ankle joint by depressing the foot still farther. Doing so exposed the tendo achillis, which was then divided at its insertion. The calcaneus was then separated from the heel flap by dissection close to the bone from above downward. The tibia and fibula were transected  $3/4$  in. to 1 in. above the highest level of the ankle joint, and the heel flap was then closed over the ends of the tibia and fibula.

Though Elmslie intended his modified Syme's amputation to be an improvement over Syme's original procedure, the result has not lived up to his expectations, and for three reasons: the small heel flap deprived the stump of an adequate covering of skin and subcutaneous tissue adapted to weight-bearing; the high transection of the tibia and fibula diminished the cross-sectional area of their cut surfaces and impaired their support for weight-bearing; the end of the stump was no longer bulbous but was tapered, a feature that permitted the artificial limb to slip up and down during walking. He succeeded in simplifying the limbfitters' problem, and he succeeded in making the stump neat and tidy, but in so doing he sacrificed the qualities of Syme's amputation essential for success—namely, a bulbous stump end to ensure that the grasp of the prosthesis would be secure and a wide area of bony support covered by a large, thick, heel pad adapted to weight-bearing.

Elmslie's modified Syme's amputation thus closely resembled Guyon's elliptical supramalleolar operation with posterior flap (4,15). It seems probable that in modifying Syme's operation Elmslie adopted Guyon's technique, for the only difference between Guyon's

elliptical supramalleolar amputation and Elmslie's modified Syme's amputation was that in the former, unlike the latter, a flake from the posterior end of the calcaneus was removed along with the insertion of the tendo achillis and that later the flake was applied to the cut surface of the tibia when the heel flap was sutured into place. Elmslie's modified Syme's amputation was widely used in England (but not in Scotland) during the period following the 1914-1918 war, probably because of the confidence with which he advanced it as an improvement over Syme's technique and probably also because he made no mention of Syme's technique (11). It is likely that this adoption of his modified Syme amputation in England led to the dissatisfaction with Syme's amputation expressed by Langdale-Kelham and Perkins of Queen Mary's Hospital at Roehampton (23). They said ". . . this type of operation does not stand weight bearing on the average longer than eight years. . . . It is to be hoped that the modified Syme's amputation will soon be as obsolete as the original Syme's." The handbook of the British Ministry of Pensions, *Artificial Limbs and their Relation to Amputations* (1), also speaks with faint praise of Syme's amputation. In Scotland, in contrast to England, a rigid adherence to the precise details of Syme's original technique resulted in satisfactory end-bearing stumps. In Canada, for a similar reason, experience has also been satisfactory. The favorable results with Syme's amputation in Scotland and Canada as contrasted with the dissatisfaction with Syme's amputation in England is evidence that a wide area of bony support covered by a large, thick, heel pad is essential for a satisfactory Syme's stump. Syme's original operation provided these indispensable features, and consequently his stumps bore weight on the end satisfactorily and more or less indefinitely. Attempts to improve upon Syme's amputation (e.g., the modifications of Roux and of Elmslie), chiefly in the matters of making the end of the stump neat and of providing the limbmaker with more space for the ankle joint of the prosthesis, proved unsatisfactory in the long run because the area of support was too small and because the covering over the end of the



stump would not stand up under long-continued end-bearing.

Syme was blessed by good fortune as well as good sense. His sound judgment brought him to the conclusion that disarticulation at the ankle joint and removal of the malleoli would constitute a safe and effective means for the removal of a damaged or carious foot. The idea of preserving the heel flap to cover the end of the stump and to provide end-bearing could have come only from profound insight. His courage, boldness, and skill enabled him to devise a simple technique by which these things could be accomplished. It was his good fortune that the operation he planned and the technique he devised have both proved to be of continuing value. He knew nothing of the minutiae which concern us today, and he ill understood the grave complications which often discounted the surgeon's efforts. But he was far-sighted enough and bold enough to embark upon a radically new approach to an old problem, to build upon his first successes, and to eliminate such defects as were present in his first efforts (*e.g.*, to preserve the integrity of the posterior tibial artery).

#### FUNDAMENTAL PRINCIPLES OF END-BEARING AMPUTATIONS OF THE LOWER EXTREMITY

The essential functions of the normal lower extremity are weight-bearing and locomotion, and amputation stumps in the lower extremity must be designed accordingly. The more perfectly they bear the body weight and transmit the forces of locomotion the more efficiently will they utilize prosthetic appliances. For purposes of weight-bearing, nothing is as satisfactory as a stump which can bear weight upon its end. Propulsion is best accomplished by a leg stump of the greatest possible residual length and with as many normally functioning nerves, muscles, and joints as can be preserved. Only two levels in the lower extremity can be adapted to provide end-bearing stumps—the lower end of the femur with a covering of prepatellar skin, and the expanded lower ends of the tibia and fibula covered by the heel pad.

To secure an end-bearing stump in lower-

extremity amputations, certain requirements must be met:

1. In order to provide a broad area of support, the bone must be divided where its cross-sectional area is as great as possible.

2. The whole of the cut surface of the bone must be capable of bearing weight. This requirement can be achieved by a strong meshwork of cancellous bone across the whole area, or, in the case of the ankle joint, by retention of the subarticular cortical bone at the lower end of the tibia. The tubular cross-section of the shaft of the tibia at higher levels is unsuited to weight-bearing.

3. The skin and subcutaneous tissue covering the end of the stump must be appropriate for weight-bearing.

4. The weight-bearing skin must be properly centered upon the area of support and firmly attached to it.

5. The end of the stump must be bulbous, thus ensuring that the prosthesis will not slide off the stump or rotate upon it.

Syme's operation, properly performed, meets all these requirements. For conditions which require amputation in the vicinity of the ankle joint, it provides a stump superior to all others. But the initial operation provides the sole opportunity for securing a Syme stump satisfactory in all respects. Even minor deviations from detail are prone to result in a stump imperfect in one way or another, and such imperfections usually cannot be corrected by secondary operations. If the imperfection is not great, the stump may function reasonably well, for some time at any rate, but it may not stand up indefinitely, as has proved to be the case with Elmslie's modified Syme's amputation.

Because preservation of the unique structure of the heel pad is essential for attaining a perfect Syme stump, it is appropriate now to describe its specialized nature. In the human heel, as in other parts of the body adapted to weight-bearing (finger tips, thenar and hypothenar eminences, ischial tuberosities, and prepatellar pads), the ability to withstand the stresses imposed by the weight of the body and by body movements derives in part from the thickness of the skin and in part from a special elastic adipose tissue beneath the skin. Of the two, the latter is the more important, for without the buffering action of this elastic adipose tissue not even a thick layer of skin

can provide satisfactory protection against the stresses of weight-bearing.

Kuhns (21) has reviewed our knowledge of elastic adipose tissue and has brought to our attention the detailed studies of Tietze (40) and Blechschmidt (3). Kuhns shows that the stress-absorbing qualities of the subcutaneous layer in areas adapted to weight-bearing are due to its structure and to the elastic qualities of its connective tissues. In these areas the subcutaneous tissue consists of dense septa of elastic connective tissue which completely enclose spaces rilled with fat cells. Each such loculus is separate from its neighbour, and the fat cells within it are isolated from the surrounding loculi. In the heel pad, the fibrous septa extend from the dermis below and are attached above to the calcaneus posteriorly and to the plantar aponeurosis anteriorly. The flasklike spaces are filled with fat cells, and their walls are reinforced by oblique and spiral bands. These compartments, bounded by sheets of elastic fibrous tissue and filled with semifluid fat, act as hydraulic buffers. Under pressure they

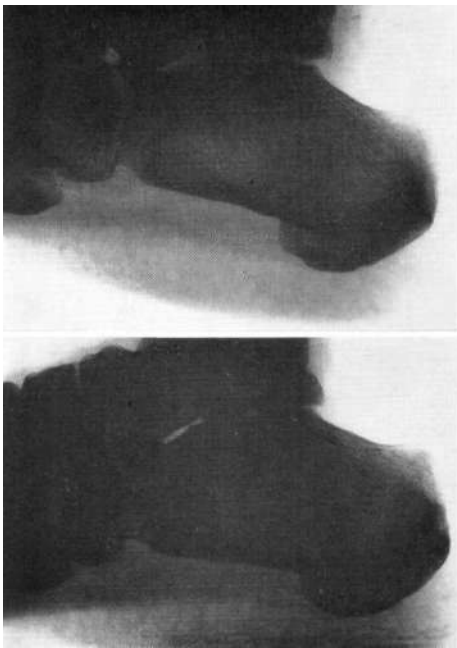


Fig. 16. Structure of the heel pad as revealed by radiograph. Top, without weight-bearing, bottom, patient standing.

change form but not contents. When pressure is released, they resume their normal size and shape owing to the elasticity of the walls. A lateral radiograph of the heel, if not over-exposed, often will reveal this fundamental structure of the subcutaneous tissue. The vertical septa of the relatively dense, elastic, connective tissue are readily seen extending upwards from the skin below to be attached above to the calcaneus posteriorly and to the plantar aponeurosis anteriorly (Figs. 16, 17, 18, 19, 20, 21, and 22).

It is important to preserve intact this specialized subcutaneous tissue in the heel flap of a Syme stump; otherwise the weight-bearing qualities will be impaired. To do so necessitates removal of the periosteum and the plantar aponeurosis with the heel flap, since these elements form the superior attachment of the septa. If the heel flap is dissected through the layer of subcutaneous tissue (*i.e.*, between the periosteum and the plantar aponeurosis above and the dermis below), the septa will be divided and the loculi opened, thus allowing the fat cells to leak out. In such circumstances, the distinctive structure and function of the elastic adipose tissue is lost,

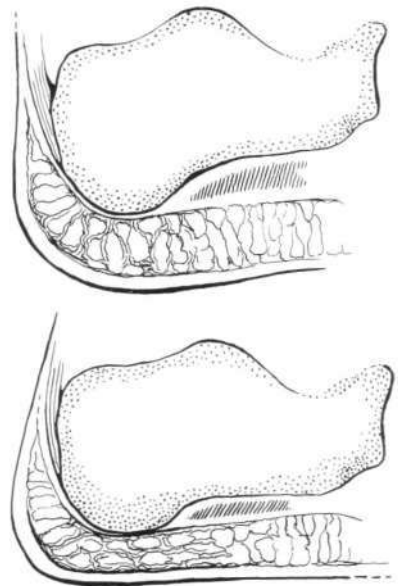


Fig. 17. Structure of the heel pad, diagrammatic representation reproduced from radiographs. Top, without weight-bearing; bottom, patient standing.

for then the tissue no longer consists of separate, elastic-walled spaces enclosing fat under tension. Once the elastic adipose tissue has been damaged, its stress-resistant properties cannot be restored.

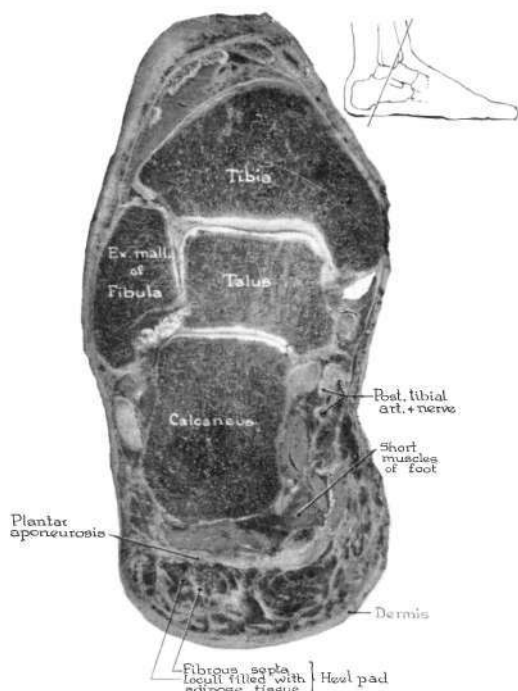


Fig. 18. Anatomy of the field of Syme's amputation. Insert shows the plane of the section.

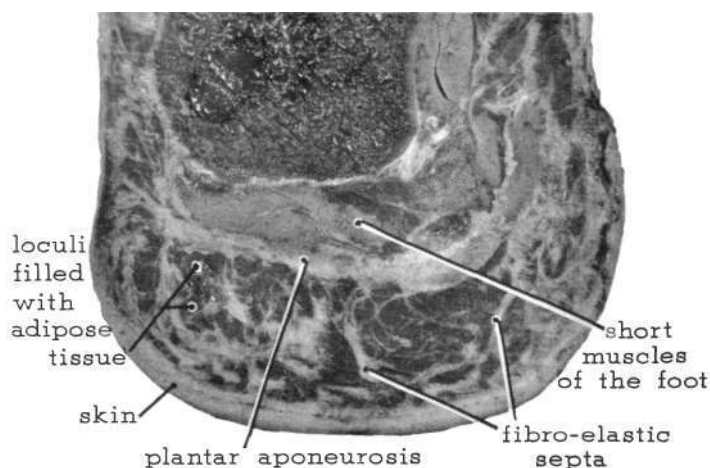


Fig. 19. Structure of the heel pad in Syme's amputation. Coronal section enlarged from Figure 18.

#### THE TECHNIQUE OF SYME'S AMPUTATION

In the five papers Syme wrote between 1843 and 1846 there is no complete and formal description of the technique of his operation, and there is only one inadequate illustration (Fig. 23). Scattered throughout the papers, however, are comments on various points in the procedure, and when the articles were gathered together and republished in the volume *Contributions to the Pathology and Practice of Surgery* (36) there was included an addendum concerned chiefly with certain details of the operation, particularly the technique for separation of the heel flap from the calcaneus. Therein, after emphasizing the desirability of "preserving entire the thick integuments of the heel to form a cushion for the stump," and after ascribing the known failures either to lack of skill in removing the flap from the calcaneus or to the use of flaps of skin other than that from the heel, Syme describes his technique as follows:

The foot being placed at a right angle to the leg, a line drawn from the centre of one malleolus to that of the other, directly across the sole of the foot will show the proper extent of the posterior flap. The knife should be entered close up to the fibular malleolus and carried to a point to the same level on the opposite side, which will be a little below the tibial malleolus. The anterior incision should join the two points just mentioned at an angle of  $45^\circ$  to the sole of the foot and the long axis of the leg. In dissecting the posterior flap, the operator should place the fingers of his left hand upon the heel, while the thumb rests upon the edge of the integuments, and then cut between the nail of the thumb and the tuberosity of the os calcis so as to avoid lacerating the soft parts which he, at the same time, gently but steadily presses back until he exposes and divides the tendo achillis. The foot should be disarticulated before the malleolar projections are removed, which it is always proper to do, and which may be most easily effected by passing a knife around the exposed extremities of the bones and then sawing off a thin slice of tibia, connecting the two processes.

Scattered throughout the five papers are some other details worth noting. Syme found it important to avoid division of the posterior tibial

artery above its branching into the median and lateral plantar arteries; otherwise there was risk that the flap would slough. Separation of the heel flap, while not easy, could be accomplished satisfactorily by keeping close to the bone. The heel flap was not to be unduly large lest its circulation be impaired. Though Syme freed the heel flap before he dislocated the talus from the ankle joint, it was not long before surgeons were freeing the ankle joint first and dissecting the calcaneus

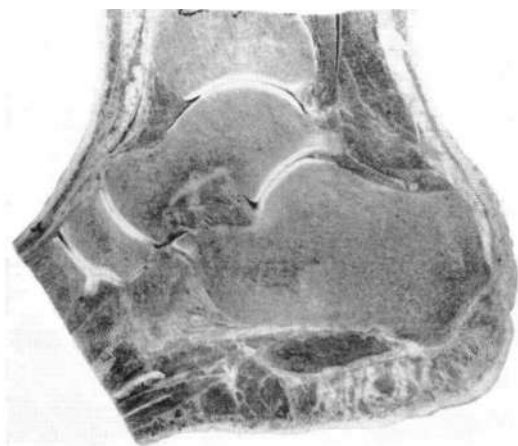


Fig. 20. Longitudinal section of foot to show structure of heel pad.

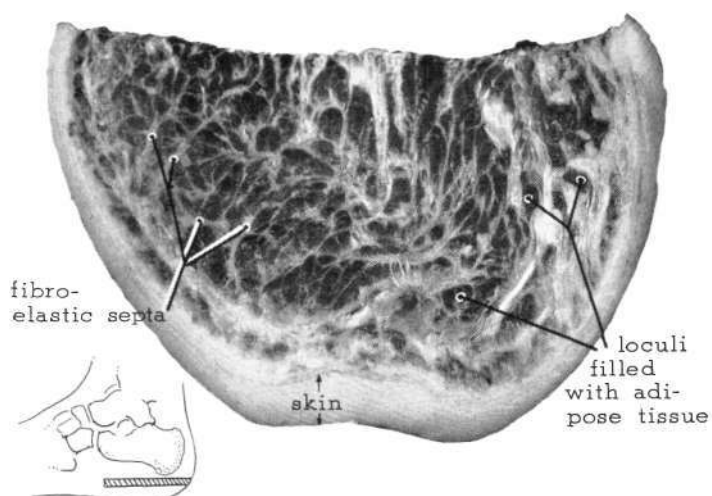


Fig. 21. Horizontal section through heel pad to show structure. This specimen is a slice of the heel pad cut parallel to the sole of the foot and midway between the skin and the inferior surface of the calcaneus. The skin surface is on the back and either side of the heel. Insert shows plane of section.

from the heel flap downward from above, and this approach is part of our present procedure (19).

Today, when the problem of infection is not paramount, the purpose of the operation is, first, to remove the foot by disarticulation at the ankle joint and without damage to the specialized structure of the heel flap; second, to remove the malleoli and trim the lower ends of the tibia and fibula so as to provide a broad support for weight-bearing; third, to fashion from the heel a flap with unimpaired blood supply and with its weight-bearing mechanism undamaged; and, last, to secure this heel flap firmly and accurately to the lower ends of the tibia and fibula. The resulting stump should have a bulbous end to facilitate maintenance of the prosthesis on the stump. To meet these requirements, the skin incisions should be so designed as to give a heel flap of generous size but not so large that its blood supply will be impaired. This shape and size may be obtained by tilting the plantar incision slightly forward. Syme advocated a smaller heel flap because he feared necrosis from impaired circulation. Today, with the risk of infection removed, the larger heel flap, if carefully separated from the calcaneus, need not suffer from impaired circulation, and when sutured in place it has the advantage of overlapping and protecting the anterior margin of the lower end of the tibia.

The lower ends of the tibia and fibula are fashioned with a saw cut which removes the medial and lateral malleoli and shaves off the articular surface of the tibia. The plane of this saw cut must be parallel to the ground when the patient stands (Fig. 24). That is to say, in all cases the tibia must be transected to suit the individual case and not necessarily in the same plane as the articular surface of the tibia or at right angles to the long axis of its shaft. The transection of the tibia and fibula must

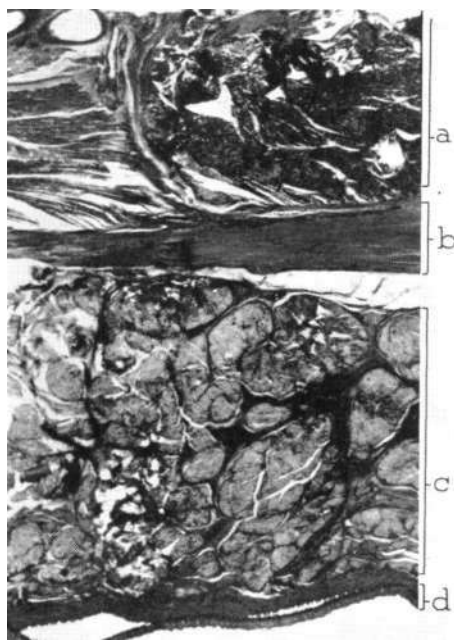


Fig. 22. Vertical section through heel flap, approximately 8X. *a*, Bellies of short muscles of foot; *b*, plantar aponeurosis; *c*, specialized elastic adipose tissue; *d*, skin.

be as low as possible to ensure that an area of support as broad as possible is obtained. With the modern type of Syme prosthesis, the resulting long stump presents no problem in fitting.

The fashioning of the heel flap and its proper attachment to the lower ends of the tibia and fibula are important steps in the operation. Preservation of the specialized fibroelastic subcutaneous tissue and the posterior tibial artery can best be assured by subperiosteal separation of the heel flap from the calcaneus. While this is a procedure somewhat more precise than that recommended by Syme (who advised that the flap be separated from the calcaneus by dissection with a sharp knife in a plane close to the bone), today with modern techniques and instruments it is easy to accomplish the desired result. The only step likely to give any difficulty is the detachment of the tendo achillis from the calcaneus, since in this situation there is no plane of cleavage. The tendon must therefore be divided carefully at its insertion close to the bone in

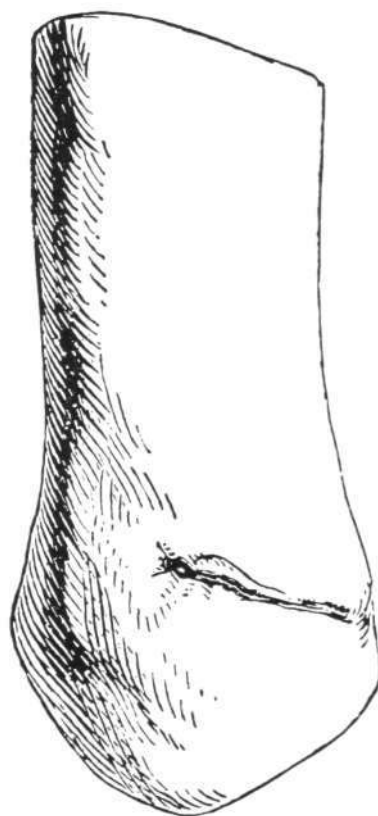


Fig. 23. The only illustration included by Syme in any of his publications on amputation at the ankle joint. It appeared in the *London and Edinburgh Monthly Journal of Medical Science* (32), with the following comment in the text: "The stump has the shape here represented, conical in form on the inferior surface and having for its apex, or central point of pressure, the thick integument which covered the heel." This illustration was not included when the five papers (30, 31, 32, 33, 35) on *Amputation of the Ankle Joint* were reproduced in *Contributions to the Pathology and Practice of Surgery* (36).

order to avoid damage to the skin close behind it.

Subperiosteal dissection of the calcaneus from the heel flap has one advantage not envisioned by Syme. Besides preserving the posterior tibial artery and the weight-bearing structure of the heel, it leaves a heel flap lined with periosteum, which more readily and more firmly adheres to the cut surfaces of the tibia and fibula. Henry Thompson (39) must have had something of this nature in mind when he advocated leaving a flake of the os calcis in

the heel flap. As can be seen in radiographs (Figs. 25 and 26), new bone sometimes forms from the periosteal lining of the heel flap, in which case there is very firm fixation of the heel flap to the tibia and fibula. In this connection, it is interesting to note an observation of Jacobson (19). In discussing Syme's amputation, he describes the technique of removal of the calcaneus from the heel flap by an approach from above:

The foot being still more pressed (*i.e.*, downward to dislocate the talus from the ankle joint), the upper nonarticular surface of the os calcis comes into view and then the tendo achillis. This is severed and the heel flap next dissected off the os calcis from above downwards, special care being taken to cut this flap as thick as possible, not to score or puncture it, but rather to peel it off the bone with the left thumb nail kept in front of the knife aided by touches of this.

Thereto is appended a footnote:

If, in a young subject, the epiphysis comes away in the heel flap, it may remain there if the parts are healthy. *The same course may be followed with the periosteum if it is found loose and peels away.* Mr.

Johnston Smith, when amputating both feet for frost-bite, left the periosteum on one side; on the other no attempt was made to save it. The first stump was much larger than the other, harder and more rounded, more like that of Pirogoff's amputation.

Published in 1889, this comment preceded introduction of the roentgen ray. In all respects, save the radiographic proof, it indicates clearly that subperiosteal separation of the heel flap results in more firm attachment of

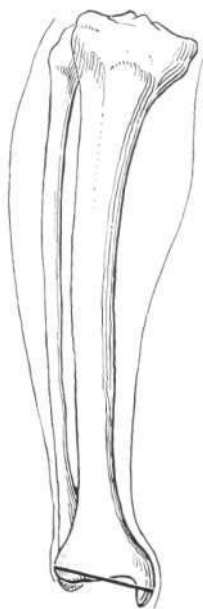


Fig. 24. Proper saw line for Syme's amputation, when tibia is abnormal or deformed. The plane of section of the lower ends of tibia and fibula is not necessarily that of the inferior articular surface of the tibia but must in all cases be parallel to the ground when the patient stands erect. When for example the tibia is bowed, as represented here, the plane of section is horizontal and not at 90 degrees to the long axis of the bone.

flap to the tibia and fibula than is the case when the periosteum is not preserved.

When stresses come upon a heel flap not firmly attached to the cut surfaces of the tibia and fibula, it wobbles and thus loses some of its functional value. Moreover, the tendo achillis and the peroneal tendons buried therein drag the heel flap this way or that when they contract (Figs. 27 and 28). Both of these problems can be eliminated by subperiosteal separation of the calcaneus from the heel flap, for doing so ensures firm fixation of the flap to the cut ends of the tibia and fibula.

A heel flap which has been formed by subperiosteal dissection from off the calcaneus is clumsy and untidy in appearance. It is a deep, cup-shaped structure covered with thick skin and rendered bulky at its anterior end by the

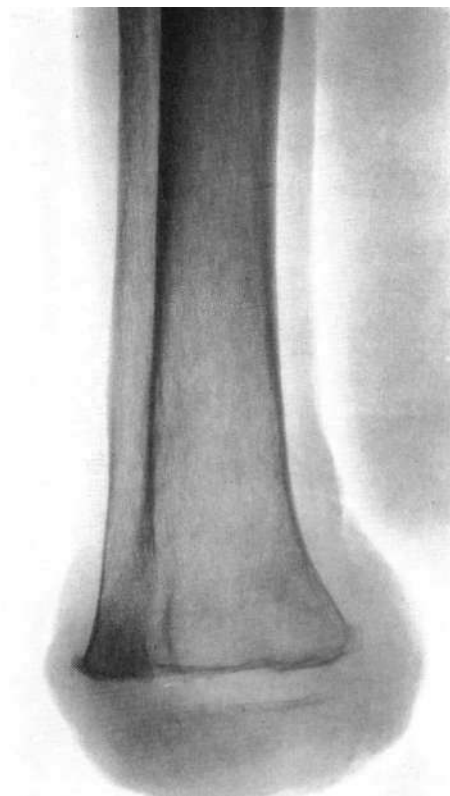


Fig. 25. A flake of new bone laid down in the heel flap of a Syme stump, the result of subperiosteal separation of the heel flap from the calcaneus. Firm fixation of the heel flap to the cut surfaces of the tibia and fibula is thus ensured.

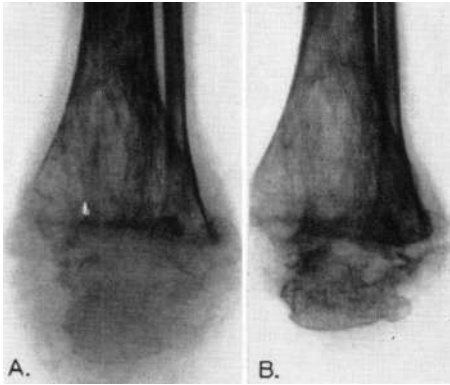


Fig. 26. A large mass of bone laid down in the heel flap of a Syme stump. *A*, four months after operation; *B*, one year after operation. This unusually large cloud of new bone resulted from the stimulation of the periosteum by the inflammatory reaction to tuberculosis of the tarsus, the reason for the amputation.

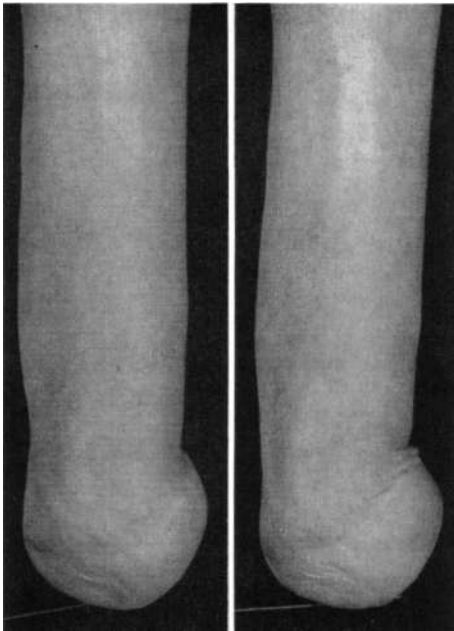


Fig. 27. Misplaced and unstable ("wobbly") heel flap, the result of tidying up the heel flap by removal of the stumps of the short plantar muscles and with them the plantar aponeurosis and the periosteum of the calcaneus. The result is a heel flap imperfectly fused to the end of the tibia and in bad position. Left, muscles at rest and heel pad held as nearly as possible under the tibia by elastic traction; right, contraction of peroneal muscles drags the unstable heel flap toward the lateral side of the stump.

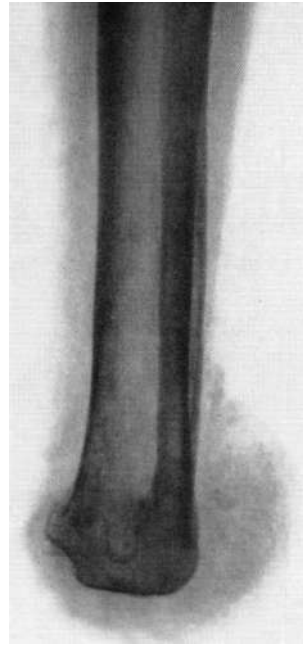


Fig. 28. Radiograph of the imperfect Syme stump shown in Figure 27. In addition to the unstable and misplaced heel flap, the high level of transection of the tibia and fibula limits the area available for support. In spite of these defects, the stump has functioned reasonably well for 12 years.

inclusion of the bellies of origin of the short plantar muscles. The instinct of every meticulous surgeon is to tidy it by removal of these bulky muscle stumps, but it is best to leave them in place. They do no harm, and any attempt to remove them may damage the specialized, weight-bearing, subcutaneous tissue by removing with them the plantar aponeurosis, from which the fibrous septa originate.

The detailed steps (Figs. 29, 30, 31, and 32) in the operation as at present performed are as follows:

1. Apply an air-pressure tourniquet to the thigh.
2. With the foot at a right angle to the tibia, make two incisions: First, from the tip of the lateral malleolus, across the sole of the foot to a point just below the tip of the medial malleolus, the cut being made through all the soft tissues directly down to the tarsal bones. At its center, this plantar incision should be curved slightly forward from the tips of the malleoli, rather than the reverse, so that the center of the flap will be elongated to facilitate covering the anterior margin of the cut sur-

face of the tibia when the wound is closed. Second, a dorsal incision joining the upper ends of the plantar incision and running upward and forward at an angle of 45 deg. from the line of the tibia and from the plantar surface of the foot. It bisects the angle between the tibia and the foot. Through it the ankle joint is entered.

3. With the ankle joint open, plantar flex the foot and divide the tibial and fibular collateral ligaments of the ankle from within the joint. On the medial side, be careful to avoid the posterior tibial artery.

4. Dislocate the talus downward from the mortise of the ankle joint, open the posterior part of the capsule of the ankle joint from within, and expose the posterosuperior nonarticular surface of the calcaneus and the anterior surface of the tendo achillis just above its insertion.

5. With a periosteal elevator (Bristow raspator), enter the subperiosteal plane on the medial and lateral sides of the calcaneus and extend this subperiosteal dissection to the inferior surface of the bone. Tilt the foot first into inversion and then into eversion and continue the subperiosteal freeing of the calcaneus on its inferior surface. Then work forward in the subperiosteal plane on the medial, lateral, and inferior surfaces of the calcaneus. Detach the origin of the long plantar ligament from the tuberosity of the calcaneus, and continue in the subperiosteal plane until the plantar skin incision is reached and the anterior end of the bone is free. Work backward in the subperiosteal plane until the whole of the calcaneus is free except at the insertion of the tendo achillis. With a knife, carefully divide the tendo achillis working downward from above. Stay close to the bone and avoid damaging the skin flap behind the tendo achillis. Remove the talus and calcaneus together with the damaged portion of the foot. If this step is accomplished successfully, the posterior tibial artery will be unharmed. Only its plantar branches will have been cut by the primary plantar incision. Do nothing to the posterior tibial nerve, which also will have been cut by the primary plantar incision.

6. Carefully turn the heel flap backward and upward, and free the malleoli and the lowest 1/4 in. of the tibia. Remove the malleoli and a thin slice of the lower end of the tibia by a saw cut. Be certain that the saw

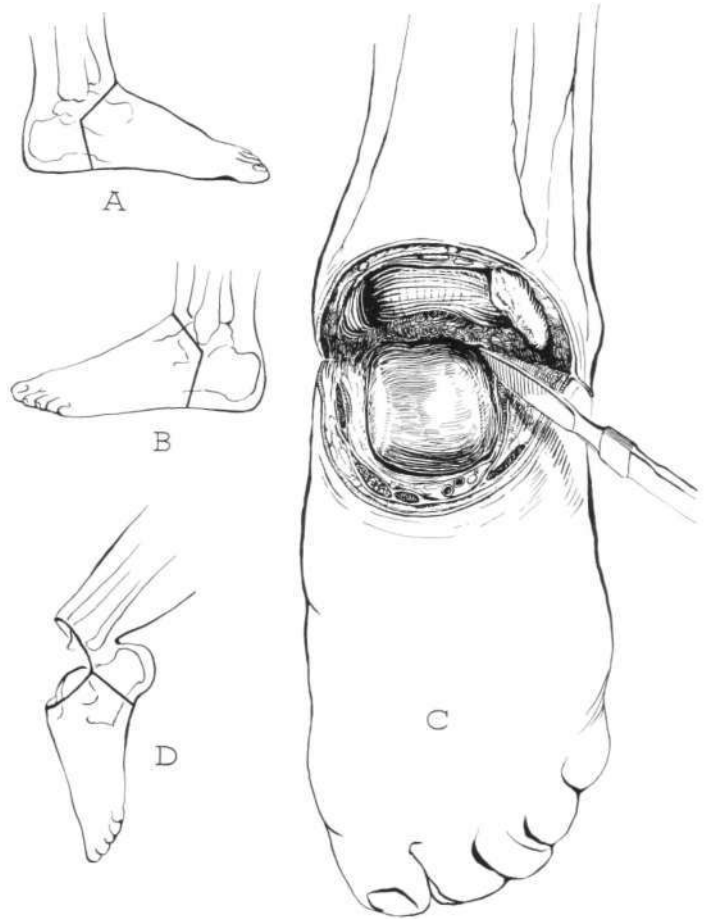


Fig. 29. Technique of the Syme amputation. A, Skin incisions from the medial side; B, skin incisions from the lateral side; C, division of the collateral ligaments from within the joint; D, dislocation of the talus downward from the mortise of the ankle joint.

cut will be parallel to the ground when the patient is standing. The amount of tibia removed should be the thinnest possible shaving from its lower end, the sub-articular cortical plate being conserved if possible. In any case, be certain that the largest possible cross-sectional area of the tibia and fibula is obtained to ensure a broad area of support (Fig. 33).

7. Remove the tourniquet and secure perfect haemostasis. Do not trim the heel flap, much as you may desire to make it tidy.

8. With interrupted sutures of chromic catgut #0 for the subcutaneous layer and interrupted everting mattress sutures of braided nylon for the skin margins, suture the margin of the heel flap to the margin of the anterior incision across the front of the ankle joint. Suture nothing but the subcutaneous layer and the skin. To drain the dead space, enclose across the wound a section of Penrose tubing and allow the ends to come out



at either corner of the wound. The line of suture should be slightly above the anterior margin of the cut surface of the tibia so that cut ends of the bones fit into the cup of the heel flap.

9. In closing the wound, pay no attention to the disparity in size, shape, and thickness between the heel flap and the skin margin to which it will be sutured. Center the hollow of the heel flap beneath the cut ends of the tibia and fibula as accurately as possible, and begin the suture line in the center anteriorly and work to either end. Do nothing to the "dog ears" of skin which project at the corners of the approximated skin margins. In time they will shrink and disappear. To trim them invites impairment of circulation.

10. The heel flap thus sutured is attached only at its margin and is not yet fixed firmly to the cut surfaces of the tibia and fibula, and accordingly it can be moved about in relation to them. It needs to be secured and maintained in a proper position. To do so, hold the heel flap accurately centered beneath the cut surfaces of the tibia and fibula and secure it in this position by two strips of adhesive tape fastened U-shaped across the end of the stump in the anteroposterior and mediolateral directions (Fig. 32). Adhesive tape is better than pins transfixing the heel pad to the tibia, as has sometimes been advocated. Do not apply the adhesive strips too tightly.

11. Dress the wound with two layers of surgical pads smoothly applied and held in place by a mildly compressive bandage. Flannelette cut on the bias is ideal, although cotton-crepe bandage (without elastic) will do if not applied tightly.

12. *Important.* Open the dressing 24 hours after the operation and every second day thereafter, and inspect the position of the heel flap in relation to the lower ends of the tibia and fibula. Adjust or renew the adhesive strips if necessary to maintain the correct position of the heel flap. If the operative dressing is left unchanged, the heel flap may unite asymmetrically. The stump must be inspected frequently in the postoperative period, and adjustments of the position of the heel flap must be made when necessary. Remove the Penrose tube about the sixth day.

13. Maintain a firm dressing until the wound is healed and the stitches are removed (about two weeks). Support the stump thereafter with a cotton-crepe elastic bandage until the first limb is fitted. At the end of four weeks, the patient may begin to put weight on the end of the stump. A prosthesis may be fitted at the end of two months, though it will require a new socket within a year, when shrinkage of the calf muscles is complete.

#### IMPERFECTIONS WHICH IMPAIR THE FUNCTION OF THE SYME STUMP—How TO AVOID OR CORRECT THEM

Not all Syme stumps are perfect, but nearly all imperfections can be avoided by meticulous attention to the details of the operation. Too much emphasis cannot be placed upon a proper

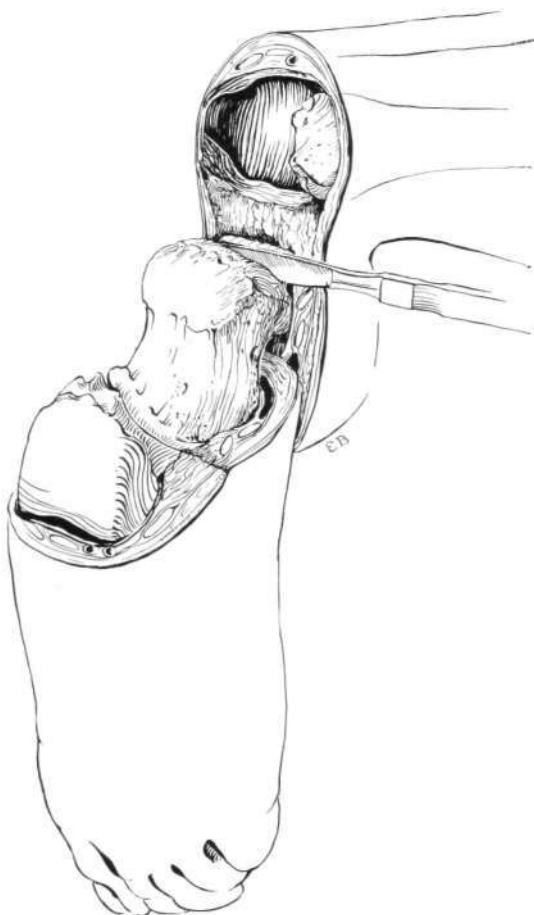


Fig. 30. Technique of the Syme amputation, continued. The talus has been dislocated from the ankle joint. The calcaneus has been separated almost completely from the heel flap by subperiosteal dissection. The tendo achillis is about to be divided at its insertion.

understanding of the principles of the amputation and upon its proper performance. Although some imperfections can be compensated for in the fitting of the prosthesis or in the manner of its use, and although some can be eliminated by revision operations, others cannot be overcome at all, usually because of faulty performance of the initial operation.

#### DAMAGE TO THE WEIGHT-BEARING STRUCTURE OF THE HEEL FLAP

A serious imperfection, which cannot be corrected by further operation, is damage to the weight-bearing structure of the heel

flap. This is almost always due to the manner in which the operation is performed. Care must be taken to preserve intact the specialized subcutaneous fibroelastic tissue of the heel pad. As previously indicated, this can be accomplished most certainly by attention to two details in the operation: subperiosteal separation of the heel flap from the calcaneus and avoidance of any attempt to tidy the clumsy flap by removing the stumps of origin of the small muscles of the foot. If these steps in the operation are properly performed, the specialized subcutaneous tissue will remain intact and its function will be unimpaired. On the other hand, if the plane of the subcutaneous tissue is entered during the operation, there will be more or less impairment of its structure and function. This is the prime example of the necessity to perform Syme's amputation by a technique which adheres rigidly to the basic principles of anatomy. There is only one opportunity to fashion a Syme stump of the best quality and that is the occasion of the primary operation. If this is performed skillfully and with due regard for basic principles, it will produce a good end-bearing stump. If the basic principles are disregarded, or if the operation is performed carelessly, the weight-bearing qualities of the flap are likely to be impaired, and they cannot be restored by any subsequent operation.

While a defective Syme stump deprives the patient of the comfort and good function he would enjoy with a perfect stump, it may still be sufficiently useful to make it worth while retaining. Reamputation at a higher level is not always inevitable (28). Even an imperfect Syme stump may be more useful than a below-knee amputation. Therefore reamputation at a higher level because of an

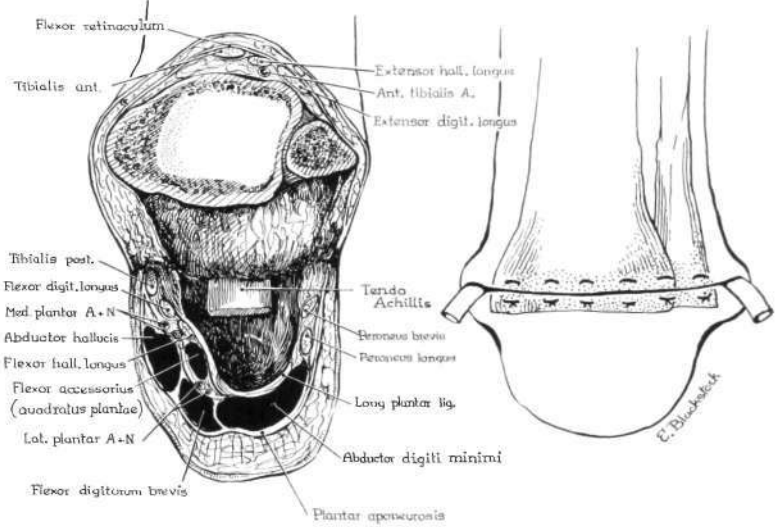


Fig. 31. Technique of the Syme amputation, continued. Left, the anatomy of the field of operation after the tarsus has been removed from the heel flap; right, closure of the wound with drainage.

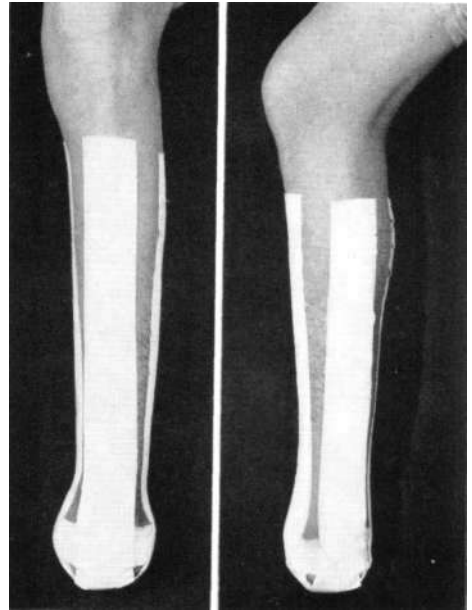


Fig. 32. Technique of the Syme amputation, continued. The method of strapping the heel flap to the leg to ensure that its position in relation to the cut ends of the tibia and fibula is exactly correct and will remain so.

imperfect Syme stump should be undertaken only after the most careful consideration of every aspect of the problem.

Besides damage to the heel flap, and consequent impairment of the weight-bearing

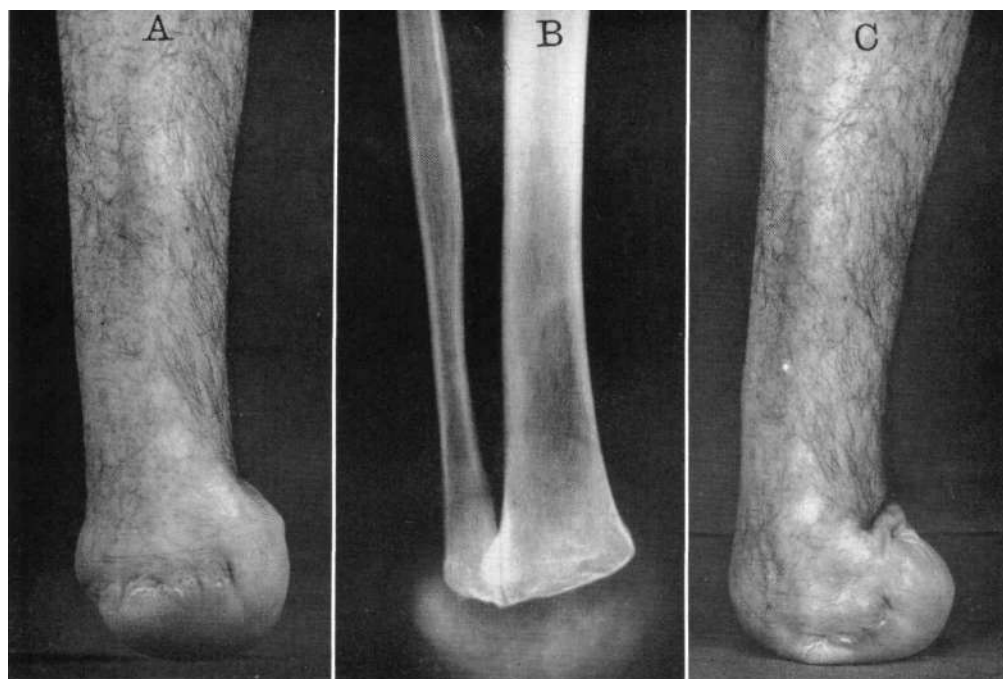

Fig. 33. Oblique transection of lower end of tibia results in displacement of heel pad to high side. *A*, The stump when no weight is upon it; the heel pad is displaced medially. *B*, Radiograph of stump; tibia transected obliquely, higher on the medial than on the lateral side. *C*, The stump bearing weight; the heel pad is markedly displaced to medial side. The function of this heel flap (which already is unstable and misplaced) is impaired still more by the displacement which occurs when weight is borne upon it. This is the result of oblique section of lower end of tibia.

qualities of the stump, a number of other faults can impair the functional value of a Syme amputation.

#### MISPLACED HEEL FLAP

Care must be taken to secure the heel flap beneath the tibia in such a manner that the plantar surface of the flap is exactly beneath the center of the lower end of the tibia. To keep it there necessitates painstaking care and supervision during the immediate postoperative period. The heel flap being a large, cup-shaped structure, loosely attached to the leg, it must be secured in its proper position by adhesive strips and maintained so until healing has fixed it to the lower end of the tibia (Fig. 32). If postoperative inspection is neglected, the heel flap may be pushed out of place by the dressing and may unite to the tibia displaced to one side or the other or backward. Its end-bearing capability is then impaired. Fortunately, if the specialized

fibroelastic adipose tissue has not been damaged, malposition of the heel flap can be corrected by detaching it and replacing it in its proper position.

#### SLOPING SURFACE OF LOWER END OF TIBIA

If the cut surface of the lower end of the tibia is not parallel to the ground when the patient stands, the heel flap tends to be pushed to the high side of the slope (Fig. 33). The plane of transection must therefore be parallel to the ground when the patient stands no matter what its geometric relationship to the long axis of the tibia. If there is any bowing or other deformity of the tibia, the proper plane of transection may actually be oblique to the long axis (Fig. 24). The particular circumstances in the individual case must be assessed at the time of the primary operation to make certain not only that the plane of section of the lower surface of the tibia is parallel to the ground but also that the maxi-

imum area of bony support for the heel flap is secured (Fig. 34). Any operation to revise an improper bearing surface must necessarily be at a higher level where the cross-sectional area for support is smaller (Fig. 24).

"WOBBLY," OR UNSTABLE, HEEL FLAP

If the heel flap is loosely attached to the lower end of the tibia, it is easily displaced, and pressure while walking or standing may wipe it to one side or the other or backward. Similarly (Figs. 27 and 28), it may be pulled out of place by the stumps of the tendons that are embedded in it, the tendo achillis and the peroneal tendons being the chief offenders. Because the thrust of weight-bearing cannot be maintained through the center of the flap, even when the prosthesis is snugly fitted, an unstable heel flap does not bear weight satisfactorily. The anterior margin of the lower end of the tibia presses through the scar of the anterior suture line, and the patient stands insecurely upon the shifting end of his stump. A flaccid, loose, heel flap occurs when the plane of separation is through the subcutaneous elastic adipose tissue. It can be prevented by subperiosteal dissection of the heel flap. The deep surface of the flap then attaches itself firmly to the cut surface of the bone, and the intact pad of weight-bearing subcutaneous tissue resists changes in shape. An unstable heel flap can be avoided only by proper operative technique. Once it exists it cannot be corrected by further operation though its shortcomings may be minimized by modifying the fit of the prosthesis.

NEUROMA ON POSTERIOR TIBIAL NERVE

In the surgery of the Syme amputation,

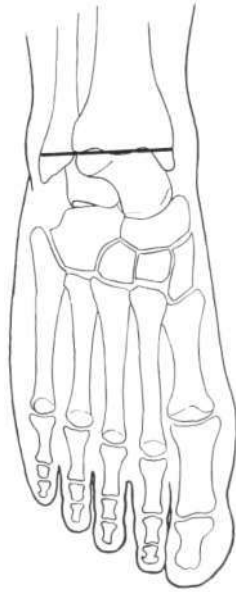


Fig. 34. The proper level for transection of the tibia and fibula in Syme's amputation.

tibial nerve and divide it at a high level lest so doing lead to damage of the adjacent posterior tibial artery and consequent impairment of the blood supply to the heel flap. Although a neuroma inevitably develops at the cut end of the nerve, it seldom gives trouble. In the rare case in which the neuroma is sensitive, a cure can be effected by late transection of the nerve at a level well above the ankle joint but without removal of the distal segment of the nerve.

MARGINAL GANGRENE OF THE HEEL FLAP

Except in cases of peripheral vascular disease, marginal gangrene of the heel flap is nearly always due to faulty operative technique. Either the blood supply to the flap is impaired by injury to the posterior tibial artery, or the dressings are put on too tightly, or swelling occurs beneath the adhesive strips and they are not loosened soon enough. With care in operating, there is little danger of necrosis of the flap. Should necrosis occur, the stump is not necessarily ruined unless the loss of tissue is very great (Figs. 35, 36, and 37).

VASCULAR INSUFFICIENCY IN THE HEEL FLAP

It has been said that the great length of a Syme stump results in vascular insufficiency manifested by a cold, blue, painful stump end, symptoms which are greatly accentuated in cold weather. There has been no such experience in Canada, where, in winter, many of the patients are exposed to very low temperatures. Experience leads to the conclusion that vascular stasis from exposure to cold is not a problem of any importance in the Syme amputation.

TENDER HEEL FLAP WITH CALLUSES

A calloused and tender heel flap is almost always due to failure to preserve the specialized fibroelastic adipose tissue. It is accentuated if the area of transection of the tibia and fibula is small or if there are projecting bone spurs. The problem can be prevented by proper fashioning of the heel flap and by division of the tibia and fibula low enough to provide a broad area of support. If bony spurs are present, they should be removed, but neither a damaged heel flap nor an inadequate area

of support can be corrected by any subsequent operation.

#### IMPERFECT SKIN COVERING OF THE STUMP

In an occasional Syme stump the end is covered with skin ill adapted to weight-bearing. Usually in such cases the extent of the original trauma was such as to leave very little material from which to fashion an adequate heel flap. Sometimes the heel flap is scarred by wounds or infection. Some of the heel flap may have been lost by vascular damage, or the original covering of the stump may have been skin from a site other than the heel. Though little can be done to improve such stumps by further operation, modification of the prosthesis so as to distribute the weight between the end of the stump and the upper end of the socket, as in a below-knee prosthesis, offers promise of improvement. Despite the great importance of covering the end of the stump with skin and subcutaneous tissue accustomed to weight-bearing,

there is reason to believe that, when the cut surfaces of the tibia and fibula are as broad as possible, the stresses of weight-bearing are distributed so widely that even ordinary skin and subcutaneous tissue can sometimes function satisfactorily (Fig. 38).

#### INDICATIONS FOR SYME'S AMPUTATION

With a technique that ensures a satisfactory end-bearing stump, Syme's amputation is indicated for all destructive, infective, or other disabling lesions of the foot that cannot be dealt with by a transmetatarsal amputation. The skin over the heel must be intact. Syme's amputation should replace Lisfranc's and Chopart's whenever these amputations are apt to be unsatisfactory, as is often the case. The

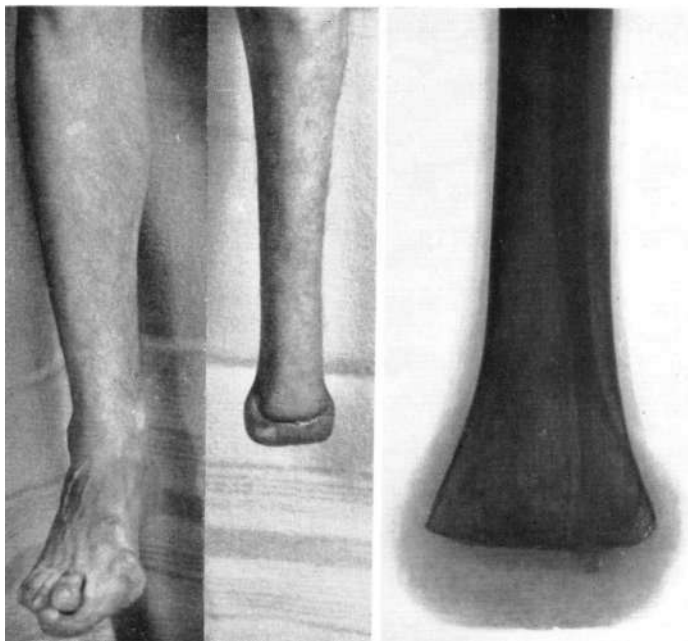


Fig. 35. Salvage of a Syme stump in spite of marginal gangrene of the flap. This 38-year-old man suffered ischemic necrosis of the muscles of his leg as a complication of fracture of the femur when he was eight years old. He slowly developed a grossly deformed, insensitive foot with trophic ulceration. When the Syme amputation was performed, the posterior tibial artery was inadvertently divided. The result was marginal gangrene of the flap. Separation of the gangrenous margin occurred slowly over a period of eight months. During that time the flap was held in place by adhesive strapping and carefully applied dressings. Wearing an "elephant prosthesis" (Fig. 36), he first walked five months after his operation. The scar is depressed at the line of suture as the result of the separation of the gangrenous margin of the heel flap. Left, appearance of stump; right, radiograph of stump.

following are the principal conditions for which Syme's amputation is most frequently performed.

#### SEVERE INJURIES OF THE FOOT

Compound and comminuted fractures of the tarsus and metatarsus and crushing injuries of the foot are usually best treated by Syme's amputation. If damage to the skeleton of the foot is severe, it is often impossible to salvage a useful and painless foot. As soon as this circumstance becomes apparent, or if from the beginning it is obvious that much of the foot must be lost by reason of the injury or that the foot will ultimately become deformed, rigid, and painful, a Syme's amputation is indicated. It should be performed as soon as the risk of infection can be eliminated.

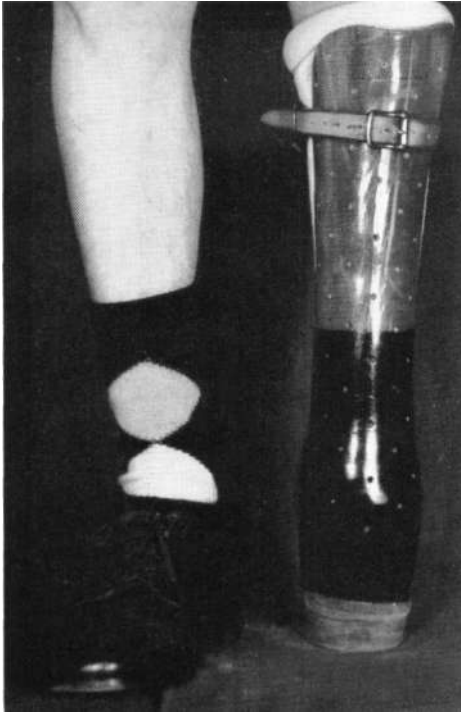


Fig. 36. The temporary "elephant prosthesis" used on the patient shown in Figure 35. It enabled him to walk during the long period of wound-healing.

With antibiotics available, the amputation can sometimes be performed as a primary measure. More frequently it will be wise to perform it as a secondary procedure after infection has been brought under control and the wound has healed or nearly healed. In dealing with injuries to the foot, especially war injuries, the advantages of the Syme amputation should be borne in mind so that, instead of immediate resort to a mid-tibial amputation, a two-stage operation can be planned, the primary stage being to remove the shattered and infected distal portions of the foot while preserving the heel flap, the second to effect a formal Syme amputation after the wound has healed or after infection is under adequate control.

#### INTRACTABLE INFECTIONS OF THE BONES AND JOINTS OF THE FOOT

Today infection is less often an indication for Syme's amputation than it was formerly. Antibiotics give us such control over infections

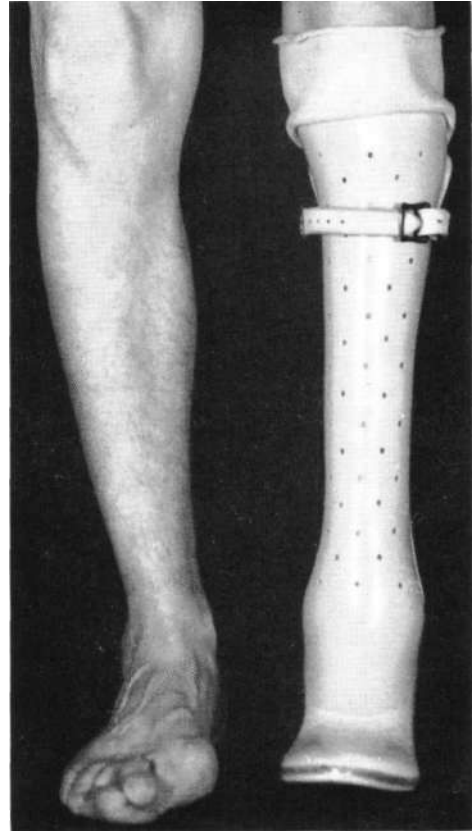


Fig. 37. The final prosthesis provided the patient shown in Figure 35. See pages 52-75.

(including tuberculosis) that amputation is seldom necessary as a life-saving measure. It still has a place in the eradication of persistent, chronic infection and in the management of a few unusual infections, such as blastomycosis. Syme's first operation was for tuberculous infection of the talus and calcaneus. It is a tribute to the operator that in a day of uncontrolled infection the result was completely successful.

#### DEFORMITIES OF THE FOOT

Foot deformities that cause serious disablement from rigidity and localized pressure and that are incapable of correction are indications for Syme's amputation. Although the chief cause of such deformities is previous trauma or infection, conditions such as old clubfoot with intractable deformity can also be well treated by Syme's amputation.

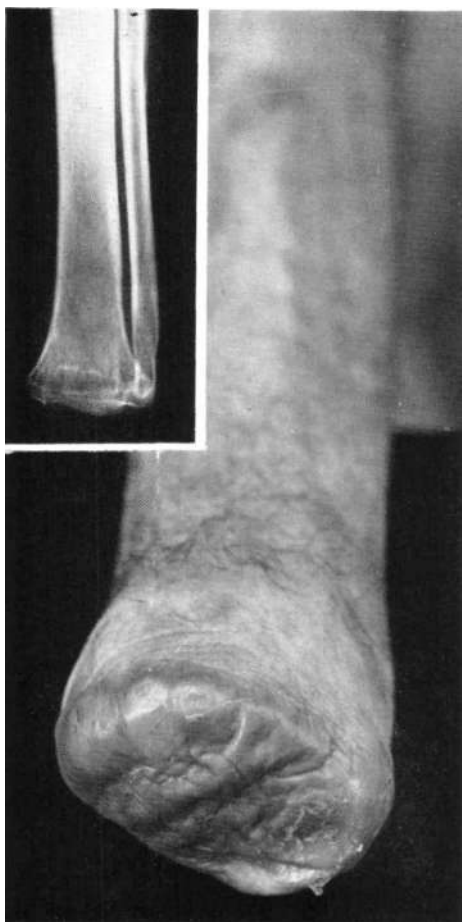


Fig. 38. A modified Syme amputation in which, because of an injury that completely destroyed the heel flap and the calcaneus, the transected ends of the tibia and fibula were covered with a flap from the dorsum of the foot. Photo shows stump 10 years after amputation, never any trouble; insert is a radiograph showing broad area of support, which probably accounts for the success of this stump despite lack of covering with normal heel pad. Similar to Baudens' supramalleolar amputation (2).

#### WAR INJURIES

Because battle wounds commonly cause gross damage to tissues, and because they must often be treated hastily, in large numbers, and usually under conditions less than ideal, the merits of Syme's amputation must be emphasized lest the soldier be deprived of its advantages. Every war injury of the foot should be regarded as a condition that might ultimately best be treated by Syme's amputa-

tion. Even in questionable cases, consideration should be given to a two-stage procedure: first, removal of the damaged parts with concomitant control of infection; second, a formal Syme amputation when healing of the first wound is well along.

#### FROSTBITE AND IMMERSION FOOT

Extreme cold causes thrombosis of the smaller vessels of the foot, especially of the distal portions, so that gangrene of the toes develops in severe cases. Foot damage from frostbite, if of considerable extent, is well treated by Syme's amputation. Less severe cases may recover without amputation, or escape with amputation of the toes, or with transmetatarsal amputation.

#### SELECTED CASES OF OBLITERATIVE VASCULAR DISEASE

Contrary to expectation, it has proved possible to deal with certain cases of Buerger's disease and of arteriosclerotic vascular disease by Syme's amputation. Buerger's disease is more often suitable for Syme's amputation than is arteriosclerotic vascular disease. The most suitable case is a young or middle-aged man suffering from obliterative disease with gangrene of the toes and neighboring parts and a favourable response to lumbar sympathectomy, followed by Syme's amputation, will often provide a useful stump that will last for years. Dr. Gordon M. Dale (P), who has had considerable experience with the Syme amputation for obliterative vascular disease (page 44), has had success in 50 percent of his cases. The Syme stump has provided much better function than would have been possible with amputation at a higher level, a matter of special importance since these patients constantly face the possible loss of the other leg at a later date for the same disease (45).

#### CERTAIN NEUROLOGICAL LESIONS

Neurological diseases occasionally produce in the foot changes which impair its usefulness and which may transform it into an encumbrance. If infection supervenes, the patient's life may be endangered.

Neuropathic joints in the foot can develop

from tabes dorsalis, syringomyelia, or Charcot-Marie-Tooth neuromyopathy. If the disability and deformity from these problems is severe, a Syme amputation is a valuable procedure. It removes the damaged joints and provides the patient with a useful end-bearing stump.

The sensory loss which accompanies irreparable sciatic-nerve lesion or spina bifida is prone to result in trophic lesions of the skin of the sole of the foot. These skin lesions occur most frequently in the anterior portion of the foot, where the metatarsal heads press unduly upon the skin which underlies them. When ulceration of the skin develops, infection follows. It must be quickly and completely eradicated. The skin beneath the heel is less often involved because of the thickness of the heel pad. The ulcers beneath the metatarsal heads are so situated that a transmetatarsal amputation is seldom possible because the skin available is inadequate to cover the end of the foot

without tension. Such cases are well treated by Syme's amputation.

#### SYME'S AMPUTATION IN CHILDREN

Syme's amputation can be utilized in children as successfully as in adults, especially in the treatment of destructive foot injuries and of certain congenital foot deficiencies and deformities. Indeed, if properly performed it has in children two special advantages not applicable to adults. Provided the lower epiphyseal line of the tibia is preserved intact, the growth in length of the tibia is but little diminished. Secondly, progressive growth does not project the lower ends of the bones through the skin, as happens all too frequently when amputation through the shaft of the tibia is performed in early childhood.

The chief indications for the operation in children are trauma that results in irreparable damage to distal parts of the foot, vascular

accidents that terminate in ischemic necrosis or gangrene of the toes and associated parts, and congenital deficiencies and deformities that result in a foot so imperfect as to be an encumbrance. It is of importance that the lower epiphyseal line of the tibia be undamaged and that an area of support as broad as possible be obtained. In children, accordingly, little more should be done to the bones than to remove the malleoli. The lower articular surface of the tibia is left untouched, while the calcaneus is removed from the heel flap by subperiosteal dissection.

The Syme amputation can be performed in children as early as the second or third year, with great benefit to the patient. Even if it does nothing more than postpone a formal, mid-tibial amputation until growth has ceased,

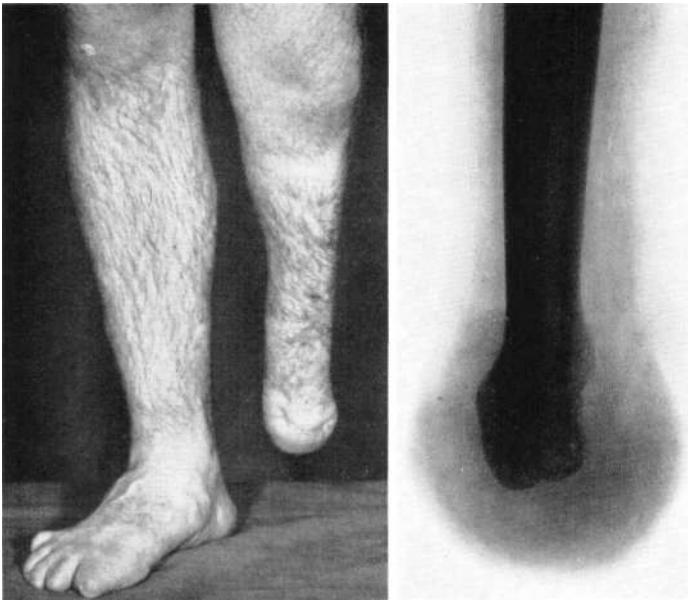

Fig. 39. The Syme amputation in children. This 18-year-old boy suffered embolism or thrombosis at the bifurcation of the aorta as a complication of septicaemia at the age of seven years. Gangrene of his right toes and of the left foot in May of 1948. A Syme amputation was performed on the left foot in May of 1948. He has had a perfectly satisfactory stump for 11 years. Left, the stump (in 1958) shows a large heel pad which moves rather loosely on the ends of the bones; right, radiograph of the stump showing that the transection was rather high. The left tibia is  $2 \frac{1}{8}$  in. shorter than the right. There is no projection of the bone ends through the end of the stump.



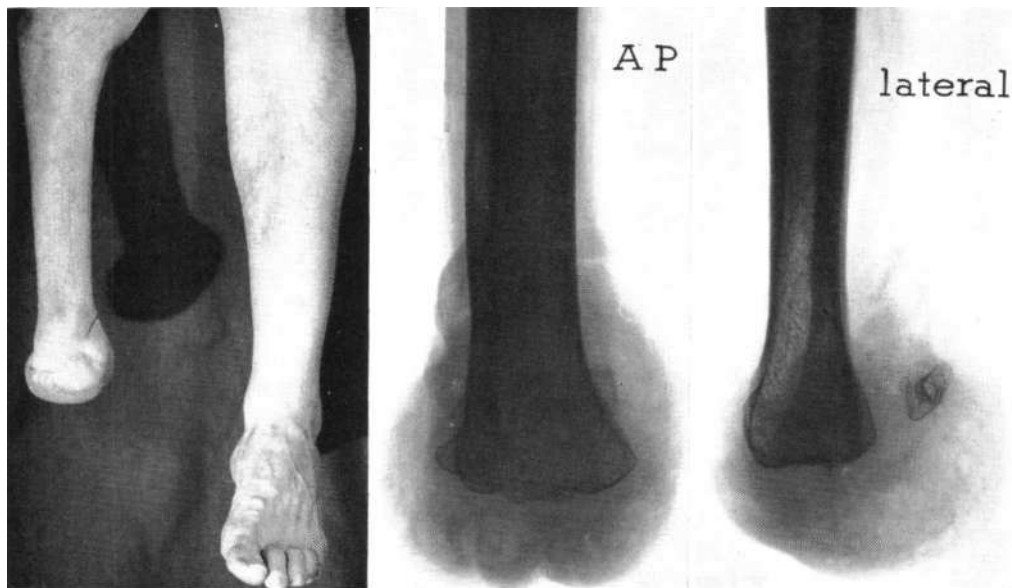


Fig. 40. Lower extremities of a 70-year-old man whose Syme amputation was performed 65 years ago for deformed foot resulting from a severe injury at the age of two. Left, appearance of the stump; right, radiographs of the stump. The heel flap is large and soft, moves rather freely on the ends of the bones, and can be moved voluntarily by contraction of the tendo achillis. There is very little shortening of the tibia. Patient has led a very active life (squash-rackets champion at one time) and has had no trouble with his stump. He wears a Marks prosthesis (wooden bucket closed with leather flaps over a tongue, solid ankle, and sponge-rubber foot.

it is worth performing (5, 24), since it ensures a shank of more or less normal length (Figs. 39 and 40).

It is interesting to record that among Syme's earliest cases were three children (32, 33), ages respectively 11 years, 10 years, and 5 months. In all three a good result was obtained.

#### MALIGNANT DISEASE OF THE FOOT

Malignant disease of some part of the foot, for example malignant melanoma, is an occasional indication for Syme's amputation. Under appropriate circumstances, tumours of the tarsus, such as osteoclastoma, may be well treated by Syme's amputation. As already noted, one of Syme's outstanding successes was an amputation at the ankle joint performed for "an erectile tumour of the foot" (probably a haemangioma). In general, it may be said that any tumour of the foot which can be completely removed without sacrificing any of the principles of the amputation should be regarded as a problem suitable for treatment by Syme's amputation.

#### RESULTS AND CONCLUSIONS

It is difficult to discuss the results of Syme's amputation because success or failure is so much dependent upon the manner in which the operation has been performed. No matter how many Syme's stumps may be examined to ascertain the end results, the conclusions will be misleading unless the technique of the operation is known for each case. If the basic principles have been observed, and if the operation has been performed properly, the result is an assured success. If any of the fundamental principles have been disregarded, the result may be unsatisfactory, and it may not be possible to improve it. The four basic principles are simple and clear-cut: 1. to remove the damaged foot by disarticulation at the ankle joint; 2. in doing so to preserve the heel flap with its blood supply and weight-bearing qualities unimpaired; 3. to remove the malleoli and the articular cartilage on the lower end of the tibia leaving a surface of support as broad as possible; and 4. to secure

the heel flap to the ends of the tibia and fibula in the best position for weight-bearing. When these principles have been followed and the operation has been performed properly, the result almost invariably is a satisfactory end-bearing stump (Figs. 41 and 42). But the less perfect the operation the less perfect the result. If some of the principles have been imperfectly applied or some of the details of the operation neglected, the result will not be an ideal Syme's stump, though it may serve the patient's needs with reasonable satisfaction for some period of time. If the principles have been completely neglected and the operation performed without regard to the precise details of technique, the resulting stump will be unsatisfactory and beyond improvement by any subsequent operation limited to the stump.

Where, in the past, tradition has given rise to a somewhat blind but devoted adherence to Syme's perfected technique, the result has usually been a firm conviction that Syme's amputation is a good amputation. Where attempts have been made

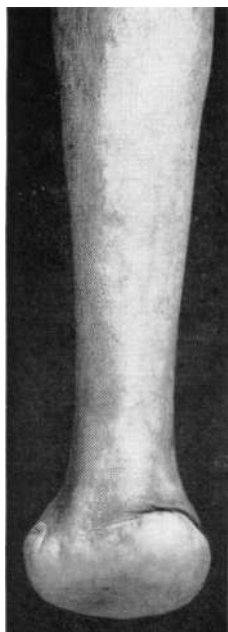

Fig. 41. A good functional Syme stump. The heel flap is large and firmly fixed to the lower end of the tibia in good position.

to improve upon the operation, usually in an attempt to simplify the limbmaker's problem or to provide a smaller and neater stump, the results have been indifferent or poor, and the operation has been condemned on inadequate grounds. This paper is the first since Syme's day to explore the reasons for the success of Syme's amputation in his hands and in the hands of those who followed him and for the failure of otherwise able surgeons to achieve equal success when they neglected or modified Syme's technique. The first merit which Syme claimed

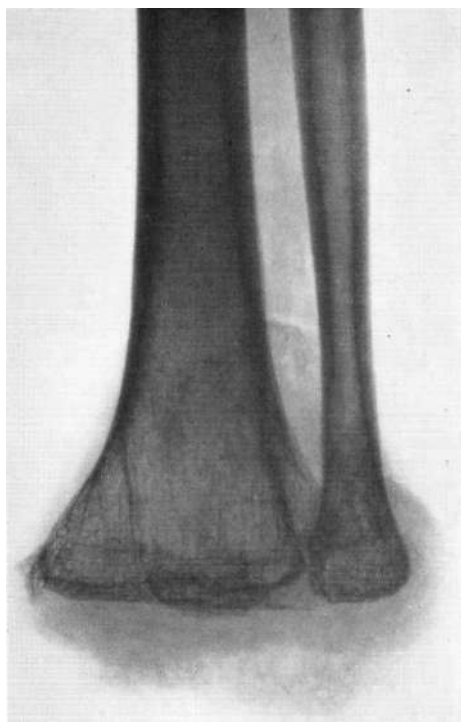


Fig. 42. Radiograph of the Syme stump shown in Figure 41. The area of support is as broad as possible.

for his new procedure was "that the risk to life will be smaller." That indeed was the case in his day, when it spared the patient the dangerous amputation at the upper end of the tibia. Today this argument in favour of Syme's operation is no longer valid, since we now know the nature of infection and have solved the problem of its control. Though the environment of surgery has changed fundamentally from the preantiseptic era of Syme to the aseptic, bacteriostatic, and antibiotic era of today, his amputation at the ankle joint still has the other merits he claimed for it—"a more comfortable stump, more seemly and useful for support and progressive motion." When circumstances permit it to be performed, Syme's amputation provides indeed the most useful of all amputation stumps of the lower extremity.

The history of Syme's amputation during the years since Syme first performed it shows that it has been used widely throughout Europe

and North America with variable results. Syme's early cases had the good fortune to escape the complications due to sepsis, such as marred Pirogoff's early experience with the operation. Syme built on the experience he gained in his early successes and gradually perfected a technique which gave a good stump. In Syme's papers on the subject there is no record of a failure or a death, a circumstance extraordinary in view of the sepsis which to some degree complicated every surgical procedure of that day and also in view of the fact that many of his amputations were undertaken for tuberculous caries of the ankle joint or subastragalar joint. The explanation may lie in the fact that in Syme's day operations in the home and in small private hospitals were much less likely to be complicated by "hospital diseases" than were those performed in public hospitals. From 1829 to 1833, all of Syme's operations were performed in the private hospital he established in Minto House. Even after his appointment to the Chair of Clinical Surgery in the University of Edinburgh in 1833, he continued for another 15 years to act as the consulting and operating surgeon of Minto House Hospital and Dispensary, though wards in the Edinburgh Royal Infirmary were assigned to his official position. Syme was well aware that hospital diseases were in some way related to the overcrowding and filth that were universal in public hospitals of that day. The Minto Surgical Hospital, which he founded and controlled, was much less troubled with these complications because he was able there to avoid overcrowding, to ensure adequate ventilation and sanitation, and to segregate ailing patients from those in good health. In discussing compound dislocation of the astragalus, for example, he makes the following reference (32, 36) to this aspect of the surgery of his day:

Compound dislocation of the astragalus with or without that curious displacement of the astragalus, which results from falling with great force on the heel, was formerly held to require amputation of the leg. The authority of Sir A. Cooper's experience encouraged attempts to preserve the limb in such cases; and in private practice both forms of injury are now frequently conducted to a successful issue, though in general through a protracted period of recovery. But it must be admitted that many lives have been lost, especially in hospitals, from trying to retain the limb. In the Royal Infirmary

I find that of thirteen patients who had suffered compound dislocation of the ankle, and were not subjected to amputation, only two recovered.

When Syme assumed charge of wards in the Edinburgh Royal Infirmary, he bent all his energy toward improving sanitation by providing adequate space between beds, by better ventilation, and by more cleanliness. An interesting outcome of this activity was his insistence that the Governors establish a separate hospital for the treatment of burns. The story is well told by Simpson and Wallace (29). Syme's purpose was not so much to improve the treatment of burns as to remove the unfortunate burn victims, with their offensive wounds and filthy dressings, from his surgical wards to avoid contamination of his operative cases. Pirogoff's experience with his first four cases of Syme's amputation, all of whom died (of scurvy, tuberculosis, and sepsis), must surely be an indication that the surgical wards of Russian hospitals provided an environment much less favourable to surgical operations than did Syme's private hospital at Minto House or his surgical wards at the Edinburgh Royal Infirmary.

It is said of Syme that he never wasted a drop of blood, never wasted a drop of ink, and never wasted a word. His publications on the subject of his amputation at the ankle joint were limited to the five papers (30, 31, 32, 33, 35) finally gathered together in *Contributions to the Pathology and Practice of Surgery* (36) and to his letter to the editor of *Lancet* (37). Having developed a new operation and perfected it to his satisfaction, he published the account of its value. He indicated how the complications and imperfections could be avoided and then left it to stand on its own merit. It must be said also that in Edinburgh his operation has always been held in high repute and that his technique for the procedure has been taught without change to successive generations of students. From the present survey it seems clear that when Syme's operation is condemned because of a poor stump it is almost always because of some obvious failure to follow Syme's technique. As time goes on, more and more evidence accumulates to demonstrate that Syme's operation, properly performed, will provide a good stump.

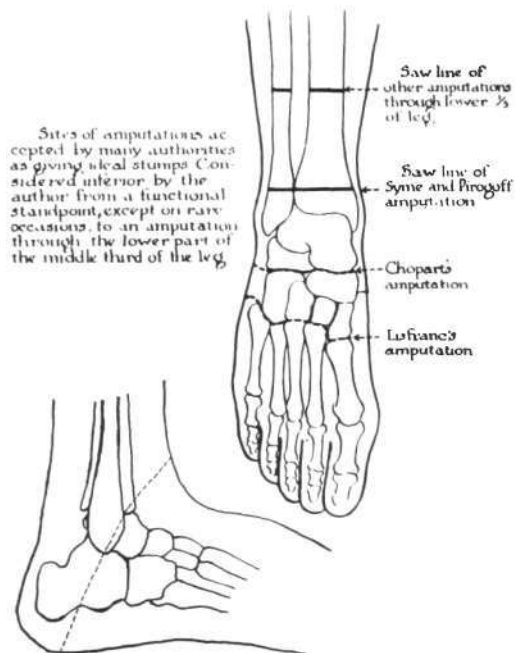


Fig. 43. Drawings from Kirk (20) showing misconception of the principle of Syme's amputation as late as the year 1942. The indicated level of division of the tibia and fibula is too high; description of Syme's amputation as a "supramalleolar amputation" is incorrect; the skin incision shown is that of Elmslie's modification of Syme's operation, not that used by Syme himself.

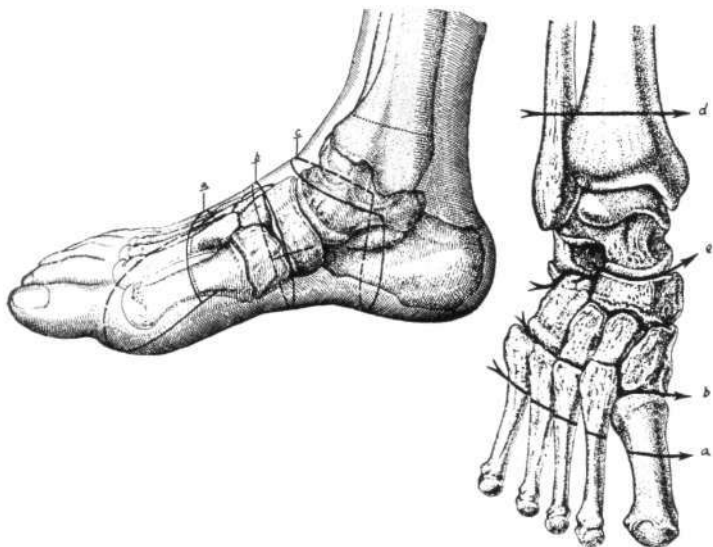


Fig. 44. Drawing of Syme's amputation showing division of tibia and fibula at a level much too high for a satisfactory stump. From Vasconcelos (42).

Imperfections are almost invariably the result of failure to follow strictly the details of technique (22).

It is strange that over the years there has been such imperfect appreciation of the principles of Syme's amputation. In Syme's own day, Guyon, Roux, and Pirogoff modified Syme's procedure in the hope that they might avoid certain complications. After the 1914—1918 war, Elmslie introduced his modification, which he confidently believed to be an improvement upon Syme's original technique. Even during the 1939-1945 war, and in subsequent years, the basic principles of Syme's operation were imperfectly understood. Figures 43 and 44, taken from standard texts of that era (20, 42), advocate such a high transection of the tibia and fibula that the result would certainly be an imperfect stump. None of these changes in Syme's procedure has improved the results.

Such misunderstandings must be due to several factors. For one thing, Syme himself wrote about his amputation at the ankle joint in a limited way only, in a style always terse and often obscure, and he published nothing on the subject after 1846. In his publications there is only one inadequate illustration (Fig. 23). For another, in Syme's day the matter

of prime importance was to remove the patient's damaged or infected foot with minimum risk to life. That accomplished, perfection of the stump and fit of the prosthesis were secondary considerations, important but not vital. When infection disappeared as a major problem, the new mastery of surgery, derived from anaesthesia and antisepsis (later asepsis), led surgeons to think that their new freedom in operating should make it possible to refine the procedure and thus to produce a more tidy, more elegant, and more useful stump. Besides this, the demands of the limbmakers led them to believe that high

transection of the tibia and fibula would ensure that the patient could more readily be fitted with a satisfactory prosthesis. Whereas in the preanaesthetic and preantiseptic days, the emphasis in operating was upon speed, dexterity, and the control of haemorrhage, in the new freedom of painless and aseptic surgery there was a widespread impulse to devise more sophisticated operations. While the functional value of Syme's amputation derived chiefly from the resulting weight-bearing properties, the stump seemed bulky, clumsy, and unsightly to the new generation of surgeons. Their success in other fields of operative procedure naturally led them to the opinion that Syme's amputation, already good, could be made still better by refining the details of the technique, and the entry into the picture of highly skilled limb-fitters encouraged a belief in the necessity for certain modifications to facilitate limb-fitting.

Today, fortunately, the perfection of a new type of Syme prosthesis (page 52) has eliminated the ankle-joint problem and minimized the bulbous appearance of the perfect Syme stump. Seldom in the history of surgery has it been necessary to adhere rigidly to the technique of an operation developed and perfected in preantiseptic days. Yet such is the case with Syme's amputation. The simple technique devised by Syme to spare his patients the risks of amputation at the site of election and to give them an end-bearing stump still provides the best end-bearing stump of the lower extremity.

Finally, and in summary, the conclusions to be drawn from this examination of the history and development of Syme's operation are as follows:

1. The stump resulting from a Syme operation has great merit. It bears all the weight of the body on its end and withstands the stresses of locomotion without difficulty and for an unlimited time. It is the most satisfactory amputation of the lower extremity and should be utilized whenever circumstances permit.

2. A satisfactory Syme stump can be assured if the principles underlying the operation are understood and if the technique of the operation is followed strictly.

3. Deviation from the basic principles or from the details of the technique of the operation will impair the perfection of the stump, and imperfections thus incurred cannot be corrected by subsequent operation.

Though imperfect, a Syme stump may still be useful, but sometimes it is ruined irreparably.

4. All surgeons who have occasion to deal with trauma or disease of the foot which may require amputation should be familiar with the merits of Syme's amputation and should be prepared to utilize it when the occasion arises. They must be familiar with the principles of the procedure, and they must perform the operation with meticulous adherence to the technique which has proven successful. Interestingly enough, that is the technique which Syme himself perfected.

This account of the history and development of Syme's amputation cannot end better than with Syme's own summary of the operative problem, which has been quoted earlier:

THE AMPUTATION IS EASILY EXECUTED AND PROVES IN THE HIGHEST DEGREE SATISFACTORY IF DONE IN ACCORDANCE WITH CERTAIN PRINCIPLES WHICH HAVE BEEN CAREFULLY EXPLAINED, BUT IS DIFFICULT AND DISASTROUS IF PERFORMED INCORRECTLY.

#### ACKNOWLEDGMENTS

My thanks are due to many colleagues who have permitted me to see their patients and to reproduce in this paper their photographs and radiographs. Dr. Robert Salter, of the Hospital for Sick Children, Toronto, brought in the patient illustrated in Figure 37. Dr. Donald E. Starr, of Vancouver, sent me the photographs and radiograph shown in Figure 38. Miss Patterson and her staff at the Library of the Academy of Medicine, Toronto, have rendered me invaluable service in securing from the most distant sources journals of a hundred years ago. Without their assistance, it would have been impossible to compile these historical notes. I am indebted also to the Librarian of the Royal College of Surgeons of Edinburgh for much assistance. I am particularly indebted to Miss Alexandra Birinkova for the translation of Pirogoff's paper (26), to Mrs. Hannah Parnas for the translation of Volkmann's address (44), and to Beatrice Harris for the translation of relevant material from the publications of Baudens (2), Farabeuf (12), and Velpeau (43), and from *Les Annates des Therapeutique* (2). My secretary, Miss Florence Spencer, has spent untold hours of unstinted labour in preparing the manuscript from my notes. I am deeply grateful to her for her devoted work on my behalf.

Both the editor and the publisher of the British Edition of the *Journal of Bone and Joint Surgery* have kindly permitted me to utilize certain illustrations which appeared in a previous publication of mine on Syme's amputation (77). Their courtesy has enabled me to use material not available elsewhere.

—R.I.H.

#### LITERATURE CITED

1. *Artificial limbs and their relation to amputations*, British Ministry of Pensions, His Majesty's Stationery Office, London, 1939. P. 55.
2. Baudens, J. B. L., *Nouvelle methode des amputations*, Premiere Memoire, *Amputation Tibio-tarsienne*, Germer Bailliere, Libraire, Editeur, Paris, 1842. See also *Annales des Therapeutique*, Paris, Vol. 3, pp. 274, 484 (1845), Vol. 4, pp. 220, 316, 348, 343 (1847).
3. Blechschmidt, E., *Die Architektur des Fersenpolsters*, *Morphol. Jahrb.*, 72:20-68 (1933).
4. Broca, A., and C. Ducroquet, *Artificial Limbs*, Military Medical Manuals, English ed., Sir Alfred Keogh and R. C. Elmslie, eds., 1918. Pp. 77 and 78.
5. Brown, Dennis, personal communication, 1955.
6. Brown, John, *Horae subsecivae*, new ed. in 3 vols., Adam and Charles Black, London, 1897. Second series, p. 363. See also Everymans Library, *Rob and his friends and other papers*, by John Brown, J. M. Dent and Sons, London, 1906.
7. Brown, John, *Horae subsecivae*, new ed. in 3 vols., Adam and Charles Black, London, 1897. First series, p. 360.
8. Carden, H. D., *On amputation by single flap*, *Brit. Med. J.*, 1:416 (1864).
9. Dale, G. M., personal communication, 1960.
10. Dent, Clinton T., *Surgical notes from the military hospitals of South Africa*, *Brit. Med. J.*, 1:1313 (1900).
11. Elmslie, R. C., in Carson's *Modern operative surgery*, 1st ed., Cassel & Co., London, 1924. Vol. 1, section on amputations, p. 132.
12. Farabeuf, L. H., *Precis de manuel operatoire (ligatures, amputations)*, G. Masson, Editeur, Paris, 1881. P. 473.
13. Fergusson, *System of practical surgery*, 4th ed., review in *Lancet*, Vol. II, p. 394 (1857).
14. Godlee, Sir Rickman, *Life of Lord Lister*, 3rd ed., Clarendon Press, Oxford, 1924. Chapter X.
15. Guyon, F., *Gazette des hopitaux*, p. 514 (1868), quoted from Farabeuf, *Precis de manuel operatoire (ligatures, amputations)* G. Masson, Editeur, Paris, 1881. P. 543.
16. Hancock, Henry, *On operative surgery of the foot and ankle joint* (1873).
17. Harris, R. I., *Syme's amputation*, *J. Bone & Joint Surg.*, 38B:614 (1956).
18. Hutchinson, J., Jr., *On the substitution (when practicable) of subastragalar for Syme's amputation*, *Brit. Med. J.*, 2:1169 (1900).
19. Jacobson, W. H. A., *The operations of surgery*, First American ed., Blakiston, Philadelphia, 1889. Pp. 939-943.
20. Kirk, N. T., *Amputations*, W. F. Prior Co., Inc., Hagerstown, Md., 1942.
21. Kuhns, J. G., *Changes in elastic adipose tissue*, *J. Bone & Joint Surg.*, 31A:541 (1949).
22. Kuhns, J., and P. D. Wilson, *Major amputations—analysis and study of end results in 428 cases*, *Arch. Surg.*, 16:887 (1928).
23. Langdale-Kelham, R. D., and G. Perkins, *Amputations and artificial limbs*, Oxford, London, 1942. P. 3.
24. LeMesurier, A. B., personal communication, 1952.
25. Paterson, R., *Memorials of the life of James Syme*, Edmonston and Douglas, Edinburgh, 1874.
26. Pirogoff, N. L., *Osteoplastic elongation of the bones of the lower leg in conjunction with release of the foot from the ankle joint*, *J. Military Med.*, St. Petersburg, 63:83 (1854). See also Farabeuf (12), *Precis de manuel operatoire (ligatures, amputations)*, G. Masson, Editeur, Paris, 1881. P. 527.
27. Roux, J., *Annales de Therapeutique*, Paris, 1846, quoted from Farabeuf, *Precis de manuel operatoire (ligatures, amputations)*, G. Masson, Editeur, Paris, 1881. Pp. 500-515.
28. Shellswell, J. H., *Syme's amputation*, *Lancet*, Vol. II, p. 1296(1954).
29. Simpson, D. C., and A. B. Wallace, *Edinburgh's first burn hospital*, *J. Roy. Col. Surg. Edinburgh*, 2:134 (1956).
30. Syme, J., *On amputation at the ankle joint*, London and Edinburgh Monthly Journal of Medical Science, Vol. 3, No. XXVI, Feb. 1843, p. 93.
31. Syme, J., *Amputation at the ankle joint*, London and Edinburgh Monthly Journal of Medical Science, Vol. 3, No. XXVIII, April 1843, p. 274.
32. Syme, J., *Amputation at the ankle joint*, London and Edinburgh Monthly Journal of Medical Science, Vol. 4, No. XLIV, August 1844, p. 647.
33. Syme, J., *Amputation at the ankle joint*, London and Edinburgh Monthly Journal of Medical Science, Vol. 5, No. LIII, May 1845, p. 341.
34. Syme, J., *On amputation at the knee*, Monthly Journal of Medical Science, Vol. 5, No. LIII, p. 337, 1845.
35. Syme, J., *Amputation at the ankle*, Monthly Journal of Medical Science, Vol. 6, No. LXVII, Aug. 1846, p. 81.
36. Syme, J., *Contributions to the pathology and practice of surgery*, Murray & Gibb., Edinburgh, 1848. Pp. 114-147.
37. Syme, J., *Mr. Syme on amputation at the ankle joint*, Letter to the Editor, *Lancet*, Vol. II, p. 394 and 480 (1857).
38. Syme, J., *On amputation at the knee*, *Edinburgh Medical Journal*, Vol. XI, p. 871 (1866).
39. Thompson, Henry, Reported in the account of the meeting of the Pathological Society of London for April 21, 1863, and published in *Lancet*, Vol. I, p. 525 (1863).
40. Tietze, A., *Über den Architektonischen Aufbau des*

- Bindegewebes in der Menschlichen Fussohle*,  
Beitrage zur Klin. Chir., No. 123, p. 493 (1921).
41. Valery-Radot, R., *Life of Pasteur*, Doubleday,  
Page & Co., New York, 1919. Chapter IV.
42. Vasconcelos, E., *Modern methods of amputation*,  
Department of War Medicine, The Philosophical  
Library, New York, 1945.
43. Velpeau, A. A. L. M., *New elements of operative  
surgery*, First American Ed., Samuel and William  
Wood, New York, 1847. P. 595.
44. Volkmann, Richard, *Sammlung klinischer Vortrage*,  
Vol. III, #221, (Surg. 70), p. 1878, Die Moderne  
Chirurgie (1882).
45. Warren, R., I. Thayer, H. Achenbach, and L.  
Kendall, *The Syme amputation in peripheral  
vascular disease*, Surgery, Vol. 37, p. 156 (1955).

# Syme's Amputation for Gangrene from Peripheral Vascular Disease

GORDON M. DALE, M.B.<sup>1</sup>

Peripheral vascular disease as a cause of amputation was first forcefully brought out in Canada by the many cases of acute thromboangiitis obliterans occurring in young men after World War I. In the early days of the 20's, amputation for this disorder was carried out at knee level (Gritti-Stokes), an operation itself considered a daring innovation at the time, the site of election in such cases then being viewed as the junction of the upper and middle thirds of the thigh. In the present series, the first Syme amputation for gangrene of the foot was performed in 1925 in a case of thromboangiitis obliterans. Since that time, the Syme amputation has been used in Canada in such cases whenever it seemed warranted.

By 1940, Syme's amputation had been used successfully for many and varied conditions, including infected and perforating ulcers in unrecovered sciatic-nerve and cauda-equina lesions, septic and tuberculous arthritis of the ankle joint, frostbite, arterial occlusion, and gangrene owing to peripheral arterial disease.

<sup>1</sup> Present address: 84 Woodlawn Ave., E, Toronto, Ontario, Canada. Until his retirement in May 1956 as Chief of the Orthopaedic Service at Sunnybrook Hospital, Toronto, Dr. Dale had for more than 35 years (since October 1920) been in charge of all amputations for the Canadian Department of Veterans Affairs at Christie Street Hospital and at Sunnybrook. His patients have been drawn not only from World Wars I and II, the Korean War, the Boer War, and the Northwest Rebellion but also from many lesser campaigns in many parts of the world, from the Canadian Mounted Police, from the Canadian Department of Indian Affairs, and, until recently, from Canada's active Army. The cases here reported upon are of interest for at least two reasons—first because a goodly number were followed for periods ranging from five to 22 years (or until death from other causes), second because Dr. Dale either has performed the operation himself or else has served as the supervisor.—ED.

When, after the beginning of World War II, the question of amputations once again became prominent, we were able to refute the views expressed by the British Ministry of Pensions in regard to Syme's and other end-bearing amputations generally.<sup>2</sup> We showed, by demonstration of actual cases, the great value and durability of these amputations in active life. We were fortunate in having an excellent prosthetic service started during World War I and concentrated in February 1919 at the Dominion Orthopaedic Hospital (later Christie Street Hospital). It had constantly been improving our prostheses, and to that group we owe much of our success.

During the period 1920-1956, many new factors modified our views and methods of treatment. In 1930, lumbar ganglionectomy was adopted in vascular disease, and it is thought that doing so saved or postponed many major amputations. Embolectomy and anticoagulants saved some limbs. Sulfa drugs, penicillin, and later antibiotics bolstered our courage. Although the incidence of infection was no lower after than before the use of such agents, there were operated upon during World War II cases that in World War I would not even have been considered for surgery. Now arterial grafting promises well in selected cases. Advances in anesthesia and in medicine generally have of course helped a great deal. Of the problems facing the Department of Veterans Affairs today, one is senile gangrene owing to the advancing age of veterans.

## CASE HISTORIES

The case histories that follow represent most of the Syme amputations performed for gan-

<sup>2</sup> *Artificial Limbs and Their Relation to Amputations*, British Ministry of Pensions, His Majesty's Stationery Office. London. 1939.



grene owing to thromboangiitis obliterans, diabetic gangrene where there was also peripheral vascular disease, and senile gangrene from arteriosclerosis *per se*. Omitted are those cases whose files were destroyed after death, but all failures are recorded. Included are 23 Syme amputations and one mid-tarsal amputation, all for vascular disease and all with gangrene. Six have undergone reamputation.

Cases 3, 6, and 7, listed under thromboangiitis obliterans, each underwent reamputation within six months and must therefore be classified as failures. Two cases (17 and 22) listed under arteriosclerotic gangrene are doubtful operative failures. The first underwent reamputation after his stump had healed and he had walked quite well. The reason for reamputation apparently was not breakdown of the stump. The stump of the second healed *per primam*. Fitted at an early date, the patient bore his weight chiefly on the stump for 18 months. Case 9, discussed under diabetic and arteriosclerotic gangrene, is considered a success. Not only did he wear his limb for nine years but his stump breakdown was occasioned by neglect and later circulatory failure from myocardial infarction. Cases 16 and 19 (arteriosclerotic gangrene) had well-healed stumps and were fitted but never wore their limbs to any useful extent. They are therefore recorded as failures.

There are thus seven failures in 23 cases (roughly 30%). So marked is the prevalence of myocardial infarction in thromboangiitis obliterans at all ages that an electrocardiogram and cardiovascular examination are now part of our routine examination.

#### CASES OF THROMBOANGIITIS OBLITERANS

##### CASE 1. (W. E.)

Male, born 1891. Served in the Imperial Army, 1914–19. Wounded and had trench feet in service. On discharge, complained of painful feet and occasional cramp in right calf. Had two attacks of phlebitis. Was doing heavy work.

Admitted to Christie Street Hospital 1924 with localized gangrene, dorsum of right foot, arising from infection between second and third toes. Severe pain. No pulse below the femoral on the right side, weak pulsation in dorsalis pedis and posterior tibial arteries on the left.

Right Syme amputation 1925, healed *per primam*. Case followed until 1947, when patient returned to England. No trouble with stump. Increasing disability

in left leg had forced change to light work. Arterial pulsation below the femoral had disappeared. Left radial pulse absent. Patient had not smoked since 1924.

Patient failed to communicate further as promised.

##### CASE 2. (R. G.)

Male, born 1900. Served in Army, 1915–19. V.D.S. on service. Subsequently worked as teamster in the bush. Had frequent mild attacks of frostbite. Patient's feet were cold in winter, scalded in summer. Had claudication of left leg 1934. In the winter of 1934–35, left foot was frozen, and gangrene of the left great toe developed. Amputation of toe was performed at local hospital. Wound did not heal for nine months.

In February 1936, right foot was frozen, right fifth toe amputated. Wound failed to heal and gangrene extended. Patient was referred to a city hospital, where thromboangiitis obliterans was diagnosed and a right lumbar ganglionectomy was done in March 1937. In May and November, same year, toes were amputated. Gangrene extended slightly.

In November 1937, patient was admitted to Christie Street Hospital with gangrene involving the distal third of the right foot. Marked equinus deformity. No palpable pulsation in arteries below the femoral on either side. Vein filling on the right, two minutes. Patient had suffered great pain and was practically a morphine addict.

Right Syme amputation in December 1937. Slight necrosis at center of wound, but stump healed well. Patient fitted and walking in March 1938.

Patient readmitted in April 1939 for disabling claudication of left leg. Findings as before, except that vein filling was 90 seconds. Left lumbar ganglionectomy done with excellent result. Patient seen February 1940, March 1943, April 1945, December 1946, and January 1947, all for minor infections, left foot, due to lack of cleanliness, a carbolic-acid burn, and an artefact. Left Syme amputation, performed July 1947, healed *per primam*.

Review in June 1948 showed excellent stumps. Patient walking well and working at woodcutting. Doing well 1953, when photograph of stumps (Fig. 1) was taken. Death for coronary thrombosis in 1954.

##### CASE 3. (T. A.)

Male, born 1886. Served in Army 1914–19. V.D.S. on service. Alcoholic. Onset vague pains in feet 1915. Nothing definite noted on discharge. Subsequent attacks of phlebitis, diagnosed as thromboangiitis obliterans 1928. Patient then had absence of pulsation both arteries right foot and in the left dorsalis pedis. Erythromelia was marked. Vein filling, 30 seconds. Admitted to Christie Street Hospital 1936. Right lumbar ganglionectomy in November 1936. Much improved. Admitted Christie Street in February 1937. Sudden onset gangrene right foot and leg. Right Gritti-Stokes amputation performed in March 1937. Healed well. Fitted with limb and walking, June 1937.

Admitted Christie Street Hospital in February 1938. Gangrene of toes, left foot. No pulse below femoral. Left lumbar ganglionectomy, performed in March 1938, produced some improvement, but patient

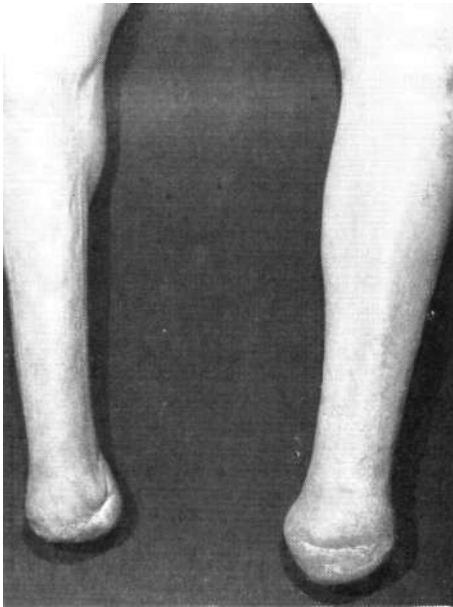


Fig. 1. Case 2 (R. G.). Anterior view of bilateral Syme stumps. Right (viewer's left), 16 years after amputation; left (viewer's right), six years.

complained greatly of pain. Left Syme amputation, May 1939. Heel flap did not slough, but wound healed slowly. Well healed in November. Patient refused to bear weight on Syme stump and complained so bitterly of pain that a left Gritti-Stokes was carried out.

Patient thereafter made no attempt at walking. Remained an invalid until death from coronary thrombosis.

#### CASE 4. (R. E. C.)

Male, born 1909. In 1947, patient was admitted to a city hospital for a nonhealing infection, right great toe nail. Thromboangiitis obliterans diagnosed and bilateral lumbar ganglionectomy performed. Right great toe was later amputated, and wound healed slowly. In 1949 and 1950, two other toes, right foot, were amputated. Right below-knee amputation, done later in 1950, healed fairly rapidly with some sloughing of the flaps. Four months after amputation, patient was fitted with a prosthesis and walked well. Shortly thereafter stump broke down.

Admitted to Sunnybrook Hospital, March 1951, with complete breakdown of end of below-knee stump. No pulsation below the femoral on either side. Left foot blanched sharply on elevation. Vein filling, 25 seconds.

Right Gritti-Stokes amputation in May 1951. Healed *per primam*. Fitted with prosthesis August 1951, and walked well. Readmitted in 1952 with minor infection of left foot requiring only few days to heal.

Working steadily as engineer, March 15, 1953. Sudden, severe pain in left foot, which rapidly changed color. Admitted to Sunnybrook Hospital. Purple discoloration, distal half of left foot, which did not change on application of pressure or on elevation. Discolored area insensitive. Vein filling, 25 seconds. Weak femoral pulse. Pain very severe in left leg and foot.

Treated by rest, heat, dry dressing, Buerger's exercise, whiskey, and papaverine. Pain not controlled and gangrene extended. Left Syme amputation in April 1953. Healed well with slight necrosis in small area around scar. Patient fitted in June 1953. In September 1953, developed stump abscess, which was opened widely and packed open. Secondary suture, done one month later, healed well.

Patient was walking well in June 1954. Returned to full-time work. Died suddenly in October 1954 from acute coronary thrombosis.

#### CASE 5. (W. S.)

Male, born 1914. While in Army, developed phlebitis in right foot, and claudication ensued. Symptoms increased, and thromboangiitis obliterans was diagnosed. Right lumbar ganglionectomy done and patient discharged.

Admitted to Christie Street Hospital in September 1947 with gangrene of left great toe and whole right foot extending to the leg. Condition grave. Had had steadily increasing doses of morphine but obtained little relief. No pulsation below the femoral, either side. Right guillotine amputation at level of tibial tuberosity, October 1947. Patient's condition improved rapidly and pain was largely relieved.

Left lumbar ganglionectomy six days later with good result. Disarticulation of the left great toe in November, flaps left open. Right Gritti-Stokes and left Syme December 1. Gritti-Stokes healed *per primam*, Syme showed slight necrosis at suture line but was well healed in seven weeks.

Patient was walking well in August 1948 (Fig. 2). Has worked as limbfitter ever since. No trouble, either stump.

#### CASE 6. (H. T. O.)

Male, born 1910. Sprained right ankle while in Army, pain and phlebitis in right leg subsequently. Thromboangiitis obliterans diagnosed and right lumbar ganglionectomy performed in 1943. Twice admitted to Sunnybrook Hospital in 1946, first with gangrene of fourth toe (amputated and healed), second with gangrene of great toe (amputated but did not heal). Right Syme amputation in January 1947. Heel flap did not slough, but wound did not heal. Right Gritti-Stokes, May 1947, healed promptly.

In 1951, patient underwent left lumbar ganglionectomy and amputation of a gangrenous great toe, then passed into other hands. Subsequent history includes left mid-tarsal amputation, 1952; left Syme, 1953; left below-knee, 1954; left Gritti-Stokes, 1956.

## CASE 7. (w. P.)

Male, born 1899. Discharged from Army in 1919 with history of painful feet. In September 1939, developed phlebitis of right leg with rapidly increasing claudication. Three weeks after onset, patient could walk only a dozen yards.

Admitted to Christie Street Hospital in November 1939 with ulceration and gangrene of fourth and fifth toes, right foot. Acute phlebitis at calf and at dorsum of foot. No pulsation in arteries below femoral, either side. On elevation of limb, color faded in two minutes. Vein filling, one minute.

Old thrombosed veins on dorsum of left foot and in left calf. On elevation of limb, purplish color remained for three minutes. Vein filling, 30 seconds. Right lumbar ganglionectomy November 17, 1939. Right Gritti-Stokes December 19, 1939. Left lumbar ganglionectomy April 5, 1940.

After the last operation, patient returned to work as repair man. No trouble until October 1949, when he had acute onset of pain in left foot and leg. Able to walk only a few steps. Left great toe was gangrenous, left foot livid, cold, and insensitive. Left Syme amputation performed April 1, 1950, at patient's request and against professional advice. Flap remained viable but never regained natural color; wound did not heal completely. Left Gritti-Stokes, performed June 1, 1950, healed *per primam*.

Walking on two Gritti-Stokes prostheses, patient was discharged in December 1950. Died August 1957, acute coronary thrombosis.

## CASE 8. (B. P. H.)

Male, born 1923. While in Army in 1944, sustained superficial wound of left leg. Healed, but scar frequently broke down. Patient was in Christie Street Hospital on another service in 1948 because of phlebitis and breaking down of wound scar. X-rays showed no retained foreign bodies. Femoral vein was ligated.

In a 1949 diagnostic, examination was negative except for erythromelia. Diagnosis of thromboangiitis obliterans was indefinite but patient was advised to stop smoking.

Admitted to Sunnybrook Hospital 1952. Two months previously had infection of the left great toe nail. Claudication appeared shortly thereafter. No pulse below femoral on left side. On elevation of limb, color faded slowly. Vein filling, 40 seconds. Marked erythromelia. All pulses palpable on right side. Vein filling, 15 seconds. Left lumbar ganglionectomy done with good result. Three weeks later guillotine amputation of the great toe was effected, and a month after that the stump of the great toe was disarticulated and flaps sutured. Wound healed in three weeks, and patient returned to work.

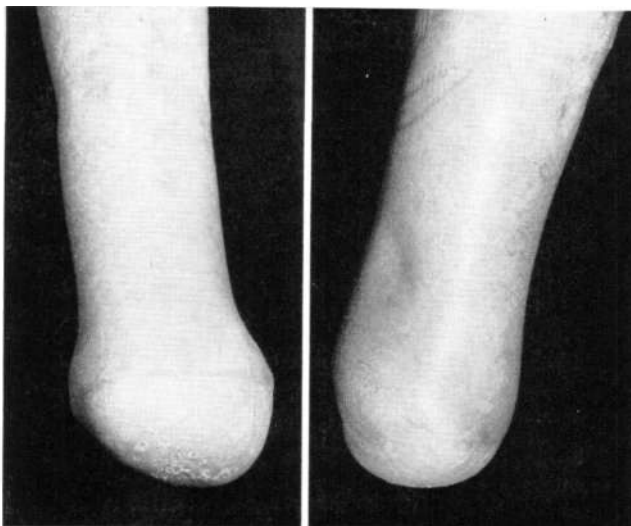


Fig. 2. Case 5 (W. S.). Anterior and lateral views of left Syme stump 11 years after amputation.

Sudden onset of pain in right leg in December 1953 following infection and gangrene of right great, second, and third toes. Admitted to Medical Service and put on anticoagulants, Priscoline, and heavy doses of morphine. Medication discontinued upon transfer to Orthopaedic Services and papaverine and whiskey substituted. When blood coagulation was again normal, right lumbar ganglionectomy was performed. Eight days later, guillotine amputation of the distal half of foot was done. Right Syme amputation, three weeks after that. Good healing. Patient was walking well on prosthesis in May 1954. Has worked steadily since and has had no trouble.

## CASES OF DIABETIC GANGRENE WITH ARTERIOSCLEROSIS

## CASE 9. (R. G.)

Male, born 1901. When patient enlisted in 1940, it was noted that the left third toe had been amputated. Subsequently, it was found that he had had diabetes prior to enlistment. Lues evident. Admitted to Christie Street Hospital in October 1940 with osteomyelitis of the tarsus and gangrene of toes. Many sinuses. Dorsalis pedis pulse absent. Weak posterior tibial. Marked neurotrophic changes. Patient emotionally unstable.

Left Syme amputation, 1941, healed well. Patient, fitted with prosthesis and able to walk well, neglected diabetic treatment and was readmitted in 1950 with ulceration in the amputation scar. Ulcer excised, stump healed. While still in hospital, patient had severe myocardial infarct and wound broke down. Gritti-Stokes was carried out.

Patient never was active, although he walked fairly well. Died in August 1954 from acute coronary throm-

bosis. Autopsy showed marked aortic degeneration with mural thrombus. Peripheral vascular endarteritis.

CASE 10. (A. E.)

Male, born 1893. Truck driver. Diabetes discovered in 1948 and patient put on diet. While in local hospital for fractured right tibia, was put on insulin. Admitted to local hospital in 1952 with ulcer on sole of right foot. With incomplete healing, patient returned to Iwork. Perforating ulcer developed, and patient was admitted to Sunnybrook Hospital in January 1955.

Examination showed extensive soft-tissue infection about a perforating ulcer. No dorsalis pedis pulse. Weak posterior tibial. X-rays showed extensive osteomyelitis (neurotrophic foot). Marked calcification of vessels. Culture showed organisms resistant to all antibiotics except terramycin.

Right Syme amputation January 31, 1955. Healed *per primam*. Fitted and walked well. Returned to work in November 1955. No trouble since.

CASE 11. (w. w.)

Male, born 1900. Diabetes recognized in 1932. In 1949, following lapse in diet, developed gangrene and osteomyelitis of right foot. Much neurotrophic change. Pulses in feet weak. Right Syme 1949. Wound healed well. Patient worked as caretaker until December 1951, when he developed infection in a callus on the left foot. Ten days later was admitted moribund to Sunnybrook Hospital. Discharging sinuses on sole of left foot, lymphangitis, and femoral adenitis. No sensation in foot. Abscess in sole drained. Patient put on antibiotics, and carbohydrate metabolism improved.

Guillotine amputation of left foot January 10, 1952, followed by marked improvement. Left Syme January 22, 1952. Some wound infection, but healed well in six weeks.

Patient is still walking on two prostheses. Is not now working, but can walk to bathroom on stumps alone (Fig. 3). Sectioned arteries in both stumps show marked endarteritis.

CASE 12. (w. c.)

Male, born 1886. Diabetes diagnosed in 1948. Admitted to Sunnybrook Hospital in 1951 on Medical Service. Diagnosis: "Arteriosclerotic heart disease; peripheral vascular disease; diabetes with peripheral neuritis; lues; gangrene of right foot." No arterial pulsations below the femorals. Gangrene in distal half of foot. Right Syme done and well healed. Fitted with artificial limb on which patient walked well.

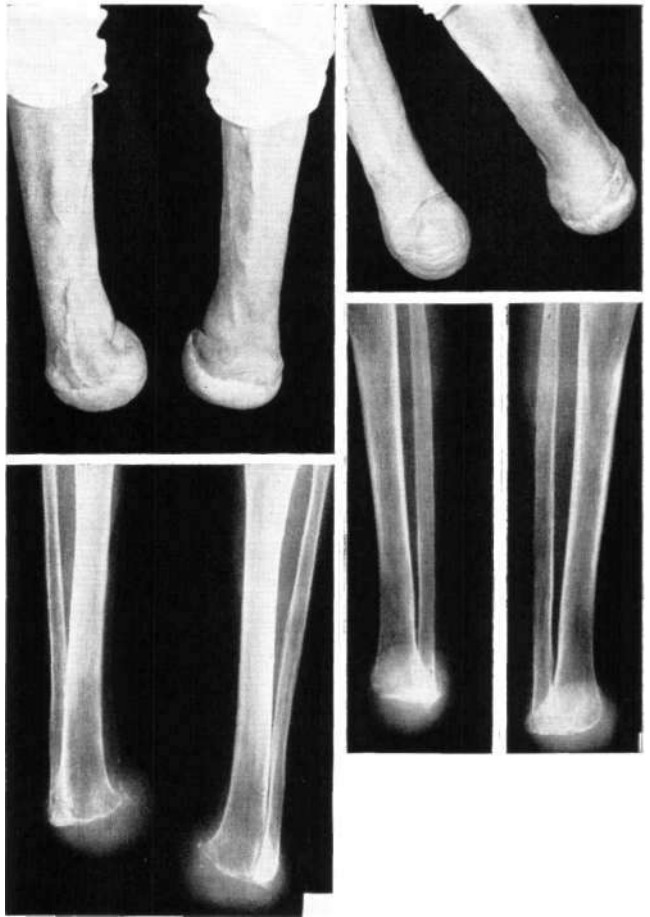

Fig. 3. Case 11 (W. W.). Front and side views of bilateral Syme stumps. Right stump (viewer's left), after nine years; left stump (viewer's right), after six years. Corresponding x-rays show bony proliferation from subperiosteal dissection of the flaps.

Admitted 1953 with congestive heart failure and ulcer of left foot. Healed with bed rest.

In 1954, dyspnoea, swelling of limbs, nephritis, ulceration (hot-water-bottle burn) on dorsum of foot.

Admitted February 10, 1956. Died. Autopsy showed marked peripheral vascular disease, arteriosclerotic heart disease, and myocardial infarction.

CASE 13. (A. J.)

Male, born 1886. Admitted to Sunnybrook Hospital in September 1949. One month previously had developed ulcer in bunion on left foot. Two weeks later great toe "became black." Patient was found to have severe diabetes, had recently lost much weight. Femoral pulse present, no pulse below. X-ray showed osteomyelitis of first and second metatarsals.

Treated by bed rest, antibiotics, and dry heat. Fever continued, and pain increased. Great toe disarticulated

October 5, 1949, and wound left open. Temperature normal 10 days later, patient much better.

Left Syme amputation April 18, 1950. Arteries sectioned showed marked endarteritis obliterans. Stump healed well. Patient fitted in June 1950, discharged in September walking well.

Patient admitted February 1951 with uncontrolled diabetes and jaundice. Had discontinued his insulin three months previously. Died June 10, 1951.

#### CASE 14. (W. R.)

Male, born 1872. Medical graduate. Diabetes diagnosed 1941, symptoms of polyuria and foot drop. Patient was put on diet and insulin. Did not follow diet strictly and stopped insulin in 1944.

In September 1954, patient pared corn on right great toe. Infection spread over foot. Treated self. Healed in nine months.

Infection, right great toe, December 1955. Hospitalized. Healed January 1956.

Admitted to Sunnybrook Hospital February 26, 1956, with gangrene of great and second toes, right. Systolic blood pressure, 210; diastolic, 90. No pulsations other than femorals in right and left lower extremities. Treated by rest and antibiotics.

Right lumbar ganglionectomy April 13, 1956. Right Syme May 3, 1956. Healed *per primam*. Fitted in August 1956. Patient gets about well on limb and states he is still (December 1958) fairly active.

#### CASE 15. (R. C.)

Male, born 1896. Discharged from Army 1919. Diabetes diagnosed 1927. Did well on diet alone for three years. Then noticed numbness and coldness of feet. Health was poor. In 1941, patient developed septic arthritis of left knee and, later same year, of right ankle. Drained at local hospital.

Admitted to Christie Street Hospital in February 1942, very ill. Sedimentation rate, 147 mm. X-rays showed destruction of outer condyle of left tibia and erosion of lower end of right tibia and upper margin of right astragalus. Ankle joint drained and knee drainage improved. *Staph. aureus* cultured from both.

Condition improved, and carbohydrate metabolism was balanced in July 1942. Right Syme then performed, but destruction of lower end of tibia required section somewhat higher than usual. Stump healed in three weeks.

In September 1942, left knee was excised. Patient fitted with prosthesis and walking well by January 1944. Continued to wear leg until sudden death in 1947, cause unknown.

### CASES OF ARTERIOSCLEROTIC GANGRENE

#### CASE 16. (J. E. N.)

Male, born 1896. Was in good health until 1945, when intermittent claudication in left calf was noted on walking half a block. In June 1950, patient was put on Prisolone. In July, developed gangrene of fourth and fifth toes. Admitted to local hospital in August 1950 for left lumbar ganglionectomy. Fifth toe amputated,

but wound failed to heal. In January 1951, patient underwent transmetatarsal amputation.

Admitted to Sunnybrook Hospital September 20, 1951, in poor condition and in great pain. Stump foul with protruding bones. No arterial pulsations below femoral. Patient given choice of gamble with a Syme or almost certainty with a Gritti-Stokes. Left Syme performed September 24, 1951. Stump healed slowly but well. Patient discharged November 5, 1951, returned for fitting. Died of coronary thrombosis before limb could be issued.

#### CASE 17. (L. G.)

Male, born 1880. Admitted to Sunnybrook Hospital in May 1954. Two years earlier had noticed claudication of left leg. Left inguinal herniotomy performed at local hospital in January 1954. Six weeks later, patient developed infection and gangrene of left third toe. Upon amputation of toe, gangrene spread rapidly involving distal third of foot.

Weak femoral pulses. No pulsation in arteries, either foot. Left lumbar ganglionectomy May 12, 1954. Left Syme amputation May 26, 1954. Stump healed slowly but with little necrosis. Patient developed moderate flexion deformity at knee despite all efforts but was walking quite well in March 1955. Patient refused Veterans' care but did not wish to be discharged. Finally discharged walking well, September 1955.

Patient returned to home town, where for reasons unknown leg was amputated at mid-thigh level. Syme stump had not broken down. Referred back to Sunnybrook in March 1956, patient had a 45-deg. flexion deformity of the hip and could not be fitted.

#### CASE 18. (F. E.)

Male, born 1885. Worked as stableman. In summer of 1949, patient noticed fissure in skin on medial side of first tarsometatarsal joint, right. Consulted physicians and chiropodists, but an ulcer formed and increased until, when patient was admitted to a city hospital, it measured 1 in. X 1 1/2 in. Given bed rest and antiluetic treatment, patient did not improve. Right lumbar ganglionectomy was performed with poor result.

Admitted to Sunnybrook Hospital February 3, 1950. No pulsation below the femorals. Ulcer was inflamed and had become larger. Very severe pain. After treatment of a flexion deformity of the knee, a right Syme amputation was done in March 1950. Healing was complete by May. Slight marginal skin necrosis along suture line.

Discharged September 1950 walking well on a prosthesis, patient has had no further trouble.

#### CASE 19. (R. E.)

Male, born 1887. In 1939, had claudication in right leg. Right lumbar ganglionectomy done at a city hospital in 1940. Considerable improvement. In 1950, a left lumbar ganglionectomy was done for similar symptoms on the left side. In January 1951, left great toe nail became infected and was removed. Toe became red and swollen. Redness spread over whole foot, and toe

became black. Large doses of morphine gave no relief for the severe pain.

Admitted to Sunnybrook Hospital in March 1951 with gangrene affecting toes and distal third of foot. No pulsation below femoral, either limb. Left Syme amputation April 3, 1951. Completely healed May 13. Patient returned for fitting November 1951, died 1952 of coronary thrombosis.

CASE 20. (G. E. O.)

Male, born 1881. Admitted to General Surgical Service, Sunnybrook Hospital, November 1950, intoxicated. Shotgun wounds both feet—superficial on left side, marked bony destruction on right. X-ray showed bony defect in right os calcis, numerous lead pellets in region of right heel. Wound debrided and plaster cast applied. Despite antibiotics, wound became infected and foot gangrenous.

When, in February 1951, patient came under care of Orthopaedic Services, distal portion of right foot was gangrenous, and marked edema and cellulitis extended to ankle. No pulsation below femoral artery. Patient very ill. Abscess drained February 19, 1951. Eusol dressings. Right Syme February 28, 1951. Standard operation, except that no section was made of lower end of tibia or of malleoli. Wound left open. Pathological report on sectioned vessels: endarteritis obliterans. Patient improved rapidly.

Right Syme completed March 14, 1951. Malleoli removed, but tibia not sectioned. Healing good, although a small sinus persisted until May 1951. Fitted in June, patient walked well.

Hospitalized June 4, 1953, for infection about residual shot pellet. Discharged. Readmitted November 30, 1955, for bronchopneumonia and empyema. Discharged. No further trouble with stump, though health is poor.

CASE 21. (J. A. S. J.)

Male, born 1876. A blind vagrant who had slept in an open boxcar while intoxicated, patient was admitted to Sunnybrook Hospital December 27, 1951, in moderate state of shock. Toes of right foot mottled but fairly warm. Distal third of left foot purple and showing no color change on application of pressure or on elevation of the limb. Left toes livid. No sensation in distal third of left foot. Edema in left leg up to knee. No arterial pulsation below the femorals.

X-ray showed marked arterial calcification. Patient treated expectantly by antibiotics, rest and dry heat. Well-marked line of demarcation, left foot, by February 16, 1952. No loss of tissue of note, right foot. Left mid-tarsal amputation proximal to line of demarcation, March 4, 1952. Wound healed well. Stump was good, but patient walked poorly. Died February 1954.

CASE 22. (W. R.)

Male, born 1890. Complained in 1953 of coldness and pain in feet, left being most affected. Admitted to a city hospital, where left lumbar ganglionectomy was

performed. In 1954, following myocardial infarction, developed gangrene in the second and third toes on the left.

Patient admitted to Sunnybrook Hospital in April 1955 on the Medical Service. Weak pulsation in arteries, right foot. Posterior tibial absent; weak dorsalis pedis, left foot. Gangrene extended and caused great pain.

Left Syme amputation, March 1, 1956, healed *per primam*. Fitted with a prosthesis, patient had no trouble with stump. Right foot broke down, and weight was borne mainly on the amputation stump. By October 1957, patient walked with crutches and took weight on the stump only.

By January 1958, stump showed bluish discoloration and was cold. Deep fluctuation appeared and was aspirated. Two c.c. of serosanguinous fluid were obtained. Skin was intact. Disarticulation at the left knee was carried out January 29, 1958. Wound healed *per primam*, but patient has not walked since.

SUMMARY

Between October 1920 and May 1956, I personally conducted or else supervised all Syme amputations performed in the DVA Hospitals at Christie Street and Sunnybrook. Uniformly satisfactory, they resulted in durable and stable stumps. In the cases owing to vascular disease with gangrene, the amputations were equally satisfactory. Six cases (2, 6, 7, 9, 17, and 22) required reamputation. Only two were subjected to amputation for failure of healing. One (Case 9) is considered a success. Two cases (16 and 19), while healed and fitted, died before use of their prostheses and are considered failures. Stumps were in active use for periods of 22, 17, 7, 12, 4, 9, 10, 7, 5, and 5 years, others for shorter periods.

From my experience, I would venture to suggest:

1. Lumbar ganglionectomy at an early date in all cases of thromboangiitis obliterans and, should gangrene develop, Syme's amputation.
2. In diabetic gangrene where carbohydrate balance can be maintained and where minor amputations have failed, Syme's amputation.
3. In selected arteriosclerotic (senile) gangrene where ganglionectomy and arterial resection and graft have failed to arrest gangrene, Syme's amputation. These patients should understand the great risk of failure.
4. In all cases of gangrene with infection, and in diabetics with infection where carbohydrate-metabolism disturbance is not yielding to treatment, a preliminary guillotine amputation.

5. Success in the Syme, or other type of tarsal amputation, gives a degree of activity otherwise impossible. Such cases may expect trouble in the other limb.

6. Amputation between the knee and ankle (below-knee) is not advisable in cases of severe vascular disease.

7. Amputations through the knee (Gritti-Stokes) are almost always successful in healing and give good walking comfort where the patient's condition warrants. Such patients frequently have severe cardiac and cardiovascular lesions, and activity may result in sudden death.

—*G. M. D.*

# Prostheses for Syme's Amputation

A. BENNETT WILSON, JR.<sup>1</sup>

Whereas detailed information on Syme prostheses prior to the turn of the 20th century is not readily to be had, the catalogs issued by limb manufacturers in the early 1900's seem invariably to include a description of a prosthesis for the Syme stump. Of many different designs offered, some used articulated ankles (if space were available below the stump and socket), some used rubber feet without ankle joint. Wood sockets, steel-reinforced leather sockets, and even cast aluminum sockets were available. Though most manufacturers showed prostheses with a full-length anterior opening for entry of the stump, there also were designs employing a partial anterior opening, and at least one used a full-length posterior opening.

The descriptions accompanying the catalog presentation of these devices indicate that the originators were themselves aware of most of the problems involved in designing a prosthesis for the Syme stump. One design of the Winkley Artificial Limb Co. (16) had no ankle joint because, according to the designer, in many cases no known ankle unit small enough to fit into the available space could withstand the high stresses involved. When ankle joints were provided (Fig. 1, left), a steel-reinforced leather socket was used; when space limitations precluded use of an ankle joint (Fig. 1, right), use was made of a willow wood socket, presumably to provide a base for attaching the felt or sponge-rubber feet available at the time.

Gaines-Erb (6) used a wood socket with a full below-knee socket at the top and only a partial opening on the anterior aspect so that it was possible to make any desired distribution of weight-bearing between distal and proximal areas of the stump (Fig. 2). Marks

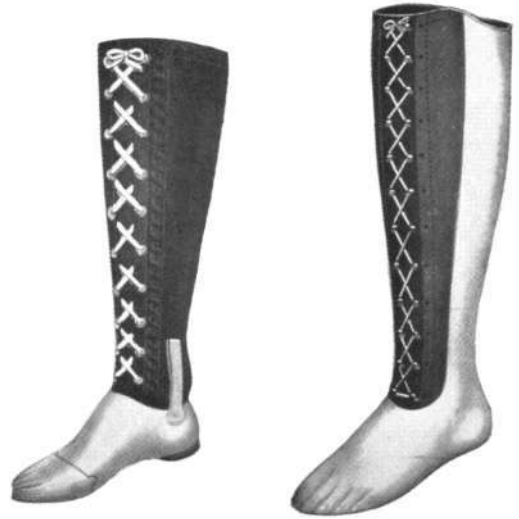

Fig. 1. Two types of Syme prostheses offered by the Winkley Artificial Limb Company, Minneapolis, circa 1910. Design at left incorporates an articulated ankle, that at right a foot without ankle joint, presumably of rubber.

(12,13) was aware of the need for distributing uniformly along each side of the tibia the loads developed on the stump during roll-over and, realizing that this requirement was rarely met with an anterior opening and lacing, attempted to solve the problem by using a cast aluminum socket with appropriate relief for the tibial crest and other sensitive areas (Fig. 3). A leather cuff closing the posterior opening encircled the shank to an anterior lacing, and the Marks rubber foot must have permitted a good cosmetic effect. An earlier version of the Marks foot, one of wood, illustrates the extent to which the inventor went to achieve resistance to the high forces developed in the area of the ankle (Fig. 4).

In a 1919 design by Bowler (1), dorsiflexion bumpers were replaced by a strap between the posterior surfaces of the socket and the foot

<sup>1</sup> Staff Engineer, Committee on Prosthetics Research and Development, National Academy of Sciences—National Research Council, 2101 Constitution Ave., Washington 25, D. C.



(Fig. 5), a feature also suggesting an appreciation of the high stresses involved in the ankle-joint mechanism. Not only were the unit stresses in the resisting material thus reduced but during dorsiflexion the forces on the ankle joint itself remained compressive instead of becoming tensile, a condition favoring longer life. Instead of being in the usual medial and lateral positions, the metal straps reinforcing the leather socket were anterior and posterior, where they were least bulky and most effective



Fig. 2. Syme prosthesis offered by the Gaines - Erb Company, Denver, circa 1915. Note provision for weight-bearing about the proximal portion of the shank.

structurally. A Syme prosthesis available from the Columbus Artificial Limb Company (2) employed the posterior strap patented by Bowler and added an anterior elastic strap, presumably to maintain compressive forces on the ankle joint during plantar flexion (Fig. 6), but the idea of anterior and posterior reinforcing straps, as proposed by Bowler, was discarded.

In almost all cases, lack of materials easily molded and with adequate strength but light in weight resulted in a certain bulkiness and heaviness that tended to produce a certain amount of discomfort for the wearer

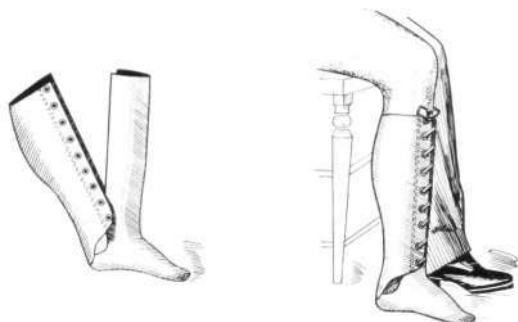


Fig. 3. Syme prosthesis offered by A. A. Marks, Inc., New York, early in the 20th century. The shank-socket, cast from aluminum, contained a posterior opening. A rubber foot was used routinely.

even if the fit itself were comfortable. In an effort to decrease weight and size, some prosthetists fabricated devices with marginal strength characteristics, devices which seldom lasted as long as comparable ones intended for leg amputations at other levels. The prosthesis that by 1940 seems to have been fitted almost routinely in both the United States and Canada consisted of a leather socket, reinforced with steel straps along the medial and lateral sides and made with a lacer and soft leather tongue along its anterior aspect (Fig. 7). Feet were generally of the so-called "conventional" type employing a single-axis ankle joint (often placed lower than usual) and incorporating foreshortened rubber bumpers. It was often uncomfortable, usually bulky because the sidebars projected beyond the bulbous end of the stump, and highly subject to mechanical failure of the sidebars.

With the introduction of plastic laminates (15) into the practice of prosthetics, research workers at the Prosthetic Services Centre of the Department of Veterans Affairs, Toronto, were quick to realize that the use of plastic laminates might well result in the development of a Syme prosthesis to a great extent free from the shortcomings of Syme prostheses previously used. Prior attempts to use laminated wood-veneer sockets had failed to produce practical prostheses owing to the difficulty of molding about the bulbous end, but the results encouraged the investigators to proceed with the then newly developed fabric-plastic laminates. The first model that showed promise (3) consisted of a socket molded of a polyester-Fiberglas laminate with a neoprene-crepe foot reinforced by a polyester-Fiberglas keel extending from the distal end of the socket (Fig. 8). To provide more comfort along the anterior aspect of the stump, the opening for

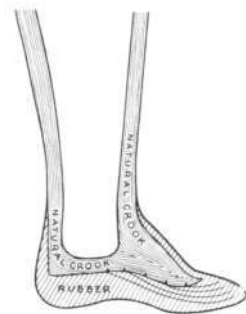


Fig. 4. An early version (circa 1889) of a Syme prosthesis manufactured by A. A. Marks, Inc. Socket and keel were formed from a single piece of wood so selected that the grain afforded maximum strength.

entry of the stump was cut out of the rear section of the socket, stability being obtained by replacing the cutout section and holding it in place by a metal fitting at the bottom and a strap and buckle at the top.

Although use of plastic laminate materially reduced bulkiness, and although the nonarticulated foot eliminated many of the problems associated with the so-called "conventional" unit, mechanical failure in the socket where the cutout was largest occurred too frequently for the new prosthesis to be adopted as a standard item (3). Fibreglas roving (loosely spun cords of Fibreglas molded in place along the edges of the cutout) increased the strength of the socket, but it was necessary to substitute

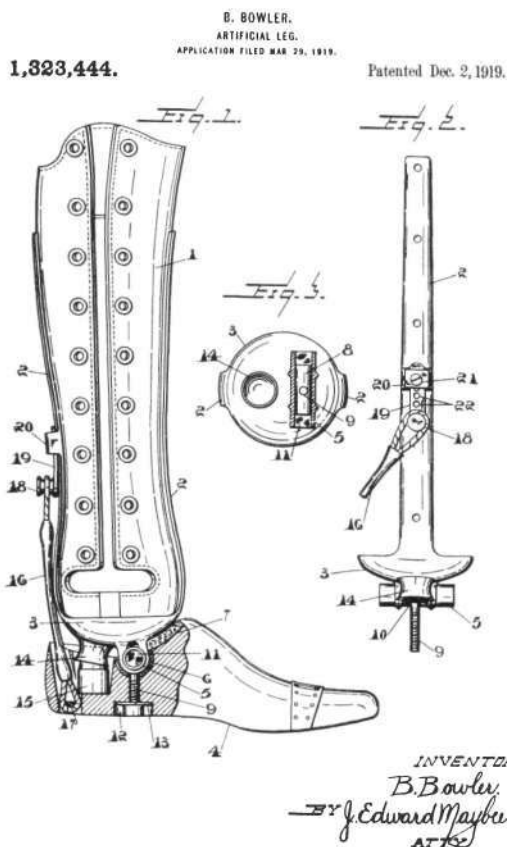


Fig. 5. Syme prosthesis patented by Bowler (1) in 1919. First known attempt to improve appearance by use of an opening on the side of the socket, reinforcing straps on the anterior and posterior surfaces. A flexible cable, another novel feature, provided resistance to dorsiflexion without placing the ankle parts in a state of tension.

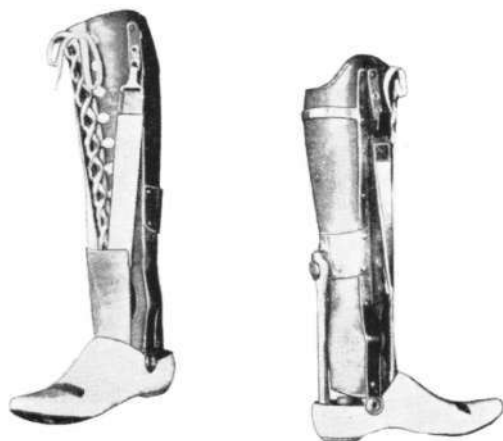

Fig. 6. Syme prosthesis offered by the Columbus Artificial Limb Company, Columbus, Ohio, circa 1925. Some of the features of the Bowler patent (1) are incorporated. Cf. Figure 5.

epoxy resins (much better adhesion to the glass fibers) for the polyesters before fully adequate strength could be obtained. With a few refinements, this prosthesis (Fig. 9) is in use routinely today by the Canadian Department of Veterans Affairs (4).

Attempts by workers in the Artificial Limb Program in the United States to employ the Canadian technique using polyester-Fibreglas laminates led to the same kinds of mechanical failures experienced by the Canadians (5,7,8). In addition, a good proportion (14) of the Syme cases fitted could not continue to assume full end-bearing comfortably throughout the entire day. This experience, coupled with a reluctance to employ Fibreglas if the more convenient nylon stockinet (15) could be used, or to use the first-available epoxy resins because of the inherent toxicity of the wet, uncured resin when mixed with the hardener,<sup>2</sup> led to the development of the "Medial-Opening Plastic Syme Prosthesis" (Fig. 10) at the Veterans Administration Prosthetics Center (10,11). To reduce the unit stresses along the periphery of the cutout necessary for entry of the stump, the cutout was made in the medial wall of the socket (page 68). Unlike the posterior cutout in the Canadian version, the medial opening does

<sup>2</sup> The recent introduction of polyamide hardeners has since greatly reduced the risk of the fabricator's contracting dermatitis.

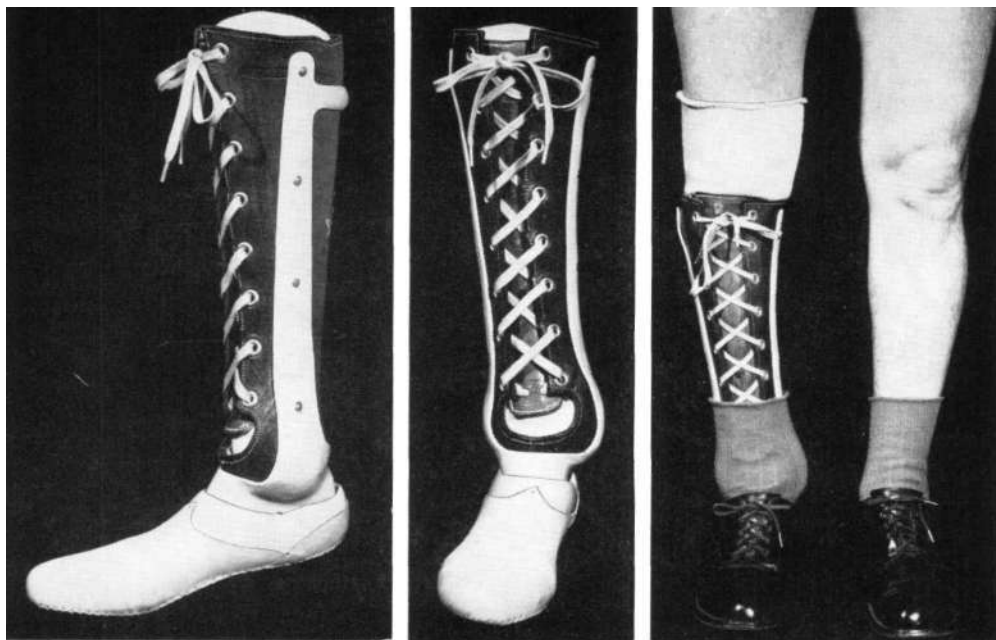


Fig. 7. Syme prosthesis typical of the era before introduction of plastic laminates into the fabrication of Syme prostheses.

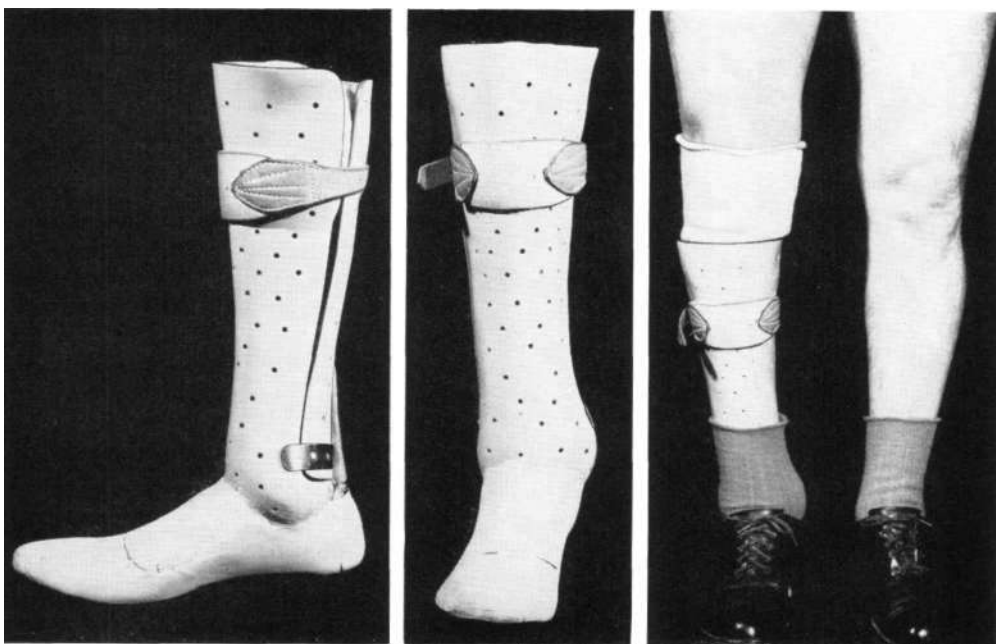

Fig. 8. An early version of the Canadian-type plastic prosthesis for Syme's amputation. The nonarticulated foot was in this instance constructed of a neoprene crepe of uniform density.

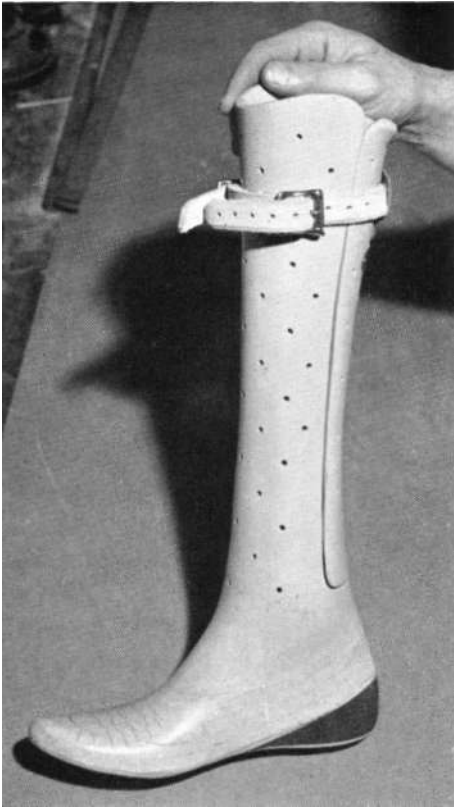

Fig. 9. The Syme prosthesis now adopted as standard by the Canadian Department of Veterans Affairs. The plastic laminate consists of Fiberglas cloth and roving impregnated with an epoxy resin, and the posterior opening extends the length of the shank.

not extend upward to the brim of the socket but resembles a door, an arrangement which permits the Syme case to be so fitted that all or any part of the weight may be carried along the brim of the socket. The foot is a commercially available version of the SACH foot (5).

Concurrent with the development of the medial-opening plastic Syme prosthesis at the Veterans Administration Prosthetics Center, the Prosthetics Research Center of Northwestern University introduced into the Canadian technique a number of refinements which might also be applied in fabricating and fitting the medial-opening type of prosthesis. Of especial interest are a new method of obtaining casts of Syme stumps and a method of attaching a SACH foot to permit greater latitude in alignment of the foot with respect to the socket,

including also a method of reinforcing the keel of a SACH foot should that be necessary in individual cases.

Manuals (4,10) containing detailed, step-by-step procedures for fabricating, fitting, and aligning the Canadian and the medial-opening Syme prostheses are available, and details of the Northwestern techniques have been published (9). An outline of all of these procedures is given here so that any might be adopted singly or in combination to meet the requirements of individual patients.

#### THE CANADIAN-TYPE PLASTIC SYME PROSTHESIS

##### TAKING THE MEASUREMENTS AND MAKING THE MODEL

All anatomical measurements necessary for constructing the Canadian-type plastic Syme prosthesis are taken while the patient bears his body weight on the end of the stump. Placed under the stump is a block of wood of such thickness as to maintain the pelvis in a horizontal position, and the anteroposterior dimension, the width, and the circumference of the stump are recorded, all at the level of the largest part.<sup>3</sup> For use later on in the alignment procedure, a line perpendicular to the floor and passing through the mediolateral center of the patella (Fig. 12) is marked on the stump with indelible pencil for eventual transfer to the plaster model.

After all sensitive areas and bony prominences, including the tibial crest throughout its length, have been similarly marked with indelible pencil, a cast is made using plaster-impregnated bandage, a longitudinal cut being made along the posterior mid-line to permit removal of the cast. Thereafter, a model of the stump is made by filling the cast with liquid plaster of Paris, a bar or pipe being inserted in the soft plaster at the proximal end to provide an extension to be used later in holding and handling the model.

##### MODIFICATION OF THE MODEL

Upon removal of the cast, a finishing nail (Fig. 13) is driven all but 1/4 in. into the bottom

<sup>3</sup> A special device, consisting of two wedges that can be moved with respect to each other so as to provide for rapid adjustment (Fig. 11), has been found to be a useful improvement over the single wood block.

of the model at the intersection of an anteroposterior extension of the vertical reference line and a medio-lateral line bisecting the area on the bottom of the model. The bulbous end is now built up by adding plaster until the dimensions conform to those recorded while the stump was bearing weight. At the same time, in order to allow space for a sponge-rubber pad in the finished socket, a layer of plaster  $1/8$ , in. thick is added to the bottom portion and faired in, leaving the nail protruding  $1/8$  in. So that a recess to receive a foot nut will be formed in the finished socket, a piece of leather or other suitable material  $1/8$  in. thick and  $1\ 1/4$  in. in diameter is pierced at its center and positioned on the protruding nail. To provide relief for the sensitive areas and bony prominences, skived leather patches are added to the model as appropriate.

The path of the sawline to be used in forming the cutout for stump entry is marked on the model, and metal wedges (Fig. 14) are inserted to facilitate the later re-establishment of the sawline on the exterior of the socket. The sawline itself is located by establishing on each side of the model a point  $3/8$  in. behind the anteroposterior mid-line of the model at the top and another point  $1/4$  in. behind the same mid-line at the level where the stump begins to bulge (Fig. 13). Two metal wedges are inserted well apart on each of these lines,  $1/4$  in. being left to protrude. After the model has dried thoroughly and three coats of cellulose-acetate lacquer have been applied, it is ready for use in fabricating the prosthesis.

#### LAMINATION

In the lamination of Fiberglas with epoxy resins, rapid work is essential to obtain the best structural results, and accordingly it is desirable here that this operation be performed by two persons working together. The model is held vertically in a vise, a brush coat of epoxy resin is applied, and a length of 10-strand



Fig. 10. Syme prosthesis developed by the Veterans Administration Prosthetics Center, New York. The nylon-dacron-polyester socket is provided with an opening in the medial wall. Weight-bearing may be divided, in any proportion, between the proximal rim and the distal portion of the socket.

Fiberglas roving is laid along the anterior side of each of the vertical portions of the sawline and fanned out over the end of the bulbous portion of the model (Fig. 15). The multiple-strand roving is held in place by encircling the model and roving with a piece of single-strand roving.

A piece of Fiberglas cloth 4 in. longer than the length of the model and 2 in. wider than its circumference at the largest part is laid up over the model so that the surplus length is placed distal to the bulbous end, and the whole is tied in place with single-strand roving (Fig. 15). The surplus length is then slit vertically every 2 in. along the periphery and laid over the bulbous end of the model, and the entire piece of cloth is saturated with the resin. Three additional pieces of Fiberglas cloth of the same size are applied in the same manner but are so placed that none of the vertical overlaps coincide.

To complete the lamination, four pieces of

Fiberglas cloth 2 in. wide and about 2 in. longer than twice the length of the model are applied, one at a time, with the transverse centers of the strips located over the bulbous end and positioned approximately 45 deg. apart (Fig. 16). The entire assembly is held in place by a spiral wrapping of single-strand roving, and after application of a final brush coat of resin a snugly fitting sleeve of polyvinyl alcohol film (PVA) is pulled over the layup, the lower end being tied snugly to the holding rod, the top end trimmed to a point 5 in. from the end of the

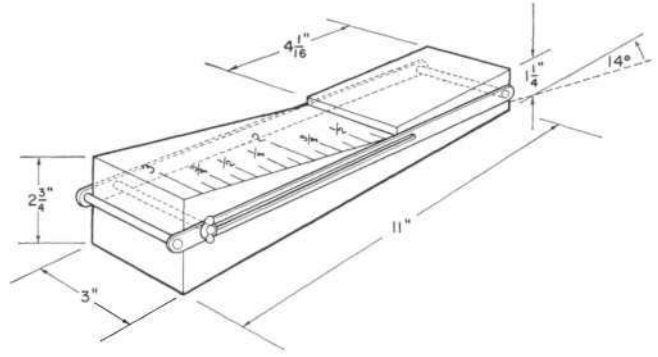


Fig. 11. Special device used in taking measurements of the Syme stump while the stump is bearing weight.

model. To compress the laminate and to remove air and excess resin, the layup is wrapped tightly in spiral fashion with a strip of PVA 2 in. wide, the wrap starting from the holding end of the model (Fig. 17). To the excess resin thus forced upward into the top end of the sleeve there is now added as much chopped roving as possible so as to form an extension around which the foot may be fabricated.

After curing for 30 min. at room temperature (or 45 min. at 250° F. if time is important),<sup>4</sup> the laminate is cut, with a cast cutter or other suitable device, along the lines defined by the protruding wedges. At the lower portion of the cutout, large radii are used, and the lowest point reached is just proximal to the point of maximum anteroposterior socket diameter.

MAKING THE FOOT

After the laminated parts, socket and cutout, have been removed from the model, the extension is so shaped by grinding that the foot

<sup>4</sup> In an alternate, and preferable, procedure, the layup is allowed to gel at room temperature overnight and then, after the cutout has been made, replaced over the model, fastened in place by suitable straps, and cured for 30 min. at 225° F.

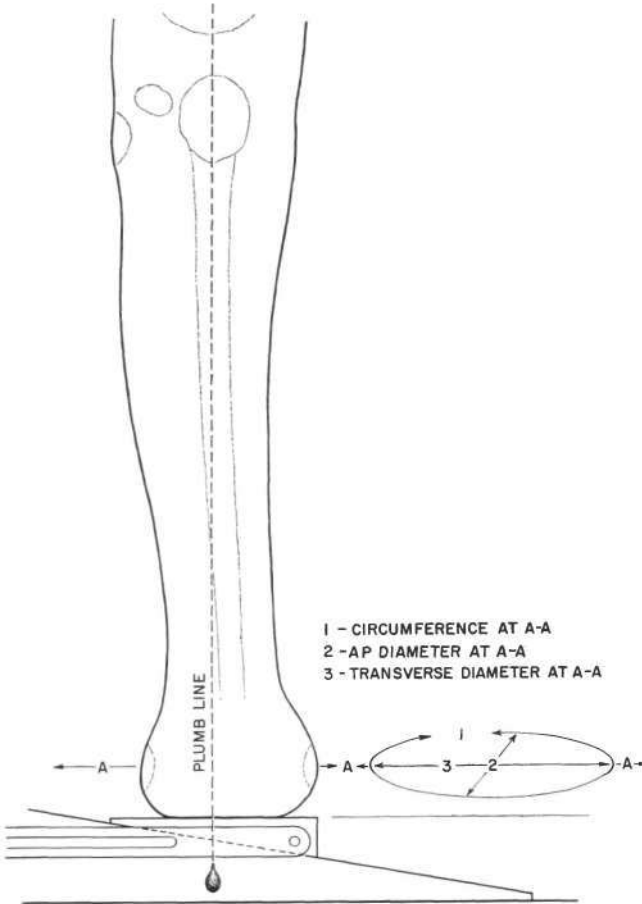


Fig. 12. Stump measurements required for fabrication of socket for the Canadian-type plastic Syme prosthesis.

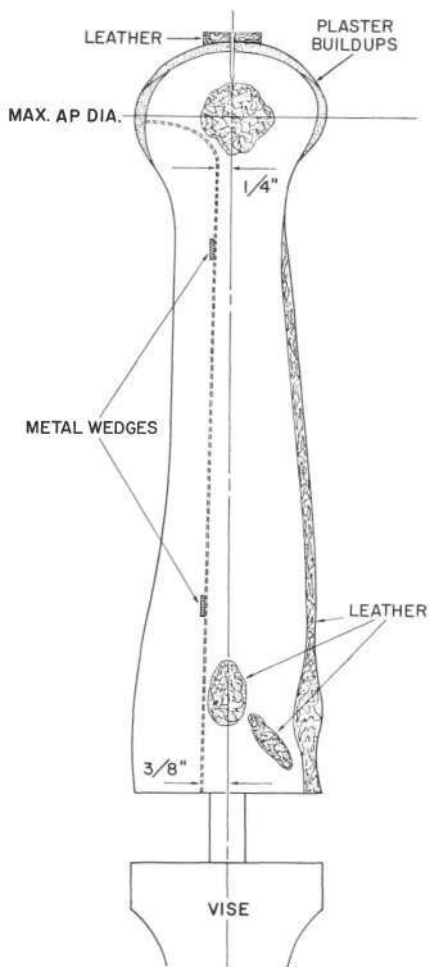


Fig. 13. Plaster model of stump just before application of Fibreglas. It is easier to modify the model before the plaster has hardened completely.

may be built around it. By means of a standard foot nut and a bolt 1 1/4 in. in diameter (Fig. 18), the keel (Fig. 19), formed from a strip of aluminum alloy (7075-T6) 1 1/4 in. wide and 0.128 in. thick, is fastened to the extension at the point indicated by the recess formed in the bottom of the socket.

For most adults, two thirds of the length of the keel is placed ahead of the center of the socket, but the proportion may be varied to suit individual cases. To

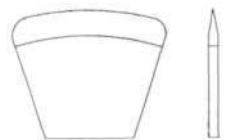

Fig. 14. Steel wedge used to outline cutout, shown twice actual size.

provide reinforcement during the fitting procedure, a piece of wood is bonded temporarily to the keel and socket extension by use of epoxy paste.

A 4-ply rubber-fabric belting 4 in. wide and four pieces of 18-iron neoprene sponge are now laminated (with Barge's cement) to the configuration shown in Figure 19, the neoprene layers being slotted to receive the keel. A wood block 4 in. wide and shaped to conform to curve A-A in Figure 19 should be used to assist in holding the layers in place while bonding is effected.

When the initial bonding of the neoprene and belting is fully set, a layer of 9-iron neoprene sponge is bonded to the underside of the belting, and a wedge of some resilient material is added to form the heel. Material for the heel, selected to meet the particular requirements of the individual patient, may be neoprene sponge, rubber sponge, solid rubber, or some other elastomer. Finally, the foot is cut and ground to the shape necessary to fit the shoe.

#### ALIGNMENT AND ASSEMBLY

Temporary attachment of the foot to the keel (Fig. 20) is effected by driving a 1/8-in. steel pin transversely through the heel section just ahead of the end of the keel (Fig. 19). The corset, the portion of the socket that has been cut out, is now provided with the means for holding it in place—a tongue-and-slot arrange-

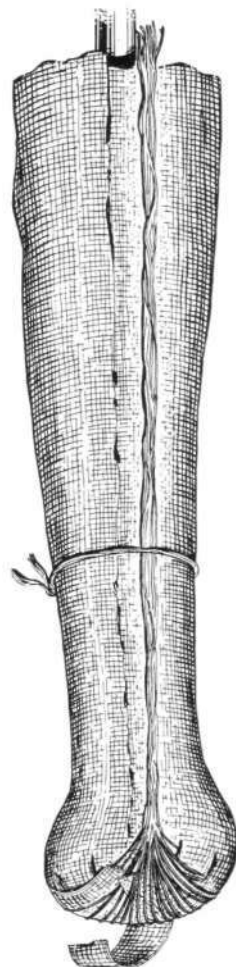


Fig. 15. First layup of Fibreglas roving and cloth. Note that roving is fanned out over ball of model.

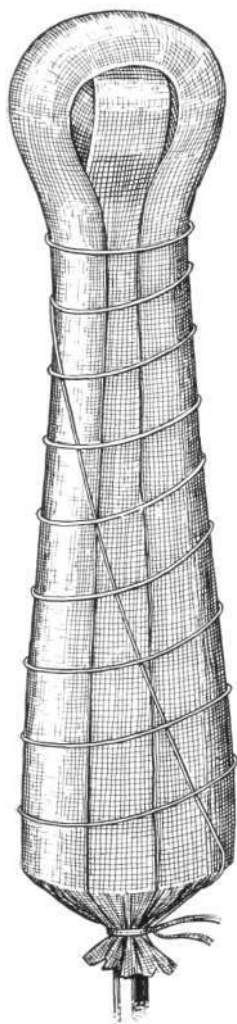


Fig. 16. Layup of longitudinal strips of Fiberglas cloth just before application of PVA bag.

obtained, a 1/8-in. hole is drilled through the aluminum keel into the socket extension, and a 1/8-in. dowel of cold-rolled steel (Fig. 19) is driven into the hole. The established alignment may thus be reproduced upon re-assembly during the finishing process. To achieve maximum rigidity of the keel, the temporary wood block is removed, two steel rods each 1/8 in. diameter are inserted into holes drilled in the anterior surface of the socket extension and allowed to extend into the cavity,

ment at the bottom (Fig. 21) and an encircling leather strap in the calf area (Fig. 9). Details of the parts required are shown in Figures 22, 23, and 24. The metal pieces are bonded and riveted to the laminated parts. Two buckles are recommended as a precaution against the possible loss of use of a particular eye in the strap (Fig. 9).

After a pad of felt or neoprene sponge, carved to fit the bottom of the socket and the end of the stump, has been placed in position, the prosthesis is ready for final alignment. The relationship between the keel and the socket may be changed by removing the attaching bolt and keel and changing the configuration of the socket extension, either by grinding or by adding shims. When the desired alignment has been

and the cavity is filled with a mixture of epoxy resin and chopped Fiberglas roving.

The aluminum surfaces must be clean to ensure an adequate bond. All gaps between keel and neoprene are filled with epoxy resin, and a fairing between the foot and socket is fashioned from a mixture of epoxy resin and fine sawdust, which after curing can be ground and sanded to shape. If desired, small holes may be drilled through the socket wall to furnish ventilation. When, after sanding, the outside of the socket and corset have received a coat of enamel, and when the neoprene parts of the foot have been sealed with two light coats of cellulose-acetate lacquer, the prosthesis is ready for use (Fig. 25).

#### THE MEDIAL-OPENING PLASTIC SYME PROSTHESIS

##### TAKING THE MEASUREMENTS

The anatomical data considered necessary for fabrication of the medial-opening socket are somewhat more extensive than are those suggested as being needed in the Canadian technique. In addition to determining the distance from the end of the stump to the floor

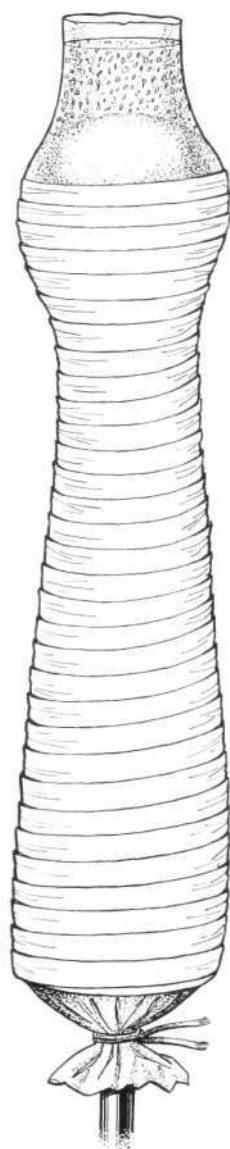


Fig. 17. Lamination for socket, ready for curing. Note extension for keel, formed by introducing resin and chopped Fiberglas roving into end of PVA bag.



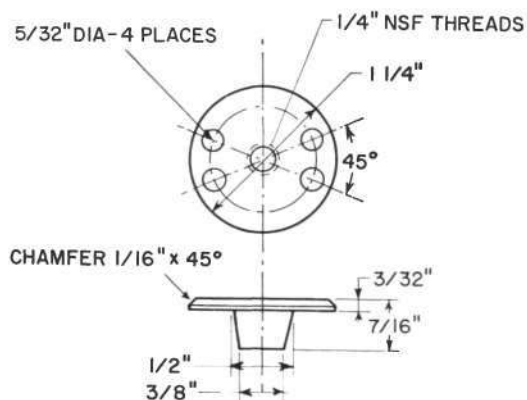


Fig. 18. Standard steel foot nut used by the Canadian Department of Veterans Affairs.

stump to the medial tibial plateau are read while the stump is free of weight-bearing. At each level measured, marks are made with indelible pencil. A form for recording the required information is shown in Figure 26.

#### MAKING THE CAST AND THE MODEL

To protect the stump from the plaster of Paris used in making the cast, a length of cotton stockinet, sewed at one end, is pulled over the stump and secured by an elastic band above the knee. Outlines of sensitive areas and bony prominences are made on the stockinet with an indelible pencil so that they will be transferred to the cast and in turn to the

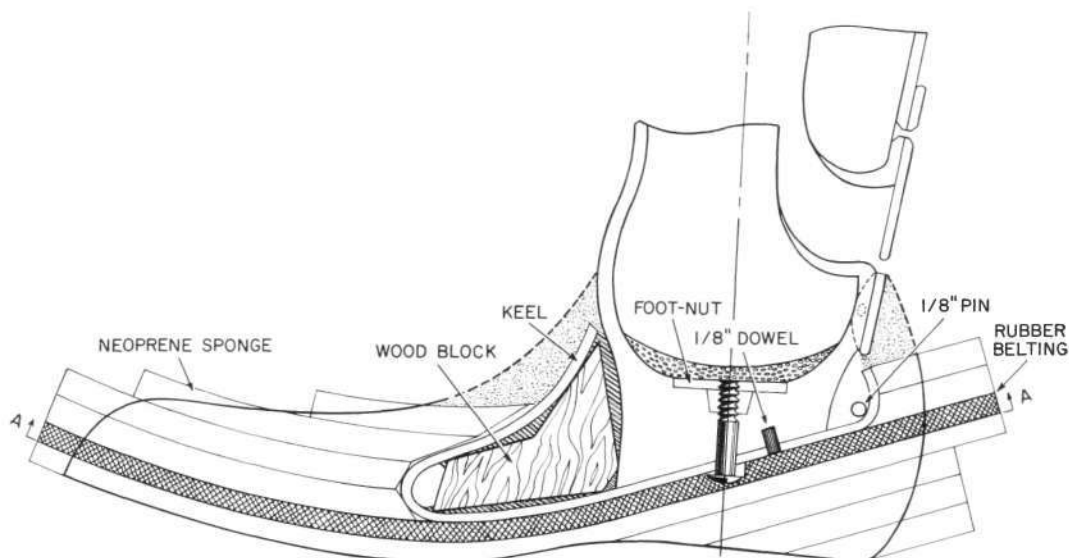


Fig. 19. Cross-section of foot and lower end of Canadian-type plastic Syme prosthesis. Before final assembly, the wood block is replaced by epoxy resin and chopped Fiberglas roving.

while the stump is bearing half of body weight,<sup>5</sup> circumferential measurements of the stump are made at 1-in. intervals in the first 5 in. of the stump while it is in the weight-bearing condition. Besides this, circumferences at these five levels and also circumferences at 2-in. intervals from a point 5 in. from the end of the

<sup>5</sup> Because a neoprene sponge-rubber pad will be used later in the end of the socket, it is recommended by VAPC that a sponge-rubber pad 1/4 in. thick be used between the stump and the supporting block (Fig. 26).

model for guidance in making appropriate modifications.

Although the particular method of obtaining a cast is not critical provided a faithful model of the stump can be obtained ultimately, the Veterans Administration Prosthetics Center suggests a method wherein the cast is made in two pieces, so as to eliminate the need for cutting the plaster to remove the stump.<sup>6</sup> To

<sup>6</sup> The same technique can, of course, be applied in obtaining any cast that requires separation for removal of the stump.

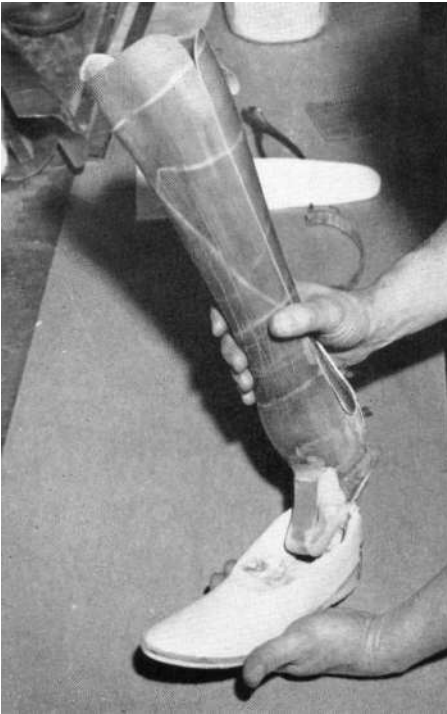

Fig. 20. Insertion of keel into neoprene portion of foot.



Fig. 21. Tongue-and-slot method of holding corset in place. Tongue and slot are held in place temporarily by the bolts and wing nuts. Epoxy resin and rivets are used for permanent attachment.

obtain the two-piece mold, the end of the stump is first wrapped with 3-in. plaster bandage to the level of greatest circumference (Fig. 27). A slab of five layers of plaster bandage 6 in. wide is then molded against the entire anterior half of the stump and secured in place by a few turns of 3-in. plaster bandage at the narrow part of the shank and again at the area just below the patella (Fig. 28). So that the cast, and hence the model, will approach the configuration of the stump in the weight-bearing condition, the plaster is allowed to harden while the patient bears weight through the distal end (Fig. 29), a sponge-rubber pad being placed between the bottom of the cast and the supporting block. As the plaster hardens, the edges should be faired to the stump.

Lateral and medial centerlines are now

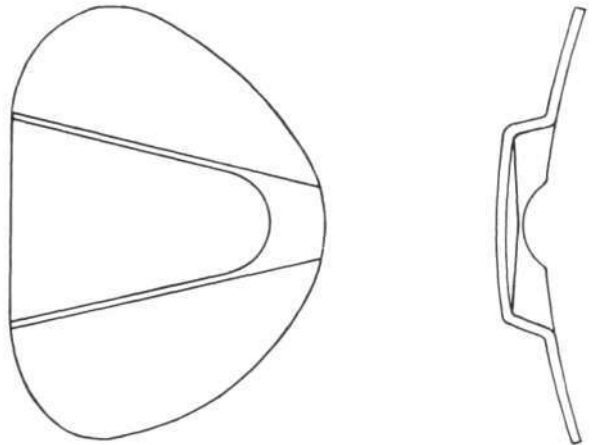


Fig. 22. Slot, shown actual size. Aluminum 0.040 in. thick.

drawn on the anterior portion of the cast for guidance in forming the parting line, petrolatum is applied to the exposed stockinet, and a similar slab of plaster bandages is molded to

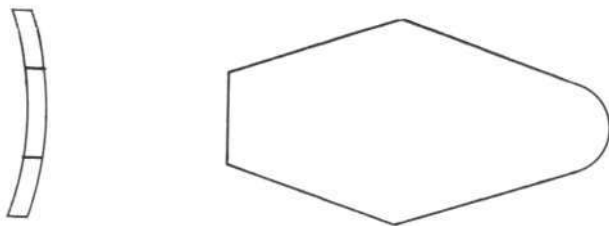


Fig. 23. Tongue, shown actual size. Aluminum 0.125 in. thick.

the posterior portion of the stump up to the lateral and medial centerlines (Fig. 30). Lines drawn transversely across the seams at several levels serve as reference points for proper reassembly of the cast after removal from the stump. Before pouring of the model is started, the indelible marks on the interior of the cast should be retraced to ensure a satisfactory transfer. For the pouring operation, the two halves may be held together by a wrapping of plaster bandage.

#### MODIFICATION OF THE MODEL

So that the finished socket will fit snugly along the sides of the tibia and yet not press unduly on its crest, plaster is removed from the model along each side of the area representing the tibial crest (Fig. 31), and a long leather patch, skived in the usual manner, is glued in place on the plaster. Skived leather patches also are attached at the points representing the malleoli, over areas corresponding to the flare of the condyles, and at any other points that will require relief in the finished socket (Fig. 32). Then the posteroproximal end of the model is flattened somewhat to provide for stability between socket and stump about the longitudinal axis. Finally, to make certain that the distal end of the socket will be of the proper volume to accommodate a sponge-rubber pad

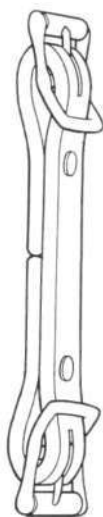


Fig. 24. Double-buckle assembly used to secure corset in place.

for cushioning the end of the stump, a circular piece of sponge rubber 1/4 in. thick is skived and glued to the distal end of the model (Fig. 33). All modifications of the model are made with reference to the circumferential measurements taken earlier, *i.e.*, the measurements over the distal 5 in. of the stump during weight-bearing and those above during relaxation are maintained.

#### THE SOFT SOCKET LINER

To provide more comfort for those patients expected to take some or all weight-bearing along the proximal end of the socket, a liner of neoprene sponge rubber covered with horsehide is provided. When a liner is to be used, a horsehide sleeve is molded around the model upward from a point 5 in. below the medial tibial plateau. Sponge-rubber sheet 1/8 in. thick is formed over the horsehide, 3/4 in. of the distal end of the leather being left exposed (Fig. 33). The distal end of both the horsehide and neoprene are skived.

#### LAMINATION

Unlike the procedure described for fabrication of the Canadian-type plastic Syme prosthesis, wherein the corset (or cover for the cutout) consists of the laminate that was cut from the socket, in the VAPC prosthesis the socket and the cover for the cutout may be laminated separately. Thus, it is here possible to begin with a socket cutout a little too small, trim away only as much material as necessary to permit easy entry of the stump, and still have available a piece of laminate large enough for a cover.

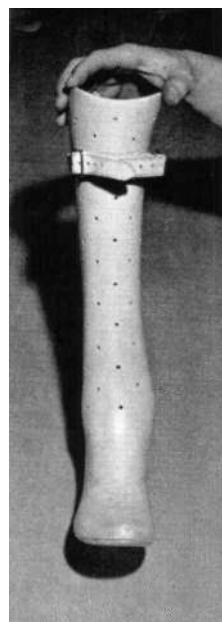


Fig. 25. Completed Canadian-type plastic Syme prosthesis.

To prevent adherence of laminate to the sponge-rubber pad (and to the soft socket liner if one is used), a snugly fitting sleeve of polyvinyl alcohol is pulled over the model and tied neatly at each end. The recommended laminate filler consists of two layers of dacron felt inside and ten layers of nylon stockinet outside. Like the PVA, the dacron felt must also be tailored into snugly fitting sleeves. If the nylon stockinet is cut into lengths slightly more than twice the length of the model, and if each length is then sewed transversely at the middle, a very neat layup can be obtained by successively pulling one half of a length over the model as far as possible and then pulling the other half over while turning it inside out. Instead of coinciding with one another, the individual transverse stitchings should be spaced equally as spokes in a wheel, the second being 36 deg. away from the first, the third 36 deg. away from the second, and so on (Fig. 34).

A sleeve of PVA film is now drawn over the layup, and a polyester resin is introduced. To date, best strength characteristics have been obtained from a mixture of 70 percent of the "rigid" type of resin and 30 percent of the "flexible" type (11,15).

Material for the medial cover is made by laminating three layers of nylon stockinet over the socket layup after it has been allowed to stand for one hour at room temperature. Resin is introduced on the medial side only (or only in that area selected for the cutout). After an additional hour of curing at room temperature, the entire assembly is subjected to a temperature of 180-190° F. for 25 min. The outer shell can now be cut and removed and the impregnated portion saved for use later (Fig. 35).

MAKING THE OPENING

The socket opening can best be cut out while the laminate is still warm. In order that the opening shall be the minimum needed for intro-

PROSTHETIC INFORMATION FORM

NAME \_\_\_\_\_ DATE \_\_\_\_\_  
 RIGHT \_\_\_\_\_ LEFT \_\_\_\_\_ SHOE SIZE \_\_\_\_\_  
 AGE \_\_\_\_\_ WEIGHT \_\_\_\_\_ PROSTHETIST \_\_\_\_\_  
 ACTIVITY LEVEL \_\_\_\_\_ OCCUPATION \_\_\_\_\_  
 WEIGHT OF FINISHED PROSTHESIS \_\_\_\_\_ DATE OF DELIVERY \_\_\_\_\_

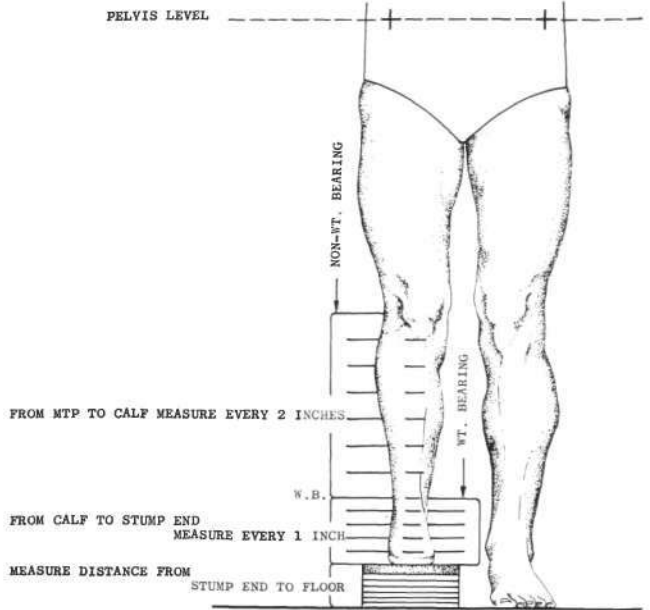


Fig. 26. Form for recording measurements and other information necessary for fabrication and fitting of a Syme prosthesis (VAPC type). From Iuliucci (10).

duction of the stump, the initial aperture is deliberately made undersize, later enlarged by trimming the edges little by little until the patient can insert the stump without experiencing discomfort. The outline of the initial opening is determined by a horizontal line 1 in. above the point of maximum circumference of the bulbous portion of the socket, two lines parallel to and medial to the line of the tibial crest (one being 3/4 in. medial, the other medial by 3/4 in. plus 1/4 of the circumference of the bulbous portion 1 in. above its maximum circumference), and a horizontal line at that point on the socket where the circumference is the same as that 1/4 in. above the point of maximum circumference at the bulbous end (Fig. 36). Because further trimming will be necessary, the dimensions of the radii at the corners are not critical at this stage.

After the initial cutout has been made, the excess material trimmed away, the plaster re-

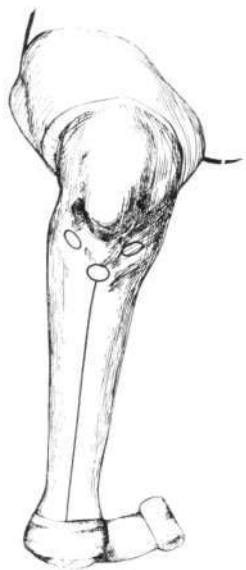

Fig. 27. First step in obtaining a plaster impression of a Syme stump. A plaster bandage 3 in. wide is applied over the end of the stump to the level of greatest circumference.

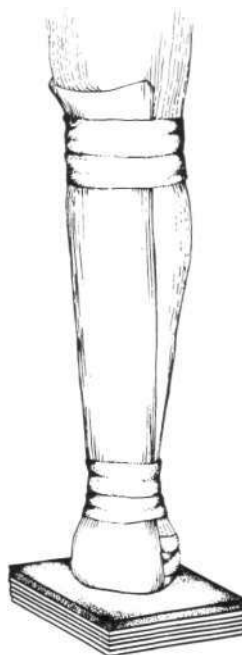

Fig. 29. Stump under weight-bearing conditions while anterior and distal portions of plaster impression are allowed to harden. The posterior portion of the impression is applied later.

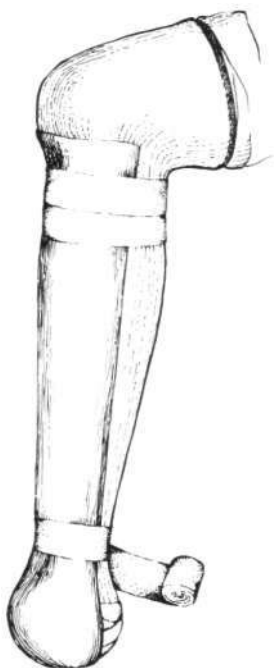


Fig. 28. Application of a slab of plaster bandage to anterior surface of stump to provide one half of a two-piece casting.

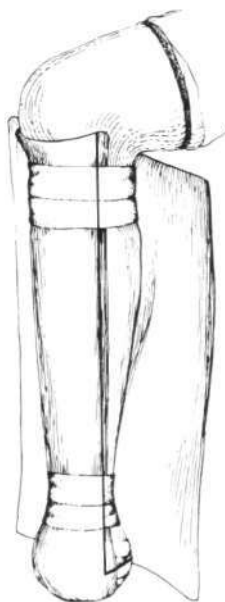


Fig. 30. Application of plaster-bandage slabs to form posterior portion of two-piece casting. Note parting line drawn on anterior casting.

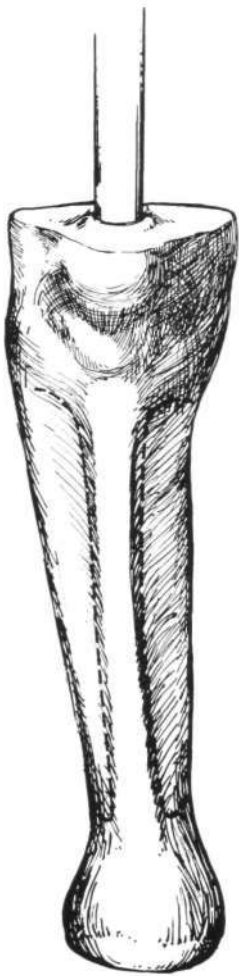

Fig. 31. Model showing where plaster should be removed so that in finished socket forces may be taken along each side of the tibial crest.

moved, and the proximal border of the socket trimmed, the cutout is enlarged enough that the patient can introduce his stump (Fig. 37). The radii of the corners should now be kept as large as possible, and the edges of the cutout should be smooth so as to contribute to the strength of the finished product by eliminating the high-stress areas commonly associated with mechanical nicks and notches.

#### ALIGNMENT AND ASSEMBLY

In most instances, satisfactory use can be made of one of the commercially available

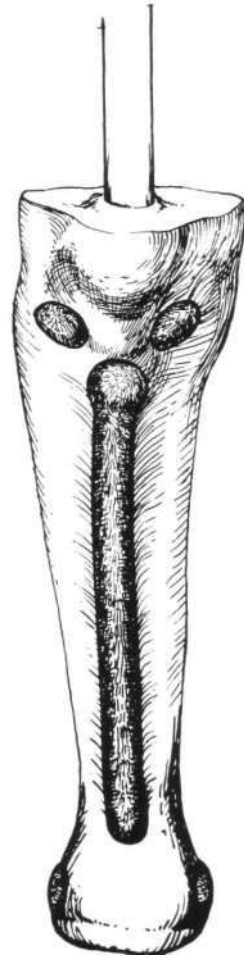


Fig. 32. Model with skived leather patches applied to provide in finished socket relief for sensitive areas.

SACH feet constructed especially for Syme prostheses. If not, a suitable SACH foot can be fabricated in accordance with the instructions given in the Canadian manual (4) or in the University of California report (5); or use can be made of the reinforcement technique introduced by Northwestern University (page 71).

When the commercial version is used, it is first shaped to fit the shoe, and a guide hole 1 1/4 in. in diameter is drilled in the keel to a height above the heel sole equal to the height of the block used while the anatomical measurements were taken (Fig. 38). The keel and neoprene crepe are then hollowed out to receive the

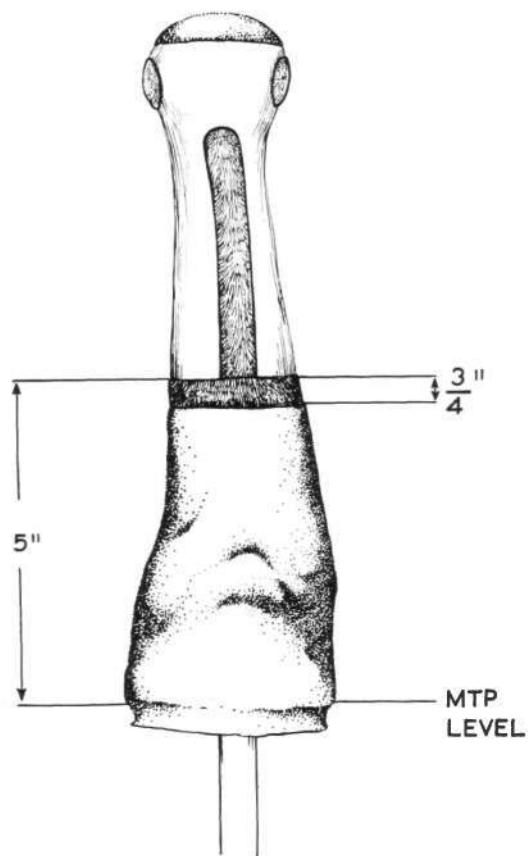


Fig. 33. Model with socket liner and sponge-rubber pad applied.

bulbous end of the socket. Because of the tendency of Syme stumps to bow toward the centerline of the body, usually both guide hole and hollow should be offset medially. Moreover, the foot should be placed as far forward as possible with respect to the socket and be set in a small amount of dorsiflexion (Fig. 39), and care should be taken to ensure that the bottom surface of the heel is parallel to the floor (Fig. 40). Such alignment should be effected by actually having the patient don the socket, place the distal end into the recess in the SACH foot, and assume a position of normal standing.

When initial, or static, alignment has been achieved, reference marks are made on the socket and foot to be used as a guide in reassembly, and masking tape (Fig. 41) is applied around the juncture of the two units to hold

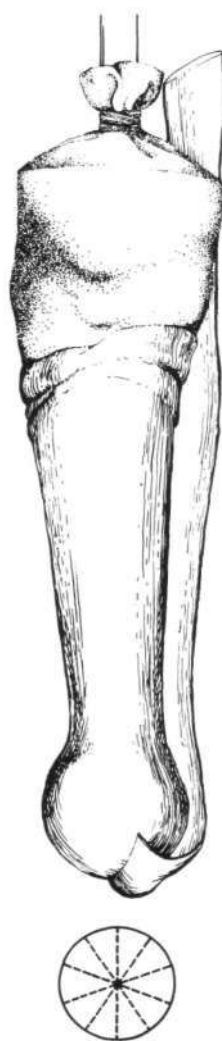


Fig. 34. Application of stockinet over model in preparation for laminating. Two layers of dacron felt have already been applied. Note seam sewed across stockinet to form neat layup at distal end of socket.

them in place while a 3/8-in. hole is drilled through the keel and socket to receive the attaching bolt. The hole in the socket is now enlarged to 5/8 in., and the hole in the keel is provided at the bottom with a 5/8-in. countersink to accommodate the nut (Fig. 42), both operations best being done with the prosthesis disassembled. A cover that will overlap the socket opening 3/4 in. around the periphery is cut from the section of laminate made for the purpose. After two single-buckle straps have been riv-

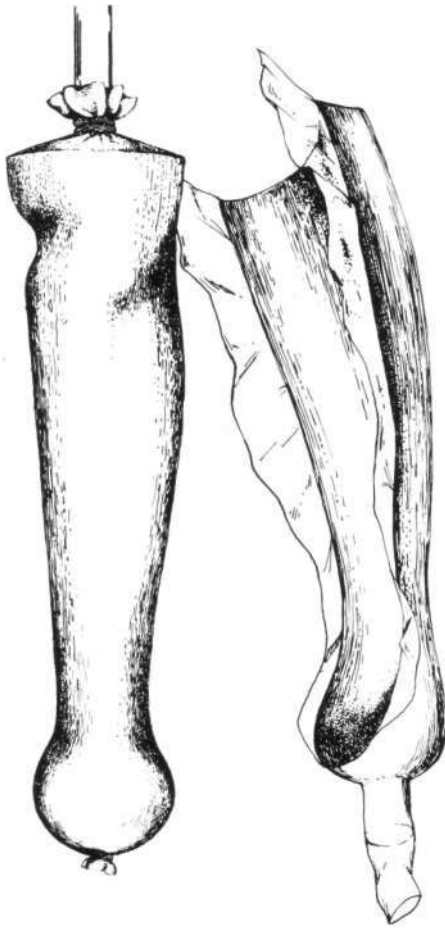


Fig. 35. Removal of laminate to be used later in fabrication of cover for opening in socket.

eted to the cover, a felt pad exactly fitting the opening is glued to the concave side, and the entire inner surface of the closure is lined with thin horsehide, care being taken to effect a rab-

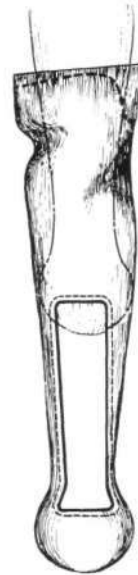


Fig. 37. Introduction of stump in socket to determine trim lines of cutout and, later, of proximal border.

betlike contour along the periphery of the felt (Fig. 43).

After the prosthesis has been assembled, dynamic alignment is effected under conditions of actual walking. Inserted into the socket in the form of contoured discs of sponge rubber is enough distal padding to distribute the forces as desired between the proximal end of the socket and the end of the stump. Slight changes in alignment can be brought about by enlarging the hole in the end of the socket.

Final finishing of the prosthesis includes bonding the foot to the socket, building up a smooth transition between foot and socket by use of a mixture of epoxy resin and chopped Fibreglas, and gluing the soft liner in place in the proximal area of the socket.

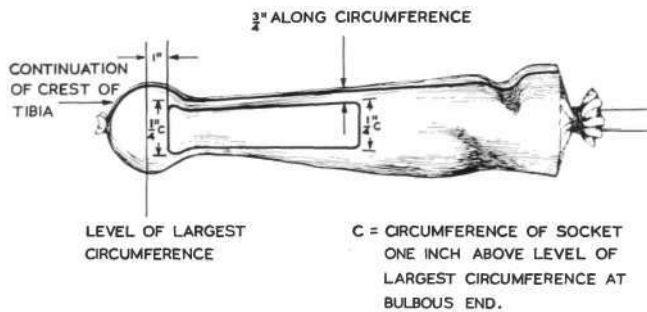


Fig. 36. Outline of initial cutout in socket.



DEVELOPMENTS AT NORTHWESTERN UNIVERSITY

TAKING THE CAST

Plaster of Paris in one form or another has been used for nearly a century in making impressions of limb stumps, and especially with the relatively new, quick-setting formulations it has proved to be fairly satisfactory. There are nevertheless certain disadvantages inherent in the use of plaster. Unless a separating medium is used, plaster will adhere to the skin. Cured plaster of Paris is extremely rigid, so that when plaster is used to take a cast of a stump like the Syme it is necessary either to cut the cast or to form it in two pieces. Furthermore, plaster is very dense and therefore heavy and comparatively hard to manage.

In an effort to overcome some of the difficulties associated with plaster, the Prosthetics Research Center at Northwestern University's Medical School has developed a procedure for taking a cast of a Syme stump with alginate, a material used by dentists in taking impressions of the gums and teeth. Because when mixed with water alginate gels rather rapidly into a rubbery solid, it seems especially useful in taking casts of bulbous stumps and of those intended to take end-bearing. To enable the gelled material to yield when the stump is withdrawn, the impression is made in a rigid, tapered cylinder lined with an oversize canvas bag which can be withdrawn so that the rubbery alginate is left free to be displaced as the bulbous portion is pulled through the narrow section of the impression (Fig. 44).

Since alginate solidifies so rapidly, and since so many factors (such as temperature and various impurities in the water used<sup>7</sup>) affect the rate of gelling, it is important always to check the gelling time on a small sample before actually taking an impression. The correct mixture should gel in about six minutes. A tapered can

<sup>7</sup> In certain areas best results can be obtained only with distilled water.

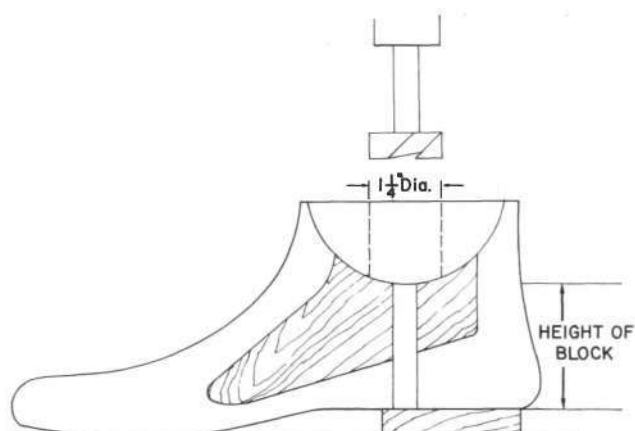


Fig. 38. Simplified cross-section of SACH foot showing certain modifications needed for use in Syme prosthesis. A hole 1 1/4 in. in diameter is drilled in keel to a depth corresponding to the height of the block used when measurements were taken (Fig. 26). The hole is used as a guide in removing material at top of foot to accommodate socket.

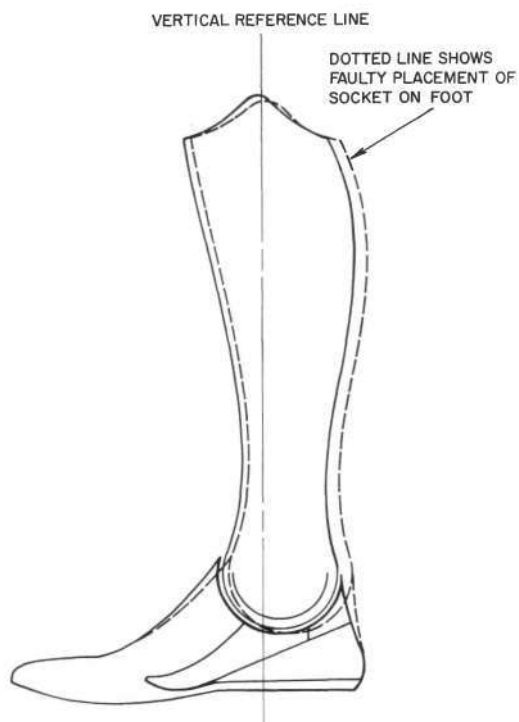


Fig. 39. Alignment of foot and socket in lateral view. Usually a slight amount of dorsiflexion results in best performance.

about 20 in. long, 5 1/2 in. in diameter at the bottom, and 6 1/4 in. in diameter at the top has

been found satisfactory for taking impressions in adults. The impression is taken while half of the body weight is borne by the stump,

*i.e.*, while the pelvis is level and the patient is standing with feet together.

After the stump has been removed, the bag and alginate are replaced in the conical can for pouring of the model, which should take place as soon as possible because the alginate has a tendency to shrink rather rapidly after gelling.

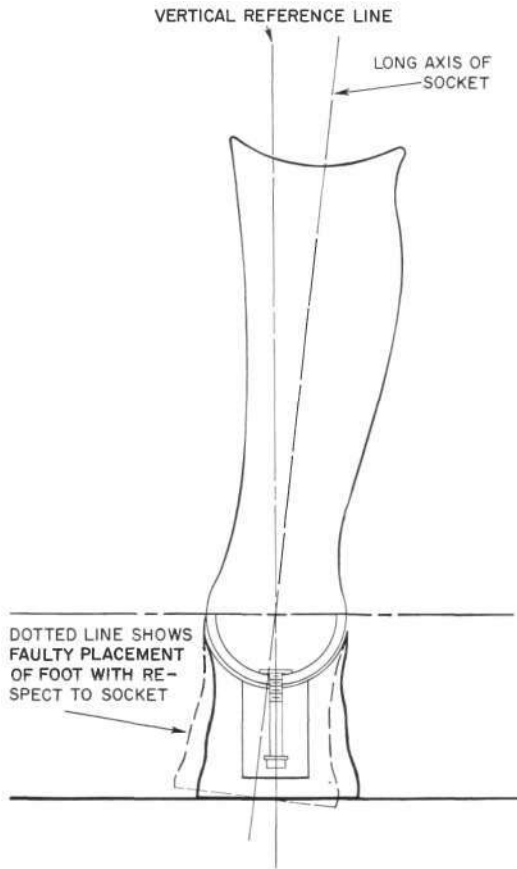


Fig. 40. Alignment of foot and socket in posterior view. The foot must be so located that the sole is parallel to the floor when the wearer stands in his own habitual position with hips level.

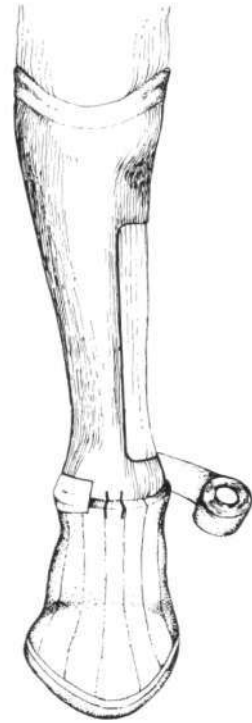


Fig. 41. Application of masking tape to secure foot to socket for drilling alignment hole through socket. Note reference marks used to ensure same alignment upon reassembly.

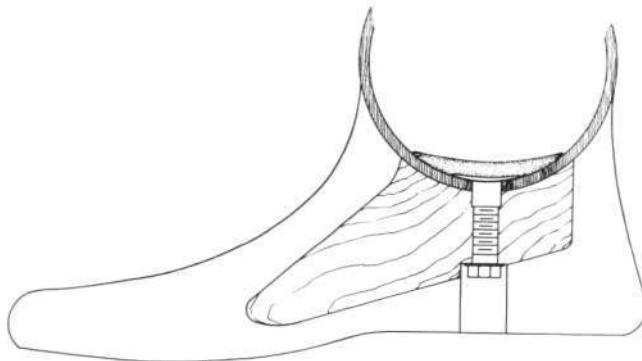


Fig. 42. Simplified cross section of foot and lower end of VAPC prosthesis showing attachment of foot to socket.

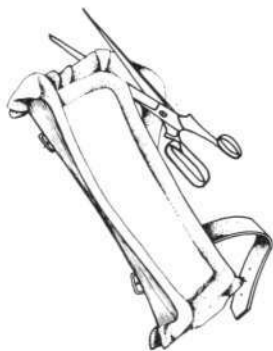

Fig. 43. Final step in fabrication of cover for opening in side of socket.

#### INSTALLATION OF THE SACH FOOT

To provide for wider degree of alignment adjustment than has been the case heretofore between the socket and the commercially available SACH foot, there has been developed a method of attachment employing a bolt with a spherical head (Fig. 45). Combined with an oversize hole in the socket, it permits some swivelling action between socket and foot. Adequate bearing area for the spherical bolt head is provided by laminating into the end of the socket a spherical washer (Fig. 45) having the same spherical radius as the head of the bolt.

Both washer and bolt head can be fabricated easily by use of plastic-laminating techniques.

A mold suitable for forming both pieces can be made by immersing in wet plaster of Paris a PVA-covered rubber ball, or other spherical object of suitable size, to a depth equal to about a third of its diameter (Fig. 46). The washer is formed by placing in the mold about eight layers of Fiberglas cloth saturated with epoxy resin, then placing the ball in the cavity and weighting it, and then curing the resin. Trimming the periphery of the washer and drilling a 1-in. hole in the center completes the job. The spherical bolt head is constructed by placing under the head of a standard 3/8-in. machine bolt 10 discs of Fiberglas cloth drilled with 3/8-in. holes, screwing the bolt into a hole drilled into the plaster mold, filling the cavity to the top of the bolt head with epoxy resin, and curing the plastic. When curing is complete, the top may be finished by sanding.

So that the spherical washer may be laminated into the socket, it is attached to the plaster model of the stump with beeswax (Fig. 47), care being taken at this point because the location of the washer with respect to the model determines the location of the foot with respect to the socket in a horizontal plane.

To enable the socket to be attached to the foot, a bandsaw is used to make in the keel of the foot a cutout conforming to the radius of the bulbous portion of the socket (Fig. 48). When the length of the stump dictates that the

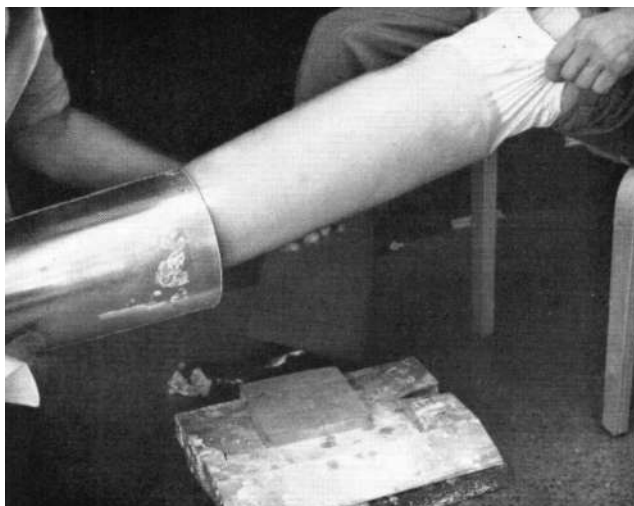


Fig. 44. Removal of stump, alginate mold, and canvas bag from canister.

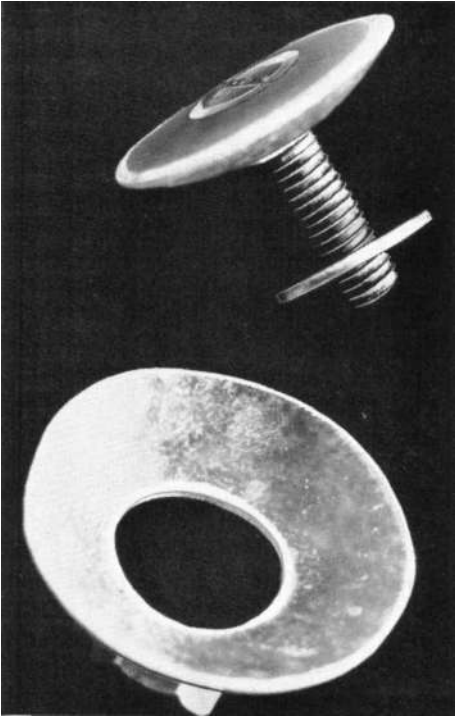


Fig. 45. Spherical-head bolt (top) and spherical washer used in attaching SACH foot to plastic socket to permit relatively wide range of adjustment. Spherical washer and spherical part of bolt head can be made using plastic-laminating techniques.

keel be so cut away as to weaken it significantly, the keel must be reinforced. In such a case, a wood screw is used to fasten the socket to the remaining portion of the keel (Fig. 49). The heel wedge and balata belting are peeled back, some nine layers of Fiberglas cloth, tailored to fit the keel and the end of the socket (which is covered with PVA film to prevent adherence), are laid up and saturated with epoxy resin, and the balata belting is screwed back in place (Fig. 50). After curing of the resin has been effected, a 3/8-in. hole is drilled through the keel reinforcement and the socket at the center of the spherical washer, the foot is removed, and that part of the hole which is in the socket is enlarged to 1 in. so as to match the hole in the spherical washer (Fig. 51).

Finally, a hole 1 1/4 in. in diameter is formed in the heel wedge and sole in such a way as to receive the wrench needed to tighten the at-




Fig. 46. Mold used in fabricating spherical washer and spherical bolt head. Convex portion consists of a rubber ball covered with PVA film. Concave portion is formed from wet plaster of Paris by pressing the ball in to a depth equal to approximately one third its diameter.

tachment nut (Fig. 51). The heel wedge having been modified to fit the contours of the reinforced keel and then cemented in place, the socket and foot can be assembled for walking trials. When all necessary adjustments have been made, the socket is bonded to the foot with epoxy resin and the space around the socket is filled with a mixture of resin and sawdust which, when cured, is ground and sanded to provide a suitable contour.

#### CONCLUSION

The several methods presented here for fabrication of a prosthesis for Syme's amputation have all been found to be useful. It seems reasonable to believe that some of the features of each method may be combined in order to suit the equipment of the individual prosthetist as

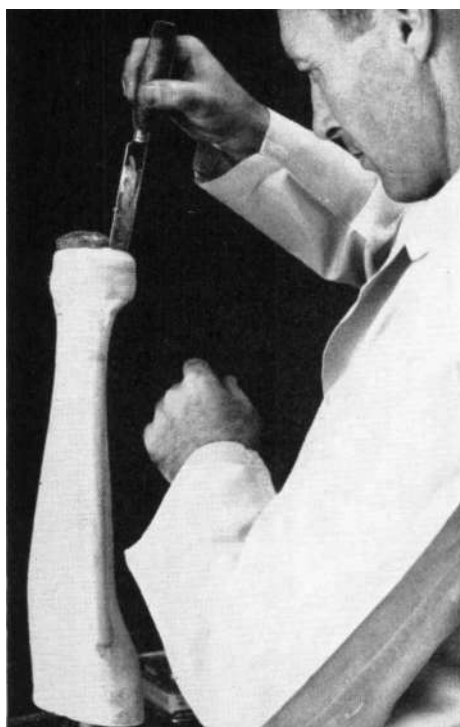

Fig. 47. Placing the spherical washer on the plaster model of the stump so that it may be laminated into the socket. Beeswax is used both to support it in the proper position and to fasten it to the model.

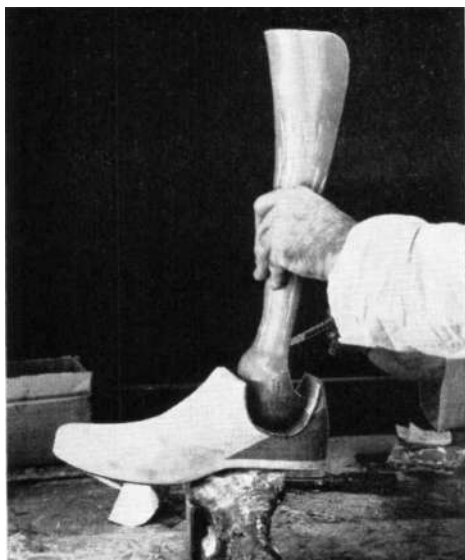


Fig. 48. View showing the type of cut made in the top portion of a SACH foot to accommodate a Syme socket.

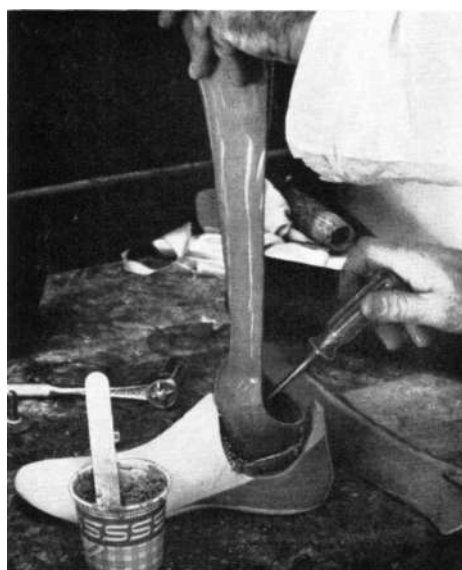


Fig. 49. Fastening the socket to the keel of the SACH foot with a wood screw.

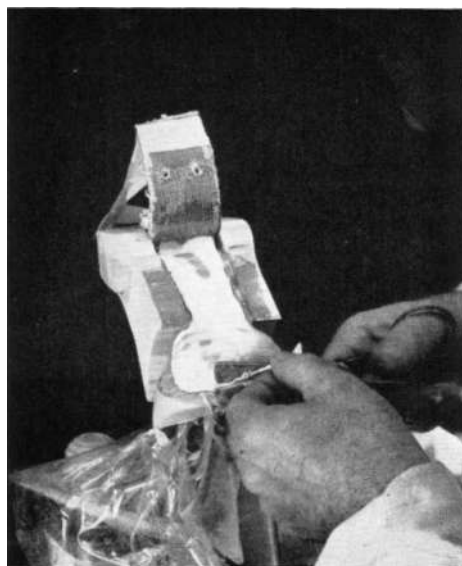

Fig. 50. Fiberglass cloth, used to reinforce keel of SACH foot, being tailored to fit bottom of keel and socket. Note PVA film placed over socket to prevent adherence to fiberglass during laminating process.

well as to meet most effectively the requirements of the individual patient. For example, the technique offered by VAPC for fabrication of a cover for the cutout might well be applied

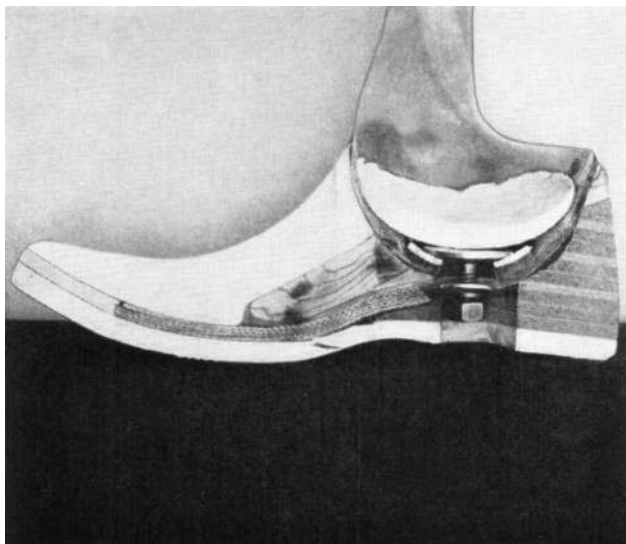


Fig. 51. Cross-section of completed prosthesis showing spherical head bolt, spherical washer, modified keel, and laminated Fiberglas reinforcement.

to fabrication of a prosthesis with a full-length posterior cutout as used by the Prosthetic Services Centre. The use of alginate as an impression material may be the method of choice for some prosthetists, while others may find the two-piece mold best for their use, especially if the local water supply contains certain minerals. The measurement-and-modification techniques described might be combined advantageously. Thus most of the individual methods are interchangeable between the basic prostheses described.

#### ACKNOWLEDGMENT

Any reliable article on the recommended methods of construction of a limb prosthesis must necessarily be based on the cumulative experience and the collective judgment of many workers in many places. Most of the material for this article was drawn from three pre-existing publications—*Construction of the Plastic Symes Appliance* (Technical Bulletin No. 32, Prosthetic Services Centre, Canadian Department of Veterans Affairs, Toronto, August 1959), *VAPC Technique for Fabricating a Plastic Syme Prosthesis with Medial Opening* (U. S. Veterans Administration, New York, September 1959), and *Recent Developments in the Fitting and Fabrication of the Syme Prosthesis* (*Orthopedic and Prosthetic Appliance Journal*,

March 1960). Much valuable advice and counsel was forthcoming from a number of highly accomplished persons, among them R. M. Turner, of the Canadian Department of Veterans Affairs, Ottawa, and C. S. Boccus, of the Prosthetic Services Centre, Toronto; Colin A. McLaurin and Fred Hampton, of the Prosthetics Research Centre of Northwestern University in Chicago; and Anthony Staros and Louis Iulicci, of the U. S. Veterans Administration Prosthetics Center, New York City. Of the 51 illustrations, the drawings not credited to original publications are the work of Annette Kissel, illustrator for the Veterans Administration Prosthetics Center in New York City, and of George Rybczynski, freelance artist of Washington, D. C. Miss Kissel executed Figures 26 through 43. Mr. Rybczynski prepared Figures 11, 12, 13, 14, 15, 16, 17, 19, 22, 23 and 24. The cooperative efforts of all these individuals are gratefully acknowledged and duly appreciated.

#### LITERATURE CITED

1. Bowler, Bartholomew, U. S. Patent 1,323,444, Dec. 2, 1919.
2. Columbus Artificial Limb Company, catalog, Columbus, Ohio, ca. 1925.
3. Department of Veterans Affairs, Prosthetic Services, Toronto, Canada, *Syme's amputation and prosthesis*, January 1, 1954.

4. Department of Veterans Affairs, Prosthetic Services Centre, Toronto, Canada, *Construction of the plastic Symes appliance*, Technical Bulletin No. 32, August 1959.
5. Foort, J., *The Canadian type Syme prosthesis* (Series 11, Issue 30), Lower-Extremity Amputee Research Project, Institute of Engineering Research, University of California, Berkeley, December 1956.
6. Gaines-Erb Company, catalog, Denver and Pueblo, Colo., ca. 1915.
7. Gardner, Henry F., *A report of the checkout of the UC-Berkeley Syme prosthesis and fabrication manual*. Veterans Administration Prosthetics Center, New York, January 31, 1958.
8. Gardner, Henry F., *First addendum to the January 31, 1958, report of the checkout of the UC-Berkeley Syme prosthesis and fabrication manual*, Veterans Administration Prosthetics Center, New York, May 1, 1958.
9. Hampton, Fred, *Recent developments in the fitting and fabrication of the Symes prosthesis*, Orthopedic and Prosthetic Appliance Journal, March 1960, p 45.
10. Iuliucci, Louis, *VAPC technique for fabricating a plastic Syme prosthesis with medial opening*, Veterans Administration Prosthetics Center, New York, September 1959.
11. Kay, H. W., and A. Staros, *Plastic laminate. Syme prosthesis*, Prosthetic Devices Study, New York University, and Veterans Administration Prosthetics Center, New York, January 1960.
12. Marks, A. A., Inc., *Manual of artificial limbs*, New York, 1889.
13. Marks, A. A., Inc., *Manual of artificial limbs*, New York, 1931.
14. New York University, Prosthetic Devices Studies, College of Engineering, *Progress report, test of the Canadian type plastic Syme prosthesis (modified)*, New York, December 1958.
15. University of California (Los Angeles), Department of Engineering, *Manual of upper extremity prosthetics*, 2nd ed., William R. Santschi, ed., 1958.
16. Winkley Artificial Limb Company, *Artificial legs with the patent adjustable double slip socket*, descriptive catalog, Minneapolis, Minn., ca. 1910.

# The Biomechanics of the Syme Prosthesis<sup>1</sup>

CHARLES W. RADCLIFFE, M.S., M.E.<sup>2</sup>

The purpose of any limb prosthesis is to replace, to the reasonable satisfaction of the wearer, as much as possible of the normal form and function lost through amputation. To provide a suitable prosthesis in any particular case, therefore, the several cooperating professional persons—physicians, prosthetists, therapists, others as appropriate—must have an intimate knowledge of just what losses have been incurred and just what new circumstances, if any, have accrued as a result of the losses. Among these are the losses of structural elements, of joint motion, and of muscle function; the decrease in proprioceptive sense as well as in sensory perception; the development of persistent or recurrent pain in one form or another; the impairment of circulation; and the losses of what in the normal would be the weight-bearing areas; not to mention numerous other matters purely medical and not necessarily associated with the amputation. Any one of these factors, or any combination of them, may influence the way in which an amputee will use a given type of limb prosthesis—that is, a device intended as a limb substitute.

In the case of the Syme amputee, where the patient has suffered loss of the foot and ankle while retaining essentially the full length of the shank and more or less of the typical weight-bearing characteristics of the normal heel, the obvious problem is to restore foot and ankle function (or to supply the equivalent of foot-ankle function), to extend the stump so as to accommodate the loss of the tarsus and of the calcaneus, to furnish adequate support for the

body during standing and during the stance phase of walking, to provide suitable suspension for the prosthesis during the swing phase, and to do all these things in such a way that the final result is acceptable to the wearer under both static and dynamic conditions. As with prostheses for other levels of amputation in the lower extremity, determination of the requirements of the Syme prosthesis takes its departure from a review of the normal pattern of locomotion and proceeds toward assessment of the means through which such a pattern may best be reproduced by application of inanimate devices. Discussion is here limited to the pertinent features of straight and level walking in the normal person and to the corresponding circumstances in a Syme amputee enjoying good general health, using a prosthesis, and having a stump itself free from any inherent medical complications such as excessive scar tissue, or neuromas, or skin disorders, or sensitive joints, or other conditions ordinarily beyond control of the limb designer.

## LOCOMOTION PATTERNS

In any analysis of bipedal locomotion such as that of man, it is common practice to divide the walking cycle into the two obvious phases through which the lower limbs pass alternately—the stance phase and the swing phase. Figures 1 and 2, based on averages from tests on four normal young males during straight and level walking (1,3), show five different kinds of data—angular motion at the knee and ankle joints, moments about the knee and ankle joints as a result of muscle activity, muscle activity as measured by electromyographic techniques, energy level at the knee and ankle joints at a given instant, and change in energy level. Correlation of the energy data (Fig. 2) with motions of the joints (Fig. 1) provides an insight into knee-ankle interaction

<sup>1</sup> A contribution from the Biomechanics Laboratory, University of California, San Francisco and Berkeley, aided by U. S. Veterans Administration Research Contract VAm-23110.

<sup>2</sup> Associate Professor of Mechanical Engineering, University of California, Berkeley.



in normal human locomotion and is useful in determining the compensation required to make up for the losses incurred by Syme's amputation.

The terms "work done on/" "work done by," "input," and "output" used in describing energy requirements can best be defined by citing examples. In the simplified sketch of musculoskeletal joint action (Fig. 3), the musculature exerts an internal moment  $M$  which resists the load  $W$ . If the load  $W$  is sufficient to overcome the moment  $M$  and thus to cause the joint to rotate in opposition to the muscle action, then work is done *on* the joint, *i.e.*, the joint absorbs energy. If the moment  $M$  is sufficient to cause the joint to rotate in the same direction as the muscle action and thus to move the load  $W$  in a direction opposite to its sense, then work is done *by* the joint, *i.e.*, the joint provides an energy output.

#### THE STANCE PHASE

Comparison of the stance phase of the normal with that of the Syme amputee wearing a prosthesis reveals an excellent example of compensation by one joint (the knee) for loss of a second joint (the ankle) in the same extremity.

#### Shock Absorption

During the subphase designated "shock absorption" (Figs. 1 and 2), the ankle in the normal subject undergoes plantar flexion while the knee flexes, both under load. Thus, an energy input results at both knee and ankle (work is done *on* both joints during the first part of the stance phase). As summarized in the bar graph of Figure 2, the work done on one joint is approximately equal to that done on the other. It could therefore be stated that in bipedal walking the knee and ankle contribute equally to the cushioning of the shock transmitted to the body at the beginning of

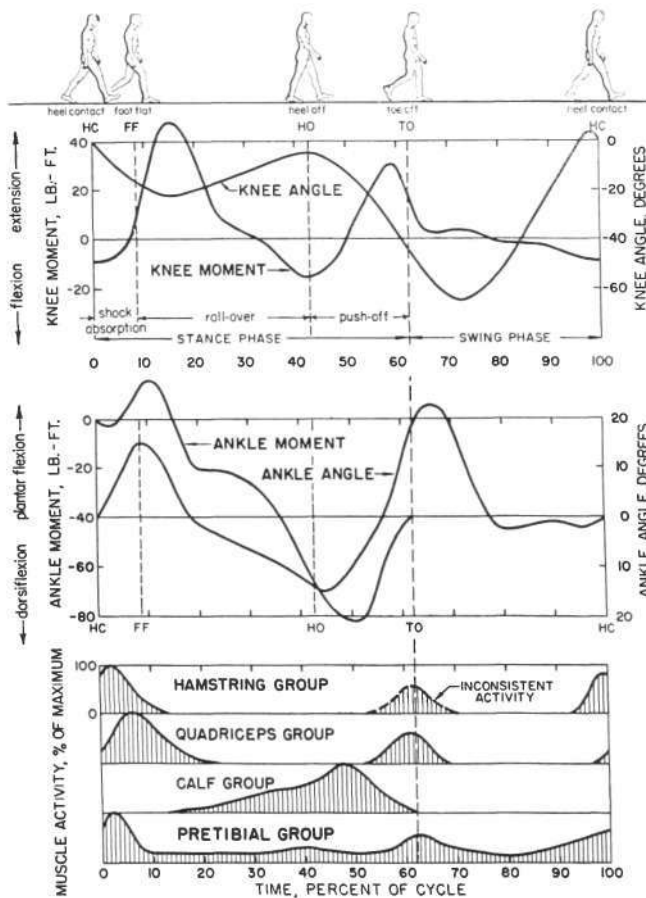


Fig. 1. Correlation between joint action and muscular activity in normal locomotion in man.

the stance phase when the leg first assumes its function of support.

In the Syme amputee, ankle function has been lost and some way of compensating for it must be found. Because of the inherent space limitations in conventional Syme prostheses, use of articulated ankle joints and elastic compression members has been for the most part unsuccessful. It is known that, in order to keep stresses in elastic bumpers within reasonable limits, the bumpers must contain a certain minimum volume of material. Otherwise the energy-absorption requirements per unit volume are excessive, and overheating and fatigue occur rapidly. The alternatives are to increase the volume of shock-absorbing material so as to reduce the unit stresses, or to

transfer shock absorption to some other area, or both.

The volume of shock-absorbing material can be increased by eliminating the articulated ankle joint and using in the heel the greatest possible volume of suitable sponge-rubber cushion—as in the SACH foot (2). In general, function may be improved over that supplied by an articulated joint, but owing to the space limitations the Syme amputee cannot be given the same degree of shock absorption as can be afforded the above-knee or below-knee amputee wearing a SACH foot.

To compensate for the lack of adequate function in the artificial foot, the knee joint on the side of the amputation must assume a greater proportion of shock absorption by increasing

the amount of knee flexion under load just after heel contact. If the knee does not assume this function, the amputee must tolerate a definite impact force from prosthesis to stump and must also accept the deviation from normal gait that might be expected to accompany such a circumstance.

#### Roll-Over

The roll-over portion of the stance phase in normals may in turn be subdivided into three parts corresponding to the direction of knee motion. During the first part, the knee continues to flex under load and thus prolongs the period of its function as a shock absorber for the initial support of the body weight. The ankle, acting as a controller, is required to supply energy during this time, as indicated by the rising curve of energy level and the positive bar for the ankle (Fig. 2). In the Syme amputee, the heel cushion of the modified SACH foot contributes some of its energy of compression and thereby simulates normal ankle action, but again the knee joint must compensate for the shortcomings of the prosthetic foot-ankle unit. Because of the lack of active plantar flexion in Syme amputees, maximum knee flexion during this subphase is in general less in persons wearing a Syme prosthesis than it is in normal persons.

While in normal locomotion the body continues to roll over the foot, which for the time being continues in full contact with the floor, the knee begins a second period of active extension, a circumstance that results in work being done on the body as a whole (*i.e.*, the knee exhibits energy output). Meanwhile, the ankle absorbs about half the energy output of the knee. In a typical Syme amputee wearing a prosthesis, the foot-ankle unit is neither absorbing nor supplying energy during this period, and the energy requirement of the knee during this interval is thus reduced as compared with that of the normal person.

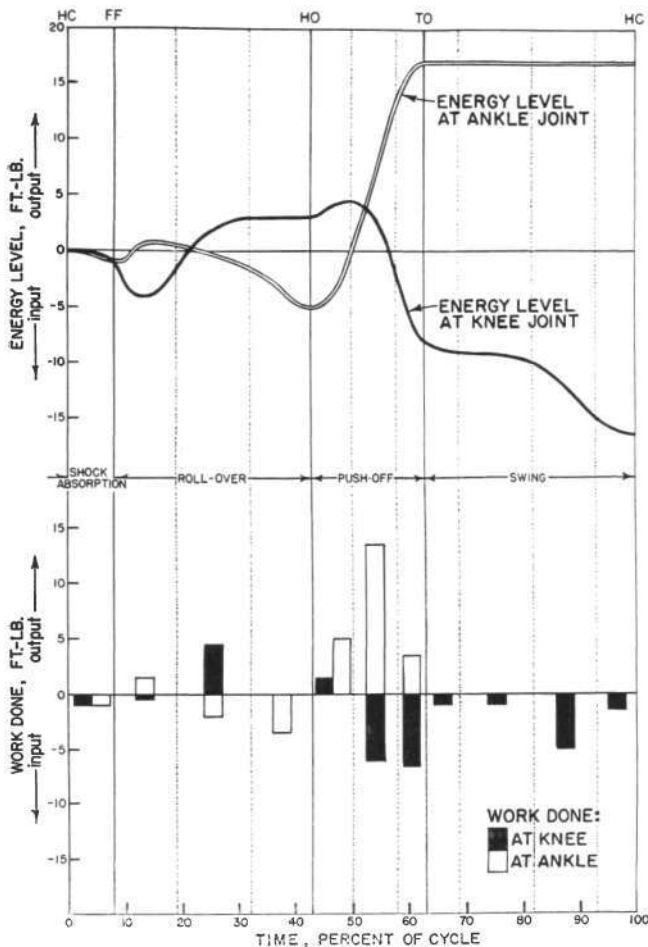


Fig. 2. Energy levels and work done at knee joint and ankle joint during normal, level walking.

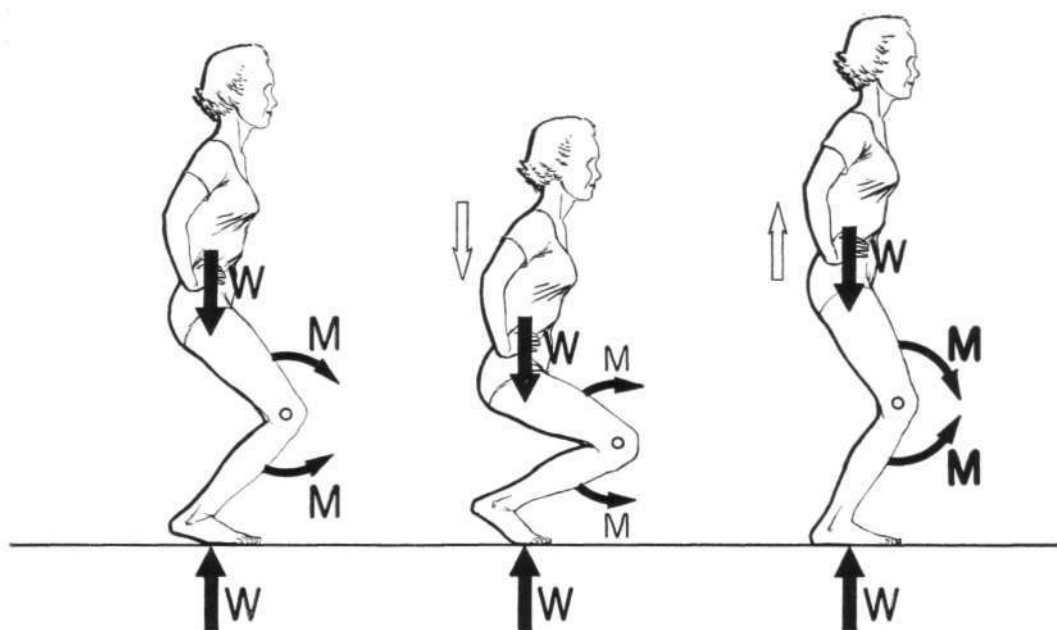


Fig. 3. Energy input and output at a typical joint. Left, equilibrium; center, energy in at knee joint, *i.e.*, work done *on* the joint; right, energy out at knee joint, *i.e.*, work done *by* the joint.

During the third part of normal roll-over, the knee is forced into full extension and maintained there by the external forces acting upward on the ball of the foot. The ankle continues to absorb energy as the tibia rotates forward over the stationary foot. To compensate for the inability of the prosthetic ankle to absorb energy during the last part of roll-over, the prosthetic foot must be designed so that the forward point of support corresponds to the ball of the foot, an arrangement which maintains the knee along a path corresponding to that of the normal. In other words, the knee should move forward smoothly, and no sensation of vaulting over the fore part of the foot should be experienced. In the amputee wearing a Syme prosthesis with a properly aligned SACH foot, knee action at the end of roll-over should be almost the same as it is in a normal person.

#### *Push-Off*

The push-off portion of the stance phase begins when the heel is lifted from the floor. During the first part of this subphase in normal persons, both knee and ankle contribute energy—the knee by virtue of energy that has been stored by passive stretching of the ham-

string ligaments and the ankle by virtue of active plantar flexion which continues throughout the push-off phase. In the Syme amputee, the ankle substitute cannot contribute energy by active plantar flexion, and accordingly other means must be found to maintain a smooth path of the center of gravity of the body. In the SACH foot, a comparatively simple keel contour, with a cylindrical or spherical surface on a 2-in. radius at the end of the keel, has been found practical for most adults. Under these circumstances, the hip and knee joints serve as the active elements in the kinematic chain which controls the pathway of the center of gravity.

In the second part of push-off, the normal knee absorbs about half as much energy as is supplied by the normal ankle joint, energy absorption by the knee being associated with the maintenance of a smooth path for the center of gravity of the body as a whole. At toe-off, for example, the knee in normal persons has flexed 40 deg. of the total of 65 deg. achieved at the point of maximum knee flexion. Energy absorption by the normal knee continues at about the same rate after active plantar flexion of the ankle has started to slow down. Since the foot-ankle unit in the Syme prosthesis must

maintain the pathway of the knee by proper keel contour rather than by active plantar flexion of the ankle, the amount of energy absorption required of the knee is less in the Syme than it is in the normal. The need to initiate knee flexion before the end of the stance phase remains, however, and the socket must therefore be designed to permit maximum control of knee motion by the stump in preparation for the swing phase.

#### THE SWING PHASE

Since in the patient with Syme's amputation the knee and hip joints are usually undisturbed, it might be assumed that the swing phase of the Syme amputee would always appear relatively normal. But the role of the ankle joint at the end of the stance phase must be considered. In normal locomotion, the knee starts to flex before the foot leaves the ground, and the controlled knee-ankle interaction provides a major source of energy for the forward propulsion of the knee. If this motion is smooth and precisely controlled, the thigh-shank-foot combination enters the swing phase normally. Anything that tends to disturb this smooth transition from stance to swing has a noticeable effect throughout the swing phase.

For the patient who has undergone Syme's amputation, poor function in the prosthetic foot and pain in the weight-bearing areas of the stump are the two most common sources of unstable or erratic action during transition from stance to swing phase. When, however, the prosthetic foot has been properly designed, aligned, and adjusted to allow the knee and hip to provide normal-appearing control of knee motion at the end of the stance phase, the amputee should, in general, have the ability to exercise complete control of his prosthesis during swing phase.

#### SOCKET DESIGN

##### ANALYSIS OF STUMP-SOCKET FORCES DURING THE STANCE PHASE

Analysis of the distribution of contact pressures between stump and socket at various times during the stance phase is useful in the design of a socket that will be comfortable for the amputee. Since pressure distribution varies

during each of the three subphases—shock absorption, roll-over, and push-off—each must be analyzed separately.

##### *Shock Absorption*

If it be assumed that body weight is supported at the distal end of the stump, it can be seen clearly from Figure 4A that during the shock-absorption subphase the major functional forces between stump and socket occur in the anterodistal and posteroproximal areas. During roll-over, the need for posteroproximal pressure decreases, and the contact pressure at the end of the stump shifts toward the center of that area. If the force system is to be in equilibrium, the paths of the forces  $P$ ,  $D$ , and  $F$  must intersect at  $M$  and their vectors must form a closed polygon. Use of this principle makes it possible to estimate the relative magnitudes of the three forces.

##### *Push-Off*

Figure 4B shows the force system that develops as the Syme amputee rolls over the ball of the foot in the push-off subphase. At the instant shown, the hip joint is being used to help flex the knee against the force acting upward on the ball of the foot. Again, the principle of force equilibrium can be applied to estimate the magnitude of the forces. A posterodistal and an anteroproximal contact force between stump and socket are seen to be necessary to resist the floor reaction against the ball of the foot. It is essential that the anteroproximal force against the tibia be kept at as high a level as possible. Shortening of the distance  $a$  results in increased inclination of the line of the posterodistal contact force and in a transfer of the force away from areas surgically prepared for end-bearing.

Since some change in the inclination of the distal stump-socket force is unavoidable, it must be anticipated during the fitting procedure. If the line of the floor reaction is kept in a particular position relative to the knee, the amputee can use some voluntary control in shifting the distal contact point. Moreover, the anteroproximal force at push-off will be several times the posteroproximal force at heel contact. For this reason, the prosthesis must be

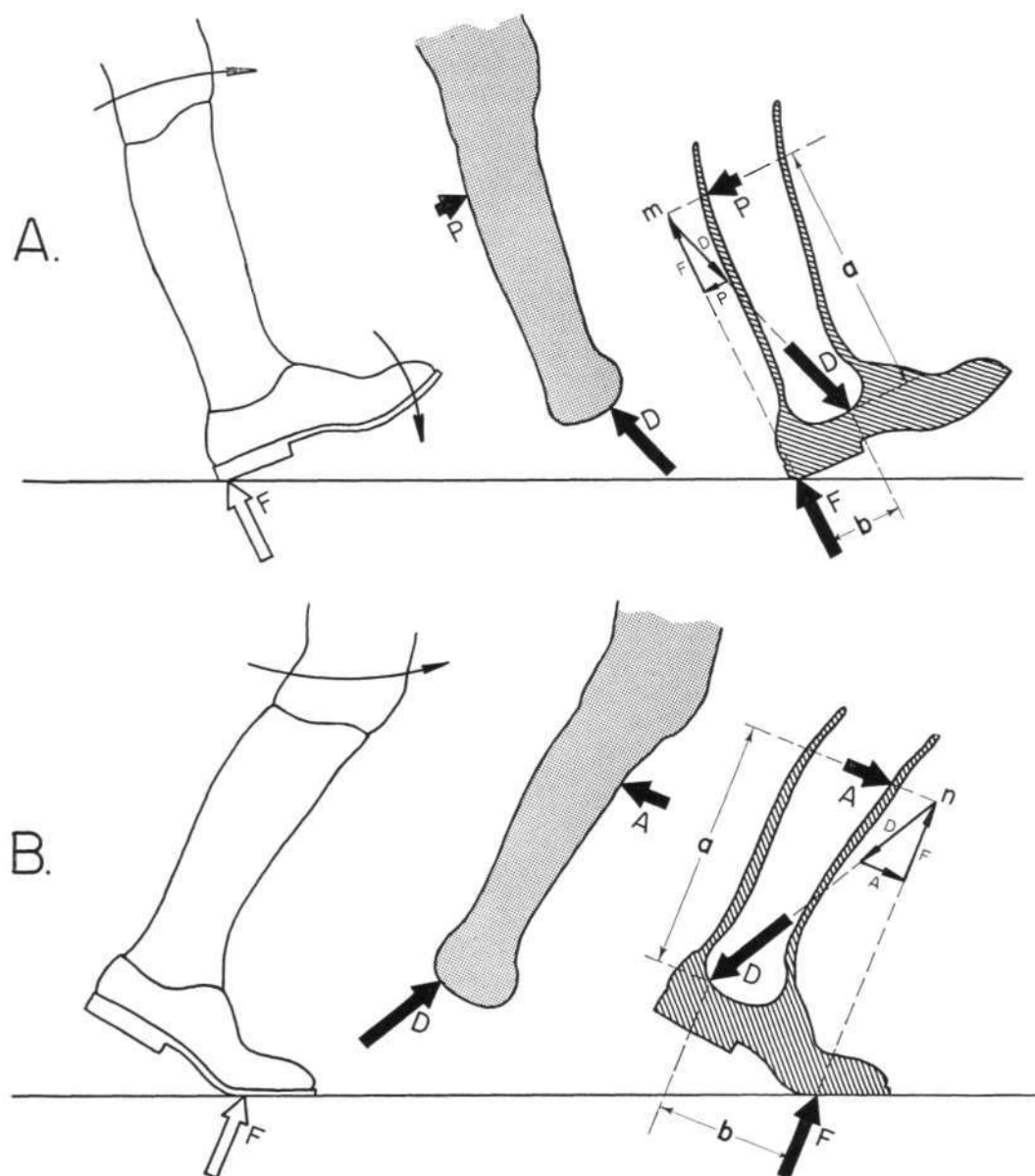


Fig. 4. Stump-socket forces during the stance phase. A, Shock absorption; B, push-off.

strong enough to resist the large bending moment in the ankle region during push-off. Suppose that in a 180-lb. man there is an increase of 30 percent (as compared with body weight) in the dynamic force against the ball of the foot during push-off and that dimension  $b$  is 4 in. Then the structure must resist a bending moment of  $1.30 \times 180 \times 4 = 936$  lb.-in.

#### SOCKET MATERIALS

Because of the bulbous form of the typical Syme stump, any prosthesis devised for it will be bulky in appearance. To provide the least bulky socket requires that the thickness of the wall be kept to a minimum commensurate with structural demands. Plastic laminates

with high strength-weight ratios that can be molded easily over a plaster model seem ideally suited for construction of sockets for the Syme prosthesis.

Since a snug fit throughout the length of the stump is necessary if proper function is to be expected, a cutout must be provided in the narrow section of the socket to permit entry of the bulbous end of the stump. The question arises as to where to locate a cutout, which in any case obviously should not interfere with the functional characteristics of the prosthesis nor affect its structural properties unduly. Several possibilities have been suggested. Among others are the posterior cutout used at Sunnybrook Hospital in Toronto and the medial cutout proposed at the Veterans Administration Prosthetics Center (page 57). Some predictions as to the relative structural strengths to be had from the several approaches may be arrived at through the techniques of engineering stress analysis.

From a review of data on normal human locomotion it has been determined that in level walking maximum forces are brought to bear on the shank at the time of push-off. At this point in the walking cycle the center of pressure is eccentric with respect to the shank.

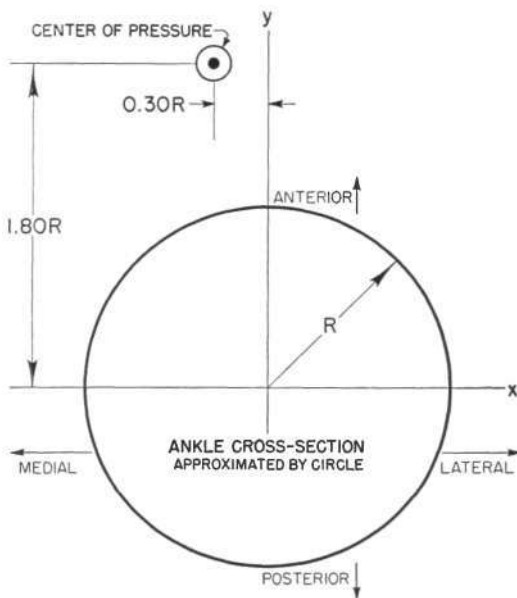
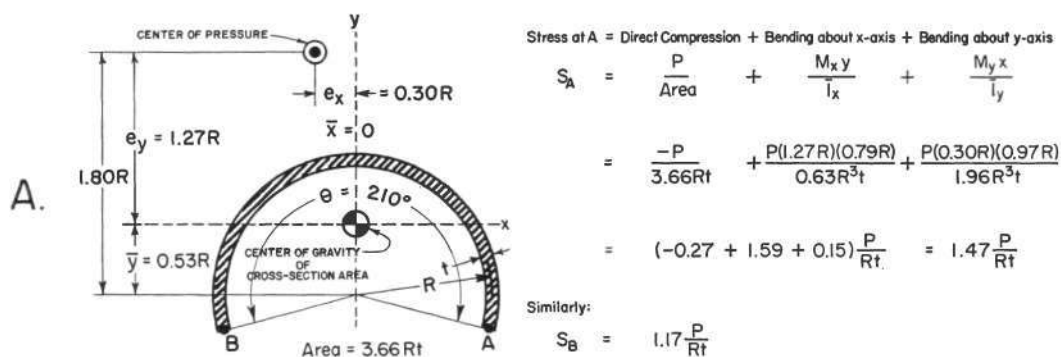


Fig. 5. Center of pressure as related to minimum cross-section of the ankle.

Obviously the highest unit stress will occur at the level of the shank where the cross-sectional area is smallest. The relationship at push-off between the center of pressure acting upward on the ball of the foot and the minimum cross-section at the ankle is indicated in Figure 5, where the ankle is approximated by a circle of radius  $R$  and where all dimensions are expressed in terms of  $R$ . If the same loading conditions be assumed to be present when a Syme prosthesis is worn, the result is a combination of three different types of stresses in the structure of the prosthesis: compression stresses resulting from the direct thrust load carried by the structure, bending stresses resulting from a tendency for the structure to bow laterally, and bending stresses resulting from a tendency for the structure to bow posteriorly. If the loading conditions and the dimensions of the cross-section are known, the magnitudes of the stresses can be calculated, as indicated in Figure 6A. In such calculations, a plus sign indicates that a fiber of the material would be in tension at the point being investigated. A minus sign shows that the fiber would be compressed.

Summarized in Figure 6B are the results of a number of calculations based on stresses in a hypothetical Syme prosthesis with a circular cross-section of radius  $R$ , with a material thickness  $t$ , carrying a load  $P$ , and with a constant eccentricity. An interesting feature is that, even when the values for direct compression as a result of proximal weight-bearing are included, in general the posterior cutout results in tensile stresses at critical points whereas the medial cutout results in compressive stresses at critical points. The posterior cutout with  $\theta = 210$  deg. and the medial cutout with  $\theta = 270$  deg. are perhaps most nearly representative of actual conditions.

These results would indicate that, when Syme prostheses are constructed with a posterior opening in the socket (tensile stresses at critical points), a material with the highest possible tensile strength should be used. A laminate of Fiberglas cloth with epoxy resin, such as is used by Canadian makers of Syme prostheses, would be an efficient material, particularly when reinforced with roving along the edge of the cutout. A laminate of Fiberglas



B.

POSTERIOR CUTOUT	MEDIAL CUTOUT	LATERAL CUTOUT
$\theta = 180^\circ$  $S_A = 2.34 P/Rt$ (TENSION) $S_B = 1.96 P/Rt$ (TENSION)	$\theta = 180^\circ$  $S_A = -3.47 P/Rt$ (COMPRESSION) $S_B = -1.17 P/Rt$ (COMPRESSION)	$\theta = 180^\circ$  $S_A = -2.19 P/Rt$ (COMPRESSION) $S_B = -0.23 P/Rt$ (COMPRESSION)
$\theta = 210^\circ$  $S_A = 1.47 P/Rt$ (TENSION) $S_B = 1.17 P/Rt$ (TENSION)	$\theta = 210^\circ$  $S_A = -2.20 P/Rt$ (COMPRESSION) $S_B = -0.42 P/Rt$ (COMPRESSION)	$\theta = 210^\circ$  $S_A = -1.45 P/Rt$ (COMPRESSION) $S_B = 0.33 P/Rt$ (TENSION)
$\theta = 270^\circ$  $S_A = 0.92 P/Rt$ (TENSION) $S_B = 0.78 P/Rt$ (TENSION)	$\theta = 270^\circ$  $S_A = -1.08 P/Rt$ (COMPRESSION) $S_B = -0.19 P/Rt$ (COMPRESSION)	$\theta = 270^\circ$  $S_A = -0.66 P/Rt$ (COMPRESSION) $S_B = 0.24 P/Rt$ (TENSION)

Fig. 6. Summary of stress calculations for various socket cutouts. A, Sample stress analysis for Canadian-type posterior cutout,  $\theta = 210$  deg. B, Comparison of stresses at edge of cutout for varying degrees of cutout at three locations about the circumference;  $P$ ,  $R$ , and  $t$  constant.

cloth and polyester resin would also be satisfactory if fabricated carefully. Either material would provide great strength and minimum thickness with more than sufficient tensile strength. Nylon stockinet with polyester-resin laminates has lower tensile strength, and the lamination would have to be thicker.

When the stresses at critical points are compressive, such as in the case of medial opening,

a material with the greatest compressive strength should be used. In situations involving compressive loading of thin-walled columns (as in a proximally loaded Syme prosthesis), failure may be due either to failure of the laminate at the area of direct compression or to buckling of the material in a localized area, such as near a free edge carrying a compression stress. The sides of the cutout in the Syme

socket with medial opening would constitute free edges of this type. To increase resistance to local buckling, the wall thickness of the laminate should be increased. Doing so will also increase resistance to direct compression because the area of the cross-section will be increased proportionally.

Since in practice it is more convenient to use nylon stockinet as a laminating material, and since the thickness must be increased to overcome the effects of buckling, nylon stockinet is probably the material of choice for the medial opening. Although theoretically Fiberglass laminates would have sufficient direct compressive strength even with thin walls, resistance to local buckling would be lower than in the case of a thicker nylon laminate. Moreover the compressive strength of a structure made of thin-walled Fiberglass laminate depends mainly on the quality of the laminating technique.

It should be pointed out that in Syme prostheses direct end-bearing has been used more often in Canada than in the United States. Since end-bearing tends to increase the critical tensile stress in the posterior-opening socket by eliminating the direct compressive stresses due to proximal loading, the need for an extremely strong laminate such as one of Fiberglass cloth, Fiberglass roving, and epoxy resin is obvious. When direct end-bearing is used with the medial opening, the critical compression stress is reduced, sometimes to the extent that it is converted into tension of some low value. Nylon stockinet and polyester resin should be an adequate material for the medial-opening socket, although such a socket is more bulky in appearance.

#### CONCLUSIONS

To ensure a satisfactory period of use, the ankle of any prosthesis must be so designed that the elastic members resisting dorsi- and plantar flexion have adequate volume to provide sufficient fatigue strength. Furthermore, the foot must be designed to permit the knee and hip joints to move smoothly through space during the roll-over and push-off phases. The SACH-type foot, with its sponge-rubber heel wedge and a keel of proper proportions, has

proved useful in meeting most of the requirements for use in a Syme prosthesis, but, like all other known foot-ankle units, its inability to provide energy at push-off requires that the remaining musculoskeletal system compensate for functions lost in amputation.

To satisfy the requirements of a comfortable transmission of functional stump-socket contact forces, the socket must provide the following features:

1. Comfortable support of the body weight on the distal end of the stump or on the proximal part of the socket brim or both.

2. Firm support against the anteroproximal surface of the leg at the time of push-off. Careful fitting against the wedgelike medial and lateral surfaces of the tibia can satisfy this requirement.

3. Similar support against the posterior surface of the leg at the time of heel contact. This requirement can be satisfied by pressure in the region of the gastrocnemius. Here the main interest is to prevent lost motion between socket and stump as the reaction point shifts from the posterior to the anterior surface of the leg.

4. Provision for shifting of the center of pressure against the distal end of the stump, as indicated by the force analysis. If a cuplike receptacle is provided for the stump end, it must extend around and up the sides of the bulbous stump far enough to prevent relative motion between stump and socket in the anteroposterior direction. It is particularly important to provide for the horizontal component of the force against the posterodistal region of the stump during push-off.

5. Adequate stabilization against the torques about the long axis of the leg. A three-point stabilization against the medial and lateral flares at the anteroproximal margin of the tibia and a flattening of the posteroproximal contour can be highly effective in providing the necessary torque resistance. If the needed stabilization is not provided, torques acting on the distal end of the stump will result in skin abrasion and other associated difficulties in more proximal areas.

Either the posterior cutout of the socket favored by the Canadian workers or the medial cutout proposed by the VA Prosthetics Center will result in a socket of adequate strength if a laminate of the correct type is used. When a posterior cutout is incorporated, the laminate must be capable of resisting high tension stresses. Fiberglass-epoxy laminates are therefore indicated. When a medial cutout is used, particularly in those cases where a large proportion of proximal weight-bearing is provided, the critical stresses are compressive. When compression stresses are involved, the thicker



nylon-polyester laminate may have advantages.

#### LITERATURE CITED

1. Bresler, B., and F. R. Berry, *Energy and power in the leg during normal level walking*, Prosthetic Devices Research Project, University of California (Berkeley), [Report to the] Advisory Committee on Artificial Limbs, National Research Council, Series 11, Issue 15, May 1951.
2. New York University, Prosthetic Devices Study, Research Division, College of Engineering, *Evaluation of the solid ankle cushion heel foot (SACH foot)*, May 1957.
3. University of California (Berkeley), Prosthetic Devices Research Project, Subcontractor's Final Report to the Committee on Artificial Limbs, National Research Council, *Fundamental studies of human locomotion and other information relating to design of artificial limbs*, 1947. Two volumes.

# The Plastic Syme Prosthesis in Canada

C S. BOCCIUS<sup>1</sup>

Opinion concerning the long-term efficacy of a Syme amputation stump is by no means unanimous. The obvious advantages of a stump that will tolerate full end-bearing and that may, if necessary, be walked upon without a prosthesis are considered by English surgeons to be offset by the likelihood of early breakdown of the stump and the later necessity for reamputation at a higher level. But the experience and consequent feeling in England is not shared by surgeons connected with Canada's Department of Veterans Affairs. The simple reason is that excellent and enduring results have been obtained in a goodly number of Syme amputations observed in Canada during and since World War I.

Were these results influenced by superior prostheses or better prosthetic management on the part of DVA? It would be nice to be able to answer in the affirmative, but it is more likely that these Canadian stumps endured in spite of prostheses none too adequate, for the techniques and designs adopted by DVA's Prosthetic Services have differed little from those used elsewhere. The experience of DVA surgeons (page 44) reveals that, in performing the amputation, they adhered as closely as possible to the account of the surgical procedure originally published by James Syme in 1843, while surgeons in other parts have modified Syme's technique with the object of producing stumps easier to fit with a more slightly prosthesis. There seems to be little doubt but that the superior results obtained in Canada have been due chiefly to adherence to classical procedure. But since it is known that in his accounts of his work Syme himself was seldom if ever meticulous as to detail, some credit is owing particularly to Dr. Gordon M. Dale, the man largely respon-

sible for DVA policy in the matter, for having" accurately interpreted and perhaps incidentally improved upon Syme's intentions. Possibly the term "Canadian Syme" should apply as much to DVA's surgical procedure as to its new prosthesis for the resulting stump.

## DEVELOPMENT OF THE CANADIAN-TYPE SYME PROSTHESIS

Syme stumps created by classical procedure are longer and more bulbous than are those obtained through modified techniques. In the corresponding prosthesis, therefore, the size of the opening needed for entry of the stump and the limited amount of space available for inclusion of an ankle joint and foot together require strong construction, and the result is often ugly. Despite these difficulties, DVA prosthetists managed to construct and fit Syme prostheses that were as good as, if not better than, those to be found elsewhere, although it must be admitted that the devices were often very heavy and in some cases not particularly durable. During the period 1926-1950, a few all-metal Syme prostheses were tried in Canada. The first ones, made from aluminum alloy, were exceptionally light, but few of them withstood the rigorous usage of Canadian amputees. An improved design, made from Monel metal and therefore as heavy as, if not heavier than, the standard type, proved exceptionally durable, but its construction was so difficult and time-consuming that it could not be adopted for general use. Of a few fitted to those who too frequently broke standard prostheses, however, some lasted through 15 to 20 years of continuous service, so that it became obvious that it must be possible in some way to produce a stronger, lighter, and neater appliance.

In 1944 a program of research toward the improvement of prostheses generally was undertaken by the National Research Council of

<sup>1</sup> Manager, Prosthetic Services, Department of Veterans Affairs, Toronto, Ontario, Canada.

Table 1  
EXPERIENCE WITH THE CANADIAN-TYPE SYME PROSTHESIS

Plastic Syme Prostheses Made Since 1954	Prosthetic Centre of Origin												Totals
	To.	Lo.	Mo.	Ot.	St.	Hx.	Wi.	Re.	Ca.	Ed.	Va.	VaS.	
Cases attempted	122	10	7	—	9	—	6	4	3	4	8	3	176
Cases satisfactory	113	10	7	—	9	—	4	4	3	4	4	3	161
Bilateral Syme included	5	—	—	—	—	—	1	—	—	—	—	—	6
Duplicate provided	16	1	4	—	—	—	1	1	3	3	—	—	29
Appliance satisfactory	134	11	11	—	9	—	6	5	6	7	4	3	196
Fitted but not accepted	3	—	—	—	—	—	2	—	—	—	3	—	8
End-bearing not tolerated	6	—	—	—	—	—	—	—	—	—	1	—	7
Replaced owing to poor fit	5	—	—	—	—	—	—	—	—	1	—	—	6
Replaced owing to breakage	3	1	—	—	1	—	—	1	1	1	—	1	9
All appliances made	151	12	11	—	10	—	8	6	7	9	8	4	226

$$\frac{\text{Cases satisfactory}}{\text{Cases attempted}} = \frac{161}{176} = 91.5\%$$

$$\frac{\text{Satisfactory prostheses}}{\text{All prostheses made}} = \frac{196}{226} = 86.7\%$$

Canada (Ottawa) at the request of its Committee for Medical Research. Col. R. I. Harris, then Medical Advisor to the Canadian Armed Forces and orthopedic consultant to DVA, and Major C. A. Bell, then Director of Prosthetic Services, were chiefly responsible for initiating this activity and for providing the necessary impetus as well as the required liaison between the Council and Prosthetic Services. Although between the years 1948 and 1952 there was a pause and a transfer of activities to a new Prosthetic Centre at Sunnybrook Hospital, Toronto, one of the direct results of the investigation was the development of the appliance that has now come to be known as the "Canadian-Type Syme Prosthesis," or more simply in Canada as the "Plastic Syme."<sup>7</sup> It was May 1954 before development had progressed to the stage where it was felt the device had sufficient merit to warrant its adoption throughout Prosthetic Services. DVA centres outside of Toronto were at the time unfamiliar with plastic techni-




Fig. 1. Plastic Syme prosthesis with tibial bearing.

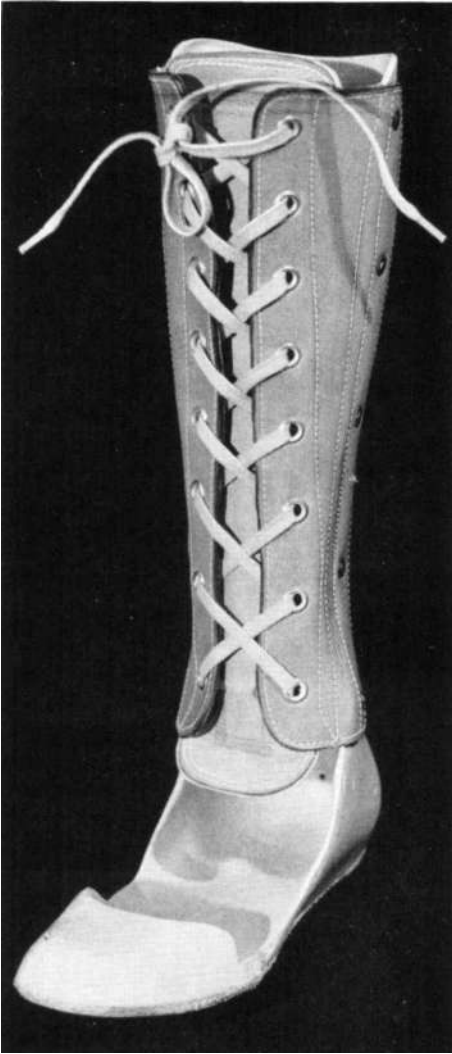


Fig. 2. Adaptation of the plastic Syme prosthesis for use with the Chopart stump.

ques, and it was therefore necessary to bring fitters to Toronto from all parts of the Dominion for training.<sup>2</sup>

#### CLINICAL RESULTS

Since that time, plastic Syme prostheses have been made throughout Canada for 176 cases, and of these one hundred and sixty-one (91.5%) are fitted satisfactorily (Table 1). Five of the remain-

<sup>2</sup> Which is to say that production outside of Toronto was not at the time in the hands of experts.

ing 15 complained that they did not like the SACH foot, and three found the plastic socket too cold in winter. In the remaining seven cases, which include one bilateral for whom the stumps are troublesome after 23 years of service and six primary cases whose stumps would not tolerate end-bearing and were therefore referred for further surgical attention, fitting was not brought to a satisfactory conclusion. Of the 161 satisfactory cases, six are bilaterals requiring two prostheses each, and 29 are individuals who, since they reside at considerable distances from fitting centres, were supplied with duplicate prostheses. In all, then, 196 satisfactory prostheses are in use by the 161 cases. Besides the 15 cases not satisfactorily equipped, six required a second prosthesis because the first was not properly fitted, and nine required replacements owing to structural failures that occurred in early models. Thus, for 176 cases, 226 appliances were constructed, and 196 of them are in satisfactory service. In this light, it may be said that the useful product was 86.7 percent of the total input.

#### SPECIAL ADAPTATIONS

Stumps which do not tolerate full end-bearing are referred routinely for re-examination by the surgeons, but occasionally no indication for further surgery is revealed or else surgery is contraindicated by physical condition. In such cases, an attempt is made to substitute tibial-bearing for end-bearing by fitting the upper part of the socket in the same manner as for a below-knee stump. Additional care is taken to size and modify the top of the cast before making the socket over it. Instead of being split medially and laterally as usual, the top of the socket is left whole, but the back is cut away just high enough to produce an aperture through which the stump can be squeezed and just low enough to allow its re-entry at the bottom (Fig. 1). A soft leather gaiter, slightly shorter than the cutout, is then wrapped completely around and laced in front. Although at first a snug fit must be achieved at the top in order to remove weight from the stump end to whatever extent is necessary, after the appliance has been used for a few weeks most of the weight is commonly taken on the end and tolerated without complaint. In only comparatively few cases is it necessary to maintain the snug fit at the top permanently.

Although Figure 2 illustrates an appliance for Chopart's amputation and therefore does not properly belong here, it shows an interesting extension of the technique used in construction of the plastic Syme prosthesis. The partial-foot amputee for whom this particular device was made could not be fitted comfortably with a conventional Chopart appliance because the inferior and anterior aspects of his stump at the site of amputation were unduly sensitive to pressure. The open-front socket of the Syme adaptation consists at the back of a rigid structural member continuing around the heel into a sturdy sole plate, which in turn extends past the stump, across the metatarsal heads, to the usual line of the toe joints, where a flexible toe piece is attached. Between toe piece and stump is left enough space so that the former, when dorsiflexed, does not impinge on the anterior aspect of the stump. Upward pressure across the metatarsal line during walking tends to force the socket away from the calf, but since the socket is secured firmly to the shank it does not move and therefore does not allow the sole plate to press upward against the inferior aspect at the stump. In the taking of the cast for such an appliance, the foot stump should be set in sufficient

plantar flexion to accommodate the heel of the shoe.

#### CONCLUSION

The figures given in Table 1 are the result of slightly over four years of routine use of the plastic Syme prosthesis. In Canada, once an appliance is in routine use no clinical procedure is followed, and it is then impossible to give a detailed account of each fitting. But because of the degree of similarity that exists among all Syme stumps no particular object would be served by doing so. A Syme stump that will not tolerate full end-bearing is considered subnormal and is treated according to the system already outlined. Additional measures, such as the provision of side joints and ischial-bearing corset may be taken to avoid further surgery, but when they prove to be necessary the case is considered a failure as a Syme. While the plastic Syme prosthesis offers adaptability to all fitting requirements, its chief advantages lie in its improved appearance with reduced weight, its improved durability by virtue of a stronger structure, its freedom from mechanical components subject to malfunction, and its reduced cost owing to simplicity in manufacture.

# Some American Experience with Syme Prostheses

HERMAN GLADSTONE, M.D.<sup>1</sup> AND  
LOUIS IULIUCCI, CP.<sup>2</sup>

At its research and service facilities in New York City, the U. S. Veterans Administration has during more than a decade accumulated considerable experience with Syme prostheses in a variety of conventional and experimental designs. Some of the patients involved were Army casualties of World War II fitted originally (for the most part at Thomas England General Hospital, Atlantic City) with molded leather socket, anterior lacing over soft leather tongue, and steel reinforcing straps medially and laterally (page 55). Others, similarly fitted with anterior tongue and lacing but with carved wood socket and sometimes with metal reinforcements, came from commercial limb-shops (Fig. 1). The Orthopedic Shop of the VA's New York Regional Office (now the Limb and Brace Section of the Veterans Administration Prosthetics Center) accommodated an occasional beneficiary with wood socket and anterior opening, and it also constructed and applied a few prostheses with wood socket but with medial opening.

At the end of the Korean conflict, six Syme amputees, young Puerto Rican males then patients at the Fort Hamilton VA Hospital in Brooklyn, were seen by New York units of the VA's Prosthetic and Sensory Aids Service. Small, agile, and at the time having only recently undergone amputation, they had rejected the conventional willow or leather-and-steel prostheses as too heavy and cumbersome. Instead they wore high combat boots stuffed

with newspaper or pieces of cloth to substitute for the amputated parts. They walked with full end-bearing and a scarcely perceptible limp and were able to run, turn, and stop easily. Some were fitted with a plastic Syme prosthesis similar to the Canadian type with posterior opening but with a rubber-block ankle joint and a more or less conventional foot (1).

Although because these patients soon returned to Puerto Rico no follow-up study was undertaken, presumably several factors—increasing age, gain in weight, loss of agility, unconventional appearance of the modified combat boot, not to mention difficulty of obtaining service for an experimental prosthesis—would have resulted in eventual replacement of either the boot or the plastic prosthesis by a more conventional prosthesis. The boot was, of course, a temporary expedient intended only to make ambulation possible. Prolonged use would probably have been unsatisfactory because fundamental fitting principles in the design of weight-bearing areas and in fixation of the stump were ignored. Nevertheless, the great difference between the boot and the conventional prosthesis served to emphasize the importance of simplicity and lightness in the development of a Syme prosthesis.

In May 1957, VAPC was requested to determine the adequacy of the procedures outlined by Foort (J) for fabricating and fitting plastic Syme prostheses patterned after earlier developments of the Prosthetic Services Centre, Department of Veterans Affairs, Toronto (2; see also page 87). Initially, amputee acceptance of the plastic prosthesis over prostheses previously worn was exceptionally high, but structural failure of the socket occurred

<sup>1</sup> Orthopedic Consultant, Veterans Administration Prosthetics Center, 252 Seventh Avenue, New York 1, N. Y.

<sup>2</sup> Research Prosthetist, Limb and Brace Section, Veterans Administration Prosthetics Center.




Fig. 1. Carved wood Syme prosthesis with anterior opening and lacer. Often steel straps are embedded in the wood medially and laterally as reinforcements. This prosthesis, finished with rawhide and paint, had a leather-covered felt toe and a single-axis ankle joint with flexion-control bumpers.

often, and a number of amputees, though capable of assuming weight-bearing on the end of the stump for a part of the day, complained that no provision was made to any appreciable extent, for assuming weight-bearing in other areas (5). From the experience gained in the clinical trials, the so-called "VAPC Medial-Opening Syme Prosthesis" (4; see also page 57) was developed.

During the course of the ensuing years, 24 Syme cases were fitted at VAPC with the medial-opening Syme prosthesis. From the clinical histories there have been selected, purely on the basis of availability, eight cases for re-examination and follow-up. Together

with some supplementary data on the other 16, they constitute the basis of this report.

All but one of the 24 cases had worn the more conventional molded leather or carved willow prostheses for at least two years before trying the VAPC type. Some amputees had had experience with polyester-Fiberglas Syme prostheses with full posterior opening. The prior experience of these cases provided opportunity to make comparisons as to comfort, weight, durability, cosmesis, and so on. When the cases were last reviewed, the new prostheses had been worn for periods ranging from 7 months to 43 months (Table 1).

#### EIGHT CASE HISTORIES

##### *Case 1 (H. H.)*

Case 1, a 38-year-old college student weighing 140 lb. and standing 5 ft. 8 in., suffered irreparable damage to his left foot and left upper extremity in a landmine explosion in Korea in 1954. In emergency treatment in Korea, left Chopart and left below-elbow amputations were performed. In January 1955, at Walter Reed General Hospital, a left Syme amputation was carried out because of poor healing at the prior level, and the stump was permitted to drain. In July 1955, the patient was admitted to the VA Hospital, Brooklyn, New York, to have the stump drainage cleared. By the time he was seen for this study, the flap had migrated posteriorly, as shown in Figure 2. Portions of the scar had moved nearer to the usual area for end-bearing and had thus created wrinkles in the skin on the posterodistal aspect of the stump.

The first prosthesis, made late in 1955, was a conventional wood-and-leather Syme prosthesis with anterior lacing. It was worn until 1957, when, because of great discomfort at the end of the stump, the patient was unable to use the limb continuously. Early in 1957 the patient was referred to the Veterans Administration Prosthetics Clinic, where another conventional prosthesis was made. It was worn a few months with moderate success but with some need for repair.

In September 1957, a plastic VAPC Syme prosthesis with medial opening was delivered. But presumably because of the displaced flap

**Table 1**  
**Summary of 24 Cases Fitted in VA Prosthetics Center With Medial-Opening,**  
**Polyester-Nylon Syme Prostheses \***

Case No. and Initials	Age (yr.)	Wt. (lb.)	Hgt. (in.)	Occupation	Other Major Medical Problems	Last Syme Prosthesis	Last Prosthesis from VAPC (date issued)
1. H. H.	38	140	68	Student	Left below-elbow amputation	Polyester-Nylon Medial opening	11/59
2. R. W.	40	170	69	Machinist	None	Polyester-Fiberglas Posterior opening <sup>b</sup>	8/58
3. K. K.	39	150	71	Auditor	None	Polyester-Nylon Medial opening	5/58 <sup>a</sup>
4. A. M.	38	175	66.5	Diamaker	None	Polyester-Fiberglas Posterior opening	11/58
5. J. J.	43	220	71	Janitor	Bilateral Syme as of 2/60, when left Syme was performed	Polyester-Fiberglas Posterior opening (right side)	10/58
6. J. B.	39	160	76	Salesman	None	Polyester-Fiberglas Posterior opening	7/59
7. S. G.	43	160	64	Clerk	None	Polyester-Fiberglas Posterior opening	10/58
8. N. B.	50	165	67.25	Tailor	None	Polyester-Nylon Anterior opening	2/59
9. H. M.	38	195	74	Design Engineer	None	Carved wood	9/59
10. L. B.	43	195	67	Clerk	None	Carved wood	11/56
11. F. C.	43	185	67	Student	Right Chopart with left Syme	Carved wood	3/59
12. A. R.	27	168	72	Truck Driver	Bilateral Syme	Bilateral carved wood	9/58 (Bilateral)
13. W.B.	36	212	72	Clerk	None	Steel and leather	1/59
14. E. V.	45	170	72	Truck Driver	None	Carved wood	1/59
15. S. C.	28	230	70.5	Draperly Hanger	None	Steel and leather	1/58
16. S. F.	35	155	68	Gardener	Right below-knee with left Syme, some paralysis in both lower extremities	Steel and leather	2/58
17. H. C.	34	175	70	Salesman	None	Carved wood	9/58
18. J. S.	35	144	72.5	Factory wkr.	None	Steel and leather	7/58
19. I. C.	35	145	70	Tailor	None	Carved wood	3/59
20. J. R.	48	125	63	Clerk	None	Steel and leather	10/58
21. E. L.	49	204	73	Carpenter	None	Carved wood	1/59
22. E. Z.	29	170	67	Accountant	Bilateral Syme	Bilateral carved wood	10/59 (Bilateral)
23. W. S.	44	170	72	Pattern-maker	Peripheral vascular weakness	Steel and leather	8/59
24. M. M.	43	175	68	Clerk	None	Carved wood	11/59

(Moved Down)

Case No. and Initials	Type of Weight-Bearing Provided in Prosthesis	Months Worn to July 1960 (last prosthesis)	Patient Status as of July 1960 (last prosthesis)
1. H. H.	Full proximal	7	Wearing, no trouble
2. R. W.	Mainly distal with some proximal	22	Wearing, no trouble
3. K. K.	Distal partial posterior opening <sup>a</sup>	25	Wearing, no trouble
4. A. M.	Mainly distal with some proximal	19	Wearing, no trouble
5. J. J.	Mainly distal with some proximal	18 (to 4/60; see text)	Not wearing. Now wears bilateral polyester-nylon full posterior opening with steel uprights made 4/60 in Buffalo, N. Y.
6. J. B.	Mainly distal with some proximal	11	Wearing, no trouble



6. J. B.	Mainly distal with some proximal	11	Wearing, no trouble
7. S. G.	Mainly distal with some proximal	20	Wearing, no trouble
8. N. B.	Mainly distal with some proximal	16	Wearing, no trouble
9. H. M.	Mainly distal with some proximal	9	Wearing, no trouble
10. L. B.	Mainly distal with some proximal	43	Wearing, no trouble
11. F. C.	Mainly distal with some proximal	15	Wearing, no trouble; duplicate spare now being fabricated
12. A. R.	Mainly distal with some proximal	21	Wearing bilaterally, no trouble
13. W. B.	Mainly distal with some proximal	17	Wearing at work, using spare M-0 Syme at home
14. E. V.	Mainly distal with some proximal	17	Wearing, no trouble
15. S. C.	Mainly distal with some proximal	29	Wearing, no trouble
16. S. F.	Mainly distal with some proximal	28	Wearing, no trouble
17. H. C.	Mainly distal with some proximal	21	Wearing, no trouble
18. J. S.	Mainly proximal with some distal	23	Wearing, no trouble
19. I. C.	Mainly distal with some proximal	15	Wearing, no trouble
20. J. R.	Mainly distal with some proximal	20	Wearing, no trouble
21. E. L.	Mainly distal with some proximal	17	Wearing, no trouble
22. E. Z.	Mainly distal with some proximal	8	Wearing bilaterally, no trouble
23. W. S.	Mainly distal with some proximal	10	Wearing, no trouble; uses for swimming
24. M. M.	Mainly distal with some proximal	7	Wearing, no trouble

Except for Cases 1 and 2, all of these cases felt that they were taking weight on the ends of their stumps. The proximal component of weight-bearing apparently was not too noticeable among these cases. Cases 1 and 2 were able to discern the proximal weight-bearing provided, Case 2 being the only one distinguishing the "same proximal" in his fitting. <sup>a</sup>With the exception of Case 3, who in May 1958 was eventually given a polyester-nylon, partial-posterior-opening prosthesis (Fig. 4). <sup>b</sup>Unless otherwise noted, "posterior opening" refers to full posterior flap hinged at the bottom. <sup>c</sup>There is probably a large component of peripheral support owing to the clamping action of the cover for the posterior opening.

the patient was unable to tolerate end-bearing. Accordingly, all support was transferred to the proximal portion of the shank, the socket being fitted and relieved as for a below-knee prosthesis. Gait was excellent. For the first time the patient was able to use a prosthesis continuously while actively wearing it an average of 16 hours a day. In November 1959, after the prosthesis had been worn for a little over two years, some stump shrinkage in the proximal weight-bearing areas required the fabrication of a new prosthesis.

#### Case 2 (R. W.)

During the campaign in the Philippines in 1945, Case 2, a 40-year-old machinist 5 ft. 9 in. tall and weighing 170 lb., received wounds in his left foot from a mortar-shell explosion. An emergency transmetatarsal amputation (through all metatarsals but the first) was performed in a field hospital. Osteomyelitis developed two years later and again in 1948. As a result, a Syme amputation was performed at a VA hospital in 1950.

The first Syme prosthesis, issued in 1950, consisted of the usual willow socket and an anterior leather lacer over a soft tongue. From the outset, the patient experienced difficulties on the anterior aspect of the shank along the tibial crest. When the patient was first seen in 1957, concentrated pressure of the lacing had led gradually to an ulcer along the upper two thirds of the anterior aspect of the shank.

In the same year, a Fiberglas, Canadian-type prosthesis with full-length posterior opening was delivered. It allowed full end-bearing, although tightening of the encircling strap tended to compress the posterior door against the stump, thus possibly increasing the proportion of weight-bearing on the sides of the socket and perhaps on flaring portions under the tibial condyles. The upper portion of the

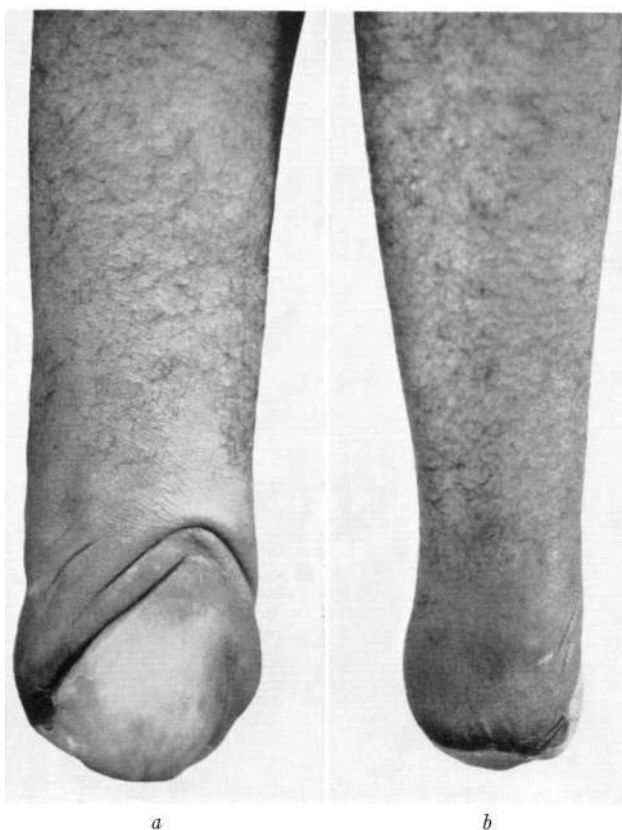


Fig. 2. Stump of Case 1, a left Syme amputee, *a*, Posterior view; *b*, anterior view. Note migration of skin flap.

anterior socket wall was made from a cast of the stump and was padded but not specifically relieved over the tibial crest. Although the patient thus continued to have considerable discomfort along the ulcerated area of the tibial crest, he wore the prosthesis for three and a half months.

Several mechanical failures occurred at and just above the ankle region. On August 1, 1958, therefore, a new Syme prosthesis, VAPC type, was delivered. It consisted of a semi-flexible plastic laminate over a modified plaster model and made provision for bearing part of the weight proximally. With the new device, the ulceration along the anteroproximal two thirds of the leg cleared, presumably because of the relief provided along the tibial crest. The patient was comfortable for the first time since amputation. He still wears the limb as of July 1960.

*Case 3 (K. K.)*

Case 3, a 39-year-old auditor 5 ft. 11 in. tall and weighing 150 lb., suffered damage to his right foot in France in 1945 in a landmine explosion. Emergency surgery performed in a field hospital was followed several months later by a Syme amputation. About two months after that, the patient was provided with a temporary prosthesis and then, later, with a conventional prosthesis fabricated of leather with a steel frame. After two more months he developed a painful callus along the line of suture, and surgery was undertaken to refashion the scar. Irregularities on the distal end of the tibia (Fig. 3) apparently caused no difficulty.

In 1946, a conventional Syme prosthesis made of wood and leather was provided by the New York VA. It broke down several times owing to structural failure, as did also two other conventional prostheses. Finally, in December 1957, the patient was supplied with a polyester-Fiberglas Syme prosthesis having a full posterior opening. In February 1958 the prosthesis was returned, again because of mechanical failure.

Repairs having been made, the patient was next referred to the VAPC Prosthetics Clinic Team, where a VAPC polyester-nylon Syme prosthesis with medial opening was prescribed. But the patient complained that, because of the bulbous end of the stump, he encountered difficulty in donning the typical prosthesis with medial opening. Later, in May 1958, to meet the patient's request, a prosthesis having a small posterior opening but closed top third (Fig. 4) was prescribed and fabricated despite apparent weakening of the structure.

This final prosthesis has been worn continuously for 16 to 18 hours a day since its initial delivery. Most of the weight-bearing is of the "distal" type, but some component of support is absorbed peripherally by the clamping action of the cover for the posterior window. The old, healed fracture with ossification near the head

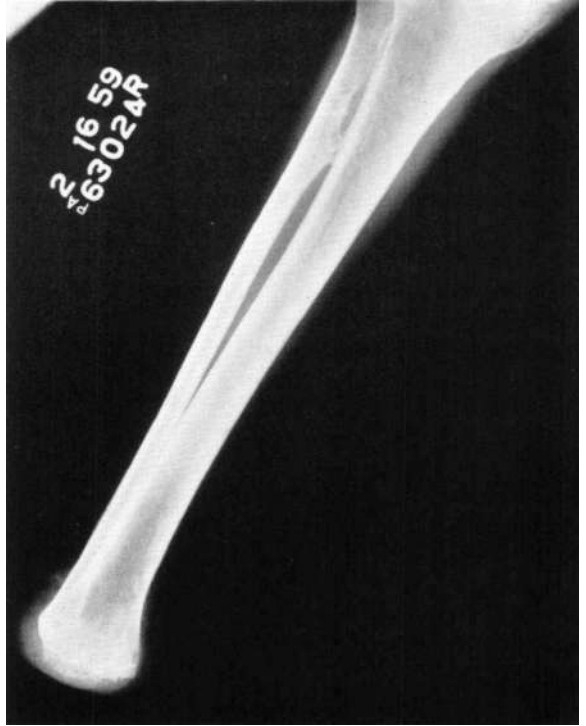

Fig. 3. X-ray (anterior view) of stump of Case 3, a right Syme amputee. Note rough surface on base of tibia and residuum of compound fracture in upper third of fibula.

of the fibula (Fig. 3) did not interfere with fitting or use. Patient continues to use the last prosthesis as of July 1960.

*Case 4 (A. M.)*

Case 4, a 175-lb., 38-year-old diemaker measuring 5 ft. 6 1/2 in., stepped on a landmine in Germany in 1944. A considerable portion of his right foot was shattered, and infection and gangrene followed. Surgical amputation of part of the foot was carried out in England. In October 1945, in the United States, a Syme amputation was performed, the fibula being transected higher than the tibia (Fig. 5).

Several weeks after the Syme amputation the patient was given a pylon, which he wore for about three months. A conventional Syme prosthesis fabricated of leather with a steel frame was then fitted, but two successive replacements were necessary because of mechanical breakdown. The patient was referred to the VAPC Prosthetics Clinic Team in

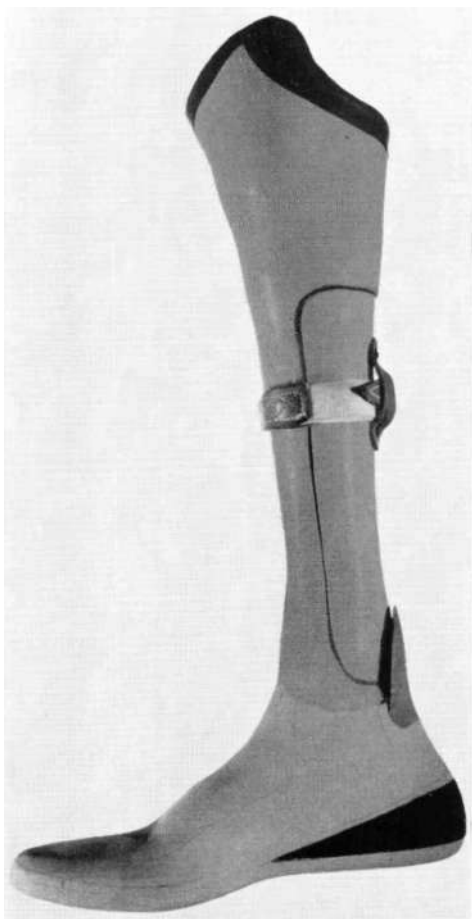

Fig. 4. Modified VAPC Syme prosthesis, partial posterior opening for Case 3, a right Syme amputee.

February 1958, at which time a Syme prosthesis of Fiberglas and polyester resin and with full-length posterior opening was prescribed. Frequent breakage of the metal hinge at the back as well as cracking of the plastic at the ankle section occurred, and the patient complained of insufficient support in the socket and of pinching of the skin at the crevices resulting from the two-piece construction of the prosthesis (J). Moreover, he had a painful callus at the end of the stump in the region of the scar.

In November 1958 a medial-opening Syme prosthesis was delivered, and a checkup at the end of 30 days showed a reduction in the

callus, absence of pain, and excellent skin over the end of the stump. Much pleased with the prosthesis, the patient wore it continuously for about 16 hours a day. He is still wearing it as of July 1960.

#### *Case 5 (J. J.)*

Because of chronic osteomyelitis of the toes bilaterally, Case 5, a 43-year-old janitor weighing 220 lb. and standing 5 ft. 11 in., was in 1946 subjected to amputation of the first toe of his right foot. In 1947, the second toe of the right foot was amputated. In 1948, the left second toe was amputated. Then, in 1955, because of progressive osteomyelitis, the second and third metatarsals of his right foot were excised. Despite these measures, he developed an ulceration of his right foot with drainage. In 1957, therefore, a right Syme amputation was performed. A conventional Syme prosthesis, supplied later in 1957, consisted of a Celastic socket (6) mounted in a steel frame. Mechanical failures were numerous, and because of anterior lacing constant pressure was experienced along the tibial crest (Fig. 6). In April 1958, a Fiberglas-reinforced polyester-plastic prosthesis with a full posterior opening was supplied, but it also suffered numerous mechanical failures, the most frequent involving cracking of the plastic at the ankle section.

A VAPC prosthesis with medial opening was provided in October 1958. Several follow-ups revealed excellent gait with only a slight limp. The patient wore the prosthesis 16 hours daily and had no complaints until, in February 1960, osteomyelitis in the left foot required a left Syme amputation—in Buffalo, N. Y. The newly acquired bilaterality necessitated a revision in the alignment previously formulated for the one prosthesis and allowed some flexibility in designing the height of both prostheses. Accordingly, the VAPC prosthesis was condemned as no longer serviceable. New bilateral Syme prostheses, procured in Buffalo in April 1960, were of the polyester-nylon type with full posterior opening but with upright steel reinforcements laminated on the medial and lateral sides.

#### *Case 6 (J. B.)*

In April 1955, a 39-year-old salesman weighing 160 lb. and standing 6 ft. 4 in. required a

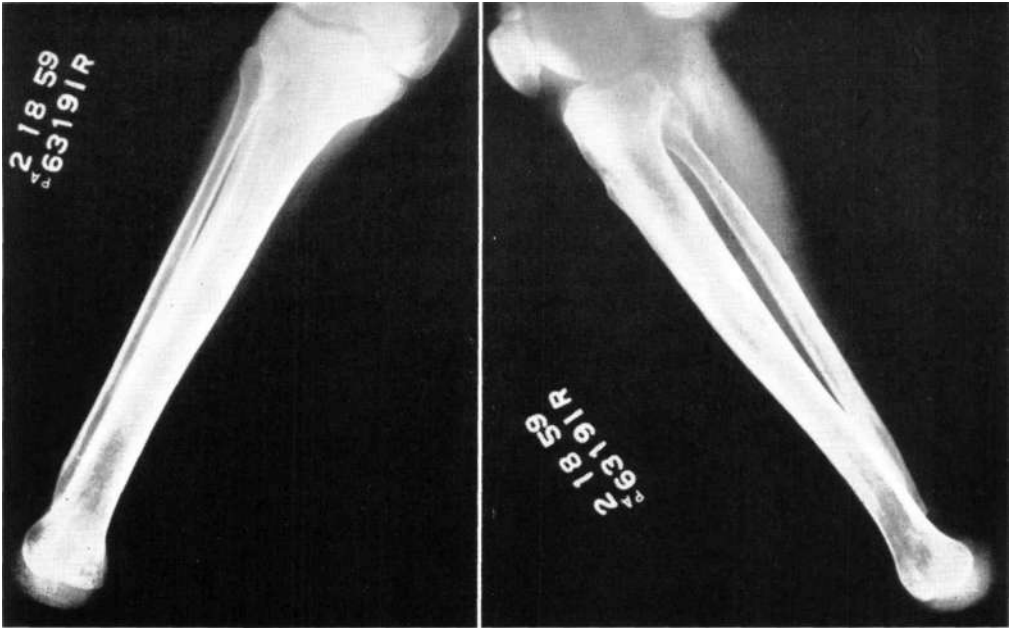


Fig. 5. X-rays of stump of Case 4, a right Syme amputee, *a*, Anterior view; *b*, medial view. Note that fibula is shorter than tibia, presumably owing to trauma.

Syme amputation for osteomyelitis, with which he had suffered for 11 years. In the same year he was given his first prosthesis, one fabricated of wood, and in March 1958 he was referred to VAPC. Provided with a prosthesis with posterior opening, he noted pressure on the tibial crest. Several unsuccessful attempts to relieve the pressure led in July 1959 to fabrication of a medial-opening VAPC prosthesis with partial proximal weight-bearing, whereupon the previous pressure areas were relieved. With the new prosthesis, the patient was able to get about easily for 16 hours daily. He continues to wear this prosthesis as of July 1960.

*Case 7 (S. G.)*

A 43-year-old clerk weighing 160 lb. and standing 5 ft. 4 in. suffered irreparable injuries to his right foot in November 1944 when he stepped on a landmine in Germany. A Chopart amputation was performed shortly thereafter in Holland, and a Syme amputation occasioned by osteomyelitis followed in the United States in 1945. A leather-and-steel prosthesis was furnished in June 1945, and the patient subsequently received, one after another, three wood-and-leather conventional prosthe-

ses, which he wore successively until 1957. At that time a posterior-opening plastic Syme prosthesis was fitted, but the patient complained that it caused constant pressure on the tibial crest, with repeated breakdown of the skin in that area, and that the numerous modifications did not relieve the pain and discomfort. In October 1958, a VAPC prosthesis with medial opening was fabricated with the usual relieved areas over the tibial crest and neighboring bony prominences. Patient now walks with no discomfort and has no complaints. He continues to wear the prosthesis as of July 1960.

*Case 8 (TV. B.)*

Case 8, a 50-year-old, 165-lb. production tailor 5 ft. 7 1/4 in. tall, received wounds of the left leg from shellfire in France in 1944. Emergency surgery was performed in an evacuation hospital, and a left Syme amputation was performed in the United States in 1945. Compound fracture of the upper end of the tibia, with subsequent osteomyelitis, resulted in the defects shown in Figures 7, 8, and 9. Severe scarring and then scalelike surface tissues replaced normal skin in the area concerned.

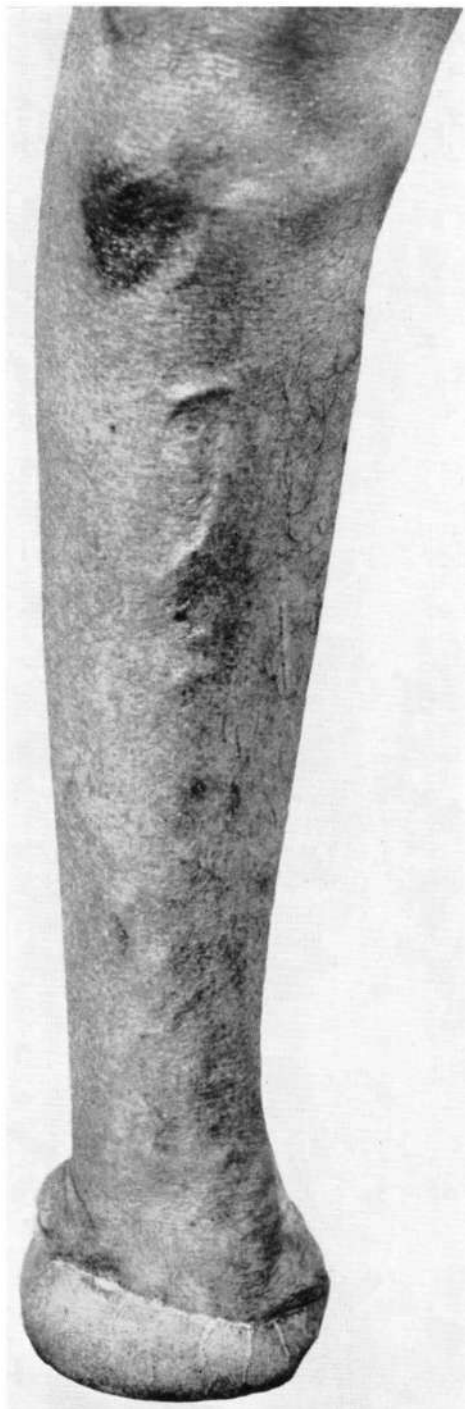

Fig. 6. Effect of tight lacing and soft tongue on tissues overlying tibial crest, especially in the vicinity

Although the patient wore a semiflexible polyester-nylon Syme prosthesis with full-length anterior opening, leather tongue, and conventional foot (Fig. 10), he was never able to wear it continuously because on the anteroproximal aspect of the leg, especially at the margin of the tibial defect (where the laces caused concentrated pressure), he experienced severe pain and frequent breakdown of scar tissue and of skin otherwise abnormal. A new Syme prosthesis, with medial opening and sufficient relief to provide air space between the anteroproximal wall of the socket and the sensitive anteroproximal scar tissue, has given complete relief of the earlier symptoms since February 1959. As of July 1960 the patient continues to wear the prosthesis.

#### SUMMARY AND CONCLUSIONS

Details concerning these eight cases, and also some information on the 16 others, are summarized in Table 1. In all of the 24 cases fitted at VAPC with the medial-opening Syme prosthesis, the surgery appeared to be adequate. In general, the long bones had been cut not necessarily perpendicular to their longitudinal axes but so that, when the patient stood, the planes of the ends were substantially parallel to the floor. Because in all cases the surgeon handled the periosteum carefully, no serious bone spurs had developed, though in a few cases (*e.g.*, Cases 3 and 8) x-rays showed that slight irregularities had formed on the cut end of the tibia. In Case 4 (Fig. 5), the fibula had been cut above the level of the tibia, probably because of damage to the end of the fibula with subsequent infection. None of the cases indicated bony cross-union between tibia and fibula.

In general, soft-tissue surgery was good, so that adequate fat pads remained in the heel cushion and good circulation prevailed in the skin flap as well as in the whole stump. A good circular flap was provided, and no significant dog-ears were noted. In Case 1 the flap was displaced (Fig. 2); in all others it was in the proper position.

All but two of the 24 preferred the VAPC type of prosthesis to any of the prostheses worn of the tibial tuberosity, as evidenced by short diagonal skin discolorations (right Syme stump of Case 5).

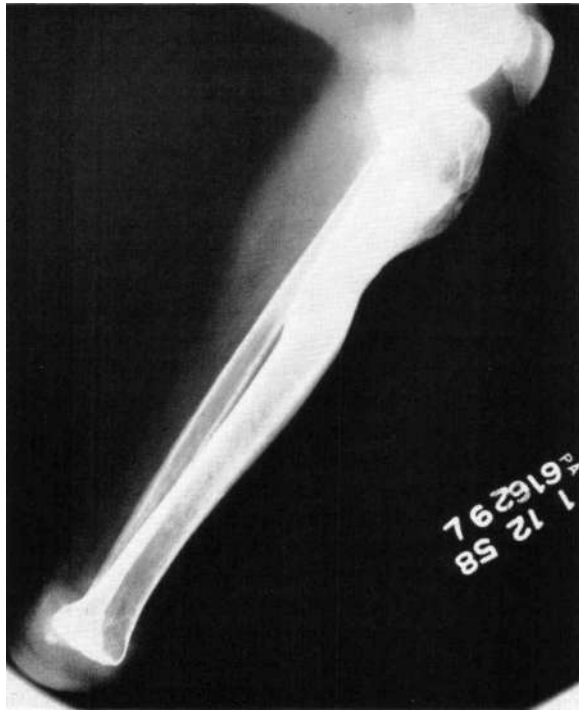

Fig. 7. X-ray (medial view) of stump of Case 8, left Syme amputee. Note anterior indentation of tibia due to compound fracture.

previously, and they all wore it rather routinely.<sup>3</sup> Each of the patients had at one time used the so-called "conventional" Syme prosthesis (wood or leather-and-steel socket with laced opening on the anterior aspect), and six had been provided later with plastic (Fiberglas-polyester) Syme prostheses incorporating a SACH foot and full-length posterior opening and fabricated and fitted according to Foort (3). In two instances, discomfort alone prompted the change to the VAPC type of socket; in another two instances rupture of the plastic caused the change; in the remaining two instances both discomfort and mechanical failure occurred. Had the so-called "Canadian-type" prostheses been fabricated of Fiberglas cloth, Fiberglas roving, and epoxy resin, the mechanical failures would likely not have occurred. It is probable also that, had the same meticulous care been employed as is now used in modification of the socket and in alignment

<sup>3</sup> Cases 3 and 5 converted to posterior openings, as already mentioned.

of the prosthesis, some of the problems of discomfort would not have developed.

As Table 1 shows, weight-bearing typically was distributed between the end of the stump and the condyles of the tibia at the proximal end of the prosthesis. Presumably the sloping walls of the socket also carried some share of the load. Generally, the VAPC prosthesis fitted precisely on the stump to a higher level than had the older prostheses. Proportioning of the weight distribution was judged by the individual prosthetist, but only one wearer (Case 3), who indeed had slight irregularities at the end of the tibia (Fig. 3), was able to utilize end-bearing alone. In contrast, Case 1 was unable to tolerate any end-bearing, though the long lever arm of the shank was advantageous. The remaining cases required weight distribution between the distal end of the stump, the sloping walls of the shank, and the proximal region in the vicinity of the tibial condyles, Case 18 alone requiring more of a proximal component than of a distal one.

Concentration of pressure on the tibial crest,

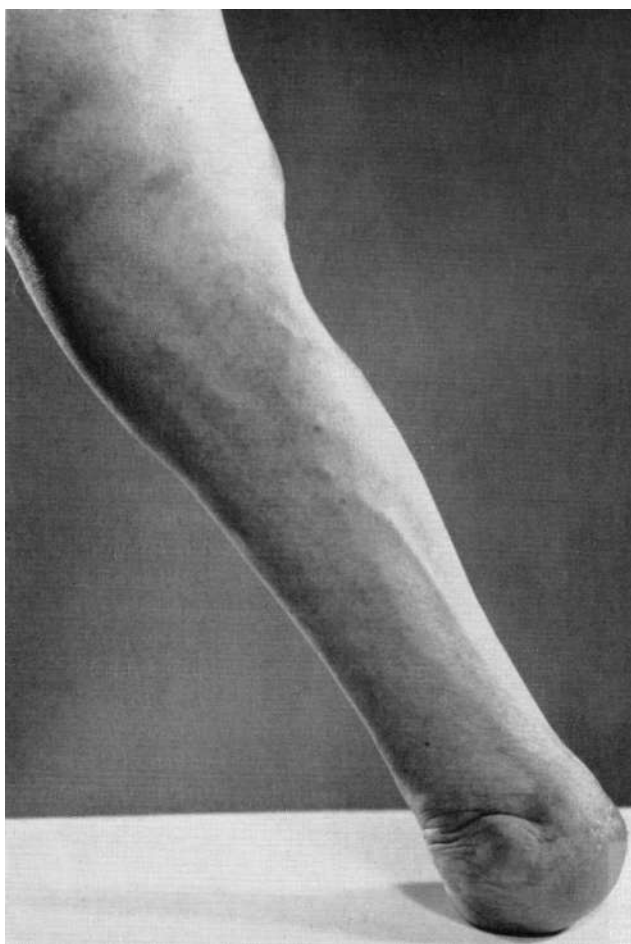


Fig. 8. Stump of Case 8 (left Syme amputee), medial view showing anterior deformity.

particularly near the tibial tuberosity, was relatively common with wood or leather prostheses having an anterior opening laced over a relatively soft leather tongue. Late in the stance phase, the Syme amputee supports his weight on the ball of the artificial foot with the heel off the ground. Biomechanical analysis (page 76) shows that at that time the prosthesis not only presses upward on weight-bearing areas with a considerable leverage behind the point where the ball of the foot contacts the floor but also exerts on the stump compensatory forces substantially horizontal—backward on the tibia near the proximal end of the socket and forward on the bulbous distal end of the stump.

In the older prostheses with anterior lacing, the proximal forces were concentrated largely in the upper laces and the knot. Deforming the soft tongue, these forces caused high pressures on the thinly padded anteromedial aspect of the tibia and especially on the sharp tibial crest (Fig. 6). Force concentration was particularly serious at the bulky knot, which typically was near the projecting tibial tuberosity. Loose laces allowed exceptional concentration near the top and the knot, while tightening of the laces in an attempt to relieve an uncomfortable stump merely added constant pressure to the inevitable dynamic pressure accompanying every step. Furthermore, any axial pumping (due to cushioning of the distal end or distortion of either the stump or the pros-



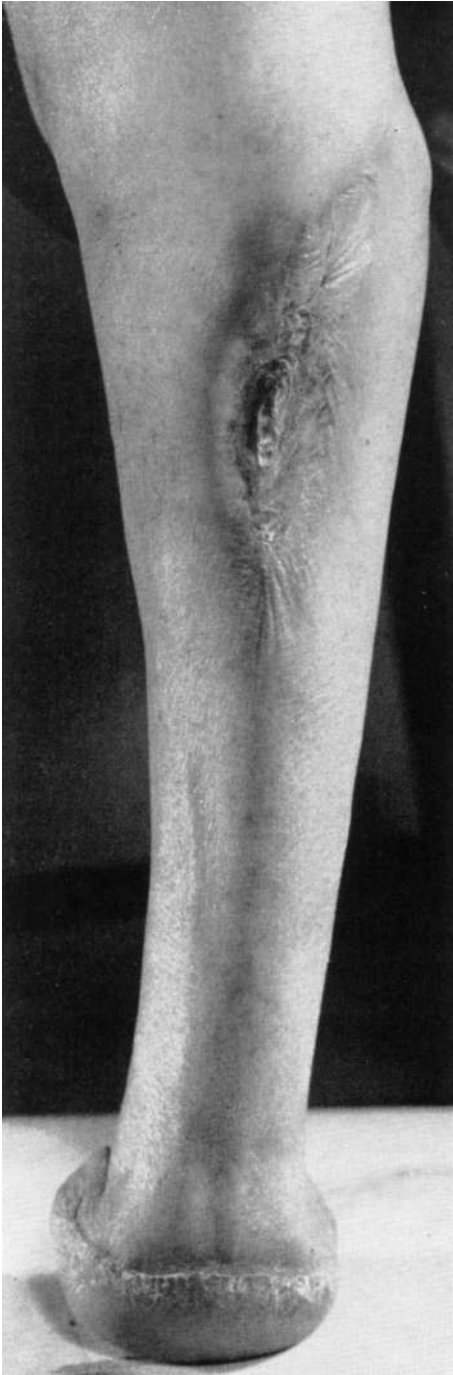


Fig. 9. Stump of Case 8 (left Syme amputee), anterior view showing scarring and tissue deterioration in region of fracture, subsequent osteomyelitis.

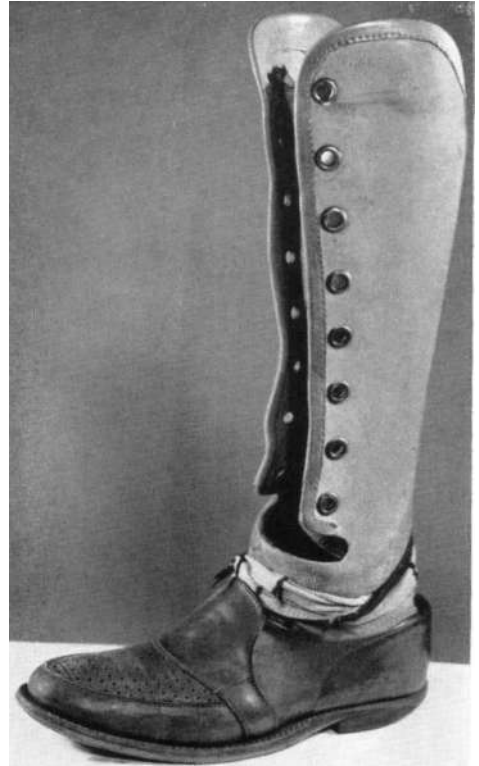


Fig. 10. Plastic Syme prosthesis worn by Case 8, left Syme amputee, until February 1959. The posterior portion of the socket was made of a fully rigid resin, the formulation being so controlled as to produce a gradual change to full flexibility in the anterior portion, which forms part of the lacer. A leather tongue was used in the anterior opening, and a conventional foot, attached to the bottom of the socket by a cable, had a well for a rubber block which provided control in flexion-extension, inversion-eversion, and torsion.

thesis) added chafing to an already unsatisfactory set of circumstances. The high incidence of discomfort and of outright ulceration in such cases is therefore not surprising. In the VAPC type of Syme prosthesis, elimination of the conventional anterior lacing and soft leather tongue, or of the snugly strapped door closing a posterior opening, relieved both dynamic and constant pressures along the anterior aspect of the tibia, especially near the tibial tuberosity. Many areas previously ulcerated were thus cured.

In one case callus developed along the scar during wear of the conventional prosthesis;

in another it formed while the Canadian type with posterior opening was used. Possibly callus of this kind arises in response to the horizontal forces on the rear of the bulbous end of the stump late in the stance phase. It may be aggravated by chafing either from antero-posterior motion or from axial pumping of an atrophied stump by virtue of loose fit of the socket below the region that can be tightened by the laces. Obviously, such callus may develop with any type of Syme prosthesis if chafing occurs, and for this reason every effort should be made to provide a socket giving the least possible degree of relative motion while avoiding constriction.

All of the eight subjects discussed in detail in this paper complained of the excessive weight of their old devices. The new prostheses were from 1 to 1 1/2 lb. lighter than the corresponding old prostheses. Durability seemed improved in the relatively short period recorded here. Width at the broadest portion of the ankle was less than with the conventional, bulky, metal sidebars formerly used to reinforce leather or Celastic sockets.

The results achieved thus far present a convincing argument in favor of the VAPC Syme prosthesis. Distribution of weight-bearing over broad areas reduces unit pressures in the socket of any artificial leg. Thus any Syme limb that offers the prosthetist the facility for *controlled* distribution of weight in distal *and* proximal regions not only offers a distinct advantage with respect to socket comfort but also allows full control of the prosthesis by the stump. A design limited primarily to distal weight-bearing but with some possibility of weight-bearing

over peripheral fleshy areas of the stump through a clamping action of a posterior "door" does not ordinarily provide the limbfitter with the weight-bearing control "adjustments" available in the "medial-window" Syme, where normal below-knee weight-bearing areas may or may not be employed as local circumstances warrant. For these reasons the VAPC Syme prosthesis deserves especially the serious consideration of those surgeons who, for the sole reason that they considered the Syme prosthesis to be unacceptable, have heretofore favored higher amputations of the leg when Syme's amputation might otherwise have sufficed. Prosthetists likewise may consider the VAPC design as a means of facilitating the fitting of Syme amputees.

#### LITERATURE CITED


1. Alldredge, Rufus H., and Eugene F. Murphy, *Prosthetics research and the amputation surgeon*, Artificial Limbs, 1(3):4 (September 1954). Especially pp. 23-25.
2. Department of Veterans Affairs, Prosthetic Services, Toronto, Canada, *Syme's amputation and prosthesis*, January 1, 1954.
3. Foort, J., *The Canadian type Syme prosthesis* (Series 11, Issue 30), Lower-Extremity Amputee Research Project, Institute of Engineering Research, University of California, Berkeley, December 1956.
4. Iuliucci, Louis, *VAPC technique for fabricating a plastic Syme prosthesis with medial opening*, Veterans Administration Prosthetics Center, New York, September 1959.
5. New York University, Prosthetic Devices Studies, College of Engineering, *Progress report, test of the Canadian type plastic Syme prosthesis (modified)*, New York, December 1958.
6. O'Flaherty, Fred, *Leather*, in *Orthopaedic Appliances Atlas*, Vol. 1, Edwards, Ann Arbor, Mich., 1952. Pp. 24-25.

## Technical Notes from the Artificial Limb Program

*This section of ARTIFICIAL LIMBS is intended as an outlet for new developments in limb prosthetics which, though not deserving of a long feature article, nevertheless ought to be brought to the attention of the readers of this journal. Notes may vary in length from a single paragraph to several pages of manuscript, as appropriate. Illustrations also are acceptable.*

In addition to its obvious possibilities as a substitute for the conventional metal zipper, therefore, Velcro tape may be so applied as to construct advantageous replacements for hooks and eyes and for the usual variety of buckles. In practice, a Velcro loop strip and a Velcro hook strip are sewn in series, end to end, as shown in the accompanying photographs. The hook strip is fastened to one part of the appliance, the loop strip is brought through a link attached to the other, and the end of the loop strip is then pressed down on to the hook strip. The result is a "snubbing-post" assembly capable of resisting higher tensile loads than would be the case were a loop strip on one part of the appliance simply lapped over a hook strip on another part.

Used in this way, Velcro makes a fastener




"VELCRO" TAPE AS NEW FASTENER—Some typical applications. Left, on a plastic-laminate body jacket; center, on the "socket" of a below-knee weight-bearing brace; right, on a VAPC plastic Syme prosthesis with medial opening. Courtesy Veterans Administration Prosthetics Center, New York City.

### "Velcro" Fasteners

Since the spring of 1958, the Veterans Administration Prosthetics Center, New York City, has been investigating possible applications of "Velcro," a nylon closure, in the construction of limb prostheses and body braces. Product of the Velcro Corporation (681 Fifth Ave., New York 22, N. Y.), this "zipperless zipper" consists of two kinds of nylon tape—a side of one having filaments with hook tips, a side of the other having loops of nylon multifilament yarn. When a strip of the first kind is pressed against a strip of the second, the hooks in the one mesh with, or grasp, the loops in the other so as to produce a juncture that resists tension in the plane of the fabric but which yields to tensile forces applied in angular directions. Separating two strips is thus simply a matter of peeling them apart.

of almost unlimited adjustment, easy to manipulate, and less bulky than the typical fastener made up of leather strap and metal buckle. The material is washable without loss of essential properties, and of course the possibility of corrosion is eliminated in all but the metal link. In the comparatively short period of study (about a dozen cases), Velcro tape has been applied to body jackets, corsets, shin guards, leg-thigh braces, leg braces, and harnesses and suspension straps for upper-extremity prostheses—almost always to the considerable satisfaction of the user. For brace-wearing hemiplegics, for example, the Velcro "buckle" makes it easier to cinch up the brace cuffs and avoids the necessity of finding the proper hole for the tine of the usual buckle. Furnished with a supply of Velcro tape, one bilateral arm amputee has been experimenting with modifications of



"VELCRO" TAPE—Close-up of the two mating surfaces, almost actual size (1 in.). *Courtesy VAPC.*

*clothing* fasteners. He has already used Velcro to replace the conventional trouser buckle and fly zipper, and he expects to try it out on shirts with a view toward eliminating the need for buttoning.

Velcro tape is, then, not only a substitute for the familiar forms of the slide fastener; it is also a means and a method for improvising useful fasteners of other kinds in specially selected cases. Accordingly, it appears to have a wide range of applicability and to be deserving of attention by practicing clinic teams. Accounts of others' experience with Velcro tape in the field of prosthetics-orthotics are solicited.

—*Anthony Staros*

## NATIONAL ACADEMY OF SCIENCES—NATIONAL RESEARCH COUNCIL

The National Academy of Sciences—National Research Council is a private, nonprofit organization of scientists, dedicated to the furtherance of science and to its use for the general welfare.

The Academy was established in 1863 under a Congressional charter signed by President Lincoln. Empowered to provide for all activities appropriate to academies of science, it was also required by its charter to act as an adviser to the Federal Government in scientific matters. This provision accounts for the close ties that have always existed between the Academy and the Government, although the Academy is not a governmental agency.

The National Research Council was established by the Academy in 1916, at the request of President Wilson, to enable scientists generally to associate their efforts with those of the limited membership of the Academy in service to the nation, to society, and to science at home and abroad. Members of the National Research Council receive their appointments from the President of the Academy. They include representatives nominated by the major scientific and technical societies, representatives of the Federal Government, and a number of members-at-large. In addition, several thousand scientists and engineers take part in the activities of the Research Council through membership on its various boards and committees.

Receiving funds from both public and private sources, by contribution, grant, or contract, the Academy and its Research Council thus work to stimulate research and its applications, to survey the broad possibilities of science, to promote effective utilization of the scientific and technical resources of the country, to serve the Government, and to further the general interests of science.