

TR 10-6  
AUGUST 1969

the **MANAGEMENT**  
of **LOWER-EXTREMITY**  
**AMPUTATIONS**

Surgery

Immediate Postsurgical Prosthetic Fitting

Patient Care

PROSTHETIC AND SENSORY AIDS SERVICE  
DEPARTMENT OF MEDICINE AND SURGERY  
VETERANS ADMINISTRATION, WASHINGTON, D.C.

the **MANAGEMENT**  
of **LOWER-EXTREMITY**  
**AMPUTATIONS**

**Surgery**  
**Immediate Postsurgical Prosthetic Fitting**  
**Patient Care**

**ERNEST M. BURGESS, M.D.,** Principal Investigator  
**ROBERT L. ROMANO, M.D.,** Associate Investigator  
**JOSEPH H. ZETTL, C.P.,** Director

Prosthetics Research Study  
Seattle, Washington

This publication was prepared  
for the Prosthetic and Sensory Aids Service  
Veterans Administration  
under the terms of  
Contract No. V5261P-438

Library of Congress Catalog Card No. 70-602816

---

For sale by the Superintendent of Documents, U.S. Government Printing Office  
Washington, D.C. 20402 - Price \$1.50

## FOREWORD

Some two years ago I had the pleasure of writing a foreword to the publication, "Immediate Postsurgical Prosthetics in the Management of Lower Extremity Amputees," under the authorship of Burgess, Traub, and Wilson. That handbook, published in 1967 and sold by the Superintendent of Documents, has been exceedingly well received. The demand for that publication is indicative of the interest shown by clinicians in these relatively new procedures. Undoubtedly, this new publication, reflecting the additional experience and insights gained by the Prosthetics Research Study in Seattle, funded through the VA Hospital in Seattle, will have a still greater impact on clinical practice.

This new monograph is much more comprehensive than its predecessor. A "how to do it" approach is utilized for all the sequences involved. Illustrations are abundantly used to facilitate the reader's understanding of the various procedures described. The decision of the authors to repeat certain sequences in each of the chapters dealing with the various levels of amputations eliminates the need for the reader to refer constantly to different parts of the book. Each chapter can thus serve as a ready reference for a given level of amputation.

A well-described and illustrated presentation on immediate postsurgical prosthetics management is obviously not enough to assure that the amputee derives the maximum advantages which these techniques can afford. As Dr. Burgess states, the procedures are not technically difficult, but precision is essential. Though somewhat different techniques formerly used by the Seattle group or other methods employed by other groups in this country or abroad have achieved gratifying success, the refined procedures described in this book have been found to be highly effective if followed without deviation.

Participation in one of the training programs now offered at New York University, UCLA, and Northwestern University is recommended for clinicians who

wish to undertake these procedures. There must be an effective relationship among the several disciplines concerned with amputee rehabilitation; the contributions of trained prosthetists are particularly desirable. Finally, and perhaps of most importance, the responsibility of the surgeon cannot end with the skillful and meticulous amputation of a limb. He must follow the progress of his patient at least until optimum rehabilitation is achieved.

It is heartening that many groups, both in the Veterans Administration and in the medical community generally, have been successfully using immediate and early postsurgical prosthetic fitting techniques. The Committee on Prosthetics Research and Development, National Research Council, has been very helpful in facilitating the exchange of research and clinical information on this as well as many other prosthetics problems. The specialized courses at the three universities with prosthetics education programs have made it possible for clinicians to acquire systematic instruction in these procedures. This new publication should serve as a reference source in the same manner as did the April 1967 manual.

We know that a great amount of effort on the part of the Seattle Prosthetics Research Study went into the preparation of this book. Our sincere appreciation goes not only to Dr. Ernest M. Burgess, Dr. Robert L. Romano, Mr. Joseph H. Zettl, and their colleagues of the Prosthetics Research Study, but to the Director and his staff of the VA Hospital in Seattle.

ROBERT E. STEWART, D.D.S.

*Director*

Prosthetic and Sensory Aids Service  
Department of Medicine and Surgery  
Veterans Administration  
Washington, D.C.

## PREFACE

Widespread and growing interest in amputation surgery and substantial improvement in the Immediate Postsurgical Prosthetic Fitting technique prompt the preparation of a major revised manual less than two years after its first appearance. Reports from throughout the world now include an experience numbering several thousand cases. Although widely varying degrees of success are being recorded, the technique continues to gain rapid acceptance.

The additional knowledge gained from analysis of accumulating experience together with the greater understanding gleaned from the very high number of successful cases and indeed from the relatively few failures has stimulated the preparation of this new book. The many advantages of immediate postsurgical

prosthetic management in amputee rehabilitation justify the high hopes of its proponents.

The method is not technically difficult, but it is *precise*. The stakes to the amputee are high. It is necessary to understand and correctly apply each stage of care if the full potential for improved amputee rehabilitation is to be realized.

We have attempted to outline specifically each aspect of this care. Careful attention to detail will be rewarded by prompt and maximum restoration of function.

ERNEST M. BURGESS, M.D.



## ACKNOWLEDGMENTS

The authors would like to express their grateful appreciation to the following persons who have contributed significantly to the preparation and final production of this manual: Shirley M. Forsgren, Administrative Assistant; Robert D. Schrock, Jr., M.D., Fellow in Prosthetic Research; Connie E. Torget, Statistical Coordinator; and Marlyn Jake Gardner, Research Prosthetist, all from the Prosthetics Research Study in Seattle. Also, our appreciation for editorial work and printing preparation is extended to William M. Bernstock, Assistant Chief, and Rhoda Beiser, Writer-Editor of the Research and Development Division, Prosthetic and Sensory Aids Service, New York City. In addition, the contributions and efforts of Anthony Staros, Director; Dr. Edward Peizer, Chief, Bioengineering Research Service; William J. Romahn, Jr., Visual Aids Specialist; and Phillip S. Carson,

Scientific Illustrator, all from the VA Prosthetics Center in New York City, are gratefully acknowledged. Gratitude is also expressed to Joseph E. Traub, Consultant, Prosthetics and Orthotics, Social and Rehabilitation Service and to A. Bennett Wilson, Jr., Executive Director, Committee on Prosthetics Research and Development, for their previous contributions in the writing of "Immediate Postsurgical Prosthetics in the Management of Lower Extremity Amputees." Above all, the support and encouragement of Dr. Robert E. Stewart, Director, Prosthetic and Sensory Aids Service, have been a continuing source of inspiration.

E. M. Burgess  
R. L. Romano  
J. H. Zettl

## CONTENTS

	<i>Page</i>
<b>FOREWORD</b> , Dr. Robert E. Stewart .....	iii
<b>PREFACE</b> , Dr. Ernest M. Burgess .....	v
<b>ACKNOWLEDGMENTS</b> .....	vi
<b>CHAPTER 1 THE PRS MANAGEMENT OF AMPUTATIONS</b> .....	1
I. History and Rationale .....	1
A. Wound Healing .....	2
B. Ambulation .....	5
C. Surgical Technique and Level of Amputation .....	5
D. Psychological .....	5
II. General Principles .....	5
A. Level Determination .....	5
B. Surgery .....	7
C. Muscle Stabilization .....	7
D. Special Considerations .....	7
III. Preoperative Preparation of the Patient .....	12
<b>CHAPTER 2 THE BELOW-KNEE AMPUTATION</b> .....	13
I. Preoperative Instructions to the Prosthetist .....	13
II. Preoperative Preparations by the Prosthetist of Materials and Components .....	14
III. The Below-Knee Amputation Surgery .....	16
A. The Preparation .....	16
B. The Operative Plan .....	17
C. The Incision .....	17
D. The Amputation .....	17
E. The Posterior Muscle Flap .....	18
F. Myodesis or Myoplasty .....	18
G. The Skin Closure .....	18
IV. The Below-Knee Immediate Postsurgical Prosthesis .....	24
A. Application of Felt (or Polyurethane) Pressure Relief Pads .....	24
B. Application of the Rigid Dressing .....	27
C. Application of the Prosthetic Unit .....	33
D. Below-Knee Prosthetic Considerations .....	38

	<i>Page</i>
<b>CHAPTER 3 THE ABOVE-KNEE AND KNEE-DISARTICULATION AMPUTATIONS</b> .....	40
I. Preoperative Instructions to the Prosthetist.....	40
II. Preoperative Preparations by the Prosthetist of Materials and Components.....	40
III. The Above-Knee Amputation Surgery.....	45
IV. The Knee-Disarticulation Surgery.....	47
V. The Above-Knee and Knee-Disarticulation Immediate Post-surgical Prosthesis.....	48
A. Preparatory Requirements before Application of the Rigid Dressing.....	48
B. Application of the Rigid Dressing.....	52
C. Application of the Prosthetic Unit.....	63
D. The Knee-Disarticulation Immediate Postsurgical Prosthesis.....	70
E. Above-Knee and Knee-Disarticulation Prosthetic Considerations.....	71
<b>CHAPTER 4 THE SYME AMPUTATION</b> .....	74
I. Preoperative Instructions to the Prosthetist.....	74
II. Preoperative Preparations by the Prosthetist of Materials and Components.....	74
III. The Syme Amputation Surgery.....	75
IV. The Syme Immediate Postsurgical Prosthesis.....	76
A. Application of Felt (or Polyurethane) Pressure Relief Pads.....	76
B. Application of the Rigid Dressing.....	78
C. Application of the Prosthetic Unit.....	82
D. Syme Prosthetic Considerations.....	83
<b>CHAPTER 5 THE HIP-DISARTICULATION AMPUTATION</b> .....	85
I. Preoperative Instructions to the Prosthetist.....	85
II. Preoperative Preparations by the Prosthetist of Materials and Components.....	85
III. The Hip-Disarticulation Amputation Surgery.....	86
IV. The Hip-Disarticulation Immediate Postsurgical Prosthesis.....	87
A. Preparatory Requirements before Application of the Rigid Dressing.....	87
B. Application of the Rigid Dressing.....	89
C. Application of the Prosthetic Unit.....	92
D. Hip-Disarticulation Prosthetic Considerations.....	95
<b>CHAPTER 6 POSTOPERATIVE MANAGEMENT</b> .....	97
I. General Principles.....	97
II. The First 2 Weeks.....	98
A. The Day of Surgery.....	98
B. The First Postoperative Day.....	99

10  
0  
0  
0  
5  
7  
8  
8  
2  
3  
0  
1  
4  
4  
4  
5  
6  
6  
8  
2  
3  
5  
5  
5  
6  
7  
7  
9  
2  
5  
7  
7  
8  
8  
9

	<i>Page</i>
C. The Second Postoperative Day.....	99
D. Postoperative Days, 3 to 14.....	101
III. The Second 2 Weeks.....	101
IV. The First Year.....	109
V. Static Alignment of the Immediate Postsurgical Prosthesis.....	110
VI. Dynamic Alignment of the Immediate Postsurgical Prosthesis....	114
VII. Postoperative Complications.....	114
<b>CONCLUSIONS</b> .....	118
<b>REFERENCES</b> .....	119
<b>APPENDIXES</b> .....	120
A. Alignment Diagrams for Immediate Postsurgical Protheses.....	120
B. Sources of Supply of Materials and Components.....	122



## CHAPTER 1

# The PRS Management of Amputations

### I. HISTORY AND RATIONALE

It has long been recognized that mature wound healing in a lower-extremity amputation is not a prerequisite to fitting of a prosthetic device. For many years the early application of a temporary or interim prosthesis has been used to observe prosthetic tolerance in patients with questionable systemic competence or local stump health. Often inadequate, these trial limbs have not accomplished the intended purpose.

The concept of fitting patients with prostheses *immediately* after surgery and initiating ambulation training the following day or two originated with Berlemont in the late fifties. Berlemont's procedure was modified by Weiss (18) who discussed it at a lecture given at the Sixth International Prosthetics Course in Copenhagen in July 1963. A visit by Weiss to the United States later that year stimulated interest at the University of California Medical School, San Francisco, and at the U.S. Naval Hospital, Oakland, California. Promising results obtained at these institutions prompted the Veterans Administration's Prosthetic and Sensory Aids Service to support an experimental program proposed by the Prosthetics Research Study (PRS) in Seattle, Washington. This research study has now been enlarged to include additional Veterans Administration Centers.

This manual is based on the PRS experience dating from May 1964 now totaling 280 unselected closed lower-extremity amputations fitted with immediate prostheses at the completion of surgery (Fig. 1, 2, 3, and 4). An additional number of open amputations and several upper-extremity patients have been similarly treated. The reasons for surgery and the age of the patients are shown in Table 1.

Early in our study it became evident that immediate postsurgical prosthetic fitting involved more than a single technical addition to our then current amputation-prosthetic management. A *total system* of amputee

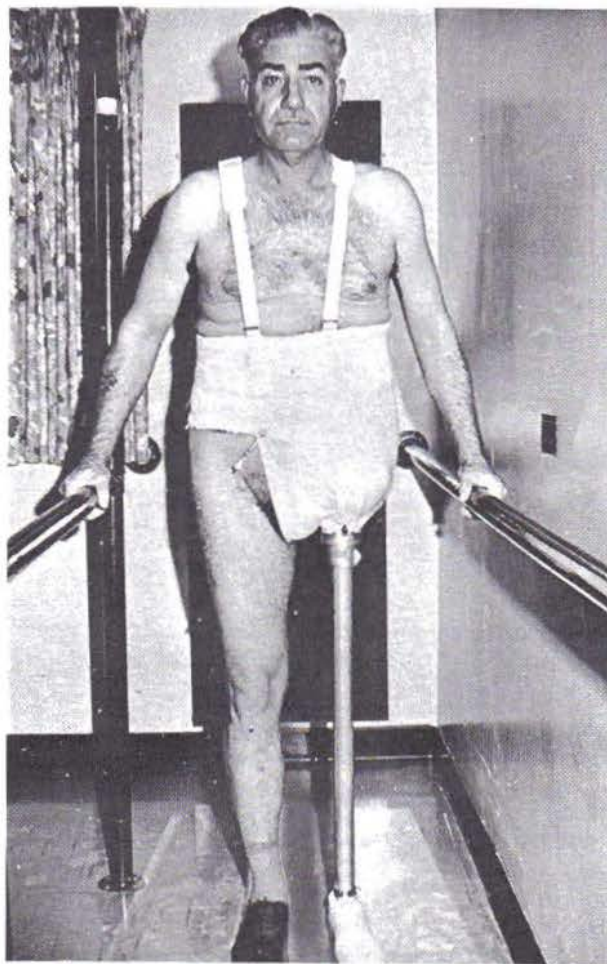

FIGURE 1.—Immediate postsurgical prosthesis for the hip-disarticulation amputation.

care has developed beginning with preoperative evaluation and continuing through definitive limb fit. The concept and rationale of this radical departure from conventional management fall into the following four



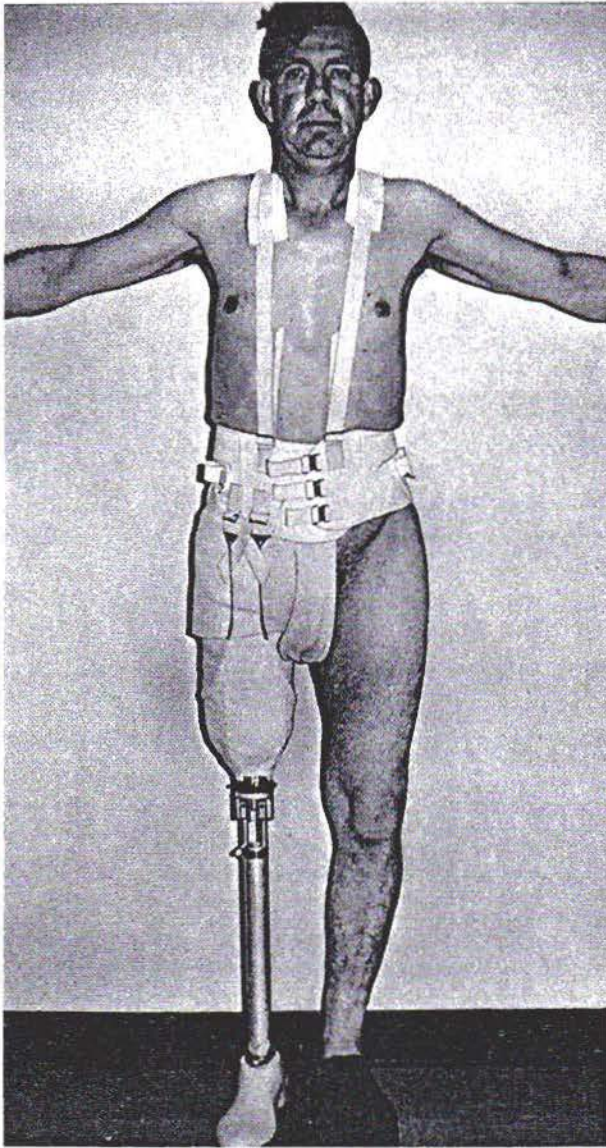


FIGURE 2.—Immediate postsurgical prosthesis for the above-knee amputation.

general categories: A. Wound Healing, B. Ambulation, C. Surgical Technique and Level of Amputation, and D. Psychological.

#### A. WOUND HEALING

By definition an amputation transects all extremity tissues; the wound is therefore terminal. This circumstance permits total emphasis on the local nature of wound healing. Since no tissue exists distal to the

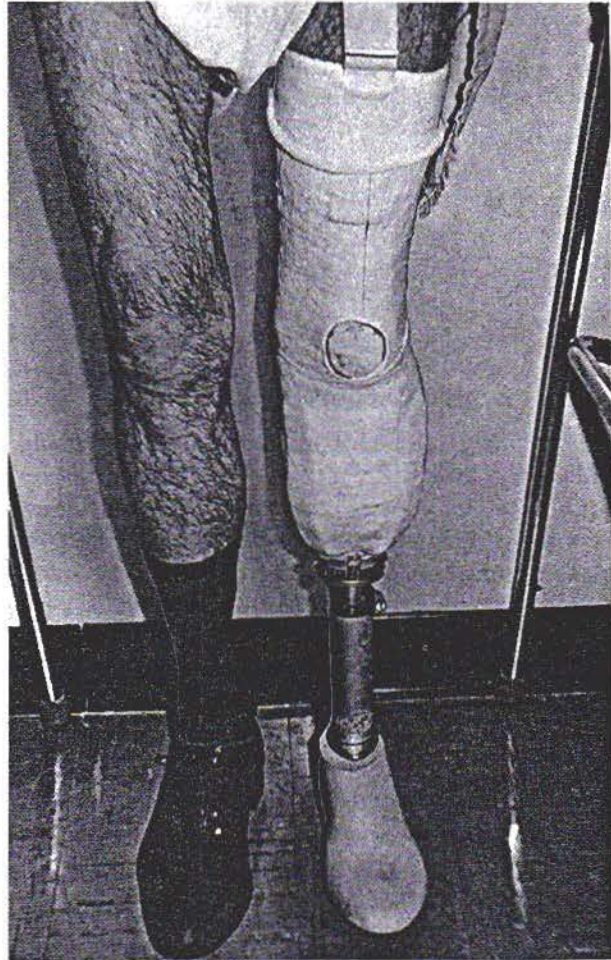


FIGURE 3.—Immediate postsurgical prosthesis for the below-knee amputation.

amputation, the site of surgery thus becomes a unique and ideal clinical laboratory for investigation of the wound healing process. With constricting forces avoided proximally, the amputation site can be subjected to those optimum pressure gradients which will control edema, support circulation, and minimize inflammatory reaction. This pressure can be intermittent or constant. It can vary in degree relative to time. When intermittent pressures are used, they can be varied in both intensity and time frequency.

A rigid postsurgical dressing, i.e., prosthetic socket applied to avoid proximal constriction and fixed in its relationship to the stump, permits controlled pressure. Interface materials with compression and/or displacement qualities, including fluids and gases, allow measurable pressure variations. Transducers placed



TABLE 1.—Distribution of Cases by Age and Etiology

Age group in years	Vascular with diabetes	Vascular without diabetes	Infection	Sarcoma	Trauma and post-trauma complications	Congenital	Other	Total
1-12.....	0	0	0	2	5	11	0	18
13-24.....	0	2	1	8	14	3	0	28
25-50.....	7	12	16	3	33	2	0	73
51-75.....	58	47	15	2	18	0	2	142
76-100.....	9	10	0	0	0	0	0	19
Total.....	74	71	32	15	70	16	2	280

within the initial socket can record pressure readings under varying circumstances of limb position, time, and in special circumstances such as isometric stump muscle activity and during ambulation with partial weight bearing (Fig. 5, 6, and 7).

The rigid dressing provides tissue rest and increases comfort. With appropriate terminal pressure and good local tissue immobilization the amputee can move about freely and comfortably in bed, in the chair, and in assisted standing and walking. Nursing care is simplified particularly in the older patients. Fear of pain on movement is minimized. Active exercises of the operated extremity further encourage fluid exchange and improved nutrition. Local and systemic postoperative complications are minimized.

Maturation of the amputation stump with favorable stump shaping is influenced by the rigid immediate postsurgical prosthesis (Fig. 8, 9, and 10). Here again local pressure relationships are significant. Ultimately

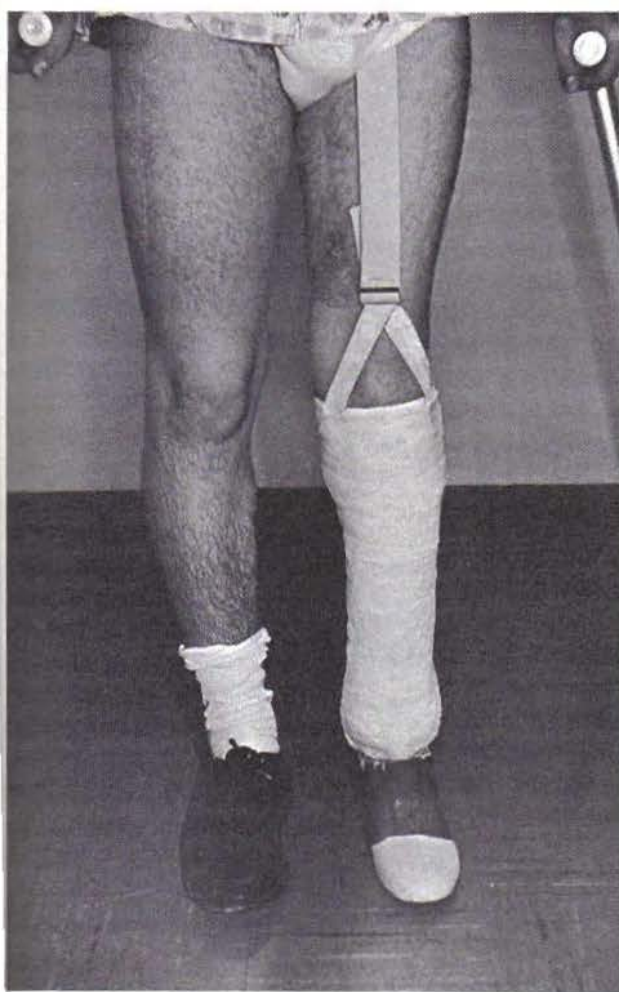

FIGURE 4.—Immediate postsurgical prosthesis for the Syme amputation.

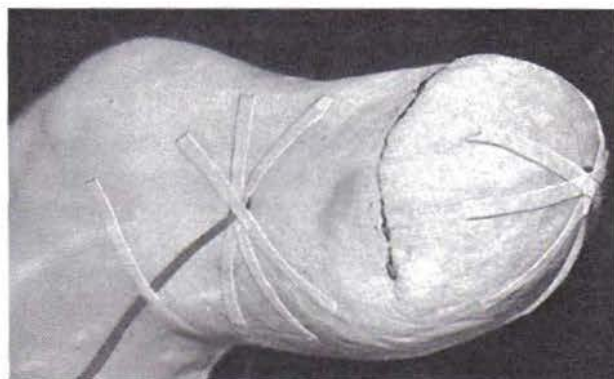

FIGURE 5.—Pressure transducers on a fresh below-knee amputation stump.



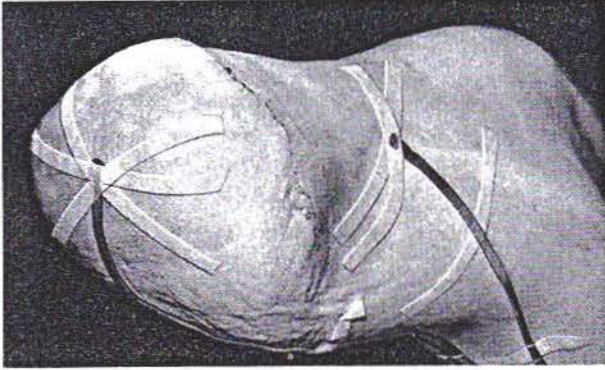


FIGURE 6.—Same as Figure 5.




FIGURE 7.—Biomechanical unit for recording pressure and electrical muscle potential following amputation and immediate postsurgical prosthetic fitting.

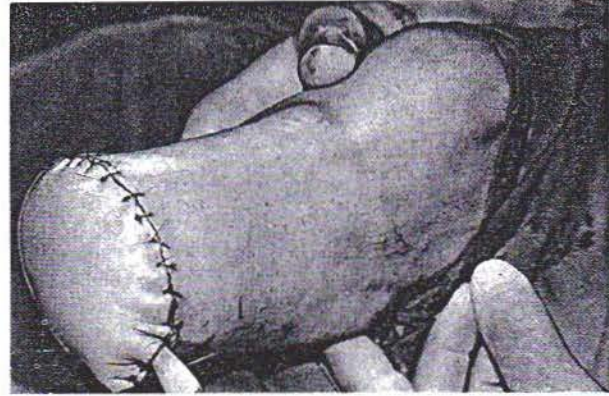


FIGURE 8.—Appearance of PRS below-knee stump at the time of wound closure.

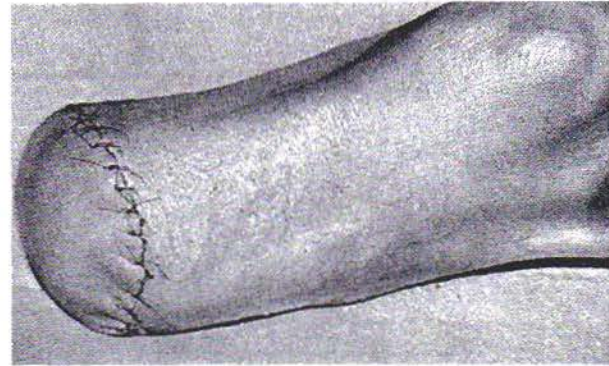


FIGURE 9.—Same patient as in Figure 7, 11th postoperative day, at initial cast change.

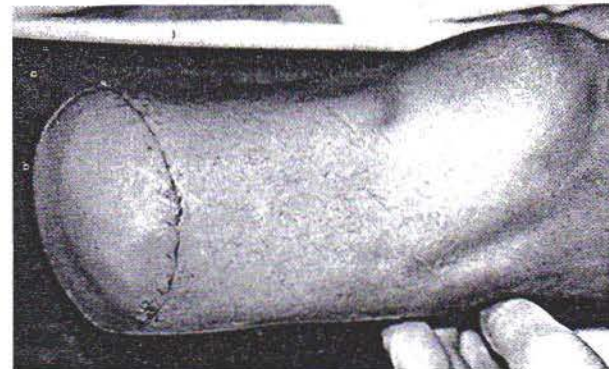

FIGURE 10.—Appearance of stump, 18th postoperative day, at second cast change.



stump shape and size are accomplished by a variety of forces and tissue responses. High in importance among these forces is the pressure applied by the total-contact definitive limb. These pressures when applied immediately postoperatively and continuing uninterrupted throughout the early weeks of healing hasten stump maturity, shaping, and eventual stump stability.

## B. AMBULATION

The immediate postsurgical prosthesis permits early upright bipedal stance and gait. Awareness of pressure and tension forces through the prosthesis to the body, specifically the remaining portion of the extremity encased in the rigid initial socket, allows for continuity in proprioception. Both the actual and visually recorded loss of the extremity are muted by the patient's ability to stand on his "leg." One-leggedness is thus to some degree circumvented. As with wound healing, the fresh amputation stump presents a fertile laboratory for neuro-physiological investigation. All of the complex mechanisms of awareness in space, of position and movement, of afferent "feed-in" derived from the pressures and tensions in the musculo-skeletal system are laid bare to analysis when by amputation a large sensory and motor organ has been suddenly ablated. No other neuromuscular disability, even total denervation of an extremity, can be likened to an amputation. In all other circumstances the limb is still "there." Even though functionless the patient may see it and feel it with other parts of his body.

As to ambulation, the amount of weight permitted through the early days of wound healing must be individualized depending on many patient-surgical factors to be outlined later in this manual. The basic concept, however, of early or immediate postsurgical stance with supported gait when possible, seems a reasonable thesis from the standpoint of total patient rehabilitation.

## C. SURGICAL TECHNIQUE AND LEVEL OF AMPUTATION

In an era of unparalleled surgical progress, amputations have been to a large measure neglected. Surgeons can take little credit for the improved rehabilitation of the amputee. Spectacular improvements in prosthetics together with attentive postsurgical therapy are largely responsible for upgraded amputee care. Immediate postsurgical fitting has forcibly brought to the attention

of the surgeon the need for thoughtful planning and precise technique. Reconstruction and rehabilitation become an intrinsic part of the operative technique.

The vital necessity of knee salvage whenever possible; the advantages to both the patient and the prosthetist in the surgical creation of a "dynamic" stump; the need for plastic management of the tissues, particularly the skin; the importance of proper mechanical preparation of the bone; the stabilization of transected muscles and treatment of sectioned nerves; all of these surgical considerations become urgent when the surgeon is involved in the immediate fitting of a prosthetic device. The kindling of surgical interest in this statistically important area goes hand in hand with immediate postsurgical fitting management. This is further translated to greater interest in limb substitutes on the part of the surgeon, an area of vast ignorance among many who perform the amputation. Under this plan of treatment, amputation surgery becomes plastic surgery as well as reconstructive surgery. If only a small portion of the interest and energy being devoted to *limb salvage* in the ischemic extremity will be directed to amputation, spectacular surgical advances in this field can be anticipated.

## D. PSYCHOLOGICAL

Intangible but definite psychological benefits should result from immediate postsurgical prosthetic fitting with ambulation. Prior to surgery in elective amputations, the patient can be told that he will be "up the next day or so and on his feet." A hopeful rather than negative approach to surgery is thus accomplished. Most elective surgery connotes a state of improved physical well being. The totally destructive nature of an amputation confronts the patient with irreparable psychological disaster in many instances. This is particularly noted among older people who, looking at their few remaining years, are concerned acutely about helplessness and dependency. The rapid transition from limb loss to function bespeaks hope. This motivation can make the difference between effective rehabilitation and failure.

# II. GENERAL PRINCIPLES

## A. LEVEL DETERMINATION

Amputation surgery in the lower extremity is performed in the Western world for four major reasons:

ischemia, revision of congenital deformities, trauma, and to ablate tumor. Level selection in the last three groups is not usually difficult. Here length is preserved to the nearest level compatible with restoration of function through prosthetic fitting and rehabilitation. Generally speaking these major levels are Syme amputation, the below-knee amputation, knee disarticulation, long above-knee amputation, short above-knee amputation, hip disarticulation, and hemipelvectomy. The decision as to level is made on the basis of skin viability (as in trauma), or the proximity of tumor, or other well-defined criteria. The problem of level selection is usually not encountered in these three groups.

In the first category, i.e., peripheral vascular disease, there are no well-defined criteria for level selection. This group makes up the vast majority (an estimated 80 percent) of amputations which are performed in the lower extremity, yet few surgeons have firm convictions as to amputation level selection and there is considerable disagreement in the surgical literature as to adequate criteria for determining amputation level. Significant improvements in below-knee prostheses and advances in surgical and postsurgical management now allow amputation below the knee in a majority of these patients. In a consecutive series of 126 unselected *major* lower-extremity amputations for peripheral vascular disease—May 1964 through May 1969—we have been able to obtain primary healing at below-knee level in 86 percent. Once healed, the stumps remain healed. With adequate prosthetic care, secondary breakdown will seldom occur. It is difficult to overestimate the great importance of the knee in amputee rehabilitation. Especially is this true in the older, classical, ischemic patient. Debility, weakness, impaired vision, poor balance, neuropathy, compromised circulation and function in the remaining lower limb, and chronic systemic illness all emphasize the critical need to save the knee. The older bilateral-leg amputee especially needs his knees to approach the rehabilitation goal permitting a reasonable degree of ambulation and self-sufficiency. When coupled with below-knee amputations for conditions other than ischemia this amputation thus becomes statistically *by far* the most important major elective technique.

There is no single test or combination of tests now available that will specifically demonstrate the lowest effective amputation level in the ischemic limb. We have repeatedly obtained successful below-knee amputations in patients whose arteriograms indicated com-

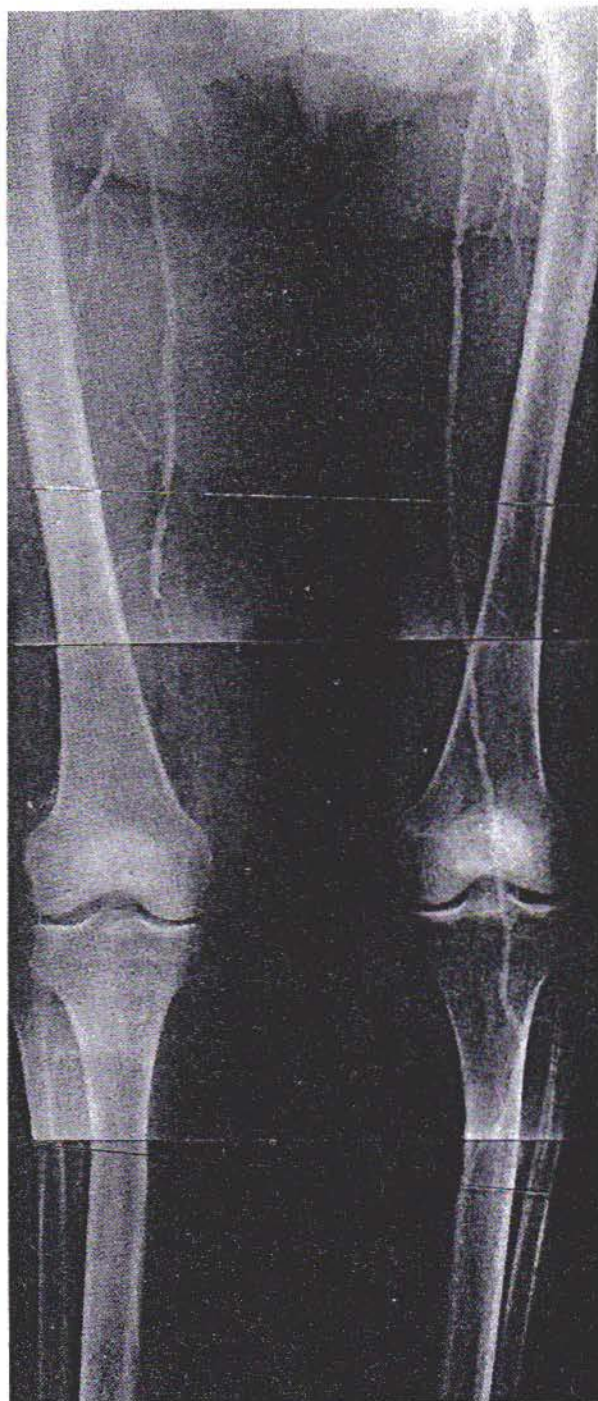

FIGURE 11.—Arteriogram in 73-year-old female with peripheral vascular disease. Two failed femoral popliteal arterial bypass grafts 3 weeks preceding development of gangrene, demarcating at lower third of leg.

Fig  
2  
c

ple  
11

in  
say  
ed  
an  
im  
lak  
the  
mi  
int  
#  
ad  
de

tal  
rec  
th  
qu  
be  
th  
su  
tis  
fir  
a  
or

B.

ce  
H  
ni



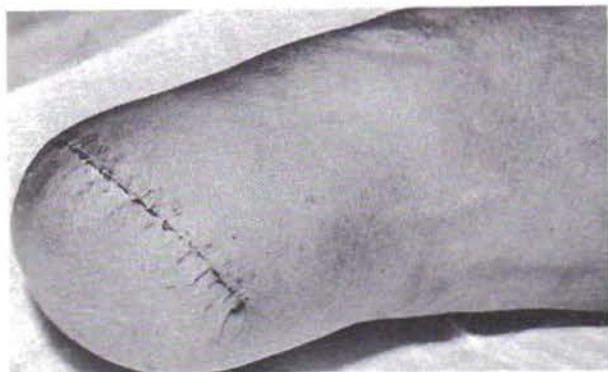

FIGURE 12.—Healed below-knee amputation, same patient as in Figure 11, on 29th postoperative day, at time of fitting definitive prosthesis.

plete occlusion of the superficial femoral artery (Fig. 11 and 12).

A careful physical examination is the first requisite in level determination. Tissue appearance, clinical assay of skin temperature, the presence or absence of edema after elevation, growth of hair, sensation level and acuity, together with palpation of pulses are all important and *cannot* at present be supplanted by laboratory data. Arteriography, plethysmography, thermography, and a number of other objective determinants are useful. These include skin mapping with intra-arterial fluorescein, the use of radioactive xenon #133, and transcutaneous Doppler recordings. Each adds to the available information and assists in level determination.

Old established guidelines for determining amputation level are not valid when weighed against our recent experience. Unless it is *clearly evident* that a through-knee or above-knee amputation will be required, the surgeon should prepare the leg for both below-knee and above-knee amputation. Incisions through the skin and muscle preparatory to below-knee surgery can then be quickly carried out. Bleeding and tissue viability can now be visualized directly and the final decision made as to the level of amputation. Only a few minutes are added to the operative time should one elect a higher amputation.

## B. SURGERY

An immediate postsurgical prosthesis can be successfully applied following conventional amputations. However, practically every aspect of surgical technique is now being reappraised in light of the imme-

diate postsurgical prosthesis concept. This recent interest has brought forth many significant departures from generally accepted surgical practice. Research continues in regard to levels of amputation, skin management, the stabilization of sectioned muscles, and nerve and bone treatment. The surgical modifications from conventional technique which have proven useful are included in subsequent chapters.

## C. MUSCLE STABILIZATION

It is our policy to stabilize surgically major transected muscle groups by suture to bone (myodesis) or to each other (myoplasty) or by combining both techniques. The advantages of muscle stabilization are many. These include:

1. A more appropriate stump contour and shape, i.e., a cylindrical rather than a conical or tapered stump; one which functions as a more physiological end-organ in the modern total-contact prosthetic socket.

2. Improved circulation both to the muscle itself and to the superficial tissues including the skin. This improvement in circulation associated with adequate muscle activity in the stump has been repeatedly recorded by objective measures.

3. Muscle stabilization under appropriate tension tends to retain more effectively the neuromuscular physiological unit. Intra-fusal neuromuscular activity is specifically effected. The relationship of this surgical restoration of effective afferentation through the stretch reflex and the muscle servo makes for improved proprioception in the stump end-organ.

Less well understood but clinically substantiated benefits associated with muscle stabilization are a reduction of both painful phantom sensations and painful contractions of stump muscles during stance and gait.

Contraindications to muscle stabilization both in upper- and lower-extremity amputations include infection in and about the site of amputation, severely ischemic muscle, and other circumstances which would mitigate against primary healing. Recommended techniques in muscle stabilization will be described under the chapters on specific amputations.

## D. SPECIAL CONSIDERATIONS

### 1. CHILDREN AND ADOLESCENTS

The experience of the Seattle group with 31 children



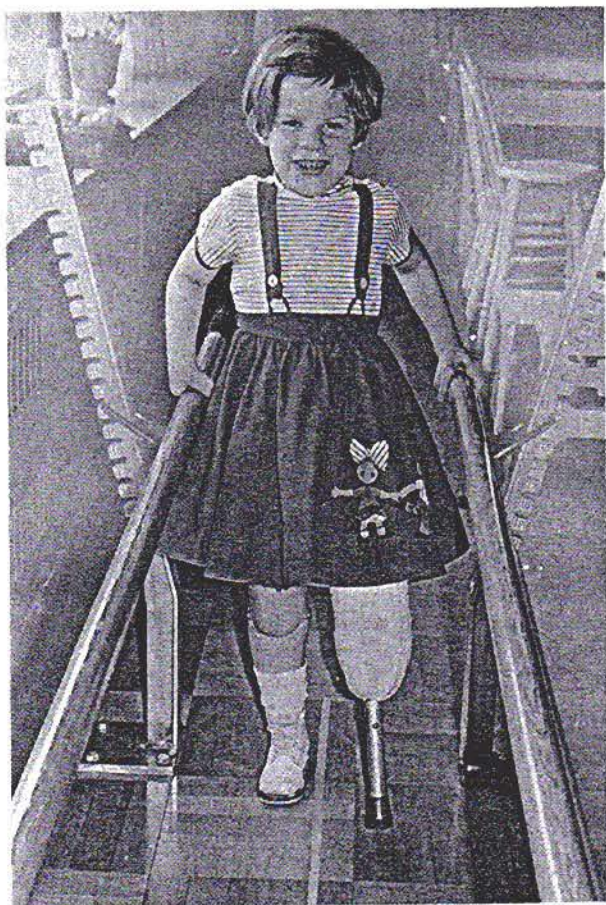

FIGURE 13.—Immediate postsurgical prosthesis in knee disarticulation for congenital anomalies. Although shown, substitution of a crutch tip for a prosthetic foot is not recommended.

and adolescents using immediate postsurgical techniques indicates the effectiveness of this management in the younger age groups. We consider it the unquestionable method of choice for the growing individual.

*Children from 1 to 5 Years of Age:* The majority of amputations in the preschool child are for the correction of congenital deformities, burns, tumor, or trauma. As has been pointed out by Aitken (1) in his concise writings on amputation levels in children, epiphyses should be preserved and maximum length retained. In effect then, most amputations are preferably through or immediately adjacent to joints. In general, these children heal rapidly with conventional management, definitive limbs can be fitted promptly, and gait patterns can be developed naturally if adequate prostheses are provided.

Immediate postsurgical prosthetic fitting is less critical for these young children than for older patients. Its specific values for juveniles lie in the immediate postsurgical degree of comfort it offers; the ease and convenience of management, since no dressings are required prior to removal of the initial cast; and the small amount of postoperative nursing care necessary. In our experience these children feel very little pain and ambulate promptly, often without support. Under normal circumstances one can anticipate rapid healing, prompt maturation of the stump, and early definitive limb fit (Fig. 13).

An interesting observation made both by ourselves and others is the occasional unawareness of limb loss on the child's part until the cast and dressings are removed and he can actually see that part of his ex-

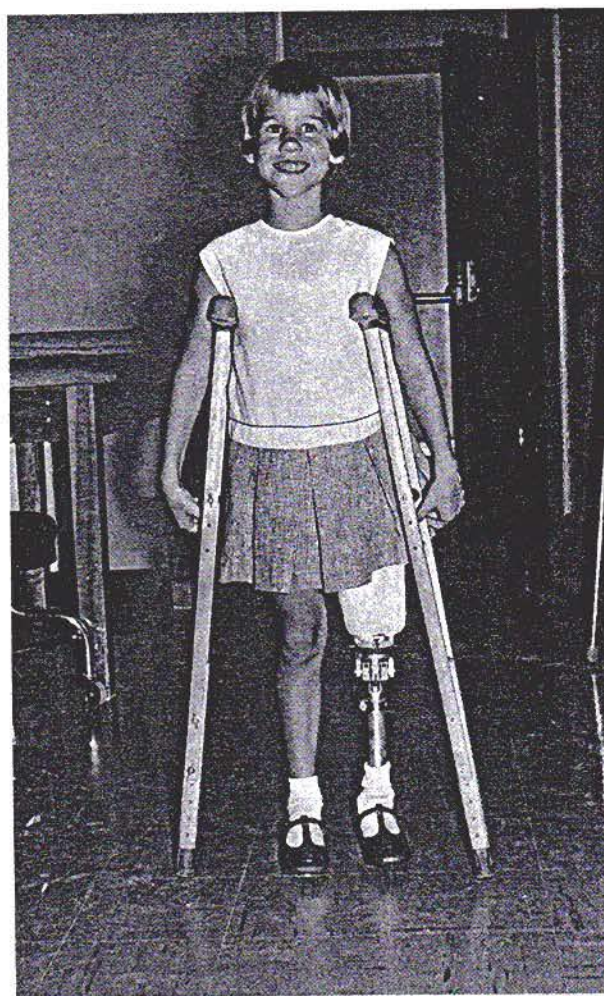

FIGURE 14.—Immediate postsurgical prosthesis in knee disarticulation for congenital anomalies.

FIG

tre  
tio  
lig  
cayo  
ha  
su  
an  
pr  
m:  
scl  
pli  
pa  
th  
ca





FIGURE 15.—Hip disarticulation for osteogenic sarcoma of proximal femur.

limbity has been amputated. Hence, fairly heavy sedation, basal anesthesia, or, in unusual circumstances, a light anesthetic may be advisable at the time of initial cast change, 10 to 14 days after surgery.

*Children from 6 to 14 Years of Age:* As with younger children, the preadolescent child amputee has responded remarkably well to immediate postsurgical prosthetic fitting (Fig. 14). Postoperative pain and apprehension are slight, activity levels are resumed promptly with the temporary limb, stump healing and maturation proceed uneventfully, and time loss from school and home is minimal. Cast changes are accomplished with analgesics only, and usually on an outpatient basis. The child, and even more specifically the family, seem to benefit psychologically from the early resumption of ambulation and recovery of activi-

ties. We have encountered no real problems in gait following conversion from the temporary to the definitive limb.

*Children from 14 to 21 Years of Age:* Immediate postsurgical prosthetic fitting has perhaps its greatest application to the adolescent amputee. Limb loss in this age group generally results from trauma or neoplasm. The catastrophic effect of such loss on both the patient and his family is softened by the relative comfort and immediate mobility provided by the technique.

In the case of malignant neoplasm, no lingering doubt remains in the youth's mind as to whether or not he is going to be fitted with a limb or will have to wait "to see how things come out." His limb is fitted upon completion of surgery, and his rehabilitation begins at once.

The difficult questioning days following amputation for osteogenic sarcoma are made easier when the patient is up and about walking, wearing a limb, and planning for the future (Fig. 15). Some of the teenagers in this program have been back participating in sports a few weeks after an above-knee amputation for malignancy. Even though life expectancy may be but a question of months, these postamputation days are easier with an artificial limb and attendant rapid progression to tolerated activity levels.

As with other reconstructive surgery in children, an amputation must anticipate growth and adult life. Expected growth must be calculated as accurately, for example, as in surgery for unequal leg length. A strong, stable stump must be achieved if normal activity levels are to be approached. In our experience, muscle stabilization in the young amputee (myoplasty and/or myodesis) is particularly effective in retaining dynamic muscle function. Proprioception seems to be enhanced when stump muscles are active under physiological tension. Scientific documentation of this clinical observation is not yet fully established (Fig. 16). Nevertheless, clinical evaluation substantiates, particularly in the growing individual, the proprioceptive value of stump muscle activity.

Tibiofibular stabilization in the below-knee amputee is also of particular value in the young person. While tibiofibular synostosis is not applicable to all children requiring below-knee amputations, its use under appropriate circumstances will increase the stability, strength, and weight tolerance of the stump. In our series, tibiofibular synostosis has been performed in three cases where amputation was carried out through





FIGURE 16.—Instrumented pylon for measuring knee moments, used in conjunction with myographic and pressure recordings.

the diaphyses of the long bones. We have not yet precisely defined the preferred surgical technique, but at this time suggest side transfer of the distal fibula into the distal tibia rather than bone graft bridge or periosteal sleeve.

## 2. TIBIOFIBULAR SYNOSTOSIS

When the tibia and fibula can be joined by bone growth in below-knee amputation, a stronger stump is produced. In the older amputee this is of academic value only since most of these patients are not called upon to do prolonged standing, walking, or heavy use involving the lower extremities. We have encountered no difficulty with pain nor bursa formation over the fibula when it has been amputated at the appropriate level in relation to the tibia. In children and young adults when surgical circumstances permit and local circulation is adequate, a synostosis between the tibia and fibula using either the osteoperiosteal sleeve (Murdoch technique) or side transplantation of the distal tibia into the fibula. Care must be taken to avoid bone projections and irregularity of the contour of the stump resulting from an attempt to obtain a synostosis.

## 3. SURGICAL IMPLANTS

Through the work of Swanson and others (17) there has been considerable recent interest in inert surgical implants in the form of intramedullary plugs designed to provide a more effective end-bearing stump. The amount of foreign material required is quite extensive but progress in the implant surgical field is great and some implant techniques may become standard in the near future. At this time we consider surgical implants primarily in the experimental stage of development.

## 4. OPEN AMPUTATIONS

A number of open amputations have been treated by the immediate postsurgical prosthetic management. Skin flaps are left long conserving all viable skin and soft tissues rather than perform the classical circular guillotine amputation. The terminal wound is packed open lightly and the rigid dressing is applied. The patient may be permitted ambulation with the initial prosthesis but weight bearing is restricted by the nature of the open wound. Secondary closure and/or revision-reamputation may be carried out at the appropriate time and changes of rigid dressing planned accordingly (Fig. 17, 18, and 19). The beneficial effects of compression, immobilization, and gentle pressure stimulate early healing in open amputation management of this type. When skin flaps are short

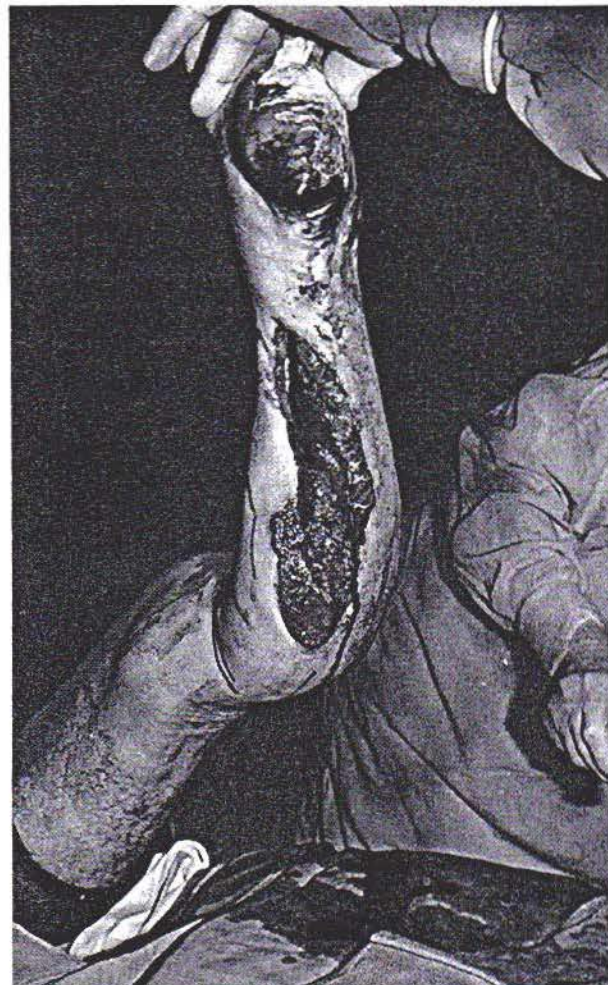


FIGURE 17.—Compound fractures, complicated by gas gangrene requiring amputation due to ischemia of foot.



FIGURE 18  
a  
P

follow  
essa  
tair  
gic  
req  
A  
imr  
inf  
ion  
sub  
pat  
the  
det  
tra  
tair  
is n



FIGURE 19  
a  
st  
w  
P



## 5. UPPER EXTREMITY

The upper extremity can effectively accept an immediate postsurgical prosthetic dressing fitted with a functional terminal unit. We have fitted a number of cases, both below-elbow and above-elbow types. While its application to the upper extremity is limited, in bilateral lesions and occasionally in the unilateral case one can find this technique most advantageous both from the standpoint of stump contour, infection control, and early rehabilitation (Fig. 20).

FIGURE 20.—Immediate postsurgical prosthesis fitted to below-elbow amputation for trauma. Appearance on 13th postoperative day.

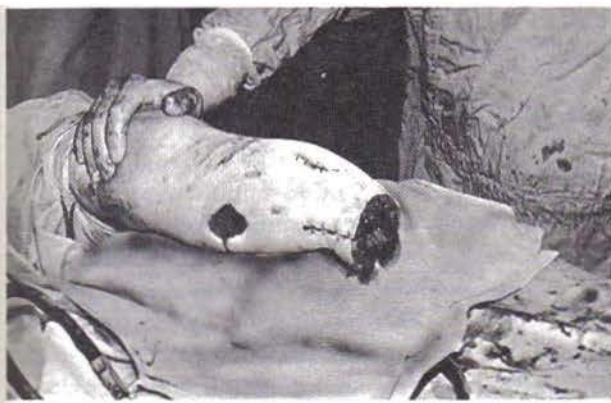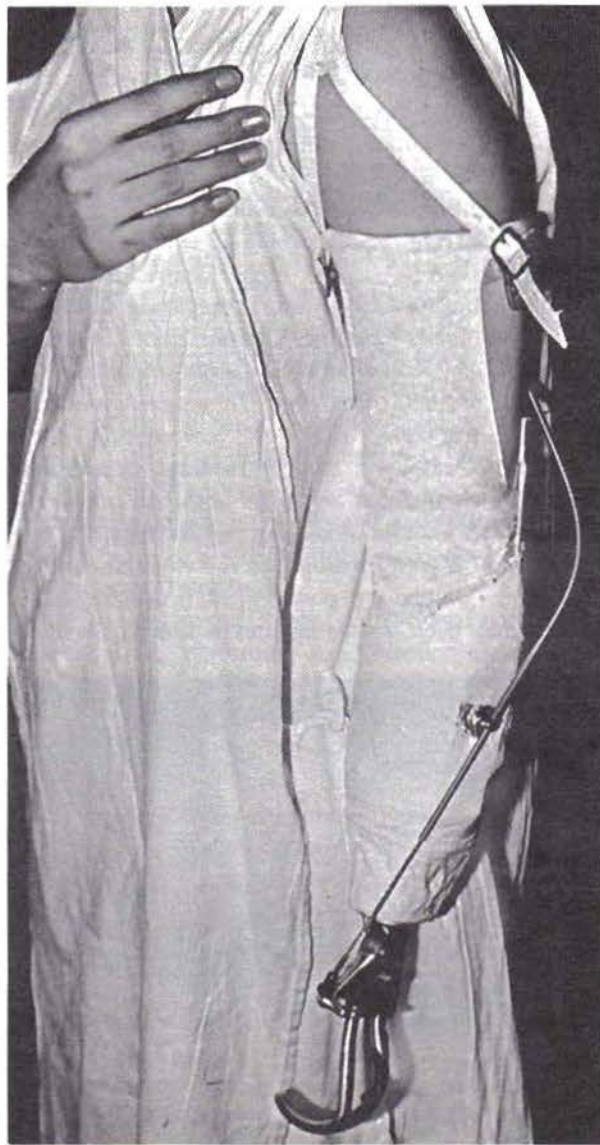


FIGURE 18.—Same patient as in Figure 17 following open amputation with long skin flap and immediate postsurgical prosthesis.

following guillotine or open amputation, it may be necessary in an occasional case to resort to traction to obtain maximum stump length. The immediate postsurgical system of management is not applicable to cases requiring continuous skin traction.

A number of military hospitals have been using immediate postsurgical prostheses after revision of open infected amputations. Skin and soft tissues are fashioned in a manner to allow closure by secondary intent, subsequent revision, or delayed primary closure. The patient is ambulated with minimal weight bearing and the immediate postoperative management will be determined by the nature of the amputation. If skin traction is necessary to prevent retraction and maintain a desired stump length the immediate prosthesis is not applicable.

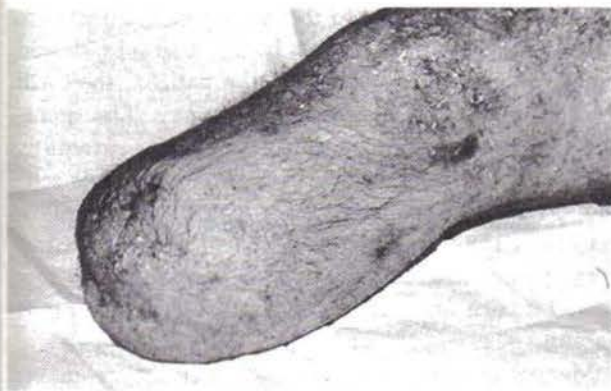

FIGURE 19.—Same patient as in Figures 17 and 18. Appearance of stump 7 weeks following initial amputation with subsequent secondary closure. Continuous wound support with immediate postsurgical management. Definitive prosthesis on 50th postoperative day.



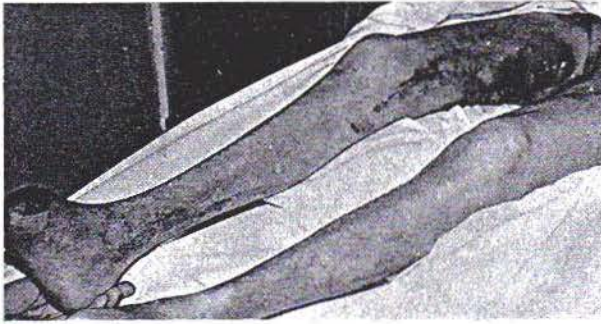

FIGURE 21.—Failed vascular reconstructive surgery, transmetatarsal amputation with gangrene on 73-year-old female.

### 6. FAILED VASCULAR SURGERY

Forty-five lower-extremity amputations have been performed in patients with ischemia who have had previous vascular reconstruction surgery. In some instances the vascular reconstruction has permitted amputation at a lower level than would otherwise have been anticipated. More often, the failed reconstruction has resulted in proximal extension of the ischemia (gangrene) and a higher amputation level. The Prosthetics Research Study is preparing a detailed analysis of lower-extremity amputations following failed vascular reconstruction. It is not appropriate to include all of these data here. In general, however, the same principles regarding amputation level, amputation technique, and immediate postsurgical prosthetic management apply as with the nonreconstructive case. Skin incisions may require variation due to previously placed incisions for the vascular surgical procedures. Immediate postsurgical prosthetic management has been gratifying and is specifically indi-

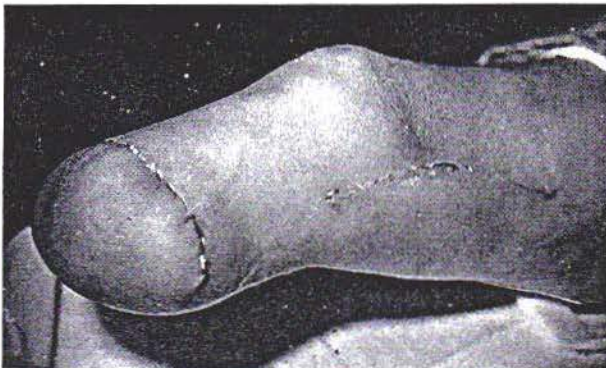


FIGURE 22.—Same patient as in Figure 21, 38 days following below-knee amputation, at the time of fitting definitive prosthesis.

cated in amputations for failed vascular reconstruction (Fig. 21 and 22).

### III. PREOPERATIVE PREPARATION OF THE PATIENT

The patient is brought to optimum preoperative metabolic status without undue delay which could compromise the amputation level. Sepsis, when present, is controlled by adequate open drainage and antibiotic therapy. Refrigeration of the extremity is avoided. We believe it can devitalize tissue proximally and may necessitate amputation at a higher level.

Hexachlorophene soap skin cleansing is begun three or more days prior to surgery, if possible. When "prophylactic" antibiotics are to be given to a patient who is not septic but in whom a focus of infection is present, they are preferably started prior to surgery according to modern concepts of prophylaxis.

The patient is psychologically prepared for a hopeful postoperative course. A visit preoperatively by an amputee who has made a successful transition to an active life can be useful. This is especially important in children and adolescents. Care is taken, however, not to give the impression that rehabilitation will be easy and effortless. Patient cooperation and motivation are essential to success.

The responsibility of the physical therapist begins prior to surgery and quickly becomes central to the success of the patient's rehabilitation. Once the patient is able to stand on the initial prosthesis, the therapist will supervise progressive daily rehabilitation. Alertness on the part of the therapist and a willingness to communicate observations to the surgeon and to the prosthetist are essential to the success of the program.

When possible preoperatively, the therapist should begin to know and understand the patient; they will be working closely together after surgery. The therapist must work to bring the patient's upper extremity, back, and hip strength to a level which will allow self-support during the postoperative ambulation. This may be a challenging problem when the patient has been restricted to bed for several weeks prior to surgery. Practice on crutches and in the parallel bars is helpful.

Maximum range of joint motion must be maintained. The prevention of hip flexion and adduction contractures in the above-knee amputee and of hip and knee flexion contractures in the below-knee amputee is essential for a satisfactory gait pattern with a prosthesis.

CH  
TI

1  
all  
tim

tior

wh  
bea

2

int  
app  
Exj  
dia  
the  
tra  
enc

tha  
teri  
at

stu  
cia  
poi  
the  
of  
dre  
ess  
me  
tio



## CHAPTER 2

# The Below-Knee Amputation

### I. PREOPERATIVE INSTRUCTIONS TO THE PROSTHETIST

1. When notified by the surgeon, obtain from him all necessary information required and available at this time.

- a. Side of amputation.
- b. Proposed level of amputation if this information is available.
- c. Any additional physical defects of the patient which might restrict or limit movement and/or weight bearing and ambulation activities.
- d. Any existing or permanent flexion contractures.

2. Talk to the patient, explain your role, what you intend to do, and what is expected of him. He may be apprehensive and anxious; don't make him more so. Explain the advantages to be derived from an immediate postsurgical prosthesis and from well-fitting prostheses, generally.

3. Consider any physical defect and/or flexion contractures noted by the surgeon which would influence casting and/or alignment of the prosthetic unit.

4. Take measurements for suspension waist belt.

5. Note approximate size of reticulated polyurethane distal pad required (3, 4, 5, or 6 in.). This interface material must be sterilized before application at surgery.

The pressure developed on the soft tissues of the stump by the rigid dressing clearly has been beneficial to wound healing and stump maturation. The supporting evidence is present in the clinical results of the PRS. In addition, direct laboratory measurements of the pressure developed between stump and rigid dressing show it to be within physiologic range. In essence, the rigid dressing markedly limits the development of postsurgical edema, thus improving circulation and promoting wound healing.

Some means of distributing pressures over the end

of the stump during weight bearing is required. From the beginning of this study an ideal interface material for use between stump and socket was sought. It should be compressible, unaffected by fluids draining through from the wound, nonirritant to skin and able to be sterilized.

Fluffed gauze, lambs wool, Stryker gel, foam rubber, various grades of steel and brass wools, and RTV (room-temperature vulcanized silicone rubber) perforated foam pads were used and evaluated clinically. All of these materials, while reasonably effective when properly applied, failed to meet our specifications. Some retained fluids, some became hard and incompressible, others created heat and were nonabsorbent, and some were irritating to the skin during ambulation.

At present the most suitable material is the preformed, reticulated polyurethane distal pad, 20 pores per inch. This material permits fluids to pass through freely while retaining its original elasticity for an unlimited time. It is nonirritating, inexpensive, and can be steam or gas sterilized.

6. Note approximate size of Orlon Lycra stump sock required. The stump sock selection chart (Table 2) represents standard sizes which have been specifically designed and developed for immediate postsurgical prosthetic fitting. These sizes are sufficient for all applications. If a special size should be required, it can be ordered from the manufacturer by giving specific details, then allowing a reasonable amount of time for knitting and delivery.

The physical characteristics of the material are:

- Three-ply weight
- Orlon acrylic 95.25 percent
- Lycra Spandex 4.75 percent
- Modified box toe
- Fleecy, both inside and outside

Packaging: Each stump sock is pre-rolled for correct application and enclosed in a sealed polyethylene bag.

TABLE 2.—Orlon Lycra Stump Sock Selection Chart

Stump sock	Stump size	Syme, small BK, small BE, small BE, med.	Syme BK, small BE, small BE, med.	BK, med. AE, small AE, med.	BK, large AK, small AE, large	AK, large Hip disarticulation Hemipelvectomy Shoulder disartic. Forequarter
Top width, in.....		5	5	6	8	9
Toe width, in.....		3-1/2	4	5	6	7
Length, in.....		14	18	18	18	18

There are four stump socks per carton. These are shipped nonsterile by the manufacturer and must be gas autoclaved before using. It is recommended that the socks be double wrapped to meet hospital standards.

**Recommended Sterilization Procedure for Orlon/Lycra Stump Socks:** The following procedure is recommended for American Sterilizer Company Gas Autoclaves only. Should another system be used, local assistance should be obtained to determine proper procedure. **DO NOT USE STEAM AUTOCLAVE!** This will result in stump sock shrinkage and loss of elasticity in the material.

a. *Autoclave setting:* Temperature—130° F. Pressure—15 p.s.i. (regular) to 5 p.s.i. (plastic). Initial vacuum—20 in. of mercury. Humidity—30-50 percent. Jacket steam pressure—3 lb.

b. *Sterilant used:* Oxyfume sterilant 12

c. Orlon Lycra stump socks are sterilized in large lots at 130° F. with 7 p.s.i. pressure, with a 570 sterilant concentration for 6 hours.

d. *Aeration time:* 24 hours.

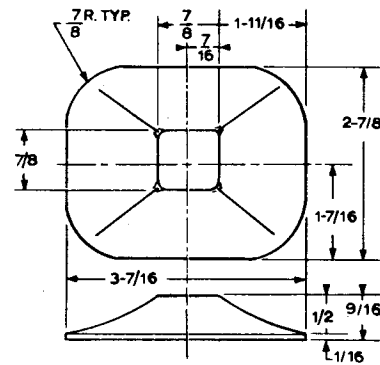
e. Each article is individually packaged in polyethylene bags to avoid storage contamination.

**II. PREOPERATIVE PREPARATIONS BY THE PROSTHETIST OF MATERIALS AND COMPONENTS**

1. Select a left or right set of appropriate felt relief pads made from medium hard felt (Fig. 23).

*Note:* Currently, efforts are being made to replace the felt relief pads with compressed reticulated polyurethane which can be steam or gas autoclaved. The shape of the relief pads will remain as shown.

2. Fabricate the waist belt with elastic suspension straps.



PATELLAR-PAD—RIGHT AND LEFT

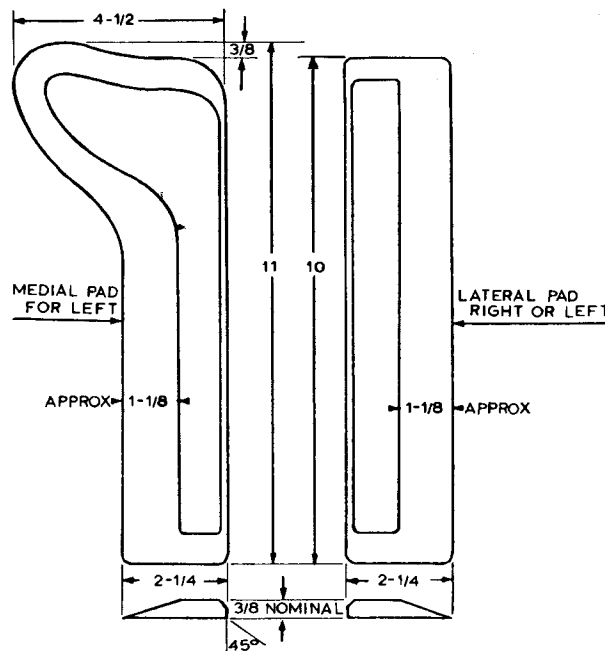


FIGURE 23.—Lateral and medial pads beveled and skived for use on left stump.

3. Select and assemble an appropriate adjustable prosthetic unit and pylon (Fig. 24). The ideal below-knee unit is compact, lightweight, durable, and free

of protruding parts. The unit should provide the following adjustment capabilities:

- a. Angular adjustments of flexion-extension, ad-

BELOW-KNEE ADJUSTABLE PROSTHESIS

- 31) Socket Attachment Straps
- 32) Tube and Foot Attachment Plug
- 33) Metal Hose Clamp
- 35) Anterior-Posterior Slide Plate and Detachable Socket Attachment
- 35A) Thumb Screw
- 36) Wedge Disks
- 37) Combination Base Plug and Medial-Lateral Slide Plate
- 37A) 9/16 Hex Nut and Washer
- 37B) Windows
- 37C) Central Bolt

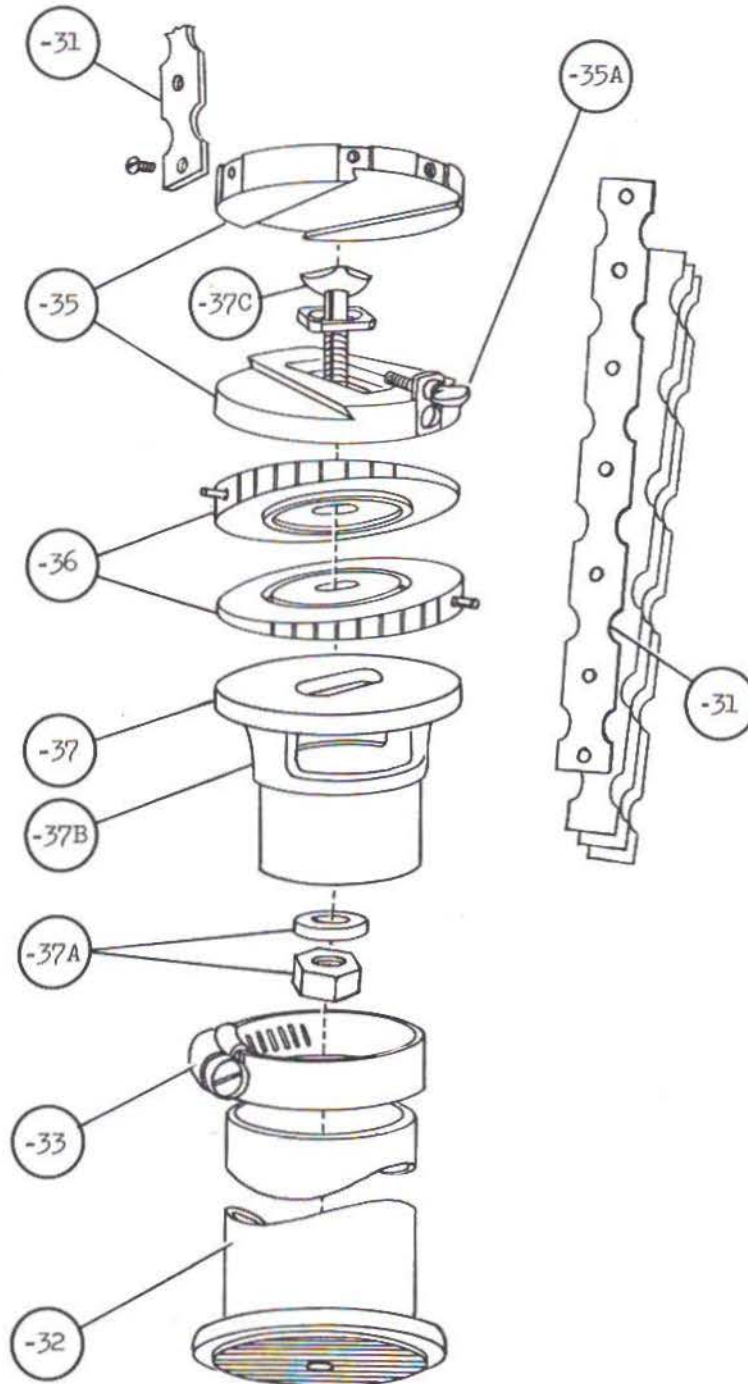


FIGURE 24

duction-abduction (tilt), or a combination of the two.

b. Horizontal adjustments in the mediolateral and anteroposterior planes (slide), or a combination of the two.

c. Length adjustment of the shank (pylon).

d. Toe-in and toe-out adjustment for the prosthetic foot.

e. Simple quick disconnect feature, allowing the pylon to be easily removed from and reattached to the cast socket without loss of alignment.

With reasonable care and by following the text in attaching the prosthetic unit, few, if any, static or dynamic alignment adjustments will be required. Three-quarters of an inch horizontal and 10 deg. of angular adjustments are most adequate especially if reduced weight of the unit can be obtained.

*Note:* While there are various prosthetic units available incorporating the above mentioned features, for the sake of brevity we limit the demonstrations to the VA Prosthetics Center and U.S. Manufacturing Company prosthetic units.

4. Obtain a shoe from the patient prior to surgery and fit a SACH foot to it. If the patient is unable to furnish a shoe or if the shoe should be unsatisfactory for proper fitting and alignment, a Kingsley Immediate Postsurgical SACH foot is selected. A neoprene rubber heel can be glued to a conventional SACH foot to level it in order to achieve proper static and dynamic alignment of the prosthesis when the patient stands.

5. Assemble components and materials required for the below-knee rigid dressing application (Fig. 25) (See Appendix B for List of Suppliers):

a. Sterile interface material (reticulated polyurethane distal pad)

b. Sterile Orlon Lycra stump sock

c. Felt or polyurethane relief pads, right or left

d. Standard below-knee suspension belt

e. Prosthetic unit, tubing, and hose clamp to form immediate prosthesis pylon

f. Immediate postsurgical SACH foot with bolt

g. Dow Corning Medical Adhesive Spray, Type B

h. 2 rolls of 4 in. elastic plaster bandage

i. 6 plaster splints, 4 in. x 15 in., extra fast setting

j. 2 rolls of 4 in. conventional plaster bandage, extra fast setting

6. Assemble kit of tools required for fitting prosthesis immediately after surgery (Fig. 26). All tools, except stainless steel tools, have been stripped, polished, and chromed to allow for repeated sterilization when required.

a. Straightedge

b. Tube cutter

c. Metal shears



FIGURE 25

d. Common screwdriver

e.  $\frac{5}{16}$  in. Allen wrench and  $\frac{3}{8}$  in. Allen wrench brazed together

f.  $\frac{3}{32}$  in. Allen wrench for VAPC unit

g.  $\frac{9}{16}$  in. open end wrench (for use with newer model prosthetic unit).

h. Pliers

i. Bandage scissors

j. Scalpel and/or skiving knife

k. Indelible pencil

### III. THE BELOW-KNEE AMPUTATION SURGERY

#### A. THE PREPARATION

The anesthetic is chosen by the anesthesiologist in consultation with the patient and the surgeon.

If the extremity has infected areas or draining sinuses, the infected area is isolated with adhesive skin drape prior to the immediate postoperative skin prep.




FIGURE 26



A pneumatic tourniquet is placed loosely on the thigh for use *only* when blood supply is adequate. If the blood supply is marginal or if the patient has shown a thrombotic diathesis, the tourniquet *should not* be inflated.

The patient lies supine on the operating table with the extremity draped free. A large adhesive plastic drape is placed between the bottom and top cloth drapes under the leg at the level of the amputation to prevent contamination from below by blood and irrigation fluid.

## B. THE OPERATIVE PLAN

A 4 to 7 in. tibial length stump is desirable; the shorter in patients with decreased arterial blood supply, the longer in patients with adequate blood supply. Total leg length will dictate optimum stump length when the site can be elected. A 6 to 7 in. stump is considered optimum for the average nonischemia adult.

A long posterior musculocutaneous flap is planned for patients with peripheral vascular disease since this flap carries the better blood supply. The final wound closure then will lie anteriorly.

However, any unusual variation may be used successfully in order to utilize available healthy skin. Position of the scar is not important due to improved prosthetic techniques. The goal is a scar which is non-adherent, nontender, and which will remain well healed. Plastic skin closure principles *must* be followed.

## C. THE INCISION

Using the long posterior flap technique, the anterior incision is made transversely at a point just distal to the desired level for tibial bone transection. It is carried to the depth of the deep fascia and extended two-thirds of the distance posteriorly on the calf on each side. The incision anteriorly, therefore, is two thirds circumferential.

The incision is next directed distal and slightly anterior on either side, a distance of 1 in. more than the anteroposterior diameter of the calf at the level of the anterior incision, usually about 5 inches. At this point it is then directed posteriorly and the lateral and medial incisions are joined, completing the incision to the level of the fascia and forming the long posterior flap. It must be remembered that excess skin can always be tailored but *too short a flap requires higher*

*bone amputation.* Hemostasis is obtained by fine vessel clamps and ligature with the smallest appropriate plain or chromic gut.

## D. THE AMPUTATION

A large scalpel is used to transect the anterior tibial and peroneal musculature at the level of the skin incision. The section is carried to the level of the interosseus membrane where the neurovascular bundle is identified. The vessels are clamped individually and tied with chromic catgut. The anterior tibial nerve in the neurovascular bundle and the superficial peroneal nerve are clamped and *moderate* traction is applied. They are circumferentially ligated with very light suture as far proximal as possible and transected high with a scalpel. They are then allowed to retract.

The periosteum of the tibia is cut sharply at the level of the skin and gently elevated proximally about 1/2 inch. Care must be taken to leave the combined periosteum-fascia layer intact for it is the sturdy tissue to which the posterior musculature is sewn for muscle stabilization.

The periosteum of the tibia is then elevated posteriorly from side to side and a periosteal elevator is placed *directly* behind the tibia. The tibia is then transected with power or hand saw just proximal to the level of the anterior skin incision. The anterior corner of the cortex is removed obliquely from a point 1/2 in. proximal to the cut end and the bone edges are *rounded* carefully with a fine rasp. Care is taken to smooth medially and posteromedially on the bone end. The bone is rounded rather than simply beveled.

The periosteum of the fibula is elevated proximally and the fibula is transected 1/4 to 1/2 in. proximal to the level of the tibia amputation. The use of a reciprocating power saw makes the transection of the fibula considerably easier and less traumatic to the surrounding tissue.

Some surgeons prefer sectioning the fibula first. The stability provided by the intact tibia makes fibula division easy. When power equipment is used, fibular instability has not presented a problem.

The fibula is left somewhat longer than in previously described amputation techniques because the modern total-contact socket depends upon the more cylindrical, broad stump for rotatory stability. Except in children and adolescents, no attempt is made to gain tibiofibular bone bridging. Fibular instability has not proven to be a significant problem in prosthetic fit.



The posterior muscle mass is now sharply and carefully freed from its attachments to the tibia and fibula distally to the level of the posterior skin incision. The posterior muscle mass is then divided with a large scalpel or sharp amputation knife, taking care to preserve the skin. The amputation is now complete and the posterior musculocutaneous flap is now ready for tailoring prior to stabilization.

#### E. THE POSTERIOR MUSCLE FLAP

Deepest in the muscle mass, and therefore most superficial in the flap as it appears on the operating table, are the tibialis posterior, flexor digitorum, and flexor hallucis longus muscles which overlie the posterior neurovascular bundle. These deep flexor muscles are transected just distal to the level of the end of the tibia and allowed to retract. Care is taken to clamp, tie, and transect the vascular structures 1 in. distal to the bone end. Bleeding from the plexus of deep veins can be difficult to control if the vessels are allowed to retract proximal to the sectioned bone prior to being secured.

Gentle traction is placed on the deep nerves. They are circumferentially ligated as far proximally as possible, cut sharply, and allowed to retract above bone level. Treated in this way, painful neuromata have not been a postoperative stump problem.

The posterior musculocutaneous flap is now brought anteriorly up to determine its adequacy for closure. In muscular patients without an atrophied extremity, considerable tailoring and thinning of the gastrocnemius-soleus group will be necessary. A sharp amputation knife or a large scalpel blade is used to taper the muscle flap from proximal to distal, and medial-lateral, thus reducing the bulk at the end of the stump to allow satisfactory closure. The surgeon should not hesitate to resect damaged or excess muscle bulk following muscle stabilization and prior to skin closure.

If a tourniquet is used, it is released before suturing the myofascial flaps, and hemostasis is obtained with as little additional tissue damage as possible.

#### F. MYODESIS OR MYOPLASTY

In the patient with severe peripheral vascular disease, muscle stabilization is accomplished by myoplasty as just outlined. When present, avascular muscle is excised. The posterior muscle flap is tapered maximally leaving only a thin muscle flap posteriorly which is

brought forward and sutured with interrupted chromic catgut sutures to the anterior tibial fascia and to tibial and fibular periosteum.

The skin and superficial fascia are separated from the posterior muscle flap for about  $\frac{1}{2}$  in. to 1 in. from the cut border in order to allow skin mobility for closure. The anterior skin flap is gently freed for *no more than*  $\frac{1}{4}$  to  $\frac{1}{2}$  in. anteriorly to facilitate the skin closure.

With compromised blood supply, great care must be taken to reduce to a minimum the amount of tissue devitalized by sutures, hemostats, and forceps. Cautery is not used. The use of mattress sutures is kept to a minimum.

In patients with normal blood supply to the stump, myodesis is combined with myoplasty for muscle stabilization. Just proximal to the end of the tibia,  $\frac{7}{64}$  in. drill holes or smaller are placed in the anterolateral and posterior tibial cortex. Mattress sutures of chromic gut or synthetic, nonabsorbable material are placed in the muscle bellies at the anterior and posterior musculature after distal traction is placed on the myofascia. The sutures are tied to bone within the medullary cavity using one drill hole for two sutures, taking care to use a large round needle to avoid cutting sutures previously placed. This completes the myodesis. A myoplasty is then also carried out, tailoring and thinning the posterior flap and suturing it to the anterior fascia as described.

#### G. THE SKIN CLOSURE

The skin is closed without tension using interrupted nonabsorbable monofilament sutures. The rigid plaster dressing will support the skin postoperatively. The skin flaps are tailored as the skin is closed since the amount of skin prior to closure can be deceptively large. Tailoring prior to placement of the first skin sutures can lead to excessive skin resection.

A medium or small Penrose drain is placed between the muscle flap and the skin at the end of the skin closure and is carried out through one end of the incision. Care is taken to be sure that the drain is freely movable so that it can be removed easily through a small window in the cast 48 hours postoperatively. The drain may be omitted in patients with minimal circulation or with a dry wound at closure. The Penrose drain is chosen in below-knee amputations because its capillary action allows for more efficient drainage under a rigid compression dressing than would the suction tubing drainage.

S  
app  
be :  
to  
sec  
vas  
hea  
allo  
7  
and  
Skin  
only  
not  
A  
anc  
end  
Lyc  
avo  
ass  
surg  
able  
thru

FIG 1

Special care must be taken to obtain exact skin apposition without tension. Often blood supply may be adequate to permit skin healing but yet inadequate to sustain granulation tissue growth and allow secondary epithelialization. Patients with peripheral vascular disease may demonstrate delayed wound healing or no wound healing at all if skin edges are allowed to gap by imprecise wound closure.

The greatest emphasis must be placed upon precise and gentle surgical technique during the procedure. Skin must be handled as little as possible, retracted only gently with a finger or plastic hook retractor and not grasped with forceps.

An occlusive wound dressing such as silk or nylon, and a small amount of fluffed gauze are placed on the end of the stump over which is rolled the sterile Orlon Lycra stump sock. The sock is carefully applied to avoid damage to the suture lines. The prosthetist then assumes charge of application of the immediate post-surgical prosthesis; if no qualified prosthetist is available, the surgeon undertakes this procedure (Fig. 27 through 54).

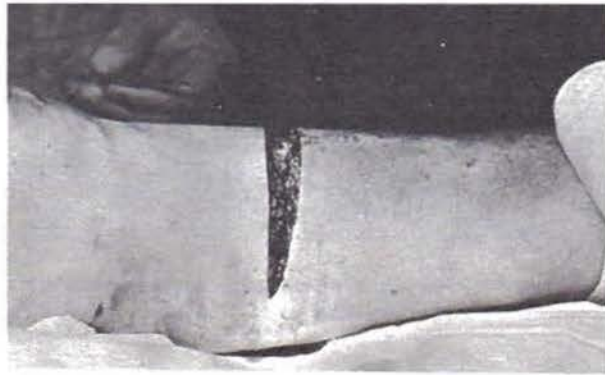


FIGURE 29.—Anterior incision approximately 4½ in. below the knee.

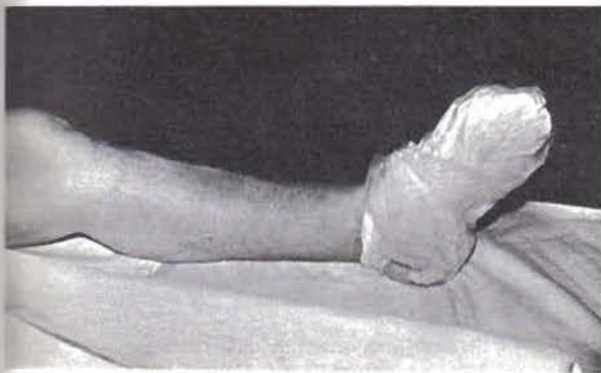


FIGURE 27.—Appearance of ischemic leg prior to amputation.

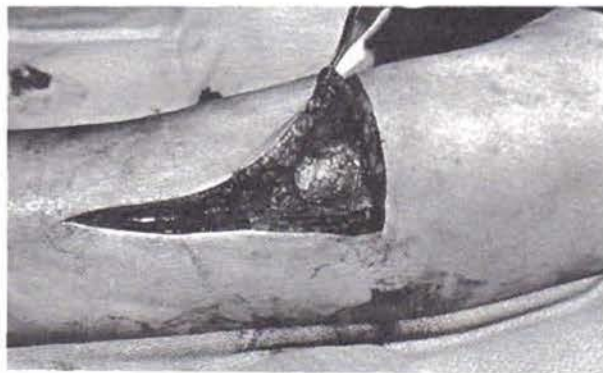

FIGURE 30.—Lateral extension of incision distally 5½ in.

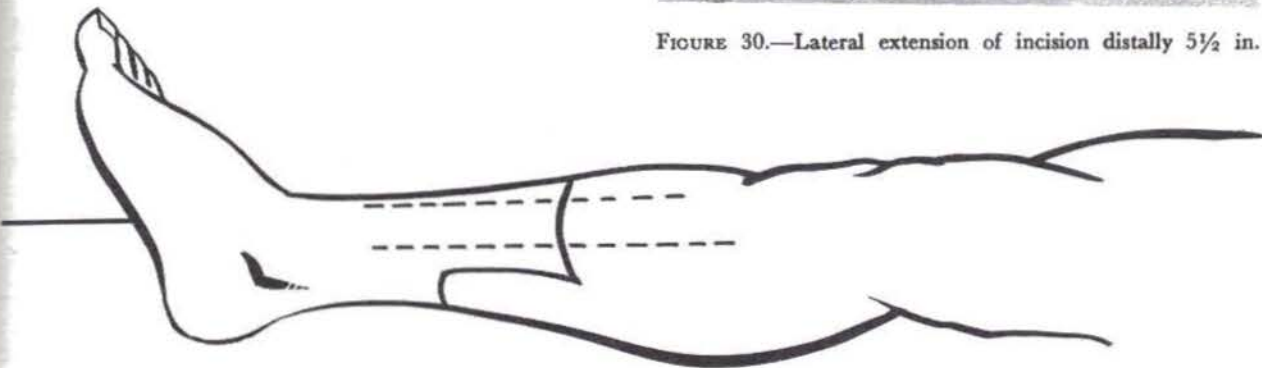


FIGURE 28.—Schematic drawing of skin incision.



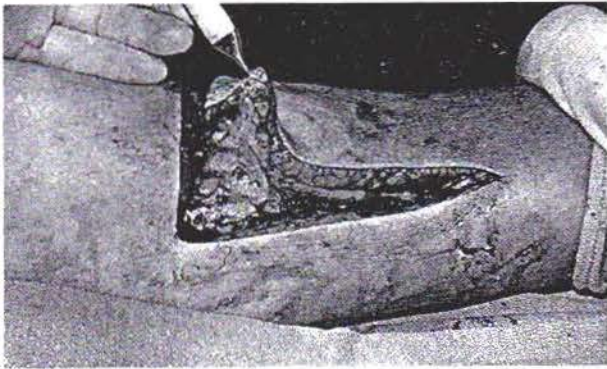


FIGURE 31.—Similar distal extension of incision on medial side of leg.

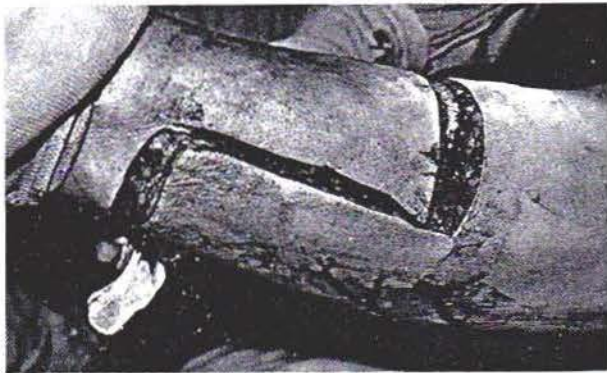


FIGURE 32.—Posterior incision completing skin flap.

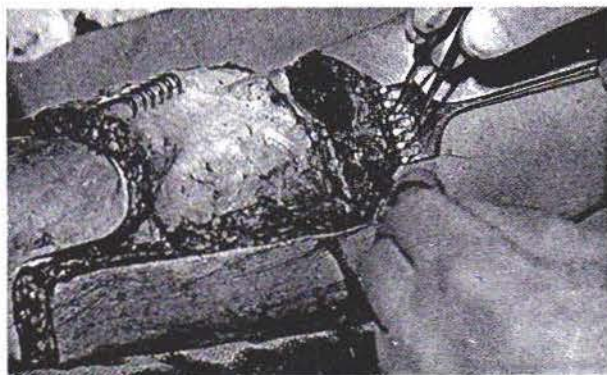


FIGURE 33.—Dissection through anterolateral muscles to intermuscular septum.

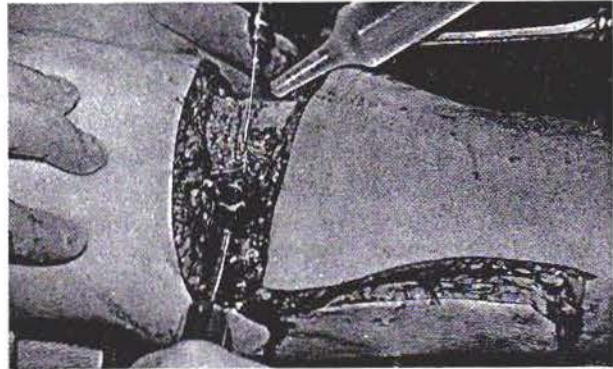


FIGURE 34.—Division of tibia and fibula with electric saw.




FIGURE 35.—Reflexion of anterior structures prior to completion of amputation.

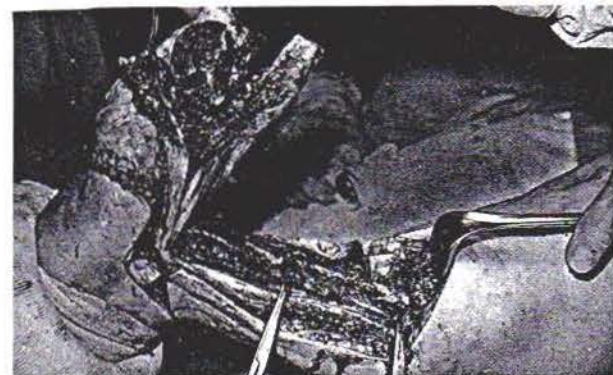

FIGURE 36.—Removal of distal leg leaving long posterior muscular tendon and skin flap.

FIGURE 37



FIGURE 38





FIGURE 37.—Illustration of posterior myofascial flap prior to contouring.

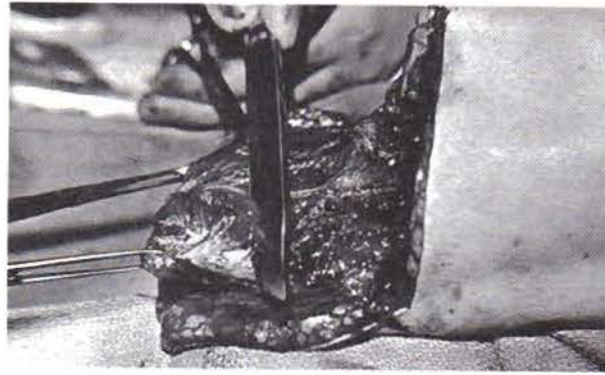
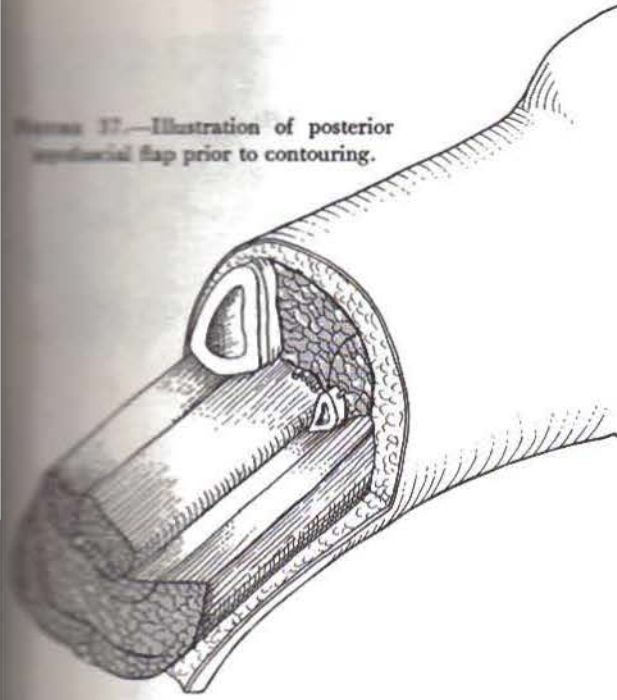


FIGURE 40.—Preparation of posterior musculotendinous flap.

FIGURE 41.—Myofascial flap contoured and tailored to bring forward and suture anteriorly.

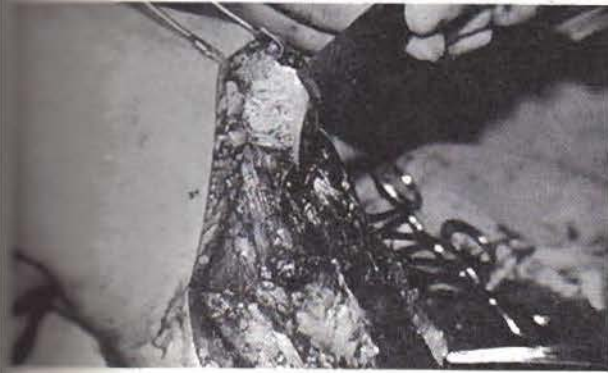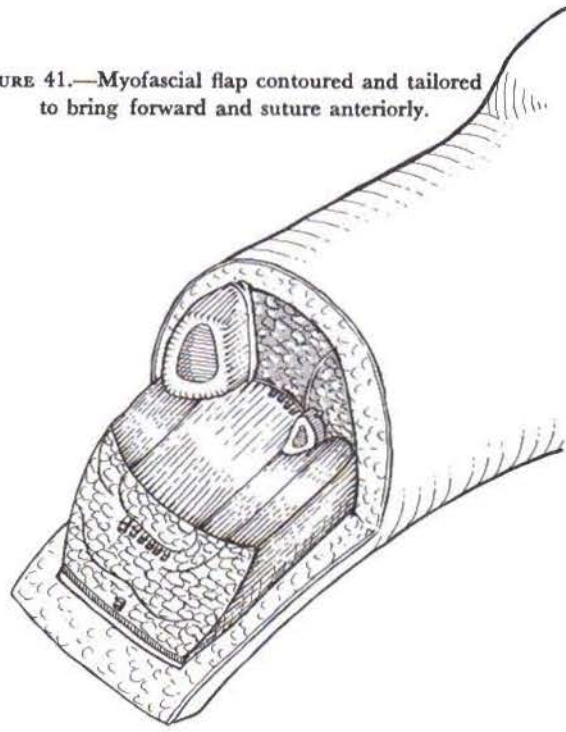


FIGURE 38.—Beveling and meticulous rounding of distal tibia.

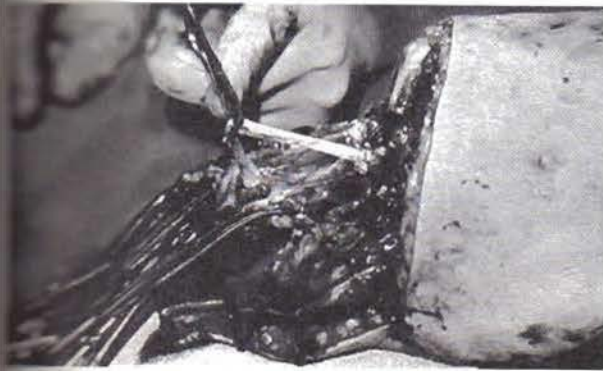


FIGURE 39.—Ligation of deep nerves and vessels.

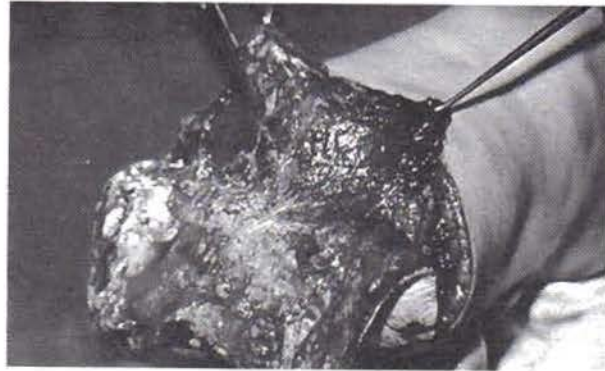

FIGURE 42.—Suture of musculotendinous flap to anterolateral deep fascia and periosteum over tibia.



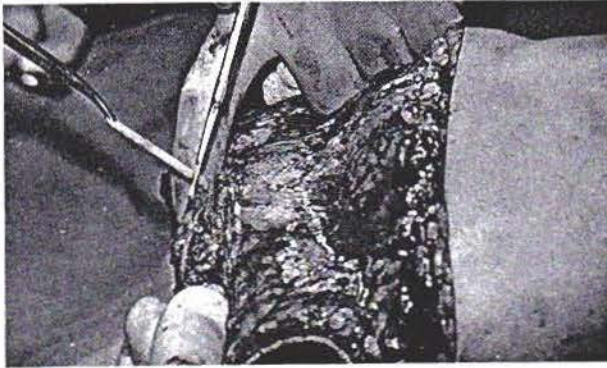

FIGURE 43.—Same as Figure 42, lateral view. Note division of saphenous nerve.

FIGURE 44.—Myoplasty completed and ready for skin closure.

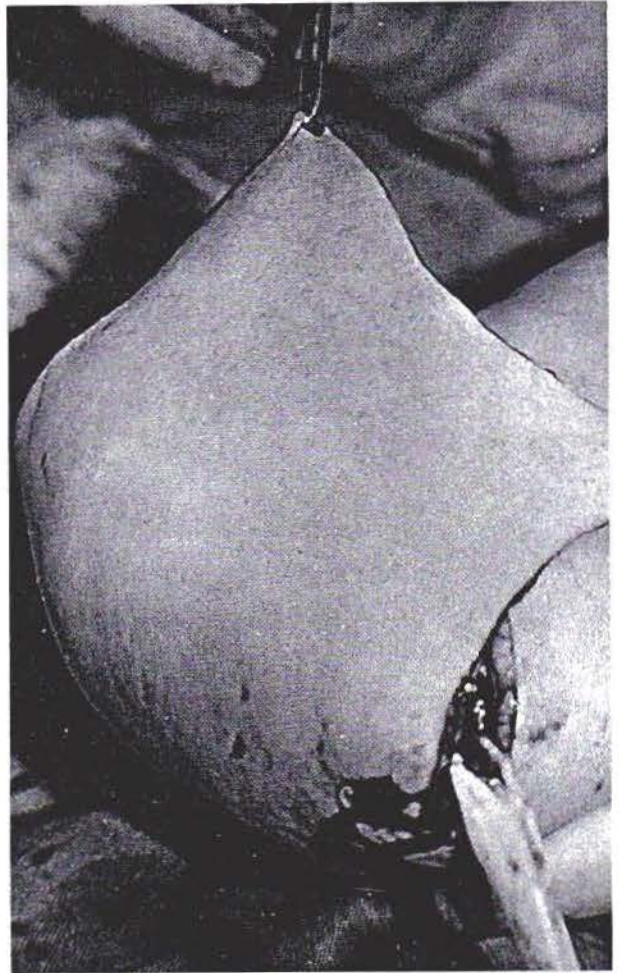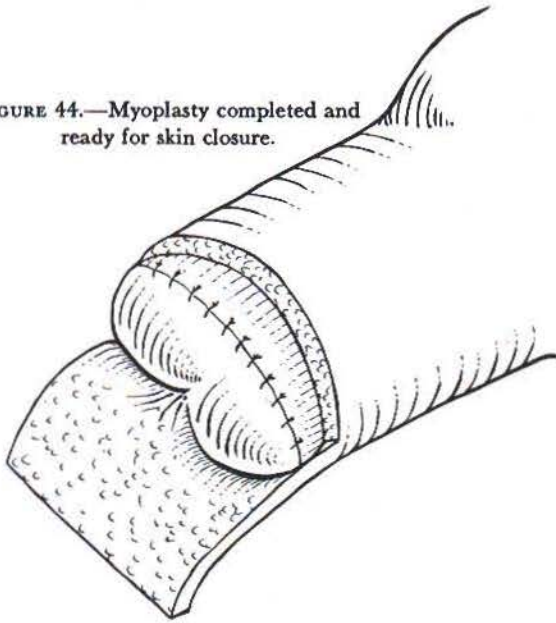


Figure 46.—Same as Figure 45.

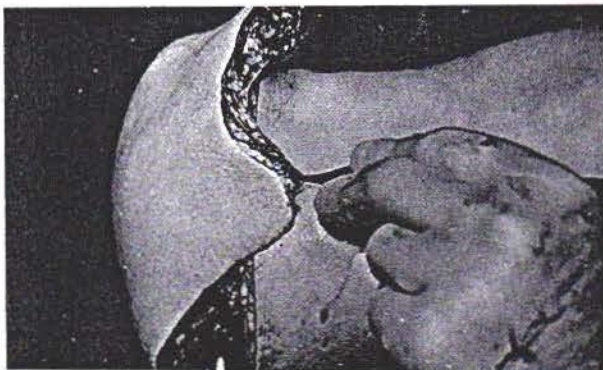


FIGURE 45.—Posterior skin flap brought forward and tailored for plastic closure.

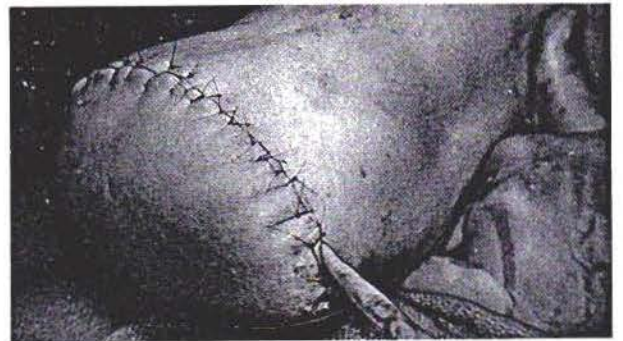

FIGURE 47.—Final closure, lateral view, with drain in place.

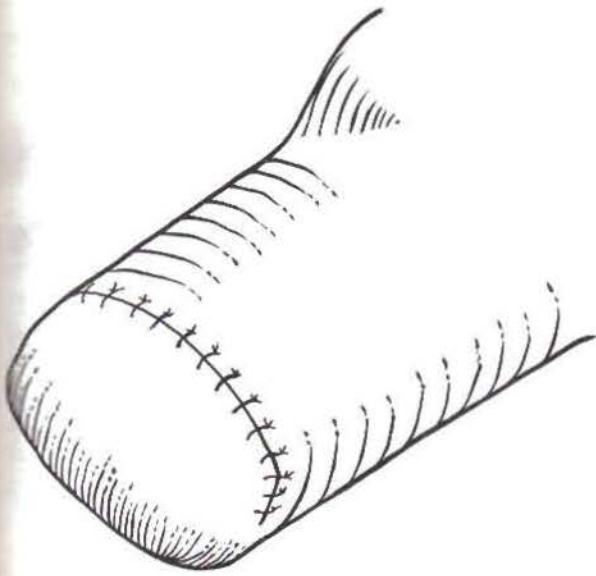


FIGURE 48.—Final closure, lateral view.

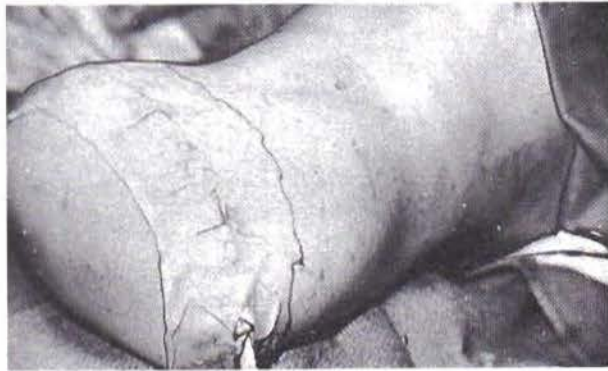

FIGURE 51.—Application of silk dressing.

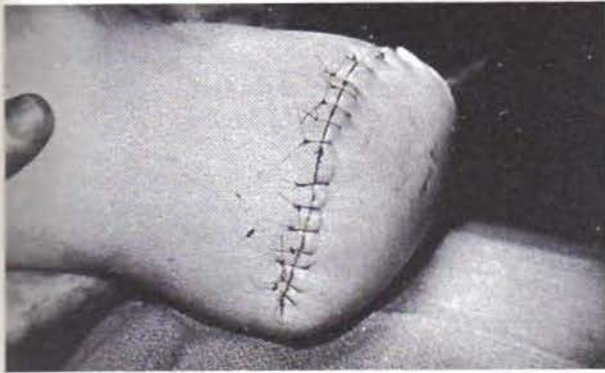

FIGURE 49.—Final closure, medial view.

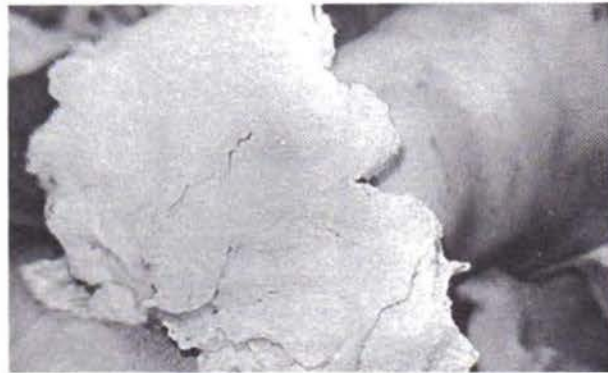

FIGURE 52.—Application of fluffed gauze.

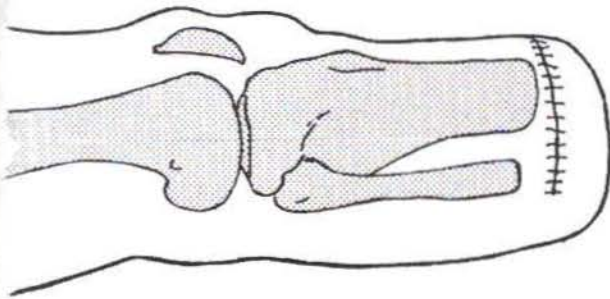


FIGURE 50.—Relationship of skin closure to tibia and fibula.

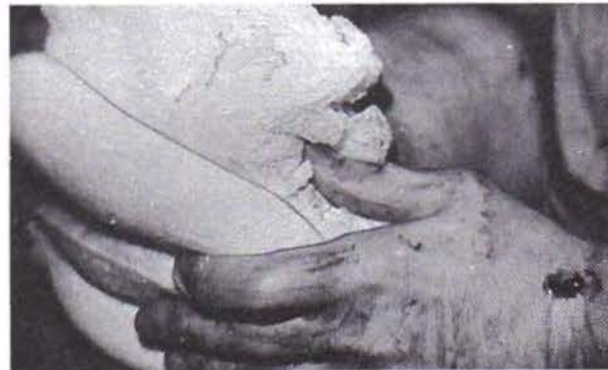

FIGURE 53.—Sterile Orlon Lycra stump sock is carefully rolled onto stump.






FIGURE 54.—Same as Figure 53.

#### IV. THE BELOW-KNEE IMMEDIATE POSTSURGICAL PROSTHESIS

##### A. APPLICATION OF FELT (OR POLYURETHANE) PRESSURE RELIEF PADS

1. (a) The sterile Orlon Lycra stump sock is held under firm tension with both hands by an assistant. The hands should be placed on the anteroproximal aspect of the thigh. The tension on the sock is correct when the stump can be held suspended off the operating table. This will also automatically place the stump in a properly flexed attitude which varies among individuals due to physical characteristics, previous trauma to the knee joint, and actual stump length. On the average, between 5 and 15 deg. of knee flexion is most desirable (Fig. 55).

(b) If no assistant is available, a simple adjustable shoulder suspension harness, which is interchangeable

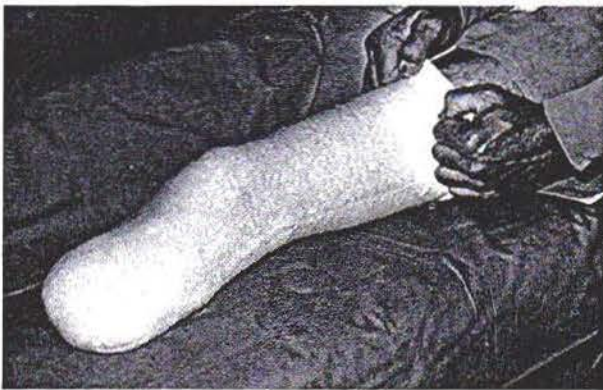

FIGURE 55

able for right and left, can be substituted to achieve the same result (Fig. 56).

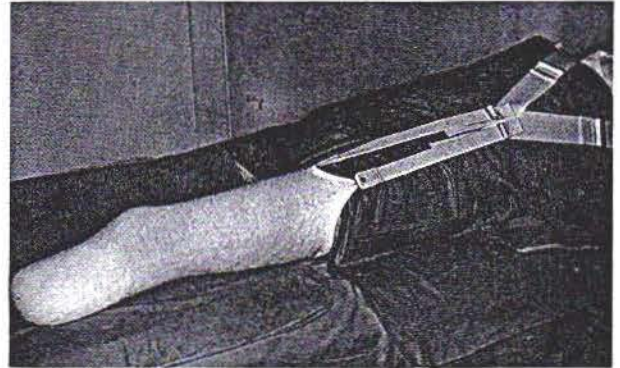


FIGURE 56

2. The felt (or polyurethane) relief pads which come in a standard size, right and left, must be trimmed, skived, and beveled in the appropriate areas for individual needs.

(a) The medial felt relief pad is located with the center of the posterior extension placed on the concave apex of the medial tibial condylar flare (Fig. 57).

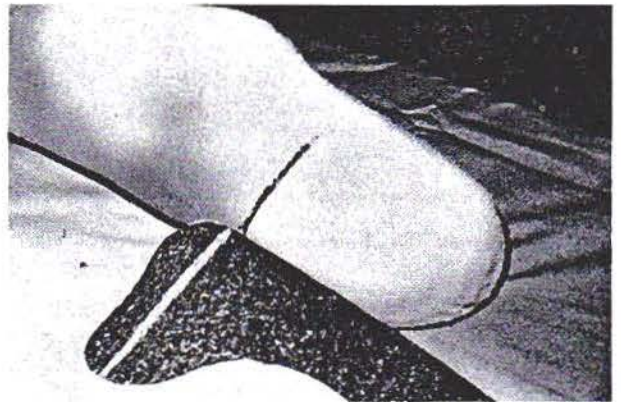


FIGURE 57

Slide the pad anteriorly on the stump until the beveled portion rests on the shaft of the tibia  $\frac{1}{4}$  in. medial to the tibial crest throughout its length. Trim the posterior extension of the felt pad so it will not impinge on the hamstring tendons (Fig. 58). Skive the area which has been trimmed.

The medial felt pad should extend distally  $\frac{3}{8}$  in. beyond the cut end of the tibia. Care should be taken



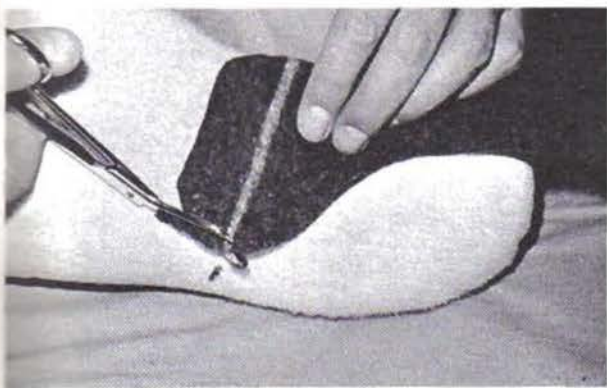


FIGURE 58

not to confuse the beginning of the bevel on the tibia with the cut end of the bone. Cut the medial felt pad to proper length and bevel the cut edge of the felt so that it will blend into the plaster wrap without causing ridges (Fig. 59).

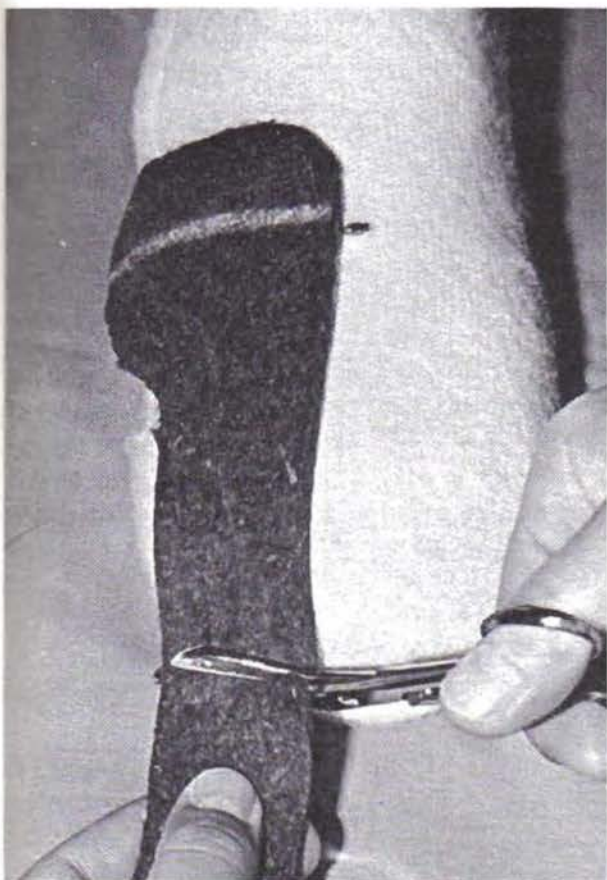

FIGURE 59

(b) The lateral felt relief pad is placed opposite the medial pad with the beveled portion located  $\frac{1}{4}$  in. lateral to the tibial crest throughout its length. If the relief pads have been applied correctly, they will relieve the entire tibial tubercle and tibial crest. Cut and bevel the lateral felt pad distally in the same manner as the medial pad (Fig. 60).

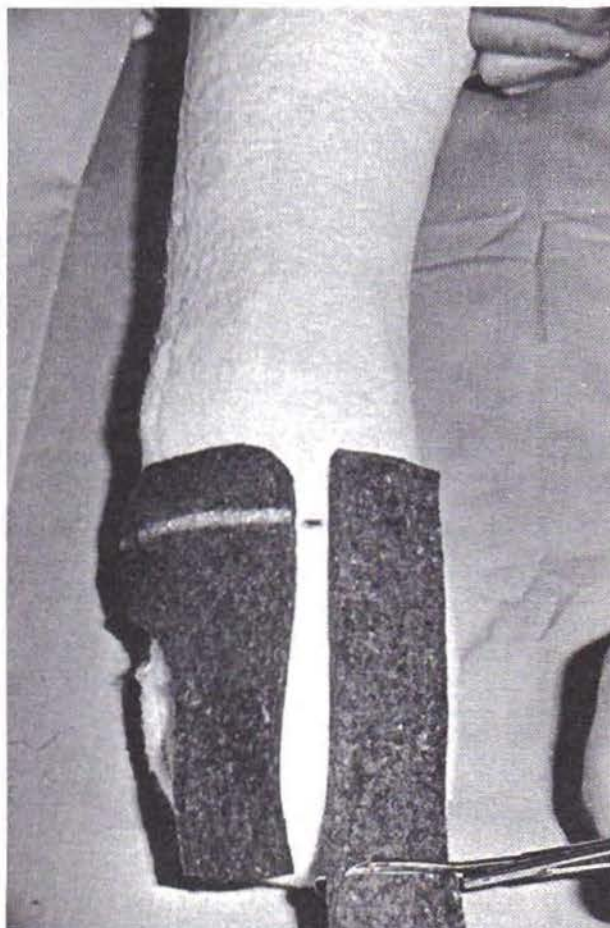


FIGURE 60



*Variation:* It is frequently necessary to cut two wedge-shaped pieces off the distal portion of the relief pads distally to insure that an equal continuous  $\frac{1}{2}$  in. relief gap is maintained between the felt pads through their entire length (Fig. 61, 62, and 63).

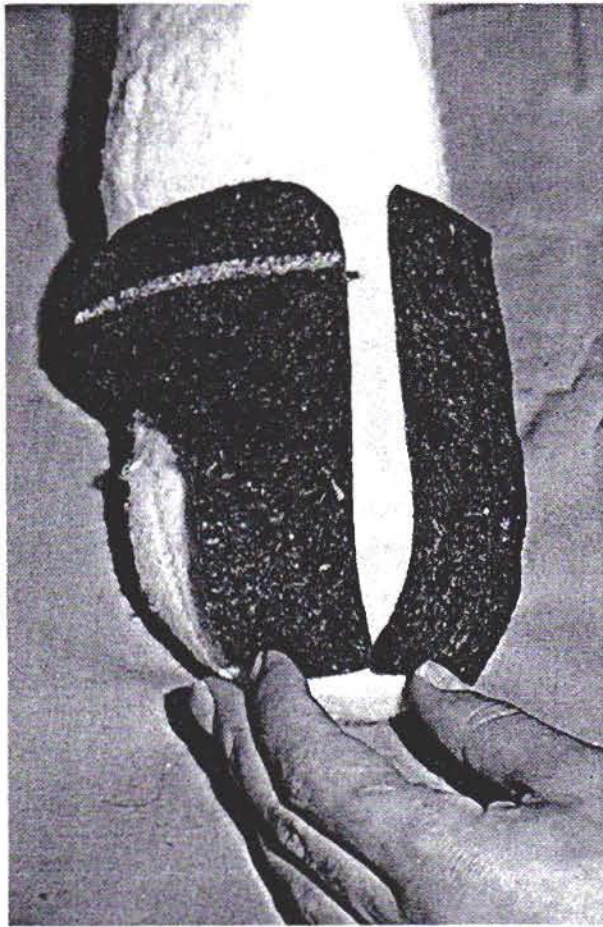


FIGURE 61

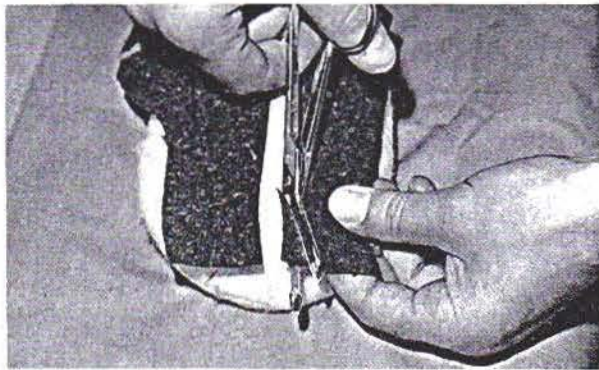


FIGURE 62

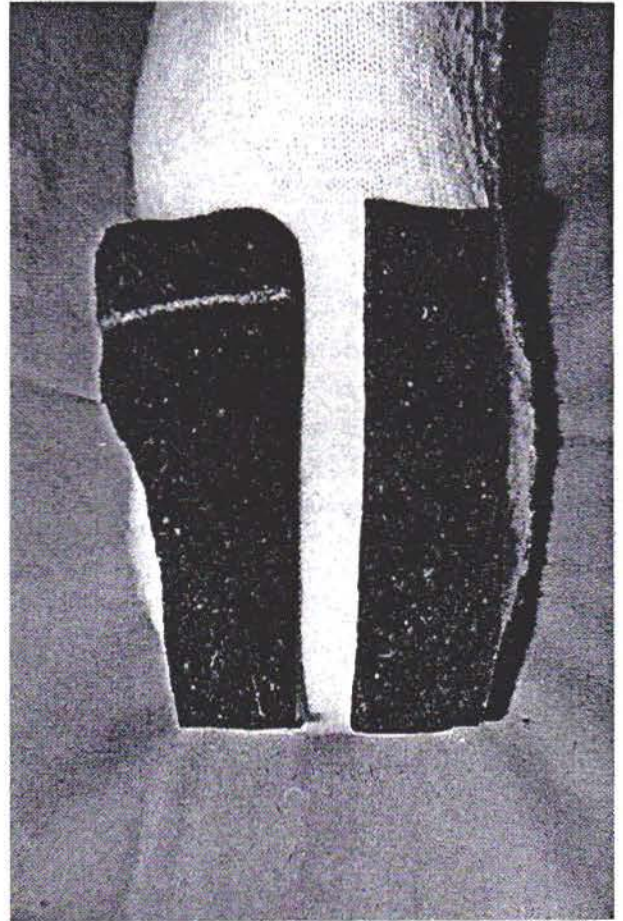

FIGURE 63

(c) The patellar felt relief pad is fitted. It must cover the entire patella and is reskived to a fine feathered edge around its outer periphery whenever trimming is indicated (Fig. 64).

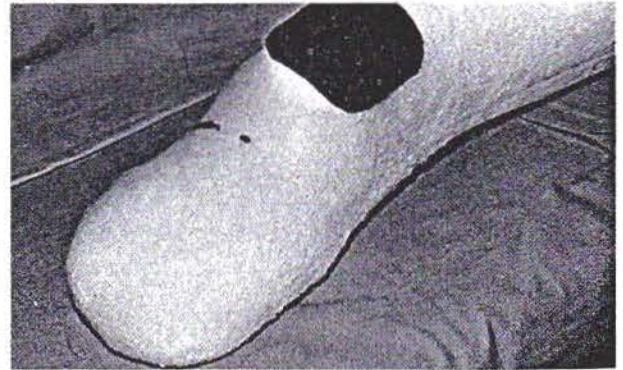


FIGURE 64



(d) *Maintaining continuous tension on the stump sock, spray the backs of the felt relief pads and the areas of the stump sock on which they will be located with Dow Corning Medical Adhesive, Type B (Fig. 65). Allow 5 seconds for the adhesive to become tacky.*

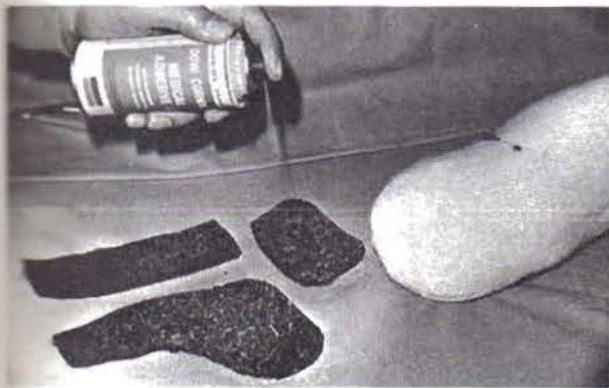

FIGURE 65

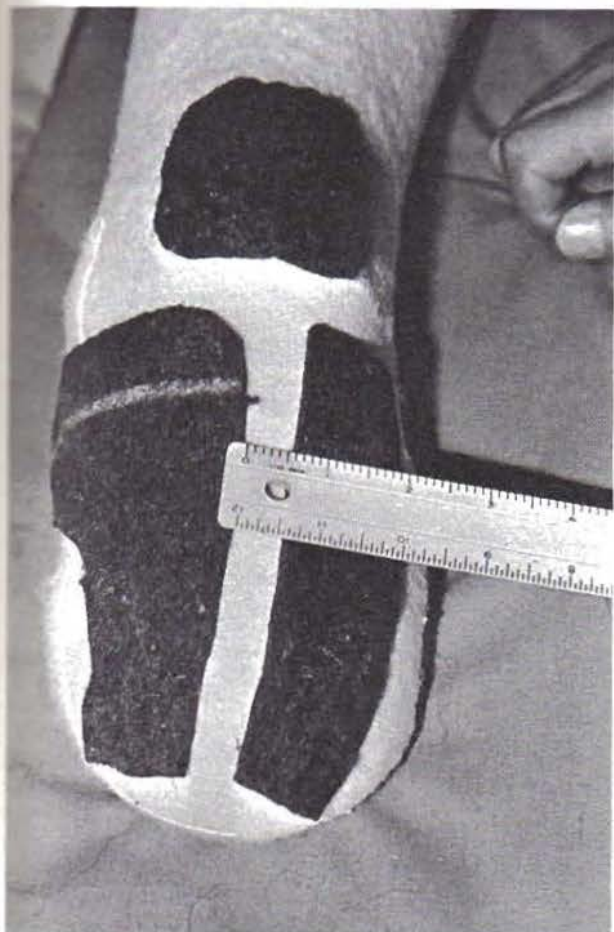


FIGURE 66

*Note: Polyurethane relief pads are provided with adhesive backing. The protective paper is peeled off just prior to application of the pads to the stump sock.*

Reapply the relief pads exactly as outlined earlier. *Unvarying tension must be maintained on the stump sock at this time and continuously thereafter until the plaster has set or the pads will be displaced and no longer serve their intended purpose.*

*Note: The 1/2 in. separation between the felt relief pads takes into consideration also the slight migration of the pads toward one another as the elastic plaster bandage is being applied (Fig. 66). If the felt pads are separated more than this, they will no longer function as supports to bridge the plaster across the tibial crest and will not relieve it from pressure. Skin damage over the tibial crest may result.*

3. A sterile reticulated polyurethane distal pad of the proper size is selected and applied over the felt relief pads to the distal end of the stump (Fig. 67).

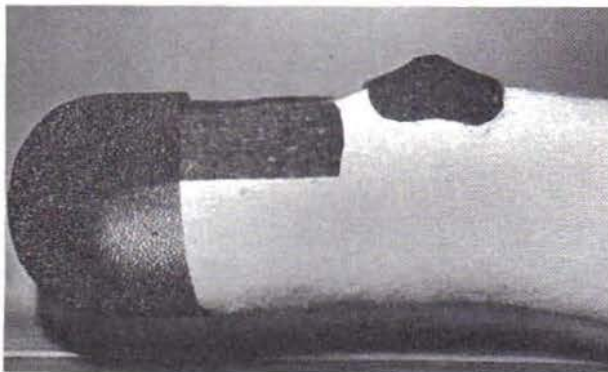


FIGURE 67

## B. APPLICATION OF THE RIGID DRESSING

1. For the initial wraps, elastic plaster bandage is used rather than conventional plaster. When using an elastic plaster bandage, the elasticity provides safe and beneficial compression of the stump while conforming well to its contours, providing a smooth rigid dressing. *Continuous tension must be maintained on the stump sock until the plaster has hardened.*

### Wraps 1 and 2:

The wrap is always started on the distal lateral aspect of the stump to avoid medial displacement of the gastrocnemius muscle. Cover the proximal feathered



edge of the polyurethane distal pad with the elastic plaster bandage. Minimal tension is applied to the bandage with this circumferential wrap, clockwise for a right stump and counterclockwise for a left stump when viewed anteriorly (Fig. 68).

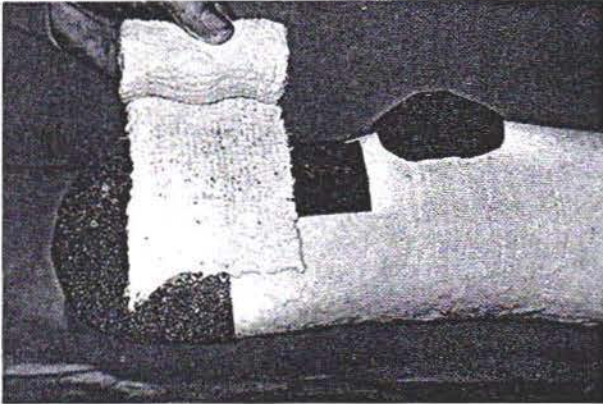


FIGURE 68

One and three quarter circumferential turns will secure the felt relief pads and the polyurethane distal pad in place and anchor the elastic plaster to itself (Fig. 69).




FIGURE 69

#### Wrap 3:

The wrap is now at a point posterolaterally. Bring it anteriorly up over the distal *LATERAL* portion of the stump pulling the plaster bandage almost to its limit of elasticity. At the anterior stump margin, release the tension and carry the wrap medially and then posteriorly with only a light pull on the plaster (Fig. 70).

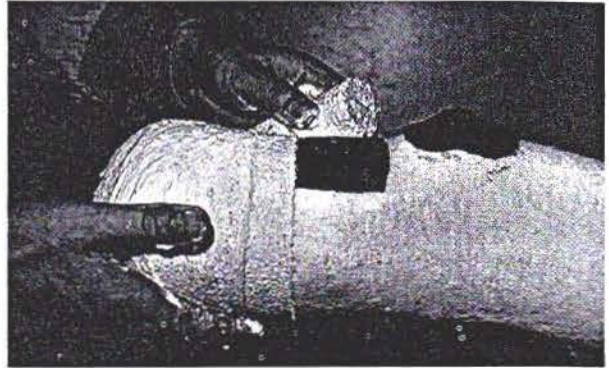


FIGURE 70

#### Wrap 4:

The fourth wrap is almost identical to wrap 3 except that now the bandage covers the distal *CENTER* of the stump (Fig. 71) (bandaging in the A-P plane rather than circumferentially or diagonally).

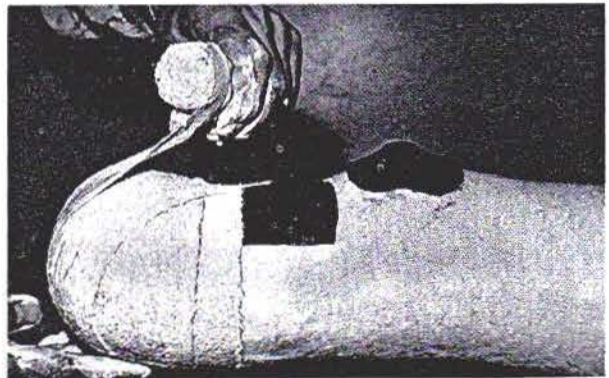


FIGURE 71

The direction of the wrap is altered anteriorly and carried toward the lateral side of the stump (Fig. 72), as if to resume circumferential wrapping.

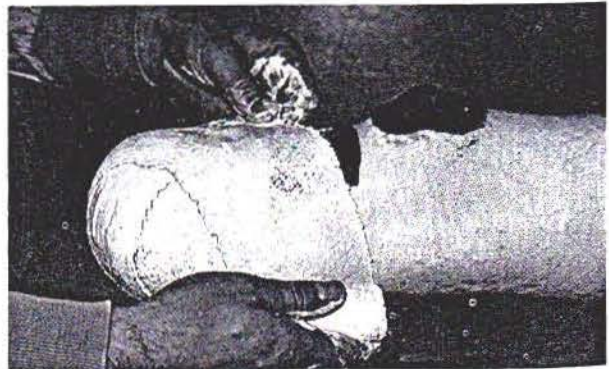

FIGURE 72



**Wrap 5:**

The fifth turn is brought anteriorly up over the distal *MEDIAL* aspect with the same controlled tension to the bandage (Fig. 73).

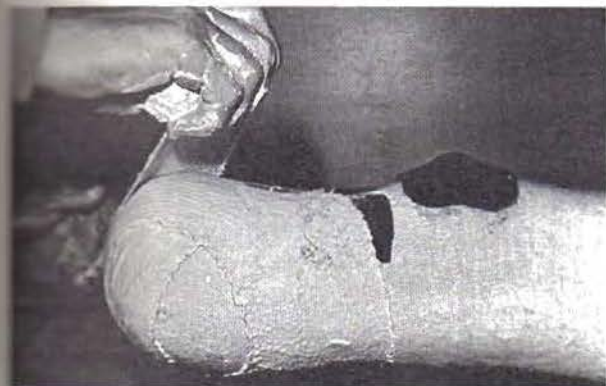

FIGURE 73

**Wrap 6:**

To achieve desired cast strength, a second diagonal layer of elastic plaster bandage is applied by repeating wrap 5 (Fig. 74). . .




FIGURE 74

**Wrap 7:**

. . . followed by wrap 4, again altering the direction of the wrap medially. This will cover the distal *CENTER* of the stump with the second layer of plaster (Fig. 75).

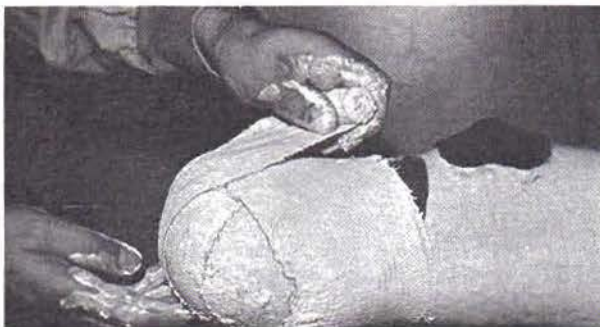


FIGURE 75

**Wrap 8:**

Repeating wrap 3 will now cover the distal *LATERAL* stump with the second layer of plaster bandage (Fig. 76).

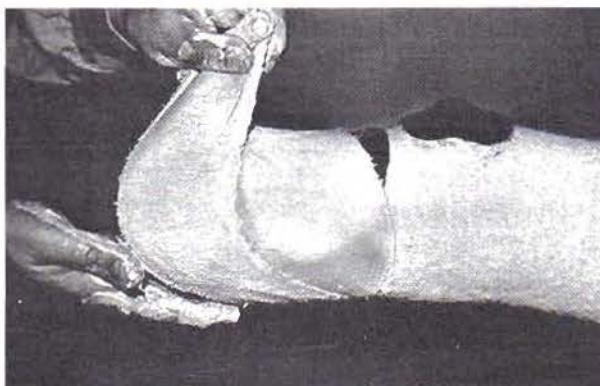

FIGURE 76

The remainder of the elastic plaster bandage is wrapped in a circular manner proximally to the knee joint (Fig. 77).



FIGURE 77



2. With the knee held between 5 and 15 deg. of flexion and still maintaining continuous tension on the stump sock, a second roll of elastic plaster bandage is started slightly distal to the level where the previous wrap terminated (Fig. 78).

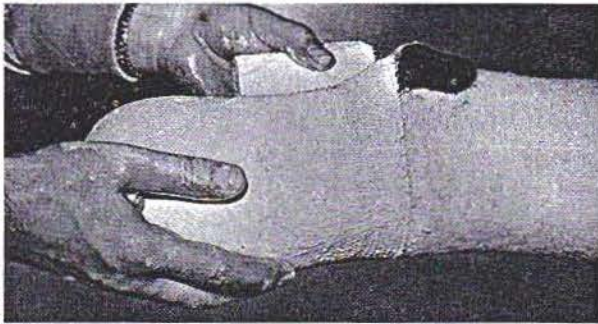


FIGURE 78

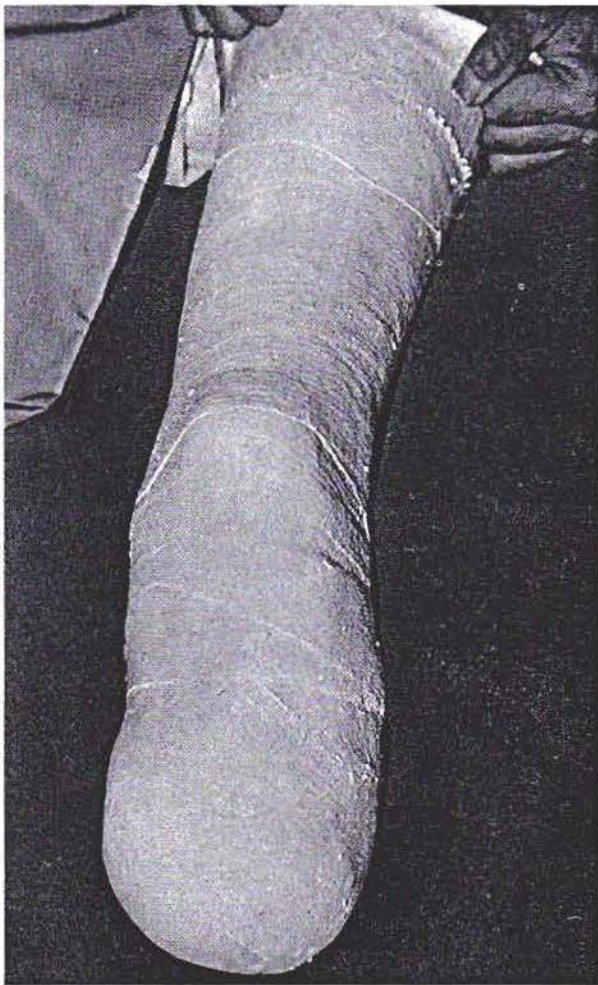

FIGURE 79

This new roll is carried proximally to just past mid-thigh, applying only minimal tension to the plaster and overlapping half of each previous turn. CARE MUST BE TAKEN TO AVOID PROXIMAL CONSTRICTION WITH THIS WRAP. Thus the tension applied to the plaster bandage must be decreased gradually to none as it is wrapped proximally (Fig. 79).

3. Because of the inherent structural weakness of elastic plaster bandage, the initial wrap must be reinforced with conventional plaster bandages and splints.

Double layers of 4 in. x 15 in. plaster splints are applied over the distal portion of the socket antero-posteriorly (Fig. 80) and mediolaterally (Fig. 81)

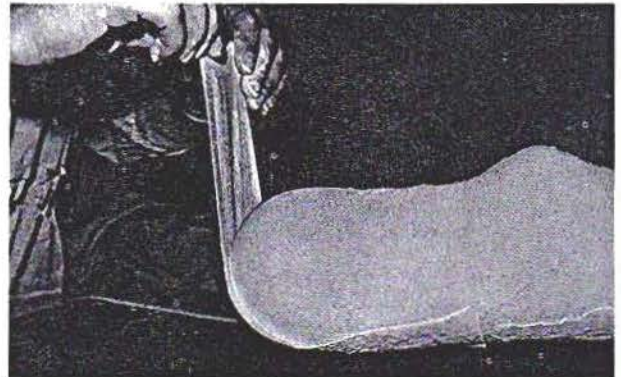


FIGURE 80

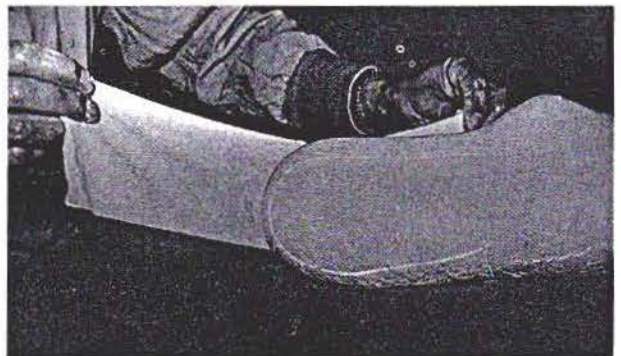

FIGURE 81

4. A roll of 4 in. conventional plaster bandage is applied starting at the distal third of the stump and wrapping proximally with even, overlapping, circular wraps (Fig. 82).





FIGURE 82

5. At the anteroproximal level of the rigid dressing, a 1½ in. suspension strap with safety buckle is incorporated into the wrap by placing two turns of the conventional plaster bandage over the webbing of the suspension strap (Fig. 83). Take care to apply it with the leg in a neutral position.

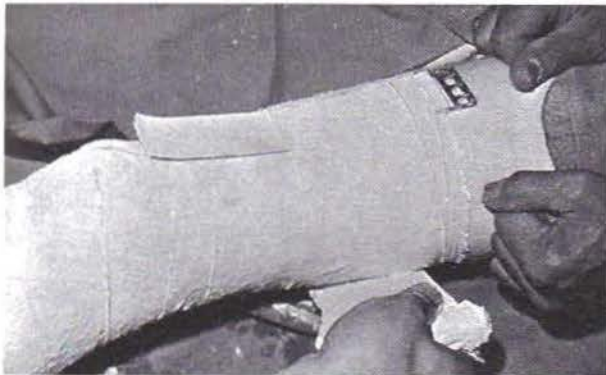

FIGURE 83

The remaining distal portion of the webbing is folded back and wrapped in place with the remaining plaster bandage to anchor it firmly in place (Fig. 84).

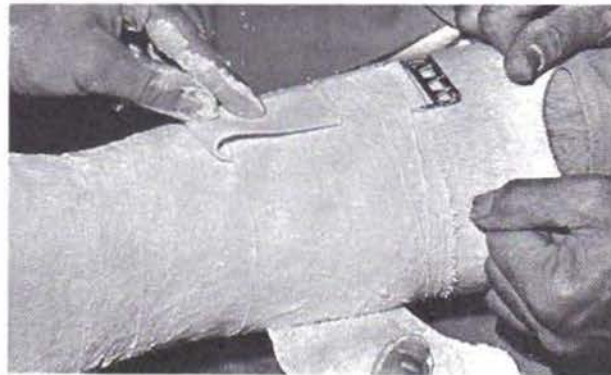

FIGURE 84

*Variation:* For an obese patient with excessive soft tissue over the thigh, it is necessary to incorporate a second elastic suspension strap with safety buckle into the wrap at the posterolateral level of the rigid dressing for added suspension when the patient is flexing the hip (Fig. 85).




FIGURE 85



The entire wrap should then be smoothed lightly by hand (Fig. 86).

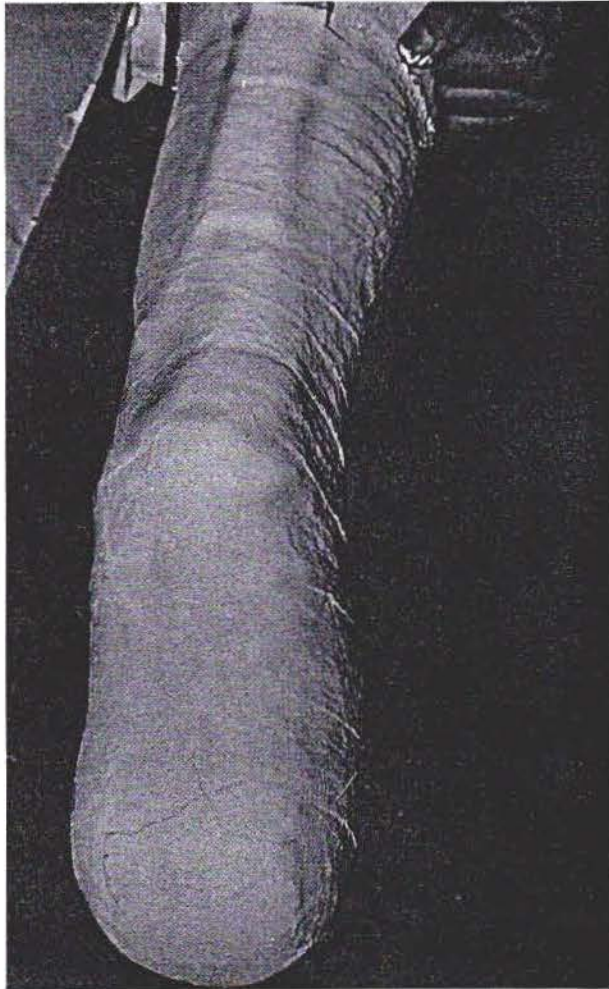


FIGURE 86

6. With the plaster of paris still wet, the cast is gently compressed with the base of each hand just proximal to the femoral condyles to provide an effective built-in suspension mechanism. Placement of the hands should be somewhat anterior from the lateral and medial centerlines of the cast. Care must be taken to compress proximal to the condyles and not over them. Repeated molding of the plaster must be avoided in order to allow the development of maximum plaster strength as it sets (Fig. 87).

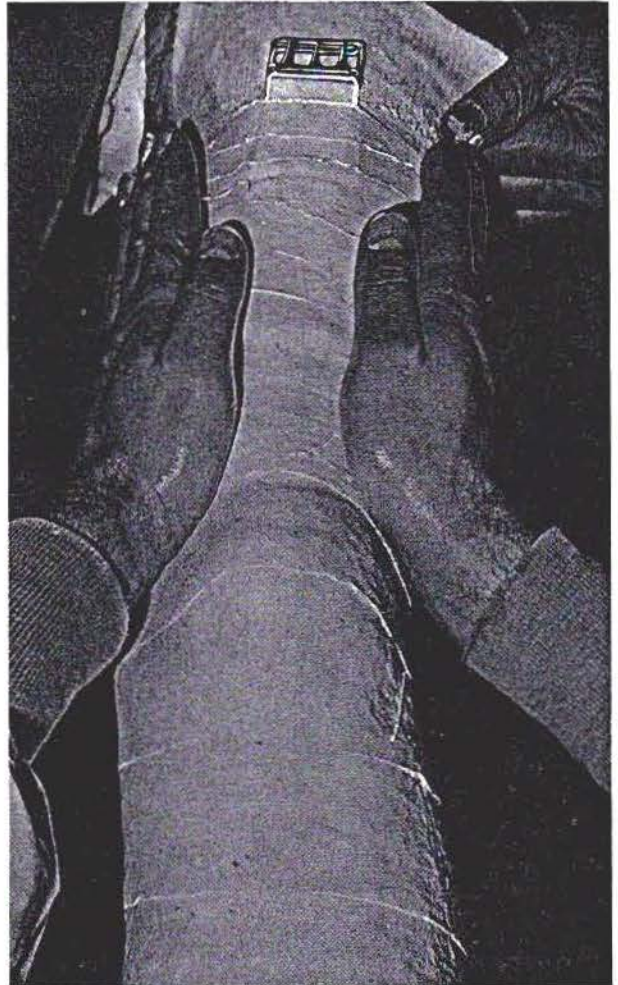

FIGURE 87

7. After the plaster has hardened sufficiently, the proximal tension on the stump sock is released. With a pair of scissors, a slot is cut in the stump sock at the level of and corresponding to the size of the safety buckle (or buckles for double suspension) (Fig. 88).



FIGURE 88



The sock is pulled down over the proximal cast brim and the buckle passed through the slot. The suspension belt is applied around the waist of the patient. The elastic webbing is attached to the suspension strap buckle. Thread the excess-elastic webbing through the lower attachment loop of the safety buckle and fold it back underneath the suspension strap (Fig. 89).

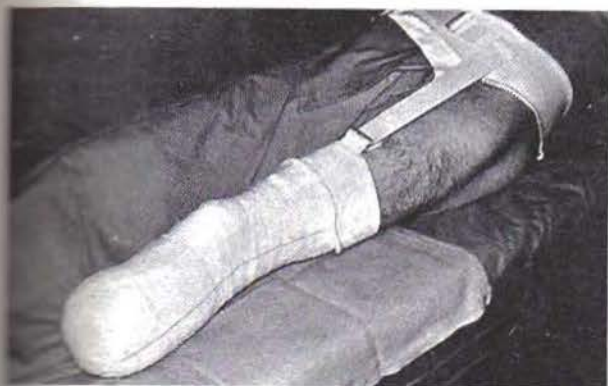

FIGURE 89

**DO NOT CUT OFF THE EXCESS ELASTIC WEBBING** since it will be needed later when the patient is in the short night cast which extends only to the patella.

*Note:* If the posterior lateral suspension strap is not required, simply remove it from the waist belt.

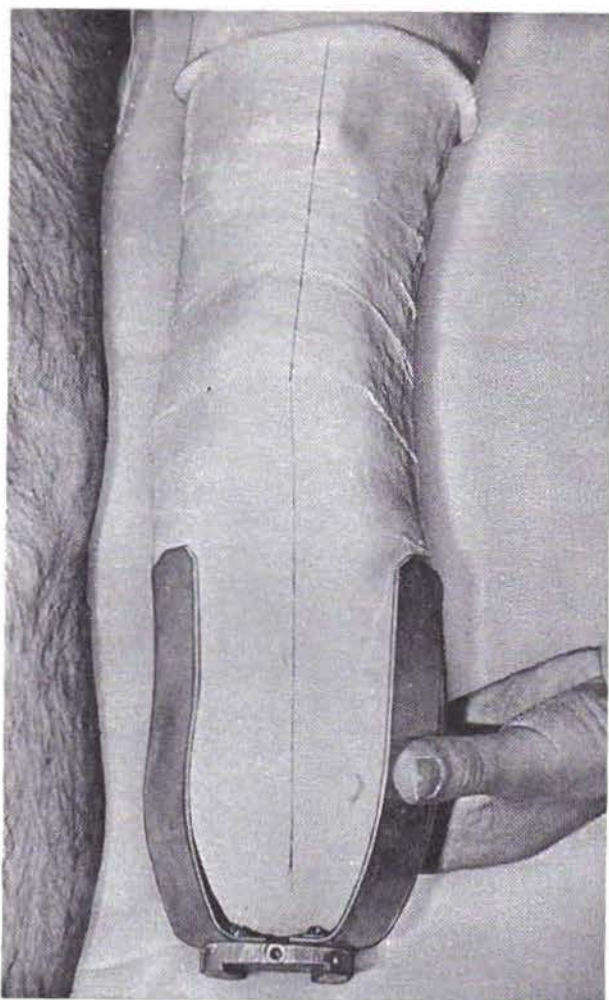


FIGURE 90

### C. APPLICATION OF THE PROSTHETIC UNIT

1. (a) Position the patient so that the pelvis is parallel to the foot edge of the operating table, with the knees about 1½ in. apart. **DO NOT LET THE SOUND LEG OR THE AMPUTATION STUMP EXTERNALLY ROTATE.** Bend the socket attachment straps so they closely conform to the exterior contour of the plaster socket (Fig. 90).

With the cast socket suspended approximately 1 in. from the table, the socket attachment plate should be 90 deg. to the table top when viewed laterally (Fig. 91).

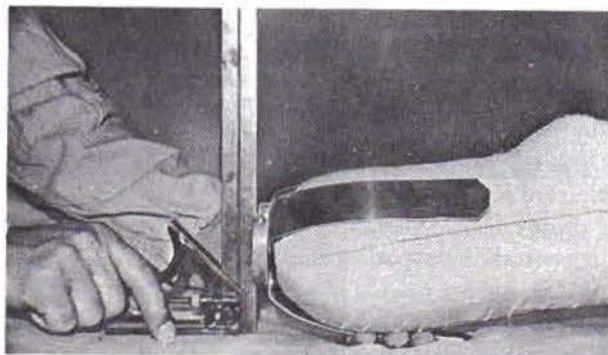


FIGURE 91



At the same time the socket attachment plate should be inset medially  $\frac{1}{2}$  in. from an imaginary line through the center of the knee and the center of the stump when viewed anteriorly (Fig. 92).

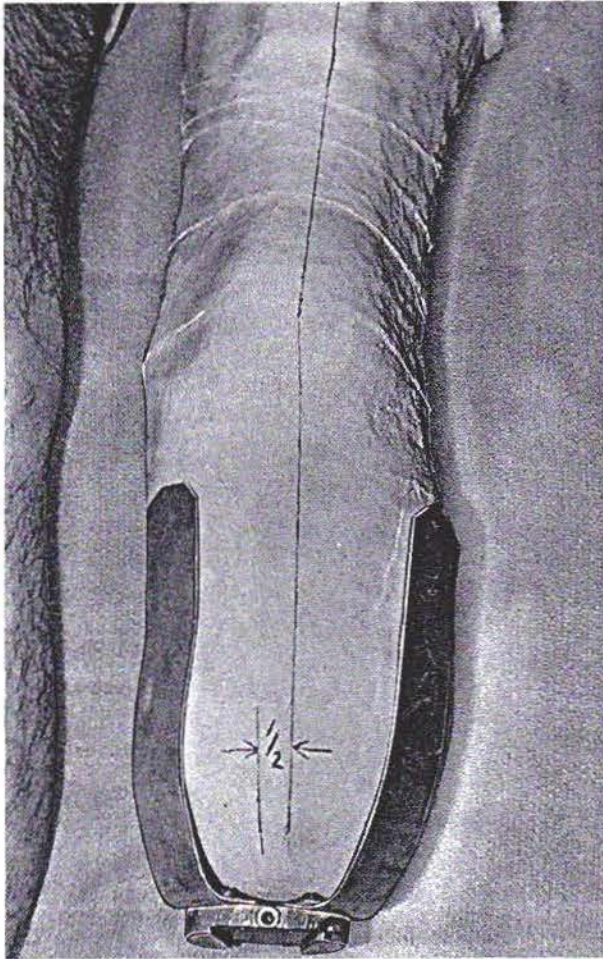


FIGURE 92

*Note:* The socket attachment straps must be located so they do not interfere with removal of the drain placed in the wound at surgery.

(b) Recheck the position of the socket attachment plate and with an indelible pencil mark the location of the straps on the cast socket (Fig. 93). Reasonable care given to this alignment procedure will result in proper bench alignment requiring little or no adjustment when the patient stands.

(c) Fold a double layer of 4 in. x 15 in. plaster splints three times and place them between the back of the socket attachment plate and the distal end of the cast socket (Fig. 94). Reapply the plate and straps

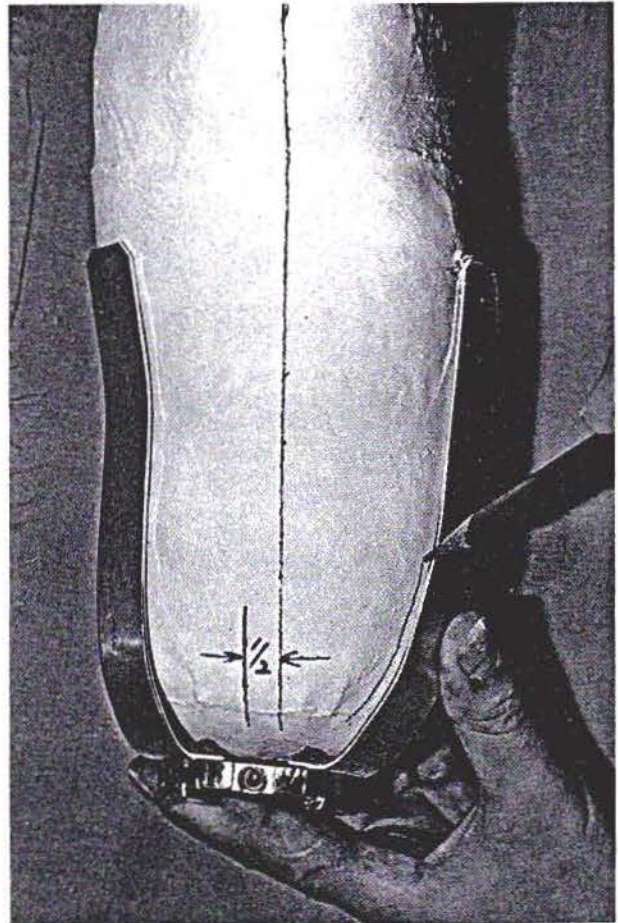


FIGURE 93

to the previously established marks and fill in all voids and hollows between the cast socket and the socket attachment plate.

*Note:* Loose and broken socket attachment straps result if this step is omitted.



FIGURE 94



2. Laminate the socket attachment straps to the cast socket with one roll of conventional plaster bandage, making sure that the straps are covered entirely all the way down to the socket attachment plate (Fig. 95).



FIGURE 95

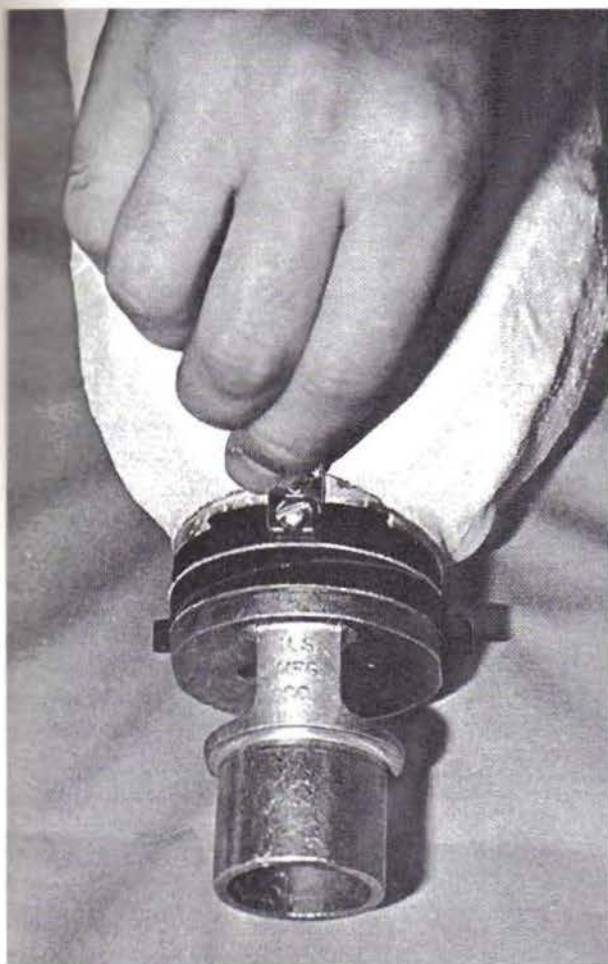

FIGURE 96

3. Assemble the adjustable prosthetic unit with all adjustments in the neutral position and attach to the socket attachment plate by means of the quick disconnect screw (Fig. 96).

4. (a) Attach the pylon tube to the foot. With the ankle of the sound foot (in the unilateral patient) held in neutral position and the knees approximately  $1\frac{1}{2}$  in. apart, the heel pad is compressed with a straightedge which is projected parallel with the bottom edge of the operating table across to the heel of a conventional artificial foot. The pylon tube will extend proximally up to the cast socket or beyond and is marked at the level of the collar of the base plug (Fig. 97).

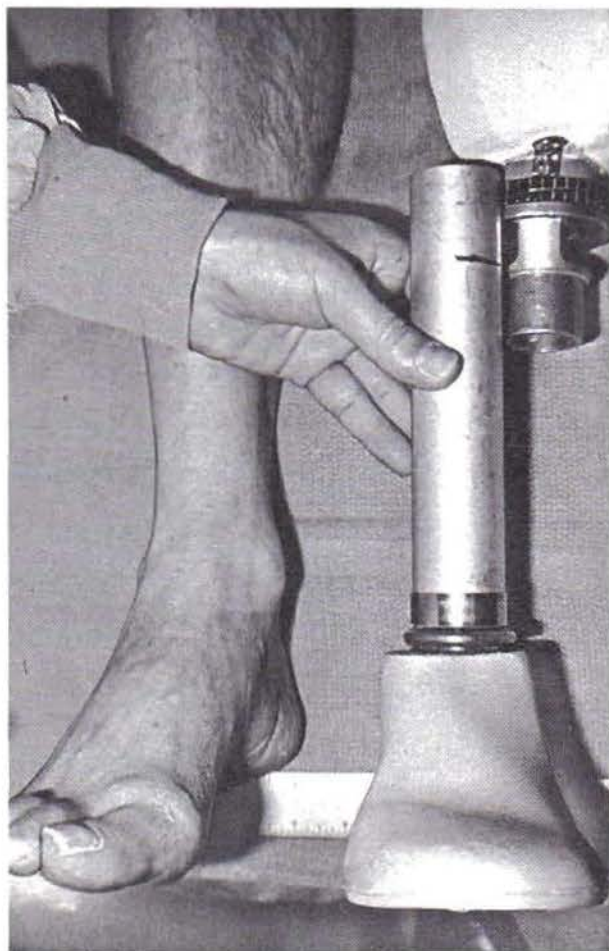


FIGURE 97

*Note:* When using a Kingsley Immediate Postsurgical SACH foot with built-in heel, add 1 in. to the overall length of the pylon tube to compensate for the thickness of the shoe on the patient's sound foot.



(b) At the established mark, cut the pylon tube with a tube cutter (Fig. 98).



FIGURE 98

(c) Remove the burr on the inside edge of the tube with the knife provided on the tube cutter, or with a reamer (Fig. 99).

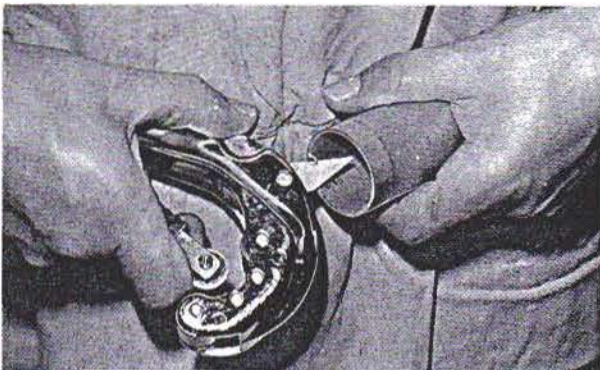

FIGURE 99

5. Remove the adjustable unit from the socket attachment plate by loosening the quick disconnect screw and connect the pylon tube to the base plug of the adjustable unit (Fig. 100).

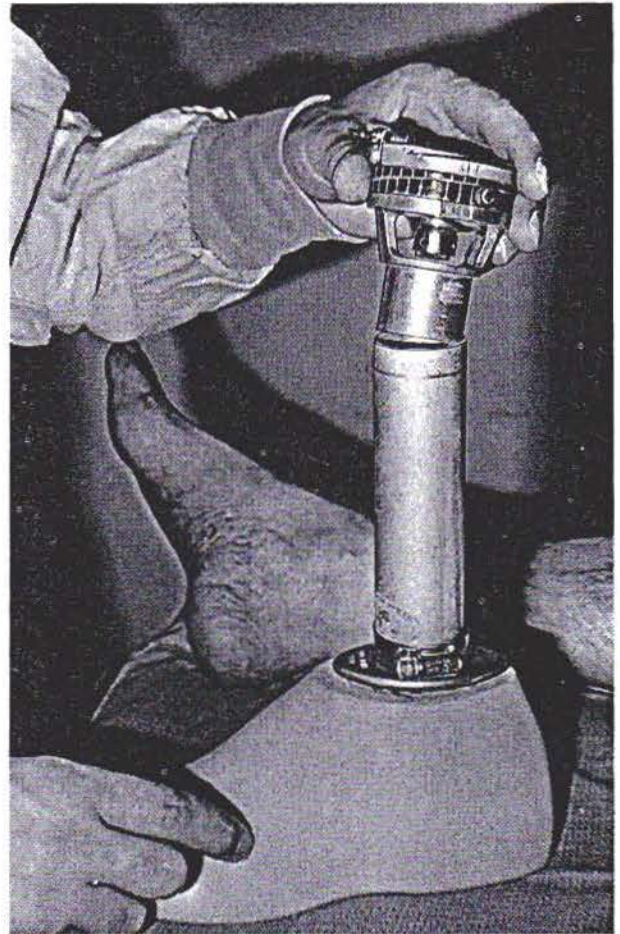


FIGURE 100

6. Reattach the adjustable unit to the socket attachment plate and establish approximate toe-out. Tighten the hose clamp connection around the pylon tube with a screwdriver, fastening it to the base plug. Do not split the pylon tube at this time (Fig. 101).

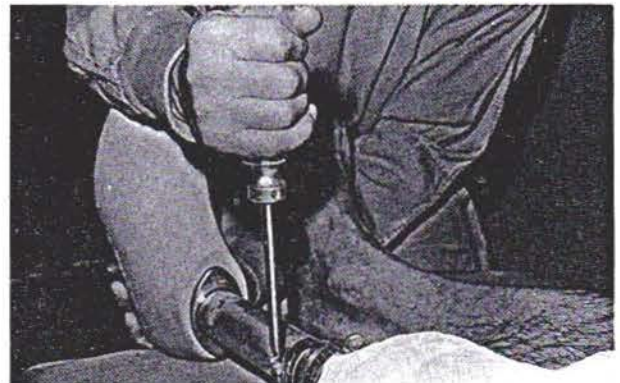

FIGURE 101



7. (a) With a sharp knife (scalpel) smoothly cut the plaster of paris at the area of the patella. Hold the knife horizontally to avoid injuring the patient or cutting the stump sock. Estimate the cut hole to be smaller than the previously applied patellar felt pad (Fig. 102).

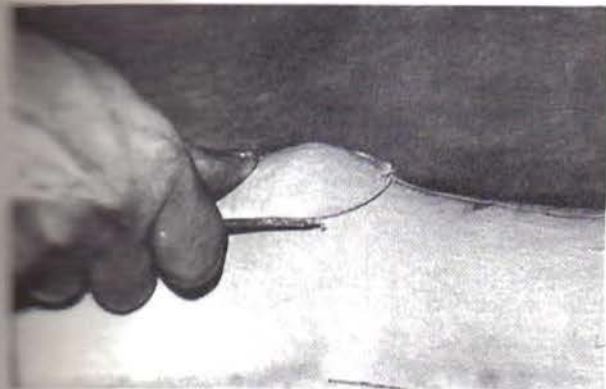


FIGURE 102

(b) After the plaster window has been removed, pull out the patellar felt relief pad. This will result in properly flared plaster edges and avoid abrasion and/or ulceration to the patella (Fig. 103).

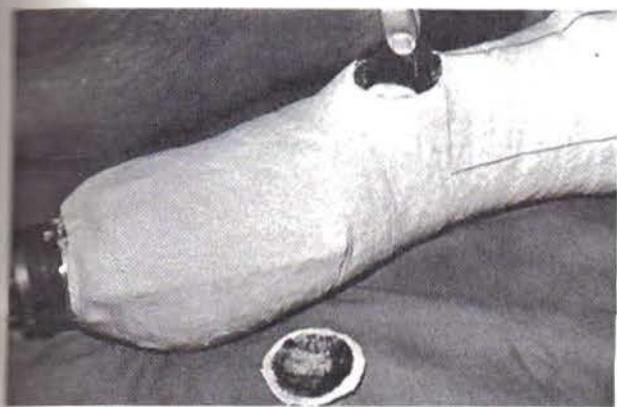

FIGURE 103

8. Figure 104 shows the completed assembly.

9. Detach complete assembly from socket attachment plate by means of the quick disconnect screw before the patient leaves the operating room (Fig. 105).

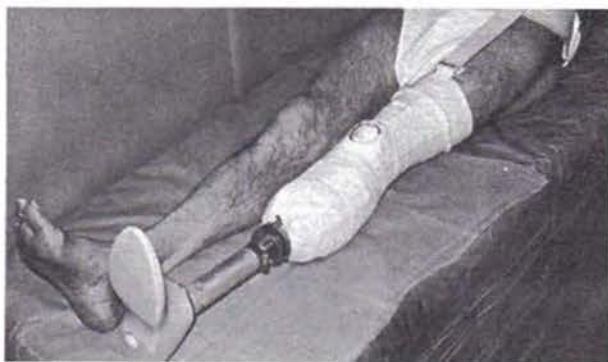

FIGURE 104

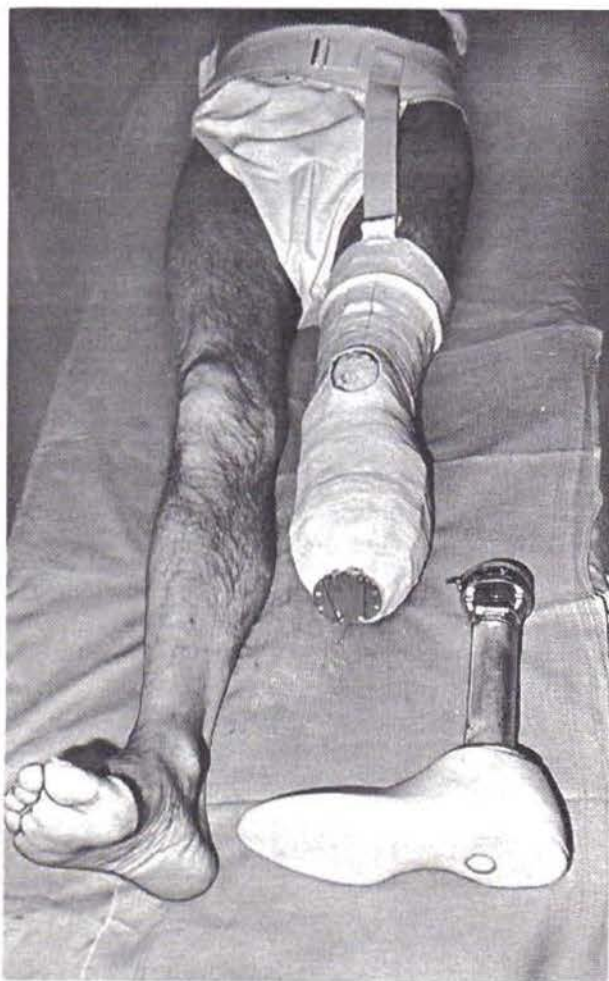

FIGURE 105

THE WHOLE PROCEDURE OF CAST APPLICATION SHOULD NOT TAKE MORE THAN 20 MINUTES WITH PRACTICE.

#### D. BELOW-KNEE PROSTHETIC CONSIDERATIONS

In applying the rigid dressing the prosthetist must think in terms of fabricating a perfectly fitting socket without having the opportunity to check the stump for factors requiring socket adjustments. More important, the application is to a fresh amputation stump, a wound sensitive to irritation, yet the initial socket is formed using a relatively rough and initially unstable material, i.e., plaster of paris. Appropriate care to detail is mandatory with relatively little latitude for error. Poor surgery cannot benefit from a well applied rigid dressing; good, precise surgery should not be impaired by a poorly applied cast socket. The two must complement one another to be effective. Avoid deviation from the technique.

1. The skived areas of the felt relief pads must end in a feathered edge or ridges will reproduce in the cast socket with obvious ill effects to the stump.

2. Improperly located felt relief pads are a frequently repeated mistake. The usual cause is not the lack of proper identification of the tibial crest and pad placement, but rather the increase or decrease in stump sock suspension by the assistant, causing displacement of the felt relief pads. Maintaining firm, even tension to the stump sock throughout the casting process is mandatory.

3. While making full use of the stretch characteristics of the elastic plaster bandage is recommended, avoid overstretching when reversing the direction of the wrap. The larger outer arc of bandage can form a ridge in the underlying plaster bandage and/or stump sock (example: Wraps 4 and 7).

4. Never turn or twist a plaster bandage so that it will bunch or have a rope effect. Use the full width of the bandage, partially overlapping each previous circumferential turn. If tucking distally appears to be a problem, use short plaster splints instead.

5. Avoid suspending the stump sock in such a manner that the proximal portion is pulling away from the thigh resulting in a loose cast in this area. At the same time avoid *proximal constriction* or cutting of the posterior socket brim into soft tissue.

6. An unstable cast usually results from terminating the rigid dressing below midthigh.

7. With the patient anesthetized, avoid forcing the knee into extension. Tightness of the hamstring tendons will cause discomfort to the patient. Painful distal socket pressure in the area of the gastrocnemius and cutting of the proximal socket brim into the posterior thigh will follow.

8. Avoid an overly thick cast.

9. Unless there are specific reasons, do not delay attachment of the socket attachment plate to the rigid dressing at the time of surgery. The cast socket must dry at least 24 hours and if attachment is delayed, so is the patient in his standing activities.

10. Do not attempt to secure the pylon tube to the base plug while the tube is attached to a wet cast socket. This practice could loosen the socket attachment plate and straps. Disconnect the adjustable prosthetic unit from the socket attachment plate with the disconnect screw before joining pylon tube and base plug.

11. I  
plate w/  
adjustal  
rigid dr  
need to

12. I  
benefit  
thetic u

13. A  
prosthe  
ing sur  
verted  
in refe  
prior to

14. C  
prove t  
surgica  
tic is lo  
ened s  
applic  
becom  
Trim t

Wh  
able to  
riodic  
tive m  
and m  
consul  
stay ir



## CHAPTER 3

# The Above-Knee and Knee-Disarticulation Amputations

### I. PREOPERATIVE INSTRUCTIONS TO THE PROSTHETIST

1. When notified by the surgeon, obtain from him all necessary information required and available at this time.

- a. Side of amputation.
- b. Proposed level of amputation if this information is available.
- c. Any additional physical defects of the patient which might restrict or limit movement and/or weight-bearing and ambulation activities.
- d. Any existing or permanent flexion contractures.

2. Talk to the patient, explain your role, what you intend to do, and what is expected of him. He may be apprehensive and anxious; don't make him more so. Explain the advantages to be derived from an immediate postsurgical prosthesis and from well-fitting prostheses, generally.

3. Consider any physical defects and/or flexion contractures noted by the surgeon which would influence casting and/or alignment of the prosthetic unit.

4. Take measurements for suspension waist belt.

5. Note approximate size of reticulated polyurethane distal pad required (3, 4, 5, or 6 in.). This interface material must be sterilized before application at surgery.

6. Note approximate size Orlon Lycra stump sock required (see Table 2, Chapter 2, Section I.6.). This sock must be gas autoclaved before application at surgery.

### II. PREOPERATIVE PREPARATIONS BY THE PROSTHETIST OF MATERIALS AND COMPONENTS

#### 1. PRS ABOVE-KNEE SUSPENSION WAIST BELT FOR ADULTS:

The adjustable suspension waist belt is manufactured

in five standard sizes and has been specifically designed and developed for immediate postsurgical prosthetic fitting. The sizes consist of extra small, small, medium, large, and extra large, for waist measurements ranging from 28 to 44 in. These are usually sufficient for all above-knee and knee-disarticulation applications. They are constructed for use on either right or left applications (Fig. 107).

After selecting the proper size, prepare the waist belt by removing the four distal suspension straps and buckles and the underlying portion of the felt apron opposite the amputation side (Fig. 108).




FIGURE 107




FIGURE 108



### ABOVE-KNEE SUSPENSION WAIST BELT FOR CHILDREN:

A proportionately smaller and simpler version of a suspension waist belt for children is custom made for each individual prior to surgery. The basic design consists of a 2-in.-wide cotton webbing waist section incorporating a safety buckle which is located on the amputation side. The waist section is lined with  $\frac{1}{8}$  in. cloth-type cotton felt which extends distally 8 in. to form the protective felt apron on the amputation side. The two shoulder and four cable suspension straps are made of 1-in.-wide cotton webbing and are sewn at one end to the waist section of the belt. These straps are adjustable by means of the corresponding safety buckles (Fig. 109).

#### 2. ABOVE-KNEE SUSPENSION CABLES:

The two stainless steel Bowden cables are provided with 1 in. strap retainers on both ends. A portion of the cables is covered by a wire housing which is enclosed in plastic tubing. Two sets LARGE and SMALL are sufficient for most applications.

LARGE: 22 in. cable length

15 in. housing length

SMALL: 18 in. cable length

11 in. housing length

If necessary, other than the above sizes can be prepared. However, for all applications, standard or special, retain a minimum 7 in. free cable travel to allow for a minimum of 90 deg. hip flexion.

3. Select and assemble an appropriate adjustable above-knee prosthetic unit and pylon (Fig. 110). The ideal above-knee unit should include all the characteristics of the below-knee unit and in addition, be capable of providing constant friction in the knee joint with a manual knee locking mechanism and extension stop.

4. Obtain a shoe from the patient at least one day prior to surgery and fit a SACH foot to it. If the patient is unable to furnish a shoe or if the shoe should be unsatisfactory for proper fitting and alignment, a Kingsley Immediate Postsurgical SACH foot is selected. A neoprene rubber heel can be glued to a conventional SACH foot to level it in order to achieve proper static and dynamic alignment of the prosthesis when the patient stands.

Although for the sake of uniformity and simplicity




FIGURE 109



THE MANAGEMENT OF LOWER EXTREMITY AMPUTATIONS  
 ABOVE-KNEE ADJUSTABLE PROSTHESIS

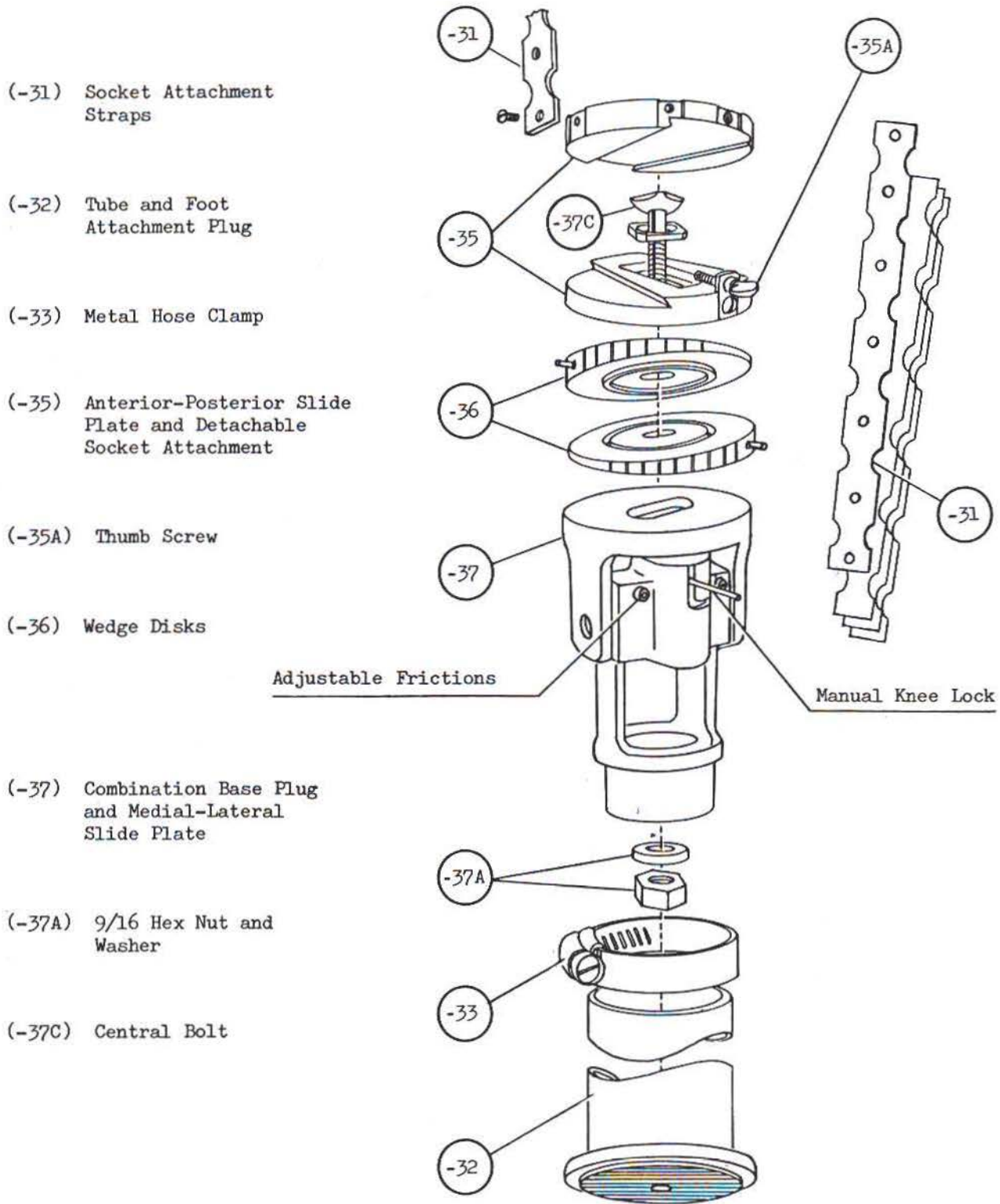


FIGURE 110

the SAC  
 ual, a m  
 sired or i  
 ankle jo  
 gical pr  
 ankle bl  
 with the  
 The tem  
 loaded r  
 dorsiflexi  
 knee stal  
 later stag



FIGURE 111

the SACH foot is demonstrated throughout this manual, a mechanical ankle can be substituted if so desired or indicated (Fig. 111). A temporary mechanical ankle joint and foot suitable for immediate postsurgical prosthetic pylon adaptation is the temporary ankle block and Hydra-Cadence foot designed for use with the Berkeley adjustable above-knee alignment jig. The temporary ankle block allows for a wide spring-loaded range of plantar flexion including an adjustable dorsiflexion stop (Fig. 112). This provides improved knee stability when the knee lock is released during the later stage of ambulation activities.

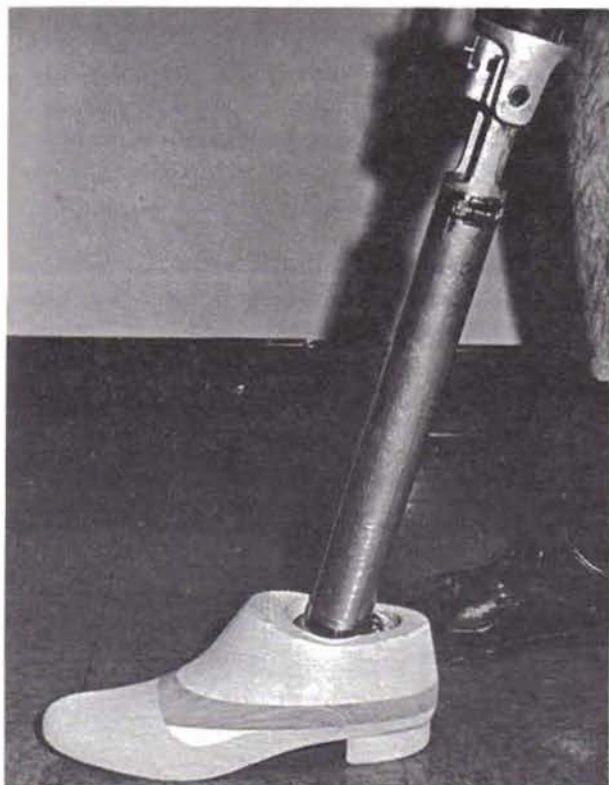

FIGURE 112

Regardless of how limited ambulation activities may be in the days following surgery, a certain rhythm or gait pattern is being established and provides the patient with a varying degree of stability and function. The extent to which the components of the immediate postsurgical prosthesis resemble the definitive prosthesis is directly reflected in the transition of one to the other. If these components differ substantially (a friction knee versus a hydraulic swing-phase control unit, or a SACH foot versus a mechanical ankle joint) the patient is forced to adopt a new gait pattern to compensate for the new sensation and prosthetic function.

If a hydraulic knee is indicated or required, the Hydra-knee swing-phase control unit mounted in a Hydra-Cadence frame and adapted to pylon use, can be quickly interchanged with the conventional constant friction knee pylon since the two types have identical adjustable prosthetic units and disconnect features (Fig. 113 and 114).



FIGURE 113



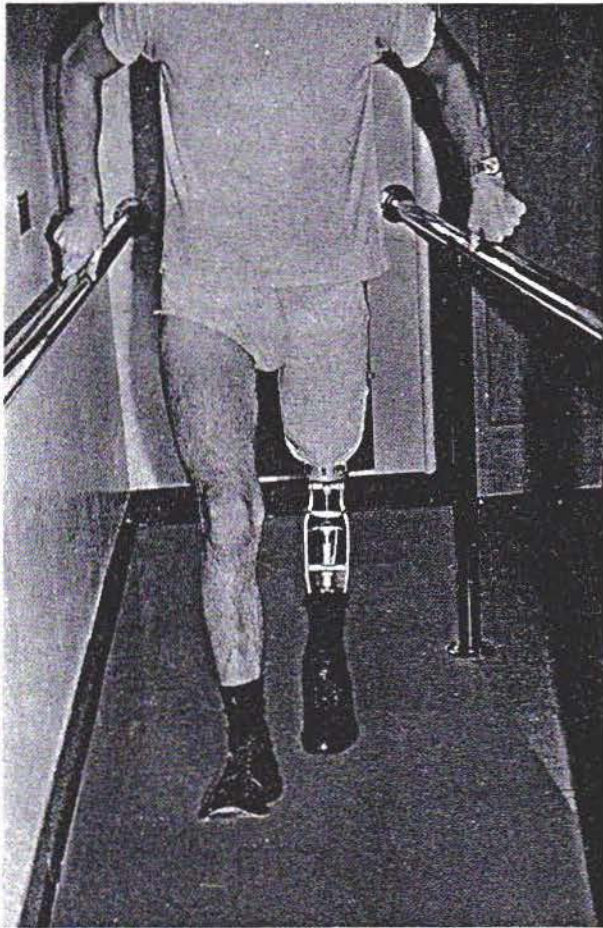


FIGURE 114

Using these available interchangeable units and components enables a simple, quick, and reasonably accurate assessment of prosthetic performance and determines patient requirements even prior to the time when the stump is ready for cast and measurements for the definitive prosthesis. This procedure provides the entire clinic team with an economical and effective diagnostic tool to determine the most suitable prosthetic component to be used in the patient's definitive prosthesis.

5. Assemble components and materials required for above-knee or knee-disarticulation rigid dressing application (Fig. 115) (see Appendix B for List of Suppliers):

- a. Sterile interface material (reticulated polyurethane end pad)
- b. Sterile Orlon Lycra stump sock
- c. 25 in. long, 6 in. wide bias-cut stockinet or equivalent




FIGURE 115

- d. Knee-disarticulation felt relief pad, if required
  - e. Above-knee suspension belt
  - f. Above-knee suspension cables
  - g. Prosthetic unit, tubing, and hose clamp to form immediate prosthesis
  - h. Immediate postsurgical SACH foot with bolt
  - i. Dow Corning Medical Adhesive Spray, Type B
  - j. 3 rolls of 5 in. elastic plaster bandage
  - k. 2 rolls of 4 in. conventional plaster bandage, extra fast setting
  - l. 9 plaster splints, 4 in. x 15 in., extra fast setting
  - m. PRS above-knee casting fixture, right or left
6. Assemble kit of tools required for fitting prosthesis immediately after surgery (Fig. 116). All tools except stainless steel tools, have been stripped, polished, and chromed to allow for repeated sterilization when required.

- a. Straightedge
- b. Tube cutter
- c. Metal shears
- d. Common screwdriver

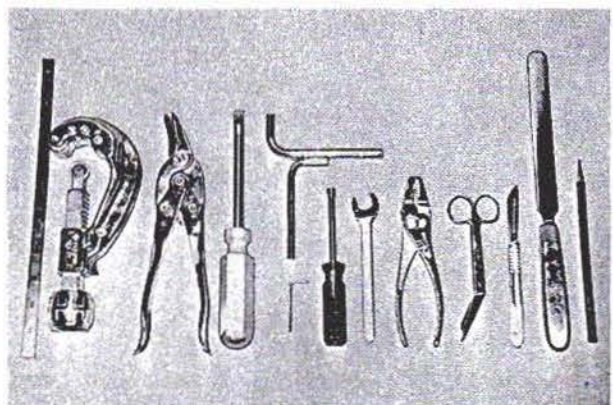


FIGURE 116

e.  
brazed  
f.  
g  
model  
h  
i.  
j.  
k

The  
mann  
on the  
inflate  
quate  
throug  
ally a  
bone  
flaps  
appre  
at the  
fascia  
of int  
be pr  
ampu  
Th  
a larg  
muscl  
bone  
espec



- e. 5/16 in. Allen wrench and 3/8 in. Allen wrench brazed together
- f. 3/32 in. Allen wrench for VAPC unit
- g. 9/16 in. open end wrench (for use with newer model prosthetic unit)
- h. Pliers
- i. Bandage scissors
- j. Scalpel and/or skiving knife
- k. Indelible pencil

### III. THE ABOVE-KNEE AMPUTATION SURGERY

The patient is prepared for surgery in the usual manner. When possible a tourniquet is provided high on the involved extremity. The tourniquet should be inflated only when the circulation is found to be adequate. A standard ("fish-mouth") incision is made through the skin to depth of the fascia starting medially and laterally just distal to the level of intended bone transection. Short equal anterior and posterior flaps are formed, each of which measures in length approximately two-thirds of the diameter of the thigh at the level of amputation. The skin flaps including fascia are carefully dissected proximally up to the level of intended bone transection. Generous skin flaps must be provided to avoid a common error in above-knee amputation—wound closure under excessive tension.

The anterior musculature is divided sharply with a large scalpel blade or with an amputation knife. The muscle is sectioned well beyond the level of intended bone transection to permit muscle stabilization. It is especially important that the anterior muscle flap, i.e.,

the quadriceps flap, is left moderately long since it will be used in the combination myodesis-myoplasty for stabilizing the muscles. The bone is sectioned, then major vessels and nerves are treated appropriately, and the amputation completed leaving the muscles long. The posterior fascial-cutaneous flap should be left adequately long laterally and medially for appropriate coverage and closure.

Stabilization of muscles in the above-knee amputation is now carried out. A tension myodesis is formed by placing approximately six drill holes circumferentially around the distal cortex of the femur using a 3/16 in. drill. Muscles are then sewn with appropriate sutures, fixing the muscle groups to the bone while distal traction is applied to the muscles so that their resting length can be maintained. Care must be taken not to sew the muscle groups in such a way as to produce a flexion or adduction contracture. The long anterior flap is then left intact after other muscle groups have been sectioned about 1 in. distal to the end of the bone suture line. The anterior flap is pulled over the end of the bone and sewn to the fascia overlying the posterior group as described by Murdoch (11) (Fig. 117).

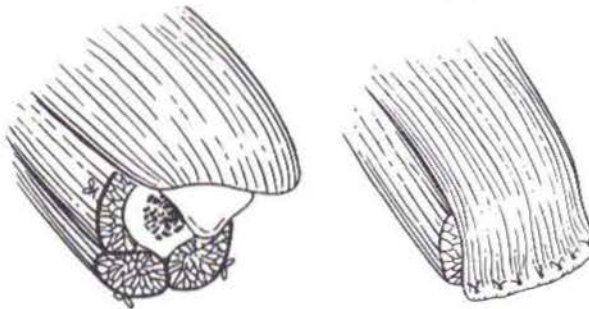


FIGURE 117



Stabilization of muscles in the above-knee amputation is essential. If circulation to the thigh musculature is tenuous, mattress sutures should not be placed through the bulk of the muscle but can be placed through the deepest fascia layer. The fascia overlying the respective muscle groups is then used to stabilize the thigh musculature over the end of the bone. Thinning of the muscle groups may be necessary to reduce muscle bulk prior to stabilization (Fig. 118, 119, 120, and 121).

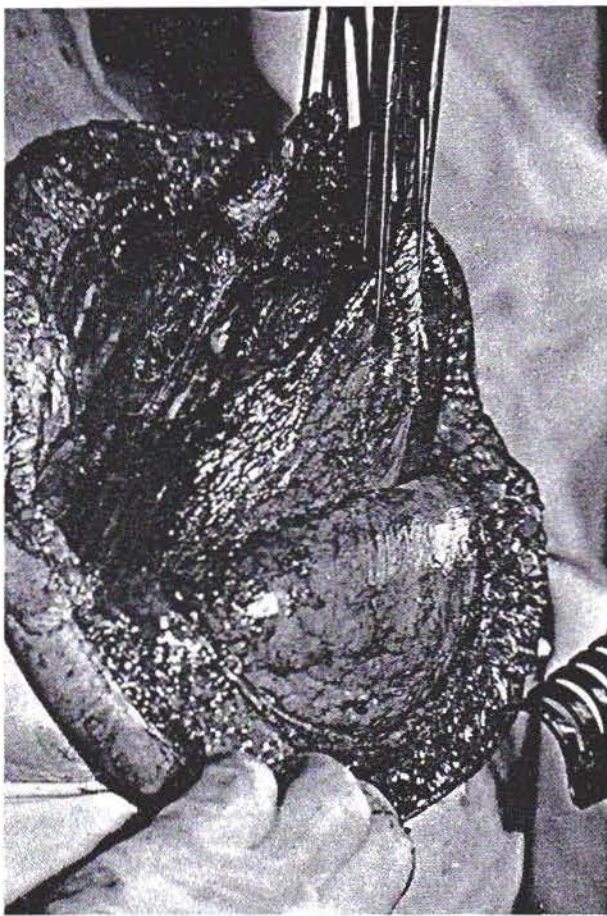


FIGURE 118.—Above-knee equal flap amputation with major muscle groups prepared for stabilization.

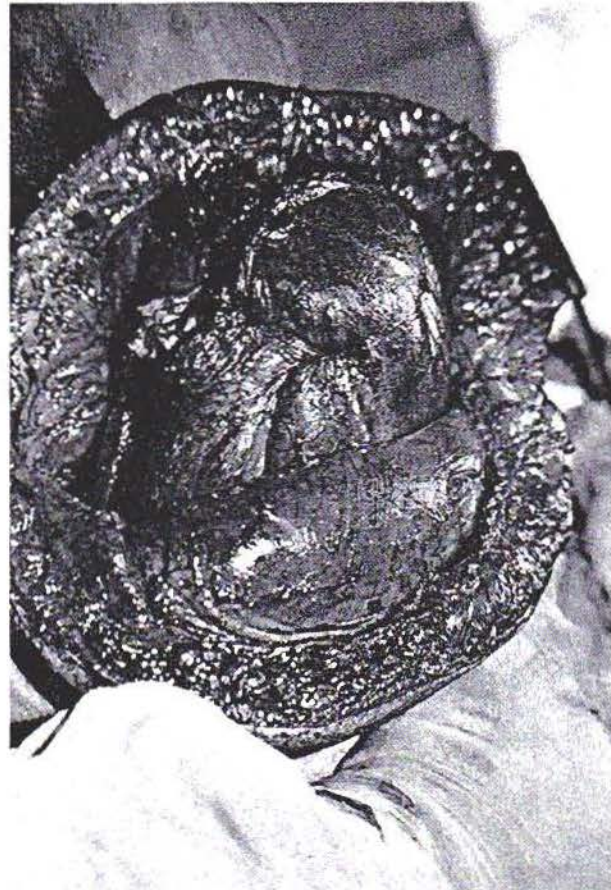

FIGURE 119.—Muscle stabilization by myodesis-myoplasty.

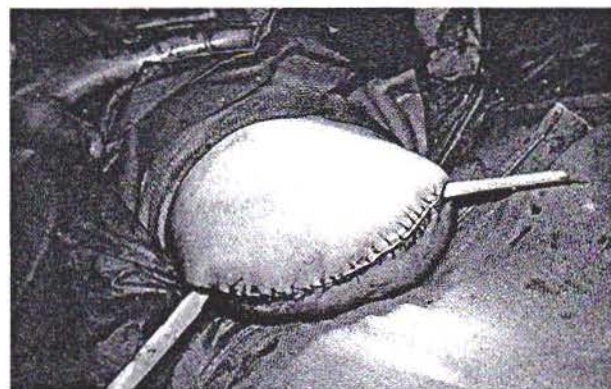


FIGURE 120.—Wound closure with drainage.



FIGURE 121

IV.

Knee the prior disease. lack of provide toleranc an a] prosthes is accep cluding limb.

The terior I we perf posterio the san in the c prefer t knee di

Und tion, ar the am with a lever a opport knee r terconc ance at

Kne postsur ful. Th with a stabiliz



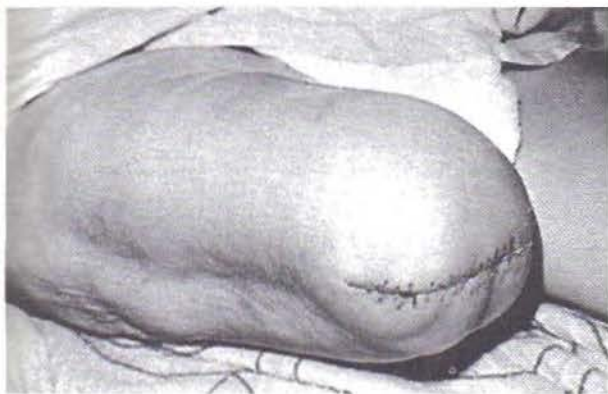

FIGURE 121.—Healed above-knee stump with muscular cylindrical configuration.

#### IV. THE KNEE-DISARTICULATION SURGERY

Knee disarticulation is used by many surgeons as the primary major amputation for peripheral vascular disease. It has the advantages of simplicity, relative lack of surgical shock, and modest blood loss. It can provide an effective endbearing stump which has good tolerance to weight bearing and fits comfortably in an appropriate prosthesis. Knee-disarticulation prostheses have so improved recently that appearance is acceptable; also most intrinsic knee mechanisms including hydraulic assists can be incorporated into the limb.

The classical knee disarticulation utilizes a long anterior flap. With the below-knee amputation which we perform for peripheral vascular disease using long posterior musculotendonous and skin flaps, essentially the same anterior skin is utilized as would be needed in the classical knee disarticulation. For this reason we prefer the below-knee amputation and seldom employ knee disarticulation in the ischemia patient.

Under other circumstance, specifically trauma, infection, and neoplastic disease, knee disarticulation may be the amputation of choice. This is particularly the case with active, younger males. The long, strong, femur lever arm, the broad irregular distal condyles, and the opportunity to stabilize surgically the powerful cross-knee musculotendonous structures into the femoral intercondylar notch make for excellent prosthetic tolerance and function.

Knee-disarticulation management with immediate postsurgical prosthetic fitting has been quite successful. The surgery is performed in the classical manner with a long anterior skin flap. Muscles are routinely stabilized according to the technique of Murdoch (11)

suturing the patellar tendon to the remaining stump of the cruciate ligaments in the intercondylar notch and also drawing one or more of the medial hamstring tendons and biceps tendon into the notch thus stabilizing the hamstring muscles also. The patella is ordinarily not disturbed. The condyles of the femur are not shaved nor rounded unless unusually prominent. The synovium is not removed. The articular cartilage on the distal femur is not disturbed. Suction and/or Penrose drainage is routinely used. Postsurgical drainage is essential.

The resulting stump is strong with good quadriceps and hamstring muscle power. The somewhat bulbous terminal bony portion of the stump resulting from the contours of the condyles and patella can be easily managed by a flexible prosthetic insert. The thigh portion of the socket need not be "fluted" to accept the stump. This somewhat bulbous and irregular contour augments rotatory stability of the stump within the socket and increases the effectiveness of the stump-socket control (Fig. 122, 123, 124, and 125).

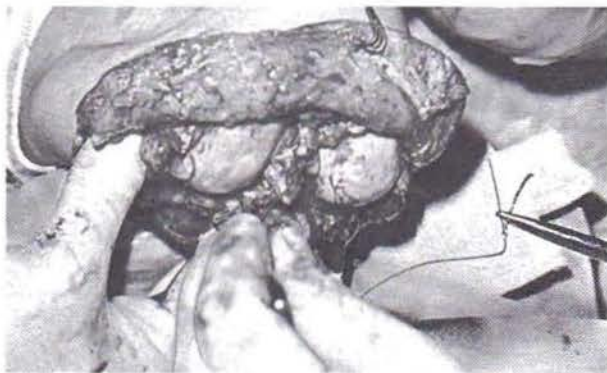


FIGURE 122.—Patellar tendon and hamstring muscles sutured under tension in the intercondylar notch.

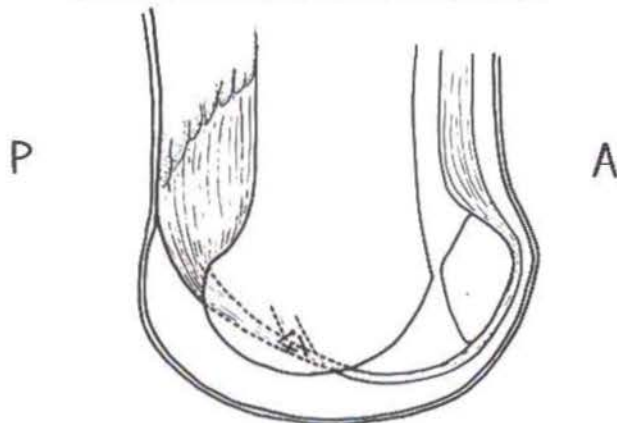


FIGURE 123.—Schematic drawing of Figure 122.



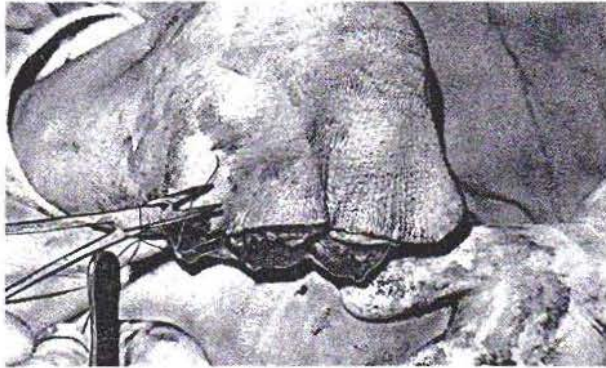


FIGURE 124.—Anterior skin flap trimmed to appropriate length.

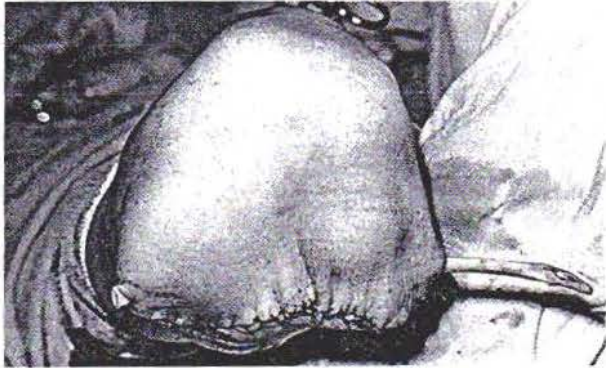


FIGURE 125.—Distal appearance of closure with drain in place.

## V. THE ABOVE-KNEE AND KNEE-DISARTICULATION IMMEDIATE POSTSURGICAL PROSTHESIS

### A. PREPARATORY REQUIREMENTS BEFORE APPLICATION OF THE RIGID DRESSING

1. Position the patient on the operating table so that the entire stump and buttock area extends well over the side of the table. The sterile Orlon Lycra stump sock, which is rolled on under tension to the level of the perineum by the surgeon, is now cut vertically at the region of the adductor longus (Fig. 126).

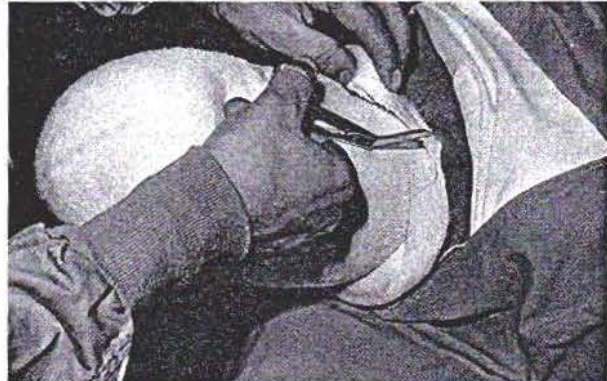

FIGURE 126

A second cut is made 1 to 1½ in. posterior to the initial cut (Fig. 127).

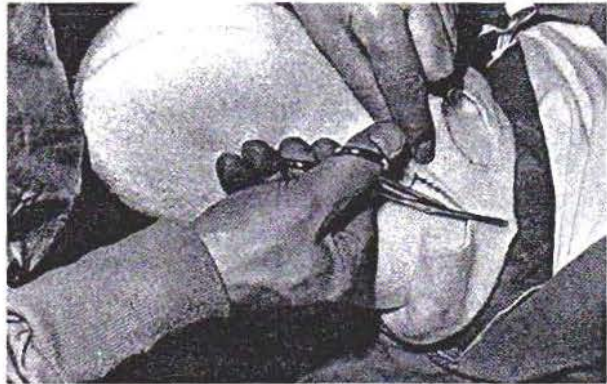


FIGURE 127

The desired depth of the cuts extends ½ in. distal to the perineum when the assistant is applying firm proximal pull on the stump sock. Tissue bunching such as an adductor roll or cutting of the stump sock into soft tissue causing tissue displacement must be avoided. Stump sock tension is satisfactory when the medial distal stump area appears well supported and compressed by the proximal pull on the stump sock. Note to what level the proximal portion of the stump sock extends on the lateral aspect of the hip or waist (Fig. 128).

2.  
expos  
holdi  
NOT  
STU



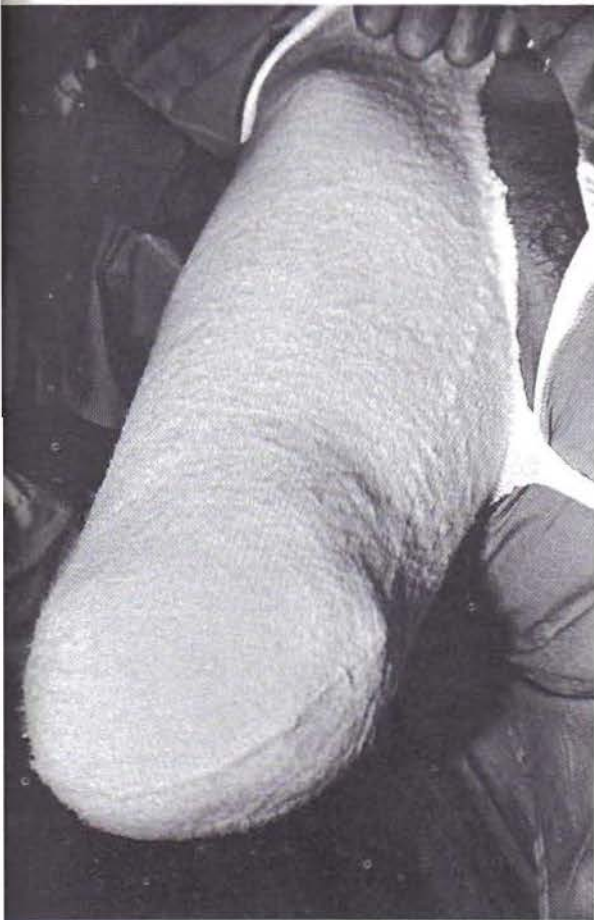


FIGURE 128

2. Fold back the proximal portion of the stump sock exposing the upper two-thirds of the stump, while holding the distal portion of the sock in place. DO NOT EXPOSE THE DISTAL THIRD OF THE STUMP OR THE WOUND ITSELF (Fig. 129).

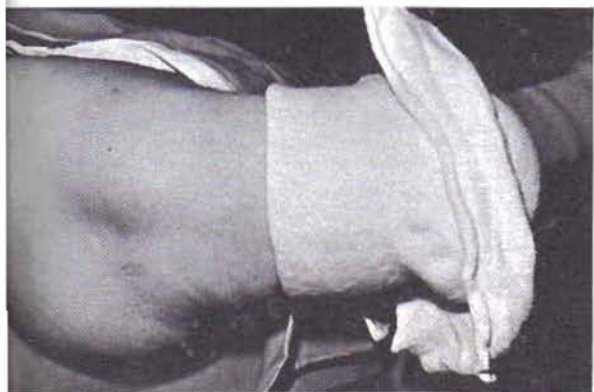


FIGURE 129

The exposed skin including the waist and hip, and the entire inner surface of the stump sock are sprayed with Dow Corning Medical Adhesive, Type B (Fig. 130). Allow 5 seconds for the adhesive to become tacky.

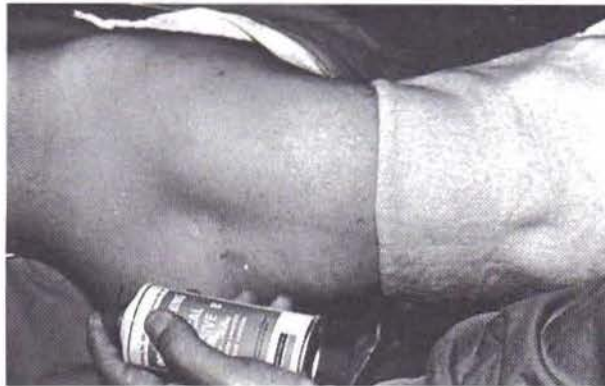

FIGURE 130

3. Insert both hands between the stump sock and its folded back portion and stretch the material by expanding the hands in a lateral-proximal fashion. Slowly reapply the stump sock with firm even pressure, avoiding wrinkles in the application (Fig. 131). An assistant is useful in this application but not absolutely necessary.

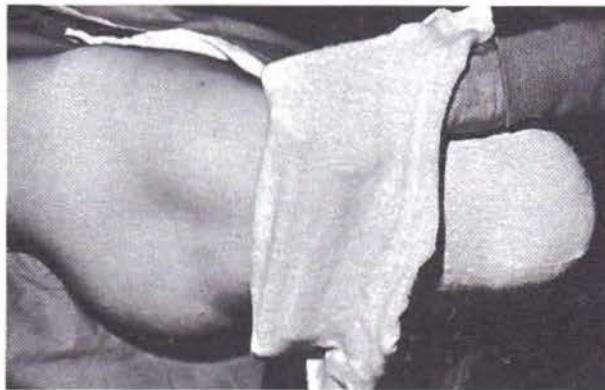


FIGURE 131



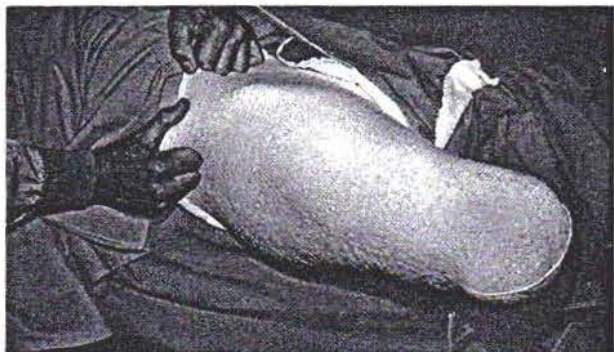

FIGURE 132

4. The proximal portion of the stump sock is held suspended by an assistant (Fig. 132) or by the shoulder suspension harness (Fig. 133).

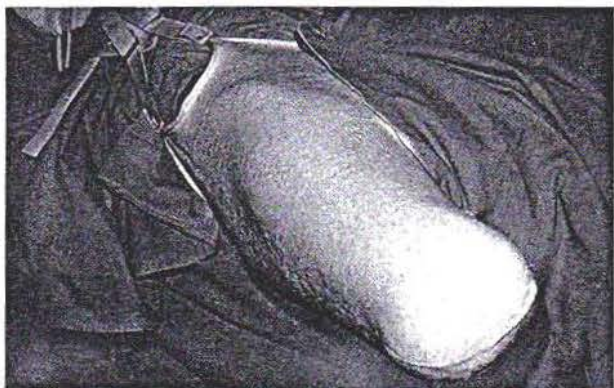


FIGURE 133

5. A 25-in.-long, 6-in.-wide bias-cut stockinet or equivalent is prepared by spraying one of the long borders 2 in. wide with Dow Corning Medical Adhesive, Type B (Fig. 134).




FIGURE 134

Also spray medical adhesive on the stump sock in a 2-in.-wide circle starting at the proximal border in the perineum, the Scarpa's triangle, over the rectus femoris to an area just proximal to the greater trochanter. Posteriorly stay slightly below the gluteal fold and the level of the ischial tuberosity (Fig. 135, 136, and 137).

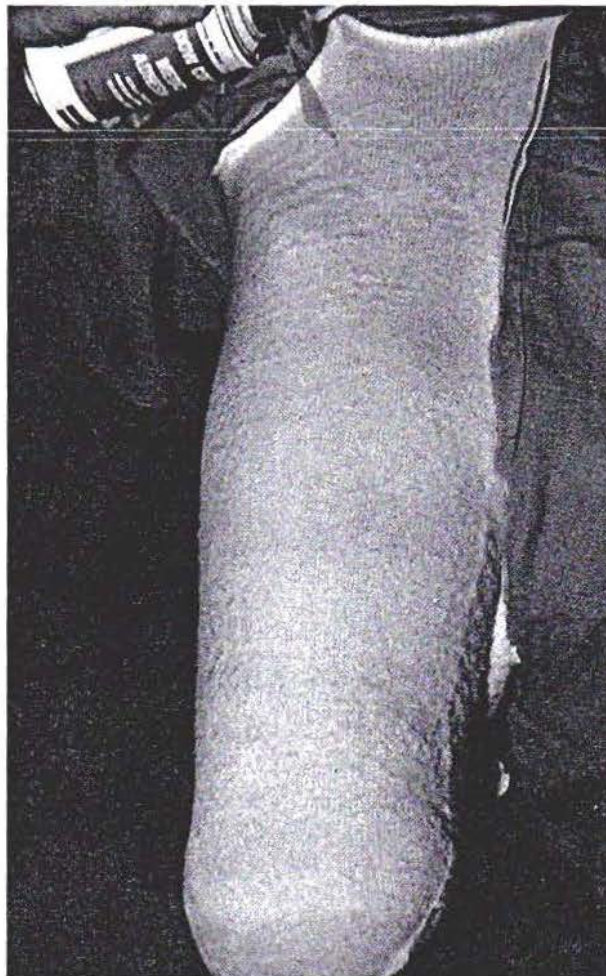

FIGURE 135



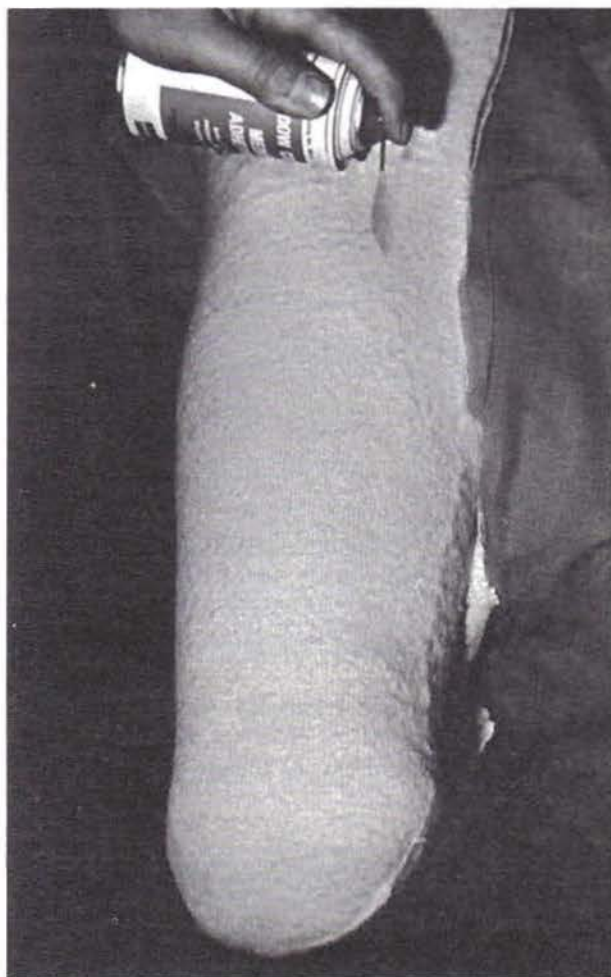

FIGURE 136



FIGURE 137

Allow 5 seconds for the adhesive to become tacky and apply the perineal apron by applying some stretch to the stockinet which will avoid wrinkles in the material (Fig. 138 and 139).

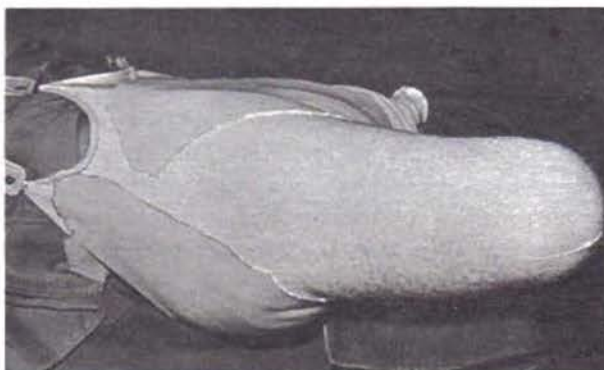


FIGURE 138

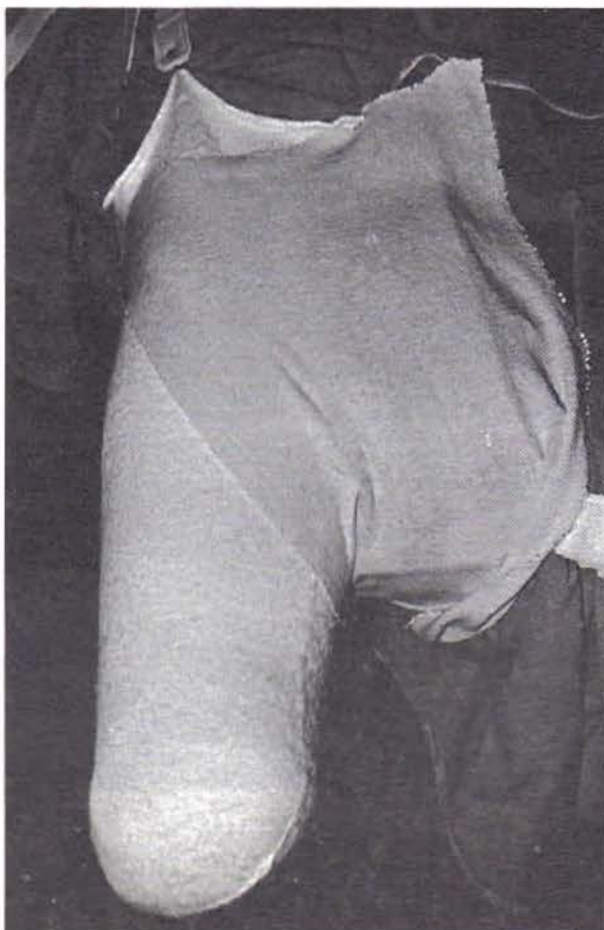

FIGURE 139



6. To avoid circumferential socket displacement, the rigid dressing or cast socket, is contoured into a modified quadrilateral shape. The PRS above-knee casting fixture developed for this purpose is fitted with the stump usually in an adducted and slightly flexed position. The anteroposterior dimension is approximately  $\frac{1}{2}$  in. larger than one would normally use in constructing an ischial weight-bearing socket. This procedure places the ischial tuberosity inside the cast socket and *not* on the posterior socket wall. This results in a gluteal weight-bearing situation only, which prevents possible proximal constriction to blood flow by the rigid dressing, and assures distal tissue support (Fig. 140).

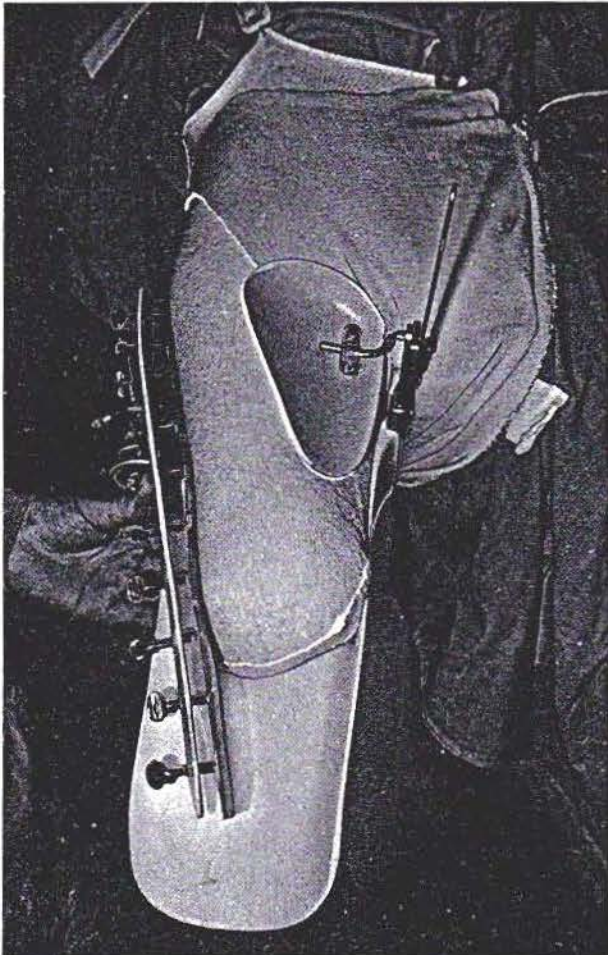


FIGURE 140

The mediolateral dimension is adjusted and secured followed by the lateral wall being shaped to the contours of the femur by means of the lateral adjustment screws (Fig. 141).




FIGURE 141

Once all adjustments have been completed, the handle of the PRS above-knee casting fixture is placed in the open position and the fixture is removed from the stump. To compensate for the initial elastic plaster bandage wrap, the anteroposterior and mediolateral dimensions of the fixture must be increased between  $\frac{1}{4}$  and  $\frac{3}{8}$  of an inch.

7. A sterile reticulated polyurethane distal pad of the proper size is selected, trimmed, and skived and applied over the distal end of the stump (Fig. 142).




FIGURE 142

#### B. APPLICATION OF THE RIGID DRESSING

1. For the initial wraps, elastic plaster bandage is used rather than conventional plaster. When using an elastic plaster bandage, the elasticity provides safe and beneficial compression of the stump while conforming well to its contours, providing a smooth rigid dressing. *Continuous tension must be maintained on the stump sock until the plaster has hardened.*

#### Wraps

The  
pect of  
of the  
bandag  
with th  
stump  
viewed



One  
cure th  
the ela



#### Wrap

The  
bring  
tion of  
to the  
rior st  
wrap  
pull or



**Wraps 1 and 2:**

The wrap is always started on the distal lateral aspect of the stump. Cover the proximal feathered edge of the polyurethane distal pad with the elastic plaster bandage. Minimal tension is applied to the bandage with this circumferential wrap, clockwise for a right stump and counterclockwise for a left stump when viewed anteriorly (Fig. 143).

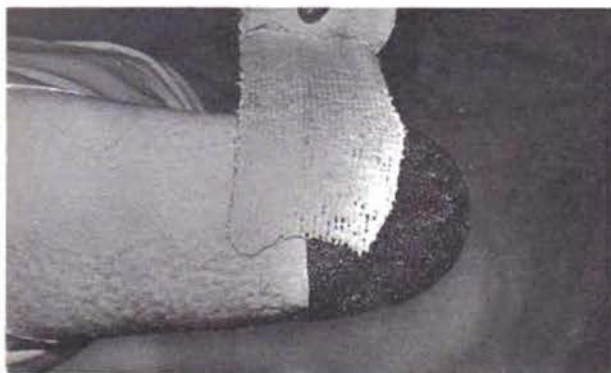


FIGURE 143

One and three quarter circumferential turns will secure the polyurethane distal pad in place and anchor the elastic plaster bandage to itself (Fig. 144).

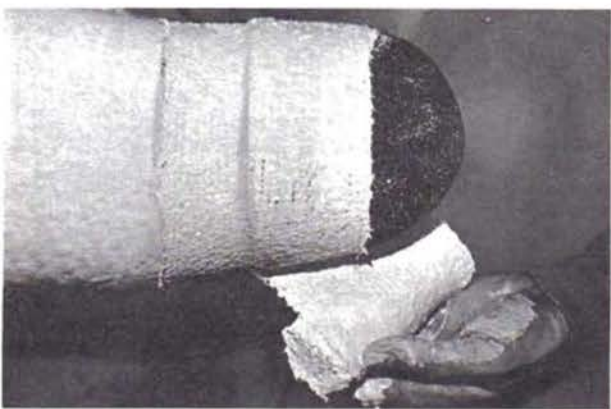

FIGURE 144

**Wrap 3:**

The wrap is now at a point posterolaterally. Now bring it anteriorly up over the distal *LATERAL* portion of the stump pulling the plaster bandage almost to the limit of its elasticity (Fig. 145). At the anterior stump margin release the tension and carry the wrap medially and then posteriorly with only a light pull on the plaster bandage.

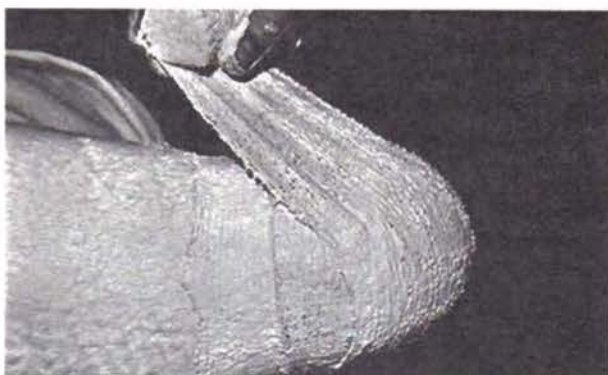

FIGURE 145

**Wrap 4:**

The fourth wrap is almost identical to wrap 3 except that now the bandage covers the distal *CENTER* of the stump (Fig. 146) (bandaging in the A-P plane rather than circumferentially or diagonally). The direction of the wrap is altered anteriorly and carried toward the lateral side of the stump, as if to resume circumferential wrapping.

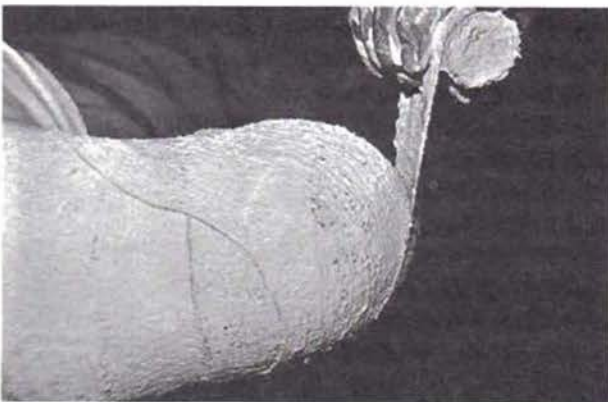


FIGURE 146



**Wrap 5:**

The fifth turn is brought anteriorly up over the distal *MEDIAL* aspect with the same controlled tension to the bandage (Fig. 147).

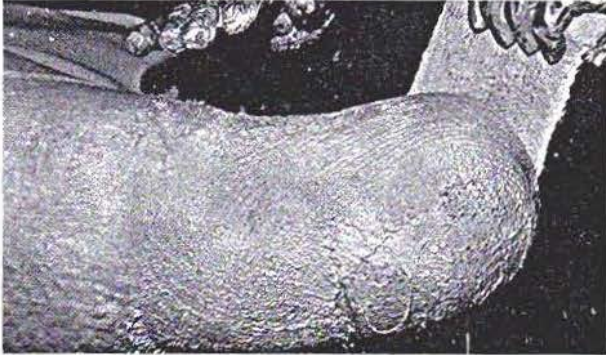


FIGURE 147

**Wrap 6:**

To achieve desired cast strength, a second diagonal layer of elastic plaster bandage is applied by repeating wrap 5 (Fig. 148).

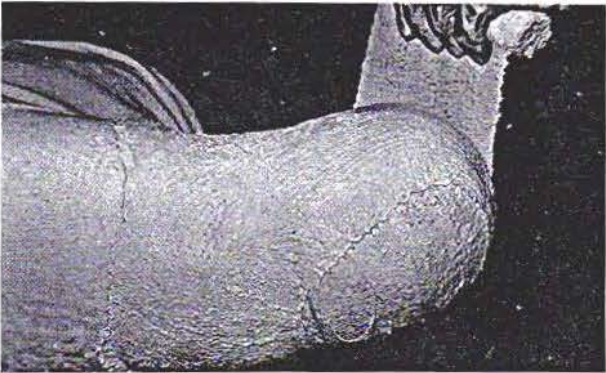


FIGURE 148

**Wrap 7:**

. . . followed by wrap 4, again altering the direction of the wrap medially. This will cover the distal *CENTER* of the stump with the second layer of plaster (Fig. 149).

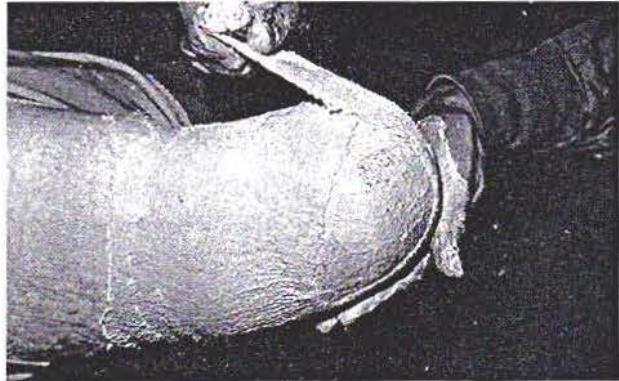


FIGURE 149

**Wrap 8:**

Repeating wrap 3 will now cover the distal *LATERAL* stump with the second layer of plaster bandage (Fig. 150).

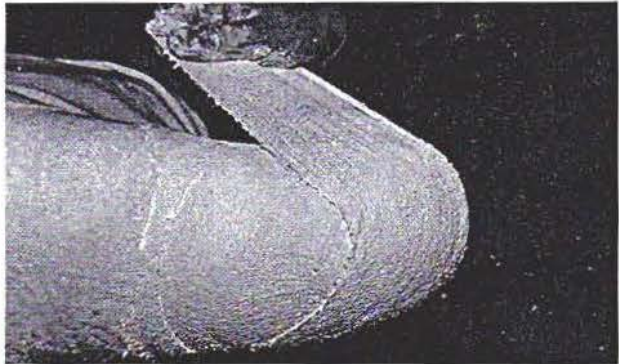


FIGURE 150

The remainder of the elastic plaster bandage is wrapped in a circular manner proximal on the stump, overlapping partially each previous turn (Fig. 151).

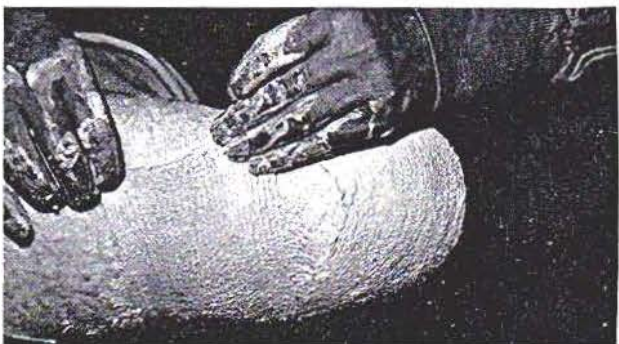


FIGURE 151

2.  
sock,  
slight  
termi



2. Still maintaining continuous tension on the stump sock, a second roll of elastic plaster bandage is started slightly distal to the level where the previous wrap terminated (Fig. 152).

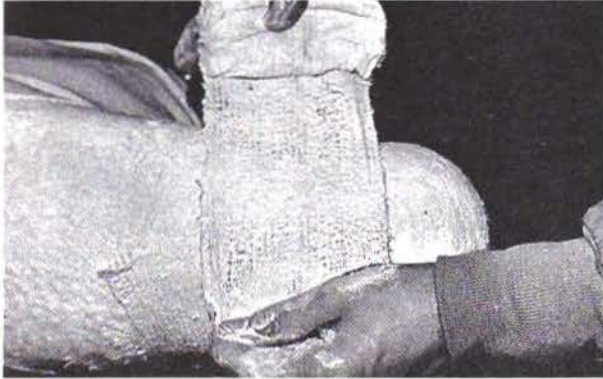

FIGURE 152

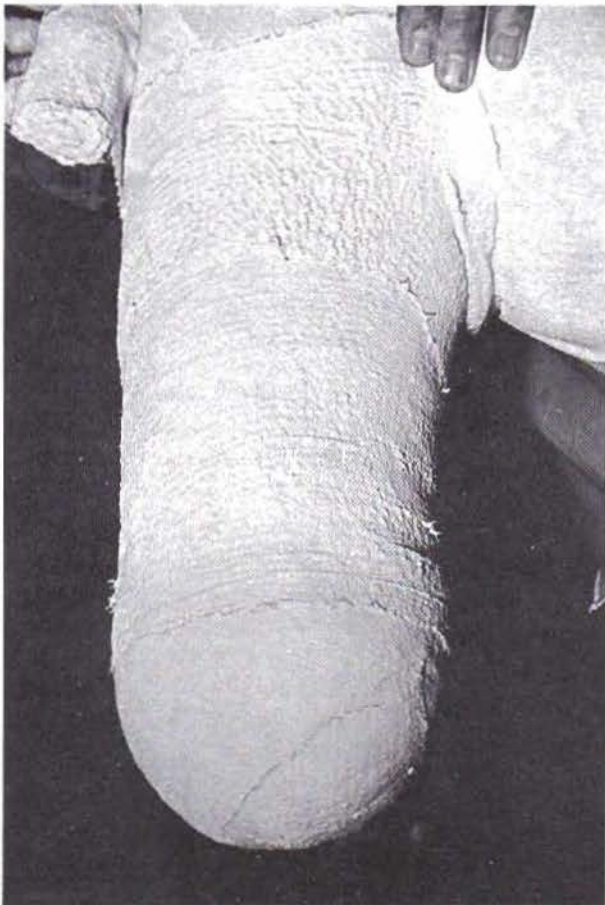

FIGURE 153

This new wrap is carried proximally on the stump  $2\frac{1}{2}$  to 3 in. past the level of the perineum on the posterior, lateral, and anterior aspects (Fig. 153). Only minimal tension is applied to the plaster as the wrap proceeds proximal, with none exerted at the upper third of the rigid dressing brim. This is to avoid proximal constriction to the blood flow.

*Note:* The circumferential wraps are smooth and even and overlap half of each previous turn. The elastic plaster will curl backwards on the proximal cast-socket brim if the desired tension is exceeded.

Be certain to bring the wrap high enough antero-medially (Scarpa's triangle) and posteromedially (ischial tuberosity) to insure a smooth well-rounded socket brim (Fig. 154 and 155).

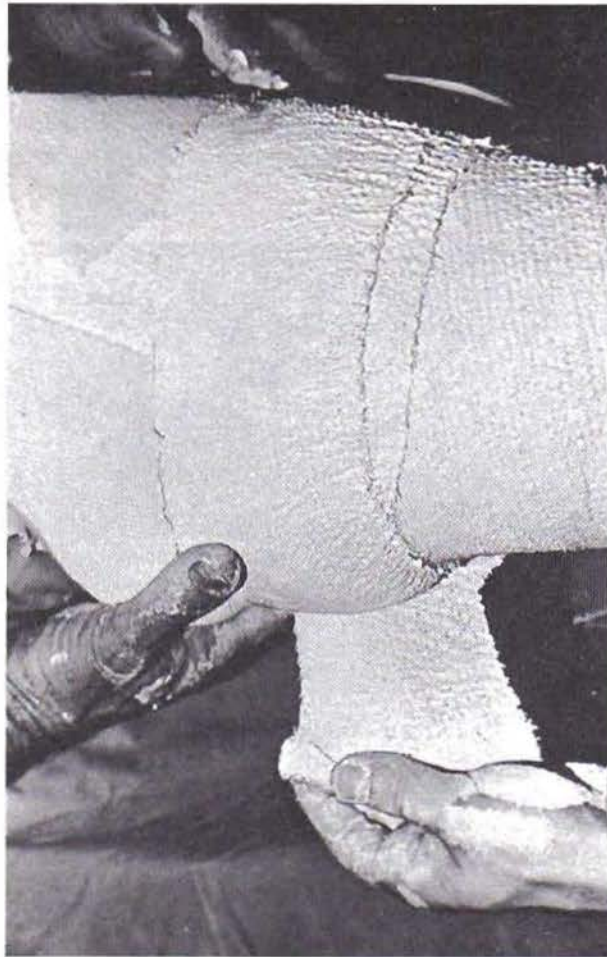


FIGURE 154



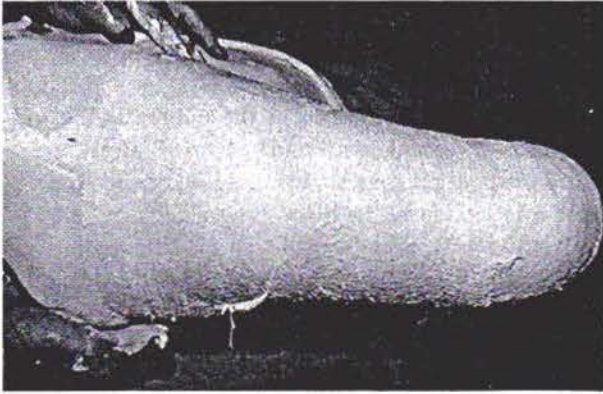


FIGURE 155

3. (a) Following completion of the initial cast application and while the elastic plaster is still wet, the PRS above-knee casting fixture, with the handle DOWN in the "open" position, is applied over the plaster wrap (Fig. 156). Position the posterior brim of the cast fixture at the level of the ischial tuberosity. This usually provides sufficient clearance between the medial-proximal socket wall and perineum when the stump is adducted.

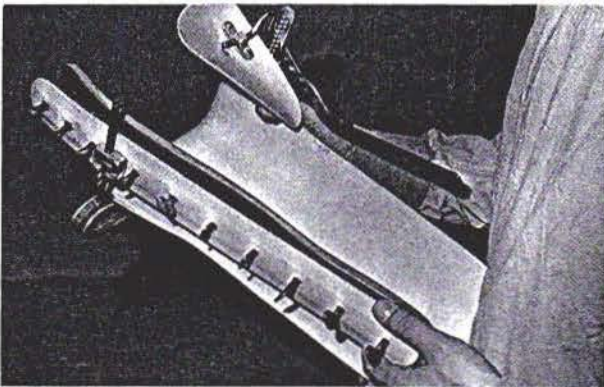


FIGURE 156

(b) Bring the handle of the casting fixture gently in the UP (closed) position (Fig. 157). Place the stump in its proper attitude of adduction and flexion and make corrections to the A-P and M-L dimensions if the plaster allowance proves excessive or insufficient. Hold the lateral wall of the casting fixture distally against the stump and check for proper contours, adjust if necessary. Check for  $\frac{1}{4}$  in. clearance between the perineum and the medial-proximal socket wall.

(c) Free one hand by holding the casting fixture in place with the stomach and pull firmly on the




FIGURE 157

medial aspect of the perineal apron and the portion of the split stump sock (Fig. 158). This insures proper brim flares and clears the stump sock and stockinet of wrinkles. This same procedure should be repeated on the posterior-medial socket wall.

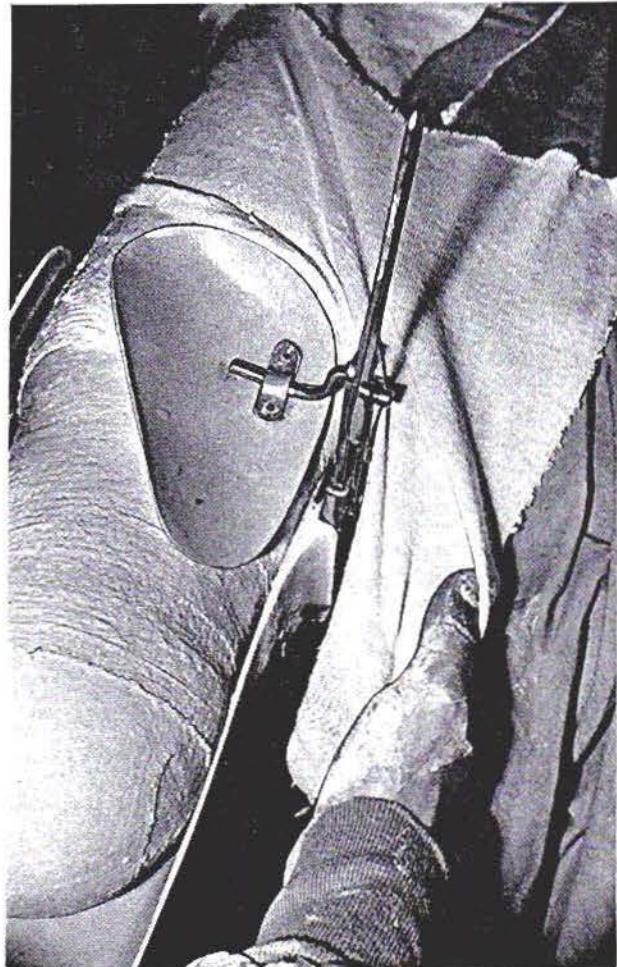


FIGURE 158



(d) At the anterior proximal cast socket brim, roll back any excess plaster bandage protruding past the Scarpa's pad of the casting fixture (Fig. 159). Form a relief in the same manner around the area of the rectus femoris to avoid contact with the iliac crest causing possible socket displacement distally when the hip is flexed to 90 deg.

(e) The stump and casting fixture are held in place with moderate pressure exerted in a proximal direction until the plaster has hardened.

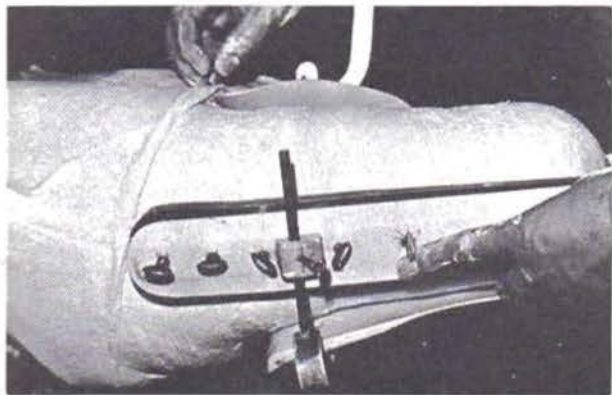


FIGURE 159

(f) After the plaster has hardened, place the handle of the casting fixture in a DOWN (open) position and carefully remove the casting fixture from the cast socket (Fig. 160, 161, and 162).

*Note:* Have an assistant support the cast socket in a proximal direction at all times until the waist belt and cable suspension are attached.

*Variation:* The following optional procedure describes the construction and application of an acceptable above-knee quadrilateral cast socket brim which can be checked for smoothness, fit, and proper shape prior to surgery and which does not require the use of the PRS above-knee casting fixture. However, the procedure is more time consuming in its initial preparatory stage, and faulty stump measurements and/or plaster mold modifications might produce a cast socket brim unfit for application. For these reasons, the PRS casting fixture is still the more reliable technique since this method yields a custom made product on the stump itself and allows, if necessary, for repeated adjustments and applications.

1. The prosthetist obtains a circumference measurement at the level of the ischial tuberosity and again 2 in. below, including the anteroposterior dimension of the patient's lower extremity, prior to surgery. Re-

duce the two circumference measurements to reflect muscle tone just as one would use in constructing a suitable socket to be worn with a three-ply stump sock. In order to avoid proximal restriction to the

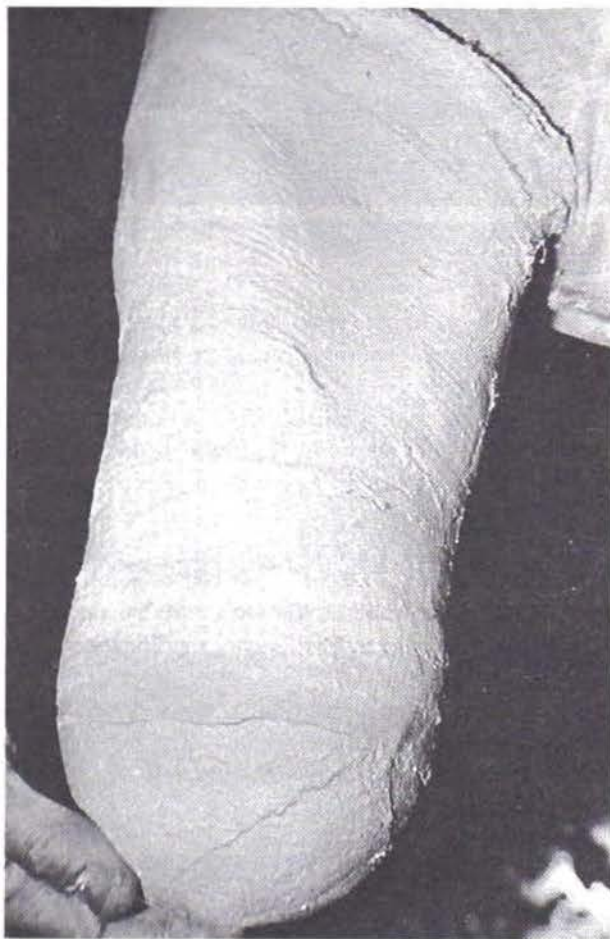

FIGURE 160

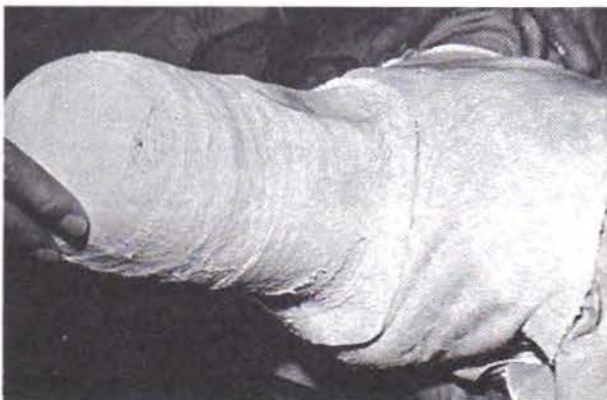

FIGURE 161



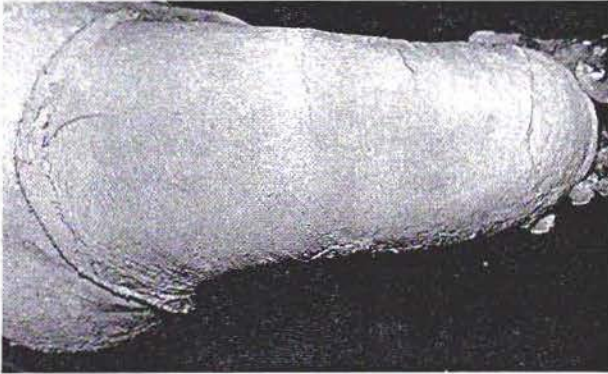

FIGURE 162

blood flow and to assure continued distal tissue support, only gluteal weight bearing is sought and no attempt is made to achieve ischial contact on the posterior socket wall. This requires the anteroposterior dimension to be increased from the usual practice  $\frac{1}{2}$  in. for stumps up to 18 in. of proximal circumference and  $\frac{3}{4}$  in. for all stumps exceeding 18 in. top circumference.

2. For economical reasons it is recommended that established above-knee molds with suitable measurements be used where few or no modifications are required.

a. Select a proper size tubular cotton stockinet to suit the stump circumference plus 2 in. for overlap when split on the lateral side. A 12 in. length stockinet is sufficient (Fig. 163).




FIGURE 163

b. Split along one side and locate on the cast model so the stockinet will extend past the distal and proximal trim lines of the finished plaster brim (Fig. 164). Overlap the split ends  $1\frac{1}{2}$  to 2 in. on the lateral side (Fig. 165).

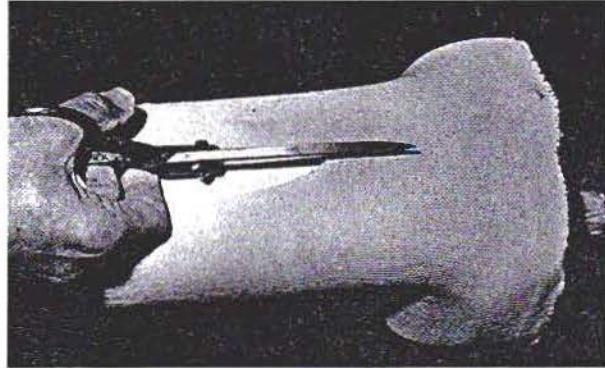


FIGURE 164




FIGURE 165

c. Fasten the stockinet with some small tacks making sure that no wrinkles remain in the material.

d. Cut four double layer 4 in. x 15 in. plaster splints from a roll of elastic plaster bandage. Begin the application on the lateral underlying (tongue) portion of the stockinet and work posteriorly around to the medial and anterior portion arriving laterally on the top of the wrap, overlapping where it began (Fig. 166). The length of the plaster brim is approximately 4 in. measured from the posterior wall distally. The lateral overlapping area including the most

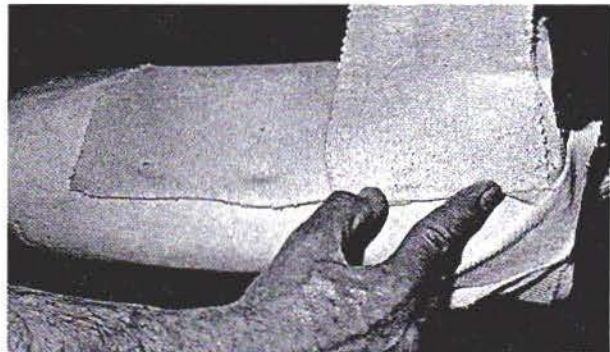


FIGURE 166



distal portion of the plaster brim feathers out to only a single splint thickness plus the cotton stockinet to assure smooth blending when completing the rigid dressing (Fig. 167).

e. Reinforce the areas of the posterior, medial, and anterior proximal socket flares with folded 4 in. x 15 in. conventional plaster splints (Fig. 168).




FIGURE 167



FIGURE 168

f. Cover the entire brim with additional plaster splints to provide a final smooth finish of the socket brim (Fig. 169).

g. When the plaster has set sufficiently, remove the brim carefully from the model. Fold the proximal extending portion of the stockinet inside the cast brim and trim the excess plaster off to achieve a desirable trim line (Fig. 170).

h. Fold the stockinet back out over the cut edge of the plaster brim and fasten with additional plaster splints (Fig. 171).

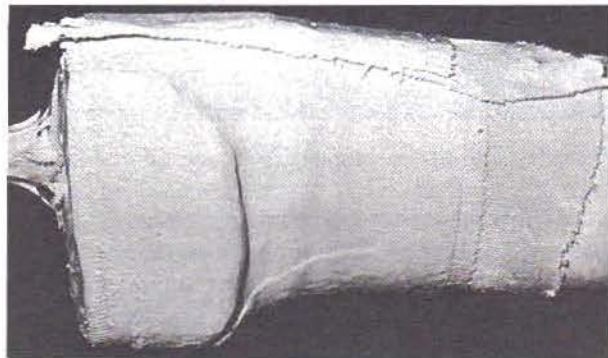

FIGURE 169

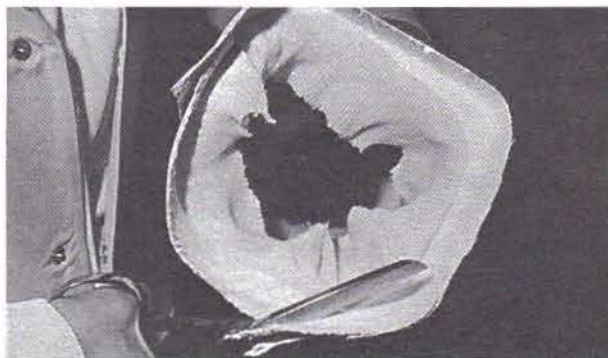


FIGURE 170




FIGURE 171



i. Trim the excess stockinet off the distal end of the cast brim. The brim is now completed and ready for application on the patient (Fig. 172).




FIGURE 172

3. With the stump sock firmly suspended, locate the prefabricated plaster brim properly on the patient and wrap the remaining portion of the stump, including the reticulated polyurethane distal pad, with elastic plaster bandage as previously described. Extend the plaster wrap proximally and secure it to the plaster brim. Reinforce the elastic plaster section of the wrap with conventional plaster bandage.

4. Because of the inherent structural weakness of elastic plaster bandage, the initial wrap must be reinforced with conventional plaster bandages and splints.

(a) Double layers of 4 in. x 15 in. plaster splints are applied over the distal portion of the socket antero-posteriorly (Fig. 173) and mediolaterally (Fig. 174).

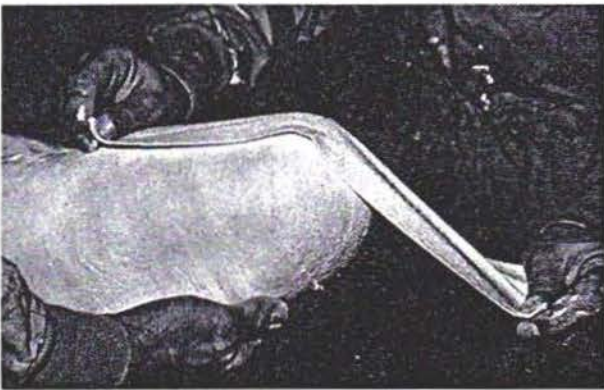


FIGURE 173

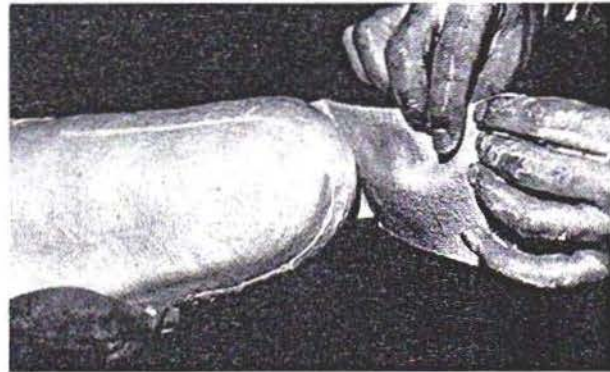


FIGURE 174

(b) Reinforce the area of the Scarpa's triangle with a double layer of plaster splint folded three times (Fig. 175).

(c) Fold a double layer of plaster splints three times and again lengthwise to reinforce the medial socket brim (Fig. 176).

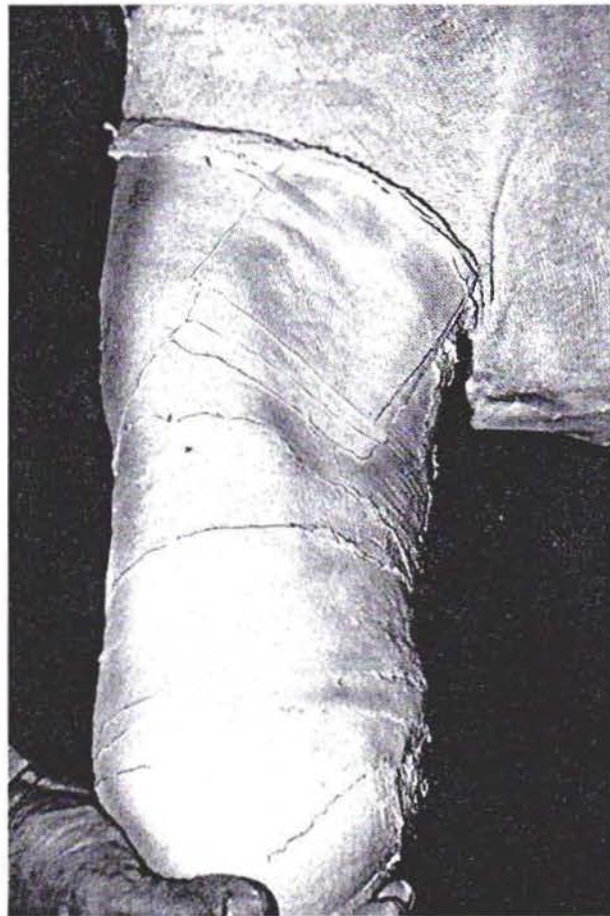

FIGURE 175



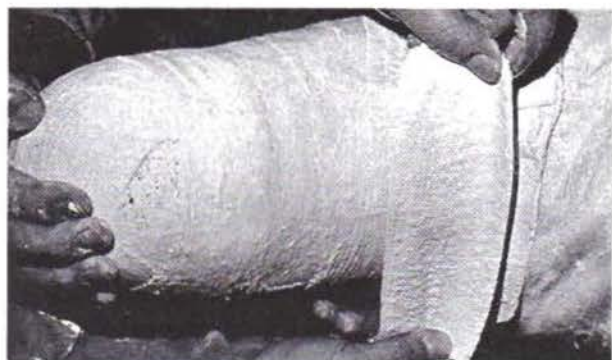

FIGURE 176

(d) Repeat this procedure to reinforce the posterior flare of the socket brim, overlapping slightly the previously applied splint (Fig. 177).

5. A roll of 4 in. conventional plaster bandage is applied, starting at the proximal socket brim and carried distally, with even, overlapping circular wraps (Fig. 178). Avoid bridging of the plaster in the areas

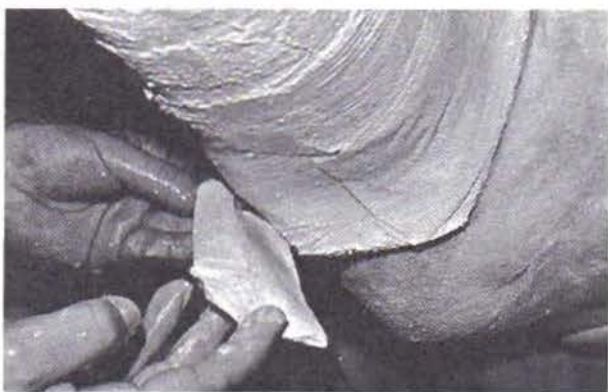

FIGURE 177

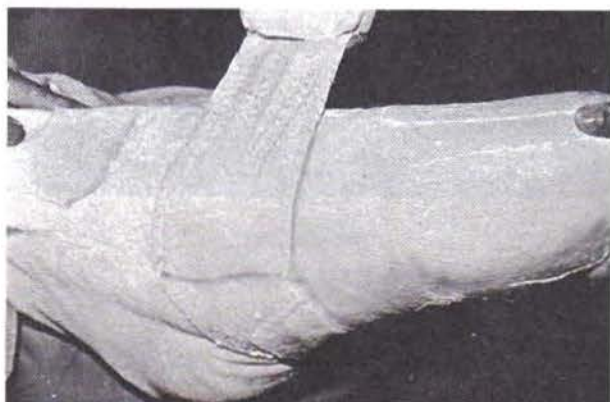

FIGURE 178

of the Scarpa's triangle and posterior flare of the socket brim by providing some slack in the plaster bandage.

Two layers of plaster are usually sufficient. Lightly smooth the proximal third of the cast socket (Fig. 179).

6. Select an appropriate size set of Bowden cables and locate on the cast in the following manner:

(a) Expose all the stainless steel Bowden cable to one side of the cable housing and locate the retainer of the exposed section on the anterior iliac crest. With the cable housing, form an arc as large as possible on the lateral cast wall to minimize cable friction against the housing.

(b) Locate the other retainer at the level of and 1 in. lateral to the center of the posterior-proximal cast socket brim.

*Note:* The apex of the arc on the cable housing should be located below or above the drain site to facilitate drain removal.

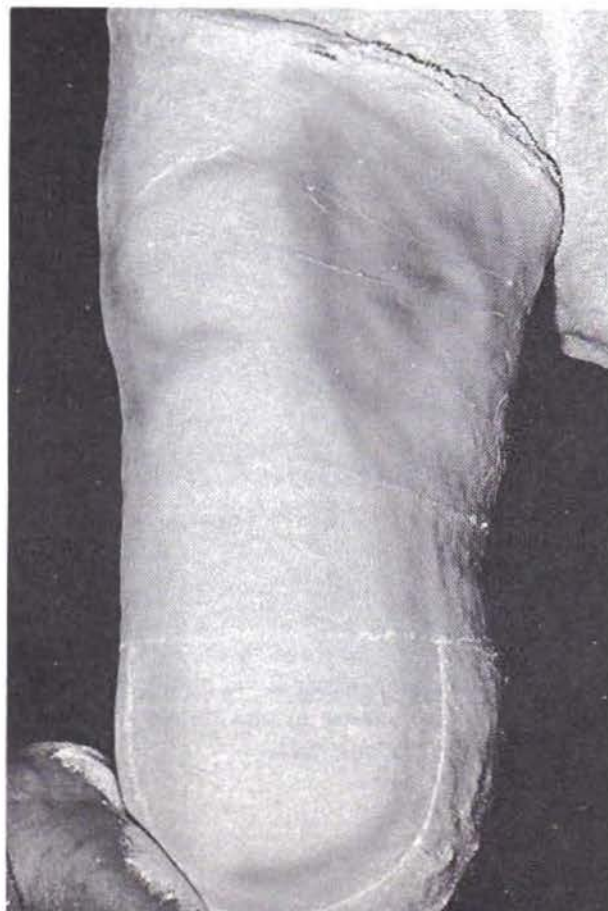


FIGURE 179



(c) Tape the cable housing in place with a strip of 1 in. masking tape or a plaster-of-paris splint.

(d) Locate the medial Bowden cable assembly in the same manner but maintain a 2 to 3 in. separation between the two retainers, both anterior and posterior (Fig. 180 and 181).

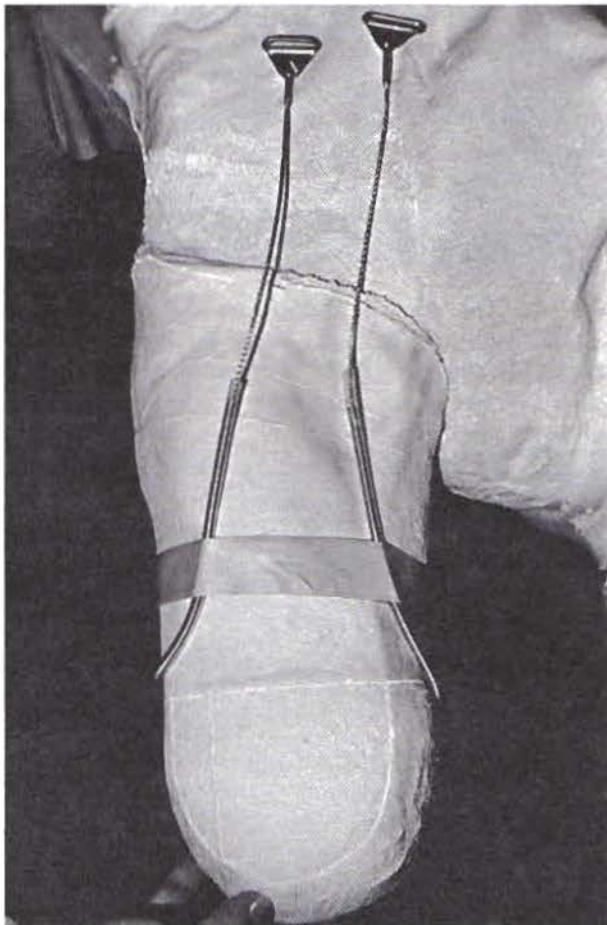


FIGURE 180

(e) Secure the cable housing to the cast socket with two plaster splints or one-third of a roll of 4 in. conventional plaster bandage. Make sure the plaster contacts the underlying cast socket on the inside of the arc of the cable housing to provide a stable attachment (Fig. 182, 183, and 184).

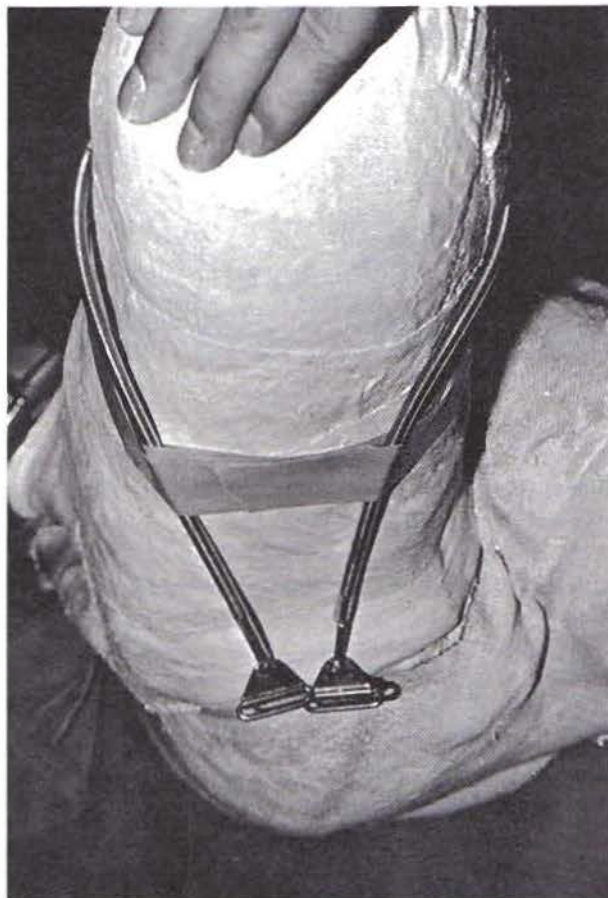


FIGURE 181

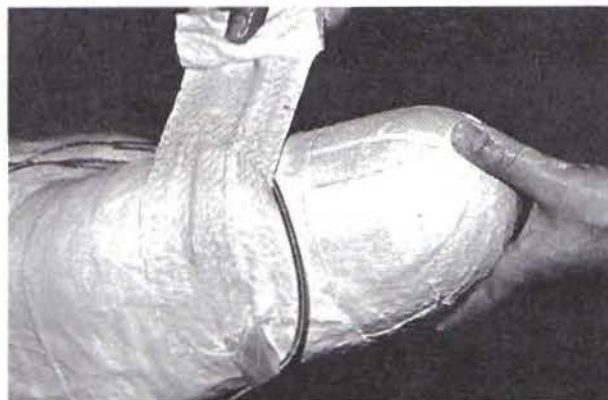

FIGURE 182

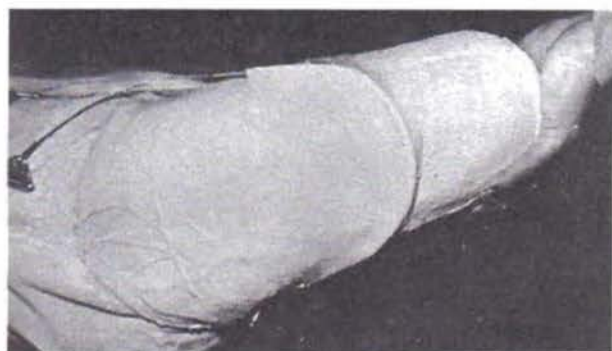


FIGURE 183

### C. APPLICATION OF THE PROSTHETIC UNIT

1. (a) Reposition the patient so that the pelvis is parallel to the foot edge of the operating table. Position the stump in a normal attitude of adduction and place the sound leg in neutral.

(b) Detach the socket attachment plate from the prosthetic unit by loosening the quick disconnect screw. Attach the socket attachment straps to the socket attachment plate with the machine screws provided and hold the assembly next to the cast socket to determine strap length (Fig. 185).

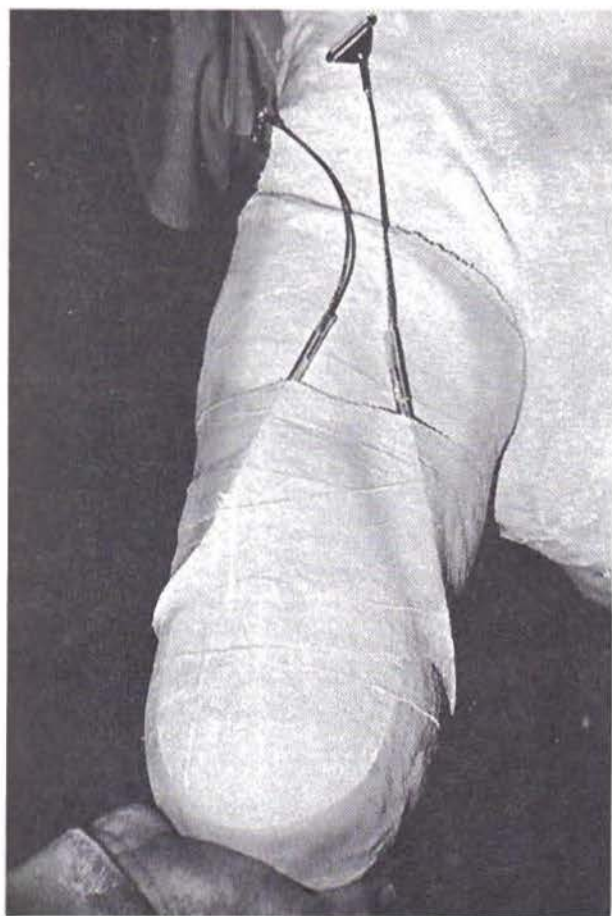


FIGURE 184

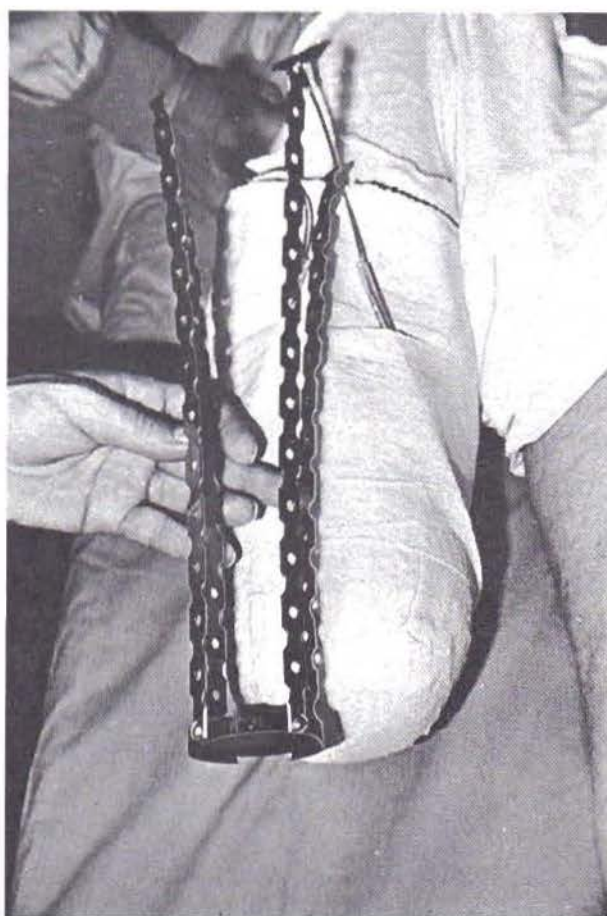

FIGURE 185



(c) Cut the straps 1 in. below the level of the exposed cable housing with metal shears (Fig. 186).

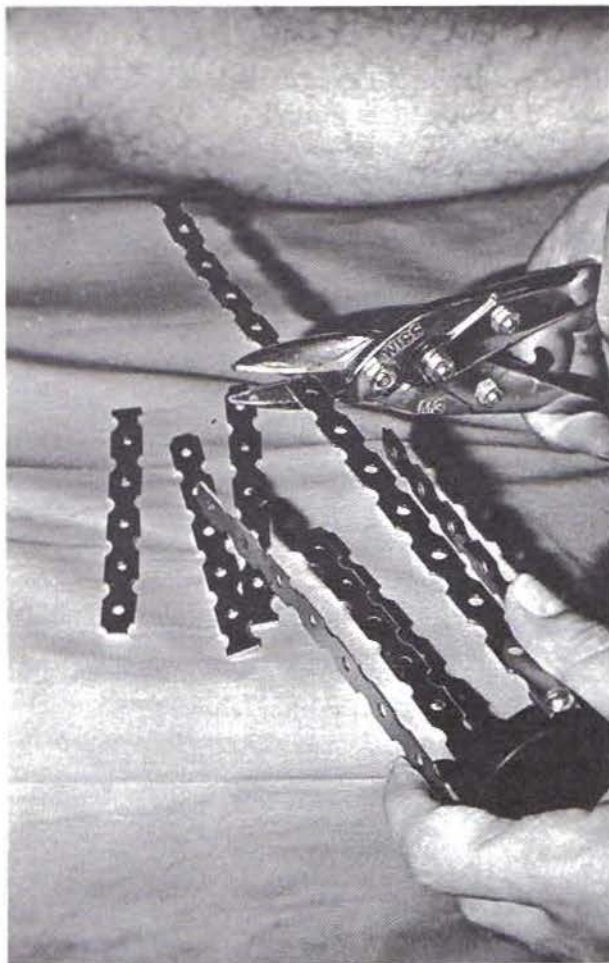


FIGURE 186

2. Bend the socket attachment straps so they conform closely to the exterior contours of the plaster socket. The socket attachment plate should be:

- a. parallel to the foot edge of the table,
- b. posterior from the distal socket center when viewed laterally, to achieve a desired TKA relationship,
- c. 90 deg. to the table top to accommodate the flexion angle in the cast socket, and (Fig. 187). . .
- d. . . . outset so an imaginary vertical line drawn from the ischial tuberosity will bisect the medial border of the socket attachment plate (Fig. 188).

*Note:* The socket attachment straps should be located so they will not interfere with the removal of the drain.

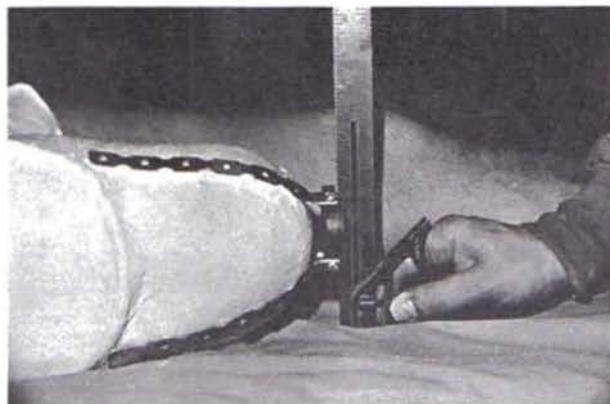


FIGURE 187

3. Recheck the position of the socket attachment plate and with indelible pencil mark the location of the two anterior socket attachment straps (Fig. 189). Reasonable care given to this alignment procedure

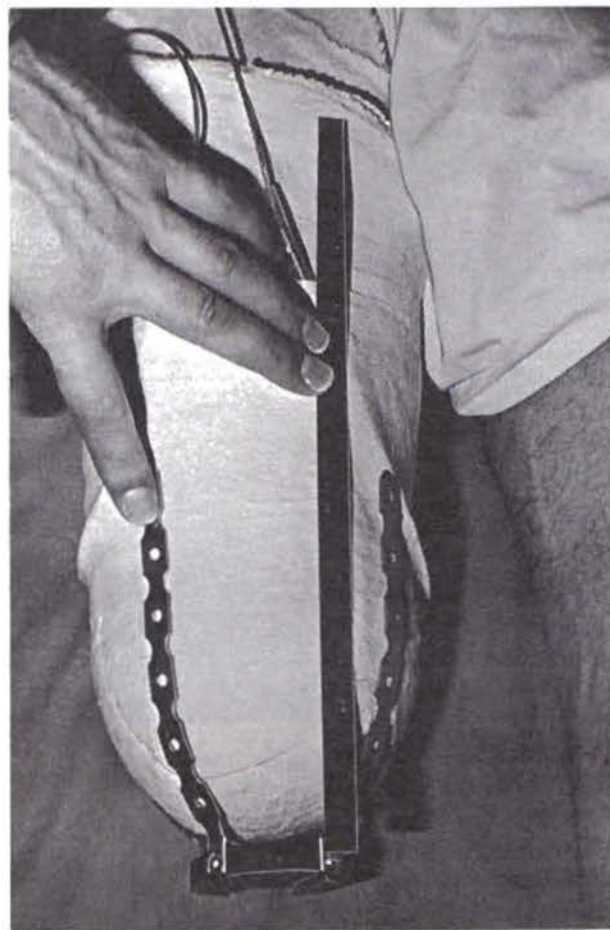


FIGURE 188

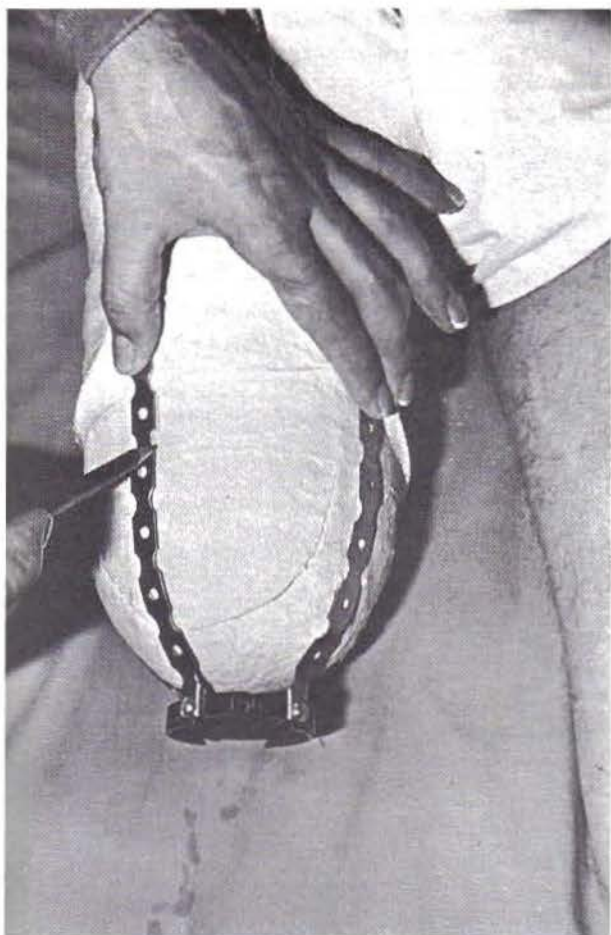


FIGURE 189

will result in proper bench alignment requiring little or no adjustment when the patient stands.

*Variation:* On a long above-knee or knee-disarticulation stump, attachment of the prosthetic unit will unavoidably lower the effective knee center somewhat, in comparison to the sound side. Aside from cosmesis, prosthetic function is hardly affected. However, on a short stump, the difference between the cast and the socket attachment plate must be filled with an appropriately sized round piece of balsa wood or styrofoam to place the prosthetic knee center in a more functional position (Fig. 190).

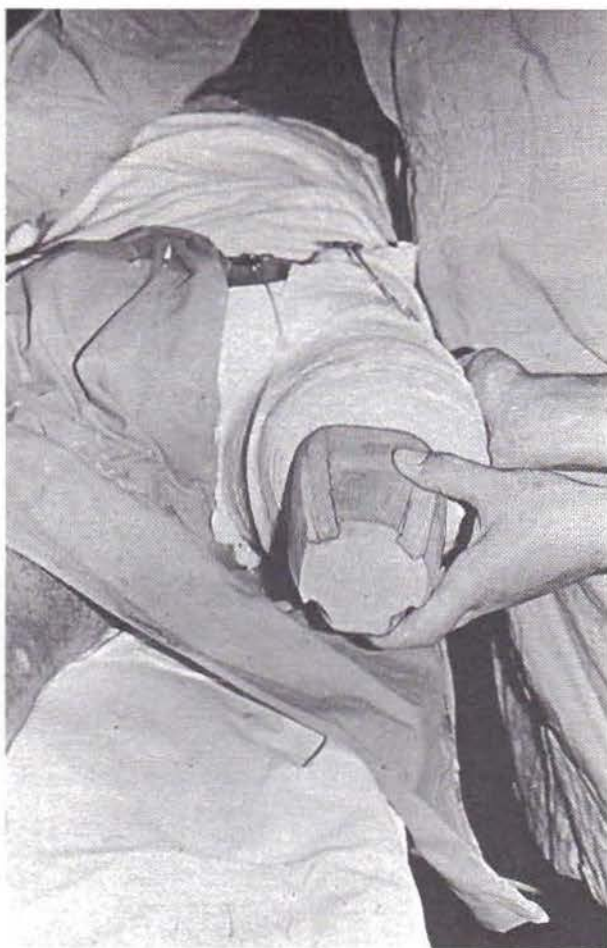

FIGURE 190

(a) Bend the socket attachment straps so they closely conform to the exterior contours of the balsa wood or styrofoam and to the cast socket (Fig. 191).

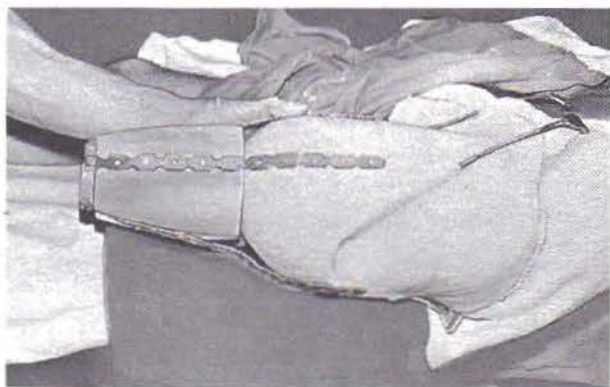


FIGURE 191



(b) Recheck the position of the socket attachment plate and mark with indelible pencil the location of the attachment straps on the cast socket.

(c) Fold a double layer of 4 in. x 15 in. plaster splints three times and place it between the back of the socket attachment plate and the distal end of the wood or styrofoam extension (Fig. 192).

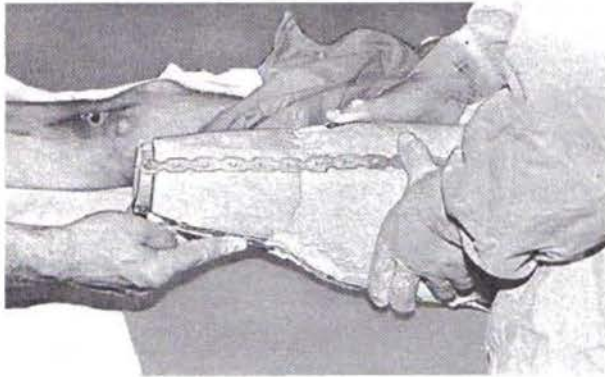

FIGURE 192

(d) Repeat the procedure between the proximal extension and the cast socket making sure all voids and hollows are filled solidly.

*Note:* Loose and broken socket attachment straps result if these last two steps are omitted.

4. If a socket extension is not required, only one double layer of 4 in. x 15 in. plaster splints is indicated as a filler between the socket attachment plate and cast socket (Fig. 193).

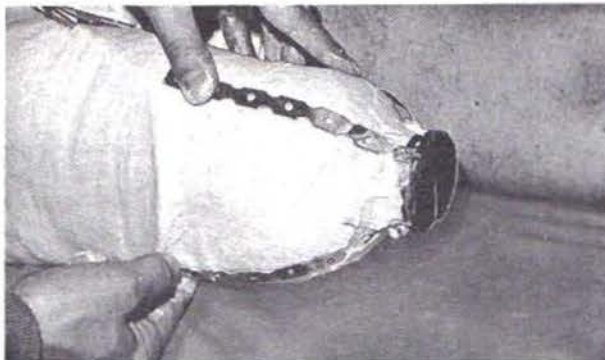


FIGURE 193

5. Laminate the socket attachment straps to the cast socket with one roll of conventional plaster bandage, making sure that the straps are *covered entirely*, down to the socket attachment plate (Fig. 194).

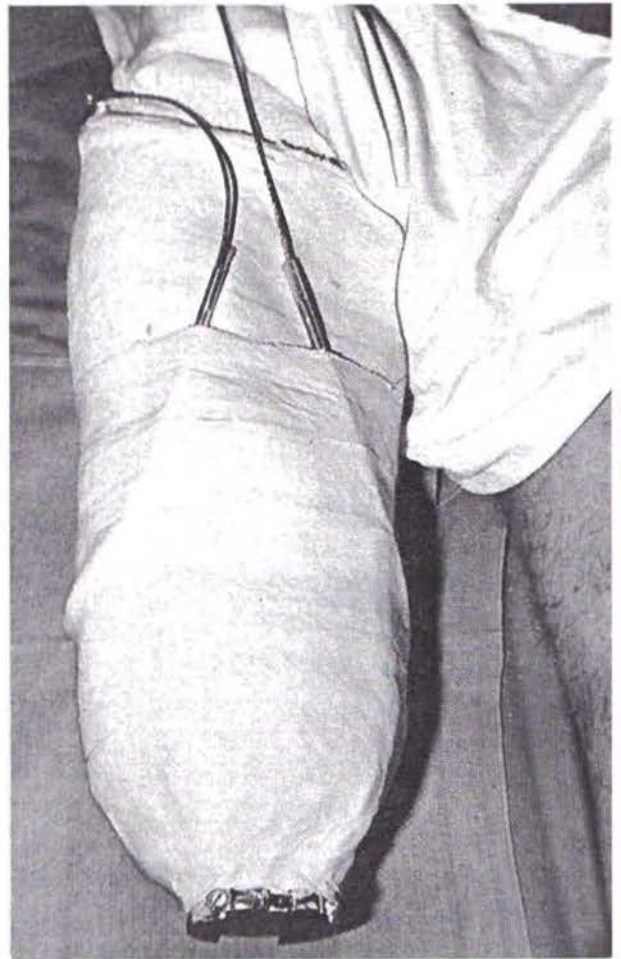

FIGURE 194

6. Trim all excess stockinet material from the perineal apron but retain 1 in. of overhang (Fig. 195 and 196).

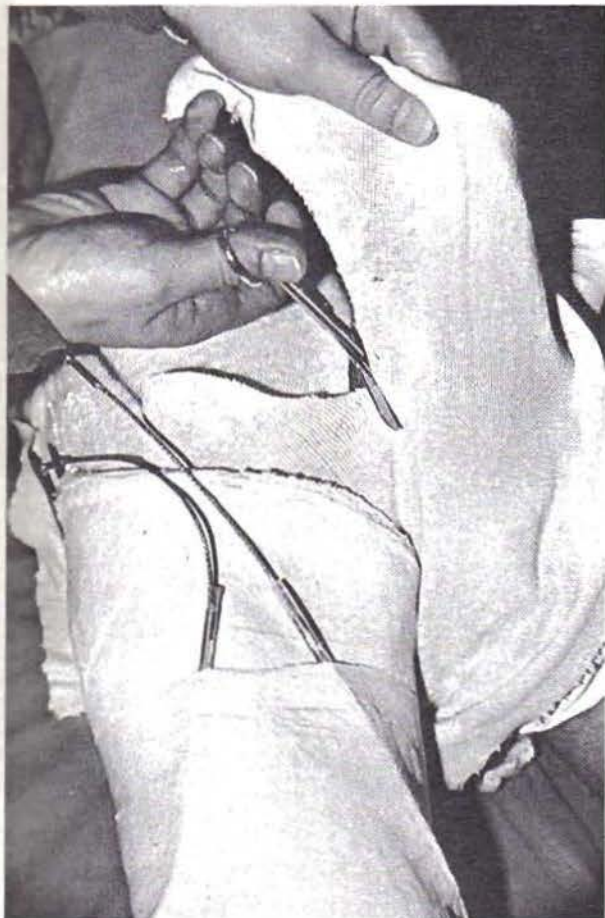

FIGURE 195

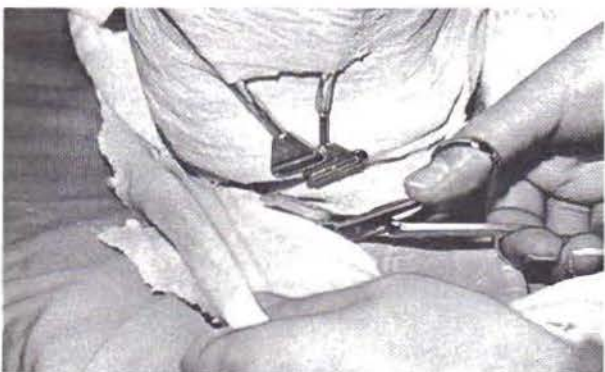

FIGURE 196

Cut the 1½-in.-wide perineal portion of the *stump sock* in the same manner (Fig. 197).

*Note:* Do not disturb or trim the glued-on portion of the Orlon Lycra stump sock around the hip and waist.

7. Only after all plaster work has been completed is the previously prepared suspension belt applied to the patient. This will keep the belt from getting soiled with plaster of paris.

(a) Locate the contoured waist belt on the patient so that the distal border rests just proximal to the iliac crest. Attach the waist straps anteriorly and tighten the two lateral adjustment straps sufficiently so the belt will not displace distally or rotate on the patient. Bring both shoulder straps over each shoulder after crossing them in back for men and in front for women. Attach the shoulder straps to the anteroproximal attachment buckles.

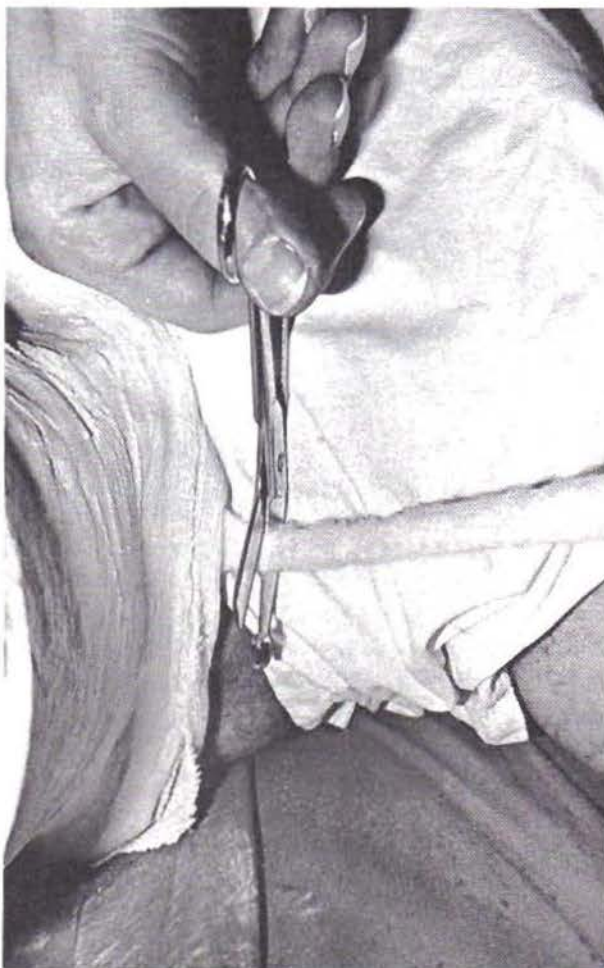

FIGURE 197



(b) Place the felt apron between the cast socket and the exposed portions of the cables and housings. Trim the excess felt at the level where the housings emerge out of the cast socket, both anterior and posterior (Fig. 198).

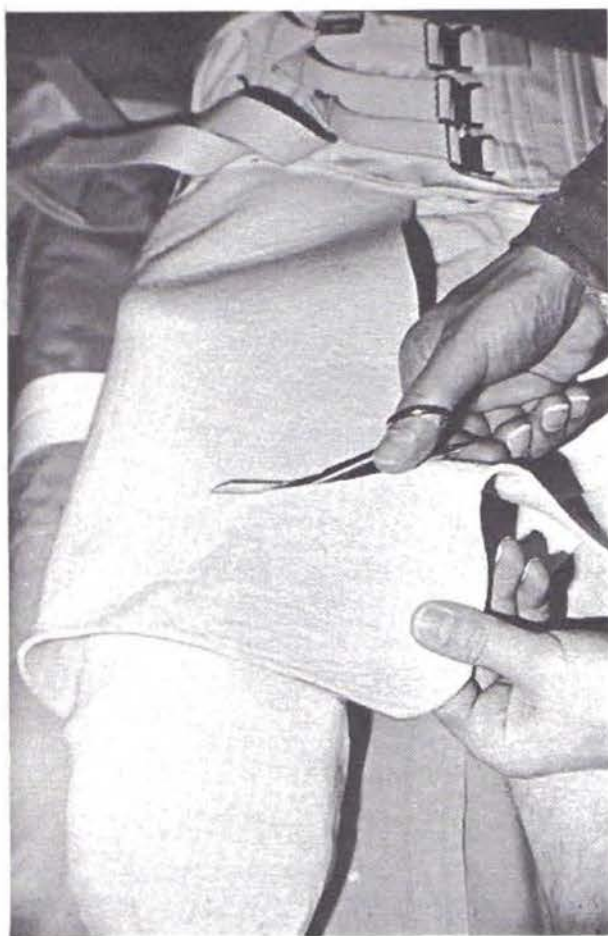


FIGURE 198

(c) Thread both *anterior* suspension straps through the retainers of the Bowden cables and fasten them to each corresponding safety buckle, exposing at this time all available cable to allow for 90 deg. of hip flexion when the patient is sitting up (Fig. 199).

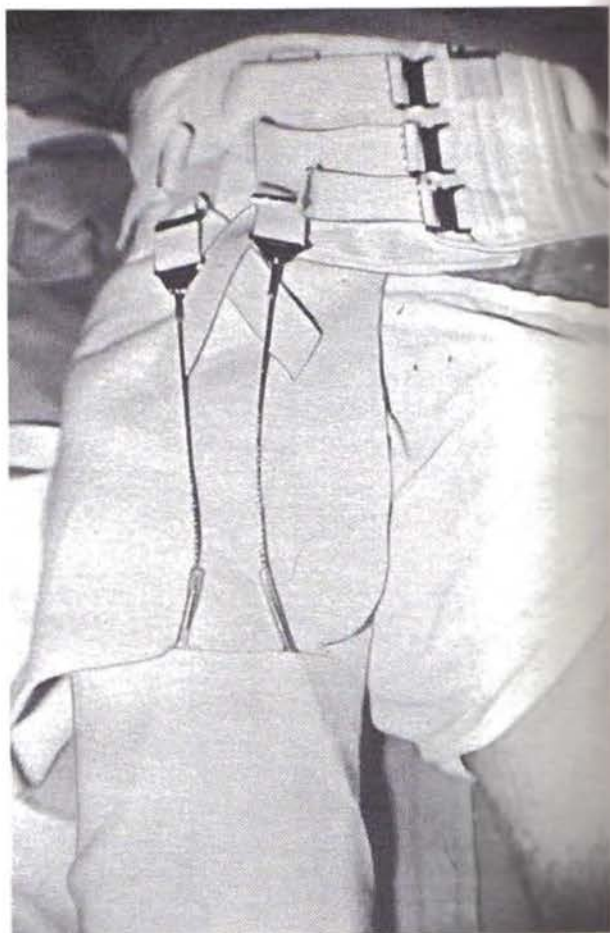


FIGURE 199

Firmly fasten the two *posterior* suspension straps to their corresponding safety buckles to maintain *distal* tissue support by suspending the cast socket and retaining it securely on the stump (Fig. 200).

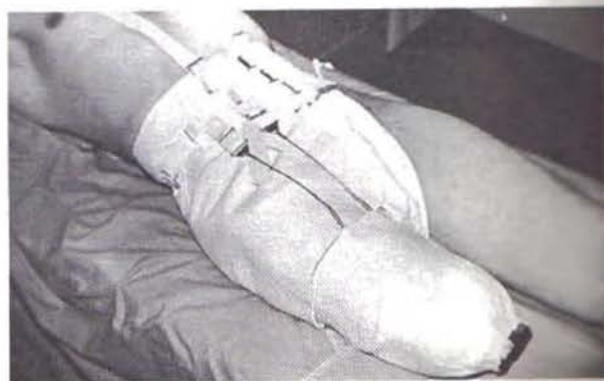

FIGURE 200

Increase socket adduction by simultaneously loosening the lateral and tightening the medial cable webbing suspension straps. Reverse the process to decrease socket adduction.

8. The adjustable prosthetic unit with all adjustments in the neutral position is attached to the socket attachment plate by loosening the quick disconnect screw (Fig. 201).

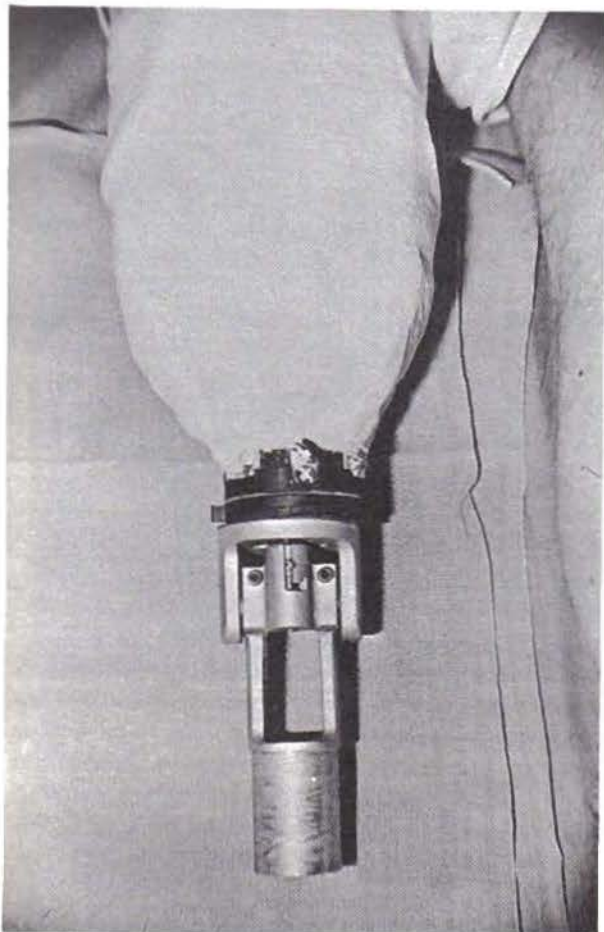


FIGURE 201

9. Attach the pylon tube to the foot.

10. Recheck that the patient's pelvis has remained level to the foot edge of the table and that the stump socket is in the desired attitude of flexion and adduction. With the ankle of the sound foot held in neutral position, the heel pad is compressed with a straight-edge projected parallel to the bottom edge of the operating table, across to the heel of the artificial foot. The pylon tube will extend proximally past the pros-

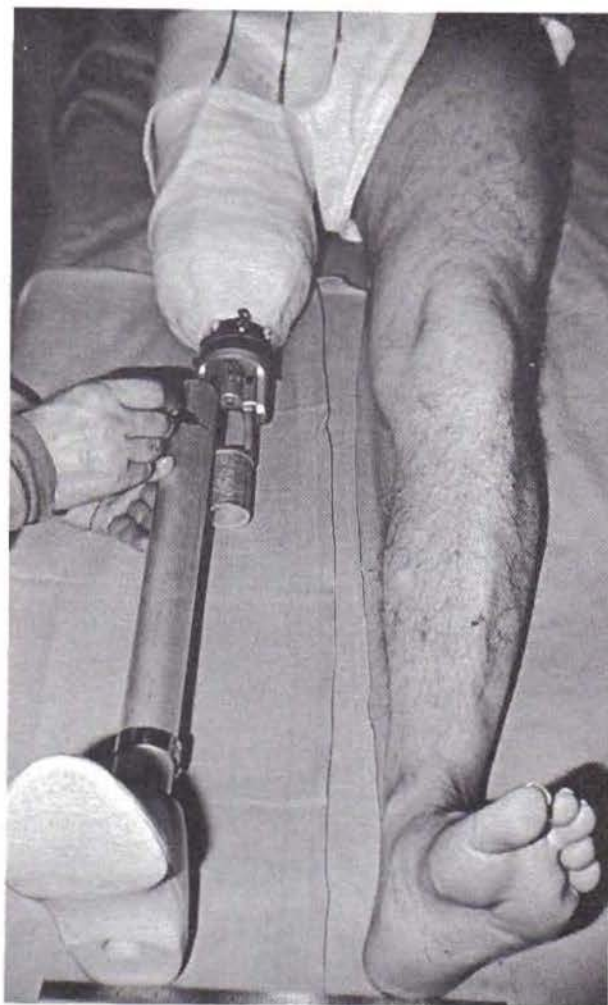

FIGURE 202

thetic unit up to the cast socket and is marked at the level of the base plug collar (Fig. 202).

*Variation:* When using a Kingsley Immediate Post-surgical SACH foot with built-in heel, add 1 in. to the overall length of the pylon tube to compensate for the absence of the shoe on the prosthetic side.



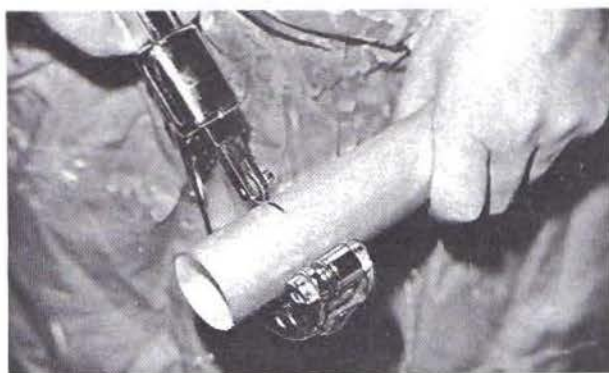

FIGURE 203

11. Cut the pylon tube at the established mark with a tube cutter (Fig. 203).

12. Remove the burr on the inside edge of the pylon tube with the knife provided on the tube cutter or with a reamer (Fig. 204).

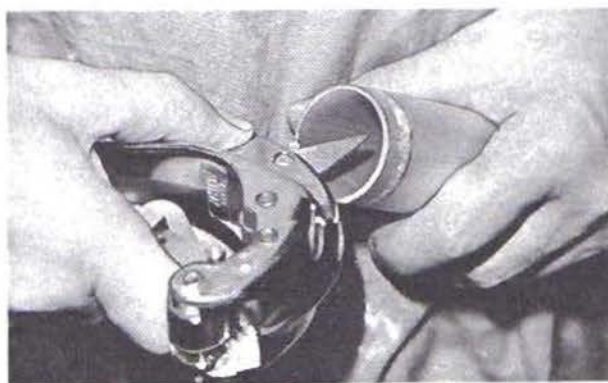

FIGURE 204

13. Remove the prosthetic unit from the socket attachment plate by loosening the quick disconnect screw and connect the pylon tube to the base plug of the unit.

Reattach the prosthetic unit to the socket attachment plate and establish approximate toe-out. Tighten the hose clamp connection around the pylon tube with a screwdriver, fastening it to the base plug. Do not cut slots in the pylon tube at this time (Fig. 205).

14. Detach the completed assembly from the socket attachment plate by loosening the quick disconnect screw before the patient leaves the operating room.

**THE WHOLE PROCEDURE OF CAST APPLICATION SHOULD NOT TAKE MORE THAN 30 MINUTES WITH PRACTICE.**



FIGURE 205

#### D. THE KNEE-DISARTICULATION IMMEDIATE POSTSURGICAL PROSTHESIS

If circumstances make it necessary for the surgeon to excise the patella during surgery, proceed with the same rigid dressing technique as described for the above-knee amputation with the following exception:

##### STEP 1—APPLICATION OF THE RIGID DRESSING, WRAPS 1 THROUGH 8

In the classical knee disarticulation the skin incision is located posteriorly, approximately 1½ in. proximal from the distal end of the stump. Since one of the reasons for a rigid dressing is tissue support and immobilization, it is most important to alter the amount of tension exerted with the elastic plaster bandage

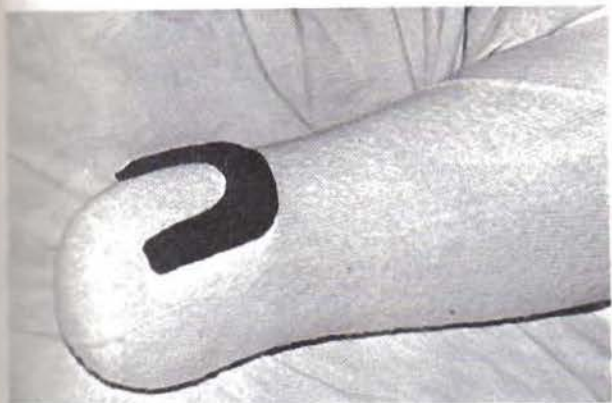

FIGURE 206

when supporting the skin flaps. Controlled tension on the plaster bandage is directed to the surrounding area of the suture line where the two skin flaps meet, in this case slightly proximal on the distal posterior stump margin. The tension of the elastic bandage must be relaxed slightly as the wrap proceeds anteriorly past the distal stump end since it would have an adverse effect of displacing the anterior skin flap proximal resulting in tension to the sutures and causing a possible separation of the wound.

When the surgeon is forced through the lack of available skin to improvise on a closure resulting, for example, in mediolateral skin flaps, this must be carefully considered and accordingly reflected in the casting technique. Support of the skin flaps in relationship to each other must always be provided by appropriate initial elastic plaster application.

When the patella is left intact and retained in the stump, it must be protected by an appropriate relief pad. Depending on the prominence of the patella, a  $\frac{3}{8}$ -in. to  $\frac{1}{2}$ -in.-thick and  $1\frac{1}{2}$ -in.-wide medium-hard felt pad is fashioned in the shape of an inverted horseshoe. The inner arc of the felt relief pad is trimmed to fit the outer border of the patella. The outer edge of the patellar relief pad is skived thin so it will blend smoothly into the rigid dressing without leaving a ridge in the cast socket.

Locate the felt relief pad around the border of the patella so that the open end of the horseshoe points distally (Fig. 206 and 207).

As previously mentioned, efforts are now being made to replace all felt relief pads with a comparable grade of compressed reticulated polyurethane which can be gas or steam sterilized.

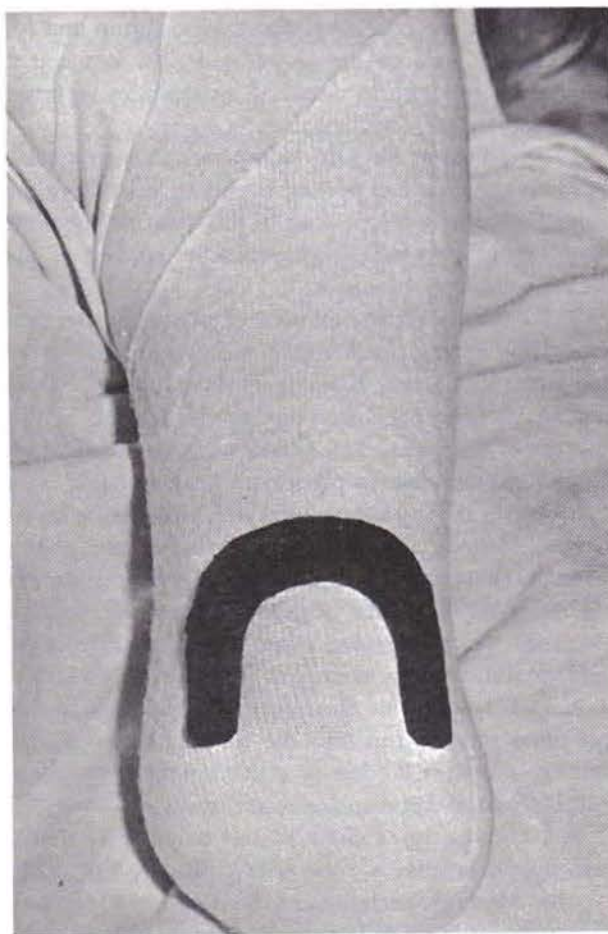

FIGURE 207

#### E. ABOVE-KNEE AND KNEE-DISARTICULATION PROSTHETIC CONSIDERATIONS

The basic theory of achieving a perfectly fitting cast socket remains the same as outlined in the below-knee considerations. However, the absence of the knee joint and the anatomical configuration of the thigh stump require not only additional prosthetic restoration of function but there is also a shift in emphasis on certain technical aspects of the rigid dressing application. The key to success is the maintenance of satisfactory suspension and rotatory stability of the cast socket on the amputation stump. The spica technique has been abandoned in favor of the present waist bet and cable suspension system. This offers the patient more comfort and mobility allowing hip flexion up to 90 deg. while maintaining an effectively suspended stump-socket relationship. At the present time, indications for hip



spica are for the very short above-knee stump and for a fused hip joint on the amputated side. While it is difficult to describe in detail all possibilities of error, following are key considerations:

1. Avoid suspending the stump sock in such a manner that the proximal portion is pulling away from the thigh resulting in a loose cast in this area. At the same time, avoid proximal construction or cutting of the socket brim into soft tissue.

2. Allow a sufficient amount of plaster on the posterior and anterior socket brim to insure a well-flared brim in those areas. Keep the plaster bandage from rolling back on itself by relaxing the tension at this portion of the cast socket. If necessary, use an assistant to hold the bandage in place with his fingertips.

3. While it is recommended that full use be made of the stretch characteristics of the elastic plaster bandage, avoid overstretching when reversing the direction of the wrap; the larger outer arc of the bandage can form a ridge in the underlying plaster bandage and/or stump sock (example: Wraps 4 and 7).

4. Insure sufficient clearance between the anterior proximal socket brim and the anterior-superior iliac crest to allow for 90 deg. of active hip flexion without causing cast socket displacement distally.

5. Never turn or twist a plaster bandage so that it will bunch or have a rope effect. Use the full width of the bandage partially overlapping each previous circumferential turn. If tucking distally appears to be a problem, use short plaster splints instead.

6. Failure to pull down firmly on the perineal apron medially and posteriorly including the split portion of the stump sock will result in difficulties in this area. Wrinkles in the stump sock or perineal apron and/or a sharp medial socket brim could cause abrasions, pinching, or pressure against pelvic rami.

7. Failure to adduct the stump properly before the elastic plaster has hardened will result in ramus or perineum pressure by the medial socket brim accompanied by looseness and gapping on the lateral proximal portion of the cast socket when the patient stands or ambulates.

8. Avoid an overly thick cast.

9. Unless there are specific reasons, do not delay application of the socket attachment plate to the rigid dressing at the time of surgery. The cast socket must dry at least 24 hours and if attachment is delayed, so are the standing activities of the patient.

10. Do not attempt to secure the pylon tube to the base plug while it is attached to a wet cast socket. This

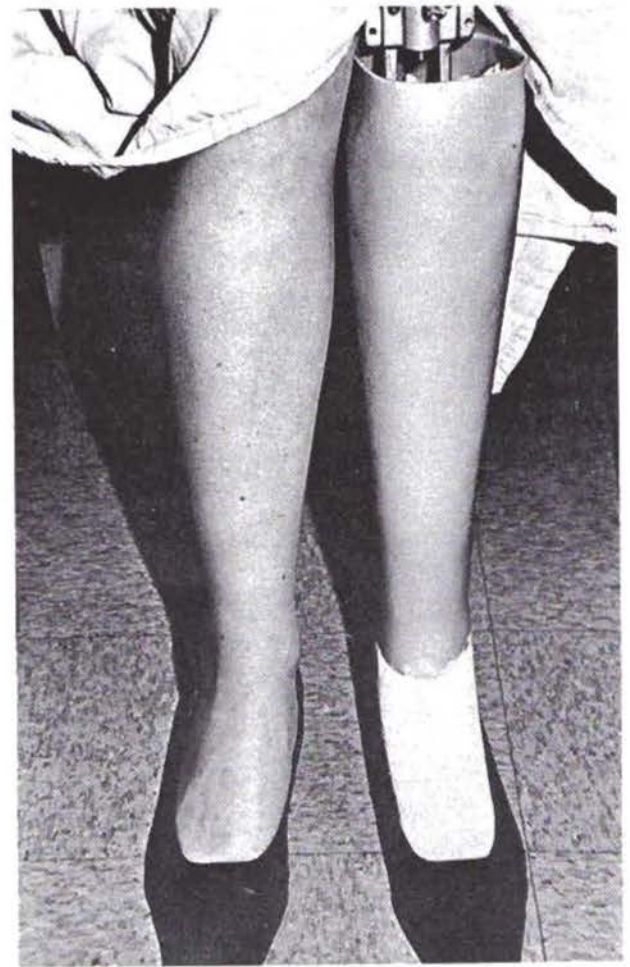

FIGURE 208

practice could loosen the socket attachment plate and straps. Disconnect the adjustable prosthetic unit from the socket attachment plate with the disconnect screw before joining pylon tube and base plug.

11. Improper location of the socket attachment plate which exceeds the corrective capabilities of the adjustable prosthetic unit requires removal from the rigid dressing and correct reapplication. *Instructions need to be carefully followed.* (See Appendix A.)

12. If the patient is unable to ambulate, he will still benefit from the rigid dressing, but, of course, the prosthetic unit and pylon are withheld.

13. Occasionally it is necessary and helpful to improve the cosmetic appearance of the immediate post-surgical prosthesis. A cover made of semi-rigid plastic is located between the foot and pylon tube and fastened securely by tightening of the foot bolt (Fig. 208).

Storage and repeated use sometimes deform the cos-

metic cover. With a heatgun render the cover pliable and restore it to its proper shape by forcing tissue paper between the pylon shank and the cosmetic cover.

When complications develop, they are usually traceable to deviations from the outlined techniques. Pe-

riodic checkups of alignment and fit are good preventive measures. Investigate patient complaints promptly and make corrections if necessary. Communicate and consult with the other team members frequently to stay informed about the patient's progress.

and  
om  
rew

ent  
the  
the  
ions

still  
ros-

im-  
ost-  
stic  
ast-  
(8).  
cos-



## CHAPTER 4

# The Syme Amputation

### I. PREOPERATIVE INSTRUCTIONS TO THE PROSTHETIST

1. When notified by the surgeon, obtain from him all necessary information required and available at this time.
  - a. Side of amputation.
  - b. Proposed level of amputation if this information is available.
  - c. Any additional physical defects of the patient which might restrict or limit movement and/or weight-bearing and ambulation activities.
  - d. Any existing or permanent flexion contractures.
2. Talk to the patient, explain your role, what you intend to do, and what is expected of him. He may be apprehensive and anxious; don't make him more so. Explain the advantages to be derived from an immediate postsurgical prosthesis and from well-fitting prostheses, generally.
3. Consider any physical defect and/or flexion contractures noted by the surgeon which would influence casting and/or alignment of the prosthetic unit.
4. Take measurements for suspension waist belt.
5. Note approximate size of Orlon Lycra stump sock required (see Table 2, Chapter 2, Section I.6). This sock must be gas autoclaved before application at surgery.

### II. PREOPERATIVE PREPARATIONS BY THE PROSTHETIST OF MATERIALS AND COMPONENTS

1. Select a left or right set of appropriate medial and lateral felt or polyurethane relief pads. A patellar relief pad is not used in the Syme immediate postsurgical prosthesis.
2. Fabricate the waist belt with elastic suspension strap.

3. Select and assemble an appropriate adjustable prosthetic unit. While we have used rubber walking heels as a base of support in our earlier cases, we now recommend the use of a Syme foot in conjunction with the PRS adjustable prosthetic Syme unit. A properly selected Syme foot aside from providing a wider base of support also decreases vertical displacement of the hip joint during stance phase and resembles dynamically the action of the definitive prosthesis.

In order to retain compactness in the prosthetic Syme unit, adjustability is limited and a quick disconnect feature has not been provided.

4. Select a strip of reticulated polyurethane sheeting, 1/2 in. thick, 2 in. wide, and approximately 7 in. long. This interface material must be sterilized before application.

### SPECIFICATIONS OF PRS SYME ADJUSTABLE PROSTHETIC UNIT (Fig. 209)

The dimensions of the socket attachment plate are 2 1/2 in. x 1/4 inch. The unit is provided with a 3/8 in. carriage bolt including a 9/16 in. hex nut with washer.

With the foot attachment bolt in neutral position the concavity of the socket attachment plate provides 10 deg. of dorsiflexion or 10 deg. of plantar flexion of the foot, for a total of 20 deg. adjustability.

Horizontal slide adjustment mediolateral is provided 7/16 in. in either direction for a total of 7/8 inch.

Adjustments are independent of each other.

Three socket attachment straps are inset to the attachment plate and secured with 5/32 in. machine screws.

The prosthetic unit including attachment straps weighs less than 200 grams.

4. Assemble components and materials required for the Syme rigid dressing application (Fig. 210) (see Appendix B for List of Suppliers) :



FIGURE 209

- a. Sterile reticulated polyurethane sheeting,  $\frac{1}{2}$  in. thick, 2 in. wide, and 7 in. long
- b. Sterile Orlon Lycra stump sock
- c. Felt or polyurethane relief pads
- d. Waist belt with suspension strap (below-knee type)
- e. 1 in. cotton webbing, 20 in. long with  $1\frac{1}{2}$  in. safety buckle
- f. PRS Syme adjustable prosthetic unit with Syme foot

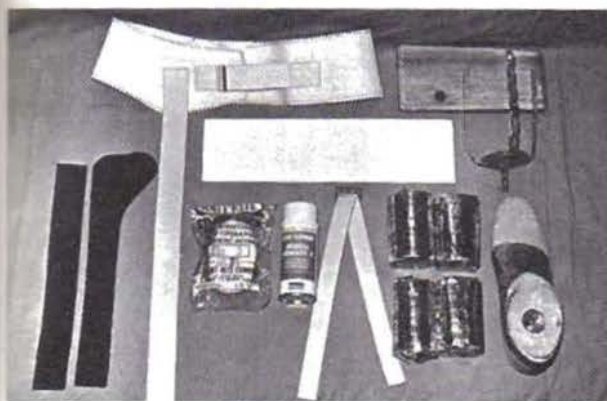

FIGURE 210

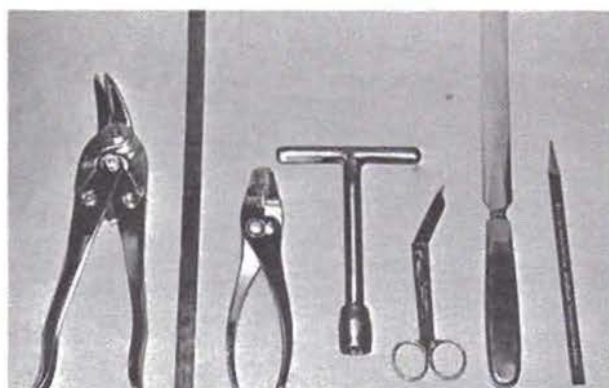


FIGURE 211

- g. Dow Corning Medical Adhesive Spray, Type B
  - h. 2 rolls of 4 in. elastic plaster bandage
  - i. 6 plaster splints, 4 in. x 15 in., extra fast setting
  - j. 2 rolls of 4 in. conventional plaster bandage, extra fast setting
  - k. Flat surface (board) to deform distal surface of cast socket
5. Assemble kit of tools required for fitting prosthesis immediately after surgery (Fig. 211). All tools except stainless steel tools have been stripped, polished, and chromed to allow for repeated sterilization when required.
- a. Metal shears
  - b. Straightedge
  - c. Pliers
  - d.  $\frac{9}{16}$  in. socket wrench
  - e. Bandage scissors
  - f. Skiving knife
  - g. Indelible pencil

### III. THE SYME AMPUTATION SURGERY

When amputation can be carried out through the ankle joint, Syme's procedure should be performed in the classical manner. We do not advocate trimming of malleoli other than the elimination of rough and sharp edges of the distal tibia and fibula. Proper *centering* and *stability* of the heel flap over the distal tibia are essential. The treatment of the wound closure is essentially the same as used in the below-knee amputation, i.e., an occlusive wound dressing such as silk or nylon with a layer or two of fluff gauze, Orlon Lycra stump sock, polyurethane sheeting, and an elastic plaster rigid dressing (Fig. 212, 213, 214, and 215).



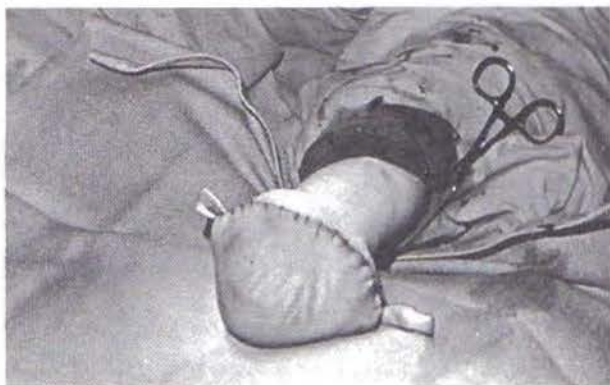

FIGURE 212.—Classical Syme amputation with drain, distal view.

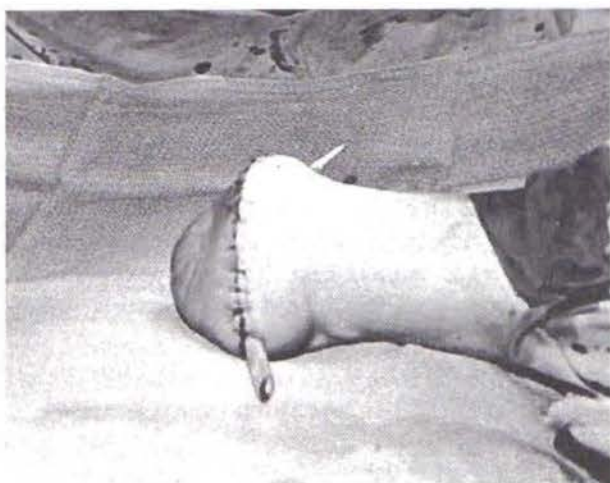


FIGURE 213.—Classical Syme amputation with drain, lateral view.

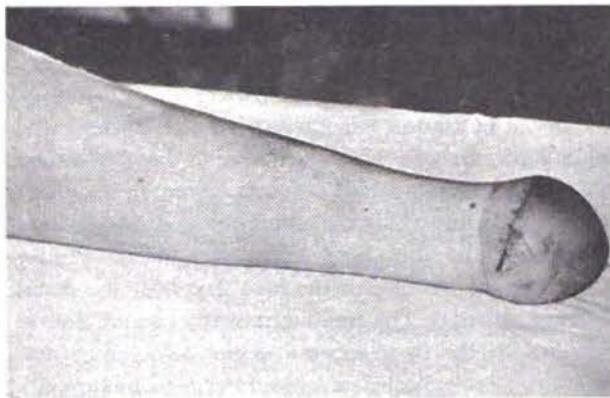


FIGURE 214.—Same patient as in Figures 212 and 213, 14th postoperative day, at initial cast change. Note contouring of stump.

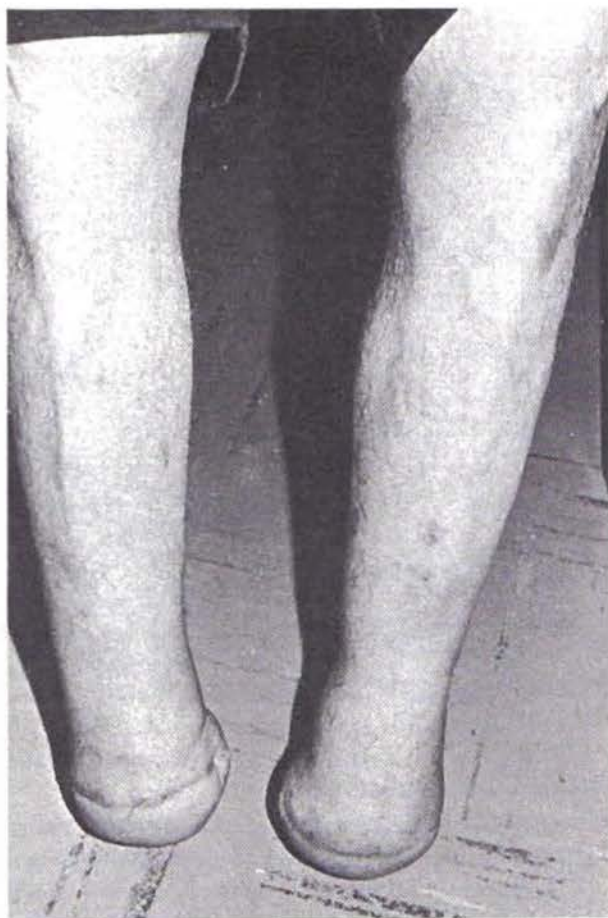

FIGURE 215.—Syme amputations 9 months following classical surgery and immediate postsurgical prostheses.

#### IV. THE SYME IMMEDIATE POSTSURGICAL PROSTHESIS

##### A. APPLICATION OF FELT (OR POLYURETHANE) PRESSURE RELIEF PADS

1. (a) The sterile Orlon Lycra stump sock is held under firm tension with both hands by an assistant. The hands should be placed on the anteroproximal aspects of the thigh. Since the knee joint is not immobilized by the cast, the flexion attitude of the knee joint is inconsequential (Fig. 216).

(b) If no assistant is available, a simple adjustable shoulder suspension harness, which is interchangeable for right and left, can be substituted to achieve the same result (Fig. 217).

2. The felt or (polyurethane) relief pads must be trimmed, skived, and beveled in the appropriate areas for individual needs.

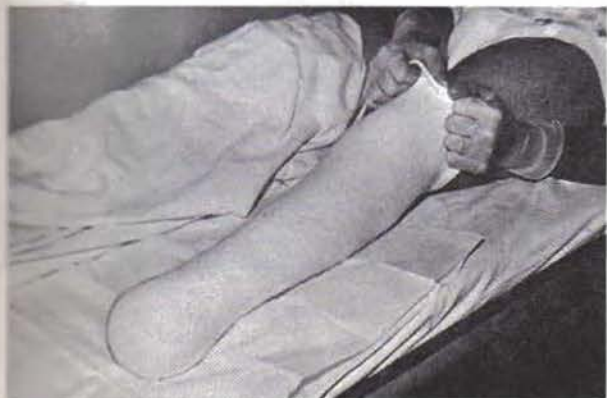

FIGURE 216




FIGURE 218

The same procedure is followed in locating the relief pads as in the below-knee application with the following exception: Extend the felt relief pads distally on the stump to a level where the bulbous heel end begins to take shape. Cut both pads at this level (Fig 218). Skive and bevel all appropriate areas which were modified. A patellar felt relief pad is not required.

3. *Maintaining continuous tension on the stump sock*, spray the backs of the relief pads and the areas of the stump sock on which they will be located with Dow Corning Medical Adhesive, Type B (Fig. 219). Allow 5 seconds for the adhesive to become tacky.

NOTE: Polyurethane relief pads are provided with adhesive backing. The protective paper is peeled off just prior to application of the pads to the stump sock.




FIGURE 217

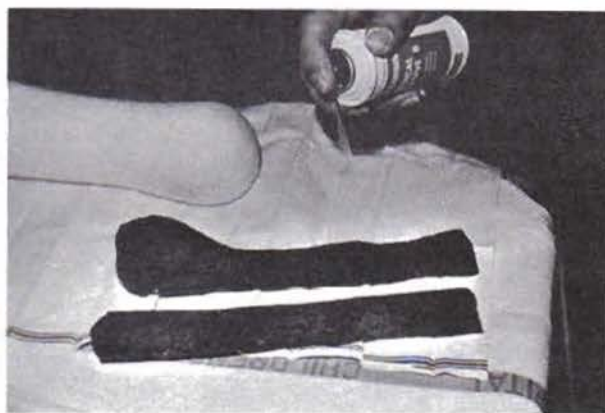


FIGURE 219



Reapply the relief pads exactly as outlined before (Fig. 220). *Unvarying* tension must be maintained on the stump sock at this time and continuously thereafter until the plaster has set or the pads will be displaced and no longer serve their intended purpose.

*Note:* The  $\frac{1}{2}$  in. separation between the felt relief pads takes into consideration also the slight migration of the pads toward one another as the elastic plaster bandage is being applied. If the pads are separated more than this, they will no longer function as supports to bridge the plaster across the tibial crest and will not relieve it from pressure. Skin damage over the tibial crest may result.

4. One potential difficulty in a Syme amputation is displacement of the heel pad medially, resulting in a possibly painful stump for the patient and fitting problems in the definitive prosthesis for the prosthetist. The surgeon will minimize this hazard by proper surgical technique. With application of the rigid dressing this




FIGURE 220




FIGURE 221

tendency can be further reduced by appropriate preventive measures in technique. The interface material is kept to an *absolute minimum*. **DO NOT USE A PREFORMED POLYURETHANE DISTAL PAD.** A strip of reticulated polyurethane sheeting,  $\frac{1}{2}$  in. thick, 2 in. wide, and approximately 7 in. long is located so it will cover the surgical site in a classical Syme amputation (Fig. 221). Glue the polyurethane strip in place with Dow Corning Medical Adhesive, Type B.

#### B. APPLICATION OF THE RIGID DRESSING

1. For the initial wraps, elastic plaster bandage is used rather than conventional plaster. When using an elastic plaster bandage, the elasticity provides safe and beneficial compression of the stump while conforming well to its contours, providing a smooth rigid dressing. *Continuous tension must be maintained on the stump sock until the plaster has hardened.*

##### Wrap 1:

The wrap is always started on the distal lateral aspect of the stump. This covers the polyurethane sheeting entirely and includes the lower ends of the relief pads (Fig. 222). Slight tension is applied circumferentially. The direction of the wrap is clockwise for a right stump and counterclockwise for a left stump when viewed anteriorly.

##### Wrap 2:

One and three quarter circumferential turns will anchor the elastic plaster bandage to itself.




FIGURE 222

**Wrap 3:**

The wrap is now at a point posterolaterally. Bring it anteriorly up over the distal *LATERAL* portion of the stump pulling the plaster bandage almost to its limit of elasticity (Fig. 223). At the anterior stump margin, release the tension and carry the wrap medially and then posteriorly with only a light pull on the plaster bandage.

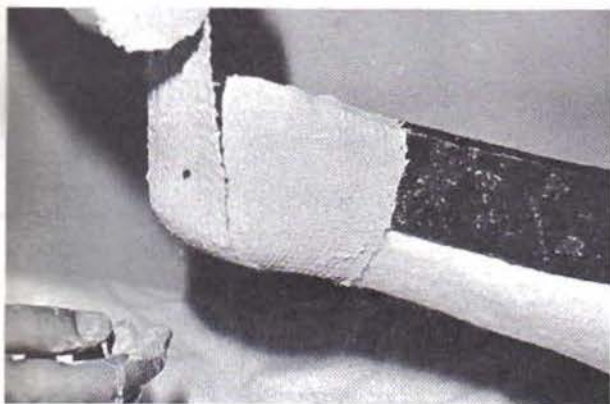


FIGURE 223

**Wrap 4:**

The fourth wrap is almost identical to wrap 3 except that now the bandage covers the distal *CENTER* of the stump (Fig. 224) (bandaging in the A-P plane rather than circumferentially on diagonally). The direction of the wrap is altered anteriorly and carried toward the lateral side of the stump, as if to resume circumferential wrapping.

356-593 O-69-6

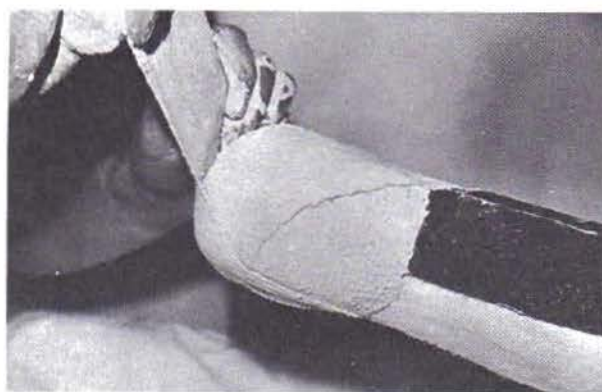

FIGURE 224

**Wrap 5:**

The fifth turn is brought anteriorly up over the distal *MEDIAL* aspect with the same controlled tension to the bandage (Fig. 225).

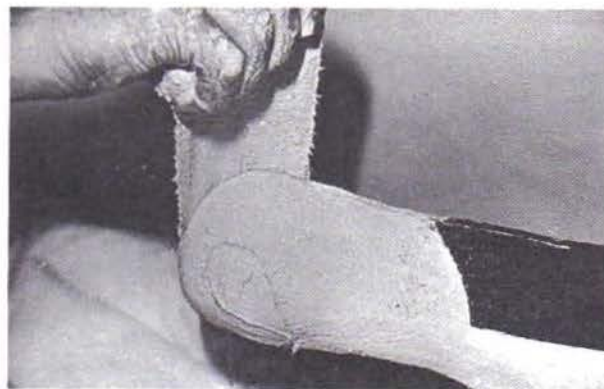


FIGURE 225

**Wraps 6, 7, and 8:**

To achieve desired cast strength, a second diagonal layer of elastic plaster bandage is applied by repeating wrap 5, followed by wrap 4, again altering the direction of the wrap medially. This will cover the distal *CENTER* of the stump with the second layer of plaster. Repeating wrap 3 will now cover the distal *LATERAL* stump with the second layer of plaster bandage. **MAKE SURE NO DISPLACEMENT OF THE HEEL PAD OCCURS AND THAT IT REMAINS CENTERED AT THE DISTAL STUMP END.**



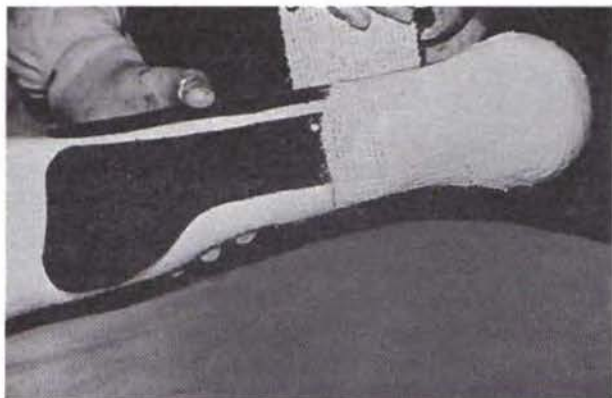


FIGURE 226

The remainder of the elastic plaster bandage is applied in a circular manner, overlapping partially each previous turn (Fig. 226) and carrying the wrap proximally with decreasing tension up to a level of the tibial tubercle where no tension is applied to the bandage. Proximal constriction must be avoided.

In the average adult it is usually necessary to use a second roll of elastic plaster bandage to complete the initial wrap with the required minimum of two layers of plaster.

2. Before the initial elastic plaster wraps harden, apply a flat surface (board) to the distal stump end to provide an effective central weight-bearing surface. Avoid displacement of the heel pad medially (Fig. 227).

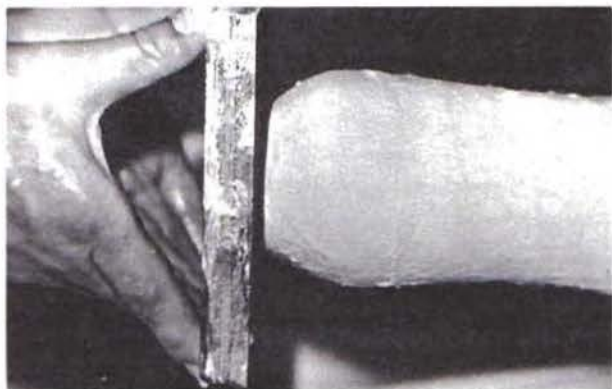


FIGURE 227

3. Because of the inherent structural weakness of elastic plaster bandage, the initial wrap must be reinforced with conventional plaster bandages and splints. Double layers of 4 in. x 15 in. plaster splints are

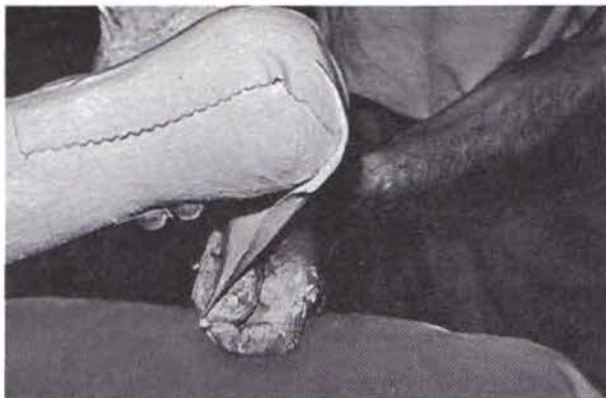

FIGURE 228

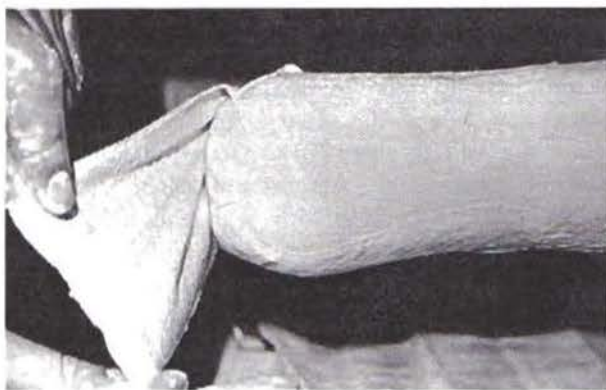


FIGURE 229

applied over the distal portion of the socket anteroposteriorly (Fig. 228) and mediolaterally (Fig. 229).

4. A roll of 4 in. conventional plaster bandage is applied starting at the distal bulbous portion of the stump (Fig. 230) and wrapping in a smooth circular fashion with overlapping turns up to the level where the elastic plaster cast terminated.

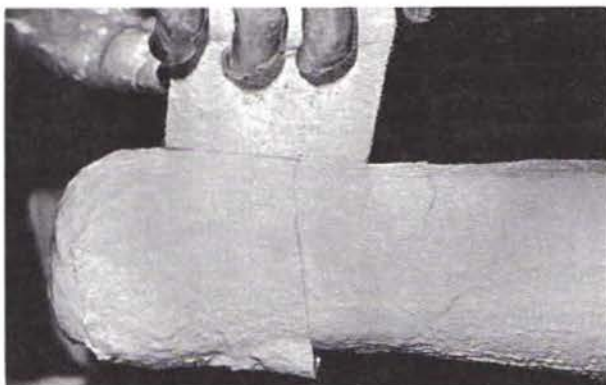


FIGURE 230

5. A 1 in. cotton webbing strap, approximately 20 in. long is looped through a 1½ in. safety buckle. The safety buckle is located approximately 1 to 1½ in. proximal to the patella. The two ends of the webbing extend distally past the medial and lateral borders of the patella. Two turns of the conventional plaster bandage are placed over the webbing to incorporate it into the wrap (Fig. 231).




FIGURE 231

Both remaining strap ends are then folded back and wrapped in place with the remaining plaster bandage to anchor it firmly in place (Fig. 232).

The entire wrap should then be smoothed lightly by hand.

6. Utilize all available excess cast sock extending proximally by folding it back over the cast brim, cutting two slots to accommodate the webbing strap, and secure in place with two short plaster splints or with tape (Fig. 233).

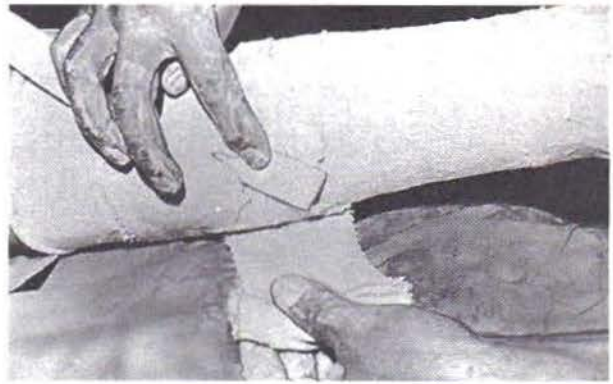

FIGURE 232

7. The suspension waist belt is applied to the patient and the elastic webbing is attached to the safety buckle. Thread the excess elastic webbing through the lower attachment loop of the safety buckle and fold it back underneath the suspension strap (Fig. 234).




FIGURE 233

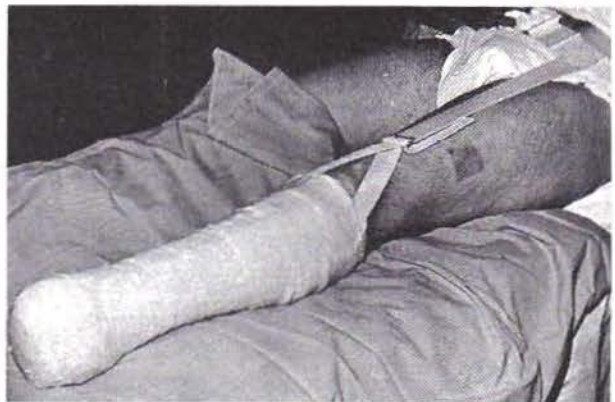

FIGURE 234



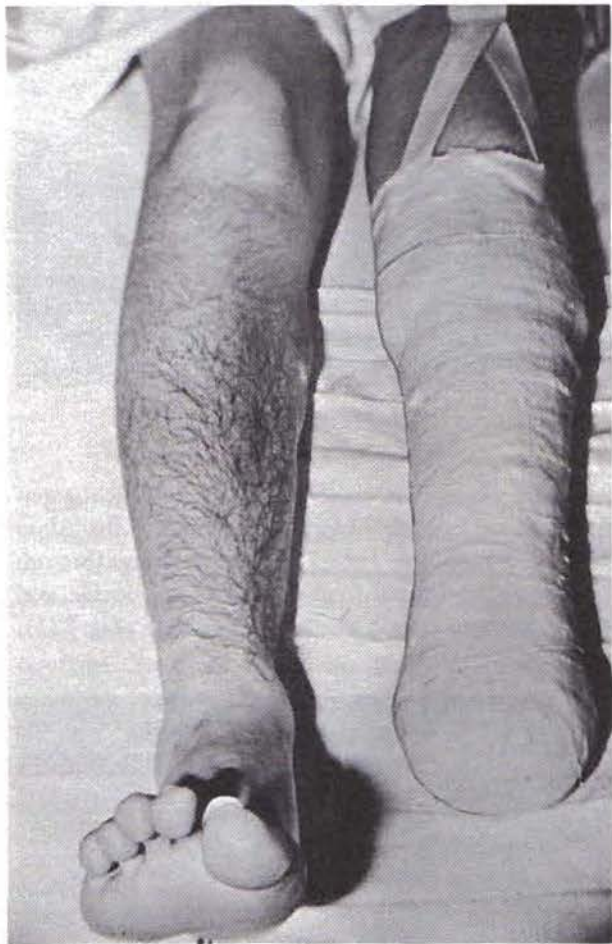


FIGURE 235

### C. APPLICATION OF THE PROSTHETIC UNIT

1. Position the patient so that the pelvis is parallel to the foot edge of the operating table, with the knees about 1½ in. apart. Do not let the sound leg or the amputation stump externally rotate (Fig. 235).

2. Bend the socket attachment straps so they conform to the exterior contour of the plaster socket (Fig. 236). The prosthetic Syme unit is correctly placed when the foot attachment bolt, which is held in neutral, is located slightly posterior and lateral of the stump center. Mark the location of the straps on the cast socket with an indelible pencil.

*Note:* There is no lateral attachment strap. This is to facilitate ease of drain removal (Fig. 237).

3. Fold a double layer of 4 in. x 15 in. plaster splints three times and place them between the back of the

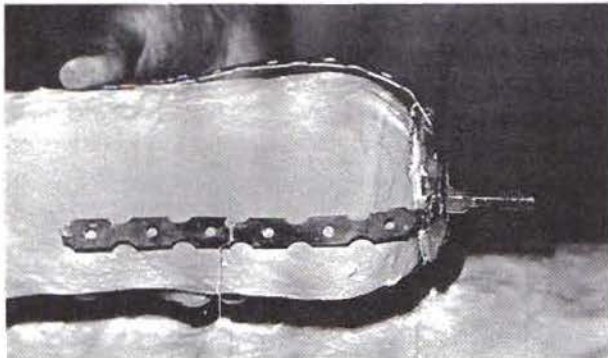

FIGURE 236

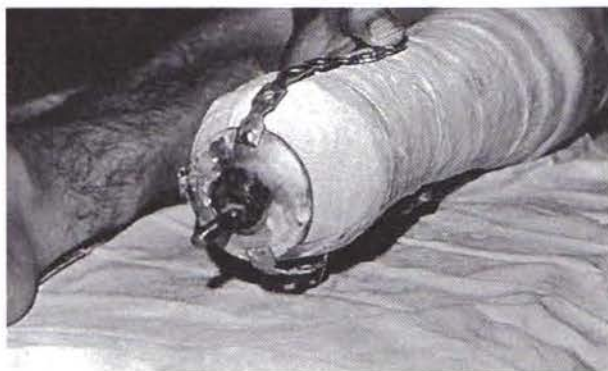

FIGURE 237

socket attachment plate and the distal end of the cast socket. Reapply the plate and straps to the previously established marks and fill in all voids and hollows between the cast socket and the socket attachment plate (Fig. 238).

*Note:* Loose and broken socket attachment straps result if this step is omitted.

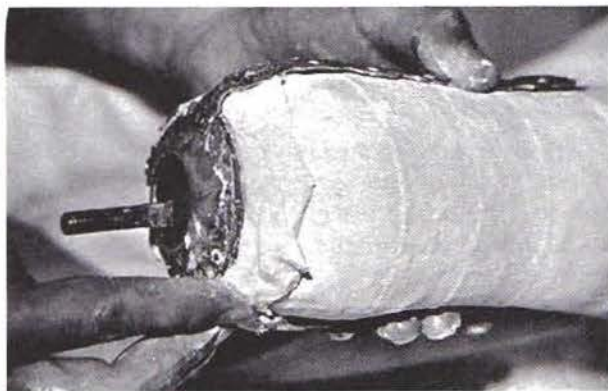

FIGURE 238



4. Laminate the socket attachment straps to the cast socket with one roll of conventional plaster bandage, making sure that the straps are covered entirely all the way down to the socket attachment plate (Fig. 239).

5. The Syme foot is attached to the prosthetic unit

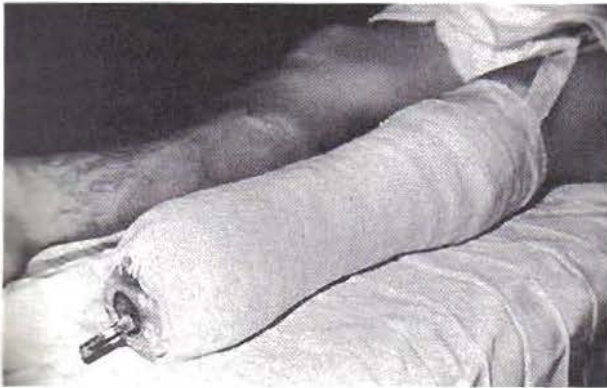

FIGURE 239

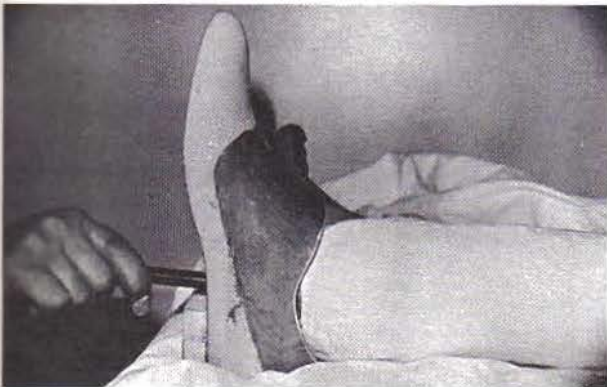

FIGURE 240

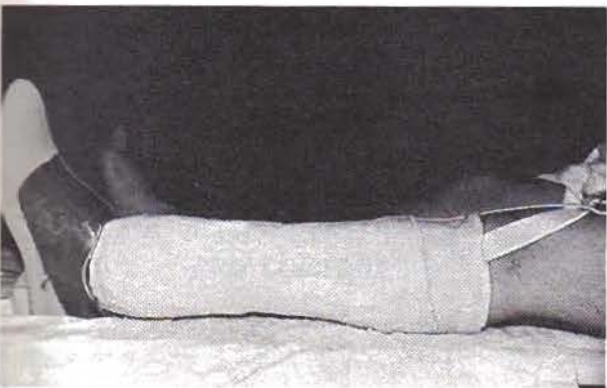


FIGURE 241

with the foot in approximately 5 deg. of dorsiflexion (Fig. 240). Any length differences are measured and recorded. If so indicated, the prosthetist will take the Syme foot back to the prosthetic facility to make the necessary correction. The foot is reattached the day the patient stands for the first time.

After the rigid dressing with suspension belt is completed and the PRS adjustable Syme unit is attached, the patient is ready to be moved to the recovery room (Fig. 241).

THE WHOLE PROCEDURE OF CAST APPLICATION SHOULD NOT TAKE MORE THAN 20 MINUTES WITH PRACTICE.

#### D. SYME PROSTHETIC CONSIDERATIONS

The general philosophy and basic principles of prosthetic considerations for each level of immediate post-surgical prosthetic fitting remain the same with the exception of a shift of emphasis on certain technical aspects. While it is difficult to describe in detail all possibilities of error, following are key considerations:

1. The skived areas of the relief pads must end in a feathered edge, or ridges will reproduce in the cast socket with obvious ill effects to the stump.

2. Improperly located felt relief pads are a frequently repeated mistake. The usual cause is not the lack of proper identification of the tibial crest and pad placement, rather the increase or decrease in stump sock suspension by the assistant, causing displacement of the relief pads. Maintaining firm, even tension to the stump sock throughout the casting process is mandatory.

3. While making full use of the stretch characteristics of the elastic plaster bandage is recommended, avoid overstretching when reversing the direction of the wrap. The larger outer arc of bandage can form a ridge in the underlying plaster bandage and/or stump sock (example: wraps 4 and 7).

4. Never turn or twist a plaster bandage so that it will bunch or have a rope effect. Use the full width of the bandage partially overlapping each previous circumferential turn. If tucking distally appears to be a problem, use short plaster splints instead.

5. Avoid proximal constriction of the cast and/or cutting of the posterior socket brim into the soft tissue.

6. The heel pad must be critically centered on the distal tibia and maintained in complete contact until healed. This is perhaps the most important single consideration in the Syme technique. Use a *minimum*



amount of interface material. DO NOT USE A PREFORMED RETICULATED POLYURETHANE DISTAL PAD. A strip of polyurethane sheeting is located over the suture line.

7. Avoid an overly thick cast.

8. Unless there are specific reasons, do not delay attachment of the PRS adjustable prosthetic Syme unit to the rigid dressing at the time of surgery. The cast socket requires 24 hours to dry and if attachment is delayed so is the patient in his standing and ambulation activities.

9. Improper location of the PRS adjustable prosthetic Syme unit which exceeds the corrective capabilities of the unit requires complete removal from the rigid dressing and correct reapplication. *Instructions need to be carefully followed.* (See Appendix A.)

10. A simultaneous bilateral amputation has the

prosthetic units applied immediately following surgery. A unilateral amputee who is being converted to a bilateral has the prosthetic unit fitted and applied in reference to the existing definitive prosthesis just prior to standing for the first time.

11. If the Syme foot requires final length adjustments, disconnect from the prosthetic unit to make the necessary changes at the prosthetic facility. Return the foot to complete static alignment when the patient stands for the first time.

When complications develop, they are usually traceable to deviations from the outlined techniques. Periodic checkups of alignment and fit are good preventive measures. Investigate patient complaints promptly and make corrections if necessary. Communicate and consult with the other team members frequently to stay informed about the patient's progress.

## CHAPTER 5

# The Hip-Disarticulation Amputation

### I. PREOPERATIVE INSTRUCTIONS TO THE PROSTHETIST

1. When notified by the surgeon, obtain from him all necessary information required and available at this time.

- Side of amputation.
- Proposed level of amputation if this information is available.
- Any additional physical defects of the patient which might restrict or limit movement and/or weight-bearing and ambulation activities.

2. Talk to the patient, explain your role, what you intend to do, and what is expected of him. He may be apprehensive and anxious; don't make him more so. Explain the advantages to be derived from an immediate postsurgical prosthesis and from well-fitting prostheses, generally.

3. Consider any physical defect noted by the surgeon which would influence casting and/or alignment of the prosthetic unit.

4. Note approximate size of the 1/2 in. reticulated polyurethane, 20 ppi, sheeting required. This interface material must be sterilized before application.

5. Note approximate size Orlon Lycra stump sock required. This sock must be gas sterilized before application at surgery (see Table 2, Chapter 2, Section I.6).

### II. PREOPERATIVE PREPARATIONS BY THE PROSTHETIST OF MATERIALS AND COMPONENTS

1. Fashion elongated horeshoe-shaped iliac crest felt relief pads, right and left, of 1/2-in.-thick medium-hard felt.

2. Select and assemble an appropriate adjustable prosthetic unit and pylon.

3. Obtain a shoe from the patient at least one day prior to surgery and fit a SACH foot to it. If the patient is unable to furnish a shoe or if the shoe should be unsatisfactory for proper fitting and alignment, a Kingsley Immediate Postsurgical SACH foot is selected. A neoprene rubber heel can be glued to a conventional SACH foot to level it in order to achieve proper static and dynamic alignment of the prosthesis when the patient stands.

4. Assemble components and materials required for the hip-disarticulation rigid dressing application at the time of surgery (Fig. 242) (see Appendix B for List of Suppliers):

- Small towel
- Sterile Orlon Lycra stump sock
- 2 rolls bias-cut cotton stockinet, 5 in.
- Sterile 1/2 in. reticulated polyurethane sheeting
- Iliac crest felt relief pads, right and left
- Dow Corning Medical Adhesive, Type B
- 4 rolls of 5 in. elastic plaster bandage
- 12 plaster splints, 4 in. x 15 in., extra fast setting
- 3 rolls of 5 in. conventional plaster bandage, extra fast setting

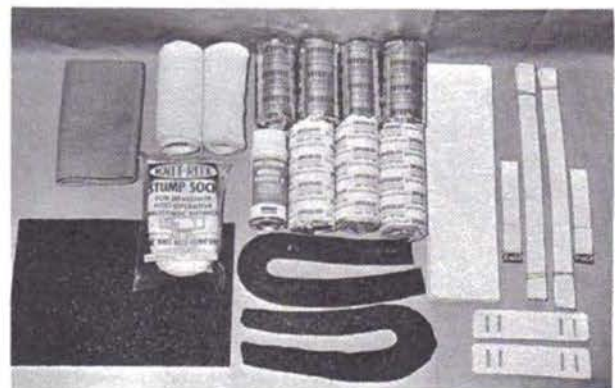

FIGURE 242



- j. 2 (1 in. wide) cotton webbing shoulder suspension straps with safety buckles
- 5. Assemble kit of tools required for hip-disarticulation rigid dressing application at the time of surgery:
  - a. Bandage scissors
  - b. Skiving knife

### III. THE HIP-DISARTICULATION AMPUTATION SURGERY

The Boyd anterior flap approach is used whenever possible and the standard hip-disarticulation procedure is carried out. Muscle stabilization and the filling of dead space are simultaneously obtained by suturing the adductors and extensors to the gluteal muscles with interrupted absorbable suture. Care must be taken to develop a myofascial flap in the adductor group which is sufficiently long for closure.

Adequate postoperative drainage is essential. Suction drainage for the acetabulum and a distal Penrose drain for soft tissue are strongly recommended. The drains are removed 48 to 72 hours after surgery. Then weight bearing is carefully started.

Initially the wound is dressed with nonadherent silk or nylon over which is placed a small amount of well-fluffed gauze.

A sterile Orlon Lycra stump sock holds the dressing in place. For application it must be unrolled completely and cut along its lateral aspect distally to the border of the box toe. Locate the uncut portion of the stump sock over the fluffed gauze dressings and firmly support the stump sock in a proximal diagonal direction.

It should be noted that for any given patient, variations in surgical technique will be necessary. Problems in our series of hip disarticulations have developed when the degree of radiation damage to the skin and myofascial flaps was not recognized and postoperative skin necrosis ensued.

Variations in surgical technique should not, however, preclude the use of the immediate postsurgical rigid dressing. It provides valuable soft tissue immobilization and allows the patient to sit and stand early in the postoperative period (Fig. 243, 244, 245, and 246).

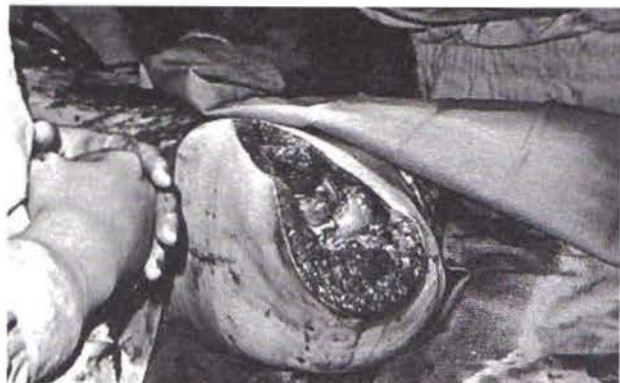

FIGURE 243.—Hip-disarticulation anterior (Boyd) technique prior to closure.

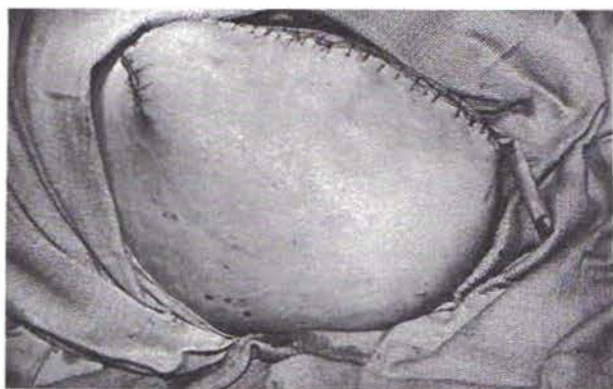


FIGURE 244.—Appearance of hip disarticulation, at time of closure, with drains.

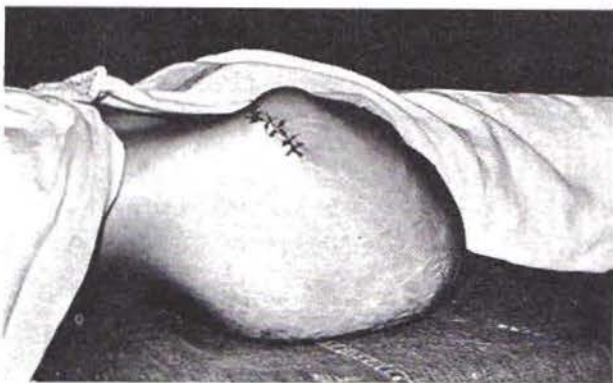


FIGURE 245.—Same patient as in Figures 243 and 244, 24th postoperative day, at time of cast change and suture removal.



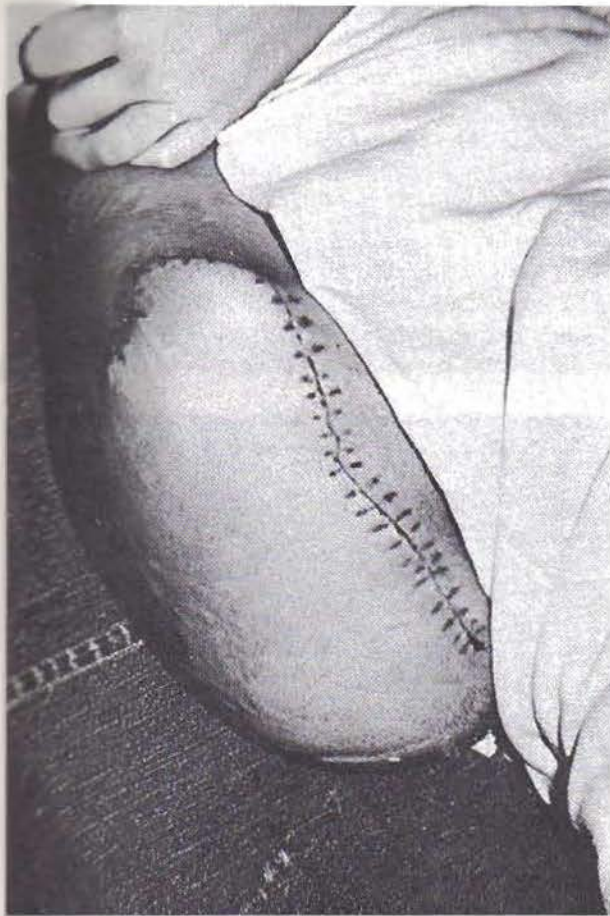


FIGURE 246.—Same as Figure 245.

#### IV. THE HIP-DISARTICULATION IMMEDIATE POSTSURGICAL PROSTHESIS

##### A. PREPARATORY REQUIREMENTS BEFORE APPLICATION OF THE RIGID DRESSING

1. The use of a fracture table for application of the rigid dressing is recommended. Fold back 4 in. of the proximal and cut borders of the Orlon Lycra stump sock. **DO NOT EXPOSE THE WOUND.**

With Dow Corning Medical Adhesive, Type B, spray the entire exposed inner portion of the stump sock including the anterior and posterior borders where the sock has previously been split. Spray the corresponding areas of the skin and allow 5 seconds for the adhesive to become tacky (Fig. 247). Reapply the stump sock firmly in a proximal-diagonal direction

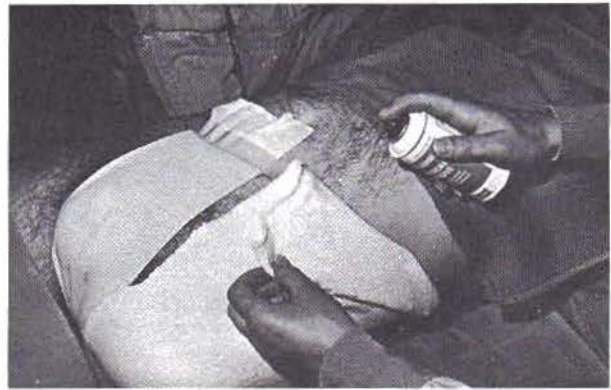

FIGURE 247

towards the sound side and instruct an assistant to maintain it suspended. Avoid leaving wrinkles in the stump sock.

The adjustable shoulder suspension harness, which is interchangeable for left and right, can be substituted to achieve the same result.

2. Place a small folded towel in the area of the stomach to allow for expansion due to food intake later (Fig. 248).

3. Depending on the patient's size, apply one to two rolls of 5-in.-wide bias-cut stockinet. Begin the wrap on the lateral distal portion of the amputated side wrapping diagonally across the abdomen towards the iliac crest and waist. Place alternating wraps over the pelvis and lower waist including the stump. Apply firm tension to the stockinet whenever wrapping over the area of the buttock and anterior distal stump margin. All portions of the pelvis and lower waist to be included in the following plaster wrap should be



FIGURE 248



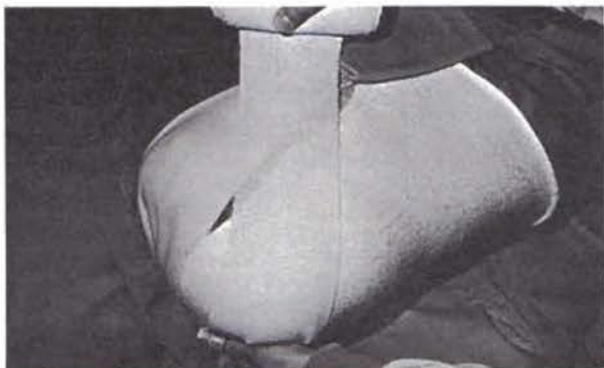

FIGURE 249

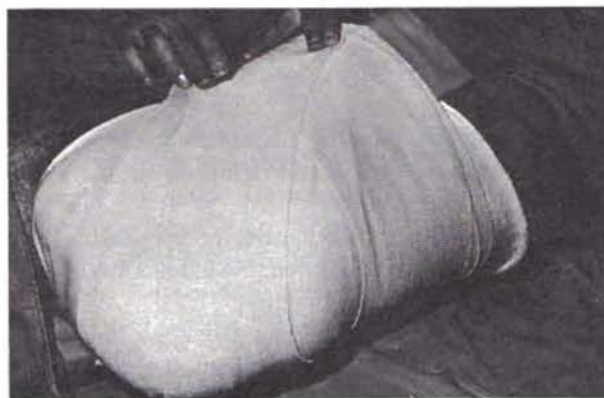

FIGURE 250

protected by approximately two layers of stockinet (Fig. 249 and 250).

4. Prepare an appropriate size of  $\frac{1}{2}$  in. reticulated polyurethane sheeting and trim it to the required shape to cover the total area where the two skin flaps meet.

5. When indicated, add additional pieces of reticulated polyurethane sheeting to areas which appear concave, to insure even overall stump compression and to prevent hematoma.

6. Bevel the polyurethane sheeting, including any additional pieces that may be required, around the entire periphery with a pair of scissors so they will blend smoothly into the plaster wrap.

7. Spray the back of the polyurethane sheeting, including the areas of the stump sock on which it will be located, with Dow Corning Medical Adhesive, Type B. Allow 5 seconds for the adhesive to become tacky, then reapply. Repeat the procedure if additional sheeting is required to fill concave areas. Locate smaller pieces beneath larger ones (Fig. 251 and 252).

8. Prominent iliac crests are relieved with elongated horseshoe-shaped  $\frac{1}{2}$ -in.-thick medium-hard felt relief pads. Both right and left pads are sized, trimmed, skived, and beveled in the appropriate areas for individual requirements.

Locate each pad close to the borders of the iliac crest so the posterior pad extensions are not more than  $\frac{1}{2}$  in. apart. By so doing, the plaster wrap will span these areas without actually contacting the underlying skin. Terminate the relief pads in a feathered edge slightly past the level of the posterior iliac crest.

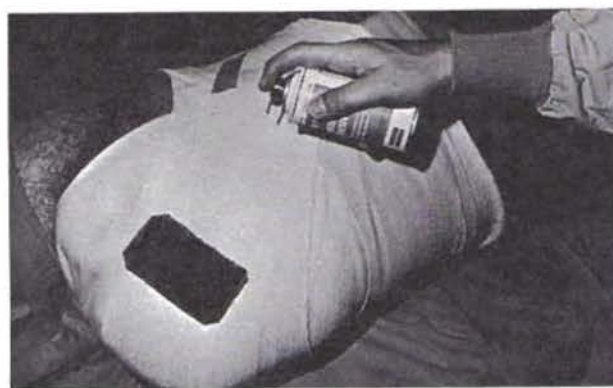

FIGURE 251

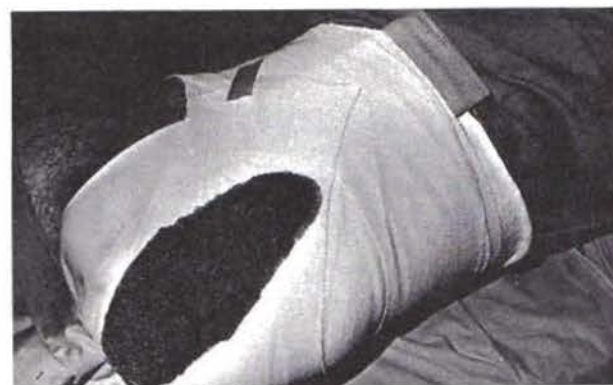

FIGURE 252

9. Maintaining continuous tension on the stump sock, spray the backs of the felt relief pads including the areas of their location on the bias-cut stockinet with Dow Corning Medical Adhesive, Type B. Allow 5 seconds for the adhesive to become tacky.

Reapply the felt relief pads exactly as outlined before (Fig. 253).



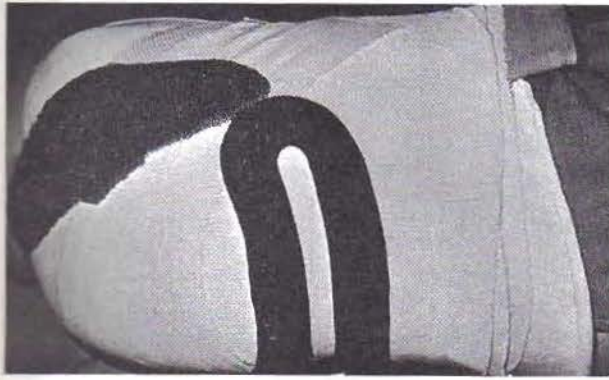


FIGURE 253

*Note:* The  $\frac{1}{2}$  in. separation between the posterior extensions of the felt relief pads also takes into consideration the slight migration of the two posterior extensions towards one another as the elastic plaster bandage is being applied. If the separation exceeds  $\frac{1}{2}$  in., the relief pads lose their function as supports to bridge the plaster wrap across the iliac crest and hence relieve it from pressure. Skin damage over the iliac crest may result. No relief pads are required for an obese patient.

#### B. APPLICATION OF THE RIGID DRESSING

1. For the initial wraps, elastic plaster bandage is used rather than conventional plaster. When using an elastic plaster bandage, the elasticity provides safe and beneficial compression of the stump while conforming well to its contours, providing a smooth rigid dressing. *Continuous tension must be maintained on the stump sock until the plaster has hardened.*



FIGURE 254

Begin the plaster wrap on the distal-lateral stump portion and continue diagonally across the abdomen to the iliac crest and lower waist (Fig. 254). Repeat this procedure twice and alternate the third wrap by placing it circumferentially, covering the pelvis and lower waist region (Fig. 255). Continue in this manner until the cast is completed (Fig. 256). Extend the wrap proximally to include the two lower ribs. The cast socket brim must flare outward for maximum comfort. Keep the plaster bandage from rolling back on itself by relaxing the tension at this portion of the cast socket.

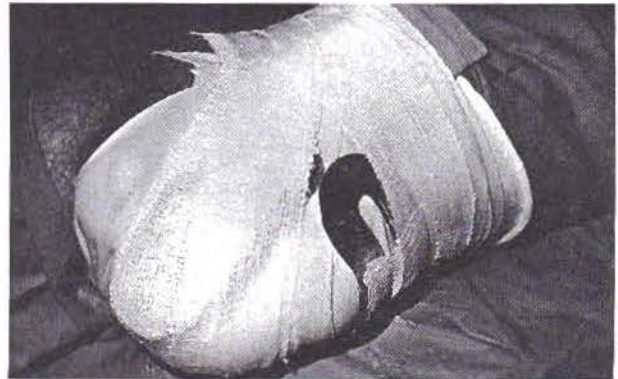

FIGURE 255

By using all available stretch from the elastic plaster bandage, apply firm tension to the buttock and distal anterior stump margin and in effect, maintain the tissue support by anchoring the wrap to the pelvis and waist of the sound side. The circumferential wraps provide cast suspension. Use sufficient elastic plaster bandage to form a three- to four-layer thickness.

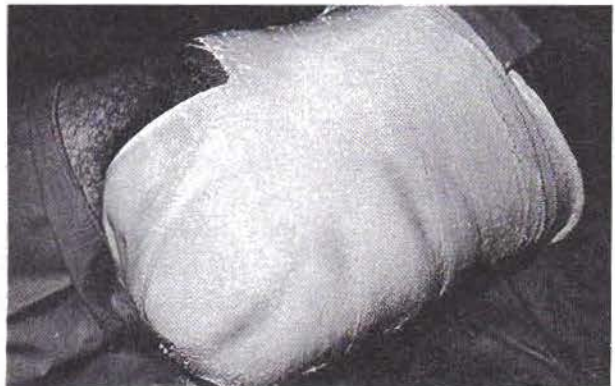

FIGURE 256



2. Because of the inherent structural weakness of elastic plaster bandage, the initial wrap must be reinforced with conventional plaster bandages and splints.

Approximately four to six double layers of 4 in. x 15 in. plaster splints are applied over the distal portion of the cast socket anteroposterior, partially overlapping each previous layer (Fig. 257, 258, and 259).

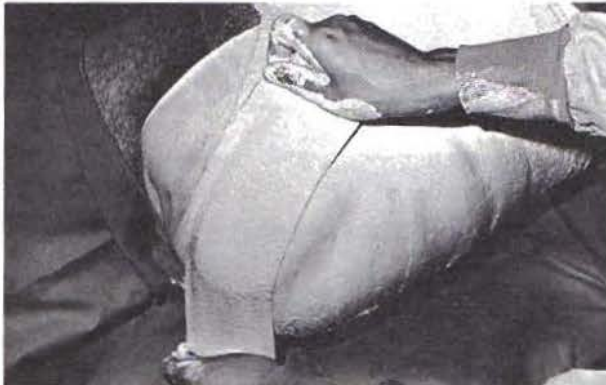

FIGURE 257

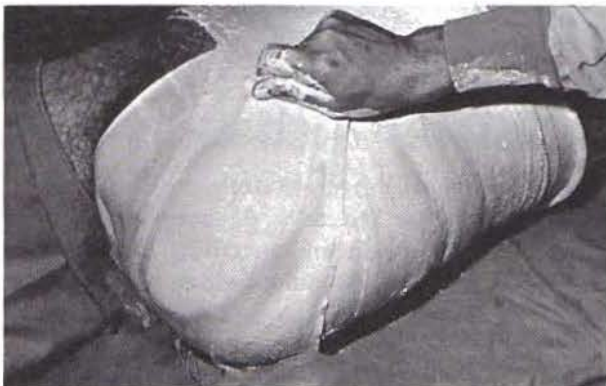

FIGURE 258

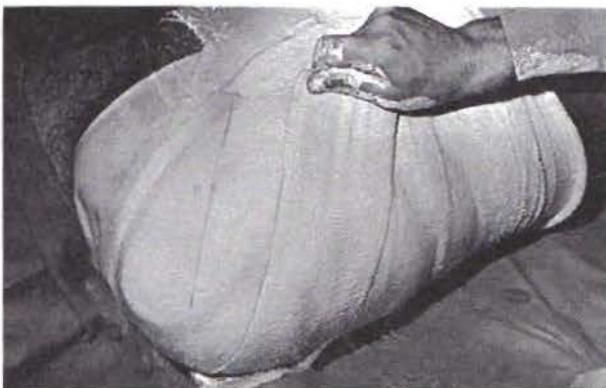

FIGURE 259

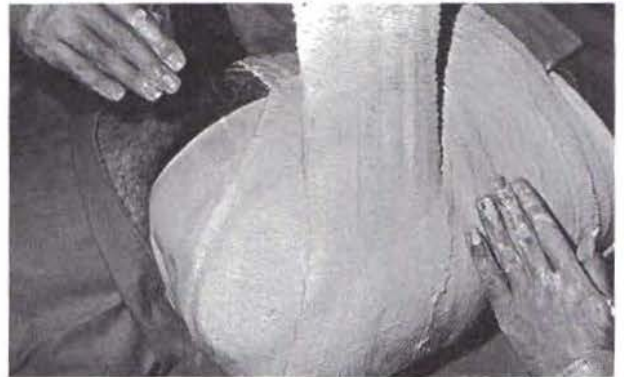

FIGURE 260

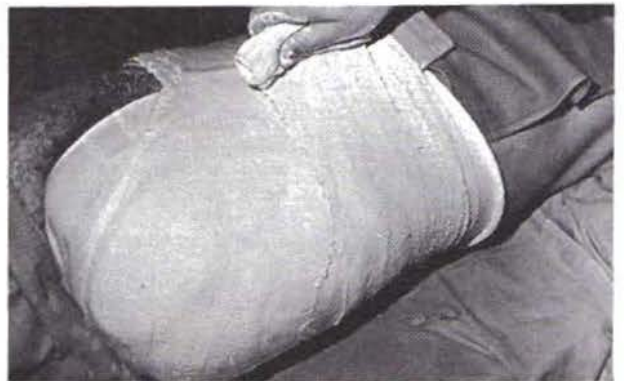

FIGURE 261

3. A roll of 5 in. conventional plaster bandage is applied over the plaster splints in a diagonal and circumferential manner with even, overlapping wraps (Fig. 260 and 261).

*Variation:* For an obese patient, with the plaster of paris still wet, flatten the cast socket slightly with both hands in the anteroposterior dimension. Also mold the plaster into the soft tissue just proximal to the ilium bilaterally. This procedure will improve cast socket suspension and avoid rotational instability (Fig. 262).

4. (a) At the anteroproximal level of the rigid dressing, two 1 in. safety buckles sewn to 1 in. x 8 in. cotton webbing straps, are located about 4 in. apart (Fig. 263).

(b) At the posteroproximal level of the rigid dressing, two 1 in. cotton webbing shoulder suspension straps are located about 4 in. apart and in a direction so they will cross when placed over both shoulders.

5. Incorporate the safety buckles and suspension straps to the cast socket by placing two turns of a 4-in.

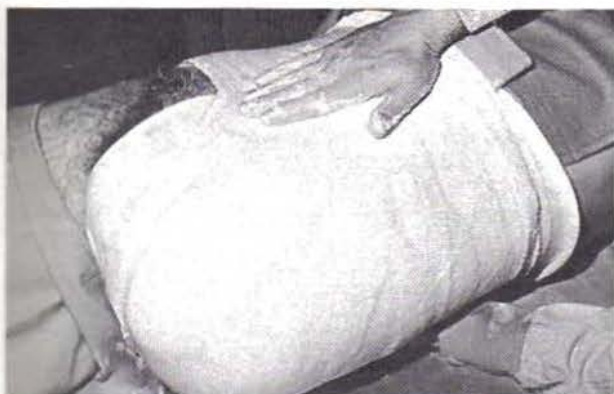

FIGURE 262

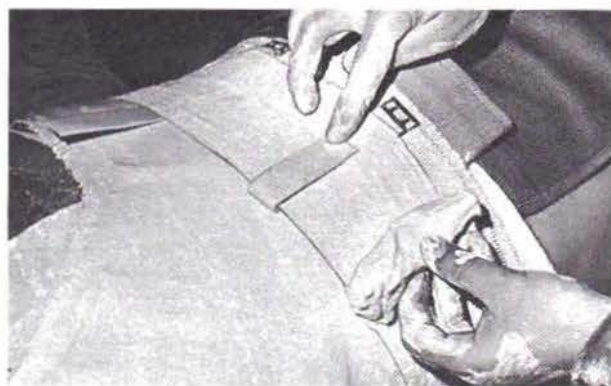


FIGURE 265

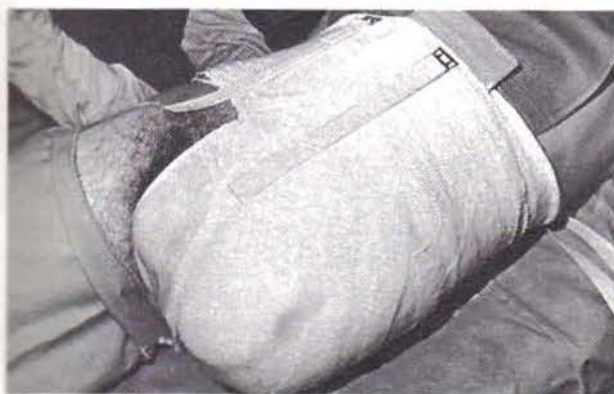

FIGURE 263




FIGURE 266



FIGURE 264

roll of conventional plaster bandage over the webbing retainers and suspension straps (Fig. 264).

The remaining distal portions of the webbing are folded back and wrapped in place with the remaining plaster bandage to anchor them firmly in place (Fig. 265).

6. After the plaster has hardened sufficiently, the proximal tension on the stump sock is released and the towel removed from over the stomach area.

7. With a pair of scissors, cut a slot in the stump sock and the bias-cut stockinet at the level of, and corresponding to, the size of the safety buckles. The sock and stockinet are pulled down over the proximal cast brim and the buckles are passed through the slots. (Fig. 266).



8. Secure the folded back portion of the stump sock and stockinet to the cast with two plaster splints (Fig. 267).

9. Place both shoulder suspension straps over each shoulder after crossing them in back for men, and in front for women. Attach them to the anterior attachment buckles. Thread the excess webbing through the lower attachment loop of the safety buckle and fold the remaining material back underneath the suspension strap (Fig. 268).

The patient is now ready to be moved to the recovery room (Fig. 269).

Drain removal is difficult, if not impossible, with the prosthetic unit attached to the rigid dressing. For this reason, attachment of the prosthetic unit is delayed until the drain (or drains) have been removed (48 to 72 hours postsurgically).

THE WHOLE PROCEDURE OF CAST APPLICATION SHOULD NOT TAKE MORE THAN 20 MINUTES WITH PRACTICE.

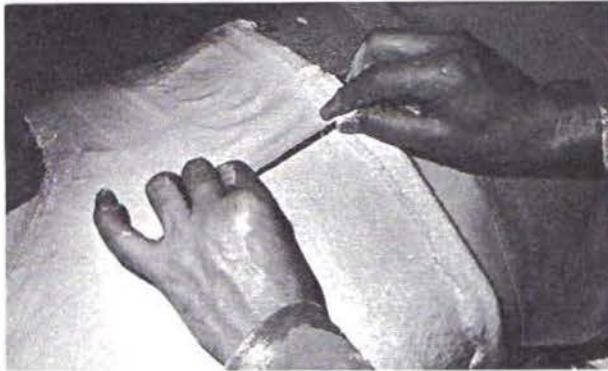

FIGURE 267

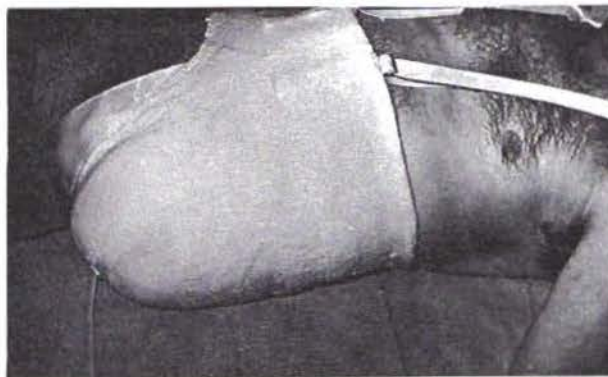


FIGURE 268

## HIP-DISARTICULATION CASTING TECHNIQUE

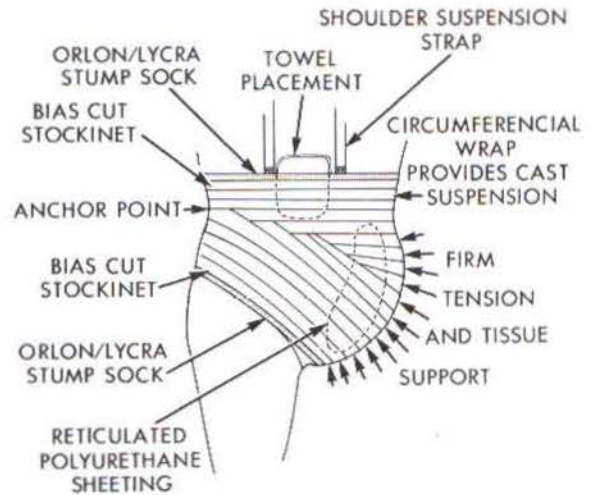


FIGURE 269

### C. APPLICATION OF THE PROSTHETIC UNIT

After the drains have been removed 48 to 72 hours after surgery, the patient is taken to the cast room for application of the prosthetic unit, pylon, and foot.

#### LIST OF SUPPLIES REQUIRED:

- Prosthetic unit, aluminum tubing, and hose clamp
- Immediate Postsurgical SACH foot with bolt and base plug
- Approximately eight plaster splints, 4 in. x 15 in., extra fast setting.

*Note:* Prior to application, two slots should be cut with a hacksaw in the distal (or foot end) of the pylon tubing.

#### LIST OF TOOLS REQUIRED (Fig. 270):

- Metal shears
- Indelible pencil
- Screwdriver
- $\frac{5}{16}$  in. Allen wrench for foot
- $\frac{3}{16}$  in. Allen wrench for prosthetic unit base plug
- $\frac{3}{8}$  in. Allen wrench for unit alignment adjustment
- Tube cutter
- Bandage scissors

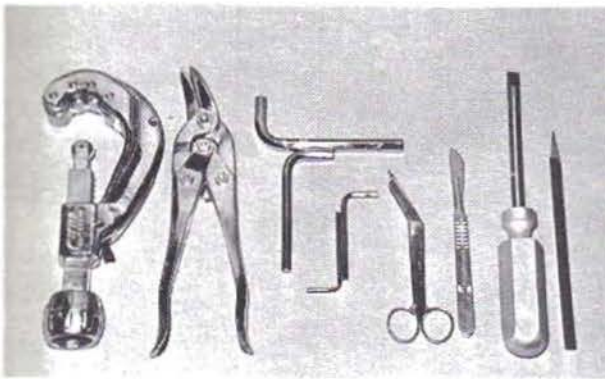


FIGURE 270

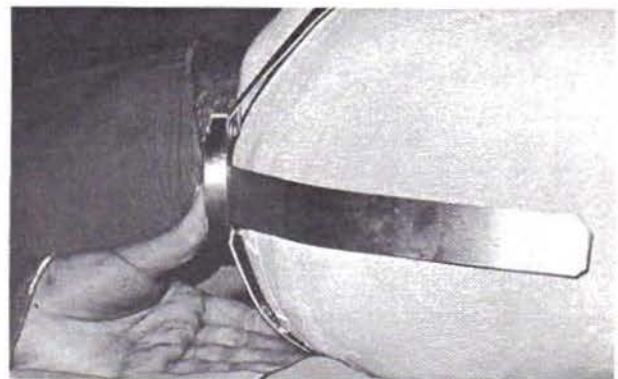


FIGURE 272

1. (a) Position the patient supine so that the pelvis is parallel to the foot edge of the table and place the sound leg in neutral position.

(b) Detach the socket attachment plate from the prosthetic unit by loosening the quick disconnect screw. Fasten three socket attachment straps to the anterior, lateral, and posterior portions of the socket attachment plate with the  $\frac{8}{32}$  in. machine screws provided. Hold the assembly next to the cast socket to determine strap length.

(c) Cut the straps 1 in. below the level of the ilium with metal shears.

2. Bend and shape the socket attachment straps so they closely conform to the exterior contours of the plaster socket (Fig. 271). The socket attachment plate should be:

- a. parallel to the foot edge of the table,
- b. located in the center of the cast socket when viewed laterally (Fig. 272),
- c. 90 deg. to the table top, and
- d. outset so an imaginary verticle line from the

ischial tuberosity will bisect the medial border of the socket attachment plate.

3. Recheck the position of the socket attachment plate to assure that placement is correct and with an indelible pencil mark the location of the socket attachment straps on the cast socket (Fig. 273). With reasonable care, this alignment procedure will result in satisfactory bench alignment requiring few, if any, adjustments when the patient stands.

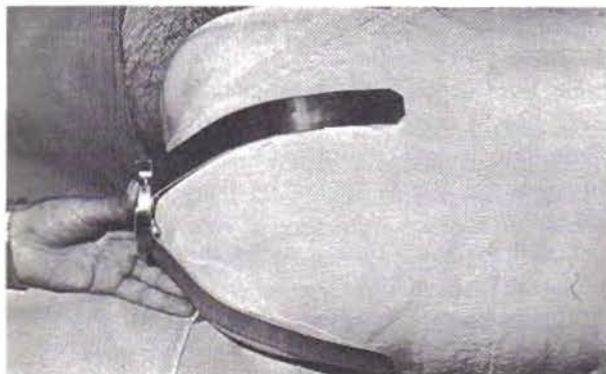


FIGURE 271



FIGURE 273



4. Fold a double layer of 4 in. x 15 in. plaster splints three times and place it between the back of the socket attachment plate and the distal end of the cast socket. Relocate the straps using the reference marks established previously (Fig. 274).

*Note:* Loose and broken socket attachment straps result if step 4 is omitted. Also, secure attachment of the straps to the socket will be impaired.

5. Laminate the socket attachment straps to the cast socket with approximately four to six 4 in. x 15 in. plaster splints and complete the application with one roll of 5 in. conventional plaster bandage. Cover the straps entirely including the portion of the straps just proximal to the socket attachment plate (Fig. 275, 276, and 277).

6. Assemble the adjustable prosthetic unit with all adjustments in neutral position. Attach the assembly to the socket attachment plate by loosening the quick disconnect screw.

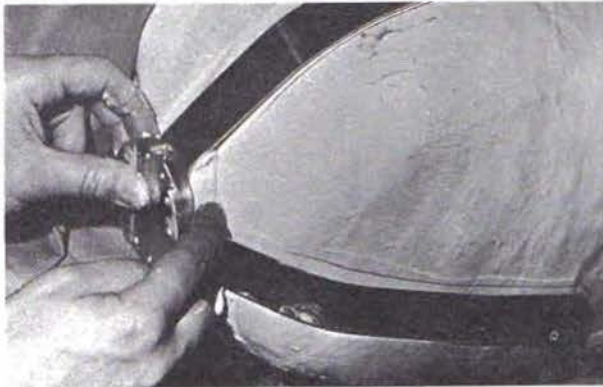


FIGURE 274

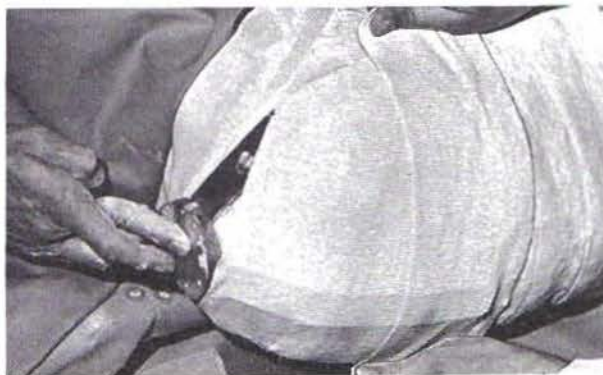

FIGURE 275

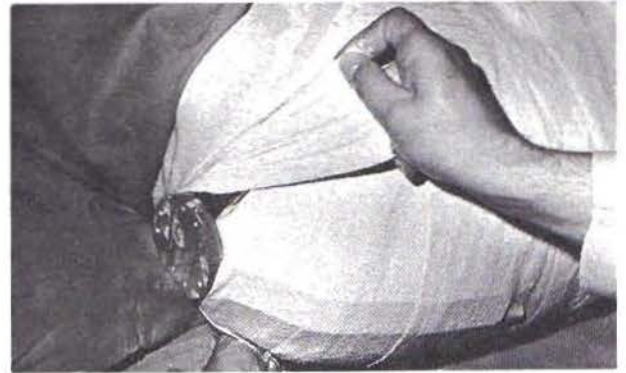

FIGURE 276



FIGURE 277

7. Attach the ankle plug to the foot. Connect the previously slotted portion of the pylon tube to the ankle plug and fasten it securely by means of the hose clamp.

8. Reposition the patient with his pelvis parallel to the foot edge of the table and place the sound leg in neutral position.

With the ankle of the sound foot held in neutral position, compress the heel pad with a straightedge which is projected parallel with the bottom edge of the table across to the heel of the SACH foot. The pylon tube which extends proximally past the prosthetic unit is marked  $\frac{3}{8}$  in. above the proximal level of the base clamp, resulting in a pylon  $\frac{3}{8}$  to  $\frac{1}{2}$  in. short when a shoe is applied on the sound side (Fig. 278 and 279).

9. Cut the pylon tube at the established mark with a tube cutter (Fig. 280).

10. Remove the prosthetic unit from the socket attachment plate by loosening the quick disconnect screw. Insert the pylon in the base clamp of the prosthetic unit.



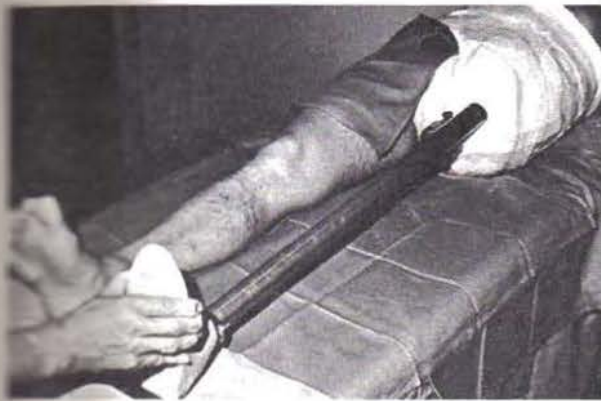

FIGURE 278



FIGURE 280



FIGURE 279

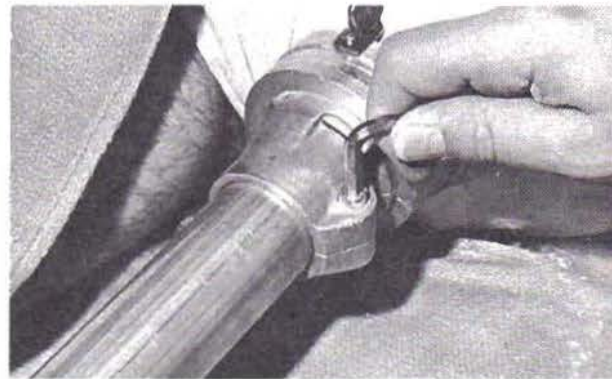

FIGURE 281

11. Reattach the complete assembly to the socket attachment plate and establish approximate toe-out.

Tighten the base clamp of the prosthetic unit with a  $\frac{3}{8}$  in. Allen wrench, securing it to the pylon tube (Fig. 281).

12. Detach the completed assembly from the socket attachment plate by loosening the quick disconnect screw before the patient is taken from the cast room.

#### D. HIP-DISARTICULATION PROSTHETIC CONSIDERATIONS

Simplicity of design, application, and alignment combined with acceptable weight characteristics of the immediate postsurgical hip-disarticulation prosthesis has so far discouraged further improvements to this unit. Simplicity is accomplished at the expense of function. Initially in the static situation, demands on the prosthesis are relatively few but these increase and become progressively more critical as the patient ambulates. While an acceptable prosthetic unit with articulation is possible, alignment and ambulation stresses

present difficulties in retaining the unit securely to the rigid dressing because of the structural weakness of plaster.

While it is difficult to describe in detail all possibilities of error in the application of the hip-disarticulation immediate postsurgical prosthesis, following are key considerations:

1. Avoid suspending the stump sock in such a manner that the most proximal portion is pulling away from the lower waist, resulting in a loose cast in this area. At the same time, avoid proximal constriction by cutting of the socket brim into soft tissue.
2. While it is recommended that full use be made of the stretch characteristics of the elastic plaster bandage, avoid overstretching either border of the bandage. Failure to do so will produce ridges in the underlying plaster bandage and/or stump sock and stockinet.
3. Never turn or twist a plaster bandage so that it will bunch or have a rope effect. Use the full width of the bandage partially overlapping each previous turn.
4. Avoid an overly thick cast.
5. Perhaps the most critical aspect of the initial



plaster wrap is the firm support of the soft tissues on the posterior, distal, and anterior stump margins including the inferior lateral stump portion. Insufficient compression and support of these areas can allow hematoma formation, or in extreme cases, wound separation.

6. There may be some difficulty securing the socket attachment plate and straps to the plaster socket because of the relatively flat attachment surface. Careful

contouring of the socket attachment straps to the rigid dressing affects ultimately the secure attachment of the prosthetic unit to the rigid dressing and the amount of plaster splints required to fill all voids between the socket attachment plate and straps.

7. After the initial cast has been removed, each subsequent cast is applied with the patient in a supported, standing position.

## CHAPTER 6

# Postoperative Management

### I. GENERAL PRINCIPLES

Following the surgery the patient's initial period of weight bearing is supervised in accordance with the surgeon's orders by both the prosthetist and therapist. The prosthetic unit must be aligned accurately with the patient standing. The initial period of standing on the prosthesis is limited to minimal, touch-down weight bearing, involving no more than 5 to 10 lb. of measured weight.

General conditions permitting, the patient stands on the first or second postoperative day for from 1 to 5 minutes. If the patient is particularly debilitated or disoriented or obese, standing should be postponed for several days; however, activity in bed is encouraged. Gentle repetitive axial load, simulating stance, can be applied to the end of the cast socket manually, or with use of a tilt table. Weight bearing is specifically delayed if, because of poor patient cooperation, excessive weight on the prosthesis is feared. The time for initiating weight bearing *must be decided* by the surgeon in consultation with the therapist.

Standing with minimal weight bearing on the first postoperative day and daily thereafter is of significant value both physiologically and psychologically, but excessive pressure on the stump in the range of forty or more pounds can compromise wound healing. Even though well tolerated by the patient, axial loads of this magnitude *should be avoided* until the wound is well healed. The temporary limb is not designed for full weight bearing even though such has occurred without untoward results in many cases, particularly with children. To obtain the maximum advantage of this system of management, however, daily protected weight bearing on the temporary prosthesis is essential. Controlled standing and walking early following surgery maintains optimal wound pressure relationships and controls edema.

Once weight bearing has been initiated and the prosthetic unit aligned, standing in the parallel bars on paired scales becomes a twice-daily exercise. When endurance has increased to permit standing for 5 minutes several times during each of the twice-daily periods, ambulation is begun. The distance traveled in the parallel bars is gradually increased according to the patient's tolerance, but weight on the amputated side *should not* exceed 20 lb. until the initial rigid dressing cast has been changed and primary wound healing assured.

Throughout the postoperative ambulation training, the patient begins and ends each session standing on the paired scales to get the "feel" of the prescribed degree of weight bearing on the initial prosthesis.

Ambulation with three-point gait without the prosthetic unit attached to the cast socket can result in loss of stump-socket pressure. Even with a well suspended cast, the prosthesis tends to fall away slightly unless the prosthetic foot rests on the floor. Total contact may thus be lost, permitting edema. Ambulation without at least touch-down or minimal weight bearing is not advised.

When the patient actually begins walking, usually within the first week after surgery, the standard principles of amputee gait training are followed. The transition from parallel bars to crutches is not advised until after the first cast change, approximately 2 weeks postoperatively. Thereafter, crutch walking is urged. When the definitive prosthesis has been delivered, progression to full weight bearing is promptly achieved.

Some discomfort and occasional phantom sensations may be expected in the early ambulation of the fresh amputee. Mild analgesics will be helpful during these first few days. Sharp or localized pain on standing or on ambulation is uncommon and should be evaluated carefully by the therapist, the prosthetist, and the surgeon.



A loose cast must be changed as soon as it is recognized. The above-knee and the hip-disarticulation sockets usually require changing at 1 week to 10 days, the Syme and the knee-disarticulation casts at 10 to 14 days, and the initial below-knee cast at 2 weeks. If the cast accidentally comes off, a tensor bandage should be applied snugly to the stump immediately and a new cast applied as soon as possible. Edema can develop within a short period of time to such a degree that many additional days of therapy are required and repeated cast changes are needed to regain proper stump conditioning and maturation.

A patient unable to ambulate can still benefit from the rigid dressing. Variations from the usual procedure depend on whether the patient is temporarily or permanently unable to ambulate. Patients who are permanently unable to walk need no prosthetic unit. Under these circumstances, manually simulated weight bearing can be carried out under the supervision of the nurse or physical therapist as an aid to wound healing and pain control. Temporary inability to ambulate may dictate incorporating the prosthetic unit in the rigid dressing at the time of surgery or at a later date. When standing activity is questionable, using only a walkerette, the patient is placed on a tilt table or circular bed. Axial loads are then controlled by the degree of the table tilt and are measured by scales located at the foot board of the tilt table or circular bed (Fig. 282).

A previously unilateral amputee converted to a bilateral amputee requires the pylon tube to be measured with the existing definitive prosthesis in place prior to standing.

The ultimate goal of immediate postsurgical fitting of a prosthesis and early ambulation is rapid, maxi-

mum rehabilitation of the patient. Prompt, primary wound healing is the first concern. This will result from meticulous and appropriate surgery, proper casting technique, and precise patient control during the post-operative period.

Equally important is the morale of the patient. Gentle, compassionate firmness must be the rule. However, the most accurate source of information regarding both wound healing and patient morale is, needless to say, the patient himself. The therapist is in the best position to elicit and evaluate these observations. As convalescence progresses, it is the therapist's singular responsibility to make them meaningful. Unusual pain or discomfort generally is first noted by the therapist who thus remains the first line of defense against delayed rehabilitation. The success of the program often depends upon the therapist's initiative to observe the patient carefully, determine what may be wrong, and then discuss the problem promptly with the surgeon and the prosthetist.

## II. THE FIRST 2 WEEKS

### A. THE DAY OF SURGERY

#### FOR THE SURGEON AND THE NURSE:

The patient is returned by way of the recovery area to his room. His bed has an overhead trapeze attached to allow the patient to assist himself.

The rigid compression dressing on the amputation stump will allow considerable freedom of movement in the bed. The leg is not elevated. Application of ice bags to the cast is not required and should be avoided, especially in the patients with peripheral vascular disease. Pain is controlled by the usual narcotics as necessary. The pain is generally described as that of circumferential constriction around the stump. Discomfort of this type is not an indication for splitting the cast nor removing it. If the patient complains of severe localized pain, particularly in the areas of bony prominences (pressure sensitive areas), then the surgeon should suspect localized undue pressure and consider relieving this pressure by splitting the cast or by removing it completely and applying a new cast. Wound breakdown can occur in a very short time, particularly in the ischemia patient, if pressure relationships are improper. Careful adherence to the technique as outlined has, in our experience, practically eliminated the necessity for premature cast removal.



FIGURE 282



However, improper placement of pressure relief pads, wrinkles in the plaster or the stump sock, or other sources of localized pressure can produce pain. The surgeon should not hesitate to split or remove the cast if he suspects undue local pressure.

Staining of the cast from bleeding and wound drainage is often seen. This is particularly expected where a drain has been left in the stump at the time of surgery.

The suspension belt must be checked frequently and adjusted to insure necessary support and suspension of the prosthesis.

#### FOR THE PROSTHETIST:

If the prosthetist did not apply and align the adjustable prosthetic unit in the operating room, he does so in the patient's room on the day or evening of surgery. He will require assistance to hold the patient's extremity while the unit is being properly applied and aligned.

### B. THE FIRST POSTOPERATIVE DAY

#### FOR THE SURGEON AND THE NURSE:

Pain will ordinarily persist for 3 to 5 days, but should decrease progressively. Standing with minimal weight bearing will often be helpful in relieving pain.

If muscle spasms in the stump are troublesome, relief may be gained by gentle compression on the cast over the end of the stump. The patient himself can accomplish this by pulling gently on the two ends of a bath-towel in which the plaster socket is cradled.

At this time, and for several days, undue active motion of the extremity may initiate muscle spasm in the stump. If muscle spasms are troublesome, the patient and nurse should be instructed in passively assisting the positioning of the extremity.

The patient may be up in a chair as tolerated with the leg supported after the first or second postoperative day. The surgeon will inform the prosthetist when the patient is ready to stand at the bedside.

Oversedation at the time of standing should be avoided. Gentle pressure on the prosthetic foot is usually not a painful experience. If narcotics are to be given, the injection should be administered immediately prior to standing so that the systemic effect occurs after the patient has been returned to bed.

Standing should be postponed beyond the first postoperative day only if medical contraindications exist or if uncontrolled excessive weight bearing is unavoid-

able because of an uncooperative, poorly coordinated, or massively obese patient. Additionally the patient may be unstable on the prosthesis of a previously amputated leg and thus be unable to control his weight bearing.

The surgeon or the nurse must be sure that the cast and suspension remain snug.

#### FOR THE PROSTHETIST:

On notification from the hospital that the patient is medically ready for standing, the prosthetist arranges a suitable time to see the patient in the hospital room, with the nurse and physical therapist present. While the patient is standing, the prosthetist checks static alignment. If care has been taken on the day of surgery to apply the unit correctly, virtually no adjustments will be necessary at this time. Any necessary changes are made after the patient has been returned to bed.

#### FOR THE PHYSICAL THERAPIST:

At the appointed time, the physical therapist, who has worked with the patient preoperatively, brings the proper size walkerette to the patient's hospital room. A shoe is placed on the sound foot, and the suspension belt is checked for tightness, adjusting it if necessary. The patient is assisted to a standing position in the walkerette.

It is best to apply the pylon, foot, and shoe in bed and then bring the patient to a sitting position, first by using the mechanics of the hospital bed. Throughout this procedure the patient is reassured and encouraged to relax.

No weight is placed on the prosthesis until the patient is standing in the walkerette at the bedside and the prosthetic foot is in proper, normal standing position. The patient is then instructed to put minimal pressure on it as if standing on two feet. As stated earlier, this will be light touch-down weight only. Standing should not exceed 5 minutes at this time. Standing should not be encouraged beyond the point of discomfort, ordinarily no more than 5 or 10 lb. of weight. Upon return to bed, the pylon and foot are removed.

### C. THE SECOND POSTOPERATIVE DAY

#### FOR THE SURGEON AND THE NURSE:

The Penrose drain, when used, is removed from the stump with sterile instruments through a window cut



in the cast directly over the drain. The dressings are disturbed minimally. The window is replaced and secured carefully with a wrap of plaster. Adhesive tape is *not sufficient* for maintaining the position of the window. Local edema in this area will result if the win-




FIGURE 283

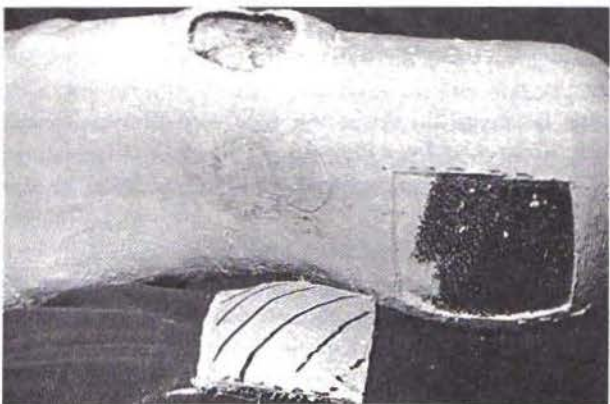


FIGURE 284

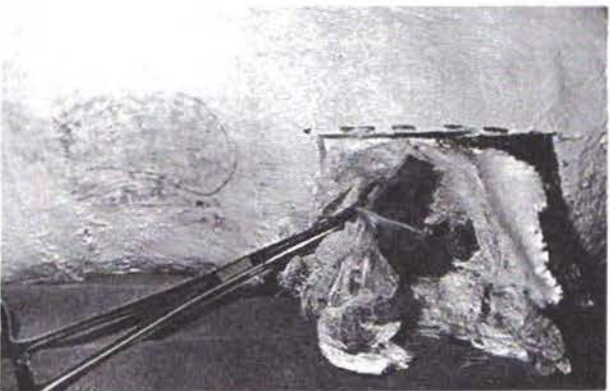


FIGURE 285

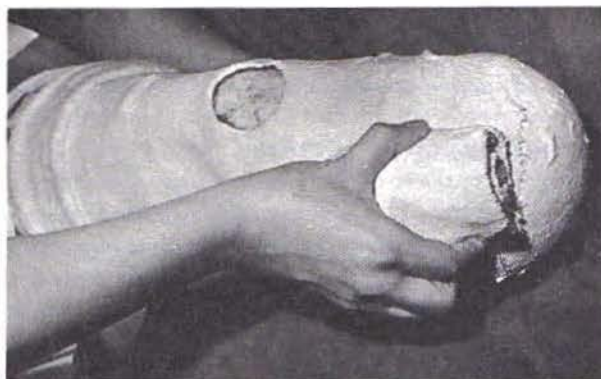

FIGURE 286

dow is not rigidly replaced in its original position. The Penrose drain should not be left in the wound more than 48 hours. Suction drains are also withdrawn at 48 hours or when drainage ceases (Fig. 283, 284, 285, and 286).

#### FOR THE PHYSICAL THERAPIST:

The patient may now come to the physical therapy department in a wheelchair twice daily for standing and continuing upper-extremity strengthening exercises.

In the physical therapy department the patient first stands between parallel bars on paired scales (Fig. 287 and 288). In this way he can be guided to apply 20-30 lb. of weight on the immediate postsurgical prosthesis while carrying virtually all of the remainder of his body weight on his opposite leg and his hands. He thus learns to balance himself bearing only partial weight on the amputated side and begins to develop a guide to the amount of pressure that he should be placing on the recently amputated stump.




FIGURE 287



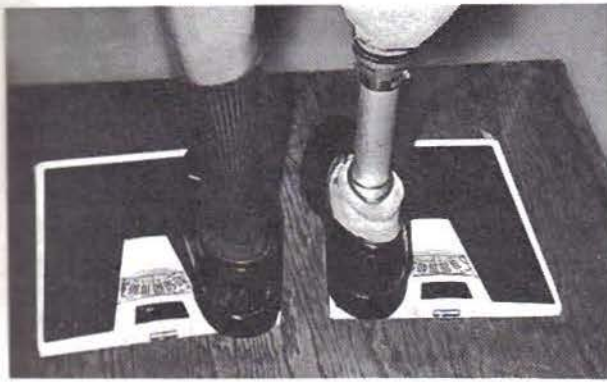


FIGURE 288

The pylon and walkerette should not be left in the patient's room for the first week or two after surgery. This precaution prevents unsupervised ambulation.

#### D. POSTOPERATIVE DAYS, 3 TO 14

##### FOR THE SURGEON AND THE NURSE:

Daily observation is essential to be sure that excessive looseness of the cast does not develop. The suspension straps must always be snug. If the below-knee cast pistons more than  $\frac{1}{2}$  in. when observed at the patellar cut-out, it should be changed. The above-knee cast has no inherent suspension so that it must be checked for looseness by inspection at the brim.

The initial below-knee amputation cast is ordinarily changed by or before the 14th postoperative day but may require changing earlier in those cases where excessive edema was present at surgery or if the patient is obese. Occasionally the original cast can be left on for as long as 3 weeks, dictated by circumstances at the time of surgery. The above-knee and hip-disarticulation sockets will require changing at 7 to 10 days. The Syme and knee-disarticulation sockets usually are changed during or at the end of the second postoperative week.

Suture removal either total or partial is often possible and even advisable at the first cast change with wound reinforcement by sterile adhesive strips. This minimizes further suture irritation when applicable.

At the time of cast change, the stump should not be left for more than a few minutes without support by tensor bandage or air splint. Significant edema in an unsupported fresh stump can develop in a very short time.

If the cast comes off inadvertently, the stump should

immediately be wrapped correctly with a tensor bandage. The prosthetist or surgeon then applies a new cast as soon as circumstances permit.

The patient may be discharged home prior to the first cast change if he is completely dependable and his postoperative course has been uncomplicated. He should be followed carefully for ambulation under the supervision of the physical therapist. The surgeon should see the patient regularly prior to initial cast change.

##### FOR THE PROSTHETIST:

The prosthetist checks the patient several times as indicated during the first postoperative week, particularly on the first few days of actual ambulation, observing alignment of the prosthetic unit. Thereafter he will carry out the cast changes and check prosthetic alignment.

##### FOR THE PHYSICAL THERAPIST:

When the patient's standing balance on the scales is satisfactory, ambulation is begun in the parallel bars. The standard principles of gait training are followed, although the below-knee amputee must walk with an immobilized knee. The distance walked is increased slowly and steadily, though not exceeding the point of the patient's fatigue or discomfort.

Throughout postoperative gait training, the patient begins and ends each session by standing on the paired scales to get the "feel" of the approximately 20 lb. maximum weight to be placed on the temporary prosthesis. Larger increments of weight will not speed healing, and excessive stress on the stump has led to wound healing problems. The transition from parallel bars to crutches is allowed prior to the first cast change only if balance is excellent. Thereafter crutch walking is urged. When the definitive prosthesis has been delivered, progression to full weight bearing is achieved as promptly as tolerated.

A loose cast is the most important external factor leading to wound complications and the most common cause of stump pain in the second postoperative week. Alertness of the patient and vigilance of the physical therapist are prerequisites to its recognition.

### III. THE SECOND 2 WEEKS

During the second 2 weeks following surgery the stump matures rapidly, yet still remains vulnerable to



injury, especially in the poorly vascularized or scarred limb. The patient, surgeon, therapist, and prosthetist must continue to be alert for incipient problems. Weight bearing now should remain limited to 20 to 30 lb., and a loose cast should be changed promptly.

#### FOR THE SURGEON:

The patient may be discharged from the hospital as soon as the surgeon and therapist are satisfied that proper management can be continued at home or in an extended care facility. This requires the safe use of crutches for daily ambulation with no more than 30 lb. weight on the prosthesis at any time. After discharge, the patient should be seen by the therapist two or three times weekly.

In the second 2 weeks following surgery the patient will require a second cast change and final sutures removed if indicated. The wound can be reinforced with sterile adhesive strips if necessary. The second cast change is usually done 10–14 days after initial cast removal depending upon suspension and fit.

Cast and measurements can be taken for the definitive prosthesis 5 to 7 days following the second cast change if the wound is well healed and all sutures have been removed.

#### FOR THE PROSTHETIST:

##### *Application of a Short Cast*

Application of a short cast in the below-knee amputee to permit mobilization of the knee joint may be utilized following suture removal. This does not include partial suture removal or substitution of sutures by sterile adhesive strips.

**THE WOUND MUST BE HEALED AND RELATIVELY STABLE TO TOLERATE INCREASED LEVERAGE AND STRESS FROM AMBULATION IN A SHORT CAST.** If there is any reason for doubt, continued immobilization of the knee joint is advised. This includes patients who are uncooperative, poorly motivated, lacking coordination, or are obese. When all indications are satisfactory, the short below-knee cast is applied as follows:

1. The patient is preferably in a supine position on a casting table or stretcher. Place a folded pillow under the thigh to allow the patient to relax completely the stump and thigh musculature. Voluntary muscle contraction by the patient during casting will result in a loose cast. The sterile Orlon Lycra stump sock of an appropriate size is rolled onto the stump and held

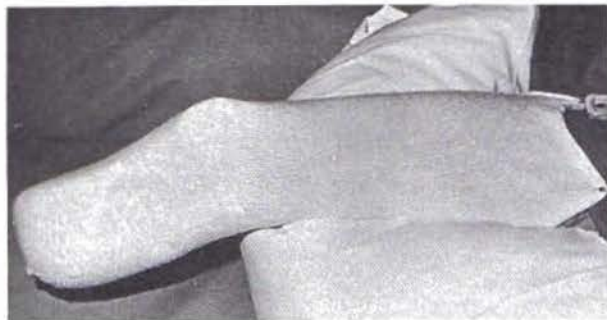


FIGURE 289

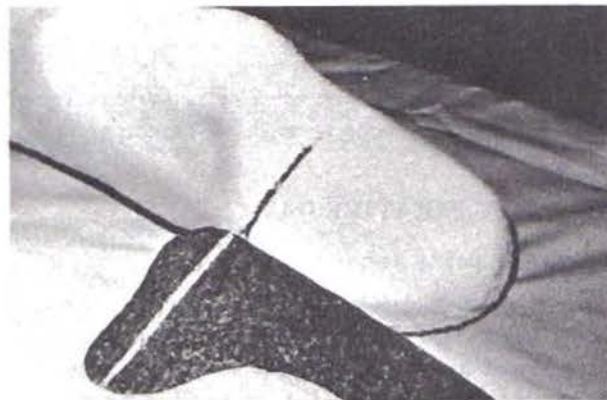

FIGURE 290

under tension as demonstrated in the below-knee initial rigid dressing application. Control the tension to the stump sock so the stump is placed in a flexed attitude of approximately 25 deg. The sock should be smooth and free of wrinkles when properly suspended (Fig. 289).

2. The felt (or compressed polyurethane) relief pads which come in a standard size, right and left, must be trimmed, skived, and/or beveled in the appropriate areas for individual needs. No patellar relief pad is required for the short below-knee cast.

(a) The medial felt relief pad is located with the center of the posterior extension placed on the concave apex of the medial tibial condylar flare (Fig. 290).

Slide the pad anteriorly on the stump until the beveled portion rests on the shaft of the tibia  $\frac{1}{4}$  in. medial to the tibial crest throughout its length. Trim the posterior extension of the felt pad so it will not impinge posteriorly on the hamstrings (Fig. 291). Skive the area which has been trimmed.

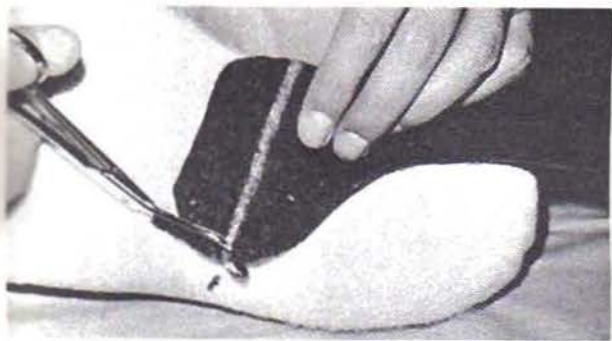


FIGURE 291

The medial felt pad should extend distally  $\frac{3}{8}$  in. beyond the cut end of the tibia. Care should be taken not to confuse the beginning of the bevel on the tibia with the cut end of the bone. Cut the medial relief pad to the proper length and bevel the cut edge of the felt so that it will blend into the plaster wrap without causing bumps or ridges (Fig. 292).

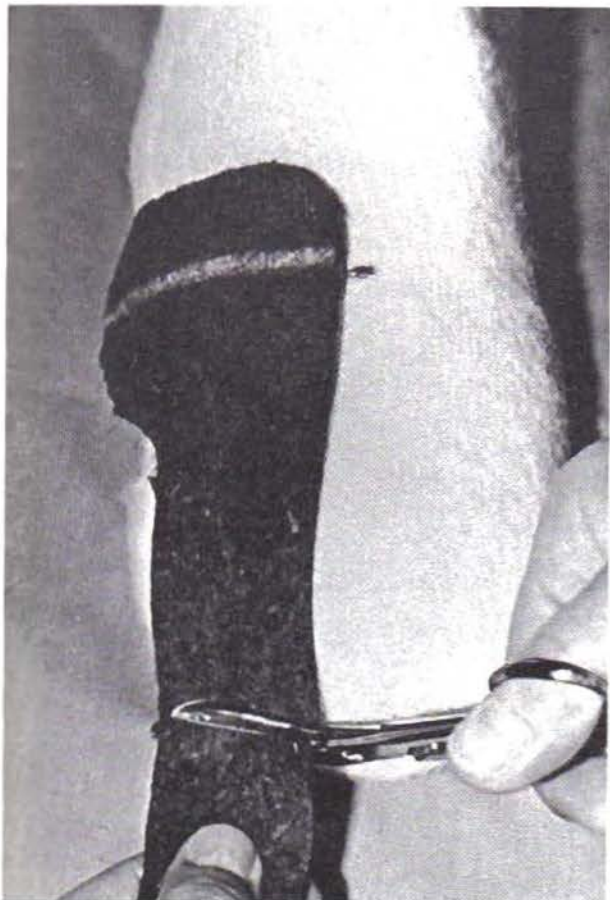


FIGURE 292

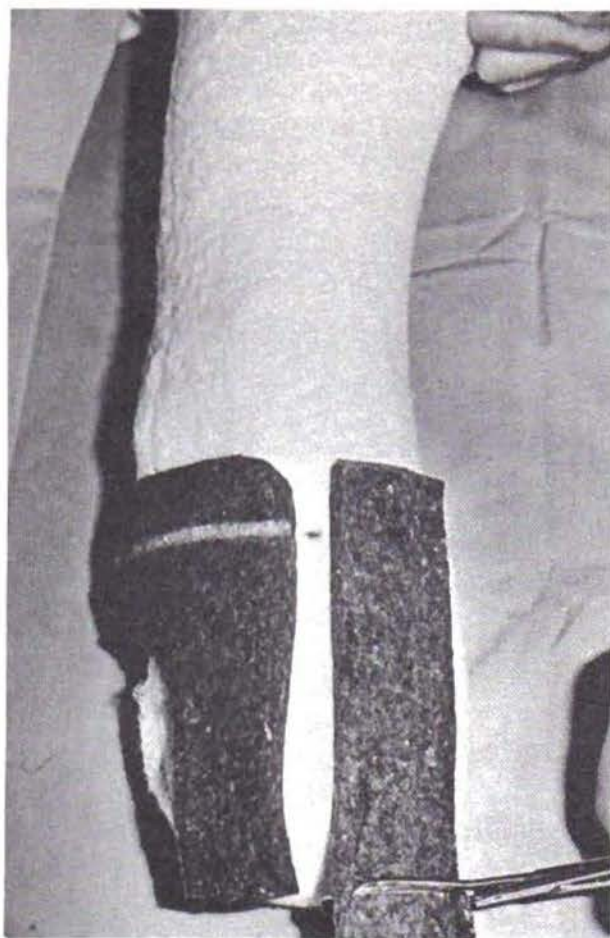


FIGURE 293

(b) The lateral felt relief pad is placed opposite the medial pad with the beveled portion located  $\frac{1}{4}$  in. lateral to the tibial crest through its entire length. If the application has been performed correctly, this will relieve the tibial tubercle and the tibial crest. Cut and bevel the lateral felt pad distally in the same manner as the medial pad (Fig. 293).



*Variation:* It is frequently necessary to cut two wedge-shaped pieces off the felt pads distally to insure that an equal continuous  $\frac{1}{2}$  in. relief gap is maintained between the felt pads throughout their entire length (Fig. 294, 295, and 296).




FIGURE 294

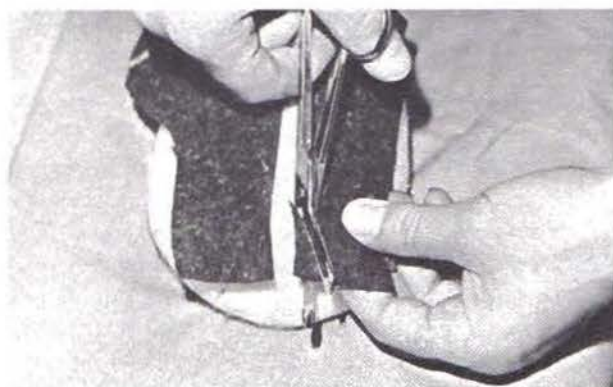


FIGURE 295




FIGURE 296

(c) *Maintaining continuous tension on the stump sock*, spray the backs of the felt relief pads and the areas of the stump sock on which they will be located with Dow Corning Medical Adhesive, Type B. Allow 5 seconds for the adhesive to become tacky. Reapply the felt relief pads exactly as outlined before (Fig. 297).

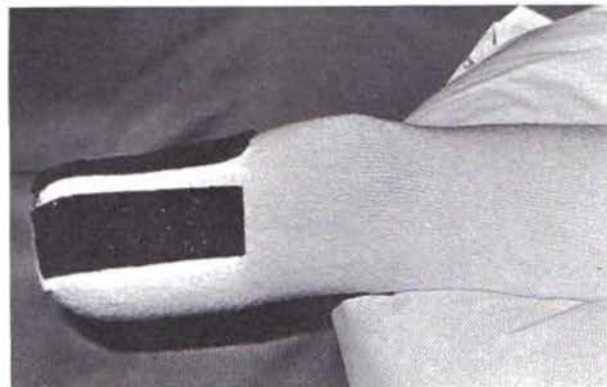


FIGURE 297

*Note:* Polyurethane relief pads are provided with adhesive backing. The protective paper is peeled off just prior to application of the pads to the stump sock.

The  $\frac{1}{2}$  in. separation between the felt relief pads takes into consideration also the slight migration of the pads toward one another as the elastic plaster bandage is being applied. If the felt pads are separated more than this, they no longer function as supports to bridge the plaster across the tibial crest and hence relieve it from pressure. Skin damage over the tibial crest may result.

3. A reticulated polyurethane distal pad of the proper size is selected and applied over the felt relief pads to the distal end of the stump (Fig. 298).

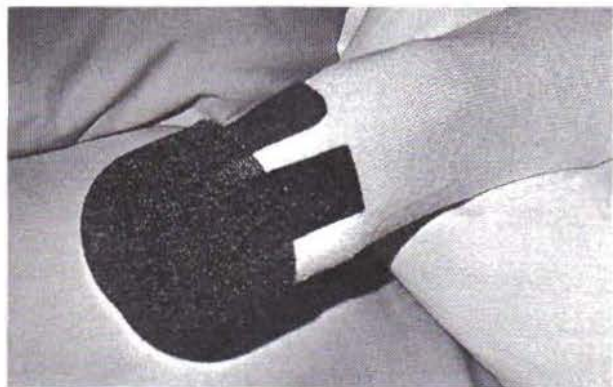

FIGURE 298

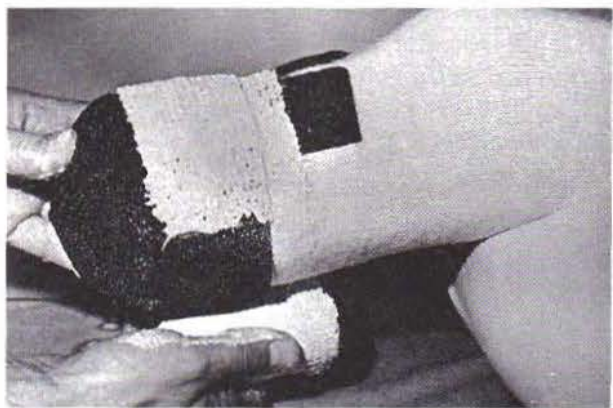


FIGURE 299

4. For the initial wraps, elastic plaster bandage is used rather than conventional plaster. Continuous tension must be maintained on the stump sock until the plaster has hardened. *The patient must keep his stump and thigh relaxed since muscle contraction during the casting procedure will result in a loose cast.*

#### Wraps 1 and 2:

The wrap is always started on the lateral aspect of the stump to avoid medial displacement of the gastrocnemius. Cover the proximal feathered edge of the polyurethane distal pad with the elastic plaster bandage (Fig. 299). Minimal tension is applied to the bandage with this circumferential wrap, clockwise for a right stump and counterclockwise for a left stump when viewed anteriorly. One and three quarter circumferential turns will secure the felt relief pads and polyurethane distal pad in place and anchor the elastic plaster to itself.

#### Wrap 3:

The wrap is now at a point posterolaterally. Carry the wrap anteriorly up over the distal *LATERAL* portion of the stump, pulling the plaster bandage almost to its limit of elasticity (Fig. 300). At the anterior stump margin, release the tension and carry the wrap medially and then posteriorly with only a light pull on the plaster.



FIGURE 300



**Wrap 4:**

The fourth wrap is almost identical to number three except that now the bandage covers the distal *CENTER* of the stump (Fig. 301).

The direction the wrap is altered anteriorly and carried toward the lateral side of the stump.

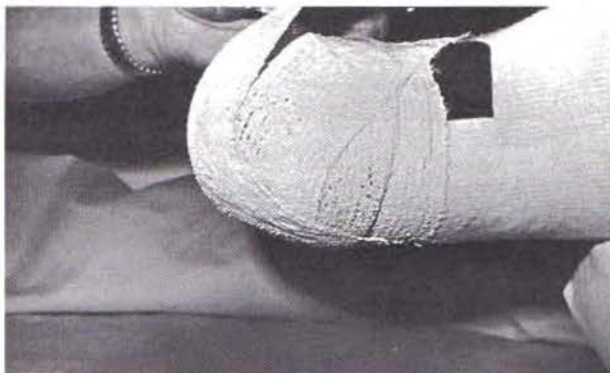

FIGURE 301

**Wrap 5:**

The fifth turn is brought anteriorly up over the distal *MEDIAL* aspect with the same controlled tension to the bandage (Fig. 302).

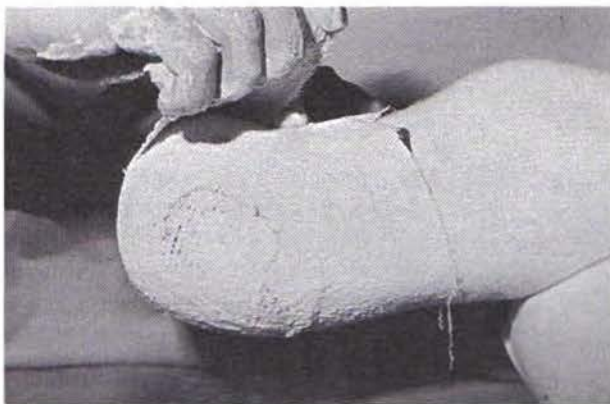


FIGURE 302

**Wrap 6:**

To achieve desired cast strength, a second layer of elastic plaster bandage is applied by repeating Wrap 5 . . .

**Wrap 7:**

. . . followed by Wrap 4, again altering the direction of the wrap medially. This will cover the distal *CENTER* of the stump with the second layer of plaster.

**Wrap 8:**

Repeating Wrap 3 now will cover the distal *LATERAL* stump with the second layer of plaster bandage.

The remainder of the elastic plaster bandage is wrapped in a circular manner with decreasing tension up to the knee joint (Fig. 303).

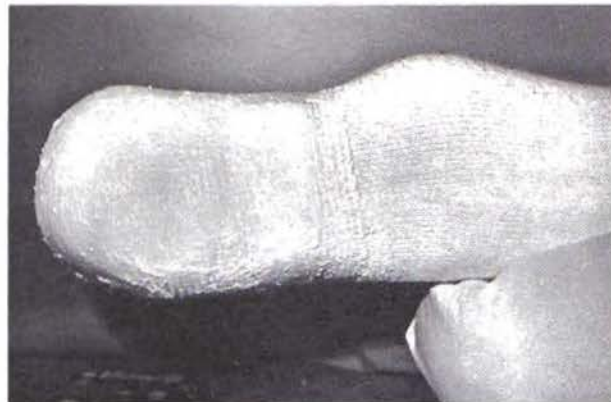

FIGURE 303

5. Depending on stump size, use a second roll of elastic plaster bandage to achieve a minimum of two layers of elastic plaster for the socket and three layers for the proximal socket brim. Wrap the plaster bandage anteriorly approximately 1 in. superior to the proximal border of the patella and remain low enough on the posterior knee joint to allow 90 deg. of knee flexion (Fig. 304, 305, and 306). Avoid proximal constriction of the cast socket in the popliteal area and over the hamstrings by eliminating all tension to the elastic plaster bandage.

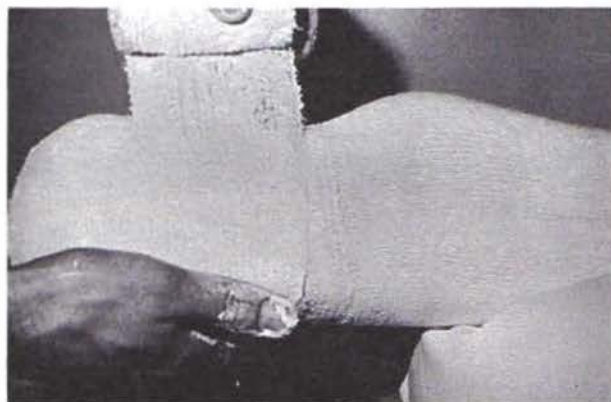


FIGURE 304



FIGURE 305

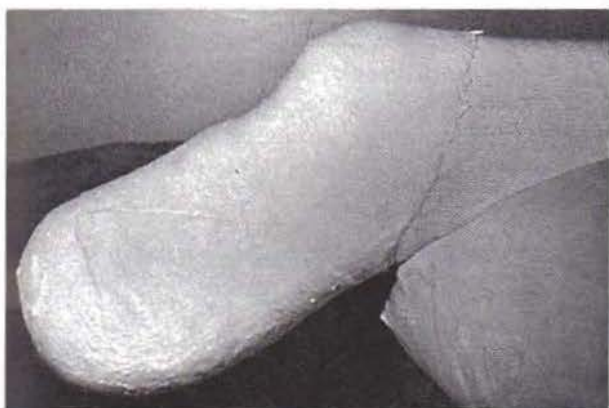

FIGURE 306

6. Because of the inherent structural weakness of elastic plaster bandage, the initial wrap must be reinforced with conventional plaster bandages and splints.

Double layers of 4 in. x 15 in. plaster splints are applied over the distal portion of the socket anteroposteriorly (Fig. 307) and mediolaterally (Fig. 308).

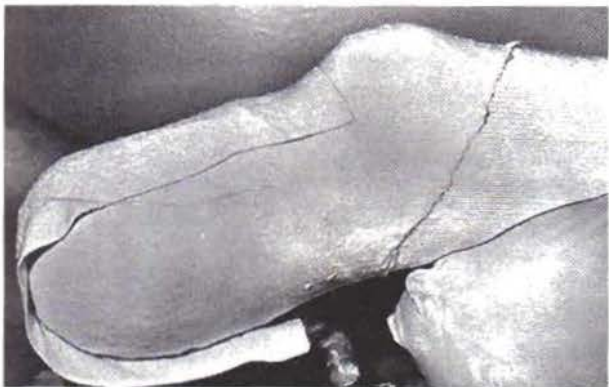


FIGURE 307

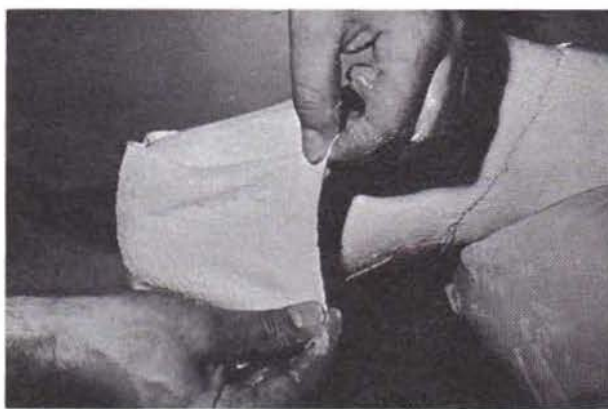

FIGURE 308

7. A roll of 4 in. conventional plaster bandage is applied starting at the proximal socket brim (Fig. 309) and wrapping distally with even, overlapping, circular wraps.

(a) After three or four circular wraps around the proximal socket brim, prepare the suspension buckle and strap arrangement. A 1-in. cotton webbing strap, approximately 16 in. long, is looped through a 1½-in. safety buckle. Locate the safety buckle just proximal to the patella on the border of the socket brim with the two ends of the webbing extending distally past the medial and lateral borders of the patella.



FIGURE 309



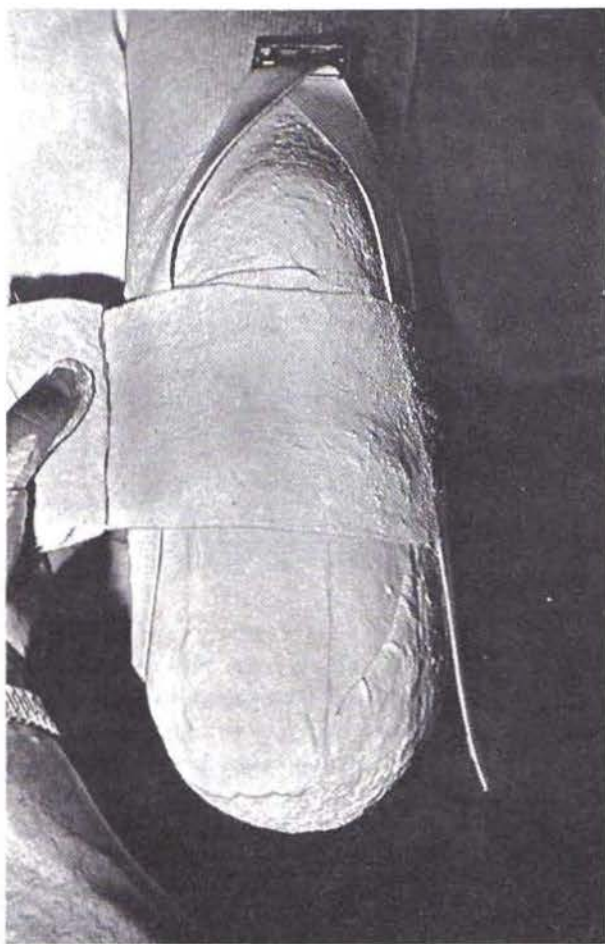


FIGURE 310

(b) Continue the wrap with the plaster bandage by placing two circular turns over the cotton webbing straps (Fig. 310).

(c) Both strap ends are then folded back and wrapped in place, securely retaining the strap and buckle to the cast (Fig. 311).

The remaining plaster bandage is continued to the distal portion of the rigid dressing.

The entire cast should then be smoothed lightly by hand, avoiding excessive rubbing or plaster distortion.

8. After the plaster has hardened sufficiently, the proximal tension on the stump sock is released. Attach the 1½ in. elastic webbing suspension strap of the waist belt firmly to the safety buckle (Fig. 312). It is for this short cast that the elastic webbing strap was not shortened during the initial cast application after surgery. Remove the posterolateral elastic suspension strap from the waist belt if this was previously utilized.

9. Remove the pillow from under the thigh and lo-

cate the patient on the table with his pelvis level and the legs approximately 1½ in. apart at the knees. Prevent external rotation of both extremities. Proceed with application of the below-knee prosthetic unit as described in Chapter 2.

#### FOR THE PHYSICAL THERAPIST

Following the first cast change, the patient can usually progress to crutch walking. Lofstrand forearm crutches are recommended. They produce a more normal gait pattern than do axillary crutches, and allow the patient to progress more quickly to the use of a cane.

Learning the proper use of crutches must include stairs and ramps, yet limiting weight bearing to no more than 30 lb. on the amputated side.

If the patient is discharged on crutches, he must be seen two or three times weekly to be sure that he is following directions and also to be sure that his cast and its suspension are correct.

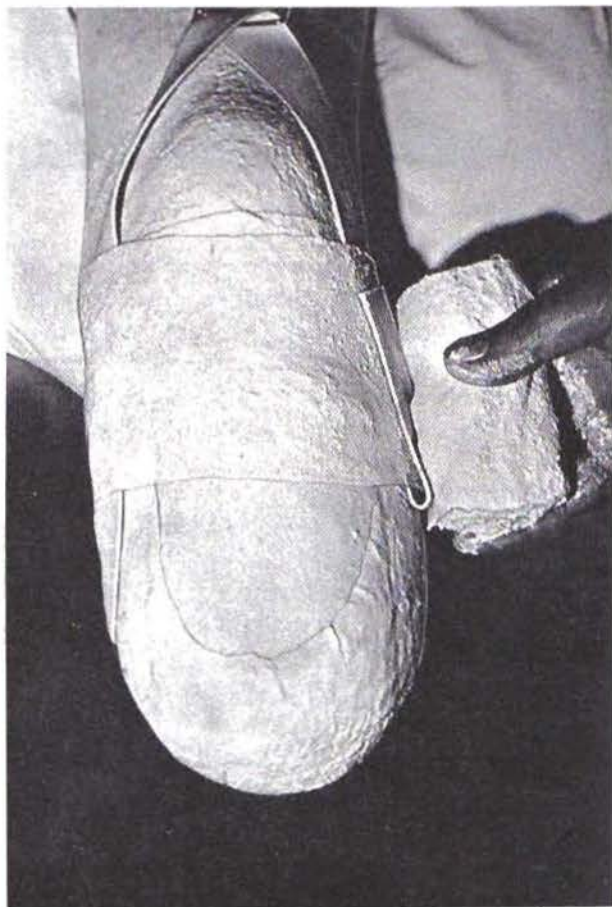

FIGURE 311



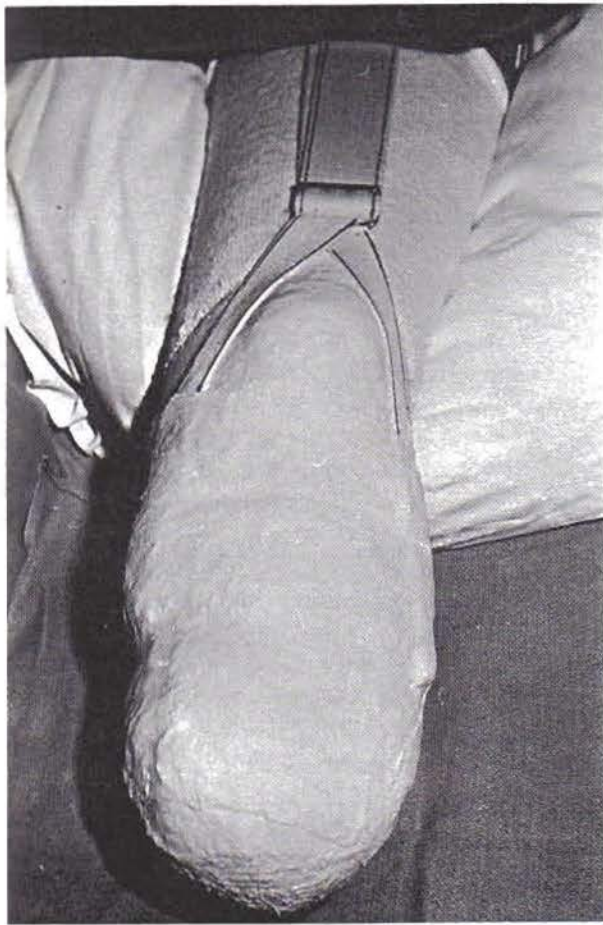

FIGURE 312

After the cast and measurements have been taken for the definitive prosthesis, the below-knee amputee is instructed in the application of his short plaster cast. The Syme, knee-disarticulation, above-knee, and hip-disarticulation amputee will need instruction in wrapping his stump with a tensor bandage.

With delivery of the permanent prosthesis, gait training is essential. Problems should be discussed with the prosthetist and the surgeon or physiatrist. Necessary adjustments are then made by the prosthetist. Once adequate gait habits are established the patient can be seen less frequently.

#### IV. THE FIRST YEAR

##### THE BELOW-KNEE NIGHT CAST

When the patient's stump is found ready to be measured and is casted for the definitive prosthesis, cer-

tain precautionary measures are indicated. It is advisable to proceed immediately with the measuring and casting procedure to avoid any interruption that would leave the stump out of its protective and controlled environment for prolonged periods.

The most common procedure to prevent edema is application of a compression wrap of elastic tensor bandage to induce stump shrinkage and to control stump volume. With proper instructions and after repeated practical experience, most patients become relatively adept in using the correct application technique. However, less motivated patients apparently have difficulties in applying the elastic bandage properly and effectively. By causing proximal restriction or by a loose wrap they achieve the direct opposite of the desired results. While edema is to be prevented, one also should not distort the general contour and stump anatomy and present a bulbous or pear-shaped stump for fitting with a definitive prosthesis. To prevent this wasteful and frustrating experience, the prosthetist fashions a removable "night cast" after completing cast and measurements for the definitive prosthesis. The night cast is not only an intermediate device for stump control and protection while the definitive prosthesis is being constructed and whenever the definitive prosthesis is removed from the stump, but also is to be worn the next 2 to 3 weeks until complete stump stability is achieved. On several occasions, elderly patients, getting up at night and forgetting they were amputees, have fallen. The protective value of the night cast has prevented serious damage to the stump.

In fabricating the night cast, the prosthetist uses the same technique as when constructing the short below-knee cast mobilizing the knee joint after suture removal, with two exceptions: The reticulated polyurethane distal pad is not used, and a three-ply non-sterile wool sock is substituted for the sterile Orlon Lycra stump sock.

It is optional to reapply the adjustable prosthetic unit, pylon and foot, depending on how soon the definitive prosthesis will be available. For a general guideline, if the definitive prosthesis is completed and the patient is allowed to take it home finished or in the "rough," simply cut out the socket attachment plate and straps from the short cast and remove the pylon and foot, thus converting it into a night cast. The only prerequisite in this procedure is that the cast still fit the stump adequately. The night cast should be snug enough to require powder for its application. The patient is instructed that whenever he is required to



add thicker ply or more stump socks for his definitive prosthesis, he must do likewise for his night cast. Usually after 2 to 3 weeks of wearing the night cast it may be discontinued.

The hip-disarticulation, above-knee, Syme, and knee-disarticulation amputees should have their stumps wrapped snugly with a tensor bandage for the period indicated above whenever they are not wearing a prosthesis.

We strongly recommend delivery of the definitive prosthesis within 3 days after cast and measurements have been taken. If the patient is without a limb for many days, edema will not be controllable and stump breakdown can result in the borderline amputee. In addition, the definitive prosthesis will not fit. In our study, a majority of the definitive prostheses were delivered within 1 day after taking cast and measurements. The definitive prostheses can, of course, be delivered in the "rough" so that adjustments can be made before final lamination is completed.

We do not recommend walking the patient for prolonged periods of time on the alignment jigs since weight and bulkiness of these devices can be dangerous to the stump and also the opposite limb. Reuse the immediate postsurgical prosthetic unit if this procedure is indicated or preferred.

For below-knee prostheses, we routinely recommend the use of the hard socket without a Kemblo rubber insert. This technique will permit almost unlimited adjustability to the prosthetic socket which would be limited with the use of a soft Kemblo insert. Elimination of the rubber insert also improves cosmetic appearance of the limb, an important factor for the adolescent and the adult female.

After the patient has received his definitive prosthesis, he is seen as necessary by surgeon and prosthetist. During the first 6 months following surgery, the amputee may require prosthetic socket adjustments to accommodate atrophic stump changes.

Sometime during the second 6 months the patient will probably require a socket replacement.

The amputee must be followed on a regular schedule. Problems with prosthetic fit must be promptly

identified and corrected, the stump inspected, and routine general supervision given.

## V. STATIC ALIGNMENT OF THE IMMEDIATE POSTSURGICAL PROSTHESIS

Accurate planning postsurgically in positioning the adjustable prosthetic unit on the cast socket (bench alignment) completes most static alignment requirements to a large extent. It is nevertheless necessary for the prosthetist along with other team members to be present when the patient stands for the first time. Acceptable shoes, or at least one shoe for the sound extremity, should be available. In the Syme patient, a shoe for the sound side is an absolute requirement.

Prosthetic adjustments not requiring removal of the prosthesis from the patient while he is standing can be performed immediately. Never remove the prosthesis to correct static alignment deviations while the patient is standing, since gravity could produce adverse effects to the total contact support of the socket-stump relationship and also cause pain to the patient.

1. *For All Levels:* With the patient standing straight and erect, with his weight supported by a walkerette, locate the feet so the heels are approximately 2 to 3 in. apart. Correct discrepancies in the length of the prosthesis by placing thin boards under the short side. Support the prosthesis when locating boards under it.

*Note:* The hip-disarticulation prosthesis should be approximately  $\frac{3}{8}$  in. to  $\frac{1}{2}$  in. shorter than the sound side.

2. (a) *For All Levels Except Syme:* Check toe-out. Correct if necessary by means of the hose clamp around the base plug of the prosthetic unit.

(b) *For the Syme:* Note required changes to the toe-out but do not correct at this time.

3. (a) *For All Levels Except Syme:* Check the pylon from the anterior or posterior and note if it remains vertical or if it leans medially or laterally (Fig. 313).

(b) *The Syme Foot* should be in flat contact with the floor. Note any deviations.

4. (a) *Syme and Below Knee:* Check the medio-

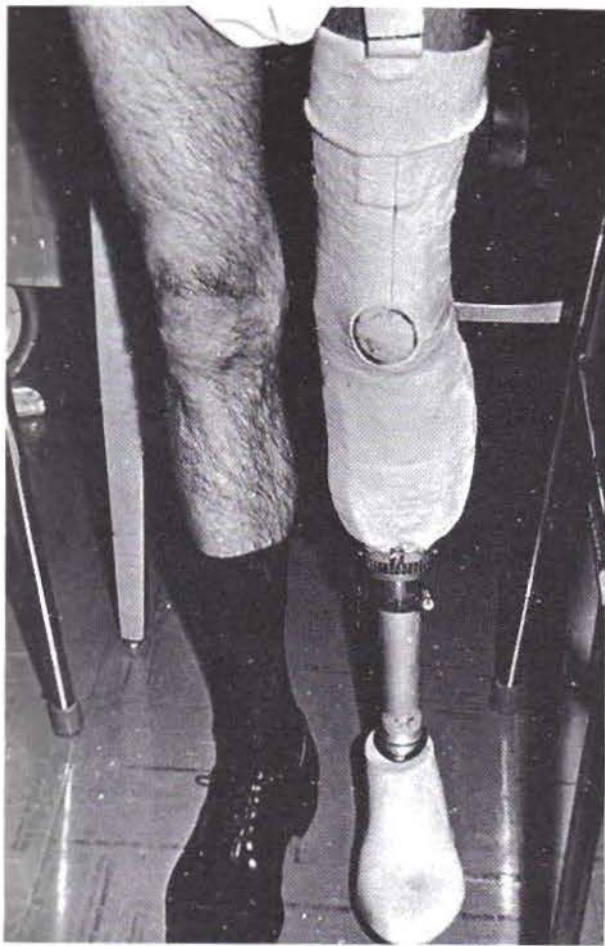


FIGURE 313

lateral placement of the pylon and foot on the cast socket as follows: Establish and mark with a pencil the center of the mediolateral cast socket dimension in the popliteal area. Place a second pencil mark  $\frac{1}{2}$  in. medial. A plumb line from the second mark should intercept the center of the heel with the shoe or foot in flat contact with the floor.

(b) *Above Knee*: Establish a pencil mark on the posterior proximal cast socket brim at the level of the ischial tuberosity. A plumb line from this mark should

bisect the medial border of the prosthetic unit and heel with the shoe or foot in flat contact with the floor (Fig. 314).

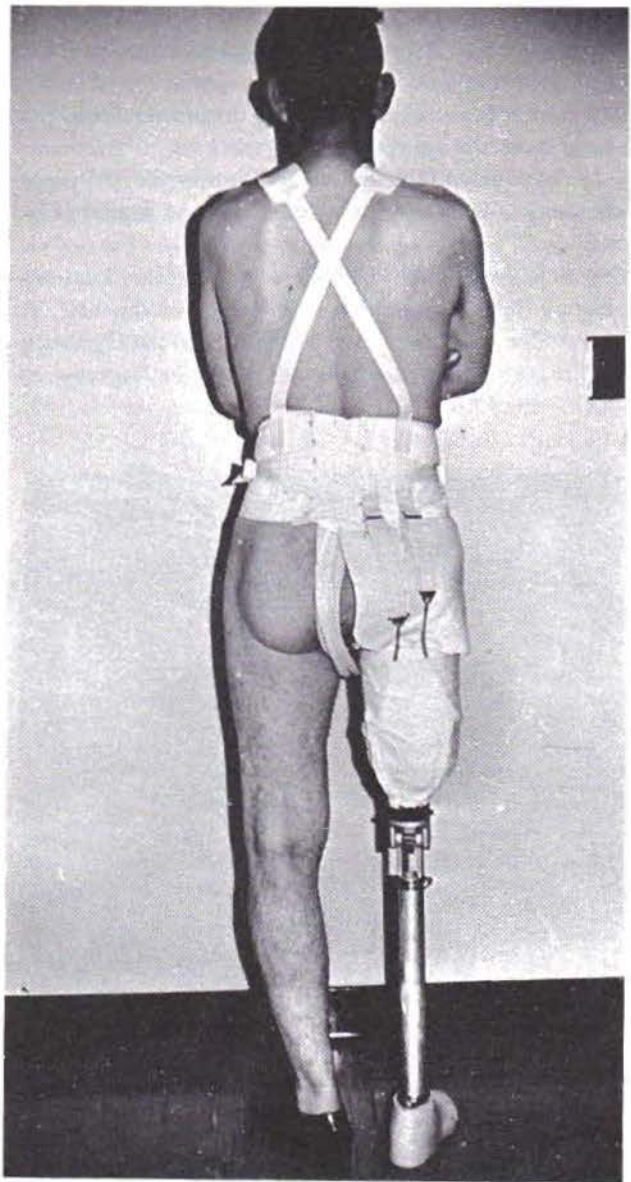


FIGURE 314



(c) *Hip Disarticulation*: Establish a pencil mark on the location of the ischial tuberosity. A plumb line from this mark should bisect the medial border of the socket attachment plate and fall medial to the center of the heel. Note any deviations.

5. (a) *Below Knee, Knee Disarticulation, Above Knee, and Hip Disarticulation*: Check the pylon from the lateral side making sure the heel is in contact with the floor (Fig. 315). Note any deviations from the vertical and the approximate degree.

(b) *Syme*: Dorsiflexion of the foot should place the cast socket in approximately 5 deg. of flexion (Fig. 316).

(c) *Syme and Below Knee*: Note the relationship of the knee center to the breast of the heel. A plumb line from the center of the medial tibial plateau (MTP) should fall approximately 1 in. anterior to the breast of the heel.

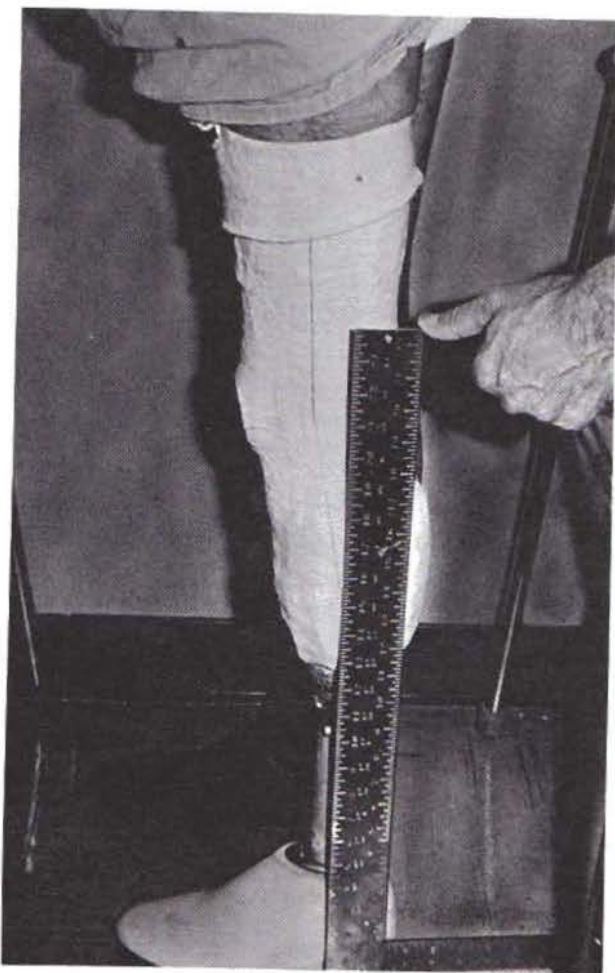


FIGURE 315

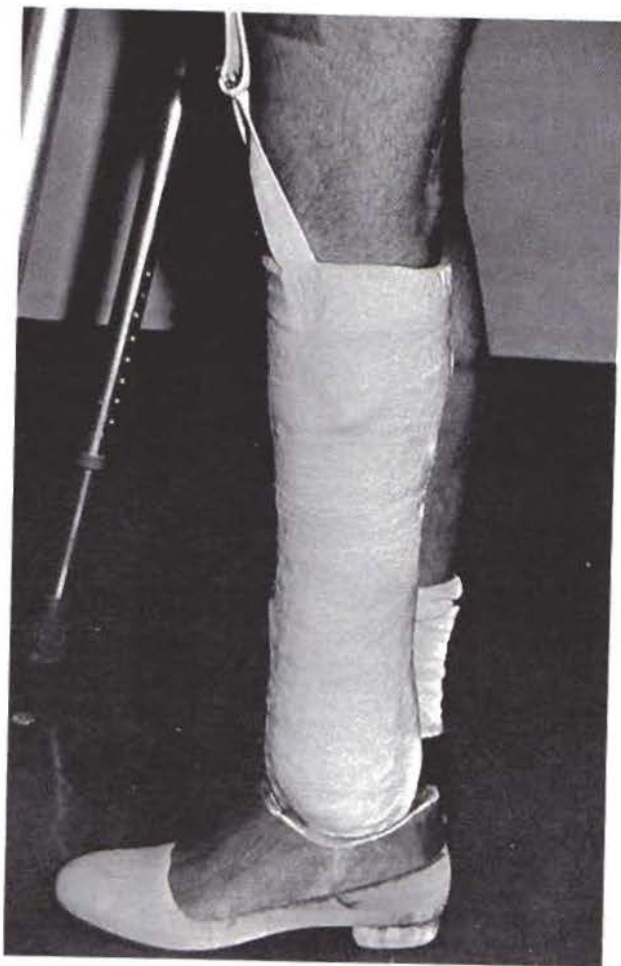

FIGURE 316

(d) *Above Knee and Knee Disarticulation*: The following alignment adjustments are indicated after the initial cast change, or prior to ambulation with the prosthetic knee unlocked: Check the relationship of the greater trochanter, knee, and ankle joint (TKA) (Fig. 317) and note the position of the knee center which should be located  $\frac{1}{4}$  in. posterior to the reference line for the friction pylon and on zero for the hydraulic swing-phase control unit. Note the position of the knee axis. It should be externally rotated approximately 5 deg.

6. (a) *Below Knee and Syme*: Check and adjust if necessary, location and fit of the waist belt including elastic suspension strap or straps.

(b) *Above Knee*: Check the location of the waist belt and shoulder straps and adjust if necessary. Check stainless steel cables for effective suspension of cast socket from waist belt. If adjustments are indicated,

perform the corrections at this time on the anterior suspension straps only. Check for correct placement of the felt apron and adjust if necessary.

(c) *Hip Disarticulation*: Check, and adjust if necessary, the location and effective suspension of the shoulder suspension straps.

7. *For All Levels*: If the patient indicates discomfort about the proximal socket brim, correct the existing static alignment deficiencies, if any, before proceeding to provide relief on the brim itself. Unless the cast socket fabrication instructions were not

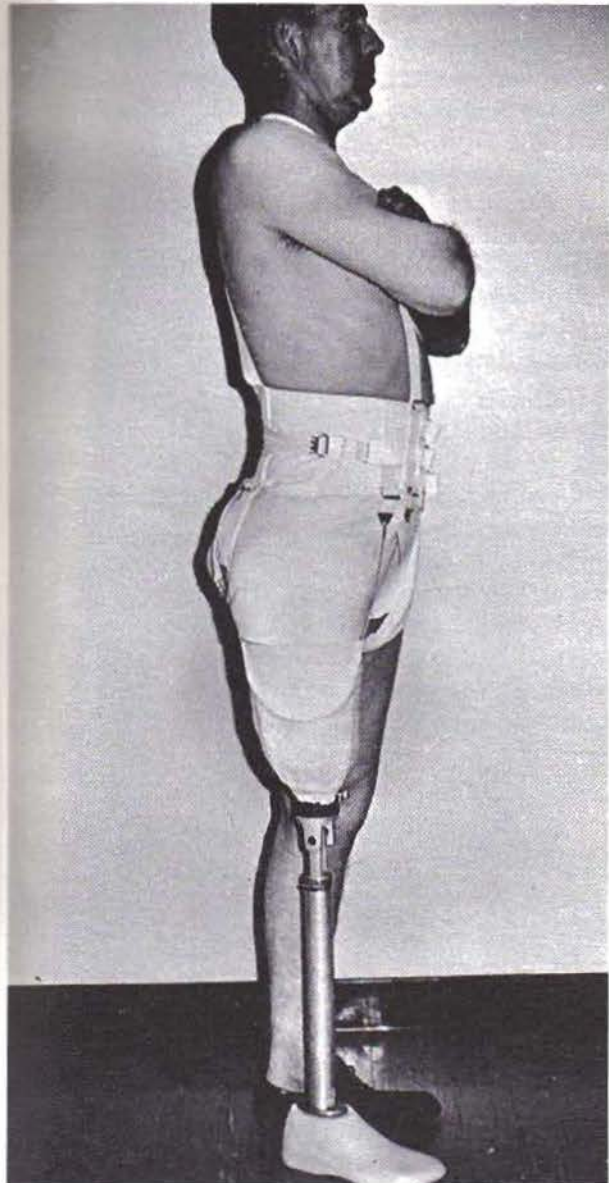

FIGURE 317

followed, it rarely should be necessary to provide relief in the area of the socket brim.

#### STATIC ALIGNMENT CONSIDERATIONS

After completion of the initial standing activity the patient is returned to bed. Depending on observations made during steps 1 through 7, make required adjustments to the prosthetic unit.

*For All Levels Except Syme*: Length can be increased up to 1 in. in a short pylon by inserting an appropriately slotted spacer on the base plug. This spacer is cut from pylon tubing. The hose clamp should be located over both pylon tube and spacer to prevent rotation of the two on each other. Once the length of the prosthetic pylon is satisfactory, cut a 1 in. longitudinal slot with a hacksaw into the proximal portion of the pylon tube to retain it more securely on the base plug with the hose clamp.

A slotted pylon tube can be successfully shortened by partially inserting the base plug into the pylon tubing to support it prior to cutting the tubing with the tube cutter (Fig. 318).




FIGURE 318

*For the Syme Case*: The use of a shoe only on the sound side is required because the application of the cast socket including the prosthetic unit would otherwise require excessive removal of material on the Syme foot to shorten to equal length. This removal would render the foot useless for the definitive prosthesis. During the alignment trials, decrease of length for the Syme temporary prosthesis requires removal of the foot from the prosthetic unit and grinding material from the proximal portion of the external wooden keel after which static alignment must be reestablished. Length increase of the Syme prosthesis as a result of



incorrect planning can be accomplished by inserting Kemblo rubber shim spacers between the prosthetic unit and the Syme foot after which static alignment is repeated.

When fabricating the definitive Syme prosthesis, the  $\frac{1}{4}$  in. thickness of the PRS adjustable prosthetic unit is more than offset by the use of a shoe on the Syme foot.

*For All Levels:* If extensive adjustments to the prosthetic unit are required, it will be necessary for the prosthetist to return when the patient stands again. After the initial cast change the patient can stand repeatedly for prosthetic adjustments. With the patient standing straight and erect, static alignment is completed when the pylon remains vertical with the foot flat on the floor when viewed anteriorly and laterally, with the cast socket and foot in proper relationship to each other.

Detailed instructions for adjustment and alignment of prosthetic units are available from the manufacturers.

## VI. DYNAMIC ALIGNMENT OF THE IMMEDIATE POSTSURGICAL PROSTHESIS

Only after all static alignment deviations have been corrected and the patient has repeatedly demonstrated his ability to distinguish reasonably well between controlled amounts of body weight to the prosthesis on measuring scales may he proceed to ambulate. In general, dynamic alignment is a repeat of the static alignment procedures steps 1 through 7, with the patient ambulating between parallel bars with controlled weight bearing. This fine tuning of the prosthesis, while beneficial in protecting the stump during ambulation, allows for maximum function of the immediate post-surgical prosthesis. For maximum results use current biomechanical alignment principles as far as these can be applied within the limitations imposed by these techniques. The following critical points require immediate adjustment:

1. *For All Levels:* With correct placement of the heel at the time of heel strike, the ball of the foot should not be over  $1\frac{1}{2}$  in. from the floor.

2. *Below Knee and Syme:* In mid-stance the ball of the foot should be in flat contact with the floor with lateral cast socket displacement not exceeding  $\frac{1}{2}$  inch.

3. *For All Levels:* From mid-stance to toe-off, check for smooth roll over the prosthetic foot. The most

common mistake is excessive anterior placement of the prosthetic unit on the cast socket resulting in a short heel and long toe lever arm causing too short a stride and the sensation of climbing a hill.

4. *For All Levels:* With proper foot placement, the pylon should be vertical in mid-stance when viewed anteriorly.

5. *Below Knee:* During ambulation, observe the cut-out patellar area in the cast socket. Cast fit and effective socket suspension are in direct proportion to the amount of stump pistoning at this area. Piston action exceeding  $\frac{1}{2}$  in. indicates a loose cast that must be changed immediately.

6. *Syme, Above Knee, Knee Disarticulation, and Hip Disarticulation:* During ambulation, observe the cast socket brim for proper suspension. Piston action exceeding  $\frac{1}{2}$  in. indicates a loose cast that needs to be changed immediately.

7. *For All Levels:* Vaulting on the sound side and/or circumduction on the prosthetic side is frequently seen as long as the knee joint remains immobilized, but is only a temporary problem. The second reason for vaulting may be a prosthesis that is too long. In the hip disarticulation, to facilitate swing-through without articulations, the prosthesis is left  $\frac{3}{8}$  to  $\frac{1}{2}$  in. shorter than the sound side.

8. *Above Knee and Knee Disarticulation:* Excessive heel rise and terminal impact on the prosthetic side indicate insufficient friction of the knee joint.

Periodic checkups of alignment and socket suspension are advised and must be repeated for each subsequent cast change. Investigate patient complaints promptly and make corrections if indicated. Communicate and consult with the other team members frequently and stay informed about the patient's progress.

## VII. POSTOPERATIVE COMPLICATIONS

Immobilization is one of the most valuable adjuncts in the early phases of wound healing and tissue repair. The success of immediate postsurgical prosthetic fitting in promoting primary healing adds further evidence in support of this time-honored physiological principle. When postoperative wound healing is compromised and stump complications develop, this principle should not necessarily be discarded.

Early in the course of the Prosthetics Research Study when wound healing was delayed, it was our practice to remove the rigid plaster dressing and treat the stump



in a conventional manner with soft dressing support only. It shortly became apparent that edema could be more effectively controlled and the amputation subjected to less harmful mechanical stress if the rigid dressing could be maintained. In the presence of wound problems, i.e., infection, necrosis, and delayed healing, the stump needs the protection of the rigid, gently compressive dressing. It should be maintained when possible.

Presently, most stump healing problems are treated as detailed below:

#### WOUND INFECTION

Superficial localized wound infection may be seen about sutures and at the site of the previously removed drain (Fig. 319). Culture of the wound and administration of appropriate antibiotic may be indicated. Adequate drainage must be established. If necessary,

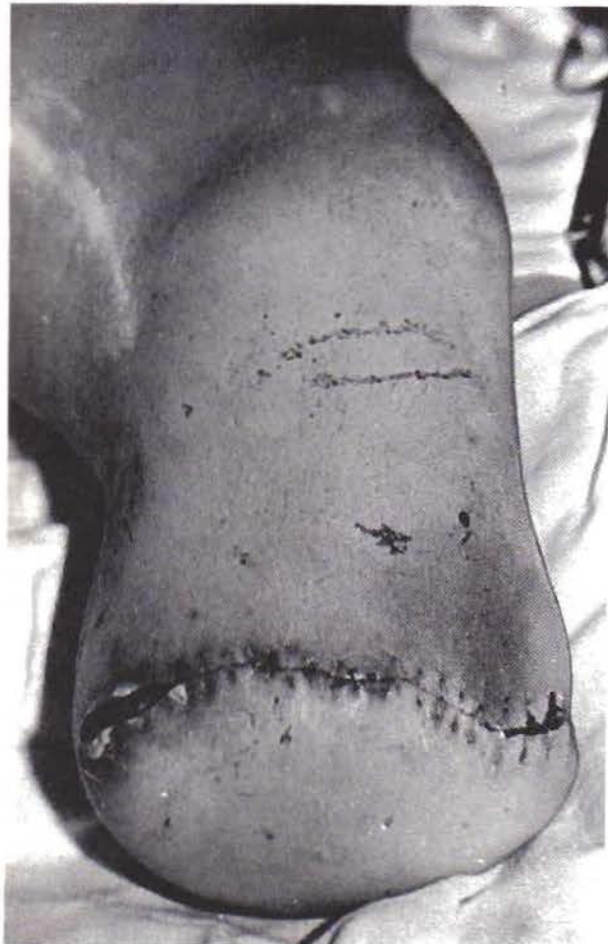

FIGURE 319

sufficient sutures should be removed adjoining the infected area to provide drainage. Uninvolved areas of the incision can be supported using sterile paper or plastic adhesive strips. With satisfactory drainage established in the superficially infected area, a new postsurgical prosthesis should immediately be reapplied. Minimal static weight bearing can be continued but ambulation should be withheld to avoid possible irritation and shear forces on the wound.

Cast removal in the face of a recognized wound infection is indicated when adequate drainage is not effective, or in the presence of persisting and increasing fever, or for severe, resistant pain. Open drainage, moist dressings, open or closed irrigation techniques, and possible delayed revision to a higher level may be necessary. If an infected stump is being treated by a rigid dressing, the cast should be changed every 5 to 10 days as indicated until the wound infection is well controlled and healing complete. Care must be taken to differentiate between wound infection and deep tissue necrosis. The latter usually becomes evident about the second or third postoperative week. Wound necrosis is not accompanied by fever and the discharge present is either sanguineous or semi-purulent, but usually negative to stain and culture.

#### WOUND NECROSIS

Superficial or deep tissue necrosis may be easily identified as such or may appear as a wound infection (Fig. 320). Necrosis occurs from inadequate tissue nutrition which is a result of:

1. The severity of the peripheral vascular disease,
2. previous tissue irradiation for tumor, and
3. rough handling of the tissue at surgery.

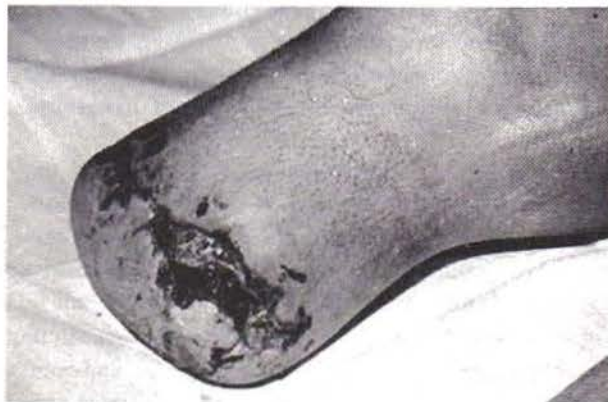

FIGURE 320



Not infrequently, small areas of tissue necrosis adjacent to the suture line will be seen. These represent local ischemia. In general, such small superficial ischemic areas will heal uneventfully by continuation of the rigid supportive postsurgical cast. Rest and appropriate pressure control edema and encourage secondary granulation and epithelialization.

Deep necrosis may require excision of the necrotic area, including necrotic muscle, establishing drainage with special care not to contaminate the wound, and the reapplication of the cast. A decision must be made as to whether local drainage and minimal local debridement without anesthesia will be adequate or whether it is necessary to return the patient to the operating room for a more complete debridement and secondary closure under anesthesia.

In general, the Prosthetics Research Study has followed a course of minimal wound disturbance in the absence of frank stump gangrene. A stump with mild to moderate peripheral vascular compromise seems able to dispose of necrotic tissue fairly well if the tissues are protected, and if damaging edema is not allowed to form. When formal stump revision is required, it is our practice to apply a rigid dressing thereafter as with the initial amputation.

#### WOUND HEMATOMA

Adequate Penrose or suction drainage or a combination of both at the completion of surgery should eliminate hematoma formation. The occasional amputation stump which is dry at the time of wound closure need not be drained.

Even when a drain has been left in the wound and removed 48 hours after surgery, a hematoma may be present at the time of the first cast change (Fig. 321). This will be due to inadequate drainage, loose application of the initial cast, or tissue trauma with renewed bleeding at the time the drain is removed. Excessive patient activity, including overzealous early weight bearing, may also produce bleeding and hematoma formation.

When present, a hematoma must be expressed under meticulous asepsis. It may be necessary to remove one or more sutures to accomplish evacuation. Complete evacuation must be carried out, however, and a snug new plaster cast applied. Weight bearing can be continued but the surgeon may wish to discontinue ambulation for a few days to minimize shear and compressive stress on the tissues. A massive hematoma may require local stump revision at the time of evacuation

of the hematoma. When this is accomplished, a new prosthetic socket should be applied.

#### DECUBITIS (PRESSURE) ULCERS

Pressure areas on the stump away from the wound site are caused by improper application of the cast, a cast that is too loose, or an inappropriately active patient (Fig. 322). Pressure necrosis should be totally preventable. The techniques outlined in the appropriate sections of this manual demonstrate how to avoid pressure on those areas which are sensitive and which can be the sites of pressure necrosis.

Treatment of pressure areas consists of reapplication of a properly fitting immediate postsurgical prosthesis and the appropriate limitation of excessive patient activity. Occasionally the proper treatment will consist of fitting a definitive prosthesis if the wound itself is adequately healed. The definitive prosthesis provides a better contour than the temporary socket. When the

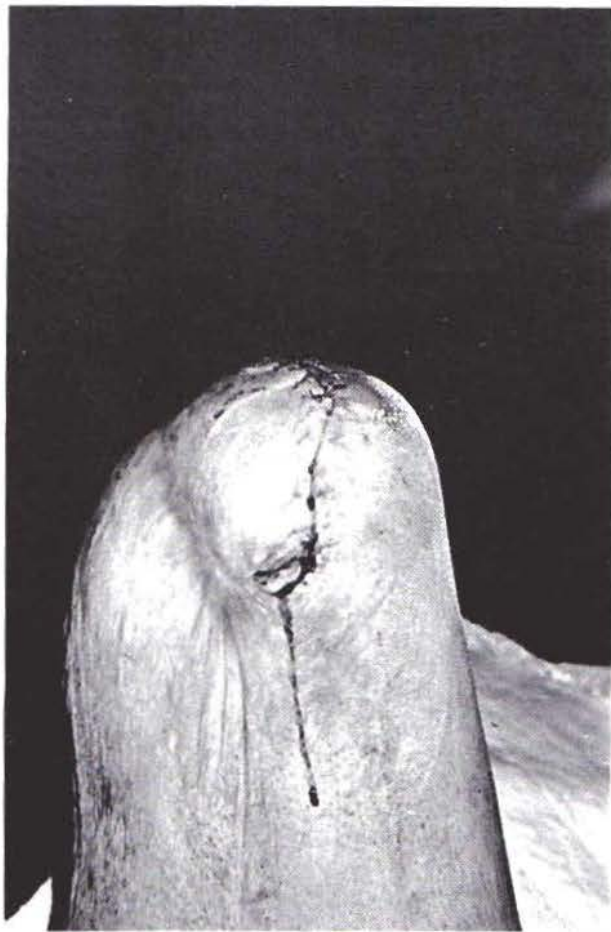

FIGURE 321

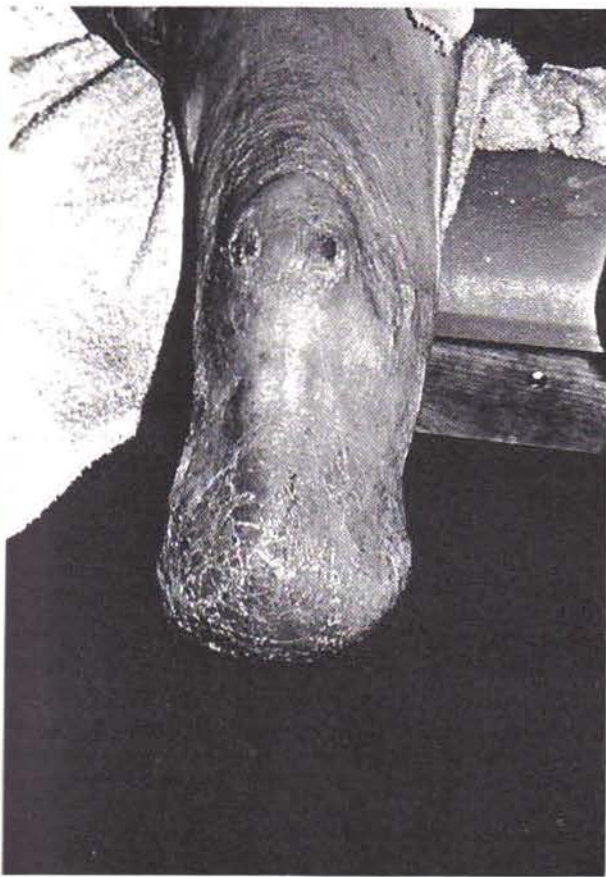

FIGURE 322

pressure area is small, it will heal in a well-fitting definitive prosthesis.

#### GANGRENE OF THE STUMP

Frank gangrene will require reamputation at a higher level (Fig. 323). The size, distribution, and area involvement of the gangrene will determine the level of reamputation. We have revised a number of below-knee amputations performed for peripheral vascular

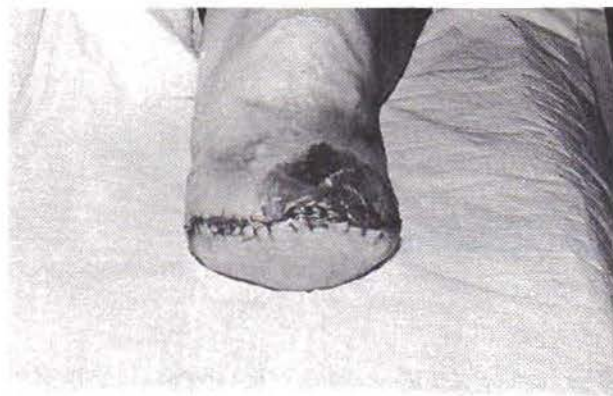

FIGURE 323

disease to a level still below the knee, but above the level of gangrene. Successful healing has taken place and long range stump tolerance has been good. Procrastination should be avoided in the presence of gangrene of the stump, but surgical judgment is crucial. The surgeon must avoid prolonging disability and hospitalization while still striving to preserve stump length and function. Sacrifice of a knee should be avoided if the gangrene is of a nature to permit localized revision or reamputation at a higher site but without sacrifice of the contiguous joint.

#### SUMMARY

Sound surgical principles are followed in the presence of postoperative wound complications. The basic principles of adequate wound support, prevention and control of edema, the management of wound infections, wound necrosis, and hematoma formation have been outlined. Familiarity with techniques and careful attention to detail will minimize postoperative wound complications. The prevention and treatment of systemic complications have not been outlined. This management is essentially that of good and appropriate total patient care.



## Conclusions

The history of amputations is literally the history of man. Our struggles against a harsh environment, our tragic conflicts one against another, the mystery of ill-formed limbs at birth, all make up the skein of man's most obvious crippling deformity—limb loss. No less historically significant is the saga of limb substitutes. Prosthetic replacement at the time of amputation closes the loss of function gap. Only the hope of human limb transplantation can be looked upon as more effective rehabilitation.

This monograph details our experience with immediate postsurgical prosthetic fitting and related amputation technique. Interest in amputation surgery and in amputee rehabilitation in general is quickened by this management. Reconstruction and rehabilitation now dominate patient care from the outset. In a field experiencing great and exciting changes, modifications and improvements can be expected. Nonetheless, our experience is now sufficient to propose with confidence the outlined management.

## References

1. Aitken, George T.: Surgical Amputation in Children, *J. Bone and Joint Surg. (Amer.)* 45-A:1735-1741, Dec. 1963.
2. Anderson, M. H. and R. E. Sollars: Manual of Above Knee Prosthetics. Prosthetics Education Program, University of California (Los Angeles) School of Medicine, Jan. 1, 1957.
3. Berlemont, M., R. Weber, and J. P. Willot: Ten Years of Experience with the Immediate Application of Prosthetic Devices to Amputees of the Lower Extremities on the Operating Table. *Prosthetics International*, Vol. 3 No. 8, 1969.
4. Burgess, E. M.: The Below Knee Amputation. *Inter-Clinic Information Bulletin*, VIII (4), Jan. 1969.
5. Burgess, E. M.: The Rationale of Immediate Post-surgical Prosthetic Fitting. Paper presented at the Symposium on Immediate Post-Operative Fitting, Biomechanical Research and Development Unit, Roehampton, England. Nov. 16, 1967.
6. Burgess, E. M. and R. L. Romano: Immediate Post-surgical Prosthetic Fitting of Children and Adolescents Following Lower Extremity Amputations. *Inter-Clinic Information Bulletin*, VII (3):1-10, Dec. 1967.
7. Burgess, E. M. and R. L. Romano: The Management of Lower Extremity Amputees Using Immediate Postsurgical Prostheses. *Clinical Orthopaedics and Related Research*, 57:137-146, 1968.
8. Burgess, E. M. and J. H. Zettl: Immediate Postsurgical Prosthetics. *Orthotics and Prosthetics Journal*, pp. 105-112, June 1967.
9. Burgess, E. M., J. E. Traub, and A. B. Wilson, Jr.: Immediate Postsurgical Prosthetics in the Management of Lower Extremity Amputees. TR 10-5, Washington, D.C., Veterans Administration, 1967.
10. McLaurin, C. A.: The Evolution of the Canadian-Type Hip Disarticulation Prosthesis. *Artificial Limbs*, 4(2): 22-28, Autumn 1957.
11. Murdoch, G.: Levels of Amputation and Limiting Factors. *Ann. Roy. Coll. Surgeons (Eng.)*, 40:204-216, 1967.
12. Pedersen, H. E.: The Problem of the Geriatric Amputee. *Artificial Limbs*, 12(2): i-iii, Autumn 1968.
13. Pedersen, H. E., R. L. LaMond, and R. H. Ramsey: Amputation for Gangrene. *South. Med. J.*, 57:820-825, 1964.
14. Radcliffe, C. W. and J. Foort: The Patellar-Tendon-Bearing Prosthesis. Biomechanics Laboratory (Berkeley and San Francisco, Calif.) 1961.
15. Romano, R. L. and E. M. Burgess: Level Selection in Lower Extremity Amputations. *Amer. J. of Surgery*. Accepted for publication, 1969.
16. Schrock, R. D., Jr., J. H. Zettl, E. M. Burgess, and R. L. Romano: A Preliminary Report of Basic Studies From Prosthetics Research Study. *Bulletin of Prosthetics Research*, BPR 10-10:90-105, Fall 1968.
17. Swanson, A. B., B. Hotchkiss, and V. Meadows: Improving End-Bearing Characteristics of Lower Extremity Amputation Stumps. *Orthotics and Prosthetics Appliance J.*, 21:23-26, March 1967.
18. Weiss, M., A. Gielzynski, and J. Wirski: Myoplasty-Immediate Fitting-Ambulation. *International Society for Rehabilitation of the Disabled*, New York. (Reprint of paper presented at the Sessions of the World Commission on Research in Rehabilitation, 10th World Congress of the International Society, Wiesbaden, Germany, Sept. 1966.)



APPENDIX A

Alignment Diagrams for Immediate Postsurgical Prostheses

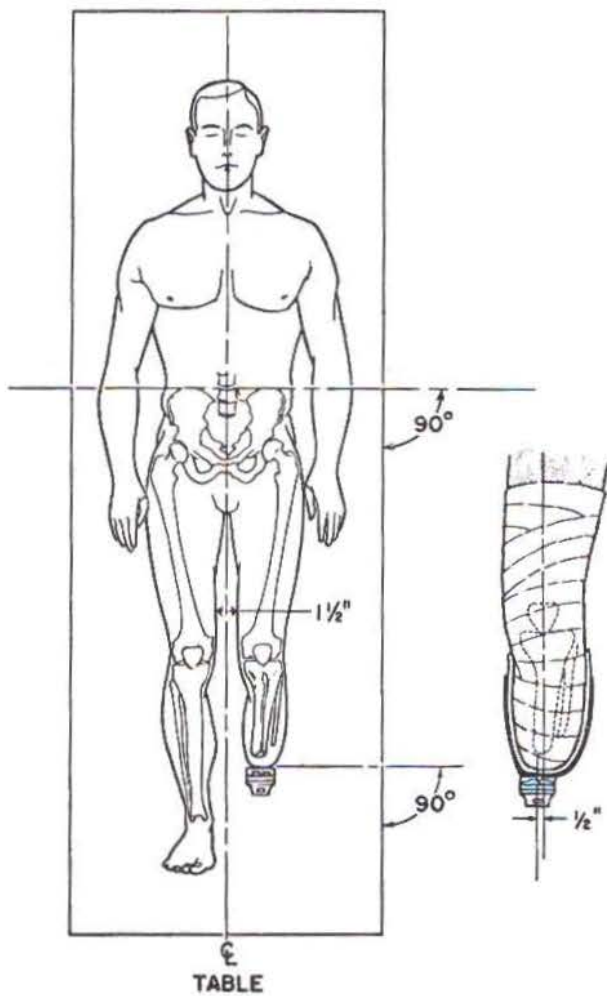


FIGURE 324.—Initial alignment for below-knee prosthesis.

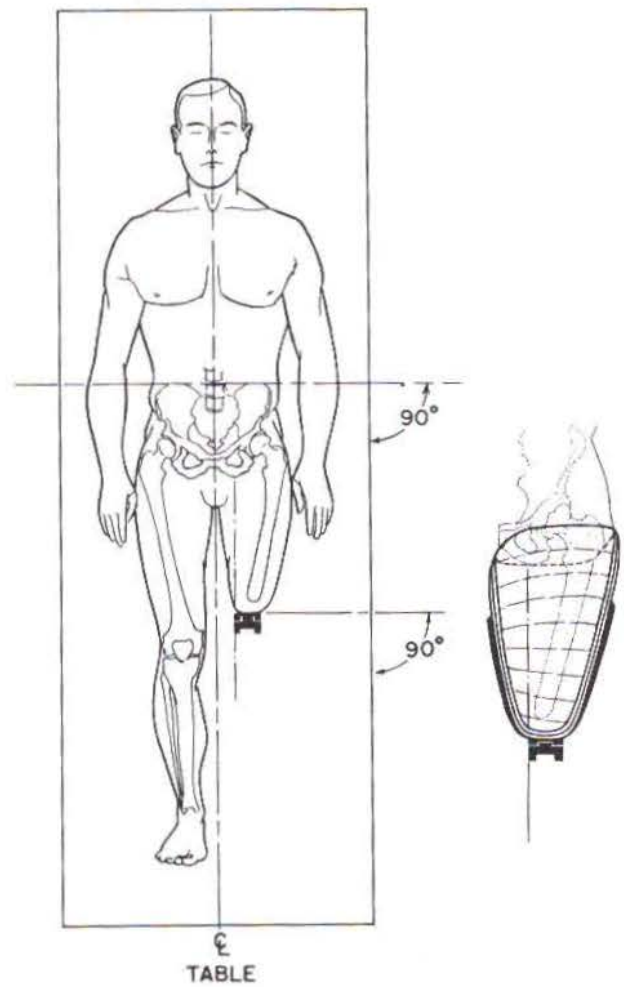


FIGURE 325.—Initial alignment for above-knee prosthesis.

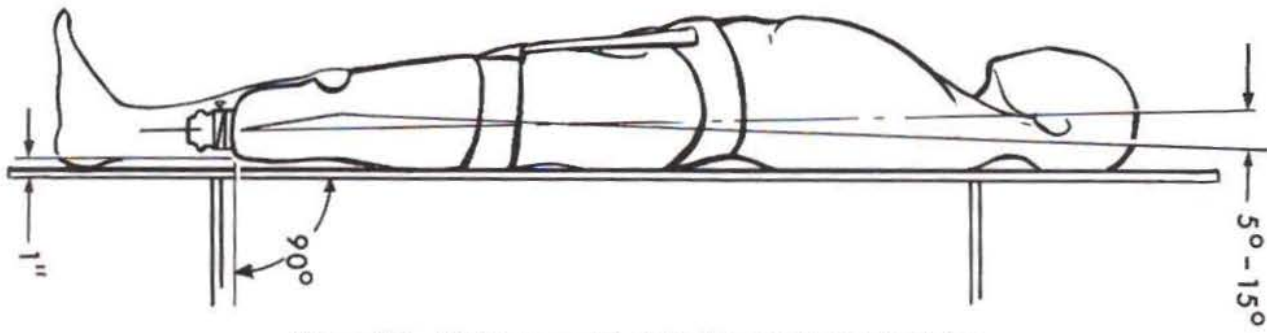


FIGURE 326.—Initial alignment for below-knee prosthesis, lateral view.

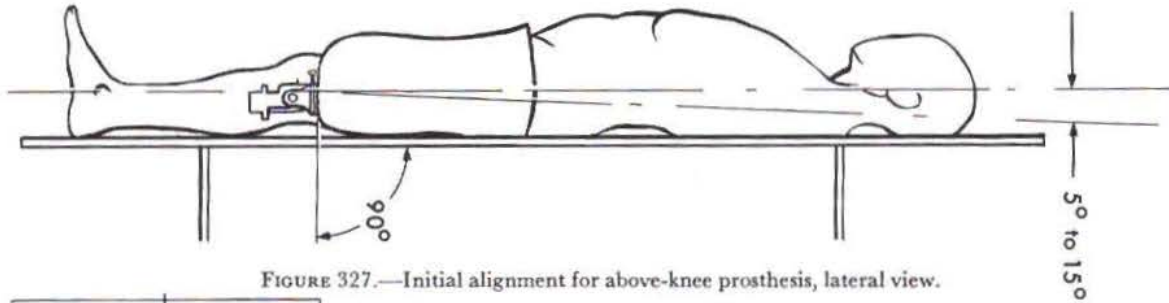


FIGURE 327.—Initial alignment for above-knee prosthesis, lateral view.

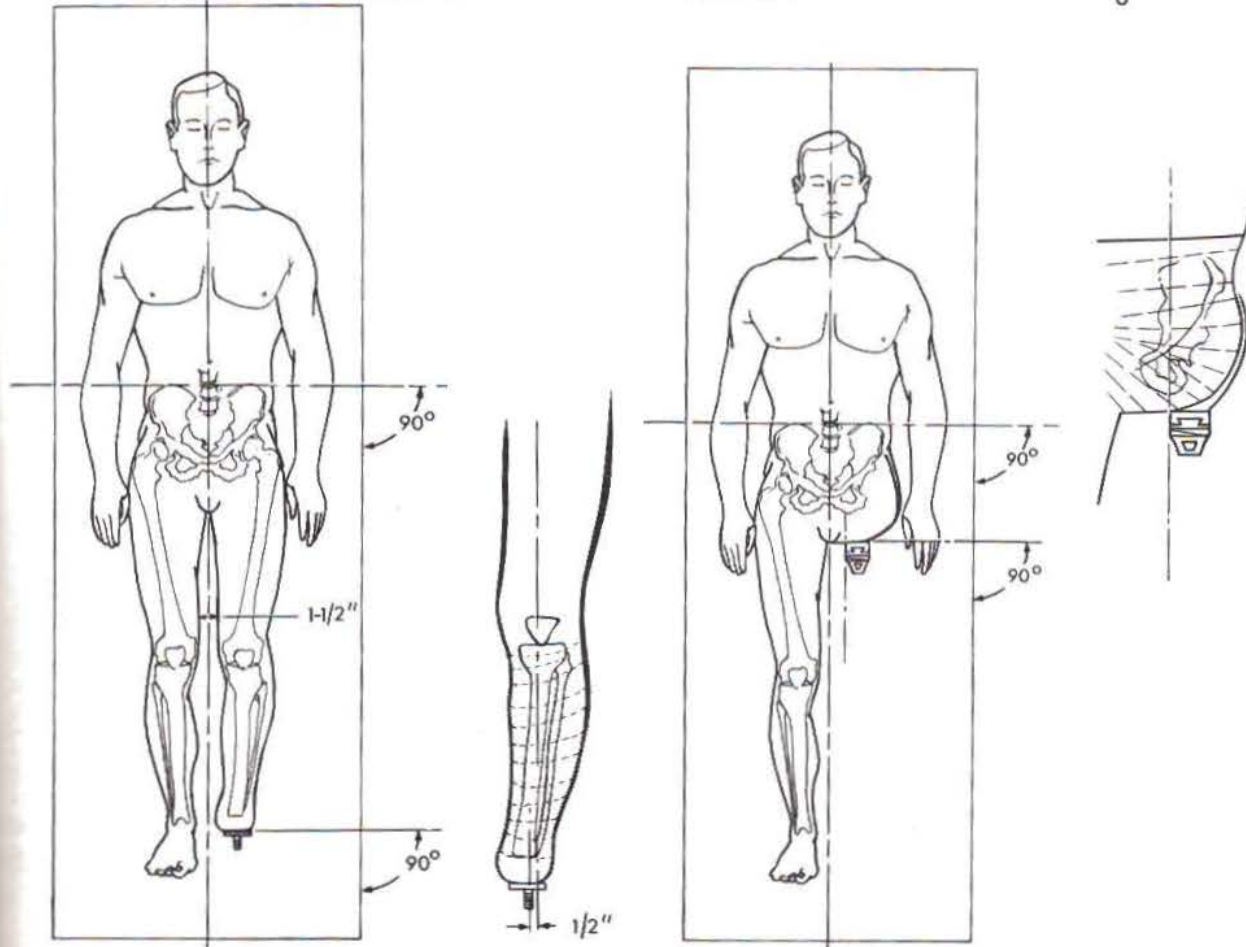


FIGURE 328.—Initial alignment for Syme prosthesis.

FIGURE 329.—Initial alignment of hip-disarticulation prosthesis.



APPENDIX B

Sources of Supply of Materials and Components

Items	List of suppliers <sup>1</sup>									
	Southern Prosthetics	S. H. Camp	Fillauer	K. & K. Prosthetics	Otto Bock	Knit Rite	Hosmer	U.S. Manufacturing	Kingsley	K W D
Polyurethane foam sheet material, 36"x48"x $\frac{1}{2}$ "						X				
Orlon Lycra stump socks	X			X		X		X		
PRS pre-cut BK felt relief pads—right and left	X			X		X		X		
PRS pre-cut BK polyurethane relief pads—right and left						<sup>4</sup> X				
Dow Corning Medical Adhesive, Type "B"	X			X		X	X	X		
PRS reticulated polyurethane distal pads—3", 4", 5", 6"						X				
"Elastic" elastic plaster-of-paris bandage (Ruhrstern)	X		X	X		X				
"Orthoflex" elastic plaster-of-paris bandage (Johnson & Johnson)	X		X			X	X	X		
PRS BK suspension waist belt (2" webbing)	X	X				X		X		
BK contoured suspension waist belt—felt lined (plastic)	X									
PRS AK suspension waist belt—webbing—felt	X	X						X		
PRS AK suspension waist belt—canvas—cloth felt	X	X		X		X				
PRS AK suspension cables—large—small	X			X		X		X		
PRS AK casting fixture—with lateral wall	X			X		<sup>5</sup> X				
PRS AK casting fixture—without lateral wall						X		X		
BK adjustable prosthetic unit (pylon)	X			<sup>2</sup> X	<sup>3</sup> X	<sup>2</sup> X	<sup>6</sup> X	X		
AK adjustable prosthetic unit (pylon)	X			<sup>2</sup> X	<sup>3</sup> X	<sup>2</sup> X		X		
PRS Syme adjustable prosthetic unit										X
SACH feet (conventional)	X		X	X	X	X	X	X	X	
Kingsley immediate postsurgical prosthetic SACH feet	X		X	X		X			X	
PRS immediate postsurgical prosthetic instrument kit	X			X		X		X		
$\frac{3}{8}$ " felt sheeting with adhesive backing (per sq. yd.)				X						

<sup>1</sup> The following are complete names and addresses of suppliers:

Southern Prosthetics Supply Co.  
Post Office Box 7443  
Atlanta, Georgia 30309

K. & K. Prosthetic Supplies, Inc.  
2436 Ocean Avenue  
Bellmore, New York 11710

A. J. Hosmer Corporation  
Post Office Box 37  
Campbell, California 95008

The S. H. Camp Company  
Birmingham, Michigan  
48012

Otto Bock, Inc.  
219 14th Avenue, North  
Minneapolis, Minnesota 55411

The United States Manufacturing Co.  
Post Office Box 110  
Glendale, California 91209

Fillauer Surgical Supplies, Inc.  
Post Office Box 1678  
Chattanooga, Tennessee 37401

The Knit Rite Company  
1121 Grand Avenue  
Kansas City, Missouri 64106

Kingsley Manufacturing Company  
1984 Placentia Avenue  
Costa Mesa, California 92626

K W D, Inc.  
5409 Russell Avenue NW  
Seattle, Washington 98107

<sup>2</sup> Type: United States Manufacturing Co. <sup>3</sup> Type: Otto Bock. <sup>4</sup> Will be available soon. <sup>5</sup> Special order. <sup>6</sup> Types: Northwestern, Hosmer, and Finnie Jig.