

Amputation surgery in the lower extremity

G. MURDOCH

Department of Orthopaedic Surgery and Traumatology, University of Dundee

Introduction

This contribution is intended to be a review of amputation surgery as it is today; yet, to present a purely surgical viewpoint would be uncomfortable for the author and inappropriate if the best interests of the patient are to be preserved. It is hoped that the review will be understandable to those others in the clinic team who are essential to the best management for the patient. Knowledgeable readers will no doubt recognize that in certain sections a highly personal viewpoint is displayed.

Advances in amputation surgery as in other branches of surgery reflect not only the increased understanding of physiology and pathology but also improvements in the technology of measurement and in prosthetics.

Causal conditions, levels and factors in amputation of the leg

In tackling this subject there are essentially three sets of information available to the surgeon and his team, namely the causal conditions, the available levels of amputation and the factors to be considered prior to operation.

The causal conditions can be listed thus:

- Vascular disease
- Trauma
- Tumours
- Infection
- Congenital limb deficiency
- Limb discrepancy, deformity, paralysis and joint instability, etc.
- Special situations; e.g. frostbite, trench foot, etc.

The levels of amputation available are:

- Hemipelvectomy
- Hip disarticulation
- Above-knee amputation
- Transcondylar amputation
- Supracondylar amputation
- Knee disarticulation
- Below-knee amputation
- Syme's amputation
- Partial foot amputations
- Toe amputations

The following are the factors to be considered in the final decision to amputate at a given level:

- The pathology
- The anatomy of the proposed level of amputation
- The surgery proposed: in effect, tissue management
- Prosthetic considerations: socket, devices, suspension, etc.
- Personal, e.g. age, sex and occupation.

This approach does display the information required but by itself becomes uncomfortable because of the degree of cross referencing needed.

Another approach to the subject is via the state of the tissues at the site of the operation. In tumours, congenital limb discrepancy, and amputation in cases of gross paralysis and ugliness the tissues are essentially "normal", whereas in vascular disease and trauma the viability of the tissues is highly variable and often in doubt. Even in these latter two groups of pathology the patients involved are widely different and the objectives have a quite different temporal scale. In the case of the dysvascular amputee the patient has a very short life span and is beset with many other problems. The objective here is to provide a reasonable and feasible quality of life and a measure of independence and this can only be achieved by the application of a total care programme. In the

All correspondence to be addressed to: Prof. G. Murdoch, Department of Orthopaedic Surgery and Traumatology, Caird Block, Royal Infirmary, Dundee.

case of trauma, the patient is usually in the prime of life with a long life expectancy and many options for the future. The emphasis here must be on high quality, often imaginative surgery coupled with equally high level prosthetic competence and suitable hardware to ensure that in physical and psychological terms the patient is offered the best opportunity for the interplay of social legislation, vocational rehabilitation and community integration.

Patient management by the team

1. Is amputation the appropriate or only solution?
2. Levels and limiting factors.
3. The development of the long term objectives of the amputation.
4. Pre-operative preparation of the patient.
5. The surgical event.
6. The environment of the stump.
7. Immediate post-operative care.
8. Prosthetic fitting and integrated rehabilitation.

1. Amputation or not?

In trauma and vascular disease this question is very often answered by the pathology itself but in other situations, for example, in cases of malignant tumours, chronic infection and in a variety of conditions involving leg shortening, deformity and joint instability, alternatives do exist. Unlike many operative procedures there is no retreat once amputation has been performed. From a philosophical point of view the situation is even more complicated in that once the leg has been removed the problem posed to the surgeon has also been removed. Where the surgeon has alternatives the decision must be based on a careful examination of the situation as it presents and also an equally careful study of the likely future of the patient and what options are available. This is particularly important in the case of a child where amputation might seem to solve many problems. The parents may welcome amputation if only because it will remove what for them may be an intolerable ugliness in their child, but in this circumstance the patient has no say in the decision. In some situations such as congenital absence of the fibula there is a fairly general agreement that ablation of the

foot at about the age of ten months provides the best solution both in the short and long term. In other situations the decision may be very marginal indeed and demand that amputation be delayed until the child is sufficiently developed to take part in the decision.

2. Levels and limiting factors

The problems regarding level selection are usually connected with the interplay of what the pathology permits and what other considerations are significant, such as the prosthesis to be fitted and the effect of such a fitting on the patient's personality and social integration. In the case of a young personable girl, the pathology may permit a knee disarticulation but the surgeon in proposing this procedure must have regard to the prostheses available, the total cosmetic effect, and in turn her resultant opportunities in terms of marriage, occupation and the like. Similar problems present if an amputation at Syme's level is permitted by the pathology. Here again the surgeon may have to consider a below-knee procedure if the best cosmesis is to be achieved. These problems have to be faced in a continually changing situation when prosthetic advances may swing the balance towards one or other closely located levels.

3. Definition of objectives

In developing the objectives the clinic team must be involved. Objectives should be defined as critically as possible, it is rarely just a question of removal of the leg. The problems requiring solution are extremely varied and range from the extreme of the dysvascular patient with the emphasis on rapid, effective, but often limited rehabilitation, to the other extreme of amputation of a leg as part of the treatment of trauma in a young man. In this case, ablation of the leg may simply be the first stage in the programme of management and a second stage envisages the careful construction of a stump which will have to last perhaps forty or fifty years. The team should be aware that after a temporary fitting is made for the first stump and, paradoxically, especially if that fitting is performed by a highly competent prosthetist, the patient may refuse the second procedure. In these circumstances the decision may seem justified in the short term as he can return to his job, wife and family at a much earlier date

without apparent detriment. However, the second procedure might have provided him with a stump capable of accepting a more sophisticated prosthetic prescription and one which was capable of withstanding much higher loads and in turn offering more job opportunities. The clinic team must have a clear understanding of the ultimate objectives and the prosthetist in particular, without denigrating his own skills, must ensure that the patient's long term needs are satisfied.

4. Pre-operative care

Once a programme of management has been developed with the full understanding and collaboration of the patient so far as this can be obtained, the pre-operative preparation must have regard to the mental adjustment of the patient and to the physical state required to face up to major surgery.

In an elective procedure in the younger patient there is no reason why the detail of what will happen to him following surgery cannot be outlined. He should be given information regarding what pain he is likely to have and how this will be overcome, how long he is likely to be in bed, when the drain is likely to be removed, when dressings or plaster are likely to be changed, when he can expect to have the stitches removed from his wound and when it is likely that he will be fitted with his first prosthesis. The patient should have some understanding of the likely functional loss and to what extent this can be compensated for by the prosthesis which will ultimately be provided. In furtherance of this it is often useful for the patient to talk to someone who has undergone the same procedure and been fitted with a similar prosthesis. A discussion should be developed outlining the extent to which he will be able to undertake his previous employment or alternatively what retraining will be required. He should have some understanding of how well he will be able to negotiate the physical obstacles of life. Whatever communication is necessary and pertinent to the patient's needs should be established with his family, employer, and those persons involved in his social welfare.

In the case of the vascular amputee there is frequently little opportunity to discuss the procedure in any detail and, very often in their toxic state, to consider anything other than the removal of their extremely painful appendage. A

careful assessment of the patient is required so that the concurrent disabilities can be identified and treated whether they be cardiac, pneumonic, diabetic or renal. Where time permits any infections should be intensively treated and diabetes stabilized.

Vasodilation is encouraged by the administration of intravenous low-molecular-weight Dextran. Before proceeding to the operating theatre the affected foot should be isolated within a plastic bag extending to just above the affected area and sealed to the skin. The skin itself is prepared with povidone-iodine on the days prior to operation and by compress from groin to protected foot for thirty minutes preceding operation. Benzyl penicillin is given, 500,000 units intramuscularly, six-hourly from two hours prior to operation continuing for two or three days and thereafter orally for a total of one week. The length of time during which intramuscular dosage will be necessary will be linked to the removal of any drainage tube. In cases of penicillin sensitivity, erythromycin should be given, the dose being 500 mgm six-hourly. Intramuscular administration will be necessary for the first few doses switching to oral dosage as soon as the patient's general condition permits.

A study on the use of "mini-heparin" for five days (5,000 international units subcutaneously), three times a day starting two hours pre-operatively, is presently under way and no general advices can be given at this time.

Perineal pads are routinely employed and the perineal area is securely draped off from the operative field.

A unilateral block spinal anaesthetic is given employing heavy Nupercaine at lumbar 2-3 level the patient being left lying on the affected side for three minutes. We believe spinal anaesthesia of this kind is advantageous as post-operative confusion is lessened due to the complete relief of pain post-operatively for one to two hours and, therefore, less post-operative narcotics are required. As the spinal anaesthesia is unilateral there are less problems with hypotension. Moreover in the case of the diabetic, liquids and a light diet can be given much sooner after operation and there are fewer chest complications in patients with chronic bronchitis. There is diminished intra-operative blood loss and the sympathetic block gives a

clearer line of demarcation useful to the operating surgeon.

5. Surgical technique

The surgery itself should encompass two basic essentials—a clear objective in tissue management and gentle handling of all tissues. Each tissue demands a particular approach.

Where bone is transected it must be sculptured so that it will best accommodate the transfer of the high forces involved in walking. This is particularly applicable in the below knee amputation but rounding off the anterior edge of the cut femur may also be required. Where feasible the medulla should be closed by a periosteal flap to retain normal intramedullary pressures. (Askalanov and Aronov (1959)).

It seems eminently sensible to attach divided muscle to the end of the stump bone. The early German workers stressed this although their objective was to produce a muscle "pad". Since then Dederich (1967), Burgess (1968) and Weiss (1969) have emphasized this requirement. The author is equally convinced but so far there is little scientific evidence to support this view which is readily appreciated in clinical practise. It is said to be more physiological, providing a more stable shape, less muscle wasting, better proprioception with retention of existing neuro-muscular mechanisms, more efficient vascular dynamics, etc., but few studies exist. Dederich (1967) demonstrated improved vascular supply to the stump end after myoplastic revision and Hansen-Leth and Reimann (1972) demonstrated in laboratory animals a better blood supply to the stump end when muscle stabilization was used.

A Dundee study (Condie 1973) suggests that muscle stabilization does give a rhythmic, phasic muscle activity on walking in contrast to the continuous but irregular pattern of EMG activity in unsecured muscle.

Management of the divided nerve has been a subject of controversy for a very long time. It has become generally accepted to undertake a high clean cut to ensure that the inevitable neuroma becomes located in such a situation that it neither interferes with prosthetic fitting nor produces significant symptoms. Swanson *et al* (1972) propose in both stump revision and primary amputation that the nerve be capped with a silicone device. Further evaluation of this work is required.

The management of skin as a tissue is basic to the success of any amputation. The higher the ratio of the base to the length of flap the better the chance of primary wound healing. Equally important is gentle handling and the close apposition of the skin edges.

All those who require to take the patient through his whole rehabilitation programme are aware that wound haematoma is the curse of amputation surgery. All but a few recommend drainage and most advocate closed suction drainage.

6. Stump environment

The stump environment imposed on the operating table must be consistent with the proposed patient management programme and may be as important as the surgery itself. The effect of surgical trauma is to produce a response from the injured tissues resulting in the clinical phenomenon of oedema and the effect is greater the more distal the wound. The responsibility of the surgeon is to ensure that this response does not adversely affect the blood supply. If oedema is permitted then interstitial pressure may rise sufficiently to depreciate an already precarious blood supply and produce ischaemia.

It is clear that bandaging techniques can be fraught with danger. Spiro *et al* (1970) showed that a sustained pressure above 15 mm Hg decreased blood flow. Other contributions such as those of Muller and Vetter (1954) and Wood (1968) confirm values of the same order and the latter emphasizes the influence of posture. When the bandage is applied above the knee, Husni *et al* (1968) suggest that pressures of that order applied to the popliteal fossa create a tourniquet effect. Johnson (1972) goes further and suggests that no dressing or bandage exerting a pressure of 10 mm Hg or more should be left on overnight. Isherwood *et al* (1975) in reviewing the subject outline the dangers of bandaging and review more recent techniques such as Puddifoot's (1973) pressure sock which exerts much lower sustained pressures. This is compared with the effects of the very high pressures produced by both skilled and unskilled "bandagers".

Since the work of Berlemont (1961), the dissemination of his work by Weiss (1966) and later by Burgess (1968), the use of the rigid plaster cast as a post-operative dressing for the

amputation stump has become widespread. Mooney *et al* (1971) defined the place of the rigid cast dressing and demonstrated its superiority over the soft dressings in a strictly controlled study. The extension of the rigid cast dressing to include a pylon and foot within the philosophy of immediate post surgical fitting remains a matter of controversy involving as it does factors relating to psychological impetus, the gradual application of functional mechanical stress, the discriminate apportionment of blood supply to different tissues on exercise, and the effect of "training muscle" with a subsequent decrease in blood flow demand, all making for individual prescription in post-operative management.

Recent work by Redhead *et al* (1974) now under study in a multi-national trial relates to a more ideal approach to stump environment encompassing control of the essential parameters of pressure, humidity, temperature and sterility—so-called Controlled Environment Treatment. Further reports of this technique are awaited with interest as early publications, e.g. Redhead (1973) suggest there are significant benefits for the patient in terms of wound healing and early maturation of the stump.

7. Immediate post-operative care

Apart from the environment of the stump the immediate post-operative care relates to the judicious deployment of analgesics and appropriate application of the elements of rehabilitation. Those undertaking amputation surgery routinely will be aware of the pattern of pain incidents under given circumstances and should be in a position to provide analgesics before the build up of pain to distressing levels. Too often analgesics are given when the pain is already intense and sustained. Once the patient has recovered from the immediate effects of surgery then he or she should be encouraged to wear day clothes and, whatever mode of mobility is chosen, be involved in an increasing programme of self-help and training in the activities of daily living. The physiotherapy programme should involve general exercises, if need be, crutch exercises and even muscle setting exercises of the muscles of the stump. The latter part of the programme will depend on the surgery applied and the stability of the proximal joint. If, for example, a rigid

cast has been applied after below-knee amputation then muscle setting exercises can begin without detriment to the patient. The speed of development of the rehabilitation programme will clearly depend on how early a prosthesis is fitted, on the stump environment, and on the general condition of the patient. In those centres with a full clinic team a programme of early post-surgical fitting can be applied with confidence based on the experience of Burgess *et al* (1971), Sarmiento *et al* (1970), Jeffrey (1974) and others. If employed, this programme must ensure very carefully graduated weight bearing along the lines recommended by Burgess. The team must be sensitive to any changes occurring in the stump or in the relationship between stump and rigid cast and be prepared to change the cast at any time if there are signs indicating ischaemia, infection, haematoma or a significant discrepancy in volume. Most centres will apply a less aggressive regime and change the initial rigid cast at 5-7 days and retain the rigid cast until the 18th or 21st day when the sutures can be safely removed. Earlier removal of the sutures is not advocated in the case of the dysvascular amputee. In the young and fit, sutures can probably be removed about the fourteenth day.

8. Prosthetic fitting and integrated rehabilitation

Whatever philosophy is practised immediately following surgery, in the uncomplicated case the patient should be ready for initial prosthetic fitting somewhere between 3-4 weeks. It is essential that the arrangements are such that the patient does not require to wait more than a few days for provision of the initial prosthesis. As the physical therapy programme develops both stump volume and shape are changing rapidly and it is essential that the team are sensitive to this situation and by one means or another ensure that a good stump/socket interface is maintained. After initial fitting, walking training is introduced into the overall rehabilitation programme. At this time the rehabilitation goals set for the individual patient should be reassessed and adjustments made. In a limited programme the accent must be on self care and the activities of daily living.

The more ambitious programmes should include progressive development of the prosthetic prescription, the performance of more

difficult mobility tasks, plans for vocational rehabilitation where required and other elements of social integration.

Amputation techniques

Hemipelvectomy

The incidence of this procedure is low, perhaps of the order of one amputation per million of population per year, and usually performed for chondrosarcoma. The procedure itself is an anatomical exercise and I suggest that the best description of the operation is that of Monro (1952). It is suggested further that one surgeon in each community should take responsibility for this demanding and mutilating procedure.

Hip disarticulation

This procedure too is normally undertaken because of tumour and is again an anatomical exercise and many descriptions including that of Boyd (1949) are available for the surgeon to study.

Above-knee amputation

Amputation in the thigh can be carried out at different levels depending on the factors already outlined and thus the surgeon must be sensitive to the anatomy of the part at which amputation is to be performed.

Generally equal anterior and posterior flaps will be employed but variations may be required. The general rule will be that the ratio of the base of the flap to its length will be as great as possible. It is important that there is an adequacy of skin so that the flaps can be sutured without undue tension. Those practising amputation surgery can usually guess this with accuracy and accommodate the terminal bulk of the stump. The inexperienced would be wise to retain a sufficiency of skin in the flaps which can later be tailored to the needs of the stump at the end of the operation. The criteria in the management of muscle should be to ensure a firm attachment of severed muscle to the end of the stump. This is essential as following amputation there is less muscle to do more work, the muscle contractions are of longer duration thus limiting blood flow in the muscle during contraction with an earlier onset of fatigue. Moreover a divided muscle has a reduced velocity of con-

tracture and a reduced excursion. It is accordingly essential that divided muscles are securely attached. The adductors, which normally contribute to stability during lateral rotation of the thigh will, after amputation if properly managed, stabilize the femur within the stump and prevent its lateral migration. The hamstrings after division forfeit their two joint functions and have instead a primary role in stabilizing the prosthetic knee and their secure attachment is equally important. The author's procedure described in detail elsewhere (Murdoch, 1968) involves suture of the hamstrings and any adductors involved via drill holes to the end of the divided femur. The medulla is closed with an anterior periosteal flap and the quadriceps drawn over the end of the stump and sutured to the posterior muscles (Figure 1). As in other amputations the nerve is drawn down gently and divided with a high, clean cut to ensure that the inevitable neuroma will be remote from any distal scarring. The main vessels are isolated, ligatured and divided low in the wound to ensure optimum terminal blood supply.

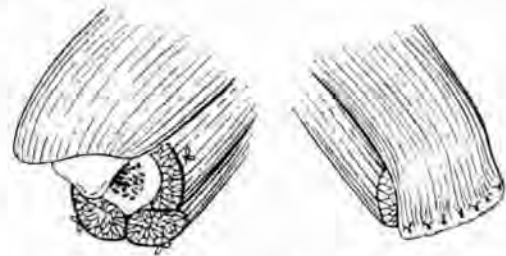


Fig. 1. Schematic illustration of procedure advised by author. Lateral and medial hamstrings and adductors sutured under tension to bone via drill holes and cut flush with bone end. Medulla closed with anterior periosteal flap. Quadriceps left long and drawn over stump end to be sutured to posterior muscles.

Transcondylar and supracondylar

A variety of these procedures have been described Callender, (1935, 1938); Gritti (1857) and Slocum (1949) and some still have their protagonists. Surgeons concerned only with early wound healing may be persuaded to perform these procedures but the resultant stump is often unable to tolerate any significant end bearing and its length will often preclude the use of a number of knee devices. Moreover the resultant stump can produce

many problems for the prosthetist, particularly in the case of the Gritti-Stokes procedure. One can accept, however, that there are special circumstances where the surgeon may elect to perform one of these procedures for reasons such as cosmesis but he should not, until evidence is available, defend his decision by referring to end bearing properties.

Knee disarticulation

This procedure provides a stump capable of true end bearing with good proprioception, excellent rotational stability between the stump and socket and, because of its bulbous end, ensures excellent suspension. It is clearly a valuable procedure in childhood as it retains the epiphysis and in the elderly too, if a below-knee amputation cannot be performed.

The surgical procedure itself is simple and non-traumatic. Few muscles are cut and haemostasis is easily obtained. Kjølbye (1970) describes this procedure in detail and advocates lateral flaps rather than long anterior flaps. The author's experience has led him to use the lateral flap techniques exclusively (Figure 2). The technique described by Kjølbye is based on that of Velpeau (1830) and Smith (1825).

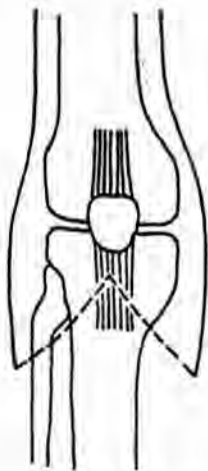


Fig. 2. Sketch showing disposition of lateral flaps in knee disarticulation amputation.

Ideally the patient is placed prone on the operating table providing easy access to both anterior and posterior aspects of the knee. The incision is planned by carefully outlining

bilateral flaps in methylene blue. The incision is started just below the tip of the patella continuing downwards vertically to the upper border of the tibial tubercle then curving laterally for the lateral flap and medially for the inner flap over the sides of the knee, ending in the mid line at the popliteal crease posteriorly at a level approximately 25 mm above the joint line. The lowest point of the lateral flap should be half of the antero-posterior diameter below the knee joint line or about 30 mm below the upper border of the tibial tubercle. The medial flap should be 20–30 mm longer than the outer in order to secure adequate covering of the slightly larger and more prominent medial femoral condyle. The incision is carried down through skin, subcutaneous tissue and fascia and the flaps raised keeping close to the periosteal covering. The patellar tendon and medial and lateral hamstrings are divided.

With the knee flexed the lateral and medial cartilages are freed from their tibial attachment and the capsule and collateral ligaments of the knee incised at the margins of the joint surfaces leaving the menisci in contact with the femoral condyles. The cruciate ligaments are divided and the posterior capsule of the joint dissected from the tibia. The popliteal vessels are identified, secured, divided and ligated. Both tibial and common peroneal nerves are isolated, pulled down gently and severed as high as possible and allowed to retract. The disarticulation is completed by dividing the remaining soft tissues.

The patellar tendon is sutured to the remainder of the cruciate ligaments. The divided hamstrings may be sutured to the intercondylar notch or to the remaining part of the capsule. The patella and fat pad are left undissected and all articular cartilage left undisturbed. The wound is closed in layers. In doing so it is extremely important that sufficient skin is present for a loose closure.

Closed suction drainage is employed and after appropriate dressing a rigid plaster of Paris cast applied.

Below-knee amputation

A variety of procedures are available including the so-called "conventional" procedure employing anterior and posterior flaps. As it happens there are few indications for this

procedure. The author's preference is for an osteomyoplasty technique (Ertl, 1949) in all conditions other than vascular deficiency. In the dysvascular patient the posterior flap procedure, Ghormley (1946), Burgess (1969), is appropriate to most cases. Increasing experience is likely to demonstrate the value of the sagittal flap technique of Persson (1974) and other flaps designed individually for the patient.

Osteomyoplasty

The procedure employed by the author is almost precisely that described by Loon (1962). The level of operation when the pathology will allow is usually just above the musculotendinous junction of the calf muscles. Vertical incisions are made on the antero-lateral and postero-medial aspects of the stump distally from a point about 25 mm above the anticipated level of bone section. With the need to expose some 75-100 mm of tibia below the anticipated level of ultimate bone section two vertical incisions are carried down far enough to permit this and are joined by a circular incision. The two flaps thus formed are elevated subcutaneously to ensure an intact deep fascia and muscle aponeurosis. A vertical cut is made through the deep fascia of the limb just lateral to the anterior tibial crest avoiding the periosteum. A further vertical incision is made through the deep fascia overlying the fibula. The whole of the anterior lateral group of muscles including the peroneals is then elevated by sharp dissection from the bed formed by the tibia with its overlying periosteum, interosseous membrane and fibula, to a point just proximal to the level of bone section. The posterior muscle flap is treated in a similar manner. The fibula is now divided at the intended level of tibial section along with the attached interosseous membrane. Two vertical incisions are made in the periosteum of the tibia so that roughly equal osteo-periosteal flaps can be elevated. The antero-medial flap of periosteum is raised with a medium sized gouge, with small flakes of bone remaining attached to the parent periosteum, to a point above the anticipated level of bone section. The same procedure is employed in elevation of the postero-lateral flap. Only now is the tibia divided and the anterior distal end sculptured.

The posterior tibial vessels are secured, isolated and divided, and the nerve divided cleanly under light tension. The postero-lateral osteo-periosteal flap is then reflected upon itself and sutured to a small cuff of periosteum elevated from the fibula. The antero-medial osteo-periosteal flap is then brought over the end of the tibia and sutured to the fibular periosteal cuff. Suture of the two flaps is now completed forming a rather firm osteo-periosteal tube bridging both bones (Figure 3). The anterior and posterior muscle flaps are then cut to length, trimmed, contoured and sutured over the periosteal tube. In the process the remaining vessels and nerves are isolated and dealt with. It is essential that both groups of muscles are separately anchored to the periosteum of the tibia and to the base of the bridge. The two skin flaps are now carefully tailored and sutured over the muscles of the stump. Closed suction drainage is employed, the wound dressed and a rigid cast applied.

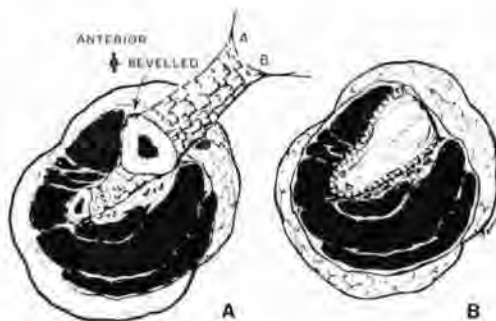


Fig. 3. Osteomyoplasty. Sketch (A) shows the postero-lateral osteo-periosteal flap reflected laterally and sutured to periosteum of fibula. The antero-medial osteo-periosteal flap displayed demonstrates attached osseous chips. It is brought over the end of the tibia after bone sculpture (sketch (B)) and sutured to the periosteum of the fibula (note points A, B) forming a firm tube.

(From *Artificial Limbs* 6, No. 2, June, 1962, 90-91).

Early ossification of the osteo-periosteal tube can be expected in seven to nine weeks after operation and the resultant stump is a particularly tough organ of locomotion subject to little change in volume and retaining muscles which on test demonstrate very satisfactory phasic muscle activity (Figure 4).

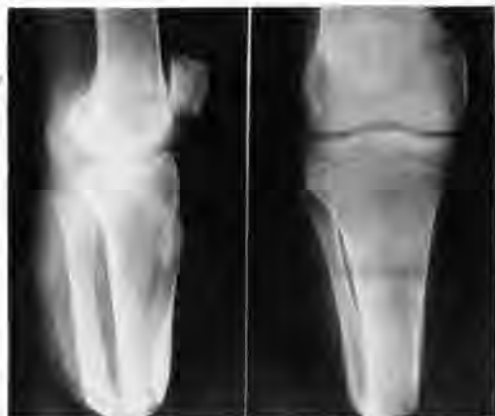

Fig. 4. Radiographs (lateral projection on the left, antero-posterior on the right) show established bony bridge between the tibia and fibula some three years after operation.

The posterior flap operation

A very short anterior flap and a long posterior flap are employed. The anterior flap is at the level of anticipated bone section and if it has a dimension of length would normally be no more than 10 mm. The flaps are outlined in methylene blue or a similar dye and the anterior incision carried down through deep fascia to the tibia. The antero-lateral muscles are divided, the artery and veins ligated and the nerve cut and allowed to retract. The fibula is divided with a Gigli power saw about 25 mm above the line of tibial section. The tibia itself is divided in a similar way. The posterior flap is deepened through the fascia and the muscles divided to complete the amputation. Practice varies with regard to the treatment of the posterior flap. Many surgeons taper the posterior flap towards the distal end to reduce the amount of tissue in the muscle mass. The author's practice is to excise not only the deep posterior muscles but the soleus as well because of the common finding of large clots in the soleal venous sinus. Whichever method is used the peroneal and posterior tibial neurovascular bundles are dealt with. The tibial bone end is then carefully sculptured to produce a smoothly contoured antero-distal aspect. After further tailoring the gastrocnemius is sutured to the anterior tibial periosteum and the fascia overlying the anterior tibial compartment. Trimming of the posterior skin flap may be required before its final

closure. There should be no concern if small "dog ears" are left at each end of the wound as they readily disappear.

Sagittal incision for below-knee amputation

This procedure described by Persson (1974) is said to improve the healing possibilities by using medial and lateral flaps (Figure 5) and avoiding the all too common occurrence of ischaemia of the short anterior flap in the procedure described above. Persson's procedure should be part of the surgeon's armamentarium.

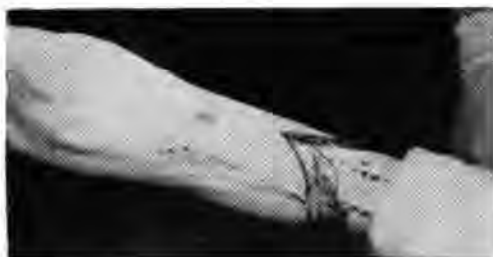

Fig. 5. Sagittal incision for below-knee amputation in ischaemic gangrene as described by Persson.

Syme's amputation

This procedure first described by Syme in a series of articles dated from 1843 to 1857 remains a useful procedure and produces a stump which in a child retains the distal tibial epiphysis and at all ages provides for a measure of end bearing. The best description of this procedure is to be found in a classical article by Harris (1966). His description does not differ in essence from that described by Syme himself.

Both incisions, dorsal and plantar are made from the tibia to the lateral malleolus to just below the medial malleolus. Both are carried down to bone. The dissection is thenceforth developed throughout with the knife against the bone thus ensuring integrity of the heel flap to the posterior tibial artery and the stabilized subcutaneous fibro-elastic tissue of the heel pad (Figure 6). The bones are divided at the dome of the ankle joint with the saw cut parallel to the ground and not necessarily at right angles to the shaft of the tibia. The heel flap is now placed precisely over the cut end of the bone, sutured, and secured in position.

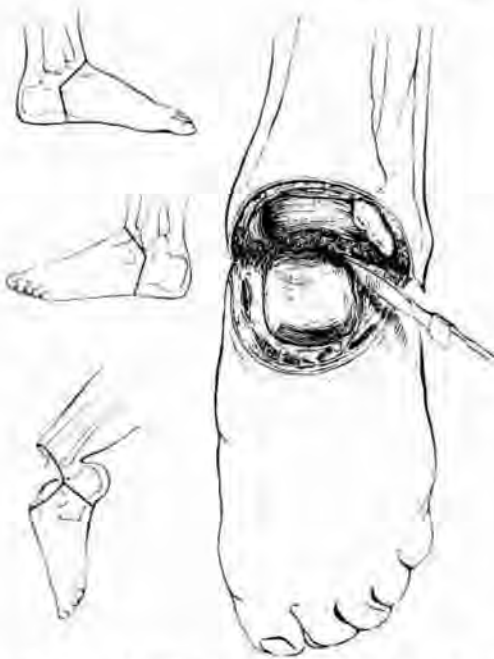

Fig. 6. Line drawing illustrating bone section and heel flaps in Syme's amputation.

Closed suction drainage is employed. It is essential to ensure the continued firm location of the heel pad. Harris recommended a strapping technique. Transfixion pins have been employed but prevent early post-operative weight bearing and can be lost in the wound. The author employs a tension sock and rigid cast. The history of this procedure is such that adherence to Syme's technique is mandatory if a good result is to be maintained; or, to quote Syme:—

"The amputation is easily executed and proves in the highest degree satisfactory . . . if done in accordance with certain principles which have been carefully explained but it is difficult and disastrous if performed incorrectly."

Modifications of this procedure (Elmslie 1924) which require a higher bone division are doomed to failure (Murdoch 1976) because of the reduced area presented by the divided bones and the inability to locate the heel pad.

The resultant stump from the classical Syme's procedure has one defect and that is primarily due to the large medio-lateral diameter which leads to poor cosmesis. Mur-

doch (1976) demonstrated that the Syme's stump in a modern prosthesis is not wholly end bearing. This would seem to justify the modification of a procedure suggested by Mazet (1968) who recommended removal of the malleolar projections. This practise is now standard in Rancho Los Amigos (Wagner, 1975—personal communication) who perform the procedure in two stages as recommended by Hulnick *et al* (1949).

Partial foot amputations

A variety of these procedures have been described over the years, Chopart (Fourcroy 1792), Lisfranc (1815), Pirogoff (1854). Pirogoff's procedure retains part of the os calcis and its associated heel pad and provides excellent end bearing properties. However it requires that bony union takes place between the os calcis and the cut end of the tibia and the resultant stump is so long that a modern prosthesis cannot be fitted. Even so within certain cultures it may remain a valuable procedure.

Chopart's procedure located at mid tarsal level has few adherents today because of the tendency of the stump to become inverted and plantar flexed even when the tendon to tibialis anterior is attached to the neck of the talus. The stump is very short and difficult to fit.

In Lisfranc's procedure the forefoot is disarticulated along the tarso-metatarsal line. This operation also has few adherents today because of the short stump and because of its poor cosmesis.

The transmetatarsal amputation is widely used in a variety of situations, for example in trauma and diabetes. It is essential that there should be an adequate plantar flap sufficient to cover the divided and sculptured metatarsal bones.

Amputation of all five toes remains a valid procedure. The technique recommended is that described by Nissen (1957). Flint and Sweetnam (1960) provided evidence of its value. The procedure may be used in a variety of conditions and provides a stump which requires no more than a special insole incorporating an arch support and toe spacer within a normal shoe.

Part II will cover the subjects of amputation in a variety of disease and disability categories, in certain special situations, and comment on recent advances and their implications for the future.

REFERENCES

- ASKALANOV, I. N. and ARONOV (1959). Comparative experimental evaluation of some methods of bone revision in amputation with primary and secondary healing. *Ortopediya, travmatologiya i protezirovanie*, **20**, 30-33.
- BERLEMONT, M. (1961). Notre experience de l'appareillage precoce des amputés de membre inferieur aux établissements. *Helio Marins de Berck. Annales de médecine physique*, **4**, 4.
- BOYD, H. B. (1949). Disarticulation of the hip. *Campbell's Operative Orthopedics* (1). Ed. Speed, J. S. and Smith, H. 824-828. The C. V. Mosby Co., St. Louis.
- BURGESS, E. M. and ROMANO, R. L. (1968). The management of lower extremity amputees using immediate post-surgical prostheses. *Clin. Orth. and Rel. Res.*, **57**, 137-146.
- BURGESS, E. M. (1968). The stabilization of muscles in lower extremity amputations. *J. Bone and Joint Surg.*, **50A**, 1486-1487.
- BURGESS, E. M. (1969). The below-knee amputation. *Inter-Clin. Inform. Bull.*, VIII, No. 4.
- BURGESS, E. M., ROMANO, R. L., ZETTLE, J. H., and SCHROCK, R. B. (1971). Amputations of the leg for peripheral vascular insufficiency. *J. Bone and Joint Surg.*, **53A**, 874-889.
- CALLENDER, C. L. (1935). A new amputation in the lower third of the thigh. *J. Amer. Med. Assoc.*, **105**, 1746-1753.
- CALLENDER, C. L. (1938). Tendoplastic amputation through the femur at the knee. *J. Amer. Med. Assoc.*, **110**, 113-118.
- CONDIE, D. N. (1973). Electromyography of the lower limb amputee. *Medicine and Sport*, Vol. **8**, *Biomechanics* 3; 482-488, Karger, Basle.
- DERERICH, R. (1967). Technique of myoplastic amputations. *Annals of the Royal College of Surgeons*, **40**, 222-227.
- ELMSLIE, R. C. (1924). In "Carson's Modern Operative Surgery". 1st. ed. 132, Cassel & Co., London.
- ERTL, I. (1949). Über Amputationsstumpf. *Chirurg.*, **20**, 218.
- FLINT, M. and SWEETNAM, R. (1960). Amputation of all toes. *J. Bone and Joint Surg.*, **42B**, 90-96.
- FOURCROY, A. F. (1792). *La médecine éclairée par les sciences physiques*, Vol. 4, 85-88. Chez Buisson. Contains first description of Chopart's method of partial amputation of the foot.
- GHORMLEY, R. K. (1946). Amputation in occlusive vascular disease. In "Peripheral Vascular Diseases". 1st. ed. Ed. Allen, E. V., Barker, N. W. and Hines, Jun., E. A. 783; W. B. Saunders Company, Philadelphia.
- GRITTI, R. (1857). Dell' amputazione del femore al terzo inferiore e della disarticolazione del ginocchio. *Ann. Univ. Milano*, **161**, 5-32.
- HANSEN-LETH, C. and REIMANN, I. (1972). Amputations with and without myoplasty on rabbits with special reference to the vascularisation. *Acta orth. Scand.*, **431** 68-77.
- HARRIS, R. I. (1966). "History and development of Syme's amputation". In "Selected articles from Artificial Limbs." January 1954-Spring 1966, p. 233.
- HULNICK, A., HIGHSMITH, C. and BOUTON, F. J. (1949). Amputations for failure in reconstructive surgery. *J. Bone and Joint Surg.*, **31A**, No. 3 639-649.
- HUSNI, E. A., XIMENES, J. O. C. and HAMILTON, F. G. (1968). Pressure bandaging of the lower extremity. *J. Amer. Med. Assoc.*, **206**, 2715-2718.
- ISHERWOOD, P. A., ROBERTSON, J. C. and ROSSI, A. (1975). Pressure measurements beneath below-knee amputation stump bandages, elastic bandaging, the Puddifoot dressing and a pneumatic bandaging technique compared. *Brit. J. Surg.*, **62**, 982-986.
- JEFFREY, A. K. (1974). Below-knee amputation and immediate prosthetic fitting in vascular disease. *New Zealand Med. J.* (in press).
- JOHNSON, H. D. (1972). Mechanics of elastic bandaging. (Correspondence) *Brit. Med. J.*, **3**, 767-768.
- KJØLBYE, J. (1970). The surgery of the through-knee amputation. *Prosthetic and Orthotic Practice*. Ed. Murdoch, G., 255-257. Edward Arnold (Publishers) Ltd., London.
- LISFRANC, J. (1815). Nouvelle méthode opératoire pour l'amputation partielle du pied dans sons articulation tarso-métatarsienne; méthode précédés des nombreuse modifications qu'a subies celle de Chopart. *Gabon, Paris*.
- LOON, H. E. (1962). Below-knee osteomyoplasty. *Art. Limbs*, **6**(2), 86-99.
- MAZET, R. (1968). Syme's amputation. A follow-up study of fifty-one adults and thirty-two children. *J. Bone and Joint Surg.*, Vol. **50A**, 8, 1549-1563.
- MONRO, R. and SIR G. GORDON-TAYLOR (1952). The technique and management of the 'Hind-quarter' amputation. *Brit. J. Surg.*, Vol. XXXIX, **158**, 536-541.
- MOONEY, V., HARVEY, J. P., MCBRIDE, E. and SNELSON, R. (1971). Comparison of post-operative stump management: plaster vs. soft dressings. *J. Bone and Joint Surg.*, **53A** (2), 241-249.
- MÜLLER, E. A. and VETTER, K. (1954). The effect of pressure loads upon blood supply to the skin. *Arbeitsphysiologie*, **15**, 295-304.
- MURDOCH, G. (1968). Myoplastic techniques. *Bull. Pros. Res.*, **10-9**, 4-13.
- MURDOCH, G. (1976). Syme's amputation. *J. Royal Coll. Surg. Edin. Jan.* Vol. **21**, No. 1, 15-30.
- NISSEN, K. I. (1957). Amputation of all five toes. In *Operative Surgery*. Vol. 5, 301. Ed. Rob, C. and Smith, R., Butterworth, London.
- PERSSON, B. M. (1974). Sagittal incision for below-knee amputation in ischaemic gangrene. *J. Bone and Joint Surg.*, **56B** (1), 110-114.
- PIROGOFF, N. I. (1854). *J. Military Medicine, St. Petersburg*, **63**, 83.
—see also Farabeuf (1881) p. 500.
- PUDDIFOOT, P. C., WEAVER, P. C. and MARSHALL, S. A. (1973). A method of supportive bandaging for amputation stumps. *Brit. J. Surg.*, **60**, 729-731.
- REDHEAD, R. G. (1973). The problems of the post-operative and stump environment interface. *First International Congress of Prosthetic Techniques and Functional Rehabilitation*. 65-73. Egermann Druckereigesellschaft, M. B. H. & Co., K. G., Vienna.

- REDHEAD, R. G., SNOWDON, C., BURGESS, E. M., and VITALI, M. (1974). Controlled environment treatment for the post-operative management of wounds of the upper and lower limb including amputation stumps. Presented at the First World Congress, International Society for Prosthetics and Orthotics, Switzerland, October.
- SARMIENTO, A., MAY, B. J., SINCLAIR, W. F., MCCOLLOUGH, N. C. III and WILLIAMS, E. M. (1970). The impact of immediate postsurgical fitting. *Clin. Orthop.*, **68**, 22-31.
- SLOCUM, D. B. (1949). The rounded epicondylar tendo-plastic amputation. *Campbell's Operative Orthopedics* (1). Ed. Speed, J. S. and Smith, H. 819-822. The C. V. Mosby Co., St. Louis.
- SMITH, N. (1825). Amputation at the knee joint. *Amer. Med. Rev., Philadelphia*, **2**, 370.
- SPIRO, M., ROBERTS, V. C. and RICHARDS, J. B. (1970). Effect of externally applied pressure on femoral vein blood flow. *Brit. Med. J.*, 719-723.
- STOKES, W. (1870). On supra-condyloid amputation of the thigh. *Med.-chir. Trans. London*, **53**, 175-186.
- SWANSON, A. B., BOEVE, N. R. and BIDDULPH, S. L. (1972). Silicone rubber capping of amputation neuromas—Investigational and clinical experience. *Inter-Clin. Inform. Bull.*, **11**, No. 5, 1.
- SYME, J. (1843). *Edinburgh Monthly Journal of Medical Science* 3, No. XXVI, p. 93. (1843) *Ibid* 3 No. XXVIII, p. 274. (1844) *Ibid* 4 No. XLIV, p. 647. (1845a) *Ibid* 5 No. LIII, p. 341. (1845b) *Monthly Journal of Medical Science* 5, No. LIII, p. 337. (1846) *Ibid* 6, No. LXVIII, p. 81. (1857) *Lancet* 2, 384, 394, 480.
- VELPEAU, A. (1830). Mémoire sur l'amputation de la jambe dans l'articulation du genou, et description d'un nouveau "procédé" pour pratiquer cette operation. *Archives générales de Médecine*. **24**, 44-60.
- WAGNER, F. William (1975). Personal communication.
- WEISS, M. (1966). Neurological implications of fitting artificial limbs immediately after amputation surgery. Report of Workshop Panel on Lower Extremity Prosthetic Fitting. Committee on Prosthetic Research and Development. National Academy of Sciences, Washington, D.C.
- WEISS, M. (1969). Physiologic amputation, immediate prosthesis and early ambulation. *Pros. Int.*, **3**, No. 8, 38-44.
- WOOD, E. J. (1968). The venous system. *Sci. Amer.* **218**, 86-96.