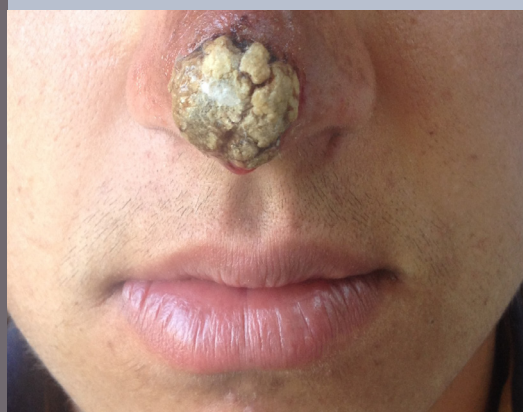

Our

Dermatology Online

www.odermatol.com

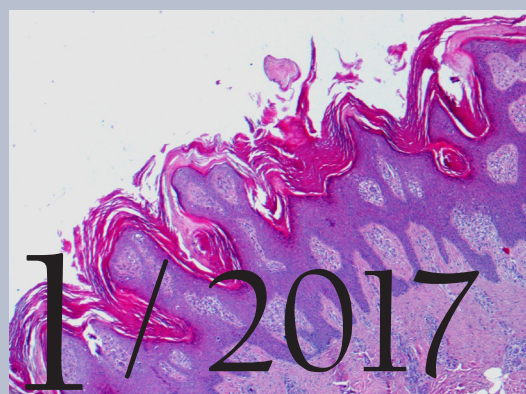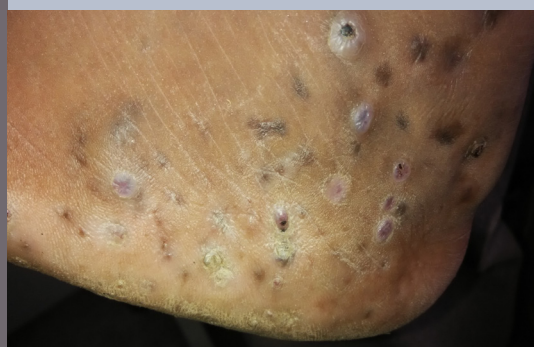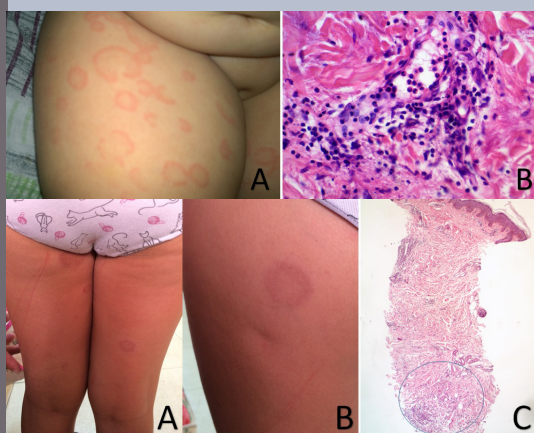


- Funda Tamer, Mehmet Eren Yuksel
A distinct cutaneous leishmaniasis lesion on the tip of the patient's nose: A visual warning for European colleagues

- Diana Narváez, Beatriz Di Martino Ortiz, Mirtha Rodríguez Masi
Annular skin lesions in childhood. Review of the main differential diagnoses

- Mrinal Gupta
Maduromycosis of foot

- Sarra Ben Rejeb, Amen Dhaoui, Dorra Ben Ghachem, Asmahane Souissi, Khadija Bellil
Psoriasis with verrucous appearance: a case report



Editorial Pages

e-ISSN: 2081-9390
DOI: 10.7241/ourd

Quarterly
Our Dermatol Online

published since 01/06/2010 years

www.odermatol.com

Editor in Chief:

Piotr Brzeziński, MD Ph.D

Address:

ul. Braille'a 50B, 76200 Słupsk, Poland
tel. 48 692121516, fax. 48 598151829
e-mail: brzezoo77@yahoo.com

Publisher:

Our Dermatology Online

Address:

ul. Braille'a 50B, 76200 Słupsk, Poland
tel. 48 692121516, fax. 48 598151829
e-mail: brzezoo77@yahoo.com

Associate Editor:

Ass. Prof. Viktoriya Kazlouskaya (USA)

Indexed in:

Universal Impact Factor for year 2012 is = 0.7319
system of opinion of scientific periodicals INDEX COPERNICUS (6,51)
(Academic Search) EBSCO
(Academic Search Premier) EBSCO
MNiSW (kbn)-Ministerstwo Nauki i Szkolnictwa Wyższego (4.00)
DOAJ (Directory of Open Access Journals)

Geneva Foundation for Medical Education and Research (GFMER), Google Scholar, Open J-Gate, NewJour,
International Committee of Medical Journal Editors (ICMJE), Genamics JournalSeek, Hinari,
Bielefeld Academic Search Engine (BASE), WorldCat, e-journal, WorldWideScience.org, National Science Library,
LibSearch, Sciencegate, Virtual Science Library (VSL), Wanfang Data, COncnecting REpositories (CORE),
CAB Abstracts, Global Health, Journal Indexed in Directory of Research Journals Indexing,
OAIster: The Open Access Initiative, OAJSE - Open Access Journals Search Engine, Scirus

Previous website:

issue 1.2010

www.ndermatol.like.pl

since issue 2.2010 to issue 3.2011

www.odermatol.like.pl

since issue 4.2011

www.odermatol.com

Previous shortcut:

since issue 1.2010 to issue 3.2011

N Dermatol Online

since issue 4.2011

Our Dermatol Online

Open access journal:

This is an open access journal which means that all content is freely available without charge to the user or his/her institution. Users are allowed to read, download, copy, distribute, print, search, or link to the full or texts of the articles in this journal without asking prior permission from the publisher or the author.

Our Dermatology Online is a international journal that publishes original contributions in the field of dermatology, including papers on biochemistry, morphology and immunology of the skin.

The journal is among the few not related to dermatological associations or belonging to respective societies which guarantees complete independence. Offers a platform for review articles in areas of interest for dermatologists.

OurDermatologyOnline offers article in English as well as in other languages. This is in accordance with the BOAI definition of open access.

Editorial Board

- Abdel-Naser, Mohamed Badawy, Prof. (Egypt)
Abdul-Lateef Mousa Haider, MD (Iraq)
Al Aboutd Khalid, MD (Saudi Arabia)
Al-Kamel Mohamed A., MD (Yemen)
Al-Mashaleh Manal Sulaiman, MD (Jordan)
Abreu-Velez Ana Maria, Prof. (USA)
Abreu Hilda, MD (Uruguay)
Adaskevich Uladzimir, Prof. (Belarus)
Afifi Mustafa, MD (United Arab Emirates)
Aghaei Shahin, Ass. Prof. (Iran)
Akpaka Patrick Eberechi, Prof. (Trinidad and Tobago)
Akyshbayeva Kulbarshin, Prof. (Kazakhstan)
Amichai Boaz, MD (Israel)
Arakelyan Hayk S. Prof. (Armenia)
Arenas Roberto, Prof. (Mexico)
Arif Tasleem, MD (India)
Asuquo Maurice Efana, Prof. (Nigeria)
Auto James, Ass. Prof. (Solomon Islands)
Fatou Barro-Traoré, Prof. (Burkina Faso)
Christian Muteba Baseke, MD (Democratic Republic of the Congo)
Beigi Pooya Khan Mohammad, Prof. (Canada)
Bharti Rakesh, MD (India)
Bonifaz Alexandro, Prof. (Mexico)
Borowska Katarzyna, Ass. Prof. (Poland)
Borruto Franco, Prof. (Monaco)
Bouadjar Bakar, Prof. (Algeria)
Bukhari Iqbal A., Prof. (Saudi Arabia)
Cabo Horacio, Prof. (Argentina)
Chamcheu Jean Christopher, Ph.D (USA)
Chang Patricia, MD Ph.D (Guatemala)
Chihanga Simon, MD (Botswana)
Choon Siew Eng, MD (Malaysia)
Chuh An Tung Antonio, Prof. (Hong Kong)
Crump Vincent, MD (New Zealand)
Daboul Mohamed Wael, MD (Syria)
Daisley Hubert, Prof. (Trinidad and Tobago)
Darlenski Razvigor, MD Ph.D (Bulgaria)
Diouf Assane, Ass. Prof. (Senegal)
Dobrev Hristo, Prof. (Bulgaria)
Doganay Mehmet, Prof. (Turkey)
Dong Huiting, Prof. (China)
Dori Geme Urge, PhD (Ethiopia)
Draganita Ana Maria, MD PhD (Romania)
Drljević Irdina, MD, Ph.D. Ass. Prof. (Bosnia and Herzegovina)
Dubakienė Rūta, Prof. (Lithuania)
Edwards Carl, Ass. Prof. (USA)
Elhassan Elizabeth, MD (Senegal)
Farkas Arpad, MD PhD (Hungary)
Fernandez-Flores Angel, MD Ph.D (Spain)
Fortuna Giulio, Ass. Prof. (USA)
Gołąb Elżbieta, Prof. (Poland)
Gómez Cuevas Alina, Prof. MD (Nicaragua)
Grattan Clive (United Kingdom)
Grivcheva-Panovska Vesna, Prof. (Macedonia)
Guzmán Antonio, MD (Paraguay)
Hashimoto Takashi, Prof. (Japan)
Hassan Iffat, Prof. (India)
Hegyí Vladimir, Prof. (Slovakia)
Hidalgo-Matlock Benjamin, MD (Costa Rica)
Hysi Katerina, MD (Albania)
Janjua Shahbaz, MD (Pakistan)
Jeseňák Miloš, Ass. Prof. (Slovakia)
Jeewon Rajesh, Ph.D. (Mauritius)
Jordán Rodríguez Ramiro, Prof. (Bolivia)
Julian Rolando, Prof. (El Salvador)
Kaszuba Andrzej, Prof. (Poland)
Kaštelan Marija, Prof. (Croatia)
Katsambas Andreas, Prof. (Greece)
Khawaja Shakeel Ahmed, PhD (Eritrea)
Kibbi Abdul-Ghani, Prof. (Lebanon)
Kossi Metowogo, Ph.D (Togo)
Kuiate Jules-Roger, Prof. (Cameroon)
Lan Cheng-Che E., Ass. Prof. (Taiwan)
Lopez-Granja Jorge, MD (Belize)
Lotti Torello, Prof. (Italy)
Mahassadi Alassan Kouamé, Ass. Prof. (Côte d'Ivoire)
Mahdi Juma Husain Ali, MD (Bahrain)
Maibach Howard I., Prof (USA)
Maio Paula, MD (Portugal)
Mekokishvili Lali, Prof. (Georgia)
Mikkelsen Carsten Sauer, MD (Denmark)
Mourad Mokni, Prof. (Tunisia)
Mota Luiz Alberto Alves, Prof. (Brazil)
Mrisho Fatma, MD (Tanzania)
Muvunyi Claude Mambo, MD (Rwanda)
Ndugwa Christopher, Prof. (Uganda)
Nedelciuc Boris, Ass. Prof. (Moldova)
Nhlengethwa Winnie, Prof. (Swaziland)
Nigam Pramod Kumar, Prof. (India)
Nikolic Milos, Prof. (Serbia)
Nowicki Roman, Prof. (Poland)
Nwabudike Lawrence Chukwudi, MD Ph.D (Romania)
Odeh Samuel, Prof. (Gabon)
Olszański Romuald, Prof. (Poland)
Oranje Arnold, Prof. (Netherlands)
Parajuli Sudip, MD (Nepal)
Parvin Rukhsana, MD (Bangladesh)
du Plessis Jeanetta, Prof. (South Africa)
Puri Neerja, MD (India)
Pusahai-Riman Paula, BSc, MS (Papua New Guinea)

Editorial Board

Qurashi Mohd, MD (Sudan)
Riedl Elisabeth, Ass. Prof. (Austria)
Ríos Yuil José Manuel, Prof. (Panama)
Ranotsi Amelia, PhD (Lesotho)
Rubio-Teixeira Marta Ph.D. (Belgium)
Rusnak Martin, Prof. (Slovakia)
Sayad Ibrahim, Prof. (Kuwait)
Sharquie Khalifa E., Prof. (Iraq)
Shawa Mary, MD (Malawi)
Shkilna Mariia, MD Ph.D (Ukraine)
Sinclair Rodney Daniel, Prof. (Australia)
Singh Harjeet, MD (Qatar)
Slavic Vjerolva, MD PhD (Montenegro)
Srinivasan Sundaramoorthy, Prof. (India)
Sumathipala Gayan Saranga, MD (Sri Lanka)
Tapia Felix J., Ass. Prof. (Venezuela)

Tatu Alin, MD (Romania)
Teixeira Roni Leonardo, MD (Brazil)
Tincopa-Wong Oscar Wilfredo, MD (Peru)
Tresh Amani, MD (Libya)
Tylewska-Wierzbanowska Stanisława, Prof. (Poland)
Uraga Pazmiño Enrique, MD (Ecuador)
Usha Rani Anaparthi, Prof. (India)
Valdebran Manuel, MD (Dominican Republic)
Vok Marko, MD (Slovenia)
Win Oo Soe, MD (Myanmar)
Wollina Uwe, Prof. (Germany)
Wortsman Ximena, Ass. Prof. (Chile)
Yamamoto Toshiyuki, Prof. (Japan)
Yuil de Ríos Emma, MD (Panama)
Zabielski Stanisław, Prof. (Poland)
Zawar Vijay, Prof (India)

Contents

ORIGINAL ARTICLES

- Erysipelas of the leg (cellulitis) in sub-Saharan Africa: A multicentric study of 562 cases 1
Bayaki Saka, Ahy Boubacar Diatta, Ousmane Faye, Boh Fanta Diané, Abdoulaye Sangaré, Pascal Niamba, Christine Mandengue, Léon Kobengue, Assane Diop, Fatimata Ly, Mame Thierno Dieng, Alassane Dicko, Mohamed Macire Soumah, Mohamed Cissé, Sarah Hamdan Kourouma, Isidore Kouassi, Sefako Akakpo, Julienne Noude Téleclessou, Palokinam Vincent Pitché
- Intense pulsed light: A promising therapy in treatment of acne vulgaris..... 6
Manjunatha Puttaiah, Shishira R. Jartarkar
- Acne: prevalence, perceptions and beliefs among pupils and students in Ouagadougou, Burkina Faso..... 10
Amina Nomtongo Ouedraogo, Sandrine Soutongo Sita Kabre Ouedraogo, Muriel Sidnoma Ouedraogo, Fagnima Traore, Patrice Gilbert Tapsoba, Fatou Barro-Traore, Adama Traore, Pascal Niamba
- Efficacy and tolerance of 2,3-diphenylcyclopropanone in propylene glycol versus 2,3-diphenylcyclopropanone in isopropanol - a novel formula designed for the treatment of alopecia areata 17
Tomasz Wasylyszyn, Katarzyna Borowska

BRIEF REPORTS

- Prevalence and determinants of eczema among females aged 21 to 32 years in Jeddah city - Saudi Arabia 22
Sultana T. Binyamin, Fathi Algamal, Amani N. Yamani, Mai S. Labani, Fatimah H. Alaqbi, Anhar A. Baeshen, Abdulelah T. Binyamin, Mohammed T. Al-Nazzawi, Shahad M. Alamoudi, Mohammed A. Aljunaid, Lamis F. Basaeed, Ahmed H. Alhasan, Alanoud M. Al-Marzoug
- A biological melange and a peculiar led light could be a thaumaturgic approach to defeat manifold types of folliculitis in man and woman 27
Lorenzo Martini

CASE REPORTS

- Lupus vulgaris of the auricle 31
Hojat Eftekhari, Rafiei Rana, Daryakar Arash, Mohammad Hosseini Maryam, Najj Rad Sara
- Malignant melanoma arising in congenital melanocytic nevi: clinical and dermoscopic challenges 34
Fatma Pelin Cengiz, Nazan Emiroglu, Anil Gulsel Bahali, Ozlem Su, Nahide Onsun
- Cutaneous sporotrichosis as an occupational disease: Case report 37
César Bimbi, Piotr Brzezinski
- Methotrexate for refractory prurigo nodularis..... 40
Mariam Al Zaabi, Mohammad Al Suwaiji, Manal Nasir
- Uncommon presentation of Pityriasis versicolor; hyper and hypopigmentation in a same patient with variable treatment response..... 43
Riti Acharya, Madhu Gyawalee
- Familial dyskeratotic comedones in a female with positive family history: A rare entity 46
Anup Kumar Tiwary, Dharmendra Kumar Mishra, Shyam Sundar Chaudhary
- Localised nasal actinic porokeratosis: An independent subtype of porokeratosis? 49
Nidhi Sharma, Yukti Aggarwal, Suresh Kumar Malhotra, Kuldeep Singh Chahal
- Anetoderma with positive Darier's sign..... 53
Rana Rafiei, Eftekhari Hojat, Arash Daryakar, Leila Yusefkhani, Behnam Rafiee
- Jadassohn Lewandowsky syndrome: Type 1 pachyonychia congenita..... 56
Anup Kumar Tiwary, Dharmendra Kumar Mishra
- Tinea manuum misdiagnosed as psoriasis vulgaris: A case of tinea incognita 60
Funda Tamer, Mehmet Eren Yuksel

Contents

Psoriasis with verrucous appearance: A case report.....	63
<i>Sarra Ben Rejeb, Amen Dhaoui, Dorra Ben Ghachem, Asmahane Souissi, Khadija Bellil</i>	
Palmar and plantar psoriasis and homeopathy – Case reports	66
<i>Lawrence Chukwudi Nwabudike</i>	
Angioma of the face: About two cases including one revealing Sturge Weber and Krabbe syndrome.....	70
<i>Bénilde Marie Ange Tiemtoré-Kambou, Nomtondo Amina Ouédraogo, Nina-Astrid Ndé/Ouédraogo, Fagnima Traoré, Pakisba Ali Ouédraogo, Ben Aziz Dao, Boubacar Ouattara, Moussa Zanga, Ousséini Diallo, Rabiou Cissé</i>	
REVIEW ARTICLES	
Annular skin lesions in childhood: Review of the main differential diagnoses	75
<i>Diana Narváez, Beatriz Di Martino Ortiz, Mirtha Rodríguez Masi</i>	
Stigmata in cutaneous leishmaniasis: Historical and new evidence-based concepts.....	81
<i>Mohamed Ahmed Al-Kamel</i>	
CASE IMAGES	
Un cas de mastocytose cutanée [A case of cutaneous mastocytosis]	91
<i>Salsabil Attafi Sehli, Salma Ghdanfi, Wafa Rkik</i>	
Maduromycosis of foot.....	92
<i>Mrinal Gupta</i>	
Angiolymphoid hyperplasia with eosinophilia	94
<i>Mrinal Gupta</i>	
HISTOLOGICAL IMAGE	
Sebaceous hyperplasia of labium major: Histopathological images.....	96
<i>Chidambharam Choccalingam, Shivakumaran Gurusamy, Premila Samuel</i>	
LETTERS TO THE EDITOR - OBSERVATION	
Pautrier-Woringer disease: lipomelanotic reticulosis/dermatopathic lymphadenitis	98
<i>Olfa El Amine El Hadj, Leila Bouhajja, Aida Goucha, Wafa Rekik, Ahmed El May, Amor Gamoudi</i>	
Chromoblastomycosis: Report of a case from a non-endemic region	100
<i>Olfa El Amine El Hadj, Issam Msakni, Fehmi Lamine, Besma Laabidi, Ammar Bouzaïène</i>	
LETTERS TO THE EDITOR	
Immunoreactivity to Meissner corpuscles and dermal nerves in a bullous arthropod bite reaction	102
<i>Ana Maria Abreu Velez, Alejandra Maria Jiménez-Echavarría, Michael S. Howard</i>	
Childhood lichen planus pigmentosus.....	104
<i>Monia Youssef, Lahouel Ines, Marmouch Héla, Rim Hadhri, Hayet Akkari, Mariem Mohamed, Yosra Soua, Hichem Belhadjali, Jameleddine Zili</i>	
Segmental lichen aureus subsequent to interdigital tinea pedis: A rare clinical appearance of “id”-reaction?	106
<i>Tatsuhiko Mori, Toshiyuki Yamamoto</i>	
A distinct cutaneous leishmaniasis lesion on the tip of the patient’s nose: A visual warning for European colleagues.....	108
<i>Funda Tamer, Mehmet Eren Yuksel</i>	
A positive patch test in an isoniazid-induced Dress syndrome.....	110
<i>Fatma Jendoubi, Kahena Jaber, Faten Rabhi, Mehdi Karray, Soumaya Youssef, Mohamed Raouf Dhaoui, Nejib Doss</i>	

Contents

HISTORICAL ARTICLES

Eponyms in dermatology literature linked to Otorhinolaryngology	112
<i>Ahed Aqeel, Khalid Al Aboud, Ashraf Al Harbi, Adnan Alehibi, Rasha Al Harbi</i>	
Dermatology eponyms – sign – Lexicon(R): Part 1.....	114
<i>Piotr Brzeziński, Manouri P. Senanayake, Irantha Karunaratne, Anca Chiriac</i>	
Dermatology eponyms – sign – Lexicon (R): Part 2.....	121
<i>Piotr Brzeziński, Max Carlos Ramírez Soto, Patrice Bourée, Balachandra S. Ankad, Shirish Dubey, Shivanand Gundalli, Martin G. Baartmans, Tomasz Wasylszyn, Katarzyna Borowska, Anca Chiriac</i>	

Erysipelas of the leg (cellulitis) in sub-Saharan Africa: A multicentric study of 562 cases

Bayaki Saka¹, Ahy Boubacar Diatta², Ousmane Faye³, Boh Fanta Diané⁴, Abdoulaye Sangaré⁵, Pascal Niamba⁶, Christine Mandengue⁷, Léon Kobengue⁸, Assane Diop², Fatimata Ly², Mame Thierno Dieng², Alassane Dicko³, Mohamed Macire Soumah⁴, Mohamed Cissé⁴, Sarah Hamdan Kourouma⁵, Isidore Kouassi⁵, Sefako Akakpo¹, Julienne Noude Téleclessou¹, Palokinam Vincent Pitché¹

¹Department of Dermatology, Sylvanus Olympio Hospital, University of Lome, Lome, Togo, ²Department of Dermatology, Le Dantec Hospital, Dakar, Cheik Anta Diop University, Dakar, Senegal, ³Department of Dermatology, CNAM, Bamako, University of Bamako, Mali, ⁴Department of Dermatology, Donka Hospital, Conakry, University of Conakry, Guinea, ⁵Dermatology Center, Treichville Hospital, University of Cocody, Ivory Coast, ⁶Department of Dermatology, Yaldago Ouédraogo Hospital, Ouagadougou, University of Ouagadougou, Burkina Faso, ⁷Department of Dermatology, Montagnes Teaching Clinic, Bangangte, Cameroun, ⁸Department of dermatology, Bangui Hospital, University of Bangui, Bangui, Centrafica

Corresponding author: Dr. Bayaki Saka, E-mail: barthelemysaka@yahoo.fr

ABSTRACT

Introduction: Erysipelas of the leg is a common and serious infection. We carried out this study aiming at describing the epidemiological and clinical characteristics, and assessing the risks factors associated with the local complications of erysipelas of the leg in sub-Saharan Africa. **Methods:** This was a prospective multicentric study carried out in the dermatology units of Hospitals located in seven sub-Saharan African countries during a period of 12 months. Patients aged 15 and above with a first episode of erysipelas of the leg were recruited. **Results:** In this study, 562 patients were recruited, having a mean age of 43.7 ± 16.9 years and a sex-ratio (M/F) of 0.67. Patients infected on one leg were 562 while those infected with two were 27. Bullous forms of the disease were observed in 95 patients, while purpuric forms were observed in 167 patients. The existence of a point of entry (485 cases), obesity (230), lymph edema (130) and the use of bleaching agents (97) were the mains risk factors. Complications during the course of the infection such as necrotizing fasciitis (34 cases) and abscesses (63 cases) were observed. They were due to the use of antibiotics and non-steroidal anti-inflammatory treatments, and the use of cataplasms. **Conclusion:** This study reveals that existence of a point of entry, obesity and lymph edema, and the use of bleaching agents were the mains risk factors influencing the local complications of erysipelas of the leg. Necrotizing fasciitis and abscesses were influenced by the use of antibiotics and non-steroidal anti-inflammatory treatments, and the use of cataplasms.

Key words: Erysipelas; Sub-Saharan Africa; Cellulitis

INTRODUCTION

Erysipelas also called bacterial dermo-hypodermatitis is an infection of deep skin layers, mainly due to streptococcus [1,2]. Facial localization became become less frequent while the infection is currently developed

on the leg [3,4]. Erysipelas of the leg is a common skin infection in dermatology consultation in sub-Saharan Africa [5-8]. However monocentric studies are rather conducted in these areas instead of multicentric type studies. We aimed at describing the epidemiological and clinical characteristics of erysipelas of the leg, and

How to cite this article: Saka B, Diatta AB, Faye O, Diané BF, Sangaré A, Niamba P, Mandengue C, Kobengue L, Diop A, Ly F, Dieng MT, Dicko A, Soumah MM, Cissé M, Kourouma SH, Kouassi I, Akakpo S, Téleclessou JN, Pitché PV. Erysipelas of the leg (cellulitis) in sub-Saharan Africa: a multicentric study of 562 cases. Our Dermatol Online. 2017;8(1):1-5.

Submission: 12.06.2016; **Acceptance:** 02.08.2016

DOI: 10.7241/ourd.20171.01

assessing the main risk factors influencing its local complications in sub-Saharan Africa.

MATERIALS AND METHODS

Type and Population of the Study

This was a multicentric study conducted during a 12 months period (October 2013-september 2014) in seven sub-Saharan African countries: (Togo, Senegal, Mali, Côte d'Ivoire, Guinea Conakry and Burkina Faso, and Cameroon).

Criteria of Inclusion

Patients aged 15 and above, who attended dermatology consultation for a first history of acute erysipelas of the leg, were recruited. The diagnosis of erysipelas was based upon following criteria: sudden onset of red and edematous and inflammatory leg associated with fever and shivers. Recurrent cases of erysipelas of leg were excluded, as well as necrotizing dermatitis with epidermitis, necrotizing fasciitis, and chronic dermatitis with epidermitis

Data Collection

A validated questionnaire was used to collect data. Clinical examination and biological tests e.g. HIV and glucose tests were performed for each patient. Following variables were collected for each patient:

- The presence of a point of entry (wound, venous ulcer, grazed dermatitis, intertrigo of intertoe), lymphedema, a past history of phlebitis and arteriopathy.
- The use of bleaching agents (i.e. cutaneous signs or a past history of use of bleaching agents).
- Obesity by determining the average of body mass index (BMI), blood pressure, chronic ethylism, diabetes, and HIV infection.

Statistical Analysis

The editing and processing of data was performed using Microsoft Excel version 2007. The data analysis was performed using IBM SPSS 20.0 statistical analysis software. The descriptive analysis (univariate, bivariate) was used to determine the Odds ratio (OR) between the occurrence of gross local complications (necrotizing fasciitis and abscess complication of erysipelas) and patient characteristics. The 95 % confidence intervals

generated, and/or statistical tests (Chi² of Pearson or Fisher) were used to assess the association between these variables.

Ethics Statement

This study was performed on human subjects; thus, all patients were aware of the presence of the study and they were fully informed about the drug and its side-effects.

RESULTS

Of the 562 cases of acute erysipelas of the leg recruited in the eight countries, 339 were women, with a mean age of 43.7 ± 16.9 years (15 and 88 years); 104 patients consulted 3 days after the onset of erysipelas and 93 patients consult after 10 days.

A point of entry was found in 485 patients. A neglected wound was found in 324 (66.80%) patients (traumatic wound, grazed dermatitis, vascular ulcer) and intertrigo of intertoe found in 161 (33.19%) patients. The use of bleaching products was detected in 97 (17.3%) patients, lymphedema in 130 (23.1%) patients, and varicose veins of the lower limb in 19 (3.4%) patients.

Concerning general factors involved with the onset of acute erysipelas of the leg, obesity was found in 230 (40.9%) patients, diabetes in 27 (4.8%) patients and HIV infection in 16 (2.8%) patients. The use of non steroid anti-inflammatory drugs (NSAID) and cataplasms before consultation were detected respectively in 207 and 104 patients (Table 1).

Infection of one leg was found in 535 patients, and especially the right leg in 335 patients; both right and left legs were infected in 27 cases. A lymph node was present in 336 patients, and fever ($> 37.8^{\circ}\text{C}$) in 424 patients.

Of the 562 recruited patients with erysipelas of the leg, 95 were associated with bullous lesions, and 167 were associated with purpuric lesions.

Complications were observed, mainly necrotizing fasciitis in 31 patients (6.1%) and abscesses in 63 patients (11.2%). They were due mainly to the delay of antibiotics treatment, and the use of non steroid anti-inflammatory drugs and cataplasms (Table 2).

DISCUSSION

In this study we described epidemiological and clinical characteristics of acute erysipelas of the leg in patients who consulted in hospitals in eight sub-Saharan Africa

Table 1: Prevalence of risk factors in patients with erysipelas of the leg

	Non complicated forms n=465	NF n=34	Abscess n=63	Total n=562
General factors				
Obesity (BMI ≥ 30 Kg/m ²)	202 (43,4)	5 (14,7)	23 (36,5)	230 (40,9)
Chronic ethylism	16 (3,4)	0 (0,0)	2 (3,2)	18 (3,2)
Diabetes	25 (5,4)	0 (0,0)	2 (3,2)	27 (4,8)
Sedentarity	65 (13,9)	8 (23,5)	12 (19,0)	85 (15,1)
Tabagism	18 (3,9)	4 (11,8)	7 (11,1)	29 (5,2)
HIV infection	15 (3,2)	0 (0,0)	1 (1,6)	16 (2,8)
Clinical factors				
Pitting edema	97 (20,9)	13 (38,2)	20 (31,7)	130 (23,1)
Varicous veins	16 (3,4)	1 (2,9)	2 (3,2)	19 (3,4)
Arteriopathy	3 (0,6)	1 (2,9)	1 (1,6)	5 (0,9)
Use of bleaching products	90 (19,4)	2 (5,9)	5 (7,9)	97 (17,3)
Point of entry	414 (89,0)	24 (70,6)	47 (74,6)	485 (86,3)
Phlebitis	2 (0,4)	0 (0,0)	0 (0,0)	2 (0,4)
Surgery of the leg	2 (0,4)	2 (5,9)	2 (3,2)	6 (1,1)
Aggravating factors				
Delay of antibiotic treatment 3-10 days	263 (56,6)	9 (26,5)	23 (36,5)	295 (52,5)
Delay of antibiotic treatment >10 days	44 (9,5)	21 (61,8)	28 (44,4)	93 (16,5)
The use of NSAID	154 (33,1)	18 (52,9)	35 (55,6)	207 (36,8)
The use of cataplasms	66 (14,2)	17 (50,0)	21 (33,3)	104 (18,5)

NF: Necrotizing fasciitis; BMI: Body mass index; NSAID: Non steroid anti inflammatory drugs; HIV: Human immunodeficiency virus

countries. The main risk factors associated with local complications of acute erysipelas of the leg were the delay of antibiotics treatment, the use of NSAID and the use of cataplasms before consultation.

The limitation of our study was mostly based upon the fact that this was not a comparative study; and also patients' long-term follow-up was not highlighted, so complications as recurrences and sequelae were not detected.

In our study the prevalence of acute erysipelas was 562 cases in a 12 months period, with a mean frequency of 6 cases per months and per dermatology service; this implies that erysipelas of the leg are common in sub-Saharan Africa. The high occurrence of erysipelas of the leg in women observed in this study has been also reported in previous studies [5-10]. The main risk factors were existence of a point of entry (86.3%), obesity (40.9%), lymphedema (23.1%) and the use of bleaching agents (17.3%).

In a previous sub-Saharan African case-control study, obesity, lymphedema, use of bleaching agents, neglected traumatic wound and intertrigo of intertoe were the identified risk factors [11]. Mahé et al had detected a point of entry in 100% of patients [10], that was also reported in two African monocentric studies by Cissé et al in Guinea Republic and Saka et al in

Table 2: Risk factors associated with complications of erysipelas of the leg

N=562	Local complications		OR	95% IC	p
	Yes	No			
Risk factors associated with necrotizing fasciitis					
Delay of antibiotic treatment					
<3 days (104)	3 (2,9)	101 (97,1)	1	[0,28–3,99]	<0,001
3-10 days (295)	9 (3,1)	286 (96,9)	1,06	[2,82–34,17]	
>10 days (93)	21 (22,6)	72 (77,4)	9,82		
The use of NSAID before consultation					0,045
Yes (207)	18 (8,7)	189 (91,3)	2,02	[1,01–4,05]	
No (355)	16 (4,5)	339 (95,5)	1		
The use of cataplasms before consultation					<0,001
Yes (104)	17 (16,3)	87 (83,7)	5,07	[2,49–10,32]	
No (458)	17 (3,7)	441 (96,3)	1		
Risk Factors associated with abscess complication of erysipelas of the leg					
Delay of antibiotic treatment					<0,001
<3 days (104)	8 (7,7)	96 (92,3)	1	[0,44–2,33]	
3-10 days (295)	23 (7,8)	272 (92,2)	1,01	[2,22–12,05]	
>10 days (93)	28 (30,1)	65 (69,9)	5,17		
The use of NSAID before consultation					0,001
Yes (207)	35 (16,9)	172 (83,1)	2,38	[1,40–4,04]	
No (355)	28 (7,9)	327 (92,1)	1		
The use of cataplasms before consultation					0,001
Yes (104)	21 (20,2)	83 (79,8)	2,51	[1,41–4,45]	
No (458)	42 (9,2)	416 (90,8)	1		

NSAID: Non steroid anti inflammatory drugs

Togo, respectively in 80% and 85,6% of patients [6,7]; these African authors also detected HIV infection in 18 % and 27 % of patients. In our multicentric study, HIV infection was associated with erysipelas of legs in 2.8 % of patients; this result reflects the prevalence of HIV infection in sub-Saharan Africa [12]. The use of bleaching products is a current practice in sub-Saharan Africa with prevalence of 25% to 60 % [13-15]. This factor was associated with erysipelas of the leg in 17.3% of patients in our study, while it was reported in Guinea republic and Togo respectively in 32 % and 10.6 % of patients [6,7]. This association may be explained by skin atrophy and fragility and a probable cutaneous immunosuppression due to the use of bleaching products by patients, then leads to erysipelas of the leg.

We reported abscess complication in 11.2% of patients. This is a common complication of erysipelas of the leg. A twenty years period metaanalysis found abscess and necrosis in 3% to 12 % of erysipelas of the leg [16]. Other studies conducted by Krasagakis et al [17], Picard et al [9], Mahé et al. [10] and Crickx et al. [18] have reported this complication respectively in 31.7%, 7.9 %, 9.9 % and 3.6% of patients, unlike in the Togo monocentric study where abscess complication was found only in 04% of patients. Abscess complication is the main factor of morbidity of erysipelas of the leg; it increases the time of hospitalization as well as the cost of healthcare.

We also found necrotizing fasciitis in 6.1% of cases, which was also reported in Guinea republic and Togo respectively in 4.5 % and 7.8 % of patients [6,7]. Nevertheless some necrotizing fasciitis are acute dermo hypodermatitis that are misdiagnosed for erysipelas of the leg at the early stage of this skin infection. Both infections may be distinguished from each other at their acute stage or by use of imaging tools such as Magnetic Resonance Imaging (MRI).

In our study the main factors associated with local complications were delay of antibiotics treatment, and the use of cataplasms and non steroid anti-inflammatory drugs before consultation. Many studies reported the delay of antibiotics treatment as a main risk factor associated with local complications and particularly with abscess complications [5,9,17,18]. Delay of antibiotics allows the bacteria to reach the deep layers of the skin, and then increases the risk of abscess complications. More than 52 % of patients were treated with NSAID before consultation. NSAID may worsen or mask the severity of erysipelas as reported

by many authors. Cissé et al. reported necrotizing complications mostly associated with NSAID [7] (OR=27; CI 95%: 8-94). However Pitché et al. and Crickx et al. did not mentioned the promoting or worsening effects of NSAID in patients [5,18]; these are not yet scientifically proven.

At last, the use of cataplasm was associated with local complications in patients in our study; meanwhile its etiopathogenic role is not proven. Cissé et al. in their study described necrotizing fasciitis in all their 11 patients who used cataplasm before consultation [6].

The role of NSAID and the use of cataplasm in the onset of complications deserve to be confirmed by others studies.

ACKNOWLEDGEMENTS

We would like to thank Mr Issifou Yaya, MPH Epidemiology/Clinical Research, Aix- Marseille University, for his help in statistical analysis.

Statement of Human and Animal Rights

All procedures followed were in accordance with the ethical standards of the responsible committee on human experimentation (institutional and national) and with the Helsinki Declaration of 1975, as revised in 2008.

Statement of Informed Consent

Informed consent was obtained from all patients for being included in the study.

REFERENCES

1. Bisno AL, Sevens DL. Streptococcal infections of skin and soft tissues. *N Engl J Med.* 1996;334:240-5.
2. Gabillot-Carré M, Roujeau JC. Acute bacterial skin infections and cellulitis. *Curr Opin Infect Dis.* 2007;20:118-23.
3. Dupuy A, Benchikhi H, Roujeau JC, Bernard P, Vaillant L, Chosidow O, et al. Risk factors for erysipelas of the leg (cellulitis): case-control study. *BMJ.* 1999;318:1591-4.
4. Mokni M, Dupuy A, Denguezli M, Dhaoui R, Bouassida S, Amri M, et al. Risk factors for erysipelas of the leg in Tunisia: a multicenter case-control study. *Dermatology.* 2006;212:108-12.
5. Pitché P, Tchangai-Walla K. Les érysipèles de jambe en milieu hospitalier à Lomé (Togo). *Bull Soc Pathol Exot.* 1997;90:189-91.
6. Cissé M, Keita A, Traoré A, Camara A, Machet L, Lorette G. Dermohypodermes bactériennes: étude monocentrique rétrospective de 244 cas observés en Guinée. *Ann Dermatol Vénéreol.* 2007;134:748-51.
7. Saka B, Kombate K, Mouhari-Toure A, Akakpo S, Boukari T, Pitché P, et al. Dermohypodermes bactériennes et fasciites

- nécrosantes: 104 observations au Togo. *Med Trop.* 2011;71:162-4.
8. Gathse A, Bengui O, Nstiba H. Etude rétrospective de 53 érysipèles hospitalisés au CHU de Brazzaville. *Bull Soc Pathol Exot.* 2006;99:3-4.
 9. Picard D, Klein A, Grigioni S, Joly P. Risk factors for abscess formation in patients with superficial cellulitis (erysipelas) of the leg. *Br J Dermatol.* 2013;168:859-63.
 10. Mahé E, Toussaint P, Lamarque D, Boutchnei S, Guiguen Y. Erysipelas in the young population of a military hospital. *Ann Dermatol Venereol.* 1999;126:593-9.
 11. Pitché P, Diatta B, Faye O, Diané BF, Sangaré A, Niamba P, et al. [Risk factors associated with leg erysipelas (cellulitis) in sub-Saharan Africa: A multicentre case-control study]. 2015;142:633-8.
 12. ONUSIDA: Rapport mondial: Rapport ONUSIDA sur l'épidémie mondiale de SIDA 2013. In Genève: ONUSIDA; 2013.
 13. Morand JJ, Ly F, Lightburn E, Mahé A. Complication of cosmetic skin bleaching in Africa. *Med Trop.* 2007;67:627-34.
 14. Mahé A, Blanc L, Halna JM, Keita S, Sanago T, Bobin P. An epidemiologic survey on the cosmetic use of bleaching agents by women of Bamako. *Ann Dermatol Venereol.* 1993;120:870-3.
 15. Pitche P, Kombate K, Tchangaï-Walla K. Cosmetic use of skin bleaching products and associated complications. *Int J Dermatol.* 2005;44:39-40.
 16. Crickx B. Erysipèle: évolution médicale sous traitement. Complications. *Ann Dermatol Venerol.* 2001;128:358-62.
 17. Krasagakis K, Samonis G, Valachis A, Maniatakis P, Evangelou G, Tosca A. Local complications of erysipelas: a study of associated risk factors. *Clin Exp Dermatol.* 2010;36:351-4.
 18. Crickx B, Chevron F, Sigal-Nahum M, Bilet S, Faucher F, Picard C, et al. Erysipelas: epidemiological, clinical and therapeutic data (111 cases). *Ann Dermatol Venereol.* 1991;118:11-6.

Copyright by Bayaki Saka, et al. This is an open access article distributed under the terms of the Creative Commons Attribution License, which permits unrestricted use, distribution, and reproduction in any medium, provided the original author and source are credited.

Source of Support: Nil, **Conflict of Interest:** None declared.

Intense pulsed light: A promising therapy in treatment of acne vulgaris

Manjunatha Puttaiah, Shishira R. Jartarkar

Department of Dermatology, Venereology and Leprosy, KVG Medical College and Hospital, Kurunjibhag, Sullia, India

Corresponding author: Dr. Shishira R. Jartarkar, E-mail: dr.shishira@gmail.com

ABSTRACT

Background: Medical treatment of acne vulgaris includes a variety of topical and oral medications. Poor compliance, lack of durable remission, potential side effects are common drawbacks to these treatment. Therefore, there is a growing demand for a fast, safe and side effect free novel therapy. Light-based therapies are an attractive alternative acne therapy because they potentially offer more rapid onset and better patient compliance with a low incidence of adverse events. **Aim:** To study the efficacy of intense pulsed light in treatment of acne vulgaris. **Materials and Methods:** Twenty five patients with acne vulgaris were subjected to IPL. Baseline grading of acne was done. IPL was administered every 2weeks for 4 sessions. Grading was done after the end of treatment. Clinical photographs were taken for evaluation. **Results:** All patients showed a reduction in the number of acne lesions after 4 sessions of IPL. No significant side effects were noted. Patients also noted an improvement in skin texture. **Conclusion:** IPL showed beneficial effects in the treatment of acne.

Key words: Improvement; Acne vulgaris; Novel therapy

INTRODUCTION

Acne vulgaris is an inflammatory disease of pilosebaceous unit, characterised by seborrhoea, comedones, papules, pustules, nodules and cysts, with occasional scarring [1].

Acne is one of the most prevalent skin disorder and single most common cause for visit to a dermatologist [1]. Acne, considered as a “Stigma of Adolescence”, causes significant psychological, social and emotional distress along with a self-perception of poor health [2,3].

The pathogenesis of acne is complex and multifactorial. The major factors in the pathogenesis of acne are increased sebum production, hypercornification of pilosebaceous duct, abnormality of the microbial flora, especially ductal colonization with *Propionibacterium acnes* and inflammation [4].

Current therapies available for acne are mainly targeted towards multiple factors contributing to

the pathogenesis of acne [5]. We are in an era where dermatologists seek to use novel treatment modalities like chemical peeling, laser and light therapies, photodynamic therapy, etc. to circumvent antibiotic resistance, reduce adverse effects seen more commonly with conventional treatment of acne like antibiotics and retinoids. Light-based therapies are an attractive alternative acne therapy because they potentially offer more rapid onset and better patient compliance with a low incidence of adverse events. However, optimal treatment methods and the relative efficacy of light-based therapies as compared to traditional therapies remain unclear. Light-based acne therapies are thought to act via reducing *P. acnes* proliferation or by targeting the sebaceous gland to reduce sebum production; however, other mechanisms may also exist [6]. The trials of IPL on acne vulgaris have been small and conflicting, till date. Hence, it is worthwhile to study the efficacy of IPL in acne vulgaris.

To study the efficacy of IPL in patients with acne vulgaris.

How to cite this article: Puttaiah M, Jartarkar SR. Intense pulsed light: A promising therapy in treatment of acne vulgaris. Our Dermatol Online. 2017;8(1):6-9.

Submission: 16.05.2016; **Acceptance:** 21.09.2016

DOI: 10.7241/ourd.20171.02

MATERIALS AND METHODS

The study was done over a period of one year from September 2014 to August 2015. The study design is a randomized open prospective study. The ethical committee clearance was obtained prior to the start of the study. Twenty five patients with mild to severe acne between the age group of 15 years and 40 years, who gave consent for the treatment were included in the study.

Age less than 15yrs and more than 40yrs, patients with extra-facial acne and acneiform eruptions, patients with keloidal tendency, patients on oral retinoids in the past 6 months, pregnant and lactating women, patients with associated systemic diseases and other facial dermatoses, patients with active herpes infection and patients who gave a history of taking treatment for acne in any form in the past one month were excluded from the study.

Baseline acne grading was done based on Global Acne Grading System [7] and acne classified as mild, moderate, severe and very severe (Tab. 1).

Note: Each type of lesion is given a value depending on severity. No lesions = 0, comedones = 1, papules = 2, pustules = 3 and nodules = 4. The score for each area (Local score) is calculated using the formula: Local score = Factor x Grade (0-4). The global score is the sum of local scores, and acne severity was graded using the global score. A score of 1-18 is considered mild; 19-30, moderate; 31-38, severe, and >39, very severe.

Informed consent was taken in all patients after ethical committee clearance from our institution for the study. Filter of 425nm was used. Test dose of IPL was given on forearm and maximum tolerable dose that the patient can tolerate was selected. According the skin type of the patients, fluence varied from 23-28J/cm² and RF energy from 23-27W, with higher energy in fairer skin types and lower energy in darker skin types. Two shots of IPL per site were administered to the acne affected area at the distance of 1-2mm with a gel interface between the skin and the probe to prevent any side effects like blistering and pigmentation. IPL was administered every two weekly for 4 sessions. Post procedure instructions were advised to the patient in the form of bland moisturizers and a sunscreen with sun protection factor of 30. The degree of the improvement (total percentage reduction in the total acne score calculated by Global Acne Grading System)

was noted after four sessions and photographs were taken.

0-25% reduction in score - mild improvement

26-50% reduction in score - moderate improvement

51-75% reduction in score - good improvement

>75% reduction in score - significant improvement.

OBSERVATIONS

In the present study, 15 (60%) were females and 10 (40%) were males. Of these, majority (80%) were students. In most of the patients 19 (76%), the duration of acne was between 1-4 years. The most common skin type noted was Fitzpatrick's skin type IV [8]. 48% of the patients had severe acne, followed by very severe acne in 36% and moderate acne in 16%.

RESULTS

In the present study, the mean age was 21.7 yrs, with minimum age of 16yrs and maximum age of 32 yrs. The mean score of acne improved from 37.96 to 10.9 i.e., mean improvement noted was 71.3%. The maximum improvement noted was 81.9% and the minimum improvement being 57.9% (Fig. 1). Using Wilcoxon test, the improvement in acne before and after the treatment was found to be significant ($p < 0.005$). All the patients with severe lesions, at the end of treatment had moderate lesions, patients with very severe acne, at the end of treatment had mild to moderate acne and patients with moderate acne had mild lesions. 64% of the patients had good improvement (Fig. 2) and 12% of the patients had significant improvement (Fig. 3). Moderate improvement was noted in 24% of the patients. In addition to clearance of acne, more than 70% patients also noted an improvement in skin texture, reduction in the oiliness of the skin and smoother appearance of the skin. No significant side effect was noted in most of the patients, though transient erythema and burning was noted in 40% of the patient, which spontaneously subsided over a period of few hours. One patient developed post inflammatory dyspigmentation (Fig. 4), who was treated with depigmenting creams and the dyspigmentation cleared in about a period of 1 to 2 months.

DISCUSSION

Intense pulsed light technology involves application of a non-coherent, non-laser broadband, filtered flash lamp source directed to the skin. Modifications of

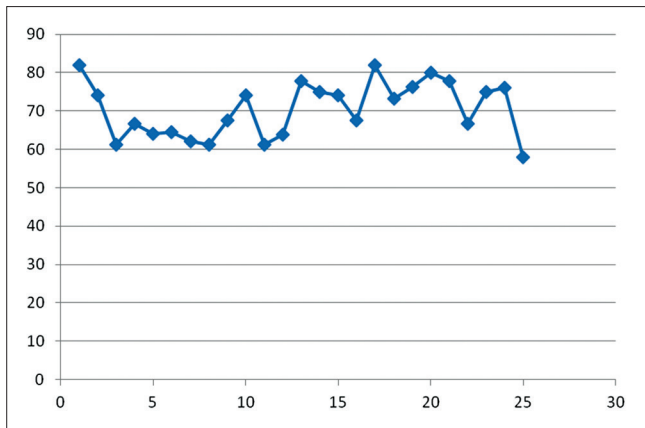


Figure 1: Graphical representation of percentage improvement of acne (in y axis) in each patient (x axis) following 4 sessions of IPL.

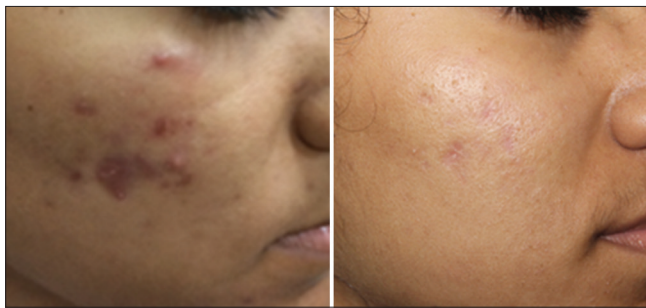

Figure 2: A 23 yr old male patient with moderate acne before and after 4 sittings of IPL with significant improvement.

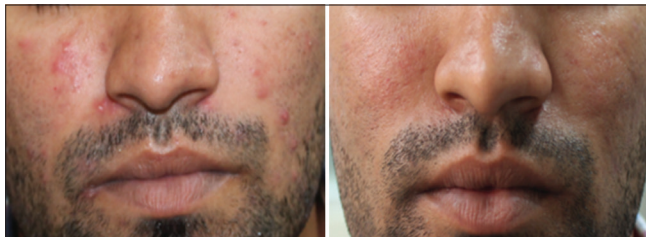

Figure 3: A 20 yr old female patient with moderate acne before and after 4 sittings of IPL with good improvement with improvement in the skin texture.

various parameters allow flexibility in treatment, which include wavelength, energy fluence, pulse duration and pulse delay. IPL acts by photodynamic therapy in treatment of acne vulgaris. P acnes produces porphyrins (protoporphyrin IX and coproporphyrin III) during their growth and proliferation in follicular units. These porphyrins have an absorption spectrum near ultraviolet and visible spectrum of light. The major absorption peak for these porphyrins is at 415nm, which is commonly known as the Soret band. A second peak corresponding to the red light is seen at 630nm. Therefore, devices that utilize either blue light or red light PDT have been developed for treatment of inflammatory acne vulgaris. After exposure to the

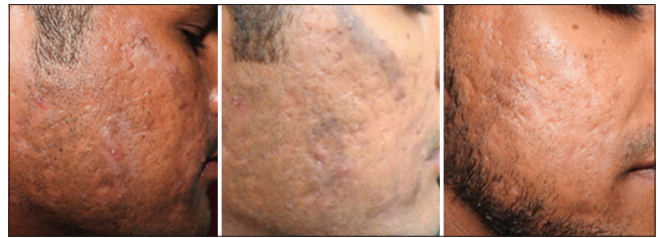

Figure 4: A 22 yr old male showing post-inflammatory dyspigmentation in first two photographs and third photograph (right most) shows reduction in the pigmentation after 2months, post use of depigmenting creams.

appropriate light source, there is photo-excitation of the porphyrins. This will cause production of singlet oxygen in the organism, causing selective destruction of the organism [9].

IPL releases yellow, green and red light that is emitted in sequence of short pulses. The yellow/green light damages the bacteria that live in the skin and cause acne, while red light will directly aim at the overactive sebaceous glands that causes outbreaks of pustules and nodules. This targeted heating, deep in the skin causes shrinkage of the inflamed sebaceous gland and helps prevent overproduction of excess sebum [10]. Hence, it is efficacious in nodulocystic acne also.

Elman et al. treated 19 patients with IPL and showed >50% improvement in acne lesions following twice weekly therapy for 4 weeks [11].

Paithankar et al. reported 50% reduction in acne vulgaris [12].

Dierickx reported 72% clearance rate in non-inflammatory acne and 73% improvement in inflammatory acne vulgaris lesions in 14 patients treated for five sessions two to four weeks apart [13].

Rojanamantin and Choawawanich demonstrated that IPL alone and following 5-aminolevulinic acid application can improve inflammatory facial acne [14].

We found a statistically significant decrease in the mean total score with a mean improvement of 71.3%. Our results were compatible with the results of Paithankar et al. but were different from Elman et al. This may have been due to difference in the skin type reaction to IPL therapy in Asians and Caucasians.

In the present study, we did not find any blister formation or scarring following treatment with IPL. Though, erythema and burning was noted in 40%, they

Table 1: Global acne grading system

Location	Multiplying factor
Forehead	2
Right cheek	2
Left cheek	2
Nose	1
Chin	1
Chest and upper back	3

were very trivial and tolerable and hence, all patients completed the study successfully. Also, the beneficial effect remained for atleast 3-4 months after the last IPL session.

CONCLUSION

Briefly, there are few previous studies demonstrating the efficacy of IPL as effective treatment modality in acne. While the previous studies excluded nodulocystic acne and have used IPL in combination with other treatment modalities, we included nodulocystic acne patients and treated successfully without encountering any significant side effects. However, further studies are necessary to define the correct role of IPL as a monotherapy in treatment of facial acne.

Statement of Human and Animal Rights

All procedures followed were in accordance with the ethical standards of the responsible committee on human experimentation (institutional and national) and with the Helsinki Declaration of 1975, as revised in 2008.

Statement of Informed Consent

Informed consent was obtained from all patients for being included in the study.

REFERENCES

- Garg VK, Sinha S, Sarkar R. Glycolic acid peels versus Salicylic-Mandelic acid peels in active acne vulgaris and post-acne scarring and hyperpigmentation. *Dermatol Surg*. 2009;35:59-65.
- Thomas DR. Psychosocial effects of acne. *J Cutan Med Surg*. 2004;8suppl4:3-5.
- Al Robaee AA. Assessment of general health and quality of life in patients with acne using a validated generic questionnaire. *Acta Dermatovenerol Alp Panonica Adriat*. 2009;18:157-64.
- Rai R, Natarajan K. Laser and light based treatments of acne. *Indian J of Dermatol Venereol Leprol*. 2013;79:300-8.
- Kim RH, Armstrong AW. Current state of acne treatment: Highlighting lasers, photodynamic therapy, and chemical peels. *Dermatol Online J*. 2011;17:2.
- Ludgate M, Orringer J. Inflammatory dermatoses: Acne. In: Raulin C, Karsai S, editors. *Laser and IPL technology in Dermatol and Aesthetic Medicine*. 2011;7:83-95.
- Doshi A, Zaheer A, Stiller MJ. A comparison of current acne grading system and proposal of a novel system. *Int J Dermatol*. 1997;36:416-8.
- Sachdeva S. Fitzpatrick skin typing: Applications in Dermatology. *Indian J Dermatol Venereol Leprol*. 2009;75:93-6.
- Kumaresan M, Srinivas CR. Efficacy of IPL in treatment of acne vulgaris: comparison of single and burst pulse mode in IPL. *Indian J of Dermatol*. 2010;55:370-2.
- Torres V, Torezan L. *Light based therapies for skin of color*. London: Springer; 2009;pp. 249-61.
- Elman M, Lask G. The role of pulsed light and heat energy in acne clearance. *J Cosmet Laser Ther*. 2004;6:91-5.
- Paithankar DY, Ross EV, Saleh BA, Blair MA, Graham BS. Acne treatment with a 1450nm wavelength laser and cryogen spray cooling. *Lasers Surg Med*. 2002;31:106-14.
- Dierick CC. Treatment of acne vulgaris with a variable filtration IPL system. *Lasers Surg Med*. 2004;34:66.
- Rojanamatin J, Choawawanich P. Treatment of inflammatory acne vulgaris with intense pulsed light and short contact of topical 5-aminolevulinic acid: a pilot study. *Dermatol Surg*. 2006;32:991-6.

Copyright by Manjunatha Puttaiah, et al. This is an open access article distributed under the terms of the Creative Commons Attribution License, which permits unrestricted use, distribution, and reproduction in any medium, provided the original author and source are credited.

Source of Support: Nil, **Conflict of Interest:** None declared.

Acne: prevalence, perceptions and beliefs among pupils and students in Ouagadougou, Burkina Faso

Amina Nomtondo Ouedraogo^{1,2}, Sandrine Soutongo Sita Kabre Ouedraogo³,
Muriel Sidnoma Ouedraogo^{2,3}, Fagnima Traore⁴, Patrice Gilbert Tapsoba^{2,3},
Fatou Barro-Traore², Adama Traore^{2,3}, Pascal Niamba^{2,3}

¹Department of Dermatology, Raoul Follereau Dermatology Center, Ouagadougou, Burkina Faso, ²University Ouaga I Professor Joseph Ki-Zerbo, Ouagadougou, Burkina Faso, ³Department of Dermatology, University Hospital Yalgado Ouédraogo, Ouagadougou, Burkina Faso, ⁴Department of Dermatology, Regional Hospital of Ouahigouya, Ouahigouya, Burkina Faso

Corresponding author: Dr. Amina Nomtondo Ouedraogo, E-mail: Nomtondo2000@yahoo.fr

ABSTRACT

Introduction: Acne, is a common disease. Its prevalence is 80% among adolescents in the world and 57,1% in Ouagadougou in 2001 among school pupils. The medical literature is provided on the epidemiological, clinical and therapeutic aspects of acne, and less on perceptions and knowledge of acne patients of their disease. The objective of this study was to evaluate the prevalence, knowledge, beliefs on acne, among pupils and students in Ouagadougou. **Patients and Methods:** We conducted a cross-sectional study from June to July 2014 in the University of Ouagadougou and in 4 secondary schools in Ouagadougou. **Results:** We surveyed 425 personnes including 40.6% of girls and 59.4% boys. The prevalence of acne was 54.8%. The mean age was 19.53 years, with extremes ranging from 13 to 30 years. Among the etiologies, food was cited by 40.05%, 25.43% puberty, cosmetics 14.03% 3.21% hormones, stress 2.33%, 0.87% seborrhea. Among the foods concerned, peanuts were cited by 37.96%, 21.22% mayonnaise, butter, 21.52%, 8.07% sweets and chocolate 9,41%. oil was incriminated by 72.6% and sugar 5.5%. Among the contributing factors, 19.70% cited tobacco, 19% no sexual relationship. Among the 192 non acne patients, 17% link acne to poor hygiene, 80% would be embarrassed to have a partner acne, 74.40% of non-acne believed that acne altered self-image. For treating acne 26.11% think that acne is incurable. Cosmetic can care acné according to 37,90% and 6,30% believed that natural products are sufficient. Only 15.02% have resorted to a dermatologist. **Conclusion:** Pupils and students have bad knowledge on acne and bad perception on those who have the disease.

Key words: Diet; Acne etiology; Knowledge

How to cite this article: Ouedraogo AN, Kabre Ouedraogo SSS, Ouedraogo MS, Traore F, Tapsoba PG, Barro-Traore F, Traore A, Niamba P. Acne: prevalence, perceptions and beliefs among pupils and students in Ouagadougou, Burkina Faso. Our Dermatol Online. 2017;8(1):10-16.

Submission: 13.10.2016; **Acceptance:** 21.11.2016

DOI: 10.7241/ourd.20171.03

Acné: prévalence, perceptions et croyances chez les élèves et étudiants à Ouagadougou, Burkina Faso

Amina Nomtondo Ouedraogo^{1,2}, Sandrine Soutongo Sita Kabre Ouedraogo³, Muriel Sidnoma Ouedraogo^{2,3}, Fagnima Traore⁴, Patrice Gilbert Tapsoba^{2,3}, Fatou Barro-Traore², Adama Traore^{2,3}, Pascal Niamba^{2,3}

¹Department of Dermatology, Raoul Follereau Center, Ouagadougou, Burkina Faso, ²University Ouaga I Professor Joseph Ki-Zerbo, Ouagadougou, Burkina Faso, ³Department of Dermatology, University Hospital Yalgado Ouédraogo, Ouagadougou, Burkina Faso, ⁴Department of Dermatology, Regional Hospital of Ouahigouya, Ouahigouya, Burkina Faso

Corresponding author: Dr. Amina Nomtondo Ouedraogo, E-mail: Nomtondo2000@yahoo.fr

RÉSUMÉ

Introduction: L'acné est une maladie fréquente. Sa prévalence atteint 80% chez les adolescents dans le monde. A Ouagadougou, elle était de 57,1% en 2001 en milieu scolaire. La littérature médicale est très fournie sur les aspects épidémiologiques, cliniques et thérapeutiques de l'acné, et l'est moins sur les perceptions et connaissances des patients souffrant d'acné. L'objectif de cette étude était d'évaluer la prévalence, les connaissances, les croyances, des élèves et étudiants de la ville de Ouagadougou sur l'acné. **Méthodes et Patients:** Nous avons réalisé une étude transversale de juin à juillet 2014 chez les étudiants de l'université de Ouagadougou et les élèves de 4 établissements secondaires. **Résultats:** Nous avons enquêté 425 personnes dont 40,6% de filles et 59,4% de garçons. La prévalence de l'acné était de 54,8%. L'âge moyen était 19,53 ans, avec des extrêmes allant de 13ans et 30ans. Parmi les étiologies de l'acné, l'alimentation était citée par 40,05% des enquêtés, la puberté par 25,43%, les cosmétiques par 14,03%. Parmi les aliments en cause, les arachides ont été cités par 37,96%, la mayonnaise par 21,22%, le beurre par 21,52%, les sucreries par 8,07% et le chocolat par 9,41%. L'huile était incriminée par 72,6% et le sucre 5,5%. Le tabac était cité par 19,70% comme facteur favorisant, l'absence de rapport sexuels par 19%. Parmi les 192 sujets non acnéiques, 17% liaient l'acné à un manque d'hygiène, 80% seraient gênés d'avoir un partenaire acnéique, Les cosmétiques soigneraient l'acné pour 37,90% et les produits naturels pour 6,30%. Ceux qui ont eu recours à un dermatologue étaient 15,02%. **Conclusion:** Les élèves et étudiants connaissent mal l'acné et perçoivent mal leurs camarades acnéiques.

Mots Clés: Alimentation; Étiologie acné; Connaissance

INTRODUCTION

L'acné est une pathologie inflammatoire du follicule pilo-sébacé fréquente, dont la prévalence atteint 80% chez les adolescents dans le monde et 40% chez les adultes [1-3]. Sa prévalence en milieu scolaire à Ouagadougou était de 57,1% en 2001 [4]. La littérature médicale est très fournie sur les aspects épidémiologiques, cliniques et thérapeutiques de l'acné [1,2,5-7], mais il en existe moins sur les

perceptions, la connaissance et la compréhension des patients de leur maladie.

Au Burkina Faso, aucune étude n'est encore disponible sur ce sujet. Avoir de telles données pourrait être utile à l'amélioration de la relation médecin-malade dans la prise en charge de l'acné, à l'élaboration d'outils, de programmes d'information de communication et de sensibilisation adaptés aux besoins spécifiques des jeunes. L'objectif de cette étude est d'évaluer

How to cite this article: Ouedraogo AN, Kabre Ouedraogo SSS, Ouedraogo MS, Traore F, Tapsoba PG, Barro-Traore F, Traore A, Niamba P. Acné: prévalence, perceptions et croyances chez les élèves et étudiants à Ouagadougou, Burkina Faso. *Our Dermatol Online*. 2017;8(1):10-16.

Submission: 13.10.2016; **Acceptance:** 21.11.2016

DOI: 10.7241/ourd.20171.03

la prévalence, les connaissances, les croyances, et perception des élèves et étudiants de la ville de Ouagadougou sur l'acné.

MATERIALS AND METHODS

Type d'étude, Lieu et Période

Notre étude était de type transversale descriptive. Elle s'est déroulée dans deux Unités de Formation et de Recherche (UFR) (UFR Sciences Juridiques et Politiques, et UFR Sciences Economiques et de Gestion) de l'université de Ouagadougou (devenue université Ouaga I Professeur Joseph Ki-Zerbo) et dans quatre centres d'examen du Baccalauréat (BAC) et du Brevet d'Etude du Premier Cycle (BEPC) des établissements secondaires de la ville de Ouagadougou (Lycée Philippe Zinda Kaboré, Lycée Nelson Mandela, Lycée Marien Nguoubi, Collège notre Dame de Kologh Naba) de juin à juillet 2014.

Echantillonnage

La population d'étude était choisie de manière raisonnée compte tenu de nos ressources humaines, et financières limitées. Nous avons retenus les étudiants de l'université et les élèves candidats aux examens du BEPC et du BAC de la ville de Ouagadougou au cours de l'année scolaire 2013-2014 comme population d'étude. La taille minimale N de l'échantillon a été calculée suivant la formule suivante: $N = [E^2.P.Q]/i^2$
 N = taille minimale de l'échantillon
 E = écart réduit pour le risque $\alpha = 5\%$ (loi normale); une précision de 6% avec un risque d'erreur $\alpha = 5\%$. Sa valeur était de 1,96
 $P = 57,1\%$ (prévalence acné milieu scolaire en 2001) [4];
 $Q = 1 - P = i$ = précision désirée; soit $i = 5\%$.
 N ajusté à 10% était 425.

Les étudiants de l'université de Ouagadougou étaient au nombre de 22.808 au cours de l'année 2013-2014. Pour le choix de l'échantillon d'étudiants, le premier degré du sondage a consisté à un tirage aléatoire de deux UFR parmi les 6 que compte l'université. Le deuxième niveau au tirage aléatoire de 57 étudiants dans chacune des 2 UFR sélectionnée soit 114 étudiants au total.

Pour le choix du nombre d'élèves, nous avons fait un choix proportionnel au nombre de candidats par niveau d'examen. La ville de Ouagadougou comptait pour l'année scolaire 2013-2014, 61668 élèves, candidats aux examens du BAC et du BEPC, dont 41005 candidats à

l'examen du BEPC et 20 663 candidats pour le BAC. Nous avons retenu donc 208 candidats du BEPC et 103 candidats du BAC proportionnellement à la taille de la population d'étude. Pour le choix des jurys et des élèves, la technique de sondage en grappe a été utilisée. Le premier degré du sondage a consisté au tirage aléatoire de deux centres d'examen du BEPC, puis le second niveau du sondage au tirage de 208 élèves dans ces centres. Nous avons procédé de même, pour le tirage de 103 élèves candidats au BAC.

Les élèves et étudiants ont été enrôlés dans l'étude au fur et à mesure qu'ils étaient rencontrés dans la cour de l'établissement jusqu'à l'atteinte du nombre voulu. Ils ont été interrogés dans un local aménagé à cet effet.

Critères D'inclusion

Ont été inclus les étudiants des UFR retenues et les élèves candidats aux examens du BEPC ou du BAC, des centres d'examens retenus ayant donné leur consentement à participer à l'étude.

Méthode et Recueil des données

Le recueil des données était fait par un questionnaire comprenant les éléments sociodémographiques. Des questions ouvertes, semiouvertes ont été utilisées pour tester les connaissances et croyances et pratiques des élèves et étudiants.

Analyse Statistique

Le test de Student était utilisé pour la comparaison des moyennes et le Khi-deux pour l'indépendance et les liaisons entre les données statistiques. Une valeur seuil $p < 5\%$ était retenu comme significatif.

Ethics Statement

Cette étude a obtenu un avis favorable du ministère des enseignements secondaire supérieur et de la recherche scientifique. Les entretiens ont été menés en respectant la dignité des élèves, l'anonymat était assuré dans le traitement des données.

RESULTS

Nous avons enquêtés 425 personnes dont 40,6% de filles et les garçons 59,4%. La prévalence globale de l'acné était de 54,8%. Chez les sujets de sexe féminin, elle était de 55,90% et 53,10% chez ceux de sexe masculin.

L'âge moyen était 19,53 ans avec des extrêmes allant de 13 ans et 30 ans

A la question ouverte de savoir quelles étaient les étiologies de l'acné ? L'alimentation, la puberté, les cosmétiques venaient en tête des réponses, 40,05%, 25,43% et 14,03% respectivement. Les hormones, le stress, la séborrhée ont été cités respectivement par 3,21%, 2,33% et 0,87%. The Figure 1 nous donne l'exhaustivité des réponses.

A la question de savoir lequel des aliments cités (arachide, chocolat, sucrerie, mayonnaise, beurre, autre) pouvaient favoriser l'acné, les arachides ont été cités par 37,96%, la mayonnaise et le beurre respectivement 21,22%, 21,52%, les sucreries et le chocolat 8,07% et 9,41% et autre 1,79%.

Parmi les 274 enquêtés ayant incriminés les aliments dans la survenue de l'acné, 72,6% (199) des personnes pensaient que l'huile contenue dans les aliments était responsable de la survenue de l'acné et 5,5% (15) pensaient que c'était plutôt le sucre contenu dans l'aliment qui en était responsable. L'allergie à ces aliments déclencherait l'acné pour 12% (33), et 9,9% (27) évoquaient leur expérience vécue.

A la question de savoir si les éléments cités (tabac, stress, menstrues, absence de rapport sexuel, autre) étaient des facteurs favorisant l'acné, 40,90% ont cités les menstrues, 30,80% le stress, 19,70% le tabac, 19% l'absence de rapport sexuels et 2,4% ont répondu autres. La comparaison entre les réponses des élèves et celles des étudiants pour les causes de l'acné, n'a pas noté de différence significative.

Parmi les 192 sujets non acnéiques interrogés, 17% pensaient que l'acné était lié à un manque d'hygiène, 40% pensaient qu'il s'agissait d'une maladie, 37% d'un phénomène physiologique normal et 6% ont donné diverse autre réponse. Parmi les sujets non acnéiques, 80% seraient gênés d'avoir un partenaire souffrant d'acné (dont 24% beaucoup gênés), 20% ne seraient pas du tout gênés, 74,40% pensaient que l'acné altérerait l'image de soi et 25,6% ne le pensaient pas.

26,11% (111/425) pensaient que l'acné était incurable 1,41% (6/425) n'avaient aucune idée sur les possibilités de traitement de l'acné, 55,70% (141/425) pensaient que l'acné pouvait être soignée par les produits pharmaceutiques dont ceux contenant du peroxyde de benzoyle, des rétinoïdes topiques et antibiotiques

topiques. Les cosmétiques (savon, crème et lotion) ont été cités par 37,90% (96/425) comme suffisant pour soigner l'acné. Les produits naturels tel le miel, le citron, l'aloë vera, l'huile de neem par 6,30 % (16/425). Parmi les sujets souffrants d'acné, 15,02% (35/233) avaient eu recours à un dermatologue pour traiter leur acné.

DISCUSSION

L'acné est une maladie fréquente, si certains auteurs rapportent des prévalences de 80 à 90% [1,3], notre étude trouve 54,8% chez les élèves et étudiants de la ville de Ouagadougou. La prévalence est plus importante chez les filles 55,90% que chez les garçons 53,10%. Cette tendance est généralement retrouvée dans la littérature. Uslu en Turquie [8] dans son étude intitulée, Acné: prévalence, perceptions et effets sur la santé psychologique chez les adolescents à Aydin avait rapporté une prévalence de 63,6%, 53,8% chez les filles et 46,2% chez les garçons. L'âge moyen des enquêtés de Uslu était de 15,24 ans tandis que nous trouvons 19,53 ans. Cette différence s'explique par le site de recrutement de notre série en milieu universitaire et le second cycle du lycée.

L'acné est une maladie multifactorielle. Parmi les éléments en cause, l'augmentation de la production de sébum, l'hyperkératinisation infundibulaire, la prolifération de *Propionibacterium acnes* et les facteurs de l'inflammation sont admis dans sa physiopathogénie [9,10]. D'une manière générale, les élèves et étudiants ne connaissent pas les causes de l'acné. La majorité des enquêtés ont plutôt cités l'alimentation (40,05%) et la puberté (25,43%) comme principales étiologies de l'acné. Dans le contexte africain en générale et burkinabé en particulier, les boutons d'acné sont très couramment appelés « boutons d'adolescence » [11], 37% des sujets non acnéiques pensaient que l'acné est un phénomène physiologique normal. Ceci pourrait également expliquer le lien fait entre la puberté et l'acné par nos répondants. Ce qui semble justifier car l'acné débute généralement à la puberté avec l'afflux d'hormones notamment la testostérone [12].

L'hyperséborrhée, le stress, les hormones bien documentés dans la physiopathologie de l'acné [12] ne sont cités que par une petite minorité de nos enquêtés, respectivement 0,87%, 2,33%, et 3,21%. Pourtant l'implication du stress dans la survenue de l'acné a

été prouvée [9]. Des cellules nerveuses situées près de la glande sébacée peuvent produire une substance, dite substance P, libérée sous l'effet du stress qui peut stimuler la production de sébum [9]. Tan et al. [13] ont rapporté que 71% de leurs patients considéraient le stress comme un facteur important dans la survenue de l'acné. Une explication possible est la sécrétion d'androgène surrénale pendant les périodes de stress et les effets subséquents sur l'hyperactivité sébacée.

Les produits cosmétiques cités par 14,03% de nos répondants et les produits dépigmentants par 2,92% sont également incriminés dans la survenue de l'acné. Ces réponses ont probablement été motivées par le vécu et l'expérience personnelle des enquêtés ou de leur entourage. En effet, le phénomène de la dépigmentation prend de l'ampleur en Afrique de l'Ouest et particulièrement au Burkina. Traoré et al [14] trouvaient déjà en 2005, 44,3% de femmes qui pratiquaient régulièrement la dépigmentation artificielle à Ouagadougou. Les élèves et étudiants représentaient 32,5% des sujets interrogés. L'acné était comptée parmi les complications dermatologiques retrouvées chez 58% de l'échantillon.

Nos répondants ont incriminé l'alimentation dans la survenue de l'acné à 40,05%, notamment les aliments à index lipidique élevé tel l'arachide (37,96%), le beurre (21,52%), la mayonnaise (21,22%). Ces aliments ont été cités sur la base d'observation faite sur le vécu, comme l'indiquait cette phrase citée par une élève « Chaque fois que je mange de l'arachide ou du beurre, le lendemain, j'ai des boutons sur le visage ». Les sucreries et le chocolat ont été moins cités, cela serait en rapport avec les habitudes alimentaires du citoyen burkinabé « lambda » incluant peu le chocolat. Nos résultats se rapprochent des constatations de Peiqi Su à Singapour [15] dans une étude sur les croyances, perceptions et impact psychosocial de l'acné parmi les étudiants d'un institut tertiaire. Il a rapporté que l'alimentation était vue par 38,7% comme un facteur aggravant de l'acné notamment les aliments épicés et les fritures. Quant à Fekih, Di Landro, Burris, ils ont souligné l'implication des aliments à index glycémique élevé dans les poussées acnéiques [16-18]. Ces aliments accroissent la production d'insuline qui contribuait à la formation d'hormones androgéniques favorisant la production de sébum donc l'apparition de l'acné. Pourtant, Smith [19] a rapporté que la consommation hebdomadaire de gâteaux, de bonbons et de chocolat n'a pas été associée à un risque plus élevé de l'acné. Le

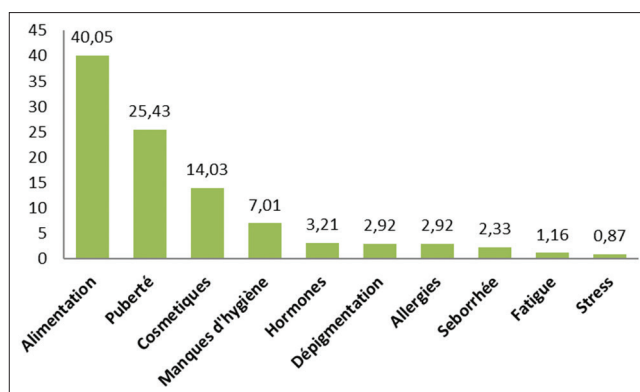


Figure 1: Répartition des étiologies en pourcentage.

rôle de l'alimentation dans l'acné reste donc d'actualité et controversé et des recherches plus poussées sur le sujet doivent se poursuivre.

Le tabac cité par 19,70% de nos enquêtés serait un facteur favorisant la survenue de l'acné. Cependant, certaines études réfutent l'implication du tabac dans la survenue de l'acné et d'autres l'acceptent. En effet, Peiqi Su [15], a rapporté que 18,9 % des sujets croient que l'acné a un lien avec la consommation de tabac. Capitanio [20] a positivement corrélée l'acné au tabagisme par le nombre de cigarettes quotidiennement fumées et la prévalence de l'acné d'apparition tardive. T. Chuh et col [21], dans une étude réalisée à Hong Kong et en Inde, l'association du tabagisme à l'acné chez les hommes a rapporté une augmentation de la sévérité de l'acné significativement associée à une augmentation du stress. Plus, les gens étaient stressés plus ils fumaient, le stress pourrait donc constitué un facteur de confusion dans l'association acné et tabagisme.

La comparaison entre les réponses des élèves et celles des étudiants sur les causes de l'acné n'a pas noté de différence significative. Ce qui nous laisse penser que le niveau d'étude n'influe pas sur le niveau de connaissance sur l'acné des élèves et étudiants et que les perceptions populaires et culturelles de la maladie prédominent. Cependant, il faut préciser que l'échantillon a regroupé des étudiants des facultés de sciences politiques et juridiques, ainsi que des sciences économiques et de gestion. Les réponses auraient probablement varié si l'échantillon avait prit en compte des étudiants en médecine ou pharmacie.

Parmi les 45,2% de sujets ne souffrant pas d'acné, 17% reliaient l'acné à un manque d'hygiène, percevant ainsi à tort leur camarade acnéique comme une

personne sale et 19% à une absence de relation sexuelle. Aussi, nous pouvons comprendre pourquoi 80% des non acnéiques déclaraient être gênés si leur partenaire avait de l'acné; et 74,4% d'entre eux étaient convaincus que l'acné diminuait la beauté. Ceci pourrait accroître le mal-être du sujet acnéique dans son milieu, favoriser son isolement social ou l'entraîner à avoir des comportements sexuels à risque dans le but de faire disparaître les lésions d'acné. Carol E cheng et al au Etats Unis [22], dans leur étude sur la gravité de l'acné, le traitement et modèles de croyance à travers les groupes raciaux et ethniques multiples des élèves adolescents ont aussi noté que 77% trouvent que l'acné rend les personnes atteintes moins attrayantes. Cette fausse idée associant l'acné à un manque d'hygiène était également rapportée par des auteurs asiatiques. Peiqi Su [15] notait que 65% des répondants liaient l'acné à une mauvaise hygiène personnelle. Suh a révélé que 48,4% de sujets ont estimé que leur acné s'empirait s'ils ne se lavaient pas le visage à fond tandis que 10% estiment que leur acné s'améliorait s'ils ne se lavaient pas le visage. Tan a également rapporté que 62% de son échantillon considéraient la saleté comme un facteur favorisant important de l'acné [23].

Face à leur acné, 15,02% seulement des sujets acnéiques ont recours à l'expertise d'un dermatologue pour se soigner, le reste préférant se soigner par d'autres moyens en ayant recours à des cosmétiques dans 37,90% ou des produits naturels tel le citron le miel, l'aloë vera dans 6,30%. D'ailleurs 26,11% des sujets souffrant d'acné la croient incurable. Ce qui est justifié par le contexte culturelle et économique. Le traitement classique d'une acné légère à modérée est suspensif, et nous avons noté une difficulté de la population illettrée (majorité de la population burkinabé) à comprendre la notion de maladie inflammatoire chronique. L'un des traitements susceptibles de donner des résultats définitifs en interrompant les poussées, en l'occurrence l'isotrétinoïne est hors de portée pour la majorité des patients burkinabés moyens ne disposant pas d'assurance maladie. Néanmoins 55% ont pu citer les produits pharmaceutiques adaptés (peroxyde de Benzoyl, rétinol topique, antibiotique topique) au traitement topique de l'acné. Uslu [8] notait une perception différente chez les adolescents de son étude. Moins de la moitié considéraient l'acné comme une «maladie», et la plupart d'entre eux pensaient qu'elle est curable et que son traitement était une nécessité.

CONCLUSION

Malgré la prévalence élevée de l'acné chez les jeunes scolarisés de la ville de Ouagadougou, il y a un déficit de connaissance sur les causes, les facteurs favorisants, le traitement de la maladie. Peu consultent les spécialistes pour se faire prendre en charge. Envisager un programme d'information, d'éducation et de sensibilisation (IEC) à l'endroit des élèves et étudiants pourrait leur donner une meilleure connaissance et compréhension de l'acné, leur permettre de recourir aux soins des professionnels de la santé et influencer positivement leurs comportements face à leur acné ou celle de leur camarade.

REFERENCES

1. Dréno B. Données récentes sur l'épidémiologie de l'acné. *Annal Dermatol Vénérool.* 2010;137:S49-S51.
2. Schäfer T, Nienhaus A, Vieluf D, Berger J, Ring J. Epidemiology of acne in the general population: the risk of smoking. *Br J Dermatol.* 2001;145:100-4.
3. Dreno B, Poli F. Epidemiology of acne. *Dermatology.* 2003;206:7-10.
4. Traore A, Ouedraogo MS, Niamba P, Barro-Traoré F, Drabo YJ. Aspects épidémiologiques et cliniques de l'acné en milieu scolaire de la ville de Ouagadougou (Burkina Faso). *Annal Dermatol Vénérool.* 2001;134:165.
5. Seité S, Rougier A, Dréno B. Enquête sur la prise en charge des patients acnéiques en France. *Annal Dermatol Vénérool.* 2012;139:611-6.
6. Rzany B, Kahl C. Epidemiology of acne vulgaris. *J Dtsch Dermatol Ges.* 2006;4:8-9.
7. Dreno B, Bodokh I, Chivot M, Daniel F, Humbert P, Poli F, et al. ECLA grading: a system of acne classification for every day dermatological practice. *Annal Dermatol Vénérologie.* 1999;126:136-41.
8. Uslu G, Şendur N, Uslu M, Savk E, Karaman G, Eskin M. Acne: prevalence, perceptions and effects on psychological health among adolescents in Aydin, Turkey. *J Eur Acad Dermatol Vénérool.* 2008;22:462-9.
9. Vexiau P, Chivot M. [Feminine acne: dermatologic disease or endocrine disease?]. *Gynecol Obstet Fertil.* 2002;30:11-21.
10. Drapier-Faure E, Faure M. Quelle est la place des traitements hormonaux dans l'acné? *Ann Dermatol Vénérool.* 2001;128:S19-24.
11. Kouotou EA, Adegbi H, Belembe RB, Sieleunou I, Nansseu JR, Kanga JP, et al. [Acne in Cameroon: Quality of life and psychiatric comorbidities]. *Annal Dermatol Vénérool.* 2016;143:601-6.
12. Dreno B. Acné. *EMC - Dermatol-Cosmetol.* 2002;98:11.
13. Tan JK, Vasey K, Fung KY. Beliefs and perceptions of patients with acne. *J Am Acad Dermatol.* 2001;44:439-45.
14. Traore A, Kadeba J-C, Niamba P, Barro F, Ouedraogo L. Use of cutaneous depigmenting products by women in two towns in Burkina Faso: epidemiologic data, motivations, products and side effects. *Int J Dermatol.* 2005;44:30-2.
15. Su P, Chen Wee Aw D, Lee SH, Han Sim Toh MP. *J Dtsch Dermatol Ges.* 2015;13:227-33.
16. Fekih N, Aounallah-Skhiri H, Hajlaoui K, Kamoun R. Évaluation du rôle de l'alimentation dans la survenue de l'acné de l'adolescent. *Annal Dermatol Vénérool.* 2011;12:A165.
17. Di Landro A, Cazzaniga S, Parazzini F, Ingordo V, Cusano F, Atzori L, et al. Family history, body mass index, selected dietary

- factors, menstrual history, and risk of moderate to severe acne in adolescents and young adults. *J Am Acad Dermatol.* 2012;67:1129-35.
18. Burris J, Rietkerk W, Woolf K. Acne: the role of medical nutrition therapy. *J Acad Nutr Diet.* 2013;113:416-30.
 19. Smith RN, Mann NJ, Braue A, Mäkeläinen H, Varigos GA. A low-glycemic-load diet improves symptoms in acne vulgaris patients: a randomized controlled trial. *Am J Clin Nutr.* 2007;86:107-15.
 20. Capitanio B, Sinagra JL, Ottaviani M, Bordignon V, Amantea A, Picardo M. Acne and smoking. *Dermatoendocrinol.* 2009;1:129-35.
 21. Chuh AAT, Zawar V, Wong WCW, Lee A. The association of smoking and acne in men in Hong Kong and in India: a retrospective case-control study in primary care settings. *Clin Exp Dermatol.* 2004;29:597-9.
 22. Cheng CE, Irwin B, Mauriello D, Liang L, Pappert A, Kimball AB. Self-Reported Acne Severity, Treatment, and Belief Patterns across Multiple Racial and Ethnic Groups in Adolescent Students. *Pediatr Dermatol.* 2010;27:446-52.
 23. Tan JK. Psychosocial impact of acne vulgaris: evaluating the evidence. *Skin Ther Lett.* 2004;9:1-3.

Copyright by Amina Nomtongo Ouedraogo, et al. This is an open-access article distributed under the terms of the Creative Commons Attribution License, which permits unrestricted use, distribution, and reproduction in any medium, provided the original author and source are credited.
Source of Support: Nil, **Conflict of Interest:** None declared.

Efficacy and tolerance of 2,3-diphenylcyclopropenone in propylene glycol versus 2,3-diphenylcyclopropenone in isopropanol - a novel formula designed for the treatment of alopecia areata

Tomasz Wasylyszyn¹, Katarzyna Borowska²

¹Department of Dermatology, Military Institute of Medicine in Warsaw, Warsaw, Poland, ²Department of Histology and Embryology with Experimental Cytology Unit, Medical University of Lublin, Lublin, Poland

Corresponding author: Prof. Katarzyna Borowska, MD, PhD., E-mail: k_borowska@wp.pl

ABSTRACT

Introduction: Topical immunotherapy of alopecia areata (AA) with contact allergens including 2,3-diphenylcyclopropenone (DCP) have been used for few decades. **Aim:** The study introduces a new preparation of DCP in isopropanol for the purpose of the treatment of AA. The aim of the study was to compare new formula with the previously used DCP in propylene glycol. Two groups of twenty patients each, treated with new and old formula respectively were observed for one year. Treatment efficacy and tolerance was then measured and compared. **Result:** All but one patient responded to the study with partial or complete hair regrowth. Results show improvement after the treatment in both groups with 75% and 85% of patients with cosmetically acceptable hair amount (grades 1 and 2 in the hair loss scale) in DCP in isopropanole and DCP in propylene glycol groups respectively. Complete hair regrowth was obtained in 35% and 25% of patients respectively. Differences in treatment's efficacy between groups were not statistically important ($p = 0.95$). Tolerance was generally good but significantly better ($p = 0.17$) in a group treated with DCP in isopropanol. **Discussion:** DCP solutions in isopropanol may have potential in the treatment of alopecia areata. Treatment efficacy in both groups (DCP in propylene glycol and DCP in isopropanol) was comparable. Tolerance of the DCP in isopropanol was significantly better than DCP in propylene glycol. Despite better tolerance of DCP in isopropanol during the proper treatment, the sensitization with 3% DCP should be done with the solution in propylene glycol.

Key words: Alopecia areata; 2,3-diphenylcyclopropenone; DCP, Isopropanol; Propylene glycol

INTRODUCTION

Topical immunotherapy of alopecia areata (AA) with contact allergens including 2,3-diphenylcyclopropenone (DCP) have been used for few decades [1-4]. Numerous authors report different data regarding this treatment efficacy; however, it ranges between 20 – 70% of patients with cosmetically acceptable hair regrowth [5,6]. The treatment itself is still in an experimental stage as there is no DCP being available as a brand medication so far. The main reasons for that, besides the preparations being relatively unstable and thus improper for pharmaceutical trade, are the

adverse allergic reactions that eventually may lead to the complications [7]. In authors' experience these reactions do not provoke serious adverse effects if the procedure is managed properly, especially when areas near eyes, ears and neck are avoided during the treatment [5,8,9]. Nevertheless, all the patients report mild to moderate discomfort related to DCP treatment. It includes: itching, erythema, redness and swelling of occipital lymph nodes. Recently authors have analyzed the stability of DCP solutions in various solvents and how addition of water to these solutions have affected their stability [10,11]. Results led to the conclusion that beside propylene glycol, an isopropyl

How to cite this article: Wasylyszyn T, Borowska K. Efficacy and tolerance of 2,3-diphenylcyclopropenone in propylene glycol versus 2,3-diphenylcyclopropenone in isopropanol - a novel formula designed for the treatment of alopecia areata. Our Dermatol Online. 2017;8(1):17-21.

Submission: 30.11.2016; **Acceptance:** 11.12.2016

DOI: 10.7241/ourd.20171.04

alcohol (isopropanol) is promising solvent for the DCP. Except for the stability, it gives the solutions a proper consistency. Meanwhile, the study revealed that the DCP solutions with acetone, which is widely used as a solvent, are stable only for few days, especially at room temperature [10]. Moreover, all the solutions turned out to be stable only in the refrigerator at temperature of 4 °C irrespective of the solvent used.

Considering the findings mentioned above authors decided to investigate the therapeutic potential and the tolerance to DCP solutions in isopropanol and compare it to the effect obtained during the treatment with DCP in propylene glycol.

METHODS

Clinical and demographic data of the patients are summed in Tables 1 and 2. After having an agreement with ethics committee, authors arranged two groups of AA patients, 20 patients in each group. Groups were randomized so that the mean initial status measured by own scale (described below) was equal in each group – thus meaning that groups had similar mean hair loss at the beginning of the study. Solutions were made of 98% diphenylcyclopropanone chemical by Sigma Aldrich (No. 177377). Basic solutions of 3% DCP were prepared in propylene glycol and isopropanol. All solutions were kept in the refrigerator at the temperature of 4 °C according to previously collected data. From the initial solutions, the solutions of 0.5%, 0.3%, 0.2%, 0.1% and 0.05% were made in each solvent in order to perform the proper treatment.

In both groups (the DCP in propylene glycol and DCP in isopropanol), on the first visit, 3% DCP was applied to bald areas on the top of the scalp to obtain sensitization. Areas near the neck and ears were avoided to prevent irritation – even if there were bald patches. Patients were instructed to avoid situations which may lead to sweating (like sports) for the next two days. During 24 to 48 hours after application, a reaction including itching, redness, edema and the presence of vesicles with serous liquid occurred. After 2 days, patients were told to wash their scalps and the reaction faded. Further applications took place during 1 week intervals. The DCP concentration was at that time between 0.05% and 0.5% (usually about 0.1%), depending on the intensity of the reaction after sensitization. Patients were equipped with the tube of strong corticosteroid ointment (clobetacole propionate

Table 1: Clinical and demographical data of the patients treated with DCP in isopropanole

Patient No.	Age (years)	Sex	Status initial	Status final	Tolerance	Observation
1	35	F	2	1	2	12 months
2	37	M	3	3	2	12 months
3	18	M	6	2	1	12 months
4	28	F	5	1	2	12 months
5	27	F	6	4	2	12 months
6	35	F	2	1	2	12 months
7	23	M	6	2	3	12 months
8	50	M	3	1	2	12 months
9	18	M	3	2	2	12 months
10	19	F	4	2	1	12 months
11	18	M	6	3	3	12 months
12	18	F	4	2	3	12 months
13	38	F	6	1	2	12 months
14	48	F	3	2	2	12 months
15	18	F	6	2	2	12 months
16	18	F	3	1	3	12 months
17	34	F	2	2	2	12 months
18	29	F	2	1	2	12 months
19	26	M	4	2	2	12 months
20	18	M	4	3	2	12 months

M: Male, F: Female

Table 2: Clinical and demographical data of the patients treated with DCP in propylene glycol

Patient No.	Age (years)	Sex	Status initial	Status final	Tolerance	Observation
21	38	M	2	1	3	12 months
22	35	F	3	2	3	12 months
23	35	F	3	1	4	12 months
24	36	M	4	2	2	12 months
25	51	M	2	2	3	12 months
26	42	F	6	2	4	12 months
27	19	F	3	2	3	12 months
28	18	F	3	2	3	12 months
29	22	M	3	1	3	12 months
30	32	F	4	3	4	12 months
31	18	F	5	2	5	12 months
32	37	F	4	2	4	12 months
33	18	F	4	2	3	12 months
34	20	M	5	2	4	12 months
35	19	F	3	1	5	12 months
36	18	M	6	2	3	12 months
37	30	F	6	3	4	12 months
38	19	F	4	1	3	12 months
39	43	F	4	2	4	12 months
40	29	M	6	2	4	12 months

M: Male, F: Female

0.05%) and were advised to use it if allergic reaction to DCP occurs on the body parts. All the patients were observed for 12 months.

To assess the grade of hair loss or hair regrowth authors used own invented scale that was used before [5,8,9]. Grade 1 of this scale indicated no hair loss or complete hair regrowth, grade 2 showed bald area below 20% of the scalp

surface, grade 3- represented bald area between 21 and 50% of the scalp surface, grade 4- had a bald area between 51 and 80% of the scalp area, grade 5 – reflected a bald area between 81 and 99% of the scalp surface and finally, grade 6 - total 100% hair loss (alopecia totalis). In the discussion grades 1 and 2 are considered as “cosmetically acceptable”. The assessment was made twice: at the beginning and at the end of the 12 months of observation.

At the end of the study each patient filled the questionnaire regarding subjective tolerance of the treatment. The tolerance was measured in six grade scale in which grade 1 indicated perfect tolerance and no side effects and grade 6 meant that treatment was intolerable and had to be withdrawn. Details of the tolerance scale are listed in the Table 3.

Statistical Analysis

For the purpose of this study Kruskal-Wallis rank sum test, Bartlett test of homogeneity of variances and Shapiro-Wilk normality test were used.

RESULTS

All but one patient responded to the study with partial or complete hair regrowth. Results show improvement after the treatment in both groups with 75% and 85% of patients with cosmetically acceptable hair amount (grades 1 and 2 in the hair loss scale) in DCP in isopropanole and DCP in propylene glycol groups respectively. By comparison initial values of “cosmetically acceptable” hair in these groups were 20% and 10% respectively. Complete hair regrowth was obtained in 35% and 25% of patients respectively (initial amount of complete regrowth was zero obviously). Differences in treatment’s efficacy (Fig. 1) between groups were not statistically important ($p = 0.95$).

Tolerance was generally good but significantly better ($p= 0.17$) in a group treated with DCP in isopropanol (Fig. 2). While patients treated with DCP in propylene glycol usually reported tolerance level between 3 and

4 (Table 3), those treated with DCP in isopropanol reported tolerance grade 1 to 2. However, in the latter group allergic reactions affecting the body were reported more often; usually disappearing during one day but annoying. The itching patches on the upper body parts required the usage of corticosteroid ointment for few days. None of the patients had to withdraw the treatment because of the side effects.

DISCUSSION

Results are similar to the ones that authors obtained in previous studies [5,8]; however, it is worth mentioning that observation in the present study lasted one year versus two years in previous ones. Hence the result after another year of observation may vary in every way. Typically patients showed improvement but required further treatment (Fig. 3). What is important, conclusion of this study is that tolerance of DCP dissolved in isopropanol is to be better than previously used DCP in propylene glycol. It is patients’ subjective impression that make them continue or withdraw the treatment. With the exception of

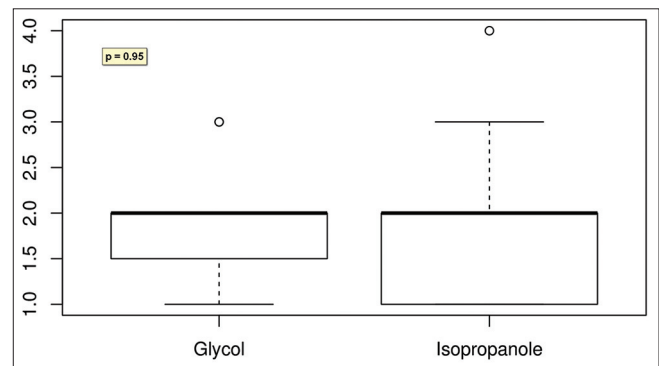


Figure 1: Comparison of treatment efficacy between DCP in propylene glycol and isopropanole.

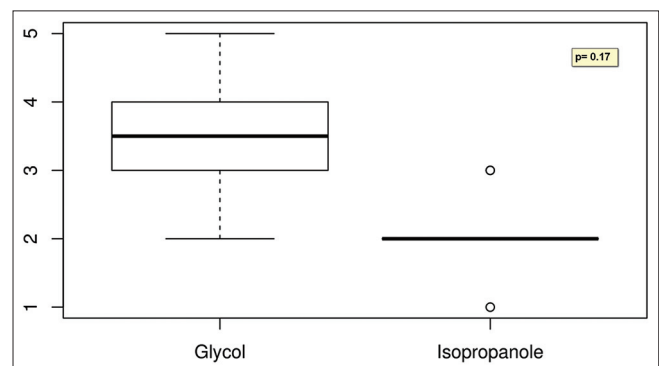


Figure 2: Comparison of treatment tolerance between DCP in propylene glycol and isopropanole.

Table 3: Tolerance of the treatment – patient’s scale for the questionnaire

Grade 1	Perfect tolerance and no side effects
Grade 2	Mild side affects that do not disturb routines
Grade 3	Side affects that sometimes disturb routines
Grade 4	Side effects that affects daily routines everyday
Grade 5	Intolerance that makes sleep impossible
Grade 6	Treatment intolerable and withdrawn

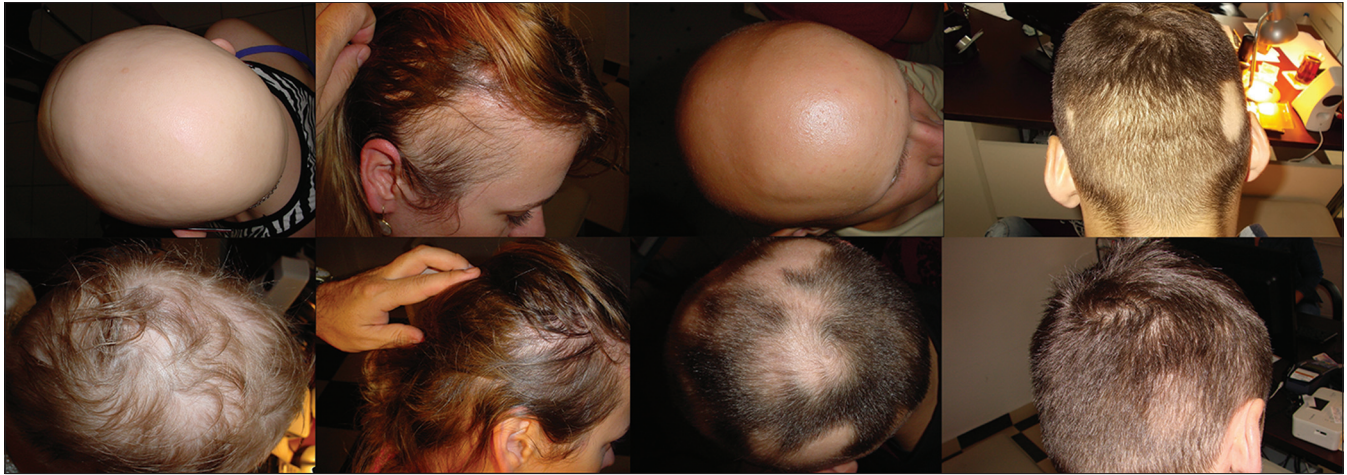

Figure 3: Clinical status of two patients treated with DCP in propylene glycol (left) and two treated with DCP in isopropanol (right). Before (top) and after (bottom) of the 12 months treatment.

sensitization with high concentration 3% DCP most patients treated with DCP in isopropanole described side effects as “none” or “mild that do not disturb routines”. In contrast, in the DCP in propylene glycol group patients complained of “side effects that affect routines”. None of them had to stop the treatment; however, a one – two week break in a treatment routine was sometimes necessary. At the beginning of their experiences with DCP authors noticed that preparations of DCP that were older than 6 months had different clinical effect on the patients scalp. While clinical efficacy seemed to gradually fade with the solution’s age the irritation was getting bigger. Now it is known that DCP solutions kept at room temperature decompose slowly and the product of DCP decomposition – diphenylacetylene (DPA) seems to have irritating qualities. Although pharmacokinetics of DCP on the surface of the skin is unknown, recent studies [10,11] confirm following hypothesis. Both solvents: isopropanol and propylene glycol are perfect solvents for DCP while solutions are kept in the refrigerator. The concentration of DCP against it’s main decomposition product – diphenylacetylene (DPA) remains unchanged after 60 days of measurement and probably longer in propylene glycol at temperature of 4 °C [11]. The situation changes when solutions of DCP are stored at room temperature or higher and are contaminated with water. Large amount of water or NaCl 0.9% solution accelerates DCP’s decomposition [10]. Propylene glycol creates dense, sticky layer on the surface of the skin and droplets of sweat appear quickly underneath this layer, especially during sunny days according to authors’ observations. This probably leads to DPA aggregation and eventually to

bigger irritation. In contrast, isopropanol evaporates quickly just seconds after it is applied to the surface of the scalp. If the patient avoids situation that might lead to sweating as he was instructed, a thin layer of DCP not contaminated with DPA will remain on his scalp until washing out. It causes usually well tolerable and controllable allergic reaction necessary to obtain therapeutic effect but not the toxic reaction leading to discomfort. The phenomenon that higher DCP concentration in isopropanole used during sensitization in our study led to irritation on the body parts can also be explained. In this special situation the amount of DCP on patient’s scalp is 30 times bigger than in 0.1% solution usually used during proper treatment. Authors believe that sensitization with 3% DCP is the only situation when properties of propylene glycol, especially its "stickiness", make it more suitable, as it is more unlikely for DCP from patient’s scalp to be spread all over the body during nighttime.

CONCLUSIONS

- DCP solutions in isopropanol may have potential in the treatment of alopecia areata.
- Treatment efficacy in both groups (DCP in propylene glycol and DCP in isopropanol) was the same.
- Tolerance of the DCP in isopropanol was significantly better than DCP in propylene glycol.
- Despite better tolerance of DCP in isopropanol during the proper treatment, the sensitization with 3% DCP should be done with the solution in propylene glycol.

REFERENCES

1. Happle R, Klein HM, Macher E. Topical immunotherapy changes the composition of the peribulbar infiltrate in alopecia areata. *Arch Dermatol Res.* 1986;278:214-8.
2. Hoting E, Boehm A. Therapy of alopecia areata with diphencyprone. *Br J Dermatol.* 1992;127:625-9.
3. Borowska K., Wasylyszyn T. Zastosowanie lecznicze alergenu kontaktowego difenylocyklopropenu. (Medical applications for the contact allergen - diphenylcyclopropenone.) *Int Rev Allergol Clin Immunol Fam Med.* 2016;22:173-8.
4. Borowska K., Wasylyszyn T. Procesy immunologiczne zachodzące w łysieniu plackowatym. (Immunological processes in alopecia areata.) *Int Rev Allergol Clin Immunol Fam Med.* 2016;22:48-52.
5. Wasylyszyn T, Kozłowski W, Zabielski SL. Changes in distribution pattern of CD8 lymphocytes in the scalp in alopecia areata during treatment with diphencyprone. *Arch Dermatol Res.* 2007;299:231-7.
6. Chiang K, Atanaskova Mesinkovska N, Amoretti A, Piliang MP, Kyei A, Bergfeld WF. Clinical efficacy of diphenylcyclopropenone in alopecia areata: retrospective data analysis of 50 patients. *J Am Acad Dermatol.* 2014;71:595-7.
7. Culp BL, Wells MJ. Generalized urticaria with use of diphencyprone in the treatment of warts. *J Drugs Dermatol.* 2007;6:529-30.
8. Wasylyszyn T, Borowska K. Possible advantage of imiquimod and diphenylcyclopropenone combined treatment versus diphenylcyclopropenone alone: An observational study of nonresponder patients with alopecia areata. *Australas J Dermatol.* 2016;17;1-5.
9. Borowska K, Wasylyszyn T, Zabielski S. The efficacy and safety of topical therapy with diphenylcyclopropenone in the treatment of alopecia areata - a retrospective study. (Ocena efektywności i bezpieczeństwa difenylocyklopropenu w leczeniu miejscowym łysienia plackowatego - badania retrospektywne. *Int Rev Allergol Clin Immunol Fam Med.* 2016;22:27-32.
10. Borowska K, Wasylyszyn T. Studies on stability of 2,3-diphenylcyclopropenone in contact with water and aqueous NaCl solutions. Conclusions for the purpose of topical therapy of patients with alopecia areata. *Acta Pol Pharmaceut.* 2016 in press; 73(6).
11. Wasylyszyn T, Borowska K. The stability of solutions of 2,3-diphenylcyclopropenone in various solvents. A novel formula – diphenylcyclopropenone in isopropanol may be useful in topical therapy of patients with alopecia areata. *Acta Pol Pharmaceut.* 2017 in press; 74 (2).

Copyright by Tomasz Wasylyszyn, et al. This is an open-access article distributed under the terms of the Creative Commons Attribution License, which permits unrestricted use, distribution, and reproduction in any medium, provided the original author and source are credited.

Source of Support: Nil, **Conflict of Interest:** None declared.

Prevalence and determinants of eczema among females aged 21 to 32 years in Jeddah city - Saudi Arabia

Sultana T. Binyamin¹, Fathi Algamal¹, Amani N. Yamani¹, Mai S. Labani¹,
Fatenah H. Alaqbi¹, Anhar A. Baeshen¹, Abdulelah T. Binyamin¹,
Mohammed T. Al-Nazzawi², Shahad M. Alamoudi¹, Mohammed A. Aljunaid³,
Lamis F. Basaeed⁴, Ahmed H. Alhasan³, Alanoud M. Al-Marzoug⁵

¹Faculty of Medicine, Ibn Sina National College, Jeddah, Saudi Arabia, ²Faculty of Medicine, Batterjee Medical College, Jeddah, Saudi Arabia, ³Faculty of Medicine, University of Jeddah, Jeddah, Saudi Arabia, ⁴Faculty of Medicine, King Abdulaziz University, Jeddah, Saudi Arabia, ⁵Faculty of Medicine, King Saud bin Abdul-Aziz University for Health Sciences, Riyadh, Saudi Arabia

Corresponding author: Dr. Sultana T. Binyamin, E-mail: sultanaalnahdi@hotmail.com

ABSTRACT

Introduction: Atopic dermatitis (AD) is a common, chronic inflammatory skin disease with early onset and with a lifetime prevalence of approximately 20%. Although the pathogenesis of the disorder is not completely understood, it appears to result from the complex interplay between defects in skin barrier function, environmental and infectious agents, and immune abnormalities. **Aim:** To investigate the prevalence and determinants of Eczema among Saudi female aged 21 to 32 years old in Jeddah city. **Methods:** A cross sectional study involved 190 female students from IbnSina National College for Allied Health Sciences in Jeddah city were chosen by convenient sampling. Data were collected by Interview questionnaire (ISAAC: Core Questionnaire for Asthma, Rhinitis and Eczema) after getting their consent. SPSS used for data entry and analysis. **Results:** Prevalence of eczema among medical college females was 16.6%, Eczema was similar in Saudi and Non-Saudi females (13.97% and 12.66% respectively, $P = 0.545$). Eczema was associated with eye allergy (34.2%) with statistical significance $P = 0.003$. Eczema was associated family members history with statistical significance $P = 0.012$. There was not statistical significant relationship between eczema and education level, parental jobs, drugs chest and nose allergy. **Conclusion:** Prevalence of eczema among female medical students was 16.6%. Eczema was significantly associated with eye allergy and Family history of skin allergy was risk factor of eczema.

Key words: Prevalence; Determinants; Eczema; Females; Saudi Arabia

INTRODUCTION

Eczema or Atopic Dermatitis is a chronic pruritic inflammatory skin disease that occurs most frequently in children, but also affects adults. Eczema is often associated with elevated serum level of immunoglobulin E and a personal or family history of atopy, which describes a group of disorders that includes eczema, asthma, and allergic rhinitis [1,2]. Although sensitization to environmental or food allergens is

clearly associated with the Eczema phenotype, it does not seem to be a causative factor but may be a contributory factor in a subgroup of patients with severe disease [3].

Epidemiology

Eczema affects approximately 5 to 20 percent of children worldwide [4]; in the United States, it is approximately 11 percent [5]. Data on prevalence of Eczema in

How to cite this article: Binyamin ST, Algamal F, Yamani AN, Labani MS, Alaqbi FH, Baeshen AA, Binyamin AT, Al-Nazzawi MT, Alamoudi SM, Aljunaid MA, Basaeed LF, Alhasan AH, Al-Marzoug AM. Prevalence and determinants of eczema among females aged 21 to 32 years in Jeddah city - Saudi Arabia. Our Dermatol Online. 2017;8(1):22-26

Submission: 25.05.2016; **Acceptance:** 15.07.2016

DOI: 10.7241/ourd.20171.05

adults are limited and in most cases based upon self-administered questionnaire information. In a Danish population-based study including approximately 16,500 adults aged 30 to 89 years, the 1-year prevalence of atopic eczema was 14 percent [6]. In a in West Sweden study of approximately 30,000 individuals aged 16 to 75 years, the current eczema prevalence was 11 percent [7]. In a Danish cohort study including approximately 1300 individuals aged 28 to 30 years who had been followed-up for 15 years, 10 percent reported atopic dermatitis, but 6 percent were found to have atopic dermatitis at clinical examination [8]. The incidence of Eczema appears to be increasing. It may occur in any race or geographic location, although there appears to be a higher incidence in urban areas and developed countries, especially Western societies. A systematic review of epidemiologic studies performed between 1990 and 2010 found an increasing trend in incidence and prevalence of atopic eczema in Africa, eastern Asia, western Europe, and parts of northern Europe [9]. In the vast majority of cases, Eczema has an onset before age five years, and prevalence data in children show a slight female to male preponderance (1.3 to 1) [10].

Risk Factors

A family history of atopy (eczema, asthma, or allergic rhinitis) and the loss-of-function mutations in the filaggrin (*FLG*) gene, involved in the skin barrier function, are major risk factors for Eczema [11]. Approximately 70 percent of patients have a positive family history of atopic diseases. Children with one atopic parent have a two- to threefold increased risk of developing Eczema, and the risk increases to three- to fivefold if both parents are atopic [2]. Although 30 to 80 percent of patients with Eczema are sensitized to certain foods, the timing of solid food introduction or food avoidance strategies in pregnant or nursing women does not appear to influence the risk of Eczema [12].

Although 30 to 80 percent of patients with atopic dermatitis are sensitized to certain foods, the timing of solid food introduction or food avoidance strategies in pregnant or nursing women does not appear to influence the risk of atopic dermatitis [13].

There is evidence from a 2011 systematic review to support an inverse relationship between atopic dermatitis and exposure to endotoxin, early day care, farm animal, and dog pets in early life (the “hygiene hypothesis”) [14].

A multiplicity of factors, including skin barrier abnormalities, defects in innate immunity response, Th2-skewed adaptive immune response, and altered skin resident microbial flora are involved in the pathogenesis of atopic dermatitis [15,16]. Whether skin inflammation is initiated by skin barrier dysfunction (“outside-in” hypothesis) or by immune dysregulation (“inside-out” hypothesis) is still in debate.

The epidermis is the first line of defense between the body and the environment. The skin barrier keeps environmental irritants, allergens, and microbes from entering the body and prevents excessive water loss. The barrier function of the skin is primarily located in the stratum corneum, which consists of vertical stacks of anucleate corneocytes packed with keratin filaments embedded in a matrix of filaggrin breakdown products [17]. The corneocyte layers are embedded in an extracellular matrix replete with multiple lamellar bilayers enriched in ceramides, cholesterol, and free fatty acids derived from secreted lamellar body precursor lipids [18].

Clinical Manifestations

Dry skin and severe pruritus are the cardinal signs of Eczema. However, the clinical presentation is highly variable, depending upon the patient’s age and disease activity.

Acute eczema is characterized by intensely pruritic erythematous papules and vesicles with exudation and crusting, whereas subacute or chronic lesions present as dry, scaly, or excoriated erythematous papules. Skin thickening from chronic scratching (lichenification) and fissuring may develop over time. In many patients, lesions in different stages may be present at the same time.

Most patients with Eczema have a cutaneous hyperreactivity to various environmental stimuli, including exposure to food and inhalant allergens, irritants, changes in physical environment (including pollution, humidity, etc), microbial infection, and stress [19].

Diagnosis

The diagnosis of Eczema is clinical, based upon history, morphology and distribution of skin lesions, and associated clinical signs [2]. The United Kingdom working group on Eczema published criteria for diagnosing Eczema that include one mandatory and

five major criteria [20,21]: Evidence of pruritic skin, including the report by a parent of a child rubbing or scratching. In addition to itchy skin, three or more of the following are needed to make the diagnosis:

- History of skin creases being involved. These include: antecubital fossae, popliteal fossae, neck, areas around eyes, fronts of ankles.
- History of asthma or hay fever (or history of atopic disease in a first-degree relative for children <4 years of age).
- The presence of generally dry skin within the past year.
- Symptoms beginning in a child before the age of two years. This criterion is not used to make the diagnosis in a child who is under four years old.
- Visible dermatitis involving flexural surfaces. For children under four years of age, this criterion is met by dermatitis affecting the cheeks or forehead and outer aspects of the extremities.

Skin biopsy and laboratory testing, including IgE levels, are not used routinely in the evaluation of patients with suspected Eczema and are not recommended. However, in selected patients, histologic examination of a skin biopsy or other laboratory tests (eg., serum immunoglobulin E, potassium hydroxide preparation, patch testing, genetic testing) may be helpful to rule out other skin conditions [2].

Treatment

Patients with Eczema do not usually require emergency therapy, but they may visit the emergency department for treatment of acute flares caused by eczema herpeticum and bacterial infections. Topical steroids are currently the mainstay of treatment. In association with moisturization, responses have been excellent [22].

Aim of the Study

Overall objective

The main objective of the present study was to investigate the prevalence and determinants of Eczema among Saudi female aged 21 to 32 years old in Jeddah city.

Specific objective

1. To study the relationship between the family characteristic and the occurrence of Eczema.
2. To study the relationship between the home characteristics of the studied females and the occurrence of Eczema.
3. To study the relationship between the family history

of Eczema and the occurrence of Eczema in the studied females.

4. To study the relationship between the personal characteristics of the studied females and the occurrence of Eczema.
5. To study the association between Eczema and the occurrence of Eczema and Bronchial Asthma.

MATERIALS AND METHODS

Study Design

A cross sectional study design.

Subjects and Study Setting

Study involved 228 university female students from IbnSina National College for Allied Health Sciences.

Sampling Techniques

A convenient sampling used and the size of the sample was determined according to the following criteria: Alpha=0.05, Beta=0.2 with moderate size effect.

Tools for Data Collection

Personal, social and environmental questionnaire, which provided information about the family characteristics, but the home circumstances and personal details of the studied female. Data were collected using ISAAC: Core Questionnaire for Asthma, Rhinitis and Eczema.

Statistical Analysis

The collected data were coded and typed on a computer file using the SPSS statistical package version 22 IBM for PC. Data was presented as tables and figures. Data was analyzed using statistical test of significance tests: Chi square test, and level of significance for the present study was chosen as 5% ($\alpha=.05$).

RESULTS

The prevalence of eczema among medical college females was 16.6%, Eczema was similar in Saudi and Non-Saudi females (13.97% and 12.66% respectively). This difference was not statistically significant where Fisher's exact test was 1, ($P = 0.545$) (Table 1).

The highest proportion of eczema was among daily times practicing exercise per week (20%). This

difference was not statistically significant where Pearson Chi-Square 0.702, $P = 0.870$ (Table 2).

The highest proportion of eczema among suffer from eye allergy (34.2 %) This difference was statistically significant where Pearson chi- square = 10.216, $P = 0.003$ (Table 3).

The highest proportion of eczema among suffer from drug allergy (21,4 %) This difference was not statistically significant where Pearson chi- square 0.252, $P = 0.419$ (Table 4).

The Eczema was higher in females students who exposure to pungent odors bother her breath (19.1%) and females students who exposure to pungent odors do not bother her breath. This difference was not statistically significant where Fisher's exact test was 0.661, and $P = 0.262$ (Table 5).

Table 1: Distribution of female student according to nationality and presence of eczema

Nationality	Eczema		Total (%)
	Yes (%)	No (%)	
Saudi	32 (16.5)	162 (83.5)	194 (100)
Non-Saudi	6 (17.1)	29 (82.9)	35 (100)
Total	38 (16.6)	191 (83.4)	229 (100)

Fisher exact test=1, ($p=0.545$)

Table 2: Distribution of female student according to times practicing exercise per week and presence of eczema

Times practicing exercise per week	Eczema		Total (%)
	No (%)	Yes (%)	
No	87 (82.1)	19 (17.9)	106 (100.0)
Daily	16 (80.0)	4 (20.0)	20 (100.0)
2-3 times	43 (84.0)	8 (15.7)	51 (100.0)
Once	45 (86.5)	7 (13.5)	52 (100.0)
Total	191 (83.4)	38 (16.6)	229 (100.0)

Fisher exact test=0.702, ($p=0.870$)

Table 3: Distribution of studied females according to suffer from eye allergy and presence of eczema

Suffer from eye allergy	Eczema		Total (%)
	No (%)	Yes (%)	
No	166 (86.9)	25 (13.1)	191 (100.0)
Sometime	25 (65.8)	13 (34.2)	38 (100.0)
Total	191 (83.4)	38 (16.6)	229 (100.0)

Fisher exact test=10.216, ($p=0.003$)

Table 4: Distribution of studied females according to suffer from drug allergy and presence of eczema

Suffer from drug allergy	Eczema		Total (%)
	No (%)	Yes (%)	
No	180 (83.7)	35 (16.3)	215 (100.0)
Sometime	11 (78.6)	3 (21.4)	14 (100.0)
Total	191 (83.4)	38 (16.6)	229 (100.0)

Fisher exact test=0.252, ($p=0.41$)

The Eczema was higher in females students who exposure to dusty air bother her breath (19.8%) and females who exposure to dusty air do not bother her breath. This difference was not statistically significant where Fisher's exact test was 1.620, and $P = 0.137$ (Table 6).

Eczema was higher in females students who their family member suffer from allergy (30.0%) and females students who their family member do not suffer from This difference was statistically significant where Fisher's exact test was 13.659, and $P = 0.012$ (Table 7).

Eczema was higher in females students who have been diagnosed before of having chest allergy, nose allergy and eczema (26.3%) and female students who have

Table 5: Distribution of studied females according to exposure to pungent odors bother her breath and presence of eczema

Exposure to pungent odors bother your breath	Eczema		Total (%)
	No (%)	Yes (%)	
No	119 (85.0)	21 (15.0)	140 (100.0)
Sometimes	72 (80.9)	17 (19.1)	89 (100.0)
Total	191 (83.4)	38 (16.6)	229 (100.0)

Fisher exact test=0.661, ($p=0.262$)

Table 6: Distribution of studied females according to exposure to dusty air bother her breath and presence of eczema

Exposure to dusty air bother your breath	Eczema		Total (%)
	No (%)	Yes (%)	
No	102 (86.4)	16 (13.6)	118 (100)
Sometimes	89 (80.2)	22 (19.8)	111 (100)
Total	191 (83.4)	38 (16.6)	229 (100)

Fisher exact test=1.620, ($p=0.137$)

Table 7: Distribution of studied females who their family member suffer from allergy and presence of eczema

Any family member suffer from allergy	Eczema		Total (%)
	No (%)	Yes (%)	
No	81 (93.1)	6 (6.9)	87 (100)
Chest allergy	58 (73.4)	21 (27.6)	79 (100)
Nose allergy	34 (85.0)	6 (15.0)	40 (100)
Skin allergy	7 (70.0)	3 (30.0)	10 (100)
Eczema	8 (80.0)	2 (20.0)	10 (100)
Eye allergy	3 (100)	0 (0.0)	3 (100)
Total	191 (83.4)	38 (16.6)	229 (100)

Fisher exact test=13.659, ($p=0.012$)

Table 8: Distribution of studied females who diagnosed before of having chest allergy, nose allergy and eczema

Diagnosed before of having chest allergy	Eczema		Total (%)
	No (%)	Yes (%)	
No	102 (88.7)	13 (11.3)	115 (100)
Chest allergy	46 (76.7)	14 (23.3)	60 (100)
Nose allergy	29 (82.0)	6 (17.1)	35 (100)
Eczema	14 (73.0)	5 (26.3)	19 (100)
Total	191 (83.4)	38 (16.6)	229 (100)

Fisher exact test=5.599, ($p=0.133$)

been not diagnosed having chest allergy, nose allergy and eczema. This difference was not statistically significant where Fisher's exact test was 5.599, and $P = 0.133$ (Table 8).

Ethics

This study was performed on human subjects; thus, all patients were aware of the presence of the study and they were fully informed about the drug and its side-effects.

CONCLUSION

Eczema was significantly associated with eye allergy and Family history of skin allergy was risk factor of eczema

Recommendations

Student with eye allergy and family history of skin allergy should be screened for eczema.

Statement of Human and Animal Rights

All procedures followed were in accordance with the ethical standards of the responsible committee on human experimentation (institutional and national) and with the Helsinki Declaration of 1975, as revised in 2008.

Statement of Informed Consent

Informed consent was obtained from all patients for being included in the study.

REFERENCES

1. Spergel JM. From Eczema to asthma: the atopic march. *Ann Allergy Asthma Immunol.* 2010;105:99.
2. Eichenfield LF, Tom WL, Chamlin SL, Krol A, Paller AS, Schwarzenberger K, et al. Guidelines of care for the management of Eczema: section 1. Diagnosis and assessment of Eczema. *J Am Acad Dermatol.* 2014;70:338-51.
3. Williams H, Flohr C. How epidemiology has challenged 3 prevailing concepts about Eczema. *J Allergy Clin Immunol.* 2006;118:209-13.
4. Strachan D, Sibbald B, Weiland S, Ait-Khaled N, Anabwani G, Anderson HR, et al. Worldwide variations in the prevalence of symptoms of atopic eczema in the International Study of Asthma and Allergies in Childhood. *J Allergy Clin Immunol.* 1999;103:125.
5. Shaw TE, Currie GP, Koudelka CW, Simpson EL. Eczema prevalence in the United States: data from the 2003 National Survey of Children's Health. *J Invest Dermatol.* 2011;131:67-73.
6. Vinding GR, Zarchi K, Ibler KS, Miller IM, Ellervik C, Jemec GB. Is adult atopic eczema more common than we think? - A population-based study in Danish adults. *Acta Derm Venereol.* 2014;94:480.
7. Rönmark EP, Ekerljung L, Lötvall J, Wennergren G, Rönmark E, Torén K, et al. Eczema among adults: prevalence, risk factors and relation to airway diseases. Results from a large-scale population survey in Sweden. *Br J Dermatol.* 2012;166:1301-8.
8. Deckers IA, McLean S, Linssen S, Mommers M, van Schayck CP, Sheikh A. Investigating international time trends in the incidence and prevalence of atopic eczema 1990-2010: a systematic review of epidemiological studies. *PLoS One.* 2012;7:e39803.
9. Kang K, Polster AM, Nedorost St. Eczema. In: *Dermatology, Bologna JL, Jorizzo JL, Rapini RP, et al (Eds), Mosby, New York 2003.* p.199.
10. Sandström MH, Faergemann J. Prognosis and prognostic factors in adult patients with Eczema: a long-term follow-up questionnaire study. *Br J Dermatol.* 2004;150:103.
11. Irvine AD, McLean WH, Leung DY. Filaggrin mutations associated with skin and allergic diseases. *N Engl J Med.* 2011;365:1315-27.
12. Kramer MS, Kakuma R. Maternal dietary antigen avoidance during pregnancy or lactation, or both, for preventing or treating atopic disease in the child. *Cochrane Database Syst Rev.* 2012;9:CD000133.
13. Flohr C, Yeo L. Eczema and the hygiene hypothesis revisited. *Curr Probl Dermatol.* 2011;41:1-34.
14. Kuo IH, Yoshida T, De Benedetto A, Beck LA. The cutaneous innate immune response in patients with Eczema. *J Allergy Clin Immunol.* 2013;131:266-78.
15. Boguniewicz M, Leung DY. Eczema: a disease of altered skin barrier and immune dysregulation. *Immunol Rev.* 2011;242:233.
16. Elias PM, Wakefield JS. Mechanisms of abnormal lamellar body secretion and the dysfunctional skin barrier in patients with Eczema. *J Allergy Clin Immunol.* 2014;134:781.
17. Feingold KR, Elias PM. Role of lipids in the formation and maintenance of the cutaneous permeability barrier. *Biochim Biophys Acta.* 2014;1841:280-94.
18. Leung DY. New insights into Eczema: role of skin barrier and immune dysregulation. *Allergol Int.* 2013;62:151.
19. Brandner JM, Zorn-Kruppa M, Yoshida T, Moll I, Beck LA, De Benedetto A. Epidermal tight junctions in health and disease. *Tissue Barriers* 2015; 3:e974451.
20. Seidenari S, Giusti G. Objective assessment of the skin of children affected by Eczema: a study of pH, capacitance and TEWL in eczematous and clinically uninvolved skin. *ActaDermVenereol* 1995; 75:429-33.
21. Kelleher M, Dunn-Galvin A, Hourihane JO, Murray D, Campbell LE, McLean WH, et al. Skin barrier dysfunction measured by transepidermal water loss at 2 days and 2 months predicts and predicts Eczema at 1 year. *J Allergy Clin Immunol* 2015; 135:930-5.
22. Flohr C, England K, Radulovic S, McLean WH, Campbell LE, Barker J, et al. Filaggrin loss-of-function mutations are associated with early-onset eczema, eczema severity and transepidermal water loss at 3 months of age. *Br J Dermatol* 2010; 163:1333-6.

Copyright by Sultana T Binyamin, et al. This is an open access article distributed under the terms of the Creative Commons Attribution License, which permits unrestricted use, distribution, and reproduction in any medium, provided the original author and source are credited.
Source of Support: Nil, **Conflict of Interest:** None declared.

A biological melange and a peculiar led light could be a thaumaturgic approach to defeat manifold types of folliculitis in man and woman

Lorenzo Martini

University of Siena, Department of Pharmaceutical Biotechnologies, Via A. Moro 2, 53100 Siena, Italy

Corresponding author: Lorenzo Martini, M.Sc., E-mail: martinil163@libero.it

ABSTRACT

Nowadays PTD (photodynamic therapy) together with methyl aminolevulinate (MAL) pomades seem to be the goal and merit of all the vanguard dermatologists and aesthetic surgeons, who are determined to struggle radically the problems of folliculitis, malaise that disturbs men and women, even by the social point of view. In this study We attempt to treat 12 different cases of folliculitis caused by symptoms of different etiologies in men, women and in a transvestite, but not operate (idest a pre-op trans), using a cosmetic formula made of a particular fermented rice starch and particular irradiation for different quantities of time, depending on the gravity of the disease to treat. Results are utterly satisfying.

Key words: PTD; Folliculitis; LED; MAL; Protoporphirin IX

INTRODUCTION

Folliculitis is an inflammation of the hair follicles. Folliculitis may occur onto any part of human body that has hair. But it is most common on the beard area, arms, back, buttocks, inner thighs and legs and can be caused by bacteria, howbeit it also can be caused by yeast or another type of fungi.

Anyway its manifestation is always accompanied by erythema and harassing itch.

Folliculitis could even arise owing to damaged hair follicles. Shaving, depilating, epilating or wearing habiliment that rubs the skin can irritate the follicles, which can lead to folliculitis. They also can become blocked or irritated by sweat, machine oils, or makeup. When the follicles are injured, they are more likely to become infected.

For, folliculitis is common in men and women as well, and symptoms are very fastidious and disagreeable.

Dermatologists too often suggest the continuous usage of corticosteroids or Mupirocin lipogels and

aqueous lotions and an avalanche of natural remedies exist, as the ancient “Venus’ milk”, based on benzoin resin oil dispersed in rose water, (notwithstanding its way of action is almost unclear, it appears to be the most preferable choice advised by herbalists) and/or sanative hydrolats based on brimstone salts and its derivatives.

When folliculitis is evoked by a serious fungal infection, as *Malassezia* folliculitis, oral antifungal medications are favoured, however antifungal remedies too often show many therapeutic weaknesses such as infection relapse, drug resistance, or adverse effects like hepatotoxicity and gastrointestinal discomfort [1].

Hereupon, we have decided to treat severe cases of recalcitrant folliculitis by a sort of PDT (photodynamic therapy), as divers dermatologists nowadays rede as an alternative therapeutic option for its antimicrobial effect, and we have chosen a type of revisited method of PDT.

Forsooth, PDT forecasts the use of methyl aminolevulinate (MAL) cream together with

How to cite this article: Martini L. A biological melange and a peculiar led light could be a thaumaturgic approach to defeat manifold types of folliculitis in man and woman. *Our Dermatol Online*. 2017;8(1):27-30.

Submission: 09.03.2016; **Acceptance:** 20.06.2016

DOI:10.7241/ourd.20171.06

irradiations emitted from a simplest lamp with light-emitting diodes (LED), easily available on the market.

MAL is considered an optimal sensitizer in photodynamic therapy, since it acts as a prodrug that is metabolized to protoporphyrin IX.

Now, Protoporphyrin IX is an important precursor to biologically essential prosthetic groups such as cytochrome C in mammals and chlorophylls in herbs. As a result, a number of organisms are able to synthesize Protoporphyrin IX from basic precursors such as glycine and succinyl CoA, or glutamate [2-4].

Glutamate occurs naturally in many foods, such as tomatoes and cheeses and in a major extent in Kelp, seaweeds and fermented starch (especially from cassava roots), sugar beets, sugar cane or molasses by the aids of *Aspergillus spp.*

Since today, instead of extracting and crystallizing glutamate from seaweed broth, it is preferable to produce it by the fermentation of manifold starches (and this fermentation process is similar to that used to make yogurt, vinegar and wine) we have decided to arrange a type of fermented starch following a revolutionary and nonconventional method heralded by Seinosuke et al [5] and thus letting to drive a complete fermentation of rice starch and soybean homogenate–enzymes–yeast mixture in a cruse at pH 3.5 and 545.67 Rankine degrees for five days, to obtain a surrogate of a fermented starch, that is admitted as ASPERGILLUS/GLUCOSE/SOYBEAN/STARCH FERMENT FILTRATE in the International Nomenclature Cosmetic Index.

The irradiation is provided by a simplest LED lamp, capable to emit light radiations at 630nm.

The times of exposure to irradiation is calculated on the basis of the intensity and severity of the folliculitis itself, and so, for all cases where the bacterial assault is the only responsible (confiding on the dermatologist's judgement or in same extreme case on the histological report, when available) 10 minutes/day of exposure is suggested for 2 weeks, while in all cases which by the Satter's method (the KOH inspection) is possible to detect a fungal infection, 20 minutes of irradiation pro day are suggested [6,7].

Satter's method (idest the KOH inspection) is based on the deposition of a sample (scare or papula picked

up from the erythematous area of the folliculitis) on a slide where a standardized KOH solution is placed in order to dissolve all the non-fungal elements, and thus by a simple examination by electronic microscope yeast cells and fungal hyphae (branching filaments) are detectable easily and an eventual gradual regression may be recorded, during and after treatment.

MATERIALS AND METHODS

We have recruited 12 volunteers, and thus:

2 (A and B) young men presenting severe folliculitis due to beard shaving.

1 (C) middle age man presenting a mild folliculitis due to beard shaving.

1 (D) streapteaseuse, who must have all legs epilated (it must be kept on account that she loves to have suppers consuming shellfishes and molluscs, food extremely rich in haemocyanins, which are photosensitizing agents).

2 (E and F) girls who love to depilate their inguinal areas.

1 (G) female clown endowed by a very delicate skin, suffering from folliculitis evoked by excessive circus make up.

2 (H and I) ripped men who like to epilate their chest, torso and axillae (it must be kept on account that Case H takes high dosages of nalidixic acid, that is a photosensitizing drug).

1 (L) transvestite who uses to epilate deeply all his body parts.

1 (M) classic dancer (young man) presenting a severe folliculitis on his buttocks cause of his ballet habillement

1 (N) middle age woman suffering from hirsutism and obliged to depilate twice a week her hirci of her axillae.

On the basis of their dermatological, histological or Satter's tests results I have traced an outline forecasting the following scores:

B1-B5 (indicating the degree of severity of the bacterial folliculitis).

F1-F5 (indicating the degree of severity of the fungal infection, determined by the Satter's method) and thus I drawn Table 1, where even the minutes of irradiation suggested are plotted:

The cosmetic system "ASPERGILLUS/GLUCOSE/SOYBEAN/STARCH FERMENT FILTRATE" to be spread onto the areas affected by folliculitis, was prepared by letting to drive a complete fermentation starting from a aqueous solution of rice starch together with soybean enzymes and *Aspergillus niger* in a cruse at pH 3.5 (by lactic acid) and 545.67 Rankine degrees for five days.

The final cosmetic item is a colourless and odourless filtrate to be spread directly onto the areas of the body that manifest rashes of folliculitis and are then destined to be irradiated by a 100W Watt Red High Power LED Light Lamp Plant Grow Growth 630nm. (Aktilite CL128), for the time requested for each of every specific case, following the values plotted in Table 1.

RESULTS

To collect results and to have the chance to demonstrate the efficacy of the treatment, the way I have chosen is the one that monitors the skin reflectance spectra using a normal spectrometer ranging from violet to green light, that is capable to determine the presence of the epidermal blood, by evaluating its intrinsic and peculiar absorbance.

Now, it is clear that blood excess, revealed by a certain type of spectrum, must be considered as an evident sign of erythema, on the other hand blood paucity, revealed by another type of spectrum, must be considered as an evident index of regression of the erythema.

To precisely determinate the general collapse of the erythematous rash in every case, I have exploited the Nielsen's method (The Norwegian Academy of Science and Letters, Oslo, 2008) [8,9], that keeps on account the main blood absorption bands that can be registered between the wavelengths 400 and 425 nm (violet light) and the wavelengths 500 and 600 nm (green light), and bands are registered as percent reflectivities.

By this way the usage of a simple spectrometer is sufficient to individuate how the different spectra recorded give information of the decrease of the epidermal blood flux, indicating the complete regression of the erythematous state of the skin itself.

The percent reflectivity (from 0.3 to 1.2%) may indicate the scarceness or the plenitude of superficial blood on epidermis, and thus each case is represented by a value expressed as percentage, from 0.3 to 1.2.

Low values (from 0.3 to 0.6) signify a dramatic decrement of the erythema, meanwhile high values (from 0.7 to 1.2) signify the presence of a frank erythema.

In Table 2 the initial and final scores (after treatment) are plotted.

It can be asserted that in every case a dramatic lowering of the symptoms of folliculitis (evidenced as collapse of skin erythematous manifestations) is really achieved, apart from two cases that are discussed in the Conclusions.

CONCLUSIONS

All the cases I have cosmetically treated presented, at the very beginning of the experimentation, divers

Table 1: Time and minutes of irradiation forecasted for each of every case, depending on the severity of the folliculitis

Case number	Type and degree of folliculitis	Time in minutes of irradiation applied in the experimentation
A	B3	10
B	B5	10
C	B1	10
D	F2	20
E	F3	20
F	F4	20
G	F2	20
H	B3	10
I	F1	20
L	F5	20
M	F3	20
N	B4	10

Table 2: The values of the percent reflectivities of volunteers' skin, at the beginning and at the end of the treatment with "ASPERGILLUS/GLUCOSE/SOYBEAN/STARCH FERMENT FILTRATE" and light

Case	Initial percent reflectivity	Final percent reflectivity
A	0.7	0.3
B	0.6	0.5
C	0.8	0.4
D	0.9	0.7
E	1.1	0.5
F	1.2	0.4
G	1.0	0.3
H	0.9	0.8
I	0.7	0.4
L	0.9	0.6
M	1.1	0.3
N	1.0	0.4

clinical pictures, regarding the presence of eventual bacterial or fungal infection and even the divers importance of the disease itself: anyway every case presented from mild to severe degrees of erythematous rashes, and this fact has elicited the possibility to calculate the real degree of regression of erythema (rubor) and thus the regression of the folliculitis as well.

It should be interesting to include even the skin colour of each individual as reference to better comprehend the real efficacy of this cosmetic treatment.

Anyway volunteers I have chosen are all white.

In a future it could be mandatory to evaluate eventual differences treating Asian or African individuals too.

It is remarkable that Case D, who likes to savour photosensitizing fishes and Case H, who uses to take nalidixic acid, seem to show discrepancies after the Nielsen's test, howbeit the complete recuperation is self evident.

REFERENCES

1. Lee JW, Kim BJ, Kim MN. Photodynamic therapy: new treatment for recalcitrant Malassezia folliculitis. *Lasers Surg Med.* 2010;42:192-6.
2. Battersby AR, Fookes CJR, Matcham GWJ, McDonald E. Biosynthesis of the pigments of life: formation of the macrocycle. *Nature.* 1980;285:17-21.
3. Leeper FJ. The biosynthesis of porphyrins, chlorophylls, and vitamin B12. *Natural Product Rep.* 1983;2:19-47.
4. Layer G, Reichelt J, Jahn D. Structure and function of enzymes in heme biosynthesis. *Protein Scien.* 2010;19:1137-61.
5. Seinosuke U. Fungal glucoamylases and raw starch digestion. *Trend Bioch Scien.* 1981;6:89-90.
6. Stollery N. Skin infections. *Practitioner.* 2014;258:32-3.
7. Bragg J, Pomeranz M. Papulopustular drug eruption due to an epidermal growth factor receptor inhibitors, erlotinib and cetuximab. *Dermatol Online J.* 2007;13:1.
8. Nielsen KP, Zhao L, Stamnesl JJ, Stamnes K, Moan J. The optics of human skin: Aspects important for human health: In: *Solar Radiation and Human Health.* Espen Bjertness Ed. 2008: Oslo: The Norwegian Academy of Science and Letters.
9. Nichols EF. A study of the transmission spectra of certain substances in the infra-red. *Phys Re.* 1893;1:1-18.

Copyright by Lorenzo Martini. This is an open access article distributed under the terms of the Creative Commons Attribution License, which permits unrestricted use, distribution, and reproduction in any medium, provided the original author and source are credited.

Source of Support: Nil, **Conflict of Interest:** None declared.

Lupus vulgaris of the auricle

Hojat Eftekhari¹, Rafiei Rana¹, Daryakar Arash², Mohammad Hosseini Maryam¹, Naji Rad Sara³

¹Skin Research Center, Guilan University of Medical Sciences, Razi Hospital, Sardare Jangal St. Rasht, Iran, ²Gastrointestinal and Liver Research Center, Guilan University of Medical Sciences, Razi Hospital, Sardare Jangal St. Rasht, Iran, ³Department of Internal Medicine, Nassau University Medical Center, 2201 Hempstead turnpike, East Meadow, NY, 11554, USA

Corresponding author: Rana Rafiei, MD., E-mail: rafieirana@yahoo.com

ABSTRACT

Nowadays despite decrease in the tuberculosis (TB) incidence around the world with standard anti tubercular treatment, atypical forms of TB is increasing due to extensive use of immunosuppressive therapy for autoimmune diseases and increasing prevalence of HIV infection, so early diagnosis of pulmonary and extra pulmonary TB in these patients is very important. Cutaneous TB could be a great imitator and confused with other granulomatous lesions. It has different morphological patterns. Lupus vulgaris (LV) is the most common type of cutaneous TB which usually involves head and neck. We present herein a case of LV in auricular region without apparent systemic involvement.

Key words: Tuberculosis; Lupus vulgaris; Auricle

INTRODUCTION

Approximately 1%-2% of all cases of TB are cutaneous TB [1]. Considerable morphological variation in clinical presentation of cutaneous TB, difficulty in mycobacterium culture and even negative results using polymerase chain reaction (PCR) in paraffin-embedded specimens could result in delayed diagnosis of cutaneous TB [2]. Lupus vulgaris is the most common type of cutaneous TB often presents as an asymptomatic, slow growing plaque on the face [3]. LV could be complicated by scarring and deformity so we should consider it in any granulomatous lesions on the skin [4].

CASE REPORT

We present herein a 51-year old farmer woman with erythematous pruritic lesions over the right auricular region of one year duration. There were erythematous, scaly and infiltrated plaques on the auricle and periauricular area. The lesions initially manifested on the retro-auricular region and gradually involved whole ear and periauricular area. Diascopy revealed

an “apple-jelly” color (Fig. 1a and b). Skin biopsy was taken from the ear lobe with considering sarcoidosis, lupus vulgaris, leprosy, leishmaniasis, deep mycosis and discoid lupus erythematosu as differential diagnosis. Histopathologic changes were flattened epidermis with confluent tuberculoid type granuloma in the upper and mid dermis included langhans type giant cell and small foci of fibrinoid necrosis (Figs. 2a-c). No acid fast bacillus or fungal element was identified in Ziehl-Neelsen and Periodic Acid Schiff (PAS) staining which was in favor of lupus vulgaris. Polymerase chain reaction (PCR) study in paraffin block was negative for mycobacterium tuberculosis.

In physical examination there was no lymphadenopathy, neural thickening or sensory changes. She had no weight loss, night sweats, fever, cough, and hemoptysis. She had Bacillus Calmette-Guerin (BCG) vaccination scar on her left arm but there was not any other skin lesion. Ritual ear piercing had been done in childhood but she did not remember any other trauma to the auricular region.

Past medical and drug histories were unremarkable. Family history was positive for pulmonary TB in her

How to cite this article: Eftekhari H, Rana R, Arash D, Maryam MH, Sara NR. Lupus vulgaris of the auricle. Our Dermatol Online. 2017;8(1):31-33.

Submission: 15.05.2016; **Acceptance:** 23.07.2016

DOI:10.7241/ourd.20171.07

mother which was treated with anti-tuberculosis therapy (ATT) when our patient was a child. Her mother died of car accident a few years ago.

There were no abnormal findings in chest x ray and laboratory data including complete blood count (CBC), basic metabolic panel (BMP), liver function test (LFT), erythrocyte sedimentation rate (ESR), C-reactive protein (CRP), angiotensin converting enzyme (ACE) level and urine analysis. The purified protein derivative (PPD) test was positive (25×20 millimeters induration with vesicle formation) after 48 hours and subsequently an edematous, erythematous, scaly plaque formed over the injection site (Fig. 3). We could not be able to rule out visceral tuberculosis in this patient so standard ATT was started.

DISCUSSION

TB is still a problem in the developed and underdeveloped countries and cutaneous TB is a small part of extra pulmonary forms [1]. The most common type of cutaneous TB is named lupus vulgaris which indicates destructive behavior of the disease (in Latin lupus means wolf). It usually affects females more than males and could be presented as plaque, nodule, ulcer, mutilating and vegetative lesions [3,5]. LV occurs on the face, ear, neck and less common extremities and trunk [6]. LV often develops by hematogenous spread of mycobacterium (endogenous type) especially in case of facial involvement but also lymphatic, contagious spread and acquired exogenous inoculation after BCG vaccination, body piercing or tattooing have been reported [6-8]. It may be confused with other granulomatous lesions or even masquerading hemangioma, psoriasis, lichen simplex, discoid lupus erythematosus and alopecia [4]. Due to high degree immunity against mycobacterium in LV patients, bacilli are rarely seen on acid fast staining and cultures are frequently negative [6,9]. Positive PPD test is observed in a subject who has a history of BCG vaccination or previous mycobacterial infection so this test is not reliable for diagnosis of LV but in our patient a LV-like plaque developed on the site of PPD test.

Absolute criteria for cutaneous TB are positive culture of mycobacterium tuberculosis or DNA identification by PCR [5]. Negative PCR result in paraffin block does not rule out cutaneous TB because formalin fixation has been found to decrease the PCR amplification signal, so a fresh specimen for PCR has been recommended [2].

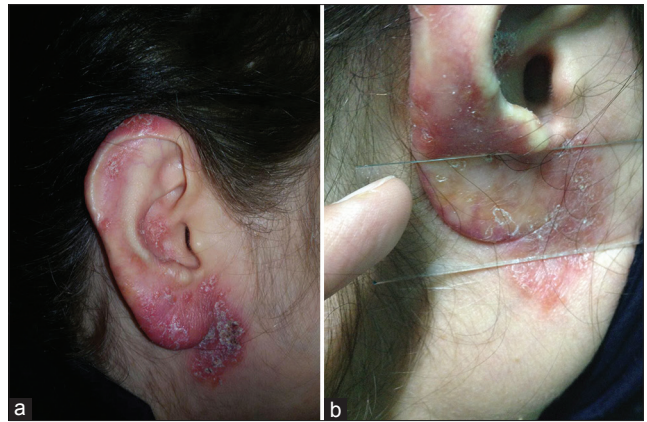

Figure 1: (a) Brown-reddish infiltrated scaly plaques on the auricle and periauricular area, (b) Diascopic examination showing the presence of light-brownish or “apple jelly” colored nodules.

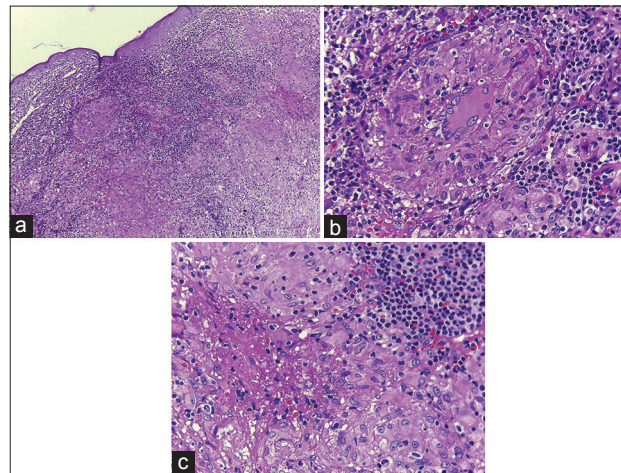


Figure 2: (a) Photomicrograph showing confluent non-caseating tuberculoid granuloma in the upper and mid dermis suggestive of lupus vulgaris (H&E, original magnification × 10). (b) Photomicrograph showing tuberculoid granuloma consisting of lymphocytes, epithelioid cells and Langhans giant cells. (c) and small foci of fibrinoid necrosis. (H&E, original magnification × 40).

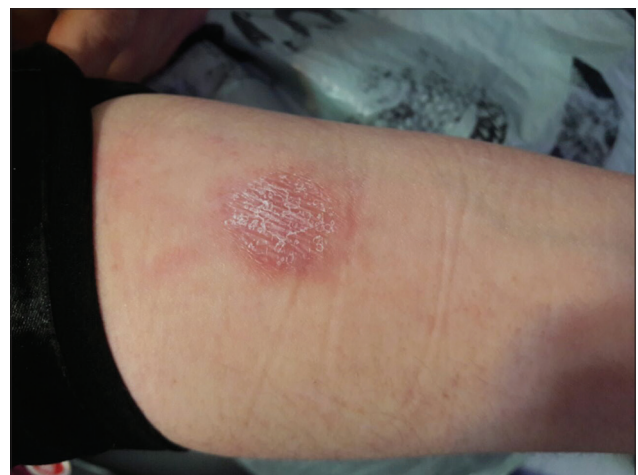

Figure 3: An edematous, erythematous, scaly plaque formed over the injection site of PPD test.

In this case PCR study was done on formalin fixed tissue.

Association between LV and clinically undiagnosed visceral tuberculosis is not uncommon [10], so we advised our patient to receive standard ATT for visceral TB and the treatment is still ongoing. Delayed diagnosis of cutaneous TB results in deformity, contracture, lymphedema and increasing rate of squamous or basal cell carcinoma, hence early diagnosis is very important.

In conclusion, we should keep in mind cutaneous TB as a differential diagnosis for any chronic granulomatous skin lesions to prevent these complications and in some cases where PCR and culture are not helpful, a therapeutic trial of ATT has been recommended [4].

REFERENCES

1. Bravo F, Gotuzzo E. Cutaneous tuberculosis. *Clin Dermatol.* 2007;25:173-80.
2. Okazaki M, Sakurai A. Lupus vulgaris of the earlobe. *J Ann Plast Surg.* 1997; 39:643-6.
3. Senol M, Ozcan A, Mizrak B, Turgut AC, Karaca S, Kocer H. A case of lupus vulgaris with unusual location. *J Dermatol.* 2003;30:566-9.
4. Saritha M, Parveen BA, Anandan V, Priyavathani MR, Tharini KG. Atypical forms of lupus vulgaris - a case series. *Int J Dermatol.* 2009;48:150-3.
5. Thomas S, Suhas S, Pai KM, Raghu AR. Lupus vulgaris-report of a case with facial involvement. *Br Dent J.* 2005;198:135-7.
6. Wozniacka A, Schwartz RA, Sysa-Jedrzejowska A, Borun M, Arkuszewska C. Lupus vulgaris: report of two cases. *Int J Dermatol.* 2005;44:299-301.
7. Khandpur S, Reddy BS. Lupus vulgaris: unusual presentations over the face. *J Eur Acad Dermatol Venereol.* 2003;17:706-10.
8. Ghorpade A. Tattoo inoculation lupus vulgaris in two Indian ladies. *J Eur Acad Dermatol Venereol.* 2006;20:476-7.
9. Hofman V, Selva E, Landraud L, Sicard D, Venissac N, Castillo L, et al. Value of PCR amplification from formalin-fixed paraffin-embedded tissues in the diagnosis of Mycobacterium tuberculosis infection. *Ann Pathol.* 2003;23:206-15.
10. Marcoval J, Servitje O, Moreno A, Jucgla A, Peyri J. Lupus vulgaris. Clinical, histopathologic, and bacteriologic study of 10 cases. *J Am Acad Dermatol.* 1992;26:404-7.

Copyright by Hojat Eftekhari, et al. This is an open access article distributed under the terms of the Creative Commons Attribution License, which permits unrestricted use, distribution, and reproduction in any medium, provided the original author and source are credited.
Source of Support: Nil, **Conflict of Interest:** None declared.

Malignant melanoma arising in congenital melanocytic nevi: clinical and dermoscopic challenges

Fatma Pelin Cengiz, Nazan Emiroglu, Anil Gulsel Bahali, Ozlem Su, Nahide Onsun

Department of Dermatology, Bezmialem Vakif University, Istanbul, Turkey

Corresponding author: Dr. Fatma Pelin Cengiz, E-mail: fpelinozgen@hotmail.com

ABSTRACT

Congenital melanocytic nevi (CMN) are visible pigmented lesions in the skin that are present at birth. CMN are benign malformations resulting from defective development of melanocyte precursors in the embryo. Six MMs from six patients were analyzed by clinical and dermoscopic examination. Of the patients, 33.3% were female (N = 2) and 66.6% were male (N = 4). Of the MMs, four (66.6%) were superficial spreading MM and two (33.3%) were in situ MM. A reticular pattern was present in the MMs of three patients (50%), a homogeneous pattern was present in the other patients (50%) at the base of the MMs. Superficial spreading melanomas and in situ melanomas with atypical dots and globules and a blue-white veil were the most common dermoscopic features of MMs found in CMN.

Key words: Melanoma; Dermoscopy; Nevi

INTRODUCTION

Congenital nevi result from a proliferation of benign melanocytes in the dermis or epidermis or both. Congenital nevi may develop during the first two years of life if they are not apparent at birth [1]. These lesions are described as ‘congenital nevus-like nevi’ or ‘tardive congenital nevi’ by some authors [2]. Congenital nevi are present in 1:20000 of newborn infants [3].

There is a low risk of developing malignant melanoma (MM) in small to medium CMN. Up to 1% of patients with small or medium CMNs will develop MM over a lifetime [3]. Our aim was to investigate the dermoscopic patterns of MM that developed in congenital melanocytic nevi (CMN) to identify specific dermoscopic features.

CASE REPORTS

Six patients at the Department of Dermatology at Bezmialem Vakif University Hospital in Istanbul over five years were recruited for the study. Essential inclusion criteria were the presence of MM and the ability of the participants to state with certainty

whether MM arose on a small or medium nevus that was present at birth or that appeared during the first two years of life. Dermoscopic images of all lesions were acquired at a 30X magnification and were stored in a digital imaging system (Fotofinder, Digital Dermoscopy).

Dermoscopic patterns were classified as reticular, globular, cobblestone, or homogeneous. A small congenital nevus was defined as having a diameter of less than 1.5 cm, and a medium congenital nevus was defined as having a diameter of more than 1.5 cm but less than 20 cm.

A descriptive analysis of the sample set was performed, which included calculation of percentages for categorical variables.

Clinical and dermoscopic examinations were performed on six patients.

Descriptive Results

There were four male patients (66.6%) and two female patients (33.3%) whose ages ranged from 40 to 82 years.

How to cite this article: Cengiz FP, Emiroglu N, Bahali AG, Su O, Onsun N. Malignant melanoma arising in congenital melanocytic nevi: clinical and dermoscopic challenges. Our Dermatol Online. 2017;8(1):34-36.

Submission: 04.05.2016; **Acceptance:** 21.06.2016

DOI:10.7241/ourd.20171.08

The mean age of the patients was 55 ± 7 years. One patient had MM on the shoulder, one patient had MM on a limb, three patients had MM on the back, and one patient had MM on the forearm. Of the MMs, four developed on medium nevi and two developed on small nevi.

Changes in nevus were reported over the past six months (two patients), one year (one patient), two years (two patients), and five years (one patient).

Dermoscopic Patterns

On dermoscopic examination, we found the presence of a reticular pattern (50%; N = 3) and a homogeneous pattern (50%; N = 3) (Fig. 1). Perifollicular hypopigmentation, milia-like cysts, an atypical pigment network and radial streaks were present in one MM (16.6%) (Fig. 2). Hypertrichosis and focal hypopigmentation were not observed in any lesion. Atypical dots and globules, blue-white veil were observed in three MMs (50%) (Fig. 3). Regression and atypical vascular structures were present in one MM (16.6%).

DISCUSSION

The congenital melanocytic nevus presents as a circumscribed, light brown to black patch or plaque, heterogeneous in consistency, covering any size and any part of the body. Most instances of small CMN usually appear during childhood or puberty [4]. Large CMN have a higher risk of developing MM than small and medium nevi. MM arising in CMN usually develop at younger ages and are located superficially within small or medium CMN and deep within large CMN. Two important meta-analyses were conducted to determine the relationship between the size of CMN and future development of MM [5,6]. In one of these studies, ten of the 432 patients developed MM within their giant congenital nevi. Krenzel *et al.* analyzed 14 studies with a combined 6,571 CMN patients who were followed for 3.4–23.7 years and found that 46 (0.7%) patients developed a total of 49 MMs (mean age at diagnosis: 15.5 years; median age: 7 years). The authors found an increased relative risk of developing MM during childhood and adolescence [6].

Many of the nevi termed ‘dysplastic’ or ‘atypical’ are actually small CMN [4]. Multiple CMN may reflect a mosaic RASopathy as a result of postzygotic activating mutations in NRAS [7], and patients with small

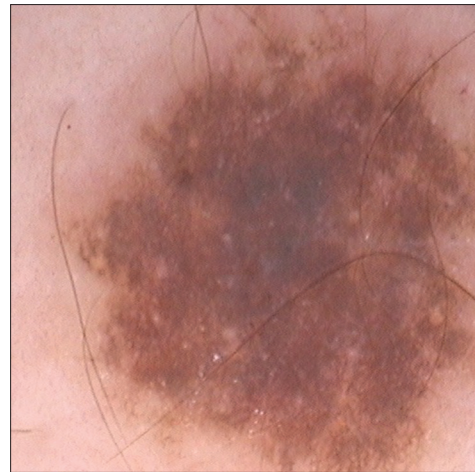

Figure 1: Atypical network, milia-like cysts, perifollicular hypopigmentation.

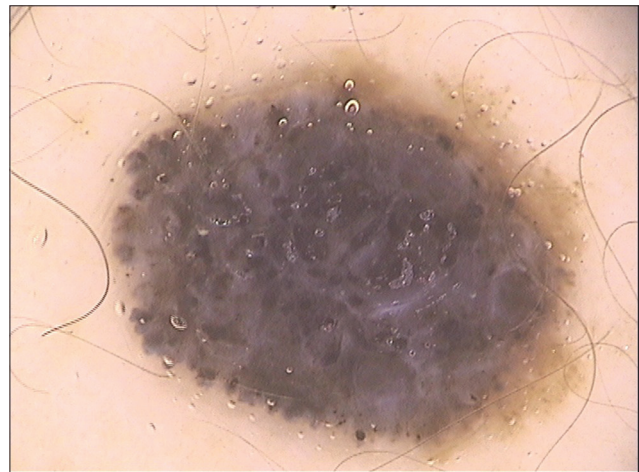

Figure 2: Spitzoid pattern, black structureless area.

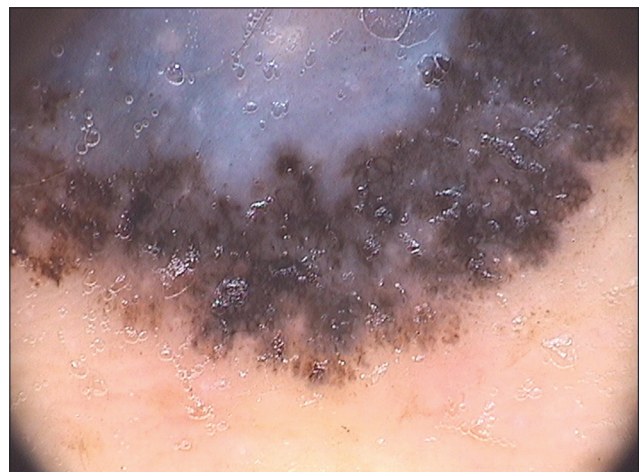

Figure 3: Radial streaks, blue-white veil, atypical dots.

CMN have a higher risk of MM. The lifetime risk of developing MM is estimated to be 1 in 100 for patients with small and medium CMN [8]. Annual clinical and digital dermoscopic examination is indicated for these

patients. Therefore, the physician should know the dermoscopic features of CMN to avoid unnecessary excisions, and to recognize MM when it begins to develop.

One patient, who attended follow-up visits for annual dermoscopic examinations at our clinic, was concerned about pigmentary changes in his nevus as he was diagnosed with in situ MM. The other patients also attended our outpatient clinic for examination of the changes in their nevi. The patients whose nevi had Breslow thickness of 6.12 mm and 13.73 mm died within the first year after diagnosis.

Although rare, the occurrence of MM in small congenital nevi has been described in adults and children [9,10]. To the best of our knowledge, the work reported herein is the first case series describing patients with MM that developed in small or medium congenital nevi.

Atypical dots and globules and a blue-white veil were the most common dermoscopic features of CMN found in our study:

- Superficial spreading MM and in situ MM were the only types of MM found in the six CMN patients examined;
- The dermoscopic features of CMN that developed MM were reticular and homogeneous patterns;
- The dermoscopic features of MM that developed in CMN were atypical dots and globules, and a blue-white veil; and
- The results may help to define accurately the dermoscopic features of congenital melanocytic nevi.

ACKNOWLEDGMENTS

We thank our patients, who were essential to this work, for their participation.

REFERENCES

1. Marghoob AA. Congenital melanocytic nevi. Evaluation and management. *Dermatol Clin.* 2002;20:607-16.
2. Makkar HS, Frieden IJ. Congenital melanocytic nevi: an update for the pediatrician. *Curr Opin Pediatr.* 2002;14:397-403.
3. Alikhan A, Ibrahim OA, Eisen DB. Congenital melanocytic nevi: where are we now? Part I. Clinical presentation, epidemiology, pathogenesis, histology, malignant transformation, and neurocutaneous melanosis. *J Am Acad Dermatol.* 2012;67:495.e1-17 [quiz: 512-4].
4. Kittler H, Rosendahl C, Cameron A, Tschandl P. *Dermatoscopy. An algorithmic method based on pattern analysis.* 2011 Edition.P:29-35.
5. Watt AJ, Kotsis SV, Chung KC. Risk of melanoma arising in large congenital melanocytic nevi: a systematic review. *Plast Reconstr Surg.* 2004;113:1968-74.
6. Krenzel S, Hauschild A, Schäfer T. Melanoma risk in congenital melanocytic nevi: a systematic review. *Br J Dermatol.* 2006;155:1-8.
7. Waelchi R, Williams J, Cole T, Dattani M, Hindmarsh P, Kennedy H, et al. Growth and hormonal profiling in children with congenital melanocytic nevi. *Br J Dermatol.* 2015;173:1366-7.
8. Sahin S, Levin L, Kopf AW, Rao BK, Triola M, Koenig K, et al. Risk of melanoma in medium-sized congenital melanocytic nevi: a follow-up study. *J Am Acad Dermatol.* 1998;39:428-33.
9. Betti R, Inselvini E, Vergani R, Crosti C. Small congenital nevi associated with melanoma: Case reports and considerations. *J Dermatol.* 2000;27:583-90.
10. Zangari A, Ilari M, Nino F, Ascanio M. Report of a malignant melanoma arising in a small congenital nevus in a 3-year-old child. *J Indian Assoc Pediatr Surg.* 2013;18:165-6.

Copyright by Fatma Pelin Cengiz, et al. This is an open access article distributed under the terms of the Creative Commons Attribution License, which permits unrestricted use, distribution, and reproduction in any medium, provided the original author and source are credited.

Source of Support: Nil, **Conflict of Interest:** None declared.

Cutaneous sporotrichosis as an occupational disease: Case report

César Bimbi^{1,2}, Piotr Brzezinski^{3,4}

¹Brazilian Society of Dermatology, ²Institute of Dermatology, Centro Historico, Porto Alegre, Brazil, ³Department of Cosmetology, Institute of Biology and Environmental Protection, Pomeranian Academy, Slupsk, Poland, ⁴Department of Dermatology, 6th Military Support Unit, Ustka, Poland

Corresponding author: Dr. César Bimbi, E-mail: cbimbi@terra.com.br

ABSTRACT

Subcutaneous mycoses are not rare in Latin America. In Brazil, sporotrichosis was once almost exclusively found in rural areas, but in recent years it changed its profile and has been more frequent among urban adults. Cutaneous sporotrichosis is acquired from saprophytic dimorphic fungus *Sporothrix schenckii* usually found in soil, vegetation, and especially decaying organic matter in tropical, subtropical, and humid environments through cutaneous inoculation. The fungus abundantly grows on dead wood. Sporotrichosis is a health hazard present in florists, gardeners and other urban professions in contact with plants and the infection is increasingly seen as an occupational disease. The patient had been hurt in the finger by a thorn of Bouganvillea tree and a primary ulcer started.

Key words: Sporotrichosis; Occupational; Thorn cut

INTRODUCTION

Sporotrichosis is a subcutaneous mycosis subacute or chronic evolution, caused by the dimorphic *Sporothrix* complex, which includes five species: *Sporothrix albicans*, *Sporothrix brasiliensis*, *Sporothrix globosa*, *Sporothrix Mexicana* and *Sporothrix schenckii* (sensu stricto). The infection occurs after trauma with contaminated material, which inoculated the fungus on the skin. The clinical types of sporotrichosis are lymphocutaneous sporotrichosis, fixed cutaneous (nodulopapular, ulcerative, verrucouse and furunculoide) and extracutaneous [1,2].

CASE REPORT

An otherwise healthy 40 years old man resident in the metropolitan area of Porto Alegre, southern Brazil, came to the office with a history of a 3 weeks ulcerated lesion in the index finger of the right hand and a wrist nodosity. The patient had been hurt in the finger by a thorn of Bouganvillea tree (Fig. 1) and a primary ulcer

started (Fig. 2). The primary lesion developed at the index finger, that was the site of inoculation, and it was followed some days later by subcutaneous nodules on the wrist that progressed along lymphatic channels. His profession was a condominium caretaker and he was in charge of gardening services. The mycological culture showed leathery wrinkled colonies progressively darker typical of *Sporothrix schenckii*. All lesions resolved after treatment with oral itraconazole 200 mg/d. The treatment usually lasts for 3-6 months (Fig. 3).

DISCUSSION

The lymphocutaneous form is the classical presentation of sporotrichosis. The primary lesion develops at the site of skin inoculation, commonly hands and arms. After some days to weeks it progresses to nodules along the lymphatic tract [2]. Patients are otherwise healthy, afebrile and well. Self-healing cases sometimes happen. Antibiotics are commonly prescribed in this phase as it mimics staphylococcal infections. When left untreated

How to cite this article: Bimbi C, Brzezinski P. Cutaneous sporotrichosis as an occupational disease: Case report. Our Dermatol Online. 2017;8(1):37-39.

Submission: 30.05.2016; **Acceptance:** 06.08.2016

DOI:10.7241/ourd.20171.09



Figure 1: Bougainvillea tree and a thorn of ornamental Bougainvillea tree.

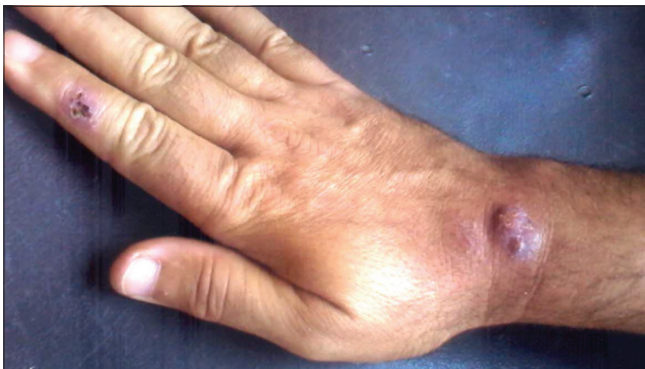

Figure 2: The primary lesion developed at the index finger, as a site of inoculation, and subcutaneous nodules on the wrist as a progressed along lymphatic channels some days later.

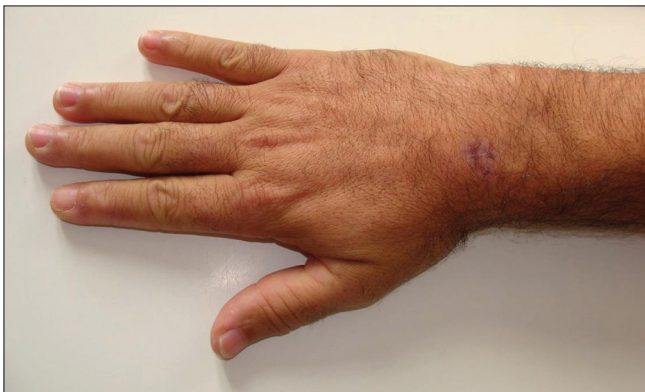

Figure 3: After treatment with oral itraconazole 200 mg/d.

it follows a chronic course although the ulcerated inoculative lesion may heal spontaneously.

Fixed and disseminated forms are other rarer cutaneous variants.

Systemic sporotrichosis is the result of conidia inhalation or hematogenous dissemination from primary sites but

is also rare. In a large outbreak that occurred in gold mines of South Africa in more than 3000 miners, none of them had disseminated disease. Pulmonary sporotrichosis via inhalation of *Sporotrichum* displays a form radiographically indistinguishable from tuberculosis and histoplasmosis in patients with severe underlying chronic obstructive pulmonary disease and alcoholism [2,3]. Granulomatous tenosynovitis and carpal tunnel syndrome have also been described [4]. Osteoarticular sporotrichosis may result from direct inoculation or hematogenous disseminated *S. schenckii*, with an involvement of multiple visceral organs; this occurs almost exclusively in persons with AIDS.

The hyperendemicity areas of certain countries and high numbers in certain populations are still unexplained. Before the Great War, many cases of the disease occurred in France but after a while, the incidence declined abruptly.

Peruvian Andes villages show the incidence of sporotrichosis as approximately 1 case per 1000 people. Epidemics have been described in western Australia, China and the large outbreak occurred in gold mines of South Africa in more than 3000 miners who had frequent physical contact with wood timber supports. In Uruguay, armadillo hunting is a high-risk activity [5].

The fungus *S. schenckii* grows abundantly on dead wood but it has never been observed as plant pathogens, probably due to the antifungal activity of plants. The fungus grew best on *Acacia melanoxylon*, *Cinnamomum camphora*, *Eucalyptus grandis*, *E. sideroxylon*, and *Ginkgo biloba* [6,7]. This patient had been hurt while trimming Bougainvillea spp. It is a tree native to Brazil and is a fast-growing plant that creates a colorful barrier - are perennials with profuse and blooms and rapid growth and prized for security features because of sharp thorns that can easily pierce through the fabric and into bare skin. Must be regularly trimmed to prevent it from growing out of control.

In Brazil in the 50`s, 93% of sporotrichosis patients were from rural areas [8], but lately the disease changed its profile and is becoming more frequent among urban adults and as an occupational disease. Decaying vegetable matter of high humidity areas with temperatures between 16 and 20oC seem to be the ideal conditions for the fungus proliferation. Splinter and thorns are favorite habitats and favor the growth of fungus. Florists, gardeners, forestry workers, miners and people who deal with soil are workers at greatest risk.

Domestic cats are frequent transmitters, by scratch. Also but rarely, cattle, dogs, horse, camel, swine, rat, mouse, lizard, chimpanzee and dolphin have been described.

Antifungal therapy is the mainstay of treatment for all forms of sporotrichosis. Itraconazole is the best drug for cutaneous sporotrichosis. Heat application to lesions may help since low temperatures are preferred by the fungus.

Wearing gloves and other protective clothing when gardening or handling animal especially cats are necessary as preventive methods against the infection.

REFERENCES

1. Ramírez Soto MC. Facial Sporotrichosis in children from endemic area in Peru. *Our Dermatol Online*. 2013;4:237-40.
2. Marques GF, Martins AL, Sousa JM, Brandão LS, Wachholz PA, Masuda PY. Characterization of sporotrichosis cases treated in a dermatologic teaching unit in the state of São Paulo - Brazil, 2003 - 2013. *An Bras Dermatol*. 2015;90:273-5.
3. Queiroz-Telles F, Nucci M, Colombo AL, Tobón A, Restrepo A. Mycoses of implantation in Latin America: an overview of epidemiology, clinical manifestations, diagnosis and treatment. *Med Mycol*. 2011;49:225-36.
4. Watanabe M, Hayama K, Fujita H, Yagoshi M, Yarita K, Kamei K, et al. A Case of sporotrichosis caused by *sporothrix globosa* in Japan. *Ann Dermatol*. 2016;28:251-2.
5. Lyon GM, Zurita S, Casquero J, Holgado W, Guevara J, Brandt ME, et al. Population-based surveillance and a case-control study of risk factors for endemic lymphocutaneous sporotrichosis in Peru. *Clin Infect Dis*. 2003;36:34-9.
6. Mahajan VK. Sporotrichosis: an overview and therapeutic options. *Dermatol Res Pract*. 2014;2014:272376.
7. Almeida-Paes R, de Oliveira MM, Freitas DF, do Valle AC, Zancopé-Oliveira RM, Gutierrez-Galhardo MC. Sporotrichosis in Rio de Janeiro, Brazil: *Sporothrix brasiliensis* is associated with atypical clinical presentations. *PLoS Negl Trop Dis*. 2014;8:e3094.
8. Almeida F, Sampaio Sap Lacaz CS, Fernan-Des JC – [Statistical data on sporotrichosis; analysis of 344 cases]. *An Bras Dermatol Sifil*. 1955;30:9-12.

Copyright by César Bimbi, et al. This is an open access article distributed under the terms of the Creative Commons Attribution License, which permits unrestricted use, distribution, and reproduction in any medium, provided the original author and source are credited.
Source of Support: Nil, **Conflict of Interest:** None declared.

Methotrexate for refractory prurigo nodularis

Mariam Al Zaabi¹, Mohammad Al Suwajji², Manal Nasir³

¹Department of Dermatology and Venereology, Mafraq Hospital, Abu Dhabi, United Arab Emirates, ²Medical Student, Faculty of Medicine and Health Science, UAE University, Al Ain, United Arab Emirates, ³Medical Student, Faculty of Medicine and Health Science, Sharjah University, Sharjah, United Arab Emirates

Corresponding author: Dr. Mariam Al Zaabi, E-mail: dr_mariam01@hotmail.com

ABSTRACT

Prurigo nodularis (PN) is chronic unbearable inflammatory skin disease. Although it was described before a century, not many studies have been conducted regarding the systemic treatment of prurigo nodularis. A 64-year-old male patient has moderate to severe atopic dermatitis superimposed by disseminated pruritic nodules over the trunk and extremities. In spite of topical treatment and Phototherapy, patient condition was deteriorating. Therefore, the patient was treated with multimodalities including high potency topical steroid, intravenous antihistamine, cyclosporine and omalizumab without improvement. Thus the patient has been treated with methotrexate which led to remarkable improvement. Management of prurigo nodularis is often challenging as the etiology of PN in the majority of the cases is unknown. Conservative treatments are often inefficient. This case proves the efficacy of methotrexate in the management of prurigo nodularis.

Key words: Refractory prurigo; Methotrexate; Pruritic nodules; Systemic therapy

INTRODUCTION

Prurigo nodularis PN is chronic intolerable inflammatory skin disease. It results from chronic pruritus. The term prurigo is Latin and means itching. PN was initially described by J.N. Hyde on 1909. Although it was described before 105 years, still the pathogenesis unclear and not many studies have been conducted regarding the systemic treatment of prurigo nodularis. The diagnosis and therapy of chronic pruritus and prurigo nodularis require multidiscipline [1].

CASE REPORT

A 64-year-old male patient has moderate to severe atopic dermatitis since 2007, and had been treated for a long time with topical and systemic steroids as well as topical calcineurin inhibitor such as pimecrolimus and tacrolimus, which lead to transit improvement in patient's condition. However, 2 years later patient developed disseminated pruritic nodules over the trunk and extremities. Clinically and histologically the diagnosis of prurigo nodularis has been established.

He was treated with high potency topical steroid and oral antihistamines medication without improvement. Intralesional injection of triamcinolone did not show any benefit. Thus patient was intensively investigated, his complete blood count test (CBC) was not significant, his urea and electrolytes as well as creatinine levels were within normal limits. His liver enzymes were normal. Thyroid function test (TFT) was not significant. Total IgE was 769 which is high whereas specific IgE were irrelevant. Prick test for pollen and food allergen and standard patch test were insignificant. Autoimmune antibodies including ANA, Pemphigus and Pemphigoid and Duhring antibodies have been investigated and were negative. CD4/CD8 ratio was normal.

In spite of topical treatment as well as Phototherapy (including UVB and PUVA), patient's condition was deteriorating. Therefore, the patient was treated with multimodalities including high potency topical steroid, intravenous antihistamine and cyclosporine. However, cyclosporin has been ceased due to uncontrolled hypertension and unbearable gastrointestinal symptoms. Moreover, his symptoms were reluctant to the systemic

How to cite this article: Al Zaabi M, Al Suwajji M, Nasir M. Methotrexate for refractory prurigo nodularis. Our Dermatol Online. 2017;8(1):40-42.

Submission: 30.03.2016; **Acceptance:** 31.05.2016

DOI:10.7241/ourd.20171.10

therapy with omluzimumab. Thus the patient has been treated with methotrexate 15mg subcutaneous weekly, remarkable improvement has been noticed 3 months following the onset of treatment. Consequently the dose of Methotrexate was gradually reduced, and then discontinued following complete resolution of the pruritus and prurigo nodules (Figs. 1 and 2).

DISCUSSION

Definition

Prurigo nodularis is chronic enervating inflammatory skin disorder that may affect the entire body. This disease can occur in all age groups but it primarily affects adults. The exact etiology of prurigo nodularis is still unknown. It results from chronic scratching due to many etiologies, such as dermatological disorders as xerosis or atopic dermatitis and systemic diseases for instance hyperthyroidism, hepatic or renal dysfunction,

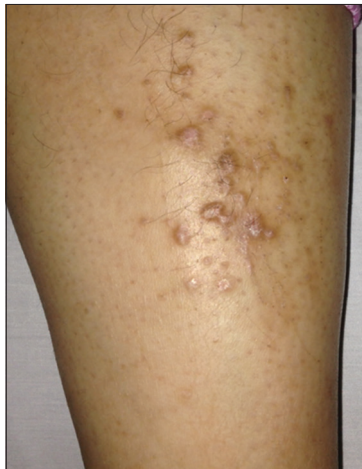


Figure 1: Before treatment with methotrexate.

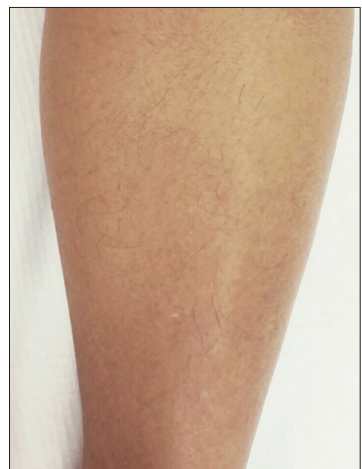

Figure 2: 8 months following discontinuation of methotrexate.

Lymphoma and iron deficiency. Emotional distress and psychological illnesses are also common contributing factors [2-4].

The lesions of prurigo nodularis vary in quantity and morphology. The eruption can be erythematous, brown or skin color. The lesions present usually in hard dome shaped, papular or nodular appearance that are excoriated and have central scale or crust. Those nodules present in a symmetric distribution with predominance on the extensor surfaces of the upper and lower limbs. Prurigo nodularis can be diagnosed clinically as it has characteristic morphology. Beside that histological investigation is a useful confirmatory diagnostic tool. Further investigations to rule out any underlying systemic causes of pruritus are crucial such as CBC, liver function test, and creatinine and TFT [4-7].

Pathogenesis

The exact pathophysiology of PN is not totally clear. Recent studies proposed neurogenic mechanisms as dermal hyperplasia and epidermal hypoplasia of sensory nerve fibers have been documented. This supported by effectiveness of thalidomide or even gabapentin in the management of PN. In addition, higher levels of the novel pruritic cytokine IL 31 were recently found in the skin of patients with prurigo nodularis than other pruritic skin disease. Moreover, latest studies have revealed that mast cells play a crucial role in the genesis of pruritus in PN. It has been observed that mast cells in PN lesions present in an abundant quantity adjacent to peripheral nerves in patients with PN and have distinctive morphology such as an enlarged cell body and a dendritic shape compared with the round or elongated figure observed in the normal skin. The PN mast cells also have an abundant cytoplasm with a reduced amount of granules, proposing that many of the granules have been released into the surrounding tissue. Mast cells in PN have been observed to produce more nerve growth factor (NGF) in the lesional skins leading to neural hyperplasia. Subsequently, this neural hyperplasia leads to intense pruritus. Apart from neural hyperplasia, there are other mast cell products that may contribute to pruritus in PN; these include histamine, tryptase, prostaglandins, and interleukins. Thus the pathogenesis of PN seems to be regulated by immunological neuronal plasticity [7-9].

Treatment

Prurigo nodularis is often refractory to various therapeutic regimens. Optimal skin hydration through

regular use of emollients is the mainstay of treatment in pruritus, as emollients enhance the skin barrier function and prevent entry of irritants. The topical treatments of PN include antipruritic agent such as menthol and anesthetic agent such as pramoxine. Topical capsaicin and calcipotriol have been reported as effective therapies. Potent and super-potent corticosteroid can also be effective due to their anti-inflammatory properties. Intralesional corticosteroids such as dexamethasone or triamcinolone suspensions may be effective but they are unpractical if there are numerous lesions. Cryotherapy has been used but depigmentation and scarring can occur. For disseminated lesions, phototherapy with UVB or PUVA can be administered. Systemic treatments used for PN includes antihistamine medication, anti-depressants such as amitriptyline or doxepin, oral steroids and naltrexone. In severe refractory cases cyclosporine, azathioprine, methotrexate, thalidomide and Immunoglobulin has been reported as efficient [10,11].

Methotrexate is a folic acid antagonist commonly used in the management of inflammatory, autoimmune and malignant disorders. The anticancer property of MTX is well described; it suppresses the key enzymes in the biosynthesis of purines and pyrimidines, thereby reducing malignant cell proliferation and turnover. Besides that, it has anti-inflammatory effect but it is poorly understood. The most probable anti-inflammatory effect of MTX is enhanced extracellular concentrations of adenosine which has potent anti-inflammatory activity. Adenosine interferes with pro-inflammatory consequences of classical macrophage activation, leading to suppression of cytokine/chemokine production such as IL6, IL12, tumor necrosis factor TNF and interferon γ . In addition, recruitment and activation of Neutrophils is impaired by Adenosine. This elucidates the efficiency of MTX in the management of atopic dermatitis and its associated PN [8,9,12].

CONCLUSION

Management of prurigo nodularis is often challenging as the etiology of PN in the majority of the cases is

unknown. Conservative treatments such as topical corticosteroids antipruritic agents and phototherapy are often inefficient. This case proves the efficacy of methotrexate in the management of prurigo nodularis, however further studies should be conducted to assess the long term effectiveness of MTX in different age groups.

Consent

The examination of the patient was conducted according to the Declaration of Helsinki principles.

REFERENCES

1. Ständer S, Mettang T. Prurigo nodularis: A puzzle for more than 100 years. *Hautarzt*. 2014;65:672-3.
2. Schedel F, Schürmann C, Metz D, Ständer S. Prurigo. Clinical definition and classification. *Hautarzt*. 2014;65:684-90.
3. Fostini A, Girolomoni G, Tessari G. Prurigo nodularis: an update on etiopathogenesis and therapy. *J Dermatology Treat*. 2013;24:458-62.
4. Mettang T, Vonend A, Raap U. Prurigo nodularis: its association with dermatoses and systemic disorders. *Hautarzt*. 2014;65:697-703.
5. Böhme T, Heitkemper T, Mettang T, Phan NQ, Ständer S. Clinical features and prurigo nodularis in nephrogenic pruritus. *Hautarzt*. 2014;65:714-20.
6. Tan WS, Tey HL. Extensive prurigo nodularis: characterization and etiology. *Dermatology*. 2014;228:276-80.
7. Raap U, Günther C. Pathogenesis of prurigo nodularis. *Hautarzt*. 2014;65:691-6.
8. György H, Bruce C. Regulation of Inflammation by Adenosine. *Front Immunol*. 2013;4:85.
9. Spring P, Gschwind I, Gilliet M. Prurigo nodularis: Retrospective study of 13 cases managed with methotrexate. *Clin Exp Dermatol*. 2014;39:468-73.
10. Zeidler C, Ständer S. Therapy of prurigo nodularis. *Hautarzt*. 2014;65:709-13. 11- Feldmeyer L, Werner S, Kamarashev J, French LE, Hofbauer GF. Atopic prurigo nodularis responds to intravenous immunoglobulins. *Br J Dermatol*. 2012;166:461-2.
11. Ashimav D. Oral Ketotifen and Topical Antibiotic Therapy in the Management of Pruritus in Prurigo Nodularis: A Randomized, Controlled, Single-Blind, Parallel Study. *Ind J Dermatol*. 2013;58:355-9.
12. Chan ES, Cronstein BN. Mechanisms of action of methotrexate. *Bull Hosp Jt Dis*. 2013;71:5-8.

Copyright by Mariam Al Zaabi, et al. This is an open access article distributed under the terms of the Creative Commons Attribution License, which permits unrestricted use, distribution, and reproduction in any medium, provided the original author and source are credited.

Source of Support: Nil, **Conflict of Interest:** None declared.

Uncommon presentation of Pityriasis versicolor; hyper and hypopigmentation in a same patient with variable treatment response

Riti Acharya, Madhu Gyawalee

Lecturer, Patan Academy of Health Sciences, Lalitpur, Nepal

Corresponding author: Dr. Riti Acharya, E-mail: riti_acharya@hotmail.com

ABSTRACT

Pityriasis versicolor (PV) is a superficial fungal infection of skin caused by yeast *Malassezia*. Typical lesions are multiple small, round macules that coalesce to form confluent lesions. Eruption varies in color from patient to patient, but each person's lesions are usually of a single hue. Here we present a combination of both hypo and hyperpigmented lesions of PV in a single patient. On treating the patient for 4 weeks with antifungals, complete clearance of hyperpigmented lesions were seen whereas hypopigmented ones became more accentuated.

Key words: Hyperpigmentation; hypopigmentation; Pityriasis versicolor

INTRODUCTION

Pityriasis versicolor (PV) is a superficial fungal infection of skin caused by yeast of genus *Malassezia* (notably *Malassezia globosa*, less commonly, *M. Furfur* and *M. Sympodialis*) [1]. Prevalence ranges from 1% in dry and temperate climates to 50% in tropics [2]. It occurs when the yeast form of the organism converts to the hyphal form. PV is characterized by multiple small, round macules that coalesce to form confluent lesions of varying colour.

CASE REPORT

23 year old lady presented with asymptomatic rash all over her upper trunk and upper extremities since 5 years. On examination, the lesions were symmetrically distributed hyperpigmented, round to oval macules with fine scales predominantly involving intertriginous areas (neck, axilla, inter and inframammary areas) (Fig. 1) whereas similar hypopigmented lesions were present over the back, chest and bilateral upper limb (Figs. 2a and 2b). To evaluate the color of the lesions, the patient was examined by Wood's lamp (Fig. 3). Yellow hue of the

lesions confirmed PV which was more prominent in hyperpigmented lesions than hypopigmented ones. In direct KOH skin smear, fungal elements with characteristic 'spaghetti and meatball' pattern was seen. On treating the patient with ketoconazole 200 mg daily for 7 days and cream ketoconazole twice daily for one month, the hyperpigmented lesions completely resolved with marked accentuation of hypopigmented ones over the previous sites (Figs. 4a and 4b).

DISCUSSION

Pityriasis versicolor is caused by dimorphic lipid-dependent yeasts *Malassezia spp.* formerly known as *Pityrosporum*) which are normal human saprophytes. It is more common in the tropics than in temperate climates. Generally lesions are restricted to anatomical sites that are covered by clothing, suggesting the role of increased heat and moisture in the pathogenesis of the lesions. Some patients experience mild pruritus, but it is usually asymptomatic. As the name suggests, it may present with color ranging from pink to tan brown to black [2]. In general, hyperpigmented, red to brown lesions erupt in fair-skinned patients whereas

How to cite this article: Acharya R, Gyawalee M. Uncommon presentation of Pityriasis versicolor; hyper and hypopigmentation in a same patient with variable treatment response. Our Dermatol Online. 2017;8(1):43-45.

Submission: 20.02.2016; **Acceptance:** 06.06.2016

DOI:10.7241/ourd.20171.11

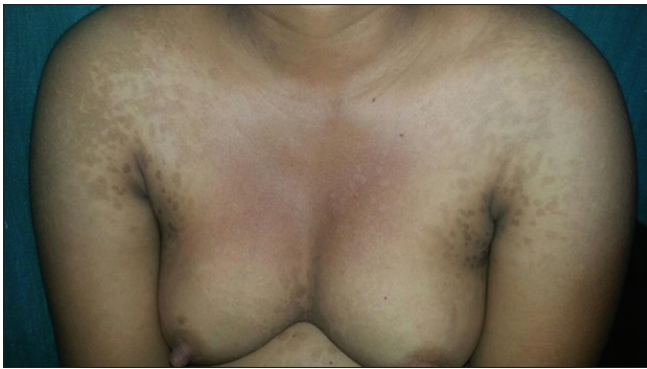

Figure 1: Hyperpigmented lesions of Pityriasis versicolor seen over B/L axilla extending to chest and arms, inter and infra mammary area.

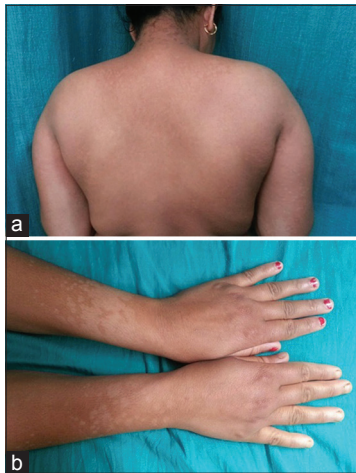


Figure 2 : (a and b) Hypopigmented macules of Pityriasis versicolor over upper back, arms and forearm.

those with dark skin tend to have hypopigmented lesions [3].

Skin pigmentary changes of PV can occur as either hyperpigmented or hypopigmented lesions in accordance with interactions between *Malassezia* yeasts and skin characteristics, such as lipoperoxidation process, stimulus of inflammatory cell to melanocytes, and increased thickness of keratin layer. However, the precise factors that enhance susceptibility to *Malassezia* yeasts and provoke PV is yet to be defined [4].

In hypopigmented lesions, the interaction between skin barrier components and *Malassezia* yeasts, such as lipoperoxidation process cause cytotoxic effect to make hypopigmented patches. To add, production of dicarboxylic acid which inhibits tyrosinase which is essential for skin pigmentation, inhibition of tanning due to overlying scales, or abnormally small melanosomes are other factors causing hypopigmentation. Whereas, the hyperpigmented lesions occur due to thicker

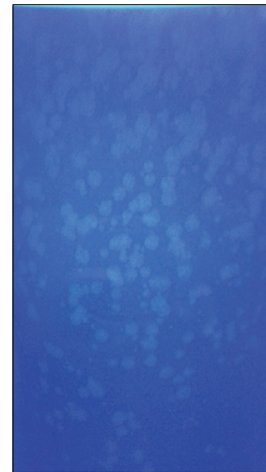


Figure 3: Wood's lamp examination showing accentuation of lesions of hyperpigmented (A) compared to hypopigmented (B) P versicolor.

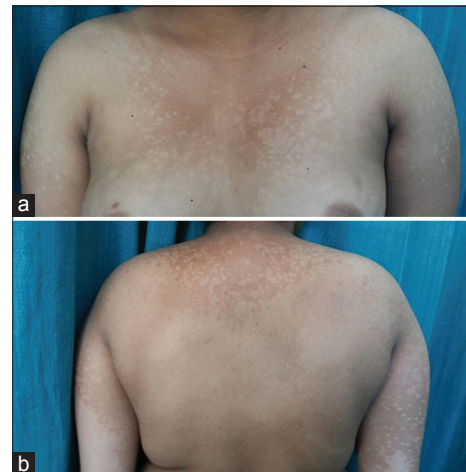


Figure 4: (a and b) Four weeks after treatment showing complete clearance of hyperpigmented macules with accentuation of hypopigmented macules.

stratum corneum, larger melanocytes and inflammatory reactions against fungus. Hence hyperpigmentation could occur as a result of both inflammation and increased melanin production [4,5].

Diagnosis is usually by clinical examination, KOH examination shows typical “spaghetti and meat ball” appearance, and Wood’s lamp examination shows orange to yellow fluorescence. Identification by culture requires lipid enrichment of the media and is rarely done to establish the diagnosis. It can be confirmed by histopathology which shows yeasts in the stratum corneum and sometimes in the perifollicular region.

PV is difficult to cure, as relapse following treatment can be as high as 80% within 2 years. Topical antifungals are currently the first line of treatment and systemic antifungals are recommended for severe or recalcitrant

cases. Among systemic antifungal, ketoconazole was once the gold standard for oral treatment. Currently, itraconazole, fluconazole, and pramiconazole are effective antifungals [6]. Patients of PV should be counselled that hyper- or hypopigmentation may persist and may take months to recover normal skin appearance despite successful treatment.

In our case, rapid control of inflammation could have cause the hyperpigmented lesion of PV to regain normal pigmentation quickly. But decrease in the activity of tyrosinase caused by dicarboxylic acids, produced by the organism and direct cytotoxic effect on melanocytes in hypopigmented lesions might have taken longer time to recover and regain normal pigmentation.

CONCLUSION

PV is common superficial fungal infection of skin causing pigmentary changes. Cosmetic concern often warrants treatment. However, even after successful treatment pigmentary alteration may persist. Hyperpigmented lesions resolve early than hypopigmented ones

which could be due to faster resolution of ongoing inflammation in hyperpigmented lesion with more gradual recovery of tyrosinase activity and cytotoxic effects of melanocytes on hypopigmented lesions.

REFERENCES

1. Lyakhovitsky A, Shemer A, Amichai B. Molecular analysis of *Malassezia* species isolated from Israeli patients with pityriasis versicolor. *Int J Dermatol.* 2013;52:231-3.
2. Gupta AK, Bluhm R, Summerbell R. Pityriasis versicolor. *JEADV.* 2002;16:19-33.
3. Leung AK. Pityriasis versicolor. In: Lang F, ed. *The Encyclopedia of Molecular Mechanisms of Disease.* Berlin: Springer-Verlag, 2009;1652-4.
4. Park HJ, Lee YW, Choe YB, Ahn KJ. Skin Characteristics in Patients with Pityriasis Versicolor Using Non-Invasive Method, MPA5. *Ann Dermatol.* 2012;24:444-52.
5. Zonunsanga. Atypical pityriasis versicolor: case report. *Our Dermatol Online.* 2015;6:198-200.
6. Gupta AK, Foley KA. Antifungal Treatment for Pityriasis Versicolor. *J Fungi.* 2015;1:13-29.

Copyright by Riti Acharya, et al. This is an open access article distributed under the terms of the Creative Commons Attribution License, which permits unrestricted use, distribution, and reproduction in any medium, provided the original author and source are credited.

Source of Support: Nil, **Conflict of Interest:** None declared.

Familial dyskeratotic comedones in a female with positive family history: A rare entity

Anup Kumar Tiwary, Dharmendra Kumar Mishra, Shyam Sundar Chaudhary

Department of Dermatology, Venereology and Leprosy, Rajendra Institute of Medical Sciences, Ranchi, India

Corresponding author: Dr. Anup Kumar Tiwary, E-mail: anup07tunnu07@gmail.com

ABSTRACT

Familial dyskeratotic comedones is an inherited disorder with characteristic clinical features characterized by disseminated, hyperkeratotic papules and comedones with evidence of dyskeratosis on histopathology. In the light of unrewarding treatment and rarity of this entity, herein we report this rare disorder in a female patient having positive family history.

Key words: Comedones, dyskeratotic, hyperkeratotic papules

INTRODUCTION

Rodin et al. first reported a rare inherited condition in 1967, called as familial dyskeratotic comedones (FDC) with autosomal dominant mode of inheritance and clinically characterized by symmetrical development of cosmetically disfiguring, progressive but asymptomatic, numerous, discrete, disseminated, hyperkeratotic papules and comedones on trunk, arms and face, appearing around puberty [1]. Histopathological examination often reveal craterlike epidermal invaginations plugged with lamellar keratinous materials and dyskeratotic cells. To the best of our knowledge, less than 50 cases of familial dyskeratotic comedones are reported in literature. Here we report a female case with this rare disorder having a positive family history.

CASE REPORT

A 17 year old female presented with multiple, asymptomatic hyperkeratotic and hyperpigmented comedone-like papules and atrophic pock-like scars predominantly over central face, neck, chest, abdomen, upper extremities. These lesions started appearing on face, trunk and then upper limbs since the age

of 11 years which gradually increased in number and severity with some exacerbations and remissions and forming multiple pock-like scars chiefly over face and back with no evidence of acne or other relevant dermatoses. There was a family history of similar lesions in her older sister and maternal grandmother since their childhood. There was no history of consanguinity among her parents.

Cutaneous examination showed numerous, hyperkeratotic papules, comedones and pock-like scars of size ranging from 0.5 to 2 cm on central area of face, neck, chest, abdomen, upper extremities and buttocks sparing scalp, legs, palms, soles, genitalia and mucosa. (Figs. 1 and 2). Systemic examination and routine laboratory parameters were within normal limits.

To reach at a final diagnosis, a punch biopsy was done and two samples were taken from comedone-like lesion and scarred lesion and sent for histopathological examination.

Histopathological evaluation demonstrated hyperkeratosis, multiple crater-like epidermal invaginations containing plugs of lamellar keratinous materials. Acantholysis was absent and dyskeratosis was observed at some places (Figs. 3a and 3b).

How to cite this article: Tiwary AK, Mishra DK, Chaudhary SS. Familial dyskeratotic comedones in a female with positive family history: A rare entity. Our Dermatol Online. 2017;8(1):46-48.

Submission: 04.03.2016; **Acceptance:** 06.06.2016

DOI:10.7241/ourd.20171.12

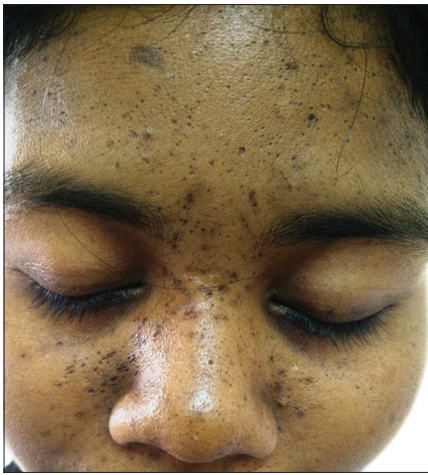

Figure 1: Hyperkeratotic papules and pock-like scars on central area of face.

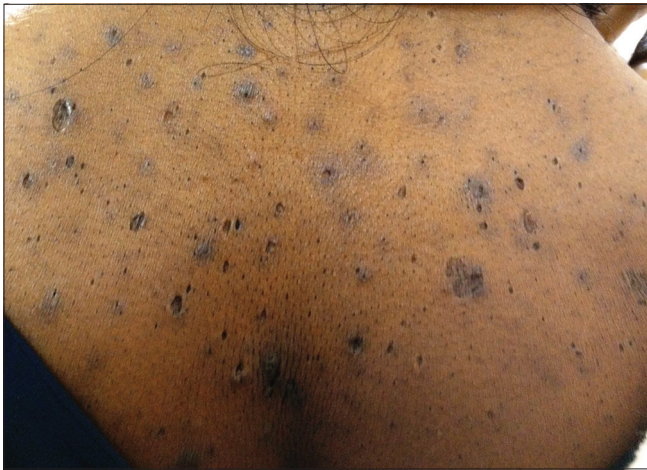

Figure 2: Hyperkeratotic comedones like papules and pock-like scars of varying sizes on back.

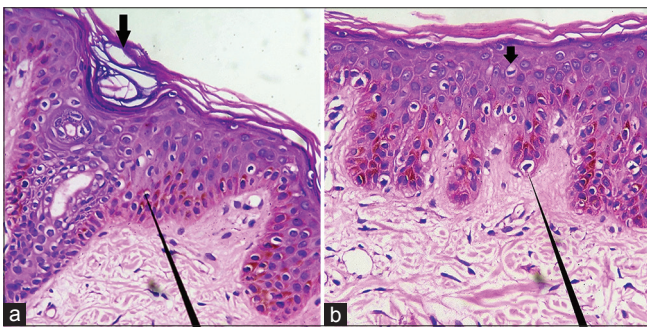


Figure 3: (a) Crater-like epidermal invagination containing plugs of lamellar keratinous materials. (b) Acantholysis was absent and dyskeratotic cells were seen (downward black arrow- grains with elongated nucleus and pointer showing corps rond). (H & E, x 40).

DISCUSSION

Although first reported in 1967, Carneiro et al. was the first who described this rare entity in a family of four affected members and proposed the term ‘familial

dyskeratotic comedones’ in 1972 based on the following distinctive clinical features [2]:

1. Lesions clinically resembling comedones
2. Occurrence in some family members
3. Presence of dyskeratotic changes on histological examination.

In 1999, McKusick kockaert proposed this disease to be inherited in autosomal dominant mode of inheritance so complete family history should always be taken [3]. Clinically, the lesions usually appear around puberty and chiefly involve face, trunk and upper extremities in progressive fashion [3]. The classical lesions of acne is usually not found to be present [4-6]. This condition is mostly asymptomatic but occasionally may be associated with pruritus, pain and burning sensation due to the inflammation [3,4,7]. Histopathologically it is characterized by hyperkeratosis, multiple crater-like epidermal invaginations containing plugs of lamellar keratinous materials, acantholysis and dyskeratosis [4,7]. On electron microscopy, FDC shows a reduced number of desmosomal attachments within the stratum malpighii leading to suprabasal acantholysis but not in all cases as in our case [4].

There are many closely simulating clinical conditions which should be kept in differential diagnoses. They are acne vulgaris, naevus comedonicus, keratosis pilaris (KP), Darier’s disease, kyrle’s disease, reactive perforating collagenosis (RPC), perforating folliculitis and recently added entity in the literature ‘familial disseminated comedones without dyskeratosis’ [1,2,5,6-8]. Comedonal Darier’s disease presents with follicular and extrafollicular greasy, hyperkeratotic papules and plaques in seborrheic areas shows dyskeratotic cells like corps ronds and grains, suprabasal acantholysis and villi, which are diagnostic [9]. Nevus comedonicus has early life onset and presents with closely arranged, dilated follicular openings with keratinous plugs predominantly over face and neck; mostly unilateral distribution. Kyrles disease, RPC and KP can be easily differentiated on histopathology.

Hence, on the basis of peculiar clinical features, mode of inheritance and distinctive histopathological findings, diagnosis of FDC was made in our case.

Treatment is a tough task because none of the available treatment modalities are effective. Treatment with topical and oral retinoic acid derivatives are also unrewarding because of the different pathophysiological process in FDC from that of normal comedones in

acne [4,5-7]. However, frequent sun exposure and carbon dioxide laser have shown good results [4,7].

CONCLUSION

Being asymptomatic and having good prognosis, this rare entity may easily be overlooked and under reported. But in view of social problems especially in the female patients due to the severe involvement of the face leading to the psychological distress and disability of patients, further studies are much needed to accumulate more knowledge about the pathogenesis of this disease to find out the definitive cure.

Consent

The examination of the patient was conducted according to the Declaration of Helsinki principles.

REFERENCES

1. Rodin HH, Blakenship ML, Bernstein G. Diffuse familial comedones. *Arch Dermatol.* 1967;96:1456.

2. Carneiro SJ, Dickson JE, Knox JM. Familial dyskeratotic comedones. *Arch Dermatol.* 1972;105:24951.
3. Van Geel NA, Kockaert M, Neumann HA. Familial dyskeratotic comedones. *Br J Dermatol.* 1999;140:9569.
4. Hall JR, Holder W, Knox JM, Verani R. Familial dyskeratotic comedones. A report of three cases and review of the literature. *J Am Acad Dermatol.* 1987;17:80814.
5. Kumaran MS, Appachu D, Jayaseelan E. Familial dyskeratotic comedones. *Indian J Dermatol Venereol Leprol.* 2008;74:1424.
6. Cheng MJ, Chen WC, Happle R, Song ZQ. Familial disseminated comedones without dyskeratosis: Report of an affected family and review of the literature. *Dermatology.* 2014;228:3036.
7. Hallermann C, Bertsch HP. Two sisters with familial dyskeratotic comedones. *Eur J Dermatol.* 2004;14:2145.
8. Cantu DJ, Gomez-Bustamente MO, Gonzalez-Mendoza A, Sanchez-Corona J. Familial comedones. *Arch Dermatol.* 1978;114:1807-9.
9. Chung J, Kim JY, Gye J, Namkoong S, Hong SP, Park BC, *et al.* A case of familial comedonal Darier's disease. *Ann Dermatol.* 2011;23(Suppl 3):S398401.

Copyright by Anup Kumar Tiwary, et al. This is an open access article distributed under the terms of the Creative Commons Attribution License, which permits unrestricted use, distribution, and reproduction in any medium, provided the original author and source are credited.

Source of Support: Nil, **Conflict of Interest:** None declared.

Localised nasal actinic porokeratosis: An independent subtype of porokeratosis?

Nidhi Sharma, Yukti Aggarwal, Suresh Kumar Malhotra, Kuldeep Singh Chahal

Departments of Dermatology and Pathology, Government Medical College, Amritsar, Punjab, India

Corresponding author: Dr. Nidhi Sharma, E-mail: drnidhisharma@hotmail.com

ABSTRACT

Porokeratosis (PK) are a group of keratinizing disorders clinically characterized by atrophic plaques with peripheral hyperkeratotic ridge which gradually spread in a centrifugal manner. The sites of predilection are trunk or extremities and facial lesions are rarely reported. We report a sporadic adult-onset case of porokeratosis of a 20 year old female with a solitary, asymptomatic, persistent classical plaque confined to the ala of nose. On reviewing the literature, nasal and perinasal area has been found to be exclusively involved in many cases of facial porokeratosis. Such cases have unique yet common epidemiological and clinical profile thereby deserving a separate category while being classified.

Key words: Porokeratosis; Nasal alae; Localized; Solar; Non-familial

INTRODUCTION

Porokeratosis (PK) is an epidermal keratinizing disorder, characterized clinically by distinct, indolently evolving, annular plaques with atrophic center and irregular, peripheral, elevated hyperkeratotic ridge as well as histologically by the cornoid lamella [1].

The etiopathogenesis of PK is complex and has been broadly attributed to the peripheral expansion of abnormal and mutant clone of parakeratotic keratinocytes [2]. The attributing risk factors for clonal proliferation may be intrinsic i.e. genetically determined or extrinsic factors like immunosuppression, immunodeficiency (AIDS), ultraviolet radiation, infections, mechanical trauma, drugs (thiazide diuretics), hematological malignancies, autoimmune diseases, and occupational exposure to benzene etc [3].

Clinically, six distinct types of PK are well recognized i.e. PK of Mibelli (PM); disseminated superficial actinic PK (DSAP); disseminated superficial PK (DSP); PK palmaris et plantaris disseminate (PPPD); punctate PK and linear PK [4]. The usual pattern of inheritance is autosomal dominant but at times it may be sporadic. A few of these subtypes exhibit propensity for

malignant transformation as conversion into squamous cell carcinoma, Bowen disease and basal cell carcinoma has been described in 6.8 -11.0% cases of PK [5].

Common sites of predilection are trunk and extremities although sporadic cases of involvement of palms and soles, face, oral mucosa, lips have been reported [5]. The present study highlights the high incidence of nasal PK among the reported cases in the world literature which is clinically and epidemiologically distinct from other types of PK.

CASE REPORT

A twenty year old female patient presented with persistent, asymptomatic plaque over nose since two years. It started as a small papule which slowly progressed in size in a centrifugal manner. Photosensitivity was present. Past medical and family history was non-significant. On clinical examination, there was a single plaque of size 1*1.5 cm confined to the right alae of nose (Fig. 1). There was atrophy in the center of the lesion and margins were hyperkeratotic and peripherally raised to a height of 3 mm with perimarginal fissure. Otherwise general physical and systemic examination

How to cite this article: Sharma N, Aggarwal Y, Malhotra SK, Chahal KS. Localised nasal actinic porokeratosis: An independent subtype of porokeratosis? Our Dermatol Online. 2017;8(1):49-52.

Submission: 26.05.2016; **Acceptance:** 21.07.2016

DOI:10.7241/our.20171.13

was unremarkable. Routine laboratory investigations were within normal limits. Viral markers and ELISA for HIV-1, 2 were non-reactive. The differential diagnosis of discoid lupus erythematosus, PK, basal cell carcinoma, lupus vulgaris and sarcoidosis were considered. An incisional skin biopsy revealed parakeratotic invaginations in the epidermis (Fig. 2) consistent with the diagnosis of PK.

DISCUSSION

Although, PK was first described by Mibelli in 1893, a case of facial PK was first reported in 1979 by Mehregan. He reported that 197 cases out of 165,000 consecutive skin biopsy specimens verified histologically for PK, of which only seven patients had primary facial lesions (3.5%) [6]. On reviewing the literature, 49 cases of Facial/Nasal PK, with variable categorization have been identified. Their demographic and clinical features are shown in Table 1.

As evident from the table, there was exclusive involvement of nose and the perinasal area in 26 cases

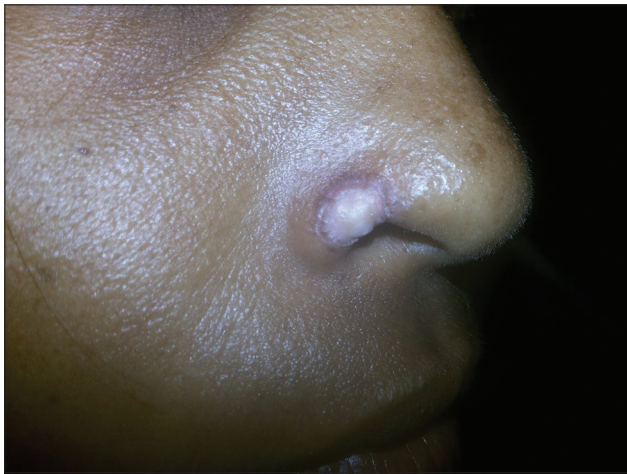

Figure 1: A single plaque of size 1*1.5 cm confined to the right alae of nose with central atrophy and peripherally raised hyperkeratotic margins.

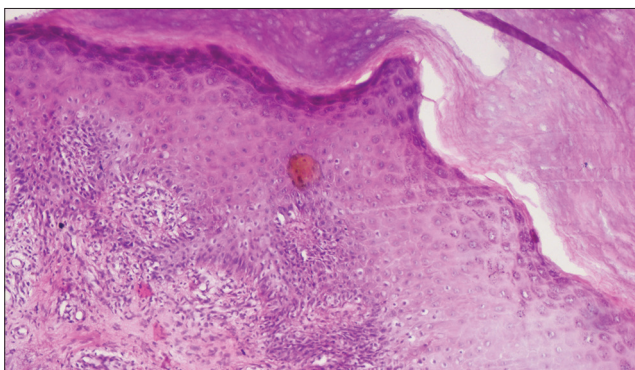


Figure 2: Parakeratotic invaginations in the epidermis. (H&E 1000x).

Table 1: Published case reports of porokeratosis on face and nose

S. No	Author	No of patients	Median age(yrs)	Sex	Duration of disease (yrs)	Distribution on face	Nasal involvement	No. of lesions (single/Multiple)	Size of lesions (cm)	Family history	Family history	Family history	Family history	H/o photo-sensitivity	Histological findings
1	Nabai et al (1979)[4]	1	18	M	2	Upper lip, chin, right cheek, right hand	0N	1M	----	NR	ND	ND	ND	NR	PK, CL, Hg, DII
2	Mehregan et al (1980) [4]	7	37.3	2F/5M	3.4	Lips, lower eyelid, cheek, neck, ears	1N*	4S+3M	----	NR	ND	ND	NR	PK, CL,	
3	Enk et al (1991) [4]	1	51	M	0.3	Right side of face	0N	1M	0.2-1.0	NR	ND	ND	NR	PK, CL, Hg, DII	
4	Rahbari et al (1995) [6]	2	26	2M	?	Right side of face and nose	1N**	2M	----	NR	2D	2D	NR	PK, CL, Hg, DII	
5	Navarro et al (2000)	1	18	M	3	Left side of face	0N	1M	Pinhead to 1.0	No	ND	ND	Absent	PK, DII	
6	Chowdhury et al (2000) [2]	1	15	M	5	Bridge of nose	1N	1S	0.5	NR	ND	ND	Present	PK, CL, Hg, DII	
7	Sharquie et al (2003) [1]	15	26.9	12F/3M	4	Nose & adjacent area	15N (7alae)	4S+11M	0.5-1	No	ND	ND	Present	PK, CL, Hg, DII	

(Contd...)

Table 1: (Continued)

S. no	Author	No of patients	Median age(yrs)	Sex	Duration of Disease (yrs)	Distribution on face	Nasal involvement	No. of lesions (Single/Multiple)	Size of lesions (cm)	Family history	Destructive/ Nondestructive	H/o photo-sensitivity	Histological findings
8	Baccouche et al (2004) [7]	1	25	F	2	Left side of nose	1N (alae)	1M	NR	No	ND	NR	PK, CL, Hg, DII
9	Miranda et al (2004)	1	29	M	12	Upper lip, nose	1N	1S	3	No	D	NR	PK, CL, Hg, DII
10	Zhang et al (2005)	1	27	M	27	Right cheek	0N	1M	6*3.5	No	ND	NR	PK, Hg, DII
11	Feranbas et al (2006)	1	42	F	20	Left side of nose ext. to cheek & eye	1N	1S	7*4	No	D	Present	PK, CL, Hg, DII
12	Carranza et al (2008) [8]	1	34	M	10	Nose	1N	1M	-----	No	ND	Present	PK, CL, Hg, DII
13	Chaudhary et al (2009)	1	21	M	2	Nose and upper part of the lip	1N (alae)	1S	10	No	ND	NR	CL(f), Hg, DII
14	Gutierrez et al (2010) [5]	6	25.8	5F/1M	1.5	Left & Right side of face & nose	2N** (2alae)	3S+3M	-----	No	ND	NR	PK, CL, Hg, DII
15	Ghorpade et al (2010) [9]	1	22	M	0.6	Left & Right side of nose	1N (alae)	1M	0.2-0.3	No	ND	NR	PK, CL, Hg, DII
16	Wang et al (2010)	1	25	F	1	Supratip of nose	1N	1S	----	No	ND	Present	CL(f), Hg, DII
17	Rocha-Sousa et al (2011)	1	19	M	4	Distal part of Nose	1N (alae)	1M	0.2-1.0	No	ND	Absent	CL(f), Hg, DII
18	Robati et al (2011)	1	30	M	4	Right side of upper lip to lower lip & dorsum of both hands	0N	1M	4*5	No	ND	NR	PK, CL, Hg,
19	Lapresta et al (2011)	1	37	F	10	Upper part of the lip & Right nasal alei	1N (alae)	1M	1.3	No	ND	NR	PK, CL, Hg, DII
20	Ragunath et al (2012)	1	22	M	0.6	Left side of nose	1N (alae)	1S	-----	No	ND	Absent	PK, CL, DII
21	Ataseven et al (2012) [10]	1	23	M	3.5	Nasal alae	1N (alae)	1M	0.8-2	No	ND	Present	PK, CL, Hg, DII
22	Raid et al (2013) [4]	1	19	F	7	Bilateral malar area & nasal alei	1N (alae)	1M	0.3-2	No	ND	Absent	PK, CL, Hg,
23	Nur et al (2014)	1	34	F	3	Right side of nose	1N (alae)	1S	1	No	ND	Absent	CL(f), Hg, DII
	*	1	14	M	3	Cheek & nose	1N	1M		No	ND	No	PK, CL
	**	1	32	M	?	Right Cheek & nose	1N	1M		No	ND	No	PK, CL, Hg, DII
	***	1	38	F	1	Right side of the nose	1N (alae)	1S		No	ND	NR	PK, CL, Hg, DII
	****	1	22	M	1.5	Right and left side of the nose	1N (alae)	1M		No	ND	NR	PK, CL, Hg, DII

NR-Not Reported, ND-Non Destructive, PK-Parakeratosis, CL-Cornoid Lamella, CL(f)-Cornoid Lamella(follicular), Hg- Hypogranulosis, DII-Dermal Inflammatory Infiltrate

out of 49 and yet another 7 cases of nasal PK had additional involvement of cheek, lips and eye. Among these 26 cases, there were 16 females and 10 males. Their ages ranged from 15-38 years with mean age being 25.49 ± 6.73 SD.

The duration of the disease ranged from 6 months to 10 years with a mean \pm SD of 3.02 ± 2.66 years. The size ranged from 0.2-2 cm in the reported cases. The lesions were solitary in 9 cases and multiple in 17 cases.

19 out of 26 cases of nasal PK had a definite history of photosensitivity which may have acted as an aggravating factor. But in 4 cases, photosensitivity was not reported while in 3 cases it was found to be altogether absent.

The family history was noticeably negative in all these patients. None of these patients reported any kind of destructive change supervening over primary lesions of PK. The histopathological hallmark of PK, the cornoid lamella was observed in all the cases. The granular layer was absent under the cornoid lamella and perivascular lymphoid infiltrate in the dermis was noted in most of the cases.

Clinically, our case did not fit completely into any of the six clinical variants of PK. Interestingly, this case had gross similarity to the single largest published series (12 female and 3 male patients) [1] and the subsequent individual case reports of nasal PK [5,7-9].

In most of these publications, similar lesions were not reported in preceding or succeeding generations, so genetics probably played no role in the etiopathogenesis of this entity. In almost all the case reports, history of photosensitivity was present thereby implicating sunlight or artificial ultraviolet light either in induction or exacerbation of cutaneous lesions over nose. UV-exposure causes p53 mutations by inducing thymidine dimers thereby causing local immunosuppression. Although face, neck, and limbs all are exposed to sunlight, in these cases a few small sized lesions of PK are limited to the nose and adjacent perinasal area only. Thus, this subtype differs from all other types of PK except DSAP in relation to sensitivity to sunlight.

In DSAP, 15% of patients with facial lesions have lesions on other sun-exposed areas of the body [1].

DSAP is inherited as an autosomal trait with the gene locus identified at chromosome 12q and 15q [4]. The lesions begin to develop in the teenagers of affected families, with penetrance nearly complete by the third and fourth decades of life.

This variant neither exhibits any inheritable pattern nor any pre-malignant potential. Thus the actinic damage seems to cause limited injury, thereby resulting in localized form of PK.

This case is reported due to exclusive location of PK on nasal alae which owing to specific morphology, distribution and clinical course may be classified into separate category of "localized nasal actinic Porokeratosis". As more and more similar cases will be reported, the existence of this entity will be further clarified.

REFERENCES

1. Sharquie KE, Al-Baghdady BA. Solar facial porokeratosis. *J Dermatol.* 2003;30:216-21.
2. Emine N Rifaioğlu, Gülzade Ö. Follicular Porokeratosis at Alae Nasi: A Case Report and Short Review of Literature. *Indian J Dermatol.* 2014;59:398-400.
3. Sertznig P, von Felbert V, Megahed M. Porokeratosis: present concepts. *J Eur Acad Dermatol Venereol.* 2012;26:404-12.
4. Riad H, Mansour K, Sada HA, Shaika SA, Ansari HA, Mohannadi HA. Disseminated Superficial Actinic Porokeratosis on the Face Treated with Imiquimod 5% Cream. *Case Rep Dermatol.* 2013;5:283-9.
5. Gutierrez EL, Galarza C, Ramos W, Tello M, De Paz PC, Bobbio Let al. Facial porokeratosis: A series of six patients. *Australas J Dermatol.* 2010;51:191-4.
6. Rahbari H, Fazel Z, Mehregan AH. Destructive facial porokeratosis. *J Am Acad Dermatol.* 1995;33:1049-50.
7. Baccouche D, Denguezli M, Sriha B, Ghariani N, Belajouza C, Nouria R. Depressed keratotic macules on the face. *Ann Dermatol Venereol.* 2004;131:1002-3.
8. Carranza DC, Haley JC, Chiu M. Facial Porokeratosis. *Skinmed.* 2008;7:51-2.
9. Ghorpade A. Localized actinic nasal porokeratosis. *Clin Exp Dermatol.* 2010;35:211-2.
10. Ataseven A, Öztürk P, Dilek N, Küçükosmanoğlu I. Localized actinic nasal porokeratosis: a case report. *Acta Dermatol Venereol.* 2012;21:79-80.

Copyright by Nidhi Sharma, et al. This is an open access article distributed under the terms of the Creative Commons Attribution License, which permits unrestricted use, distribution, and reproduction in any medium, provided the original author and source are credited.
Source of Support: Nil, **Conflict of Interest:** None declared.

Anetoderma with positive Darier's sign

Rana Rafiei¹, Eftekhari Hojat¹, Arash Daryakar², Leila Yusefkhani¹, Behnam Rafiee³

¹Department of Dermatology, Skin Research Center, Guilan University of Medical Sciences, Razi Hospital, Sardare Jangal St. Rasht, Iran, ²Department of Pathology, Skin Research Center, Guilan University of Medical Sciences, Razi Hospital, Sardare Jangal St. Rasht, Iran, ³Department of Internal Medicine, University of Texas, MD Anderson Cancer Center 1515 Holcombe Blvd. B4.4512, Houston, USA.

Corresponding author: Rana Rafiei, MD., E-mail: rafieirana@yahoo.com

ABSTRACT

Anetoderma describes a localized laxity of the skin due to dermal elastolysis. It can be either primary or secondary to an inflammatory dermatosis. Rarely secondary anetoderma has been associated with mastocytosis. We report a 16-year-old man, with multiple pouch like lesions (anetoderma) mostly on the face, neck and upper trunk which had positive Darier's sign. Anetodermic lesions developed two years ago without preceding urticaria pigmentosa lesions. In skin biopsy perivascular mast cell and eosinophil infiltrations were observed.

Key words: Anetoderma; Mastocytosis; Darier's sign

INTRODUCTION

Anetodermic lesions are localized areas of flaccid or herniated saclike skin with focal loss of dermal elastic tissue. This rare condition has been classified as primary or idiopathic anetoderma which flaccid lesions occur in normal skin and secondary anetoderma which is preceded by inflammatory, autoimmune, infectious or neoplastic processes. The most common sites of anetoderma are the trunk, thighs and upper arms [1]. Cutaneous mastocytosis is characterized by accumulation of mast cells in the skin with heterogeneous clinical presentations [2], which include maculopapular lesions (urticarial pigmentosa), erythrodermic and telangiectatic aspect. Rare and atypical presentations of mastocytosis has been reported in literatures consist of bullous, pseudoxanthomatous, congenital dermographism and anetodermic lesions [3,4]. Degranulating mast cells could be able to degraded dermal elastin [5] and induce anetoderma. Mild trauma results in erythema and urticaria around mastocytosis macule which named Darier's sign which helps us as a clinical guide for detecting anetodermic mastocytosis [2].

CASE REPORT

We present herein a 16-year-old man, with multiple asymptomatic flaccid pouch like lesions mostly on the face, neck and upper trunk. On skin examination the lesions could be depressed deeply without resistance (Figs. 1a and b). Stroking of the lesions resulted in erythema and swelling (positive Darier's sign) but he had no dermographism on the normal skin. These lesions developed two years before the first visit without any inflammatory skin lesions such as acne vulgaris or insect bite. Past medical, drug and family history were negative. He had no atopy, allergic rhinitis or asthma. His parents did not remember any skin lesions during the infancy to suggest urticaria pigmentosa (UP). He mentioned that his lesions began as a soft skin color nodules which were gradually changed to flaccid pouch like lesions or spontaneously. Two skin biopsies were done. One from a soft nodule on the back and the other one from a pouch like lesion on the chin. Histopathologic sections of both specimens showed skin tissue covered by an atrophic epidermis under lied by edematous dermis with prominent separation of collagen bundles and perivascular infiltrations of lymphocytes, mast cells and eosinophils. Significant loss of elastic

How to cite this article: Rafiei R, Hojat E, Daryakar A, Yusefkhani L, Rafiee B. Anetoderma with positive Darier's sign. Our Dermatol Online. 2017;8(1):53-55.

Submission: 04.03.2016; **Acceptance:** 25.05.2016

DOI:10.7241/ourd.20171.14

fibers in orcein staining was reported (Figs. 2a and b). No mucin identified in alcian blue stained sections. Immunohistochemistry (IHC) study revealed increased perivascular CD117 positive cells (Fig. 2c), which all of these findings were in favor of anetodermic mastocytosis.

Our patient had no systemic symptoms such as flushing, abdominal pain, diarrhea or bone pain. On clinical examination there was no organomegaly or lymphadenopathy. Laboratory evaluations including complete blood count, erythrocyte sedimentation rate, C- reactive protein, liver function test, urine analyses, were normal. Urinary 24-hour N-methyl histamine levels were slightly elevated. Due to lack of the systemic symptoms, serum tryptase level and bone marrow aspiration were not done. He complained of development of new lesions almost every six months, so phototherapy was considered for him.

Prior to the study, patient gave written consent to the examination and biopsy after having been informed about the procedure.

DISCUSSION

Anetoderma is a benign condition with focal loss of dermal elastic tissue resulting in localized areas of flaccid or herniated saclike skin, whose etiopathogenesis

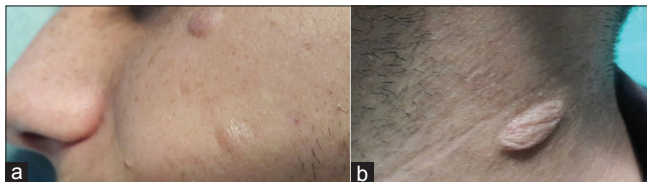


Figure 1: (a and b) Anetodermic lesions on the face and neck.

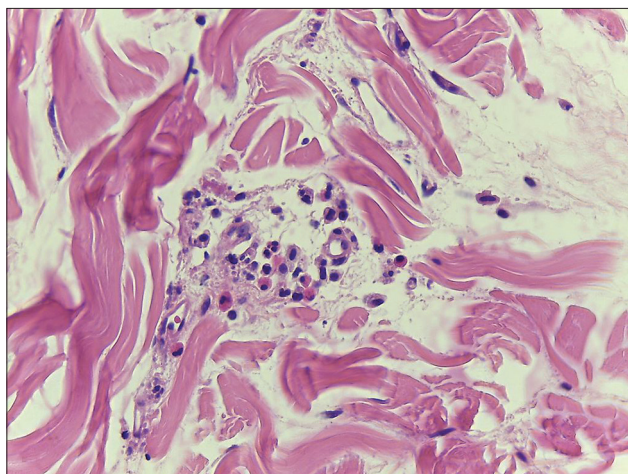


Figure 2a: Perivascular mast cell and eosinophilic infiltrations in dermis were seen (H & E, x 40).

has been unknown. This rare disorder occurs mainly in women aged 20–40 years. In the most usual form, crops of round or oval, pink macules 0.5–1 centimeter in diameter develop on trunk, thighs and upper arms, less commonly on the neck and face and rarely elsewhere. The lesions remain unchanged throughout life, and new lesions often continue to develop for many years [6]. Anetoderma has been classified as primary and secondary. In primary anetoderma, patients do not remember prior inflammation in the lesions and no abnormal inflammatory infiltrate in dermis or microthrombosis are seen in skin biopsy. Secondary anetoderma develops after many different dermatosis including acne, varicella, syphilis, leprosy, sarcoidosis, mastocytosis, granuloma annulare, xanthoma, pilomatrichoma, lymphoma and lupus profundus [7].

Our case was interesting to us because secondary anetoderma associated with mastocytosis has been rarely reported in the literature. It has been observed in only a

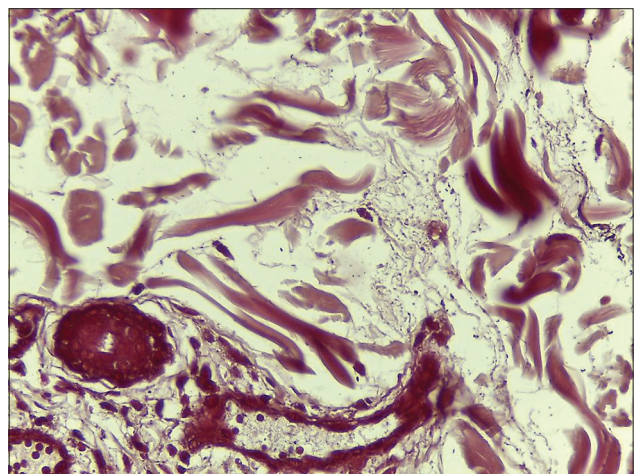


Figure 2b: In orcein staining mid dermal elastolysis was seen (x 40).

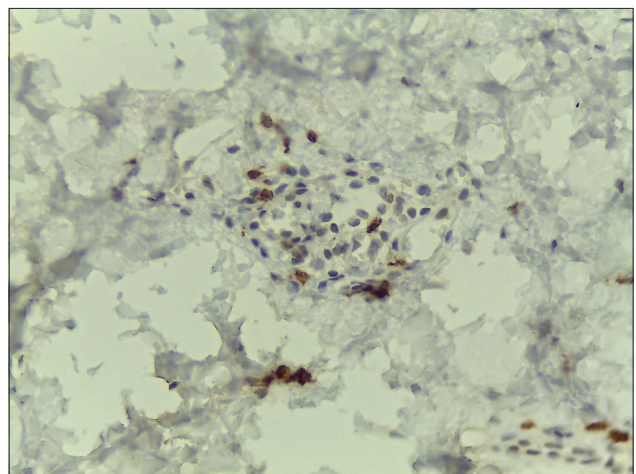


Figure 2c: In Immunohistochemistry perivascular CD117 positive mast cells were seen (x 40).

few patients with UP which is the most common type of mastocytosis in children [3]. Kalogeromitros, et al reported anetodermic lesions developed on the sites of UP lesions [8] but our patient's family did not report any preceding UP lesions during the childhood and anetodermic lesions superimposed over the soft asymptomatic new skin color nodules or sometimes developed spontaneously. Positive Darier's sign on anetodermic lesions was the only point for diagnosis which is pathognomonic for mastocytosis. So Darier's sign should be investigated in anetodermic lesions with unknown origin in order to exclude cutaneous mastocytosis [2]. The exact mechanism of mechanical degranulation of tissue mast cells after rubbing the lesions is still obscure. Darier's sign might reflect abnormal mechanosensitivity of mast cells in certain skin lesions [9].

Pathogenesis of anetoderma is unclear but degeneration of the elastic fibers could be mediated by close contact of degranulating mast cells with elastic fibers [5]. The role of elastase and other serine proteinases such as tryptase and chymase in mast cells has been postulated in anetoderma [10]. On the other hand elastin fragments are chemoattractant for phagocytes such as macrophage [5] which aggravate dermal elastolysis and result in anetoderma.

Our patients had no pruritus or UP lesions but he complained of new onset lesions during last two years. Del Pozo, et al reported phototherapy with ultra violet A and psoralen (PUVA) was effective in control of anetodermic mastocytosis [2]. So we scheduled phototherapy for him to prevent new lesions and he was followed for detecting any systemic symptoms of the mastocytosis in futures.

Abbreviations

(UP): Urticaria pigmentosa

(IHC): Immunohistochemistry

(PUVA): Psoralen- Ultraviolet A

Consent

The examination of the patient was conducted according to the Declaration of Helsinki principles.

REFERENCES

1. Aghaei S, Sodaifi M, Aslani FS, Mazharinia N. An unusual presentation of anetoderma: a case report. *BMC Dermatol.* 2004;4:9.
2. Del Pozo J, Pimentel MT, Paradelo S, Almagro M, Martinez W, Fonseca E. Anetodermic mastocytosis: response to PUVA therapy. *J Dermatolog Treat.* 2007;18:184-7.
3. Fernandes IC, Teixeira Mdos A, Freitas I, Selores M, Alves R, Lima M. Adult mastocytosis: a review of the Santo Antonio Hospital's experience and an evaluation of World Health Organization criteria for the diagnosis of systemic disease. *An Bras Dermatol.* 2014;89:59-66.
4. Rajesh J, Dogra S, Verma S, Mohanty SK, Handa S. Diffuse cutaneous mastocytosis: pseudoxanthomatous variant. *J Dermatol.* 2002;29:354-6.
5. Sheu HM, Yu HS, Chang CH. Mast cell degranulation and elastolysis in the early stage of striae distensae. *J Cutan Pathol.* 1991;18:410-6.
6. Venencie PY, Winkelmann RK, Moore BA. Anetoderma: clinical findings, associations, and long term follow-up evaluations. *Arch Dermatol.* 1984;120:1032-9.
7. Sparsa A, Piette JC, Wechsler B, Amoura Z, Frances C. Anetoderma and its prothrombotic abnormalities. *J Am Acad Dermatol.* 2003;49:1008-12.
8. Kalogeromitros D, Gregoriou S, Makris M, Georgala S, Kempuraj D, Theoharides TC. Secondary anetoderma associated with mastocytosis. *Int Arch Allergy Immunol.* 2007;142:86-8.
9. Kiorpelidou D, Gaitanis G, Bassukas ID. Darier's sign: a model for studying dermatographism. *Indian J Dermatol Venereol Leprol.* 2008;74:271-2.
10. Harvima IT, Naukkarinen A, Harvima RJ, Fraki JE. Immunoperoxidase and enzyme-histochemical demonstration of human skin tryptase in cutaneous mast cells in normal and mastocytoma skin. *Arch Dermatol Res.* 1988;280:363-70.

Copyright by Rana Rafiei, et al. This is an open access article distributed under the terms of the Creative Commons Attribution License, which permits unrestricted use, distribution, and reproduction in any medium, provided the original author and source are credited.

Source of Support: Nil, **Conflict of Interest:** None declared.

Jadassohn Lewandowsky syndrome: Type 1 pachyonychia congenita

Anup Kumar Tiwary, Dharmendra Kumar Mishra

Department of Dermatology, Venereology and Leprosy, Rajendra Institute of Medical Sciences, Ranchi, India

Corresponding author: Dr. Anup Kumar Tiwary, E-mail: anup07tunnu07@gmail.com

ABSTRACT

Pachyonychia congenita (PC) is a rare, usually autosomal dominant, genodermatosis characterized by tetrad of wedge shaped nail hypertrophy, focal palmoplantar keratoderma, oral leukokeratosis and follicular hyperkeratosis due to mutation in either of the three keratin genes, KRT6, KRT16 and KRT17. Classically, it has been subdivided into 2 major types: PC-1 (Jadassohn Lewandowsky syndrome) and PC-2 (Jackson-Lawler syndrome) but, genotypically, now PC has been classified into 5 types depending upon the underlying keratin gene mutations: PC-K6a, PC-K6b, PC-K6c, PC-K16 and PC-K17. Since 1904 when Muller documented the first case of PC, around 700 cases have been reported till now. Hence, in the view of rarity of such crippling and debilitating dermatosis of congenital or early life onset, we herein report a clinically diagnosed case of Pachyonychia congenita- type 1 (Jadassohn Lewandowsky syndrome) in a 16 years old girl with affection of 2 other members of her family with the same disorder.

Key words: Jadassohn Lewandowsky syndrome; Nail hypertrophy; Pachyonychia congenita; Palmoplantar keratoderma

INTRODUCTION

PC is commonly described as a rare genodermatosis characteristically manifesting as massive subungual hyperkeratosis with nail thickening, focal palmoplantar keratoderma alongwith deep fissuring and blistering, oral leukokeratosis and discrete follicular hyperkeratosis [1,2]. Other features including abnormalities of teeth, hairs and larynx can also be seen depending on the clinical types. Onset is usually within first year of life and mode of inheritance is autosomal dominant. After first description by Muller in 1904, next reports were published by Wilson in 1905 and Jadassohn Lewandowsky in 1906 [3-5]. Further, depending on the genetic mutation and clinical correlations, 4 types of PC have been defined.

CASE REPORT

A 16 yrs old girl came to our out patient department of dermatology presenting with chief complaint of hypertrophy of all the finger and toe nails with upward

growth and brownish discolouration, palmoplantar keratoderma with painful blistering since the age of 1 year. The patient was born of non-consanguineous parents and normal at birth but after 1 year of age, when she started walking, recurrent blistering on soles occurred. There was no history of natal teeth. Gradually, thickening of the palm and soles developed and upward growth of nails were noticed. Then, spiny follicular hyperkeratotic lesions appeared on trunk and extremities. She also complained of intolerance to hot and spicy food. Her father and younger brother had similar affection of same degree since their infancy. She was admitted and examined thoroughly.

On cutaneous examination, all the fingernails and toe nails were seen to be thick, lusterless, brownish and hypertrophied and vertically grown giving a 'door wedge shape' to the free of the nail plate due to massive subungual hyperkeratosis (Fig. 1) Both soles were hyperkeratotic, fissured and macerated with hyperhidrosis (Fig. 2). There was minor involvement of left palm with only focal thickening (Fig. 3). The oral mucosa and tongue showed leukokeratosis with

How to cite this article: Tiwary AK, Mishra DK. Jadassohn Lewandowsky syndrome: Type 1 pachyonychia congenita. Our Dermatol Online. 2017;8(1):56-59.

Submission: 09.02.2016; **Acceptance:** 18.04.2015

DOI:10.7241/ourd.20171.15

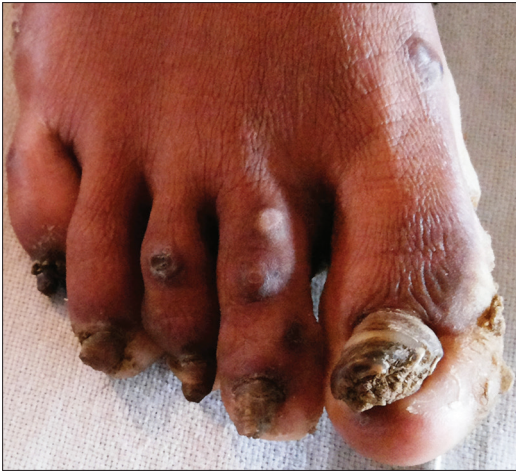

Figure 1: Wedge shaped nail hypertrophy with massive subungual hyperkeratosis in all twenty nails.

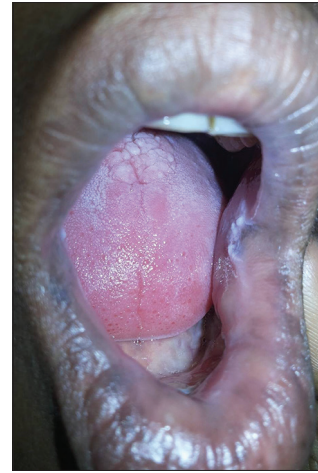

Figure 4: Leukokeratosis on left buccal mucosa.

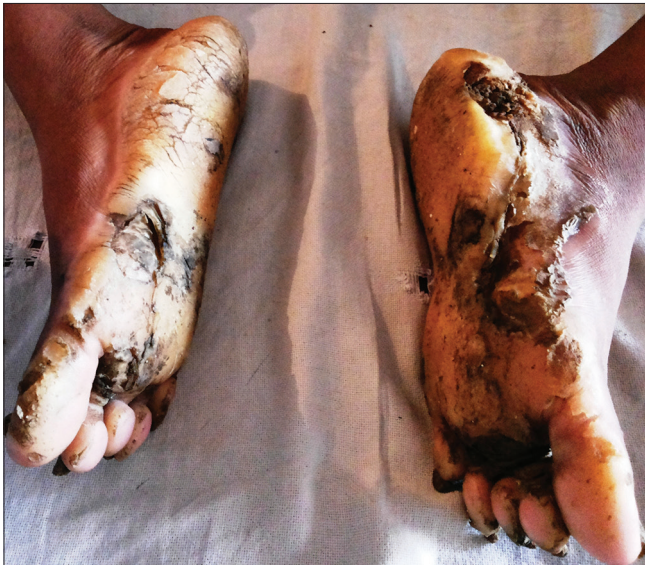

Figure 2: Plantar hyperkeratosis with deep fissuring.

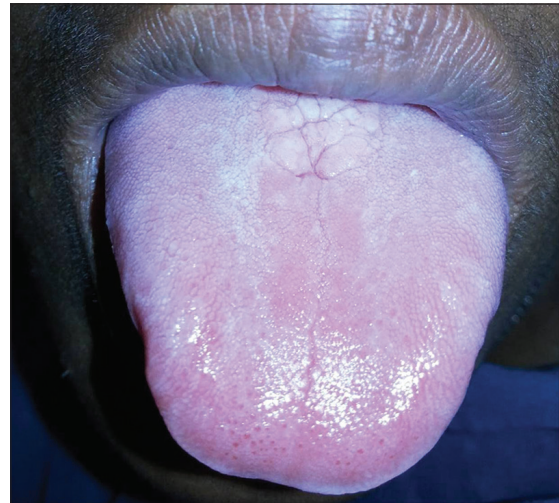

Figure 5: Leukokeratosis on tongue.

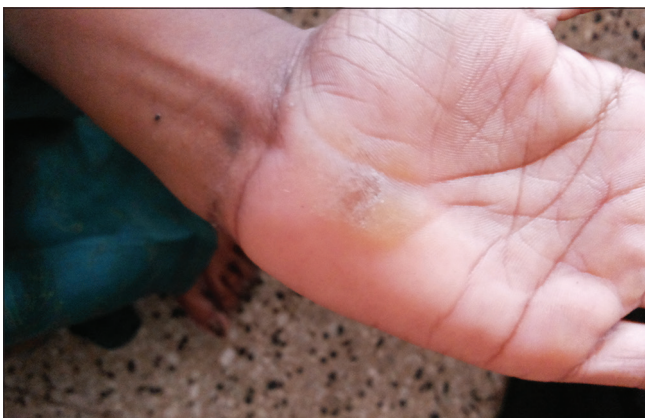

Figure 3: Mild focal hyperkeratosis of left hypothenar region.

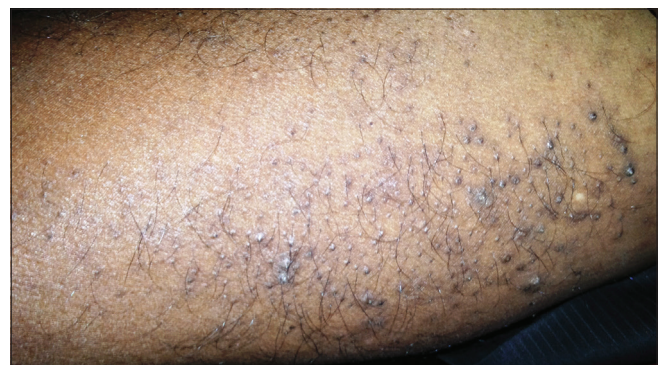

Figure 6: Multiple, discrete, follicular, hyperkeratotic, papular lesions on buttocks, extensor aspect of thighs and knees.

erosion (Figs. 4 and 5). She also had multiple, follicular, hyperkeratotic and spiny discrete papules over buttocks, knee and extensor aspect of thighs (Fig. 6).

Examination of hair, teeth, throat and eyes were normal and systemic examinations were also not remarkable. There was no sign of mental retardation and all routine laboratory parameters were within normal limits. The possibility of fungal cause of nail dystrophy was ruled out by KOH microscopy.

On the basis of these clinical features, she was diagnosed with PC type 1 and started on oral isotretinoin and topical keratolytics but there was no relief and patient did not follow up.

DISCUSSION

Pachyonychia congenita is a rare group of inherited, ectodermal dysplastic disorders characterized by tetrad of wedge shaped nail hypertrophy and subungual hyperkeratosis, varying degree of focal palmoplantar keratoderma with history of recurrent blisters, oral leukokeratosis and discrete follicular papules on the sites of friction [2,3]. Other features which may be associated include alopecia, keratosis pilaris, hyperhidrosis of the palms and soles, natal teeth, laryngeal involvement causing hoarseness of voice and corneal opacities [4]. Although mode of inheritance is autosomal dominant but autosomal recessive transmission has also been seen and even sporadic cases can also occur without any family history due to spontaneous mutation. Based on the certain genetic mutations and their correlation to the presenting features, 4 clinical types or variants have been proposed over the time [5].

I. PC tupe-1 (Jadassohn-Lewandowski syndrome) – is a relatively common type, characterized by upward growth of thick, friable and lusterless discoloured nails of all the digits (most severely of thumb and index finger), palmoplantar keratoderma with hyperhidrosis in more than half of the cases, follicular hyperkeratosis, oral or laryngeal leukokeratosis and blisters [6].

II. PC type-2 (Murray–Jackson–Lawler syndrome) - natal teeth and cysts like epidermoid cysts, eruptive vellus hair cyst or steatocytoma multiplex along with less prominent features of PC type 1 [2].

III. PC type-3 (Schafer–Brunauer syndrome) – characterized by features of types 1 and 2 with angular chelitis, corneal dyskeratosis and cataracts [1].

IV. PC type-4 (PC tarda) – This type was suggested by Paller et al. in 1991, having late onset (during late childhood or adulthood) and manifest features of all three types with laryngeal involvement, mental retardation and hair changes like sparse kinky hairs and alopecia [7,8].

IV. PC with only nail involvement has also been reported.

Aetiopathologically, around 100 mutations have been identified which can lead to the development of such deformities. The keratin genes which are expressed on palm, soles, nail bed, oral mucosa and pilosebaceous units and responsible for this syndrome are- KRT6a, KRT6b, KRT6c, KRT16 and KRT17 [5,6]. These mutations interferes with the assembly of polypeptides forming the keratin skeleton of epidermal cells. Histological examination of keratoderma is non-specific with the demonstration of orthokeratosis and parakeratosis, non epidermolytic acanthosis [9]. Cytological atypia is usually not seen but the possibility of malignant changes in palmoplantar lesions can not be neglected over the time. Although PC is usually diagnosed on the clinical grounds, only genetic testing can confirm the diagnosis and types of PC due to the overlapping clinical features.

Treatment modalities are chiefly meant for hyperkeratosis and includes topical keratolytics (salicylic acid, urea, lactate), oral retinoic acid derivatives (isotretinoin, acitretin), mechanical abrasion with hand tool or by dermabrasion, electrofulguration and excision. Treatment of aggravating factors like hyperhidrosis by means of aluminium chloride lotion, iontophoresis or botulinum toxin injection may provide pain-relief and also reduce blistering.

Research work on gene therapies are being carried out to make ‘inhibition of mutant allele’ possible.

CONCLUSION

Being a very rare, genetic and crippling condition and having only old, conventional and very few treatment options, every clinically diagnosed case of PC should be reported and efforts should be made for genetic testing so as to help advancement in the genetic therapies.

Consent

The examination of the patient was conducted according to the Declaration of Helsinki principles.

REFERENCES

1. McLean WH, Hansen CD, Eliason MJ, Smith FJ. The phenotypic and molecular genetic features of pachyonychia congenita. *J Invest Dermatol.* 2011;131:10157.
2. Leachman SA, Kaspar RL, Fleckman P, Florell SR, Smith FJ, McLean WH, et al. Clinical and pathological features of

- pachyonychia congenita. *J Investig Dermatol Symp Proc.* 2005;10:317.
3. Fernandez RJ, Parikh DA. Pachyonychia Congenita. *Indian J Dermatol Venereol Leprol.* 1989;55:334-5.
 4. Rodríguez H, Cuestas G, Zanetta A, Balbarrey Z. Pachyonychia congenita with involvement of the larynx. *Acta Otorrinolaringol Esp.* 2013;6519:2646.
 5. Munro CS. Pachyonychia congenita: Mutations and clinical presentations. *Br J Dermatol.* 2001;144:929-30.
 6. Al Aboud A, Al Aboud K. Josef Jadassohn (18631936), Felix Lewandowsky (18791921), and their syndrome. *Clin Cosmet Investig Dermatol.* 2011;4:17982.
 7. Vaccaro M, Guarneri F, Barbuzza O, Guarneri C. Pachyonychia congenita tarda affecting only the nails. *Dermatol Online J.* 2008;14:12.
 8. Moger G, Shashikanth MC, Chandrashekar KT, Kurein S. Pachyonychia congenita tarda: A rare case report. *Contemp Clin Dent.* 2013;4:409-11.
 9. Johnson BL Jr, Yan AC. Congenital diseases (Genodermatosis). In: Elder DE, editors. *Lever's Histopathology of the Skin.* 10th ed. Philadelphia: Lippincott Williams and Wilkins; 2009. p. 138.

Copyright by Anup Kumar Tiwary, et al. This is an open access article distributed under the terms of the Creative Commons Attribution License, which permits unrestricted use, distribution, and reproduction in any medium, provided the original author and source are credited.
Source of Support: Nil, **Conflict of Interest:** None declared.

Tinea manuum misdiagnosed as psoriasis vulgaris: A case of tinea incognito

Funda Tamer¹, Mehmet Eren Yuksel²

¹Department of Dermatology, Medical Park Hospital, Ankara, Turkey, ²Department of General Surgery, Devrek State Hospital, Zonguldak, Turkey

Corresponding author: Dr. Funda Tamer, E-mail: fundatmr@yahoo.com

ABSTRACT

Tinea incognito is a dermatophyte infection with altered clinical appearance which is usually caused by the use of immunosuppressive agents such as topical corticosteroids. Hereby, we present a 59-year-old Caucasian male patient with tinea manuum on the dorsum of his left hand. The lesion was formerly misdiagnosed as psoriasis vulgaris and treated with topical corticosteroids. However, the symptoms were worsened. Moreover, new papules and pustules appeared within the lesion. The past medical history was remarkable for psoriasis vulgaris and he had an erythematous and squamous plaque on his lower back resembling psoriasis vulgaris. In order to reach a definitive diagnosis, the skin lesion on the dorsum of the patient's left hand was examined by light microscopy after the application of 10% potassium hydroxide solution. Detection of septate hyphae confirmed dermatophytosis. The lesion was completely healed with oral terbinafine 250 mg daily for four weeks. Dermatophyte infections in early stages may be misdiagnosed as psoriasis vulgaris and thus, prolonged use of corticosteroids can lead to tinea incognito. Therefore, cutaneous lesions unresponsive to topical corticosteroid treatment should be evaluated with microscopic examination and fungal culture to confirm a suspected dermatophyte infection. Past medical history can provide useful information but a complete dermatological examination should be performed before the final diagnosis is made.

Key words: Tinea manuum; Tinea incognito; Psoriasis vulgaris

INTRODUCTION

Tinea manuum is a fungal infection of the hands caused by dermatophytes. It can present with erythema and minimal scale on the dorsum of the hand. However, chronic tinea manuum lesions located on the palmar region may be scaly and hyperkeratotic. Tinea manuum usually affects the dominant hand but it can also occur bilaterally. The term 'tinea incognito' is used to describe a dermatophyte infection with altered morphology. Tinea incognito usually occurs after inappropriate treatment with topical steroids. Wood's lamp examination, mycological culture, direct microscopy and molecular techniques like polymerase chain reaction are the methods to reach a definitive diagnosis [1]. Dermatophyte infections can be managed with antifungal and keratolytic agents [2].

CASE REPORT

A 59-year-old Caucasian male presented with an itchy rash on his left hand for further clinical evaluation. The chief complaint of the patient was pruritus. The lesion on the left hand of the patient was formerly misdiagnosed as psoriasis vulgaris. Therefore, he was treated with topical corticosteroids. Nevertheless, the symptoms were not relieved by the application of topical corticosteroids. In addition, the patient complained of gradual enlargement of the lesion in the last two months. The past medical history was remarkable for diabetes mellitus and psoriasis vulgaris for the past three years. However, he wasn't taking any medications regularly. He admitted that he could manage his blood glucose levels with diet. He was put on topical calcipotriol and clobetasol propionate to treat psoriasis vulgaris. The family history was

How to cite this article: Tamer F, Yuksel ME. Tinea manuum misdiagnosed as psoriasis vulgaris: A case of tinea incognito. Our Dermatol Online. 2017;8(1):60-62.

Submission: 16.03.2016; **Acceptance:** 24.08.2016

DOI: 10.7241/ourd.20171.16

unremarkable. The physical examination showed an erythematous patch with a slightly raised edge on the dorsum of the left hand. There were erythematous, skin colored papules and pustules within this lesion. He also had hyperkeratotic plaques and fissures on both palms (Figs. 1 and 2). In addition, we noticed an erythematous and squamous plaque resembling psoriasis vulgaris on his lower back.

Laboratory tests including blood count and chemistry panel such as urea, glomerular filtration rate, creatinine, alanine amino transferase, aspartate amino transferase, total bilirubin, direct bilirubin were all in the normal ranges. But gamma glutamyl transferase was 56 U/L (normal range 5-40).

We scraped active edge of the lesion on the left hand using a scalpel and we applied 10% potassium hydroxide (KOH) solution to the sample. KOH preparation was examined microscopically and branched hyphae of the fungus were detected. The patient was treated with oral

terbinafine 250 mg once daily and topical sertaconazole nitrate twice daily. The lesion on the dorsum of the left hand disappeared completely within four weeks.

DISCUSSION

Tinea manuum is a dermatophyte infection of the palms, interdigital spaces and dorsal aspect of the hands. Fingernails may also be involved. Tinea manuum typically presents with diffuse scaling and hyperkeratosis of the palms and fingers. In addition, annular lesions with erythematous scaly borders may appear on the dorsum of the hand. Exfoliative, vesicular and papular lesions are other clinical manifestations of the tinea manuum. Psoriasis vulgaris, dermatitis, dermatophytid reaction, keratoderma and dyshidrosis should be considered in the differential diagnosis of tinea manuum [3].

The term tinea incognito describes dermatophytic infections with atypical appearance due to topical and systemic immunosuppressants such as steroids and immunomodulators [4]. The lesions are less scaly but more pustular, pruritic, widespread and erythematous than common dermatophytosis. The active margins may be lost [5]. In addition to topical immunosuppressive therapy, virulence of pathogen, individual and environmental factors such as unsanitary conditions may play role in atypical presentation [4]. Tinea incognito can mimic other skin disorders such as neurodermatitis, rosacea, lupus erythematosus, contact dermatitis impetigo, lichen planus, psoriasis vulgaris, erythema migrans and drug eruptions. Systemic antifungal agents are usually indicated in patients with tinea incognito [6].

The diagnosis of cutaneous fungal infections may be difficult and tinea manuum can be easily misdiagnosed as psoriasis vulgaris. In our case, the patient's past medical history of psoriasis vulgaris caused a misdiagnosis and delay in the treatment. However, exacerbation of the lesions during treatment with corticosteroids and active border of the lesions led us to reevaluate the initial diagnosis.

CONCLUSION

In conclusion, dermatophyte infections may present with a variety of unusual clinical features. Dermatophytosis should be kept in mind in differential

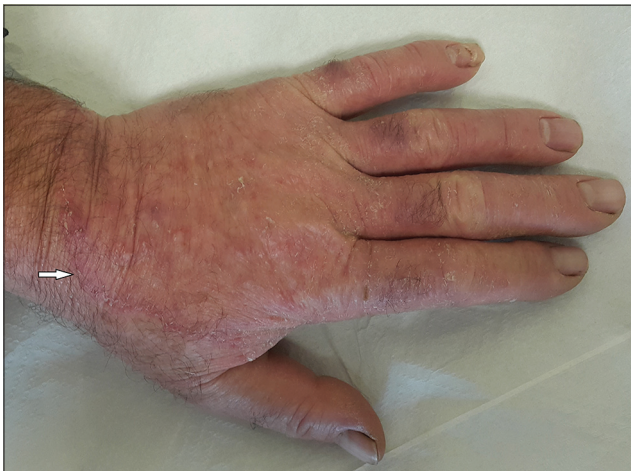

Figure 1: Tinea incognito: Red papules and pustules on erythematous patch with a well defined border on the lateral side of the left hand (white arrow)

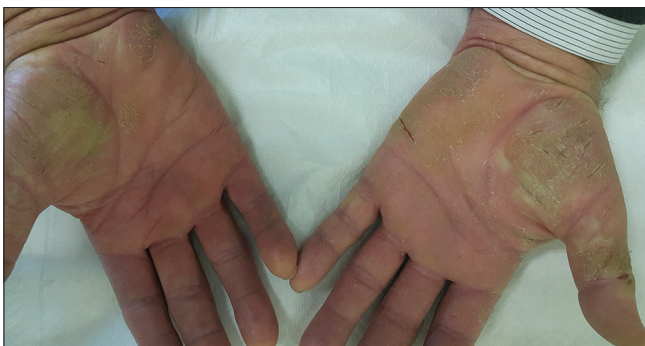

Figure 2: Hyperkeratotic plaques and fissures on the palms

diagnosis of other skin diseases especially when there is no response as expected to topical corticosteroid treatment. A misdiagnosis may lead to chronic and disseminated lesions. Tinea incognito should be treated with systemic antifungal agents and treatment should be continued until the lesions disappear.

Consent

The examination of the patient was conducted according to the Declaration of Helsinki principles.

REFERENCES

1. Moriarty B, Hay R, Morris-Jones R. The diagnosis and management of tinea. *BMJ*. 2012;345:e4380.
2. Drake LA, Dinehart SM, Farmer ER, Goltz RW, Graham GF,

Hardinsky MK, et al. Guidelines of care for superficial mycotic infections of the skin: Tinea corporis, tinea cruris, tinea faciei, tinea manuum and tinea pedis. Guidelines/Outcomes Committee. American Academy of Dermatology. *J Am Acad Dermatol*. 1996;34:282-6.

3. Sobera JO, Elewski BE. Fungal Diseases. In Bologna JL, Jorizzo JL, Rapini RP, eds. *Dermatology. Spain: Elsevier*, 2003; 1178-1179
4. Segal D, Wells MM, Rahalkar A, Joseph M, Mrkobrada M. A case of tinea incognito. *Dermatol Online J*. 2013;19:18175.
5. Arenas R, Moreno-Coutiño G, Vera L, Welsh O. Tinea incognito. *Clin Dermatol*. 2010;28:137-9.
6. Zisova LG, Dobrev HP, Tchernev G, Semkova K, Aliman AA, Chorleva KI, et al. Tinea atypica: Report of nine cases. *Wien Med Wochenschr*. 2013;163:549-5.

Copyright by Funda Tamer, et al. This is an open access article distributed under the terms of the Creative Commons Attribution License, which permits unrestricted use, distribution, and reproduction in any medium, provided the original author and source are credited.

Source of Support: Nil, **Conflict of Interest:** None declared.

Psoriasis with verrucous appearance: A case report

Sarra Ben Rejeb¹, Amen Dhaoui¹, Dorra Ben Ghachem¹, Asmahane Souissi², Khadija Bellil¹

¹Department of Pathology, FSI Hospital, La Marsa, Tunisia, ²Department of Dermatology, FSI Hospital, La Marsa, Tunisia

Corresponding author: Dr. Sarra Ben Rejeb, E-mail: sarrabenrejeb88@yahoo.fr

ABSTRACT

Psoriasis verrucosa is a rare clinical variant of psoriasis with peculiar histologic features. Only few cases have been reported in the literature. We herein report a rare case of psoriasis with verrucous appearance occurring in a 63 year-old woman who presented with verrucous and scaly erythematous plaque of the legs which was developed thirty years ago. The biopsy specimen showed regular psoriasiform epidermal hyperplasia with acanthosis, hyperkeratosis, and focal spongiosis with a superficial perivascular infiltrate. The patient was diagnosed with verrucous psoriasis. Recognition of this entity should preempt confusion with verruca vulgaris or other entities capable of producing wart-like epidermal changes.

Key words: Psoriasis; Verrucous; Histology

INTRODUCTION

Psoriasis is an inflammatory disorder characterized by peculiar skin and joint manifestations. The most common clinical presentation is a scaly erythematous plaque with thick silvery white scale. Psoriasis with verrucous appearance is a rare variant of the disease with characteristic clinical and pathological features; it might be confused with many other lesions including warts, epidermal nevus, contact dermatitis, eczema and fungal infection [1,2].

We herein describe another case of this rare entity. The clinicopathological features of this disease are discussed.

CASE REPORT

A 63 year-old woman with no past medical history presented with erythematous, scaly lesions of the lowers extremities developed thirty years ago. They were painless but were progressively growing, causing significant physical dis-figurement and discomfort on wearing shoes. Physical examination revealed verrucous plaques of the legs (Fig. 1). A skin biopsy of these lesions has been performed.

Pathologic examination revealed psoriasiform epidermal hyperplasia of rete ridges with prominent papillomatosis, marked parakeratosis and hyperkeratosis. It also showed epidermal hypogranulosis, thin suprapapillary epidermal plates, focal spongiosis of the Malpighi mucous body and a superficial perivascular inflammatory infiltrate. No inflammatory collection has been noted within the epidermal layers (Figs. 2 and 3). Koilocytic changes were not observed.

Clinical and pathological findings were consistent with verrucous psoriasis (VP). The patient was treated with local dermocorticoid. The patient has not been seen since the beginning of the treatment.

Prior to the study, patient gave written consent to the examination and biopsy after having been informed about the procedure.

DISCUSSION

Verrucous psoriasis is a rare variant of the disease with less than thirty cases reported in the literature [3]. It is mostly occurring on men with a sex ratio of 1.6 and a mean age of 53 year old [1,4]. Clinically, VP is characterized by a scaly erythematous plaque with

How to cite this article: Ben Rejeb S, Dhaoui A, Ben Ghachem D, Souissi A, Bellil K. Psoriasis with verrucous appearance: A case report. Our Dermatol Online. 2017;8(1):63-65.

Submission: 05.04.2016; **Acceptance:** 07.07.2016

DOI: 10.7241/ourd.20171.17

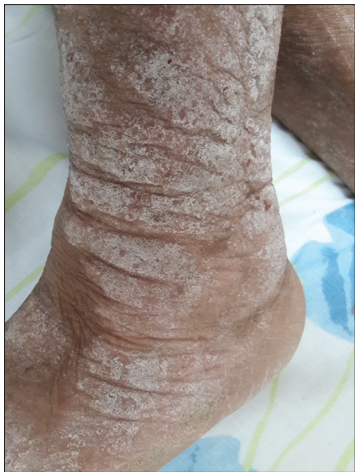

Figure 1: Warty plaques of the foot.

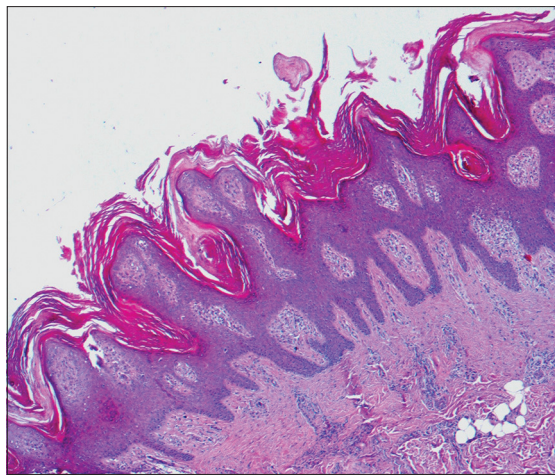


Figure 2: Wart-like appearance of the epidermis (HEx400).

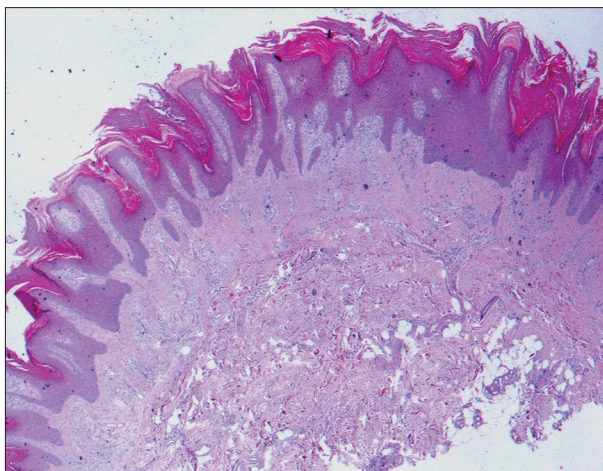


Figure 3: Epidermal hyperplasia with parakeratosis and prominent papillomatosis (HE x200).

wart-like changes. It is commonly occurring on frictions area such as elbows, hands, knees and feet. VP may be confused with many other benign lesions, including

verruca vulgaris, epidermal nevus, contact dermatitis, eczema and fungal infection [1]. However, a verrucous carcinoma must be ruled out on biopsy. Microscopically, the lesion has a characteristic feature of psoriasis with wart-changes, it is typically showing parakeratosis, epidermal psoriasiform hyperplasia with elongation of rete ridges, thin suprapapillary epidermal plates, thinning of the granular layer, and dilated, tortuous capillaries with an inflammatory infiltrate, which may contain admixed neutrophils in the papillary dermis. Munro abscesses and spongiform pustules are frequently noted. In our case, despite the absence of characteristic neutrophils collection's of psoriasis within the epidermal layer, the correlation of clinical and other histologic features including papillomatosis and epithelial buttressing suggested the diagnosis. Moreover, Munro abscesses might be absent in 35% of authentic psoriasis. Classically, absence of koilocytic changes and Human papilloma virus (HPV) immunostaining support the diagnosis of verrucous psoriasis.

The etiology of verrucous psoriasis remains unclear. It has been associated in some cases to lymphatic obstruction, microangiopathy, diabetes and obesity [5,6]. Other authors consider it as a progressive form of vulgaris psoriasis [1,5]. The verrucous changes in this case have been related to repeated trauma.

However, although it is considered to be a variant from psoriasis, little is known about its adequate treatment because of poor response to classic local therapy (dermocorticosteroid, vitamine D, puvatherapy). Some authors reported the efficacy of etretinate, adalimumab and methotrexate. However, further investigations are required to determine an optimal treatment for this rare entity.

CONCLUSION

Verrucous psoriasis is a rare variant of psoriasis that might prompt consideration of verruca vulgaris. Combination of clinical and pathological findings is required for precise diagnosis. Because of its rarity, no codified therapy has been established yet.

Consent

The examination of the patient was conducted according to the Declaration of Helsinki principles. Written informed consent was obtained from the patient for publication of this article.

REFERENCES

1. Khalil FK, Keehn CA, Saeed S, Morgan MB. Verrucous psoriasis: a distinctive clinicopathologic variant of psoriasis. *Am J Dermatopathol.* 2005;27:204-7.
2. Monroe HR, Hillman JD, Chiu MW. A case of verrucous psoriasis. *Dermatol Online J.* 2011;17:10.
3. Kawtar I, Mariame M, Siham L, Fatimazahra M, Hassania A, Taoufiq H. Verrucous Psoriasis and Verrucous Lichen Associated With an Autoimmune Hepatitis. *J Clin Diagn Res.* 2014;2:2.
4. Curtis AR, Yosipovitch G. Erythrodermic verrucous psoriasis. *J Dermatolog Treat.* 2012;23:215-8.
5. Okuyama R, Tagami H. Psoriasis verrucosa in an obese Japanese man; A prompt clinical response observed with oral etretinate. *J Europ Acad Dermatol Venereol.* 2006;20:1359-61.
6. Zouboulis CC, Biczó S, Gollnick H, Reupke HJ, Rinck G, Szabó M, et al. Elephantiasis nostras verrucosa: beneficial effect of oral etretinate therapy. *Br J Dermatol.* 1992;127:411-6.

Copyright by Sarra Ben Rejeb, et al. This is an open access article distributed under the terms of the Creative Commons Attribution License, which permits unrestricted use, distribution, and reproduction in any medium, provided the original author and source are credited.

Source of Support: Nil, **Conflict of Interest:** None declared.

Palmar and plantar psoriasis and homeopathy – Case reports

Lawrence Chukwudi Nwabudike

N. Paulescu Institute of Diabetes, Str. I.L. Caragiale, Nr. 12, Sector 2, Bucharest, Romania

Corresponding author: Dr. Lawrence Chukwudi Nwabudike, E-mail: Chukwudi.nwabudike@live.com

ABSTRACT

Psoriasis is a chronic cutaneous disorder, which is protean in its manifestation. It is a significant source of morbidity and mortality. It is associated with arthropathy as well as disorders such as diabetes mellitus and coronary artery disease. Therapeutic guidelines offer a wide range of topical and systemic treatments, yet a number of patients are often dissatisfied with the treatment of their disease and, in consequence, seek other alternatives. Homeopathy is a gentle, safe method of treatment that would appear to have positive effects in the treatment of psoriasis. Three cases of palmar and plantar psoriasis treated with homeopathy are presented.

Key words: Palmar and plantar psoriasis; Homeopathy; Homeopathic medicine; Drug-aggravated psoriasis

INTRODUCTION

Psoriasis is a chronic inflammatory disorder with cutaneous and extracutaneous manifestations. Its prevalence varies from 0% in Taiwanese children to 8.5% in Norwegian adults [1]. There are various forms of psoriasis, which may be localized or generalized, including the plaque, guttate, pustular, flexural, erythrodermic, nail, articular, oral and ocular forms.

Management includes topical and systemic therapy, followed by maintenance therapy to maintain remission.

Homeopathy is a form of treatment that has evidence of efficacy in the management of psoriasis and may not require maintenance treatment, following remission [2,3]. Homeopathic medicines are known to rarely produce side-effects and are also cheap.

Presented in this paper are three cases of palmar and plantar psoriasis treated with homeopathy.

CASE REPORTS

Case 1

A 55-year old female, with a 4-month history of rash on her left sole with nail lesions affecting her left large toe. Past medical history was significant for Type 2 diabetes mellitus and hypertension. Examination revealed a single, hyperkeratotic plaque on the sole of the left foot, with occasional vesicles. She also had a hyperkeratotic area of skin on her left big toe, with nail dystrophy. Fungal examination was negative. She had received a topical steroid cream, followed by a herbal preparation, both of which failed to help. She was prescribed the homeopathic medicine *Staphysagria*, at MK potency, weekly. She went into remission in 6 months, but relapsed. Review showed that she had been on angiotensin converting enzyme (ACE) inhibitors. The cardiologist subsequently changed her medication to verapamil and she went into remission once more, with growth of nails and clearance of the toe and plantar lesions (Fig. 1a-c).

How to cite this article: Nwabudike LC. Palmar and plantar psoriasis and homeopathy – Case reports. Our Dermatol Online. 2017;8(1):66-69.

Submission: 13.04.2016; **Acceptance:** 27.07.2016

DOI: 10.7241/ourd.20171.18

Case 2

A 65-year old female presented with a 4-year history of a palmar rash, previously treated as eczema and fungal infection unsuccessfully. Examination revealed erythematous plaques on palms of hands. Biopsy confirmed psoriasis. The patient received the homeopathic medicine *Lycopodium*, MK potency, weekly, with remission within 3 months and remains in remission 2 years later. This patient also had received Beta-blockers during the period of remission, which caused flare-ups, with axillary lesions. The flares remitted upon substituting with rilmenidine (Fig. 2a-c).

Case 3

A 64-year old male presented with a history of generalized rash of 30 years duration. The rash was associated with intense itch. The rash was also present in the palmar and plantar areas, manifesting as hyperkeratosis and fissuring with erythema and mild swelling. This was a source of distress for him both personally and professionally as the patient is a driver by profession.

A biopsy was carried out, which confirmed the suspicion of psoriasis. He was given the homeopathic medicine *Tuberculinum* at MK potency, to be taken weekly, the homeopathic medicine *Sulphur* at CH30 potency to be taken for the itch and bland soaps and emollients were recommended.

The patient improved gradually with marked improvement of the palmar and plantar areas at 4 months of treatment and improvement of other skin areas, together with reduction in itch. The palmar and plantar lesions were in full remission at 1 year, together with most body areas (Fig. 3a-d).

DISCUSSION

Psoriasis is a chronic inflammatory disease. It is characterized by periods of spontaneous regression of variable length. Topical and systemic therapies are recommended, according to international clinical guidelines [4,5]. Maintenance therapy is often the rule, in order to avoid relapse. Complications, which may sometimes be severe, especially with the biologic agents, may occur. The cost of treatment can be very high and prohibitive especially for those not on health insurance.

Comorbidities may be associated with psoriasis and their treatment may affect the course of the disease. This was the case with patients 1 and 2, who relapsed

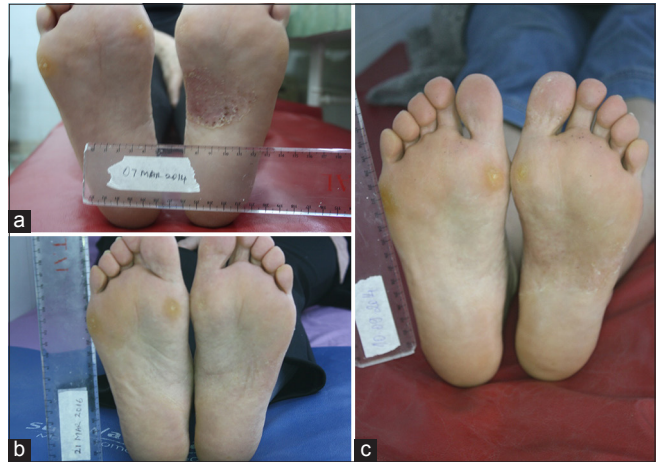

Figure 1: a) Erythematous, well-defined plaque, on left sole of foot. The right sole has calluses. b) Patient still in full remission 18 months later and after removal of ACE inhibitor therapy, c) Patient in full remission.

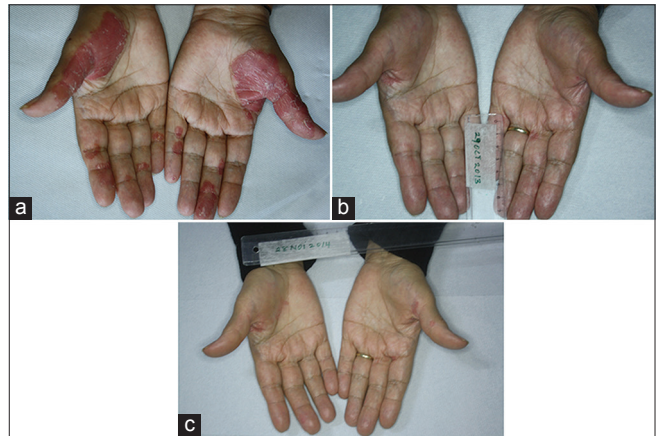


Figure 2: a) Erythematous, well-defined plaques on the palms and plantar aspects of fingers bilaterally. b) Patient in remission after 3 months. c) Patient still in remission.

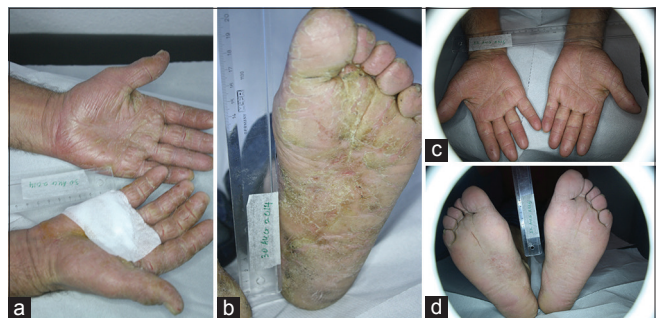


Figure 3: a) Erythema, hyperkeratosis and deep fissuring of both palms. The dressing is for the biopsy area. b) Hyperkeratosis of soles of foot. c) Patient in remission. Palmar hyperkeratosis, erythema and fissuring gone. d) Patient in remission. Plantar hyperkeratosis gone.

following treatment with ACE inhibitors and beta-blockers respectively, for hypertension. The patients subsequently improved upon withdrawal of the suspect medication. ACE inhibitors and beta-blockers are two classes of drugs, which have been associated with onset or exacerbation of psoriasis, amongst other medications such as NSAIDs, antimalarials, lithium, benzodiazepines, tetracyclines and dipyron [6,7]. Such a reaction, occurring in patients with a history of psoriasis, has been designated as “drug-aggravated psoriasis” and tends to continue even after the removal of the offending agent [7]. Improvement resumed after the removal of the offending drug, which may be an indication of efficacy of homeopathy as opposed to a spontaneous remission and may indicate the possible usefulness of homeopathy for this form of psoriasis also.

Homeopathy is a safe, cheap method of treatment that has also been found to be useful in certain cutaneous disorders, including atopic dermatitis [8], eczema [9], lichen striatus [10], seborrheic dermatitis [11], melasma [12], rosacea [13], dermatitis herpetiformis [14], verucca vulgaris [15], as well as psoriasis [2,3].

The mechanism of action of homeopathy in general and in skin diseases in particular is still not elucidated. What appears to be known is that highly diluted solutions emanate electromagnetic signals that mimic that of the original solute and that the water molecules in which the solute was originally dissolved form nanoparticles that appear to be identical to the original solute molecule [16,17]. These nanoparticles may then act to ameliorate the disease.

Although Witt et al [2] showed clear improvement in clinical lesions of psoriasis as well as quality of life scores, other authors in an earlier work suggest that there is no beneficial effect [18] of homeopathy in the therapy of psoriasis. This difference may be due to different population characteristics, as the positive study [2] was carried out amongst patients that were treated by classical homeopathy (the form used in this study also), which is individualized and tailored to each patient. Classical homeopathy is often the preferred method for deep-seated, chronic ailments. The patients in the negative study were drawn from those visiting an outpatient clinic and the method of homeopathic treatment not specified [18].

A recent study has shown a 15% increase in the number of adults using homeopathy in the United States [19].

This study also highlighted the fact that the patients mostly perceived a positive effect from their treatment.

CONCLUSION

Psoriasis can take many forms and the palmoplantar form is one of them. This form of psoriasis presents many challenges as the ability to work would be affected by both the cosmetic aspect of the disorder and the discomfort it would cause. Case three was a very clear example of this. Palmoplantar psoriasis may be mild and hard to detect or involve the entire palmar and plantar surface. The differential diagnosis includes eczema, dermatophyte infection, palmoplantar pustulosis, Reiter's disease and pompholyx.

Usually, the diagnosis of palmoplantar psoriasis is straightforward, but some cases required biopsy for confirmation.

Clinical improvement was sustained in these cases, following homeopathic treatment. Some cases relapsed following introduction of ACE inhibitors and beta-blockers, subsequently improving upon their removal, which may also be evidence of the efficacy of the homeopathic treatment, counting against a coincidental improvement, as drug-aggravated psoriasis does not improve after the removal of the offending agent, where no effective treatment is in place [7].

Homeopathy is a cheap and gentle form of treatment, which rarely produces side-effects. In an era of limited health budgets, where patients seek alternative solutions for their chronic disorders, there may be a place for homeopathy in the care of their chronic skin disorders.

Larger studies would probably be required to elucidate the place homeopathy might occupy in the treatment of patients with palmoplantar psoriasis.

REFERENCES

1. Parisi R, Symmons DP, Griffiths CE, Ashcroft DM. IMPACT Team. Global epidemiology of psoriasis: a systematic review of incidence and prevalence. *J Invest Dermatol.* 2013;133:377-85.
2. Witt CM, Lüdtke R, Willich SN. Homeopathic treatment of patients with psoriasis – a prospective observational study with 2 years follow-up *JEADV.* 2009;23:538-43.
3. Nwabudike LC. Psoriasis and homeopathy. *Proc Rom Acad Series B.* 2011;3:237-42.
4. Menter A et al. Guidelines for care for the management of psoriasis and psoriatic arthritis. *JAAD.* 2011;65:137-74.
5. Pathirana D, Ormerod AD, Saiag P, Smith C, Spuls PI, Nast A,

- et al. European S3-guidelines on the treatment of psoriasis vulgaris. *JEADV*. 2009;23:5-70.
6. Cohen AD, Bonneh DY, Reuveni H, Vardy DA, Naggan L, Hallevy S. Drug exposure and psoriasis: Case control and case-crossover studies *Acta Derm Venereol*. 2005;85:299-303.
 7. Kim GK, Del Rosso JQ Drug-provoked psoriasis: is it drug induced or drug aggravated? *J Clin Aesth Dermatol* 2010;3:32-8.
 8. Nwabudike LC. Atopic dermatitis and homeopathy. *Our Dermatol Online*. 2012;3:217-20.
 9. Signore RJ. Classic homeopathic medicine and the treatment of eczema. *Cosm Derm*. 2011;24:420-5.
 10. Signore RJ. Treatment of lichen striatus with homeopathic calcium carbonate. *Jl Amer Ost College Derm*. 2011;21:43.
 11. Nwabudike LC. Seborrheic dermatitis and homeopathy. *Our Dermatol Online*. 2011;2:208-10.
 12. Nwabudike LC. Melasma and Homeopathy. *Homeopathic Links*. 2012;25:99-101.
 13. Nwabudike LC. Rosacea and Homeopathy. *Proc Rom Acad Series B*. 2012;14:207-11.
 14. Nwabudike LC. Homeopathy in the treatment of dermatitis herpetiformis – a case presentation *Homeopathic Links*. 2015;28:44-6.
 15. Nwabudike LC. Homeopathy in the treatment of verruca vulgaris – An experience of two cases. *Proc Rom Acad Series B*. 2010;2:147-9.
 16. Montagner L, Aïssa J, Ferris S, Montagner J-L, Lavallée C. Electromagnetic signals are produced by aqueous nanostructures derived from bacterial DNA sequences. *Interdiscip Sci Comput Life Sci*. 2009;1:81-90.
 17. Chickramane PS, Suresh AK, Bellare RJ, Kane GS. Extreme homeopathic dilutions retain starting materials: A nanoparticulate perspective. *Homeopathy*. 2010;99:231-42.
 18. Jenssen P. Alternative therapy for atopic dermatitis and psoriasis: patient-reported motivation, information source and effect. *Acta Derm Venereol*. 1990;70:425-8.
 19. Dosset ML, Davis RB, Kaptchuk TJ, Yeh GY. Homeopathy use by US adults: Results of a national survey. *Am J Public Health*. 2016;106:743-5.

Copyright by Lawrence Chukwudi Nwabudike. This is an open access article distributed under the terms of the Creative Commons Attribution License, which permits unrestricted use, distribution, and reproduction in any medium, provided the original author and source are credited.
Source of Support: Nil, **Conflict of Interest:** None declared.

Angioma of the face: About two cases including one revealing Sturge Weber and Krabbe syndrome

Bénilde Marie Ange Tiemtoré-Kambou^{1,2}, Nomtongo Amina Ouédraogo^{1,3},
Nina-Astrid Ndé/Ouédraogo^{1,2}, Fagnima Traoré^{1,3}, Pakisba Ali Ouédraogo⁴,
Ben Aziz Dao^{1,4}, Boubacar Ouattara^{1,4}, Moussa Zanga^{1,5}, Ousséini Diallo^{1,4}, Rabiou Cissé^{1,4}

¹Faculté de Médecine Université Ouaga 1 Pr Joseph Ki-Zerbo, Ouagadougou, Burkina Faso, ²Service de Radiologie, Hôpital de District de Bogodogo, Ouagadougou, Burkina Faso, ³Service de Dermatologie, Centre Raoul Follereau, Ouagadougou, Burkina Faso, ⁴Service de Radiologie, Centre Hospitalier Universitaire Yalgado Ouédraogo, Ouagadougou, Burkina Faso, ⁵Centre Hospitalier Universitaire Pédiatrique Charles De Gaulle, Ouagadougou, Burkina Faso

Corresponding author: Dr. Bénilde Marie Ange Tiemtoré-Kambou, E-mail: kbenildema@yahoo.fr

ABSTRACT

Sturge Weber and Krabbe syndrome or Sturge Weber Syndrome (SWS) is a rare and sporadic disease. It associates with a variety of degrees a flat facial skin angioma in the V1 territory of the trigeminal, a pial angioma and a choroidal angioma all in the one side. The neurological involvement of epileptic seizures in fact all the gravity. The authors report two cases of angiomas plane of the face. The first case presents a complete association of the 3 signs in a 5 year old child. The second case presents an association of angioma and choroidal involvement without cerebral damage to imaging in a 25-year-old adult. They thus highlight the interest of imaging examinations in particular MRI in the diagnosis through the classification and follow-up of this pathology.

Key words: Sturge weber syndrome; Glaucoma; Epilepsy; Calcification

How to cite this article: Tiemtoré-Kambou BMA, Ouédraogo NA, Ndé/Ouédraogo NA, Traoré F, Ouédraogo PA, Dao BA, Ouattara B, Zanga M, Diallo O, Cissé R. Angioma plane of the face: About two cases of which one revealing sturge weber and krabbe syndrome. Our Dermatol Online. 2017;8(1):70-74.

Submission: 13.11.2016; **Acceptance:** 07.12.2016

DOI: 10.7241/ourd.20171.19

Angiome plan de la face: À propos de deux cas dont l'un révélant un syndrome de Sturge Weber et Krabb

Bénilde Marie Ange Tiemtoré-Kambou^{1,2}, Nomtongo Amina Ouédraogo^{1,3}, Nina-Astrid Ndé/Ouédraogo^{1,2}, Fagnima Traoré^{1,3}, Pakisba Ali Ouédraogo⁴, Ben Aziz Dao^{1,4}, Boubacar Ouattara^{1,4}, Moussa Zanga^{1,5}, Ousséini Diallo^{1,4}, Rabiou Cissé^{1,4}

¹Faculté de Médecine Université Ouaga 1 Pr Joseph Ki-Zerbo, Ouagadougou, Burkina Faso, ²Service de Radiologie, Hôpital de District de Bogodogo, Ouagadougou, Burkina Faso, ³Service de Dermatologie, Centre Raoul Follereau, Ouagadougou, Burkina Faso, ⁴Service de Radiologie, Centre Hospitalier Universitaire Yalgado Ouédraogo, Ouagadougou, Burkina Faso, ⁵Centre Hospitalier Universitaire Pédiatrique Charles De Gaulle, Ouagadougou, Burkina Faso

Corresponding author: Dr. Bénilde Marie Ange Tiemtoré-Kambou, E-mail: kbenildema@yahoo.fr

RÉSUMÉ

Le syndrome de Sturge Weber et Krabbe ou Sturge weber Syndrome (SWS) est une pathologie rare et sporadique. Il associe à des degrés divers un angiome plan cutané facial dans le territoire V1 du trijumeau, un angiome pial et un angiome choroïdien tous homolatéraux. L'atteinte neurologique faite de crises épileptiques en fait toute la gravité. Les auteurs rapportent deux cas d'angiomes plan de la face. Le premier cas présente une association complète des 3 signes chez un enfant de 5 ans. Le second cas présente une association de l'angiome et de l'atteinte choroïdienne sans lésion cérébrale à l'imagerie chez un adulte de 25 ans. Ils mettent ainsi en évidence l'intérêt des examens d'imagerie en particulier l'IRM dans le diagnostic à travers la classification et le suivi de cette pathologie.

Key words: Syndrome de sturge weber; Glaucome; Épilepsie; Calcification

INTRODUCTION

Les angiomes plans de la face sont des malformations capillaires. Elles peuvent révéler un syndrome de Sturge Weber krabbe ou syndrome de Sturge-Weber (SWS) ou angiomatose encéphalotrigémينية. Le SWS est un syndrome neuro-cutané grave qui associe un angiome plan de la face atteignant tout ou partie du territoire de la première branche du nerf trijumeau (ou nerf ophtalmique de Willis); un angiome capillaro-veineux cérébral, leptoméningé, souvent localisé en pariéto-occipital du même côté que l'angiome plan facial; des anomalies oculaires (glaucome, angiome choroïdien). Les trois tissus concernés par ces lésions ont la même origine embryologique (le derme du territoire de la première branche du nerf trijumeau, la pie mère, la choroïde oculaire [1]).

L'imagerie cérébrale permet d'en faire le diagnostic, montrant le plus fréquemment un angiome leptoméningé

homolatéral à l'angiome cutané. Le diagnostic doit être évoqué devant tout enfant présentant un angiome plan de la face atteignant le V1, puis complété par une imagerie cérébrale (IRM ou tomodensitométrie) et un examen ophtalmologique car les manifestations ophtalmologiques et neurologiques (épilepsie, retard mental, déficit moteur) en grèvent le pronostic [2].

Nous rapportons deux cas d'angiome plan de la face dont l'un révélant un SWS chez un enfant dans sa forme complète et l'autre chez un adulte associé uniquement à un glaucome.

CASE REPORT

Observation 1

Un enfant de 5 ans, issu d'un mariage non consanguin, venait réaliser une IRM cérébrale pour des troubles

How to cite this article: Tiemtoré-Kambou BMA, Ouédraogo NA, Ndé/Ouédraogo NA, Traoré F, Ouédraogo PA, Dao BA, Ouattara B, Zanga M, Diallo O, Cissé R. Angiome plan de la face: À propos de deux cas dont l'un révélant un syndrome de sturge weber et krabbe. Our Dermatol Online. 2017;8(1):70-74.

Submission: 13.11.2016; **Acceptance:** 07.12.2016

DOI: 10.7241/our.d.20171.19

du comportement, une épilepsie généralisée, un retard psychomoteur évoluant depuis la naissance. La tomодensitométrie cérébrale réalisée à la naissance avait conclu à un syndrome de Sturge Weber.

Il serait né d'une grossesse à terme qui se serait déroulée sans particularités. Sa consultation en dermatologie pour une plaque pigmentée étendue de l'hémiface droite retrouvait une vaste lésion maculeuse érythémateuse angiomatose siégeant sur la face en regard du territoire des trois branches du nerf trijumeau droit (Fig. 1). Comme antécédents il avait des crises tonico-cloniques. Il s'agissait de crises partielles complexes de l'hémicorps droit, fréquentes (parfois plus de 3 épisodes/jour), d'emblée graves et prolongées, avec des troubles de la conscience. Ces crises avaient amené les parents à consulter un pédiatre qui avec le diagnostic posé avait institué un traitement à base de Valproate de sodium en gouttes tous les soirs. A l'âge de la scolarité, 3 ans les parents l'inscrivirent à la maternelle et constatèrent ses difficultés d'apprentissage. Ils furent orientés vers un neurologue qui leur conseilla une école spécialisée et une imagerie par résonance magnétique (IRM) cérébrale pour apprécier l'évolutivité de la pathologie.

Le bilan sanguin était normal. La ponction lombaire était normale. L'examen ophtalmologique était revenu normal.

L'examen neurologique retrouvait des troubles du comportement (hyperactivité, écholalie), une épilepsie généralisée, un retard psychomoteur évoluant depuis la naissance. La tomодensitométrie (TDM) cérébrale réalisée à la naissance avait conclu à un syndrome de Sturge Weber. Cette TDM n'a pas été retrouvée.

L'imagerie par résonance magnétique aux séquences axiales en pondération T2 (TSE), (turbo spin écho), FLAIR (Fluid Attenuation inversion recovery), T2 * et diffusion T1 sans injection dans les trois plans, T1 HR 3D (Haute Résolution tridimensionnelle) après injection de contraste paramagnétique (Fig. 2a-d) associée aux séquences vasculaires retrouvait une atrophie corticale et sous corticale, pariéto-occipitale et temporale droite avec dilatation notable des sillons en regard.

On notait une bande en signal gyriiforme sur toutes les séquences de localisation occipito-pariétale droite en faveur d'une zone de calcifications. Il existait une prise de contraste gyriiforme superficielle au contact

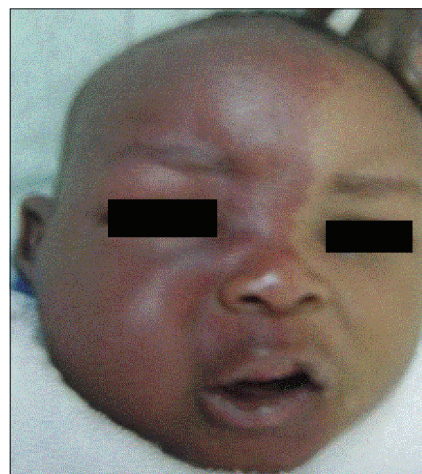

Figure 1: Photo du 1^{er} patient qui présentait depuis la naissance un angiome plan de la face occupant tous les territoires du trijumeau droit.

de la zone sus décrite correspondant à l'angiome leptoméningé. S'y associait une dilatation des veines corticales profondes communicantes avec les plexus choroïdes occipitaux droits, hypertrophiés et qui prenaient notablement le contraste après injection de gadolinium.

Devant l'angiome de l'hémiface droite, les antécédents du patient, les données de l'examen neurologique et les résultats de l'imagerie nous confirmons le SWS.

La prise en charge fait recours à un traitement médical à base de valproate de sodium 30 ml tous les jours. L'enfant ne fait plus de crises épileptiques depuis un an. Il a été inscrit dans une école spécialisée et s'adapte à la vie sociale. Une thérapie par le laser est préconisée pour l'angiome de la face mais non disponible dans notre contexte de travail. Une surveillance régulière neurologique est préconisée.

Observation 2

Un jeune adulte de 25 ans, élève-maitre consultait pour des céphalées de l'hémicrâne droit avec une rougeur de l'œil droit. On ne notait pas d'antécédents de trouble neurologique à type d'épilepsie. Il avait des céphalées épisodiques. Il n'y avait pas de déficit moteur. L'examen clinique retrouvait une macule angiomatose asymptomatique de la face en regard du territoire du V1 droit évoluant depuis la naissance (Fig. 3a and b). L'examen Neurologique Était Normal. L'examen ophtalmologique notait une dilatation des vaisseaux de l'oeil droit. Une lésion de chorio-rétinite étendue en temporal respectant la macula, un angle irido cornéen libre concluant à un glaucome au stade terminal de l'œil droit.

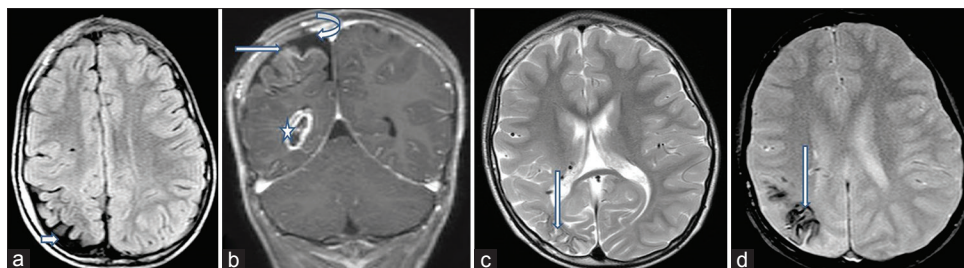


Figure 2: (a) Atrophie corticale et sous corticale pariéto-occipitale et temporale droite avec dilatation notable des sillons en regard, (b et c) - Bande en signal gyriforme (flèche blanche) sur toutes les séquences de localisation occipito-pariétale droite en faveur d'une zone de calcifications et hypertrophie des plexus choroïdes (étoile). Prise de contraste gyriforme superficielle (flèche courbe), (d) Dilatation des veines corticales profondes au voisinage et communiquant avec les plexus choroïdes occipitaux droits (flèches).

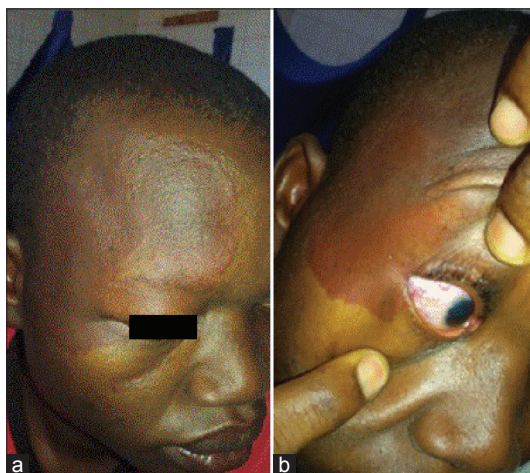


Figure 3: Photo du deuxième patient montrant un angiome plan droit "lie de vin" visible sur peau noire atteignant le territoire du V1: derme frontal et palpébral (a) et un angiome choroïdien (b).

Limagerie par résonance magnétique cérébrale n'a pas révélé d'anomalie à type d'angiome capillaro-veineux cérébral, leptoméningé, en pariéto-occipital du même côté que l'angiome plan facial.

La prise en charge a fait recours à cartéolol chlorhydrate 1 % une goutte dans chaque œil chaque soir, et un antalgique pour les céphalées. Une surveillance annuelle a été proposée. L'angiome choroïdien pourra être traité par chirurgie, ou surtout radiothérapie externe non disponible dans notre contexte.

DISCUSSION

Le syndrome de Sturge-Weber (SSW) est une phacomatose neuro-cutanée et oculaire à substratum malformatif vasculaire, congénitale, rare et non familiale, dont la description fut établie sur des bases clinique, histologique et radiologique entre 1879 et 1923. [3]

Il entraîne des désordres physiques, psychologiques et sociaux [4].

La fréquence du SSW chez un nourrisson porteur d'un AP facial touchant l'aire de la première branche du trijumeau V1 est diversement appréciée dans la littérature, du fait de biais de recrutement et de variations dans l'âge des populations étudiées; elle est actuellement estimée à 10 à 20% [3].

Notre premier patient avait tous les signes du SWS en dehors de l'atteinte oculaire. Devant tout angiome plan de la face en regard du territoire du trijumeau, il faut évoquer un SWS car l'angiome plan est un marqueur de risque de ce syndrome [3]. Il peut y être associé à 90 % chez Benedikt [5] ou à 84 % chez Zouiri [6].

Notre deuxième patient, adulte présentait une céphalée comme signe neurologique. En effet l'épilepsie et le retard mental sont les symptômes les plus communs dans le SWS, les céphalées migraine like a été reconnue comme la caractéristique la plus importante du SWS, 28% des patients suivis pour SSW peuvent avoir des céphalées ayant les caractéristiques cliniques de la migraine [7,8].

L'atteinte oculaire était marquée chez ce second patient. On estime que 10 % des angiomes plans sur le territoire du V1, avec répercussion ophtalmique, sont liés à une atteinte méningée associée [9].

L'atteinte cérébrale reste très peu probable avec un examen neurologique normal, sans comitalité et avec une IRM normale après l'âge de 1 an [10]. Cela pourrait corroborer avec le tableau du deuxième patient.

Selon Sujansky [11], dont la série ne comporte que des adultes, la disparité des fréquences des différentes manifestations tient à l'âge des malades des populations étudiées. Sur ses 52 patients, l'épilepsie est retrouvée dans 83% des cas, un déficit neurologique dans 65% des cas et un glaucome dans 60% des cas.

Ce syndrome est une urgence neuropédiatrique qui nécessite un suivi ophtalmique jusqu'à l'âge adulte, même si les premiers examens sont normaux.

Le syndrome de Sturge-Weber-Krabbe est exploré par des radiographies du crâne afin de détecter les calcifications cérébro-méningées, rarement visibles chez le nourrisson, un encéphalogramme et surtout par le scanner, ou par l'IRM, par l'étude du métabolisme cérébral (consommation de glucose).

Le traitement des angiomes plans est possible du moment que la comitialité est traitée.

Ces deux cas montrent la difficulté diagnostique du syndrome de Sturge Weber qui est rare 1/20000 et 1/50 000 naissances vivantes [12] et qui peut se présenter sous différents formes qui sont incomplètes selon la classification de Roch et coll [1,13].

Type I: angiome facial et leptoméningé. Type II: angiome facial sans atteinte cérébrale décelable. Type III; angiome leptoméningé isolé.

La littérature fait état d'atteinte bilatérale à l'imagerie cérébrale [13,14] mais un SWS sans lésions cérébrales est rare d'où la particularité de notre patient adulte. Cela constitue selon Benchekroun une curiosité dermatologique [1]. Cependant le glaucome et les signes neurologiques à type de céphalées chez notre second patient nous ont fait évoquer un SWS, bien que l'IRM n'ait pas montré de lésions. Il n'a pas été retrouvé de malformation artérioveineuse, cérébelleuse, d'anomalie des veines. Il n'y avait pas non plus de contraste méningé. Cette absence de signes neurologiques autres que les céphalées pourrait expliquer le diagnostic tardif de notre 2^e patient.

En revanche, tous les APF occupant le territoire de VI ne constituent pas le SWS.

CONCLUSION

Les angiomes plans de la face peuvent avoir des étiologies multiples, dont certaines pathologies graves comme le SWS. Il faut savoir y penser devant des signes d'appels surtout oculaires et neurologiques d'où l'intérêt de l'imagerie par résonance magnétique.

REFERENCES

1. Benchekroun TS, Jorio-Benkhra M, El Malki-Tazi A. Syndrome de Sturge Weber Krabbe à propos de deux observations. Méd Maghreb. 1998;71:15-9.
2. Pascual-Castroviejo I, Pascual-Pascual S, Velázquez-Fragua R, Viano J. Sturge-Weber syndrome: study of 55 patients. Can J Neurol Sci. 2008;35:301-7.
3. Boukobza M, Enjolras O, Cambra MR, Merland JJ. Syndrome de Sturge-Weber. Données actuelles de l'imagerie neuroradiologique. J Radiol. 2000;81:765-71.
4. Govori V, Gjikolli B, Ajvazi H, Morina N. Management of patient with Sturge-Weber syndrome: a case report. Cases J. 2009;2:9394.
5. Benedikt R, Brown D, Walker R, Ghaed V, Mitchell M, Geyer C. Sturge-Weber syndrome: cranial MR imaging with Gd-DTPA. AJNR Am J Neuroradiol. 1993;14:409-15.
6. Zouiri G, Ahmina A, Kriouile Y. Syndrome de Sturge-Weber-Krabbe: à propos de 6 cas. Research. 2014;1:894.
7. Klapper J. Headache in Sturge-Weber syndrome. Headache.1994;34:521-2.
8. Smirniotopoulos J, Murphy F. The phakomatoses. AJNR Am J Neuroradiol. 1992;13:725-46.
9. Maruani A. Syndrome de Sturge-Weber. Presse Méd. 2010;39:482-86.
10. Ville D, Enjolras O, Chiron C, Dulac O. Prophylactic antiepileptic treatment in Sturge-Weber disease. Seizure. 2002;11:145-50.
11. Sujansky E, Conradi S. Outcome of Sturge-Weber syndrome in 52 adults. Am J Med Genetics. 1995;57:35-45.
12. Dahan D, Fenichel G, El-Said R. Neurocutaneous syndromes. Adolesc Med. 2002;13:495-509.
13. Cagneaux M, Caron S, Auvin S, Soto Ares G. Syndrome de Sturge-Weber bilatéral. J neuroradiol. 2009;35:305-6.
14. Moifo B, Nguefack S, Moulion Tapouh JR, Gonsu Kamga J, Abdouramani A, Mah E, et al. Syndrome de Sturge-Weber bilatéral: aspects cliniques et scanographiques; à propos de deux cas. J Afr Imag Méd. 2016;1:1-5.

Copyright by Bénilde Marie Ange Tiemtoré-Kambou, et al. This is an open-access article distributed under the terms of the Creative Commons Attribution License, which permits unrestricted use, distribution, and reproduction in any medium, provided the original author and source are credited.

Source of Support: Nil, Conflict of Interest: None declared.

Annular skin lesions in childhood: Review of the main differential diagnoses

Diana Narváez, Beatriz Di Martino Ortiz, Mirtha Rodríguez Masi

Department of Dermatology, Clinicas Hospital, Faculty of Medical Sciences, National University of Asuncion, Paraguay

Corresponding author: Prof. Dr. Beatriz María Di Martino Ortiz, E-mail: beatrizdimartino@gmail.com

ABSTRACT

Figurate skin eruptions are fixed or migratory lesions, which is clinically characterized by annular circinate, arcuate, targetoid or polycyclic plaque. Although most skin lesions typical annular are dermatophytosis (ringworm), general practitioners and especially pediatricians have to consider other possible diagnoses. Tinea corporis often can be diagnosed based on a direct positive test with potassium hydroxide. Topical and systemic antifungal are usually curative. Pityriasis rosea is characterized by small lesions, light erythematous colored, distributed along the lines of division of the skin. Treatment is symptomatic. Granuloma annulare is characterized by annular plaques with non-squamous indurated edges, usually in the extremities. Half of the cases resolve spontaneously within two years. Hansen's disease may present with similar body ringworm plates by submitting one or more annular lesions. Urticaria, that may affect 10 to 20 percent of the population, is presented with evanescent annular plates with no scales. The subacute cutaneous lupus erythematosus may occur in a ring on sun-exposed areas as well as Papulosquamous form. Erythema annulare centrifugum typically presents annular shaped scaly patches on the edges of the erythematous plaques. In all cases both findings, clinical and histopathological should be considered when it comes to annular lesions which are frequently seen in daily routine.

Key words: Figurate erythema; Erythema annular; Granuloma annulare; Tinea corporis; Centrifugal annular erythema

INTRODUCTION

Annular lesions are extremely common in daily clinical dermatological practice, but can be misleading for general practitioners unfamiliar with them.

The term “annular” is derived from the Latin word “ring”. The lesions appear as macules (changes in skin color) circular or ovoid, or plaques (solid content lesions more than 1 cm. of diameter in which predominate the extent and surface rather than deep) with an erythematous border and a clear center.

The most common cause of annular lesions found in the adult and child population is ringworm, which can be successfully diagnosed without a biopsy, in typical cases. However, conditions other than this, may present the same clinical appearance (Table 1).

Various mechanisms have been proposed to explain the annular configuration of lesions, not always satisfactory. One of the proposed mechanisms is based on irrigation, so that each round macula represent the territory irrigated by a single arteriole. Other authors consider that it could be centrifugal extension of a pathological process, whether infectious, neoplastic or allergic phenomenon.

Tinea Corporis

Ringworm is caused by fungi of the genus *Microsporum*, *Trichophyton* and *Epidermophyton*. The transmission thereof occurs by direct contact from person to person, from animals to humans and from the soil to animals and/or humans, depending if you try to anthropophilic, zoophilic or geophilic species [1].

How to cite this article: Narváez D, Di Martino Ortiz B, Rodríguez Masi M. Annular skin lesions in childhood: Review of the main differential diagnoses. Our Dermatol Online. 2017;8(1):75-80.

Submission: 29.04.2016; **Acceptance:** 13.06.2016

DOI: 10.7241/ourd.20171.20

Table 1: Main annular lesions that occur in childhood

Diagnosis	Clinical features	Histopathology	Treatment
Tinea corporis	Erythematous annular plates.	Psoriasiform epidermal acanthosis. Intracorneal pustules. PAS+for hyphae.	Topical or systemic antifungals.
Pityriasis rosae	Small salmon plates, with scales on the edges, along the lines of division of the skin. One is higher (herald).	Irregular epidermal acanthosis, spongiosis, diskeratosis (in heraldic plate), dermal hematic extravasation.	Topical or systemic corticosteroids; UVA; UVB.
Granuloma annulare	No scaly skin color patches, with raised indurated edges, extremities.	Necrobiosis area of dermal collagen surrounded by a palisade of inflammatory cells.	Spontaneously resolution or after biopsy. Topical or intralesional corticosteroids.
Hansen's disease	Hypochromic macules or erythematous plaques without scales. The edges will be more or less defined depending on the type of Hansen.	Lymphocytic (HI), granulomatous (HT, HBT) or macrophage (HBB, HBL, HL), periadnexal, perivascular and perineural infiltrate. ZN+for BAAR.	Dapsone, rifampicin, clofazimine.
Urticaria	Evanescient not scaly erythematous wheals. Absence of skin alterations.	Perivascular dermal edema. Extra and intravascular neutrophils. Perivascular eosinophils. Mild leukocytoclasia. No vasculitis.	Oral antihistamines
Centrifugal annular erythema	Annular plate with scale leaves the erythematous border.	Superficial and deep perivascular dermal lymphocytic infiltrate. Variable skin alterations.	Topical or systemic corticosteroids. Oral antihistamines. Treating the underlying cause.
Subacute cutaneous lupus erythematosus	Papulosquamous annular plates, with or without scales, in sun-exposed areas.	Vacuolar interface dermatitis with apoptotic keratinocytes. Pigmentary incontinence. Superficial perivascular lymphocytic infiltrate. Mucin.	Topical, systemic or intralesional, antimalarials.

It is characteristic in the skin of the trunk and extremities, restricted to the stratum corneum and most commonly occurs on exposed skin, although it can develop anywhere on the body.

It is most common in tropical regions like our country. Pets are an important factor in transmission, especially those zoophilic species. The incubation period is 1 to 3 weeks. The infection spreads centrifugally from the point of skin infection with a clear center, resulting in typical erythematous annular lesions of different sizes, with well circumscribed scaly, papular, vesicular or pustular edge. As they increase in size, the plates may have concentric rings (Fig. 1) [2,3].

Topical and oral imidazoles are the treatment of choice for ringworm. General measures are indispensable, such as avoiding moisture or maceration of the skin, weight loss and the use of cotton clothes [4,5].

Pityriasis Rosea

Common skin disease of children and young adults characterized by been a self-limited disease. It is usually preceded by upper tract respiratory symptoms [6].

Initially a heraldic plaque or mother plaque, typically located in the trunk, between 2 and 10 cm of diameter appears. The plaque is oval, erythematous, with a collarette desquamation on the periphery. After days, others plaques appear, similar in appearance to heraldic plaque but smaller in size, between 5 and 10 mm in

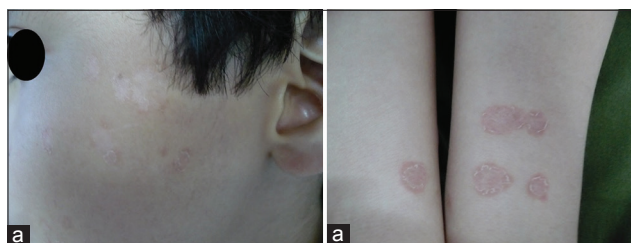


Figure 1: a) Tinea faciei, b) Tinea corporis. Erythematous annular lesions of different sizes, with well circumscribed scaly in the face and arms.

diameter distributed throughout the trunk and less commonly in extremities, along the lines of division of the skin. If they are located on the back take on the appearance of a Christmas tree.

Skin biopsy usually is not indicated in these patients, although in borderline cases is performed. It shows a spongiform-subacute pattern with chronic non-specific inflammatory infiltrate, with apoptotic keratinocytes in the epidermis (especially in heraldic plaque). The picture is resolved between five to eight weeks from the beginning [4].

Rarely needs treatment, but if patients have accompanying pruritus, emollients such as zinc oxide, calamine lotions, and topical low power corticosteroids can be used [7]. Systemic antihistamines can also be used. In more severe cases treatments with ultraviolet light and natural sun exposure are described [4,8].

Granuloma Annulare

Self-limiting inflammatory entity of unknown etiology, characterized by annular skin color or slightly erythematous plaques, with elevated periphery and depressed center (Fig 2a and 2b), possibly result of non-specific reactions from various agents [9-11].

Located more often in the hands, feet, wrists and ankles, they can be located anywhere in the body. These lesions are usually asymptomatic, although some patients report mild itching. It is more frequent in females, predominantly in children and young adults. Four clinical forms are described: classical or localized, generalized, perforating and subcutaneous [12]. It have been linked to certain triggers such as: vaccination, insect bites, contact dermatitis to nickel, solar exposure, intestinal parasites and Epstein-Barr virus, HIV, Herpes zoster virus infections among others. Is thought to be the result of vasculitis, necrobiosis secondary to trauma, activation of monocytes, Langerhans cell or a T cell phenomenon of type IV hypersensitivity. Some even believe there is a Koebner phenomenon [13].

Three histological varieties are distinguished: granulomatous (palisade), interstitial (incomplete) and deep (nodular) forms (Fig. 2c). They differ only in the location of granulomas. The granulomatous form is characterized by a palisade of histiocytes around degenerated collagen area where it can be mucin shown with special stains (Alcian blue or colloidal iron). It can be seen eosinophils and lymphocytes in the inflammatory infiltrate. In interstitial variant, macrophages are disposed between the collagen bands without forming palisade granulomas. The nodular form is characterized by deep subcutaneous granulomas with necrobiosis, but clinical presentation is not annular, it's nodular [14].

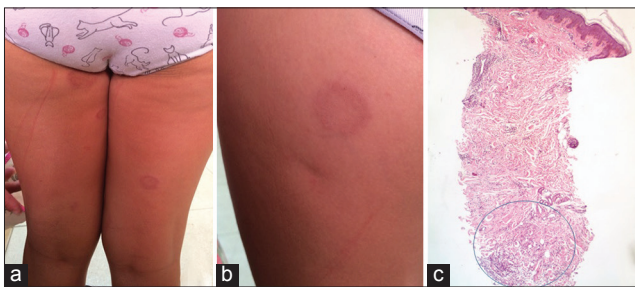


Figure 2: Granuloma annulare. (a and b) No scaly skin color patches, with raised indurated edges in lower extremities. (c) Necrobiosis area of dermal collagen surrounded by a palisade of inflammatory cells.

The diagnosis is made by clinical and histopathologic correlation. In the absence of fever or other symptoms it is not necessary to request additional tests. Some of the patients with granuloma annulare can present hyperlipidemia, hipergammaglobulineamia and circulating antinuclear antibodies. It can be ordered fasting and postprandial and determinations of glycated hemoglobin in patients with a family history of diabetes [4].

There is no successful treatment of the disease. Up to 50% of patients with localized forms may have spontaneous resolution in two years with a likely recurrence in 80% of cases, unlike the generalized form, where it is rarer and if there is not a spontaneous resolution it last at least 3 to 4 years.

In the limited forms it is not recommended any treatment. It is advisable to explain to parents the mildness of the disease, although if the therapeutic demand is strong, you can try the local treatment with topical corticosteroids, medium or high power, to avoid intralesional injection. In the deep or subcutaneous forms excision is indicated. In generalized forms dapsone (100 mg/day) can be used [4].

Hansen's Disease

Leprosy is a chronic infectious disease caused by *Mycobacterium leprae*; as intracellular parasite triggers an immune response in the host, with the participation of cell-mediated immunity. The development of the disease is determined by two variables: a) opportunity for exposure to mycobacteria b) the ability of immune response that the host can offer.

The household contacts are the main source of infection. It has an incubation period of between 3 and 10 years.

The diversity in clinical manifestations will be conditioned by the play of interactions between *M. leprae* and the immune response offered by the host. And they may be: indeterminate, tuberculoid, dimorphic or borderline and lepromatous. Of these, the dimorphic form, which is a rare type even in childhood, is characterized by annular lesions tend to enclose areas of healthy skin and result in cut wafer images (Fig. 3). No mucous membranes or internal organs are affected. The smear is generally negative, because in the pediatric population pauci bacillary forms are the most frequent.

The histopathology evidence lymphohistiocytic perivascular and perineural dermal infiltrates (Fig. 4). With Zeehl - Neelsen staining AAR may be displayed, but not in the indeterminate or tuberculoid forms [4]. The dimorphic leprosy should be treated with 3 drugs (multibacillary).

Urticaria

Acute urticaria, annular urticarial or acute hypersensitivity syndrome represents an allergic hypersensitivity reaction mediated by histamine after viral or bacterial infections or after consumption of food or drugs. It is frequent in infants and children aged between 4 months and 4 years.

Most authors believe that this is not a single entity. In early childhood is often misdiagnosed as erythema multiforme or as serum sickness disease. Clinically, it begins as a pruritic maculopapules growing rapidly to form erythematous annular, polycyclic or arcuate evanescent character (disappear in less than 24 hours).

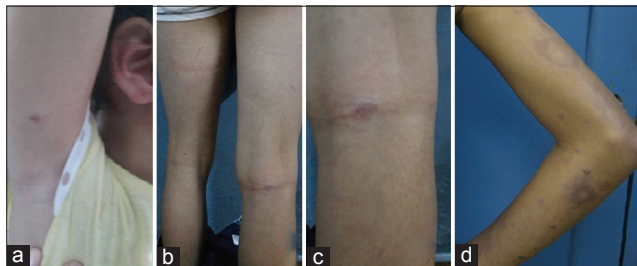


Figure 3: Hansen's disease. (a, b and c) Erythematous plaques without scales. (d) Borderline type. The plaque has a clear center in "wafer cut".

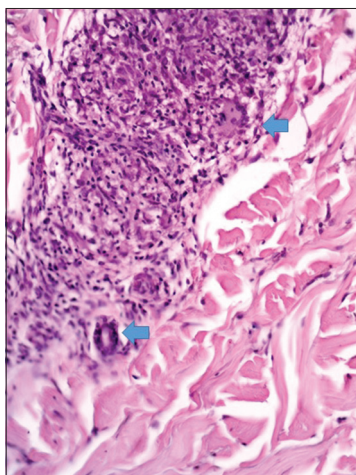


Figure 4: Histopathology of Hansen's disease. Periadnexal, perivascular and perineural infiltrate of macrophages and lymphocytes. The arrows point a giant cell (as seen in tuberculoid and borderline tuberculoid types) and an eccrine duct.

It may have a central clearing or acquire a ecchymotic tone, which simulates the target lesions of erythema multiforme, but there are not epidermal necrosis, blisters or mucosal involvement (Fig. 5a).

Histologically is characterized by dermal edema, vascular dilation, presence of perivascular cellular infiltrate composed of lymphocytes, mast cells, eosinophils and neutrophils and as diagnostic key there are many intravascular neutrophils. There are no fibrin extravasation or leukocytoclasia, findings in vasculitis, despite the large number of neutrophils in biopsies. The findings are most striking in superficial dermis (Fig. 5b).

The existence of dermografism, with erythema and edema in areas of trauma, is a regular feature of urticaria. Another typical manifestations of that entity is the appearance of angioedema in the face, hands and feet. It can be confused with serum sickness disease, however in this case the individual lesions are fixed and there is no dermografism associated [15,16].

It is a self-limiting rash with resolution of episodes in about 8-10 days, with good response to oral antihistamines, reserving the use of systemic corticosteroids for more severe cases [15].

Centrifugal Annular Erythema

It is considered a hypersensitivity reaction to different antigens. Its appearance is preferably in adults, although there are also cases reported in infants and children. In the pediatric population centrifugal annular erythema is more frequently associated with *Candida albicans*, dermatophytes, VEB and poxvirus infections. It can also occur in relation to most common cancers in children, such as leukemia and Hodgkin lymphoma [17].

Usually asymptomatic or poorly pruritic rash remits spontaneously in about two or three weeks, reappearing in the same locations or in other different at variable

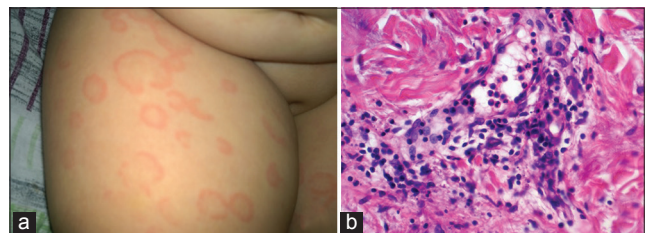


Figure 5: Urticaria. (a) Evanescent not scaly erythematous wheals. (b) Perivascular dermal edema. Extra and intravascular neutrophils. No leukocytoclasia. No vasculitis.

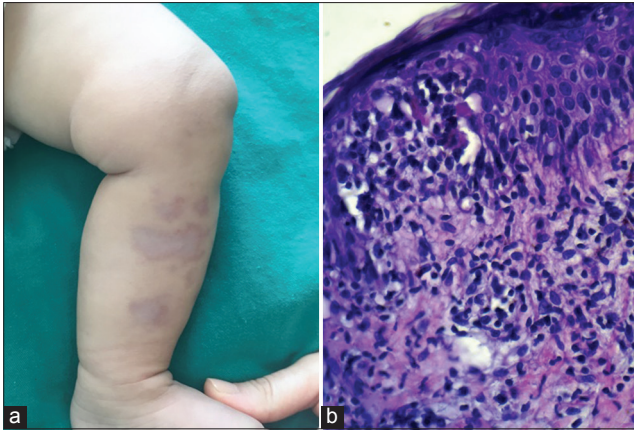


Figure 6: Neonatal lupus (sub acute form). (a) Papulosquamous annular plates, with or without scales, in sun-exposed areas. (b) Vacuolar interface dermatitis with apoptotic keratinocytes. Superficial perivascular lymphocytic infiltrate.

time intervals. Lesions, single or multiple, appear anywhere on the body, but preferably on the trunk and the root of the limbs, in the form of erythematous papules that migrates slowly (2-3 mm/day), flattening as it grows, fading at its center and leading to complete annular lesions or arc segments. There are two variants, one with peripheral scaly edge and intensely itchy, and the other with deeply infiltrated sharp edge without scale and asymptomatic [18].

As we already indicate, depending on the location of the perivascular infiltrate we found two variants; in the superficial type there is focal parakeratosis in the edge of the lesion, spongiosis and superficial perivascular lymphohistiocytic infiltrate, while in the deep form there is no epidermal changes, superficial and deep perivascular mononuclear cells, melanophages, slight vacuolization and necrotic keratinocytes in the dermo epidermal junction [18].

As for treatment, antihistamines are effective when there is itching, especially in children. The use of antibiotics or antifungals, in the absence of demonstrated disease, has been useful in some isolated cases, as well as administration of systemic corticosteroids [19,20].

Subacute Cutaneous Lupus Erythematosus

The subacute cutaneous lupus erythematosus may present with polycyclic annular lesions. They can accompany a commitment systemic lupus erythematosus. This variant has pronounced photosensitivity and, regression leave a hypochromia

without atrophy. The periphery can have blistering or crusting.

Histopathology of these lesions shows thickening of the basal membrane, hydropic degeneration of the basal layer, and superficial lichenoid lymphocytic infiltrate with melanophages (Figs 6a and 6b) [4].

They are very important measures designed to avoid exposure to sunlight, such as the use of sunscreens. Topical treatments include the use of corticosteroids and tacrolimus. For systemic treatment are useful hydroxychloroquine to 6.5 mg/kg/day, prior ocular control and every 4 to 6 months (color vision and visual field) or thalidomide at a dose of 50 to 100 mg/day [4].

CONCLUSION

1. The appearance of annular lesions in childhood is always a diagnostic challenge.
2. The clinical history, appearance and characteristics of lesions by the valuable contribution of histopathology, allow us to know the different entities and separate benign self-limiting pathologies that do not require treatment of those who needed.
3. For all of the above, when we confronted a ring, annular or figurative lesion in children we paust y attention to the age of the onset injury, lesion characteristics, duration and location, evolution and histological findings to establish a diagnostic orientation and an etiological treatment.

REFERENCES

1. Bologna J, Jorizzo J, Rapini R. *Dermatology*. 3rd Ed. USA: Elsevier; 2012;2:1255-65.
2. Hainer BL. Dermotphyte infections. *Am Fam Physician*. 2003;67:101-8.
3. Elewski BE, Nagashima – Whalen L. Superficial fungal infections of the skin 5th Ed Philadelphia 1994: 1029-49.
4. Larralde M, Abad E, Luna P. *Dermatología pediátrica*. 2da Ed. Buenos Aires: Journal; 2013: p. 225-563.
5. Smith EB. The treatment of Dermatophytosis: safety considerations. *J Am Acad Dermatol*. 2000;43:113-9.
6. Cheong WK, Wong KS. An epidemiological study of pityriasis rosea in Middle Road Hospital. *Singapore Med J*. 1989;30:60-2.
7. Fitzpatrick TB, et al., eds. *Dermatology in general medicine*. 4th Ed. New York: McGraw-Hill, 1993: 261-79.
8. Stulberg D, Wolfrey J. Pityriasis Rosea. *Am Fam Physician*. 2004;69:87-91.
9. Hawryluk EB, Izikson L, English JC. Non-infectious granulomatous diseases of the skin and their associated systemic diseases: an evidence-based update to important clinical questions. *Am J Clin Dermatol*. 2010;11:171-81.
10. Cyr PR. Diagnosis and management of granuloma annulare. *Am Fam Physician*. 2006;74:1729-34.

11. Narvaez V, Vera M, Sáez de Ocariz M, Castillo M, Domínguez L. Granuloma anular en pacientes pediátricos. *Dermatol Pediatr Latinoam*. 2005;3:117-22.
12. Smith D, Downie J, Dicostanzo D. Granuloma annulare. *Int J Dermatol*. 1997;36:326-33.
13. Hsu S, Le E, Khoshevis M. Differential diagnosis of annular lesions. *Am Fam Physician*. 2001;64:289-96.
14. Requena L, Fernández-Figueras MT. Subcutaneous granuloma annulare. *Semin Cutan Med Surg*. 2007;26:96-9.
15. Chen KR, Pittelkow MR, Su D, Gleich J, Newman W, Leiferman KM. Recurrent cutaneous necrotizing eosinophilic vasculitis. A novel eosinophil-mediated syndrome. *Arch Dermatol*. 1994;130:1159-66.
16. Torrelo A. Urticaria y síndromes urticariales. *Dermatología en pediatría general*. Madrid: Aula médica; 2007. p. 251-8.
17. Cohen BA. Neonatal dermatology. *Pediatric dermatology*, 3rd Ed. Philadelphia. Elsevier; 2005: 59–61.
18. Toledo-Alberola F, Betloch-Mas I. Eritemas Anulares en la Infancia. *Actas Dermo-Sifiliogr*. 2010;101:473-84.
19. Freedberg IM, Eisen AZ, Wilff K, Austen KF, Goldsmith LA, Katz SI. Erythema annulare centrifugum and other figurate erythemas. *Fitzpatrick's dermatology in General medicine*, 6th ed. NewYork: McGraw-Hill; 2003 p. 977-9.
20. García Muret MP, Pujol RM, Giménez-Arnau AM, Barranco C, Gallardo F, Alomar A. Annular recurring erythema annulare centrifugum: a distinct entity? *J Am Acad Dermatol*. 2006;54:1091-5.

Copyright by Diana Narv ez, et al. This is an open access article distributed under the terms of the Creative Commons Attribution License, which permits unrestricted use, distribution, and reproduction in any medium, provided the original author and source are credited.
Source of Support: Nil, **Conflict of Interest:** None declared.

Stigmata in cutaneous leishmaniasis: Historical and new evidence-based concepts

Mohamed Ahmed Al-Kamel

¹Chair, Department of Dermatology, Regional Leishmaniasis Control Center (RLCC), Sana'a University Hospital, Sana'a, Yemen

Corresponding author: Dr. Mohamed Ahmed Al-Kamel, E-mail: dralkamel@hotmail.com

ABSTRACT

This report is a part of many articles and studies published by the Regional Leishmaniasis Control Center (RLCC). Willing that this review might enrich understanding of the global epidemiological profile of CL, the author relied on research evidence, his experience and a social survey to highlight historical and current concepts of cutaneous leishmaniasis (CL) as a globally most prevalent and highly stigmatizing form of leishmaniasis disease, introduce new ideologies upon CL-related stigmata, review the most common determinants and implications of CL stigmata; and report a short survey illustrating stigmata experience among some affected patients from Yemen. He also reviewed a successful community-led action to reduce the burden of CL and its related stigmata in Yemen.

Key words: Cutaneous; Leishmaniasis; Stigma; Stigmata; Concepts; Yemen

Abbreviations: ELYP, Eradication of Leishmaniasis from Yemen Project; RLCC, Regional Leishmaniasis Control Center; CL, Cutaneous leishmaniasis; MCL, Mucocutaneous leishmaniasis; VL, Visceral leishmaniasis; DCL, Disseminated cutaneous leishmaniasis; CLS, Cutaneous leishmaniasis stigma; CLSS, Cutaneous leishmaniasis social stigma; CLAS, Cutaneous leishmaniasis aesthetic stigma; CLPS, Cutaneous leishmaniasis psychological stigma; NTD, Neglected tropical diseases; WHO, World Health Organization; ISD, International Society of Dermatology; AAD, American Academy of Dermatology; ILDS, International League of Dermatological Societies

INTRODUCTION

Stigma related to chronic health conditions, particularly neglected tropical diseases (NTD) is a global phenomenon and stealth weapon that results in severe unwanted consequences, and its related concepts have become an increasingly important topic for health sciences.

Although leishmaniasis disease-linked lifelong stigma have been reported from several countries and the WHO has recently highlighted its severity, dermatology literatures characterizing the epidemiology of leishmaniasis have almost not readily accounted for the ideologies and hidden burden of its stigma [1,2].

Molly's concluded with a proposed origin and evolution of human Leishmaniasis being initially linked to the

origin of man in Africa (since the beginning of life on Earth) and then following these organisms throughout the Paleolarctic. It has been historically portrayed in ceramics, figures, papyrus and statues [3-5].

Leishmaniasis, a chronic infectious but non-contagious disease, is widespread in tropical and subtropical areas, caused by *Leishmania* parasites, transmitted by bites of infected female phlebotomine sandflies and its primary hosts are vertebrates (most likely humans, canids, rodents and hyraxes). The human leishmaniasis particularly affects the poor [1].

As per previously published recommendation by the author and according to several dermatology literatures, leishmaniasis has been simply classified into two broad clinical types: (1) stigmatizing cutaneous leishmaniasis

How to cite this article: Al-Kamel MA. Stigmata in cutaneous leishmaniasis: Historical and new evidence-based concepts. Our Dermatol Online. 2017;8(1):81-90.

Submission: 24.05.2016; **Acceptance:** 29.09.2016

DOI: 10.7241/ourd.20171.21

(CL); (2) the lethal (if untreated) visceral leishmaniasis (VL) [1,4,5].

Stigma - Historical Background

The Greeks first used the term ‘stigma’ to describe a mark made through branding to designate a person of undesirable moral character. In the nineteenth century, there were a striking analogy between skin disease and poverty, therefore stigma connected with skin disorders might have gained greater cultural value. In 1895, French sociologist Émile Durkheim was the first to explore stigma as a “social phenomenon”. In 1963, Canadian-American Erving Goffman [1], one of the most influential sociologists of the twentieth century, introduced stigma into the psychological literature as “the phenomenon whereby an individual with an attribute which is deeply discredited by his/her society is rejected as a result of the attribute; stigma is a process by which the reaction of others spoils normal identity.” Stigmatized people are those that do not have full social acceptance and are constantly striving to adjust their social identities. He identified three types of stigma: stigma of character traits, physical stigma and stigma of group identity (tribal stigma). Merriam-Webster simply defines stigma as “a set of negative and often unfair beliefs that a society or group of people have about something.” [6,7]

Cutaneous Leishmaniasis - Historical and Current Concepts

First description of conspicuous lesions similar to current cutaneous leishmaniasis (CL) has been reported in texts dating back to 2500-1500 BC [1]. In the Americas, evidence of the cutaneous form of the disease in Peru, Colombia and Ecuador appears in pottery depicting skin lesions and deformed faces dating back to AD 400 to AD 900. In the 10th century, Arab physicians provided more descriptions about the disease [8,9].

Clinically, CL is considered one of the most serious skin diseases in developing countries. The World Health Organization (WHO, 2004) has acknowledged it as a severely neglected ‘Category 1’ disease, which covers emerging or uncontrolled diseases. In 2013, the global mean age-standardized DALYs for CL was 0.58 per 100,000 people [3].

CL is a spectral and extremely stigmatizing disease that is often compared with leprosy, and predominantly

affects face and other visible parts of the body. It usually presents with a single or multiple nodules, ulcers, or plaques on skin (cutaneous leishmaniasis; CL), mucous membranes (mucosal leishmaniasis; ML), or both, skin and mucous membranes (mucocutaneous leishmaniasis; MCL).

Although, some CL lesions heal spontaneously leaving ugly life-long scars, the majority of lesions are non-healing or chronic with sequels leading to disfigurement or mutilation with severe social and economic consequences [10].

CL may progress to MCL when dissemination by hematogenic or lymphatic route occurs, and most discussions of the disease have considered MCL as a severe form of CL. Untreated MCL lesions often lead to extensive, disfiguring destruction of mucous tissues of the mouth, pharynx, larynx, nose, or eyes, as well as other affected parts of the skin, causing extreme aesthetic alteration, serious disability and may end with death due to chronicity and respiratory complications [4,11].

Synonyms

As a mysterious disease with persistent prevalence, CL lesions have been cited with various popular names that differ from a region to region, such as; “Balkh” and “Kandehar sore” in Afghanistan; “Baghdad boil” and “Basra button” in Iraq; “Biskra boil” or “bouton de Biskra” in Algeria; “Aleppo evil” in Syria; “badah”, “Ofiah” and “atharah” in Yemen; “little sister” in Saudi Arabia (the South); “Jericho boil” in Jordan; “Pendeh sore” in central Asia; “Delhi boil” in India; “Ashkhabad sore” in Turkmenistan; “godovik” in Russia; “caneotica” in China; “salek” in Iran; “angry ulcer” in the Pacific; “bouton de Crète” in Greek island; “mountain leprosy” in Amazon region; “chiclero’s ulcer” in Mexico and Ecuador; etc.

Although, some of these vernacular names suggest links to the lesion’ morphology, disease course, geographic location, cultural beliefs (mythology), other terms refer to CL accompanying stigma. As an example, all identified local terms for CL in Yemen actually mean ‘stigma’ and refer to both aesthetic and social stigmata (Al-Kamel MA, 2016); “Badah” means “apparent”, “Atharah” means “trace” and “Ofiah” means “ugly” [5].

Cutaneous Leishmaniasis Stigma (CLS)

Stigmatization is the hidden and often neglected manifestations of the visible features of CL. Evidence shows that CLS is developed primarily from the extreme

aesthetic and functional alteration that disfigurement, ulceration, scarring and deformities may cause, making affected people look different from others.

CLASSIFICATION OF CUTANEOUS LEISHMANIASIS-RELATED STIGMATA

As per author's perspective, stigmata that potentially apply to CL has been classified into three main types:

CL Social Stigma (CLSS)

CLSS is that has been referred to by most the literatures discussing stigmatization in CL and some chronic skin conditions, such as leprosy.

Simply, CLSS is the negative and often unfair beliefs that a society have about patient bearing CL. The concept of social stigma has been classified into [2]: (1) enacted stigma, when patients are confronted with overt acts of discrimination; (2) perceived stigma, when patients fear encountering overt or enacted stigma; (3) internalized stigma, when the social stigma is internalized or accepted by those at whom it is targeted.

In addition to CLSS, the author has identified and defined two more types of CL-related stigmata that he has previously discussed (Al-Kamel, 2015). CL also causes important social and psychological stigma (WHO, 2007) [12].

CL Aesthetic Stigma (CLAS)

The author has defined CLAS as a sense of a bodily image dissatisfaction and how aesthetic the CL active lesions, scars, deformities and disabilities look like. CLAS is not necessarily associated with social discrimination or individual isolation. Subsequently, CLAS might be classified into; (1) individual (perceived) CLAS and (2) social (enacted) CLAS.

Because of sandfly vector exposure, most leishmaniasis lesions occur on prominent parts of the body such as mouth, nose, eyes, ears and hands, and thus resulting with a sort aesthetic stigmata that make CL different from all other comparable tropical skin diseases, such as prosy. Evidence showed that patients with active lesions or healed scars showed increased rates of body satisfaction impairment [13,14].

CL Psychological Stigma (CLPS)

CL might profoundly influences patient's personality and psychological well-being, constituting

a more destructive power inside CL-affected individuals.

CLPS is the deepest dimension of the prominent CL lesions. The authors has defined CLPS as the deep pain or the psychological stress the infected patient feels as a result of CL-related fears, social stigma and aesthetic stigma.

"The deep pain the leishmaniasis-related-stigma insert inside the affected women is the most destructive power in their social lives [15]."

GLOBAL BURDEN

A severe stigma associated with CL, has been reported¹. It is a global phenomenon of an important consideration [13,16].

In Afghanistan that has had the highest incidence of cutaneous leishmaniasis in the world, it was reported that severe stigma and trauma are associated with CL among all age groups, particularly in children and women [17].

In Yemen, women with CL often present late and experience not only physical deformities and the risk of death, but also the painful stigma and its consequences, a similar situations to that of Leprosy, decades ago.[15].

In Ecuador, women from leishmaniasis-endemic areas of NW Ecuador appeared to be more aware of CL and scars because of its associating stigmatization [18].

In Pakistan, "this is not me," a woman said when she explained her encounter with CL related stigma [13].

However, literatures measuring the stigmata arising from CL in some endemic geographical areas in Asia, Africa, South America and Europe have not existed [19].

DETERMINANTS

All the physical and organic precipitating factors related to the host, vector, reservoir and environment that may influence the morbidity of CL as a physical illness, might also influence the severity of stigmata related to the disease as a stigmatizing agent. Hereafter, determinant factors directly linked to the stigmatization as a moral challenge.

Personal Determinants

Disfiguring lesions' attitude (location, severity, visibility and chronicity)

CL scars leave a very strong stigmatizing impact as they last for years. CL disfiguring nodular lesions resemble those of lepromatous leprosy, and patients with disseminated cutaneous leishmaniasis (DCL) usually suffer stigma similar to that associated with leprosy^[2]. Mucosal lesions are more stigmatizing than cutaneous lesions, active lesions than residual scars, DCL more than individual lesions and those on the prominent features more than those on the hidden parts are.

Physical disabilities

Some CL forms are chronic with sequels leading to severe disabilities or mutilation with severe social, aesthetic and psychological stigmata.

Gender and age

Yanik et al. (2004) reported that younger generations affected by CL showed less acceptance of stigma than older adults did [20]. Although, stigmatization occurs in all age and sex groups, its effects are greater in female than male patients are [15].

Morality and psychological wellbeing

In relation to CL stigma, many suicides or attempts have been recorded [21].

Fearfulness and misconceptions

Unreasonable fears of infecting others, carcinogenesis and death are not uncommon feelings that could exacerbate CL-related stigmata. Moreover, fears from antileishmanial drugs-associated complications or from social stigmatization beyond exposure and diagnosis, were reported to the author, may prevent patient from seeking medical assistance, make barriers to recovery, and thus directly aggravate CLS. The same outcomes may accompany the false belief that leishmaniasis is of little health importance.

Socio and Geopolitical Determinants

Sociocultural attitudes

Magnitude and consequences of CLS vary across societies, respecting several dimensions, such as civilizational, religious and cultural peculiarities. In spite it is well documented that CL stigmatized women are often put on the edges of society and been not eligible for marriage or work in some societies, such as Afghanistan

and Yemen, it is likely true in other countries with such conservative societies. On the contrary, S. Ramdas et al. concluded that CL is not generally a stigmatized disease in Suriname (though this is not to deny that stigmatization may occur occasionally) [3].

Mythology

Myths and often mistaken beliefs, such as “the disease is directly contagious or by sharing meals and household goods”, “leishmaniasis is necessarily concomitant with AIDS” and “it is a Divine punishment” are still having an overwhelming impact in some traditional societies with an extreme negative impacts especially on children, as they are prevented from attending school, stigmatized in their communities, and families have been documented to isolate their children from siblings to stop further spread of the infection. Another example, Chayahuitas, a community in the Peruvian Amazon, believe that CL patient has a worm in the nasal cavity that nibbles away at night at the rim of the nostrils and ears [22,23].

Economic context

Because, leishmaniasis is strongly linked with poverty, scars are considered a mark of low social status carrying with them a social stigma.

Population mobility

Migration and displacement are important factor in the disease and its related stigmata transmission. People with CL have been victimized as individuals and even in groups, for example, refugees from Afghanistan are identified by their “trademark” scars left behind by CL disease [14].

IMPLICATIONS

CL not only affects the physical well-being of the infected individual, but also its related stigmata impose what has been termed a “hidden burden” and often affect their psychological, social and economic well-beings.

Implications Upon Individual Context

CL-related stigmata often lead to a high social burden and marginalization. Unaffected people tend to isolate affected, parents isolate their affected children from others in the family, women are often separated from their children during the disease by their family and not allowed to breast-feed, and younger women often experience difficulties in marriage [3,16,24].

Evidence showed that CLS might affect the behavior of those who are stigmatized, mould one's personality, shape their emotions and beliefs and completely change one's perception of self, especially for children and women [25]. CL stigmatized patients showed body satisfaction impairment, increased rates of depression and anxiety and even suicidal tendency, with a larger decrement in their quality of life. This may predispose to further physical health deterioration and severe psychiatric morbidity [13,15,22].

In certain societies, CL stigma may also influence individuals' ability for education and employment. Girls and women who became lonely on the grounds of leishmaniasis usually face destitution. Therefore, CL stigma kills its victim socially and literally [13,26].

Implications Upon Social Context

The social implication of CLS is much more distressing to patients with CL than the disease individual effects. Thus affecting their community interaction, social relationships and friendships. Their families may experience reduced educational opportunities that may contribute to higher illiteracy rates and further inequities between those affected and those who are not. An example, about 2,000 students in different parts of Badakhshan (Afghanistan), most of them girls, have reportedly been absent since the leishmaniasis outbreak started, provincial officials said.

CLS also may influences labor market, reduces work capacity and national income. For example, 77% of men in Ecuador believe that CL diminishes their ability to work [22].

Implications Upon Public Health

CLS may hinder treatment seeking through fear or shame to be seen in public places or because of social exclusion that may result in the disease getting worse, increase transmission and make it difficult to trace patients [27].

SITUATION IN YEMEN: IMAGE, ACTION AND SURVEY

Yemen republic is high endemic for the neglected, deadly flesh-eating leishmaniasis disease that affects predominantly poor rural women and children [13]; it is one of the nine countries that had significantly greater DALYs from CL than the mean [27].

Literatures conducted at the Regional Leishmaniasis Control Center (RLCC), Yemen, concluded that: Leishmaniasis is the most common parasitic infestation and the first most prevalent infectious disease in some regions; Mutilating MCL is the most prevalent form (Fig. 1); Stigma is synonymous with CL; Women with leishmaniasis often present late and experience not only physical deformities and the risk of death, but also the painful stigma of the disease and its consequences, a similar situation to that of leprosy decades ago [5,15,28].

RLCC and ELYP – Community-led Actions

Regional Leishmaniasis Control Center (RLCC), a charitable non-governmental organization that currently involve 4 regional centers and more than 100 volunteers, was founded during April 2013 in collaboration with the American Academy of Dermatology (AAD) and the International Society of Dermatology (ISD). RLCC was established as the first stage of the ISD-sponsored community dermatology project Eradication of Leishmaniasis from Yemen Project (ELYP) to execute ELYP's community educational, surveillance, detection, treatment, control and research programs and campaigns (Fig. 2). ELYP had took place in January 2013 by the ISD member Dr. Mohamed Ahmed Al-Kamel to confront the dire need for action to implement effective leishmaniasis surveillance and control [15,29].

As an outcome, the project ELYP has achieved spectacular success and received worldwide critical acclaim. It made a big difference in the leishmaniasis

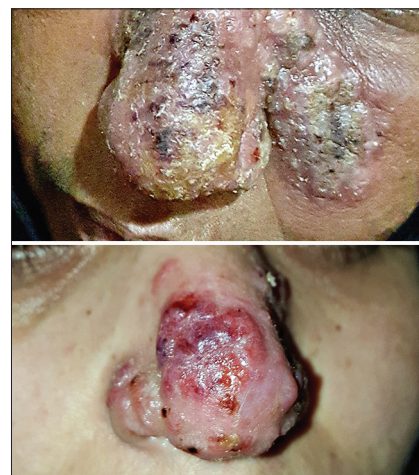

Figure 1: Socially, aesthetically and psychologically stigmatizing MCL lesions affecting two female interviewees at the Regional Leishmaniasis Control Center office in Sana'a, Yemen.



Figure 2: Regional Leishmaniasis Control Center's educational and treatment campaigns to reduce the burden of CL stigmata in Yemen through remote field campaigns (a and b), congresses (c), workshops (d), mass media (e), outpatient clinics (f), and free medicine donation (g and h).

situation in Yemen, addressed its magnitude, eradicated it from some areas, dealt with and improved its alarming prevalence among children and women who are the neglected and highest risk groups, solved some issues associated with poor access to proper drugs and significantly raised community awareness of the disease that was near to zero among most community sectors. Medicine donation through Medicine-For-All Program has enabled patients with leishmaniasis to freely receive medicine they otherwise would not have been able to afford, reduced their mortality and morbidity and minimized the extensive impact leishmaniasis stigmata have on their lives. In addition to those sensible achievements, ELYP has attracted local and global attention to these problematic issues [13].

SOCIAL SURVEY

Objective

To screen, assess and measure the existence and extent of the above mentioned types, determinantes and implications of CL-related stigmata (CLS) among

Yemeni patients population and their relatives, the author concurrently conducted this short social survey at the Regional Leishmaniasis Control Center (RLCC) clinics in Sana'a (the capital city) and Radaa (an endemic district of Al-Baydaa governorate). He's willing that it may enrich this review and support his concepts upon classification, determinants and implications of CL-related stigmata (CLS).

Methods

This survey was conducted in May 2016, through free discussions with randomly chosen patients with CL who were under treatment and follow-up at the RLCC units in Sana'a and Radaa. Eleven patients (10 females and 1 male) from seven Yemeni governorates were recruited. Only one oral question was directed to all interviewees "How have this disease affected your life?"; without written questionnaires, leading questions or guiding answers, except little words to clarify the type of stigma the patient complained. Variables included patient's number, name, sex, governorate, type of lesions, lesion's/s' location, detected types of stigmata and remarks. Obtained opinions were manually recorded as per **their own words**, analyzed and tabled.

Results

Table 1 demonstrates the interviewees' demographic data and the analytical distribution of their answers as per their words over the related variables. Interviewees reported their experience with CLS as the following, seven patients (63.64%) experienced social stigma, seven patients (63.64%) experienced aesthetic stigma and eight patients (72.73%) experienced psychological stigma.

Discussion

Ten patients (90.91%) experienced at least one type of CL stigmata, five patients (45.45%) experienced the three types of CLS, two patients (18.18%) experienced two types of CLS, three patients (27.27%) experienced one type of CLS, and only one patient hadn't had any experience with CLS.

"She lost herself from all aspects, became dark and sick. But after the successful treatment at RLCC, she improved, attends parties, and her psychological stress was decreased," said a mother of a 17-year-old Yemeni girl with CL small scar on her forehead and complaining of the three types of CLS. "I had a fear from eating or deforming my face and death," said

Table 1: Interviewees answers' details categorization

Pt. No.	Pt. name	Sex	Age	Governorate	Lesions	Location	Social stigma CLSS	Aesthetic stigma CLAS	Psychological stigma CLAS	Remarks
1	Molouk	F	39	Dhamar	Big multifocal MCL plaque	Nose	Fears of infecting their children Locked into home Socially denied	It is ugly	Depression Fears of deformity and death	N/A
2	Naseem	F	19	Raimah	Big ulcer	Left wrist	No shame	It is cosmetically embarrassing	No fears	I had not known what is!
3	Amnah	F	40	Al Baydaa	Big scar	Left forearm	Shame from getting outside, joining social events, or working in farm	N/A	Fear of malignancy	"We shy if it is on the face Infected girls usually are not married, and refrained from going to school. Affected women afraid of infecting their children by direct contact or while showering them," she said
4	Amar	F	15	Ibb	DCL	Cheeks and left hand	Always covers her face	Always covers her face	Stress	N/A
5	Saleh	M	40	Al Baydaa	CL	Left hand's dorsum	Feels forestation	It is ugly	Depression	N/A
6	Tahani	F	16	Mahweet	Ulcer	Upper lip	Feels shame Fear of infecting others through food and drink	It is ugly	Feels something spreading inside Fear of getting disability	"Early and free medicine fro, RLCC decreased the stigma," she said
7	Sondos	F	17	Sana'a	Scar	Forehead	Friends were afraid of being infected Home stay Avoids all social activities Covering scar with hair Left work Became careful about study	Unaccepted look Carefulness about others' opinion Always asks her friends about their feeling towards her affected face	Severe depression Aggression Fair of malformation	"She lost herself from all aspects, became dark, and sick. After treatment, she improved, is attending parties, and her psychological stress is decreased," her mother said
8	Sa'diah	F	60	Al Baydaa	DCL	Nose and left forearm	Doesn't shy Usually attends social events	N/A	Anxiousness Fear of medical treatment (injections) Fear of disability and nasal destruction	"I do not experience any social or aesthetic stigma, because I am old," she said
9	Rokaiah	F	12	Ibb	Ulcer	Nasal tip	Does not shy	N/A		"I do not shy, because it's from God," she said
10	Mo'agabah	F	50	Hajjah	Plaque	Nose and left cheek	Does not shy	Disfigured face	No anxiety or depression	N/A
11	Sa'adah	F	15	Al Baydaa	Nodule	Left cheek	Avoidance of going out home Cover face, even among relatives	N/A	Fear of deformity	N/A

a 39-year-old Yemeni mother with MCL plaque on her nose during a treatment session at the RLCC in Sana'a (Fig. 1). "We shy if it is on the face, infected girls usually do not marry and refrained from going to school, and affected women afraid of infecting their children by direct contact or while showering them," said a 40-year-old woman with a big CL scar on the left forearm. "Early diagnosis and medicine donation through RLCC minimized stigmata that I have," said a 16-year-old girl with upper lip CL ulcer and had the three types of CLS. "I do not experience any social or aesthetic stigma, because I am old," said an elderly woman with DCL and had only CLPS. However, "I do not shy, because it's from the God," said the 12-year-old girl with a small nasal tip CL ulcer who had not experienced any sort of CL-related stigmata. All patients who experienced stigmatization were rural inhabitants while the non-complained girl was an urban inhabitant.

In this survey, interviewees reported variable levels of CL-related social isolation, aesthetic impairment and emotional stress, particularly the girls who would lose their chance of getting married. Interviewees praised the role of the RLCC in alleviating their suffering.

The current survey has supported most of the concepts, implications and determinants introduced in this review in relation to CLS, and concluded that: Yemeni patients and their relatives show challengeable concerns towards CLS as a common complaint which is not only age- or sex-specific, but also depends on many other determinants, such as disease nature, fears, personal and social beliefs. Some patients consider stigmata related to CL worse than the disease itself; Almost, the majority of Yemeni patients with active CL lesions or those carrying CL-related scars and deformities experience at least one type of CL-related stigmata; Psychological type (CLPS) is the most prevalent form of CLS, followed by social (CLSS) and aesthetic (CLAS) types.

DE-STIGMATIZATION

It is concluded that identifying and resolving its determinants are the two key points to destigmatize CL, or at least decrease the risk of developing serious implications, through: (1) integrating national and community-based programs to combat CL and its related stigmata; (2) early detection and management of CL cases; (3) resolving issues associated with access to antileishmanial drugs; (4) resolving issues associated with women and children who are at the highest risk for

CL stigma; (5) changing the image and misconceptions related to CL as a mysterious disease through education and mass media; (6) physical and social rehabilitation of stigmatized patients; (7) improving economic and general health conditions of the poor.

CONCLUSION

Apart from its physical impact, it is evident that CL poses severe and spectral stigmata with considerable implications upon the physical, moral, social, economic and public health contexts that may kill stigmatized individuals, both socially and literally.

The author has identified and classified CL related stigmata into three types: (1) CL Social Stigma (CLSS), which might be perceived, enacted or internalized; (2) CL Aesthetic Stigma (CLAS), which might be perceived or enacted; (3) CL Psychological Stigma (CLPS). Almost, every patient with CL may have at least one of the three CL-related stigmata.

CLAS is the differential feature that causes stigmatization in CL to look more challengeable, spectral and different from that of all other comparable neglected tropical diseases, such as leprosy. Social and aesthetic stigmata are synonyms of CL in some countries, such as Yemen, and young women are the most affected sex group.

Although, CL is stigmatizing in all affected societies that affects all sex and age groups, the type and severity of CL stigmata vary, however, and rely on several personal, sociopolitical and geopolitical determinant factors that may be common or different across societies.

Available evidence shows that the key point of stigmatization in CL are the characteristic visible active lesions, scars and deformities that predominantly affect exposed, aesthetic parts of the body, in addition to fears and mistaken beliefs about CL nature and transmission methods. Mucosal lesions are more distressing than cutaneous lesions, active lesions than residual scars, DCL more than individual lesions and those on the prominent features more than those on the hidden parts are.

The concurrent survey supports most of the concepts, implications and determinants of CLS introduced in this review. It concluded that the majority of Yemeni patients with active CL lesions or those carrying CL-related scars and deformities experience at least one type of CL-related stigmata considering them worse than the disease itself. Psychological type (CLPS) is

the most prevalent form of CLS, followed by social (CLSS) and aesthetic (CLAS) types.

Community-led initiatives such as ELYP and RLCC would significantly minimize the extensive impact CL stigmata have on patients' lives.

This report has introduced new ideologies upon stigmatizing process in CL and highlighted further types of CL-related stigmata, which might increase the understanding of that hidden dimension and enrich the global epidemiological profile of CL.

HIGHLIGHTS

- CL is a spectral and extremely stigmatizing disease that is often compared with leprosy.
- Stigmatization is the hidden and often neglected manifestations of the visible features of CL.
- CL-related stigmata has been classified into three main types, social (CLSS), aesthetic (CLAS); and psychological (CLPS).
- CLSS is 'the negative and often unfair beliefs that a society have about patient bearing CL'.
- CLAS is 'a sense of a bodily image dissatisfaction'.
- CLPS is 'the deep pain or the psychological stress the infected patient feels as a result of CL-related fears, social stigma and aesthetic stigma'.
- CLPS is the most destructive power in the lives of the affected individuals, particularly women.
- Patients with diffuse or disseminated cutaneous leishmaniasis (DCL) usually suffer stigmata similar to those associated with leprosy.
- The social implication of CLS is much more distressing to patients than the disease individual effects.
- The majority of Yemeni patients with active CL lesions or those carrying CL-related scars and deformities experience at least one type of CL-related stigmata.
- Yemeni patients with CL often consider CLS worse than the disease itself.
- Stigmata may kill the stigmatized individuals, both socially and literally.

REFERENCES

1. Van Brakel WH. Measuring health-related stigma--a literature review. *Psychol Health Med.* 2006;11:307-34.
2. Ramdas, van der Geest S, Henk DFH. Nuancing stigma through ethnography: the case of cutaneous leishmaniasis in Suriname. *Social Scien Med.* 2016;151:139-46.
3. Tuon FF, Amato Neto V, Sabbaga Amato V. Leishmania: origin, evolution and future since the Precambrian. *FEMS Immunol Med Microbiol.* 2008;54:158-66.
4. Molly MacMorris-Adix. Leishmaniasis: A review of the disease and the debate over the origin and dispersal of the causative parasite *Leishmania* 2008;1.
5. Al-Kamel MA. Leishmaniasis in Yemen: a clinicoepidemiological study of leishmaniasis in central Yemen. *Int J Dermatol.* 2016;55:849-55.
6. Émile Durkheim (1982). *Rules of Sociological Method* 1895; The Free Press. <http://comparsociology.com/wp-content/uploads/2013/02/Emile-Durkheim-Rules-of-Sociological-Method-1982.pdf> [Accessed May 08, 2016.]
7. Goffman E. *Stigma: Notes on the management of spoiled identity.* Prentice-Hall, Englewood Cliffs (NJ), 1963.
8. Akhouni M, Kuhls K, Cannel A, Votyčka J, Marty P, Delaunay P, et al. A Historical Overview of the Classification, Evolution and Dispersion of Leishmania Parasites and Sandflies. *PLoS Negl Trop Dis.* 2016;10:4349.
9. Manson-Bahr PEC. Old World leishmaniasis, p. 206-217. In F. E. G. Cox (ed.), *The Wellcome Trust illustrated history of tropical diseases.* The Wellcome Trust, 1996, London, United Kingdom.
10. Alrajhi AA, Ibrahim EA, De Vol EB, Khairat M, Faris RM, Maguire JH. Fluconazole for the Treatment of Cutaneous Leishmaniasis Caused by *Leishmania major*: *N Engl J Med.* 2002;346:891-5.
11. Camargo LB, Langoni H. Impact of leishmaniasis on public health. *J Venom Anim Toxins incl Trop Dis.* 2006;12:527-48.
12. WHO. Leishmaniasis Control programme. Report: the consultative meeting on cutaneous leishmaniasis geneva, who headquarters, 2007.
13. Reyburn H, Rowland M, Mohsen M, Khan B, Davies CR. The prolonged epidemic of anthroponotic cutaneous leishmaniasis in Kabul, Afghanistan: "bringing down the neighbourhood. *Trans R Soc Trop Med Hyg.* 2003;97:170-6.
14. Kassi M, Afghan AK, Rehman R, Kasi PM. Marring Leishmaniasis: The Stigmatization and the Impact of Cutaneous Leishmaniasis in Pakistan and Afghanistan. Utzinger J, ed. *PLoS Neglected Tropical Diseases.* 2008; 2:259.
15. Al-Kamel MA. Impact of leishmaniasis in women: A practical review with an update on my ISD-supported initiative to combat leishmaniasis in Yemen (ELYP). *Int J Women Dermatol.* 2016. doi:10.1016/j.ijwd.2016.04.003
16. Weiss MG. Stigma and the Social Burden of Neglected Tropical Diseases. Utzinger J, ed. *PLoS Neglected Tropical Diseases.* 2008;2:237.
17. Reithinger R, Aadil K, Kolaczinski J, Mohsen M, Hami S. Social impact of leishmaniasis, Afghanistan. *Emerg Infect Dis.* 2005;11:634-6.
18. Calvopina M, Armijos RX, Hashiguchi Y. Epidemiology of leishmaniasis in Ecuador: current status of knowledge - A review. *Mem Inst Oswaldo Cruz.* 2004;99:663-72.
19. Diniz JL, Costa MO, Gonçalves DU. Mucocutaneous Leishmaniasis: clinical markers in presumptive diagnosis. *Braz J Otorhinolaryngol.* 2011;77:380-4.
20. Yanik M, Gurel M, Kati M. The psychological impact of cutaneous leishmaniasis. *Clin Exp Dermatol.* 2004;29:464-7.
21. Modabber F1, Buffet PA, Torreele E, Milon G, Croft SL. onsultative meeting to develop a strategy for treatment of cutaneous leishmaniasis. *Kinetoplastid Biol Dis.* 2007;6:3.
22. Homsy Y, Makdisi G. Leishmaniasis: A forgotten disease among neglected people. *Internet J Health.* 2009;11:1.
23. Odone G1, Bourdy G, Castillo D, Estevez Y, Lancha-Tangoa A, Alban-Castillo J, et al. Perception of leishmaniasis and evaluation of medicinal plants used by the chayahuita in peru. part II. *J Ethnopharmacol.* 2009;126:149-58.
24. WHO EMRO. 2016. Malaria and leishmaniasis.
25. Major B, Laurie T. O'Brien. The Social Psychology of Stigma. *Ann Rev Psychol.* 2005;56:393-421.

26. Muela Ribera J, Peeters Grietens K, Toomer E, Hausmann-Muela S. A Word of Caution against the Stigma Trend in Neglected Tropical Disease Research and Control. *PLoS Negl Trop Dis*. 2009;3:445.
27. Karimkhani C, Wanga V, Coffeng LE, Naghavi P, Dellavalle RP, Naghavi M. Global burden of cutaneous leishmaniasis: a cross-sectional analysis from the Global Burden of Disease Study 2013. *Lancet Infect Dis*. 2016;pii: S1473-3099(16)00003-7.
28. Al-Kamel MA. Spectrum of winter dermatoses in rural Yemen. *Int J Dermatol*. 2016;55:512–17.
29. Al-Kamel MA. Regional leishmaniasis control center (RLCC) Yemen. in: 22nd Congress of the European Academy of Dermatology and Venereology, Istanbul, Turkey. October 2-6, 2013. EADV Abstracts 2013. - Istanbul: October 02, 2013.

Copyright by Mohamed Ahmed Al-Kamel. This is an open access article distributed under the terms of the Creative Commons Attribution License, which permits unrestricted use, distribution, and reproduction in any medium, provided the original author and source are credited.
Source of Support: Nil, **Conflict of Interest:** None declared.

Un cas de mastocytose cutanée [A case of cutaneous mastocytosis]

Salsabil Attafi Sehli¹, Salma Ghdanfi², Wafa Rkik¹

¹Department of Pathology, Siliana Hospital, Siliana, Tunis, Tunisia, ²Department of Dermatology, Siliana Hospital, Siliana, Tunis, Tunisia

Corresponding author: Salsabil Attafi Sehli, MD., E-mail: sehlialsabil@hotmail.com

Nous rapportons l'observation d'un garçon âgé de 13 ans, qui consultait pour des macules éruptives de l'avant bras (Fig. 1) évoluant depuis 1an. Le signe de Darier était négatif. Une biopsie a été effectuée. Histologiquement, le tissu cutané était le siège d'un infiltrat inflammatoire superficiel, interstitiel ou péri vasculaire, composé essentiellement de cellules mastocytaires, à noyau dense, ovalaire et à cytoplasme mal défini, comportant de nombreuses granulations intra et extracytoplasmiques, (Fig. 2a) bleutée en coloration usuelle et éosinophile après coloration au Giemsa (Fig. 2b).

Le diagnostic de mastocytose cutanée était retenu.

Après élimination d'une atteinte systémique, le patient était mis sous antihistaminiques et une liste des aliments, des médicaments et des circonstances histamino-libératrices a été remise aux parents afin de prévenir l'aggravation de la symptomatologie.

Les mastocytoses cutanées sont les formes les plus fréquentes des mastocytoses, maladies rares, caractérisées par une accumulation et une prolifération anormales de mastocytes dans un ou plusieurs organes. Elles sont le plus souvent isolées, mais peuvent être associées à d'autres atteintes et font alors partie des mastocytoses systémiques. Elles surviennent surtout chez les jeunes enfants.

Les mastocytoses cutanée hétérogènes sur le plan clinique, sont de diagnostic facile et de pronostic favorable, surtout chez l'enfant.

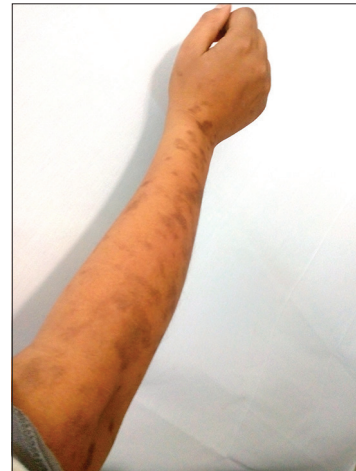

Figure 1: Lésions maculeuses de couleur brun-rouge de taille variable de l'avant bras.

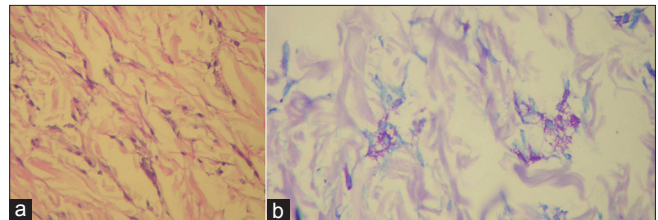


Figure 2: Cellules mastocytaires, à noyau dense, ovalaire et à cytoplasme mal défini, comportant de nombreuses granulations intra et extracytoplasmiques, bleutée en coloration usuelle (a) et éosinophile après coloration au Giemsa (b).

Copyright by Salsabil Attafi Sehli, et al. This is an open access article distributed under the terms of the Creative Commons Attribution License, which permits unrestricted use, distribution, and reproduction in any medium, provided the original author and source are credited.

Source of Support: Nil, **Conflict of Interest:** None declared.

How to cite this article: Sehli SA, Rkik W. Un cas de mastocytose cutanée [A case of cutaneous mastocytosis]. Our Dermatol Online. 2017;8(1):91.

Submission: 06.03.2016; **Acceptance:** 28.09.2016

DOI: 10.7241/ourd.20171.22

Maduromycosis of foot

Mrinal Gupta

Consultant Dermatologist, Treatwell Skin Centre, Jammu, India

Corresponding author: Dr Mrinal Gupta, E-mail: drmrinalgupta@yahoo.com

Maduromycosis is a progressive granulomatous infection of the skin and subcutaneous tissues which may involve muscle and bone. *Mycetoma pedis* (mycetoma of the foot), the most common form of mycetoma, is known widely as the Madura foot. The infection is endemic in Africa, India and South Americas and *Madurella mycetomatis* is the most prevalent cause of mycotic mycetoma worldwide. The characteristic clinical presentation includes a triad of tumor like swelling, draining sinuses, and macroscopic grains [1]. Infection usually follows a traumatic inoculation of the pathogen into subcutaneous tissue via contaminated mechanical vectors. This infection can spread and involve fascia, muscle, bone and regional lymph nodes [2]. Mycetoma requires long-term treatment, consisting of a combination of surgical procedures and prolonged medical therapy. In the absence of a correct diagnosis and appropriate treatment, mycetoma can lead to significant morbidity due to bone destruction and deformities [3].

A 45 year old male presented to us with 5 years history of gradually progressive swelling and painful nodular lesions over the plantar and lateral aspect of his right foot. The lesions were a single nodule to begin with, but over the time, they had increased in size and number to their present size, and there was history of intermittent purulent discharge and crusting over these nodules. He did not recall any predisposing injury and did not suffer from systemic symptoms. On physical examination, the patient had a large swelling in the dorsum of his right foot with multiple crusted nodules and sinuses draining purulent fluid (Fig. 1a and b). There was no lymphadenopathy. Other systems were normal.

A biopsy of the lesions was done which revealed large amount of black grains, with a reactive

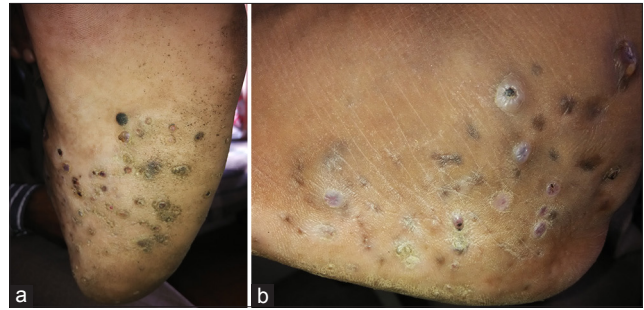


Figure 1: (a and b) Multiple crusted nodules and sinuses present over the foot.

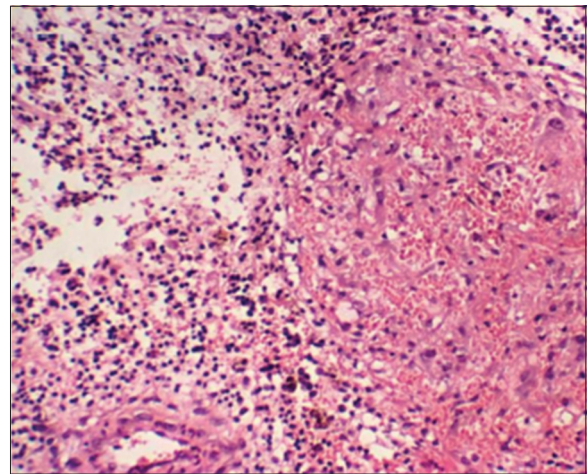


Figure 2: Histopathology showing dense inflammatory infiltrate with few dark grains.

inflammatory process surrounding the lesion (Fig. 2), which confirmed the diagnosis of Maduromycosis. The patient was treated with Itraconazole for 6 months which showed mild improvement in symptoms.

REFERENCES

1. Venkatswami S, Sankarasubramanian A, Subramanyam S. The madura foot: looking deep. *Int J Low Extrem Wounds*. 2012;11:31-42.

How to cite this article: Gupta M. Maduromycosis of foot. *Our Dermatol Online*. 2017;8(1):92-93.

Submission: 13.05.2016; **Acceptance:** 16.08.2016

DOI: 10.7241/ourd.20171.23

2. Ahmed AO, van Leeuwen W, Fahal A, van de Sande W, Verbrugh H, van Belkum A. Mycetoma caused by *Madurella mycetomatis*: a neglected infectious burden. *Lancet Infect Dis.* 2004;4:566-74.
3. Abd Bagi ME, Fahal AH, Sheik HE, Abdul Wahab O, Taifoor MK, Osmanr EM. Pathological fractures in mycetoma. *Trans R Soc Trop Med Hyg.* 2003;97:582-4.

Copyright by Mrinal Gupta. This is an open access article distributed under the terms of the Creative Commons Attribution License, which permits unrestricted use, distribution, and reproduction in any medium, provided the original author and source are credited.

Source of Support: Nil, **Conflict of Interest:** None declared.

Angiolymphoid hyperplasia with eosinophilia

Mrinal Gupta

Consultant Dermatologist, Treatwell Skin Centre, Jammu, India

Corresponding author: Dr Mrinal Gupta, E-mail: drmrinalgupta@yahoo.com

Angiolymphoid hyperplasia with eosinophilia (ALHE), also called as atypical or pseudo pyogenic granuloma, is characterized by solitary or multiple red to brown papules or nodules seen commonly in women between 20 and 40 years of age. The etiology of ALHE remains unknown, because it is not clear if it is primarily a vascular neoplasm, a lymphoproliferative process or a heterogeneous group of entities [1]. Trauma, infections and hyperestrogenic conditions (pregnancy or oral contraceptive agents) are considered to be the likely causes. ALHE usually appears in head and neck region, frequently in the auricular area and usually measures about 2-3 cm in size [2]. ALHE must be histologically and clinically differentiated from Kimura disease, which is a chronic inflammatory condition characterized by large subcutaneous nodules in the head and neck region [3].

A 15 year old male presented to us with history of asymptomatic, gradually progressive nodular lesions over the meatus of the right ear. The lesions started at the age of 11 years and were a single nodule to begin with, but over the time, they had increased in size and number to their present size, but had remained asymptomatic throughout. The patient had consulted some physicians and had applied numerous medications without any relief. On examination, there were multiple red, non-pulsatile smooth surfaced papules, over the pre auricular region extending on to the crus of the helix, and into the meatus of the right ear (Fig. 1). There was no lymphadenopathy. Other systems were normal. Differential count showed 16% eosinophils and her IgE level was normal.

An excisional biopsy of the lesions was done which revealed proliferation of small vessels lined by plump

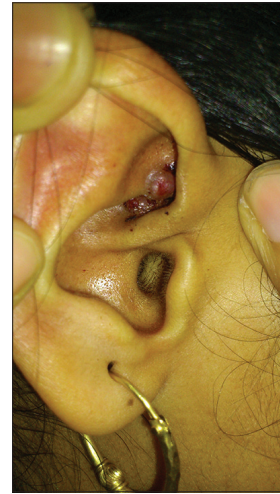

Figure 1: Multiple angiomatous nodules present over the meatus of ear.

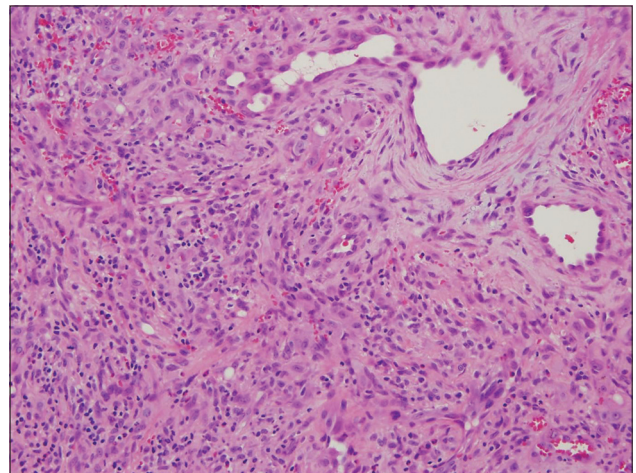


Figure 2: Proliferation of blood vessels in the dermis. The vessels are lined by plump epithelioid endothelial cells with surrounding eosinophilic infiltration.

endothelial cells, surrounded by inflammatory cells including lymphocytes, mastocytes and eosinophils which confirmed the diagnosis of ALHE (Fig. 2).

How to cite this article: Gupta M. Angiolymphoid hyperplasia with eosinophilia. Our Dermatol Online. 2017;8(1):94-95.

Submission: 10.05.2016; **Acceptance:** 16.08.2016

DOI: 10.7241/ourd.20171.24

REFERENCES

1. Karabudak O, Taskapan O, Bozdogan O, and Dogan B. Angiolymphoid hyperplasia with eosinophilia: Atypical appearance in an older patient. *Indian J Dermatol.* 2008;53:144-5.
2. Zarrin-Khameh N, Spoden JE, Tran RM. Angiolymphoid hyperplasia with eosinophilia associated with pregnancy: A case report and review of the literature. *Arch Pathol Lab Med.* 2005;129:1168-71.
3. Zaraa I, Mlika M, Chouk S, Chelly I, Mokni M, Zitouna M, et al.

Angiolymphoid hyperplasia with eosinophilia: A study of 7 cases. *Dermatol Online J.* 2011;17:1.

Copyright by Mrinal Gupta. This is an open access article distributed under the terms of the Creative Commons Attribution License, which permits unrestricted use, distribution, and reproduction in any medium, provided the original author and source are credited.

Source of Support: Nil, **Conflict of Interest:** None declared.

Sebaceous hyperplasia of labium major: Histopathological images

Chidambharam Choccalingam¹, Shivakumaran Gurusamy¹, Premila Samuel²

¹Department of Pathology, SRL Ltd, Chennai, India, ²Lab Head, Labolathory, SRL Ltd, Chennai, India

Corresponding author: Dr. Chidambharam Choccalingam, E-mail: chidambharam@gmail.com

A 29 year old female presented with swelling in the right labium major for a period of 2 months. Gynaecological examination revealed a soft, non tender, skin covered polypoidal swelling measuring 2 x 2 cms at the right labium major (Fig. 1). An elective excision biopsy was performed. Gross examination showed a skin covered polypoidal tissue with underlying multiple yellow papular areas and with central depression. On microscopy, enlarged sebaceous gland composed of numerous lobules (>4 lobules) grouped around a centrally located sebaceous duct. Most of the sebaceous gland lobules appeared mature (Fig. 2). The cells had vesiculated cytoplasm and central nucleus with no atypical features (Figs. 3a and b). Overlying epidermis did not have any pathological feature. No atypia or necrosis or mitosis was seen. With the morphological features a diagnosis of sebaceous hyperplasia of labium major was made.

Sebaceous glands are present throughout the skin except the palms and soles [1]. Sebaceous hyperplasia is commonly seen in the face and less frequently seen in the chest, ocular caruncle, penis, scrotum and vulva [2]. Though, no definite criteria available for diagnosis of sebaceous hyperplasia, sebaceous gland hyperplasia has been defined as the presence of >4 sebaceous lobules attached to the infundibulum of each pilosebaceous unit [1,3]. Sebaceous hyperplasia of vulva differs from their counterparts arising in the face, by having almost always a polypoidal presentation; larger size and affecting a younger age group [1]. The clinical differential diagnosis includes condyloma acuminata and vulval neoplasms, while the histopathological differential diagnosis includes ectopic sebaceous glands and sebaceous

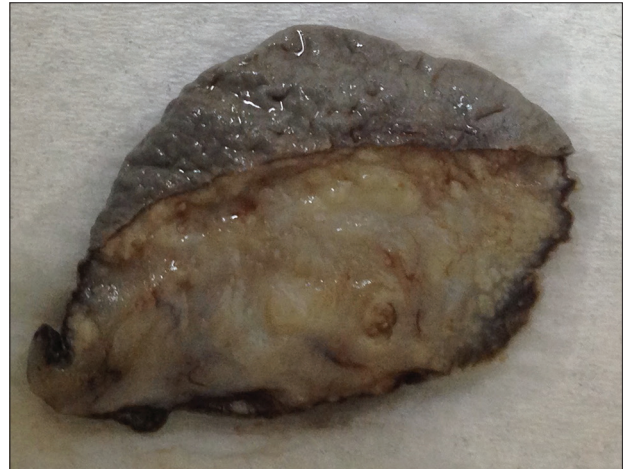


Figure 1: Polypoidal skin covered tissue with underlying yellow papular areas.

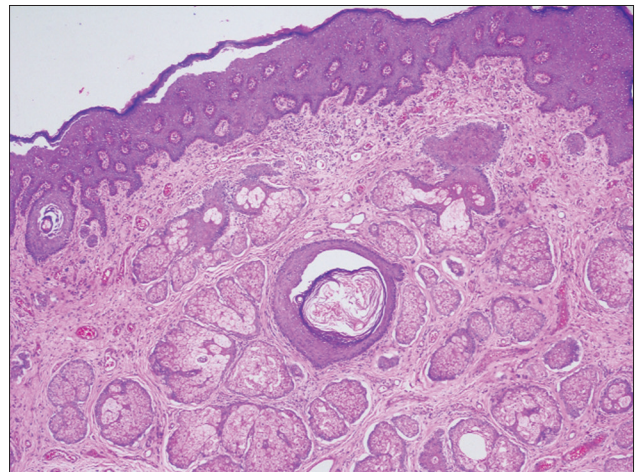


Figure 2: Numerous lobules of sebaceous glands around pilosebaceous unit (H&E x 10).

adenoma [1]. Sebaceous hyperplasia has more than 4 lobules around pilosebaceous units; whereas ectopic

How to cite this article: Choccalingam C, Gurusamy S, Samuel P. Sebaceous hyperplasia of labium major: histopathological images. Our Dermatol Online. 2017;8(1):96-97.

Submission: 09.05.2016; **Acceptance:** 09.07.2016

DOI: 10.7241/ourd.20171.25

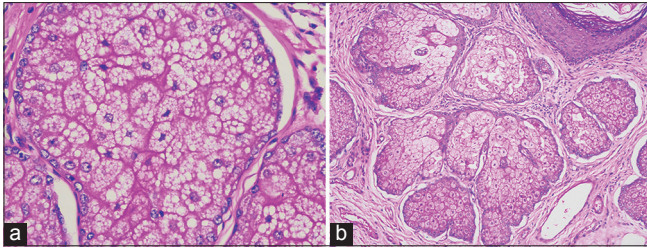


Figure 3: (a and b) Cytologically the cells show vesiculated cytoplasm and central nucleus with no atypical features (H&E x 40).

sebaceous glands have sebaceous lobules without attached follicles; sebaceous adenoma has lobules with predominantly basaloid cells with interspersed mature sebaceous cells [4]. Surgical excision is curative [5], as in our case which had no recurrence after a period of 2 years follow up.

REFERENCES

1. Daraji WI, Wagner B, Ali RBM, McDonagh AJG. Sebaceous hyperplasia of the vulva: a clinicopathological case report with a review of the literature. *J Clin Pathol.* 2007;60:835-7.
2. Calonje E, Brenn T, Lazar A. *Mckee's Pathology of skin with clinical correlation.* 4 ed 2012.
3. Yavuz E, Celik H, Kokcub A, Süllüç Y. Sebaceous gland hyperplasia of vulva: A case report. *J Exp Clin Med.* 2012;29:231-3.
4. Rao ACK, Nayal B, Gopal SM, Valliathan M, Shenoy R. Sebaceoma of the lip originating in Fordyce's spot – A rarity. *Our Dermatol Online.* 2016;7:48-50
5. Brzezinski P, Chiriac A. Sebaceous hyperplasia in neonates and adults. *Our Dermatol Online.* 2015;6:107-8.

Copyright by Chidambaram Choccalingam, et al. This is an open access article distributed under the terms of the Creative Commons Attribution License, which permits unrestricted use, distribution, and reproduction in any medium, provided the original author and source are credited.

Source of Support: Nil, **Conflict of Interest:** None declared.

Pautrier-Woringer disease: lipomelanotic reticulosis/dermatopathic lymphadenitis

Olfa El Amine El Hadj, Leila Bouhajja, Aida Goucha, Wafa Rekik, Ahmed El May, Amor Gamoudi

Immuno-Histo-Cytological Department, Salah Azaiez Institute Tunis, Boulevard 9 Avril, Bab Saadoun 1006 Tunis, Tunisia

Corresponding author: Dr. Olfa El Amine El Hadj, E-mail: olfaelamine@yahoo.fr

Sir,

We report a 62 year-old woman with a 20-year's history of extensive psoriasis, and thyroidectomy, presented with a 3-month history of multiple hypertrophied axillary lymph nodes. At first the diagnosis of metastatic breast cancer was suggested. Physical examination revealed a 2cm, firm and slightly mobile axillary lymph node. A cutaneous diffuse psoriasis was observed on the chest and upper limbs. The breast mammography showed foci of microcalcifications (ACR3) in the right breast, and bilateral axillary lymphadenopathies. The cervical and abdominal ultrasonographies were normal. A surgical resection of the axillary mass was performed. Grossly, the lymph node measured 2,5cm in size, had a soft consistency with black pigment on the cut. Histological examination showed large melanin granules in intra and extra cytoplasmic cells (Fig. 1). Paracortical and interfollicular spaces were colonized by a proliferation of histiocytes and interdigitating cells with elongated shape nuclei (Fig. 2). They were organized in very large nodules. Immunohistochemical evaluation showed intense and diffuse expression of S-100 protein and CD1a attesting of the interdigitating nature of cell proliferation. On the other hand, the cytokeratin antibody was negative. The patient received medical treatment, no other lymph nodes was found. These features confirmed the diagnosis of Dermatopathic lymphadenitis. At 3 years of follow-up, the patient was asymptomatic and there was no recurrence.

Dermatopathic lymphadenitis (DL) also known as lipomelanotic reticulosis or Pautrier-Woringer

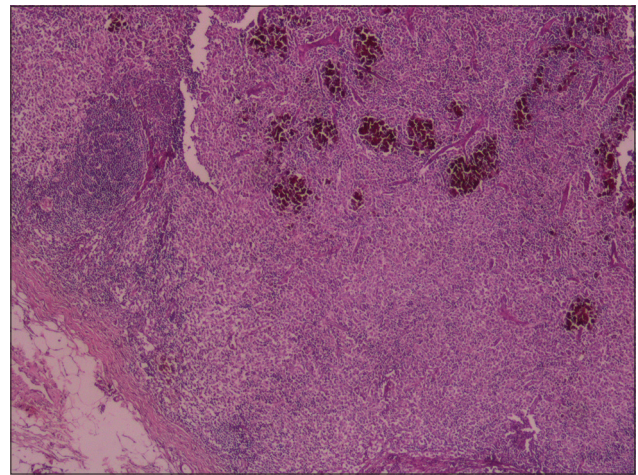


Figure 1: Node structure with large melanin granules in intra and extra cytoplasmic cells.

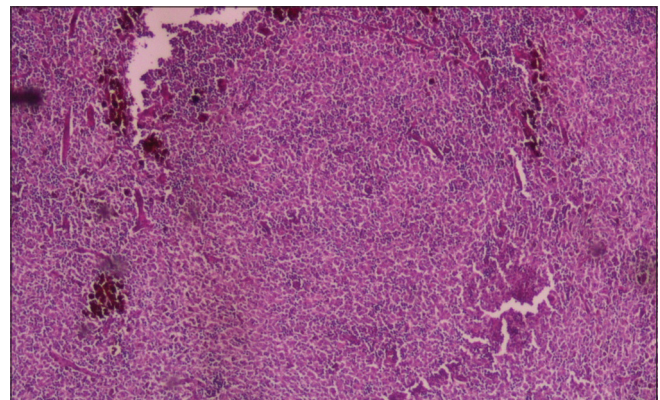


Figure 2: Paracortical and interfollicular proliferation of histiocytes and interdigitating cells with elongated shape nuclei with abundant melanin deposit.

disease, represents a rare form of benign lymphatic hyperplasia associated with most exfoliative or

How to cite this article: El Hadj OE, Bouhajja L, Goucha A, Rekik W, El May A, Gamoudi A. Pautrier-Woringer disease: lipomelanotic reticulosis/dermatopathic lymphadenitis. *Our Dermatol Online*. 2017;8(1):98-99.

Submission: 10.03.2016; **Acceptance:** 05.06.2016

DOI:10.7241/ourd.20171.26

eczematoid inflammatory erythrodermas, including pemphigus, psoriasis, eczema, neurodermatitis, and atrophica senilis. It involves the axillary, inguinal and cervical regions [1-3]. These Lymph nodes are moderately enlarged, firm, movable, and rather painless [4]. Diagnosis of DL is mostly based on the lymph node biopsy [5]. The differential diagnosis includes anthracosis, melanoma metastasis and mycosis fungoides. DL is a benign process and management of these patients consists in simple clinical, mammographic and ultrasonographic follow-up [6].

Dermatopathic lymphadenitis is a benign lymphatic hyperplasia, histologically usually mimicking lymphoma. Immunohistological exam is of great support for differential diagnosis.

Consent

The examination of the patient was conducted according to the Declaration of Helsinki principles. Written informed consent was obtained from the patient for publication of this article.

The patient's informed consent was obtained.

Prior to the study, patient gave written consent to the examination and biopsy after having been informed about the procedure.

REFERENCES

1. Makis W, Hickeys M, and Blumenkrantz M. Dermatopathic Lymphadenitis A Pitfall for Lymphoma Evaluation by F-18 FDG PET/CT. *Clin Nucl Med.* 2010;35:872-4
2. Acipayam C, Kupeli S, Sezgin G, Acikalin A, Ozkan A, Inan DA, et al. Dermatopathic lymphadenitis associated with human papilloma virus infection and verruca vulgaris. *J Pediatr Hematol Oncol.* 2014;36:e231-3.
3. Steffen C, Frédéric Woringe: Pautrier-Woringe disease (lipomelanotic reticulosis/dermatopathic lymphadenitis). *Am J Dermatopathol.* 2004;26:499-503.
4. Ioachim HL, Medeiros LJ. Dermatopathic lymphadenopathy. *Ioachim's Lymph Node Pathology 2009*; Philadelphia: Lipincott Company, 223-6.
5. Hu N, Tan YL, Cheng Z, Wang YH. Dermatopathic Lymphadenitis. *Chin Med J.* 2015;128:3121-2.
6. Rocco N, Della Corte GA, Rispoli C, Sabatino V, Romano F, Altiero M, et al. Axillary masses in a woman with a history of breast cancer: dermatopathic lymphadenopathy. *Int J Surg.* 2014;12:S40-3.

Copyright by Olfa El Amine El Hadj, et al. This is an open access article distributed under the terms of the Creative Commons Attribution License, which permits unrestricted use, distribution, and reproduction in any medium, provided the original author and source are credited.

Source of Support: Nil, **Conflict of Interest:** None declared.

Chromoblastomycosis: Report of a case from a non-endemic region

Olfa El Amine El Hadj¹, Issam Msakni², Fehmi Lamine¹, Besma Laabidi²,
Ammar Bouzaiène²

¹Immuno-Histo-Pathological Department Salah Azaiez Institute, Tunis, Tunisia, ²Pathological Department, Military Hospital, Tunis, Tunisia

Corresponding author: Dr. Olfa El Amine El Hadj, E-mail: olfaelamine@yahoo.fr

Sir,

Chromoblastomycosis is a chronic fungal infection prevalent in tropical regions, but rare in Tunisia. It causes some diagnostic difficulties. We report the third case of a Tunisian man.

A 47-year-old man presented with a skin lesion, of 3 years duration, located in the right limb. The lesion gradually expanded to form a 20 cm violet-colored papule with an atrophic center (Fig. 1). The diagnosis of cutaneous tuberculosis was suspected. Cultures were negative. A deep skin biopsy revealed the presence of fungal elements within a granulomatous reaction (Figs. 2 and 3). There was no evidence of any immunodeficiency.

In the Maghreb countries, chromomycosis is rare. Among 30 observations of deep mycoses in Morocco, only 5 patients presented chromomycosis [1]. Eight cases have been reported in Algeria [2]. In Tunisia, only two cases were reported [3,4].

The primary lesion is thought to develop as a result of percutaneous traumatic inoculation [5]. This is the case of our patient. Indeed, he was a victim of limb traumatism with inoculation of wood in the area of the lesion.

The disease affects predominantly men. Typical lesions grow slowly over many years and tend to be found on the lower limbs. The morphology of the lesion may be tumor, nodular, verrucous, plaque-like, psoriasiform, and papule as in our case or scar [6].

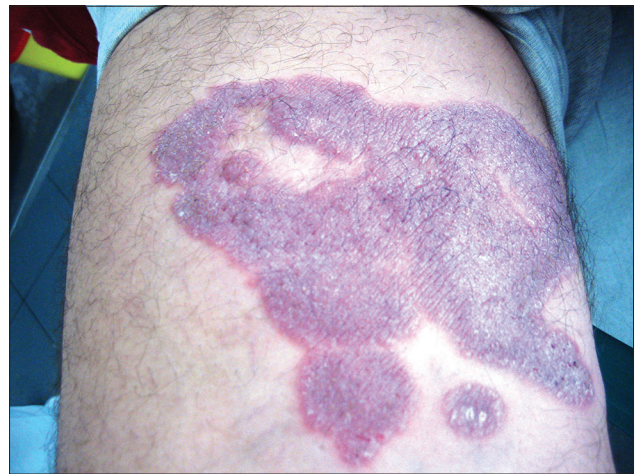

Figure 1: Violet-colored papule with an atrophic center.

In our country chromomycosis lesions may be confused with leishmaniasis, verrucous tuberculosis, and tertiary syphilis [3,4]. Mycologic tests are used to confirm the diagnosis. The principal causal agent is *Fonsecaea pedrosoi*, followed by four species in order of frequency, *Phialophora verrucosa*, *Cladosporium carrionii*, *Fonsecaea compacta*, and *Rhinochrysiella aquaspera* [6,7].

Histologic appearances are hyperkeratosis, pseudoepitheliomatous hyperplasia and granulomas in the upper and mid dermis. The granulomas are mostly of tuberculoid type, although a few suppurative granulomas are present. Intraepidermal microabscesses are often present. There is a background infiltrate of chronic inflammatory cells, and sometimes a few eosinophils, in the upper dermis, round, thick-walled, golden brown cells (sclerotic bodies, muriform cells,

How to cite this article: El Amine El Hadj O, Msakni I, Lamine F, Laabidi B, Bouzaiène A. Chromoblastomycosis: Report of a case from a non-endemic region. Our Dermatol Online. 2017;8(1):100-101.

Submission: 05.06.2016; **Acceptance:** 20.08.2016

DOI: 10.7241/ourd.20171.27

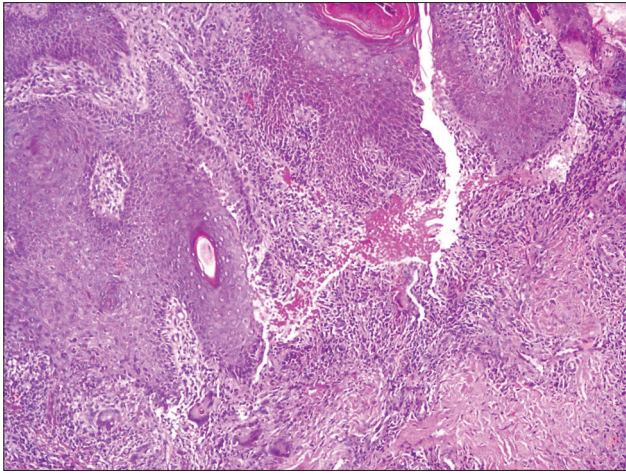


Figure 2: Biopsy showed hyperplastic epidermis within a granulomatous reaction in the dermis.

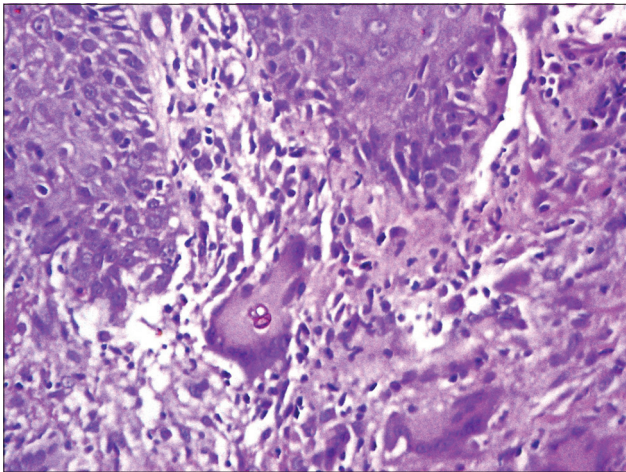


Figure 3: A deep skin biopsy revealed the presence of fungal elements.

medlar bodies) 5-12 micrometer can be seen in giant cells and lying free in the epidermal microabscesses. These sclerotic bodies are usually seen readily in hematoxylin and eosin preparations and particularly in sections stained with hematoxylin alone [2,5,8].

If not diagnosed and treated early, chromomycosis has a chronic evolutionary course. The most frequent complication was secondary bacterial infection. Chronic chromomycosis also has potential association with epidermoid carcinoma (14 cases are reported in the literature) [8,9] and also with skin melanoma [10].

Central nervous system invasion is possible and may be fatal [11].

Treatment in localized lesions can be surgical. Widespread lesions and long-standing cases can be treated medically [12]

Finally, Chromomycosis is quite rare in our country. Anatomopathologists should be aware of this diagnosis.

REFERENCES

1. Jarmouni R, Ntidam H, Afailal A et al. Les mycoses profondes (À propos de 30 cas). Rapports du XIX^e Congrès de l'Association des Dermatologistes et Syphiligraphes de Langue Française, Rabat, 12-15 mai 1989:39-43.
2. Boughdène-Stambouli C, Belbachir OH, Bariout H. La chromomycose: A propos de 7 cas. *Ann Dermatol Venerol.* 2001;128:S21-7,C29.
3. Marrak H, Mnajaa N, Fenniche S, Fourati M, Zghal M, Chaker E, et al. Chromomycose: A propos d'une observation. *J Mycol Med* 2003;13:37-9.
4. Sebaï E, Benmously R, Fazaa B, Chaker E, Zermani R, Kamoun MR. Chromomycosis arising in a Tunisian man. *Dermatol Online J.* 2005;11:14.
5. Piepenbring M, Mendez C, Espinoza E, Kirschner R, Schöfer H. Chromoblastomycosis caused by *Chaetomium funicola*: A case report from Western Panama. *Br J Dermatol.* 2007;157:1025-9.
6. Bonifaz A, Carrasco-Gerard E, Saul A. Chromoblastomycosis: Clinical and mycologic experience. *Mycoses.* 2001;44:1-2.
7. Minotto R, Bernardi CD, Mallmann LF, Edelweiss MI, Scrofeneker ML. Chromoblastomycosis: A review of 100 cases in the state of Rio Grande do Sul, Brazil. *J Am Acad Dermatol.* 2001;44:585-92.
8. Vijaya D, Kumar BH Chromoblastomycosis. *Mycoses.* 2005;48:82-4.
9. Esterre P, Pecarrere JL, Raharisolo C, Huerre M. Squamous cell carcinoma arising from chromomycosis. Report of two cases. *Ann Pathol.* 1999;19:516-20.
10. dos Santos A, Minelli L. Melanoma in a long-standing lesion of chromoblastomycosis. *Int J Dermatol.* 2006;45:1331-3.
11. Artüz F, Alli N, Lenk N, Güngör E. Purple erythematous plaques on the face and left arm. *Arch Dermatol.* 1997;133:1027-32.
12. Smith CH, Barker JN, Hay RJ. A case of chromomycosis responding to treatment with itraconazole. *Int J Dermatol.* 1993;128:436-9.

Copyright by Olfa El Amine El Hadj, et al. This is an open access article distributed under the terms of the Creative Commons Attribution License, which permits unrestricted use, distribution, and reproduction in any medium, provided the original author and source are credited.

Source of Support: Nil, **Conflict of Interest:** None declared.

Immunoreactivity to Meissner corpuscles and dermal nerves in a bullous arthropod bite reaction

Ana Maria Abreu Velez¹, Alejandra Maria Jiménez-Echavarría², Michael S. Howard¹

¹Georgia Dermatopathology Associates, Atlanta, Georgia, USA, ²Dermatology Resident, Hospital das Clinicas da Faculdade de Medicina de la Universidad de São Paulo (HCFMUSP), Sao Paulo, Brazil

Corresponding author: Ana Maria Abreu Velez, M.D, Ph.D., E-mail: abreuvelez@yahoo.com

Abbreviations: Hematoxylin and eosin (H&E), periodic acid Schiff (PAS), immunohistochemistry (IHC), direct immunofluorescence (DIF), 4,6-diamidino-2-phenylindole (DAPI), glial fibrillary acidic protein (GFAP), antibody to protein gene product 9.5 (PPG 9.5), Meissner corpuscle (MC).

Sir,

A clinical pruritus and inflammation is present following most insect bites. Here we document immunoreactivity to Meissner corpuscles and dermal nerves following arthropod bites.

Case: A 67 year old male presented with small, itchy red bumps, and recalled recent insect bites (Fig. 1a). We examined his skin biopsies utilizing hematoxylin and eosin (H&E) and direct immunofluorescence (DIF). These tests and the clinical data demonstrated evidence of insect bites. Following the diagnosis of arthropod bites, the patient was instructed to wash the lesions with soap and water, apply cool compresses, use antihistamines to relieve itching and acetaminophen for pain relief. In addition, 1% Hydrocortisone cream was prescribed, and the patient reported symptomatic relief.

Our hematoxylin and eosin (H&E), periodic acid Schiff (PAS) and multiple fluorochrome direct immunofluorescence (DIF) procedures were performed as previously described [1,2]. For nerve co-localization, we utilized Cy3 conjugated anti-glial fibrillary acidic protein (GFAP) antibody from Sigma-Aldrich (Saint Louis, Missouri, USA). We also used Texas red conjugated Protein Gene Product 9.5 antibody (PPG 9.5) from Abcam (Cambridge, Massachusetts, USA) and performed nuclear counterstaining with 4,6-diamidino-2-phenylindole (DAPI; Pierce, Rockford, Illinois, USA). All samples were consistently run with

positive and negative controls. We classified our DIF findings as negative (-), weakly positive (+), positive (++) and strongly positive (+++). H&E staining showed subepidermal blistering, with a moderately florid superficial and perivascular infiltrate of lymphocytes, histiocytes and eosinophils; these findings were consistent with a bullous arthropod bite reaction (Fig. 1b). The multicolor DIF showed reactivity to Meissner corpuscles (MCs) and dermal nerves under the bite, using neural markers colocalizing with antibodies to human Complement/C3c and fibrinogen (Figs. 1c and d). The PAS stain showed positive staining of basement membrane areas around the blister.

Overall, our DIF displayed IgG (+, punctate staining in epidermal stratum spinosum); IgA, IgM, IgD, IgE, Complement/C1q, Complement/C3 and Kappa light chains (all ++, all with punctate staining on possible dermal cell junctions of an unknown nature; Complement/C3 (+++, on dermal grouped nerves; albumin (++), staining on several large deep dermal nerves) and fibrinogen (++), dermal perivascular, on dermal nerves and on MCs). Large deep dermal nerves also stained positive for PPG9.5; small dermal nerves and Meissner corpuscles stained positive for GFAP (+++). In summary, we detected immunoreactivity to dermal nerves and MCs subjacent to the insect bite using multiple fluorochrome DIF.

Bites or stings from arthropods are common, and sometimes an allergic reaction occurs to toxins

How to cite this article: Abreu Velez AM, Jiménez-Echavarría AM, Howard MS. Immunoreactivity to Meissner corpuscles and dermal nerves in a bullous arthropod bite reaction. *Our Dermatol Online*. 2017;8(1):102-103.

Submission: 04.10.2016; **Acceptance:** 20.11.2016

DOI: 10.7241/ourd.20171.28

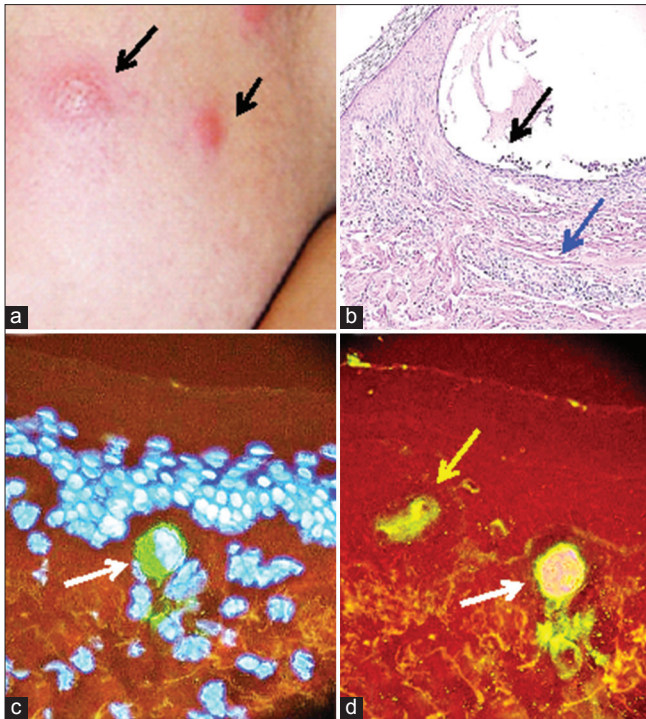


Figure 1: (a) A clinical photograph shows soft, erythematous papules (black arrows). (b) H&E staining shows a subepidermal blister (black arrow) with some fibrin inside the blister. Below the blister, note the perivascular infiltrate around upper dermal blood vessels (blue arrow; 100X). (c) Positive DIF staining on a MC, using anti-human FITC-conjugated fibrinogen antibodies (green staining; white arrow), cell nuclei are counterstained with DAPI (light blue). (d) Multiple fluorochrome DIF staining, using anti-human FITC conjugated fibrinogen antibodies and demonstrating positive staining to a MC, and its neurovascular supplies (green staining; white arrow), colocalizing with Texas red conjugated antibodies against GFAP (pink staining; white arrow). The yellow arrow shows positivity to a separate dermal neurovascular package.

associated with the bite or sting. Some individuals have severe clinical reactions to the stings of bees, wasps, hornets, yellow jackets and or other insects [3]. These stings may require emergency treatment for anaphylactic reactions. Here we report, to our

knowledge for the first time an arthropod bite showing reactivity to Meissner's corpuscles (MCs). MCs are a type of nerve ending in the skin, responsible for sensitivity to light touch. These corpuscles display the highest sensitivity for detecting vibrations, and are rapidly adaptive receptors [4]. Nerves and Meissner corpuscles colocalized with neural antibodies, as well as autoantibodies developed by the patient after the arthropod bite. We conducted a combined PubMed search for all publication years entering "arthropod bites" and the Mesh words "Meissner corpuscles"; we found no citations. We have previously reported nerve reactivity following a scabies mite infection. MCs are part of the purinergic signaling system; this system involves adenosine 5'-triphosphate and adenosine receptors, neurotransmission, exocrine and endocrine secretion and regulation of immune cell function [4].

The significance of our findings is unknown; we suggest further investigation into these findings.

REFERENCES

1. Abreu Velez AM, Klein AD, Howard MS. Autoreactivity to sweat glands and nerves in acinical scabies infection. *North Am J Med Sci.* 2010;2:422-5.
2. Abreu Velez AM, Calle Isaza J, Howard MS. Immunofluorescence patterns in selected dermatoses, including blistering skin diseases utilizing multiple fluorochromes. *North Am J Med Sci.* 2015;7:397-402.
3. Singh S, Mann BK. Insect bite reactions. *Indian J Dermatol Venereol Leprol.* 2013;79:151-64.
4. Paré M, Elde R, Mazurkiewicz JE, Smith AM, Rice FL. The Meissner corpuscle revised: a multiafferented mechanoreceptor with nociceptor immunochemical properties. *J Neurosci.* 2001;15;21:7236-46.

Copyright by Ana Maria Abreu Velez, et al. This is an open-access article distributed under the terms of the Creative Commons Attribution License, which permits unrestricted use, distribution, and reproduction in any medium, provided the original author and source are credited.

Source of Support: Georgia Dermatopathology Associates, Atlanta, Georgia, USA, **Conflict of Interest:** None declared.

Childhood lichen planus pigmentosus

Monia Youssef¹, Lahouel Ines¹, Marmouch Héla², Rim Hadhri³, Hayet Akkari¹,
Mariem Mohamed¹, Yosra Soua¹, Hichem Belhadjali¹, Jameleddine Zili¹

¹Department of Dermatology, Fattoum Bourguiba Hospital, University of Medicine, Monastir, Tunisia, ²Department of Endocrinology, Fattouma Bourguiba Hospital, University of Medicine, Monastir, Tunisia, ³Department of Anatomopathology, Fattoum Bourguiba Hospital, University of Medicine, Monastir, Tunisia

Corresponding author: Dr. Lahouel Ines, MD, E-mail: lahouel.iness@gmail.com

Sir,

Lichen planus pigmentosus (LPP) is a rare variant of lichen planus that presents as asymptomatic to mildly pruritic, hyperpigmented macules and/or patches. This dermatosis has been rarely reported in children. We report a first series of childhood LPP illustrating 5 cases from Tunisia.

Of 5 patients (age range 6–16 years), 3 were male (mean age, 9.3 years) and 2 were females (mean age, 13 years). The duration of disease at presentation ranged from 1 month to 1 year. In 4 patients, lesions were present at more than one anatomical site and the patients had bilateral involvement. The trunk was the commonest site affected (4 cases). In our all cases, the lesions were a few mm to a few cm in diameter (Fig. 1). The various colour shades noted were dark brown in four cases and slate grey in one patient. The pattern of pigmentation was diffuse in all patients. In 4 patients, the lesions were asymptomatic. One patient had mild itching. Oral mucosa was involved in only one patient, who had lesion localized in the lips. This patient had brown pigmentation present over the buccal mucosa (gingivae) of both sides. Palms, soles and nails were spared in all cases. None of the patients presented coincidental lichen planus.

No elevated active red border as seen in erythema dyschromicum perstans was noticed in any patient. The history of previously inflammatory processes in affected areas was not present. All cases had no concomitant diseases. Related external factors such as drug intake prior to the onset or use of cosmetics were absent. Our second patient reported that lesions appeared after the exposure to a severe stress. None

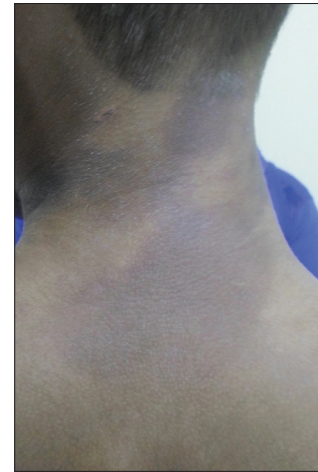

Figure 1: Pigmented brownish, well-defined macules located on the neck.

of our patients had a family history of a similar skin disorder.

Of the 4 patients, who were treated with topical betamethasone, two showed a slight lightening of the pigmentation after an average of 16 weeks.

Skin biopsies were performed from all the patients. Three patients had band-like lymphocytic infiltrate and two patients had superficial perivascular pattern. Melanin incontinence was a constant finding in all cases. Hyperkeratosis was marked in three cases and keratinocyte necrosis in one case.

The clinical, histological and therapeutic features of our patients are summarized in Table 1.

We reported 5 Tunisian cases of childhood LPP, a rare entity in children. LPP is a rare variant of lichen planus,

How to cite this article: Youssef M, Lahouel I, Héla M, Hadhri R, Akkari H, Mohamed M, Soua Y, Belhadjali H, Zili J. Childhood lichen planus pigmentosus. Our Dermatol Online. 2017;8(1):104-105.

Submission: 22.02.2016; **Acceptance:** 29.08.2016

DOI: 10.7241/ourd.20164.29

Table 1: Clinical, histological, and therapeutic features of patients

No. of cases	Sex/age	Duration	Site	Histological examination	Treatment	Course
Case1	M/6	4 months	Neck Trunck	Perivascular lymphohistiocytic infiltrate, pigmentary incontinence,	Topical betamethasone	No improvement
Case2	F/10	1 year	Upper and lower limbs, trunck	Hyperkeratosis, band-like lymphocytic infiltrate, pigmentary incontinence	Topical betamethasone	Slight improvement
Case 3	M/13	1 month	Trunck, Upper limbs	Hyperkeratosis, pigmentary incontinence, band-like lymphocytic infiltrate, keratinocyte necrosis	Topical betamethasone	No improvement
Case4	F/16	3 months	Lips, Oral mucosa	Hyperkeratosis, pigmentary incontinence, melanophages, band-like lymphocytic infiltrate	Photoprotection	No improvement
Case 5	M/9	6 months	Neck, trunck, lowerlimbs	Perivascular lymphohistiocytic infiltrate, pigmentary incontinence	Topical betamethasone	Slight improvement

first described by Bhutani et al [1]. It generally starts in the third or fourth decade of life and there is a slight female predilection [2]. The prevalence of LPP among children with lichen planus is low ranging from 2.8 to 4% [3,4].

LPP is characterized by the presence of the hyperpigmented, dark-brown macules in the sun exposed or flexural areas of the body. Face and neck are the most frequent initial sites of involvement. Palms, soles and nails are not affected. Although lesions are generally asymptomatic, mild pruritus and burning sensations are present in about one-third of patients [2]. In our pediatric series, the trunk was the most common site of lesions, itching was present in only one patient.

Our fourth patient presented oral lesions. In fact, while Bhutani et al [1] stressed that LPP was never localized in the oral mucosa. Laskaris et al [5] described a case of LPP of the oral mucosa. To our Knowledge, this rare clinical variety had never been reported before in children.

Histopathological examination typically shows vacuolar alteration of the basal layer, variable dense of lymphocyte infiltration, pigmentary incontinence and melanophages in the superficial dermis. In our cases we have found similar histopathological results, as well.

The differential diagnosis of childhood LPP includes idiopathic eruptive macular pigmentation, ash dermatosis and post-inflammatory pigmentation.

The etiopathogenesis of the condition remains unknown. Kanwar et al suggested that mustard oil, amla oil, henna and hair dye could be the precipitating factors

in predisposed individuals [2]. These factors could not be identified in any of our patients. Nevertheless, the exposure to a severe stress might be a precipitating factor in one of our patients.

The disease is insidious in onset and has a chronic course [2]. The treatment is based on corticosteroids and topical tacrolimus. The skin lesions are often resistant to treatment, as evidenced by our observations.

To conclude, LPP in childhood is uncommon. As this was a first series of childhood LPP. It confirms the literature data when the scarcity of the entity and the disappointing response to treatment. Mucosal involvement might be not infrequent. However, additional studies are needed to better characterize this entity in children.

REFERENCES

1. Bhutani LK, Bedi TR, Pandhi RK, Nayak NC. Lichen planus pigmentosus. *Dermatologica*. 1974;149:43-50.
2. Kanwar AJ, Dogra S, Handa S, Parsad D, Radotra BD. A study of 124 Indian patients with lichen planus pigmentosus. *Clin Exp Dermatol*. 2003;28:481-5.
3. Pandhi D1, Singal A, Bhattacharya SN. Lichen planus in childhood: a series of 316 patients. *Pediatr Dermatol*. 2014;31:59-67.
4. Nanda A1, Al-Ajmi HS, Al-Sabah H, Al-Hasawi F, Alsaleh QA. Childhood lichen planus: a report of 23 cases. *Pediatr Dermatol*. 2001;18:1-4.
5. Laskaris GC, Papavasiliou SS, Bovopoulou OD, Nicolis GD. Lichen planus pigmentosus of the oral mucosa: a rare clinical variety. *Dermatologica*. 1981;162:61-3.

Copyright by Monia Youssef, et al. This is an open access article distributed under the terms of the Creative Commons Attribution License, which permits unrestricted use, distribution, and reproduction in any medium, provided the original author and source are credited.

Source of Support: Nil, **Conflict of Interest:** None declared.

Segmental lichen aureus subsequent to interdigital tinea pedis: A rare clinical appearance of “id”-reaction?

Tatsuhiko Mori, Toshiyuki Yamamoto

Department of Dermatology, Fukushima Medical University, Fukushima, Japan

Corresponding author: Dr. Tatsuhiko Mori, E-mail: mtatsu@fmu.ac.jp

Sir,

A 59-year-old male visited our department, complaining of red itchy papules on his right lower leg. Initially, the papules appeared on the dorsum of his right foot, and spread upwards to the shin. He had no infectious symptoms, such as throat pain and fever, prior to the development of the dermatosis. Physical examination revealed that a number of reddish papules and erythematous lesions with slight scales were distributed along Blaschko's lines (Fig. 1a and b). Moreover, there were scaly erythema and vesicles between the third and fourth toes (Fig. 1c), and a potassium hydroxide preparation test detected a number of fungi (Fig. 1d). Unfortunately, a mycological culture was not carried out. He had not been aware of his tinea pedis. A biopsy specimen taken from the dorsum of the foot showed parakeratosis, individual cell keratinization, spongiosis, and liquefaction degeneration in the epidermis. Furthermore, red blood cell extravasation, hemosiderin deposition, and perivascular inflammatory cell infiltrates, mainly composed of lymphocytes, were observed in the upper dermis (Fig. 1e). Immunohistochemistry revealed a number of CD4- as well as CD8-positive T-cells in the dermis, with a slight predominance of CD8-positive epidermal T-cells (Fig. 1f). Other dermatitis showing linear distribution, such as inflammatory linear verrucous epidermal nevus, linear lichen striatus, and linear lichen planus were all ruled out. The patient was successfully treated with topical corticosteroid (betamethasone butyrate propionate) ointment.

Lichen aureus is a rare variant of pigmented purpura frequently involving the lower legs. Lichen aureus rarely develops in a linear, segmental, or zosteriform

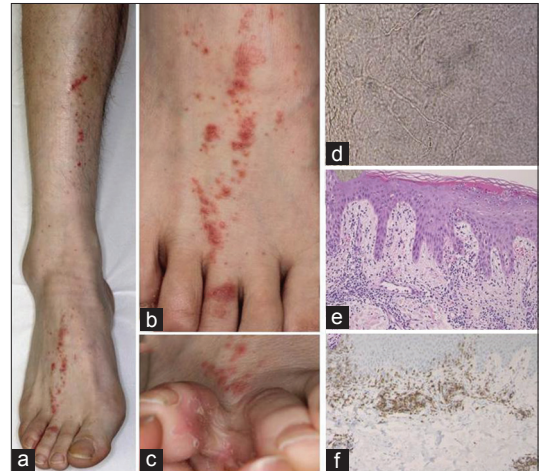

Figure 1: Clinical appearances showing linear distribution of reddish papular and erythematous lesions on the right lower leg (a, b). Note the toe web scaly erythematous lesions (c). KOH test showed fungi (d). Histological features showing parakeratosis, slight acanthosis, individual cell keratinization, and liquefaction degeneration of the basal cell layer of the epidermis, with inflammatory infiltrates in the upper dermis (e). (hematoxylin-eosin, original magnification $\times 200$). Mononuclear cells also infiltrated in the upper dermis as well as the epidermis, which were immunoreactive for CD8 (f).

distribution following Blaschko's lines [1,2]. Although the etiology of lichen aureus is still unknown, possible candidates are increased venous pressure or stasis, increased capillary fragility, infection, drugs, and dysregulated T-cell-related immune reaction [2]. Also a few reports have suggested that an association with trauma and perforator vein incompetence may cause lichen aureus [3,4]. The Koebner phenomenon was demonstrated in a previously reported case [5]. Our patient developed lichen aureus following a tinea pedis infection in the intertriginous areas of the foot, from where reddish papules spread upward. Thus, fungal infection may have triggered the onset of

How to cite this article: Mori T, Yamamoto T. Segmental lichen aureus subsequent to interdigital tinea pedis: A rare clinical appearance of “id”-reaction? Our Dermatol Online. 2017;8(1):106-107.

Submission: 27.03.2016; **Acceptance:** 01.10.2016

DOI:10.7241/ourd.20171.30

lichen aureus, although there was no evidence which showed the direct relationship between the lesion and tinea infection in our patient. In our case, a number of CD4- and CD8-positive T-cells infiltrated into the lesional skin, suggesting a cell-mediated cytotoxic injury. Following some external triggers such as tinea infection, adaptive effector T-cells may play an important role in the pathogenesis of lichen aureus. Lichen aureus has been shown to be resistant to topical therapy, and thus phototherapy, pentoxifylline, prostacyclin, and pulsed-dye laser have been used. In the present case, the lesions were transient and responded well to the topical corticosteroids. This may suggest that lichen aureus was triggered by fungal infection and thus ran an acute course. To the best of our knowledge, this is the first case of lichen aureus possibly induced by tinea pedis.

Hyperergic id-reaction secondary to fungi is known as mycid. Various clinical features are induced from distant focus of microbial infection, such as grouped or scattered follicular papules, dyshidrotic eczema-like lesions, or erythema multiforme-like eruptions [6]. Histology shows perivascular inflammatory infiltrates in the dermis. In the present case, the eruptions originated from the root of the digit close to the inter-toe-web tinea pedis, spreading upwards, but no eruptions on the distant areas. Histological examination

revealed prominent red blood cell extravasation and hemosiderin deposition, suggesting attack to the basement membrane by T-cells. Although the good response to the topical steroids may suggest an id-reaction, we conclude that this is a rare case of lichen aureus subsequent to tinea pedis.

REFERENCES

1. Lee HW, Lee DK, Chang SE, Lee MW, Choi JH, Moon KC, et al. Segmental lichen aureus: combination therapy with pentoxifylline and prostacyclin. *J Eur Acad Dermatol Venereol.* 2006;20:1378-80.
2. Moche J, Glassman S, Modi D, Grayson W. Segmental lichen aureus: a report of two cases treated with methylprednisolone aceponate. *Australas J Dermatol.* 2011;52:e15-e18.
3. Ruiz-Esmenjaud J, Dahl MV. Segmental lichen aureus: onset associated with trauma and puberty. *Arch Dermatol.* 1988;124:1572-4.
4. Shelley WB, Swaminathan R, Shelley ED. Lichen aureus: a hemosiderin tattoo associated with perforator vein incompetence. *J Am Acad Dermatol.* 1984;11:260-4.
5. Reinhardt L, Wilkin JK, Trausend R. Vascular abnormalities in lichen aureus. *J Am Acad Dermatol.* 1983;8:417-20.
6. Thomas PA, Korting HC. The "id"-concept: new insight into an old problem. *Eur J Dermatol.* 1995;5:114-6.

Copyright by Tatsuhiko Mori, et al. This is an open access article distributed under the terms of the Creative Commons Attribution License, which permits unrestricted use, distribution, and reproduction in any medium, provided the original author and source are credited.

Source of Support: Nil, **Conflict of Interest:** None declared.

A distinct cutaneous leishmaniasis lesion on the tip of the patient's nose: A visual warning for European colleagues

Funda Tamer¹, Mehmet Eren Yuksel²

¹Department of Dermatology, Medical Park Hospital, Ankara, Turkey, ²Devrek State Hospital, Department of General Surgery, Zonguldak, Turkey

Corresponding author: Dr. Funda Tamer, E-mail: fundatmr@yahoo.com

Sir,

An 18-year-old Caucasian male presented with a six-month history of non-healing wound on his nose. The patient admitted that the lesion started as a small erythematous papule and it increased in size gradually. Thereafter, the lesion became ulcerated. It was painless, however bleeding occurred when the patient scratched the lesion on the tip of his nose. The past medical history was unremarkable. The patient was living in a rural area of eastern Anatolia in Turkey. The physical examination revealed an erythematous, indurated, crusted plaque on the tip of the nose (Figs. 1 and 2). A skin biopsy was performed to reach a definitive diagnosis. The histopathological examination revealed cutaneous leishmaniasis. The patient was treated with intralesional meglumine antimoniate three times a week and cryotherapy every two weeks until the lesion was completely healed.

Cutaneous leishmaniasis is a parasitic disease which clinically presents with erythema, papule, nodule and ulcerative skin lesions. The causative agent of cutaneous leishmaniasis is the leishmania parasite which has several species. The leishmania parasites are spread by the bite of infected sandflies. Therefore, the leishmania lesions usually occur on the site of the sandfly bites including face, hands and feet [1]. It has been suggested that approximately 1.71 billion people are at risk for cutaneous leishmaniasis in the world [2]. The presence of sandflies, climate factors like temperature, unawareness of the disease, poor personal protection, poor housing and environmental

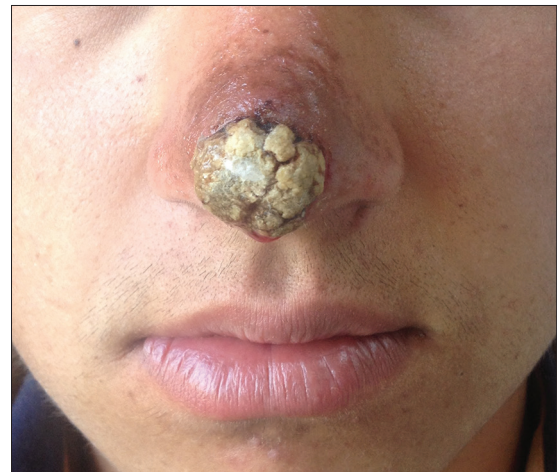

Figure 1: Cutaneous leishmaniasis: An erythematous, indurated, crusted plaque on the tip of the patient's nose.

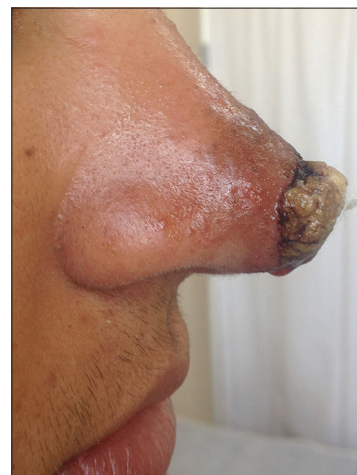

Figure 2: The right lateral view of the cutaneous leishmaniasis lesion on the patient's nose.

How to cite this article: Tamer F, Yuksel ME. A distinct cutaneous leishmaniasis lesion on the tip of the patient's nose: A visual warning for European colleagues. Our Dermatol Online. 2017;8(1):108-109.

Submission: 27.04.2016; **Acceptance:** 11.06.2016

DOI:10.7241/ourd.20171.31

conditions are the factors which affect the incidence and distribution of cutaneous leishmaniasis [2]. Cutaneous leishmaniasis occurs worldwide, however, most cases occur in Afghanistan, Algeria, Brazil, Pakistan, Peru, Saudi Arabia, and Syria [1].

Cutaneous leishmaniasis is endemic in Syria and increased incidence of the disease has been reported between 1997 and 2011 [3]. Recently, civil war in Syria led massive displacement of people. Therefore, the number of cutaneous leishmaniasis cases increased significantly in neighbouring countries like Turkey, Jordan and Lebanon [3]. Alawieh et al. reported that 96.6% of the all new cases in Lebanon in 2013 occurred among Syrian refugees [4].

Cutaneous leishmaniasis is endemic in southeastern Anatolia, eastern Anatolia and eastern mediterranean regions of Turkey. Inci et al. investigated the effect of Syrian war on prevalence of cutaneous leishmaniasis in southeastern Anatolia. They evaluated 110 patients who were diagnosed with cutaneous leishmaniasis between 2011 and 2014. 69% of the patients were Syrian refugees. Inci et al. reported that there was a relationship between increased incidence of cutaneous leishmaniasis and increased number of Syrian refugees from highly endemic areas [5].

Moreover, refugees from countries where cutaneous leishmaniasis is endemic may spread the infection to

non-endemic regions including European countries. For this reason, health care providers in Europe should be aware of the diagnosis and management of cutaneous leishmaniasis. Therefore, we would like to share a case of cutaneous leishmaniasis with distinct clinical features with our European colleagues.

REFERENCES

1. Reithinger R, Dujardin JC, Louzir H, Pirmez C, Alexander B, Brooker S. Cutaneous leishmaniasis. *Lancet Infect Dis.* 2007;7:581-96.
2. Haouas N. Estimations of cutaneous leishmaniasis burden: a constant challenge. *Lancet Infect Dis.* 2016. pii: S1473-3099(16)00058-X.
3. Haddad N, Saliba H, Altawil A, Villinsky J, Al-Nahhas S. Cutaneous leishmaniasis in the central provinces of Hama and Edlib in Syria: Vector identification and parasite typing. *Parasit Vectors.* 2015;8:524.
4. Alawieh A, Musharrafieh U, Jaber A, Berry A, Ghosn N, Bizri AR. Revisiting leishmaniasis in the time of war: the Syrian conflict and the Lebanese outbreak. *Int J Infect Dis.* 2014;29:115-9.
5. Inci R, Ozturk P, Mulayim MK, Ozyurt K, Alatas ET, Inci MF. Effect of the Syrian civil war on prevalence of cutaneous leishmaniasis in southeastern Anatolia, Turkey. *Med Sci Monit.* 2015;21:2100-4.

Copyright by Funda Tamer, et al. This is an open access article distributed under the terms of the Creative Commons Attribution License, which permits unrestricted use, distribution, and reproduction in any medium, provided the original author and source are credited.

Source of Support: Nil, **Conflict of Interest:** None declared.

A positive patch test in an isoniazid-induced Dress syndrome

Fatma Jendoubi, Kahena Jaber, Faten Rabhi, Mehdi Karray, Soumaya Youssef, Mohamed Raouf Dhaoui, Nejib Doss

Department of Dermatology, Military Hospital of Tunis, Tunisia

Corresponding author: Dr. Fatma Jendoubi, E-mail: dr.jendoubi.fatma@gmail.com

Sir,

A 59-year old patient was diagnosed with severe psoriasis since 1989. He was treated with different therapies without any improvement. Therefore the decision was to start an anti-TNF therapy. Before initiating the treatment, latent tuberculosis was diagnosed with Mantoux test and quantiferon TB gold. The patient was treated by isoniazid (450mg/day) and rifampicin (600mg/day). Three weeks later, he was hospitalized for a generalized cutaneous rash associated with an erythema and oedema of the face and hands and cheilitis. The patient had no fever and no lymphadenopathy. Laboratory evaluations showed a moderate increase in liver transaminases (aspartate aminotransferase = 85 U/l) and eosinophilia (1200/mm³). The diagnosis of Drug Reaction with Eosinophilia and Systemic Symptom (DRESS) syndrome was made (RegiSCAR score = 3). Antituberculous treatment was discontinued and 15 days later, he was asymptomatic. Patch testing with rifampicin and isoniazid (each 30 and 20 %) was performed. Readings on day 2 showed a positive reaction only to isoniazid (Figs. 1 and 2).

Drug reaction with eosinophilia and systemic symptoms (DRESS) is a severe adverse drug-induced reaction. The syndrome includes a severe skin eruption, fever, hematologic abnormalities (eosinophilia or atypical lymphocytes) and internal organ involvement. The other features are a delayed onset usually after 2-6 weeks after the initiation of drug therapy and a recovery over a period of two weeks of discontinuation of the culprit drug. Diagnostic criteria usually adopted are those of the international Registry of Severe Cutaneous

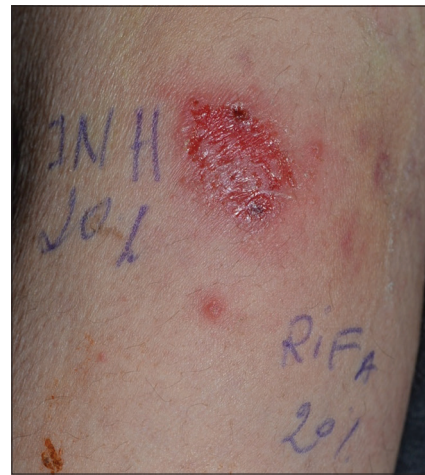

Figure 1: Positive patch test to isoniazid 20%, negative to rifampicin.

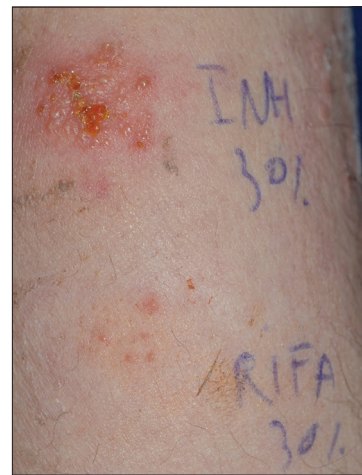

Figure 2: Positive patch test to isoniazid 30%, negative to rifampicin.

Adverse Reactions group (RegiSCAR). The most often involved drugs are aromatic anti-epileptics (phenytoin, carbamazepine and phenobarbital) and allopurinol [1].

How to cite this article: Jendoubi F, Jaber K, Rabhi F, Karray M, Youssef S, Dhaoui MR, Doss N. A positive patch test in an isoniazid-induced Dress syndrome. Our Dermatol Online. 2017;8(1):110-111.

Submission: 29.06.2016; **Acceptance:** 08.08.2016

DOI:10.7241/ourd.20171.32

Isoniazid is a very rare cause of DRESS [2-5]. The etiologic diagnosis is difficult as the result of the allergy workup is usually negative, and a challenge test is not advisable owing to potentially life-threatening consequences [3].

We present a case of isoniazid-induced DRESS in which the culprit agent was identified by positive patch test. Although the patch test was helpful in the diagnosis of DRESS, physicians should be aware of the possibility of life-threatening drug reactions associated with patch testing in DRESS [6].

REFERENCES

1. Cacoub P, Musette P, Descamps V, Meyer O, Speirs C, Finzi L, et al. The DRESS syndrome: a literature review. *Am J Med.* 2011;124:588-97.
2. Iwamoto S, Suzuki T, Sutani A, Kuraki T, Isobe T. [A case of atypical drug-induced hypersensitivity syndrome caused by isoniazid]. *Kekkaku.* 2012;87:777-82.
3. Arruti N, Villarreal O, Bernedo N, Audicana MT, Velasco M, Uriel O, et al. Positive Allergy Study (Intradermal, Patch, and Lymphocyte Transformation Tests) in a Case of Isoniazid-Induced DRESS. *J Investig Allergol Clin Immunol.* 2016;26:119-20.
4. Rubira N, Baltasar MA, Marti E. Hypersensitivity syndrome from isoniazid. *Allergy.* 1999;54:1011-2.
5. Ogawa K, Morito H, Kobayashi N, Fukumoto T, Asada H. Case of drug-induced hypersensitivity syndrome involving multiple-drug hypersensitivity. *J Dermatol.* 2012;39:945-6.
6. Shebe K, Ngwanya MR, Gantsho N, Lehloenyia RJ. Severe recurrence of drug rash with eosinophilia and systemic symptoms syndrome secondary to rifampicin patch testing in a human immunodeficiency virus-infected man. *Contact Dermatitis.* 2014;70:125-7.

Copyright by Fatma Jendoubi, et al. This is an open access article distributed under the terms of the Creative Commons Attribution License, which permits unrestricted use, distribution, and reproduction in any medium, provided the original author and source are credited.
Source of Support: Nil, **Conflict of Interest:** None declared.

Eponyms in dermatology literature linked to Otorhinolaryngology

Ahed Aqeel¹, Khalid Al Aboud², Ashraf Al Harbi¹, Adnan Alehibi², Rasha Al Harbi²

¹Department of Hospital Administration, King Faisal Hospital, Makkah, Saudi-Arabia, ²Department of Public Health, King Faisal Hospital, Makkah, Saudi-Arabia

Corresponding author: Dr. Khalid Al Aboud, E-mail: amoa65@hotmail.com

ABSTRACT

In some disorders, there are symptoms or signs shared by dermatology and ears, nose and throat (ENT) specialty. It is also known that there are eponyms in dermatology and ENT. The aim in this short communication is to shed some lights on the eponyms in dermatology literature linked to ENT.

Key words: Dermatology; Diseases; Eponyms

In some disorders, there are symptoms or signs shared by dermatology and ears, nose and throat (ENT) specialty. It is also known that there are eponyms in dermatology and ENT.

The aim in this short communication is to shed some lights on the eponyms in dermatology literature linked to ENT.

However, one may note that not all the disorders with shared symptoms and signs between dermatology and ENT are familiarly known by its correct eponym. Just as example, is Schwann syndrome, which is a combination of knuckle pads, leukonychia, and sensorineural deafness. It was first reported by Jadwiga Schwann.

Jadwiga Schwann was a dermatologist from Poland. Among her contributions to dermatology, she is credited for describing a syndrome, in German and Polish languages. This syndrome appeared latter in English literature by Robert S. Bart (Dermatologist) (Fig. 1) and Robert E. Pumphrey (Otolaryngologist); both from USA, and so the syndrome was then known as Bart – Pumphrey syndrome. Schwann syndrome is



Figure 1: Robert S. Bart.

cited in the Online Mendelian Inheritance in Man, as knuckle pads, leukonychia, and sensorineural deafness. It is characterized by knuckle pads, leukonychia, palmoplantar keratoderma (PPK) and sensorineural deafness [1].

In Table 1 was listed selected eponymous conditions in dermatology literature linked to ENT.

How to cite this article: Aqeel A, Al Aboud K, Al Harbi A, Alehibi A, Al Harbi R. Eponyms in dermatology literature linked to Otorhinolaryngology. Our Dermatol Online. 2017;8(1):112-113.

Submission: 09.11.2016; **Acceptance:** 22.11.2016

DOI: 10.7241/ourd.20171.33

Table 1: Selected eponymous conditions in dermatology literature linked to ENT

Eponymous conditions in dermatology literature linked to ENT	Remarks
Frey's syndrome [1-3]	It is named after, Lucja Frey or Łucja Frey-Gottesman (1889 in Lwów – 1942), [Fig. 2], who was a Polish physician and neurologist. She was one of the first female academic neurologists in Europe. She perished in 1942 in Lwów ghetto aged 53.
Ludwig angina [4]	Wilhelm Frederick von Ludwig (1790-1865), [Fig. 3], a German physician first described in 1836 a potentially fatal, rapidly spreading soft tissue infection of the neck and floor of the mouth. The condition was later named „Ludwig's angina”, a term which persists in medicine to this day.
Ramsay Hunt syndrome [5-7]	Also known as herpes zoster oticus. It is associated with an acute peripheral facial nerve paresis and quite often with other cranial nerve lesions. The combination of motor, sensory and autonomic involvement leads to a variety of neurological damage patterns, i. e. facial muscle paresis, hearing and balance disorders, sensory problems and disturbances of taste as well as lacrimal and nasal secretion. Additional variability of the clinical picture of Ramsay Hunt syndrome is produced by varying patterns of skin involvement explained by individual anastomoses between cranial and cervical nerves. It is named after, James Ramsay Hunt (1872-1937), [Fig. 4], who was an American neurologist. Hunt served as president of the American Neurologic Association in 1920, the New York Neurologic Society in 1929, the American Psychopathological Society in 1932, and the Association for Research in Nervous and Mental Disorders in 1934. He described three discrete syndromes, the best known of which is herpes zoster oticus, also known as Ramsay Hunt syndrome type 2.



Figure 2: Lucja Frey (1889-1942).




Figure 3: Wilhelm Frederick von Ludwig (1790-1865).



Figure 4: James Ramsay Hunt (1872-1937).

REFERENCES

1. Al Aboud K, Al Aboud A. Eponyms in the dermatology literature linked to Poland. *Our Dermatol Online*. 2013 4(Suppl. 2):424-5.
2. Bourgeois P, Morren MA. Frey's Syndrome After Herpes Zoster Virus Infection in a 2-Year-Old Girl. *Pediatr Dermatol*. 2015;32:e184-5.
3. O'Neill JP, Condron C, Curran A, Walsh A. Lucja Frey--historical relevance and syndrome review. *Surgeon*. 2008;6:178-81.
4. Al Aboud K, Al Aboud A. Eponyms in the dermatology literature linked to the oral disorders. *Our Dermatol Online*. 2013;4:247-50.
5. Wagner G, Klinge H, Sachse MM. Ramsay Hunt syndrome. *J Dtsch Dermatol Ges*. 2012;10:238-44.
6. Chodkiewicz HM, Cohen PR, Robinson FW, Rae ML. Ramsay Hunt syndrome revisited. *Cutis*. 2013;91:181-4.
7. Louis ED, Williams M. A biography of James Ramsay Hunt (1874-1937). *J Hist Neurosci*. 2003;12:266-75.

Copyright by Ahd Aqeel, et al. This is an open-access article distributed under the terms of the Creative Commons Attribution License, which permits unrestricted use, distribution, and reproduction in any medium, provided the original author and source are credited.

Source of Support: Nil, **Conflict of Interest:** None declared.

Dermatology eponyms – sign – Lexicon(R): Part 1

Piotr Brzeziński¹, Manouri P. Senanayake², Irantha Karunaratne², Anca Chiriac³

¹Department of Cosmetology, Institute of Biology and Environmental Protection, Pomeranian Academy, Slupsk, Poland,

²Department of Pediatrics, Faculty of Medicine, University of Colombo, Kynsey Road, Colombo 008, Sri Lanka, ³Department of Dermatology, Nicolina Medical Center, Iasi, Romania

Corresponding author: Piotr Brzezinski, MD, PhD., E-mail: brzezoo77@yahoo.com

ABSTRACT

Eponyms are used almost daily in the clinical practice of dermatology. And yet, information about the person behind the eponyms is difficult to find. Indeed, who is? What is this person's nationality? Is this person alive or dead? How can one find the paper in which this person first described the disease? Eponyms are used to describe not only disease, but also clinical signs, surgical procedures, staining techniques, pharmacological formulations, and even pieces of equipment. In this article we present the symptoms starting with (R) and other. The symptoms and their synonyms, and those who have described this symptom or phenomenon.

Key words: Eponyms; Skin diseases; Sign; Phenomenon

Rabbit Fever Sign

Tularemia infection [1].

Raccoon Sign

1. The periorbital bruising associated with anterior basilar skull fracture or fracture of the nose and neuroblastoma. Sometimes associated with the reservoir phenomenon of cerebrospinal fluid in the sinus cavity [2]. Also known as “panda eyes”.
2. The most common cutaneous manifestation of neonatal lupus erythematosus is erythematous, slightly scaly eruption on the face and periorbital skin (raccoon sign/owl-eye/eye mask).
3. Periorbital hemorrhage due to laxity of blood vessels seen after proctoscopic examination (postproctoscopic periorbital Purpura) in patients having systemic amyloidosis is also called as Raccoon eyes/sign/panda sign.

Rag-sorters's Sign

1. Malignant pustule in rag-sorters [3].
2. A febrile disease with cough and headache, seen in rag-sorters, and due probably to a bacillus.

Rain Rot Sign

Pustular desquamative dermatitis, caused by the zoonotic fungal *Dermatophilus congolensis*. Found in horses, cattle, sheep, and other mammals worldwide [4]. Also called Rain Scald sign and Dew Poisoning sign.

Rain Scald Sign

Also called Rain Rot sign.

Rash-extinction Sign

Schultz-Charlton reaction phenomenon [5]. The specific blanching of a scarlatinal rash at the site of intracutaneous injection of scarlatina antiserum.

In 1918, Schultz and Charlton first reported that the intracutaneous injection of from 0.5 to 1 cc. of normal or scarlet fever convalescent serum would blanch the rash of scarlet fever at the site of injection. They also showed that the blanching substance was present in serum taken after the fourteenth day of scarlet fever, but that serum taken earlier in the disease did not have blanching power. Plain horse serum or diphtheria antitoxin failed to blanch the rash. Schultz

How to cite this article: Brzeziński P, Senanayake MP, Karunaratne I, Chiriac A. Dermatology eponyms – sign – Lexicon (R): Part 1. Our Dermatology Online. 2017;8(1):114-120.

Submission: 25.03.2016; **Acceptance:** 09.09.2016

DOI:10.7241/ourd.20171.34

and Charlton also made injections of a dilute solution of epinephrine hydrochloride intracutaneously, and found that the rash blanched within a few minutes. This blanching lasted five or six hours. In contrast, the reaction produced by scarlet fever convalescent serum appeared only after five or six hours and lasted several days. Schultz and Charlton expressed the belief that human serum contained some vasoconstricting factor which counteracted the vasodilating effect.

Rasin's Sign

The pigmentation, usually brownish, occurring on the lid margins in many cases of hyperparathyroidism [6]. Also known as Jellinek's sign.

Stefan Jellinek

Austrian physician, 1871-1968 (Fig. 1). He studied medicine at the University of Vienna from 1892 to 1898. From December 1898 to April 1899 Senator's assistant at the clinic in Berlin. In the years 1900-1903 the aspirant in the third clinic in Vienna, from 1903 sekundariusz in the Department of Dermatology. In December 1908 his habilitation in internal medicine. Since 1910 assistant at the Institute Elektropatologicznym. May 14, 1929 elektropatologii was an associate professor at the University of Vienna. In 1938, because of his Jewish origin had lost his job, then emigrated to the UK. He practiced at Queen's College [6].

Raspberry Sign

Contagious raspberry like nodules beginning with minute red spots, then after seven days form yellow papules, then the raspberry crust, sometimes with edema of the limbs and eyelids. Also called by the Carib word yaws and the French framboise or frambesia. Believed to be same as button-scurvy of Ireland [7].

Raynaud's Sign

Raynaud phenomenon, a vasospastic disorder, is characterized by sensitivity to cold temperatures, triggering the release of vasoconstrictors, including catecholamines, endothelin-1, or 5-hydroxytryptamine (Fig. 2). Clinically, vasospasm or vasoconstriction may be associated with a change in the color of the fingers or toes, starting with one or several digits and spreading symmetrically to all fingers or toes (A cold pale condition of the fingers and toes alternating with heat



Figure 1: Stefan Jellinek.

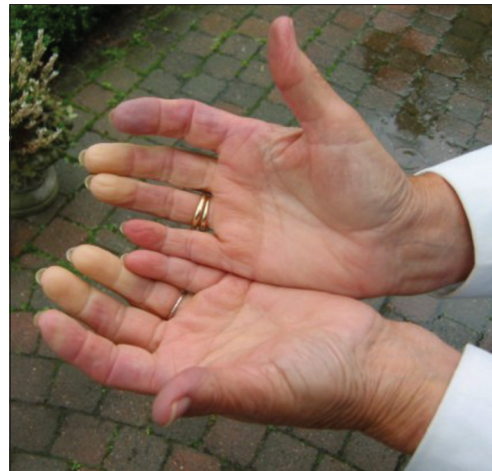

Figure 2: Raynaud sign.

and redness). Attacks usually end with a sudden reflow of blood to the area, creating a reactive hyperemia. Criteria for primary Raynaud phenomenon (RP) are symmetrical attacks without necrosis, ulceration, or gangrene and no evidence of secondary causes. Typical onset of primary RP occurs in the early to middle teens as well as sometimes after the fourth decade of life. Symptoms may be mild. In contrast, criteria for secondary RP are associated with severe episodic attacks, usually asymmetrical or with ulcerations. Patients also may have other manifestations of connective tissue disease (eg, arthritis, systemic sclerosis). An early sign of asymmetric gangrene or Raynaud's disease. Also known as acro-asphyxia or Dead-finger sign and sphaceloderma [8,9].

Auguste Gabriel Maurice Raynaud

French physician, (1834-1881) (Fig. 3). He discovered Raynaud's Disease, a rare vasospastic disorder which

contracts blood vessels in extremities and is the “R” in the CREST syndrome acronym, in the late 19th century.

Maurice Raynaud was the son of a university professor. He commenced his medical studies at the University of Paris with the help of his uncle, the well known Paris physician Ange-Gabriel-Maxime Vernois (1809–1877), and obtained his medical doctorate in 1862. He thus became one of the select few who have achieved eponymous fame with their doctoral dissertation, in his case: *De l’asphyxie locale et de la gangrène symétrique des extrémités*.

Raynaud never received a senior position at any of the Paris hospitals, but became Médecine des hôpitaux (received hospital privileges) in 1865. At various times, he was attached to the hospitals of Hôtel Dieu (1866), Sainte Périne (1868), Saint-Antoine (1872), Lariboisière (1872) et La Charité (1880), among others. In 1866 he became an agrégé with the works *Sur les hyperhémies non phlegmasiques* and *De la revulsion*, which established him as a professor of medical pathology.

He was made an officer of the Légion d’honneur in 1871 and elected to the Académie de Médecine in 1879, and lectured with great success at the university as well as the Lariboisière and Charité hospitals.

Although Raynaud always wanted to hold the chair of medical history at the University of Paris, he died on 29 June 1881, in his prime, before achieving that goal, shortly before the international medical congress in London that year. At the London congress, Raynaud’s paper, “Scepticism in Medicine, Past and Present”, was read by one of his colleagues.

He was also a busy writer. His book *Sur la salive d’un enfant mort de la rage* was the result of research done with Louis Pasteur and Odilon Marc Lannelongue.

Recklinghausen’s Sign

Multiple neurofibromata (Fig. 4) [10].

Friedrich Daniel Von Recklinghausen

German pathologist, 1833-1910 (Fig. 5). He began his medical studies in Bonn in 1852, continued them in Würzburg, and completed his doctorate in Berlin in 1855. Subsequently, he studied pathology with Rudolf Virchow, after which he traveled to Vienna, Rome, and




Figure 3: Auguste Gabriel Maurice Raynaud.

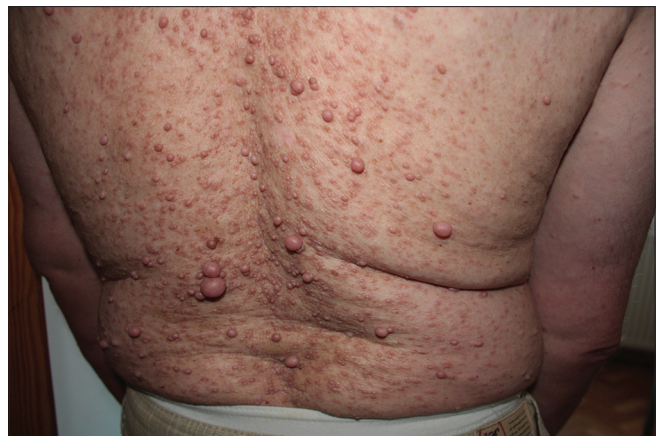

Figure 4: Recklinghausen's sign.




Figure 5: Friedrich Daniel von Recklinghausen.

Paris for further study. He returned to Berlin in 1858 and served as an assistant in Virchow’s Institute for Pathology until 1864. In Königsberg, he was briefly appointed as Professor Ordinarius—without having gone through the usual academic steps of Docent

and Professor Extraordinary—until six months later, when he went to Würzburg until 1872. He was then appointed Professor at the new university in Strassburg. He became Rector of the university in 1877, and remained there until his death in 1910.

Recklinghausen was well known for many important contributions, including early descriptions of hemochromatosis, bone lesions in hyperparathyroidism, and, of course, a number of eponymous conditions: von Recklinghausen's Disease, von Recklinghausen's tumor (adenoleiomyofibroma on wall of the fallopian tube or posterior uterine wall), and von Recklinghausen's canals (lymphatic canaliculi). He developed a silver nitrate stain to allow visualization of cell structures.

While von Recklinghausen was not the first to recognize spina bifida (the first description was apparently in 1641 by Fulpius, who coined the term), he was one of the first to provide such a complete description. We reproduce here a brief abridgement of his classic article, "Untersuchungen über die Spina bifida," published in 1886 [11,12].

Relapsing Sign

A zoonotic louseborne *Borrelia* disease, causing a relapsing fever every three to five days. Also called relapsing fever disease [13].

Remak's Sign

A double sensation caused by pricking with a needle. A sign of tabes dorsalis [14].

Ernst Julius Remak

German neurologist, 1849-1911 (Fig. 6). He was the son of famed neurologist Robert Remak.

He received his education at the Universities of Breslau, Berlin, Würzburg, Strasbourg and Heidelberg, and obtained the degree of M.D. in 1870. Afterwards he took part in the Franco-Prussian War of 1870-71. After serving as assistant in the department for nervous diseases at the Charité Hospital, Berlin from 1873 to 1875, he established himself as a neuropathologist in the German capital, where he became privat-docent in 1877, and professor in 1893. With Edward Flatau, he published an important work on neuritis and polyneuritis.

His name is associated with the eponymous "Remak reflex", which is plantar flexion of the first three toes



Figure 6: Ernst Julius Remak.

and sometimes the foot with extension of the knee, induced by stroking of the upper anterior surface of the thigh. This reflex takes place when the conducting paths in the spinal cord are interrupted [15].

Remak has contributed more than 50 essays to the professional journals, and is the author of: "Grundriss der Elektrodiagnostik und Elektrotherapie für Praktische Aerzte", Vienna, 1895. "Neuritis und Polyneuritis," in Nothnagel's, "Handbuch der Speziellen Pathologic und Therapie", ib. 1900.

Renbök Phenomenon

In 1991, Happle et al. coined the term "Renbök" phenomenon to describe the opposite of the Koebner phenomenon, designating the withdrawal of a lesion with the appearance of another one. It was originally described in alopecia areata (AA) patients experiencing hair growth in psoriatic lesions. Although psoriasis can often co-exist with AA, reports on psoriasis-induced Renbök phenomenon in AA have been exceedingly sparse, and did not demonstrate the interchanging nature of these two disorders [16].

Rendu's Sign

Telangiectases around the mouth found in the malabsorption Osler-Weber-Rendu disease [17,18].

Henri Jules Louis Marie Rendu

French physician, 1844-1902 (Fig. 7). In 1865, on the advice of his father, Rendu registered in the School of Medicine in Paris. First in his class, he became externe in 1867, and in 1868 interne at the Hôpital Saint-Antoine in the department of Jules Guyot, also working




Figure 7: Henri Jules Louis Marie Rendu.

under Adolphe-Marie Gubler, Ernest Henri Besnier, Henri Louis Roger, and Pierre Charles Édouard Potain, with whom he became closely associated.

In 1870, after the declaration of the Franco-Prussian war, he was appointed as surgeon to the army. He did not accept the principle of evacuation of patients upon whom he had operated, taking a great risk, and asked the help of locals to keep them with him. Coming back to Paris, he held a junior appointment at the Hôpital Saint-Louis where he became involved in dermatology, then spent some time in the care of infants and children. In 1873 he was awarded the Médaille d'Or of internship and spent a year at the Hôpital Necker in the department of professor Pierre Charles Édouard Potain, one of France's leading clinicians. In 1874 he produced his thesis on the "Paralyses related to tuberculous meningitis in children" for which he received the Médaille d'Argent. At this time he also started a private practice.

In 1877 Rendu received the degree of hospital physician – médecin des hôpitaux – and then married Marie Labric, whose father was a physician at the Hôpital des Enfants. In 1878 he finally achieved professeur agrégé with a thesis on "Comparative study of chronic nephritis".

He then began his career in the Hôpital Tenon, and in 1885 moved to a senior post as Head of the Department of Medicine at the Hôpital Necker, where he spent the remainder of his career.

Rendu published more than 100 medical articles and his academic activities were rewarded in 1878

by elevation to the status of professeur agrégé of the faculty of medicine at the University of Paris. In 1897 he received the ultimate accolade of election to membership of Academy of Medicine. He had a large private practice, and even though he was offered the chair of pathology after the death of Victor Charles Hanot he preferred to remain an active clinician [18].

He spent his spare time travelling throughout France seeking specimens for the botanical collection which had been started by his grandfather, and which he made one of the finest collections of plants in France. He was also a great lover of the belle arts.

Rendu published many of his articles in Bulletin de la Société anatomique de Paris and was its editor 1873-1874. He was a contributor to Dictionnaire encyclopédique des sciences médicales.

Reverse Namaskar Sign

Namaskar' is the typical Indian way of greeting people, where the forearms are folded in front of the chest and the palms are closely approximated together. In patients with hyperextensible joints as seen in Ehler Danlos syndrome, they are able to fold their forearms at the back and oppose their palms to say "Namaskar," demonstrating the hyper extensible joints [19].

Rhagades Sign

White linear scars which radiate from the corners of the mouth, a sign of congenital syphilis [20].

Rhodesian Sleeping Sign (Africa)

Zoonotic trypanosomiasis [21].

Rhodium's Sign

The sweetness of sweat after the ingestion of honey [22].

Apollonius of Rhodes

Was a Greek epic poet and scholar of the Library of Alexandria (First half of 3rd century BCE) (Fig. 8). He was the author of a celebrated epic entitled the Argonautica which described the journey of the Argonauts in their quest for the Golden Fleece. The key episodes of the myth were sourced from older poets such as Hesiod and Pindar [23].

“Apollonius Rhodius. Argonautica. Translated by Seaton, R. C. Loeb Classical Library Volume 001. London, William Heinemann Ltd, 1912.”

Riga-Fede Sign

Cachectic aphthae (Fig. 9). It is a benign and uncommon mucosal disorder, characterized by an ulceration of the tongue, often caused by repetitive traumatic injuries due to backward and forward movements of the tongue over the mandibular anterior incisors. Also called as Riga’s disease or Riga-Fede disease [24].

Antonio Riga

Italian physician, 1834-1918 (Fig. 10). The young Antonio Riga after finishing his studies in medicine at the University of Naples, he joined the army, reaching the rank of Major.




Figure 8: Apollonius of Rhodes.

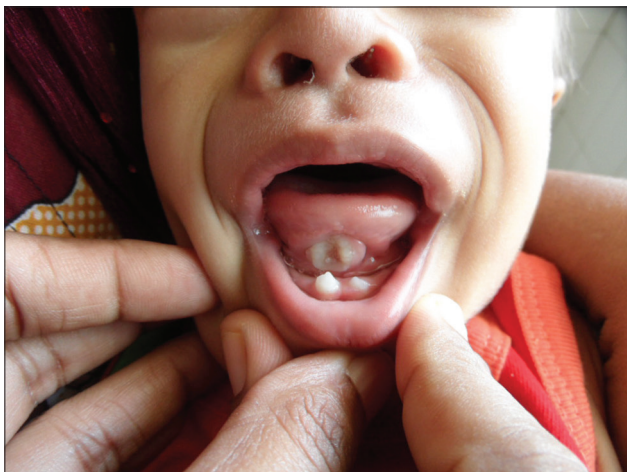

Figure 9: Riga-Fede sign in a child with down syndrome. Ulcer on ventral surface of tongue and natal teeth.

Back in Sant’Elia Fiumerapido was very active in public and professional life, in fact quickly became known for his scientific studies led him to the discovery of a rash illness of childhood that is called “Riga Disease”.

Later he wrote remarkable works on scientific topics including “Epidemics of malaria fever in 1879”.

Very thick was another work written from Riga, but not scientific, but sociological inherent to the condition of the society of his time: “Memoria intorno al brigantaggio nel territorio di S’Elia e i suoi dintorni”. He was ruling with the painter Enrico Risi, the Workers’ Association of Sant’Elia.

In 1889 he did his utmost for the affixing of a commemorative plaque in memory of the martyr



Figure 10: Antonio Riga (Thanks to: COMUNE di SANT’ELIA FIUMERAPIDO <http://www.comune.santeliafiumerapido.fr.it/>).




Figure 11: Francesco Fede. (Thanks to Prof. Italo Farnetani from Collaboratori dell’Istituto dell’Enciclopedia Italiana, Treccani, Roma, Italia).

Angelo Santilli died in Naples during the riots of 1848. Major Doctor Antonio Riga after a very active life and satisfying, died aged 84. Today he is entitled to the square adjacent to the City Hall Sant'Elia. [25].

Francesco Fede

Italian pediatrician, 1832-1913 (Fig. 11). Francesco Fede studied medicine in Napoli and then worked at the physiological institute under Giuseppe Albini (1860-1885), while also teaching embryology. A large number of his works stems from this time. Besides his normal employment he was also physician to the Nosocomia degli incurabili and taught medical pathology and clinics. He then changed to paediatrics and in 1892 became professor of this discipline in Napoli.

Fede's works on anaemia splenica infantilis, nephritis, Parrot's disease, rachitis, etc. are fundamental. In 1893 he founded the journal *La Pediatria*, which was to gain a leading role in Italian paediatrics [26].

REFERENCES

- Su TY, Shie SS, Chia JH, Huang CT. Case Report of Low Virulence Francisella tularensis Presented as Severe Bacteremic Pneumonia. *Medicine (Baltimore)*. 2016;95:e3390.
- Kandavar S, Varghese N, Rao M, Shetty S. Curious case of raccoon eye under general anaesthesia. *Indian J Anaesth*. 2016;60:442-3.
- Chellini E, Martino G, Grillo A, Fedi A, Martini A, Indiani L, et al. Malignant mesotheliomas in textile rag sorters. *Ann Occup Hyg*. 2015;59:547-53.
- Beylot C, Bioulac P. [Pustular psoriasis in infants and Leiner-Moussous desquamative erythroderma]. *Nouv Presse Med*. 1973;2:1000.
- Calder RM. Allergic Shock following a Schultz-Charlton Test. *Br Med J*. 1941;2:198-9.
- Brzezinski P, Chiriac A, Munsey C, Sinjab AT. Dermatology Eponyms – sign – Lexicon (J). *Our Dermatol Online*. 2013;4:399-402.
- Morton RS. The button scurvy of Ireland: postscript of the mssvd meeting in Dublin, May 29 and 30, 1964. *Br J Vener Dis*. 1964;40:271-2.
- Leroux MB, Lashak C. Evolution of video capillaroscopy for 10 years in a patient with Raynaud. *Our Dermatol Online*. 2014;5:374-7.
- Ajili F, Mansour HB, Ghedira H, Zriba S, Metoui L, Gharsallah I, et al. Digital ischemia due to Systemic Sclerosis associated to Essential Thrombocythemia: A case report. *Our Dermatol Online*. 2013;4:508-10.
- Radek M, Tomasiak B, Wojdyn M, Snopkowska-Wiaderna D, Blaszczyk M, Radek A. Neurofibromatosis type 2 (NF 2) or schwannomatosis?--Case report study and diagnostic criteria. *Neurol Neurochir Pol*. 2016;50:219-25.
- Brand RA. Biographical sketch: Friedrich Daniel von Recklinghausen, MD (1833-1910). *Clin Orthop Relat Res*. 2011;469:1225-6.
- Al Aboud K, Al Aboud D. Eponyms in the dermatopathology literature linked to the neural tissues. *Our Dermatol Online*. 2013;4:395-8.
- Seilmaier M, Guggemos W, Wieser A, Fingerle V, Balzer L, Fenzl T, Hoch M, von Both U, Schmidt HU, Wendtner CM, Strobel E. [Louse-borne-relapsing-fever in refugees from the Horn of Africa; a case series of 25 patients]. *Dtsch Med Wochenschr*. 2016;141:e133-42.
- Pearce JM. The Argyll Robertson pupil. *J Neurol Neurosurg Psychiatry*. 2004;75:345.
- Holderhoff B, Winau R. *Geschichte der Neurologie in Berlin*. Walter de Gruyter. Berlin/New York. 2001.
- Ovcharenko Y, Serbina I, Zlotogorski A, Ramot Y. Renbök phenomenon in an alopecia areata patient with psoriasis. *Int J Trichology*. 2013;5:194-5.
- Brzezinski P. Dermatology Eponyms – phenom/sign – Lexicon (E). *Our Dermatol Online*. 2011;2:235-40.
- [No authors listed]. Henri Rendu (1844-1902). Rendu-Osler-Weber disease. *JAMA*. 1966;197:583.
- Premalatha S, Sarveswari KN, Lahiri K. Reverse-Namaskar: a new sign in Ehlers-Danlos syndrome: a family pedigree study of four generations. *Indian J Dermatol*. 2010;55:86-91.
- Khetarpal S, Kempf E, Mostow E. Congenital syphilis: early- and late-stage findings of rhagades and dental anomalies. *Pediatr Dermatol*. 2011;28:401-3.
- El-Bahnasawy MM, Khater MKh, Morsy TA. African trypanosomiasis with special reference to Egyptian Trypanosoma evansi: is it a neglected zoonosis? *J Egypt Soc Parasitol*. 2014;44:741-8.
- Finlayson LH, Osborne MP, Anwyl R. Effects of acetylcholine, physostigmine, and hemicholinium-3 on spontaneous electrical activity of neurosecretory nerves in Carausius and Rhodius. *J Insect Physiol*. 1976;22:1321-6.
- <http://www.theoi.com/Text/ApolloniusRhodius1.html>
- Senanayake MP, Karunaratne I. Persistent lingual ulceration (Riga-Fede disease) in an infant with Down syndrome and natal teeth: a case report. *J Med Case Rep*. 2014;8:283.
- Lanni A. Guida storica-turistica-commerciale di Sant'Elia Fiumerapido. Editore LAPI sas, Arti Grafiche Carmanica Marina di Minturno (LT) 1999.
- Farnetani F, Navarra A, Farnetani I. [Biography and bibliography of Francesco Fede, the founder of Italian pediatrics]. *Minerva Pediatr*. 2011;63:515-26.

Copyright by Piotr Brzezinski, et al. This is an open access article distributed under the terms of the Creative Commons Attribution License, which permits unrestricted use, distribution, and reproduction in any medium, provided the original author and source are credited.
Source of Support: Nil, **Conflict of Interest:** None declared.

Dermatology eponyms – sign – Lexicon (R): Part 2

Piotr Brzeziński¹, Max Carlos Ramírez Soto^{2,3}, Patrice Bourée⁴, Balachandra S. Ankad⁵, Shirish Dubey⁶, Shivanand Gundalli⁷, Martin G. Baartmans⁸, Tomasz Wasylyszyn⁹, Katarzyna Borowska¹⁰, Anca Chiriac¹¹

¹Department of Cosmetology, Institute of Biology and Environmental Protection, Pomeranian Academy, Slupsk, Poland, ²Unit Graduate School of Medicine, National University of San Marcos, Lima, Peru, ³Publications Office, National Institute of Health, Peru, ⁴Parasitic Diseases Unit, Hospital Cochin, 75014 Paris, France, ⁵Department of Dermatology, S N Medical College, Bagalkot, Karnataka, India, ⁶Consultant Rheumatologist University Hospital Coventry and Warwickshire NHS Trust, Clifford Bridge Road, Coventry, UK, ⁷Department of Pathology, S. Nijalingappa Medical College, Bagalkot, Karnataka, India, ⁸Department of Paediatrics, Maasstadziekenhuis, Rotterdam, Netherlands, ⁹Department of Dermatology, Military Institute of Medicine in Warsaw, Poland, ¹⁰Department of Histology and Embryology with Experimental Cytology Unit, Medical University of Lublin, Poland, ¹¹Department of Dermatology, Nicolina Medical Center, Iasi, Romania

Corresponding author: Piotr Brzezinski, MD, PhD., E-mail: brzezoo77@yahoo.com

ABSTRACT

Eponyms are used almost daily in the clinical practice of dermatology. And yet, information about the person behind the eponyms is difficult to find. Indeed, who is? What is this person's nationality? Is this person alive or dead? How can one find the paper in which this person first described the disease? Eponyms are used to describe not only disease, but also clinical signs, surgical procedures, staining techniques, pharmacological formulations, and even pieces of equipment. In this article we present the symptoms starting with (R) and other. The symptoms and their synonyms, and those who have described this symptom or phenomenon.

Key words: Eponyms; Skin diseases; Sign; Phenomenon

Rinman's Sign

The appearance of cord like radiations proceeding from the nipple. An early sign of pregnancy.

Ringworm Sign

Tinea corporis ("ringworm"): Note the outer red border and clear center (Fig. 1). *T. rubrum* is the most common cause [1].

Ritter's Sign

Dermatitis exfoliativa neonatorum (Fig. 2), with diffuse and universal scaling, which may be branny or in laminae like pityriasis rubra [2,3].

Gottfried Johann Nepomucenus Ritter von Rittershain

German physician and pediatrician, 1820-1883 (Fig. 3).

He studied at Lviv University and Charles University. The title of his thesis was "De epilepsia". He worked at the clinic in Prague and was interested in episode paediatrics. In 1864 he was appointed professor of pediatrics in Prague. He was founder of the Prague medical weekly. In 1880 he had to give up his job because of his epilepsy. He died on August 20, 1883 of a stroke [4]. On Ritter is the Ritter disease, so the staphylococcal scalded skin syndrome.

Rivolta's Sign

Actinomycosis (Fig. 4). The term "Actinomycosis" was derived from the Greek terms aktino, which refers to the radiating appearance of a sulfur granule, and mykos, which labels the condition a mycotic disease [5].

Sebastiano Rivolta

Italian veterinarian and bacteriologist, (1832-1893) (Fig. 5). He was persuaded by his father to join the

How to cite this article: Brzezinski P, Ramirez Soto MC, Bourée P, Ankad BS, Dubey S, Gundalli S, Baartmans MG, Wasylyszyn T, Borowska K, Chiriac A. Dermatology eponyms – sign – Lexicon (R): Part 2. Our Dermatology Online. 2017;8(1):121-127.

Submission: 22.08.2016; **Acceptance:** 01.12.2016

DOI: 10.7241/ourd.20171.35

Royal School of Veterinary Medicine of Turin in 1852, winning a scholarship and graduating with honors four years later.

He immediately set out for his intensive research in parasitology, bacteriology, pathology and clinical anatomy, which led to the discovery and observation of the agents responsible for numerous veterinary diseases. Among them we can mention the *Discomyces bovis* (1868); *Cryptococcus farciminosus* (1873); *Avitellina centripunctata* (1874); *Discomyces equestris* (1884); *Opisthorchis felineus* (1884).

With his studies contributed to a greater understanding of the role of many pests germs from income and not: *Demodex folliculorum*; *Moniezia expansa*; *Taenia echinococcus*; *Bacillus anthracis*. First he observed the cellular inclusions characteristic of diftero-avian pox, laying the foundation for the study of this disease caused by a virus, in a period when the virology was yet to be born. To him we owe the discovery of some special cells in the retina of the horse, so called “cells of the Revolt”.

The experience allowed him to teach six different

materials at the Turin University, before moving to the University of Pisa. He became a full professor of General Pathology and Veterinary Pathological Anatomy, practiced teaching in the Tuscan city for 22 years, until his death occurred as a result of complications of his precarious state of health, due to a severe chronic disease that accompanied him from his youth. It is still buried in the monumental cemetery of Alexandria [6].

Robinson's Sign

Hidrocystoma (Fig. 6a and b) [7].

Andrew R. Robinson

American dermatologist, 1845.

Rodent Ulcer Sign

Malignant ulcer situated above a line which joints the angle of the mouth and the tragus of the ear. Called a rodent ulcer because the wound looks like a rat has gnawed at the tissue and bone (Fig. 7) [8].

Sir Charles Mansfield Clarke

(1st Baronet) English physician, 1782-1857 (Fig. 8). After leaving St Paul's School, he received his medical training at St George's Hospital and the Hunterian School of Medicine. He spent two years as assistant surgeon in the Hertfordshire Militia. He left the army and, specialised in midwifery and in women's and children's diseases. Between the years 1804 and 1821, he delivered regular courses of lectures on these subjects. His reputation as a practitioner during these years reached great heights and numerous honours were bestowed on him, including the Fellowship of the Royal Society in 1825, the appointment of Physician to Queen Adelaide in 1830, a baronetcy in 1831, and honorary degrees at Cambridge and Oxford in 1842 and

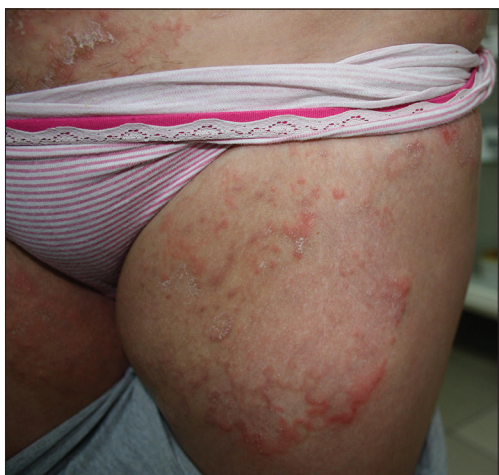

Figure 1: Ringworm sign.

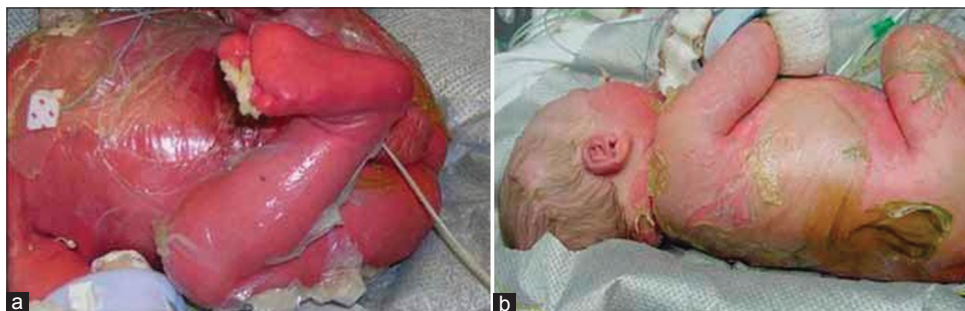


Figure 2: Ritter's sign.



Figure 3: Gottfried Johann Nepomucenus Ritter von Rittershain.

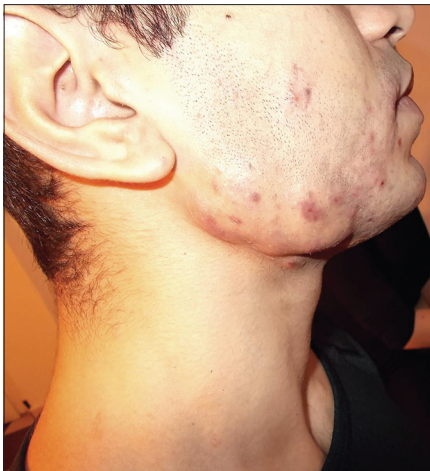

Figure 4: Rivolta's sign.




Figure 5: Sebastiano Rivolta.

1845. He was president, and an enthusiastic supporter, of the Society for the Relief of the Widows and Orphans of Medical Men [9].

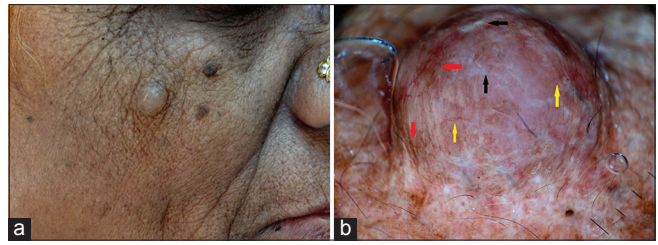


Figure 6: Robinson's sign. (a) Skin colored translucent tumor on the right cheek. (b). Dermoscopy showing brown pigment globules (red arrows), telangiectasia (yellow arrows) and whitish strands (black arrows).

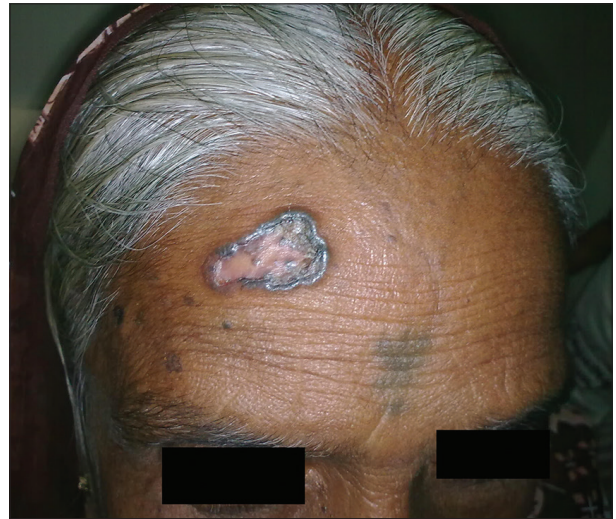

Figure 7: Noduloulcerative (rodent ulcer) Basal cell carcinoma.



Figure 8: Sir Charles Mansfield Clarke.

Romaña's Sign

Romaña's sign is the first symptom of american trypanosomiasis (or Chagas' disease) (Fig. 9). When the route of inoculation of parasites (*Trypanosoma cruzi*) is the ocular mucosa, edema of the eyelids and

conjunctivitis may occur. This unilateral periorbital edema which does not pit on pressure and with a dry skin is thought to be pathognomonic for early Chagas' disease. Chagas' disease is a zoonosis, caused by *Trypanosoma cruzi*, which was discovered by Carlos Chagas in Brazil in 1909. About 18 million persons are infected in south America, mostly in Brazil and Argentina [9,10].

Cecilio Felix Romaña

Argentinean physician (1899-1997). He was an Argentinean researcher dedicated to tropical diseases firstly in the area of Santa Fe then in Oswaldo Cruz Institute (Rio da Janeiro) with S. Mazza. Romaña became famous when he described this symptom in 1935. But, the director of the Institute, S. Mazza, never accepted neither the specificity of this sign nor its popular name as Romaña's sign [10].

Rhomboid Sign

Central papillary atrophy of the tongue, associated with the presence of *Candida albicans* [11,12].

Rope Sign

It refers to the thick indurated inflammatory cord like structure that extends from the lateral trunk to the axillae and said to be a classical finding of interstitial granulomatous dermatitis (Ackerman's syndrome) with arthritis (Fig. 10) [13].

Rose Handler's Sign

Ulcerative skin lesions with nodular lymphangitis, due to exposure to the zoonotic fungal *Sporothrix schenckii*, found on peat moss, horses, laboratory animals, other mammals, and birds (Fig. 11a and b) [14].

Rose Spots Sign

Rose spots on the abdomen with typhoid fever [15].

Rosenbach' Sign

1. Absence of the abdominal skin reflex in inflammatory disease of the intestines.
2. Absence of the abdominal skin reflex in pinching the skin of the abdomen on the paralyzed side in hemiplegia.
3. A fine rapid tremor of the closed eyelids in Graves' disease.

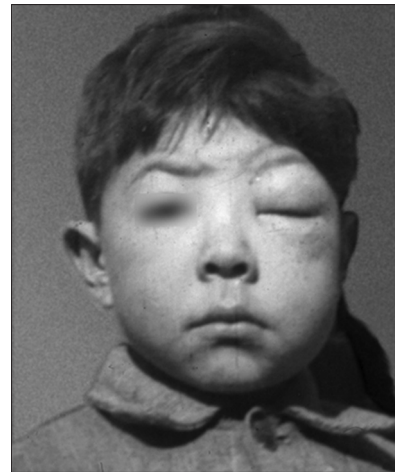

Figure 9: Romaña's sign.

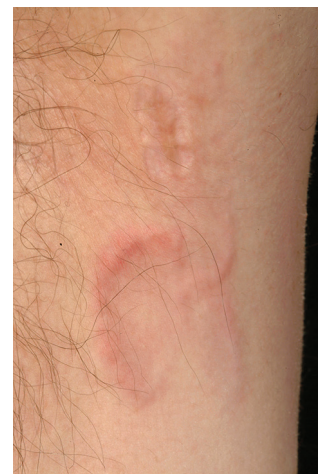

Figure 10: Rope sign.

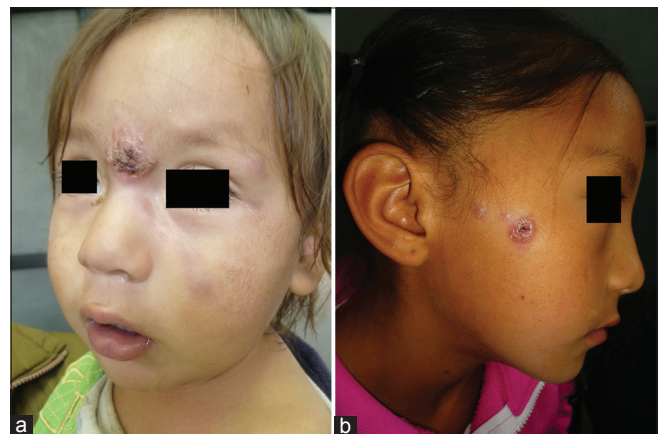

Figure 11: Rose Handler's sign. (a) Cutaneous lymphatic sporotrichosis crusted-ulcer on the forehead and nose with nodules on the cheeks; (b) Sporotrichosis lymphocutaneous on the malar region.

4. Inability to close the eyes immediately on command; seen in neurasthenia.

Ottomar Ernst Felix Rosenbach

German physician, 1851-1907 (Fig. 12). He received his education at the universities of Berlin and Breslau (M.D. 1874). His studies were interrupted by the Franco-Prussian war, in which he took an active part as a volunteer. From 1874 to 1877 he was assistant to Wilhelm Olivier Leube and Carl Wilhelm Hermann Nothnagel at the medical hospital and dispensary of the University of Jena; in 1878 he was appointed assistant at the Allerheiligen-Hospital at Breslau, and became privatdozent at the university of that city; in 1887 he became chief of the medical department of the hospital, which position he resigned in 1893; and in 1888 he was appointed assistant professor. In 1896 he resigned his professorship and removed to Berlin, where he practised until his death.

He discovered unusual eye tremors when the eyelids are closed in patients with Graves disease. He also described a clinical sign for aortic regurgitation (involving systolic pulsations of the liver) [16].

Ross River Rash Sign (Australia, South Pacific Islands)

Purpura on the lower extremities with fever and polyarthritis. Caused by the mosquito-borne zoonotic Ross River alphavirus [17].

Rössle's Sign

Plantar hypersensitivity. A sign in thrombosis [18].

Robert Rössle

German pathologist, 1876-1956 (Fig. 13). In 1900 he received his medical doctorate from Munich, and went to work at the Pathological Institute of the University of Kiel. From 1911 to 1921, he was a professor of general pathology and pathological anatomy at the University of Jena, and from 1922 until 1929 he held a similar position in Basel. In 1929 he succeeded Otto Lubarsch in the department of pathology at the Charité in Berlin, where he remained until 1948.

Rössle performed pathological investigations in several facets of medicine, including liver disease, allergies, inflammation, cellular pathology and geriatrics. He described aspects associated with a form of secondary biliary cirrhosis that was once referred to as "Hanot-Rössle syndrome" (named in conjunction with French physician Victor Charles Hanot).



Figure 12: Ottomar Ernst Felix Rosenbach.




Figure 13: Robert Rössle. Thanks to: Humboldt-Universität Berlin: <http://www.sammlungen.hu-berlin.de/dokumente/13197/>.

Rössle published over 300 medical papers, and was editor of 39 volumes of Virchow's *Archiv für Pathologische Anatomie und Physiologie und für Klinische Medizin* (now: *Virchows Archiv*). Today, the Robert-Rössle-Hospital and Tumor Institute is named in his honor. It is located at the Max-Delbrück-Center of Molecular Medicine at the Humboldt University of Berlin [18].

Rostan's Sign

Gangrene of the penis associated with small pox.

Léon Louis Rostan

French physician, 1790-1866 (Fig.14). He studied medicine in Marseilles and Paris. He was a disciple of Philippe Pinel, and for much of his professional career was associated with the Pitié-Salpêtrière Hospital in Paris.

In 1819 Rostan was the author of *Recherches sur le ramollissement du cerveau* (Researches on cerebral softening), in which he provided the first accurate description of spontaneous cerebral softening. He documented that the disorder was a specific anatomoclinic entity that was different from encephalitis and apoplexy. His findings were harshly criticised by followers of Broussais' teachings on physiological medicine, who claimed that brain softenings were the result of an inflammation process, and therefore should be depicted as encephalitis.

He also did extensive research of animal magnetism and somnambulism, and wrote a treatise on charlatanism for his graduate thesis. Rostan performed early studies on the classification of body types, using descriptive terms such as respiratory-cerebral, muscular and digestive in his analysis.

In 1845, he was elected a foreign member of the Royal Swedish Academy of Sciences [19].

Rothschild's Sign

Loss of hair from lateral third of eyebrows in hyperthyroidism [20].

Rumpel-Leede Sign

The appearance of minute subcutaneous haemorrhages below a bandage applied on the upper arm for ten minutes (Fig. 15). A sign of haemorrhages diathesis, capillary fragility, and scarlet fever [21]. Also known as Hechtsign.

Carl August Theodor Rumpel

German surgeon, 1862-1923. He was remembered for describing the Rumpel-Leede sign.

He received his doctorate in 1887 in Marburg and worked at the Hamburg-Eppendorf Hospital and took part in the fight against the cholera epidemic of 1892. He oversaw the building of the Barmbecker Krankenhaus in Hamburg, of which he became director in 1913.

With internist Alfred Kast, he was co-author of a patho-anatomical atlas titled: "Pathologisch-anatomische Tafeln nach frischen Präparaten mit erläuterndem anatomisch-klinischem" [22].




Figure 14: Léon Louis Rostan.

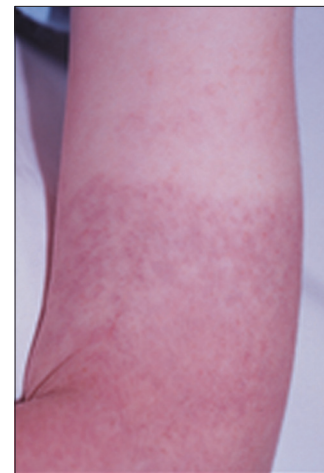


Figure 15: Rumpel-Leede sign.

Carle Stockbridge Leede

German-American physician, 1882-1964 (Fig. 16). Physician at the Children's Hospital in Seattle.

Russell's Sign

Lanugo, dry skin, and hand calluses, associated with purgino and bulimia [23].

Gerald Francis Morris Russell

British psychiatrist, born in 1928. In 1979 he published the first description of bulimia nervosa, and Russell's sign has been named after him. Russell was schooled at George Watson's College, Edinburgh, and he qualified as a medical doctor with BM BCH from the University of Edinburgh in 1950.



Figure 16: Carle Stockbridge Leede.

From 1971 to 1979 Russell was a professor and consultant psychiatrist at the Royal Free Hospital, London, and from 1979 to 1993 he was a professor at the Institute of Psychiatry at the Maudsley Hospital, London, where he set up an eating disorder unit, which has been named after him. From 1993 he has worked at Priory Hosp Hayes Grove, Bromley, Kent.

Russian Horse Sign

Glanders, a zoonotic bacterium *Burkholderia mallei*, that causes skin and mucous membrane lesions, as well pneumonia. The bacteria has been used as a biological warfare weapon in World Wars I and II [24].

ACKNOWLEDGEMENTS

Giuseppina Piccolo from Biblioteca di medicina veterinaria Via Celoria, 10 20133 Milano, Italy, for the information about Sebastiano Rivolta.

REFERENCES

1. Chiriac A, Brzezinski P, Chiriac AE, Pinteala T, Mares M, Moldovan C, et al. Why Is Tinea an Annular Lesion With Centrifugal Growth? *Int J Surg Pathol*. 2015;23:652-3.28.
2. Oishi T, Hanami Y, Kato Y, Otsuka M, Yamamoto T. Staphylococcal scalded skin syndrome mimicking toxic epidermal necrolysis in a healthy adult. *Our Dermatol Online*. 2013;4:347-8.
3. Baartmans MG, Dokter J, den Hollander JC, Kroon AA, Oranje AP. Use of skin substitute dressings in the treatment of staphylococcal scalded skin syndrome in neonates and young infants. *Neonatology*. 2011;100:9-13.

4. Oehme J. [Pioneers in pediatrics. Gottfried Ritter von Rittershain (1820-1883)]. *Kinderkrankenschwester*. 1990;9:334.
5. Wasylyszyn T, Borowska B. Cutaneous actinomycosis. A case report. *Our Dermatol Online*. 2016;7:450-1.
6. Theodorides J. Sebastiano Rivolta (1832-1893) parasitologiste et microbiologiste. *Hist Scien Med*. 1980;14:227-32.
7. Ankad BS, Dumble V, Sujana L. Dermoscopy of apocrine hydrocystoma: A first case report. *Our Dermatol Online*. 2015;6:334-6.
8. Gundalli S, Kolekar R, Kolekar A, Nandurkar V, Pai K, Nandurkar S. Study of basal cel carcinoma and its histopathological variants. *Our Dermatol Online*. 2015;6:399-403.
9. Brzezinski P, Passarini B, Nogueira A. Dermatology eponyms – phenomenon/sign –dictionary (C). *N Dermatol Online*. 2011;2:81-100.
10. Bourée P. Romana's sign. *Our Dermatol Online*. 2015;6:248.
11. Al Aboud K, Al Aboud A. Eponyms in the dermatology literature linked to Latin America. *Our Dermatol Online*. 2013;4(Suppl.1):405-8.
12. Farman AG, van Wyk CW, Staz J, Hugo M, Dreyer WP. Central papillary atrophy of the tongue. *Oral Surg Oral Med Oral Pathol*. 1977;43:48-58.
13. Dubey S, Merry P. Clinical vignette. Interstitial granulomatous dermatitis (Ackerman's syndrome) in SLE presenting with the 'rope sign'. *Rheumatology (Oxford)*. 2007;46:80.
14. Ramirez Soto MC. Facial Sporotrichosis in children from endemic area in Peru. *Our Dermatol Online*. 2013;4:237-40.
15. Raveendran KM, Viswanathan S. Typhoid Fever, Below the Belt. *J Clin Diagn Res*. 2016;10:OD12-3.
16. Temmen H. [Ottomar Rosenbach 1851-1907] and his contribution to psychotherapy]. *Acta Psychother Psychosom*. 1964;12:10-20.
17. Reusken C, Cleton N, Medonça Melo M, Visser C, GeurtsvanKessel C, Bloembergen P, et al. Ross River virus disease in two Dutch travellers returning from Australia, February to April 2015. *Euro Surveill*. 2015;20.pii:21200.
18. Schlag PM. [Hans Gummel on the 30th anniversary of his death. 1954-1973 chief surgeon and director of the Robert-Rössle Clinic]. *Chirurg*. 2004;75:300-1.
19. Poirier J, Chretien F. Léon Rostan (1790-1866). *J Neurol*. 2000;247:659-60.
20. Jordan DR, Ahuja N, Khouri L. Eyelash loss associated with hyperthyroidism. *Ophthalm Plast Reconstr Surg*. 2002;18:219-22.
21. Brzezinski P, Pessoa L, Galvão V, Barja Lopez JM, Adaskevich UP, Niamba PA, et al. Dermatology Eponyms – sign –Lexicon (H). *Our Dermatol Online*. 2013;4:130-43.
22. Pieper C. Die Sozialstruktur der Chefärzte des Allgemeinen Krankenhauses Hamburg-Barmbek 1913 bis 1945. LIT Verlag Münster, 2003.
23. Young J, Henderson MC, Thompson GR 3rd. Anorexia nervosa: Russell's sign with concurrent tetany. *J Gen Intern Med*. 2011;26:668.
24. Jones BV. Glanders and history. *Vet Rec*. 2016;178:664.

Copyright by Piotr Brzezinski, et al. This is an open access article distributed under the terms of the Creative Commons Attribution License, which permits unrestricted use, distribution, and reproduction in any medium, provided the original author and source are credited.
Source of Support: Nil, **Conflict of Interest:** None declared.



O u r D e r m a t o l o g y O n l i n e

w w w . o d e r m a t o l . c o m

1.2017 (09.January.2017)