

Pediatric application of modulated electro-hyperthermia (mEHT)

Sun-Young Lee¹

¹Chonbuk National University Hospital,
Jeonbuk, South Korea

Citation: Lee S.Y. (2020): Pediatric application of modulated electro-hyperthermia (mEHT), *Oncothermia Journal* 29: 25 – 59,

www.oncotherm.com/sites/oncotherm/files/2021-02/Lee_Pediatric

Abstract

Introduction: Pediatric oncology has numerous tasks that are difficult to handle with conventional therapies. Most of the cancers that are common in adults differ from those seen in children and adolescents. In the last three decades, mortality from pediatric cancers has been cut in half, which is a remarkable result, but many cases are difficult and challenging and often do not have conventional protocols.

Method: I will show several cases successfully treated with a new treatment modality: modulated electro-hyperthermia (mEHT, trade name of oncothermia). When conventional therapies were not effective enough, mEHT was applied as a complementary treatment to existing protocols. We followed the case through various imaging facilities (CT, MRI, PET) as well as laboratory controls and measurement of tumor markers.

Results: I have collected 8 characteristic cases, 5 boys and 3 girls, with severe neoplasms. The age of the children ranged from 1 to 16 years. Treated tumors cover a wide spectrum of cases, including neuroblastoma, brain stem cell tumor, germ cell tumor, B cell lymphoma, Hodgkin lymphoma, and desmoplastic small cell tumor. The children received intensive pretreatments, underwent surgery when possible, and were given appropriate adjuvant chemotherapy and radiation therapy. At the end of a long follow-up (various periods of time), three children have no evidence of disease, one has stable disease, and one died. Two children were transferred to another hospital, with no data available on their current condition. The children tolerated the treatments well, no notable adverse effects were observed.

Discussion: I will show the details of the cases in my presentation. The main guide we followed in therapy was to focus on the child rather than looking at the tumors only. This complex approach was in harmony with our general philosophy: change from tumor-oriented to patient-oriented methods.

Conclusion: These case reports show the feasibility of applying mEHT to pediatric tumors in the cases studied, of children from 1 year up to 16 years.




38th Conference of the International Clinical Hyperthermia Society
November 5, 2020



Hyperthermia for pediatric cancer

Department of Radiation Oncology
Chonbuk National University Hospital
LEE SUN YOUNG

 대한민국 의료의 또 하나의 중심



Introduction

1. Treatment of pediatric cancer
2. Palliative aim hyperthermia
 - 4 patients
brain stem tumor, germ cell tumor,
neuroblastoma
dermoplastic small cell tumor,
3. Definitive aim hyperthermia
 - 4 patients
neuroblastoma, lymphoma (3)
4. Conclusions

Pediatric cancer

- Pediatric oncology has numerous tasks that are difficult to handle with conventional therapies.
- Most of the cancers that are common in adults differ from those seen in children and adolescents.
- In the last three decades, mortality from pediatric cancers has been cut in half, which is a remarkable result, but many cases are difficult and challenging and often do not have conventional protocols.

Pediatric cancer

- treatment methods
 - : surgery, chemotherapy, radiotherapy so on
- In particular, in the case of radiation therapy for symptom relief purposes, it is difficult to perform if the patient is in poor condition.
 - : Reduce patient compliance
 - : If the child does not cooperate with the treatment at each treatment, he should sleep with a sleeping drug.
 - : Radiation treatment side effects were also not negligible.

Pediatric cancer

- Hyperthermia

- : Treatment that does not need to sedation the patient
- : The patient's emotions are stabilized during treatment as it can be accompanied by a parent.
- : It is an optimized treatment that can be used for pain control purposes without side effects.

No. 1

- 4/M
- brain stem tumor (pontine glioma)
- previous treatment
 - : CTx (CCG9991A)
 - RTx (50Gy)
- general status before hyperthermia
 - : progressive disease
- symptoms
 - : severe headache, nausea, vomiting, anorexia

No. 1

-MRI (3/14/2013) before hyperthermia

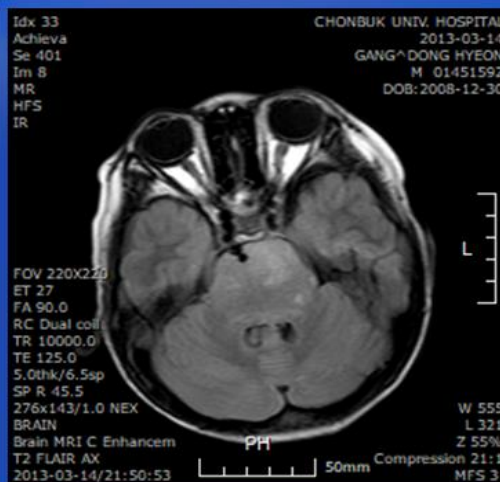
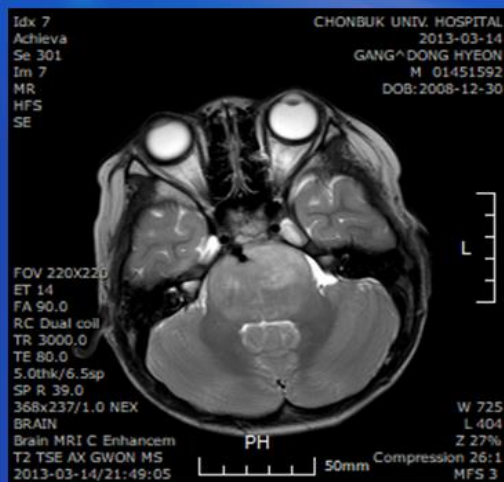
:Pons show a high signal at T2WI, and a mass that does not enhance contrast is still observed,

and is still extended to prepontine.

:Compared to the 2013-January image, there was no significant change in the size, and compared to the 2012-October image, both obstructive hydrocephalus and basilar artery encasement were improved.

No. 1

-MRI (3/14/2013) before hyperthermia



No. 1

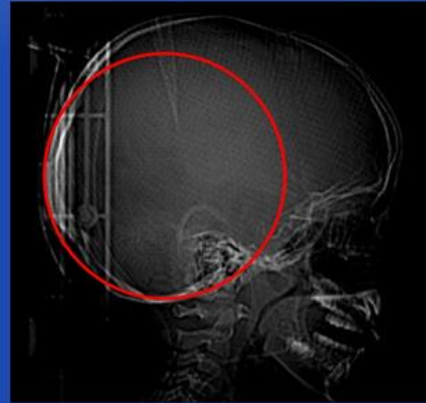
-hyperthermia

: **decubitus position**

: **brain (electrode 20x20 cm)**

: **no sedation**

: **36 sessions**



No. 1

-MRI, after HT (16/7/2013)

: **The overall size of the expansile tumor mass lesion on the pons is slightly reduced.**

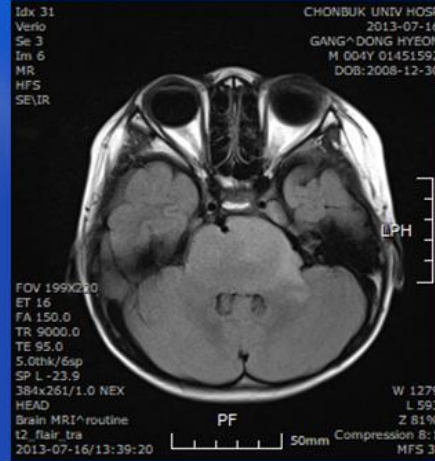
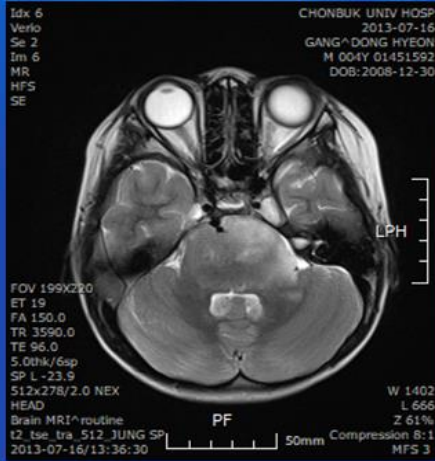
: **However, microhemorrhage is newly observed**

inside the mass in the SWI image, and microhemorrhage is also observed in the Rt posterior temporal lobe.

: **No mass enhancement and no hydrocephalus findings.**

No. 1

-MRI, after HT (16/7/2013)



No. 1

- : decreased tumor volume
- decreased symptoms (> 50%)
- decreased pain killer drugs
- : no complications related hyperthermia
- : last follow up status death
- : survival periods 62 months

No. 2

-2/F

-germ cell tumor (york cell tumor - coccyx)

-previous treatment

: CTx (CCG8882/Cis VAB/POG-ICE/ VELP/T-ICE/Taxo-VBL+IRT+Oxel so on)

RTx (5040Gy at coccyx)

surgical excision

-general status before hyperthermia

: progressive disease

-symptoms

: severe pelvic pain, nausea, vomiting, anorexia

No. 2

-MRI (28/6/2010) before hyperthermia

: **Pelvic cavity mass: Probably malignant tumor, most likely**

: **The main lesion is in the presacral area, pushing the rectum forward**

: **The boundary with Rectum is relatively clear.**

: **The mass destroys and encases parts of lower sacrum and coccyx bone**

: **Some masses infiltrate from the sacrum level to the central spinal canal and surround the sacrum and coccyx.**

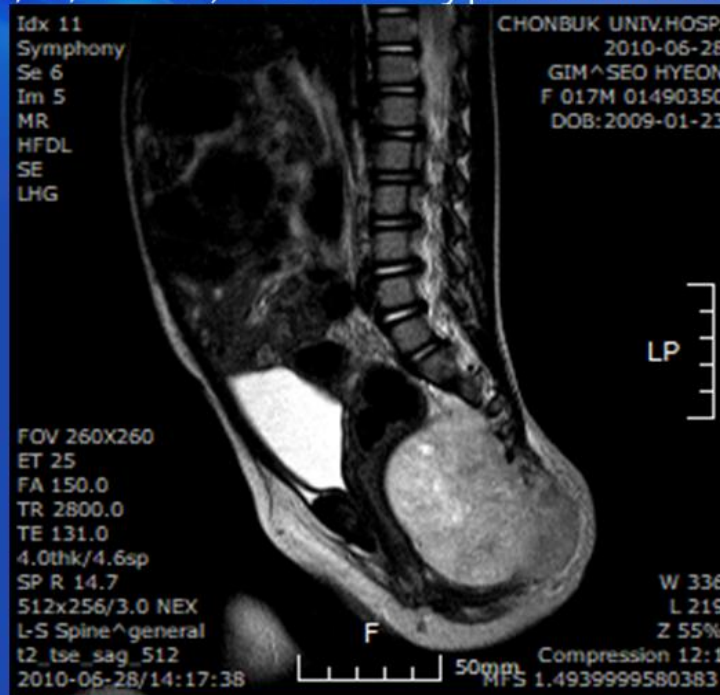
: **Plain radiography also shows bone destruction**

: **When a contrast agent is given, it enhances the contrast and contains several cystic spaces inside, and some bleeding is also accompanied.**

: **Some masses in the Rt side are infiltrated toward the gluteus muscle.**

No. 2

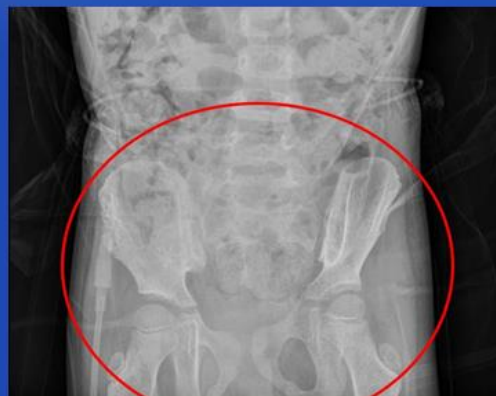-MRI (28/6/2010) before hyperthermia



No. 2

-hyperthermia

- : prone position
- : pelvis (electrode 20x20 cm)
- : no sedation
- : 9 sessions



No. 2

-treatment results

: could not perform image examination because very poor general condition and could not sedation.

: decreased symptoms (> 30%)
decreased pain killer drugs

: no complications related hyperthermia

: last follow up status
death

: survival periods
40 months

No. 3

-2/M

-neuroblastoma (Rt adrenal neuroblastoma)

-previous treatment

: CTx (Cytosan, Topotecan, VP-16, Ifosfamide,
carboplatin)

surgical resection

palliative radiotherapy at Lt lower leg (22Gy)

-general status before hyperthermia

: progressive disease (Lt tibia/fibula/Lt inguinal
area)

-symptoms

: severe pain, anorexia

No. 3

-leg MRI, before HT (31/12/2012)

: Compared to the October 2012 MR image,

tumors grew much more in the bone marrow space and in the subperiosteal space.

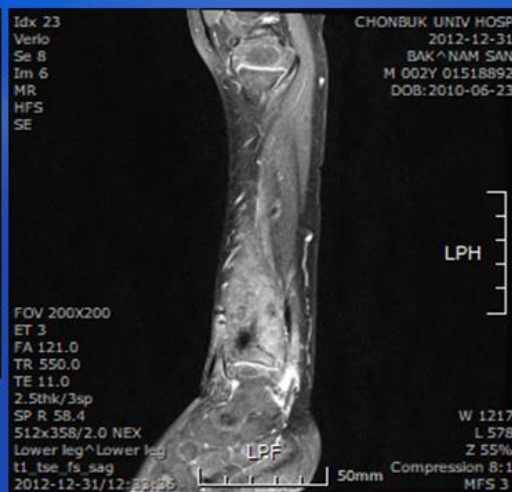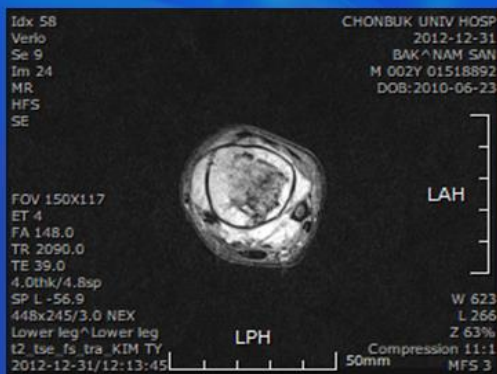
: The lesion is spread upward from the distal tibia plafond level to about 9cm, and the periosteum is generally lifted

and the mass is filled.

: Signal intensity of the mass is the same as that of normal tumor

No. 3

-leg MRI, before HT (31/12/2012)



No. 3

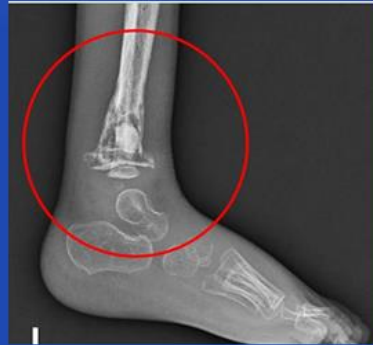-hyperthermia

: **sitting position**

: **Lt lower leg (electrode 20x20 cm)**

: **no sedation**

: **28 sessions**



No. 3

-treatment results

: could not perform image examination because very poor general condition and could not sedation.

: decreased symptoms (> 60%)
decreased pain killer drugs

: no complications related hyperthermia

: last follow up status
death

: survival periods
36 months

No. 4

-15/M

-desmoplastic small cell tumor (abdomen)

-previous treatment

: CTx (ICE/IE/VDC/VAC/irinotecan+TMZ so on)
palliative colostomy

-general status before hyperthermia

: progressive disease

-symptoms

: severe abdomen/pelvic pain, nausea,
vomiting, anorexia

No. 4

- abdomen CT (14/08/2018) before HT

: **Clinical information: Known Desmoplastic small round cell tumor,**

2016-11 Colostomy state Due to bowel strangulation

: **Scalloping masses are observed around Liver, periportal hilum, and**

CBD, accompanied by diffuse biliary dilatation.

: **Several low attenuated lymph nodes are enlarged in the periportal,**

portocaval, aortocaval, and paraaortic areas.

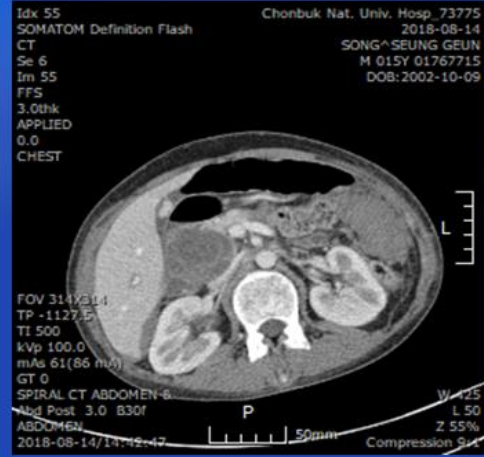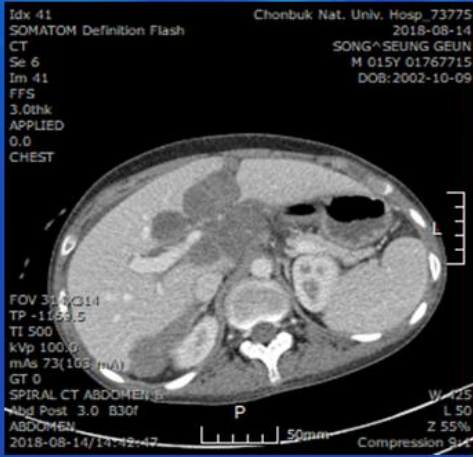
: **Masses within 4cm with nodularity are scattered throughout the peritoneum, and peritoneal fluid collection is observed.**

: **There is no mass that distinguishes pancreas, adrenal gland, kidney, spleen itself.**

: **There is a dominant fluid collection in the Rt subpleural space.**

No. 4

- abdomen CT (14/08/2018) before HT



No. 4

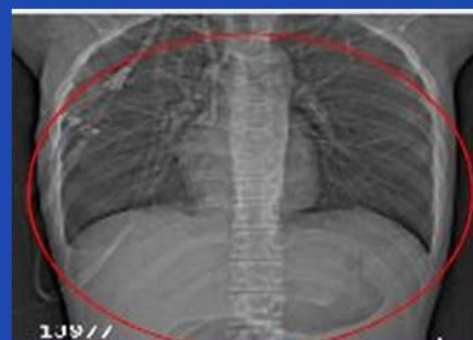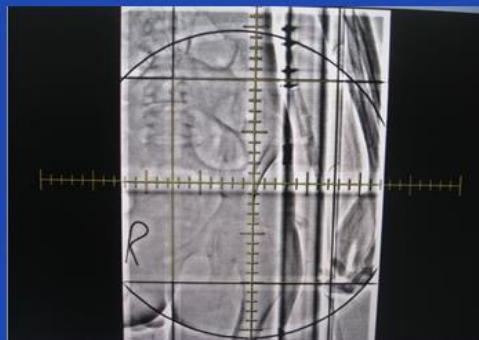
-hyperthermia

: supine position

: chest/ abdomen (electrode 30x30 cm)

: no sedation

: 29 sessions



No. 4

-abdomen CT (16/4/2019) after HT

: Clinical information: Known Desmoplastic small round cell tumor, 2016-11 Colostomy state Due to bowel strangulation

: Metastatic lesions up to 2.7cm in size are scattered inside the Liver, and some of them are conglomerated.

: Around the periportal hilum and CBD, scalloping masses with a size of up to 6 cm or less are observed, and both sizes and numbers are increased compared to previous tests.

: Several low attenuated lymph nodes are enlarged in the periportal, portocaval, aortocaval, and paraaortic areas.

: There is nodularity throughout the peritoneum, and the size and extent increase compared to the previous one.

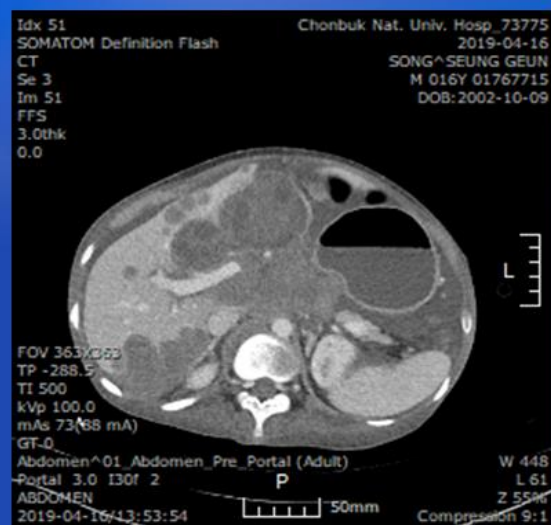
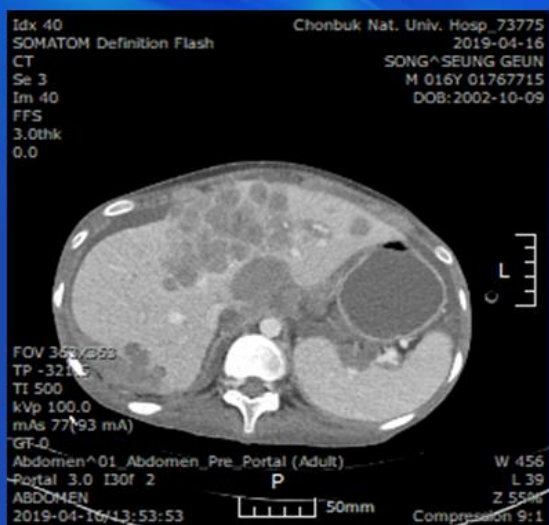
: It is judged that these masses in the mesentery are aggregated and pressed or adhered to the surrounding structures.

: Due to this, the jejunum and duodenum showed diffuse dilatation from the upper part of the ileostomy.

: Large amount of fluid collection in the Lt pleural space

No. 4

-abdomen CT (16/4/2019) after HT



No. 4

-treatment results

- : more aggravation tumor
- : decreased symptoms (> 30%)
decreased pain killer drugs
- : no complications related hyperthermia
- : last follow up status
death
- : survival periods
36 months

Palliative aim hyperthermia

1. Can be usefully used for treatment in the absence of other alternative treatment.
2. In the case of treatment that requires sedation, it is a treatment that can be performed when the patient does not sedate.
3. Improves the quality of life of the patient by reducing pain.
4. No obvious side effects.
5. Helps to stabilize the patients mind and body as treatment can be carried out with a patient.

Pediatric cancer

- definitive aim
: surgery/chemotherapy/radiotherapy so on
- In particular, in the case of lymphatic cancer, radiation therapy is often performed after chemotherapy.
- At this time, since the children are in the growing stage, chronic side effects such as growth retardation, metabolic disease due to hormonal imbalance, and bone growth delay occur depending on the irradiated area.
- As the average survival periods of patients increases, various treatments are being tried to reduce chronic side effects.

No. 5

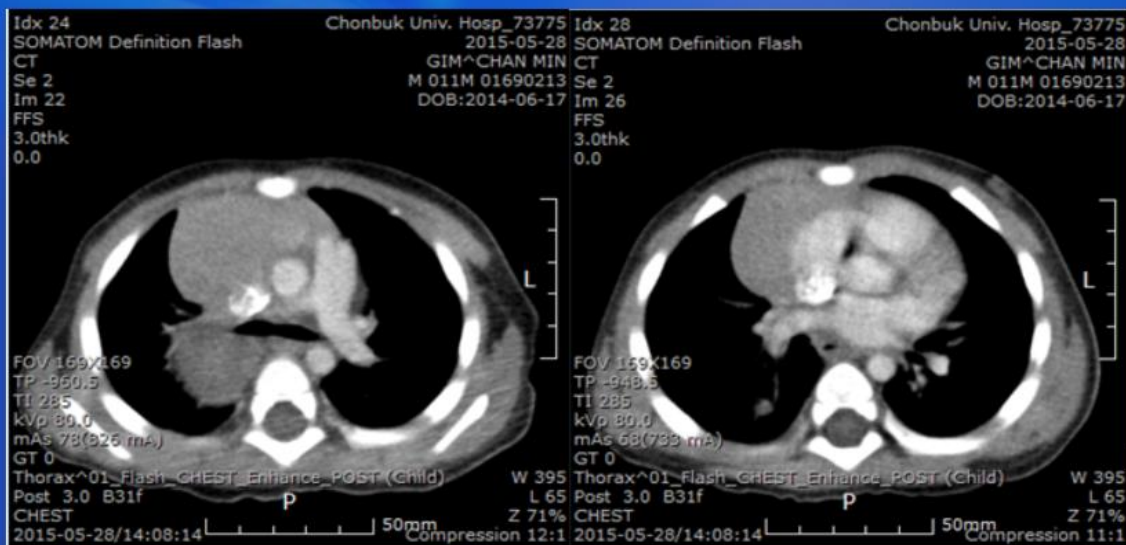
- 1/M
- neuroblastoma (ganglioblastoma – chest)
- previous treatment
: CTx (CEDE+ICE/Cis-retinoic acid)
surgical excision
- general status before hyperthermia
: stable disease
- symptoms
: nausea, vomiting, anorexia

No. 5

- chest CT, (20/05/2015), at first diagnosis
 - : Both thyroid gland and both neck showed no abnormal findings.
 - : A homogenous enhancing mass like lesion of about 5 cm in size on the anterior mediastinum was judged as thymus and as reactive hyperplasia. There is an enhancing mass of about 4cm in Superoposteior mediastinum, and it is judged as a neurogenic tumor such as neuroblastoma.
 - : No evidence of tracheal mass or stenosis.
 - : There is a nodular consolidation of about 8mm in the RUL posterior segment, and there is GGO around it.
 - : There were no abnormal findings in both pleural space and bony thorax.

No. 5

- chest CT, (20/05/2015), at first diagnosis



No. 5

-chest CT, (20/10/2015), before hyperthermia

: Both thyroid gland and both neck showed no abnormal findings.

: Thymus reactive hyperplasia approximately 3 cm in size in the anterior mediastinum currently shows a reduction in size to 2.5 cm. Known neuroblastoma of about 3.5*2cm in Superoposteior mediastinum is currently showing a decrease in size to 3.3*1.8cm.

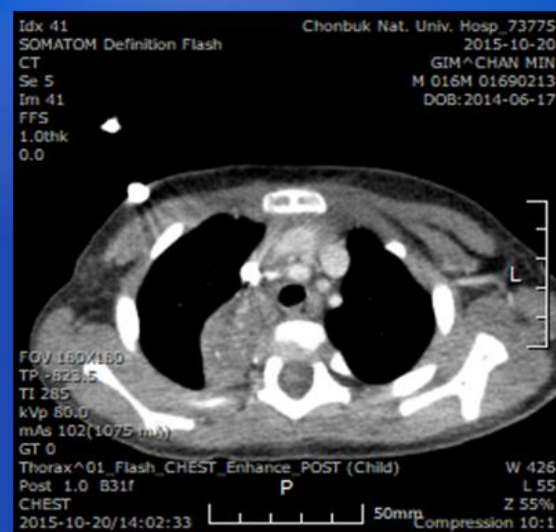
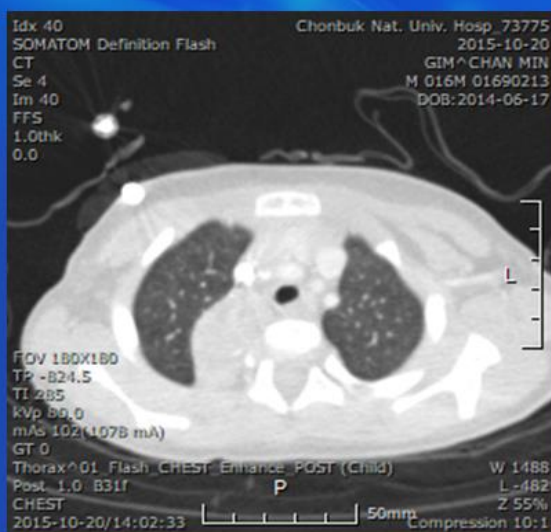
: No evidence of tracheal mass or stenosis.

: Nodular consolidation(2015-05-28) of about 8mm in the RUL posterior segment is not clearly visible.

: No abnormal findings in both pleural space and bony thorax

No. 5

-chest CT, (20/10/2015), before hyperthermia



No. 5

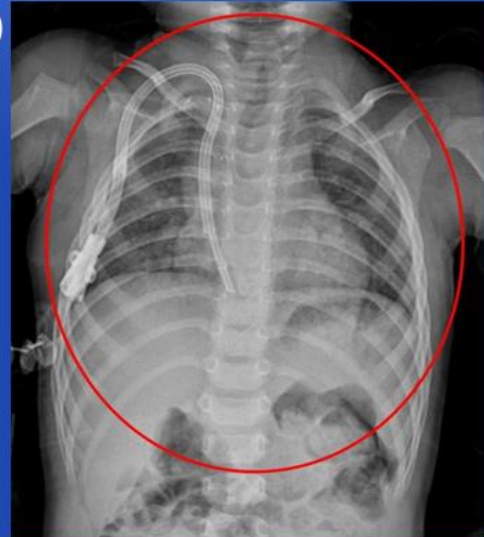-hyperthermia

: **supine position**

: **chest (electrode 20x20 cm)**

: **no sedation**

: **12 sessions**



No. 5

-chest CT, (19/03/2016), after hyperthermia

: **Thymus reactive hyperplasia with a size of about 2.5 cm in the anterior mediastinum showed an increase in size to 3.5 cm, but it was judged as a normal range for the age of the patient.**

: **In Superoposteior mediastinum, known neuroblastoma of about 3.5*2cm in size was markedly reduced and not seen.**

: **No evidence of tracheal mass or stenosis.**

: **Nodular consolidation(2015-05-28) of about 8mm in the RUL posterior segment is currently not clearly visible.**

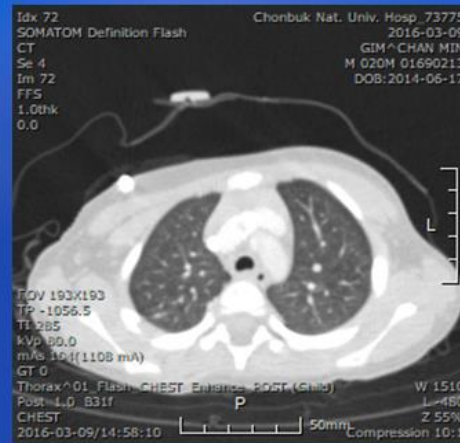
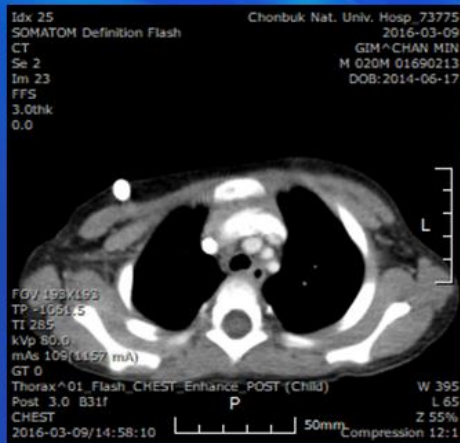
: **No abnormal findings in both pleural space and bony thorax**

[CONCLUSION]

1. Known neuroblastoma - Complete remission compared with 2015-05-28

No. 5

-chest CT, (19/03/2016), after hyperthermia



No. 5

-treatment results

- : complete remission after hyperthermia
- : no complications related hyperthermia
- : last follow up status
alive
- no evidence without disease
- : survival periods
60 months

No. 6

-11/F

-Hodgkin's lymphoma (diffuse large B cell lymphoma, tonsil/both neck LN)

-previous treatment

: CTx (R-CHOP)

surgical excision (tonsilectomy)

-general status before hyperthermia

: stable disease

-symptoms

: nausea, vomiting, anorexia

No. 6

-PET/CT (08/12/2016, at diagnosis)

<Head & Neck>

: Both palatine tonsillectomy state, showing increased intake of intense FDG (Rt<Lt) in both tonsillar beds. Soft tissue thickening suspected in Lt tonsillar bed.

: There are enlarged LNs with mild FDG intake at both cervical level II. F/U required.

: Both thyroid gland observed small.

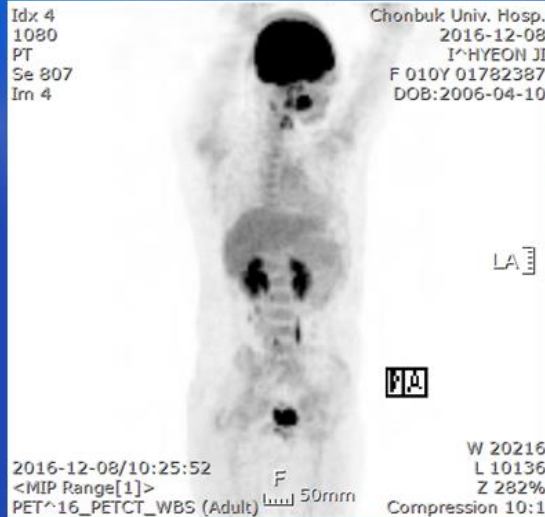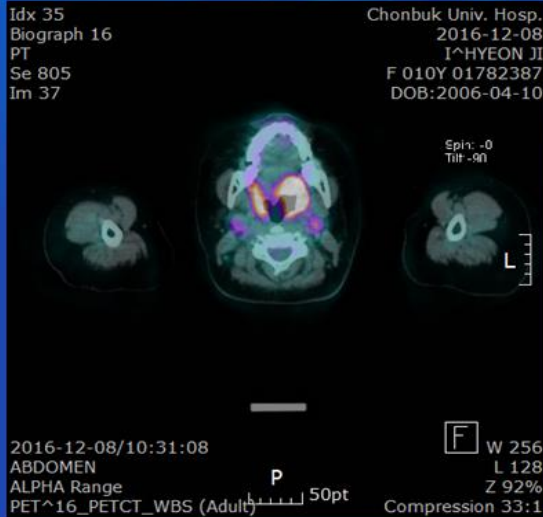
<Chest> No significant increase in FDG intake was observed in lung parenchyme or mediastinum.

<Abdomen & pelvis> - Nonspecific finding

<Bone, Joint & Soft tissue> - Nonspecific finding

No. 6

-PET/CT (08/12/2016, at diagnosis)



No. 6

-PET/CT (25/04/2017, before hyperthermia)

<Head & Neck>

: Both palatine tonsillectomy state, no significant FDG intake. Compared with the previous FDG PET/CT (2016.12.08), the size and metabolism were significantly reduced.

: Hyper-metabolism in the postcricoid portion and vocal cord seems to have a high possibility of physiologic uptake by vocalization.

: Both thyroid gland observed small.

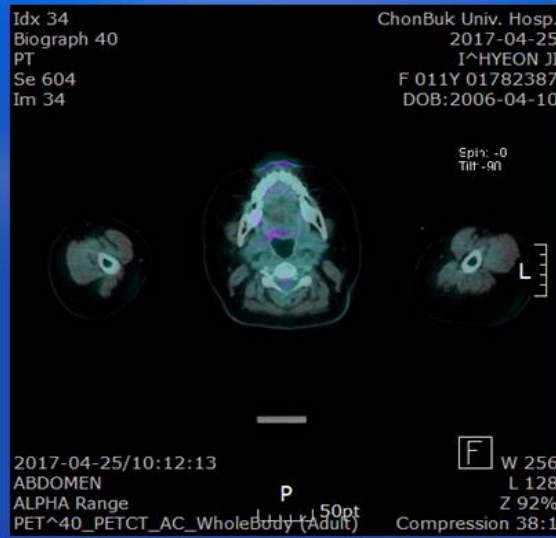
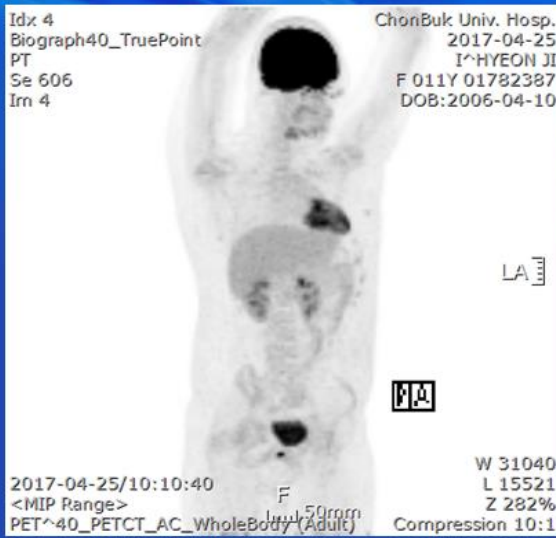<Chest> No significant increase in FDG intake was observed in lung parenchyme or mediastinum.

<Abdomen & pelvis> - Nonspecific finding

<Bone, Joint & Soft tissue> - Nonspecific finding

No. 6

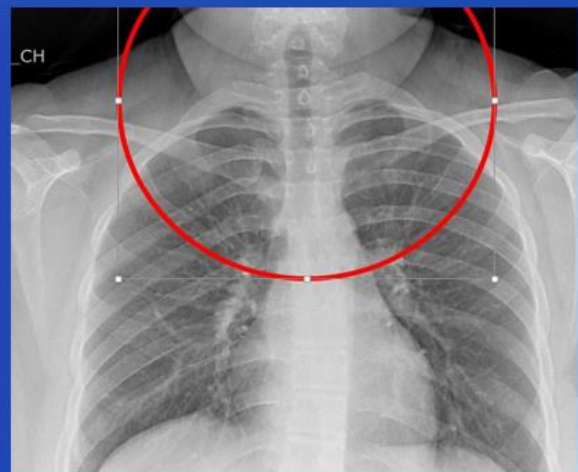
-PET/CT (25/04/2017, before hyperthermia)



No. 6

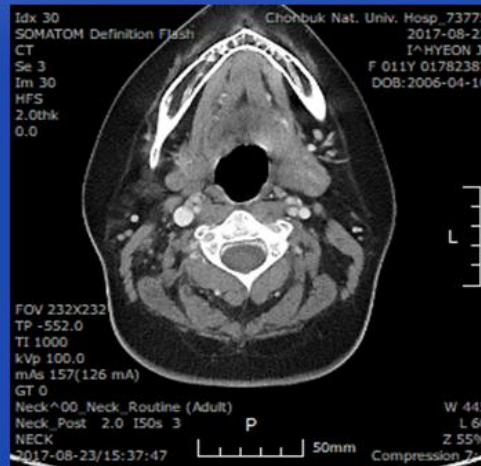
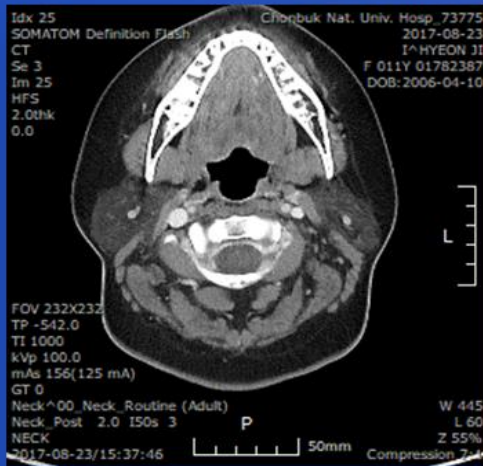-hyperthermia

- : supine position
- : neck (electrode 20x20 cm)
- : no sedation
- : 24 sessions



No. 6

- neck CT (23/08/2017), after HT
- : Lymph node enlargement not visible
- : Other than that, no abnormality was found on the neck.



No. 6

- treatment results
- : complete remission after hyperthermia
- : no complications related hyperthermia
- : last follow up status
alive
no evidence without disease
- : survival periods
42 months

No. 7

-16/M

-Hodgkin's lymphoma (mixed cellularity,
neck/axillary/mediastinum/spleen)

-previous treatment

: CTx (OEPA-CDPDAC)

-general status before hyperthermia

: stable disease

-symptoms

: nausea, vomiting, anorexia

No. 7

PET/CT (05/02/2018), at diagnosis,

<Lymph node>

There are multiple FDG-avid enlarged LNs in Rt supraclavicular, Rt axilla, and mediastinum, and FDG-avid lesions in subcarina~posterior mediastinum extend to T9 level.

<Head & Neck> Nonspecific finding

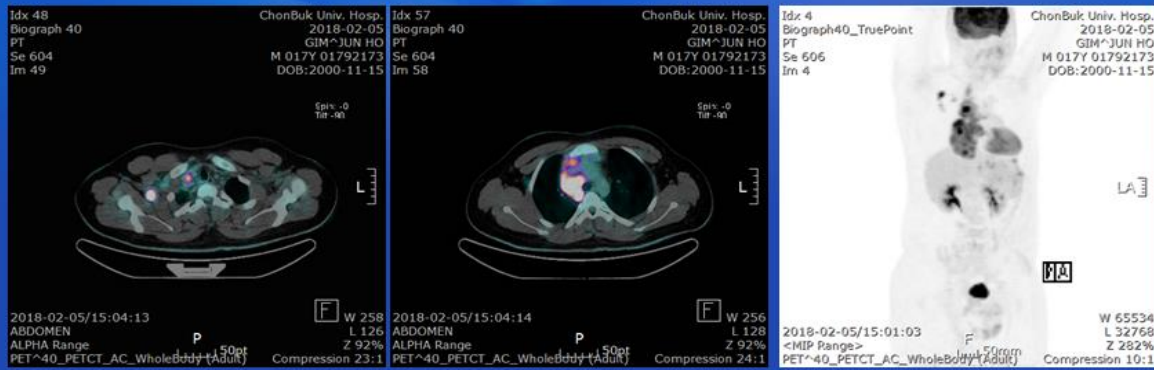
<Chest> Nonspecific finding

<Abdomen & pelvis> Spleen has multifocal FDG-avidities.

<Bone, Joint & Soft tissue> Nonspecific finding

No. 7

PET/CT (05/02/2018), at diagnosis,



No. 7

PET/CT (05/04/2018), before HT

<Lymph node>

Multiple FDG-avid LNs of Rt supraclavicular, Rt axilla, and mediastinum, which were previously observed in FDG PET/CT

(2018.02.05), significantly decreased in size and metabolism. Most are not observed and remain tiny to small LNs showing some minimal metabolism.

<Head & Neck> - Nonspecific finding

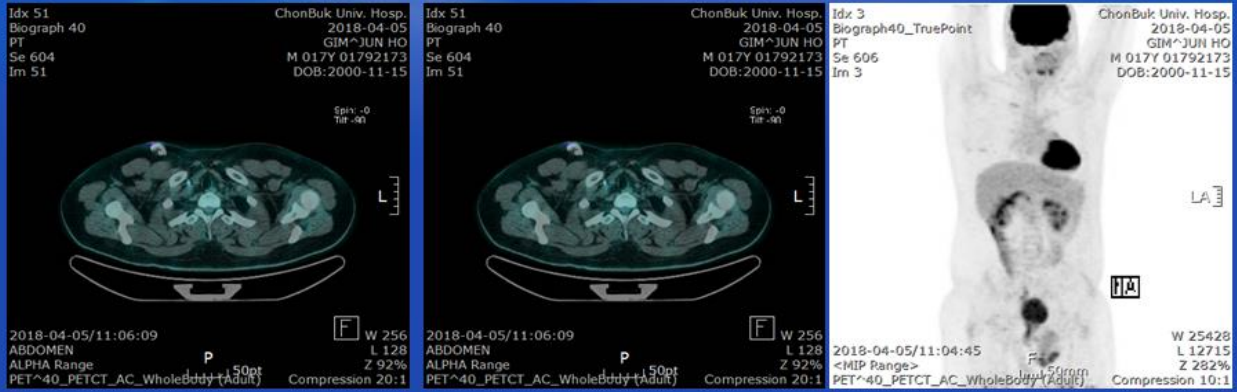<Chest> - Nonspecific finding

<Abdomen & pelvis> Spleen's multifocal FDG-avid lesions were no longer observed. Colon has diffuse physiologic uptake.

<Bone, Joint & Soft tissue> - Nonspecific finding

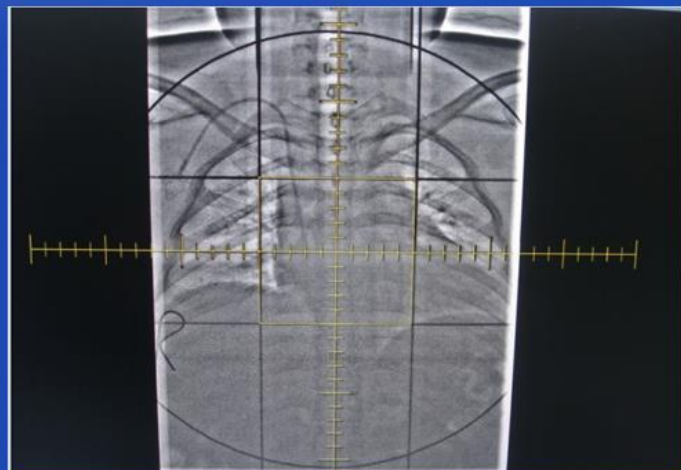
No. 7

PET/CT (05/04/2018), before HT



No. 7

- hyperthermia
- : supine position
- : neck and mediastinum (electrode 30x30 cm)
- : no sedation
- : 24 sessions



No. 7

PET/CT (19/11/2018), after HT

<Lymph node> Significant FDG-avid LN in Rt supraclavicular, Rt axilla, and mediastinum, which were the lymphoma involvement sites, were no longer observed. There are some tiny to small LN and no significant FDG intake.

<Head & Neck> - Nonspecific finding

<Chest> - Nonspecific finding

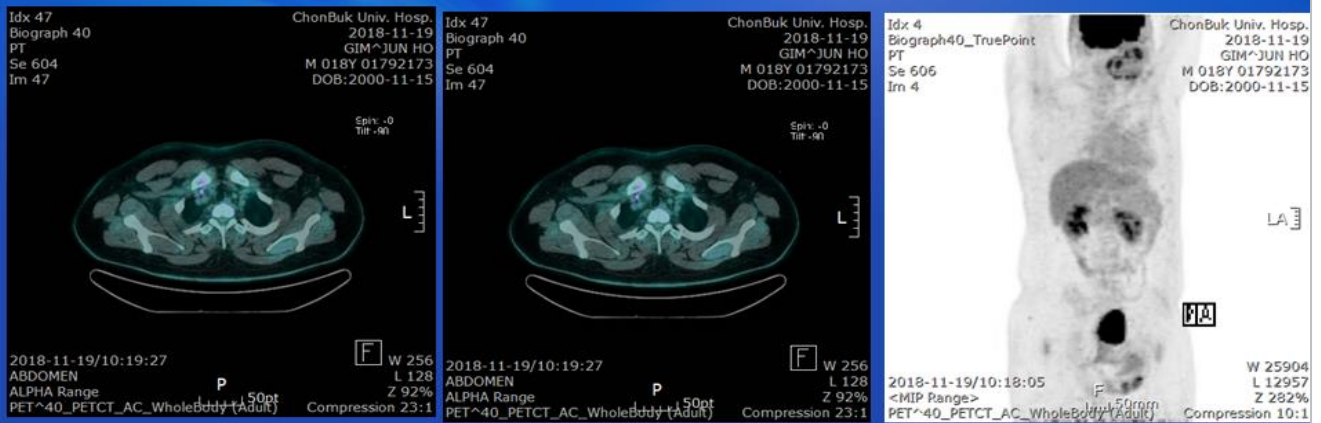<Abdomen & pelvis> Spleen multifocal FDG-avid lesions were no longer observed.

<Bone, Joint & Soft tissue> - Nonspecific finding

[CONCLUSION] No demonstrable FDG-avid lesion

No. 7

PET/CT (19/11/2018), after HT



No. 7

-treatment results

: complete remission after hyperthermia

: no complications related hyperthermia

: last follow up status

alive

no evidence without disease

: survival periods

27 months

No. 8

-15/F

-Hodgkin's lymphoma (lymphocyte rich classic, neck)

-previous treatment

: CTx (OEPA-CDPDAC)

-general status before hyperthermia

: stable disease

-symptoms

: nausea, vomiting, anorexia

No. 8

PET/CT (08/07/2020), before HT

<Head & Neck> Compared to the previous FDG PET/CT (2020.03.23), LNs in Lt cervical level II~V, Rt cervical level II, & Lt supraclavicular area were further reduced in size, resulting in tiny to small LNs suspected of some minimal metabolism.

<Chest> No significant increase in FDG intake was observed in lung parenchyme or mediastinum.

<Abdomen & pelvis> nonspecific finding

<Bone, Joint & Soft tissue> nonspecific finding

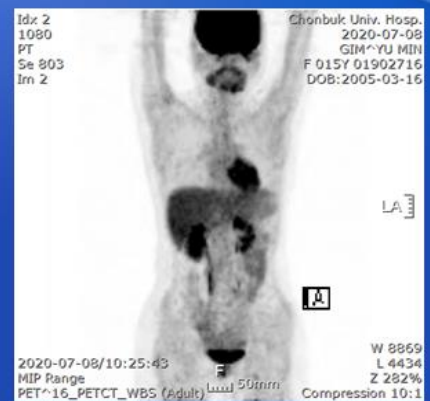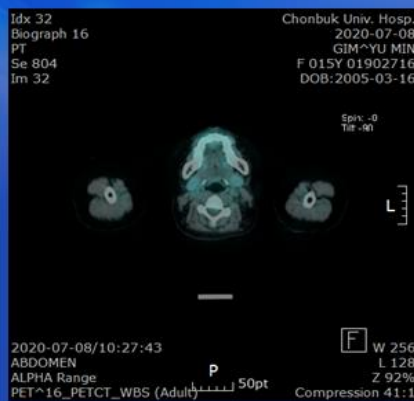
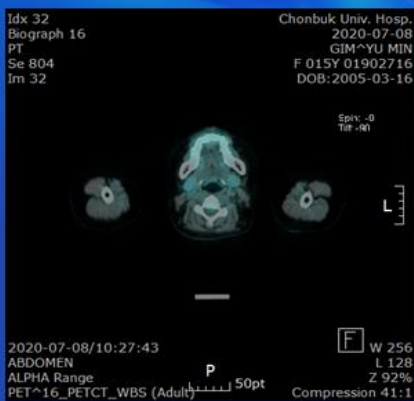
[CONCLUSION]

Known lymphoma involving LNs in Lt cervical level II~V, Rt cervical level II, & Lt supraclavicular areas

=> decreased size, compared with previous FDG PET/CT(2020.03.23)

No. 8

PET/CT (08/07/2020), before HT



No. 8

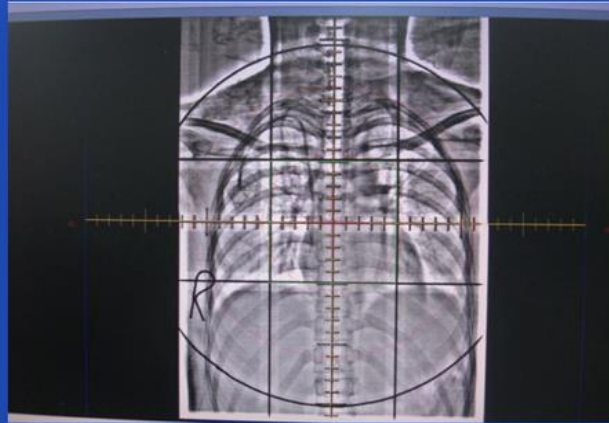
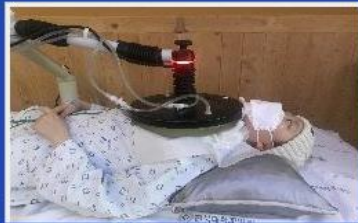-hyperthermia

: **supine position**

: **neck and mediastinum (electrode 30x30 cm)**

: **no sedation**

: **24 sessions**



No. 8

-treatment results

: not evaluate radiologic examination

: no complications related hyperthermia

: last follow up status
alive

: survival periods
10 months

Conclusions

1. With the development of anticancer chemicals these days, the average survival time of childhood cancer patients is also increasing.
2. Previously, the purpose of treatment was to remove the mass, but the recent treatment focuses not only on the removal of the mass, but also on the reduction of acute and chronic side effects.

Conclusions

3. In the case of pain relief purposes, if it is difficult to calm the patient or cooperation is difficult, an alternative to radiation therapy can be tried.
4. Can be used for pain control-Helps improve quality of life.
5. Since there is no specific side effect, it can be tried if the existing treatment is refused due to concerns of chronic side effects.