

Bone Tumors - Differential diagnosis

by Henk Jan van der Woude and Robin Smithuis

Radiology department of the Onze Lieve Vrouwe Gasthuis, Amsterdam and the Rijnland hospital, Leiderdorp, the Netherlands

Systematic Approach

- Zone of transition
- Age
- Periosteal reaction
- Cortical destruction
- Location: epiphysis - metaphysis - diaphysis
- Location: centric - eccentric - juxtacortical
- Matrix
- Polyostotic or multiple lesions

Bone tumors in the spine

Bone tumors in the foot

Printing of the article

Publicationdate: 10-4-2010

In this article we will discuss a systematic approach to the differential diagnosis of bone tumors and tumor-like lesions.

The differential diagnosis mostly depends on the review of the conventional radiographs and the age of the patient.

Abbreviations used:

- ABC = Aneurysmal bone cyst
- CMF = Chondromyxoid fibroma
- EG = Eosinophilic Granuloma
- GCT = Giant cell tumour
- FD = Fibrous dysplasia
- HPT = Hyperparathyroidism with Brown tumor
- NOF = Non Ossifying Fibroma
- SBC = Simple Bone Cyst

Systematic Approach

The most important determinators in the analysis of a potential bone tumor are:

1. The morphology of the bone lesion on a plain radiograph
 - Well-defined osteolytic
 - ill-defined osteolytic
 - Sclerotic
2. The age of the patient

It is important to realize that the plain radiograph is the most useful examination for differentiating these lesions.

CT and MRI are only helpful in selected cases.

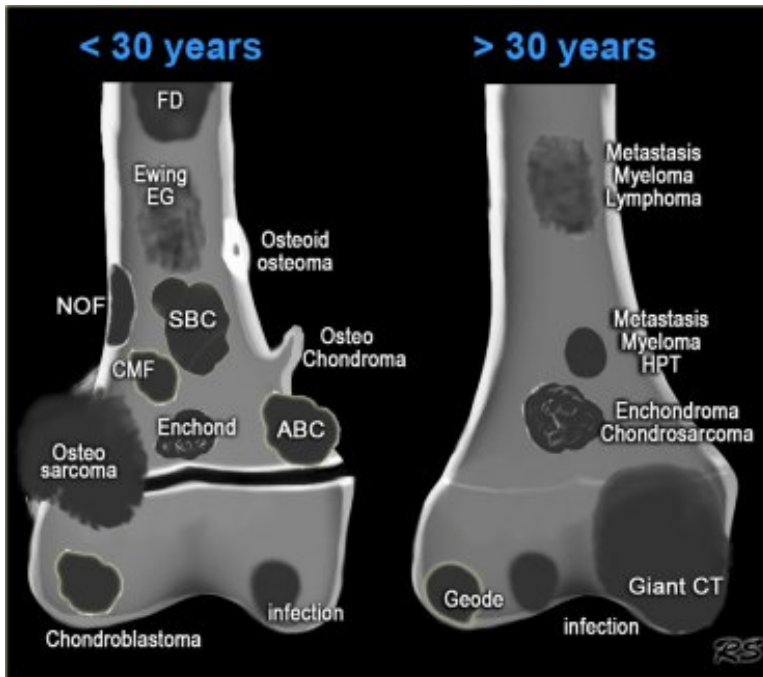
In this article there are links to other articles about bone tumors.

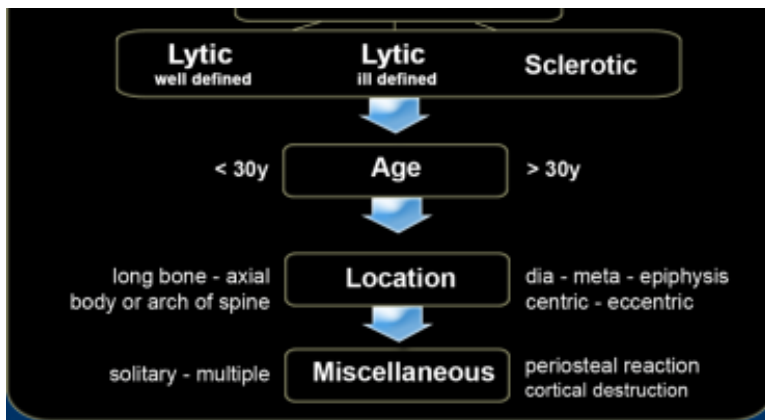
- *well-defined osteolytic bone tumors*
- *ill-defined osteolytic bone tumors*
- *Bone tumors A-G*

Most bone tumors are osteolytic.

The most reliable indicator in determining whether these lesions are benign or malignant is the zone of transition between the lesion and the adjacent normal bone (1).

Once we have decided whether a bone lesion is sclerotic or osteolytic and whether it has a well-





Age	Well-defined	ill-defined	Sclerotic
0 - 10	EG SBC	EG - Ewing Osteosarcoma Leukemia	Osteosarcoma
10 - 20	NOF, Osteoblast Fibr dysplasia EG SBC ABC Chondroblast CMF	Ewing EG Osteosarcoma	Osteosarcoma Fibr dysplasia EG Osteoid osteo Osteoblastoma
20 - 40	Giant CT Enchondroma Chondrosarcoma (low grade) HPT - Brown tumor Osteblastoma	Giant CT	Enchondroma Osteoma Bone island Parosteal Osteosar Healed lesions: - NOF, EG - SBC, ABC - Chondroblast
40+	Metastases Myeloma Geode	Metastases Myeloma Chondrosarcoma (high grade)	Metastases Bone island
All ages	Infection	Infection	Infection

In patients less than 30 years of age a narrow zone of transition indicates benignancy

sclerotic or osteolytic and whether it has a well defined or ill-defined margins, the next question should be: how old is the patient? Age is the most important clinical clue. Finally other clues need to be considered, such as a lesion's localization within the skeleton and within the bone, any periosteal reaction, cortical destruction, matrix calcifications, etc.

In the table on the left the morphology of a bone lesion is combined with the age of the patient.

Notice the following:

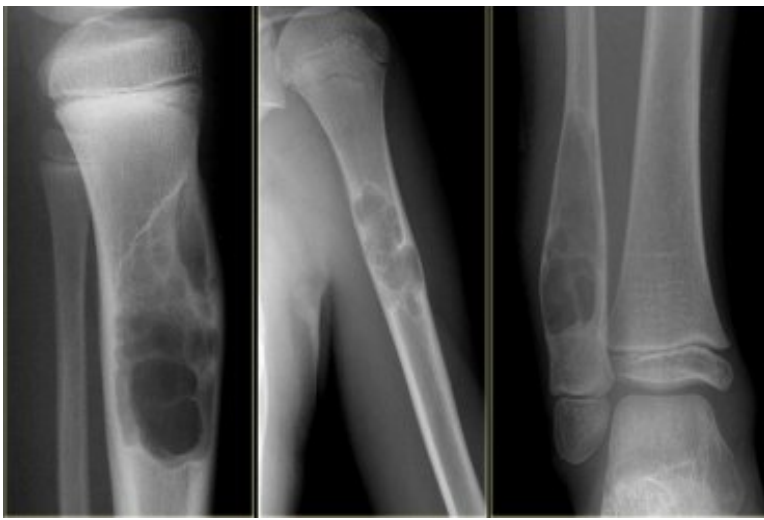
- Infections, a common tumor mimic, are seen in any age group.
- Infection may be well-defined or ill-defined osteolytic, and even sclerotic.
- EG and infections should be mentioned in the differential diagnosis of almost any bone lesion in patients < 30 years.
- Many sclerotic lesions in patients > 20 years are healed, previously osteolytic lesions which have ossified, such as: NOF, EG, SBC, ABC and chondroblastoma.

Zone of transition

In order to classify osteolytic lesions as well-defined or ill-defined, we need to look at the zone of transition between the lesion and the adjacent normal bone.

The zone of transition is the most reliable indicator in determining whether an osteolytic lesion is benign or malignant (1).

The zone of transition only applies to osteolytic lesions since sclerotic lesions usually have a narrow transition zone.



Narrow zone of transition: NOF, SBC and ABC

Small zone of transition

A small zone of transition results in a sharp, well-defined border and is a sign of slow growth. A sclerotic border especially indicates poor biological activity.

In patients < 30 years a well-defined border means that we are dealing with a benign lesion.

In patients > 30years, and particularly over 40 years, despite benign radiographic features, metastasis or plasmacytoma also have to be considered

On the left three bone lesions with a narrow zone of transition.

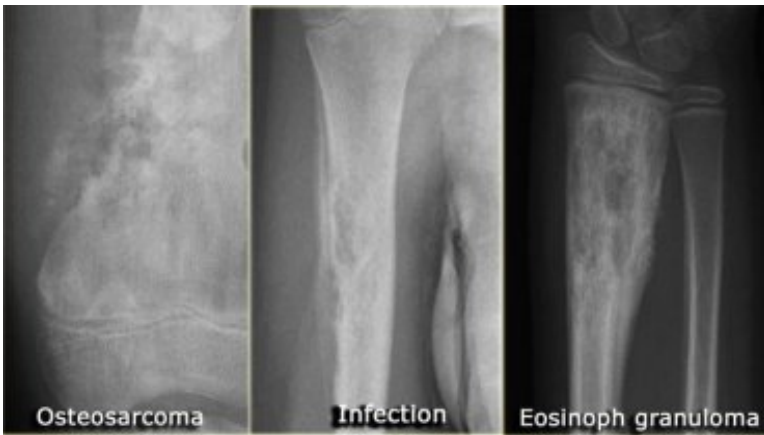Based on the morphology and the age of the patients, these lesions are benign.

Notice that in all three patients, the growth plates have not yet closed.

Metastases and Myeloma always have to be included in the differential diagnosis of a well-defined bone lesion in a patient > 40 years

In patients > 40 years metastases and multiple myeloma are the most common bone tumors. Metastases under the age of 40 are extremely rare, unless a patient is known to have a primary malignancy.

Metastases could be included in the differential diagnosis if a younger patient is known to have a malignancy, such as neuroblastoma, rhabdomyosarcoma or retinoblastoma.



Wide zone of transition indicates malignancy or infection or eosinophilic granuloma

Wide zone of transition

An ill-defined border with a broad zone of transition is a sign of aggressive growth (1).

It is a feature of malignant bone tumors.

There are two tumor-like lesions which may mimic a malignancy and have to be included in the differential diagnosis.

These are infections and eosinophilic granuloma.

Both of these entities may have an aggressive growth pattern.

Infection and Eosinophilic Granuloma can mimic a malignant tumor They can have an ill-defined border, cortical destruction and an aggressive type of periostitis

Infections and eosinophilic granuloma are exceptional because they are benign lesions which may seem malignant due to their aggressive biologic behavior.

These lesions may have ill-defined margins, but cortical destruction and an aggressive type of periosteal reaction may also be seen.

EG almost always occurs in patients < 30 years and has to be included in the differential diagnosis of any

bone lesion in a patient < 30 years.

Infections have to be included in the differential diagnosis of any bone lesion at any age.

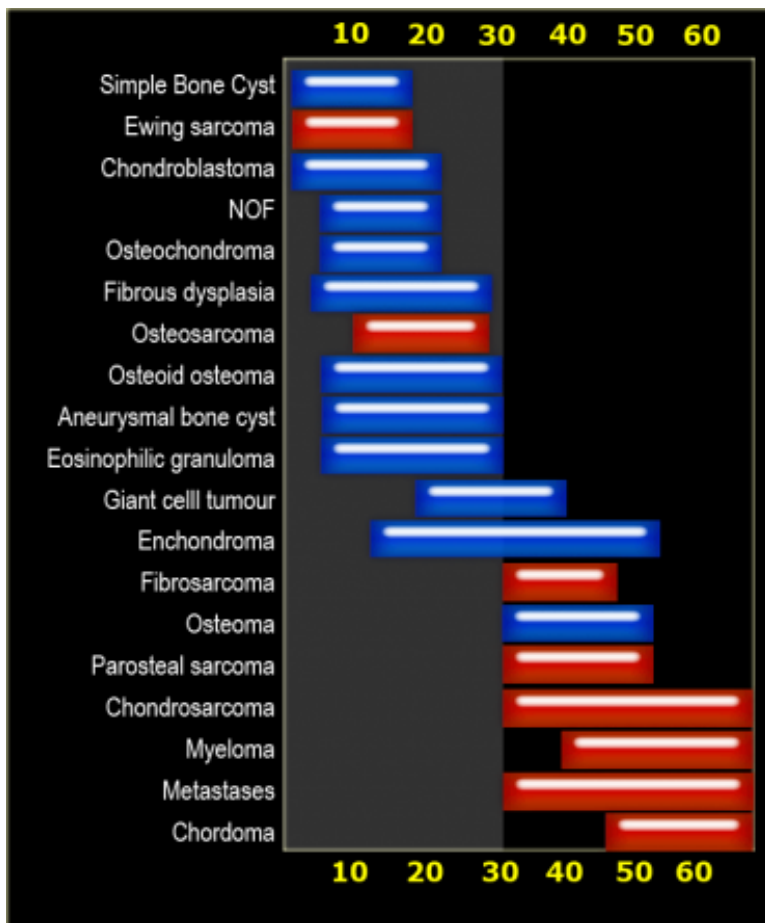
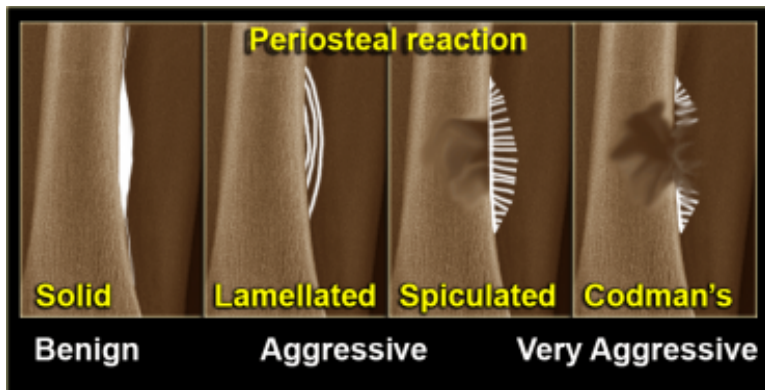


Table: specific tumors by age
Malignant bone tumors in red and benign tumors in blue



Age

Age is the most important clinical clue in differentiating possible bone tumors.

There are many ways of splitting age groups, as can be seen in the first table.

Some prefer to divide patients into two age groups: < 30 or > 30 years.

Most primary bone tumors are seen in patients < 30 years.

In patients > 30 years we must always include metastases and myeloma in the differential diagnosis.

Periosteal reaction

A periosteal reaction is a non-specific reaction and will occur whenever the periosteum is irritated by a malignant tumor, benign tumor, infection or trauma. There are two patterns of periosteal reaction: a benign and an aggressive type.

The benign type is seen in benign lesions such as benign tumors and following trauma.

An aggressive type is seen in malignant tumors, but also in benign lesions with aggressive behavior, such as infections and eosinophilic granuloma.


Benign periosteal reaction

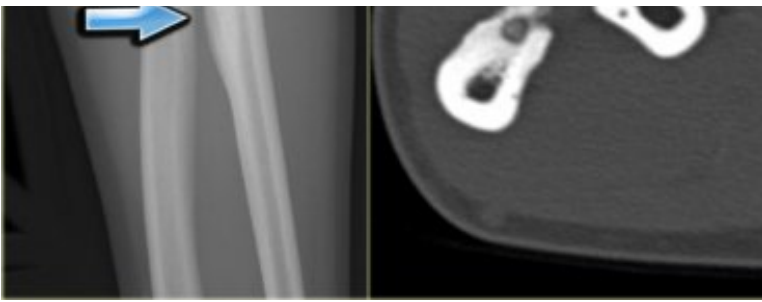
Detecting a benign periosteal reaction may be very helpful, since malignant lesions *never cause* a benign periosteal reaction.

A benign type of periosteal reaction is a thick, wavy and uniform callus formation resulting from chronic irritation.

In the case of benign, slowly growing lesions, the

periosteum has time to lay down thick new bone and remodel it into a more normal-appearing cortex.





Benign periosteal reaction in an osteoid osteoma

*Malignant bone tumors
do not cause a benign periosteal reaction*

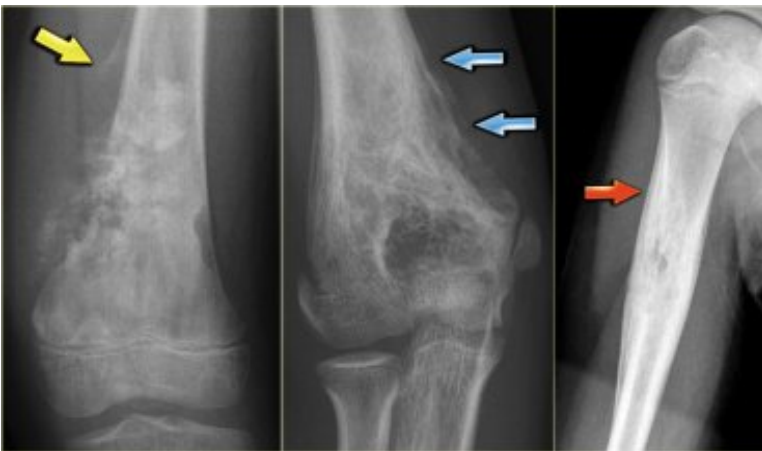Aggressive periosteal reaction

This type of periostitis is multilayered, lamellated or demonstrates bone formation perpendicular to the cortical bone.

It may be spiculated and interrupted - sometimes there is a Codman's triangle.

A Codman's triangle refers to an elevation of the periosteum away from the cortex, forming an angle where the elevated periosteum and bone come together.

In aggressive periostitis the periosteum does not have time to consolidate.



Aggressive periosteal reaction

Aggressive periosteal reaction (2)

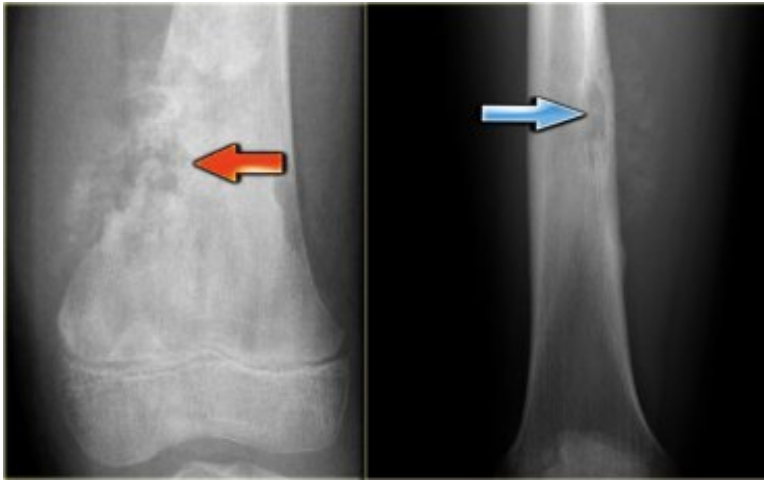
- *left:*
Osteosarcoma with interrupted periosteal reaction and Codman's triangle proximally. There is periosteal bone formation perpendicular to the cortical bone and extensive bony matrix formation by the tumor itself.
- *middle:*
Ewing sarcoma with lamellated and focally interrupted periosteal reaction. (blue arrows)
- *right:*
Infection with a multilayered periosteal reaction. Notice that the periostitis is aggressive, but not as aggressive as in the other two cases.

*A Periosteal reaction excludes the diagnosis of
Fibrous dysplasia, Enchondroma, NOF and SBC
unless there is a fracture*

Fibrous dysplasia, Enchondroma, NOF and SBC are common bone lesions.

They will not present with a periosteal reaction unless there is a fracture.

If no fracture is present, these bone tumors can be excluded.



Osteosarcoma (left) and Ewings sarcoma (right)

Cortical destruction

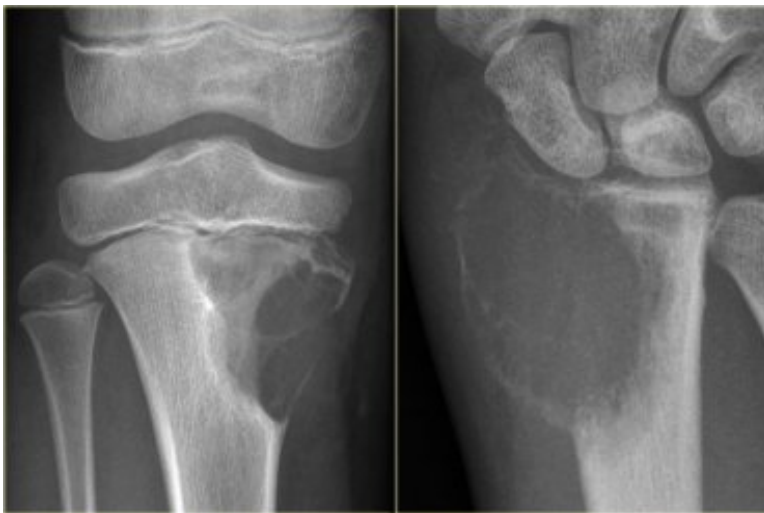Cortical destruction is a common finding, and not very useful in distinguishing between malignant and benign lesions.

Complete destruction may be seen in high-grade malignant lesions, but also in locally aggressive benign lesions like EG and osteomyelitis.

More uniform cortical bone destruction can be found in benign and low-grade malignant lesions.

Endosteal scalloping of the cortical bone can be seen in benign lesions like FD and low-grade chondrosarcoma.

The images on the left show irregular cortical destruction in an osteosarcoma (left) and cortical destruction with aggressive periosteal reaction in Ewing's sarcoma.



Chondromyxoid fibroma (left), Giant cell tumor (right)

Ballooning is a special type of cortical destruction.

In ballooning the destruction of endosteal cortical bone and the addition of new bone on the outside occur at the same rate, resulting in expansion.

This 'neocortex' can be smooth and uninterrupted, but may also be focally interrupted in more aggressive lesions like GCT.

- *left*: Chondromyxoid fibroma
A benign, well-defined, expansile lesion with regular destruction of cortical bone and a peripheral layer of new bone.
- *right*: Giant cell tumor
A locally aggressive lesion with cortical destruction, expansion and a thin, interrupted peripheral layer of new bone.
Notice the wide zone of transition towards the marrow cavity, which is a sign of aggressive behavior.

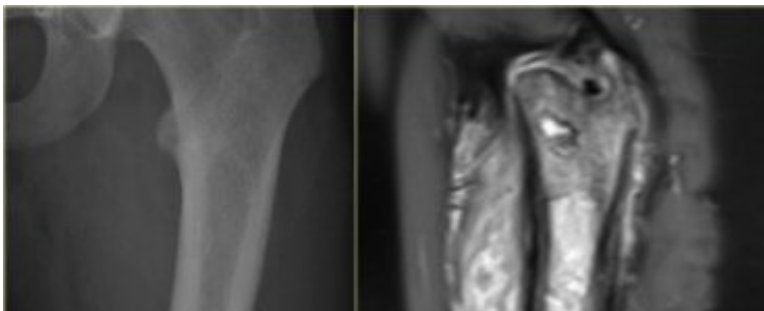
Cortical destruction (3)

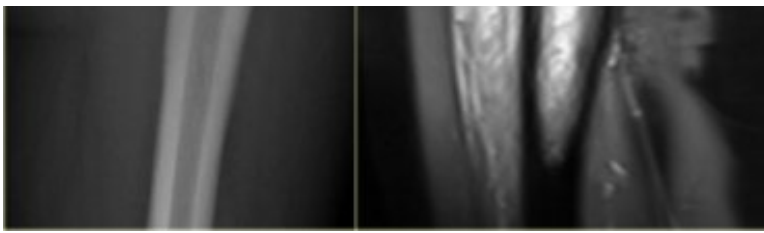
In the group of malignant small round cell tumors which include Ewing's sarcoma, bone lymphoma and small cell osteosarcoma, the cortex may appear almost normal radiographically, while there is permeative growth throughout the Haversian channels.

These tumors may be accompanied by a large soft tissue mass while there is almost no visible bone destruction.

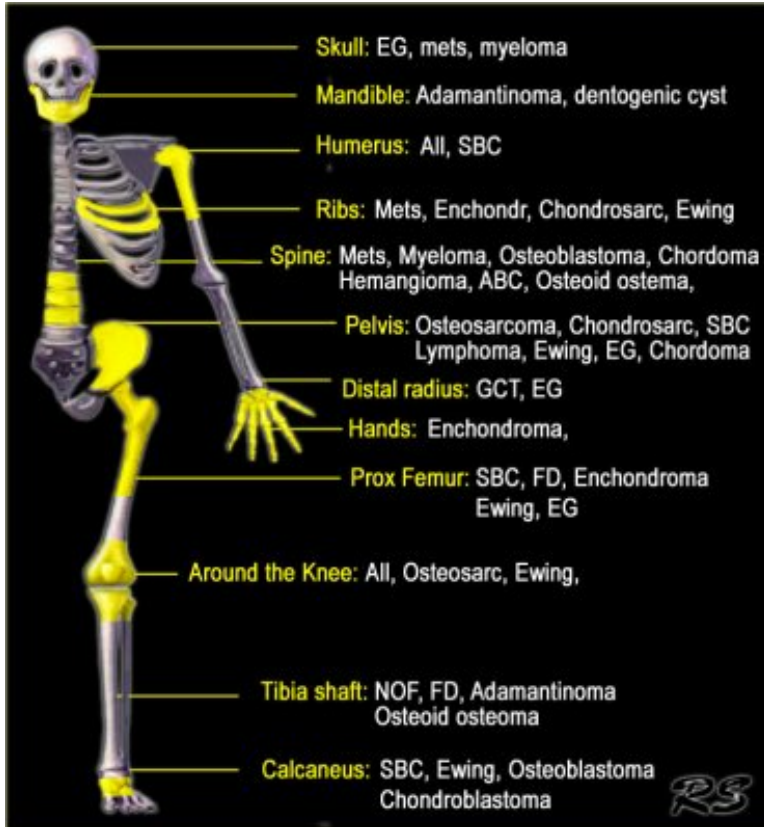
The image on the left shows an Ewing's sarcoma with permeative growth through the Haversian channels accompanied by a large soft tissue mass.

The radiograph does not show any signs of cortical destruction.





Ewing's sarcoma with permeative growth through the Haversian channels accompanied by a large soft tissue mass



Location within the skeleton

The location of a bone lesion within the skeleton can be a clue in the differential diagnosis.

The illustration on the left shows the preferred locations of the most common bone tumors.

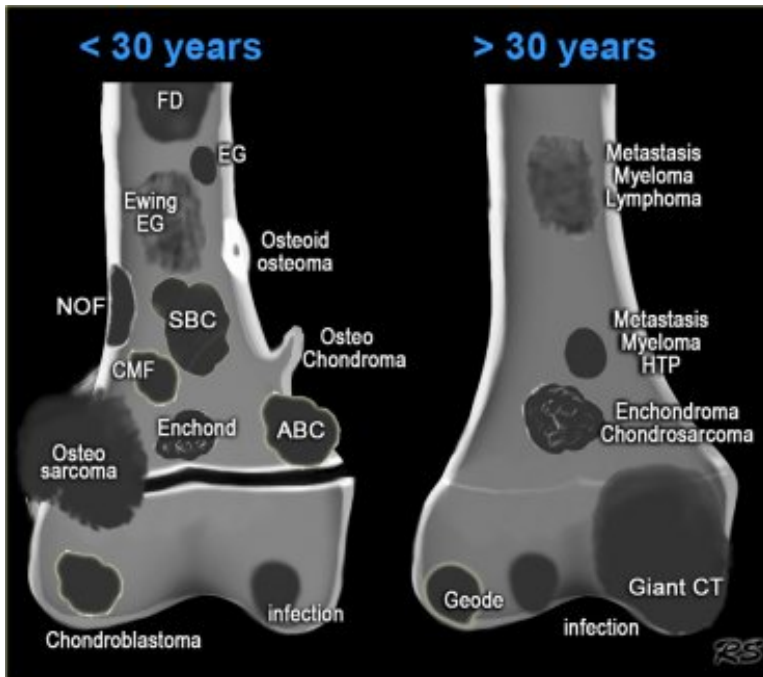
In some locations, such as in the humerus or around the knee, almost all bone tumors may be found.

Top five location of bone tumors in alphabetic order

- Aneurysmal Bone Cyst
tibia, femur, fibula, spine, humerus
- Adamantinoma
tibia shaft, mandible
- Chondroblastoma
femur, humerus, tibia, tarsal bone (calc), patella
- Chondromyxoid fibroma
tibia, femur, tarsal bone, phalanx foot, fibula
- Chondrosarcoma
femur, rib, iliac bone, humerus, tibia
- Chordoma
sacrococcygeal, spheno-occipital, cervical, lumbar, thoracic
- Eosinophilic Granuloma
femur, skull, iliac bone, rib, vertebra
- Enchondroma
phalanges of hands and feet, femur, humerus, metacarpals, rib
- Ewing's sarcoma
femur, iliac bone, fibula, rib, tibia
- Fibrous dysplasia
femur, tibia, rib, skull, humerus
- Giant Cell Tumor
femur, tibia, fibula, humerus, distal radius
- Hemangioma
spine, ribs, craniofacial bones, femur, tibia
- Lymphoma

femur, tibia, humerus, iliac bone, vertebra
- Metastases
vertebrae, ribs, pelvis, femur, humerus
- Non Ossifying Fibroma
tibia, femur, fibula, humerus
- Osteoid osteoma
femur, tibia, spine, tarsal bone, phalanx
- Osteoblastoma
spine, tarsal bone (calc), femur, tibia, humerus
- Osteochondroma
femur, humerus, tibia, fibula, pelvis
- Osteomyelitis

- Osteomyelitis
femur, tibia, humerus, fibula, radius
- Osteosarcoma
femur, tibia, humerus, fibula, iliac bone
- Solitary Bone Cyst
proximal humerus, proximal femur, calcaneal bone, iliac bone



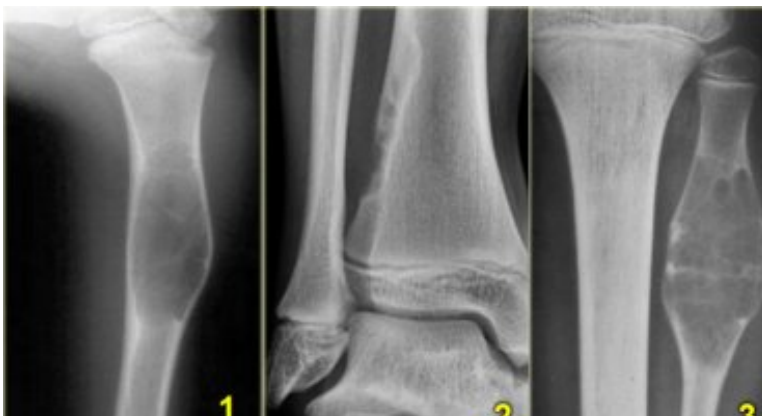Location: epiphysis - metaphysis - diaphysis

- *Epiphysis*
Only a few lesions are located in the epiphysis, so this could be an important finding.
In young patients it is likely to be either a chondroblastoma or an infection.
In patients over 20, a giant cell tumor has to be included in the differential diagnosis.
In older patients a geode, i.e. degenerative subchondral bone cyst must be added to the differential diagnosis.
Look carefully for any signs of arthrosis.
- *Metaphysis*
NOF, SBC, CMF, Osteosarcoma, Chondrosarcoma, Enchondroma and infections.
- *Diaphysis*
Ewing's sarcoma, SBC, ABC, Enchondroma, Fibrous dysplasia and Osteoblastoma.

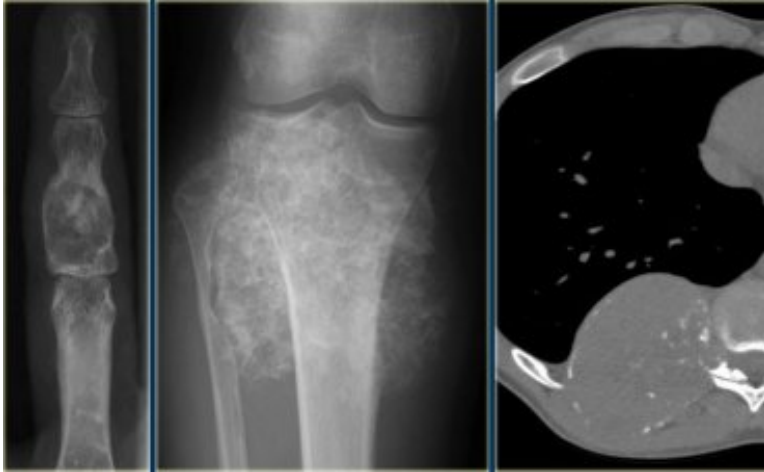
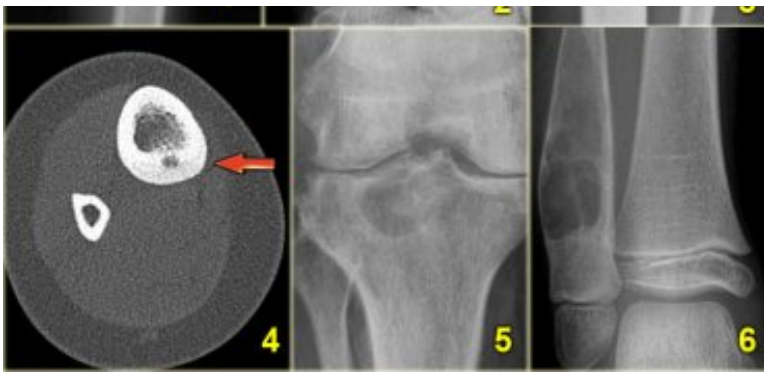
Differentiating between a diaphyseal and a metaphyseal location is not always possible. Many lesions can be located in both or move from the metaphysis to the diaphysis during growth. Large lesions tend to expand into both areas.

Location: centric - eccentric - juxtacortical

- *Centric in long bone*
SBC, eosinophilic granuloma, fibrous dysplasia, ABC and enchondroma are lesions that are located centrally within long bones.
- *Eccentric in long bone*
Osteosarcoma, NOF, chondroblastoma, chondromyxoid fibroma, GCT and osteoblastoma are located eccentrically in long bones.
- *Cortical*
Osteoid osteoma is located within the cortex and needs to be differentiated from osteomyelitis.
- *Juxtacortical*
Osteochondroma. The cortex must extend into the stalk of the lesion.
Parosteal osteosarcoma arises from the periosteum.



1. SBC: central diaphyseal
2. NOF: eccentric metaphyseal
3. SBC: central diaphyseal
4. Osteoid osteoma: cortical
5. Degenerative subchondral cyst: epiphyseal
6. ABC: centric diaphyseal



Chondroid matrix

Matrix

Calcifications or mineralization within a bone lesion may be an important clue in the differential diagnosis. There are two kinds of mineralization: a chondroid matrix in cartilaginous tumors like enchondromas and chondrosarcomas and an osteoid matrix in osseous tumors like osteoid osteomas and osteosarcomas.

Chondroid matrix

Calcifications in chondroid tumors have many descriptions: rings-and-arcs, popcorn, focal stippled or flocculent.

- *left*: Enchondroma, the most commonly encountered lesion of the phalanges.
- *middle*: middle: Peripheral chondrosarcoma, arising from an osteochondroma (exostosis).
- *right*: Chondrosarcoma of the rib.

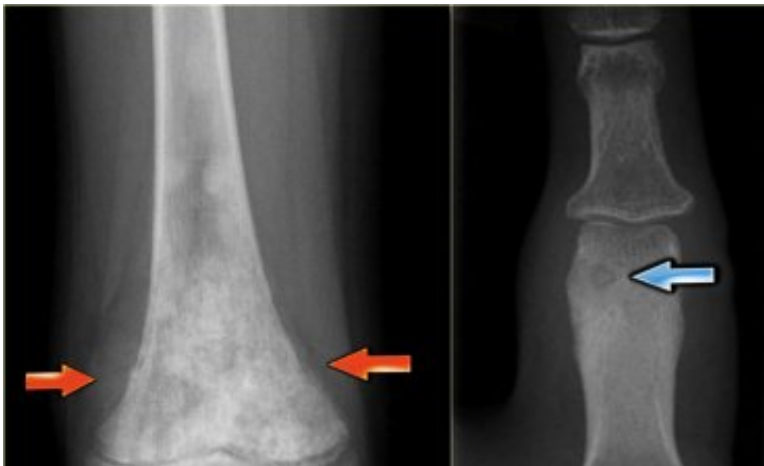Osteoid matrix

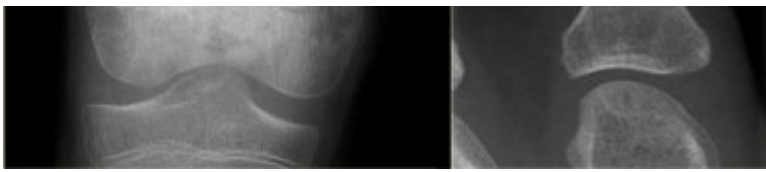
Mineralization in osteoid tumors can be described as a trabecular ossification pattern in benign bone-forming lesions and as a cloud-like or ill-defined amorphous pattern in osteosarcomas.

Sclerosis can also be reactive, e.g. in Ewing's sarcoma or lymphoma.

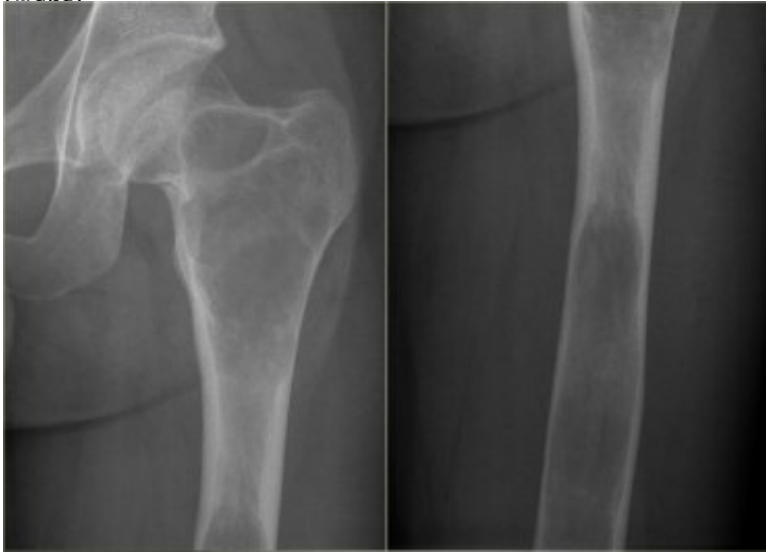- *left*
Cloud-like bone formation in osteosarcoma. Notice the aggressive, interrupted periosteal reaction (arrows).
- *right*

Trabecular ossification pattern in osteoid osteoma. Notice osteolytic nidus (arrow).





Osteoid matrix in Osteosarcoma (left) and Osteoid osteoma (right)



Polyostotic Fibrous Dysplasia. Multiple osteolytic lesions in femur.

Polyostotic or multiple lesions

Most bone tumors are solitary lesions. If there are multiple or polyostotic lesions, the differential diagnosis must be adjusted.

Polyostotic lesions < 30 years

NOF, fibrous dysplasia, multifocal osteomyelitis, enchondromas, osteochondroma, leukemia and metastatic Ewing's sarcoma.

Multiple enchondromas are seen in Morbus Ollier. Multiple enchondromas and hemangiomas are seen in Maffucci's syndrome.

Polyostotic lesions > 30 years

Common: Metastases, multiple myeloma, multiple enchondromas.

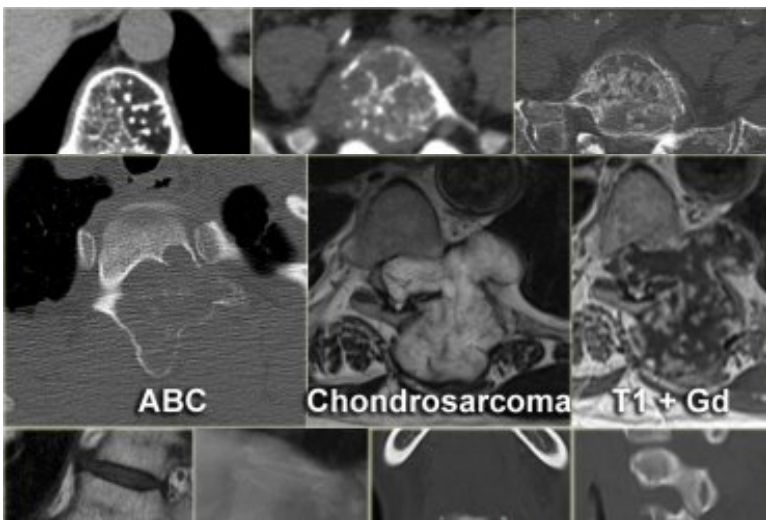
Less common: Fibrous dysplasia, Brown tumors of hyperparathyroidism, bone infarcts.

Mnemonic for multiple osteolytic lesions: FEEMHI:

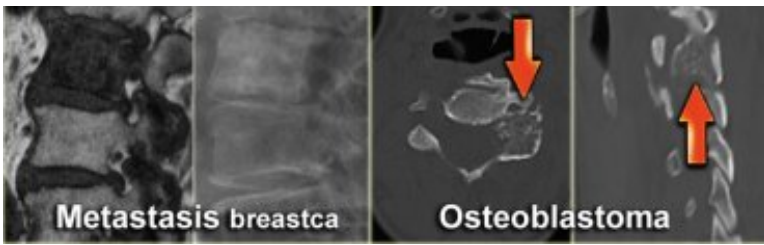
Fibrous dysplasia, enchondromas, EG, Mets and myeloma, Hyperparathyroidism, Infection.

Bone tumors in the spine

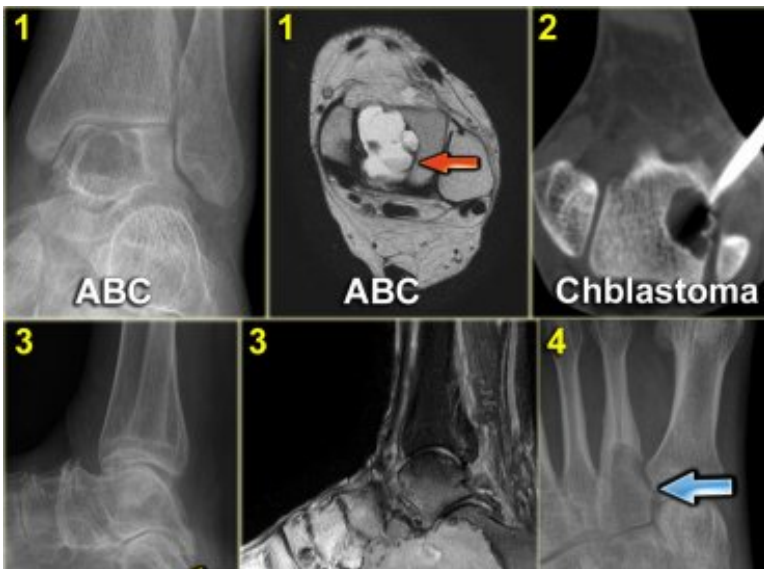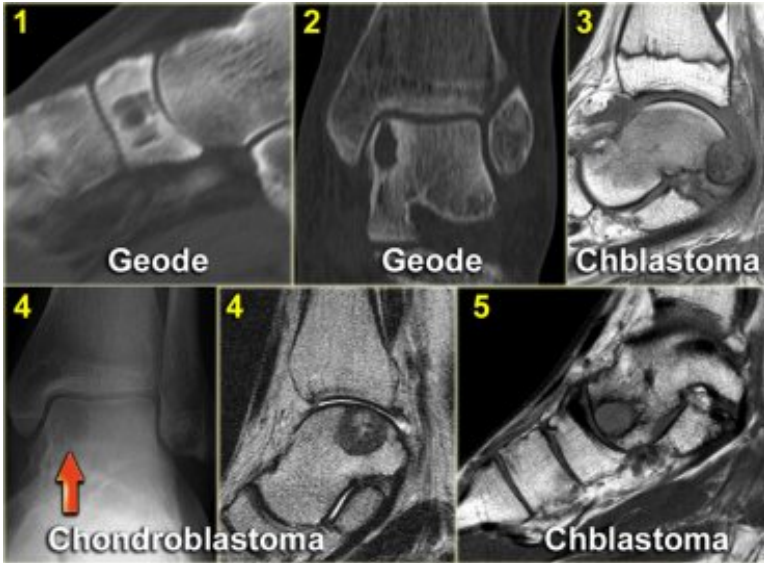1. Hemangioma.
2. Metastasis.
3. Multiple myeloma.
4. Plasmocytoma: vertebra plana.
This 'Mini Brain' appearance of plasmocytoma in the spine is sufficiently pathognomonic to obviate biopsy (9).

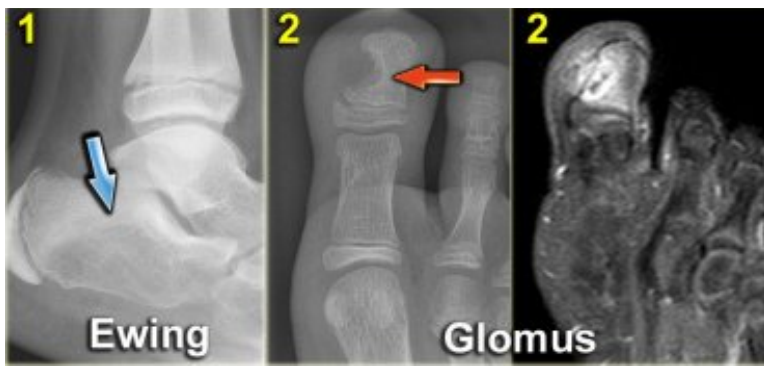

- 1.



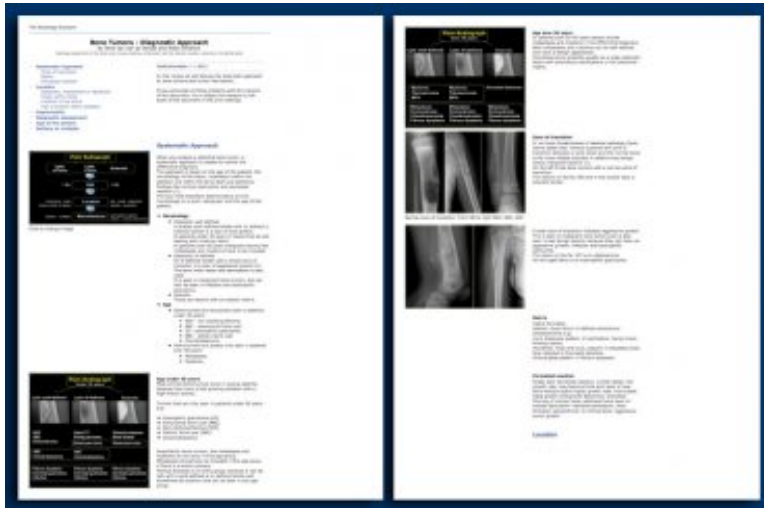
Bone tumors in the foot





Printing of the article

If you encounter printing problems with the margins of the document, simply adjust the margins or the scale of the document in the print settings. On the left an example with the print settings on a 70% scale.



References

1. Fundamentals of Skeletal Radiology, second edition
by Clyde A. Helms
W. B. Saunders company 1995
2. Aneurysmal Bone Cyst: Concept, Controversy, Clinical Presentation, and Imaging
by Mark J. Kransdorf and Donald E. Sweet
AJR 1995;164:573-580
3. Lucent Lesions of Bone
Online teaching by the Musculoskeletal Radiology academic section of the University of Washington
4. Sclerotic Lesions of Bone
Online teaching by the Musculoskeletal Radiology academic section of the University of Washington
5. Periosteal Reaction
Online teaching by the Musculoskeletal Radiology academic section of the University of Washington
6. Bone Tumors and Tumorlike Conditions: Analysis with Conventional Radiography
by Theodore Miller
March 2008 Radiology, 246, 662-674
7. Bonetumor.org
by Henri de Groot
8. Parosteal sarcoma (pdf)
by Jack Edeiken
9. The 'Mini Brain' Plasmacytoma in a Vertebral Body on MR Imaging
by Nancy M. Major, Clyde A. Helms and William J. Richardson.
AJR 2000; 175:261-263
10. Radiological atlas of bone tumours of the Netherlands Committee on Bone Tumors
by Mulder JD, et al.
Amsterdam: Elsevier, 1993.