

# Abdominal Masses in the Newborn

Marshall Z. Schwartz, MD,\* and Donald B. Shaul, MD†

The questions below should help focus the reading of this article.

1. What organ accounts for the majority of neonatal abdominal masses?
2. What causes of abdominal masses in newborns are commonly associated with abnormal calcifications?
3. Which imaging techniques are generally most cost-effective when evaluating a newborn with an abdominal mass?
4. What are the advantages and disadvantages of abdominal ultrasound when compared with other imaging techniques?
5. What is the current status of prenatal management of fetal abdominal masses?

The presence of an abdominal mass in the neonatal period is common, occurring in approximately 1 infant in 1000 live births. Despite this relatively high incidence, the finding of an abdominal mass in a neonate can be alarming for both parents and physicians. Until recently, the identification of an abdominal mass was made by physical signs (ie, abdominal distention, palpable mass). However, in the past decade, fetal ultrasound has become technically refined and is more widely practiced. As a result, the presence of an abdominal mass in the fetus may be known long before birth, allowing for the formation of a specific diagnosis and treatment plan. In addition to fetal ultrasonography, a wide array of sophisticated imaging techniques have become available to aid in the diagnosis of an abdominal mass. However, in the cost-conscious environment in which health care must be provided, it is the physician's responsibility to evaluate an abdominal mass as cost effectively as possible. Early consultation among the pediatrician, pediatric ra-

diologist, pediatric surgeon, and, in the case of prenatal diagnosis, the obstetrician can expedite this process.

Many abdominal masses are of the nonsurgical variety (ie, organomegaly or bladder distention). Most masses requiring surgical intervention are benign (87%), and the prognosis for neonates with an abdominal mass is good.

In this article, we will review the various causes of an abdominal mass in the newborn, provide a differential diagnosis based on the physical findings, and describe an expeditious route to arrive at a definitive diagnosis. In addition, appropriate initial treatment will be discussed.

## INITIAL EVALUATION

Evaluation of an abdominal mass in neonates can be facilitated by a practical understanding of the most likely diagnoses and the ability to categorize the mass based on symptoms, location, and physical characteristics. A review of neonatal abdominal masses indicates that the organ or system of origin are as follows: 55% are renal, 15% involve the genital tract, 15% involve the gastrointestinal tract, 10% are retroperitoneal (nonrenal), and 5% involve the liver, biliary tract, and spleen (Fig 1). As part of the initial evaluation, the presence or absence of symptoms may be useful. Is the baby irritable or a poor feeder? Is emesis (nonbilious or bilious) present? These symptoms or signs might implicate the gastrointestinal tract as the origin of the abdominal mass.

The findings during physical examination can be helpful in making a tentative diagnosis. Is the mass located in the flank, midabdomen, or suprapubic area? Does the mass feel firm (solid) or compressible (cystic)? Can the mass be moved easily or is it fixed in position? Does the surface of the mass feel smooth or irregular? Is there tenderness associated with palpation, suggesting inflammation or hemorrhage? Is the mass indicative of generalized enlargement of a specific organ (eg, hepatomegaly or

## EDUCATIONAL OBJECTIVE

4. The pediatrician should have knowledge to make an appropriate evaluation of a newborn male infant with a left flank mass, differentiating among hydronephrosis (ureteropelvic junction obstruction, vesicoureteral reflux, urethral obstruction), Wilms tumor, neuroblastoma, multicystic disease of the kidney, renal vein thrombosis, and adrenal hematoma, and develop an appropriate plan for management (Topics, 89/90).

splenomegaly) or overdistention (stomach or urinary bladder)?

Thus, by knowing the general distribution of neonatal abdominal masses, as well as the history and physical findings, the physician can make a more focused differential diagnosis or even a specific diagnosis without having to order several costly or time-consuming hematologic or imaging tests. For example, a newborn infant who is found to have a unilateral, irregular, compressible flank mass without evidence of gastrointestinal impairment is likely to have a multicystic, dysplastic kidney. Thus, further evaluation can be directed toward this tentative diagnosis. A renal ultrasound may be the only study necessary to confirm this diagnosis.

Physical findings can be useful in narrowing the differential diagnosis.

After the history has been obtained and physical examination performed, plain abdominal radiographs should be obtained. Considerable information can be obtained from this simple, inexpensive test. The bowel gas pattern can indicate obstruction or displacement which may be helpful in determining whether the mass is intra- or retroperitoneal. Calcification can suggest neuroblastoma, hepatoblastoma, or meconium peritonitis.

\* Professor, Dept of Surgery and Pediatrics, and Chief, Division of Pediatric Surgery, University of California—Davis, School of Medicine, Sacramento.

† Surgical resident, Dept of Surgery, University of California—Davis, Sacramento.

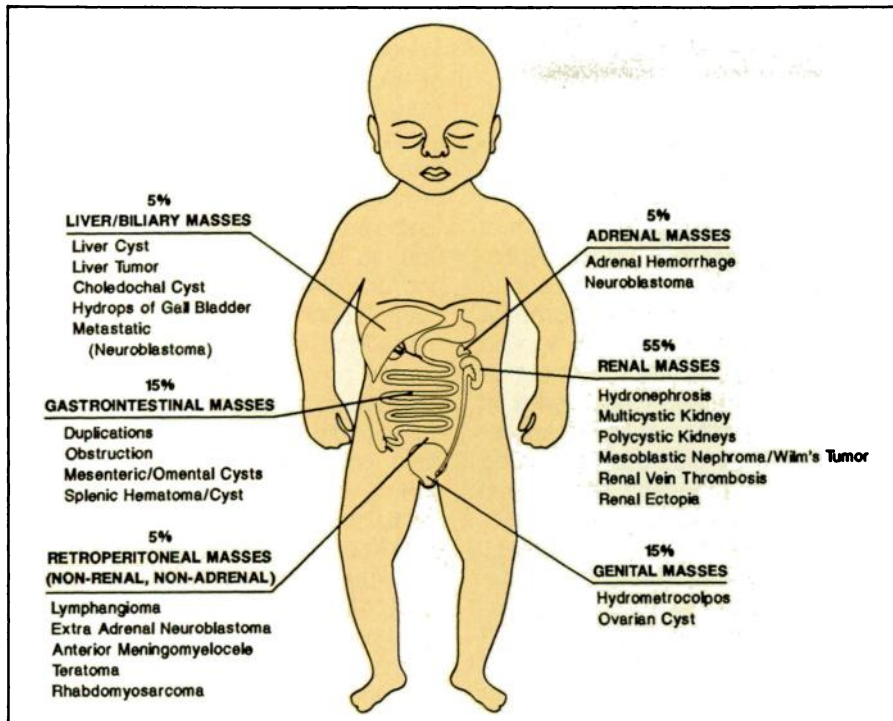


Fig 1. Distribution of abdominal masses in neonate by organ system. Data derived from Kirks et al. *Radiol Clin North Am.* 1981;19:527-545.

If there are no clinical or radiographic findings suggestive of a bowel obstruction, then abdominal ultrasound is the next appropriate study. Abdominal ultrasound has proved to be a valuable diagnostic tool which has the added benefits of being painless, harmless, and inexpensive, requires no sedation, and can be performed at the bedside. Frequently, ultrasound can provide a definitive diagnosis by differentiating solid from cystic masses and defining the organ of origin. Relative disadvantages include a greater dependence on the ultrasonographer for interpretation, the inability of ultrasound to scan through bone or gas, and its lack of ability to provide information about organ function.

Computed tomography (CT) is currently the most versatile imaging procedure for the evaluation of abdominal masses. It has the advantage of providing precise anatomic detail, especially for the evaluation of solid tumors of the retroperitoneum (eg, mesoblastic nephroma, neuroblastoma, sacrococcygeal teratoma) and the peritoneal cavity (eg, hepatoblastoma, ovarian teratoma). It has the disadvantages of requiring moderate doses of ionizing radiation and is ex-

pensive. In addition, to obtain an optimal CT scan, sedation is nearly always required for the neonate.

An abdominal radiograph and an ultrasound may be the only imaging techniques necessary.

Magnetic resonance imaging (MRI) is a relatively new modality that can be used in the evaluation of neonatal abdominal masses. Its true potential has not yet been fully realized. It has the advantages of avoiding ionizing radiation and intravenous or enteral contrast are not necessary. MRI can provide anatomic definition in several different planes. Because a mass can be viewed in several different planes, a more specific anatomic location can be determined. Differentiation of benign from malignant solid tumors may be possible with this technology, based on different cell characteristics. MRI has been used for detection of thrombus and tumor in the renal vein and inferior vena cava. It may be useful in detecting fetal abdominal anomalies as its use in pregnancy

becomes more widespread. The disadvantages of MRI at the present time are its more limited availability, considerable expense, and need for sedation to keep the patient relatively motionless during the study.

One or more of the previously described imaging modalities, although not directed at a specific organ, may provide a specific diagnosis and eliminate the need for further studies. However, several other tests are available to study the anatomy or function of specific organs.

Radionuclide scans of specific organs have proved to be useful in evaluating certain neonatal abdominal masses. Radiation exposure can be minimized by administering the minimum amount of radiopharmaceutical agent required to obtain a reliable examination. A renal scan using technetium 99m-labeled diethylene-triamine allows precise assessment of renal function and the relative contribution provided by each kidney. Biliary excretion can be assessed by technetium 99m-labeled derivatives of iminodiacetic acid in suspected cases of extrahepatic biliary tract anomalies (eg, choledochal cyst). A liver-spleen scan with technetium 99m-labeled sulfur colloid may be useful in diagnosing liver tumors or splenic enlargement but probably offers little more information than CT.

Voiding cystourethrography is the optimal method of assessing vesicoureteral reflux and the urethral anatomy in boys. Hydronephrosis and hydroureter secondary to reflux, an abnormally innervated bladder, or posterior urethral valves are best evaluated by voiding cystourethrography.

Intravenous pyelography, at one time the only method of evaluating renal anatomy and function, has been circumvented by the availability of ultrasound, CT, and renal scintigraphy. Because the newborn infants kidneys are immature, intravenous pyelography has proven inadequate. To obtain a more accurate study, it is necessary to wait 1 to 2 weeks after birth, at which time better definition of the renal collecting system and ureters can be obtained.

Other modalities, such as angiography and venography, have a limited role in the evaluation of neonatal ab-

dominal masses. For example, angiography may be indicated for patients with a hepatic tumor in whom assessment of resectability is being determined.

## WORKUP BY ANATOMIC LOCATION

### Retroperitoneal Masses

An algorithm has been devised (Fig 2) to aid in the evaluation of a neonatal abdominal mass. This has been made as simple as possible. A more comprehensive discussion follows.

**Kidney.** Since the majority of neonatal abdominal masses are renal in origin, the flank is the most common site of presentation. A list of possible masses arising from the kidney or adrenal gland can be found in Table 1. Defining the mass as either solid or cystic during physical examination and ultrasound is useful in narrowing the differential diagnosis. Cystic masses are more common, with multicystic, dysplastic kidney, and hydronephrosis making up most of the neonatal flank masses and accounting for 40% of all neonatal abdominal masses. A multicystic, dysplastic kidney consists of multiple noncommunicating cysts thought to be the result of atresia of the ureteropelvic system and is often palpable as an irregular feeling, compressible flank mass. The ultrasound findings of multiple hypoechoic, noncommunicating cysts of variable sizes are usually diagnostic. Both kidneys should be evaluated because in one third of cases the contralateral kidney is abnormal. Multicystic, dysplastic kidneys are nonfunctional, and therefore, it is generally recommended that they be removed to avoid development of hypertension, infection, or carcinoma.

Infants with congenital hydronephrosis are usually asymptomatic; the flank mass results from mechanical obstruction, defects in ureteral propulsion secondary to muscle dysfunction, or vesicoureteral reflux. Ureteropelvic junction obstruction is the most common cause of hydronephrosis (22%) and is considered to be due to intrinsic or extrinsic mechanical obstruction or poor peristalsis of the proximal ureter. Posterior urethral valves, ureterovesical junc-

tion obstruction, and ectopic ureteroceles are other causes of hydronephrosis but, unlike ureteropelvic junction obstruction, are associated with ureteral dilation (hydroureter), a finding frequently detectable by ultrasound. Reflux may occur alone or in association with posterior urethral valves. The initial workup for hydronephrosis should be with ultrasound and voiding cystourethrography. Using these studies, one will be able to determine the level of obstruction and whether ureterovesical reflux is present. No further imaging procedures may be indicated, depending on the results of these studies. Renal scintigraphy to evaluate renal function and intravenous pyelography (1 to 2 weeks postnatally) to better define the anatomy may be useful under specific circumstances. CT and MRI are not necessary. Obstructing lesions involving the ureteropelvic junction or ureterovesical junction are treated surgically. Temporary decompression by ultrasound-guided percutaneous nephrostomy can be useful in preserving renal function and assessing whether renal function might improve in a severely compromised kidney. This would provide information concerning whether to repair or resect the involved kidney. Reflux severe enough to produce significant hydronephrosis is usually the result of urethral obstruction (posterior urethral valves) or a neurogenic bladder. Vesicostomy has proved to be helpful as initial treatment. Transurethral fulguration is the definitive treatment for posterior urethral valves.

The kidney accounts for more than 50% of neonatal abdominal masses.

Intermittent catheterization has been used with some success in patients with neurogenic bladder.

Polycystic kidney disease is usually bilateral, has a genetic basis, and requires no specific treatment. The infantile form is uniformly fatal. The adult form rarely occurs in the neonate and only requires surveillance for the development of hypertension and renal failure.

Solid renal lesions occur much less frequently than cystic lesions. Most of these masses are benign and include renal vein thrombosis and mesoblastic nephroma. Renal vein thrombosis in the newborn usually produces no symptoms and may be associated with hematuria or proteinuria. In addition, thrombocytopenia and/or disseminated intravascular coagulation may be initial signs. Dehydration and hemoconcentration are usually predisposing factors. Infants of diabetic mothers are particularly susceptible. Diagnosis is usually possible with ultrasound alone, which shows absence of blood flow in the renal vein and an enlarged kidney. CT or MRI can demonstrate thrombus in the renal vein and/or inferior vena cava. A diethylenetriamine renal scan has been suggested as another method of diagnosing renal vein thrombosis. However, these procedures are usually not necessary. Treatment is nonoperative and consists of rehydration and correction of electrolyte disturbances. Heparinization is only indicated in cases of pulmonary embolus (rare). Recovery of renal function is variable but may be good.

Mesoblastic nephroma (fetal renal hamartoma) is benign and the most common neonatal renal tumor. More than 90% of these tumors are palpable and 18% of the infants have hematuria. Ultrasound is usually diagnostic, but a CT scan may be helpful in older neonates. Complete surgical excision is curative for mesoblastic nephromas, but differentiation from Wilms tumor can only be done after surgical removal and histologic examination. Nephroblastomatosis and nodular renal blastema are rare bilateral lesions in which both kidneys have multiple confluent nodules composed of metanephric epithelium. Ultrasound and CT are the optimal methods of diagnosis.

Neonatal Wilms tumor (nephroblastoma) is rare. Evaluation is usually by ultrasound and CT. It is difficult to preoperatively differentiate mesoblastic nephroma from Wilms tumor. Surgical excision is the treatment of choice for both lesions.

**Adrenal Gland.** The adrenal gland may be the source of a flank mass in the newborn. The most common

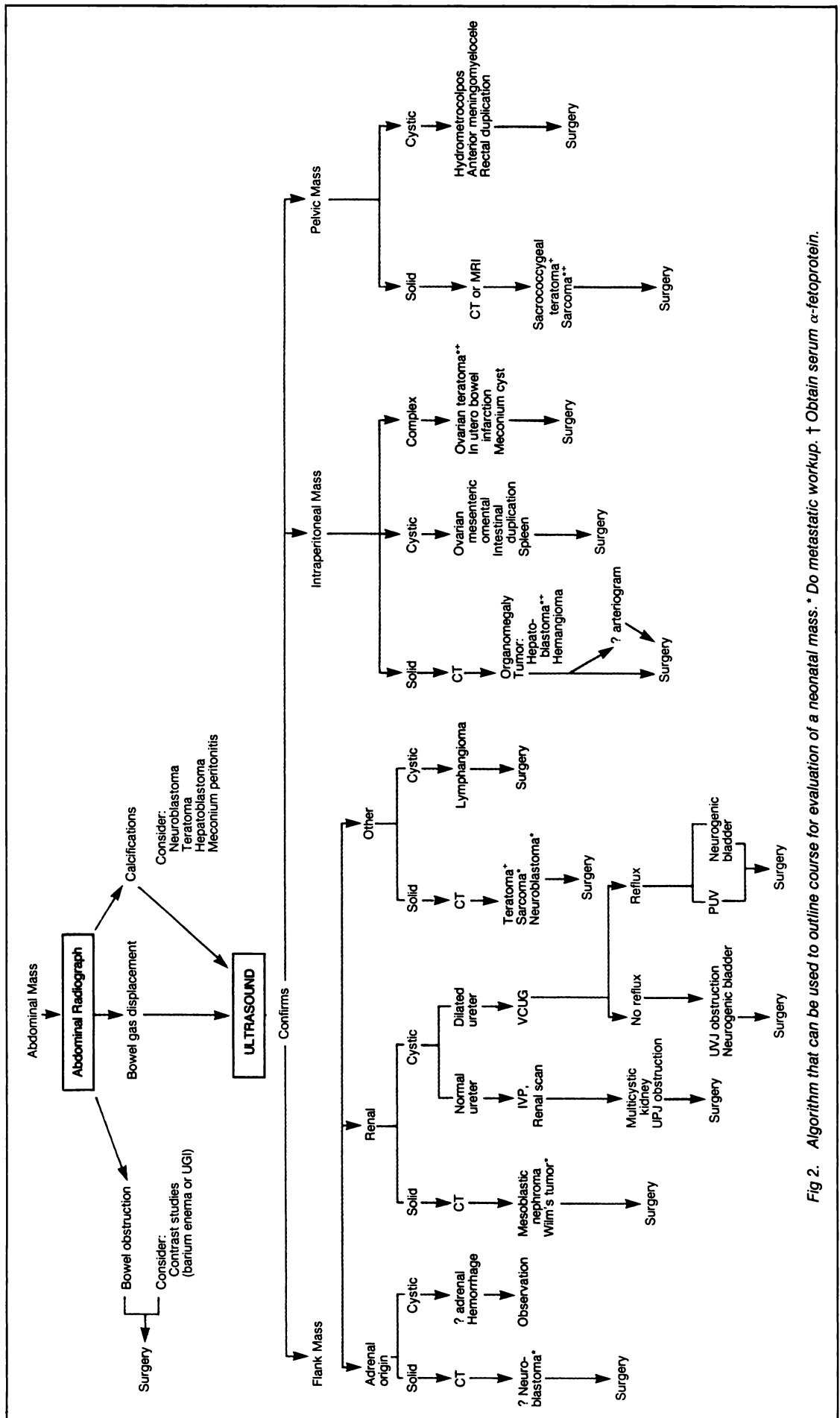


Fig 2. Algorithm that can be used to outline course for evaluation of a neonatal mass. \* Do metastatic workup. † Obtain serum  $\alpha$ -fetoprotein.

**TABLE 1.** Neonatal Flank Masses After Ultrasonographic Categorization\*

Ultrasound Findings and Differential Diagnosis	Relative Incidence	Associated Findings	Further Management
<b>Renal</b>			
<b>Cystic</b>			
Hydronephrosis	Common	May be bilateral	Voiding cystourethrogram, renal scan, decompression/reconstruction
Multicystic kidney (type II)	Common	Ureteral atresia may be bilateral	Voiding cystourethrogram, renal scan, nephrectomy
Infantile polycystic kidney disease (type I)	Uncommon	Bilateral pulmonary hypoplasia, hepatic disease	Supportive respiratory care and dialysis, excretory urogram if needed for diagnosis
Adult polycystic kidney disease (type III)	Rare in neonates	Bilateral large renal cysts	Follow-up for development of hypertension, renal failure
<b>Solid</b>			
Renal vein thrombosis	Uncommon	Birth trauma, maternal toxemia or diabetes mellitus	Hydration, acid-base, and electrolyte correction; CT scan or MRI if ultrasound nondiagnostic
Mesoblastic nephroma	Uncommon	Occasional hypertension	Chest roentgenogram, CT scan, or MRI; nephrectomy
Wilms tumor	Rare in neonates	May be bilateral hypertension, hematuria	Chest and abdominal CT, radical nephrectomy, may require adjuvant therapy
Nephroblastomatosis	Rare	Bilateral renal enlargement with solid parenchymal densities	Possible biopsy, continued follow-up
<b>Adrenal</b>			
<b>Cystic</b>			
Early hemorrhage	Uncommon	Birth trauma, anemia, shock	Rule out ongoing hemorrhage, evaluate for caval compression, serial ultrasound to document shrinkage
<b>Solid</b>			
Late hemorrhage	Uncommon	Adrenal insufficiency, calcified rim around hematoma	Serial ultrasound to rule out enlargement as in neuroblastoma
Neuroblastoma	Isolated mass or with metastatic disease (stage IV-S)	Involvement of skin, liver, bone marrow; occasional hypertension	Urinary vanillylmandelic and homovanillic acids, tumor resection or biopsy

\* Abbreviations: CT, computed tomography; MRI, magnetic resonance imaging.

masses include adrenal hemorrhage and neuroblastoma. Birth trauma, anemia, or evidence of adrenal insufficiency may be present in the neonate with adrenal hemorrhage. However, the usual finding is a palpable mass. In 70% of patients, the hemorrhage occurs in the right adrenal gland. Diagnosis is usually by ultrasound and no specific treatment is required. However, if bilateral hemorrhage (5% to 10%) is present, steroid replacement may be necessary.

Neuroblastoma in the neonate frequently arises in the adrenal gland or sympathetic chain. Stippled calcification in the mass visualized by abdominal radiograph can help make the diagnosis. Urinary catecholamines

and metabolites (eg, vanillylmandelic acid and homovanillic acid) should be measured. Ultrasound shows a homogeneous echogenic solid mass frequently associated with stippled calcification. Congenital neuroblastoma often is associated with skin, liver, and bone marrow metastases (stage IV-S). Therefore, these potential metastatic sites should be investigated. CT can be useful in evaluating the site of origin as well as areas of intraabdominal extension or metastases. Treatment depends on the stage. Surgical excision of the primary tumor in stages I, II, and IV-S is the usual treatment. Radiation and chemotherapy are important adjuvant modes of treatment.

*Other Retroperitoneal Masses.* Other tumors, both cystic and solid, may arise in the retroperitoneum. Cystic lesions usually are lymphangiomas. Solid masses may be teratomas or soft tissue tumors such as rhabdomyosarcoma. Ultrasound and CT are useful methods of diagnosis. MRI may prove to be more useful than CT when evaluating these lesions. Treatment is by surgical excision.

**Intraperitoneal Masses**

*Right Upper Abdominal (Hepatobiliary) Masses.* Most right upper quadrant masses are hepatobiliary in origin. Cystic masses in this location

include hydrops of the gallbladder, choledochal cyst, and solitary liver cysts. These masses are palpable and either cause no symptoms or cause jaundice (choledochal cyst). Solid masses include hepatic hemangioma, cavernous hemangioma, hamartoma, and hepatoblastoma. The findings depend on the specific lesion. Generalized hepatomegaly or a mass contiguous with the liver by physical examination are best evaluated by ultrasound and CT with intravenous contrast. Cystic masses in the right upper quadrant are best evaluated by ultrasound and radionuclide scanning. If a choledochal cyst is identified, then resection with Roux-en-Y hepaticojejunostomy should be performed.

The initial signs of a hepatic cavernous hemangioma or hemangioma may be indicated by a mass, by generalized hepatomegaly, and/or by congestive heart failure. Diagnosis is by CT or liver scan which shows a highly vascular lesion. MRI may prove to be a better imaging modality. Both vascular lesions may spontaneously involute. Steroid therapy may occasionally hasten this process. However, congestive heart failure may be profound and require intervention by hepatic artery embolization, ligation, or resection.

Hepatic hamartoma is a firm mass that is homogeneous by ultrasound or CT. Treatment is by surgical excision. Hepatoblastoma is a malignant tumor that may be identified in an infant with massive hepatomegaly or a specific mass. It is associated with an elevated serum  $\alpha$ -fetoprotein level. CT and perhaps MRI are the optimal imaging techniques. Arteriography may be indicated to determine resectability. Surgical excision is the treatment of choice. However, some lesions that are initially unresectable may be amenable to excision after a course of chemotherapy.

**Gastrointestinal Masses.** Masses related to the gastrointestinal tract can be detected in an infant by the physical findings of a palpable mass, generalized abdominal distention, or intestinal obstruction. A palpable abdominal mass associated with intestinal obstruction almost always originates in the gastrointestinal tract. In the absence of intestinal obstruction,

a mass associated with the gastrointestinal tract may take several days or weeks to be identified. When palpated, most gastrointestinal tract-related masses are smooth, round, and mobile.

Evaluation of an intraperitoneal mass suspected of being related to the gastrointestinal tract should begin with an abdominal roentgenograph. This may show partial intestinal obstruction and/or linear calcification in the wall of a cyst. Further evaluation should be accomplished by ultrasound. Gastrointestinal contrast studies (upper gastrointestinal or barium enema) may be indicated, depending on the findings of the other studies.

Duplications are the most common gastrointestinal masses in the neonate. They can occur from the stomach to the rectum, but the ileocecal area is the most common site. Duplications are usually cystic and do not communicate with the normal gastrointestinal lumen. However, some duplications are tubular, communicate with the adjacent bowel lumen, and contain ectopic gastric mucosa. Both forms can be detected as a mass or intestinal obstruction (usually partial). The latter variety can cause bleeding similar to a Meckel's diverticulum, but this usually does not occur in the neonatal period. Cysts originating in the omentum or mesentery also occur. In utero intestinal perforation can produce a meconium cyst which often has areas of calcification ("meconium peritonitis") that are visible on abdominal radiographs. A splenic cyst may rarely be present in the newborn.

Dilated intestinal loops from intraluminal air or intestinal contents can be mistaken for an intraperitoneal mass. The workup should begin with plain abdominal radiographs to rule out obstruction. If obstruction is present, intestinal atresia(s), meconium ileus (cystic fibrosis), volvulus or Hirschsprung disease are possibilities. A CT scan or MRI are unnecessary studies because they do not provide useful information related to gastrointestinal masses or obstruction.

#### **Pelvic Masses**

The finding of a mass arising from the pelvis in boys is likely to be a

distended bladder or urachal remnant. In girls, hydrometrocolpos and ovarian cysts are additional diagnostic possibilities. Masses that originate from the presacral space include sacrococcygeal teratoma and anterior meningocele. The physical examination by abdominal palpation, rectal examination, and inspection of the introitus in girls can be helpful in arriving at a tentative diagnosis.

Examination of the introitus in a girl might reveal a bulging membrane in cases of imperforate hymen or a pinpoint opening in the perineum associated with vaginal atresia. An ultrasound will confirm either a dilated vagina (hydrocolpos) or dilated vagina and uterus (hydrometrocolpos). Treatment is surgical and depends on the specific problem.

Although the ovary is a pelvic structure, ovarian lesions in newborn girls extend out of the pelvis as they grow and most often are detected as an abdominal mass. In fact, a cystic mass that appears to be mobile within a female newborn's lower abdomen is most likely to be ovarian in origin. Ultrasound will confirm the cystic nature of the mass but may not be able to define the organ or origin. If the cyst produces no symptoms, it may be possible to follow-up the infant by serial ultrasounds because some ovarian cysts will spontaneously resolve. If surgery is warranted, the goal should be resection

**TABLE 2.** Recommended Obstetric Management for Ultrasound-Identified Fetal Urologic Abnormalities

Term gestation: Vaginal delivery
Intestinal atresia
Mesenteric, omental or splenic cysts
Intestinal duplications
Omphalocele
Small to moderate sacrococcygeal teratoma
Ovarian cyst
Term gestation: Possible cesarean delivery
Giant omphalocele
Large sacrococcygeal teratoma
Possible preterm gestation: Vaginal or cesarean delivery
Gastroschisis*

\* Experimental and controversial.

of the cyst alone, sparing as much ovarian tissue as possible. Solid lesions of the ovary are usually teratomas. Treatment is by excision of the mass or ovary if necessary to rule out malignancy.

Sacrococcygeal teratomas are the most common congenital neoplasm. The diagnosis is usually obvious, because they typically are exophytic masses posterior to the sacrum. Occasionally, they may grow primarily presacrally and extend out of the pelvis and be detected as a mass during a rectal or abdominal examination. Ultrasound usually reveals solid and cystic components. A CT scan with contrast will help define the local extent of the tumor and its relationship to surrounding structures. Although the great majority of sacrococcygeal teratomas are benign at birth, prompt en bloc removal of the tumor and the tip of the coccyx is indicated because prolonged delay increases the risk of adverse effects from malignancy. Anterior myelomeningocele may, occasionally, be detected as a pelvic mass, but the presence of lower extremity paraplegia and muscle atrophy generally makes the diagnosis obvious.

**PRENATAL DIAGNOSIS**

The increasing use of fetal ultrasonography has provided a unique opportunity to prenatally diagnose abdominal masses. Frequently, the neonatologist, pediatrician, and pediatric surgeon are consulted by the obstetrician to render advice regarding the optimal perinatal care.

**Planning for prompt and appropriate postnatal treatment is the advantage of prenatal diagnosis of an abdominal mass.**

Prenatal management of fetal intraabdominal anomalies are largely obstetric in nature at the present time. They include the need for maternal transport to a facility in which optimal neonatal and pediatric surgical care are available, determination of the type of delivery (cesarean or vaginal), and whether premature delivery is appropriate. If resources for in utero intervention are available, this may be a consideration. The sug-

gested obstetric management for nongenitourinary fetal anomalies diagnosed by prenatal ultrasound are shown in Table 2. Elective cesarean section can be considered when those abdominal abnormalities such as giant omphalocele might produce dystocia during vaginal delivery. Preterm delivery has been suggested in cases of gastroschisis because of an increased risk to the extracoelomic intestinal tract late in the third trimester. The etiology of this is not clear but may be due to contraction of the abdominal wall opening and secondary vascular compromise to the intestine. This concept is not proven, and therefore, preterm delivery in these cases remains controversial.

Genitourinary anomalies present a greater number of management options (Table 3). Patients with unilateral renal disease are best managed after term delivery. Adequate renal function in the unaffected kidney does not warrant the risks associated with in utero manipulation or premature delivery. However, severe bilateral obstructive uropathy is frequently associated with significant postnatal morbidity due to pulmonary hypoplasia. Successful treatment of

**TABLE 3. Management of Genitourinary Anomalies Diagnosed in Utero**

Diagnosis	Cause	Prenatal Management	Postnatal Management
Renal agenesis	Failed development, autosomal recessive	Selective abortion and family counseling	Supportive
Infantile polycystic kidney disease	Autosomal dominant		Observe for hypertension
Adult polycystic kidney disease	Failed ureteropelvic development	Deliver at term	Renal scan to assess function (affected vs nonaffected side), unilateral nephrectomy
Multicystic kidney	UPJ obstruction, ureterocele, UVJ obstruction, reflux	Deliver at term	VCUG to rule out reflux, renal scan to assess function, decompression/reconstruction/nephrectomy
Hydronephrosis, unilateral	UPJ obstruction, posterior urethral valves, ureteroceles, Prune belly syndrome, neurogenic bladder, megaureter syndrome	Weekly ultrasound: oligohydramnios occurs (>20 wk: assess for value of in utero decompression if available†; >32 wk: deliver preterm for decompression†)	VCUG to rule out reflux, renal scan to assess function, decompression/reconstruction/excretory urography when 7–10 d old to assess anatomy
Hydronephrosis, bilateral	Urethral obstruction, neurogenic bladder (meningomyelocele)	No oligohydramnios—deliver at term	VCUG, decompression/reconstruction
Megacystis syndrome			

\* Abbreviations: UPJ, ureteropelvic junction; UVJ, ureterovesical junction; VCUG, voiding cystourethrogram.

† Experimental and controversial (see text for discussion).

fetal urinary tract obstruction has been limited by our inability to select the appropriate fetus for intervention, ie, the fetus who has renal and pulmonary damage severe enough to preclude survival without intervention but not yet so severe that damage is irreversible if the urinary obstruction is relieved. Promising methods being evaluated for predicting a good fetal outcome after in utero urinary tract decompression include sonographic assessment of renal parenchyma and temporary catheterization of the fetal bladder. Fetal bladder catheterization allows measurement of urinary output and quantitation of fetal urinary sodium and chloride concentrations, osmolarity, and creatinine clearance using maternal blood samples. Presently, in utero urinary tract decompression should be considered investigational and should only be carried out at centers with special interest and experience in this area. Preterm delivery is an option that allows earlier decompression of the obstructed urinary tract in highly selective cases. As stated before, one must weigh the risk of intervention against the risk of prematurity.

Preliminary results suggest that the neonates most likely to benefit from preterm delivery are those in whom oligohydramnios developed after 32 weeks' gestation when the risk of prematurity is relatively less.

In utero intervention will become a more likely alternative when the risks to the fetus can be minimized and initiation of labor can be avoided following uterine manipulation.

## CONCLUSION

Most neonatal abdominal masses are benign and more than half are of renal origin. Knowledge of the most common lesions, as well as basic clinical information, can provide a prioritized list of diagnoses. Ultrasound has proven to be an optimal imaging technique because it is safe and effi-

cient in neonates. Frequently, ultrasound is the only test required to confirm the diagnosis. The increased use of ultrasound during pregnancy has disclosed several abdominal anomalies that are correctable antenatally. Establishment of guidelines addressing the indications for and timing of in utero intervention is an ongoing and a rapidly changing field.

**Most neonatal masses are benign.**

The purpose of this paper has been to familiarize the practicing pediatrician with a practical scheme by which a correct diagnosis can be expeditiously obtained and management initiated for neonates with an abdominal mass. An algorithm (Fig 2) was formulated to summarize this process. Major emphasis is placed on avoidance of obtaining additional studies that will not alter the therapy but may be expensive, incur risks, and/or delay institution of the appropriate treatment.

The optimal evaluation of an abdominal mass in the newborn is best achieved by early communication between the pediatrician, pediatric surgeon, and radiologist.

## SUGGESTED READING

- Adzick NS, Flake AW, Harrison MR. Recent advances in prenatal diagnosis and treatment. *Pediatr Clin*. 1985;32:1103-1116
- Coran AG, Behrendt DM, Weintraub WH, et al. *Surgery of the Neonate*. Boston, MA: Little, Brown and Co; 1978:204-233
- Harrison MR, Golbous MS, Filly BA, et al. Fetal hydronephrosis: selection and surgical repair. *J Pediatr Surg*. 1987;22:556-558
- Kirks Dr, Merten DF, Grossman H, et al. Diagnostic imaging of pediatric abdominal masses: an overview. *Radiol Clin North Am*. 1981;19:527-545
- Siegel MJ, Claiborne AK. Imaging of abdominal and pelvic masses in children. *Curr Probl Diagn Radiol*. 1985;14:1-48
- Stevenson RI. Abdominal masses. *Surg Clin North Am*. 1985;65:1481-1504

## Self-Evaluation Quiz

7. More than 50% of neonatal abdominal masses originate from which of the following sites?
  - A. Renal system.
  - B. Genital tract.
  - C. Gastrointestinal tract.
  - D. Retroperitoneal (nonrenal).
  - E. Liver, biliary tract, and spleen.
8. An abdominal radiograph of a newborn with an abdominal mass is likely to show abnormal calcifications in each of the following except:
  - A. Neuroblastoma.
  - B. Teratoma.
  - C. Hepatoblastoma.
  - D. Hydronephrosis.
  - E. Meconium peritonitis.
9. When evaluating neonatal abdominal masses, which of the following should be done first?
  - A. Computed tomography.
  - B. Abdominal radiograph and ultrasound.
  - C. Magnetic resonance imaging.
  - D. Radionuclide scan.
  - E. Intravenous pyelography.
10. Each of the following are advantages of abdominal ultrasound, except:
  - A. Harmless.
  - B. Less expensive.
  - C. No sedation.
  - D. Able to perform at bedside.
  - E. Ability to scan through bone and gas.
11. Each of the following is a true statement about the prenatal diagnosis and management of fetal abdominal masses, except:
  - A. The increased use of fetal ultrasound has provided an opportunity to prenatally diagnose abdominal masses.
  - B. Prenatal management of fetal intraabdominal masses is largely obstetric in nature.
  - C. Patients with unilateral renal disease are best managed after term delivery.
  - D. In utero urinary tract decompression should be considered a standardized procedure of proven value.
  - E. Successful treatment of fetal urinary tract obstruction has been limited by the inability to select the appropriate fetus for intervention.