

# PLASTIC REPAIR TECHNIQUES: Skin Plasties and Local Flaps

*Thomas J. Chang, DPM*

*Elaine G. Stanifer, DPM*

*A. Louis Jimenez, DPM*

## INTRODUCTION

A variety of plastic surgical techniques may be employed in the covering of a wound defect or revision of a disfiguring scar. Many factors play a role in choosing an optimal procedure, including the size, orientation, anatomic region, and vascularity of the surgical site, as well as the age of the patient.

Whether a scar is excised and revised, or a deficit is remodeled and covered, the ultimate result is the formation of a scar. Optimal scar formation is not only important with regards to the cosmetic result, but more important in terms of the functional result. A large, bound-down scar may cause restriction of motion or loss of weight-bearing capabilities. Careful operative planning leads to a less conspicuous scar with greater functional results.

## DYNAMICS OF SCAR FORMATION

It is well known that a breach in the dermal layer will cause the formation of a scar. The degree to which a scar is formed, and subsequently matures, is dependent upon many factors. Dynamic and static skin forces create tension across a wound site. The greater the tension, the greater the proliferation of scar tissue. Dynamic forces include joint motion and muscle movement. Relaxed skin tension lines (RSTL) are, in general, perpendicular to the axis of motion (joint or muscle). Static tension, which is the natural tension that exists within the skin, varies in different parts of the body. Borges relates that black

patients have a greater tendency to form hypertrophic scars than whites, and that among whites, blondes demonstrate better healing than brunettes. It is possible that the increased tendency for hypertrophic scar formation is related to differences in static skin tension between individuals, however, this has not been proven. He also relates a greater tendency for hyper-pigmentation in Northern Europeans and Latinos.

Both static and dynamic skin tension decreases with age. The response of aged skin, and subcutaneous tissue, to indentation demonstrates a marked decrease in immediate resiliency, when compared to younger subjects. Young children and obese patients form more prominent scars due to the increased tension across the wound site. Children go through periods of growth where there is overactive fibroblastic proliferation.

Regions on the body which are almost guaranteed to form hypertrophic scars are the sternum and shoulder region (deltoid). Again, this tendency is related to a high degree of tension and, in this case, tension exists in all directions, not just in apposition to the RSTL. Different surfaces also influence scar formation. Concave surfaces tend to produce a bowstrung, disfiguring scar. Convex surfaces are generally less disfiguring, unless there is a loss of deep tissue structures.

Accidental wounds (i.e. trauma) do not heal as well as clean surgical wounds, because necrotic, devitalized, tissue will increase the amount of scar tissue proliferation. Often, these wounds have a bevelled edge, or are oblique to the skin surface, producing a wider scar. Wounds that heal

by secondary intention produce a wider and deeper scar than those healing by primary intention. Burn scars demonstrate increased tension in all directions.

The vascular supply of local skin and fasciocutaneous flaps relies principally upon perforating muscle and fascial vessels to supply the dermal-subdermal plexus. This type of blood supply is known as a random pattern. Systemic factors which may delay wound healing include anemia, diabetes, uremia, hyperproteinemia, and scurvy.

In evaluating the age of a cicatrix, a well-defined cycle of maturity is known to occur. In a young, hypertrophic scar, a pink or reddish hue is present which is representative of increased vascularity to the wound site. As a scar matures, it softens and becomes paler, relating to a decrease in vascularity. Scars generally look the worst between two weeks to two months following injury. A keloid, on the other hand, does not follow this same progressive decrease in vascularity and cellularity.

### **TECHNICAL CONSIDERATIONS**

Cross-hatching the proposed incision line with a skin marker is beneficial for a more accurate realignment. A #11 blade is preferred when making sharply angled incisions. The blade should be angled perpendicular to the skin surface, and the skin should be held taut and firm while making the incision.

The specific suture material used is not critical to the final outcome. According to Borges, the result depends less on the type of suture used, than on the direction and location of scar revision, as well as the surgical technique. He prefers braided 6-0 silk on the face, and a larger suture (5-0, 4-0) in areas requiring greater tensile strength. Silk is preferable, due to the ease of tying and wound edge adjustment. One method of wound closure places the first suture in the middle of the incision and the next two at midway points. Wounds sutured in line with RSTL need less sutures than anti-tension line (ATL) sutures.

In regards to hemostasis, bleeding should be controlled to prevent the formation of a blood clot beneath the skin. A clot separates the walls of the wound, and interferes with blood flow to the area. They can also act as a foreign body, and

provide an excellent culture medium for the growth of bacteria. At the other extreme, excessive use of suture ligatures adds additional foreign debris to the wound, and the over-utilization of hemostats for hemostasis will inflict unnecessary trauma to the tissues. Furthermore, electrocoagulation creates charred tissue, which increases the repair load on the body.

### **HYPERTROPHIC SCARS AND KELOIDS**

The distinction between hypertrophic scar and keloid formation is often difficult to ascertain. Comparing the scar to that of a healed wound in another part of the body may help to distinguish the type of scar. A hypertrophic scar is limited to the tissue which constitutes the wound. Keloids, however, extend beyond the boundary of the wound and produce tumor-like appendages in surrounding tissue. They grow slowly, and years may elapse before they reach maximal dimensions. Spontaneous resolution is rare. Hypertrophic scars are paler, softer, and less noticeable over time, and complete maturation may occur over several years. Keloids are most commonly encountered in young, dark-skinned, persons between 20 and 30 years of age. In keloid revision, compression and immobility are key to successful or improved outcome. Baker and Smith have reported initial success by applying silicone gel sheeting to hypertrophic scars and keloids.

### **TECHNIQUES FOR SCAR REVISION**

A scar may be revised and improved, but not erased. Disfiguring scars develop from increased tension on the wound, which is largely due to the dynamic forces below the skin surface (muscle and joint movement). RSTL generally run perpendicular to the longitudinal axis of muscle. The resultant motion causes an increase in connective tissue proliferation.

The primary objectives of scar revision are to redirect the scar into a position of increased dynamic activity (or closer to RSTL), to divide the scar into smaller components, and to achieve a leveling effect. Secondary benefits of scar revision may include improvement in the condition of the wound, camouflaging, and the creation of elasticity. Common techniques for scar revision include simple excision and "Z", "W", or "M" geometric

broken line plasty. It is best to choose a revision technique that optimally improves a particular scar, i.e. the arms of a Z-plasty follow RSTL as much as possible.

### FUSIFORM EXCISION OF A SCAR

This is the oldest technique used in the treatment of a linear scar, and repair of small defects. It involves the excision of a fusiform segment of tissue with direct apposition of skin borders. Although the term "elliptical" has been used interchangeably with fusiform, they are not synonymous. (Figure 1) Fusiform excisions are used primarily where the long axis closely approximates the RSTL. (Figure 2)

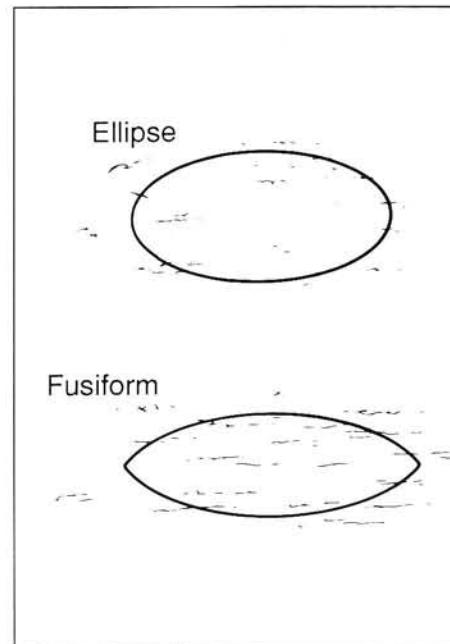
The usual length:width ratio equals 4:1, and undermining is performed on either side of the incision. If at least a 4:1 ratio is not maintained, closure is more difficult, creating excessive tension on the wound, with dog ear formation at either end of the incision. Normal tissue is sacrificed, therefore, this technique is limited to regions of greater mobility and elasticity.

### The "Z-Plasty"

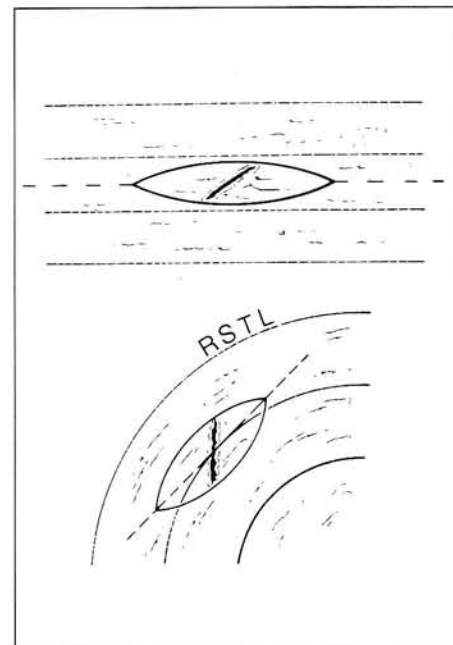
The Z-plasty technique allows for re-direction and elongation of a scar without excision of normal tissue. The central arm of the "Z" lies along the line of contracture to be released or lengthened. A helpful analogy was introduced by McGregor, in which he refers to the Z-plasty as a parallelogram. The short diagonal line of the parallelogram corresponds to the central arm of the Z, and is referred to as the "contractural" diagonal. The longer diagonal is the "transverse" diagonal. When the Z-plasty is performed, increase in the length of the contractural diagonal will occur at the expense of equal shortening of the transverse diagonal. (Figure 3)

The broad spectrum of Z-plasty applications extends to inelastic tissue where skin needs to be deeply planed, and in burns where the prime objective is to preserve tissue. The arms and central limb of each Z-plasty should be of equal length. The central limb should always fall over the scar. The arms should approximate RSTL as close as possible, but not exceed a 60 degree angle.

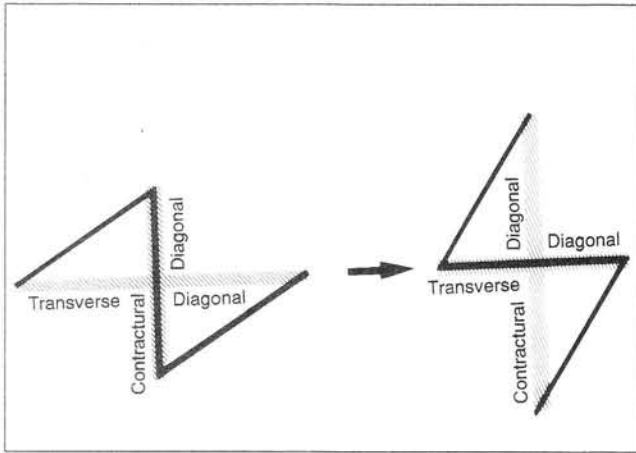
Although the surgeon is generally interested in gaining length, it is crucial that transverse slack



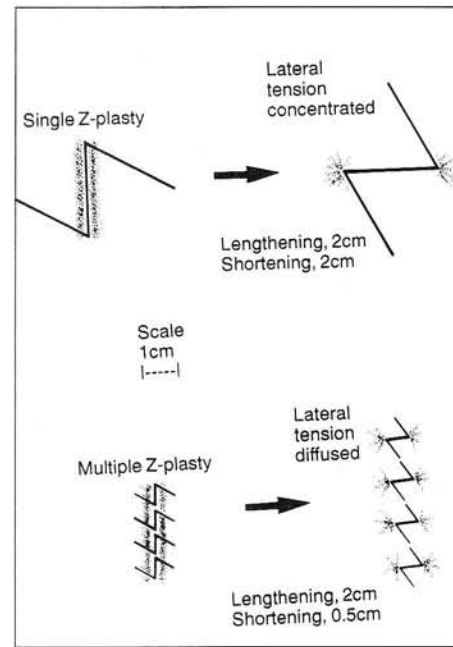
**Figure 1.** Although the terms are used interchangeably, elliptical and fusiform lesions each have different configurations.



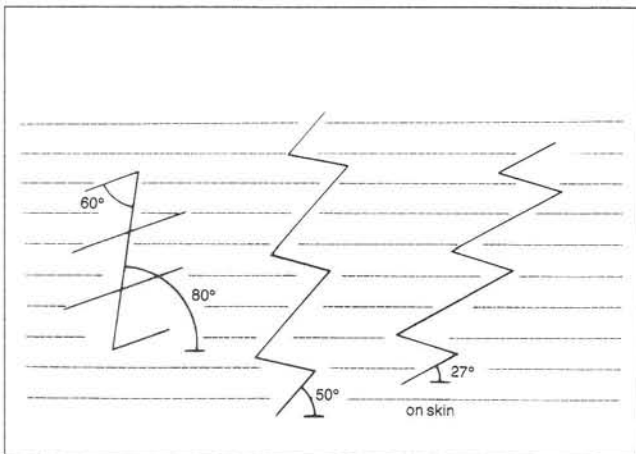
**Figure 2.** Alignment of the long axis closely approximating RSTL. This method is preferred for optimal scar placement.




**Figure 3.** Transverse and contractural diagonals associated with Z-plasty technique.



**Figure 4.** Sequence of multiple Z-plasties used to reduce transverse shortening without compromising the desired lengthening.



**Figure 5.** Reorientation of an old scar using multiple Z-plasty technique in an attempt to parallel RSTL.



**Figure 6.** Illustration of running W-plasty technique in an attempt to parallel RSTL.

is available for this method to work. Occasionally the situation arises where the resultant shortening within the transverse diagonal compromises vascular or functional capabilities. The search for a method of reducing the amount of transverse shortening, without compromising desired lengthening, has led to the development of the "multiple Z-plasty". Dividing one single Z-plasty into multiple Z-plasties in a series, where the central limb lies on the same axis, will effectively reduce the transverse shortening proportionately by the same amount. (Figure 4)

Multiple Z-plasties are also useful in the reorientation of an unsightly scar. Theoretically, an

almost vertical scar (80 degrees from RSTL) can be divided into 2 new scar orientations; one closely paralleling RSTL, and one running obliquely, but closer to RSTL, than the original scar (50 vs 80 degrees). Dividing a lengthy scar into multiple Z-plasties will decrease the transverse tension on the skin. The cosmetic result is further improved due to the added length in the direction of tension. This creates a bunching-up of the triangular flaps, with subsequent narrowing of the angles (27 vs 50 degrees). (Figure 5) The decrease in tension created by the elongation of tissue contributes to the overall improvement. Scars orientated 60 degrees or less to RSTL will

result in oblique scars which are in the same direction as the original scar, after transposition.

Two other skin plasty techniques deserve mentioning and are included below for completeness. These techniques have been used primarily in facial surgery, however, the plastic principles behind their design are fundamental to understanding manipulations of RSTL and scar placement.

### **The Running W-Plasty**

The running W-plasty is a method of scar excision which employs a sequence of 60 degree triangular flaps. In addition to excision of the scar, a portion of normal surrounding tissue is also excised. For this reason, it is not indicated for use in regions of skin inelasticity and limited mobility. The greater the angle used, the greater the percent of tension reduction. However, angles greater than 60 degrees increase the chance of ischemia. Uniformity in the reduction of tension occurs where all of the angles are oriented at 60 degrees. With a near vertical scar (80 degrees to RSTL), a running W-plasty can theoretically improve scar orientation 20 and 40 degrees to RSTL. The distal ends, however, will follow the original direction of the cicatrix. (Figure 6)

Technical points to keep in mind while performing the running W-plasty are as follows. The base of the last triangle at each end should be perpendicular to the scar, while the tip of each triangle should be parallel to the scar. The length of each triangular segment varies, depending on the size and location of the scar (between 5 and 7 mm on facial tissue). The larger the segments, the greater percentage of normal surrounding skin excised, and the greater the tension across the wound. Smaller segments make for less conspicuous scars.

### **Geometric Broken Line Plasty**

The geometric broken line closure consists of varying combinations of triangular, square, and rectangular interposed flaps. The intention is to divide the scar into smaller and more varying components, thus increasing the camouflage effect. A criticism of the W-plasty is its predictable and regular pattern, which is more readily noticeable. This can be a time-consuming procedure and is more practically performed with running W-and Z-plasties. As with the W-plasty, the exci-

sion of surrounding normal tissue is required, and it is not indicated in areas of extreme tissue loss. In facial work, the largest flap should be no greater than 6 mm in length or width.

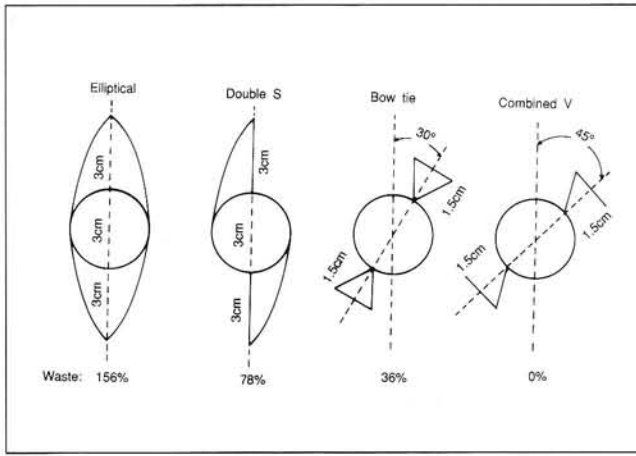
Circular scars, which commonly produce a "trap-door" effect, are more challenging to revise and have a high rate of recurrence with simple excision. Concentric, contractural skin forces cause a piling-up of tissue in the curved flap, giving rise to outward bulging or the "trap-door" effect. The circular pattern needs to be broken up, and the geometric broken line and running W-plasty combination provides a more successful revision.

## **CIRCULAR DEFECTS**

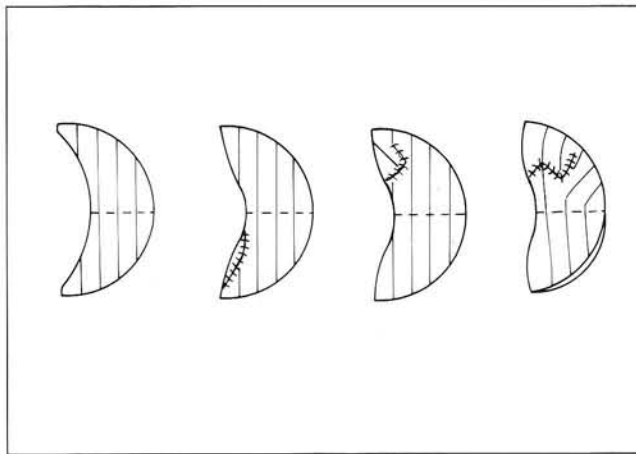
Ulcers and other various skin lesions commonly found on the lower extremity may require excision as the treatment protocol. In excising skin lesions, the ideal incisional approach should be circular. Since most skin lesions are round, this approach provides equal margins of resection while saving as much normal skin as possible.

Difficulty in primarily closing a circular defect is often encountered. In certain circumstances, only partial closure may be achieved before tension on surrounding tissue is affected. The traditional approach to primary closure of a circular defect entails the removal of a fusiform segment of skin. Although closure with this technique is a viable option, the ratio of normal skin loss to the original defect is 3-4:1. The normal skin which is lost can be used more effectively to reduce tension along the suture lines.

Alvarado, in 1981, presented "reciprocal incision" techniques for the closure of a circular defect. He compared and contrasted the traditional fusiform ellipse with four variations of circular skin closure. Objective analysis of these techniques included the following parameters: size of skin extension, length of suture lines, waste of normal skin, measurements of tissue after closure, profile and plasticity of the suture line, and tension at the suture line. (Figure 7A-C) For a cosmetic and functional wound closure, the most significant parameters described are the profile and plasticity of the suture line. Flat lesions provide the most optimal profile and plasticity of the closure, which is inversely related to wound tension. The "combined V" approach is attractive due to



**Figure 7A-C.** Alvarado's description of reciprocal incision techniques for revision of circular defects. A. Surgical planning with skin dimensions illustrated.

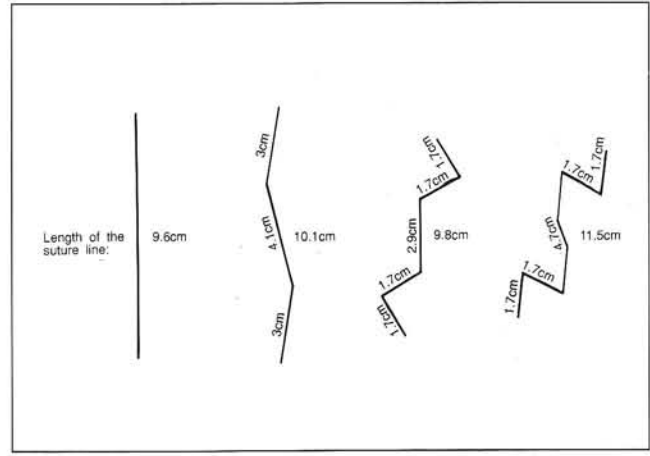


**Figure 7C.** Side profile demonstrating scar contracture.

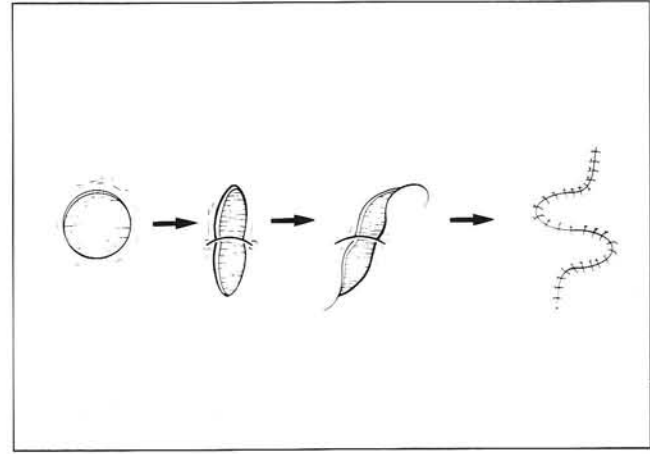
the fact that no good skin is excised for closure of the defect. The profile and plasticity of this technique is superior to the other techniques discussed.

The "double S" and "bowtie" closures offer intermediate tension between the fusiform skin excision and the "combined V". In the authors' experience, the central arm of the "double S" is placed under considerably more tension than the peripheral arms during suturing. Care must be taken to achieve exact wound apposition in order to minimize dehiscence. Bolster sutures have been utilized for this technique with good success. For small to intermediate-sized circular defects, these approaches are indicated. For larger lesions, particularly in an effort to completely negate any further tissue loss, the "combined V" technique is ideal.

Arnold and Bennett recently described a double-transpositional flap for circular defect clo-



**Figure 7B.** Excision of circular defect and wound closure configuration.

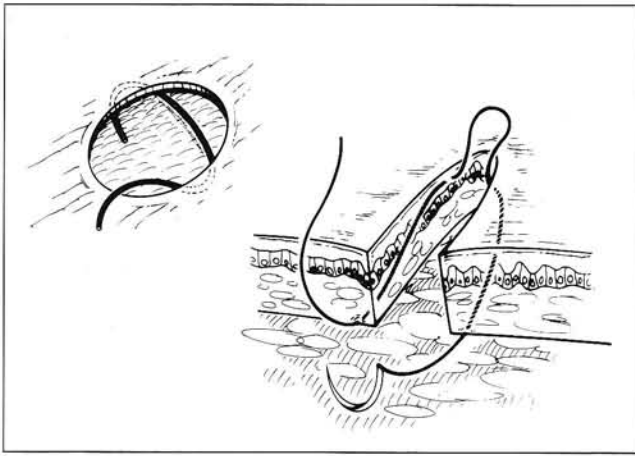


**Figure 8.** Double transpositional flap technique. Note the use of dog-ears to assist in wound closure.

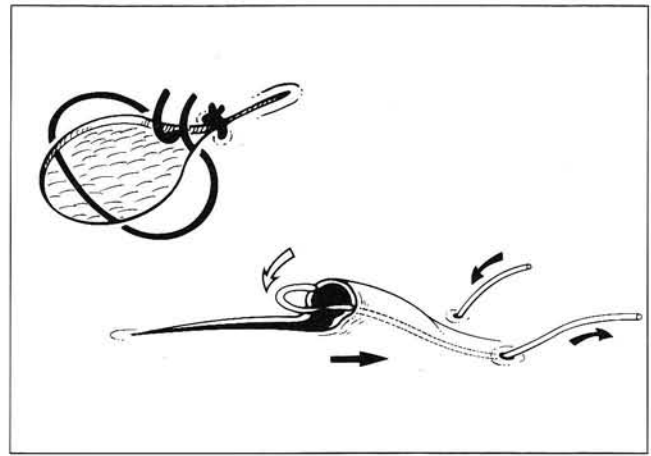
sure. This technique takes advantage of resultant "dog-ears", and utilizes them to assist in wound closure. This technique also minimizes the sacrifice of additional normal tissue by transpositional flaps, rather than rotational flaps. This is ideal for relatively small defects in inelastic areas such as the anterior aspect of the leg. (Figure 8)

Another unique technique described by Stewart in 1992 is termed a "tissue sparing repair". This repair uses primary closure to make a circular defect into a line. While a fusiform excision of a circular defect leaves a repair:lesion ratio of 3-4:1, this repair leaves a ratio of 1.5:1. The obvious advantage is a smaller scar, and this technique is useful where a fusiform excision is not possible. Two new suture techniques, the horizontal oblique dermal suture and the apex cutaneous suture are illustrated in Figure 9A and 9B.

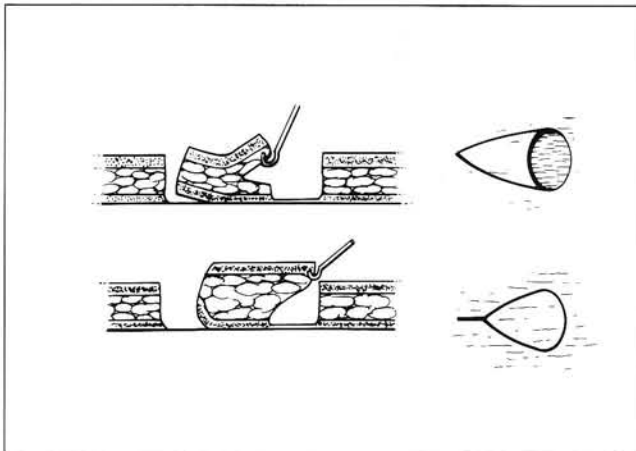
Primary closure, which is performed parallel to RSTL, is ideal in regions possessing adequate



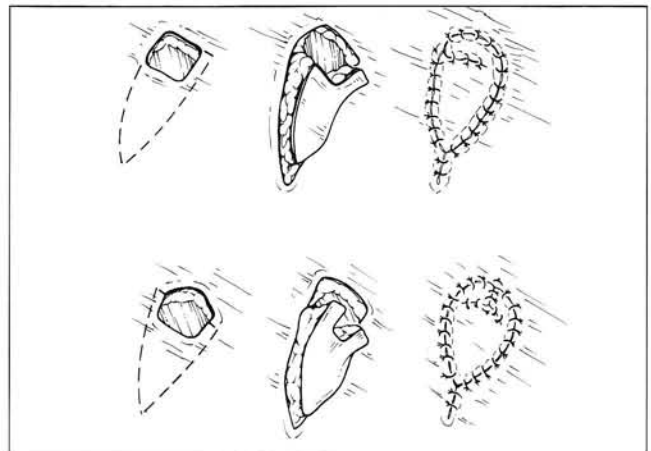
**Figure 9A.** Horizontal oblique dermal suture. Note the oblique pass of the suture within the dermal layer. The knot is buried deep within the skin.



**Figure 9B.** Apex cutaneous suture. Proper placement of the suture will effectively repair the dog-ear created.



**Figure 10.** Cross-section illustrating movement of an advancement flap.



**Figure 11.** Illustration of single arm (top) and double arm (bottom) extended V-Y flaps, used where limited mobility of tissue exists.

skin flexibility. An area with extremely thin or thick dermis/epidermis, such as the plantar aspect of the foot, is not amenable to a tissue-sparing repair technique. When applicable, this new technique closes cutaneous wounds with no normal tissue loss, and less tissue movement than a flap or a graft.

## FLAPS

The same principles for incision placement are followed in wound coverage techniques using local flaps. The V-Y advancement flap is simple in its use and design. It can cover a range of small and large defects and may also be used for re-advancement one or more times. The degree of mobility of a V-Y advancement flap is dependent upon the laxity of the underlying subcutaneous tissue. In areas of limited mobility, where a single V-Y flap might be placed under excessive tension,

a double flap may be a viable option. The posterior, medial, and lateral aspect of the heel are areas of inelastic, but mobile tissue.

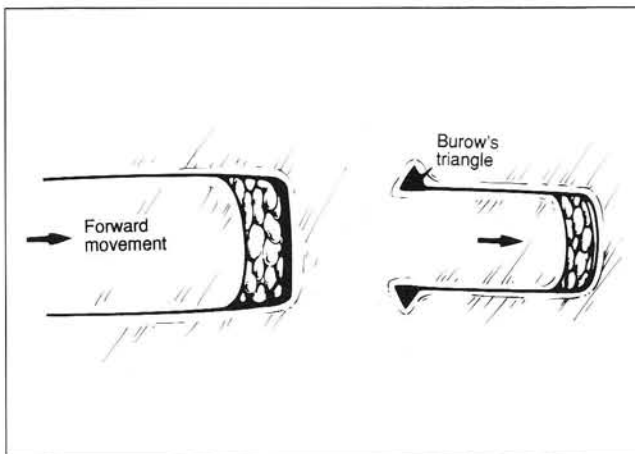
The long axis of the flap should be in the direction of maximal mobility, or as close to it as possible. Surrounding structures frequently preclude the use of skin in the most optimal direction. The triangular flap is designed to be 1.5 to 2 times the length of the defect diameter, in the plane of advancement. The base of the triangle equals the perpendicular diameter of the defect. The pedicle is made as broad as possible, and is undermined deep to the fascia. The advancement portion (base of the triangle) is undermined less extensively, and splits the subcutaneous tissue. Undermining is continued until the flap moves freely into the defect. (Figure 10)

The extended V-Y flap is a modification of the standard V-Y flap. This modification is necessary in situations where there is limited mobility

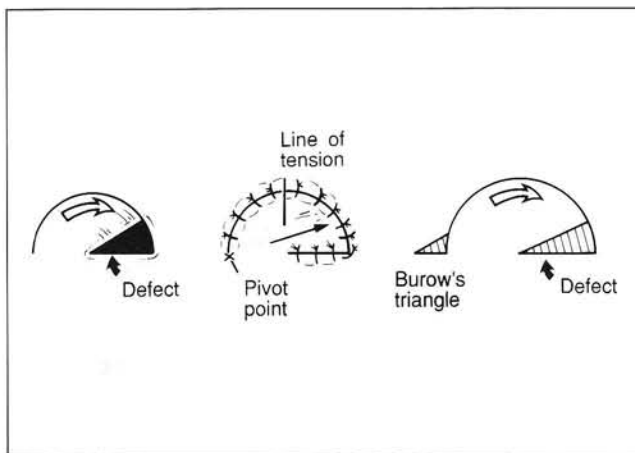
of the subcutaneous tissue. An extension is made at the base, where the diameter is increased for one or two additional arms (extensions). (Figure 11) Complications can occur with this type of procedure in areas of inelastic skin, where excess tension can cause necrosis of the tip. Dog ears are common at the base of the transposed extension, but according to Pribao et al., they spontaneously resolve without further revision.

Another flap design is the rectangular advancement flap. (Figure 12) This flap is predisposed to dog ear formation at its base, requiring the use of a Burow's triangles for remodeling. These triangles also function to relieve excess tension from the skin edges.

The pantographic expansion technique eliminates the formation of dog ears by its inward slits and expanded base. (Figure 13) However, even with its wider base, this technique runs the risk of damaging the vascular supply with the possibility of flap failure.



**Figure 12.** Burow's triangle used to facilitate wound closure.



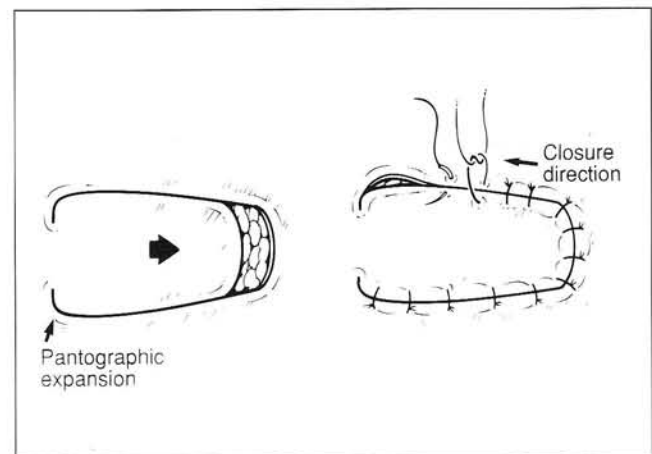
**Figure 14.** Application of Burow's triangle, used to relieve skin tension in a rotational flap.

Rotation flaps may be used to cover circular or triangular defects. (Figure 14) These flaps require both rotational (primary) and advancement (secondary) movement. Again, dog ears commonly occur at the pedicle bases, and can be eliminated by the use of simple Burow's triangles.

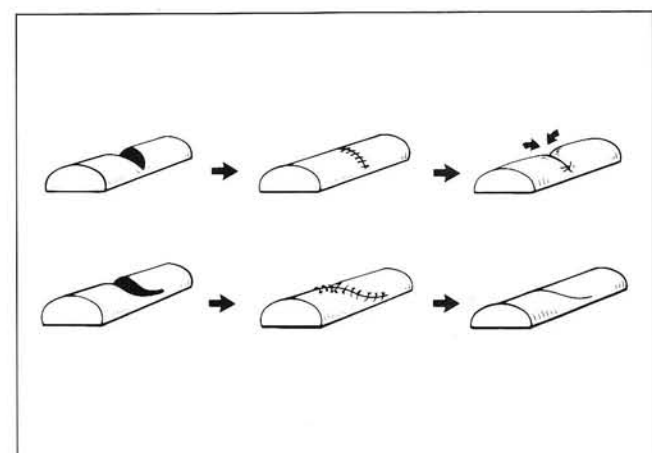
## DOG EARS

"Dog-ear" is a term which describes the bunching-up of skin when closing a wound. Commonly, these are redundant aggregations of skin created by forced movement of tissue. Although skin is extremely malleable, areas of tissue redundancy only become significant dog-ears when the visual absorbing limits of skin have been exceeded. The degree of tissue redundancy will vary primarily with patient age and anatomic site.

Several basic points can be stated concerning minimizing the potential of dog-ear formation. First, careful incision planning and placement can



**Figure 13.** Pantographic expansion, used to facilitate closure while minimizing dog-ears.



**Figure 15.** Placement of curvilinear incision over convex surfaces to prevent scar depression.



reduce dog-ear occurrence, especially on a convex surface. When a standard fusiform excision of skin is performed on a convex surface, there is a tendency for flattening of the wound in the center, with dog-ear formation at each end. A common example of this is observed when performing a simple ellipse in hammertoe surgery. To decrease general wound tension during closure, a safe guideline to follow is a length:width ratio of at least 4:1. If the long axis of the fusiform excision is too short in relation to the short axis, dog-ears will form at the extremities of the sutured wound. One common technique in repair consists of extending the excision of tissue in the same direction as the long axis, thus actually increasing the length:width ratio of the original defect. A golden rule in wound closure is to avoid dog-ears, even at the expense of lengthening the wound.

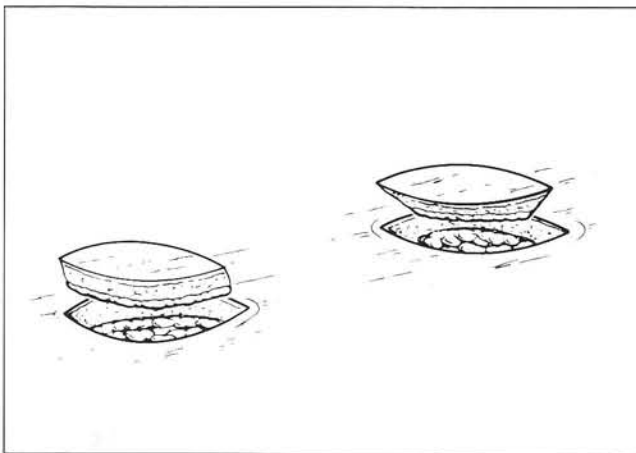
Although planning a closure with adequate length is important, the surgeon must also consider the effects of wound contraction during healing. A linear wound on a convex surface will tend to contract and result in a depressed scar. The depressed center also accentuates the dog-ear. An "S" shaped fusiform excision with the same end points can avoid this phenomenon. As this scar heals and contracts, the scar will tend to straighten rather than become depressed. (Figure 15)

A skin excision technique is another important aspect of addressing a dog-ear. It is a common error to change the angle of the blade tip when approaching the tip of a fusiform defect. The result is a skived skin border with excess

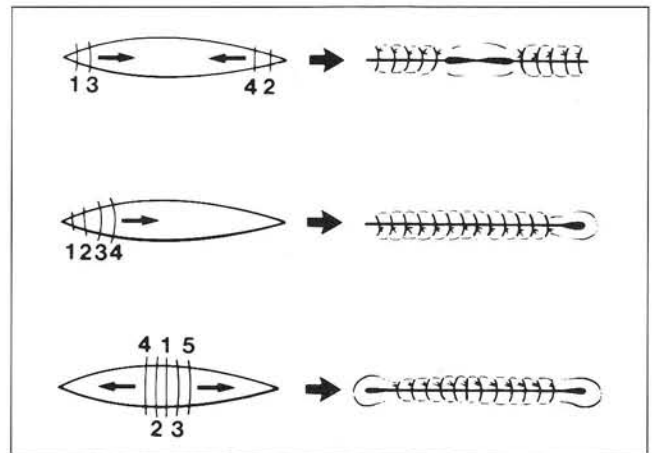
subcutaneous tissue and dermis left behind. The excessive amount of deep tissue will elevate the skin at the tips, and can contribute to dog-ear formation. The technique of orienting the scalpel blade 90 degrees to the skin is illustrated in Figure 16.

Proper undermining can also help to minimize dog-ear formation. The length of the outside curve in a fusiform defect is always greater than the distance between the two ends. When the wound is sutured together, there is a pushing away of tissue from the wound center along the long axis, with a tendency to increase the distance between the ends. When the elastic limit of the skin is exceeded, the tissue will tend to protrude upward or downward, producing a dog-ear. Undermining the tip and edges will allow the tissues being pushed away to move horizontally, thus preventing dog-ear formation.

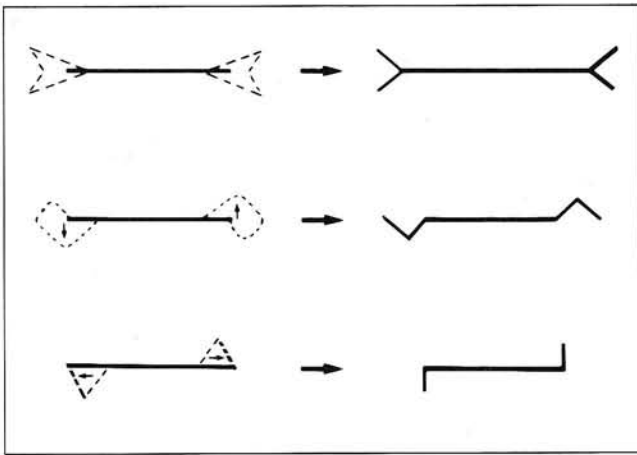
When faced with a fusiform defect to close, one can anticipate and prevent a dog-ear by the direction of suturing. Dog-ears will tend to be "pushed" in the direction of suturing. Suturing from each end, towards the center, will push a dog ear towards the center, while suturing from the center outward will create dog-ears at the edges. Several techniques, in addition to undermining, are illustrated in addressing dog-ear formation along the wound line. Selection of the best cosmetic technique also depends on the relaxed skin tension lines. Regardless of the orientation of the long axis of the original defect, the long axis of the fusiform excisions for dog-ear repair should parallel the RSTL. (Figure 17A-C)



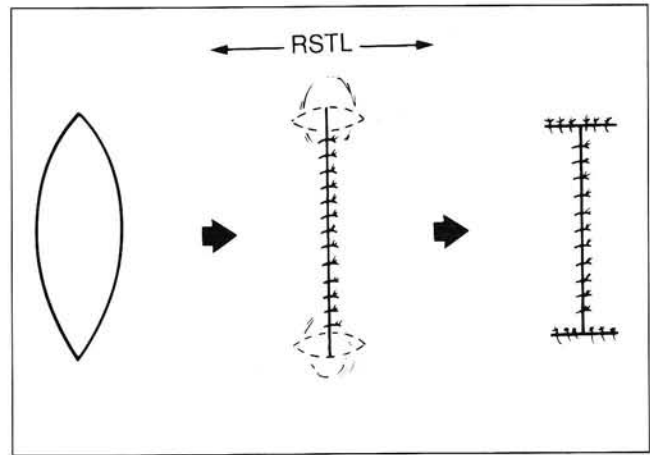
**Figure 16.** Proper (left) and improper (right) techniques in excision of full-thickness defect.



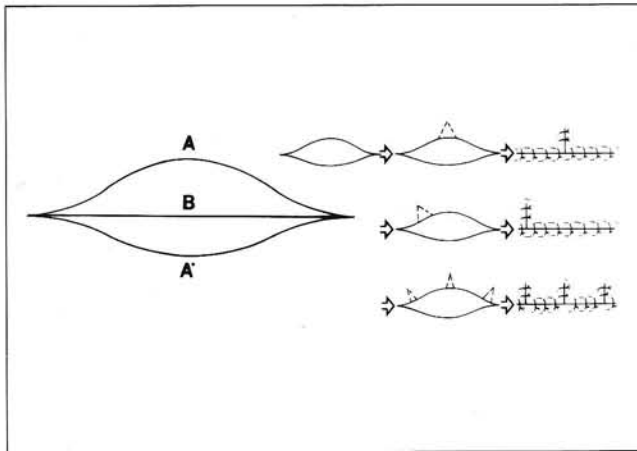
**Figure 17A-C.** Techniques for control of placement and excision of dog-ears. A. Dog-ear formation is influenced by the direction of suturing.



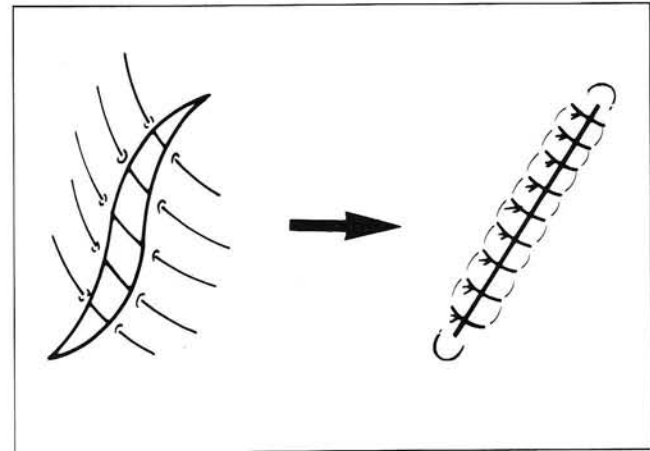
**Figure 17B.** Three illustrations used for excision of dog-ears.



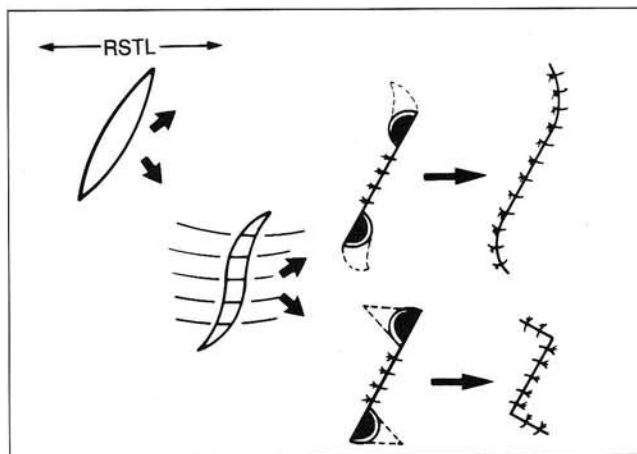
**Figure 17C.** Placement of dog-ear excision along RSTL, when possible, will minimize scar formation.



**Figure 18.** Use of Burow's triangle is helpful when confronted with fusiform defects of unequal length.



**Figure 19A.** Direction of suture required for wound closure without dog-ear formation.

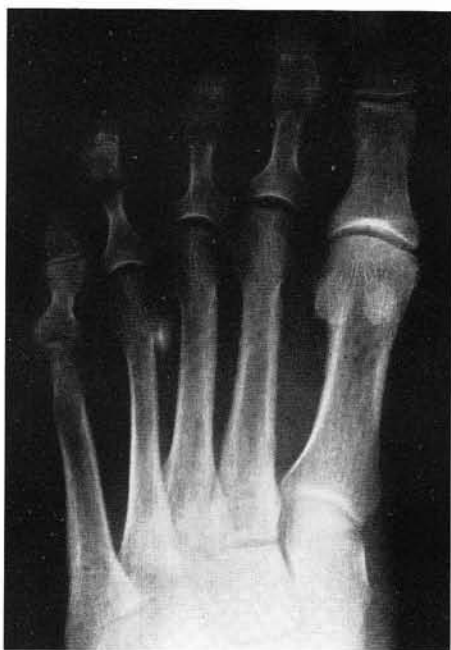

**Figure 19B.** Techniques for revision of dog-ears formed by alternative suture technique.

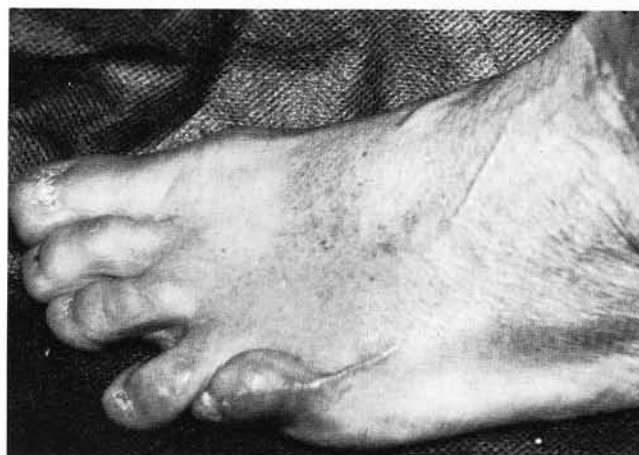Certain fusiform defects will present with unequal length tissue edges, which adds another twist to wound closure. Three lengths must be reconciled in this situation: the two different wound edges, as well as the intermediate length long axis. Redundant tissue will develop from attempting to match not only each edge to the long axis, but also from matching the edges to each other. The goal is to remove a sufficient amount of tissue from the longer edge, to permit apposition to the shorter edge without visible bunching. Single or multiple Burow's triangles can be utilized along the longer edge until a cosmetic wound closure is achieved. (Figure 18)

Dog-ears can also appear when a wound is not properly sutured. This occurs most commonly with fusiform or straight defects oriented oblique to the RSTL. Due to the tension on the skin, these defects will appear as an "S-shaped" incision. If the defect is not too wide, correct wound closure should not create dog-ears. Commonly however, the skin borders of the defect are sutured in a simple straight advancement technique parallel to RSTL, while the incision is oblique to the RSTL. To avoid dog-ears in this situation, the concave border segments of the "S-shaped" fusiform defect must be pulled towards the center of the wound. (Figure 19)

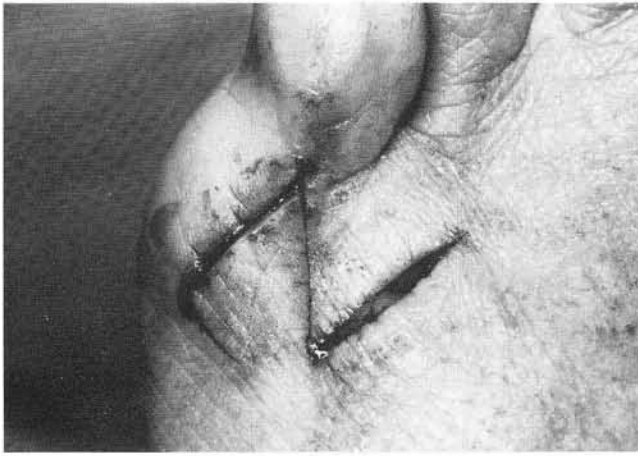
### CASE STUDY #1



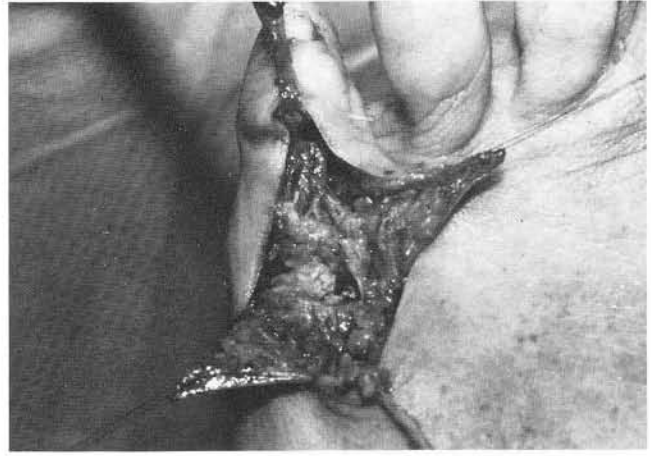
**Figure 20.** DP radiograph of a 41-year-old male who presented with a 5th digital contracture at 8 months postoperative tailor's bunionectomy.



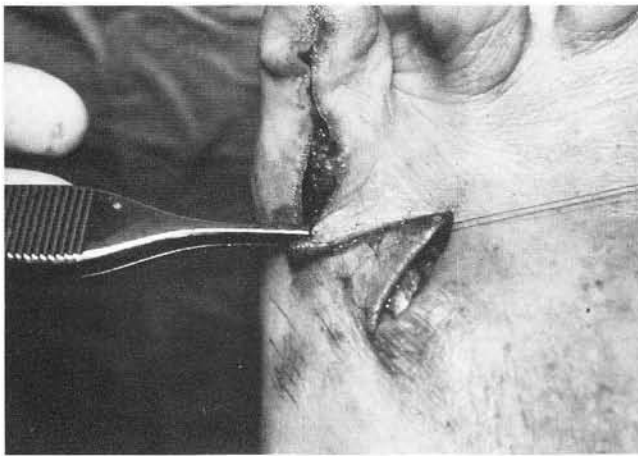
**Figure 21.** Contracted fifth digit with involvement of the fourth digit as well.



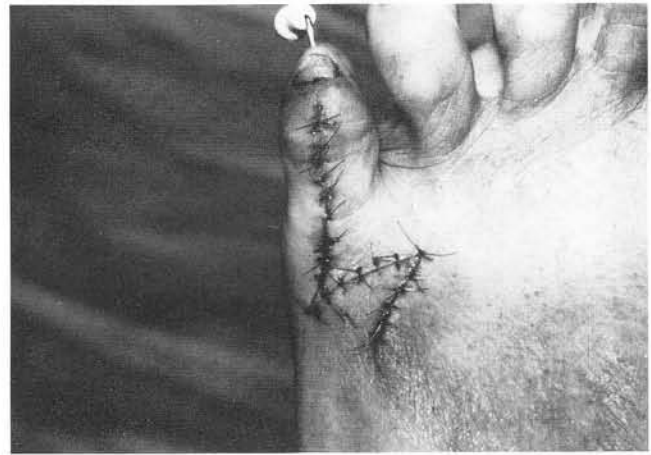**Figure 22.** The central arm of the Z-plasty is placed along the previous scar. This is always directed along the axis of intended lengthening.



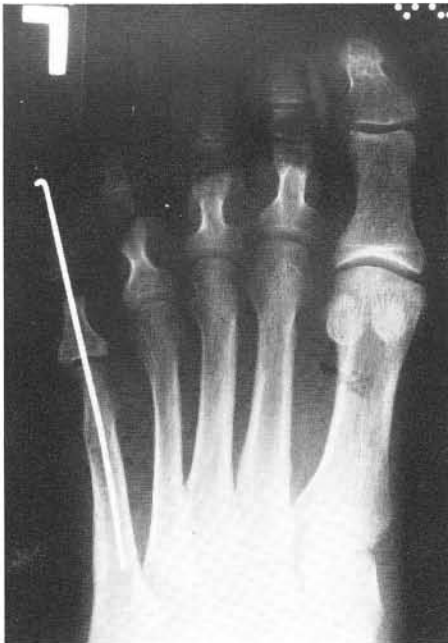**Figure 23.** Reflection of the flaps for exposure and release of soft tissue contractures. A Z-lengthening of the extensor tendon with further de-lamination of soft tissues was essential for complete release. A PIPJ arthroplasty was also performed to assist relaxation, and a K-wire was used to maintain stability of the digit.



**Figure 24.** Transposition of the flaps is performed.

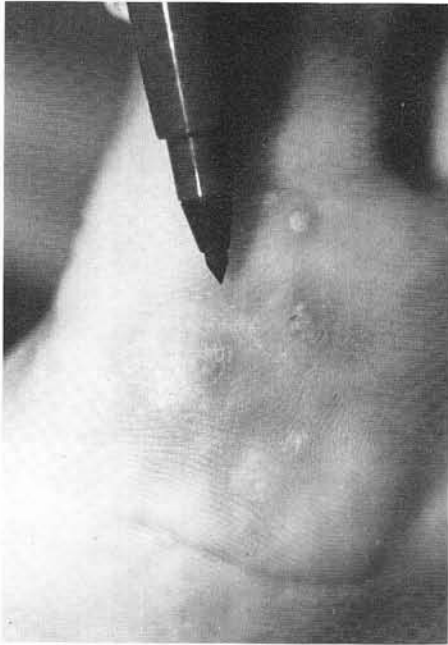


**Figure 25.** Appearance after skin closure.

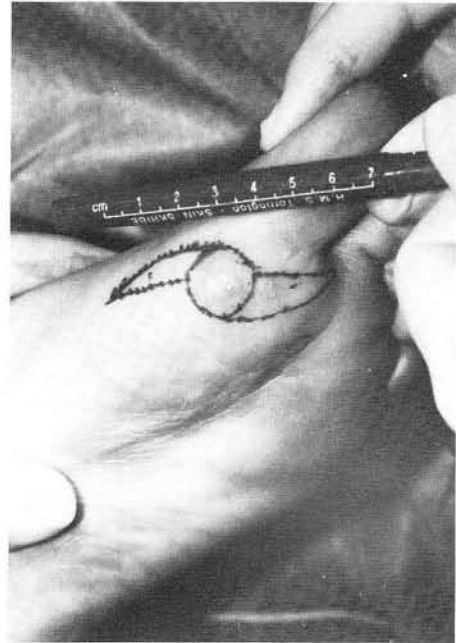


**Figure 26.** Postoperative radiograph demonstrating alignment of the digit and position of K-wire.

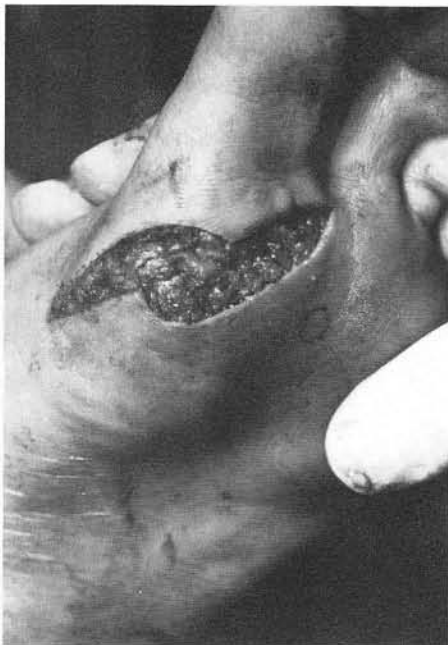## CASE STUDY #2



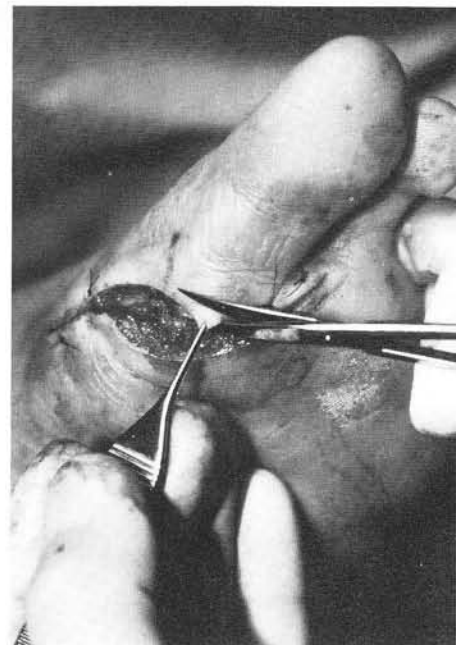
**Figure 27.** A 22-year-old female presented with a painful plantar verrucae of several months duration. Plantar satellite lesions are also noted.



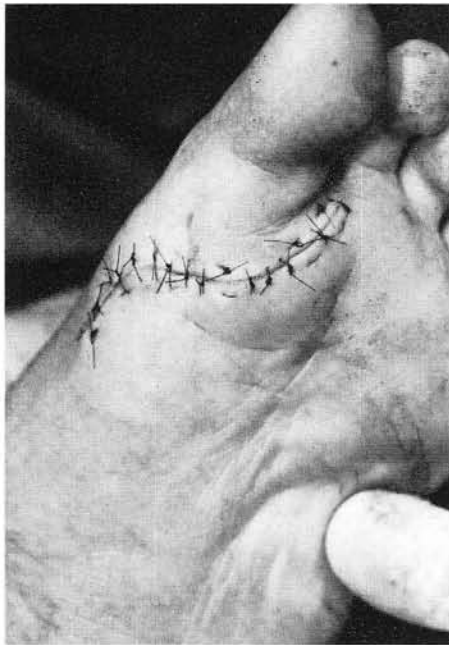**Figure 28.** A Double-S approach is planned in an effort to minimize excision of normal soft tissue. This approach sacrifices one-half of the normal tissue as compared to a traditional fusiform excision.



**Figure 29.** Excision of the skin to the level of the subcutaneous tissue. Undermining is carried out to facilitate skin movement and closure.



**Figure 30.** The pointed edges are excised for proper contouring prior to closure.



**Figure 31.** Closure is performed with simple interrupted and horizontal mattress stitches. Mild tension is placed on the central incision, evidenced by skin blanching.

## BIBLIOGRAPHY

- Alvarado A: Reciprocal Incisions for Closure of Circular Skin Defects. *Plastic Reconst Surg* 67(4):482-490, 1981.
- Arnold A: The Bilateral Dog-Ear Transposition Flap. *J Dermatol Surg Oncol* 16(7):667-671, 1990.
- Ausin A: The "Trap-Door" Scar Deformity. *Clin Plastic Surg* 4(2):255-261, 1977.
- Baker JE, Smith TF: Management of Keloids and Hypertrophic scars. In Ruch JA, Vickers NS (eds) *Reconstructive Surgery of the Foot and Leg, Update '92* Tucker, GA, Podiatry Institute Publishing, 1992, pp. 382-386.

- Borges AF: *Elective Incisions and Scar Revisions*. Boston, Little, Brown and Company, 1973.
- Borges AF: Scar Analysis and Objectives of Revision Procedures. *Clin Plastic Surg* 4(2):223-237, 1977.
- Borges AF: Historical Review of Z-Plastic Techniques. *Clin Plastic Surg* 4(2):207-216, 1977.
- Borges AF: The W-Plastic versus the Z-Plastic Scar Revision. *Plast Reconst Surg* 44(1):58-62, 1969.
- Borges AF: Dog-Ear Repair. *Plast Reconst Surg* 69(4):707-713, 1982.
- Dockery GL, Christensen JC: Principles and Descriptions in Design of Skin Flaps for Use on the Lower Extremity. *Clin Pod Med Surg* 3(2):563-577, 1986.
- Dzubow LM: The Dynamics of Dog-Ear Formation and Correction. *J Dermatol Surg Oncol* 11(7):722-728, 1985.
- Flemming JH, Williams HE: Mathematical Analysis of the W-Plasty and Related Revisions. *Clin Plastic Surg* 4(2):275-281, 1977.
- Hinderer UJ: Prevention of Unsatisfactory Scarring. *Clin Plastic Surg* 4(2):199-205, 1977.
- McGregor IA: *Fundamental Techniques of Plastic Surgery (8th ed.)*. Churchill Livingstone, Singapore, 1989.
- Marino H: Levelling of Linear Scars with Z-Plasties. *Clin Plastic Surg* 4(2):239-245, 1977.
- Maruyama Y, Iwahira Y, Ebihara H: V-Y Advancement Flaps in the Reconstruction of Skin Defects of the Posterior Heel and Ankle. *Plast Reconst Surg* 85(5):759-64, 1990.
- Pribaz JJ, Chester CH, Barrall DT: The Extended V-Y Flap. *Plast Reconst Surg* 90(2):275-279, 1992.
- Robinson DW: Simple Revisions of Scars. *Clin Plastic Surg* 4(2):217-222, 1977.
- Stewart JB: Tissue Sparing Repair. *J Dermat Surg Oncol* 18:822-826, 1992.
- Thacker JG, Stalneck MC, Allaire PE, Edgerton MT, Rodeheaver GT, Edlich RF: Practical Application of Skin Biomechanics. *Clin Plastic Surg* 4(2):167-171, 1977.
- Tobin GR, Brown GL, Derr JW, Barker JH, Weiner LJ: V-Y Advancement Flaps. *Clin Plastic Surg* 17(4):727-732, 1990.
- Webster RC: Cosmetic Concepts in Scar Camouflaging-Serial Excisional and Broken Line Techniques. *Symposium Plast Surg* 73:256-265, 1969.
- Webster RC, Davidson TM, Smith RC: Broken Line Scar Revision. *Clin Plast Surg* 4(2):263-274, 1977.
- Zitelli JA: Tips for Wound Closure. *Dermatol Clin* 7(1):123-128, 1989.