

## POST-POLIO SYNDROME AND TENDON TRANSFER AS SURGICAL MANAGEMENT

*Melissa Robitaille, DPM, MS*

Many patients who were diagnosed with poliomyelitis 30 to 40 years ago are currently experiencing increased muscle fatigue, new weakness, and pain. This decline in muscle function frequently affects the patient's ability to ambulate and necessitates additional bracing, assistive devices and possibly surgical treatment. The characteristics of post-polio syndrome (PPS) and tendon transfers for the treatment of weakness and joint instability will be discussed.

In order to understand the possible causes of PPS and to provide the best plan for its treatment, knowledge of acute polio is necessary. Acute anterior poliomyelitis is a viral infection localized in the anterior horn cells of the spinal cord and certain brainstem motor nuclei. Initial invasion of the virus occurs through the gastrointestinal and respiratory tracts and spreads to the central nervous system through a hematogenous route. Once there, neurologic and functional loss occurs as anterior horn cells are damaged, destroying the efferent pathway, and thus the muscle fibers lose their

innervations (Figures 1,2). Asymmetric, flaccid paralysis occurs as well as other lower motor neuron symptoms. Only 1 to 2% of all those infected with the poliovirus develop paralysis. Also, in children, paralysis occurs in 1/1000 case, whereas in adults, the frequency increases to 1/75. It is important to note that patients retain normal afferent/sensory and central neurologic control.<sup>1</sup>

The threat of poliomyelitis in developed countries is practically non-existent today thanks to the development of the Salk vaccine in 1955 and the Sabine oral vaccine in 1961. Polio still continues to be a problem in third world countries where mass immunizations are not always available. Many of those who contracted the disease were able to recover from the resulting paralysis and went on to lead active, normal lifestyles. The potential for recovery of muscle function depends on the recovery of damaged but not destroyed anterior horn cells. Most clinical recovery occurs during the first month after the acute illness and is almost complete within 6

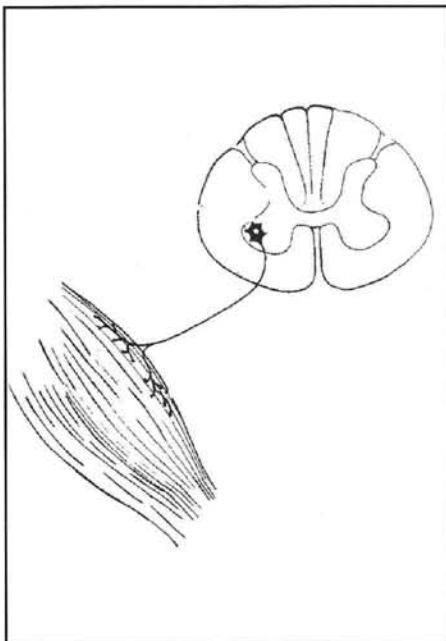


Figure 1. Normal anterior horn cell with its motor-neuron.

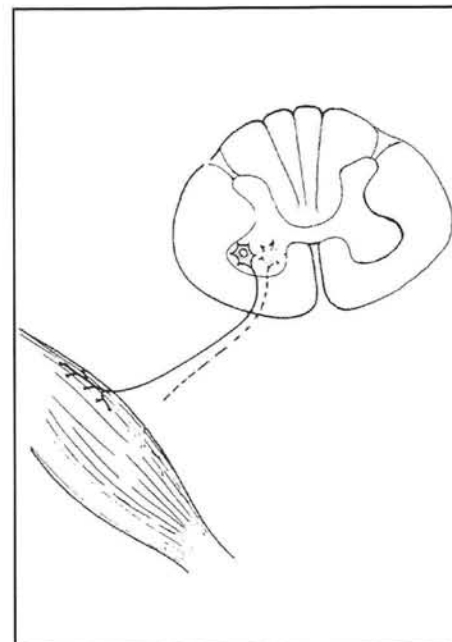


Figure 2. In acute poliomyelitis, the anterior horn cells are destroyed and the muscle fiber lose their innervations creating weakness or paralysis.

months although limited recovery may occur for about 2 years.

The extent of neurologic and functional recovery is determined in part by the phenomenon of terminal axon sprouting where a motor neuron can re-innervate muscle fibers which have lost their nerve supply. In addition to this re-innervation, the remaining muscle fibers hypertrophy to increase the strength of the muscle group. As a result, the survivors of acute polio may be left with a few, significantly enlarged motor units doing the work previously performed by many units.<sup>2</sup>

A survey in 1987 found there were more than 640,000 survivors of paralytic polio in this country. Population based surveys have indicated that as many as 64% of polio survivors develop new symptoms. If we consider these estimates to be accurate, over 400,000 people may experience the late effects of polio. It is important to realize that there are many affected and the possibility of encountering this condition in the office setting is quite likely.<sup>3</sup>

### Post-Polio Syndrome

Today, many of those earlier polio survivors are developing new problems and facing new challenges. These problems typically occur about 30 to 50 years after their initial polio illness and include new weakness, fatigue, pain, functional loss, and cold sensitivity.<sup>4</sup> The cause of these new symptoms is unclear, with many theories regarding the etiology of post-polio syndrome being proposed; however, the pathologic changes that cause the symptoms of PPS have not been proven conclusively.<sup>2</sup> Although many of these etiologies continue to be the subject of debate, the most popular and consistent factors appear to be motor unit dysfunction due to overuse and/or premature aging of large motor units. Following anterior horn cell death, adjacent healthy anterior horn cells assume the function of those ion cells. Subsequently, the metabolic demand placed on them is greater (Figure 3). It is hypothesized that these over-worked anterior horn cells succumb prematurely to the aging process due to greater than normal stress placed on them. Although this hypothesis is attractive to many, it has not been supported by biopsy or direct, conclusive experimental data.<sup>2</sup>

In general, the patients most at risk for developing new problems are those who experienced more severe polio at onset, although some patients with typical post-polio symptoms had seemingly mild polio with excellent clinical recovery. In addition, persons who were older when they contracted polio appear to be at an increased risk for new neurological symptoms. The onset of these new problems is most commonly insidious, but in many persons they are precipitated by specific events such as minor accident, period of bed rest, or weight gain. Patients characteristically say that a similar event several years earlier would not have caused the same decline in health and function. Likewise, new problems may begin when coexisting medical problems such as diabetes develop or worsen.<sup>2</sup>

This seemingly new phenomenon was actually recognized over 100 years ago, with the first descriptions of the disease reported in 1875 in the French literature. Sporadic reports describing similar phenomenon appeared in the literature throughout much of the 20th century. It was not until the early 1980s, approximately 40 years after the major epidemics of the 1940s and 1950s, that post-polio syndrome (PPS) became widely recognized.<sup>5</sup>

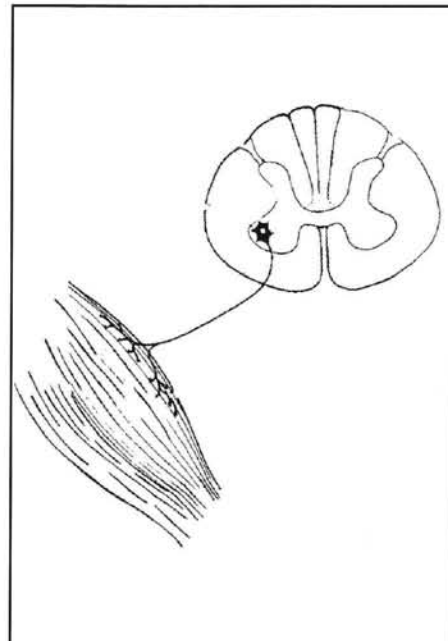


Figure 3. Following anterior horn cell death, adjacent healthy anterior horn cells assume the function of those ion cells.

## Criteria for the diagnosis of PPS

The criteria for the diagnosis of PPS used by most investigators and clinicians were first described by Mulder et al in 1972. These criteria include 1) a documented history of polio (can be confirmed through medical records, neurologic examinations and electromyography showing large polyphasic motor unit action potentials and a decrease in the number of motor units on maximum recruitment in weak muscles with fibrillations); 2) a period (usually >15 yrs) of neurologic and functional stability after recovery from acute illness; 3) the gradual or rarely abrupt onset of new weakness. New neurogenic weakness is essential for making the diagnosis of PPS and presumably reflects continuing dysfunction of previously injured motor units. It is important to make a distinction between new neurogenic weakness versus disuse weakness, which is not always apparent. This can be inferred by the onset of diminished function despite maintaining the usual level and intensity of activity. Finally, 4) the criteria is the exclusion of all other conditions that might cause the weakness or other health problems.<sup>3,6</sup> As previously mentioned, the symptoms of fatigue, joint pain, muscle pain, new weakness, and cold sensitivity are vague and can have a number of differentials. The major differential diagnosis include focal neurologic disease such as a radiculopathy, focal compressive neuropathy, or spinal cord lesion and medical causes of neuropathy such as diabetes, thyroid disease, uremia, alcohol, and hereditary neuromuscular disease. Attempts must be made to rule out other causes of disease since the management of different diseases can vary greatly.

## Physical exam and gait evaluation

Muscles innervated by the cervical and lumbar spinal segments are most often affected, and paralysis occurs twice as often in the lower extremity muscles as in upper extremity muscles. In the lower extremity, the most commonly affected muscles are the quadriceps, glutei, tibialis anterior, medial hamstrings, and hip flexors. The most common deformities of the foot include clawtoes, cavovarus foot, dorsal bunion, talipes equinovarus, and talipes calcaneus.<sup>1</sup>

Because of muscle weakness, gait characteristics in post-polio patients are predictably abnormal. A study by Perry et al found that impaired ankle plantarflexion due to weakness of triceps surae was the most significant indicator of abnormal gait pattern in these patients. This led to a reduced velocity and stride length, which was amplified in fast gait.<sup>5</sup> The significance of this relates to the increased demand of the plantar flexors during the single support phase of stance, since this is when the greatest demand is placed on these muscles. Forward momentum of the body over the supporting foot stimulates action of the gastrocnemius and soleus muscles to control the rate of tibial advancement and maintain stability at the ankle. Likewise, calf muscle action is the only mechanism used for knee stability in normal gait after early mid-stance. The consequence is that a patient with weak plantar flexors has poor tibial control and an unstable ankle joint. Therefore, when the stability of the lower extremity is threatened during single limb stance, the velocity is limited to decrease the chance of falling. Also, the heel cannot rise until the contralateral limb is loaded, so a significant portion of stride length is lost.<sup>5,7</sup>

New muscle weakness usually appears in muscles previously affected with the initial attack, however muscles that were believed to be spared can be affected as well. Because the mechanism of neurologic compensation, previously described, is so effective, a muscle can retain normal strength even after 50% of the original motor neurons have been lost. This is why manual muscle testing in some patients may be normal. These patients manage to function at an extraordinarily high level of performance on relatively few surviving motor units.<sup>8,9</sup> The neurologic examination in PPS is characteristic of a lower motor neuron lesion. The patients will have intact sensorium, flaccid paralysis, diminished reflexes and absence of clonus or Babinsky. Intact sensation helps distinguish PPS from other common differentials such as neuropathy.

It is important for the podiatrist to be aware of this condition, since the treatment differs greatly from that of the initial polio experience. A team approach with the physical therapist, primary care physician, pedorthist, and orthopaedist is vital to the success of the treatment.

## Conservative treatment

Once other causes are ruled out, a distinction between disuse versus overuse weakness needs to be made so that appropriate recommendations regarding exercise and activity can be made. There has been a controversy about management of new weakness with exercise in the post-polio patient because the pathophysiology of PPS remains unclear. Traditional therapy such as exercise may cause further weakness, so it must be used cautiously. There are four possible directions for patient management: muscle strengthening, shortening the duration of effort, substitute devices in the form of orthoses and walking aids, and reconstructive surgery.<sup>5</sup>

Strengthening exercises have been the traditional means of overcoming fatigue and weakness. Workouts under the supervision of a trained physical therapist are absolutely essential for developing and monitoring the best workout program tailored to a particular patient. Muscle pain is considered a contraindication to any therapeutic exercise. Lifestyle modification to reduce the demand on symptomatic muscles including frequent rest periods is also essential. This may often require a change in vocation and/or support from family members.

Orthoses, walking aids, and wheel chairs offer a means of reducing muscular demand while preserving function. The most commonly needed

orthosis is a dorsiflexion-stop ankle-foot orthosis (AFO) to supplement weak calf musculature. To avoid introducing additional strain on the quadriceps, the orthosis also must have free plantar flexion. Persons with combined weakness and knee flexion contractures need a locked knee-ankle-foot orthosis (KAFO). Hip abductor and/or extensor muscle weakness require the use of crutches. If a patient also has insufficient upper body strength, then that patient must progress to a wheelchair.<sup>5</sup>

## Surgical Treatment

Surgery should be used selectively when attempting to improve walking ability. Release or lengthening of contracted muscles is straightforward and necessary when it presents; however, care must be taken not to be overzealous in correction as this may cause an iatrogenic muscle imbalance or instability. Tendon transfers may also be necessary in order to provide joint stability or supplement muscle loss or weakness. As with any other transfer, it is important to establish the viability of the muscle to be transferred. For this reason, electrodiagnostic testing can be done to establish the extent of disease and those muscle groups affected before any transfer is attempted, even in the setting of a "normal" physical exam. If a soft tissue procedure will not provide the necessary support or stability, or if a fixed deformity is noted, a joint arthrodesis will be required.<sup>5</sup>

**Table 1**

### MUSCLE IMBALANCE AND THEIR RESULTING DEFORMITY

Muscle paralysis	Deformity
Tibialis Anterior	Equino-Cavo-Varus Drop-Foot +/- Planovalgus
Tibialis Posterior	Rearfoot and Forefoot Eversion
Tibialis Anterior and Posterior	Rearfoot and Forefoot Equinovalgus
Peroneal	Rearfoot Varus Forefoot Adduction Dorsal Bunion
Peroneals and Extensors	Mild Equinovarus
Tibialis Anterior and Peroneal and Extensors	Severe Equinovarus
Triceps	Cavus



Table 2

### DEFORMITY WITH THEIR SUGGESTED TENDON TRANSFER PROCEDURE

Deformity	Tendon transfer procedure
Clawtoes/ Hallux malleus	EHL lengthening PIPJ arthrodesis Hibbs and Jones tenosuspension
Dorsal Bunion	Jones tenosuspension Tibialis anterior transfer to the 2nd metatarsal STATT
Dropfoot	EHL transfer to navicular Peroneus longus transfer to 2nd metatarsal Tibialis posterior transfer through interosseus membrane
Equino-Cavo-Varus	Tibialis anterior transfer to middle cuneiform EDL transfer to lateral cuneiform Hibbs and Jones tenosuspension Tibialis posterior transfer through interosseus membrane to middle cuneiform Tendo Achilles lengthening Plantar fasciotomy with Steindler stripping Posterior capsule release
Calcaneal cavus	Tibialis anterior or tibialis posterior transfer posteriorly into the calcaneus Peroneus longus transfer to the calcaneus
Rearfoot/ forefoot valgus	FDL or FHL transfer to tibialis posterior Equino valgus Peroneus brevis or peroneus longus transfer to base 2nd metatarsal Talonavicular arthrodesis
Any fixed deformity	Arthrodesis of isolated or multiple joints

Isolated muscles may be paralyzed in patients with poliomyelitis, but more often combinations of muscles are affected. The specific muscle or muscles involved and the resulting muscle imbalance should be determined before treatment is started. (Table 1). The exact pattern of muscle paralysis and specific deformity that occurs must also be carefully determined before any surgical intervention is undertaken. An in-depth discussion of tendon transfers is beyond the scope of this paper, however to achieve a successful tendon transfer a plantigrade foot must be present before the tendon transfer. This can be created by performing a tendon lengthening (e.g. Achilles tendon), release of a joint contracture, or if necessary, a joint arthrodesis. Another principle that should be considered when contemplating a tendon transfer is that a transferred muscle usually loses one grade of muscle strength; therefore, if the muscle strength is only good to fair, the transfer may not be successful.

Tibialis anterior muscle weakness or paralysis results in the loss of dorsiflexion and inversion power of the foot; therefore, it produces a slowly progressive deformity of equinus, dropfoot and cavus or varying degrees of planovalgus that is first evident in the swing phase of gait. Compensation by extensors for dorsiflexion causes hyperextension of the proximal phalanges and depression of the metatarsal heads. A cavovarus deformity occasionally results from the unopposed activity of the peroneus longus combined with an active tibialis posterior muscle. Therefore the treatment is dependent on the deformity and the treatment options consist of the following (Table 2); posterior tibial transfer through the interosseous membrane, extensor digitorum longus transfer to the second or third cuneiform, jones tenosuspension with a Hibbs tenosuspension, peroneus longus transfer to the second metatarsal base, plantar fasciotomy with Steindler stripping, correction of clawtoes with

arthrodesis of the PIPJ, arthrodesis of any rearfoot joint, release of soft tissue contractures (usually a tendo-Achilles lengthening and posterior capsule release). These can be performed as an isolated procedure or combination as indicated by the level of pathology.

Asirvatham et al<sup>10</sup> published a report using an extensor hallucis longus coaptation to the tibialis anterior to correct drop foot deformity in eight post-polio patients. Early results were promising, as all eight patients had improved ankle dorsiflexion; however, long-term follow-up revealed that 75% had lost the ability to actively dorsiflex the ankle against gravity. They concluded that coaptation alone was insufficient to give long-term support and recommended EHL transfer to the navicular, possibly with other procedures as warranted.

Tibialis posterior muscle paralysis is rare but can result in hind foot and forefoot eversion. A flexor digitorum longus or flexor hallucis longus transfer is usually done, similar to repair for a posterior tibial tendon dysfunction. A tendo-Achilles lengthening is also commonly performed.

When both the tibialis anterior and posterior muscle are paralyzed, the development of hindfoot and forefoot equino-valgus is more rapid and the deformity becomes fixed as the tendo-calcaneus and peroneal muscles shorten. A review of the recent literature revealed a small amount of published reports for the specific correction of post-polio deformities using tendon-balancing procedures. Faraj<sup>11</sup> reported on a case of paralytic valgus deformity resulting from weakness of the anterior and posterior tibial muscles secondary to polio where the initial treatment was a transfer of the peroneus brevis tendon to the base of the second metatarsal. (If the peroneal muscles are normal, the peroneus longus is transferred to the base of the second metatarsal, because of its longer excursion). This had been performed in an attempt to restore inversion and dorsiflexion strength to the foot. This was unsuccessful and resulted in a laterally deviated forefoot. A talonavicular arthrodesis was performed in an attempt to stabilize and correct the midtarsal joint deviation. This case illustrates the need to accurately assess the amount of initial deformity. Without the tibialis posterior to help support or brace the foot in inversion, the peroneus brevis acted solely as an evertor of the forefoot accentuating the lateral dislocation at the midtarsal joint.

Tibialis anterior, toe extensor, and peroneal muscle weakness results in progressively severe equinovarus deformity due to the tibialis posterior and triceps surae being unopposed. Anterior transfer of the tibialis posterior to the base of the third metatarsal or middle cuneiform can be supplemented by anterior transfer of the long toe flexors. This is done through the interosseous membrane. A tendo-Achilles lengthening is almost always indicated.

Isolated peroneal muscle weakness is rare in patients with poliomyelitis but can cause severe hindfoot varus deformity because of the unopposed activity of the tibialis posterior muscle. The calcaneus becomes inverted, the forefoot is adducted, and the varus deformity is increased by the action of the invertor muscles during gait. The unopposed tibialis anterior activity can cause a dorsal bunion. In this situation, the tibialis anterior can be transferred laterally to the second metatarsal base. Jones tenosuspension is performed usually to prevent contracture of the hallux that is common after a tibialis anterior tendon transfer. Likewise, a split tibialis anterior tendon transfer can be performed instead.

In another report from Faraj,<sup>12</sup> a Jones tenosuspension procedure was performed on post-polio patients with an increasing claw hallux deformity. His prospective study was performed on 12 patients with a mean follow-up of three years. Ten patients had good results with two patients having recurrence of deformity that was treated with a combined EHL and tendo Achilles lengthening (TAL). His conclusion was that an equinus contracture of the Achilles tendon, which was present in both of the fair results, led to the recurrence of deformity. Subsequently, he recommended identification of any equinus deformity prior to any surgical correction, and if present, performing a simultaneous TAL in order to ensure success of any other transfer.

Peroneal and long toe extensor muscle paralysis causes a less severe equinovarus deformity that can be treated by transfer of the tibialis anterior to the base of the third metatarsal or the middle cuneiform.

A triceps surae muscle paralysis causes a rapidly progressive cavus deformity. Compensation by the plantarflexors results in a cavus deformity. Depending on the muscle function present, posterior transfer of the tibialis anterior tendon

through the interosseous septum into the calcaneus or posterior transfer of the peroneus longus or posterior tibial tendon transfer is done. If possible, a phasic transfer is more desirable, although the anterior tibial tendon has been shown to undergo phase conversion and function as a plantar flexor during gait. Plantar fasciotomy and intrinsic muscle release are required before tendon transfer in fixed forefoot cavus deformity.

As these reports show, it is important to perform a thorough evaluation prior to any attempted muscle transfer. Additionally, it is important to recognize any other musculoskeletal deformities that could adversely affect the outcome and formulate the surgical plan accordingly. Finally, one must recognize that arthrodesis might be necessary, either initially in order to provide for optimum joint stability, or in the future, if the tendon transfer has not provided long term success.

### Conclusion

Post-polio syndrome is a neuromuscular disease entity associated with symptoms of weakness, fatigue, and muscle and joint pain. Diagnosis is made difficult by the large number of differentials, which must be excluded. Because it is not a rare pathology, the podiatric physician must be diligent and recognize the PPS patient. Treatment is largely based on conservative measures including physical therapy, orthoses and lifestyle changes. If surgical correction is necessary, a thorough physical examination and appropriate testing need to be performed. There is a scarcity of published literature regarding PPS and tendon transfers. Although there are case reports and small studies published, no large trial assessing the success of tendon transfer exists. The vast majority of recent literature regarding PPS deals with its identification, etiology, and basic treatment. Physical therapy and

conservative treatment play a large role in the rehabilitation of the PPS patient and as such have dominated in regard to published literature. It is obvious that studies determining the effectiveness of tendon transfer in the PPS are needed. Although tendon transfer have been used in conditions similar to PPS for identical reasons, it would be helpful to surgeons to have more than anecdotal evidence for the support of such procedures.

### References

1. Canale ST. Campbell's Operative Orthopaedics, 9th ed., Nervous System, Paralytic Disorders, pp. 3972-3994. Mosby-Year Book, St. Louis, MO, 1998.
2. Gawne A, Halstead L. Post-Polio syndrome: pathophysiology and clinical management. *Clin Rev Phys Rehab Med* 1995;7:147-88.
3. Jubelt B, Agre J. Characteristics and management of postpolio syndrome. *JAMA*. 2000;284:412-4.
4. Nordgren B. Postpolio muscular dysfunction: relationships between muscle energy metabolism, subjective symptoms, magnetic resonance imaging, electromyography, and muscle strength. *Muscle Nerve* 1997;20:1341-51.
5. Perry J, Barnes G, Gronley J. The Postpolio syndrome: an overuse phenomenon. *Clin Orthop* 1988;233:145-62.
6. Tillett S, Monzena J. The reappearance of polio: postpolio syndrome. *J Am Podiatric Med Assoc* 1999;89:183-7.
7. Hurmuzlu Y, Basdogan C, Stoinovici D. Kinematics and dynamic stability of the locomotion of post-polio patients. *J Biomech Eng* 1996;118:405-11.
8. Klein M, Whyte J, Keenan M, Esquenazi A, Polansky M. Changes in Strength Over Time Among Polio Survivors. *Arch Phys Med Rehab*. 2000; 81:1059-1064.
9. Perry J, Mulroy S, Renwick S. The Relationship of lower extremity strength and gait parameters in patients with post-polio syndrome. *Arch Phys Med Rehab* 1993;74:165-9.
10. Asirvatham R, Watts H, Gillies H. Extensor Hallucis Longus coaptation to tibialis anterior: a treatment for paralytic drop foot. *Foot Ankle Int* 1993;14:343-6
11. Faraj A. Talonavicular joint arthrodesis for paralytic post poliomyelitis forefoot instability. *J Foot Ankle Surg* 1996;35:166-8
12. Faraj A. Modified jones procedure for post-polio claw hallux deformity. *J Foot Ankle Surg* 1997;36:356-9.

### Additional References

- Mulder DW, et al. Late progression of poliomyelitis or forme fruste amyotrophic lateral sclerosis. *Mayo Clin Proc* 1972; 47:756-61.
- Trojan DA, Cashman NR. An open trial of Pyridostigmine in Post-Poliomyelitis syndrome. *Can J Neurol Sci* 1995;22:223-7.