

REDUCTION OF LISFRANC DISLOCATIONS USING SECOND RAY AXIAL TRACTION

Charles C. Southerland, Jr., DPM

Caroline E. Smith, DPM

Thomas J. Merrill, DPM

INTRODUCTION

Lisfranc fracture dislocations are an often misdiagnosed injury pattern, which if left unreduced can lead to significant disability (1-5). The articulation between the bases of the 5 metatarsals, cuneiforms, and cuboid has been termed the Lisfranc joint (6, 7). Lisfranc joint represents a junction between the forefoot and the midfoot. Three functional columns make up the tarsometatarsal area, the medial, middle, and lateral columns. The base of the first metatarsal articulates with the medial cuneiform to make up a medial column (8). The middle column is composed of an articulation between the second metatarsal and intermediate cuneiform, as well as the third metatarsal and the lateral cuneiform (7). Finally the fourth and fifth metatarsals articulate with the cuboid to form a lateral column (7). The base of the second metatarsal sits in a recessed area between the medial and lateral cuneiforms forming a mortise or “keystone” of the tarsometatarsal joints (9). Due to this configuration, the base of the second metatarsal is wedged between the base of the first and third metatarsals and is thus only capable of roughly 0.6 mm of sagittal plane or transverse plane motion. It is this joint and an associated thick interosseous ligament spanning from the medial side of the base of the second metatarsal to the medial cuneiform, which is specifically known as “Lisfranc joint/ligament.”

The Lisfranc joint is a key point of articulation in the midfoot. Since there is no proximal transverse ligament spanning between the first and second metatarsals, Lisfranc joint is the weakest or least structurally reinforced of the tarsometatarsal joints (8). According to Peicha et al the anatomy of this second metatarsocuneiform “keystone” or mortise created by the second metatarsal base becomes a risk factor for dislocation injuries, enhanced by the depth of the mortise. In research done by Peicha et al, it was found that the majority of patients with a dislocation injury had a very shallow mortise when compared to those with a deeper mortise.

The Lisfranc complex was named after Jacques Lisfranc (1790-1847), a French surgeon who served in the Napoleonic Army (10, 11). Lisfranc saw the majority of these injuries in soldiers whose feet would become caught in their riding stirrup while falling from their horses. It

is related that Dr. Lisfranc often treated these injuries by amputating the forefoot at the tarsometatarsal joint. This level of amputation became known as a Lisfranc amputation. Today the Lisfranc fracture accounts for about 0.2% of all reported fractures (12-15). However, this number may be underestimated due to frequent misdiagnosis. According to well established research, about 20% of these injuries are commonly misdiagnosed (16).

METHODS OF DIAGNOSIS

Diagnosis often begins with a thorough history of the injury, physical examination, and plain films (17). Initial physical examination findings reveal tenderness, erythema, and swelling about the midfoot as well as plantar ecchymosis. However, these findings alone are not exclusively indicative of a Lisfranc injury. Physical examination will reveal tenderness upon palpation of the tarsometatarsal joints and passive abduction and pronation of the forefoot will also produce pain in the tarsometatarsal joints if there is a Lisfranc injury present. The “Piano Key” test may also prove to be a helpful diagnostic tool. When performing the Piano Key test, the midfoot and rearfoot are stabilized and each metatarsal head is individually plantar flexed; a positive test reveals focal pain at the base of the involved metatarsal(s).

Other possible signs to look for include an absence of the dorsalis pedis pulse and a shorter and/or wider appearing foot. Anteroposterior (AP), medial oblique (MO), and lateral radiographs should be examined (18). Slight widening in the joint space between the second metatarsal bases and the medial cuneiform should draw suspicion to the area and bilateral films may need to be taken for comparison. This widening of the joint space was referred to by Davies and Saxby as the “gap space” (9). As mentioned previously, about 20% of cases are missed on the initial radiographic reading. Myerson described a fleck sign (avulsed fragment), which can sometimes be seen on an AP or MO radiographic, this is indicative of a ligamentous injury and probable joint disruption (2, 8).

When evaluating a plain film there are two areas of alignment that should be evaluated. First, observe for alignment of the medial side of the second metatarsal base with the medial side of the intermediate cuneiform. Second,

ascertain that the medial aspect of the base of the fourth metatarsal is in line with the medial side of the cuboid. If plain films fail to demonstrate signs of a Lisfranc injury, yet clinical signs are positive, a computed tomography (CT) image or magnetic resonance image (MRI) should be ordered (19). MRIs are good in evaluating ligamentous injuries and edema and may be useful in distinguishing between acute and chronic Lisfranc injuries (20). CT films are optimal, particularly if they can be reconstructed into a small cut (<0.5 mm) three-dimensional imaging with axial rotation (Figure 1).

CLASSIFICATION

Mechanism of injury can be grossly categorized into direct or indirect type injuries (21). Direct injuries result from external forces acting upon the foot; such as might be the case with crush injuries or motor vehicle accidents. Direct injuries usually produce a dorsal or plantar direction of dislocation. Indirect injuries result from a force being applied to a stationary foot in a way that causes the weight of the body to act as the deforming force (22). In 1909, Quenu and Kuss divided the injuries into three groups: 1) Homolateral displacement is present when all rays are displaced in the same direction; 2) Isolated displacement is when the first ray and/or the second ray are displaced while the lateral three rays remain in place; 3) Divergent displacement is when the first ray is displaced medially and the lateral rays displaced laterally (Figure 2).

Hardcastle expanded on the Quenu and Kuss system by describing each type of displacement in such a way that a treatment plan could be formulated. The Hardcastle system divides injury patterns into three alphanumeric indicators, types A, B and C with subtypes indicated by numeric specifiers. The type A injury pattern is a single pattern designator, represented as total displacements resulting in a complete incongruity of the tarso-metatarso joint (TMJ) complex. Displacement typically occurs in the transverse plane with the forward segment of the foot moving in a lateral direction relative to the rearfoot. In order for all 5 metatarsophalangeal joints to be affected in this homolateral displacement, there must be sagittal and coronal plane disruptions of the tarso-metatarso interface.

Type B is partial displacement in which only a portion of the joint is displaced. In a B-1 injury, there is medial displacement of the first metatarsal. In a B-2 there is lateral displacement of one or more of the lateral 4 metatarsals, while the first ray is left undisrupted (note that this "B" classification pattern is more specific than the original Quenu and Kuss "isolated" fracture classification).

Type C is a divergent displacement, which may demonstrate partial or total incongruity. C-1 presents with a total medial dislocation of the first metatarsal and partial

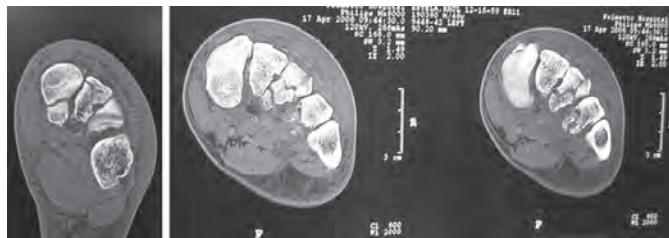


Figure 1. Computed axial tomographic scans of Lisfranc fractures missed on plain films.

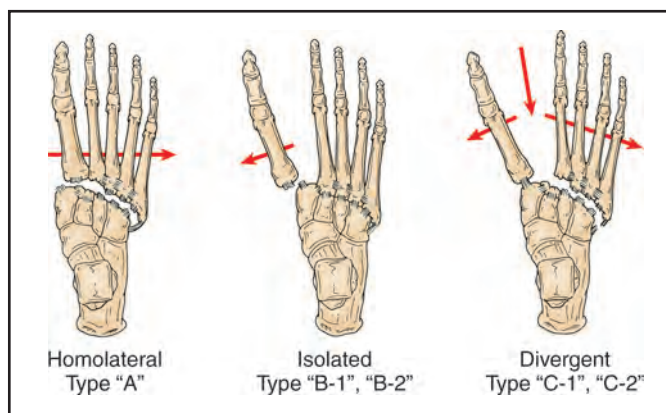


Figure 2. Lisfranc fracture dislocation patterns of injury.

lateral dislocation of some of the lesser metatarsals. C-2 presents with total medial dislocation of the first metatarsal as well as total lateral dislocation of all the lesser metatarsals (once again much more specific in its description than the Quenu and Kuss divergent descriptor). The Hardcastle classification system is the preferred system used today for Lisfranc injury definition and surgical planning (7).

Lisfranc fracture/dislocations must be reduced to restore correct anatomical alignment. Failure to obtain an anatomical reduction is the most common reason for unsatisfactory outcomes. There are various methods of reduction used to realign the tarsometatarsal joints such as closed reduction using longitudinal distraction, and open reduction using a reduction clamp.

A traditional and reportedly successful method of closed reduction and percutaneous pinning is a method that employs Chinese finger traps to provide longitudinal distraction to the involved metatarsals. Once the Chinese finger traps have restored alignment, Kirschner wires (K-wires) are inserted percutaneously to maintain the correction. Open reduction using a reduction clamp is often employed during open reduction internal fixation (ORIF) procedures (23). After anatomical dissection has been achieved and the fracture/dislocation has been delivered to the wound site, a bone clamp is used to reduce the deformity and allow for either pinning with K-wires or screw fixation. While this is an effective method of reduction it can be difficult to maneuver around reduction clamps.

METHODS/ RESULTS

A method for axial tension reduction has been developed by one of the authors, using a technique of reducing Lisfranc dislocations that employs the use of a Steinmann pin and a 3 inch or 4 inch roll of the dressing material, Kling or Kerlix. When using this technique a $7/64$ ths (2.8 mm) or $3/32$ nds (2.4 mm) Steinmann pin is driven through some point of intact shaft located along the proximal two-thirds of the second metatarsal from the dorsum of the foot, exiting through the plantar aspect of the foot, so that the wire is protruding both dorsally and plantarly (Figures 3,4,5). An unwrapped roll of Kling or Kerlix dressing is used to create distraction across the pin site depending on the type of injury pattern. The direction that the Kling or Kerlix is wrapped around the foot is dependent upon the direction of dislocation. Thus, if there is lateral displacement of the foot, the Kling or Kerlix is placed proximal to the Steinmann pin and wrapped laterally from the dorsum of the foot to the plantar surface of the foot. The two free ends of the Kling or Kerlix are then pulled anteriorly along the medial sides of the Steinmann pin, creating a lateral reduction force on the injury (Figures 3, 4, 5). The free ends of the Kling or Kerlix are placed under traction, while a gentle, constant pressure is applied to the lateral side of the foot at the same time that the second metatarsal is being distracted under traction. This allows for proper anatomical reduction of the fracture dislocation. The Kling or Kerlix wrap is reversed when there is medial displacement. The Steinmann pin is driven through the proximal two-thirds of the second metatarsal from the dorsum of the foot, exiting from the plantar surface of the foot. This placement is used with virtually any Lisfranc injury pattern.

In a type B-1 injury, the Kling or Kerlix is placed proximal to the Steinmann pin and then wrapped medially around the foot, with free ends of the Kling or Kerlix passing around the lateral side of the Steinmann pin. Just as with the lateral displacement, the free ends of the Kling or Kerlix are pulled anteriorly to provide simultaneous distraction of the second metatarsal and gentle, constant compression placed against the medial side of the foot over the base of the first metatarsal. In the event of a C-type injury, in which there is both medial and lateral displacement, two Kling or Kerlix rolls are used, one medially, the other laterally. Both Kling or Kerlix rolls will transit from proximal to the Steinmann pin. One will be passed laterally around the foot and the other will be passed medially around the foot (Figures 3, 4, 5). The free ends of the Kling or Kerlix that were passed laterally should exit around the medial side of the Steinmann pin, as the medially passed Kling or Kerlix's free ends should exit around the lateral side of the pin. The

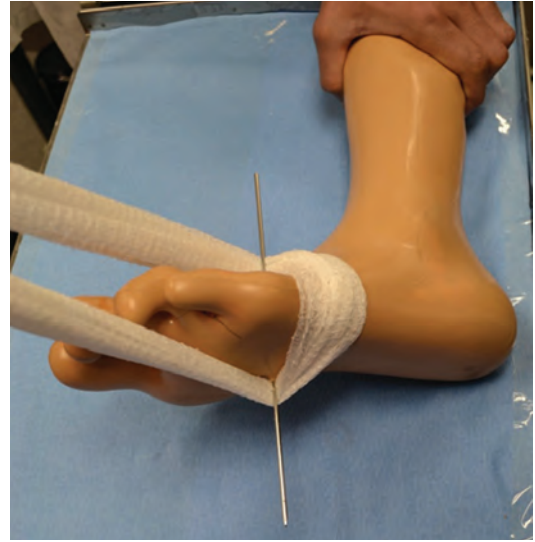

Figure 3. Lateral displacement.

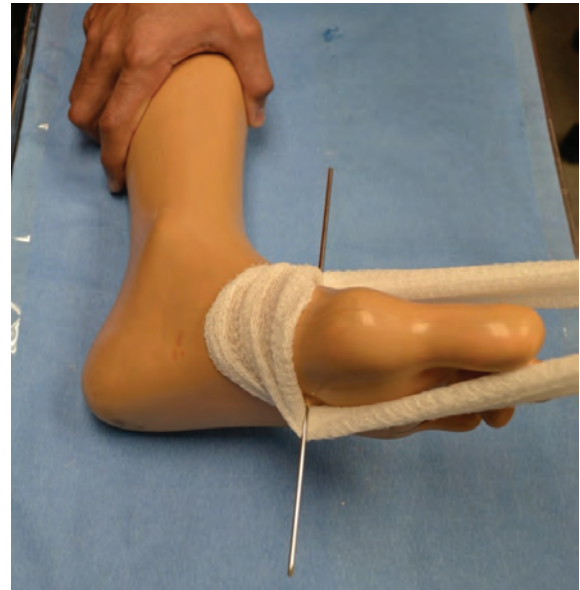

Figure 4. Medial displacement.

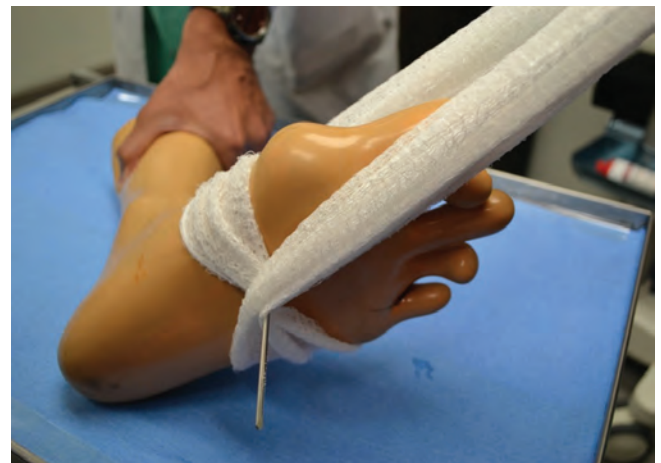

Figure 5. Divergent displacement.

free ends of both Kling or Kerlix's are placed under anterior traction, providing simultaneous distraction of the second metatarsal and gentle, constant compression on both the medial and lateral sides. This "Kling or Kerlix wrap around Steinmann Pin" technique is capable of very effectively reducing virtually any pattern of Lisfranc injury.

Once reduced, the reduction can be secured with either percutaneous or open reduction at the discretion of the surgeon. There is mention in the literature of performing a similar reduction method with percutaneous clamping, using a large reduction forceps (21). We found the forceps method to produce significant soft tissue damage. The axial traction method limits soft tissue damage by maintaining traction within the endoskeleton. If performed correctly, there is relatively little soft tissue tension produced by the Steinman pin. This leaves only small dorsal and plantar puncture wounds.

Between 2000 and 2008 (with 5-year follow up to 2013), this technique was used on 12 focus cases, and contrasted with 38 cases, using other forms of reduction during the same period (Figures 6, 7). Five of the 12 focus cases involved the left foot while the remaining 7 of 12 focus cases involved the right foot. There were no bilateral cases in this series. The patients range in age from 19 to 75-years-old. There were 2 females and 10 males. Two of the cases were type A, 4 of the cases were type B-1, 3 of the cases were type B-2, 2 of the cases were type C-2, and 1 of the cases was a type C-1. In all of these cases this technique, dubbed "axial traction technique" was used to reduce the Lisfranc dislocations. Once anatomical alignment was achieved, the Kling or Kerlix was held in place until permanent fixation could be achieved, either percutaneously or with open placement of screws/plates. Though the method of permanent fixation varied in each of the 12 focus cases, the method of reduction was constant.

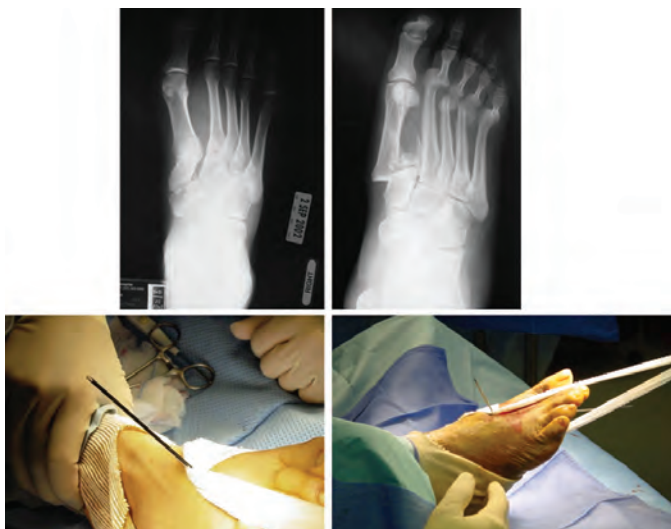

Figure 6. B-1 type medially divergent fracture patterns.

All 12 cases had favorable long term outcomes, based on subsequent patient contact and subjective response to the Foot and Ankle Disability Index (FADI) scoring system (24). The 12 cases using the Axial Traction technique were performed by a single surgeon. The 38 patients, which were not subjected the axial tension technique, had Lisfranc fracture dislocations reduced by common methods among 4 different surgeons. The overall extrapolated FADI scores for those nonaxial traction reduction patients was ~80.8. The overall FADI score for those undergoing the axial tension technique in this series was ~89.6.

DISCUSSION

Lisfranc injuries can be very difficult to diagnose and to reduce. Correct anatomic alignment is crucial to the outcome of the injury. A misaligned Lisfranc joint can cause years of chronic pain and arthritis, which could eventually lead to a fusion of the entire joint complex. The axial traction technique for Lisfranc dislocation reduction focuses on reducing the dislocation using the second metatarsal as an axial tension strut. Because the second metatarso-cuneiform articulation is the keystone of Lisfranc joint, it plays a crucial role in successful reduction. The second metatarsal forms a mortise by sitting in a recessed slot between the medial and lateral cuneiform. By restoring a proper alignment of the keystone, other areas of dislocation tend to drift back in to anatomic alignment with little more than a side-to-side squeeze of the midfoot.

This axial traction technique also has many advantages over using a reduction clamp. Kling or Kerlix rolls are easily retracted out of the way to allow for a better field of view as compared to a bone reduction clamp, which can occlude the operative site and make K-wire and screw placement more challenging. Also, use of a reduction clamp can put

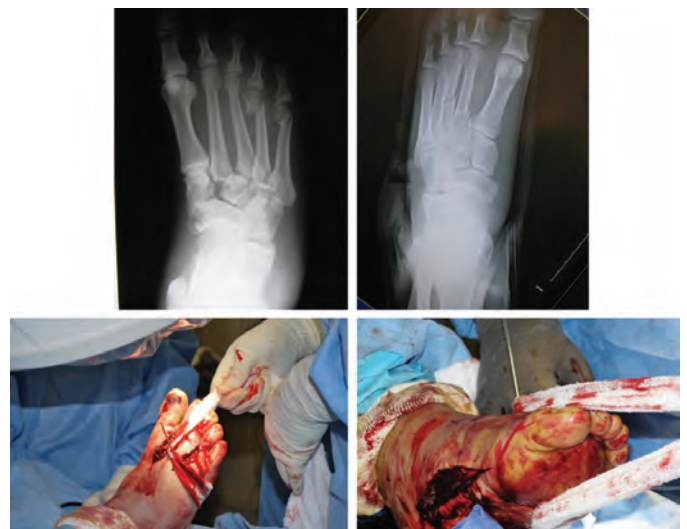

Figure 7. B-2 type laterally divergent type fracture patterns (with compartment syndrome).

unwanted stress on soft tissue surrounding the operative site. This is not so much a concern when using a soft roll Kling or Kerlix, which will not damage surrounding soft tissue. The axial traction technique can be used for both ORIF and for closed reduction with percutaneous pinning. It is a relatively safe, easy and very effective method of reducing a Lisfranc fracture-dislocation.

SUMMARY

The Lisfranc joint is composed of articulations between the bases of the 5 metatarsals, cuneiforms and cuboid joints (4 and 8). The keystone of the Lisfranc joint is formed by the recessed base of the second metatarsal. An incompletely reduced, shallow Lisfranc mortise puts a patient at higher risk for further dislocation and arthritis. Diagnosis should be based on a thorough history of the injury, clinical signs and symptoms, radiographs, and CT scans. If plain films fail to reveal an injury to Lisfranc joint, but clinical signs and symptoms warrant, as well as the history of the injury, collectively provide a reasonable suspicion, either CT (preferred) or MRI imaging should be ordered.

Lisfranc injuries may be classified using the Hardcastle classification system, which is helpful when planning surgical correction and offering long term prognoses (higher the injury classification, the poorer the prognoses). The key to any good surgical correction is proper anatomic restoration of alignment about the second ray. Without proper alignment, the injury is likely to result in a poor prognosis. When selecting a method to reduce the dislocation, one should choose a method that is easy and effective. The axial traction technique is an easy to use method that employs a 7/64 or 3/32 Steinmann pin and Kling or Kerlix.

The axial traction technique focuses on using longitudinal distraction of the second metatarsal to restore the keystone of the Lisfranc joint complex. Although complications were not encountered in this series, there might logically be a potential for fracturing the second metatarsal shaft if the shaft is particularly thin or if the Steinmann pin is offset or placed in the thinnest part of the metatarsal shaft. This is why it is important to use intraoperative fluoroscopy. It is best to use a portion of the proximal shaft that is wide enough to accommodate the pin and hold against distraction traction forces. With proper anatomical realignment of the joint, fixation outcomes are more predictable, and offer improved prognoses.

Acknowledgment: Special thanks to Michael Anderson, James Averett, Paul Fawson, and Benjamin Lewis for their presentation of this topic as a Student Poster exhibit at the APMA National Meeting, 2012.

REFERENCES

1. Pergia D, Basile A, Battaglia A, Stopponi M. Fracture dislocations of Lisfranc joint treated with closed reduction and percutaneous fixation. *Int Orthop* 2003;27:30-5.
2. Myerson MS, Fisher Rt, Burgess AR, Kenzora JE. Fracture dislocations of tarsometatarsal joints: end results correlated with pathology and treatment. *Foot Ankle* 1986;6:225-42.
3. Juo RM, Tejwani N, DiGiovanni C, et al. Outcome after open reduction and internal fixation of Lisfranc joint injuries. *J Bone Joint Surg Am* 2000;82:1609-18.
4. Richter M, Wippermann B, Krettek C. Fractures and fracture dislocations of the midfoot: occurrence, causes, and long-term results. *Foot Ankle Int* 2001;22:392-89.
5. Calder J, Whitehouse S, Saxby T. Results of isolated Lisfranc injuries and the effect of compensation claims. *J Bone Joint Surg Br* 2004;86:527-30.
6. Desmond E, Chou L. Current concepts review: Lisfranc injuries. *Foot Ankle Int* 2006;27:653-60.
7. Hardcastle PH, Reschauer R, Kutscha-Lissberg E, Schoffmann W. Injuries to the tarsometatarsal joint: incidence, classification and Treatment. *J Bone Joint Surg Br* 1982;64:349-56.
8. Myerson M. The diagnosis and treatment of injuries to the Lisfranc joint complex. *Orthop Clin North Am* 1999;20:655-64.
9. Davis E. Lisfranc joint injuries. *Trauma* 2006;8:225-31.
10. Buchholz RW, Early JS. Lisfranc injuries and their management. *Curr Orthop* 1996;10: 169-73.
11. Ly T, Coetzee J. Treatment of primarily ligamentous Lisfranc joint injuries: primary arthodesis compared with open reduction and internal fixation. *J Bone Joint Surg Am* 2006;88:514-20.
12. Englanoff G, Auglin D, Huston HR. Lisfranc fracture dislocation: a frequently missed diagnosis in the emergency department. *Ann Emerg Med* 1995;26:229-33.
13. Lee C, Birkedal J, Dickerson E, Vieta J, Webb L, Teasdall J. Stabilization of Lisfranc joint injuries: a biomechanical study. *Foot Ankle Int* 2004;25:365-70.
14. Makwana N. Tarsometatarsal injuries-Lisfranc injuries. *Curr Orthop* 2005;19:108-18.
15. Richter M, Thermann H, Huefner T, Schmidt U, Krettek C. Aetiology treatment and outcome in Lisfranc joint dislocation and fracture dislocation. *J Foot Ankle Surg* 2002;8: 21-32.
16. Dudko S, Kusz D, Pierzchaa A. Lisfranc injury-fixation with Kirschner wires. *J Foot Ankle Surg* 2003;10:5-8.
17. Keiserman I, Cassandra J, Amis J. The piano key test: a clinical sign for the indication of subtle tarsometatarsal pathology. *Foot Ankle Int* 2003;24:437-8.
18. Lattermann C, Goldstein J, Wukich D, Lee S, Bach B. Practice management of Lisfranc injuries in athletes. *Clin J Sports Med* 2007;17:311-5.
19. Kendrick B, Von Arx O, Deo D. Medial and middle cuneiform diastasis. a case report. *J Foot Ankle Surg* 2005;11:167-9.
20. Gillespei P, Robertson A, George B, Nihal A. Acute Lisfranc joint disruption in a ballet dancer. *J Foot Ankle Surg* 2005;11:105-8.
21. Abicht BP, Plovanih EJ, Roukis TS. A novel approach to treating Lisfranc fractures. *Podiatry Today* 2011; p 48-52
22. Peicha G, Labovitz J, Seibert F, Grechenig W, Weiglein A, Preidler K, et al. The anatomy of the joint as a risk factor for Lisfranc dislocation and fracture-dislocation. *J Bone Joint Surg* 2002; 84:981-5.
23. Kinki H, Erdemli B, Gurkan I, Arikan M, Mergen E. Surgical management of Lisfranc injuries. *J Foot Ankle Surg* 1999;5:105-8.
24. Martin RL, Burdett RG, Irrgang JJ. Development of the Foot and Ankle Disability Index (FADI) *J Orthop Sports Phys Ther* 1999;29:32-3.